Get Full Access and More at ExpertConsult.com

Diagnostic Imaging
Brain

THIRD EDITION

Osborn | Salzman | Jhaveri

AMIRSYS®
ELSEVIER

https://CafePezeshki.IR

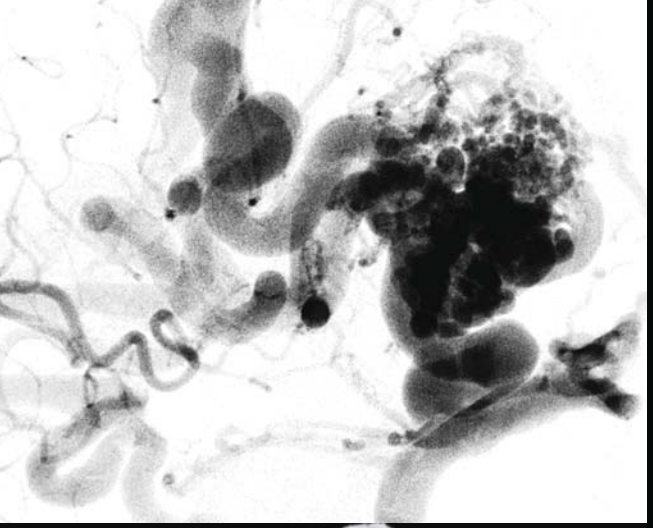

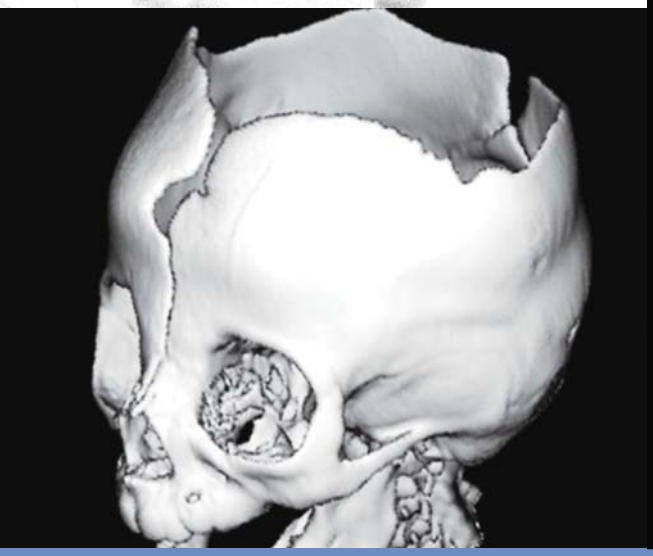

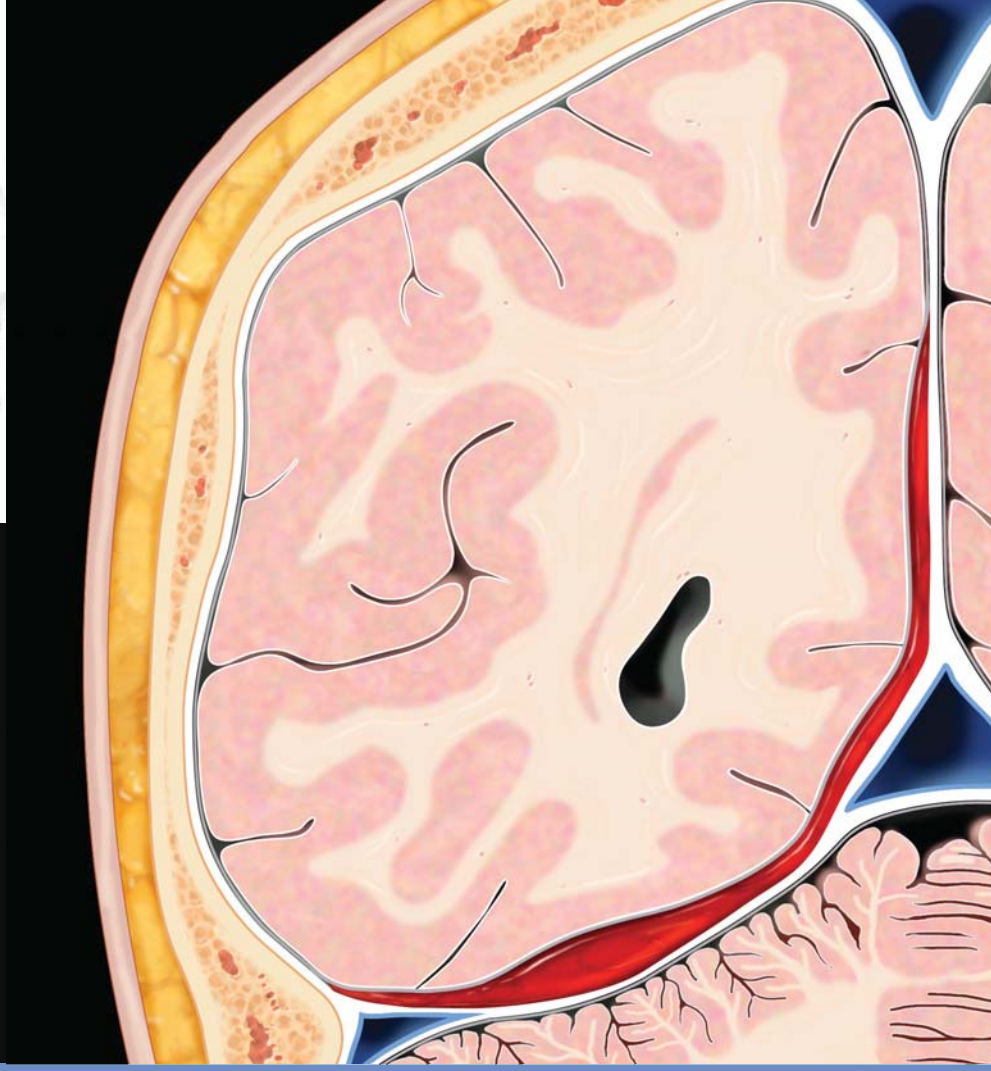

Diagnostic Imaging

Brain

THIRD EDITION

https://CafePezeshki.IR

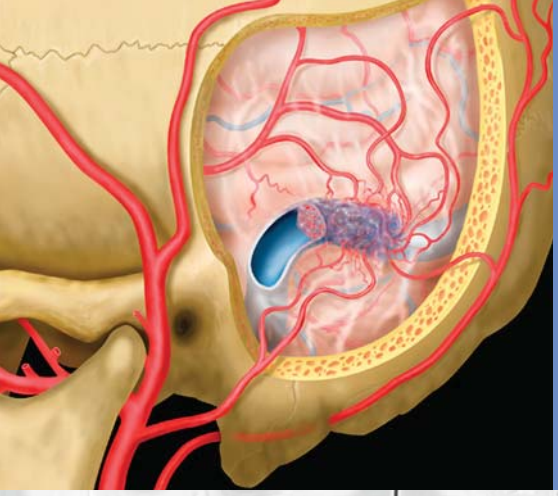

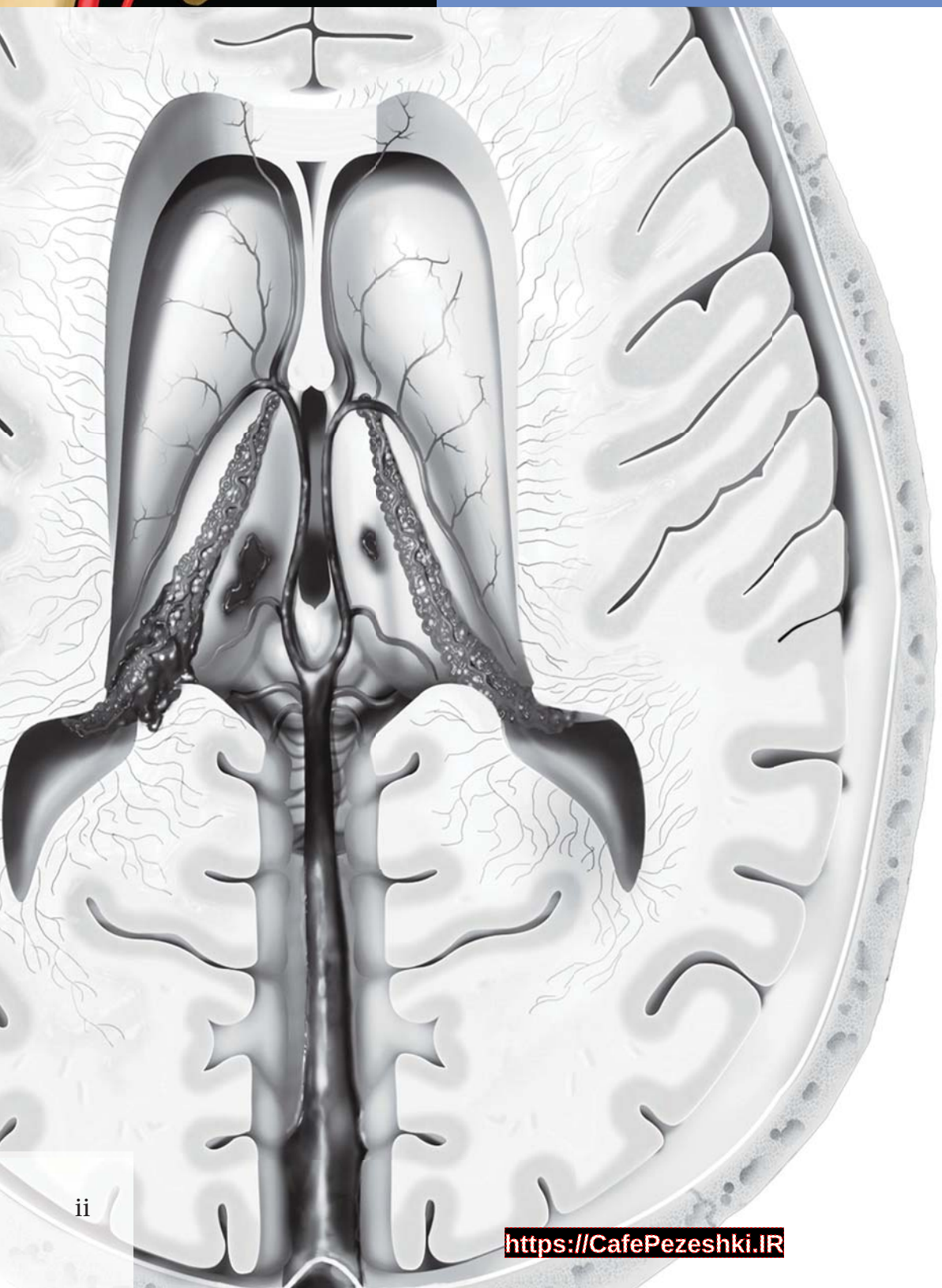

https://CafePezeshki.IR

Diagnostic Imaging

Brain

THIRD EDITION

Anne G. Osborn, MD, FACR
University Distinguished Professor
William H. and Patricia W. Child Presidential Endowed Chair
University of Utah School of Medicine
Salt Lake City, Utah

Karen L. Salzman, MD
Professor of Radiology
Leslie W. Davis Endowed Chair in Neuroradiology
University of Utah School of Medicine
Salt Lake City, Utah

Miral D. Jhaveri, MD
Associate Professor
Division Head, Neuroradiology
Department of Diagnostic Radiology and Nuclear Medicine
Rush University Medical Center
Chicago, Illinois

https://CafePezeshki.IR

ELSEVIER

1600 John F. Kennedy Blvd.
Ste 1800
Philadelphia, PA 19103-2899

DIAGNOSTIC IMAGING: BRAIN, THIRD EDITION ISBN: 978-0-323-37754-6

Copyright © 2016 by Elsevier. All rights reserved.

No part of this publication may be reproduced or transmitted in any form or by any means, electronic or mechanical, including photocopying, recording, or any information storage and retrieval system, without permission in writing from the publisher. Details on how to seek permission, further information about the Publisher's permissions policies and our arrangements with organizations such as the Copyright Clearance Center and the Copyright Licensing Agency, can be found at our website: www.elsevier.com/permissions.

This book and the individual contributions contained in it are protected under copyright by the Publisher (other than as may be noted herein).

Notices

Knowledge and best practice in this field are constantly changing. As new research and experience broaden our understanding, changes in research methods, professional practices, or medical treatment may become necessary.

Practitioners and researchers must always rely on their own experience and knowledge in evaluating and using any information, methods, compounds, or experiments described herein. In using such information or methods they should be mindful of their own safety and the safety of others, including parties for whom they have a professional responsibility.

With respect to any drug or pharmaceutical products identified, readers are advised to check the most current information provided (i) on procedures featured or (ii) by the manufacturer of each product to be administered, to verify the recommended dose or formula, the method and duration of administration, and contraindications. It is the responsibility of practitioners, relying on their own experience and knowledge of their patients, to make diagnoses, to determine dosages and the best treatment for each individual patient, and to take all appropriate safety precautions.

To the fullest extent of the law, neither the Publisher nor the authors, contributors, or editors, assume any liability for any injury and/or damage to persons or property as a matter of products liability, negligence or otherwise, or from any use or operation of any methods, products, instructions, or ideas contained in the material herein.

Publisher Cataloging-in-Publication Data

Diagnostic imaging. Brain / [edited by] Anne G. Osborn, Karen L. Salzman, and Miral D. Jhaveri.
3rd edition.
pages ; cm
Brain
Includes bibliographical references and index.
ISBN 978-0-323-37754-6 (hardback)
1. Brain--Pathophysiology--Handbooks, manuals, etc. 2. Central nervous system--Diseases--Handbooks, manuals, etc. 3. Brain--Imaging--Handbooks, manuals, etc.
I. Osborn, Anne G., 1943- II. Salzman, Karen L. III. Jhaveri, Miral D. IV. Title: Brain.
[DNLM: 1. Brain--physiopathology--Atlases. 2. Central Nervous System Diseases--pathology--Atlases. 3. Neuroimaging--methods--Atlases. WL 301]
RC386.5.D515 2015
616.8--dc23

International Standard Book Number: 978-0-323-37754-6

Cover Designer: Tom M. Olson, BA
Cover Art: James A. Cooper, MD and Lane R. Bennion, MS

Printed in Canada by Friesens, Altona, Manitoba, Canada

Last digit is the print number: 9 8 7 6 5 4 3 2 1

ELSEVIER Book Aid International Working together to grow libraries in developing countries
www.elsevier.com • www.bookaid.org

https://CafePezeshki.IR

Dedications

To our neuroradiology friends and colleagues all over the world: Thanks for your longstanding interest, support, and generosity in sharing cases and concepts. This newest edition is for you.

AO

To the loves of my life: Craig, Sophia, Aubrey, and Ian. Thank you for your endless patience, love, and support.

KLS

To Palmi and Aanya: Thanks for all your support and patience.
To Michael and Beverly: Thanks for everything.

MJ

https://CafePezeshki.IR

Contributing Authors

A. James Barkovich, MD
Professor of Radiology and Biomedical Imaging, Neurology, Pediatrics, and Neurological Surgery
UCSF-Benioff Children's Hospital
University of California, San Francisco
San Francisco, California

H. Ric Harnsberger, MD
R.C. Willey Chair in Neuroradiology
Professor of Radiology and Otolaryngology
University of Utah School of Medicine
Salt Lake City, Utah

Luke N. Ledbetter, MD
Assistant Professor of Radiology
Division of Neuroradiology
University of Kansas Medical Center
Kansas City, Kansas

Nicholas A. Koontz, MD
Assistant Professor of Clinical Radiology
Department of Radiology and Imaging Sciences
Indiana University School of Medicine
Indianapolis, Indiana

Kevin R. Moore, MD
Pediatric Neuroradiologist
Primary Children's Hospital
Salt Lake City, Utah

Charles Raybaud, MD, FRCPC
Derek Harwood-Nash Chair in Medical Imaging
Division Head of Neuroradiology
The Hospital for Sick Children
Professor of Radiology
University of Toronto
Toronto, Ontario, Canada

Anna Illner, MD
Pediatric Neuroradiologist
Texas Children's Hospital
Assistant Professor of Radiology
Baylor College of Medicine
Houston, Texas

Sheri L. Harder, MD, FRCPC
Assistant Professor of Radiology
Division of Neuroradiology
Loma Linda University Medical Center
Loma Linda, California

Gregory L. Katzman, MD, MBA
Professor of Neuroradiology
Vice Chair of Radiology Operations
Chief Quality Officer
Chief Business Development Officer
Department of Radiology
University of Chicago School of Medicine
Chicago, Illinois

Bronwyn E. Hamilton, MD
Professor of Radiology
Oregon Health & Science University
Portland, Oregon

Lubdha M. Shah, MD
Associate Professor of Radiology
Division of Neuroradiology
University of Utah School of Medicine
Salt Lake City, Utah

Perry P. Ng, MBBS (Hons), FRANZCR
Adjunct Associate Professor
Department of Radiology
University of Utah School of Medicine
Salt Lake City, Utah
Interventional Neuroradiologist
Centura Health Physician Group
Denver, Colorado

Gary M. Nesbit, MD
Professor of Radiology, Neurology, Neurological Surgery
Dotter Interventional Institute
Oregon Health & Science University
Portland, Oregon

Ulrich Rassner, MD
Associate Professor of Radiology
Division of Neuroradiology
University of Utah School of Medicine
Salt Lake City, Utah

https://CafePezeshki.IR

Laurie A. Loevner, MD
Chief, Division of Neuroradiology
Director, Head and Neck Radiology
Professor of Radiology, Otorhinolaryngology: Head and Neck Surgery, and Neurosurgery
University of Pennsylvania Health System Perelman School of Medicine at the University of Pennsylvania
Philadelphia, Pennsylvania

Jeffrey S. Anderson, MD, PhD
Associate Professor of Radiology and Bioengineering
University of Utah School of Medicine
Salt Lake City, Utah

Chang Yueh Ho, MD
Assistant Professor of Radiology
Director of Pediatric Neuroradiology
Program Director of Pediatric Neuroradiology Fellowship
Riley Hospital for Children
Indiana University School of Medicine
Indianapolis, Indiana

Edward P. Quigley, III, MD, PhD
Associate Professor of Radiology
Division of Neuroradiology
University of Utah School of Medicine
Salt Lake City, Utah

John H. Rees, MD
Chief of Neuroradiology: Partners Imaging
Sarasota, Florida
Assistant Professor of Radiology
Georgetown University
Previously: Visiting Scientist
Armed Forces Institute of Pathology
Washington, DC

Majda M. Thurnher, MD
Associate Professor of Radiology
Medical University Vienna
Department of Biomedical Imaging and Image-Guided Therapy
Vienna, Austria

Gary L. Hedlund, DO
Adjunct Professor of Radiology
University of Utah School of Medicine
Pediatric Neuroradiologist
Department of Medical Imaging
Primary Children's Hospital
Salt Lake City, Utah

James M. Provenzale, MD
Professor of Radiology
Duke University Medical Center
Durham, North Carolina

Yoshimi Anzai, MD, MPH
Professor of Radiology
Associate Chief Medical Quality Officer
University of Utah
Salt Lake City, Utah

Susan I. Blaser, MD, FRCPC
Staff Neuroradiologist
The Hospital for Sick Children
Professor of Neuroradiology
University of Toronto
Toronto, Ontario, Canada

P. Ellen Grant, MD
Associate Professor in Radiology, Harvard Medical School
Founding Director, Center for Fetal-Neonatal Neuroimaging & Developmental Science
Director of Fetal and Neonatal Neuroimaging Research
Children's Hospital Boston Endowed Chair in Neonatology
Children's Hospital Boston
Boston, Massachusetts

Gilbert Vézina, MD
Director, Program in Neuroradiology
Children's National Medical Center
Professor of Radiology and Pediatrics
The George Washington University School of Medicine and Health Sciences
Washington, DC

Blaise V. Jones, MD
Associate Director of Radiology
Neuroradiology Section Chief
Cincinnati Children's Hospital Medical Center
Professor of Clinical Radiology and Pediatrics
University of Cincinnati College of Medicine
Cincinnati, Ohio

https://CafePezeshki.IR

Preface

Welcome to one of the first volumes in the third series of the brand new *Diagnostic Imaging* books. You'll note that our newest book bears the imprint of both Amirsys and Elsevier. The fresh new look and layout reflects our best creative efforts. Yet, we've kept the synoptic, highly efficient bulleted text that you've come to expect from us as well as the beloved key facts summary boxes at the beginning of each diagnosis.

A lot has happened since we published the second edition of *Diagnostic Imaging: Brain* back in 2010. We've added new diagnoses, including important topics such as tumor pseudoprogression and pseudoresponse. New entities such as CLIPPERS and the hot subject of IgG4-related disease are included. There are literally thousands of new images in the diagnosis galleries together with references that have been updated with the latest findings. You told us you loved the section introductions that were a new feature of the second edition, so we've included new and updated introductions to reflect the current thinking on these general topics.

The second edition covered the fourth (2007) edition of the World Health Organization (WHO) classification and grading of brain tumors. These have been published every seven years. If you "do the math," you know the fifth edition would normally have been published in 2014. It wasn't. So before you ask, I'll tell you it isn't coming out in 2015 either. The field of tumor diagnosis is changing so rapidly with the advent of genomic analysis that it's almost impossible to keep up with it. Our neuropathology colleagues expect to publish an online update in 2016 (maybe). So, what we've done here is update the neoplasms section with the latest literature to give you the current best understanding of classification and grading. It's changing rapidly so stay tuned.

We've loved hearing from you. We appreciate (and pay close attention to) your ideas and input on what new diagnoses or information you'd like to see included. Many of you have shared cool cases with us, and we've selected images from some that are used in this new edition with our grateful acknowledgement. After all, YOU are the reason we keep doing these books. So thanks for your interest and input. Enjoy our newest "baby"!

https://CafePezeshki.IR

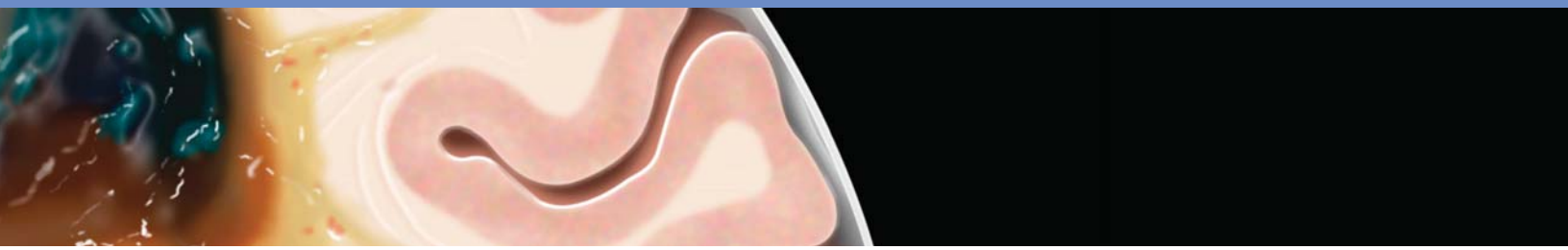

Anne G. Osborn, MD, FACR
University Distinguished Professor
William H. and Patricia W. Child Presidential Endowed Chair
University of Utah School of Medicine
Salt Lake City, Utah

Karen L. Salzman, MD
Professor of Radiology
Leslie W. Davis Endowed Chair in Neuroradiology
University of Utah School of Medicine
Salt Lake City, Utah

Miral D. Jhaveri, MD
Associate Professor
Division Head, Neuroradiology
Department of Diagnostic Radiology and Nuclear Medicine
Rush University Medical Center
Chicago, Illinois

https://CafePezeshki.IR

https://CafePezeshki.IR

Acknowledgements

Text Editors

Dave L. Chance, MA, ELS
Arthur G. Gelsinger, MA
Nina I. Bennett, BA
Sarah J. Connor, BA
Terry W. Ferrell, MS
Lisa A. Gervais, BA
Karen E. Concannon, MA, PhD

Image Editors

Jeffrey J. Marmorstone, BS
Lisa A. M. Steadman, BS

Medical Editors

Nicholas A. Koontz, MD
Remy Rosario Lobo, MD
Sarah Cantrell, MD

Illustrations

Lane R. Bennion, MS
Richard Coombs, MS
Laura C. Sesto, MA
James A. Cooper, MD

Art Direction and Design

Laura C. Sesto, MA
Tom M. Olson, BA

Lead Editor

Tricia L. Cannon, BA

Production Coordinators

Rebecca L. Hutchinson, BA
Angela M. G. Terry, BA

ELSEVIER

https://CafePezeshki.IR

https://CafePezeshki.IR

Sections

PART I: Pathology-Based Diagnoses

SECTION 1: Congenital Malformations

SECTION 2: Trauma

SECTION 3: Subarachnoid Hemorrhage and Aneurysms

SECTION 4: Stroke

SECTION 5: Vascular Malformations

SECTION 6: Neoplasms

SECTION 7: Primary Nonneoplastic Cysts

SECTION 8: Infectious, Inflammatory, and Demyelinating Disease

SECTION 9: Inherited Metabolic/Degenerative Disorders

SECTION 10: Acquired Toxic/Metabolic/Degenerative Disorders

PART II: Anatomy-Based Diagnoses

SECTION 1: Ventricles and Cisterns

SECTION 2: Sella and Pituitary

SECTION 3: CPA-IAC

SECTION 4: Skull, Scalp, and Meninges

https://CafePezeshki.IR

TABLE OF CONTENTS

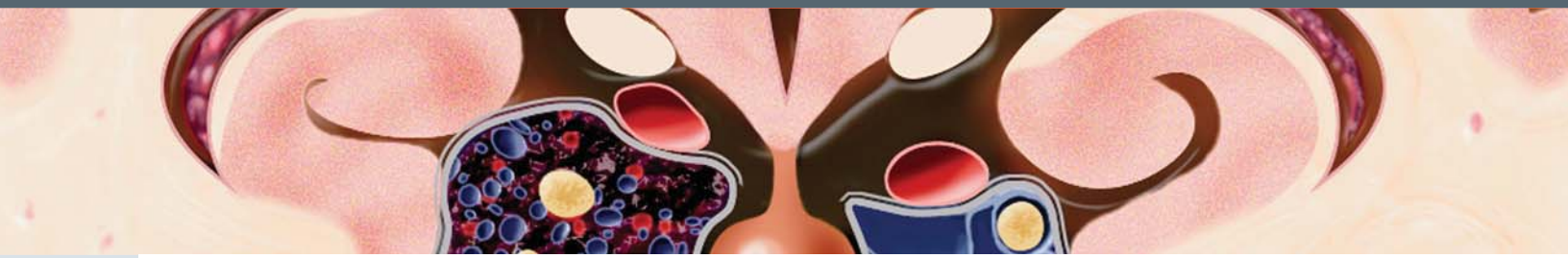

Part I: Pathology-Based Diagnoses

SECTION 1: CONGENITAL MALFORMATIONS

4 **Congenital Malformations Overview**
A. James Barkovich, MD

HINDBRAIN HERNIATIONS, MISCELLANEOUS MALFORMATIONS

8 **Chiari 1**
Susan I. Blaser, MD, FRCPC and Anne G. Osborn, MD, FACR
12 **Chiari 2**
Susan I. Blaser, MD, FRCPC and Kevin R. Moore, MD
16 **Chiari 3**
Susan I. Blaser, MD, FRCPC and Kevin R. Moore, MD
18 **Callosal Dysgenesis**
Charles Raybaud, MD, FRCPC and Anne G. Osborn, MD, FACR
22 **Lipoma**
A. James Barkovich, MD

HINDBRAIN MALFORMATIONS

26 **Dandy-Walker Continuum**
Susan I. Blaser, MD, FRCPC
30 **Rhombencephalosynapsis**
Blaise V. Jones, MD and Anne G. Osborn, MD, FACR
34 **Unclassified Cerebellar Dysplasias**
Blaise V. Jones, MD
36 **Molar Tooth Malformations (Joubert)**
Charles Raybaud, MD, FRCPC and Anne G. Osborn, MD, FACR

DISORDERS OF DIVERTICULATION/CLEAVAGE

40 **Holoprosencephaly**
Charles Raybaud, MD, FRCPC and Anne G. Osborn, MD, FACR
44 **Holoprosencephaly Variants**
Anna Illner, MD
48 **Syntelencephaly (Middle Interhemispheric Variant)**
Charles Raybaud, MD, FRCPC
52 **Septooptic Dysplasia**
A. James Barkovich, MD

MALFORMATIONS OF CORTICAL DEVELOPMENT

56 **Microcephaly**
Gary L. Hedlund, DO
60 **Congenital Muscular Dystrophy**
Charles Raybaud, MD, FRCPC
64 **Heterotopic Gray Matter**
Charles Raybaud, MD, FRCPC
68 **Polymicrogyria**
A. James Barkovich, MD
72 **Lissencephaly**
Blaise V. Jones, MD
76 **Schizencephaly**
Blaise V. Jones, MD
80 **Hemimegalencephaly**
Anne G. Osborn, MD, FACR and Blaise V. Jones, MD

FAMILIAL TUMOR/NEUROCUTANEOUS SYNDROMES

84 **Neurofibromatosis Type 1**
Gilbert Vézina, MD and Anne G. Osborn, MD, FACR
88 **Neurofibromatosis Type 2**
Gilbert Vézina, MD
92 **von Hippel-Lindau Syndrome**
Anne G. Osborn, MD, FACR and Gilbert Vézina, MD
96 **Tuberous Sclerosis Complex**
Gilbert Vézina, MD and Anne G. Osborn, MD, FACR
100 **Sturge-Weber Syndrome**
Gilbert Vézina, MD and Anne G. Osborn, MD, FACR
104 **Meningioangiomatosis**
Anne G. Osborn, MD, FACR
106 **Basal Cell Nevus Syndrome**
Gilbert Vézina, MD
110 **Hereditary Hemorrhagic Telangiectasia**
Anne G. Osborn, MD, FACR and Charles Raybaud, MD, FRCPC
114 **Encephalocraniocutaneous Lipomatosis**
Gilbert Vézina, MD
118 **Lhermitte-Duclos Disease**
Anne G. Osborn, MD, FACR and P. Ellen Grant, MD
122 **Neurocutaneous Melanosis**
Gilbert Vézina, MD
126 **Aicardi Syndrome**
P. Ellen Grant, MD
128 **Li-Fraumeni Syndrome**
Gilbert Vézina, MD
130 **Schwannomatosis**
Nicholas A. Koontz, MD

https://CafePezeshki.IR

TABLE OF CONTENTS

SECTION 2: TRAUMA

134 **Introduction to CNS Imaging, Trauma**
Anne G. Osborn, MD, FACR

PRIMARY EFFECTS OF CNS TRAUMA

140 **Scalp and Skull Injuries**
Anne G. Osborn, MD, FACR
144 **Missile and Penetrating Injury**
Anne G. Osborn, MD, FACR and Sheri L. Harder, MD, FRCPC
148 **Epidural Hematoma, Classic**
Anne G. Osborn, MD, FACR and Gregory L. Katzman, MD, MBA
152 **Epidural Hematoma, Variant**
Anne G. Osborn, MD, FACR
156 **Acute Subdural Hematoma**
Anne G. Osborn, MD, FACR and Bronwyn E. Hamilton, MD
160 **Subacute Subdural Hematoma**
Anne G. Osborn, MD, FACR and Bronwyn E. Hamilton, MD
164 **Chronic Subdural Hematoma**
Anne G. Osborn, MD, FACR
168 **Traumatic Subarachnoid Hemorrhage**
Anne G. Osborn, MD, FACR and Gregory L. Katzman, MD, MBA
172 **Cerebral Contusion**
Anne G. Osborn, MD, FACR
176 **Diffuse Axonal Injury**
Anne G. Osborn, MD, FACR
180 **Subcortical Injury**
Anne G. Osborn, MD, FACR and Gregory L. Katzman, MD, MBA
184 **Pneumocephalus**
Anne G. Osborn, MD, FACR and Gregory L. Katzman, MD, MBA
188 **Abusive Head Trauma**
Gary L. Hedlund, DO

SECONDARY EFFECTS OF CNS TRAUMA

192 **Intracranial Herniation Syndromes**
Anne G. Osborn, MD, FACR
196 **Post-Traumatic Brain Swelling**
Anne G. Osborn, MD, FACR
200 **Traumatic Cerebral Ischemia/Infarction**
Anne G. Osborn, MD, FACR and Gregory L. Katzman, MD, MBA
204 **Brain Death**
Anne G. Osborn, MD, FACR
206 **Second Impact Syndrome**
Anne G. Osborn, MD, FACR
208 **Traumatic Intracranial Arterial Dissection**
Anne G. Osborn, MD, FACR
212 **Traumatic Carotid Cavernous Fistula**
Anne G. Osborn, MD, FACR and Perry P. Ng, MBBS (Hons), FRANZCR
214 **Chronic Traumatic Encephalopathy**
Anne G. Osborn, MD, FACR

SECTION 3: SUBARACHNOID HEMORRHAGE AND ANEURYSMS

218 **Subarachnoid Hemorrhage & Aneurysms Overview**
Anne G. Osborn, MD, FACR

SUBARACHNOID HEMORRHAGE

220 **Aneurysmal Subarachnoid Hemorrhage**
Anne G. Osborn, MD, FACR
224 **Perimesencephalic Nonaneurysmal SAH**
Anne G. Osborn, MD, FACR
226 **Convexal Subarachnoid Hemorrhage**
Anne G. Osborn, MD, FACR
228 **Superficial Siderosis**
Anne G. Osborn, MD, FACR and H. Ric Harnsberger, MD

ANEURYSMS

232 **Saccular Aneurysm**
Anne G. Osborn, MD, FACR and Perry P. Ng, MBBS (Hons), FRANZCR
236 **Pseudoaneurysm**
Anne G. Osborn, MD, FACR
238 **Vertebrobasilar Dolichoectasia**
Anne G. Osborn, MD, FACR
240 **ASVD Fusiform Aneurysm**
Anne G. Osborn, MD, FACR
242 **Non-ASVD Fusiform Aneurysm**
Anne G. Osborn, MD, FACR
244 **Blood Blister-Like Aneurysm**
Anne G. Osborn, MD, FACR

SECTION 4: STROKE

248 **Stroke Overview**
Karen L. Salzman, MD

NONTRAUMATIC INTRACRANIAL HEMORRHAGE

254 **Evolution of Intracranial Hemorrhage**
Karen L. Salzman, MD and Ulrich Rassner, MD
258 **Spontaneous Nontraumatic Intracranial Hemorrhage**
Karen L. Salzman, MD and Laurie A. Loevner, MD
262 **Hypertensive Intracranial Hemorrhage**
Karen L. Salzman, MD and Laurie A. Loevner, MD
266 **Remote Cerebellar Hemorrhage**
Karen L. Salzman, MD and Bronwyn E. Hamilton, MD
268 **Germinal Matrix Hemorrhage**
Karen L. Salzman, MD and P. Ellen Grant, MD

ATHEROSCLEROSIS AND CAROTID STENOSIS

272 **Intracranial Atherosclerosis**
Anne G. Osborn, MD, FACR
276 **Extracranial Atherosclerosis**
Karen L. Salzman, MD and Bronwyn E. Hamilton, MD
280 **Arteriolosclerosis**
Karen L. Salzman, MD

https://CafePezeshki.IR

TABLE OF CONTENTS

NONATHEROMATOUS VASCULOPATHY

284 **Aberrant Internal Carotid Artery**
Karen L. Salzman, MD and H. Ric Harnsberger, MD
288 **Persistent Carotid Basilar Anastomoses**
Karen L. Salzman, MD and Charles Raybaud, MD, FRCPC
290 **Sickle Cell Disease, Brain**
Anna Illner, MD
294 **Moyamoya**
Anne G. Osborn, MD, FACR and Anna Illner, MD
298 **Primary Arteritis of the CNS**
Anne G. Osborn, MD, FACR
302 **Miscellaneous Vasculitis**
Anne G. Osborn, MD, FACR
306 **Reversible Cerebral Vasoconstriction Syndrome**
Karen L. Salzman, MD and Perry P. Ng, MBBS (Hons), FRANZCR
308 **Vasospasm**
Karen L. Salzman, MD and Perry P. Ng, MBBS (Hons), FRANZCR
312 **Systemic Lupus Erythematosus**
Karen L. Salzman, MD and Gary M. Nesbit, MD
316 **Cerebral Amyloid Disease**
Karen L. Salzman, MD and Bronwyn E. Hamilton, MD
320 **CADASIL**
Karen L. Salzman, MD and Ulrich Rassner, MD
324 **Behçet Disease**
Karen L. Salzman, MD
326 **Susac Syndrome**
Karen L. Salzman, MD and Jeffrey S. Anderson, MD, PhD
328 **Fibromuscular Dysplasia**
Karen L. Salzman, MD and Perry P. Ng, MBBS (Hons), FRANZCR

CEREBRAL ISCHEMIA AND INFARCTION

330 **Hydranencephaly**
Anne G. Osborn, MD, FACR
332 **White Matter Injury of Prematurity**
P. Ellen Grant, MD
336 **Term Hypoxic Ischemic Injury**
P. Ellen Grant, MD
340 **Adult Hypoxic Ischemic Injury**
Karen L. Salzman, MD and Lubdha M. Shah, MD
344 **Hypotensive Cerebral Infarction**
Anne G. Osborn, MD, FACR and Bronwyn E. Hamilton, MD
348 **Childhood Stroke**
Anne G. Osborn, MD, FACR and Blaise V. Jones, MD
352 **Cerebral Hemiatrophy**
Karen L. Salzman, MD
354 **Acute Cerebral Ischemia-Infarction**
Anne G. Osborn, MD, FACR and Edward P. Quigley, III, MD, PhD
358 **Subacute Cerebral Infarction**
Karen L. Salzman, MD and Sheri L. Harder, MD, FRCPC
362 **Chronic Cerebral Infarction**
Sheri L. Harder, MD, FRCPC and Anne G. Osborn, MD, FACR
366 **Multiple Embolic Cerebral Infarctions**
Karen L. Salzman, MD
367 **Fat Emboli Cerebral Infarction**
Karen L. Salzman, MD
368 **Lacunar Infarction**
Karen L. Salzman, MD and Ulrich Rassner, MD
372 **Cerebral Hyperperfusion Syndrome**
Anne G. Osborn, MD, FACR
376 **Dural Sinus Thrombosis**
Anne G. Osborn, MD, FACR
380 **Cortical Venous Thrombosis**
Anne G. Osborn, MD, FACR and Bronwyn E. Hamilton, MD
384 **Deep Cerebral Venous Thrombosis**
Anne G. Osborn, MD, FACR and Bronwyn E. Hamilton, MD
388 **Dural Sinus and Aberrant Arachnoid Granulations**
H. Ric Harnsberger, MD

SECTION 5: VASCULAR MALFORMATIONS

394 **Vascular Malformations Overview**
Anne G. Osborn, MD, FACR

CVMS WITH AV SHUNTING

396 **Arteriovenous Malformation**
Anne G. Osborn, MD, FACR and Perry P. Ng, MBBS (Hons), FRANZCR
400 **Dural AV Fistula**
Anne G. Osborn, MD, FACR and Perry P. Ng, MBBS (Hons), FRANZCR
404 **Pial AV Fistula**
Anne G. Osborn, MD, FACR
406 **Vein of Galen Aneurysmal Malformation**
Anne G. Osborn, MD, FACR and Anna Illner, MD

CVMS WITHOUT AV SHUNTING

410 **Developmental Venous Anomaly**
Anne G. Osborn, MD, FACR
416 **Sinus Pericranii**
Anne G. Osborn, MD, FACR and Anna Illner, MD
420 **Cavernous Malformation**
Anne G. Osborn, MD, FACR
424 **Capillary Telangiectasia**
Anne G. Osborn, MD, FACR

SECTION 6: NEOPLASMS

430 **Neoplasms Overview**
Anne G. Osborn, MD, FACR

ASTROCYTIC TUMORS, INFILTRATING

434 **Low-Grade Diffuse Astrocytoma**
Karen L. Salzman, MD
438 **Anaplastic Astrocytoma**
Karen L. Salzman, MD
442 **Glioblastoma**
Karen L. Salzman, MD
446 **Gliosarcoma**
Karen L. Salzman, MD
448 **Gliomatosis Cerebri**
Karen L. Salzman, MD

https://CafePezeshki.IR

TABLE OF CONTENTS

ASTROCYTIC TUMORS, LOCALIZED

452 **Pilocytic Astrocytoma**
Karen L. Salzman, MD and Chang Yueh Ho, MD
456 **Pilomyxoid Astrocytoma**
Anne G. Osborn, MD, FACR
460 **Pleomorphic Xanthoastrocytoma**
Karen L. Salzman, MD
464 **Subependymal Giant Cell Astrocytoma**
Anne G. Osborn, MD, FACR and John H. Rees, MD

OLIGODENDROGLIAL AND MISCELLANEOUS TUMORS

468 **Oligodendroglioma**
Karen L. Salzman, MD
472 **Anaplastic Oligodendroglioma**
Karen L. Salzman, MD
476 **Astroblastoma**
Karen L. Salzman, MD
478 **Chordoid Glioma of the Third Ventricle**
Karen L. Salzman, MD and John H. Rees, MD
480 **Angiocentric Glioma**
Karen L. Salzman, MD and Majda M. Thurnher, MD

EPENDYMAL TUMORS

482 **Infratentorial Ependymoma**
Anne G. Osborn, MD, FACR and Majda M. Thurnher, MD
486 **Supratentorial Ependymoma**
Majda M. Thurnher, MD
490 **Subependymoma**
Karen L. Salzman, MD

CHOROID PLEXUS TUMORS

494 **Typical Choroid Plexus Papilloma**
Anne G. Osborn, MD, FACR and Chang Yueh Ho, MD
498 **Choroid Plexus Carcinoma**
Anne G. Osborn, MD, FACR and Chang Yueh Ho, MD

NEURONAL AND MIXED NEURONAL-GLIAL TUMORS

502 **Ganglioglioma**
Karen L. Salzman, MD
506 **Desmoplastic Infantile Astrocytoma and Ganglioglioma**
Chang Yueh Ho, MD
510 **DNET**
Karen L. Salzman, MD and Laurie A. Loevner, MD
514 **Central Neurocytoma**
Karen L. Salzman, MD
518 **Extraventricular Neurocytoma**
Karen L. Salzman, MD
520 **Cerebellar Liponeurocytoma**
Karen L. Salzman, MD and John H. Rees, MD
521 **Papillary Glioneuronal Tumor**
Karen L. Salzman, MD and John H. Rees, MD
522 **Rosette-Forming Glioneuronal Tumor**
Karen L. Salzman, MD and Majda M. Thurnher, MD

PINEAL PARENCHYMAL TUMORS

524 **Pineocytoma**
Karen L. Salzman, MD and Laurie A. Loevner, MD
528 **Pineal Parenchymal Tumor of Intermediate Differentiation**
Karen L. Salzman, MD and Anne G. Osborn, MD, FACR
530 **Pineoblastoma**
Anne G. Osborn, MD, FACR and Laurie A. Loevner, MD
534 **Papillary Tumor of the Pineal Region**
Karen L. Salzman, MD and John H. Rees, MD

EMBRYONAL AND NEUROBLASTIC TUMORS

536 **Medulloblastoma**
Anne G. Osborn, MD, FACR and Majda M. Thurnher, MD
540 **Supratentorial PNET**
Anne G. Osborn, MD, FACR and Laurie A. Loevner, MD
544 **Atypical Teratoid-Rhabdoid Tumor**
Anne G. Osborn, MD, FACR and Chang Yueh Ho, MD
548 **Metastatic Neuroblastoma**
Anne G. Osborn, MD, FACR and Chang Yueh Ho, MD

TUMORS OF CRANIAL/PERIPHERAL NERVES

552 **Nonvestibular Schwannoma**
Nicholas A. Koontz, MD and Anne G. Osborn, MD, FACR
556 **Neurofibroma**
Nicholas A. Koontz, MD and John H. Rees, MD

BLOOD VESSEL AND HEMOPOIETIC TUMORS

558 **Hemangioblastoma**
Karen L. Salzman, MD and John H. Rees, MD
562 **Hemangiopericytoma**
Karen L. Salzman, MD
566 **Primary CNS Lymphoma**
Karen L. Salzman, MD
570 **Intravascular (Angiocentric) Lymphoma**
Karen L. Salzman, MD
574 **Leukemia**
Karen L. Salzman, MD and Miral D. Jhaveri, MD

GERM CELL TUMORS

578 **Germinoma**
Anne G. Osborn, MD, FACR and Majda M. Thurnher, MD
582 **Teratoma**
Anne G. Osborn, MD, FACR and Majda M. Thurnher, MD
586 **Miscellaneous Malignant Germ Cell Neoplasms**
Karen L. Salzman, MD and Majda M. Thurnher, MD

METASTATIC TUMORS AND REMOTE EFFECTS OF CANCER

590 **Parenchymal Metastases**
Anne G. Osborn, MD, FACR
594 **Miscellaneous Intracranial Metastases**
Anne G. Osborn, MD, FACR
596 **Metastatic Intracranial Lymphoma**
Karen L. Salzman, MD
598 **Paraneoplastic Syndromes**
Karen L. Salzman, MD

https://CafePezeshki.IR

TABLE OF CONTENTS

SECTION 7: PRIMARY NONNEOPLASTIC CYSTS

604 **Primary Nonneoplastic Cysts Overview**
Anne G. Osborn, MD, FACR
608 **Arachnoid Cyst**
Anne G. Osborn, MD, FACR
612 **Colloid Cyst**
Anne G. Osborn, MD, FACR
616 **Dermoid Cyst**
Chang Yueh Ho, MD
620 **Epidermoid Cyst**
Anne G. Osborn, MD, FACR and Gregory L. Katzman, MD, MBA
624 **Neuroglial Cyst**
Anne G. Osborn, MD, FACR
626 **Periventricular Cyst**
Anne G. Osborn, MD, FACR and Susan I. Blaser, MD, FRCPC
630 **Choroid Fissure Cyst**
Chang Yueh Ho, MD
631 **Hippocampal Sulcus Remnant Cysts**
Chang Yueh Ho, MD
632 **Enlarged Perivascular Spaces**
Anne G. Osborn, MD, FACR
636 **Pineal Cyst**
Anne G. Osborn, MD, FACR
640 **Choroid Plexus Cyst**
Anne G. Osborn, MD, FACR
644 **Ependymal Cyst**
Anne G. Osborn, MD, FACR
646 **Porencephalic Cyst**
Anne G. Osborn, MD, FACR and Gregory L. Katzman, MD, MBA
650 **Neurenteric Cyst**
Anne G. Osborn, MD, FACR
652 **Nonneoplastic Tumor-Associated Cysts**
Anne G. Osborn, MD, FACR

SECTION 8: INFECTIOUS, INFLAMMATORY, AND DEMYELINATING DISEASE

656 **CNS Infectious Disease Overview**
Miral D. Jhaveri, MD and Anne G. Osborn, MD, FACR

CONGENITAL/NEONATAL INFECTIONS

658 **TORCH Infections, Overview**
Gary L. Hedlund, DO
662 **Congenital CMV**
Miral D. Jhaveri, MD and Gary L. Hedlund, DO
666 **Congenital HIV**
Miral D. Jhaveri, MD and Gary L. Hedlund, DO
668 **Neonatal Herpes Encephalitis**
Miral D. Jhaveri, MD and Gary L. Hedlund, DO

ACQUIRED INFECTIONS

670 **Group B Streptococcal Meningitis**
Gary L. Hedlund, DO
674 **Citrobacter Meningitis**
Gary L. Hedlund, DO
678 **Meningitis**
Miral D. Jhaveri, MD and Karen L. Salzman, MD
682 **Abscess**
Miral D. Jhaveri, MD and Karen L. Salzman, MD
686 **Ventriculitis**
Miral D. Jhaveri, MD and Karen L. Salzman, MD
688 **Empyema**
Miral D. Jhaveri, MD and Karen L. Salzman, MD
692 **Herpes Encephalitis**
Miral D. Jhaveri, MD and Karen L. Salzman, MD
696 **Miscellaneous Encephalitis**
Miral D. Jhaveri, MD and Karen L. Salzman, MD
700 **West Nile Virus Encephalitis**
Miral D. Jhaveri, MD and Laurie A. Loevner, MD
702 **HHV-6 Encephalitis**
Miral D. Jhaveri, MD
704 **Cerebellitis**
Miral D. Jhaveri, MD
706 **Rasmussen Encephalitis**
Miral D. Jhaveri, MD and Gary L. Hedlund, DO
710 **Subacute Sclerosing Panencephalitis**
Gary L. Hedlund, DO
712 **Tuberculosis**
Miral D. Jhaveri, MD and Sheri L. Harder, MD, FRCPC
716 **Neurocysticercosis**
Miral D. Jhaveri, MD and Karen L. Salzman, MD
720 **Hydatid Disease**
Miral D. Jhaveri, MD
722 **Amebic Disease**
Miral D. Jhaveri, MD
724 **Cerebral Malaria**
Anne G. Osborn, MD, FACR
726 **Miscellaneous Parasites**
Miral D. Jhaveri, MD and Karen L. Salzman, MD
730 **Fungal Diseases**
Miral D. Jhaveri, MD and Laurie A. Loevner, MD
734 **Rickettsial Diseases**
Miral D. Jhaveri, MD and Laurie A. Loevner, MD
736 **Lyme Disease**
Miral D. Jhaveri, MD and Laurie A. Loevner, MD
738 **Acquired HIV Encephalitis**
Miral D. Jhaveri, MD and James M. Provenzale, MD
742 **Acquired Toxoplasmosis**
Miral D. Jhaveri, MD and James M. Provenzale, MD
744 **Acquired CMV**
Miral D. Jhaveri, MD and Yoshimi Anzai, MD, MPH
746 **Cryptococcosis**
Yoshimi Anzai, MD, MPH
748 **Progressive Multifocal Leukoencephalopathy (PML)**
Miral D. Jhaveri, MD and Yoshimi Anzai, MD, MPH
750 **Immune Reconstitution Inflammatory Syndrome (IRIS)**
Miral D. Jhaveri, MD
752 **HIV/AIDS, Miscellaneous Manifestations**
Miral D. Jhaveri, MD

https://CafePezeshki.IR

TABLE OF CONTENTS

INFLAMMATORY AND DEMYELINATING DISEASE

756 **Multiple Sclerosis**
Miral D. Jhaveri, MD
760 **Neuromyelitis Optica**
Miral D. Jhaveri, MD
764 **ADEM**
Miral D. Jhaveri, MD and Jeffrey S. Anderson, MD, PhD
768 **AHLE**
Anne G. Osborn, MD, FACR
770 **CLIPPERS**
Anne G. Osborn, MD, FACR

SECTION 9: INHERITED METABOLIC/DEGENERATIVE DISORDERS

774 **Inherited Metabolic Disorders Overview**
A. James Barkovich, MD

NORMAL VARIANTS

778 **Hypomyelination**
Blaise V. Jones, MD

MITOCHONDRIAL DISORDERS

782 **Leigh Syndrome**
A. James Barkovich, MD
786 **MELAS**
Susan I. Blaser, MD, FRCPC
790 **Kearns-Sayre Syndrome**
Susan I. Blaser, MD, FRCPC

LYSOSOMAL DISORDERS

792 **Mucopolysaccharidoses**
Susan I. Blaser, MD, FRCPC
796 **Gangliosidosis (GM2)**
Anna Illner, MD
800 **Metachromatic Leukodystrophy (MLD)**
Anna Illner, MD and Anne G. Osborn, MD, FACR
804 **Krabbe**
Blaise V. Jones, MD
808 **Fabry Disease**
Miral D. Jhaveri, MD and Anne G. Osborn, MD, FACR

PEROXISOMAL DISORDERS

810 **Zellweger Syndrome Spectrum**
P. Ellen Grant, MD
812 **X-Linked Adrenoleukodystrophy**
Susan I. Blaser, MD, FRCPC and Anne G. Osborn, MD, FACR
816 **Other Peroxisomal Disorders**
Susan I. Blaser, MD, FRCPC

ORGANIC AND AMINOACIDOPATHIES

820 **Maple Syrup Urine Disease**
Susan I. Blaser, MD, FRCPC
824 **Urea Cycle Disorders**
P. Ellen Grant, MD
826 **Glutaric Aciduria Type 1**
Susan I. Blaser, MD, FRCPC
830 **Canavan Disease**
P. Ellen Grant, MD
832 **Alexander Disease**
Anna Illner, MD
836 **Miscellaneous Organic/Aminoacidopathies**
Anna Illner, MD and Anne G. Osborn, MD, FACR

MISCELLANEOUS

838 **Megalencephaly With Leukoencephalopathy and Cysts (MLC)**
Susan I. Blaser, MD, FRCPC
842 **Neurodegeneration With Brain Iron Accumulation (NBIA)**
Chang Yueh Ho, MD and Anne G. Osborn, MD, FACR
844 **PKAN**
Anna Illner, MD
848 **Huntington Disease**
James M. Provenzale, MD
852 **Wilson Disease**
Anne G. Osborn, MD, FACR and James M. Provenzale, MD

SECTION 10: ACQUIRED TOXIC/METABOLIC/DEGENERATIVE DISORDERS

858 **Acquired Toxic/Metabolic Disorders Overview**
Miral D. Jhaveri, MD and Karen L. Salzman, MD

TOXIC, METABOLIC, NUTRITIONAL, SYSTEMIC DISEASES WITH CNS MANIFESTATIONS

862 **Pediatric Hypoglycemia**
Miral D. Jhaveri, MD and P. Ellen Grant, MD
866 **Adult Hypoglycemia**
Miral D. Jhaveri, MD and John H. Rees, MD
868 **Kernicterus**
Miral D. Jhaveri, MD and P. Ellen Grant, MD
870 **Thyroid Disorders**
Miral D. Jhaveri, MD
874 **Parathyroid Disorders**
Miral D. Jhaveri, MD
876 **Fahr Disease**
Miral D. Jhaveri, MD and Gregory L. Katzman, MD, MBA
880 **Alcoholic Encephalopathy**
Miral D. Jhaveri, MD
884 **Hepatic Encephalopathy**
Miral D. Jhaveri, MD
888 **Acute Hypertensive Encephalopathy, PRES**
Miral D. Jhaveri, MD and Anne G. Osborn, MD, FACR
892 **Chronic Hypertensive Encephalopathy**
Miral D. Jhaveri, MD and James M. Provenzale, MD
896 **Idiopathic Intracranial Hypertension**
Miral D. Jhaveri, MD
900 **Carbon Monoxide Poisoning**
Yoshimi Anzai, MD, MPH
904 **Drug Abuse**
Miral D. Jhaveri, MD

https://CafePezeshki.IR

TABLE OF CONTENTS

908 **Methanol Poisoning**
Sheri L. Harder, MD, FRCPC
910 **Cyanide Poisoning**
Miral D. Jhaveri, MD and Sheri L. Harder, MD, FRCPC
912 **Osmotic Demyelination Syndrome**
Miral D. Jhaveri, MD and Sheri L. Harder, MD, FRCPC
916 **Radiation and Chemotherapy**
Miral D. Jhaveri, MD and Karen L. Salzman, MD
920 **Pseudoprogression**
Karen L. Salzman, MD
922 **Pseudoresponse**
Karen L. Salzman, MD
924 **Mesial Temporal Sclerosis**
Miral D. Jhaveri, MD and Kevin R. Moore, MD
928 **Status Epilepticus**
Miral D. Jhaveri, MD and Karen L. Salzman, MD
932 **Transient Global Amnesia (TGA)**
Anne G. Osborn, MD, FACR

DEMENTIAS AND DEGENERATIVE DISORDERS

934 **Normal Aging Brain**
Miral D. Jhaveri, MD and Sheri L. Harder, MD, FRCPC
938 **Alzheimer Disease**
Miral D. Jhaveri, MD and James M. Provenzale, MD
942 **Vascular Dementia**
Miral D. Jhaveri, MD and James M. Provenzale, MD
946 **Frontotemporal Lobar Degeneration**
Miral D. Jhaveri, MD and James M. Provenzale, MD
950 **Dementia With Lewy Bodies**
Miral D. Jhaveri, MD and James M. Provenzale, MD
952 **Creutzfeldt-Jakob Disease (CJD)**
Miral D. Jhaveri, MD and Karen L. Salzman, MD
956 **Parkinson Disease**
Miral D. Jhaveri, MD and James M. Provenzale, MD
960 **Multiple System Atrophy**
Miral D. Jhaveri, MD
964 **Corticobasal Degeneration**
Miral D. Jhaveri, MD and James M. Provenzale, MD
968 **Progressive Supranuclear Palsy**
Miral D. Jhaveri, MD and James M. Provenzale, MD
972 **Amyotrophic Lateral Sclerosis (ALS)**
Miral D. Jhaveri, MD and Lubdha M. Shah, MD
976 **Wallerian Degeneration**
Miral D. Jhaveri, MD and Lubdha M. Shah, MD
980 **Crossed Cerebellar Diaschisis**
Miral D. Jhaveri, MD and Anne G. Osborn, MD, FACR
982 **Hypertrophic Olivary Degeneration**
Miral D. Jhaveri, MD and Anne G. Osborn, MD, FACR

Part II: Anatomy-Based Diagnoses

SECTION 1: VENTRICLES AND CISTERNS

988 **Ventricles and Cisterns Overview**
Miral D. Jhaveri, MD

NORMAL VARIANTS

994 **Cavum Septi Pellucidi (CSP)**
Miral D. Jhaveri, MD and Anne G. Osborn, MD, FACR
995 **Cavum Velum Interpositum (CVI)**
Miral D. Jhaveri, MD and Anne G. Osborn, MD, FACR
996 **Enlarged Subarachnoid Spaces**
Miral D. Jhaveri, MD and Chang Yueh Ho, MD

HYDROCEPHALUS

1000 **Intraventricular Obstructive Hydrocephalus**
Miral D. Jhaveri, MD
1004 **Extraventricular Obstructive Hydrocephalus**
Miral D. Jhaveri, MD
1006 **Aqueductal Stenosis**
Miral D. Jhaveri, MD and Kevin R. Moore, MD
1010 **Normal Pressure Hydrocephalus**
Miral D. Jhaveri, MD
1014 **CSF Shunts and Complications**
Miral D. Jhaveri, MD and Kevin R. Moore, MD

SECTION 2: SELLA AND PITUITARY

1020 **Sella and Pituitary Overview**
Karen L. Salzman, MD and Anne G. Osborn, MD, FACR

CONGENITAL

1024 **Pituitary Anomalies**
Karen L. Salzman, MD and Kevin R. Moore, MD
1028 **Tuber Cinereum Hamartoma**
Karen L. Salzman, MD and Kevin R. Moore, MD
1032 **Rathke Cleft Cyst**
Karen L. Salzman, MD and Anne G. Osborn, MD, FACR

NEOPLASMS

1036 **Pituitary Microadenoma**
Karen L. Salzman, MD and Anne G. Osborn, MD, FACR
1040 **Pituitary Macroadenoma**
Karen L. Salzman, MD and Anne G. Osborn, MD, FACR
1044 **Pituitary Apoplexy**
Karen L. Salzman, MD and Anne G. Osborn, MD, FACR
1048 **Craniopharyngioma**
Karen L. Salzman, MD and John H. Rees, MD
1052 **Pituicytoma**
Karen L. Salzman, MD
1054 **Spindle Cell Oncocytoma**
Anne G. Osborn, MD, FACR and Karen L. Salzman, MD
1055 **Granular Cell Tumor**
Karen L. Salzman, MD

MISCELLANEOUS

1056 **Empty Sella**
Luke N. Ledbetter, MD and Anne G. Osborn, MD, FACR
1060 **Pituitary Hyperplasia**
Luke N. Ledbetter, MD and Anne G. Osborn, MD, FACR
1062 **Lymphocytic Hypophysitis**
Karen L. Salzman, MD

https://CafePezeshki.IR

TABLE OF CONTENTS

SECTION 3: CPA-IAC

1066 **CPA-IAC Overview**
H. Ric Harnsberger, MD

CONGENITAL

1070 **Lipoma, CPA-IAC**
H. Ric Harnsberger, MD
1074 **Epidermoid Cyst, CPA-IAC**
H. Ric Harnsberger, MD
1078 **Arachnoid Cyst, CPA-IAC**
H. Ric Harnsberger, MD

INFLAMMATORY

1082 **Bell Palsy**
H. Ric Harnsberger, MD

VASCULAR

1086 **Trigeminal Neuralgia**
H. Ric Harnsberger, MD
1088 **Hemifacial Spasm**
H. Ric Harnsberger, MD

NEOPLASMS

1090 **Vestibular Schwannoma**
H. Ric Harnsberger, MD
1094 **Meningioma, CPA-IAC**
H. Ric Harnsberger, MD
1098 **Metastases, CPA-IAC**
H. Ric Harnsberger, MD

SECTION 4: SKULL, SCALP, AND MENINGES

1104 **Skull, Scalp, & Meninges Overview**
Karen L. Salzman, MD

CONGENITAL

1108 **Congenital Calvarial Defects**
Kevin R. Moore, MD
1112 **Craniostenoses**
Kevin R. Moore, MD
1116 **Cephalocele**
Kevin R. Moore, MD
1122 **Atretic Cephalocele**
Anne G. Osborn, MD, FACR and Kevin R. Moore, MD

TRAUMA

1126 **Leptomeningeal Cyst ("Growing Fracture")**
Anne G. Osborn, MD, FACR and Kevin R. Moore, MD
1128 **Intracranial Hypotension**
Anne G. Osborn, MD, FACR

NONNEOPLASTIC AND TUMOR-LIKE DISORDERS

1132 **Intracranial Idiopathic Inflammatory Pseudotumor**
H. Ric Harnsberger, MD
1136 **IgG4-Related Disease**
Anne G. Osborn, MD, FACR
1138 **Fibrous Dysplasia**
Anne G. Osborn, MD, FACR and Miral D. Jhaveri, MD
1142 **Paget Disease**
Anne G. Osborn, MD, FACR and Miral D. Jhaveri, MD
1146 **Extramedullary Hematopoiesis**
Anne G. Osborn, MD, FACR and Charles Raybaud, MD, FRCPC
1150 **Thick Skull**
Anne G. Osborn, MD, FACR and Miral D. Jhaveri, MD
1152 **Langerhans Cell Histiocytosis, Skull and Brain**
Anne G. Osborn, MD, FACR and Gary L. Hedlund, DO
1156 **Neurosarcoid**
Anne G. Osborn, MD, FACR and Gregory L. Katzman, MD, MBA
1160 **Miscellaneous Histiocytoses**
Anne G. Osborn, MD, FACR and Karen L. Salzman, MD
1164 **Sebaceous Cyst**
Anne G. Osborn, MD, FACR

NEOPLASMS

1166 **Meningioma**
Anne G. Osborn, MD, FACR and Majda M. Thurnher, MD
1172 **Atypical and Malignant Meningioma**
Anne G. Osborn, MD, FACR and Majda M. Thurnher, MD
1176 **Miscellaneous Benign Mesenchymal Tumors**
Anne G. Osborn, MD, FACR and Gregory L. Katzman, MD, MBA
1180 **Miscellaneous Malignant Mesenchymal Tumors**
Anne G. Osborn, MD, FACR and Gregory L. Katzman, MD, MBA
1184 **Calvarial Hemangioma**
Anne G. Osborn, MD, FACR and Gregory L. Katzman, MD, MBA
1188 **Dura/Venous Sinuses Hemangioma**
Anne G. Osborn, MD, FACR and Gregory L. Katzman, MD, MBA
1190 **Myeloma**
Anne G. Osborn, MD, FACR and Miral D. Jhaveri, MD
1194 **Skull and Meningeal Metastases**
Anne G. Osborn, MD, FACR and Miral D. Jhaveri, MD

https://CafePezeshki.IR

This page intentionally left blank

https://CafePezeshki.IR

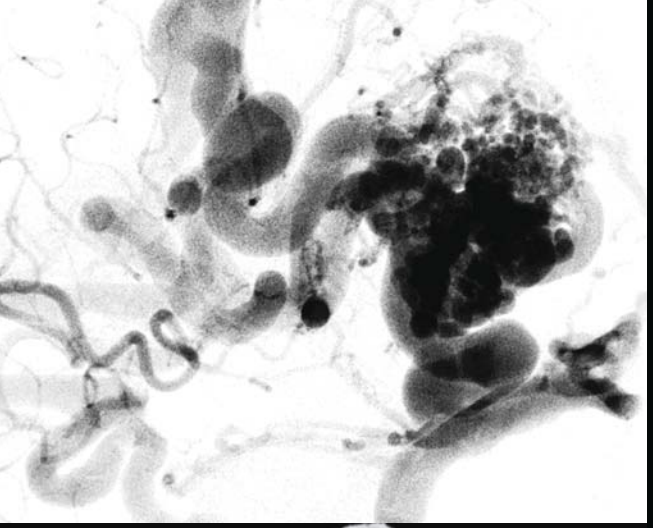

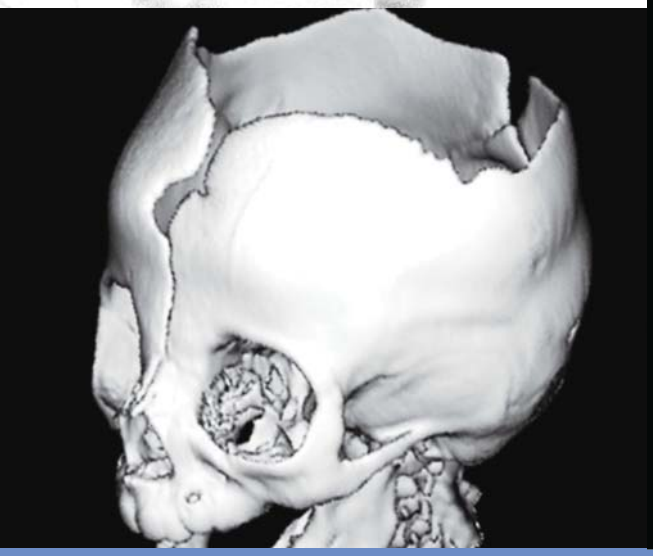

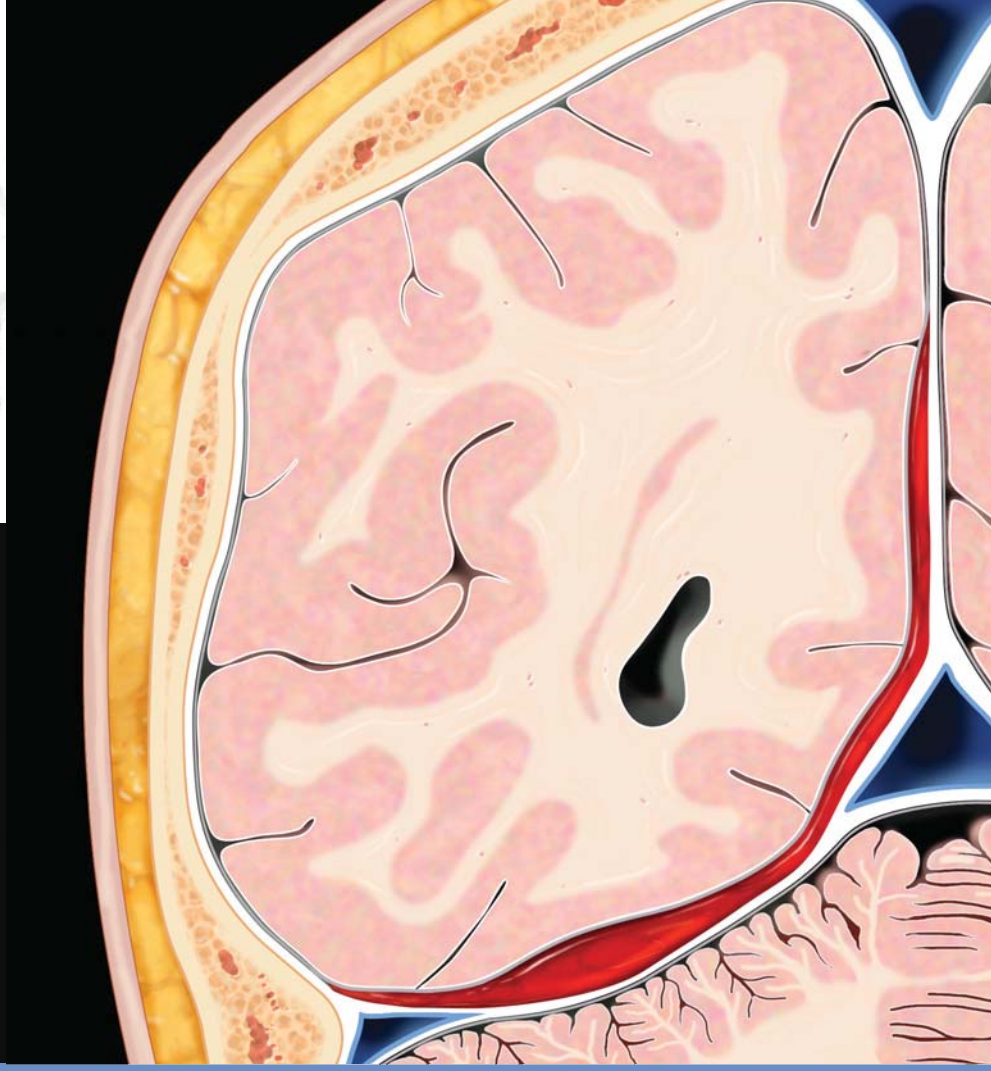

Diagnostic Imaging

Brain

THIRD EDITION

https://CafePezeshki.IR

PART I
SECTION 1

Congenital Malformations



Congenital Malformations Overview 4

Hindbrain Herniations, Miscellaneous Malformations

Chiari 1 8
Chiari 2 12
Chiari 3 16
Callosal Dysgenesis 18
Lipoma 22

Hindbrain Malformations

Dandy-Walker Continuum 26
Rhombencephalosynapsis 30
Unclassified Cerebellar Dysplasias 34
Molar Tooth Malformations (Joubert) 36

Disorders of Diverticulation/Cleavage

Holoprosencephaly 40
Holoprosencephaly Variants 44
Syntelencephaly (Middle Interhemispheric Variant) 48
Septooptic Dysplasia 52

Malformations of Cortical Development

Microcephaly 56
Congenital Muscular Dystrophy 60
Heterotopic Gray Matter 64
Polymicrogyria 68
Lissencephaly 72
Schizencephaly 76
Hemimegalencephaly 80

https://CafePezeshki.IR

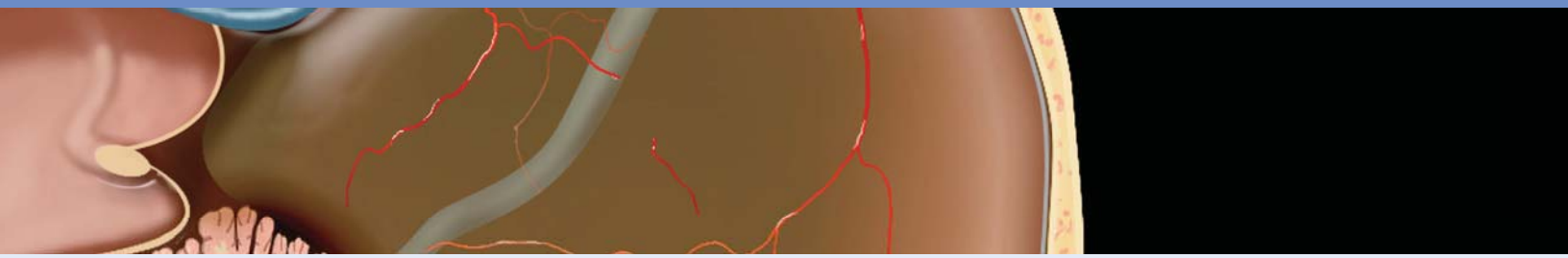

Familial Tumor/Neurocutaneous Syndromes

Neurofibromatosis Type 1	**84**
Neurofibromatosis Type 2	**88**
von Hippel-Lindau Syndrome	**92**
Tuberous Sclerosis Complex	**96**
Sturge-Weber Syndrome	**100**
Meningioangiomatosis	**104**
Basal Cell Nevus Syndrome	**106**
Hereditary Hemorrhagic Telangiectasia	**110**
Encephalocraniocutaneous Lipomatosis	**114**
Lhermitte-Duclos Disease	**118**
Neurocutaneous Melanosis	**122**
Aicardi Syndrome	**126**
Li-Fraumeni Syndrome	**128**
Schwannomatosis	**130**

https://CafePezeshki.IR

General Imaging Approach to Brain Malformations

Whenever an infant or child is referred for imaging because of either seizures or delayed development, a brain malformation is a possible cause. If the child appears dysmorphic in any way (low-set ears, abnormal facies, hypotelorism), the likelihood of an underlying brain malformation is even higher. In all such cases, imaging should be geared toward showing a structural abnormality. The imaging sequences should maximize contrast between gray matter and white matter, have high spatial resolution, and should be acquired as volumetric data whenever possible so that images can be reformatted in any plane or as a surface rendering. The high resolution and ability to reformat will aid in the diagnosis of subtle abnormalities. High-resolution T1-weighted volumetric images are essential for this purpose. If possible, volumetric T2-weighted images can be acquired, but the images must have excellent spatial resolution and sharp contrast between gray matter and white matter, which is not currently easy to achieve with volumetric T2-weighted sequences. If contrast between gray and white matter is poor with volumetric acquisition, acquire two dimensional sequences (2D) in at least two planes and with relatively thin (3-4 mm) section size. FLAIR images are not particularly useful in looking for malformations, as the contrast between gray matter and white matter is often poor. Diffusion-weighted images are not currently of diagnostic utility, although the use of diffusion tensor imaging (DTI) to acquire color fractional anisotropy (FA) maps and perform tractography is useful to better understand the connectivity of the malformed brain and may become clinically useful in the near future.

After acquisition of appropriate images, image analysis must take place in an orderly manner. The midline structures (including cerebral commissures, septum pellucidum, nose and rhinencephalon, pituitary gland, and hypothalamus), the cerebral cortex (cortical thickness, gyral pattern, and cortical-white matter junction), cerebral white matter (myelination, presence of nodules or clefts), the basal ganglia, the ventricular system (are all ventricles completely present and normally shaped), the interhemispheric fissure, and the midbrain hindbrain structures (brainstem and cerebellum) should all be scrutinized in every patient.

Evaluate the midline structures first, as many disease processes of children take place in the midline, including anomalies of the cerebral commissures (corpus callosum, anterior commissure, and hippocampal commissure), midline tumors (suprasellar, pineal, brainstem, and fourth ventricle), anomalies of the cerebellar vermis, and anomalies of the craniocervical junction. Anomalies of the cerebral commissures are the most common of brain malformations; more than 130 syndromes involving them have been described. Many of these are associated with anomalies of the hypothalamus, so remember to always look at the hypothalamus and pituitary gland to ensure that the posterior pituitary gland is in the sella turcica and not in the median eminence of the hypothalamus. The midline leptomeninges are important in commisural development, so make sure to look for other anomalies associated with abnormal midline leptomeninges, such as interhemispheric lipomas and interhemispheric cysts when the commissures are absent or dysmorphic. Remember that large cerebrospinal fluid (CSF) spaces in the posterior fossa (mega cisterna magna) are often associated with anomalies of the cerebellum. The reason for this has only recently been discovered. Several cerebellar growth factors derive from the overlying leptomeninges. Therefore, abnormalities of the cerebellar leptomeninges may result in anomalies of the cerebellum itself, as well as abnormalities of the surrounding CSF spaces. This is the basis of development of the Dandy-Walker malformation: It requires abnormal development of the cerebellum itself and of the overlying leptomeninges. Looking at the midline image also gives an idea of the relative head size by assessing the craniofacial ratio. In the normal neonate, the ratio of the cranial vault to the face on midline images is 5:1 or 6:1. By the age of 2 years, it should be 2.5:1, and by age 10 years, it should be about 1.5:1.

After looking at the midline, evaluate the brain from outside to inside. Start with the cerebral cortex. Is the thickness normal (2-3 mm)? If it is too thick, think of pachygyria or polymicrogyria. Is the cortical-white matter junction smooth or irregular? If it is irregular, think of polymicrogyria or the cobblestone cortex seen associated with congenital muscular dystrophies such as muscle-eye-brain disease. The location of these abnormalities is important as well. Pachygyria more severe in the parietal and occipital lobes suggests a mutation of *TUBA1A*, whereas pachygyria worst in the frontal lobes suggests a mutation of *DCX*. Similarly, there are many different polymicrogyria syndromes that depend upon the location of the polymicrogyria: Bilateral frontal polymicrogyria is a different entity than bilateral perisylvian polymicrogyria or bilateral parasagittal parietooccipital polymicrogyria; it is important to be specific in reporting the location of the abnormality. If the cortex is abnormally thin, one should think of a prenatal injury (infectious or ischemic), particularly if the thinning is focal or multifocal.

After the cortex, look at the cerebral white matter. Make sure myelination is appropriate for age (there are many sources of normal myelination charts, including journal articles and textbooks). Then, look for areas of abnormal myelination within the deep white matter. Diffuse layers of hypomyelination or amyelination associated with overlying polymicrogyria should raise suspicion for congenital cytomegalovirus infection. More localized foci of delayed or absent myelination are often seen in deep white matter of patients with congenital muscular dystrophy and in the subcortical white matter of those with focal cortical dysplasias (FCDs). With FCDs, the absent myelination may be localized to a gyrus or may extend centrally as a curvilinear cone-shaped abnormality coursing from the cortex to the superolateral margin of a lateral ventricle (this is known as the "transmantle" sign). Also, look for nodules of heterotopic gray matter in the periventricular or deep white matter. Subcortical heterotopia typically extend from the cortex all the way to the lateral ventricular wall, while periventricular nodular heterotopia are more localized to the immediate subependymal/periventricular region. Heterotopia might be difficult to differentiate from unmyelinated or injured white matter on T1-weighted images, so be sure to look at T2-weighted images or FLAIR images to ensure that the lesion is isointense to gray matter on all sequences.

The basal ganglia are sometimes abnormal in disorders of neuronal migration, as they are formed from neurons generated in the medial and lateral ganglionic eminences, the same germinal zones that produce GABAergic neurons that migrate to the cerebral cortex. In particular, the basal ganglia tend to be dysmorphic in appearance in patients with

https://CafePezeshki.IR

Brain Anomaly Imaging Checklist

Anomaly	Findings
Anomalies of the Cerebral Cortex	
Agyria/pachygyria	Thick cortex, smooth inner margin, few shallow sulci
Polymicrogyria	Thin undulating cortex, irregular inner margin
Cobblestone cortex	Thick cortex, irregular inner margin, abnormal myelin
Focal cortical dysplasia	Blurred gray-white junction, ± abnormal myelination
White Matter Abnormalities With Cortical Malformation	
Polymicrogyria	Enlarged perivascular spaces
Cobblestone cortex	Delayed myelination, patchy hypomyelination
Congenital cytomegalovirus	Deep layers of hypomyelination/gliosis
Focal cortical dysplasia	Focal subcortical hypomyelination
Malformations Associated With Absent Septi Pellucidi	
Septooptic dysplasia	
Holoprosencephaly	
Bilateral schizencephaly	
Bilateral polymicrogyria	
Rhombencephalosynapsis	
Malformations with prolonged severe hydrocephalus	

subcortical heterotopia. In addition, the hippocampi are often abnormal in malformations of cortical development. In patients with lissencephaly, in particular, the hippocampi are incompletely folded. Sometimes, the only structural abnormalities in children with developmental delay are hippocampal; always look to make sure that they are fully folded and not too round.

Always look at the entire interhemispheric fissure (IHF); if the cerebral hemispheres are continuous across the midline, holoprosencephaly should be diagnosed. In severe holoprosencephalies, the interhemispheric fissure is completely absent, whereas in milder forms of holoprosencephaly certain areas of the interhemispheric fissure will be absent (anterior IHF in semilobar holoprosencephaly, central IHF in syntelencephaly). Look at the septum pellucidum; absence of the septum is seen in corpus callosum dysgenesis/agenesis, septo-optic dysplasia, and in some cases of schizencephaly or bilateral polymicrogyria. While checking the septum, look at the lateral ventricles to ensure that they are normal in size and shape. Abnormally enlarged trigones and temporal horns are often associated with callosal anomalies and pachygyria. Enlarged frontal horns are often seen in bilateral frontal polymicrogyria.

Don't forget to look carefully at the posterior fossa; anomalies of the brainstem and cerebellum are commonly overlooked. Make sure that the 4th ventricle and cerebellar vermis are normally sized. In newborns, the vermis should extend from the inferior colliculi to the obex, while infants and older children should have a vermis that extends from the intercollicular sulcus to the obex. Also, make sure you see normal vermian fissures. If the fissuration of the vermis looks abnormal, look at an axial or coronal image to make sure the vermis is present; if the cerebellar hemispheres are continuous without a vermis between them, make a diagnosis of rhombencephalosynapsis. If the 4th ventricle has an abnormal rectangular shape (with a horizontal superior margin) with a narrow isthmus and small vermis, think about a molar tooth malformation. To confirm this diagnosis, look for the molar tooth sign of the lower midbrain, consisting of large, horizontal superior cerebellar peduncles extending posteriorly toward the cerebellum, and a longitudinal cleft in the superior vermis. Make sure that the components of the brainstem are of normal size; in a child, the height of the pons should be double that of the midbrain on the midline sagittal image. An important clue can be provided by looking at the size of the pons compared to that of the cerebellar vermis. Since much of the anterior pons is composed of the decussation of the middle cerebellar peduncles, development hypoplasia of the cerebellum is nearly always associated with hypoplasia of the ventral pons. If the pons is normal in the setting of a small cerebellum, it is most likely that the cerebellum lost volume near the end of gestation or after birth. Remember that a small posterior fossa, intracranial **hypo**tension, **or** intracranial **hyper**tension can result in descent of the cerebellum below the foramen magnum. Look for causes of a small posterior fossa (clival anomaly, anomaly of the craniovertebral junction), intracranial hypertension (space-occupying mass, hydrocephalus), or evidence of intracranial hypotension (large dural venous sinuses, large pituitary gland, "slumping" brainstem) before making a diagnosis of Chiari 1 malformation. Finally, remember to look at the size of the CSF spaces in the posterior fossa, enlargement of which may be a sign of abnormal leptomeningeal development.

https://CafePezeshki.IR

(Left) *Midline analysis using sagittal T1WI MR shows classic findings of Dandy Walker spectrum with a large posterior fossa cyst, high torcular and a small, upwardly rotated vermis. There is also a significant commissural anomaly with only a small corpus callosum remnant present. The rostrum and splenium are absent. The anterior commissure is present and appears normal.* **(Right)** *T2WI in the same case shows the 4th ventricle is open dorsally, contiguous with the huge posterior fossa cyst.*

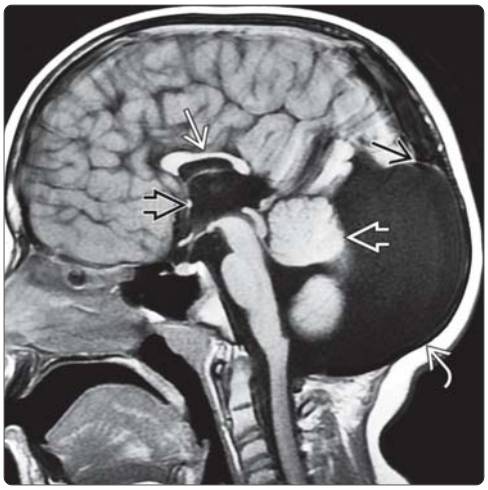

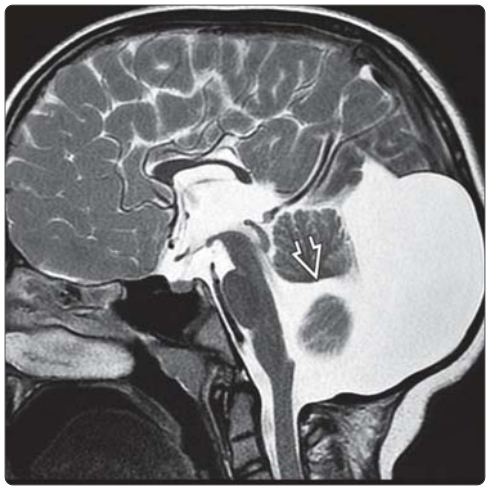

(Left) *Sagittal T1WI shows a hypoplastic callosum rostrum and splenium, plus a small interhemispheric lipoma.* **(Right)** *Sagittal T2WI shows a very small posterior fossa with a low-lying torcular and an elongated 4th ventricle that lacks a fastigium. This patient has a classic Chiari 2 malformation.*

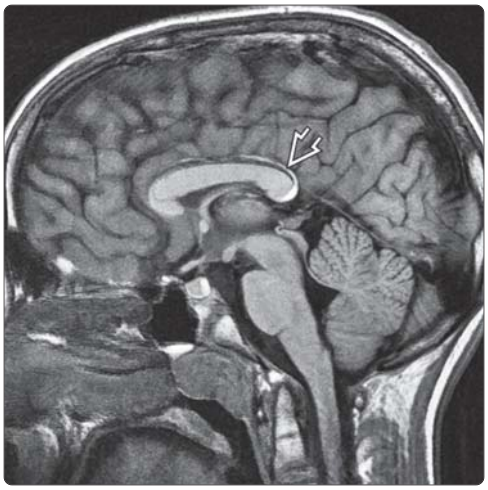

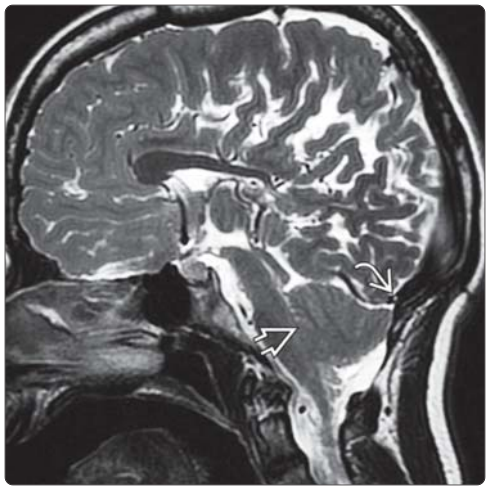

(Left) *Midline analysis of a sagittal T2WI shows a normal-sized posterior fossa. The cerebellar tonsils are pointed and displaced inferiorly 1 cm below the foramen magnum. Note cord hyperintensity, suggesting a "pre-syrinx" state in this case of Chiari 1 malformation.* **(Right)** *Axial T2WI in the same case shows the mass-like thickening of the right medial parietal gray matter and distorted sulcal-gyral pattern of cortical dysplasia.*

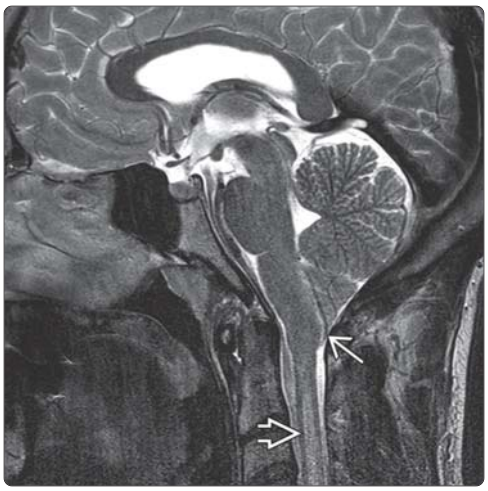

https://CafePezeshki.IR

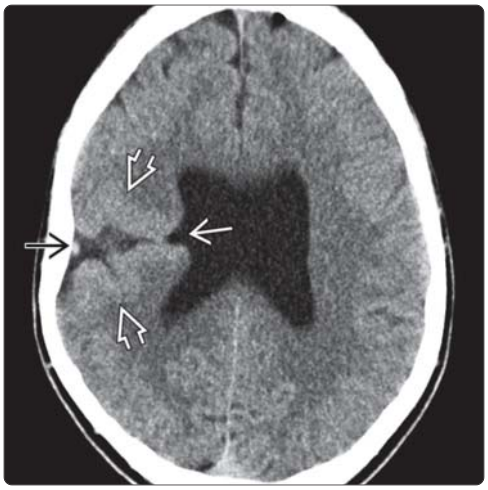

(Left) *Axial NECT scan in an 18-year-old male with seizures shows a unilateral schizencephalic cleft extending from the pial surface of the brain ⇨ to the ventricle. Note the characteristic CSF "nipple" ➡ at the ventricular margin. The cleft is lined by thickened, dysplastic gray matter ➡.* **(Right)** *Axial T2WI shows bilateral schizencephalic clefts ➡ lined by dysplastic gray matter ➡. Note the abnormal cortical veins ⇨ associated with the clefts.*

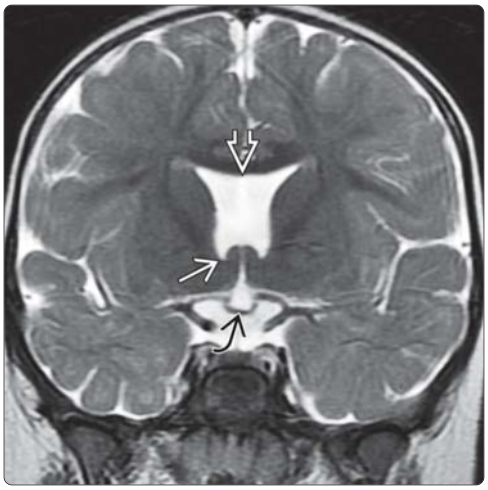

(Left) *Axial T2WI MR allows analysis of midline and shows absent interhemispheric fissure in frontal lobes (white matter continuous across midline ➡). This finding, plus the absence of frontal horns, gives the diagnosis of holoprosencephaly.* **(Right)** *Analysis of coronal images shows a squared-off appearance to the lateral ventricles with inferiorly pointed frontal horns ➡, absent septum pellucidum ➡, and hypoplastic optic chiasm ⇨ characteristic of septooptic dysplasia.*

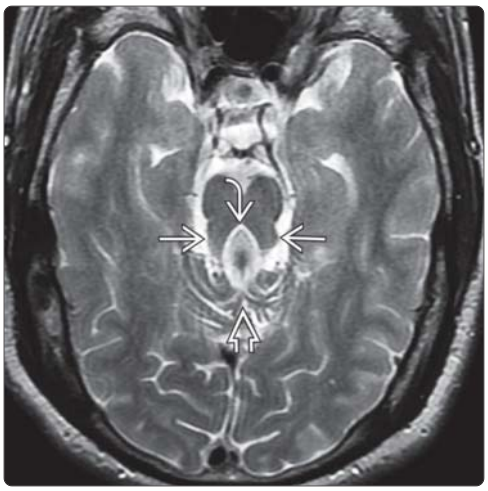

(Left) *Midline analysis of posterior fossa structures shows an upwardly convex superior 4th ventricle and a dysplastic-appearing vermis.* **(Right)** *Axial T2WI in the same case shows the elongated 4th ventricle ➡, cleft vermis ➡, and thickened, horizontally oriented superior cerebellar peduncles ➡ forming the classic molar tooth sign of Joubert syndrome.*

https://CafePezeshki.IR

KEY FACTS

TERMINOLOGY

- Chiari 1 malformation (CM1)
  - CM1: Constellation of findings (not a disease, not simply a measurement)
- No clear consensus definition of what constitutes CM1
  - Traditional: Elongated, peg-shaped cerebellar tonsils extend below foramen magnum into upper cervical spinal canal
  - The "5 mm" criterion for tonsillar displacement below basion-opisthion line is flawed criterion
    - Tonsillar position is a morphometric distribution and also changes with time
    - Tonsillar position **plus** shape/configuration (elongated, pointed)
    - Tonsillar position also risk factor for syrinx (the lower the tonsils, the higher the risk)
  - "Crowding" of posterior fossa with compression of CSF spaces
  - Evaluate skull base, upper cervical spine
    - PF may be undersized, shallow (especially children)
    - Short clivus, CVJ assimilation anomalies common

TOP DIFFERENTIAL DIAGNOSES

- Normal anatomic variant (normal-shaped tonsils below FM)
- Intracranial hypotension
  - Critical not to mistake this for CM1
- Acquired tonsillar herniation (don't call "acquired Chiari 1")
- "Complex Chiari malformation" ("Chiari 1.5" is neurosurgical term)
  - Tonsillar herniation complicated by other abnormalities (caudal descent of brainstem with low-lying obex, bony anomalies, such as "retroflexed" odontoid)

CLINICAL ISSUES

- Up to 50% of CM1 is asymptomatic

DIAGNOSTIC CHECKLIST

- Look for findings of intracranial hypotension before making diagnosis of CM1

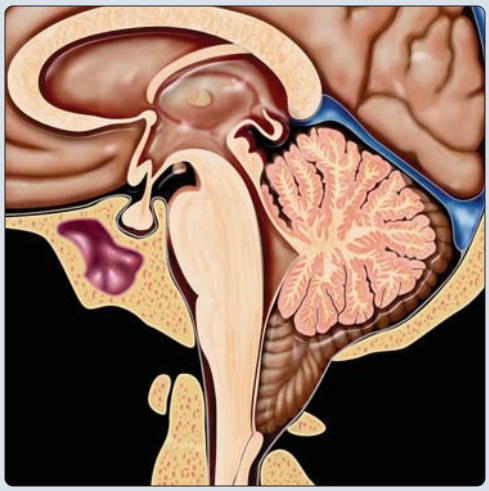

(Left) *Sagittal graphic demonstrates pointed peg-like tonsils extending below foramen magnum, elongating the normally positioned 4th ventricle.* **(Right)** *Sagittal T2WI in a 23-year-old male with classic Chiari 1 malformation shows low-lying pointed tonsils ➡ and hyperintensity in the upper cervical cord ➡ that may represent "presyrinx" state.*

(Left) *Sagittal T1WI MR shows normal 4th ventricle position and appearance. The fastigium ➡ is in normal position, helping to distinguish from Chiari 2 malformation. There is inferior displacement of the ectopic cerebellar tonsils ➡ through the foramen magnum with odontoid process retroflexion and clivus foreshortening.* **(Right)** *Axial T2WI MR confirms inferior displacement of ectopic cerebellar tonsils ➡ through the foramen magnum, producing foramen magnum crowding.*

https://CafePezeshki.IR

TERMINOLOGY

Abbreviations

- Chiari 1 malformation (CM1)

Synonyms

- Chiari type I

Definitions

- No clear consensus definition of what constitutes CM1
  - Traditional: Elongated, peg-shaped cerebellar tonsils extend below foramen magnum into upper cervical spinal canal
    - The "5 mm" criterion for tonsillar displacement below basion-opisthion line is flawed criterion
      - Tonsillar position is a morphometric distribution and also changes with time
  - CM1: Constellation of findings (not a disease, not simply a measurement)
    - Tonsillar position **plus** shape/configuration (elongated, pointed)
      - Tonsillar position also risk factor for syrinx (the lower the tonsils, the higher the risk)
    - "Crowding" of posterior fossa with compression of CSF spaces
    - Evaluate skull base, upper cervical spine
      - Short clivus, craniovertebral junctioni (CVJ) assimilation anomalies common

IMAGING

General Features

- Best diagnostic clue
  - Combination of inferiorly displaced "pointed" tonsils with "crowded" posterior fossa, effaced retrocerebellar CSF spaces at foramen magnum/upper cervical level
- Morphology
  - Low-lying, pointed peg-like tonsils with oblique vertical sulci, elongated but normally located 4th ventricle (normal dorsally-pointed fastigium)

CT Findings

- Bone CT
  - Often normal; abnormal cases → short clivus, CVJ segmentation/fusion anomalies

MR Findings

- T1WI
  - Pointed (not rounded) tonsils ≥ 5 mm below foramen magnum
  - "Tight" foramen magnum with small/absent cisterns
  - ± 4th ventricle elongation, hindbrain anomalies
- T2WI
  - Oblique tonsillar folia (sergeant's stripes like)
  - ± short clivus → apparent descent of 4th ventricle, medulla
  - ± syringohydromyelia (14-75%)
- MR cine
  - Disorganized CSF pulsation, ↑ brainstem/cerebellar tonsil motion → ↑ peak systolic velocity, ↓ flow through foramen magnum
    - Tonsillar pulsatility may be better predictor than CSF flow

Imaging Recommendations

- Best imaging tool
  - Multiplanar MR ± sagittal cine MR

DIFFERENTIAL DIAGNOSIS

Normal Tonsillar Displacement Below Foramen Magnum

- Tonsils may normally lie below foramen magnum
- Unless also pointed, with "crowded" appearance around FM, probably not CM1 and is normal anatomic variant

Intracranial Hypotension

- "Pull from below" (LP shunt, CSF leak) secondary to intracranial hypotension
  - "Sagging" brainstem, tonsillar herniation, smooth dural enhancement, dilated epidural plexus, retrospinal C1/C2 fluid collection, spinal hygroma
- Don't mistake this for Chiari 1
  - FM/C1 decompression can exacerbate CSF leak with disastrous consequences

Acquired Tonsil Herniation (Acquired Chiari 1)

- Acquired basilar invagination → small posterior fossa
  - Osteogenesis imperfecta
  - Paget disease
  - Craniosynostosis
  - Rickets
  - Achondroplasia
  - Acromegaly
- "Push from above"
  - Chronic VP shunt; thick skull, premature sutural fusion, arachnoidal adhesions
  - ↑ intracranial pressure (ICP), intracranial mass

Complex Chiari Malformation

- Sometimes called "Chiari 1.5" by neurosurgeons
  - Tonsillar herniation with caudal descent of brainstem (low-lying obex, nucleus gracilis)
  - Bony anomalies (such as retroflexed odontoid, C0-C1 assimilation, short clivus, etc.)
  - More severe clinical phenotype than CM1, may require anterior, as well as posterior, decompression

PATHOLOGY

General Features

- Etiology
  - Hydrodynamic theory
    - Systolic piston-like descent of impacted tonsils/medulla → plugging of CSF pathway at foramen magnum
    - During diastole, rapid recoil of brainstem/tonsils disimpacts foramen magnum, permits normal CSF diastolic pulsation
  - Posterior fossa underdevelopment theory
    - Underdeveloped occipital somites of paraxial mesoderm → small posterior fossa → secondary tonsillar herniation
    - But: Not all CM1 patients have small posterior fossae
- Genetics

https://CafePezeshki.IR

- Autosomal dominant inheritance with reduced penetrance or autosomal recessive inheritance
- Syndromic/familial associations
  - Velocardiofacial/microdeletion chromosome 22, Williams syndrome, craniosynostosis, achondroplasia, Hajdu-Cheney syndrome, and Klippel-Feil syndrome
- Associated abnormalities
  - 4th occipital sclerotome syndromes (50%): Short clivus, CVJ segmentation/fusion anomalies
  - Osseous skull base/skeletal anomalies (25-50%)
    - Scoliosis ± kyphosis (42%); left thoracic curve
    - Retroflexed odontoid process (26%)
    - Platybasia, basilar invagination (25-50%)
    - Klippel-Feil syndrome (5-10%)
    - Incomplete C1 ring ossification (5%)
    - Atlantooccipital assimilation (1-5%)
  - Syringomyelia (30-60%); 60-90% in symptomatic CM1 patients
    - Most common C4-C6; holocord hydrosyringomyelia, cervical/upper thoracic syrinx, syringobulbia uncommon
  - Hydrocephalus (11%)
- FM arachnoid adhesions, obstruction → decreased communication between cranial, spinal CSF compartments

Staging, Grading, & Classification

- Diagnostic criteria: Herniation of at least 1 cerebellar tonsil > 5 mm or herniation of both tonsils ≥ 3-5 mm below line connecting basion with opisthion
  - Herniation of both tonsils ≥ 3-5 mm below foramen magnum + syrinx, cervicomedullary kink, 4th ventricular elongation, or pointed tonsils → congenital CM1
  - Tonsil herniation ≤ 5 mm does not exclude CM1

Gross Pathologic & Surgical Features

- Herniated, sclerotic tonsils grooved by opisthion
- Arachnoidal scarring and adhesions at foramen magnum

Microscopic Features

- Tonsillar softening or sclerosis with Purkinje/granular cell loss

CLINICAL ISSUES

Presentation

- Most common signs/symptoms
  - Up to 50% asymptomatic (especially if ≤ 5 mm caudal displacement)
  - Most common symptoms at presentation are headache, neck pain
  - Symptomatic patients present with constellation of findings
    - Sudden death (rare)
    - Suboccipital headache, cranial nerve palsy, ocular disturbances, otoneurologic dysfunction
    - Cord motor or sensory abnormalities, gait disturbance, neuropathic joint
    - Tonsillar herniation > 12 mm nearly always symptomatic; ~ 30% with tonsils 5-10 mm below foramen magnum asymptomatic
    - CM1 patients with syrinx nearly always present with symptoms referable to syrinx; if syrinx extends into medulla, bulbar symptoms predominate
  - Trauma is common precipitating event for symptom onset (24%)
- Clinical profile
  - Clinical CM1 syndrome: Headache, pseudotumor-like episodes, Ménière disease-like syndrome, lower cranial nerve and spinal cord signs

Demographics

- Age
  - 10 months to 65 years; syrinx, congenital CVJ anomalies hasten presentation
- Gender
  - F > M (3:2)
- Epidemiology
  - Incidence: 0.01-0.6% all age groups, 0.9% pediatric patient groups
  - Asymptomatic CM1 discovered incidentally on imaging relatively common; perhaps best described as cerebellar tonsillar ectopia)

Natural History & Prognosis

- Natural history not clearly understood
  - Many patients asymptomatic, CM1 discovered incidentally
  - Increasing ectopia → ↑ risk of syrinx
- Children respond better to treatment than adults

DIAGNOSTIC CHECKLIST

Consider

- Degree of tonsillar correlates with clinical severity
- Unless tonsils > 5 mm and pointed ± "crowded posterior fossa" probably not clinically significant

Image Interpretation Pearls

- Don't use 5 mm cut-off point alone to diagnosis CM1 (with pathological and clinical implications)

SELECTED REFERENCES

1. Alperin N et al: Imaging-Based Features of Headaches in Chiari Malformation Type I. Neurosurgery. ePub, 2015
2. Bond AE et al: Changes in cerebrospinal fluid flow assessed using intraoperative MRI during posterior fossa decompression for Chiari malformation. J Neurosurg. 1-8, 2015
3. Quon JL et al: Multimodal evaluation of CSF dynamics following extradural decompression for Chiari malformation Type I. J Neurosurg Spine. 1-9, 2015
4. Roller LA et al: Demographic confounders in volumetric MRI analysis: is the posterior fossa really small in the adult Chiari 1 malformation? AJR Am J Roentgenol. 204(4):835-41, 2015
5. Strahle J et al: Syrinx location and size according to etiology: identification of Chiari-associated syrinx. J Neurosurg Pediatr. 1-9, 2015
6. Godzik J et al: Relationship of syrinx size and tonsillar descent to spinal deformity in Chiari malformation Type I with associated syringomyelia. J Neurosurg Pediatr. 13(4):368-74, 2014
7. Lee S et al: Surgical outcome of Chiari I malformation in children: clinico-radiological factors and technical aspects. Childs Nerv Syst. 30(4):613-23, 2014
8. McVige JW et al: Imaging of Chiari type I malformation and syringohydromyelia. Neurol Clin. 32(1):95-126, 2014
9. Moore HE et al: Magnetic resonance imaging features of complex Chiari malformation variant of Chiari 1 malformation. Pediatr Radiol. 44(11):1403-11, 2014

https://CafePezeshki.IR

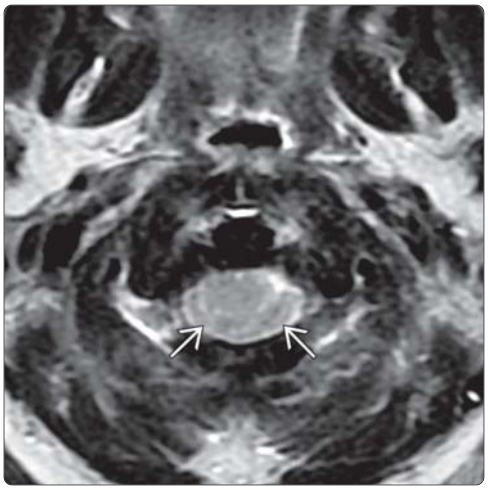

(Left) *Sagittal T1WI MR (osteopetrosis) demonstrates severe cerebellar tonsillar ectopia, with extension of the elongated cerebellar tonsils into the upper cervical canal to the C2-C3 level. Hypointense marrow signal reflects diffuse sclerosis.* **(Right)** *Axial T2WI MR (osteopetrosis) reveals characteristic crowding of the foramen magnum related to CM1, with extension of the ectopic cerebellar tonsils into the upper cervical canal.*

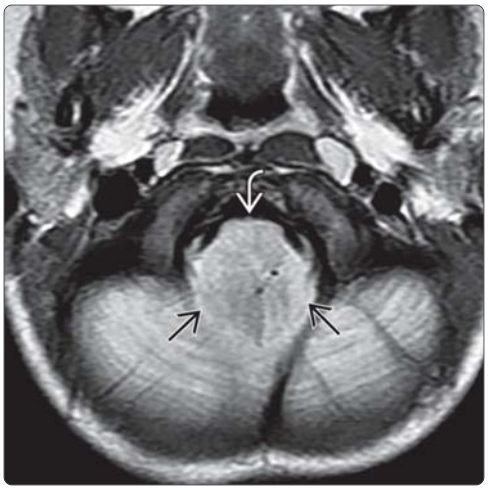

(Left) *Sagittal T2WI MR (asymptomatic CM1) demonstrates severe cerebellar tonsillar ectopia. The tonsils produce deformation of the upper cervical spinal cord and abnormal cord T2 prolongation reflecting edema and potentially an early presyrinx state.* **(Right)** *Axial T2WI MR (asymptomatic CM1) reveals caudal extension of ectopic cerebellar tonsils into the foramen magnum, completely effacing the basilar cisterns and displacing the adjacent spinal cord.*

(Left) *Sagittal T2WI MR depicts marked cerebellar tonsillar ectopia with normal tectum and 4th ventricular position. The clivus is mildly foreshortened and dens retroflexed. There is central intramedullary edema in the cervical spinal cord without frank syringomyelia, a finding that has been described as a "presyrinx" state.* **(Right)** *Axial T2WI MR confirms displacement of the ectopic cerebellar tonsils through the crowded foramen magnum, producing foramen magnum crowding.*

https://CafePezeshki.IR

KEY FACTS

TERMINOLOGY

- Complex hindbrain malformation
- Virtually 100% associated with neural tube closure defect (NTD), usually lumbar myelomeningocele (MMC)

IMAGING

- Crowded posterior fossa, widened tentorial incisura, tectal beaking, inferior vermian displacement
- Cascade or waterfall of cerebellum/brainstem downward
  - Uvula/nodulus/pyramid of vermis → sclerotic peg
  - Cervicomedullary kink (70%)
  - Towering cerebellum → compresses midbrain, associated beaked tectum
  - 4th ventricle elongated with no posterior point (fastigium)
- Lacunar skull: Focal calvarial thinning with scooped-out appearance

TOP DIFFERENTIAL DIAGNOSES

- Chiari 1 malformation
- Chiari 3 malformation
- Intracranial CSF hypotension
- Severe, chronic shunted hydrocephalus (congenital)

PATHOLOGY

- Secondary to sequelae of CSF leakage through open spinal dysraphism during gestation (4th fetal week)
- Methylenetetrahydrofolate reductase (*MTHFR*) mutations → abnormal folate metabolism
- Spine- and brain/skull-associated anomalies common

DIAGNOSTIC CHECKLIST

- Towering cerebellum, downward vermian displacement, ± brainstem compression diagnostic for Chiari 2 especially if MMC present

(Left) *Sagittal graphic of the posterior fossa and upper cervical spine demonstrates characteristic findings of Chiari 2 malformation, including callosal dysgenesis ⇨, tectal beaking ➡, small posterior fossa, vermian ectopia ➡, and medullary kinking ⇨.* **(Right)** *Sagittal T1WI MR reveals characteristic Chiari 2 malformation findings. Note the tectal beaking ➡, vermian displacement ➡ through the foramen magnum, large massa intermedia ➡, and dysplastic corpus callosum ⇨.*

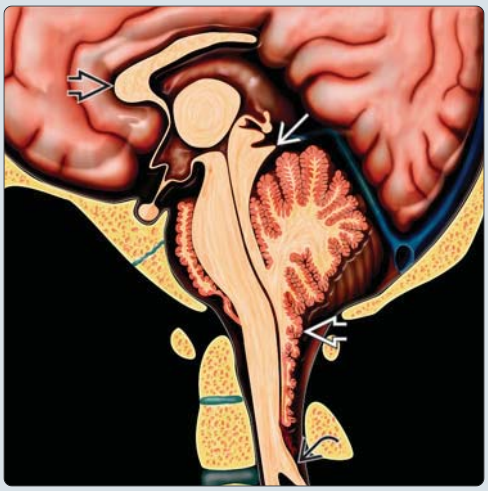

(Left) *Sagittal T2WI MR confirms characteristic findings of Chiari 2 malformation, including tectal beaking ➡, vermian displacement through the foramen magnum ➡, "towering" cerebellum ➡, large massa intermedia ⇨, and dysplastic corpus callosum ⇨.* **(Right)** *Axial T2WI MR shows characteristic posterior fossa crowding at the foramen magnum, reflecting small dimensions of the posterior fossa combined with cerebellar ectopia and vermian displacement through the foramen magnum.*

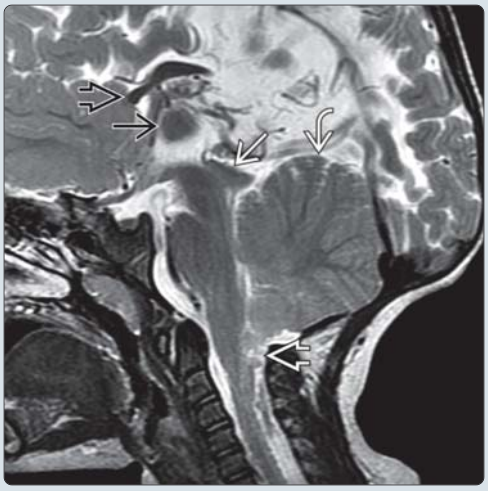

https://CafePezeshki.IR

TERMINOLOGY

Abbreviations

- Chiari 2 malformation (CM2)

Synonyms

- Chiari type II

Definitions

- Complex hindbrain malformation
  - Virtually 100% associated with neural tube closure defect (NTD), usually lumbar myelomeningocele (MMC)
    - Rare reports in closed spinal dysraphism (probably misinterpreted Chiari 1)

IMAGING

General Features

- Best diagnostic clue
  - Downward herniation of cerebellar vermis plus myelomeningocele
- Location
  - Posterior fossa (PF), upper cervical spine; syrinx may involve entire cord
- Size
  - Posterior fossa smaller than normal
- Morphology
  - Cerebellum "wraps" around medulla and "towers" through incisura, with "beaked" tectum and heart-shaped midbrain

CT Findings

- NECT
  - Crowded posterior fossa, widened tentorial incisura, tectal beaking, and inferior vermian displacement
- Bone CT
  - Small PF
    - Low-lying tentorium/torcular inserts near foramen magnum
    - Large, funnel-shaped foramen magnum with "notched" opisthion
    - "Scalloped" posterior petrous pyramids, clivus
  - Posterior C1 arch anomalies (66%), enlarged cervical canal
  - Lacunar skull: Focal calvarial thinning with scooped-out appearance
    - Mostly resolved by 6 months, but some scalloping of inner table often persists into adulthood

MR Findings

- T1WI
  - Cascade or waterfall of cerebellum/brainstem downward
    - Uvula/nodulus/pyramid of vermis → sclerotic peg
    - Cervicomedullary kink (70%)
    - Towering cerebellum → compresses midbrain, associated beaked tectum
    - 4th ventricle elongated with no posterior point (fastigium)
  - Open spinal dysraphism, MMC ~ 100% (lumbar > > cervical)
  - Hydrosyringomyelia (20-90%)
- T2WI
  - Similar to T1WI + hyperintense, gliotic cerebellar tissue
  - ± 4th ventricular lesions (rare)
    - Roof of 4th ventricle adjacent/within choroid plexus
    - Glial or arachnoidal cysts, glial or choroidal nodules, subependymoma
- MR cine
  - Phase contrast cine MR → restricted CSF flow through foramen magnum
- Diffusion tensor imaging (DTI)
  - Fractional anisotropy (FA) map and quantitative analysis defines callosal dysgenesis, confirms abnormal white matter architecture

Ultrasonographic Findings

- Grayscale ultrasound
  - Fetal obstetrical ultrasound (US) pivotal for early diagnosis
    - MMC may be identified as early as 10 weeks
    - Characteristic brain findings (lemon and banana signs) seen as early as 12 weeks

Imaging Recommendations

- Best imaging tool
  - Multiplanar MR for initial brain, spine evaluation
  - Follow-up brain CT or MR to assess hydrocephalus
  - Cervical spine MR for progressive brainstem or spinal symptoms

DIFFERENTIAL DIAGNOSIS

Chiari 1

- No association with myelomeningocele
- Tonsillar herniation (not vermis)

Chiari 3

- Brainstem, cerebellum herniating through C1-C2 spinal dysraphism

Intracranial Hypotension

- Symptomatic expression of low CSF pressure; distinguishable by clinical onset and symptoms
- Slumping posterior fossa with pons compressed against clivus, dural thickening/enhancement

Severe, Chronic Shunted Hydrocephalus (Congenital)

- May cause collapsed brain, upwardly herniated cerebellum

PATHOLOGY

General Features

- Etiology
  - Secondary to sequelae of CSF leakage through open spinal dysraphism during gestation (4th fetal week)
    - Abnormal neurulation → CSF escapes through NTD → failure to maintain 4th ventricular distention → hypoplastic PF chondrocranium → displaced/distorted PF contents
    - Exceedingly rare cases of closed spinal dysraphism with Chiari 2 malformation may contradict this theory
  - Alternative theory proposes association between Chiari 2 malformation and myelomeningocele is due to rostral and caudal neural tube dysgenesis

https://CafePezeshki.IR

- Genetics
  - Methylenetetrahydrofolate reductase (*MTHFR*) mutations associated with abnormal folate metabolism
    - *MTHFR* mutations **plus** folate deficiency → ↑ risk NTD → Chiari 2
    - 4-8% risk of 2nd affected child
- Associated abnormalities
  - Spine
    - Open dysraphism (MMC) ~ 100% (lumbar > > cervical)
    - Posterior arch C1 anomalies (66%)
    - Syringohydromyelia (20-90%)
    - Diastematomyelia (5%)
    - Klippel-Feil syndrome
    - Cervical myelocystocele
  - Brain/skull
    - Corpus callosum (CC) dysgenesis (90%), aqueductal stenosis, rhombencephalosynapsis, gray matter malformations, absent septum pellucidum, fused forniceal columns
    - Lacunar skull (Lückenschädel)
- Hydrocephalus and severity of brain malformation relate to size of PF, degree of caudal hindbrain descent

Gross Pathologic & Surgical Features

- Small PF → contents shift down into cervical spinal canal
  - Cerebellar hemispheres/tonsils "wrap" around medulla
  - Pons/cranial nerve roots often elongated
  - Compressed/elongated/low 4th ventricle → pouch in cervical canal
  - Medullary kink
  - ± syringohydromyelia

Microscopic Features

- Purkinje cell loss, sclerosis within herniated tissues

CLINICAL ISSUES

Presentation

- Most common signs/symptoms
  - Neonate: MMC, enlarging head circumference ± hydrocephalus symptoms
  - Older child/adult: Clinical hydrocephalus, symptoms referable to tethered cord (MMC repair)
  - All age groups: Varying degrees of lower extremity paralysis/sphincter dysfunction/bulbar signs
- Clinical profile
  - Usually presents within context of known MMC
    - Infants: Enlarging head circumference
    - Child/adult: Known Chiari 2 malformation, signs of hydrocephalus/shunt failure ± bulbar symptoms
- Laboratory
  - Fetal screening: ↑ alpha-fetoprotein

Demographics

- Age
  - Usually presents at birth with MMC ± hydrocephalus
- Gender
  - M = F
- Epidemiology
  - Incidence: 0.44 per 1,000 births, ↓ with folate replacement therapy

Natural History & Prognosis

- Most common cause of death in MMC
  - Brainstem compression/hydrocephalus, intrinsic brainstem "wiring" defects
- Progression of spinal neurological deficits is rare; suspect hydrocephalus, associated undiagnosed spinal deformity (diastematomyelia), tethered cord
- Cerebellar tonsil/vermian ectopia may "improve" (ascend) following postnatal repair

Treatment

- Folate supplement for pregnant mothers (preconception → 6 weeks post conception) significantly decreases MMC risk
- Surgical management
  - Chiari decompression with resection of posterior foramen magnum, C1 ring
  - CSF diversion/shunting
  - Fetal MMC repair in selected patients may ameliorate Chiari 2 severity

DIAGNOSTIC CHECKLIST

Consider

- Brain/spinal axis MR to detect presence of Chiari 2, assess severity, look for complications

Image Interpretation Pearls

- Low torcular herophili indicates small posterior fossa
- CT or MR showing towering cerebellum, downward vermian displacement, ± brainstem compression diagnostic of Chiari 2

SELECTED REFERENCES

1. Cesmebasi A et al: The Chiari malformations: A review with emphasis on anatomical traits. Clin Anat. 28(2):184-194, 2015
2. Akbari SH et al: Surgical management of symptomatic Chiari II malformation in infants and children. Childs Nerv Syst. Epub ahead of print, 2013
3. Messing-Jünger M et al: Primary and secondary management of the Chiari II malformation in children with myelomeningocele. Childs Nerv Syst. 29(9):1553-62, 2013
4. Sweeney KJ et al: Spinal level of myelomeningocele lesion as a contributing factor in posterior fossa volume, intracranial cerebellar volume, and cerebellar ectopia. J Neurosurg Pediatr. 11(2):154-9, 2013
5. Citton V et al: Chiari 2 without spinal dysraphism: does it blow a hole in the pathogenesis? J Child Neurol. 27(4):536-9, 2012
6. Geerdink N et al: Essential features of Chiari II malformation in MR imaging: an interobserver reliability study–part 1. Childs Nerv Syst. 28(7):977-85, 2012
7. Juranek J et al: The cerebellum in children with spina bifida and Chiari II malformation: Quantitative volumetrics by region. Cerebellum. 9(2):240-8, 2010
8. Luigetti M et al: Improvement of obstructive sleep apneas caused by hydrocephalus associated with Chiari malformation Type II following surgery. J Neurosurg Pediatr. 6(4):336-9, 2010
9. Morota N et al: Postnatal ascent of the cerebellar tonsils in Chiari malformation Type II following surgical repair of myelomeningocele. J Neurosurg Pediatr. 2(3):188-93, 2008
10. Vinck A et al: Arnold-Chiari-II malformation and cognitive functioning in spina bifida. J Neurol Neurosurg Psychiatry. 77(9):1083-6, 2006

https://CafePezeshki.IR

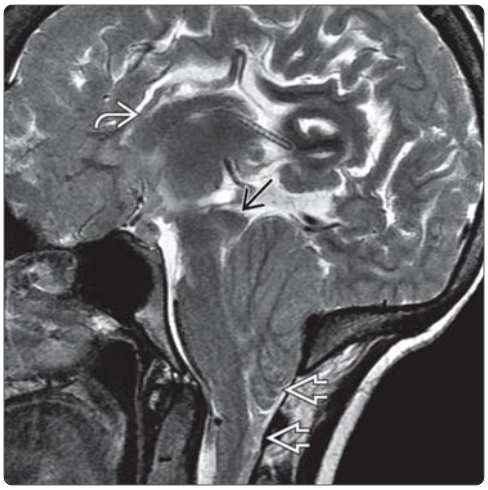

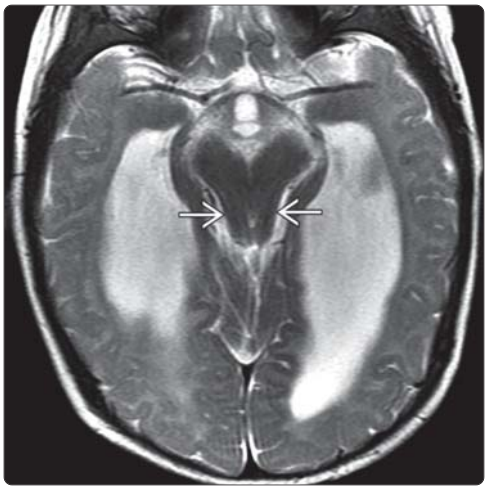

(Left) *Sagittal T2WI MR of the brain shows characteristic Chiari 2 findings, with very small posterior fossa size, prominent tectal beak, and vermian/tonsillar extension through the foramen magnum. The corpus callosum is severely dysplastic and the ventricles small following CSF shunting.* **(Right)** *Axial T2WI MR depicts enlargement of the occipital horns of the lateral ventricles (colpocephaly) related to callosal dysgenesis in conjunction with beaked tectum.*

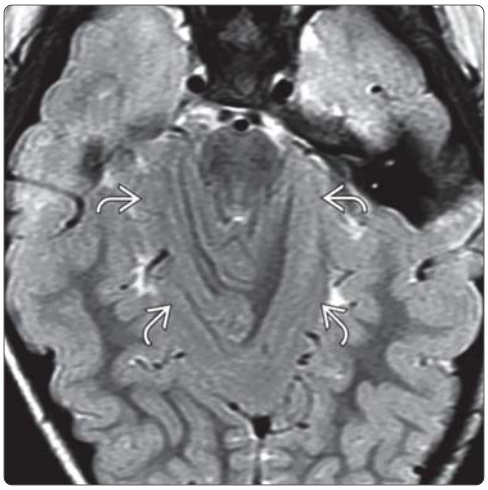

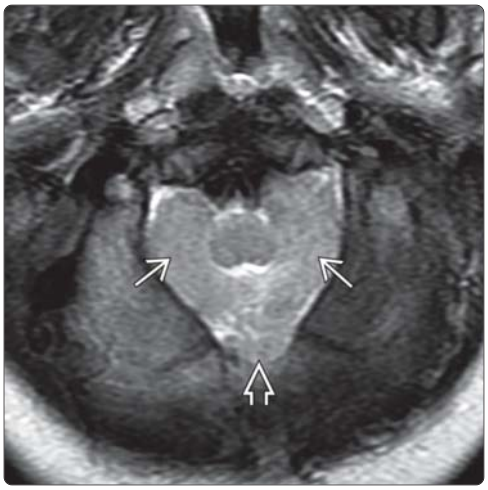

(Left) *Axial T2WI MR at the posterior fossa level demonstrates the classic axial image manifestation of the towering cerebellum extending through the wide tentorial incisura.* **(Right)** *Axial T2WI MR performed at the foramen magnum level depicts characteristic crowding of the inferior posterior fossa. Both of the cerebellar tonsils, as well as vermis, are inferiorly displaced into the foramen magnum.*

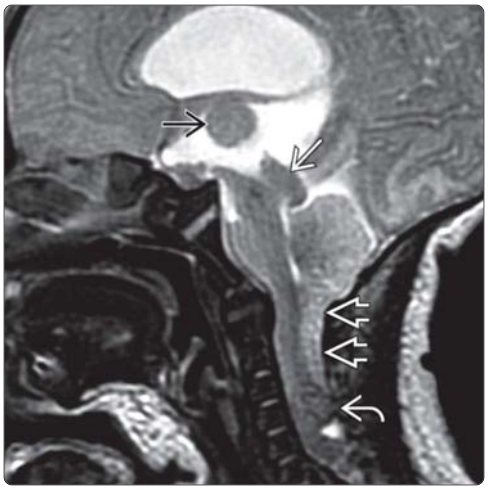

(Left) *Sagittal T2WI MR depicts marked vermian ectopia and prominent medullary kink positioned lower than typically seen at the C4 level. Note also the dysplastic beaked tectum and prominent massa intermedia.* **(Right)** *Sagittal T2WI MR shows crowded posterior fossa with vermian ectopia, large cervicothoracic cord syrinx as well as sizable focal cervicomedullary syrinx (syringobulbia). Note the hyperintense gliotic changes of scarred vermis.*

https://CafePezeshki.IR

KEY FACTS

TERMINOLOGY

- Chiari 3 malformation (CM3)
- Synonyms: Chiari III, rhombencephalocele

IMAGING

- Low occipital or high cervical meningoencephalocele containing cerebellum ± brainstem, meninges, vessels, CSF
- Midline bone defect within supraoccipital bone, opisthion

TOP DIFFERENTIAL DIAGNOSES

- Isolated occipital encephalocele
- Other occipital encephaloceles
  - Iniencephaly
  - Syndromic occipital encephalocele

PATHOLOGY

- Severity classified by sac contents
- Cephalocele contents: Meninges, cerebellum, brainstem ± cervical cord, occipital poles, vasculature
  - Disorganized (neuronal migration anomalies, cortical dysplasias) and gliotic brain tissue
  - Lining of sac may show gray matter heterotopias
- Associated abnormalities: Corpus callosum anomalies, gray matter heterotopia, syringohydromyelia, tethered cord

CLINICAL ISSUES

- Microcephaly, severe developmental delay, spasticity, hypotonia, seizures
- Mechanical brainstem traction, respiratory deterioration, lower cranial nerve dysfunction

DIAGNOSTIC CHECKLIST

- Occipitocervical cephalocele containing cerebellum ± brainstem in conjunction with C1-C2 spina bifida = Chiari 3 malformation

(Left) *Sagittal T2WI MR reveals a large defect in the ventral chondral portion of the supraoccipital bone and opisthion of foramen magnum. Gliotic cerebellar tissue ⇨ protrudes into a large sac. Note the displacement of the brainstem ⇨ and basilar artery ⇨.* **(Right)** *Sagittal T1WI MR shows a large meningoencephalocele composed of meninges, CSF, cerebellum ⇨, brainstem ⇨, and upper cervical spinal cord herniated through a bone defect in the lower occiput and upper cervical spine.*

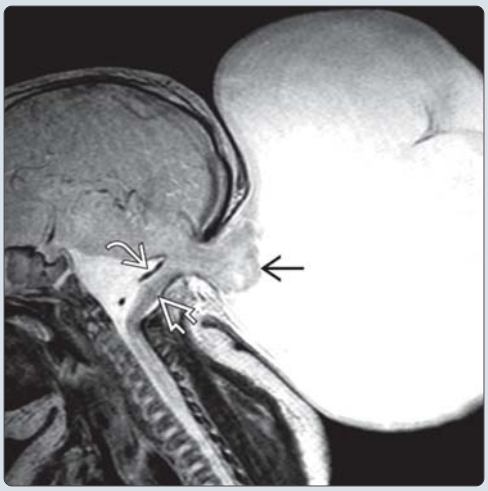

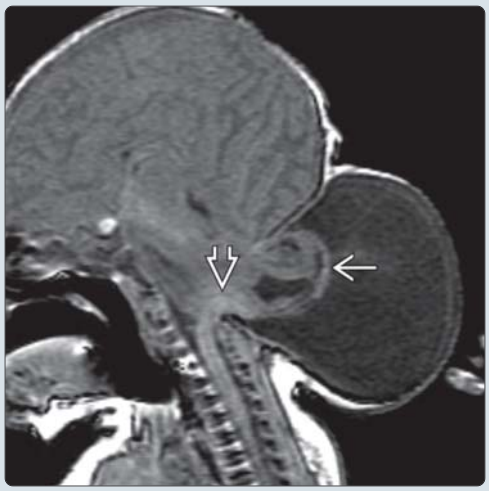

(Left) *Bone CT 3D shaded surface rendering of the posterior calvaria/upper cervical spine in a Chiari 3 malformation (CM3) patient shows a large defect ⇨ of the ventral chondral and squamous supraoccipital bones in conjunction with upper cervical spina bifida ⇨.* **(Right)** *Sagittal MRV demonstrates typical venous abnormalities of Chiari 3. The straight sinus ⇨ and vein of Galen is severely hypoplastic. Large occipital sinuses ⇨ rather than transverse sinuses are present.*

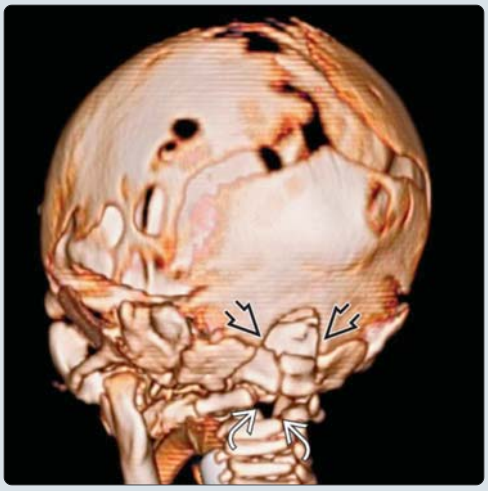

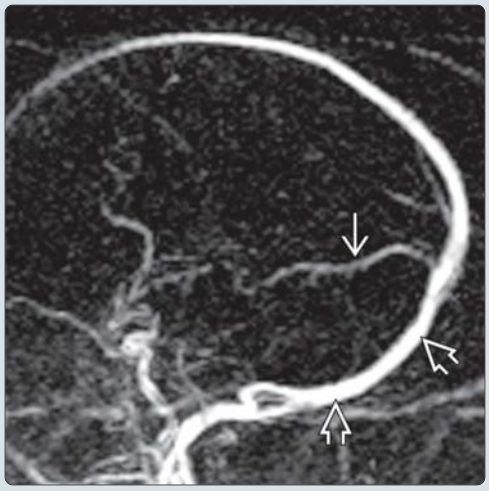

https://CafePezeshki.IR

TERMINOLOGY

Synonyms

- Chiari III, rhombencephalocele

Definitions

- Combined cephalocele with myelocele herniating through high cervical ± low occipital dysraphic defect

IMAGING

General Features

- Best diagnostic clue
  - Skin-covered upper cervical meningoencephalocele containing cerebellum

CT Findings

- NECT
  - Midline posterior cephalocele containing cerebellum
  - Small posterior cranial fossa ± scalloped clivus, lacunar skull
- Bone CT
  - Opisthion, upper cervical osseous dysraphic bone defect
- CTA
  - Basilar artery "pulled" into defect along with brainstem into cephalocele sac
  - ± veins/dural sinuses within cephalocele sac
  - Anomalous &/or ptotic veins, dural sinuses

MR Findings

- T1WI
  - High cervical cephalocele sac containing meninges and cerebellum ± brainstem, upper cervical cord
  - Cisterns, 4th ventricle, dural sinuses may extend into cephalocele (50%)
- T2WI
  - Tissues in cephalocele sac may be bright (gliosis), strand-like (necrotic), or hypointense (hemorrhagic)

Imaging Recommendations

- Best imaging tool
  - Multiplanar brain MR with MRV to characterize occipitocervical encephalocele, vessels
  - Multiplanar bone CT to evaluate osseous defects

DIFFERENTIAL DIAGNOSIS

Isolated Occipital Encephalocele

- Spares foramen magnum, lacks intracranial Chiari 2 findings

Other Occipital Encephaloceles

- Iniencephaly
- Syndromic occipital encephalocele
  - Meckel-Gruber, Goldenhar-Gorlin, MURCS (müllerian, renal, cervical-spine), Walker-Warburg, amniotic band

PATHOLOGY

General Features

- Genetics
  - 677C → T mutation on methylenetetrahydrofolate reductase (*MTHFR*) gene (≤ 50%)
- Associated abnormalities
  - Corpus callosum anomalies, gray matter heterotopia, syringohydromyelia, tethered cord
  - Previously described in combination with intracranial CM2 manifestations
    - Now thought that tectum, lower brainstem findings actually reflect distortion related to cerebellar displacement into sac

Gross Pathologic & Surgical Features

- Cephalocele contents: Meninges, cerebellum, brainstem ± cervical cord, ± occipital poles, ± vasculature

Microscopic Features

- Disorganized (neuronal migration anomalies, cortical dysplasias, gliotic) brain tissue within sac

CLINICAL ISSUES

Presentation

- Most common signs/symptoms
  - Occipital/upper cervical cephalocele, microcephaly
  - Discovered by fetal ultrasound/MR or surprise at birth
- Other signs/symptoms
  - Mechanical brainstem traction, respiratory deterioration, lower cranial nerve dysfunction
- Clinical profile
  - Severe developmental delay, spasticity, hypotonia, seizures

Demographics

- Age
  - Newborn
- Gender
  - F > M (as in all NTDs) in most series
- Epidemiology
  - Rare; 1-4.5% of all Chiari malformations

Natural History & Prognosis

- Dependent on amount, type of herniated tissue
- Prognosis usually dismal, with severe disability and early death

Treatment

- Surgical resection, encephalocele repair
  - Resect or repair sac (most structures in sac are nonfunctioning)
  - If amount CNS tissue in sac > intracranial → not surgical candidate
- Cerebrospinal fluid diversion for hydrocephalus

DIAGNOSTIC CHECKLIST

Consider

- Chiari 3 in newborn presenting with low occipital encephalocele

SELECTED REFERENCES

1. Cesmebasi A et al: The Chiari malformations: A review with emphasis on anatomical traits. Clin Anat. 28(2):184-194, 2015
2. Deans AE et al: Radiology of the Chiari Malformations. In Tubbs RS et al: The Chiari Malformations. New York: Springer. 153-69, 2013

https://CafePezeshki.IR

KEY FACTS

TERMINOLOGY

- Partial or complete absence of corpus callosum (CC), hippocampal commissure (HC), or anterior commissure (AC); can be isolated or associated with additional cerebral malformations
- Spectrum of congenital CC structural abnormalities
  - Total agenesis (absence from birth of all anatomically defined regions of CC)
  - Partial agenesis (absence from birth of at least 1, but not all, regions of CC)
  - Hypoplasia (thinner CC with normal anteroposterior extent)
  - Hyperplasia (thick CC resulting from decreased postnatal axonal pruning)
  - Dysgenesis (CC present but malformed in some way, including partial ACC and hypoplasia of CC)

IMAGING

- Absent corpus callosum on sagittal, coronal views
- Atrium/occipital horns often dilated ("colpocephaly")
- DTI: Callosal fiber tracts form Probst bundles instead of crossing, where corpus callosum is absent
- Vertical/posterior course of anterior cerebral artery

CLINICAL ISSUES

- Any age; classically identified in early childhood, most common malformation found in fetuses
- Seizures, developmental delay, cranial deformity/hypertelorism
- Sporadic/isolated agenesis/dysgenesis corpus callosum: Normal/near normal at 3 years (75%), but subtle cognitive defects apparent with increasing complexity of school tasks
- Agenesis/dysgenesis corpus callosum with associated/syndromic anomalies = worst

DIAGNOSTIC CHECKLIST

- Look for absent/incomplete corpus callosum rather than indirect signs
- Fully assess for associated lesions

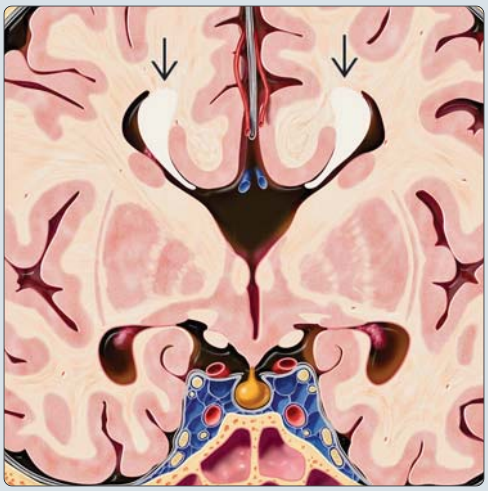

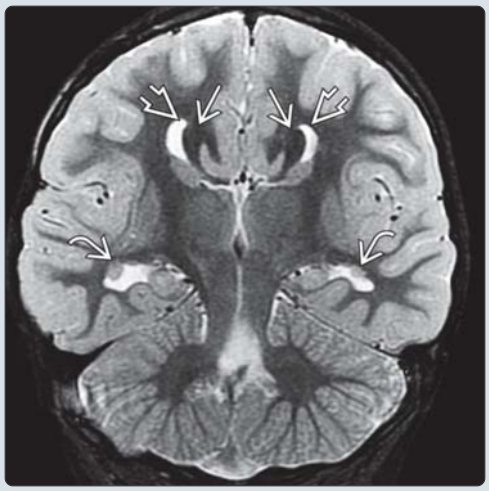

(Left) *Coronal graphic shows a lack of transverse corpus callosum and separate lateral ventricles. The interhemispheric fissure extends to the 3rd ventricle. The bundles of Probst ⇨ contain the parasagittally rerouted callosal fibers.* **(Right)** *Coronal T2WI with callosal dysgenesis shows Viking helmet or moose head appearance of widely separated lateral ventricles ⇨. The very hypointense white matter tracts medial to the lateral ventricles are the Probst bundles ⇨. Note the heterotopic GM ⇨.*

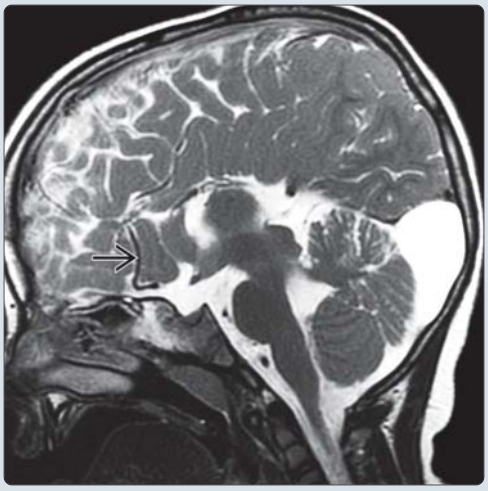

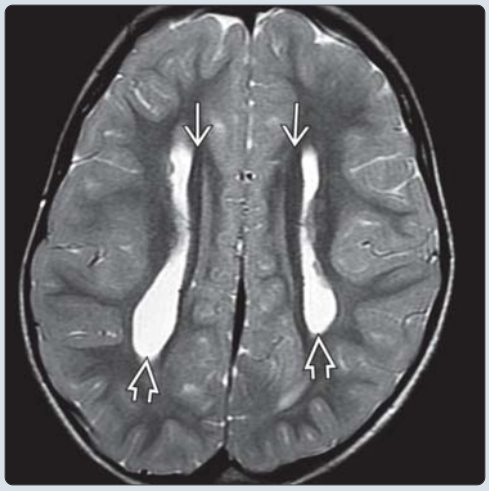

(Left) *Sagittal T2WI in the same patient shows absence of the corpus callosum, radially-oriented gyri converging on a high-riding 3rd ventricle. Note the azygous anterior cerebral artery (ACA) ⇨. The anterior commissure is also absent.* **(Right)** *Axial T2WI in the same case shows the characteristic parallel, nonconverging lateral ventricles ⇨ seen in corpus callosum agenesis. Heavily myelinated Probst bundles ⇨ are seen just medial to the lateral ventricles.*

https://CafePezeshki.IR

TERMINOLOGY

Abbreviations

- Agenesis/dysgenesis corpus callosum (ACC)

Synonyms

- Callosal agenesis/dysgenesis, commissural agenesis/dysgenesis

Definitions

- Partial or complete absence of corpus callosum (CC), hippocampal commissure (HC), or anterior commissure (AC); can be isolated or associated with additional cerebral malformations
- Spectrum of congenital CC structural abnormalities
  - Total agenesis (absence from birth of all anatomically defined regions of CC)
  - Partial agenesis (absence from birth of at least 1, but not all, regions of CC)
  - Hypoplasia (thinner CC with normal anteroposterior extent)
  - Hyperplasia (thick CC resulting from decreased postnatal axonal pruning)
  - Dysgenesis (CC present but malformed in some way, including partial ACC and hypoplasia of CC)

IMAGING

General Features

- Best diagnostic clue
  - Partially or completely absent CC on midline sagittal and coronal planes
  - Lateral ventricles separate and parallel (axial), bull's head, trident, Viking helmet, or moose head appearances (coronal)
- Size
  - When present, CC remnants vary in size, extent, shape
    - Prior to myelin maturation, may be difficult to define (T2WI is better)
- Morphology
  - Commissural plate, clockwise
    - AC
    - Lamina rostralis and rostrum
    - Genu, body and isthmus, splenium
    - HC below CC, largest posterior to septum pellucidum

CT Findings

- NECT
  - On axial CT, lateral ventricles key to diagnosis
    - Parallel and separate
    - Atrium/occipital horns dilated ("colpocephaly")
- CTA
  - Anterior cerebral arteries (ACAs) course directly upward in interhemispheric fissure

MR Findings

- T1WI
  - Sagittal
    - Absent or incomplete commissures, expanded 3rd ventricular roof
    - Abnormal cingulate gyrus: Radiating sulcal pattern
    - AC may be absent, small, or normal
  - Coronal
    - Interhemispheric fissure extends down to 3rd ventricular roof
    - Probst bundles: Medial parasagittal white matter tracts, brighter than other myelin on T1WI, indent lateral ventricles ("bull's head," etc.)
    - Bifid temporal horns and rounded hippocampi
  - Axial
    - Parallel separate lateral ventricles, colpocephaly
- T2WI
  - Same morphology as on T1WI
    - Probst bundles darker than rest of white matter
  - Variants and associated malformations
    - High-riding 3rd ventricle
    - Partial agenesis usually affects posterior CC and HC
    - Multiple interhemispheric cysts (meningeal dysplasia)
    - Lipomas: Nodular, curvilinear
    - Malformations of cortical development (MCD): Polymicrogyria-like cortical malformation (often along midline cysts), subcortical or periventricular nodular heterotopia
    - Malformation of eyes, hindbrain (Dandy-Walker), hypothalamus-pituitary, cord, heart
- DWI
  - DTI: Callosal fiber tracts form Probst bundles instead of crossing, where CC is absent
  - Callosal remnants may contain axons from any part of cerebrum
- MRA
  - Vertical/posterior course of ACA (no genu to sweep around), ± azygous ACA
- MRV
  - Occasional midline venous anomalies, persistent falcine sinus

Ultrasonographic Findings

- Grayscale ultrasound
  - Coronal
    - Absent CC, bull's head lateral ventricles, separated lateral ventricles, colpocephaly
  - Sagittal
    - Radially arranged gyri "point to" 3rd ventricle
- Color Doppler
  - Abnormal posterior ACA course

Imaging Recommendations

- Best imaging tool
  - MR
- Protocol advice
  - Multiplanar MR (look for associated malformations)
  - If MR unavailable, multiplanar CT will diagnose ACC
  - In fetuses, use ultrafast single-shot T2WI in 3 planes

DIFFERENTIAL DIAGNOSIS

Destruction of Corpus Callosum

- Surgery (callosotomy), trauma
- Hypoxic-ischemic encephalopathy, infarcts, hemorrhages
- Metabolic (Marchiafava-Bignami) with necrosis, longitudinal splitting of CC

https://CafePezeshki.IR

Stretched Corpus Callosum

- Thinned CC (e.g., hydrocephalus), but all parts present

Hypoplastic Corpus Callosum

- CC thin, but all parts present

Immature Corpus Callosum

- Premyelinated CC may be difficult to confirm; look for cingulate gyrus

Thick Corpus Callosum ("Mega-Corpus Callosum")

- Excessively thick CC can be isolated or occur with brain malformations, congenital metabolic diseases
  - Probably due to delayed retraction of transitory collateral axons

PATHOLOGY

General Features

- Etiology
  - Axons fail to form
    - Rare: CRASH syndrome/*L1CAM* gene defect, "cobblestone" lissencephaly
  - Axons not guided to midline (mutations in adhesion molecules)
  - Axons reach midline but fail to cross (absence or malfunction of midsagittal guiding substrate)
    - Turn and form large, aberrant, parasagittal Probst bundles
  - Miscellaneous
    - Toxic: Fetal alcohol exposure may affect *L1CAM*
    - Infection: In utero cytomegalovirus (CMV)
    - Inborn errors of metabolism: Nonketotic hyperglycinemia, pyruvate dehydrogenase deficiency, maternal phenylketonuria (PKU), Zellweger
- Genetics
  - Genetics of associated/syndromic CC anomalies
    - Most common abnormality seen as part of CNS malformations: > 130 syndromes
    - Chiari 2, frontonasal dysplasia, syndromic craniosynostoses, MCD, tubulin mutations, etc.
    - Aicardi syndrome: X-linked ACC, polymicrogyria and heterotopia, infantile spasms, retinal lacunae, developmental delay
- Associated abnormalities
  - MCD: Heterotopia, lissencephaly, polymicrogyria, etc.
  - Ocular/hypothalamic-pituitary/cord/facial anomalies
  - Heart, limbs
  - ACC may be malformation in itself or feature of many malformative syndromes

Staging, Grading, & Classification

- May be isolated or part of syndrome; complete or partial
- May have interhemispheric dysplasia: Meningeal cysts, lipomas
- May be part of syndrome (> 130)

Gross Pathologic & Surgical Features

- Leaves of septum pellucidum laterally displaced, contain Probst bundles
- Probst bundles contain parasagittal callosal bundle
  - Only form if callosal neurons present
  - Variable-sized bundles smaller than normal CC
- Associated dysgenetic brain lesions

CLINICAL ISSUES

Presentation

- Most common signs/symptoms
  - Seizures, developmental delay, cranial deformity-hypertelorism
  - Hypopituitarism-hypothalamic malfunction
  - Autism spectrum disorders
- Clinical profile
  - None specific

Demographics

- Age
  - Any age, classically identified in early childhood, most common malformation found in fetuses
- Gender
  - M > F, if isolated finding
- Epidemiology
  - 0.5-70 per 10,000 live births
  - 4% of CNS malformations
  - Can be isolated (often males) or part of other CNS malformations

Natural History & Prognosis

- Sporadic/isolated ACC: Normal/near normal at 3 years (75%), but subtle cognitive defects apparent with increasing complexity of school tasks
- ACC with associated/syndromic anomalies = worst

DIAGNOSTIC CHECKLIST

Consider

- Syndromic associations common

Image Interpretation Pearls

- Look for absent/incomplete CC rather than indirect signs
- Fully assess for associated lesions

SELECTED REFERENCES

1. Craven I et al: Antenatal diagnosis of agenesis of the corpus callosum. Clin Radiol. 70(3):248-53, 2015
2. Edwards TJ et al: Clinical, genetic and imaging findings identify new causes for corpus callosum development syndromes. Brain. 137(Pt 6):1579-1613, 2014
3. Palmer EE et al: Agenesis of the corpus callosum: a clinical approach to diagnosis. Am J Med Genet C Semin Med Genet. 166C(2):184-97, 2014
4. Lau YC et al: Autism traits in individuals with agenesis of the corpus callosum. J Autism Dev Disord. 43(5):1106-18, 2013
5. Owen JP et al: The structural connectome of the human brain in agenesis of the corpus callosum. Neuroimage. 70:340-55, 2013
6. Santo S et al: Counseling in fetal medicine: agenesis of the corpus callosum. Ultrasound Obstet Gynecol. 40(5):513-21, 2012
7. Vasudevan C et al: Long-term outcome of antenatally diagnosed agenesis of corpus callosum and cerebellar malformations. Semin Fetal Neonatal Med. 17(5):295-300, 2012
8. Hopkins B et al: Neuroimaging aspects of Aicardi syndrome. Am J Med Genet A. 146A(22):2871-8, 2008
9. Lee SK et al: Diffusion tensor MR imaging visualizes the altered hemispheric fiber connection in callosal dysgenesis. AJNR Am J Neuroradiol. 25(1):25-8, 2004
10. Küker W et al: Malformations of the midline commissures: MRI findings in different forms of callosal dysgenesis. Eur Radiol. 13(3):598-604, 2003

https://CafePezeshki.IR

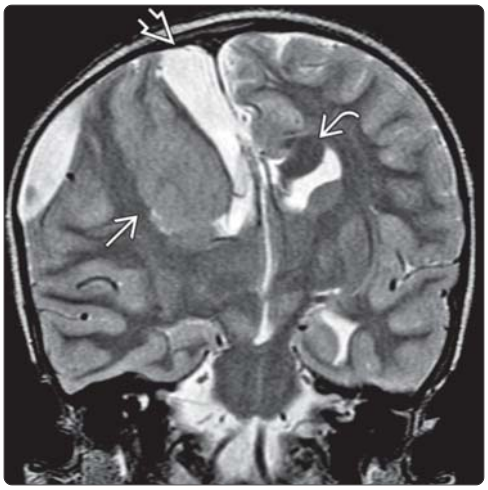

(Left) *Sagittal T1WI MR shows pure partial agenesis/dysgenesis corpus callosum (ACC). The posterior portion of the corpus callosum is missing ⇨, but the junction with the fornix ⇨ seems preserved. Posterior coronals would show Probst bundles, whereas anterior images would appear normal.* **(Right)** *Coronal T2WI MR shows ACC with (shunted) interhemispheric meningeal cysts ⇨. Note the massive nodular heterotopia on the patient's right ⇨. A Probst bundle has formed on the left ⇨ but not on the right.*

(Left) *Axial NECT with widened windows shows ACC with colpocephaly, calcified ⇨ midline lipoma that extends through choroid fissures into lateral ventricles ⇨.* **(Right)** *Axial T1WI MR in ACC shows parallel ventricles, colpocephaly, and a midline lipoma ⇨. Note that the lipoma protrudes through the choroid fissure into the lateral ventricles ⇨.*

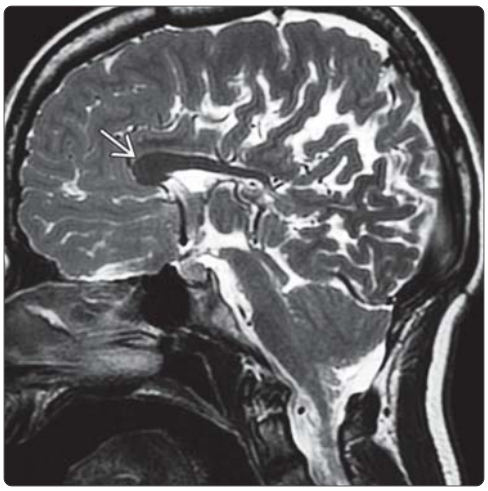

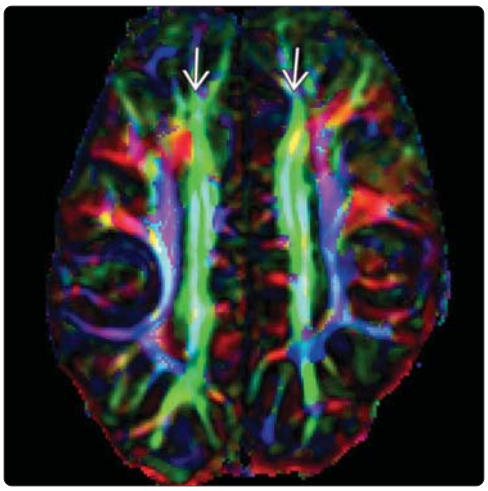

(Left) *Sagittal T1WI MR in a 19-year-old female with Chiari 2 is shown. ACC in Chiari 2 is always partial ⇨; Probst bundles are never seen. Note the multiple supra- and infratentorial Chiari 2 features.* **(Right)** *Axial DTI of a child with complete callosal agenesis shows Probst bundles as green uncrossed callosal fibers ⇨ coursing front to back.*

https://CafePezeshki.IR

KEY FACTS

TERMINOLOGY

- Intracranial lipoma (ICL)
- Mass of mature nonneoplastic adipose tissue
- CNS lipomas are congenital malformations, not true neoplasms

IMAGING

- Well-delineated lobulated extraaxial mass with fat attenuation/intensity
- 80% supratentorial
  - 40-50% interhemispheric fissure (over corpus callosum; may extend into lateral ventricles, choroid plexus)
  - 15-20% suprasellar (attached to infundibulum, hypothalamus)
  - 10-15% tectal region (usually inferior colliculus/superior vermis)
- 20% infratentorial
- Cerebellopontine angle (may extend into internal auditory canal, vestibule)
- Lobulated pial-based fatty mass that may encase vessels and cranial nerves
- CT: -50 to -100 Hounsfield units (HU) (fat density)
- Ca++ varies from none to extensive
- Standard SE MR: Hyperintense on T1WI
- Becomes hypointense with fat suppression

TOP DIFFERENTIAL DIAGNOSES

- Teratoma
  - Locations similar to lipoma
  - Tissue from all 3 embryonic germ layers

DIAGNOSTIC CHECKLIST

- When in doubt, use fat-saturation sequence
- Could high signal on T1WI be due to other substances with short T1 (e.g., subacute hemorrhage)
- Beware: Lipoma can mimic intracranial air on NECT (use bone windows to distinguish)

(Left) *Coronal graphic shows callosal agenesis with a bulky tubulonodular interhemispheric lipoma* ⇨ *that encases the arteries* ⇨ *and extends into the lateral ventricles* ⇨. **(Right)** *Sagittal T1WI MR shows a rather thin curvilinear interhemispheric lipoma in a 9 month old. Note that the hyperintense lipoma* ⇨ *is thicker posteriorly than anteriorly. It wraps around the back of the corpus callosum and extends beneath the corpus* ⇨ *into the velum interpositum.*

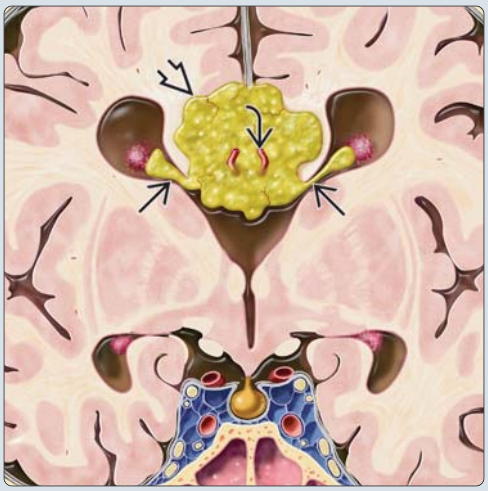

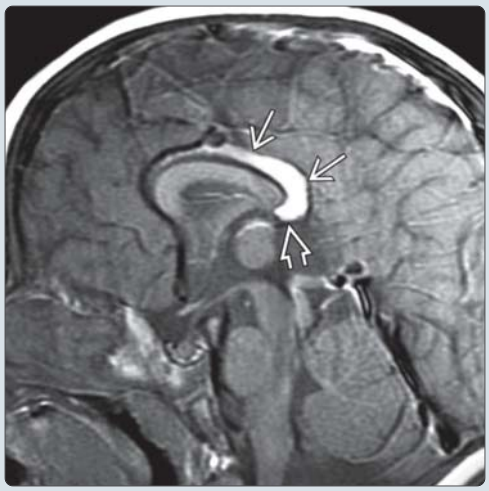

(Left) *Sagittal T1WI MR in a neonate shows a large, tubulonodular, interhemispheric lipoma* ⇨ *dorsal to a wedge-shaped callosal remnant* ⇨. *The brain is otherwise normal.* **(Right)** *Axial T2WI FS MR in the same patient shows the lipoma* ⇨ *as hypointense and lying between the 2 cerebral hemispheres. The lipoma extends through the choroidal fissures into the lateral ventricles* ⇨ *where it is in the stroma of the choroid plexuses.*

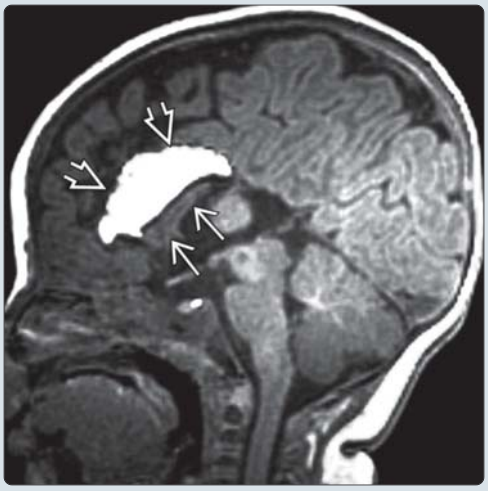

https://CafePezeshki.IR

TERMINOLOGY

Abbreviations

- Intracranial lipoma (ICL)

Synonyms

- Lipomatous hamartoma

Definitions

- Mass of mature nonneoplastic adipose tissue
  - CNS lipomas are congenital malformations, not true neoplasms
  - Lipoma variants in CNS include angiolipoma, hibernoma, osteolipoma

IMAGING

General Features

- Best diagnostic clue
  - Well-delineated lobulated extraaxial mass with fat attenuation/intensity
- Location
  - Midline location common
  - 80% supratentorial
    - 40-50% interhemispheric fissure (over corpus callosum [CC]; may extend into lateral ventricles, choroid plexus)
    - 15-20% suprasellar (attached to infundibulum, hypothalamus)
    - 10-15% tectal region (usually inferior colliculus/superior vermis)
    - Uncommon: Meckel cave, lateral cerebral fissures, middle cranial fossa
  - 20% infratentorial
    - Cerebellopontine angle (may extend into internal auditory canal, vestibule)
    - Uncommon: Jugular foramen, foramen magnum
- Size
  - Varies from tiny to very large
- Morphology
  - Lobulated pial-based fatty mass that may encase vessels and cranial nerves
  - 2 kinds of interhemispheric lipoma
    - Curvilinear type (thin ICL curves around callosal body, splenium)
    - Tubulonodular type (bulky mass; frequent Ca++, usually associated with callosal agenesis)

Radiographic Findings

- Radiography
  - Usually normal
  - Very large interhemispheric lipomas may show low density
  - Tubulonodular lipomas may show rim Ca++

CT Findings

- NECT
  - -50 to -100 Hounsfield units (HU); fat density
  - Ca++ varies from none to extensive
    - Present in 65% of bulky tubulonodular CC lipomas
    - Rare in posterior fossa, parasellar lesions
- CECT
  - Does not enhance
- CTA
  - May demonstrate aberrant pericallosal artery course in interhemispheric lipoma associated with callosal dysgenesis

MR Findings

- T1WI
  - Hyperintense mass
  - Becomes hypointense with fat suppression
  - Chemical shift artifact in frequency-encoding direction
- T2WI
  - Hypointense on conventional spin-echo (SE) with striking chemical shift artifact
    - Round/linear "filling defects" present where vessels and cranial nerves pass through lipoma
    - May show low signal intensity foci (Ca++)
  - FSE: Iso- to hyperintense (J-coupling)
- PD/intermediate
  - Iso- to hyperintense (depending on repetition and echo times)
    - Striking chemical shift artifact
- STIR
  - Hypointense
- FLAIR
  - Hyperintense
- T2* GRE
  - Hypointense
- DWI
  - Diffusion tensor imaging visualizes altered fiber connections if associated callosal dysgenesis present
- T1WI C+
  - Does not enhance

Ultrasonographic Findings

- Grayscale ultrasound
  - Fetal/neonatal mass, generally hyperechoic
  - May show other fetal anomalies (CC agenesis, etc.)

Imaging Recommendations

- Best imaging tool
  - MR
- Protocol advice
  - Add fat-suppression sequence for confirmation

DIFFERENTIAL DIAGNOSIS

Dural Dysplasia

- Fat often in falx, cavernous sinuses
- Metaplastic ossified dura may contain fat

Dermoid

- Density usually 20-40 HU
- Signal intensity usually more heterogeneous
- Rupture with cisternal fat droplets common
- Usually no associated malformations (common with lipoma)
- Dermoids often calcify; lipomas in locations other than interhemispheric do not

Teratoma

- Locations similar to lipoma
- Tissue from all 3 embryonic germ layers

https://CafePezeshki.IR

- Imaging appearance usually more heterogeneous
  - May show foci of contrast enhancement

Lipomatous Differentiation of Neoplasm

- May occur occasionally in PNETs, ependymoma, gliomas
- Cerebellar liponeurocytoma
  - Primarily hypointense on T1WI, mixed with hyperintense foci
  - Patchy, irregular enhancement
- Meningiomas, schwannomas, metastases rarely have lipomatous transformation

Subacute Hemorrhage

- T1 shortening can be confused with lipoma
- Use T2* (hemorrhage blooms), fat saturation (hemorrhage does not suppress)

Encephalocraniocutaneous Lipomatosis

- Eye anomalies, skin lesions, intracranial lipomas, cortical dysgenesis

PATHOLOGY

General Features

- Etiology
  - Persistent maldevelopment of embryonic meninx primitiva
    - Normally differentiates into leptomeninges, cisterns
    - Maldifferentiates into fat instead
  - Developing pia-arachnoid invaginates through embryonic choroid fissure
    - Explains frequent intraventricular extension of interhemispheric lipomas
- Genetics
  - No known defects in sporadic ICL
- Associated abnormalities
  - Most common: Interhemispheric lipoma with corpus callosum anomalies
  - Other congenital malformations: Cephaloceles, closed spinal dysraphism
  - Encephalocraniocutaneous lipomatosis → Fishman syndrome
  - Pai syndrome → facial clefts, skin lipomas; occasional ICLs, usually interhemispheric

Gross Pathologic & Surgical Features

- Yellow lobulated fatty mass attached to leptomeninges, sometimes adherent to brain
- Cranial nerves, arteries/veins pass through lipoma

Microscopic Features

- Identical to adipose tissue elsewhere
- Cells vary in shape/size, measure up to 200 μm
- Occasional nuclear hyperchromasia; mitoses rare/absent
- Liposarcoma: Extremely rare malignant intracranial adipose tumor

CLINICAL ISSUES

Presentation

- Most common signs/symptoms
  - Usually found incidentally at imaging, autopsy
  - Rare: Cranial neuropathy (vestibulocochlear dysfunction, facial pain), seizures (associated with other congenital anomalies)
  - Seizures associated with lipomas over (dysmorphic) cortex

Demographics

- Age
  - Any age
- Gender
  - M = F
- Ethnicity
  - None known
- Epidemiology
  - < 0.5% of all intracranial masses (not true neoplasm)

Natural History & Prognosis

- Benign, usually stable
- May expand with corticosteroids
  - High-dose, long-term administration may result in neural compressive symptoms

Treatment

- Generally not surgical lesion
  - Surgery has high morbidity/mortality
- Reduce/eliminate steroids

DIAGNOSTIC CHECKLIST

Consider

- Could high signal on T1WI be due to other substances with short T1 (e.g., subacute hemorrhage)

Image Interpretation Pearls

- When in doubt, use fat-saturation sequence
- Beware: Lipoma can mimic intracranial air on NECT (use bone windows to distinguish)

SELECTED REFERENCES

1. Maher CO et al: Incidental findings on brain and spine imaging in children. Pediatrics. 135(4):e1084-96, 2015
2. Bacciu A et al: Lipomas of the internal auditory canal and cerebellopontine angle. Ann Otol Rhinol Laryngol. 123(1):58-64, 2014
3. Mashiko R et al: Quadrigeminal cistern lipoma mimicking intracranial air. BMJ Case Rep. 2014, 2014
4. Gossner J: Small intracranial lipomas may be a frequent finding on computed tomography of the brain. A case series. Neuroradiol J. 26(1):27-9, 2013
5. Nanni M et al: Prenatal and postnatal imaging of multiple intracranial lipomas: report of a case. Fetal Diagn Ther. 30(2):160-2, 2011
6. Jabot G et al: Intracranial lipomas: clinical appearances on neuroimaging and clinical significance. J Neurol. 256(6):851-5, 2009
7. Moog U: Encephalocraniocutaneous lipomatosis. J Med Genet. 46(11):721-9, 2009
8. Kemmling A et al: A diagnostic pitfall for intracranial aneurysms in time-of-flight MR angiography: small intracranial lipomas. AJR Am J Roentgenol. 190(1):W62-7, 2008
9. Loddenkemper T et al: Intracranial lipomas and epilepsy. J Neurol. 253(5):590-3, 2006
10. Yildiz H et al: Intracranial lipomas: importance of localization. Neuroradiology. 48(1):1-7, 2006
11. Gaskin CM et al: Lipomas, lipoma variants, and well-differentiated liposarcomas (atypical lipomas): results of MRI evaluations of 126 consecutive fatty masses. AJR Am J Roentgenol. 182(3):733-9, 2004

https://CafePezeshki.IR

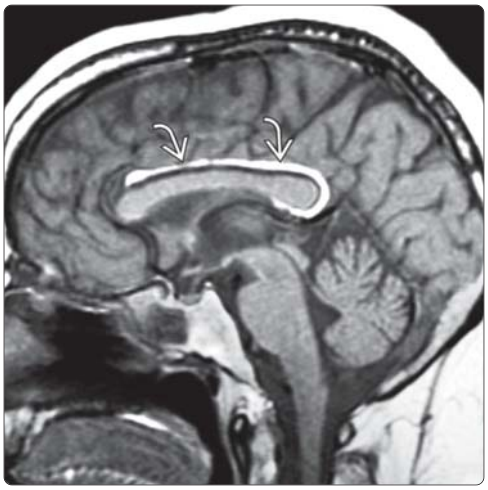

(Left) *Axial NECT in a young woman studied for an unrelated headache shows a hypodense linear structure ➡ in the midline.* **(Right)** *Sagittal T1WI MR in the same patient shows that the linear structure ➡ is a curvilinear interhemispheric lipoma that wraps around the posterior aspect of a hypogenetic corpus callosum and courses into the posterior part of the velum interpositum. The callosal genu and splenium are incompletely formed.*

(Left) *Sagittal T1WI MR in a 25-year-old man with unrelated symptoms shows a hypothalamic lipoma ➡, which is located in the tuber cinereum of the hypothalamus (between the infundibulum and the mammillary bodies).* **(Right)** *Sagittal T1WI MR shows a tectal lipoma ➡ situated immediately posterior to the inferior tectum and between the inferior colliculus and the superior surface of the cerebellar vermis. This is a very common location for lipomas.*

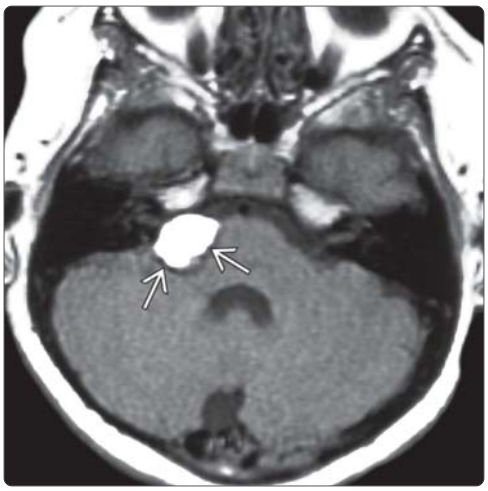

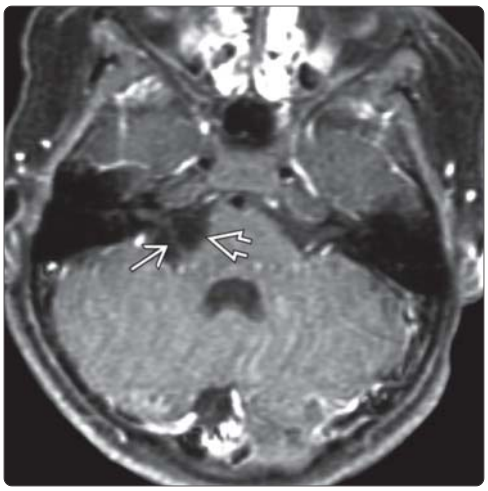

(Left) *Axial T1WI MR shows a round lipoma ➡ in the right cerebellopontine angle cistern, adjacent to the internal auditory canal (IAC). Lipomas do not cause hearing loss and should not be resected.* **(Right)** *Axial T1WI C+ FS MR shows that the mass ➡ becomes very hypointense after the fat-suppression pulse is applied. With fat signal suppressed, the 8th cranial nerve ➡ can be seen coursing through the lipoma in the cerebellopontine angle cistern to the internal auditory canal.*

https://CafePezeshki.IR

KEY FACTS

TERMINOLOGY

- DWS represents broad spectrum of cystic posterior fossa (PF) malformations
  - Dandy-Walker spectrum (DWS)/complex (DWC)
  - "Classic" DW malformation (DWM)
  - Hypoplastic vermis with rotation (HVR)
  - Persistent Blake pouch cyst (BPC)
  - Mega cisterna magna (MCM)

IMAGING

- "Classic" DWM
  - Cystic dilatation of 4th ventricle → enlarged PF
  - Vermis hypoplastic, rotated superiorly
- HVR
  - Variable vermian hypoplasia
  - PF/brainstem normal-sized
  - No or small cyst, "keyhole" vallecula
- BPC
  - "Open" 4th ventricle communicates with cyst
  - Fastigial recess, primary fissure, PF/brainstem normal
- MCM
  - Enlarged pericerebellar cisterns communicate with basal subarachnoid spaces
- Occipital bone may appear scalloped/remodeled with **all** DWS types (including MCM)
- Routine MR imaging (thin sagittal views crucial)

PATHOLOGY

- Most severe to mildest: DWM with 4th ventriculocele → classic DWM → HVR → BPC → MCM
- Numerous syndromes associated with DWS

CLINICAL ISSUES

- Marked heterogeneity in genetic, clinical findings
- DWM: 80% diagnosed by 1 year

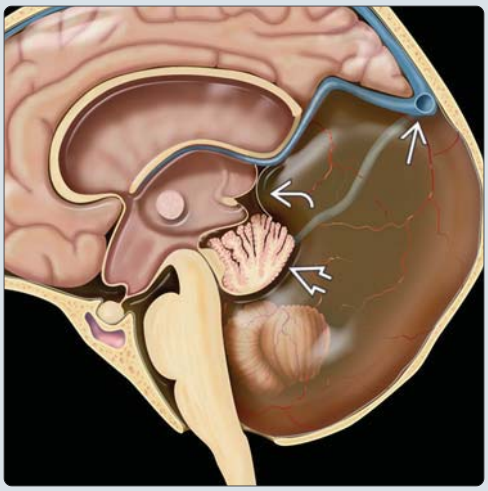

(Left) *Sagittal graphic of classic Dandy-Walker malformation shows an enlarged posterior fossa, elevated torcular herophili, superior rotation of hypoplastic cerebellar vermis, an overexpanded 4th ventricle with a thin wall, and a dilated ventricle (hydrocephalus).* **(Right)** *Sagittal T2WI MR DWS shows a hypoplastic, rotated vermis, lack of fastigial crease, and incomplete vermian lobulation of the posterior lobules beyond the primary fissure. The cyst wall is faintly seen.*

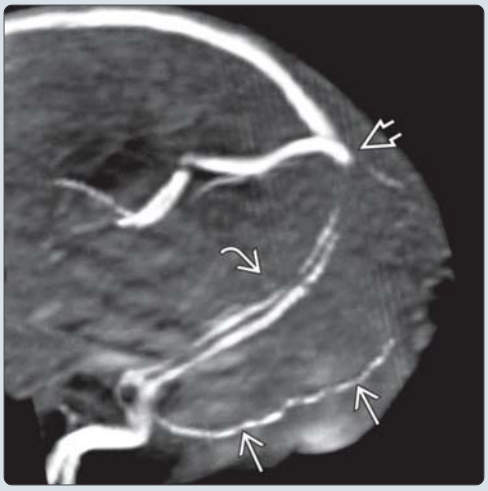

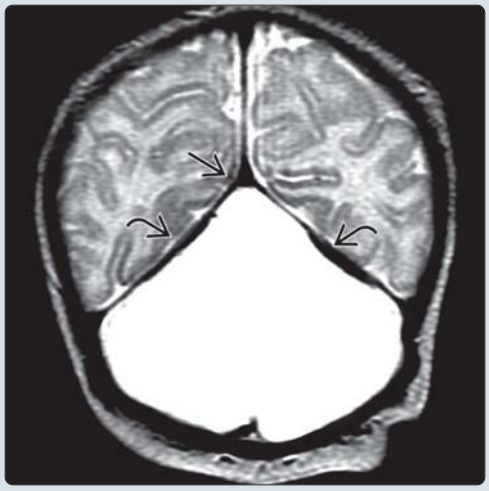

(Left) *Sagittal MRV demonstrates torcular-lambdoid inversion. The transverse sinuses angle upward toward the torcular as the cyst has prevented normal fetal torcular descent. Note the persistent fetal occipital sinus.* **(Right)** *Coronal T2WI MR demonstrates a huge, fluid-filled posterior fossa. Again, notice that the transverse sinuses are angled upward toward the torcular herophili.*

https://CafePezeshki.IR

TERMINOLOGY

Abbreviations

- Dandy-Walker (DW) spectrum (DWS), DW complex (DWC), "classic" DW malformation (DWM)
- Hypoplastic vermis with rotation (HVR), formerly DW variant (DWV)
- Persistent Blake pouch cyst (BPC), mega cisterna magna (MCM)

Definitions

- DWS represents heterogeneous spectrum of cystic posterior fossa (PF) malformations

IMAGING

General Features

- Best diagnostic clue
  - DWM: Large PF with small, counterclockwise (CCW) rotated vermis
  - HVR, BPC: Failure of "closure" of 4th ventricle
- Location
  - Posterior fossa
- Size
  - Variable
- Morphology
  - DWS (from most to least severe)
    - 4th ventriculocele (10-15% of cases)
      - DWM with large 4th ventricle erodes occipital bone → "encephalocele"
    - "Classic" DWM
      - Cystic dilatation of 4th ventricle → enlarged PF, superiorly rotated hypoplastic vermis
      - Torcular-lambdoid inversion: Cyst mechanically hinders normal fetal caudal migration of torcular
    - HVR (formerly DW variant)
      - Variable vermian hypoplasia, no or small cyst, normal sized PF/brainstem, "keyhole" vallecula
    - BPC
      - "Open" 4th ventricle communicates with infravermian cyst, normal fastigial recess, and primary fissure
    - MCM
      - Enlarged retrocerebellar cistern communicates with foramen magnum and basal subarachnoid spaces
      - Cistern crossed by falx cerebelli, tiny veins
      - Normal vermis/4th ventricle

Radiographic Findings

- Radiography
  - Enlarged calvaria, particularly posterior fossa
  - DWM: Lambdoid-torcular inversion (transverse sinus grooves elevated above lambda)
    - Sinuses are originally above lambda in fetus; cyst mechanically hinders descent

CT Findings

- NECT
  - DWM: Large posterior fossa
    - Variable-sized cyst communicates with 4th ventricle
    - Torcular-lambdoid inversion (torcular above lambdoid suture)
  - Occipital bone may appear scalloped, remodeled with all DWS types, including MCM

MR Findings

- T1WI
  - Sagittal DWM
    - Floor of 4th ventricle present
    - 4th ventricle opens dorsally to variable-sized CSF cyst
    - Cyst wall difficult to discern
    - Vermian remnant (± fastigium, fissures) rotated CCW, over cyst
    - ± remnant fused to tentorium
    - Elevated torcular with high/steeply sloping tentorium (classic)
  - Sagittal HVR
    - Smaller PF ± cyst
    - 4th ventricle "open" with partial CCW rotation vermis, presence of fastigium, fissures variable
  - Sagittal BPC
    - Rotated but normal-appearing vermis
    - Free communication of 4th ventricle with prominent inferior CSF space
    - Basal cisterns compressed posteriorly or effaced
  - Sagittal MCM
    - Normal vermis (not rotated/hypoplastic)
    - 4th ventricle is "closed"
- T2WI
  - Associated anomalies
    - Cortical dysplasia, heterotopias, myelination delays (syndromic DWS)
- FLAIR
  - ± very slight signal difference between cyst, CSF
  - ± compressed basal cisterns
- DWI
  - Very slight restriction may be seen if reduced fluid motion
- MRV
  - Elevated torcular herophili (DWM)

Ultrasonographic Findings

- Identical to MR; can diagnose in fetus

Nonvascular Interventions

- Cisternography delineates cyst wall

Imaging Recommendations

- Best imaging tool
  - MR best characterizes severity, associated anomalies
- Protocol advice
  - Routine MR imaging (thin sagittal views crucial)

DIFFERENTIAL DIAGNOSIS

Dandy-Walker Spectrum

- "In-between" cases common

Posterior Fossa Arachnoid Cyst (AC)

- Location: Retrocerebellar, supravermian, or in cerebellopontine angle
- Included in DW spectrum by some authors

https://CafePezeshki.IR

- Normal 4th ventricle compressed or displaced
- AC not traversed by falx cerebelli, tiny veins
- ACs lined by arachnoid cells/collagen

Molar Tooth Deformity (Joubert)

- Prototype = Joubert anomaly
- Episodic hyperpnea, oculomotor apraxia, retinal dystrophy, ± renal cysts, hepatic fibrosis
- Split vermis, bat wing 4th ventricle, mesencephalon is shaped like molar tooth

Isolated 4th Ventricle

- Inferior 4th ventricle "closed" vs. "open" in DWM/DWV on sagittal view

PATHOLOGY

General Features

- Etiology
  - Rhombencephalic roof divides into cephalic (anterior membranous area [AMA]) and caudal (posterior membranous area [PMA])
    - AMA invaded by neural cells → becomes cerebellum
    - PMA expands then disappears to form outlet foramina of 4th ventricle
  - Hindbrain development arrested
    - Defective AMA and PMA → DWM and HVR
    - Defective PMA only → BPC and MCM
- Genetics
  - Majority sporadic, x-linked DWM reported
    - Some have interstitial deletions of 3q2, which encompass *ZIC1* and *ZIC4* genes
  - Many, many syndromes with DWS
    - Chromosomal or midline anomalies; PHACES (facial hemangiomas, coarctation, DWS in 81%)
    - Neurocutaneous melanosis
- Associated abnormalities
  - 2/3 have associated CNS/extracranial anomalies
    - Craniofacial, cardiac/urinary tract anomalies, polydactyly, orthopedic ± respiratory problems
- Embryology
  - Common association DWM/HVR with facial, cardiovascular anomalies suggests onset between formation, migration of neural crest cells (3rd-4th postovulatory week)

Staging, Grading, & Classification

- Spectrum: DWM with 4th ventriculocele (most severe) → classic DWM → HVR → BPC → MCM (mildest)

Gross Pathologic & Surgical Features

- DWM: Large PF with big CSF-containing cyst
  - Inferior margin vermian remnant continuous with cyst wall
  - 4th ventricle choroid plexus absent or displaced into lateral recesses

Microscopic Features

- DWM: Outer cyst wall layer continuous with leptomeninges
  - Intermediate stretched neuroglial layer is continuous with vermis
  - Inner layer of glial tissue lined with ependyma/ependymal nests
  - ± anomalies of inferior olivary nuclei/corticospinal tract crossings

CLINICAL ISSUES

Presentation

- Most common signs/symptoms
  - DWM: Macrocephaly, bulging fontanel, etc.
  - MCM: Incidental finding
- Clinical profile
  - Marked heterogeneity in genetic, clinical findings

Demographics

- Age
  - DWM: 80% diagnosed by 1 year
- Gender
  - M ≤ F
- Epidemiology
  - 1:25,000-100,000 births
  - Accounts for 1-4% of all hydrocephalus cases

Natural History & Prognosis

- Classic DWM: Very variable
- Cognitive outcome dependent upon associated syndromes or supratentorial anomalies/hydrocephalus and completeness of residual vermis
  - Intelligence normal in 35-50% of patients with classic DWM
    - Small remnant without fissures or fastigium
      - Seizures
      - Cognitive delay
      - Poor motor skills/balance
    - Large remnant, normal lobulation and fastigium, normal supratentorial brain
      - Better cognition
      - Better skills/balance

Treatment

- CSF diversion **if** hydrocephalus: VP shunt ± cyst shunt/marsupialization

DIAGNOSTIC CHECKLIST

Consider

- Many associated syndromes, mimics

Image Interpretation Pearls

- Presence of fastigium/vermian lobulation predicts cognitive outcome
- Thin sagittal views crucial for delineation, diagnosis

Reporting Tips

- Is fastigium/vermian lobulation normal?

SELECTED REFERENCES

1. Chapman T et al: Diagnostic imaging of posterior fossa anomalies in the fetus and neonate: part 2, posterior fossa disorders. Clin Imaging. 39(2):167-175, 2015
2. Volpe P et al: Appearance of the fetal posterior fossa at 11-14 weeks in foetuses with Dandy-Walker complex or chromosomal anomalies. Ultrasound Obstet Gynecol. ePub, 2015
3. De Cock J et al: A newborn with neurocutaneous melanocytosis and Dandy-Walker malformation. Pediatr Neurol. 50(3):276-8, 2014
4. Barkovich AJ et al: A developmental and genetic classification for midbrain-hindbrain malformations. Brain. 132(Pt 12):3199-230, 2009

https://CafePezeshki.IR

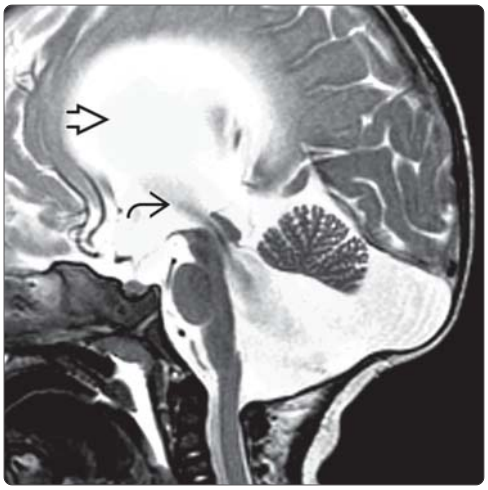

(Left) *Sagittal T2WI MR in a patient with DWM demonstrates hydrocephalus, a large posterior fossa, cephalad rotation of a small, incompletely lobulated vermis with a very shallow fastigial crease ⇨, and a very thin cyst wall ⇨.* **(Right)** *Sagittal T2WI MR in HVR shows ventriculomegaly ⇨, patent aqueduct with prominent flow void ⇨, and a large posterior fossa. There is no torcular-lambdoid inversion.*

(Left) *Sagittal bSSFP demonstrates ventriculomegaly ⇨ in a patient with open inferior 4th ventricle. There is cyst wall visualization inferiorly ⇨. The posteriorly displaced choroid plexus ⇨ suggests Blake pouch cyst. Fastigial recess, primary fissure, and vermian lobulation are intact.* **(Right)** *Sagittal bSSFP shows a closed inferior 4th ventricle with acquired Chiari 1 ⇨. The primary fissure ⇨ and the vermis are compressed by the wall of the retrocerebellar cyst.*

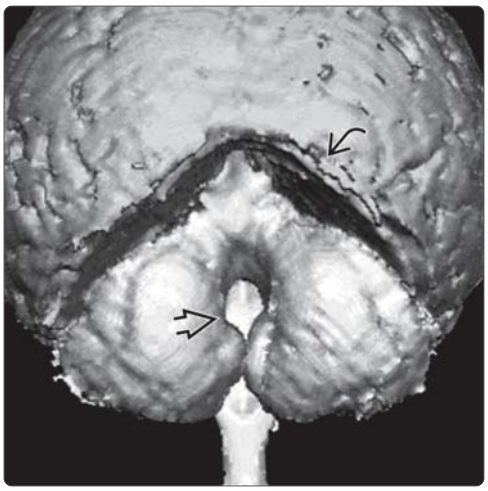

(Left) *Axial T2WI MR in a patient with DWM reveals relative hypoplasia of the cerebellar hemispheres and nonvisualization of the vermis at its usual location. There is a focal calvarial ⇨ defect at the site of a prior occipital encephalocele.* **(Right)** *Coronal 3D surface reconstruction of the brain (viewed from the inferoposterior aspect) from T1 gradient-echo sequence shows the typical elevation of the tentorium ⇨ and separation of the cerebellar hemispheres ⇨ without intervening vermis.*

https://CafePezeshki.IR

KEY FACTS

TERMINOLOGY

- Rhombencephalosynapsis (RES): Congenital continuity (lack of division) of cerebellar hemispheres
  - Complete or partial absence of vermis
  - Varying degrees of midline fusion of cerebellar hemispheres, dentate nuclei
  - May be partial; any portions of hemispheres may be affected

IMAGING

- Small, single hemisphere cerebellum
  - Continuous white matter (WM) tracts crossing midline
  - Absent primary fissure
  - Fused dentate nuclei
  - Small diamond- or keyhole-shaped 4th ventricle
  - ± aqueductal stenosis → hydrocephalus
  - ± corpus callosum dysgenesis (especially posterior)

TOP DIFFERENTIAL DIAGNOSES

- Molar tooth malformations
- Lhermitte-Duclos syndrome
- Vermian hypoplasia
- Diffuse cerebellar cortical dysplasia

PATHOLOGY

- Failure of vermian differentiation
  - Differentiation of vermis required to separate cerebellar hemispheres

DIAGNOSTIC CHECKLIST

- Remember to define associated supratentorial anomalies
- Can be mimicked by mechanically induced cerebellar deformation in chronically shunted patients

(Left) *Coronal graphic of rhombencephalosynapsis shows that no vermis is present in the midline of the cerebellum. Instead, the folia, interfoliate sulci, and cerebellar white matter* ⇨ *are continuous across the cerebellar midline.* **(Right)** *Sagittal T1WI in this child with rhombencephalosynapsis shows absence of the normal vermian lobules and fissures. The cerebellum appears abnormally rounded.*

(Left) *Axial T2WI in the same patient shows continuity of the cerebellar folia of both hemispheres across the midline.* **(Right)** *Coronal T2WI shows the absence of a vermis, with continuity of the cerebellar WM and cortex across the midline* ⇨.

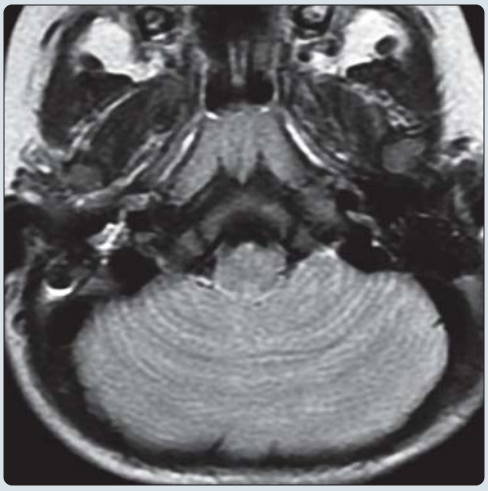

https://CafePezeshki.IR

TERMINOLOGY

Abbreviations

- Rhombencephalosynapsis (RES)

Definitions

- Congenital continuity (lack of division) of cerebellar hemispheres
  - Complete or partial absence of vermis
  - Varying degrees of midline fusion of cerebellar hemispheres, dentate nuclei
    - Hemispheres usually continuous across midline
    - May be partial, affect any part(s) of hemispheres
  - Best classified as abnormal induction of dorsal cerebellar midline

IMAGING

General Features

- Best diagnostic clue
  - Single (often small) hemisphere cerebellum with continuous white matter (WM) tracts crossing midline
    - Small diamond- or keyhole-shaped 4th ventricle
    - Fused dentate nuclei
- Location
  - Midline posterior fossa
- Size
  - Posterior fossa typically smaller than usual
- Morphology
  - Round or oval solitary cerebellar hemisphere

CT Findings

- NECT
  - Cerebellar hemispheric fusion
  - Diamond- or keyhole-shaped 4th ventricle
  - Narrowed transverse diameter of cerebellum
  - Often hydrocephalus with absent septum

MR Findings

- T1WI
  - Sagittal
    - Absent primary fissure
    - ± upwardly rounded fastigial recess of 4th ventricle
      - Nodulus preserved if fastigial recess present
    - ± aqueductal stenosis → hydrocephalus
    - ± corpus callosum dysgenesis (especially posterior)
  - Axial
    - ± collicular fusion
    - ± supratentorial cortical dysplasias
- T2WI
  - Coronal
    - Fused cerebellar hemispheres → total or partial
      - Continuous WM tracts across midline
      - Midline superior "tenting" of WM
    - Absent or severely hypoplastic vermis
    - Transverse folia
    - ± absent septum pellucidum
    - ± fused thalami and fornices
  - Fetal
    - Can be identified on fetal MR
      - Typically performed to investigate hydrocephalus seen on US
    - Abnormal shape of 4th ventricle and absence of vermis most reliable signs

Ultrasonographic Findings

- Grayscale ultrasound
  - Occasionally identified on fetal sonography

Imaging Recommendations

- Best imaging tool
  - MR
- Protocol advice
  - High-resolution FSE T2WI in multiple imaging planes
    - T2WI more clearly defines posterior fossa structures in neonate and infant

DIFFERENTIAL DIAGNOSIS

Molar Tooth Malformations

- Joubert syndrome
  - Vermian dysplasia with prominent superior cerebellar peduncles
  - 4th ventricle has bat wing shape

Lhermitte-Duclos Disease

- Dysplastic cerebellar gangliocytoma
- Striated cerebellar hemisphere
- Associated with Cowden syndrome

Vermian Hypoplasia

- Small vermis without hemispheric fusion
- Vermis develops enough to separate hemispheres, then arrests

Single Hemisphere Cerebellar Hypoplasia

- Often secondary to in utero insult

Diffuse Cerebellar Cortical Dysplasia

- May be associated with congenital muscular dystrophies
- Type 2 lissencephaly

PATHOLOGY

General Features

- Etiology
  - Unknown; 2 major theories
    - Failure of vermian differentiation
      - Based on evidence that hemispheres develop as unpaired structure from cerebellar primordium
      - Differentiation of vermis required to separate cerebellar hemispheres
      - Better explains cases of partial rhombencephalosynapsis
    - Vermian agenesis allowing hemisphere continuity
      - Based on theory that hemispheres form separately from rhombic lips
      - Absence of vermian development allows hemispheres to become apposed and then fuse in midline
- Genetics
  - *FGF8* and *LMX1A* genes may influence expression of isthmic organizer

https://CafePezeshki.IR

- Isthmic organizer
  - Controls/influences patterning of midbrain and anterior hindbrain
  - Located within neuroepithelium of isthmic constriction at midbrain-hindbrain boundary
- No genetic mutations have been found in rhombencephalosynapsis
- Associated abnormalities
  - Frequently occurs with other midline anomalies
    - Absent septum pellucidum, holoprosencephalies
    - Callosal and anterior commissure dysgenesis
    - Thalamic fusion with 3rd ventricle atresia (diencephalosynapsis)
    - Collicular fusion ± aqueductal stenosis/atresia, hydrocephalus
  - Prosencephalic and midline facial anomalies
  - Occasional associated extracranial anomalies
    - Segmentation and fusion anomalies in spine
    - Cardiovascular (conotruncal) anomalies reported
    - Variable respiratory, GU anomalies reported
    - Musculoskeletal anomalies common: Phalangeal and radial ray

Staging, Grading, & Classification

- Partial fusion
  - Fusion may be in any part of cerebellum
- Presence or absence of supratentorial anomalies

Gross Pathologic & Surgical Features

- Typical
  - Fused cerebellar hemispheres
  - Fused cerebellar white matter → large corpus medullare
  - Absent posterior cerebellar incisura, vallecula
  - Horseshoe-shaped dentate nuclei
  - Agenesis or hypogenesis of anterior vermis, velum medullare anterior, and nuclei fastigii
  - Hypoplastic posterior vermis
    - Nodulus may form
- Rare
  - Aventriculy (also called synencephalyor telencephalosynapsis)
  - Encysted 4th ventricle

CLINICAL ISSUES

Presentation

- Most common signs/symptoms
  - Variable neurological signs
    - Ataxia, gait abnormalities, seizures
    - Developmental delay
    - RES discovered in near-normal patients at autopsy
  - Most common associated congenital syndrome = Gomez-Lopez-Hernandez syndrome
    - Cerebello-trigeminal-dermal dysplasia
      - RES with scalp alopecia, abnormal head shape
      - Trigeminal anesthesia
      - Craniofacial dysmorphisms, short stature common

Demographics

- Age
  - Usually found during early infancy or childhood
  - Rarely an incidental finding
- Epidemiology
  - Rare but increasingly recognized on MR

Natural History & Prognosis

- Developmental delay
- Psychiatric disorders (self injurious, bipolar, hyperactive)
- Additional midline supratentorial anomalies and hydrocephalus → worse prognosis

Treatment

- Treat related hydrocephalus, monitor hypothalamic-pituitary axis

DIAGNOSTIC CHECKLIST

Consider

- Rhombencephalosynapsis in severe congenital hydrocephalus
- Isolated rhombencephalosynapsis is less common than with supratentorial anomalies

Image Interpretation Pearls

- Can be mimicked by mechanically induced cerebellar deformation in chronically shunted patients

Reporting Tips

- Remember to define associated supratentorial anomalies

SELECTED REFERENCES

1. Chapman T et al: Diagnostic imaging of posterior fossa anomalies in the fetus and neonate: part 2, posterior fossa disorders. Clin Imaging. 39(2):167-175, 2015
2. Passi GR et al: Rhombencephalosynapsis. Pediatr Neurol. ePub, 2015
3. Poretti A et al: Cerebellar hypoplasia: Differential diagnosis and diagnostic approach. Am J Med Genet C Semin Med Genet. 166(2):211-26, 2014
4. Weaver J et al: Rhombencephalosynapsis: embryopathology and management strategies of associated neurosurgical conditions with a review of the literature. J Neurosurg Pediatr. 11(3):320-6, 2013
5. Ishak GE et al: Rhombencephalosynapsis: a hindbrain malformation associated with incomplete separation of midbrain and forebrain, hydrocephalus and a broad spectrum of severity. Brain. 135(Pt 5):1370-86, 2012
6. Tully HM et al: Beyond Gómez-López-Hernández syndrome: recurring phenotypic themes in rhombencephalosynapsis. Am J Med Genet A. 158A(10):2393-406, 2012
7. Barkovich AJ et al: A developmental and genetic classification for midbrain-hindbrain malformations. Brain. 132(Pt 12):3199-230, 2009
8. Dill P et al: Fetal magnetic resonance imaging in midline malformations of the central nervous system and review of the literature. J Neuroradiol. 36(3):138-46, 2009
9. Jellinger KA: Rhombencephalosynapsis with and without associated malformations. Acta Neuropathol. 117(2):219, 2009
10. Michael GA et al: Reactivity to visual signals and the cerebellar vermis: Evidence from a rare case with rhombencephalosynapsis. Behav Neurosci. 123(1):86-96, 2009
11. Pasquier L et al: Rhombencephalosynapsis and related anomalies: a neuropathological study of 40 fetal cases. Acta Neuropathol. 117(2):185-200, 2009
12. Poretti A et al: Cognitive outcome in children with rhombencephalosynapsis. Eur J Paediatr Neurol. 13(1):28-33, 2009
13. Elliott R et al: Rhombencephalosynapsis associated with autosomal dominant polycystic kidney disease Type 1. J Neurosurg Pediatr. 2(6):435-7, 2008
14. Demaerel P et al: Partial rhombencephalosynapsis. AJNR Am J Neuroradiol. 25(1):29-31, 2004
15. Patel S et al: Analysis and classification of cerebellar malformations. AJNR Am J Neuroradiol. 23(7):1074-87, 2002
16. Toelle SP et al: Rhombencephalosynapsis: clinical findings and neuroimaging in 9 children. Neuropediatrics. 33(4):209-14, 2002

https://CafePezeshki.IR

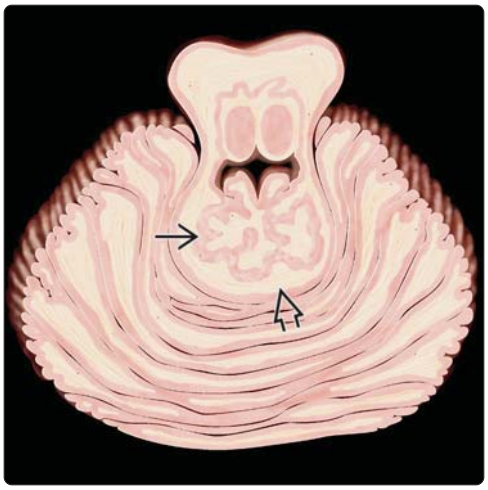

(Left) *Axial graphic of rhombencephalosynapsis shows the absence of vermis. There is fusion of folia, interfoliate sulci, dentate nuclei ⇨, and cerebellar white matter ⇨ across the midline.* **(Right)** *Axial NECT in a child with rhombencephalosynapsis shows the cerebellum appears continuous across the midline, without a discernible vermis.*

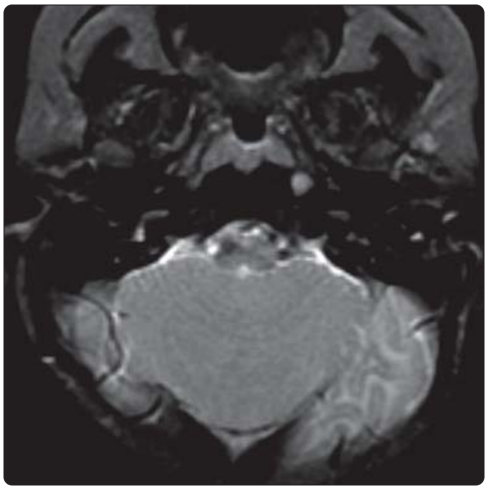

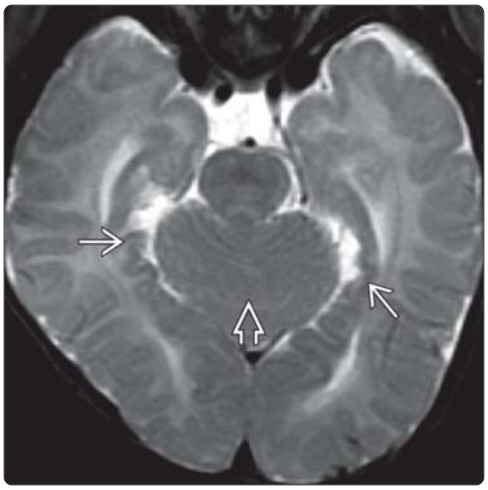

(Left) *Axial T2WI in a case of classic rhombencephalosynapsis shows the vermis is absent and the cerebellar hemispheres appear fused across the midline.* **(Right)** *More cephalad axial T2WI in the same patient shows the cerebellum appears fused across the midline ⇨. Note the abnormal gray matter in the adjacent medial temporal lobes ⇨.*

(Left) *Midline sagittal T2WI in an 11-year-old male with mild mental retardation appears almost normal.* **(Right)** *Coronal T2WI in the same case shows the cerebellar white matter ⇨ is fused across the midline.*

https://CafePezeshki.IR

KEY FACTS

TERMINOLOGY

- Focal or diffuse dysplasias of cerebellar hemispheres or vermis not associated with other known malformations or syndromes

IMAGING

- Asymmetry or focal disruption of cerebellar folial and sulcal morphology
  - Sometimes frank cleft is present
- Bumpy gray-white matter interface in cerebellum
- Lack of normal arborization of white matter
- Abnormal hyperintense signal in subcortical white matter → cyst-like foci
- Cerebellar gray matter heterotopia
- Enlarged and vertically oriented fissures
- Disordered foliation

PATHOLOGY

- Cerebellar cortex does not assume adult-like histology prior to age 1
- In 1 study of 147 normal infants, minor cerebellar dysplasias were identified in close to 85%
  - Some minor dysplasias involute after 9 months of age

CLINICAL ISSUES

- Hypotonia, microcephaly, speech delay

DIAGNOSTIC CHECKLIST

- Assess for "cobblestone" lissencephaly and congenital muscular dystrophy when considering diagnosis of isolated cerebellar dysplasia
- Look for and document associated posterior fossa and supratentorial lesions
- Small cerebellar hemisphere in fetus may reflect dysplasia

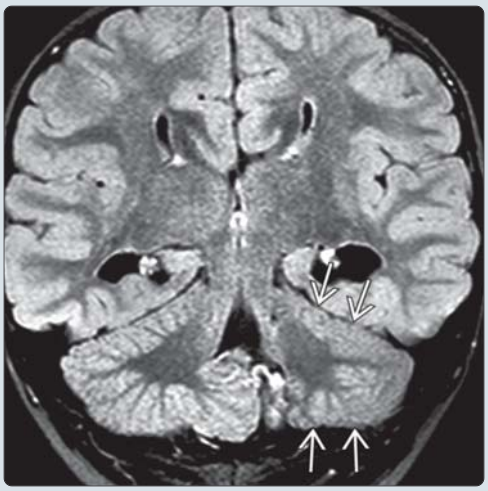

(Left) *Coronal FLAIR MR in a 5 year old with developmental delay and right hemiparesis shows agenesis of the corpus callosum with focal dysplasia of the left cerebellar hemisphere. Note the abnormal foliation in the small affected hemisphere compared to the normal right side.* **(Right)** *Axial T2WI MR in the same patient shows the distorted and disorganized pattern of white matter in the dysplastic left hemisphere in comparison with the normal right cerebellum (folia should be parallel to calvaria in axial plane).*

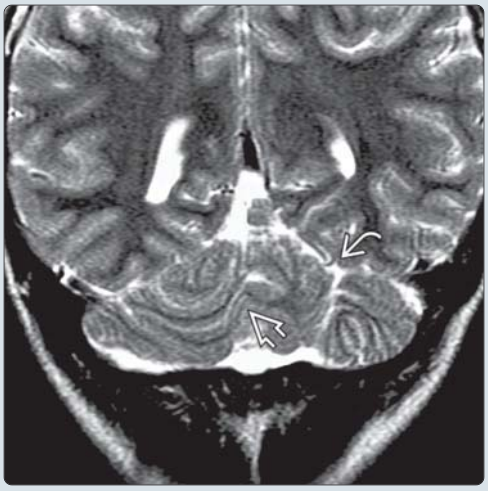

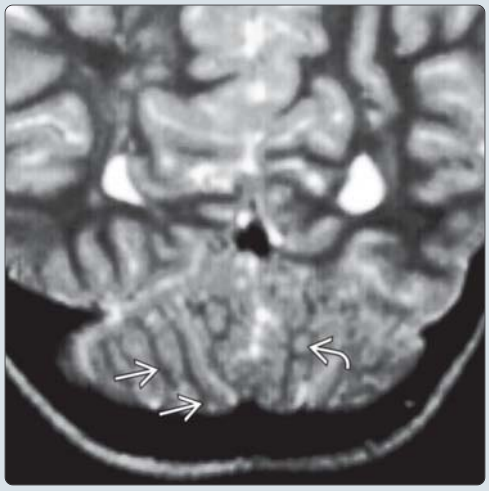

(Left) *Coronal T2WI MR in a child with vermian hypoplasia shows disordered foliation in the right hemisphere and a prominent vertical fissure on the left. These disorders are thought to most likely be disruptions due to prenatal injury.* **(Right)** *Coronal T2WI MR in a 4-year-old boy with global developmental delay shows a very abnormal cerebellum with vertically oriented folia and fissures along with nodular areas of gray matter, likely cerebellar heterotopia.*

https://CafePezeshki.IR

TERMINOLOGY

Synonyms

- Diffuse cerebellar dysplasia
- Cerebellar cortical dysplasia

Definitions

- Focal or diffuse dysplasias of cerebellar hemispheres or vermis not associated with other known malformations or syndromes
  - Excludes Dandy-Walker spectrum, Lhermitte-Duclos disease, rhombencephalosynapsis, molar tooth malformations, congenital muscular dystrophies, syndromic (e.g., PHACES)
  - Excludes infectious (e.g., cytomegalovirus), metabolic etiologies (including inherited, e.g., congenital disorders of glycosylation-1a)

IMAGING

General Features

- Best diagnostic clue
  - Asymmetry or focal disruption of cerebellar folia and sulcal morphology
- Location
  - Variable
    - Can involve both hemispheres and vermis or mainly vermis
    - Can be uni- or bilateral
- Size
  - Variable
- Morphology
  - Variable

CT Findings

- Irregular morphology of 4th ventricle or cisterna magna

MR Findings

- T1WI
  - Bumpy gray-white matter interface in cerebellum
  - Lack of normal arborization of white matter
- T2WI
  - Cyst-like foci in subcortical white matter
  - Gray matter heterotopias, disordered foliation
  - Enlarged and vertically oriented fissures

Imaging Recommendations

- Best imaging tool
  - MR
- Protocol advice
  - Use thin-slice profile T2WI in axial and coronal planes to define cerebellar morphology

DIFFERENTIAL DIAGNOSIS

Rhombencephalosynapsis

- Fused cerebellar hemispheres with vermian hypo-/aplasia

Molar Tooth Malformations (Joubert)

- Bat wing 4th ventricle

Cerebellar Dysplasia Associated With Lissencephalies

- Congenital muscular dystrophies

PATHOLOGY

General Features

- Cerebellar cortex does not assume adult-like histology prior to age 1
- In 1 study of 147 normal infants, minor cerebellar dysplasias were identified in close to 85%
  - Some minor dysplasias involute after 9 months of age

Gross Pathologic & Surgical Features

- Dysmorphic foliation, hemispheres often small
- Primitive foliation
- Mega cisternal magna

Microscopic Features

- Fusing of apposed molecular layers
- Small cavities with meningeal vessels
- Nodules of Purkinje cells
- Deficient/absent granular layer

Associated Findings

- Cerebral cortical dysplasia
- Agenesis/dysgenesis of corpus callosum
- Macro-/microscopic heterotopia
  - Most often posterior (occipital/temporal horns)

CLINICAL ISSUES

Presentation

- Most common signs/symptoms
  - Hypotonia, microcephaly, speech delay
- Other signs/symptoms
  - Ataxia, facial malformations, abnormal eye movements, motor delay

DIAGNOSTIC CHECKLIST

Consider

- Assess for "cobblestone" lissencephaly and congenital muscular dystrophy when considering diagnosis of isolated cerebellar dysplasia

Reporting Tips

- Look for and document-associated posterior fossa and supratentorial lesions

SELECTED REFERENCES

1. Poretti A et al: Cerebellar hypoplasia: Differential diagnosis and diagnostic approach. Am J Med Genet C Semin Med Genet. 166(2):211-26, 2014
2. González G et al: Location of periventricular nodular heterotopia is related to the malformation phenotype on MRI. AJNR Am J Neuroradiol. 34(4):877-83, 2013
3. Massoud M et al: Prenatal unilateral cerebellar hypoplasia in a series of 26 cases: significance and implications for prenatal diagnosis. Ultrasound Obstet Gynecol. Epub ahead of print, 2013
4. Sajan SA et al: Both rare and de novo copy number variants are prevalent in agenesis of the corpus callosum but not in cerebellar hypoplasia or polymicrogyria. PLoS Genet. 9(10):e1003823, 2013
5. Demaerel P: Abnormalities of cerebellar foliation and fissuration: classification, neurogenetics and clinicoradiological correlations. Neuroradiology. 44(8):639-46, 2002

https://CafePezeshki.IR

KEY FACTS

TERMINOLOGY

- Joubert syndrome and related disorders (JSRD)
  - Hindbrain anomaly characterized by dysmorphic vermis, lack of decussation of superior cerebellar peduncle, central pontine tracts, corticospinal tracts
  - JSRD considered as a ciliopathy
- Also sometimes called molar tooth malformation (MTM)

IMAGING

- Molar tooth appearance of midbrain on axial images
- Midline vermian clefting
- Thick, horizontal (perpendicular to brainstem), superior cerebellar peduncles
- Midline depression of 4th ventricular floor at isthmus (thin isthmus on midline)
- High-definition T2 (CISS/FIESTA) provides exquisite structural analysis
- HASTE allows clear identification of molar tooth sign in fetuses
- DTI is useful complementary technique

TOP DIFFERENTIAL DIAGNOSES

- Dandy-Walker continuum
- Vermian and pontocerebellar hypoplasia
- Cerebellar vermian hypoplasia
- Cerebellar vermian atrophy

PATHOLOGY

- > 20 causative genes have been discovered so far
  - All encode for proteins expressed in primary cilium/its apparatus
- Absence of decussation of superior cerebellar peduncles
- Near total absence of pyramidal decussation

CLINICAL ISSUES

- Ataxia, developmental delay, oculomotor and respiratory abnormalities

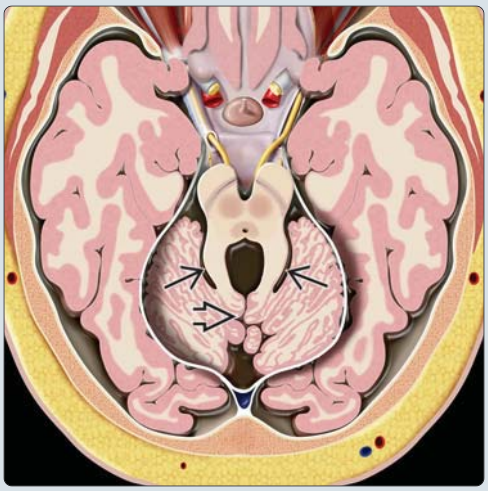

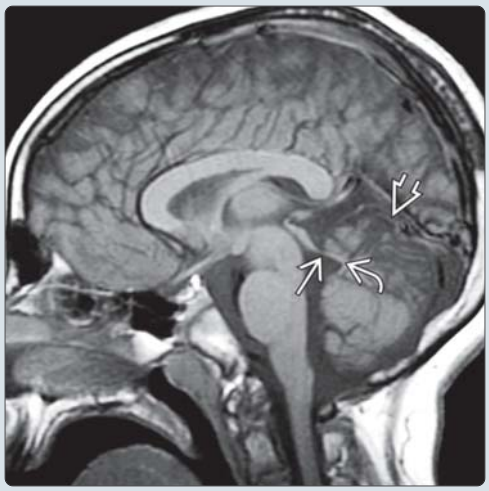

(Left) *Axial graphic depicts Joubert malformation. Thickened superior cerebellar peduncles around the elongated 4th ventricle form the classic molar tooth seen in this anomaly. Note the cleft cerebellar vermis.* **(Right)** *Sagittal T1WI in a patient with classic Joubert syndrome shows a small, grossly malformed cerebellar vermis with upwardly convex superior 4th ventricle and a rounded fastigial point.*

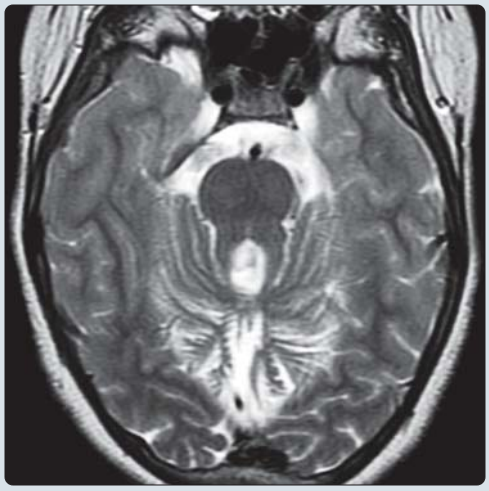

(Left) *Axial T1 MP-RAGE image in the same patient shows a classic molar tooth sign with a foreshortened midbrain and a narrow isthmus. Thick, elongated superior cerebellar peduncles surround an elongated 4th ventricle. Note the vermis clefting.* **(Right)** *Axial T2WI in the same case shows the molar tooth sign even more clearly.*

https://CafePezeshki.IR

TERMINOLOGY

Abbreviations

- Molar tooth malformation (MTM)
- Joubert syndrome and related disorders (JSRD)
  - Include Joubert, Dekaban-Arima, COACH, Senior-Loken, Varadi-Papp, Joubert-polymicrogyria syndromes
  - New genes/syndromes with MTM continue to be described
  - JSRD considered as ciliopathy

Definitions

- Hindbrain anomaly characterized by dysmorphic vermis, thick horizontal superior cerebellar peduncles (SCPs)
  - Sagittal clefting of cerebellar vermis
  - Abnormal brainstem nuclei
  - SCPs, central pontine tracts, corticospinal tracts do not decussate

IMAGING

General Features

- Best diagnostic clue
  - Molar tooth appearance of midbrain on axial images
  - Small vermis with midline clefting
- Location
  - Brainstem isthmus (pontomesencephalic)
  - Vermis and superior (efferent) cerebellar peduncle
- Morphology
  - Hard to identify vermis with midline sagittal cleft
    - Dorsal 4th ventricle has dysmorphic, irregular fastigium
  - Thick, horizontal (perpendicular to brainstem), superior cerebellar peduncles
  - Midline depression of 4th ventricular floor at isthmus (thin isthmus on midline)

CT Findings

- NECT
  - Vermis clefting
  - 4th ventricle has bat wing configuration

MR Findings

- T1WI
  - Sagittal
    - Normal midline appearance of vermis lost
    - Dysmorphic roof of 4th ventricle with fastigial point lost
    - Large CSF spaces, but tentorium in normal location
  - Coronal
    - Vermian clefting above apposed hemispheres (cleft lined with cortex)
  - Axial: Vermian clefting, molar tooth appearance
    - Anteriorly pointed ventricular floor at pons-midbrain junction (thin isthmus)
    - Prominent, in-plane, parallel superior cerebellar peduncles (molar roots)
- T2WI
  - Same findings as T1WI
    - Better contrast than T1WI
    - Prominent CSF spaces common
    - Abnormal myelination sometimes
  - High-definition T2 (CISS/FIESTA) provides exquisite structural analysis
  - HASTE allows clear identification of molar tooth sign in fetuses
- Diffusion tensor imaging (DTI)
  - Superior cerebellar peduncles fail to decussate in mesencephalon
  - ± thinning of middle cerebral peduncle, ventral pontocerebellar tracts

Ultrasonographic Findings

- Prenatal ultrasound shows small vermis, large cisterna magna
  - May show supernumerary digits, heart disease, kidney disease, etc.

Imaging Recommendations

- Best imaging tool
  - MR
- Protocol advice
  - Use high definition; posterior fossa structures are small
  - DTI is useful complementary technique

DIFFERENTIAL DIAGNOSIS

Dandy-Walker Continuum

- Hypo/agenetic vermis (not clefting)
- Cerebellar hemispheres often small
- Elevated tentorium

Vermian and Pontocerebellar Hypoplasia

- Vermis is small, no clefting
- Variable abnormalities of pons, medulla, midbrain

Rhombencephalosynapsis

- Cerebellar hemispheres/dentates are fused without differentiated midline vermis

Cerebellar Vermian Atrophy

- Midbrain, cerebellar peduncles normal; normal vermian foliation with enlarged fissures
- Causal context (prematurity, metabolic, etc.)

PATHOLOGY

General Features

- Etiology
  - Thought to result from mutations of ciliary/centrosomal proteins that can affect cell migration, axonal pathway, other still unknown mechanisms
    - Referred to as ciliopathy
    - Seen in many syndromes (Meckel-Gruber, orofacial-digital syndrome type VI (OFD VI), Bardet-Biedl, Senior-Loken, others)
- Genetics
  - Predominately autosomal recessive
  - > 20 causative genes discovered so far
    - All encoding proteins expressed in primary cilia and its apparatus
    - Associated CNS findings include ocular anomalies, polymicrogyria, cephaloceles, hamartomas
    - Mutations in CSPP1 → classical Joubert syndrome

https://CafePezeshki.IR

- Malformation complexes probably result from disruption of several of the many different processes involving cilia
- Associated abnormalities
  - Polymicrogyria; renal, retinal, hepatic abnormalities
    - Prominent CSF spaces and ventriculomegaly
    - Rarely: Meningoencephaloceles, microcephaly, lissencephaly, agenesis of corpus callosum
    - Hypothalamic hamartomas
  - Juvenile nephronophthisis or multicystic dysplastic kidney
  - Ocular anomalies (retinal dysplasias and colobomata)
  - Hepatic fibrosis and cysts, heart disease, polydactyly

Gross Pathologic & Surgical Features

- Midbrain-hindbrain malformation characterized by
  - Dysmorphic vermis with midline cleft
  - Thick horizontal SCPs
  - Ocular colobomas, polymicrogyria can be found

Microscopic Features

- Absence of decussation of superior cerebellar peduncles
- Near total absence of pyramidal decussation
- Dysplasias and heterotopia of cerebellar nuclei
- Structural anomalies in multiple locations
  - Inferior olivary nuclei, descending trigeminal tract, solitary fascicle, dorsal column nuclei

CLINICAL ISSUES

Presentation

- Most common signs/symptoms
  - Core features: Hypotonia, ataxia, intellectual disability
  - Other: Variable involvement of retina, kidneys, liver
- Other signs/symptoms
  - Neonate: Nystagmus, alternating apnea, hyperpnea (Joubert syndrome), seizures
  - Characteristic facial features
    - Large head
    - Prominent forehead
    - High, rounded eyebrows
    - Epicanthal folds
    - Upturned nose with evident nostrils
    - Tongue protrusion and rhythmic tongue motions
    - In OFD VI, teratomas of tongue
  - Retinal anomalies
    - Congenital retinal dystrophy
    - Pigmentary retinopathy
    - Chorioretinal colobomata
    - Fundus flavus

Demographics

- Age
  - Infancy and childhood; isolated oculomotor apraxia may present later
- Gender
  - M = F

Natural History & Prognosis

- Early death in affected infants
- Older children → problems with temperament, hyperactivity, aggressiveness, and dependency
  - Most affected children are severely impaired

Treatment

- Genetic counseling, physical therapy, occupational therapy

DIAGNOSTIC CHECKLIST

Consider

- MTM whenever scanning infants/children with severe hypotonia and ocular anomalies

Image Interpretation Pearls

- If vermis not recognized or looks small and dysmorphic on sagittal image
- Sometimes vermis looks nearly normal
  - Look for vermian cleft and molar tooth sign on axials

SELECTED REFERENCES

1. Chapman T et al: Diagnostic imaging of posterior fossa anomalies in the fetus and neonate: part 2, posterior fossa disorders. Clin Imaging. 39(2):167-175, 2015
2. Hsu CC et al: High-Resolution Diffusion Tensor Imaging and Tractography in Joubert Syndrome: Beyond Molar Tooth Sign. Pediatr Neurol. ePub, 2015
3. Huppke P et al: Tectonic gene mutations in patients with Joubert syndrome. Eur J Hum Genet. 23(5):616-20, 2015
4. Van Battum EY et al: Axon guidance proteins in neurological disorders. Lancet Neurol. 14(5):532-546, 2015
5. Akizu N et al: Mutations in CSPP1 lead to classical Joubert syndrome. Am J Hum Genet. 94(1):80-6, 2014
6. Poretti A et al: The molar tooth sign is pathognomonic for Joubert syndrome! Pediatr Neurol. 50(6):e15-6, 2014
7. Romani M et al: Joubert syndrome: congenital cerebellar ataxia with the molar tooth. Lancet Neurol. 12(9):894-905, 2013
8. Simms RJ et al: Modelling a ciliopathy: Ahi1 knockdown in model systems reveals an essential role in brain, retinal, and renal development. Cell Mol Life Sci. 69(6):993-1009, 2012
9. Lee JE et al: Cilia in the nervous system: linking cilia function and neurodevelopmental disorders. Curr Opin Neurol. 24(2):98-105, 2011
10. Poretti A et al: Joubert syndrome and related disorders: spectrum of neuroimaging findings in 75 patients. AJNR Am J Neuroradiol. 32(8):1459-63, 2011
11. Saleem SN et al: Prenatal magnetic resonance imaging diagnosis of molar tooth sign at 17 to 18 weeks of gestation in two fetuses at risk for Joubert syndrome and related cerebellar disorders. Neuropediatrics. 42(1):35-8, 2011
12. Sattar S et al: The ciliopathies in neuronal development: a clinical approach to investigation of Joubert syndrome and Joubert syndrome-related disorders. Dev Med Child Neurol. 53(9):793-8, 2011
13. Zaki MS et al: The molar tooth sign: a new Joubert syndrome and related cerebellar disorders classification system tested in Egyptian families. Neurology. 70(7):556-65, 2008
14. Fluss J et al: Molar tooth sign in fetal brain magnetic resonance imaging leading to the prenatal diagnosis of Joubert syndrome and related disorders. J Child Neurol. 21(4):320-4, 2006

https://CafePezeshki.IR

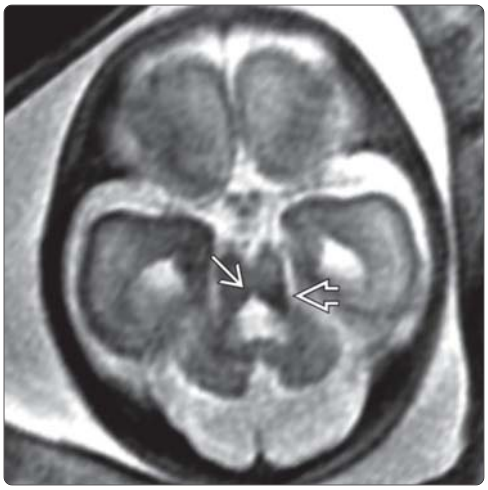

(Left) *Sagittal T2WI MR (HASTE) of a 27-week fetus shows a dysmorphic 4th ventricle ➡ with a hardly recognizable vermis ➡ (abnormal shape, no normal fissures identified). The posterior fossa cisterns are markedly enlarged. Supratentorial structures are normal.* **(Right)** *Axial T2WI MR (HASTE) in the same patient demonstrates an anteriorly pointed 4th ventricle ➡ and thick superior cerebellar peduncles ➡, giving an appearance like a molar tooth.*

(Left) *Sagittal T1WI MR shows classic molar tooth malformation (MTM). Midbrain is elongated and narrow at isthmus ➡. Vermis ➡ is small and dysplastic (abnormal foliation). Fourth ventricle is high, at pons-midbrain junction.* **(Right)** *Axial T1WI MR shows molar tooth sign. Midbrain is narrow in midline due to absent decussation of superior cerebellar peduncles (SCPs). SCPs ➡ are large and horizontal, forming the "roots" of the molar tooth.*

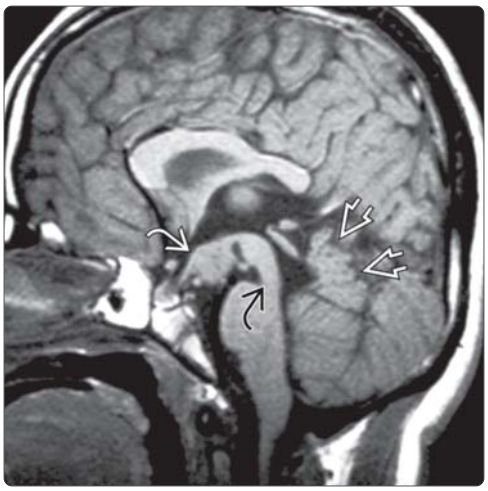

(Left) *Sagittal T1WI MR shows typical features of Joubert with narrow midbrain isthmus ➡, small dysplastic vermis ➡, and a hypothalamic hamartoma ➡ that is characteristic of the Varadi-Papp syndrome.* **(Right)** *Sagittal T1WI MR shows subtle MTM with slightly high 4th ventricle and small vermis. The cerebellar hemisphere ➡ is seen to come into the midline below the abnormal vermis.*

https://CafePezeshki.IR

KEY FACTS

TERMINOLOGY

- Incomplete separation of cerebral hemispheres

IMAGING

- Anomaly and severity defined by degree of forebrain cleavage
  - Spectrum; no clear division between types
- Alobar holoprosencephaly (HPE)
  - Single "ball," "cup," or "pancake" brain around primitive monoventricle
  - ± dorsal cyst, dysmorphic facies
- Semilobar HPE
  - Frontal lobes > 50% fused
  - Thalami, hypothalamus "fused"
  - Posterior interhemispheric fissure, falx may be present
  - ± dorsal cyst, mild/absent facial malformations
- Lobar HPE
  - Interhemispheric fissure present along most of midline
  - Only most inferior frontal lobes fused
  - Thalami almost/completely separated
  - Septum pellucidum always absent
  - Rudimentary frontal horns, ± 3rd ventricle, corpus callosum normal or incomplete

TOP DIFFERENTIAL DIAGNOSES

- Maximal obstructive hydrocephalus
  - Some cortex, falx present; basal ganglia separated
- Hydranencephaly
  - Minimal/no cortex, basal ganglia separated, falx present
- Syntelencephaly or middle interhemispheric variant (MIH) of HPE
  - Anterior, posterior hemispheres separated by falx
  - Midsections fused across midline
- Septooptic dysplasia
  - Frontal horns well formed; fornices fused but present
- Schizencephaly
  - Hemispheric clefts lined with heterotopic gray matter, fornices present

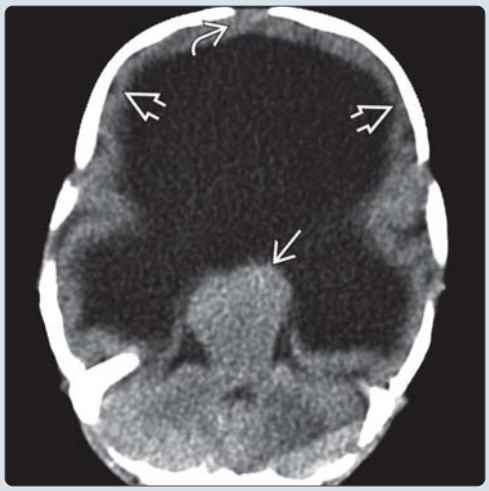

(Left) *3D reconstruction of the facial bones in a newborn infant with a cleft lip and palate shows severe hypotelorism ⇨ and a moderately large midline defect of the maxilla extending into the hard palate and nasal septum ⇨. The 2 central incisors are absent.* **(Right)** *Axial NECT scan in the same patient shows a horseshoe-shaped central monoventricle with a thin rim of surrounding cortex ⇨ that is fused across the midline ⇨. The basal ganglia ⇨ are also fused, characteristic of alobar holoprosencephaly.*

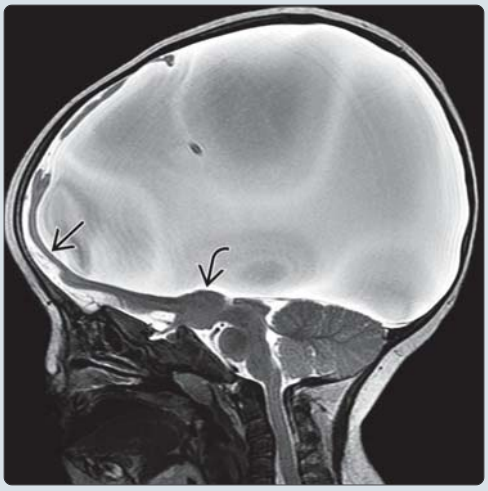

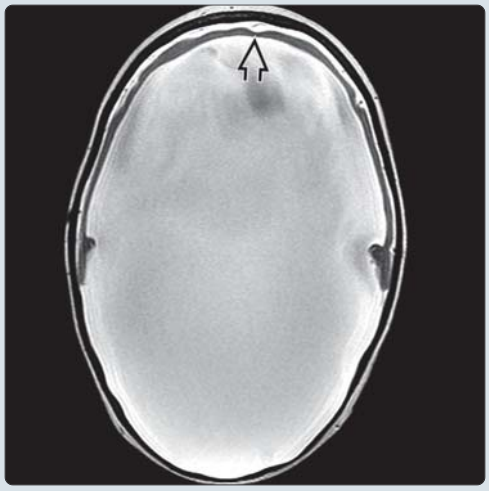

(Left) *Sagittal T2WI in the same patient at 17 months shows the posterior fossa and brainstem appear relatively normal. The supratentorial compartment is almost completely filled with the CSF-containing monoventricle. The hypothalamus and basal ganglia ⇨ are fused and there is a thin rim of agyric cortex ⇨ around the anterior aspect of the monoventricle.* **(Right)** *T2WI in the same patient shows the thin cortex is fused across the midline anteriorly ⇨. No interhemispheric fissure was present and the falx is absent.*

https://CafePezeshki.IR

TERMINOLOGY

Abbreviations

- Holoprosencephaly (HPE)

Synonyms

- Formerly called arrhinencephaly

Definitions

- Incomplete separation of cerebral hemispheres

IMAGING

General Features

- Best diagnostic clue
  - Single ventricle
  - Absent or partial hemispheric and basal cleavage with absent/incomplete interhemispheric fissure/falx
  - Azygous anterior cerebral artery (ACA)
  - ± associated facial defects
- Location
  - Forebrain ± midface
- Morphology
  - Anomaly and severity defined by degree of forebrain cleavage
    - Spectrum; no clear division between types
  - Alobar HPE
    - Single "ball," "cup," or "pancake" brain around primitive monoventricle
      - ± dorsal cyst, dysmorphic facies
  - Semilobar HPE
    - Frontal lobes > 50% fused
    - Posterior interhemispheric fissure, falx may be present
    - Thalami, hypothalamus "fused"
    - ± dorsal cyst, mild/absent facial malformations
  - Lobar HPE
    - Interhemispheric fissure present along most of midline
    - Only most inferior frontal lobes fused
    - Thalami almost/completely separated
    - Septum pellucidum always absent
    - Rudimentary frontal horns, ± 3rd ventricle, corpus callosum normal or incomplete

CT Findings

- NECT
  - Single ventricle without septum pellucidum
  - Uncleaved basal nuclei
  - Variable extent of posterior interhemispheric fissure
  - Variable degree of aplasia of midface, nasal cavity, and paranasal sinuses (all derived from neural crest)

MR Findings

- T1WI
  - Evaluates severity: Alobar, semilobar, or lobar HPE
    - Degree of differentiation of single ventricular cavity, presence of dorsal cyst
      - 3rd ventricle identified when thalami are separated
    - Hemispheric cleavage (extent of interhemispheric fissure [IHF], falx) defines anatomic severity
      - Alobar: No fissure
      - Semilobar: Divided temporal lobes around midbrain
      - Lobar: Fissure extends anteriorly to frontal lobes, posterior callosum present
      - All intermediate degrees can be encountered
    - Gyration variably developed, from agyria to well convoluted
    - Variable extent of basal cleavage: Thalami, striatum, hypothalamus
  - Sylvian angle (SA) reflects frontal development, hence severity of HPE as well
    - Superiorly tilted sylvian fissures (↑ SA) = less developed frontal lobes, more severe HPE
- T2WI
  - Same as T1WI
  - In addition, evaluates myelin maturation, optic nerves/globes, olfactory nerves, pituitary
- DWI
  - DTI helps in identifying white matter (WM) tracts
- MRA
  - ACA
    - May present with early fan-like array of branching arteries over surface of single frontal lobe
- MRV
  - Absent venous sinuses correlate falx/tentorium malformations

Ultrasonographic Findings

- Grayscale ultrasound
  - HPE diagnosable on fetal ultrasound and MR

Angiographic Findings

- Azygous ACA

Imaging Recommendations

- Best imaging tool
  - MR (3-planar, high definition), special attention to midline

DIFFERENTIAL DIAGNOSIS

Severe Obstructive Hydrocephalus

- Severe obstructive hydrocephalus may have massively enlarged ventricles, thin rim of cortex
- Falx present; basal ganglia separated

Hydranencephaly

- Water bag brain appearance; little or no cortex; falx present

Syntelencephaly or Middle Interhemispheric Variant (MIH) of HPE

- Single ventricular cavity: No septum pellucidum, no fornix, no 3rd ventricular roof
- Azygous ACA
- Noncleavage of anterior-inferior basal ganglia (BG)
- Interhemispheric cortical continuity usually in posterior frontal-parietal area
- Anterior &/or posterior corpus callosum found

Absent Septum Pellucidum

- False single ventricular cavity and paired ACA
- Septooptic dysplasia (fornices fused but present)
- Schizencephaly (hemispheric clefts, fornices present)

https://CafePezeshki.IR

Torn Septum Pellucidum

- Severe, usually congenital hydrocephalus
- Typically macrocephalic (HPE usually microcephalic), fornices present

PATHOLOGY

General Features

- Etiology
  - Primary defect of ventral induction, patterning
    - Results in total or partial failure of separation of prosencephalon into 2 separate hemispheres
  - Multifactorial; at least 13 HPE-associated genes but no strict genotype-phenotype correlation
    - Chromosomal abnormality (classically trisomy 13) in 25-50%
      - *SHH* gene 1 of the most important in ventralizing signals during forebrain development
      - *SHH* also controls neural crest (midface), oligodendrocytic (myelination) development
    - Other: Environmental/maternal factors: Diabetes (1% HPE in diabetic mothers), alcohol, retinoid acid, plant alkaloids (*Veratrum californicum*)
- Associated abnormalities
  - HPE mostly sporadic, sometimes familial, 25% syndromic
  - 80% of facial anomalies; correlate with severity of HPE
    - Cyclopia, proboscis; single nare; single nasal bone/absent internasal suture
    - Midline cleft lip or palate; premaxillary agenesis
    - Single maxillary central incisor; absent superior lingual frenulum

Staging, Grading, & Classification

- Class 1 HPE spectrum: All ranges of decreasing severity may be found in same pedigree
  - Includes alobar, semilobar, lobar
  - Midfacial abnormalities without overt brain malformation
    - Flat face, maxillary hypoplasia, midline cleft lip/palate, hypotelorism
  - Isolated single maxillary central incisor (SMCI)
    - Often associated with, but not always an indicator of, HPE
- Class 2 syntelencephaly, or MIH variant of HPE
  - Posterior frontal-parietal cortical continuity across midline; both callosal genu and splenium often present

Gross Pathologic & Surgical Features

- Variable hypoplasia of cortex, variable gyral development
- Variable degree of separation of diencephalon and BG with incorporation into upper brainstem
- Dorsal cyst represents posteriorly located tela choroidea of single ventricle

CLINICAL ISSUES

Presentation

- Most common signs/symptoms
  - Facial malformation with hypotelorism
  - Seizures (50%) and developmental delays
  - Hypothalamic/pituitary malfunction (75%, mostly diabetes insipidus), poor body temperature regulation
  - Dystonia and hypotonia: Severity correlates with degree of BG nonseparation
- Clinical profile
  - Mentally retarded microcephalic infant with hypotelorism

Demographics

- Age
  - Presentation in infancy or early childhood
    - Can be diagnosed with fetal US or MR
- Gender
  - M:F = 1.4:1
- Epidemiology
  - Most common malformation of brain and face in humans
  - 1.3/10,000 live births, but 1 in 250 conceptuses

Natural History & Prognosis

- Over represented in fetal demise, stillbirths
- Clinical severity and life expectancy relate to degree of hemispheric and deep gray nuclei nonseparation (alobar HPE = worst)

Treatment

- Treat seizures and endocrine dysfunction

DIAGNOSTIC CHECKLIST

Consider

- Whenever HPE in doubt, look at basal forebrain for cleavage failure

Image Interpretation Pearls

- Not all cases of missing septum pellucidum are single ventricles

SELECTED REFERENCES

1. Winter TC et al: Holoprosencephaly: a survey of the entity, with embryology and fetal imaging. Radiographics. 35(1):275-90, 2015
2. Gregory LC et al: The role of the sonic hedgehog signalling pathway in patients with midline defects and congenital hypopituitarism. Clin Endocrinol (Oxf). 82(5):728-38, 2015
3. Kruszka P et al: Expanding the phenotypic expression of Sonic Hedgehog mutations beyond holoprosencephaly. J Craniofac Surg. 26(1):3-5, 2015
4. Petryk A et al: Holoprosencephaly: signaling interactions between the brain and the face, the environment and the genes, and the phenotypic variability in animal models and humans. Wiley Interdiscip Rev Dev Biol. 4(1):17-32, 2015
5. Ghosh PS et al: Fetal magnetic resonance imaging in hydranencephaly. J Paediatr Child Health. 49(4):335-6, 2013
6. Lami F et al: Holoprosencephaly: report of four cases and genotype-phenotype correlations. J Genet. 92(1):97-101, 2013
7. Arora K et al: Teaching NeuroImages: fused brain: does face predict the brain? Neurology. 79(23):e201, 2012

https://CafePezeshki.IR

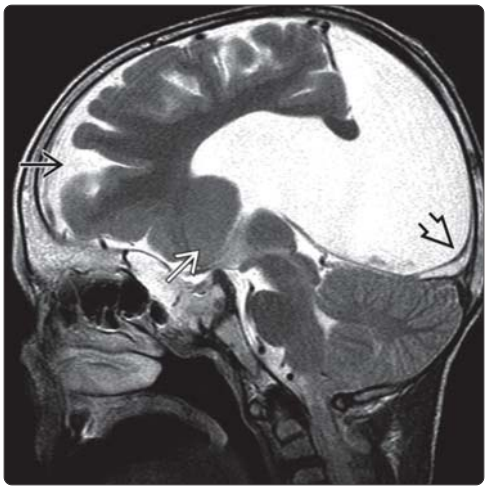

(Left) *Sagittal T2WI MR shows small, single frontal lobe ⇨ with single undivided anterobasal striatum ➡ and the widely expanded tela choroidea forming the prosencephalic dorsal cyst ⇨.* **(Right)** *Axial T1WI MR in the same patient shows lack of hemispheric division. The Sylvian fissures ➡ are anteromedial due to frontal hypoplasia. The anterobasal striatum ⇨ and medial thalamus ➡ are not divided, and the ventricular atria open posteriorly into the dorsal cyst.*

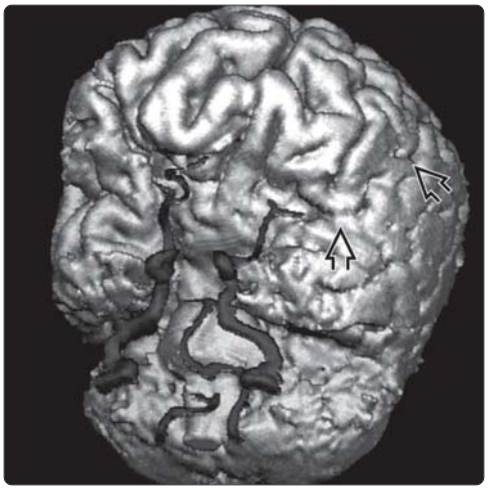

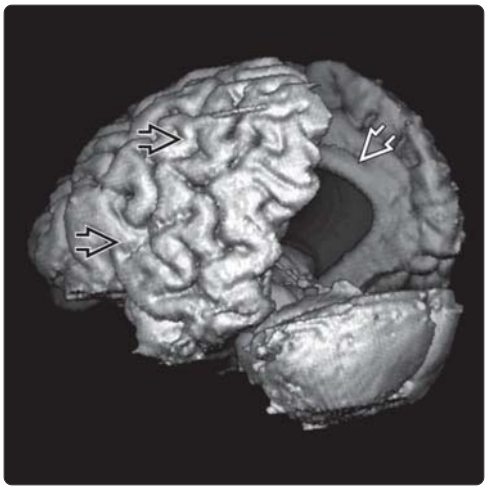

(Left) *Oblique 3D reconstruction was obtained in the same child with semilobar holoprosencephaly (HPE). The major finding is absence of anterior interhemispheric fissure. The gyral pattern is almost normal, but the sylvian fissure ⇨ is shallow and vertical (due to frontal lobe hypoplasia).* **(Right)** *Oblique posterior view of surface rendering 3D T1 gradient-echo sequence shows the large dorsal cyst ➡. Note that the temporal ⇨ cortex shows no normal recognizable gyral pattern. The cerebellum appears normal.*

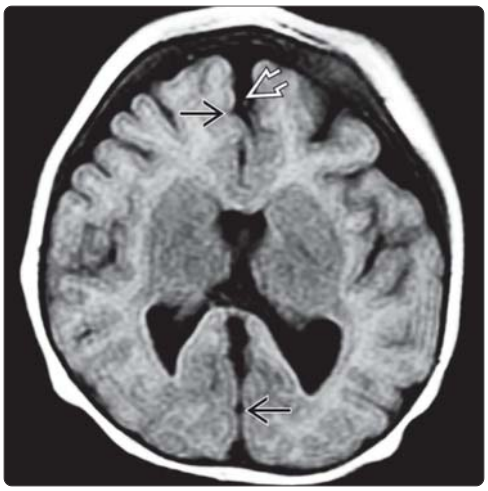

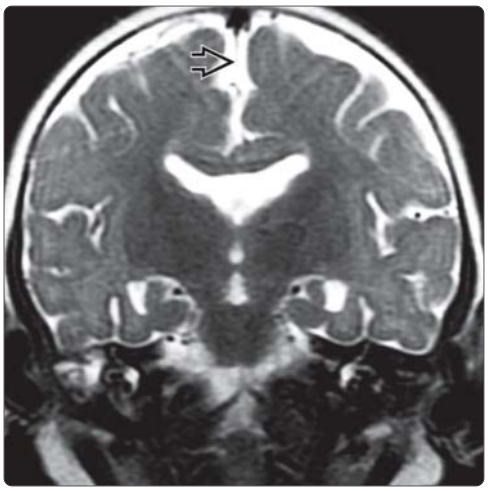

(Left) *Axial T1WI in a 7 month old with central incisor shows mostly separated frontal lobes with a moderately well-developed interhemispheric fissure ⇨ and falx ➡. The septum pellucidum is absent and the frontal horns appear rudimentary.* **(Right)** *Coronal T2WI in the same patient shows the falx cerebri ⇨ in a well-developed interhemispheric fissure. The basal ganglia are separated. The temporal horns are relatively well-formed but vertically oriented. The findings are consistent with lobar holoprosencephaly.*

https://CafePezeshki.IR

KEY FACTS

TERMINOLOGY

- Solitary median maxillary central incisor (SMMCI)
- Middle interhemispheric variant of holoprosencephaly (MIH) (syntelencephaly)
- SMMCI: 1 of several microforms of autosomal dominant holoprosencephaly (HPE)

IMAGING

- MIH: Interhemispheric fusion of posterior frontal/parietal lobes with normal separation of frontal/occipital poles
- SMMCI: Findings range from isolated dental abnormality to alobar HPE
  - Up to 90% have congenital nasal atresia/stenosis

TOP DIFFERENTIAL DIAGNOSES

- Hypodontia: Congenital absence of teeth
- Mesiodens: Supernumerary tooth
- Classic holoprosencephaly

PATHOLOGY

- MIH: Linked to *ZIC2* mutation at 13q32
- *SHH* and *TGIF* mutations identified in SMMCI

CLINICAL ISSUES

- SMMCI: 1:50,000; MIH: Rare
- SMMCI prognosis: Determined by CNS involvement; isolated SMMCI or other microforms, good to excellent
- Clinical profile MIH most similar to lobar HPE

DIAGNOSTIC CHECKLIST

- SMMCI: Inspect nose for nasal stenosis
- SMMCI can be microform HPE, and further MR evaluation of brain should be performed

(Left) *Axial NECT 3D reconstruction shows hypotelorism and an unerupted solitary median maxillary central incisor (SMMCI)* ⇨. **(Right)** *Axial NECT in the same patient shows the precise midline location of the SMMCI* ⇨. *In addition to the prominent midpalatal ridge* ⇨, *the hard palate appears transversely narrow and V-shaped. Although some cases of SMMCI are isolated, many are microforms of holoprosencephaly, and further evaluation with brain MR should be performed.*

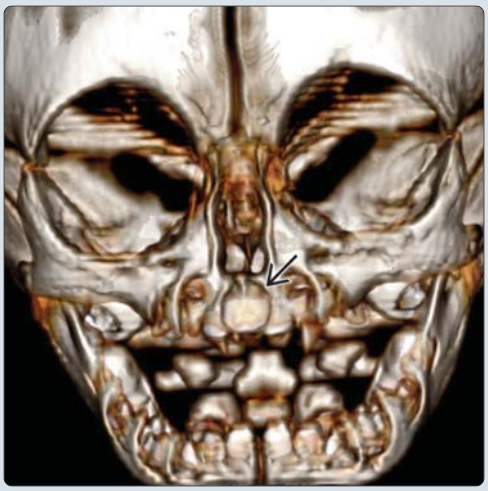

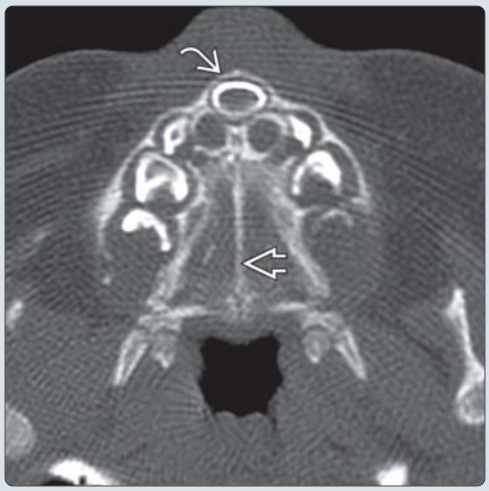

(Left) *Coronal NECT performed in a newborn for nasal obstruction shows the SMMCI* ⇨. *The brain was normal.* **(Right)** *Axial NECT in the same patient shows pyriform aperture stenosis* ⇨ *causing nasal obstruction. Up to 90% of patients with SMMCI have nasal obstruction 2° to choanal atresia, mid-nasal stenosis, or pyriform aperture stenosis and are thus identified in the newborn period. Approximately 60% of patients with pyriform aperture stenosis have SMMCI.*

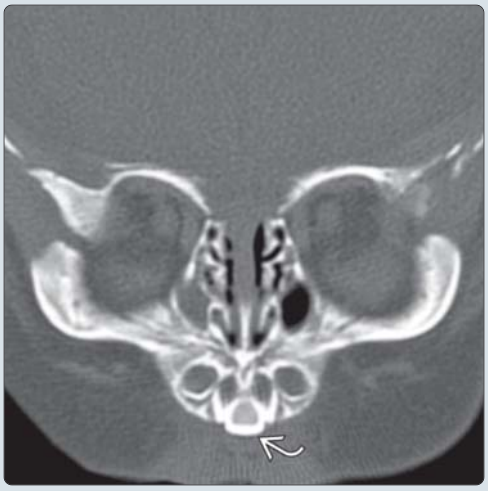

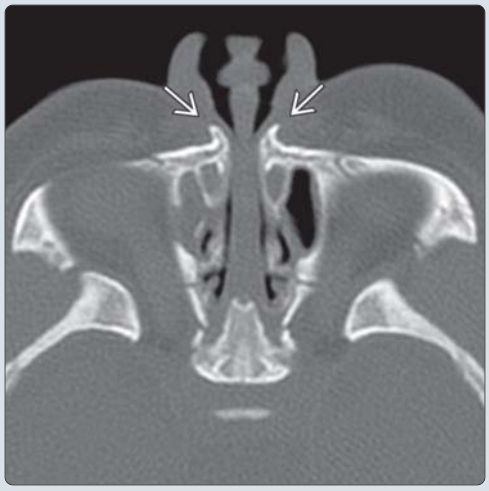

https://CafePezeshki.IR

TERMINOLOGY

Abbreviations

- Solitary median maxillary central incisor (SMMCI)
- Middle interhemispheric variant of holoprosencephaly (MIH)

Synonyms

- Syntelencephaly

Definitions

- SMMCI: 1 of several microforms of autosomal dominant holoprosencephaly (HPE)
- MIH: HPE variant characterized by dorsal telencephalic fusion

IMAGING

General Features

- Best diagnostic clue
  - SMMCI: Single, midline central maxillary incisor
  - MIH: Midline continuity of posterior frontal/parietal lobes with normal separation of frontal/occipital poles
- Location
  - SMMCI: Midline, superior alveolar ridge
  - MIH: Posterior frontal and parietal lobes
- Size
  - SMMCI: Equivalent to normal central incisor
- Morphology
  - SMMCI: Symmetric crown
- MIH
  - Features distinguishing MIH from classic HPE
    - Continuity of posterior frontal and parietal lobes across midline
    - Normal separation of frontal poles with present anterior interhemispheric fissure (IHF)/falx
    - Callosal (CC) dysgenesis characterized by presence of genu and splenium with absent body
    - Normal separation of hypothalamus, basal ganglia
  - Frequent features of MIH
    - Continuity of sylvian fissures across midline
    - Incomplete thalamic separation (33%)
    - Cortical dysplasia/heterotopia
  - Occasional features of MIH
    - Cerebellar abnormalities (20%): Cerebellar hypoplasia, Chiari 1 and 2, cephalocele
  - Features in common with classic HPE
    - Absent septum pellucidum
    - Azygous anterior cerebral artery

CT Findings

- NECT
  - SMMCI
    - Single, midline central maxillary incisor
    - Midpalatal vomerine ridge
    - V-shaped palate
    - Up to 90% have choanal atresia, midnasal stenosis, or pyriform aperture stenosis
  - MIH
    - Interhemispheric isodense band of brain ± sylvian fissure (SF)
- CTA
  - MIH
    - Azygous anterior cerebral artery
    - Middle cerebral artery branches identified in abnormal SF

MR Findings

- T1WI
  - SMMCI
    - Findings range from isolated dental abnormality to alobar HPE
    - Frequent microcephaly, hypotelorism
    - Occasional pituitary/stalk hypoplasia
  - MIH
    - Fused posterior frontal, parietal lobes isointense to brain on all pulse sequences; ± SF fusion
    - Frequent heterotopia/cortical dysplasia along fusion
    - Normal myelin maturation (in contrast to classic HPE)
    - Dysgenetic CC (genu > splenium present, absent body)
- T2WI
  - MIH: 25% hyperintense dorsal cyst
    - Occurs with thalamic noncleavage → obstructs 3rd ventricle
- MRA
  - MIH
    - Azygous anterior cerebral artery
    - Middle cerebral artery branches identified in abnormal SF

Prenatal US/MR

- MIH can be identified in 2nd trimester
- SMMCI can be identified on prenatal MR

Imaging Recommendations

- Best imaging tool
  - SMMCI: Maxillofacial CT
  - MIH: MR with multiplanar 3D T1 gradient-echo sequence
- Protocol advice: Follow-up brain MR for SMMCI

DIFFERENTIAL DIAGNOSIS

Hypodontia

- Congenital absence of teeth
- 2nd premolars, 3rd molars, and maxillary lateral incisors most commonly affected

Mesiodens

- Supernumerary permanent tooth between central maxillary incisors
- Conical, slightly off midline

Classic Holoprosencephaly

- Failure of basal forebrain structures to cleave
- Severity of malformation related to degree of anterior brain development
  - Alobar (least differentiated): Absent IHF, falx, and CC with pancake-like mass of brain
  - Semilobar: IHF/falx formed posteriorly; splenium CC present; fused caudate heads
  - Lobar (most differentiated): IHF/falx extend anteriorly; genu CC aplastic/hypoplastic; minimal frontal lobe fusion

https://CafePezeshki.IR

PATHOLOGY

General Features

- Etiology
  - Theory for SMMCI: Lack of midline cell division and lateral growth of dental lamina by day 35-38 gestation → fusion of left and right dental lamina into single midline incisor
  - MIH: Impaired expression of roof plate properties by week 3-4 gestation alters mitosis/apoptosis → faulty IHF formation and fusion of cerebral hemispheres
- Genetics
  - SMMCI: Microform of autosomal dominant HPE (ADHPE); fewer reported sporadic cases
    - Most common genetic mutations ADHPE: *SHH* 7q36, *ZIC2* 13g32, *SIX3* 2p21, *TGIF* 18p11.3
    - *SHH* and *TGIF* mutations identified in SMMCI
    - Variable expression of ADHPE accounts for wide range of phenotypes (alobar HPE → microforms)
    - 70% penetrance of ADHPE → risk of SMMCI or other microform in offspring obligate carrier = 13-14%
    - Risk of severe (semilobar/alobar) HPE in offspring obligate carrier ADHPE = 16-21%
  - Mutations of SMMCI not associated with HPE: 22q11 deletion, ring chr 18, 47XXX
  - MIH: Linked to *ZIC2* mutation at 13q32
    - In mice, *ZIC2* plays role in differentiation of embryonic roof plate; mutations cause neural tube defects, HPE
    - In contrast to other genes linked to classic HPE, *ZIC2* is not involved in ventral patterning of neuraxis → accounts for lack of severe midline facial dysmorphisms in MIH
- Associated abnormalities
  - SMMCI: VACTERL, CHARGE, velocardiofacial syndrome, ectodermal dysplasia, Duane syndrome, cardiac anomalies (25%), vertebral anomalies
  - MIH: Report of 5 patients with *ZIC2* mutations with limb, renal, and genital anomalies

Gross Pathologic & Surgical Features

- MIH: IHF present in frontal, occipital poles; hemispheric fusion of posterior frontal and parietal lobes; fused SF
- MIH: Foci of undifferentiated cortex, subependymal gray matter heterotopia

Microscopic Features

- MIH: Callosal fibers identified anteriorly, posteriorly

CLINICAL ISSUES

Presentation

- Most common signs/symptoms
  - SMMCI
    - Neonatal nasal obstruction (choanal atresia, midnasal stenosis, or pyriform aperture stenosis)
    - Eruption deciduous SMMCI at 7-8 months; absent upper labial frenulum
  - MIH
    - Spasticity, hypotonia, seizures, developmental delay
- Other signs/symptoms
  - SMMCI
    - Short stature (50%), hypotelorism, microcephaly
      - 33% short stature 2° to ↓ growth hormone
    - Other microforms of ADHPE: Cleft lip, midface hypoplasia, microcephaly, coloboma, choanal atresia, midnasal stenosis, pyriform aperture stenosis, developmental delay, learning difficulties
    - SMMCI with severe HPE (alobar) uncommon
  - MIH
    - Mild facial dysmorphisms frequent: Hypertelorism, cleft lip/palate, SMMCI
    - Severe facial dysmorphisms (as with classic HPE) do not occur
    - Endocrine disorders uncommon
- Clinical profile
  - SMMCI
    - Infant with SMMCI, short stature, hypotelorism
    - Isolated SMMCI in mother and offspring with classic HPE
  - MIH
    - Infant/young child with spasticity

Demographics

- Age
  - SMMCI: Eruption of deciduous incisor at 7-8 months
- Gender
  - Isolated SMMCI more common in females
- Epidemiology
  - SMMCI: 1:50,000
  - MIH: Rare

Natural History & Prognosis

- Prognosis
  - SMMCI: Determined by CNS involvement; isolated SMMCI or other microforms, good to excellent
  - MIH: Mild/moderate psychomotor delay, seizures
    - Clinical profile of MIH most similar to lobar HPE

Treatment

- SMMCI: No treatment for isolated dental abnormality
  - Hormone replacement, corrective surgery for other microforms of ADHPE
- MIH: Antiepileptics

DIAGNOSTIC CHECKLIST

Image Interpretation Pearls

- SMMCI: Inspect nose for nasal stenosis

Reporting Tips

- SMMCI can be microform HPE and further MR evaluation of brain should be performed

SELECTED REFERENCES

1. Ginat DT et al: CT and MRI of congenital nasal lesions in syndromic conditions. Pediatr Radiol. ePub, 2015
2. Winter TC et al: Holoprosencephaly: a survey of the entity, with embryology and fetal imaging. Radiographics. 35(1):275-90, 2015
3. Lygidakis NN et al: Solitary median maxillary central incisor syndrome (SMMCI) with congenital nasal puriform aperture stenosis: literature review and case report with comprehensive dental treatment and 14 years follow-up. Eur Arch Paediatr Dent. 14(6):417-23, 2013

https://CafePezeshki.IR

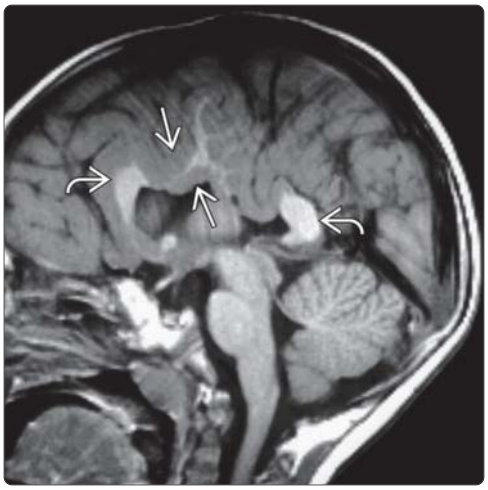

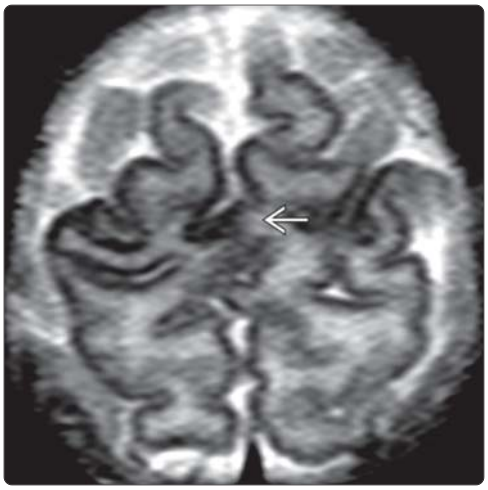

(Left) *Sagittal T1WI MR shows middle interhemispheric variant (MIH) of holoprosencephaly (HPE). GM & WM are continuous across midline at the posterior frontal/parietal lobe levels. Heterotopia/cortical dysplasia cross the midline ➡. In contrast to classic HPE, the callosal body is absent with present genu & splenium ➡. The pituitary/hypothalamus are usually normal in MIH.* **(Right)** *Axial T2WI MR in a patient with MIH shows posterior frontal/parietal continuity across the midline ➡.*

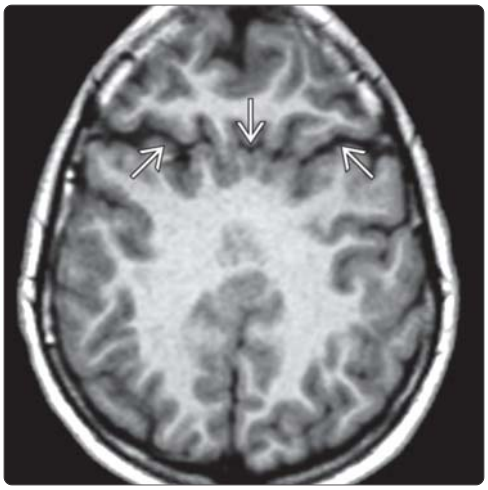

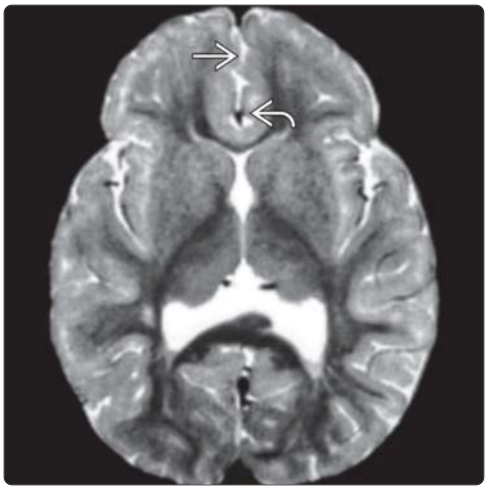

(Left) *Axial T1WI MR shows continuity of frontal white matter & sylvian fissures ➡ across the midline. Sylvian fissure continuity is an inconstant finding but fairly specific for MIH when present.* **(Right)** *Axial T2WI FS MR shows absent septum pellucidum and an azygous anterior cerebral artery ➡ as seen in classic HPE. In contrast to classic HPE, the anterior interhemispheric fissure ➡ & falx are formed and the basal ganglia are separated. Incomplete thalamic separation occurs in 33% of patients.*

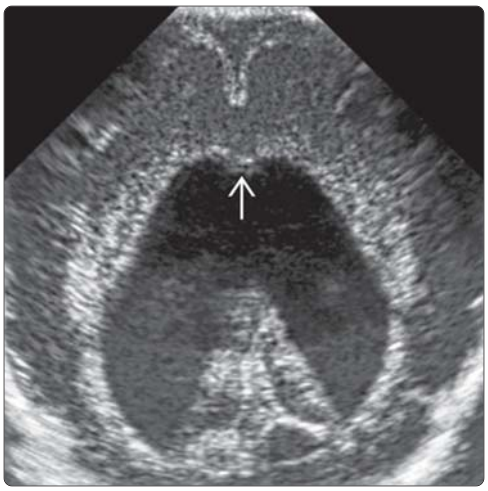

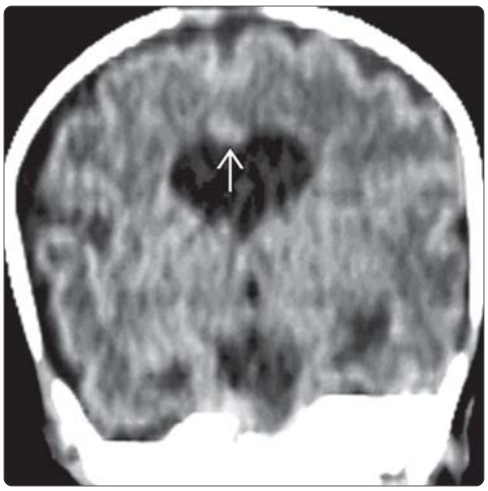

(Left) *Cranial ultrasound in a premature newborn with MIH nicely demonstrates abnormal continuity of the cerebral hemispheres across midline at the mid cranial level. Note the gray matter nodule ➡ in the midline.* **(Right)** *Coronal reconstruction from axial NECT in the same patient confirms MIH. In the location of the posterior frontal and parietal lobes, there is continuity of gray and white matter across the midline. Characteristic of MIH is the gray matter nodule in the midline ➡.*

https://CafePezeshki.IR

KEY FACTS

TERMINOLOGY

- Syntelencephaly; middle interhemispheric (MIH) variant of holoprosencephaly (HPE)

IMAGING

- Single ventricular cavity (100%)
- Fused dorsal mid- or posterior hemispheric cortex (100%) (by definition)
- Azygous anterior cerebral artery (ACA) (100%)
- Abnormal sylvian fissure (SF) spans both hemispheres (86%)
- Heterotopia, cortical malformations (86%)
- Dysgenetic corpus callosum (CC)
- Hypertelorism (most HPEs have hypotelorism)

TOP DIFFERENTIAL DIAGNOSES

- Classic HPE
- Septooptic dysplasia
- Bilateral schizencephaly
- Bilateral perisylvian polymicrogyria (PMG)

PATHOLOGY

- High occurrence of syntelencephaly (as well as other forms of HPE) has been observed in babies born from diabetic mothers
- *ZIC2* mutation at 13q32 is observed in 5-6% of patients

CLINICAL ISSUES

- Spasticity (86%), hypotonia (57%), dystonia (50%), seizures (40%), developmental delay (common)
- Mild facial dysmorphisms frequent: Hypertelorism, cleft lip/palate

DIAGNOSTIC CHECKLIST

- Always look for IHF, septum pellucidum
- Look at bridging cortex lining upper surface of pseudo-corpus callosum
- Distortion of the anterior interhemispheric fissure on prenatal imaging: Look for cerebral midline anomalies

(Left) *Axial graphic depicts classic findings of syntelencephaly, with an anomalous coronal fissure ⇨ and both gray matter (GM) and white matter (WM) bridges ⇨ crossing the interhemispheric fissure in several locations. The gray matter in the cortical bridges appears thickened and dysplastic.* **(Right)** *Axial T1WI MR shows white and gray matter crossing the interhemispheric fissure in the midline ⇨, creating several interhemispheric cortical bridges.*

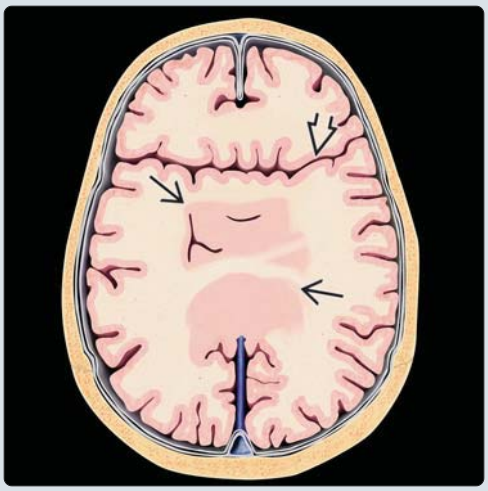

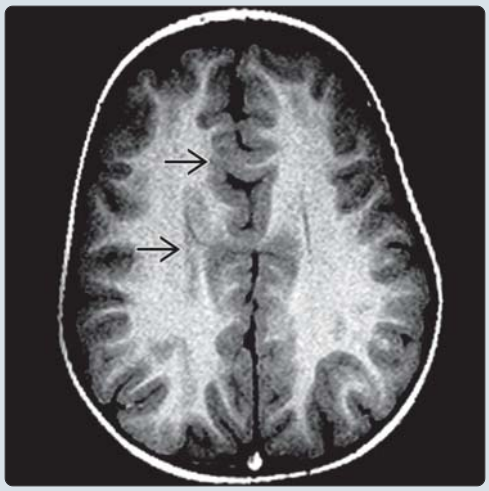

(Left) *Sagittal T1WI MR shows posterior frontal interhemispheric fusion. Note the well-developed callosal splenium ⇨/posterior body, azygous ACA ⇨, & heterotopic GM bulging into the ventricle under the interhemispheric fusion ⇨.* **(Right)** *Coronal T1WI MR (same patient) shows a thick layer of cortex ⇨ crossing the interhemispheric fissure; some GM ⇨ protrudes into the ventricular lumen. Note the parasagittal bright T1 signal bundle of WM ⇨ on each side, which may represent misdirected callosal fibers.*

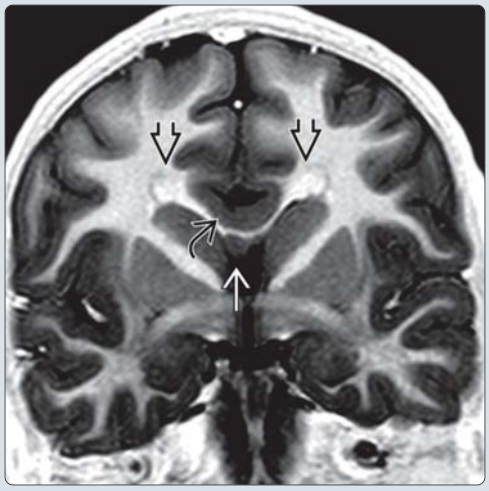

https://CafePezeshki.IR

TERMINOLOGY

Synonyms

- Syntelencephaly
- Middle interhemispheric variant (MIH) of holoprosencephaly (HPE)

Definitions

- Variant of HPE characterized by lack of separation of midportion of hemispheres

IMAGING

General Features

- Best diagnostic clue
  - Midline continuity of posterior frontal/parietal cortex with normal separation of frontal pole
  - Single ventricular cavity
- Location
  - Midline
- Size
  - Typically normocephalic
- Morphology
  - Noncleavage of dorsal aspect of cerebral hemispheres, usually posterior frontal lobes
  - Single ventricular cavity
  - Single (azygous) anterior cerebral artery (ACA)
  - Mostly normal ventral hemispheres, basal ganglia, and hypothalamus

CT Findings

- Axial view: Absent septum pellucidum
- Sagittal reformats: Segmented corpus callosum (typically, only genu and splenium present)
- Coronal reformats: Cortical bridge between midportion of hemispheres, convex upper border of lateral ventricles
- Bone algorithms of facial bones: Cleft lip, cleft palate, hypertelorism
  - Never hypotelorism (unlike true HPE)

MR Findings

- T1WI
  - Hemispheres
    - Unseparated ("fused") dorsal mid-hemispheric cortex (100%) (by definition)
    - Single ventricular cavity (100%)
    - Single abnormal sylvian fissure (SF) spans both hemispheres dorsally (86%)
    - Heterotopia, cortical malformations (86%)
      - Thick cortex lining anterior interhemispheric fissure
      - Heterotopic gray matter nodules often situated on top of lateral ventricle bodies
    - Dysgenetic corpus callosum (CC)
      - Genu and splenium only (61%)
      - Genu or splenium (22%)
      - Genu, splenium, and some of body (20%)
    - Olfactory sulci normal (57%), olfactory bulbs (64%)
    - Hippocampi poorly developed
  - Deep gray matter
    - Lentiform nuclei normal, anterobasal caudate fused (11%)
    - Hypothalamus usually normal
    - Thalami fused (33%)
  - Midbrain
    - Incomplete segmentation diencephalon-mesencephalon (18%)
  - Posterior fossa
    - Chiari malformation, cerebellar hypoplasia possible
  - Meninges
    - Dorsal cyst (25%), may require CSF diversion
    - Rarely, cephaloceles overlying unseparated portion of hemispheres
  - Others
    - No endocrinopathy (unlike HPE)
    - Normal thermoregulation (unlike HPE)
- T2WI
  - Brain morphology
    - Similar to T1WI
  - Brain maturation
    - Myelination is normal, in keeping with patient age (unlike in classic HPE)
- MRA
  - ACA (100%)

Imaging Recommendations

- Best imaging tool
  - MR
- Protocol advice
  - Multisequence triplanar
  - T1-weighted IR, MP-RAGE/SPGR provide exquisite gray/white contrast
  - DTI may help in understanding white matter organization

Ultrasonographic Findings

- Grayscale ultrasound
  - Absent septum pellucidum
  - Absence of middle portion of interhemispheric fissure
- Color Doppler
  - Azygous anterior cerebral artery

DIFFERENTIAL DIAGNOSIS

Classic Holoprosencephaly

- Single hemisphere and ventricle
- Failure of cleavage
  - Hypothalamus
  - Basal ganglia
  - Prefrontal cerebrum

Septooptic Dysplasia

- Absent/incomplete septum pellucidum
- Well-separated cerebral hemispheres
- Well-separated basal ganglia and thalami
- Normal corpus callosum
- Bilateral ACA

Bilateral Schizencephaly

- Clefts communicate with ventricles
- Well-separated cerebral hemispheres
- Bilateral ACA

Bilateral Perisylvian Polymicrogyria (PMG)

- Well-divided hemispheres and ventricles

https://CafePezeshki.IR

- Bilateral ACA

PATHOLOGY

General Features

- Etiology
  - Mitosis/apoptosis of embryonic roof plate form interhemispheric fissure (IHF) after neural tube closure (fetal weeks 3-4)
    - Impaired expression of roof plate properties alters mitosis and apoptosis → faulty dorsal IHF formation, poor cleavage of cerebral hemispheres
  - High occurrence of syntelencephaly (as well as other forms of HPE) has been observed in babies born from diabetic mothers
- Genetics
  - Presumably linked to dorsal induction genes
    - Genes linked to classic HPE (e.g., sonic hedgehog [*SHH*]) mostly affect ventral induction
      - May explain importance of facial defects in classic HPE
    - By contrast, dorsal induction disorder is predominant in syntelencephaly
      - May explain lack of severe midline facial dysmorphisms
      - Presumably induction of neural crest that forms midfacial skeleton proceeds normally
    - *ZIC2* mutation at 13q32 is observed in 5-6% of patients
      - Involved in differentiation of embryonic roof plate
- Associated abnormalities
  - Hypertelorism
  - Cleft lips, palate

Staging, Grading, & Classification

- Classic spectrum of HPEs from alobar to lobar
- Syntelencephaly considered milder end of spectrum
  - Clinically severe, although less than complete HPE

Gross Pathologic & Surgical Features

- IHF present at frontal, occipital poles
  - Hemispheric fusion posterior frontal and parietal lobes
- Lentiform nuclei normal, caudate fused
- Thalami fused in 1/3
- Hypothalamus not fused

CLINICAL ISSUES

Presentation

- Most common signs/symptoms
  - Developmental disorders
    - Spasticity (86%)
    - Hypotonia (57%)
    - Dystonia (50%)
    - Seizures (40%)
    - Developmental delay (speech, etc.) (100%)
    - Absence of choreoathetosis (common in classic HPE)
- Other signs/symptoms
  - Mild facial dysmorphisms frequent
    - Hypertelorism
    - Cleft lip/palate
- Clinical profile
  - Developmental delay
  - Spasticity
  - Seizures

Demographics

- Age
  - Presents in infancy

Natural History & Prognosis

- Static course

Treatment

- Rehabilitation

DIAGNOSTIC CHECKLIST

Consider

- Always look for normal IHF, septum pellucidum in fetuses, developmentally delayed children

Image Interpretation Pearls

- Distortion of the anterior interhemispheric fissure on prenatal imaging: Look for cerebral midline anomalies
- Look at ventricle
- Look at bridging cortex lining upper surface of pseudo-corpus callosum

SELECTED REFERENCES

1. Winter TC et al: Holoprosencephaly: a survey of the entity, with embryology and fetal imaging. Radiographics. 35(1):275-90, 2015
2. Vinurel N et al: Distortion of the anterior part of the interhemispheric fissure: significance and implications for prenatal diagnosis. Ultrasound Obstet Gynecol. 43(3):346-52, 2014
3. Lami F et al: Holoprosencephaly: report of four cases and genotype-phenotype correlations. J Genet. 92(1):97-101, 2013
4. Arora A et al: Teaching NeuroImages: Syntelencephaly: Middle interhemispheric fusion. Neurology. 79(10):e86, 2012
5. Solomon BD et al: Genotypic and phenotypic analysis of 396 individuals with mutations in Sonic Hedgehog. J Med Genet. 49(7):473-9, 2012
6. Mercier S et al: New findings for phenotype-genotype correlations in a large European series of holoprosencephaly cases. J Med Genet. 48(11):752-60, 2011
7. Pineda-Alvarez DE et al: A broad range of ophthalmologic anomalies is part of the holoprosencephaly spectrum. Am J Med Genet A. 155A(11):2713-20, 2011
8. Marcorelles P et al: Neuropathology of holoprosencephaly. Am J Med Genet C Semin Med Genet. 154C(1):109-19, 2010
9. Solomon BD et al: Analysis of genotype-phenotype correlations in human holoprosencephaly. Am J Med Genet C Semin Med Genet. 154C(1):133-41, 2010
10. Dheen ST et al: Recent studies on neural tube defects in embryos of diabetic pregnancy: an overview. Curr Med Chem. 16(18):2345-54, 2009
11. Picone O et al: Prenatal diagnosis of a possible new middle interhemispheric variant of holoprosencephaly using sonographic and magnetic resonance imaging. Ultrasound Obstet Gynecol. 28(2):229-31, 2006
12. Biancheri R et al: Middle interhemispheric variant of holoprosencephaly: a very mild clinical case. Neurology. 63(11):2194-6, 2004
13. Lewis AJ et al: Middle interhemispheric variant of holoprosencephaly: a distinct cliniconeuroradiologic subtype. Neurology. 59(12): 1860-5, 2002
14. Marcorelles P et al: Unusual variant of holoprosencephaly in monosomy 13q. Pediatr Dev Pathol. 5(2):170-8, 2002
15. Simon EM et al: The middle interhemispheric variant of holoprosencephaly. AJNR Am J Neuroradiol. 23(1): 151-6, 2002
16. Barkovich AJ et al: Middle interhemispheric fusion: an unusual variant of holoprosencephaly. AJNR Am J Neuroradiol. 14(2):431-40, 1993

https://CafePezeshki.IR

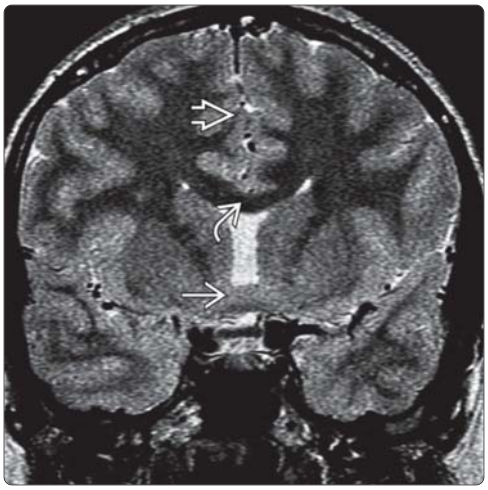

(Left) *Sagittal T1WI MR shows a patient with frontal interhemispheric fusion. The posterior CC is well developed, but the anterior portion is attenuated.* **(Right)** *Coronal thin section T2WI MR shows a continuous bridge of cortex anteriorly between the frontal lobes, with an interhemispheric fissure present dorsally. A single ventricular cavity is present, without a septum pellucidum or forniceal columns. Note the fusion of the anterobasal caudate (nucleus accumbens).*

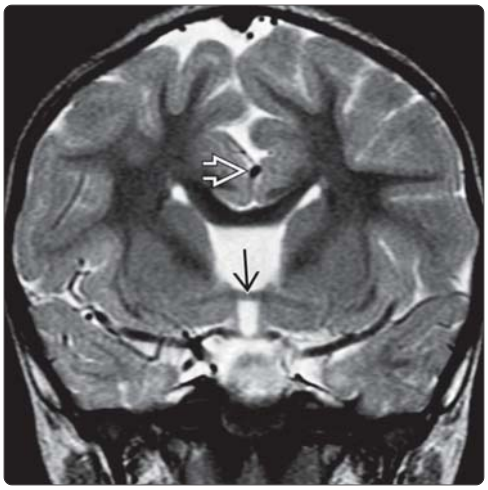

(Left) *Sagittal T1WI MR shows a patient with a more posterior hemispheric fusion. No frank callosal splenium can be seen, although some white matter fibers appear to be crossing the midline just above the lateral ventricles. The genu is present, although hypoplastic.* **(Right)** *Coronal T2WI MR shows clearly separate frontal lobes with azygous ACA. No septum pellucidum can be identified. The anterior commissure appears normal. The hypothalamus is well divided above the chiasm.*

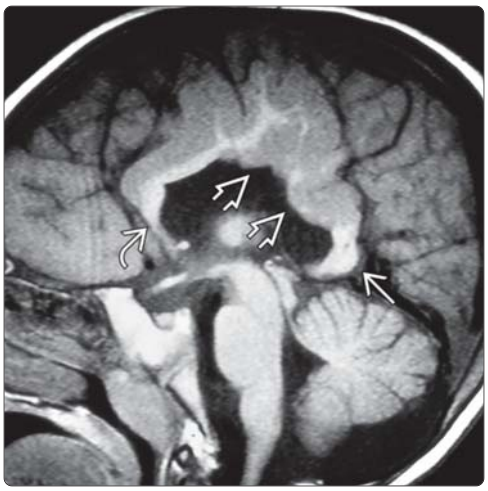

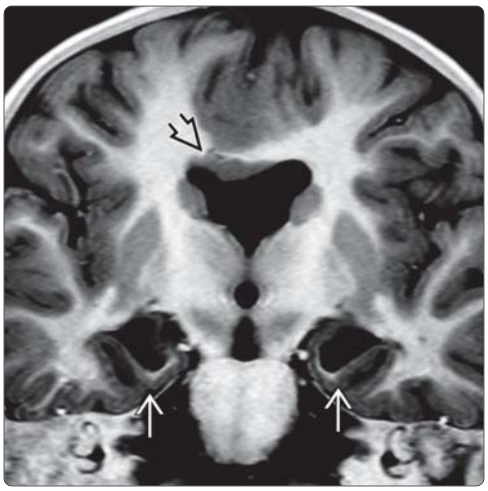

(Left) *Sagittal T1WI MR shows middle hemispheric fusion. The splenium and rostrum are well delineated. In the area of interhemispheric continuity, gray matter encroaches on the ventricular lumen. Interhemispheric fissure was normal in the anterior frontal and the parietooccipital areas.* **(Right)** *Coronal T1WI MR shows a single ventricular cavity and interhemispheric cortical continuity. Note the heterotopic gray matter on the ventricular roof and the poorly developed hippocampi.*

https://CafePezeshki.IR

KEY FACTS

TERMINOLOGY

- Septooptic dysplasia (SOD)
- De Morsier syndrome

IMAGING

- Absent septum pellucidum, small optic chiasm
- Optic nerves, pituitary gland, septum pellucidum
- Coronal imaging shows
  - Flat-roofed ventricles
  - Downward pointing anterior horns
- 3 orthogonal planes crucial to identify all findings
  - Absent septum pellucidum, flat roof of frontal horns, small optic chiasm

CLINICAL ISSUES

- Newborns: Hypoglycemic seizures, apnea, cyanosis, hypotonia, prolonged conjugated jaundice, and (in boys) microphallus
- Abnormal endocrine function (60%): Look for multiple pituitary deficiencies
- Normal endocrine function (40%): Often have schizencephaly, seizures
- Child with short stature, endocrine dysfunction
- Normal or color blindness, visual loss, nystagmus, strabismus
- ± mental retardation, spasticity, microcephaly, anosmia
- 75-90% have brain abnormalities; 45% have pituitary insufficiency
- Bilateral optic nerve hypoplasia (70%)

DIAGNOSTIC CHECKLIST

- SOD in small stature pediatric patient with absent septum pellucidum
- Small optic nerves, with ectopic posterior pituitary lobe, with absent septum pellucidum

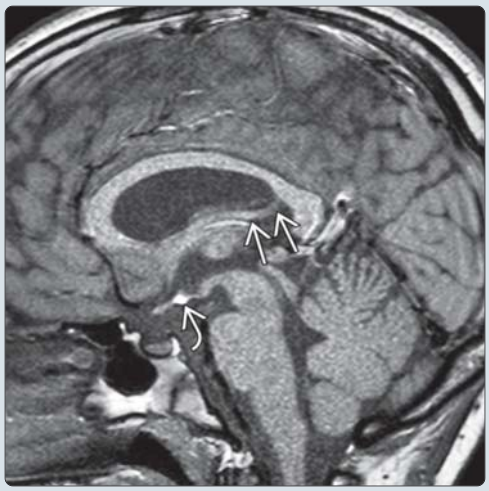

(Left) *Coronal graphic depicts flat-roofed anterior horns and the absence of a midline septum pellucidum. The anterior horns are draped inferiorly around the fornices ⇨, and the optic chiasm ➡ is small.* **(Right)** *Sagittal T1WI MR shows absent septum pellucidum (note the low-lying fornices ➡) and the ectopic posterior lobe of the pituitary gland ➡ at the median eminence. Note that the pituitary gland is small for an adolescent, and the infundibulum is not seen.*

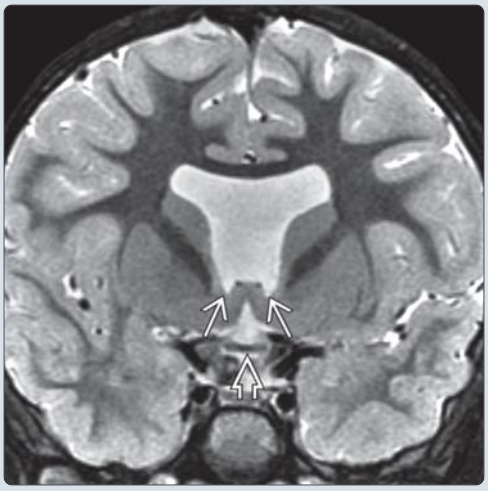

(Left) *Coronal T2WI FSE MR shows the absence of septum pellucidum and pointing ➡ of the inferior margins of the frontal horns, draped over fornices. Note that the optic chiasm ⇨ is normal in size, as is often the case in septooptic dysplasia (SOD).* **(Right)** *Coronal T2WI FSE MR in the same patient at the level of the intraorbital optic nerves shows unilateral optic nerve hypoplasia. The right optic nerve ⇨ is tiny, running through a small optic nerve sheath. The left optic nerve ⇨ is normal.*

https://CafePezeshki.IR

TERMINOLOGY

Abbreviations

- Septooptic dysplasia (SOD)

Synonyms

- De Morsier syndrome
- Kaplan-Grumbach-Hoyt syndrome
- Suprasellar dysgenesis
- Septooptic-pituitary dysgenesis

Definitions

- Heterogeneous association characterized by optic nerve hypoplasia (ONH), absent septum pellucidum, hypothalamic-pituitary dysfunction
  - De Morsier (1956): Described 7 patients with SOD
  - Hoyt (1978): Described association of SOD with hypopituitarism
- Some authors consider SOD and lobar holoprosencephaly to overlap
- SOD plus: Abnormal optic nerves/chiasm, septum pellucidum, pituitary gland, plus cortical dysplasias

IMAGING

General Features

- Best diagnostic clue
  - Absent septum pellucidum, small optic chiasm
- Location
  - Optic nerves, pituitary gland, septum pellucidum
- Size
  - Small optic nerves
  - Small pituitary gland with ectopic posterior lobe
  - Absent septum pellucidum
- Morphology
  - Coronal imaging shows
    - Flat-roofed ventricles
    - Downward-pointing anterior horns

CT Findings

- NECT
  - Absent septum pellucidum
  - Large lateral ventricles
  - Small bony optic foramina on axial and coronal imaging

MR Findings

- T1WI
  - 3 orthogonal planes crucial to identify all findings
    - Absent septum pellucidum (remnants may be present)
    - Flat roof of frontal horns, pointed inferior aspect of frontal horns
    - Small optic chiasm/nerves (fat saturation aides visualization of optic nerves)
    - ± thin pituitary stalk, small anterior lobe of pituitary
    - ± posterior pituitary ectopia
    - Callosal-forniceal continuation or fused midline fornices
    - Thin corpus callosum
    - Vertical hippocampi
    - ± hypoplastic/absent olfactory nerves
    - ± schizencephaly
    - ± heterotopia, polymicrogyria
    - Midbrain-hindbrain abnormalities (short midbrain, small pons, thick quadrigeminal plate, vermian dysplasia) significant but underrecognized component of SOD spectrum
- T2WI
  - Deficient falx (especially anteriorly) ± hypomyelination
- T1WI C+
  - ± ectopic posterior pituitary lobe
  - Delayed enhancement of anterior pituitary lobe on dynamic MR

Angiographic Findings

- Conventional

Imaging Recommendations

- Best imaging tool
  - MR
- Protocol advice
  - Coronal, sagittal thin sections through sella/orbits
  - Use fat saturation or CISS/FIESTA/SPACE to better see optic nerves

DIFFERENTIAL DIAGNOSIS

Syndromes Overlapping With Septooptic Dysplasia

- Optic-infundibular dysplasia, normal septum
- Schizencephaly with absent septum

Kallmann Syndrome

- Absent olfactory nerves
- ± visual, septal, pituitary abnormalities

Holoprosencephaly

- Similar to SOD
  - Many consider it same disorder as SOD

Isolated Ectopic Posterior Pituitary Lobe

- Normal chiasm/nerves, septum pellucidum

PATHOLOGY

General Features

- Etiology
  - Theories
    - Midline heritable defect (mild holoprosencephaly variant)
    - Or secondary degeneration of optic nerve fibers due to cerebral lesion
    - Or vascular disruption (field defect) during brain development
    - Damage to cerebral and optic nerve around 6th week gestation
    - Teratogens: Cytomegalovirus, antiepileptic drugs, alcohol, maternal diabetes
- Genetics
  - Most are sporadic
  - Some are autosomal dominant or recessive
  - Some cases have mutations in *HESX1* gene
    - Homozygous mutations = full syndrome
    - Heterozygous mutations = milder pituitary phenotypes

https://CafePezeshki.IR

- Inactivation of *HESX1* (3p21.2-3p21.2) by Arg53Cys substitution leads to deficient anterior pituitary lobe (does not occur in sporadic SOD)
- Mutations of *FGFR1*, *PROKR2* also described
- Associated abnormalities
  - Frequently associated with other cerebral anomalies
    - Most common = schizencephaly
    - Perisylvian polymicrogyria
    - Midline malformations (callosal dysgenesis, etc.)
    - Ocular anomalies (coloboma, anophthalmia, microphthalmia)
    - Olfactory tract/bulb hypoplasia
    - Incomplete hippocampal rotation
  - Overlapping syndromes with optic, septal, frontal lobe, midline, olfactory deficiencies

Staging, Grading, & Classification

- Isolated ONH: Visual defect only; intelligence and growth normal
- ONH and septal deficiency: Same as isolated
- ONH and septal and pituitary deficiency: May have developmental delay
- Complete septal agenesis: Worse developmental prognosis
- Intrauterine or perinatal insult (especially meningitis) as cause of optic nerve, chiasmatic, and hypothalamic deficiency

Gross Pathologic & Surgical Features

- Small optic chiasm/nerves
- Small or absent geniculate nucleus
- Deficient/absent septum pellucidum
- Forniceal columns (± fused) → run along roof of 3rd ventricle
- Common: Hypoplasia pituitary, olfactory lobes

Microscopic Features

- Optic nerves, chiasm have sparse or absent myelinated fibers
- Geniculate nucleus (if found): Disorganized layering of small neurons

CLINICAL ISSUES

Presentation

- Most common signs/symptoms
  - Newborns: Hypoglycemic seizures, apnea, cyanosis, hypotonia, prolonged conjugated jaundice, and (in boys) microphallus
  - Abnormal endocrine function (60%): Look for multiple pituitary deficiencies
  - Normal endocrine function (40%): Often have schizencephaly, seizures
- Clinical profile
  - Child with short stature, endocrine dysfunction
  - Normal or color blindness, visual loss, nystagmus, strabismus
  - ± mental retardation, spasticity, microcephaly, anosmia

Demographics

- Age
  - Generally detected in infants
  - More common among younger mothers and 1st born child
- Gender
  - M = F
- Epidemiology
  - 1 in 50,000 worldwide
  - Optic nerve hypoplasia
    - 60% have brain abnormalities (not just schizencephaly); 62-88% have pituitary insufficiency
      - 30% have both
    - 25-50% have absent septum pellucidum
  - Septooptic dysplasia
    - 75-90% have brain abnormalities; 45% have pituitary insufficiency
    - Bilateral optic nerve hypoplasia (70%)

Natural History & Prognosis

- Hypothalamic and pituitary crises; sudden death (hypocortisolism)
- Depends upon severity of associated brain and pituitary malformations

Treatment

- Hormonal replacement therapy

DIAGNOSTIC CHECKLIST

Consider

- SOD in small stature pediatric patient with absent septum pellucidum

Image Interpretation Pearls

- Small optic nerves, + ectopic posterior pituitary lobe, plus absent septum pellucidum

SELECTED REFERENCES

1. Cemeroglu AP et al: Spectrum of clinical presentations and endocrinological findings of patients with septo-optic dysplasia: a retrospective study. J Pediatr Endocrinol Metab. ePub, 2015
2. Winter TC et al: Holoprosencephaly: a survey of the entity, with embryology and fetal imaging. Radiographics. 35(1):275-90, 2015
3. Severino M et al: Midbrain-hindbrain involvement in septo-optic dysplasia. AJNR Am J Neuroradiol. 35(8):1586-92, 2014
4. Garcia-Filion P et al: Optic nerve hypoplasia syndrome: a review of the epidemiology and clinical associations. Curr Treat Options Neurol. 15(1):78-89, 2013
5. García-Arreza A et al: Isolated absence of septum pellucidum: prenatal diagnosis and outcome. Fetal Diagn Ther. 33(2):130-2, 2013
6. Bancalari RE et al: Pituitary gland development: an update. Endocr Dev. 23:1-15, 2012
7. Raivio T et al: Genetic overlap in Kallmann syndrome, combined pituitary hormone deficiency, and septo-optic dysplasia. J Clin Endocrinol Metab. 97(4):E694-9, 2012
8. Signorini SG et al: Septo-optic dysplasia in childhood: the neurological, cognitive and neuro-ophthalmological perspective. Dev Med Child Neurol. 54(11):1018-24, 2012
9. Volpe P et al: Disorders of prosencephalic development. Prenat Diagn. 29(4):340-354, 2009
10. Borchert M et al: The syndrome of optic nerve hypoplasia. Curr Neurol Neurosci Rep. 8(5):395-403, 2008
11. Hung JH et al: Prenatal diagnosis of schizencephaly with septo-optic dysplasia by ultrasound and magnetic resonance imaging. J Obstet Gynaecol Res. 34(4 Pt 2):674-9, 2008
12. Riedl S et al: Refining clinical phenotypes in septo-optic dysplasia based on MRI findings. Eur J Pediatr. 167(11):1269-76, 2008
13. Camino R et al: Septo-optic dysplasia plus. Lancet Neurol. 2(7):436, 2003

https://CafePezeshki.IR

(Left) *Axial steady state acquisition (FIESTA) MR with 1 mm sections shows that the right intraorbital section of the optic nerve is extremely thin. Steady state magnetization sequences are excellent for assessing the optic nerve, both in the intraorbital and intracranial segments.* **(Right)** *Axial steady-state acquisition (FIESTA) MR with 1 mm sections in the same patient shows the small intracranial right optic nerve. Compare this with the normal left optic nerve.*

(Left) *Sagittal T1WI MR in a young boy shows stretched corpus callosum and low-lying fornix to suggest absent septum. The optic chiasm is tiny, and the pituitary infundibulum is very attenuated.* **(Right)** *Axial T1WI MR in the same patient confirms absent septum pellucidum and brain anomalies, such as left posterior sylvian polymicrogyria, and transmantle column of heterotopic gray matter extending from the tip of the right occipital horn to the medial occipital cortex.*

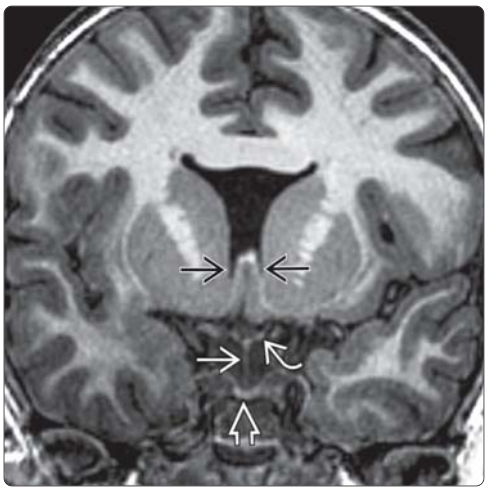

(Left) *Sagittal T1WI MR shows anomalous corpus callosum with discontinuous genu and an abnormally thick, flat, callosal body. The optic chiasm is unusually thin, the pituitary infundibulum is not seen, and the anterior lobe of the pituitary gland is too small.* **(Right)** *Coronal T1WI MR in the same patient shows tiny optic tracts, infundibulum, and anterior lobe of the pituitary gland. The inferior aspects of frontal horns are pointed, curving around the fornices.*

https://CafePezeshki.IR

KEY FACTS

TERMINOLOGY

- Primary (genetic) microcephaly, secondary (nongenetic) microcephaly
- Proportionate vs. disproportionate volume loss of structures

IMAGING

- Imaging findings dictated by cause of microcephaly
  - Dysmorphic vs. destructive
  - Brain anomalies give clues to causative gene
- Consider supplemental use of NECT to detect Ca++
- MR brain: SWI or GRE T2* (blood and Ca++), 3D T1 gradient-echo (brain topography), FLAIR for detecting subdurals
- Ca++ in TORCH and pseudo-TORCH syndromes

TOP DIFFERENTIAL DIAGNOSES

- Antenatal: Preeclampsia, maternal infection (TORCH), maternal diabetes, fetal alcohol syndrome
- Perinatal: Hypoxic-ischemic encephalopathy (HIE), infection
- Postnatal: Prolonged status epilepticus, HIE, hypoglycemia, meningeo-encephalitis, neurodegenerative, abusive head injury

PATHOLOGY

- From any cause, there is reduced growth of brain, ↓ proliferation of glia and neurons
- Simple gyral pattern (oligogyria) vs. dysmorphic growth

CLINICAL ISSUES

- Criteria for diagnosis of microcephaly: Head circumference > 3 standard deviations (SDs) below mean for age and sex

DIAGNOSTIC CHECKLIST

- If midline anomalies accompany microcephaly, consider fetal alcohol syndrome

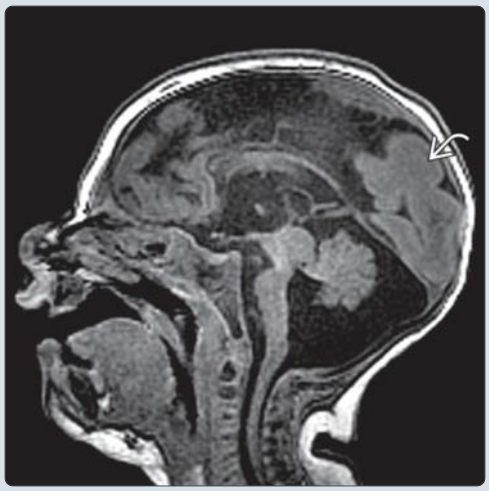

(Left) *Sagittal T1WI MR in an 11-month-old infant shows severe microcephaly with normal posterior fossa structures. Notice the very low craniofacial ratio, which is < 1. The cerebellum and brainstem are disproportionately large.* **(Right)** *Sagittal T1WI MR in a microcephalic newborn (craniofacial ratio slightly ~ 1.5) shows a very small corpus callosum. The pons and cerebellum are disproportionately small compared with the cerebrum. The occipital gyral pattern is simplified.*

(Left) *Coronal T2WI MR of a neonate with MSG group 5 and a head circumference > 3 standard deviations below the mean shows the brain surface is smooth, with reduced white matter volume and an indistinct appearance of the cortical-white matter junction.* **(Right)** *Axial T2WI MR of a microcephalic infant with classical lissencephaly (type 1, LIS1) shows a thick inner band of cortex, cell sparse zone, thin outer cortex, shallow sylvian fissures, and an "hourglass" configuration of the brain.*

https://CafePezeshki.IR

TERMINOLOGY

Abbreviations

- Microcephaly (MCPH)

Synonyms

- Microcephaly with simplified gyral pattern (MSG)

Definitions

- Primary (genetic): Mendelian inheritance **or** associated with genetic syndrome
  - MSG: Head circumference > 3 standard deviations (SDs) below mean, simplified gyri, shallow sulci
  - Microlissencephaly: Head circumference > 3 SDs below mean, pachy- or agyria
- Secondary (nongenetic): Noxious agent affecting fetal, neonatal, or infant brain growth

IMAGING

General Features

- Best diagnostic clue
  - ↓ craniofacial proportions, suture overlap, simplified gyri, shallow sulci
  - Imaging findings dictated by the cause of MCPH
  - More severe MCPH is associated with simplification of gyral pattern
  - Classify by gene mutation if known; also by
    - Relative size of supratentorial/infratentorial structures
    - Supratentorial anomalies (polymicrogyria, heterotopia, callosal anomalies)
    - Association with extra-CNS anomalies
      - Musculoskeletal, cardiac, gastrointestinal, etc.
- Imaging: Dictated by cause of MCPH
  - Primary (genetic) MCPH: Prenatal vs. postnatal, often associated with developmental delay (DD)
    - Prenatal MCPH: Associated with severe MCPH (< 3 standard deviations from mean) at birth
    - Postnatal MCPH: Low normal head size at birth, dropping percentiles (10% to < 1%) during infancy
  - Secondary (nongenetic) MCPH
    - Hypoxic-ischemic encephalopathy (HIE): ± cortical, white matter, or basal ganglia volume loss
    - TORCH infection: Ca++, abnormal white matter, neuronal migration anomalies, germinolytic cysts
    - Abusive head injury: Encephalomalacia, chronic subdurals, ± parenchymal lacerations
- Lateral radiograph, CT scout, or sagittal MR: ↓ craniofacial proportions
  - Normal craniofacial ratios: Preterm (5:1), term (4:1), 2 years (3:1), 3 years (2.5:1), 12 years (2:1), adult (1.5:1)

Radiographic Findings

- Radiography
  - ↓ craniofacial ratio, slanted forehead, closely apposed or overlapping calvarial sutures

CT Findings

- NECT
  - Small cranial vault: Sutures closely apposed, overlapping ± secondary craniosynostosis
  - Ca++ in TORCH and pseudo-TORCH syndromes
  - Cortical surface: Normal ↔ simplified ↔ migrational abnormalities ↔ microlissencephaly

MR Findings

- T1WI
  - Primary (genetic) MCPH, MSG
    - Small yet normal brain ↔ simplified gyral pattern (oligogyria) ↔ microlissencephaly
    - Normal myelination ↔ hypomyelination ↔ demyelination
    - ± various telencephalic anomalies: Callosal absence or dysgenesis, holoprosencephaly, polymicrogyria (PMG), cobblestone cortex, agyria/pachygyria
      - Brainstem/cerebellum may proportional, disproportionately large, or disproportionately small compared with cerebrum
  - Secondary (nongenetic) MCPH
    - Destructive changes: Encephalomalacia, ± Ca++ TORCH infections, ± subdural collections
- T2WI
  - Primary (genetic) MCPH, MSG, or microlissencephaly
    - Sulci (1/4-1/2 normal depth), simplified cortex ↔ pachygyria ↔ heterotopia ↔ PMG ↔ microlissencephaly
    - ↓ commisural fiber tracts, normal basal ganglia volume, ± cerebellar hypoplasia
    - White matter maturation: Normal ↔ hypomyelinated ↔ demyelinated
    - Possible midline anomalies: Absent corpus callosum, holoprosencephaly
  - Secondary (nongenetic) MCPH
    - White matter: Gliosis, cavitation, demyelination, diminished volume, ± hypointensity (Ca++)
    - Cortex: Normal ↔ simplified ↔ polymicrogyria (TORCH)
    - May see thick calvaria, subdurals from shrinking brain
- PD/intermediate
  - Gliosis (↑ signal) and Ca++ (↓ signal) more common in secondary MCPH (infection)
- FLAIR
  - Periventricular: Cavitation (↓ signal), gliosis (↑ signal), ± hyperintense chronic subdural collections
- T2* GRE
  - Sequelae to nonaccidental trauma: Hypointensities from hemorrhagic parenchymal shear injury
- DWI
  - T2 shine through associated with gliosis or demyelination
- MRS
  - ↓ NAA; myoinositol and choline may be ↑ in states of ongoing demyelination and neurodegeneration

Ultrasonographic Findings

- Grayscale ultrasound
  - ± basal ganglia or thalamic Ca++ (TORCH or HIE), ± germinolytic cysts (TORCH)

Imaging Recommendations

- Best imaging tool
  - NECT detects: Ca++ (TORCH, pseudo-TORCH, HIE), encephalomalacia, and subdural collections in abusive head injury

https://CafePezeshki.IR

- MR depicts: Gyral pattern, cortical organization/migration, myelination, midline anomalies, relative size of cerebrum to posterior fossa structures, gliosis, hemorrhage
- Protocol advice
  - Consider supplemental use of NECT to detect Ca++
  - MR brain: SWI or GRE T2* (blood and Ca++), 3D T1 gradient-echo (brain topography), FLAIR for detecting subdurals

DIFFERENTIAL DIAGNOSIS

Secondary (Nongenetic) Microcephaly

- Antenatal
  - Preeclampsia, maternal infection (TORCH), maternal diabetes, fetal alcohol syndrome (FAS)
- Perinatal
  - Hypoxic-ischemic encephalopathy, infection
- Postnatal
  - Prolonged status epilepticus, HIE, hypoglycemia, meningoencephalitis, neurodegenerative, abusive head injury
- Noxious insult

PATHOLOGY

General Features

- Etiology
  - From any cause, there is reduced growth of brain, ↓ proliferation of glia and neurons
- Genetics
  - Primary (genetic) MCPH is typically autosomal recessive (e.g., familial form → 1/40,000 births)
  - Syndrome associations
    - MCPH genetic heterogeneity: Mutations in 1q31 most prevalent
    - Down (21-trisomy), Edward (18-trisomy), Cri-du-chat (5p-), Cornelia de Lange, Rubinstein-Taybi

CLINICAL ISSUES

Presentation

- Most common signs/symptoms
  - Severe mental retardation, ± seizures, developmental delay
- Criteria for diagnosis of MCPH: Head circumference > 3 SDs below mean for age and sex

Demographics

- Age
  - Primary (genetic) MCPH often detected in utero or shortly after birth
  - Secondary (nongenetic) MCPH usually results from insults within first 2 years of life
- Gender
  - Variable based on type: Primary (autosomal recessive inheritance) vs. secondary (nongenetic)
- Ethnicity
  - Common genetic forms ~ panethnic; certain syndromic causes of MCPH may show ethnic preference
- Epidemiology
  - Incidence of MCPH in general population: 0.06-0.16%
  - Incidence of genetically determined MCPH: Familial 1/40,000, Down syndrome 1/800

Natural History & Prognosis

- Dictated by cause of MCPH, variable seizures, mental retardation, and motor handicap

Treatment

- Supportive; genetic testing available for some microcephalic disorders

DIAGNOSTIC CHECKLIST

Consider

- Presence of cerebellar hypoplasia more common in primary MCPH
- If midline anomalies accompany microcephaly, consider FAS

Image Interpretation Pearls

- MR provides most sensitive tool for investigating simplified cortex in MCPH

SELECTED REFERENCES

1. Andrews T et al: Gene networks underlying convergent and pleiotropic phenotypes in a large and systematically-phenotyped cohort with heterogeneous developmental disorders. PLoS Genet. 11(3):e1005012, 2015
2. Moog U et al: Phenotypic and molecular insights into CASK-related disorders in males. Orphanet J Rare Dis. 10(1):44, 2015
3. Çelikel E et al: Evaluation of 98 immunocompetent children with cytomegalovirus infection: importance of neurodevelopmental follow-up. Eur J Pediatr. ePub, 2015
4. Adachi Y et al: Posterior fossa in primary microcephaly: relationships between forebrain and mid-hindbrain size in 110 patients. Neuropediatrics. 45(2):93-101, 2014
5. von der Hagen M et al: Diagnostic approach to microcephaly in childhood: a two-center study and review of the literature. Dev Med Child Neurol. Epub ahead of print, 2014
6. Poirier K et al: Mutations in TUBG1, DYNC1H1, KIF5C and KIF2A cause malformations of cortical development and microcephaly. Nat Genet. 2013 Jun;45(6):639-47. Epub 2013 Apr 21. Erratum in: Nat Genet. 45(8):962, 2013
7. Abdel-Salam GM et al: Profound microcephaly, primordial dwarfism with developmental brain malformations: a new syndrome. Am J Med Genet A. 158A(8):1823-31, 2012
8. Barkovich AJ et al: A developmental and genetic classification for malformations of cortical development: update 2012. Brain. 135(Pt 5):1348-69, 2012
9. Guven A et al: Novel NDE1 homozygous mutation resulting in microhydranencephaly and not microlyssencephaly. Neurogenetics. 13(3):189-94, 2012
10. Adachi Y et al: Congenital microcephaly with a simplified gyral pattern: associated findings and their significance. AJNR Am J Neuroradiol. 32(6):1123-9, 2011
11. Berger I: Prenatal microcephaly: can we be more accurate? J Child Neurol. 24(1):97-100, 2009
12. Abdel-Salam GM et al: Microcephaly, malformation of brain development and intracranial calcification in sibs: pseudo-TORCH or a new syndrome. Am J Med Genet A. 146A(22):2929-36, 2008

https://CafePezeshki.IR

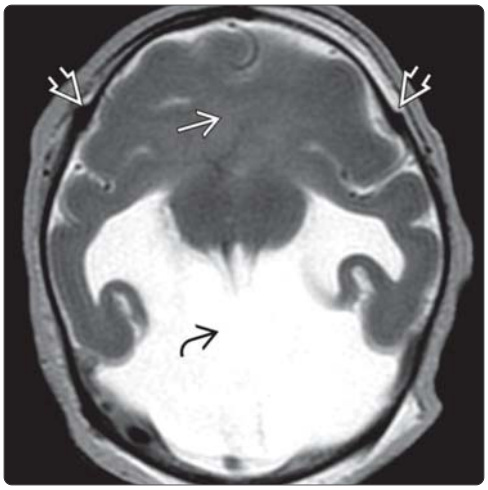

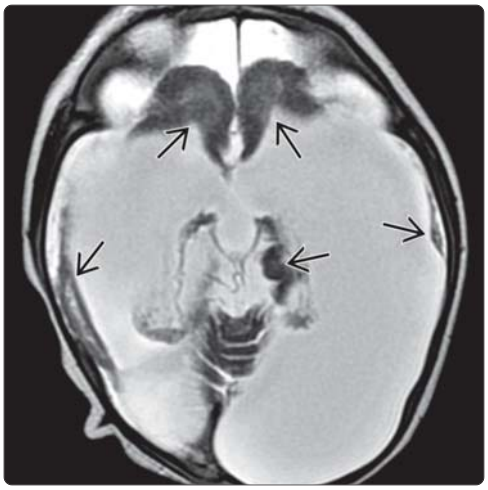

(Left) *Axial T2WI MR of a microcephalic neonate with alobar holoprosencephaly shows fused anterior cerebral tissue ➡. The monoventricle is uncovered posteriorly (dorsal cyst) ⇨. The coronal suture overlap ➡ reflects micrencephaly.* **(Right)** *Axial T2WI MR in a profoundly microcephalic newborn with hydranencephaly shows that the obliteration of tissue is in the carotid arterial distributions. Note the small residual islands of cerebral tissue ⇨ from the frontal and temporal lobes.*

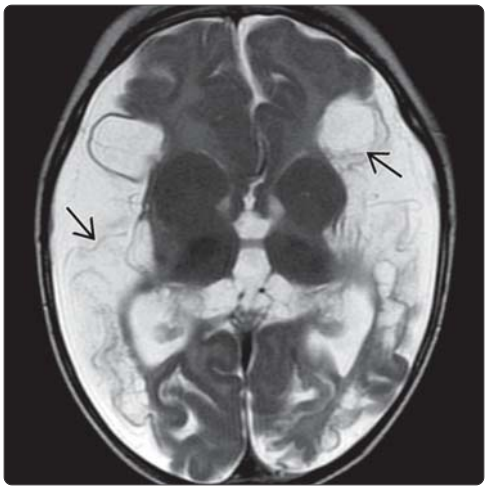

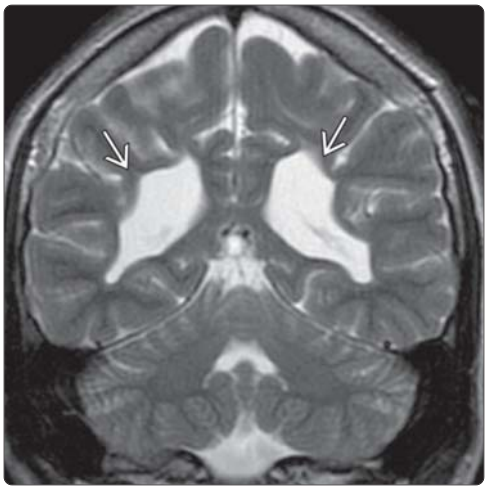

(Left) *Axial T2WI MR in an infant with microcephaly resulting from in utero middle cerebral artery territory infarctions shows extensive hemispheric cystic encephalomalacia ⇨.* **(Right)** *Coronal T2WI MR in a premature microcephalic infant with a maternal history of chorioamnionitis demonstrates marked reduction of periventricular and deep white matter ➡. Axial FLAIR (not shown) revealed findings of periventricular gliosis. These findings reflect a remote perinatal brain injury.*

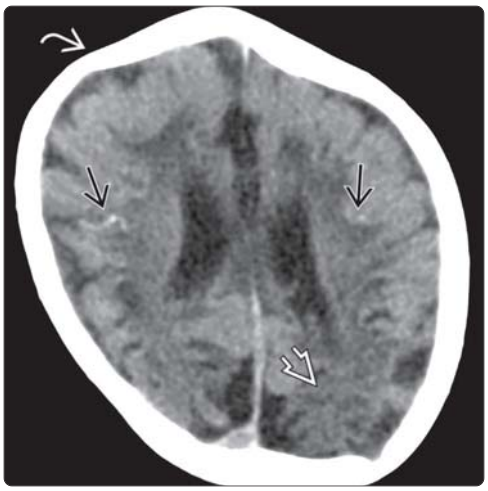

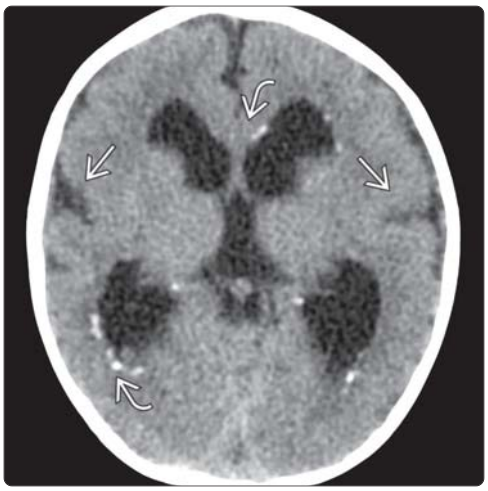

(Left) *Axial NECT in a microcephalic infant, who was the product of a precipitous birth following placental abruption, shows scattered focal subcortical calcifications ⇨, cerebral cortical atrophy ➡, and overlapping of the right coronal suture ⇗, reflecting micrencephaly.* **(Right)** *Axial NECT in a microcephalic infant with a congenital CMV infection shows scattered periventricular calcifications ⇗. Note the shallow sylvian fissures ➡ and associated simplified gyri (polymicrogyria seen on MR).*

https://CafePezeshki.IR

KEY FACTS

TERMINOLOGY

- Congenital muscular dystrophies (CMD): Heterogeneous group of autosomal recessive myopathies presenting at birth with hypotonia

IMAGING

- Cobblestone brain with myelination defects and Z-shaped brainstem in hypotonic infant
  - Look for enlarged tectum
- Polymicrogyria, abnormal myelin, cerebellar cysts

PATHOLOGY

- Mutations in molecules (merosin: Laminin-α2) with roles in cell migration and connection
- Skeletal muscle extracellular matrix protein that binds dystrophin-associated glycoprotein complex utilized in migration of oligodendrocyte precursors
- Autosomal recessive
- CMDs with brain anomalies have hypoglycosylation of α-dystroglycan → neurons overmigrate through gaps in external lamina; "pebbled" brain surface
- Marked phenotypic overlap amongst Fukuyama CMD, Walker-Warburg, and muscle-eye-brain (MEB)
- Muscle biopsy: Mild to moderate dystrophic changes, ± inflammatory infiltrate, ± absent staining laminin-α2

CLINICAL ISSUES

- Hypotonia, developmental delay, poor vision, seizures
- "Floppy" newborn

DIAGNOSTIC CHECKLIST

- Not all Z-shaped brainstems are CMD
- Not all CMD have Z-shaped brainstems (e.g., merosin [-] CMD)

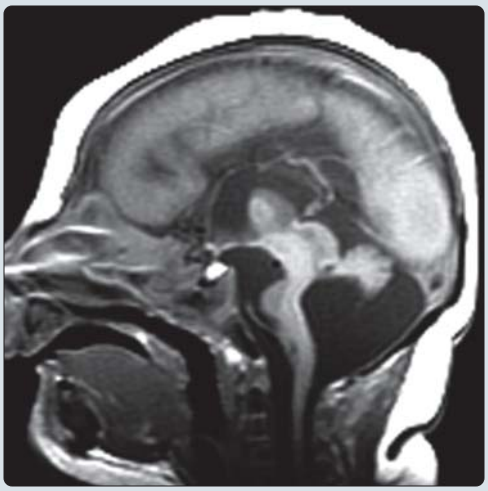

(Left) *Sagittal T1WI MR shows facial dysmorphism, smooth brain, and absent commissures (anterior, callosal, hippocampal). Note the kinked "Z-shaped" brainstem, with small, rotated vermis giving a pseudo-Dandy-Walker appearance. Tentorium is not elevated, however.* **(Right)** *Sagittal T1WI shows a small, flattened pons ⇨, large tectum ⇨, and lack of normal gyration/sulcation in the parietaloccipital region with a cortex that appears thick but somewhat irregular ⇨. The vermis ⇨ is severely hypoplastic.*

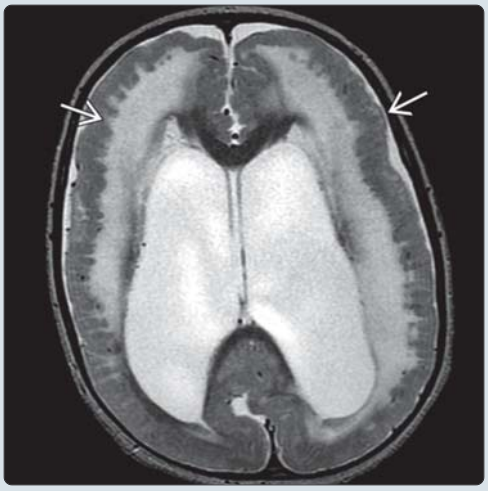

(Left) *Axial T2WI in the same patient shows the classic "pebbly" look of cobblestone gyri ⇨. Severe ventriculomegaly and hypomyelination of the white matter are also present.* **(Right)** *Coronal T2WI in the same case shows the cobblestone cortex with multiple cysts ⇨. "Cobblestone" lissencephaly (LIS2) and congenital muscular dystrophy (CMD) with severe CNS malformations (Walker-Warburg).*

https://CafePezeshki.IR

TERMINOLOGY

Abbreviations

- Congenital muscular dystrophy (CMD)

Synonyms

- Dystroglycanopathies
- CMD 1: Merosin (+) or merosin (-) CMD
- CMD 2-4: "Cobblestone" lissencephaly (LIS2); CMD with severe CNS malformations

Definitions

- CMDs: Heterogeneous group of autosomal recessive myopathies presenting at birth with hypotonia
- CMDs without major brain malformations are either merosin (+) or merosin (-)
  - CMD 1 merosin (+) normal laminin-α2 expression: Normal/very mild imaging findings (cerebellar hypoplasia, nonspecific white matter [WM] changes, focal PMG)
  - CMD 1 merosin (-) deficient laminin-α2 expression: Significant dys-/hypomyelination of WM
- CMD 2-4 with major brain abnormalities (50%) variably associated ("cobblestone" brain, abnormal WM signal, ocular and cerebellar anomalies)
  - CMD 2: Fukuyama CMD (FCMD) least severe
  - CMD 3: Santavuori muscle-eye-brain (MEB) (Finnish type)
  - CMD 4: Walker-Warburg syndrome (WWS) most severe
- Mixed patterns may occur: Merosin (-) CMD with brain malformations
- All result from disturbed late migration of neurons

IMAGING

General Features

- Best diagnostic clue
  - "Cobblestone" brain and Z-shaped brainstem in hypotonic infant
- Morphology
  - CMDs with major brain malformations (WWS most severe)
    - "Cobblestone" brain ± ventriculomegaly ± posterior cephalocele
      - Often nodules of gray matter below cobblestone cortex
    - Agenesis/hypogenesis of corpus callosum
    - Flat or Z-shaped brainstem or notched pons, hypoplastic vermis
  - Less severe cases have polymicrogyria-like malformation with dysmorphic cerebellum, disturbed myelination

CT Findings

- NECT
  - All imaging findings most severe in WWS
    - Huge ventriculomegaly, shallow or absent sulci
    - ↓ attenuation WM
    - Vermian hypoplasia (Dandy-Walker-like) ± posterior cephalocele

MR Findings

- T1WI
  - Thin, dysplastic, polymicrogyric (PMG) or "pebbled" hemispheric cortex, ± ventriculomegaly
  - ± callosal, septal, or vermian hypogenesis
  - Flat, deeply clefted, notched, Z-shaped brainstem with large tectum
- T2WI
  - PMG or "pebbled" cortex, abnormal myelin, cysts cerebellum
    - CMD merosin (-): Dysmyelination centrum semiovale ≤ subcortical WM
    - FCMD, MEB: WM abnormalities in 50%
    - WWS: Severe WM hypomyelination

Imaging Recommendations

- Best imaging tool
  - MR
- Protocol advice
  - Multiplanar, multisequence for white matter, brainstem, and cerebellar changes

DIFFERENTIAL DIAGNOSIS

Multiple Disorders With Brainstem Clefting

- Joubert (mesencephalon and vermian hypoplasia); midline clefting syndromes

Horizontal Gaze Palsy Associated With Progressive Scoliosis (HGPS): Chr 11q23

- Also: Brainstem hypoplasia/clefting, mild cerebellar atrophy

CEDNIK Syndrome

- Mutation of *SNAP29* on 22q11.2

True Polymicrogyria

- Myelination, posterior fossa normal

Peroxisomal Biogenesis Disorders

- Polymicrogyria, hypomyelination, germinolytic cysts

PATHOLOGY

General Features

- Etiology
  - Mutations in molecules (laminin-α2, α-dystroglycan, *ADGRG1*, others) with roles in attachment of radial glial cells to pial limiting membrane (PLM)
    - Disturbed attachment results in gaps in PLM, overmigration of neurons into subarachnoid space
    - Laminin mutations impair oligodendrocyte migration
- Genetics
  - Autosomal recessive
  - CMD 1 merosin (+): Genetic defect(s) unknown
  - CMD 1 merosin (-): Mutation in gene for laminin-α2 on Chr 6
  - CMDs with brain anomalies have hypoglycosylation of α-dystroglycan → neurons overmigrate through gaps in external lamina; "pebbled" brain surface
    - FCMD: Mutation in gene encoding fukutin (*FKTN* at 9q31)
    - MEB: O-Mannoside N-acetyl-glucosaminyl-transversae (*POMGNT1* at 1p32-p34)
    - WWS: O-Mannosyltransferase gene (*POMT1*)

https://CafePezeshki.IR

- Mutations in *FKRP* (fukutin-related protein gene) may cause congenital or late-onset phenotypes
- Other CMD variants with known defects
  - CMD with mutation integrin-α7 gene on Chr 12
  - CMD with familial junctional epidermolysis bullosa (plectin gene on Chr 8)
  - CMD with spine rigidity (linked to Chr 1 in some)
- Mixed patterns and intermediate forms occur
  - CMD merosin (-) with brain anomalies, cerebellar cysts, vermis hypoplasia, mental retardation
- Associated abnormalities
  - Some associated features in CMD variants with "not yet found" mutations: Occipitotemporal PMG, occipital agyria, calf-hypertrophy, arthrogryposis, ptosis, adducted thumbs

Staging, Grading, & Classification

- CMD 1: Abnormal WM varies from mild (CMD 1 merosin [+]) to more severe (CMD 1 merosin [-])
- CMD 2: FCMD: Moderate dysplasia of cerebral neocortex and cerebellum, abnormal WM
  - Frontal PMG, occipital cobblestone cortex, "peripheral 1st" myelination pattern
- CMD 3: Finnish-type MEB, less severe than CMD 4
  - Ventriculomegaly, vermian hypogenesis, dysplastic cortex, patchy abnormal WM, ± callosal dysgenesis
- CMD 4: Walker-Warburg, most severe
  - "Cobblestone" brain, massive ventriculomegaly with absent/abnormal callosum, no myelin, kinked pons-midbrain, vermian hypoplasia ± cephalocele

Gross Pathologic & Surgical Features

- CMDs with brain malformations
  - Supratentorial: Coarse gyri, agyric regions, ± ventriculomegaly and focal interhemispheric fusion
  - Brainstem: Variable degrees of pontine hypoplasia and fused colliculi; flat, cleft, or Z-shaped brainstem
  - Cerebellum: Cerebellar hypoplasia, PMG, and cysts ± encephalocele
  - Ocular: Retinal/optic nerve dysplasias, microphthalmia, buphthalmos, glaucoma, anterior chamber dysplasias, cataracts
- Marked phenotypic overlap amongst FCMD, Walker-Warburg, and MEB

Microscopic Features

- Cortical disorganization, cerebral and cerebellar PMG
- Fibroglial proliferation of leptomeninges (→ "pebbled" surface and trapped CSF "cysts")
- Hypoplasia of white matter
- Muscle biopsy: Mild to moderate dystrophic changes, ± inflammatory infiltrate, ± absent staining laminin-α2

CLINICAL ISSUES

Presentation

- Most common signs/symptoms
  - Hypotonia, developmental delay, poor vision, seizures

Demographics

- Age
  - CMD with brain malformations can be diagnosed in utero via US and MR, otherwise in early infancy
  - FCMD: High percentage of spontaneous abortions
- Gender
  - M = F usually (some M > F or M < F variants)
- Ethnicity
  - FCMD most common in Japan (carrier state 1:88)
  - MEB more prevalent in Finland
  - WWS has worldwide distribution
- Epidemiology
  - 7-12 per 100,000 children in Japan; incidence elsewhere uncertain

Natural History & Prognosis

- CMD 1 (merosin [+]): Mild or nonprogressive; most can sit, some can walk; intellect usually normal
- CMD 1 (merosin [-]): More severe; intellect usually normal; some have seizures
- FCMD: Early contractures, rarely learn to walk, death < 20 years
- MEB: May survive to 20 years but spasticity and contractures
- WWS: Lethal in infancy

Treatment

- No treatment other than supportive

DIAGNOSTIC CHECKLIST

Consider

- Typical brainstem and cerebellar findings should prompt diagnosis even if eyes and supratentorial cortex radiographically normal
- PMG-like cortex with myelination defects: Look for brainstem, cerebellar, and ocular findings

Image Interpretation Pearls

- Not all Z-shaped brainstems are CMD
- Not all CMD have Z-shaped brainstems (e.g., merosin [-] CMD)
- Look for large tectum

SELECTED REFERENCES

1. Kang PB et al: Evidence-based guideline summary: Evaluation, diagnosis, and management of congenital muscular dystrophy: Report of the Guideline Development Subcommittee of the American Academy of Neurology and the Practice Issues Review Panel of the American Association of Neuromuscular & Electrodiagnostic Medicine. Neurology. 84(13):1369-78, 2015
2. Yamamoto T et al: The muscular dystrophies associated with central nervous system lesions: a brief review from a standpoint of the localization and function of causative genes. Curr Pediatr Rev. 10(4):282-91, 2014
3. Quattrocchi CC et al: Conventional magnetic resonance imaging and diffusion tensor imaging studies in children with novel GPR56 mutations: further delineation of a cobblestone-like phenotype. Neurogenetics. 14(1):77-83, 2013
4. Radmanesh F et al: Mutations in LAMB1 cause cobblestone brain malformation without muscular or ocular abnormalities. Am J Hum Genet. 92(3):468-74, 2013
5. Devisme L et al: Cobblestone lissencephaly: neuropathological subtypes and correlations with genes of dystroglycanopathies. Brain. 135(Pt 2):469-82, 2012
6. Myshrall TD et al: Dystroglycan on radial glia end feet is required for pial basement membrane integrity and columnar organization of the developing cerebral cortex. J Neuropathol Exp Neurol. 71(12):1047-63, 2012

https://CafePezeshki.IR

(Left) *Sagittal T2WI (ultrafast single shot) MR in a 20-week-old fetus shows kinked brainstem, dilated 4th ventricle, and hypoplastic vermis. At GA 20 weeks, the abnormal hindbrain is the most significant diagnostic feature of WWS (confirmed postnatally).* **(Right)** *Axial T2WI (ultrafast single shot) MR shows an agyric brain; sylvian fissure at this GA should be apparent. No corpus callosum as well as ventriculomegaly without hydrocephalus are consistent with poor development of WM.*

(Left) *Axial FLAIR MR in a 9-month-old girl, whose brother has MEB, shows prominent CSF spaces and irregular sulcation. Myelination is extensively abnormal ➡ in subcortical, deep, and periventricular WM, with more normal posterior limb of the internal capsule and callosum.* **(Right)** *Sagittal T1WI MR in MEB shows grossly normal forebrain and commissural morphology. Cerebellar vermis is small with microcysts. Note the large tectum ➡ and small pons (flat ventrally ➡ and excavated dorsally ➡).*

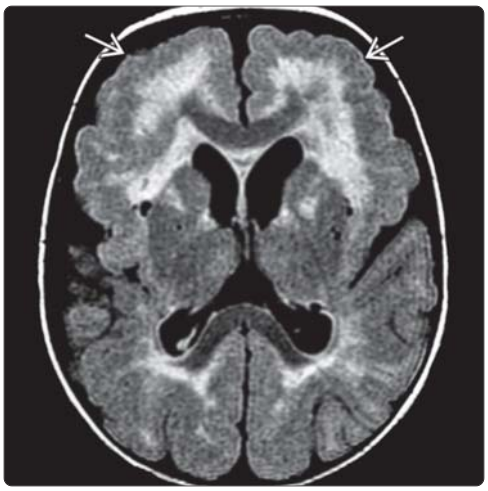

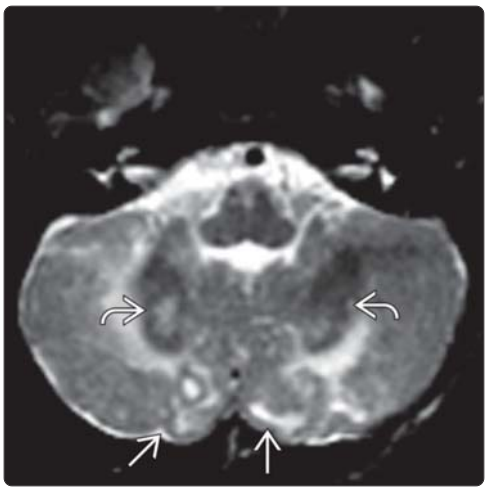

(Left) *Axial FLAIR MR in a 1-year-old girl with FCMD shows large pericerebral spaces, mild ventriculomegaly, and abnormal myelination sparing the corpus callosum. Bilateral frontal polymicrogyria ➡ is a relatively specific finding.* **(Right)** *Axial T2WI MR in FCMD shows a cerebellar cortex that appears blurred due to polymicrogyria. Note the poor myelination of arbor vitae with prominence of dentate nuclei ➡. Multiple high T2 signal cortical microcysts ➡ are typical of FCMD.*

https://CafePezeshki.IR

KEY FACTS

TERMINOLOGY

- Heterotopia (HTP)
- Arrested/disrupted migration of groups of neurons from periventricular germinal zone (GZ) to cortex

IMAGING

- Ectopic nodule or ribbon, isointense with gray matter (GM) on every MR sequence
- Periventricular, subcortical/transcerebral, molecular layer
- Periventricular HTP located next to periventricular white matter (WM) (GZ of cerebral mantle) but not in corpus callosum (fiber tract) or next to basal ganglia (GZ of ganglionic eminence)
- Variable: From tiny to huge, isolated to diffuse
- Thin-slice, high-definition 3D acquisition, heavily weighted T1 provides optimal contrast and definition
- Large nodular HTP: Often thinned, polymicrogyric-looking overlying cortex

TOP DIFFERENTIAL DIAGNOSES

- Tuberous sclerosis
- "Closed-lip" schizencephaly
- Tumors

PATHOLOGY

- Periventricular nodular HTP often genetic when diffuse
  - *FLNA* gene commonly involved (required for cell migration to cortex) on Xq28
- Band HTP: Mild form of type 1 (classic) lissencephaly (agyria/pachygyria/double cortex)
  - Predominantly posterior lissencephaly/band HTP: Deletion *LIS1* located on 17p13.3
  - Predominantly anterior lissencephaly/band HTP: Deletion *DCX* = double cortin on Xq22.3-q23

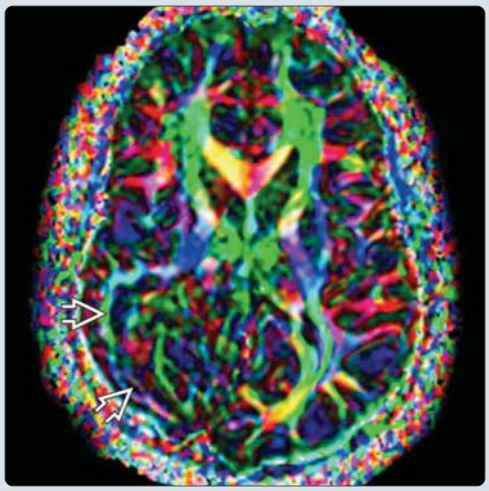

(Left) *Axial T2WI MR in a 6-year-old girl with refractory epilepsy shows massive right posterior subcortical heterotopia (HTP) containing cortex-like GM, white matter (WM), and CSF spaces ⇨, and blood vessels ⇨. The mass may suggest a tumor, but the hemisphere is small. Note the thin overlying cortex.* **(Right)** *Axial DTI color FA map (same patient) depicts the complete disorganization of white matter (WM) in and around nodular subcortical HTP ⇨. Red=R-L, green=A-P, blue=S-I fiber orientation. Other hues imply intermediate directions.*

(Left) *Axial 3D T2WI MR shows subcortical band heterotopia in a 12-year-old boy. The symmetric HTP lies below an intermediate layer of WM. It is thicker posteriorly, in keeping with LIS1 mutation (autosomal recessive). The overlying cortex looks essentially normal.* **(Right)** *Axial T1WI MR in the same patient coregistered with magnetoencephalography (MEG) shows that the MEG spikes (triangles) originate from HTP, yet both the HTP and overlying cortex participate in the epileptogenic loop.*

https://CafePezeshki.IR

TERMINOLOGY

Abbreviations

- Heterotopia (HTP); malformations of cortical development (MCD)

Synonyms

- Gray matter heterotopia; double cortex = band HTP

Definitions

- Heterotopias: Group of MCD characterized by presence of excessive neurons (either isolated or clustered) in subcortical white matter (WM)
  - Reflects arrested/disrupted migration of groups of neurons anywhere from periventricular germinal zone (GZ) to cortex

IMAGING

General Features

- Best diagnostic clue
  - Nodule, clump of nodules or ribbon of tissue isointense with gray matter (GM) on every MR sequence but in wrong location
- Location
  - 3 groups according to location/distribution of heterotopic neurons
    - Neuronal heterotopia (characterized by individual misplaced neurons in WM)
    - Nodular heterotopia (nodules of GM within WM)
    - Band (laminar) heterotopia (double cortex)
  - GM heterotopia can be diffuse or localized; occur anywhere from ependyma to pia
    - Diffuse: Subcortical laminar (band) heterotopia, extensive bilateral periventricular nodular heterotopia
    - Localized: Subependymal (uni- or bilateral), subcortical (nodular, laminar), or unilateral transmantle extension from subependymal region to cortex
- Size
  - Variable: From tiny to huge, isolated to diffuse
- Morphology
  - Periventricular nodular heterotopia (most common)
    - Focal/multifocal asymmetric GM indentation of ventricle
    - Diffuse vs. anterior vs. posterior
  - Band heterotopia = laminar HTP, double cortex
    - Thick symmetric subcortical GM band with thin cortex
  - Subcortical nodular heterotopia
    - Focal HTP nodules, often single
      - Large nodular HTP: Often thinned, polymicrogyria-like overlying cortex
    - Multinodular, swirling GM mass continuous both with cortex and ventricular surface; contain GM, WM, sometimes pia, vessels, and CSF
  - Associated subcortical and periventricular HTP

CT Findings

- NECT
  - Isodense with GM (extremely rare dysplastic Ca++)
- CECT
  - No enhancement

MR Findings

- T1WI
  - Imaging characteristics match GM
  - Well demarcated
- T2WI
  - Imaging characteristics match GM
  - If subcortical, look for continuity with cortex and ventricular surface
    - If large → small ipsilateral hemisphere, large ipsilateral ventricle common (poor WM development)
- FLAIR
  - GM signal
- DWI
  - DTI shows connectivity patterns

Ultrasonographic Findings

- Grayscale ultrasound
  - Fetal US and MR have documented periventricular heterotopia

Nuclear Medicine Findings

- PET
  - Band HTP: Glucose uptake ≥ normal cortex
- SPECT (HMPAO-SPECT)
  - Perfusion similar to normal cortex; HTP included in brain circuitry

Imaging Recommendations

- Best imaging tool
  - MR imaging
- Protocol advice
  - Thin-slice and high-definition 3D acquisition, heavily weighted T1 provides optimal contrast and definition

DIFFERENTIAL DIAGNOSIS

Tuberous Sclerosis

- Subependymal nodules of tuberous sclerosis bulge into ventricular lumen, along thalamocaudate groove, or over caudate
  - Often calcify; may enhance; associated with tubers, subependymal giant cell astrocytoma

"Closed-Lip" Schizencephaly

- Gray matter extending from cortex to ventricle lines cleft (look for "kissing" ventricle)
  - Transcerebral HTP may be associated with, even contralateral to, schizencephalic cleft

Tumors

- Ependymal seeding

Cytomegalovirus

- Periventricular calcifications

PATHOLOGY

General Features

- Etiology
  - Genetic: Mutations alter molecular interactions at multiple migration points → migration arrest → HTP
    - Mutation impairs neuroblast from migrating along radial glial cell to cortex

https://CafePezeshki.IR

- Acquired (rare): Toxins/infections → reactive gliosis/macrophage infiltration → disturbed neuronal migration/cortical positioning
- Genetics
  - Periventricular nodular HTP often genetic
    - *FLNA* gene commonly involved (required for cell migration to cortex) on Xq28
    - Other periventricular HTP localizing to 5p15.1, 5p15.33, 7q11.23
    - Microcephaly and nodular periventricular HTP: *ARFGEF2*
  - Band HTP is mild form of classic lissencephaly (agyria/pachygyria/double cortex)
    - Predominantly posterior lissencephaly/band HTP: Deletion *LIS1* located on 17p13.3
    - Predominantly anterior lissencephaly/band HTP: Deletion *DCX* = double cortin on Xq22.3-q23
    - Mutations of Tubulin genes and microtubule associated protein genes also cause band HTP
- Associated abnormalities
  - Associated malformations vary with location of periventricular HTP
    - Hypoplasia of corpus callosum with diffuse or anterior periventricular HTP
    - Agenesis of corpus callosum with interhemispheric cysts (e.g., Aicardi syndrome): Nodular subcortical HTP nearly always present
    - Corpus callosum dysgenesis, cerebellar and hippocampal malformations associated with trigonal and temporal periventricular HTP
- Embryology
  - Cellular migration: Cell-cycle control, cell-cell adhesion, growth factor, neurotransmitter release, interaction with matrix proteins
    - Pyramidal cell progenitors produced in subventricular GZ (mantle) migrate toward surface, guided by radial glia
    - Stop-signal from Cajal-Retzius cells in molecular layer (future cortical layer 1)
    - Inside-out process: Younger neurons more superficial
    - Migration essentially finished by week 20
  - Abnormal migration
    - → GZ (periventricular HTP), → mantle but below cortex (subcortical HTP), → molecular layer, beyond pia → meninges (leptomeningeal HTP = "cobblestone" brain)

Staging, Grading, & Classification

- Classification by location, type, and size; phenotype may predict genotype
  - Periventricular nodular HTP
    - Isolated, multiple, diffuse/anterior/posterior, uni-/bilateral
  - Band HTP (laminar HTP, double cortex) part of lissencephaly type 1
    - Lesser form of agyria, agyria/pachygyria spectrum
  - Leptomeningeal HTP
    - Seen in "cobblestone" brain (often with congenital muscular dystrophies)

Gross Pathologic & Surgical Features

- Variable gray matter masses

Microscopic Features

- Multiple cell types, immature/dysplastic cells
  - Excitatory exceeds inhibitory

CLINICAL ISSUES

Presentation

- Most common signs/symptoms
  - Cognitive function, seizure onset/severity depend on location/degree of abnormalities
- Clinical profile
  - Young child with developmental delay, seizures

Demographics

- Age
  - Severe cases present in infancy with seizure and severe motor and cognitive dysfunction
  - In milder cases, epilepsy may appear in 2nd decade and tends to become severe
- Gender
  - Males with X-linked disorders have significantly worse brain malformation and outcome
- Epidemiology
  - 17% of neonatal CNS anomalies at autopsy
  - Found in up to 40% of patients with intractable epilepsy

Natural History & Prognosis

- Variable life span dependent on extent of malformation and severity of epilepsy
- Can be incidental on imaging/autopsy

Treatment

- Palliative surgery reserved for intractable seizures

DIAGNOSTIC CHECKLIST

Consider

- Gray matter HTP common and commonly associated with other anomalies

Image Interpretation Pearls

- Gray matter HTP does not enhance or calcify
  - Extremely rare dystrophic Ca++

SELECTED REFERENCES

1. Pardoe HR et al: Quantitative assessment of corpus callosum morphology in periventricular nodular heterotopia. Epilepsy Res. 109:40-7, 2015
2. Sarnat HB et al: Timing in Neural Maturation: Arrest, Delay, Precociousness, and Temporal Determination of Malformations. Pediatr Neurol. 52(5):473-486, 2015
3. Bahi-Buisson N et al: New insights into genotype-phenotype correlations for the doublecortin-related lissencephaly spectrum. Brain. 136(Pt 1):223-44, 2013
4. Conti V et al: Periventricular heterotopia in 6q terminal deletion syndrome: role of the C6orf70 gene. Brain. 136(Pt 11):3378-94, 2013
5. 1: Aronica E, Becker AJ, Spreafico R. Malformations of cortical development. Brain Pathol. 2012 May;22(3):380-401. doi: 10.1111/j.1750-3639.2012.00581.x. Review. PubMed PMID: 22497611.
6. Barkovich AJ et al: A developmental and genetic classification for malformations of cortical development: update 2012. Brain. 135(Pt 5):1348-69, 2012
7. Pisano T et al: Peritrigonal and temporo-occipital heterotopia with corpus callosum and cerebellar dysgenesis. Neurology. 79(12):1244-51, 2012

https://CafePezeshki.IR

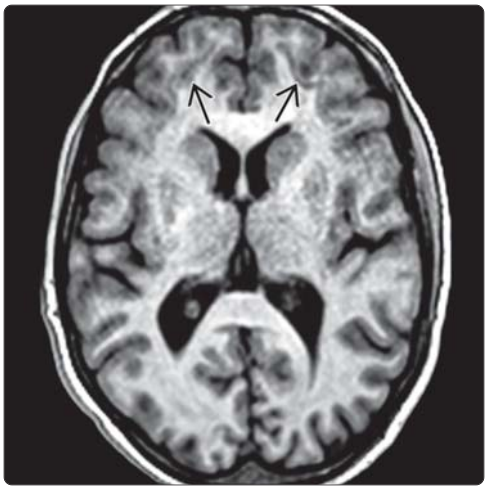

(Left) *Axial T1WI MR in a 15-year-old girl with severe epilepsy shows small, bilateral, frontal band HTP ⇨ seen under a normal-looking cortex. The anterior location of the HTP suggests a DCX gene defect.* **(Right)** *Axial T2WI MR shows a 2-year-old girl with optic atrophy disclose bilateral perisylvian polymicrogyria, absent septum pellucidum, and a single nodular periventricular HTP ➡, isointense to cortex. Heterotopia are rarely seen beneath polymicrogyria.*

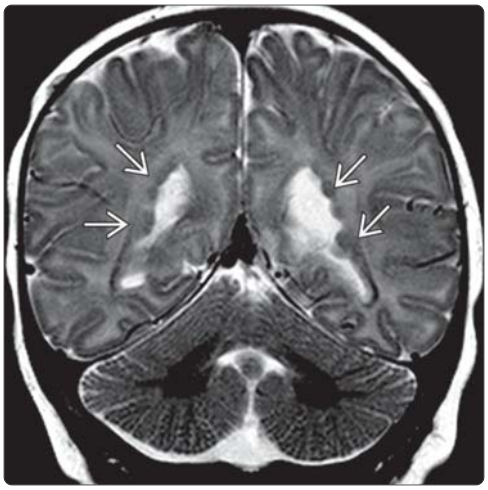

(Left) *Coronal T2WI MR in a 5-month-old boy shows mild ventriculomegaly with multiple nodular periventricular HTP ➡ lining the ventricular atria. A mega cisterna magna was also present.* **(Right)** *Axial T1WI MR of a 9-year-old girl with headaches (no seizures) reveals extensive bilateral periventricular nodules, isointense to gray matter ⇨ that continuously line the lateral ventricles. Bilateral diffuse nodular periventricular HTP is often related to a FLNA mutation (Xq28).*

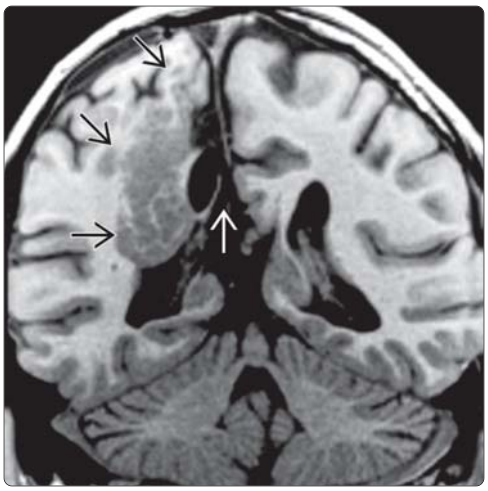

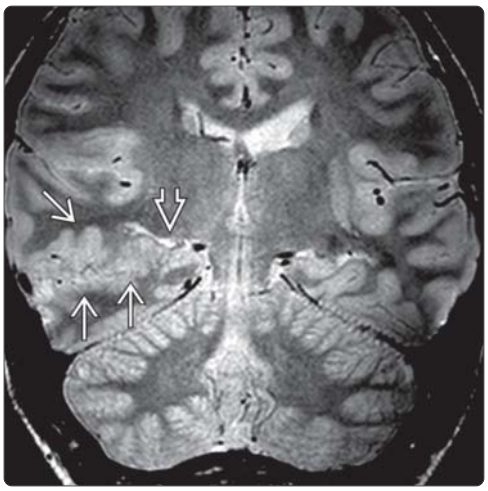

(Left) *Coronal T1WI MR in a 15-year-old boy with epilepsy shows ACC with interhemispheric meningeal cysts and a massive nodular subcortical HTP ⇨, located on the medial aspect of the hemisphere, adjacent to previously drained cysts ➡.* **(Right)** *Coronal T2WI MR shows surface coil in a 14-year-old boy with intractable mesial temporal epilepsy. A large nodular subcortical HTP ➡ extends to where the hippocampus should have been ➡. A normal right hippocampus cannot be identified.*

https://CafePezeshki.IR

KEY FACTS

TERMINOLOGY

- Malformation due to abnormality in late neuronal migration and cortical organization
  - Neurons reach cortex but distribute abnormally, forming multiple small undulating gyri
  - Result is cortex containing multiple small sulci that often appear fused on gross pathology and imaging

IMAGING

- Excessively small and prominent convolutions
- Predilection for perisylvian regions; when bilateral, often syndromic
- Small irregular gyri, but cortex appears normal or thick on MR
- May appear as deep infolding of thick cortex
- MR comprehensively assesses malformation; NECT for suspected Ca++ (TORCH)
- Best sequence: Volume 3D SPGR (T1 weighted) in mature brain; thin-section T2WI if unmyelinated

TOP DIFFERENTIAL DIAGNOSES

- Microcephaly with simplified gyral pattern
- Hemimegalencephaly
- Congenital cytomegalovirus
- Pachygyria
- "Cobblestone" malformations

CLINICAL ISSUES

- Polymicrogyria most commonly → developmental delay, seizure
- Onset and severity of seizures, neurological deficits relate to extent of malformation, presence of associated anomalies

DIAGNOSTIC CHECKLIST

- Remember that polymicrogyria can result from injury, infection, metabolic or destructive causes
- If visual or auditory symptoms, rule out congenital infection

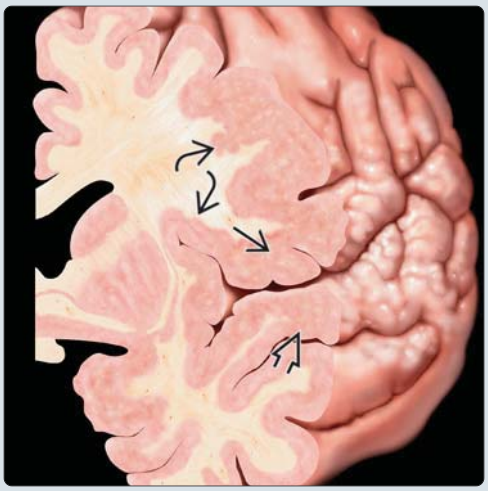

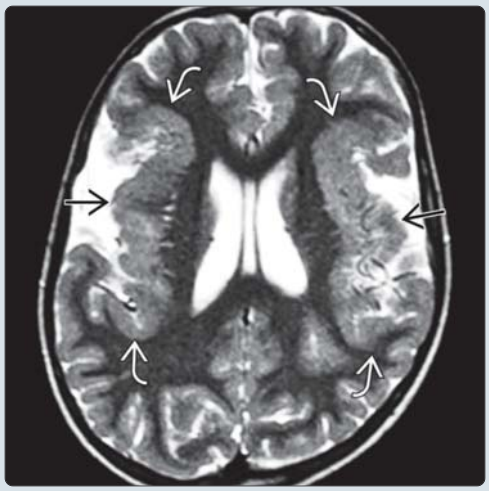

(Left) *Coronal oblique graphic shows the thickened pebbly gyri of polymicrogyria involving the frontal and temporal opercula. Note the abnormal sulcation and the irregular cortical-white matter junction in the affected regions.* **(Right)** *Axial T2WI MR of a patient with bilateral perisylvian polymicrogyria shows a thickened, irregular cortex in the insulae, as well as frontal and parietal opercula. Incidental cavum septi pellucidi is also seen.*

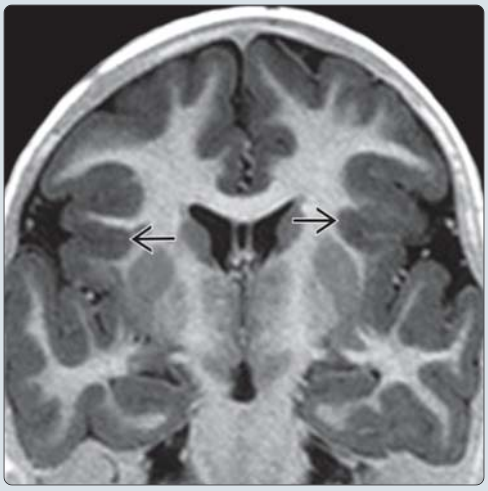

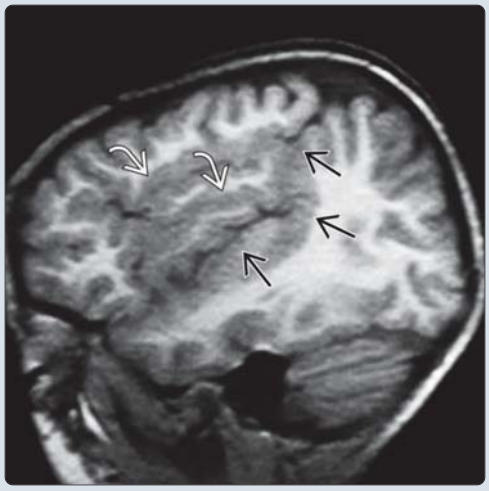

(Left) *Coronal T1WI MR of the same patient shows thickened, deeply undulating insulae and opercula around the abnormal sylvian fissures. PMG is often more poorly characterized in the coronal plane. The microgyri are not as well seen.* **(Right)** *Sagittal T1WI MR shows the characteristic continuation of the perisylvian PMG posteriorly into the superior parietal lobule, which establishes the diagnosis. Other abnormal horizontal sulci with thick, irregular cortex are present.*

https://CafePezeshki.IR

TERMINOLOGY

Abbreviations

- Polymicrogyria (PMG)

Definitions

- PMG: Heterogeneous disorder with "too many/too small" cortical gyri
  - Pathologically, clinically, radiologically, etiologically heterogeneous
- Malformation due to abnormality in both early (impaired proliferation, migration of neuroblasts) and late (disordered postmigrational cortical maturation) neuronal migration and cortical organization
  - Neurons reach cortex, but distribute abnormally, forming multiple small undulating gyri
  - Result is cortex containing multiple small sulci with fusion of molecular layer (layer 1) of cortex
    - May give false impression of several large, thick gyri

IMAGING

General Features

- Best diagnostic clue
  - Excessively small gyri and prominent convolutions
- Location
  - Can be unilateral, bilateral, multifocal
  - Predilection for perisylvian regions
  - When bilateral, often symmetric
- Size
  - Ranges from single gyrus to entire cerebrum
- Morphology
  - Small irregular gyri, but cortex looks normal or thick
  - May appear as deep infolding of thick cortex

CT Findings

- NECT
  - Look for altered sulcation pattern; suggests PMG
  - Excessive small convolutions difficult to detect on CT due to poor contrast resolution
  - Will detect periventricular Ca++ if secondary to cytomegalovirus (CMV)

MR Findings

- T1WI
  - Irregular cortical surface, often seen best on parasagittal images
  - May appear as arc of thick (5-7 mm) cortex with irregular cortex-white matter junction, without normal sulci
  - May appear as deep infolding of irregular, thick cortex
- T2WI
  - Polymicrogyria (2 imaging patterns)
    - < 12 months: Small, fine undulating cortex with normal thickness (3-4 mm)
    - > 18 months: Thick, bumpy cortex (6-8 mm), ± large perivascular spaces, ± cortical infolding
- STIR
  - Less useful due to poor spatial resolution
- FLAIR
  - May be difficult to see microgyri because of poor contrast between cortex and white matter
  - Allows differentiation between dilated perivascular spaces (common in PMG) and abnormal myelination (suggests dystroglycanopathy/"cobblestone" malformation or prenatal infection, such as CMV)
- T2* GRE
  - Hypointense foci of periventricular Ca++ → CMV
- T1WI C+
  - Amplifies dysplastic leptomeningeal veins (when present) overlying regions of polymicrogyria
- MRV
  - Demonstrates large leptomeningeal veins overlying abnormal cortex
- MRS
  - ↓ NAA at seizure-precipitating, atrophic, &/or hypomyelinated sites

Angiographic Findings

- May see large veins in clefts of PMG

Nuclear Medicine Findings

- PET
  - Increased metabolism during ictus
  - Hypometabolic interictally

Other Modality Findings

- Fetal MR and US: Agyric cortex normal up to 26 weeks
  - Premature appearance of sulci suggests early PMG
- Prenatal MR can detect PMG and other anomalies of cortical development as early as 22 weeks

Imaging Recommendations

- Best imaging tool
  - MR comprehensively assesses malformation; NECT for suspected Ca++ (TORCH)
- Protocol advice
  - Volume 3D SPGR (T1 weighted) in mature brain; thin-section T2WI if unmyelinated

DIFFERENTIAL DIAGNOSIS

Malformations Secondary to Inborn Errors of Metabolism

- Mitochondrial and pyruvate metabolism disorders
- Zellweger syndrome: Deficiency of peroxisomes, severe hypomyelination, cortical malformations

Microcephaly With Simplified Gyral Pattern

- Disorder of stem cell proliferation, head circumference < 3 standard deviations (SDs) below mean
- Normal cortical thickness, smooth inner cortical margin, normal primary and secondary sulci

Hemimegalencephaly (HME)

- Disorder of neuronal proliferation, migration, and differentiation
- In HME, affected hemisphere is large; in unilateral PMG, affected hemisphere is small

Congenital Cytomegalovirus

- Association with neuronal migration anomalies including PMG
- If infant with brain malformations, Ca++, ventricular dilatation, cerebellar hypoplasia, evaluate for CMV

https://CafePezeshki.IR

Pachygyria

- Thicker cortex (8-10 mm), smooth gray-white matter junction

"Cobblestone" Malformations

- Associated with hypomyelination, cerebellar dysgenesis, pontine hypoplasia
- Often associated with congenital muscular dystrophy

PATHOLOGY

General Features

- Etiology
  - Causes: Intrauterine infection, ischemia, toxins, or gene mutations
    - Timing: 2nd 1/2 of 2nd trimester
- Genetics
  - Many gene mutations associated with PMG but in none is PMG sole or specific abnormality
  - Mutations of Xq28, Xq21.33-q23 (*SRPX2*),16q12.2-21, 1p36, and 22q11.2, and genetic loci on chromosomes 1p36.3, 2p16.1-p23, 4q21.21-q22.1, 6q26-q27, and 21q21.3-22.1 have been identified
  - Associated with many loci but few genes
    - Most consistent genetic defect associated with PMG: del 22q11.2
    - Bilateral frontoparietal PMG is autosomal recessive, distinct clinicoradiologic profile
- Associated abnormalities
  - Congenital bilateral perisylvian syndrome (Foix-Chavany-Marie)
  - Aicardi, Zellweger, Delleman, DiGeorge, Warburg micro syndromes

Staging, Grading, & Classification

- Polymicrogyria → unlayered or 4-layered cytoarchitecture

Gross Pathologic & Surgical Features

- Multiple small gyri that lie in haphazard orientation
- Fusion of molecular layer (cortical layer 1)
- Multiple appearances and locations
  - Unilateral: Focal, perisylvian, or hemispheric
  - Bilateral symmetrical: Perisylvian, frontal, frontoparietal, lateral parietal, medial parasagittal parietooccipital
  - Bilateral asymmetrical

Microscopic Features

- Range of histology reflecting derangement of 6-layered lamination of cortex
  - Cortical layers 4 and 5 most involved
  - Leptomeningeal embryonic vasculature overlies malformation
  - Myelination within subcortical or intracortical fibers changes cortical appearance on T2-weighted images
  - Areas of 6-layered, 4-layered, and 2-layered cortex may be found

CLINICAL ISSUES

Presentation

- Most common signs/symptoms
  - Polymicrogyria most commonly → developmental delay, seizure
    - Bilateral perisylvian PMG may cause faciopharyngoglossomasticatory diplegia
    - Unilateral PMG often → hemiparesis/seizures
  - When PMG is 2° to CMV infection, presentation may be congenital deafness
- Clinical profile
  - Onset and severity of seizures, neurological deficits relates to location and extent of malformation

Demographics

- Age
  - Varies with extent/location of malformation
- Gender
  - No gender preference
- Ethnicity
  - Found in all populations
- Epidemiology
  - Malformations of cortical development found in ~ 40% of children with intractable epilepsy

Natural History & Prognosis

- Variable based on severity of genetic mutation, resultant malformation, associated anomalies
- Many patients are self-sufficient, integrated into society

Treatment

- Options, risks, complications
  - Focal PMG may be resected in refractory epilepsy
  - Corpus callosotomy if bilateral or diffuse unresectable lesions

DIAGNOSTIC CHECKLIST

Consider

- Polymicrogyria always seen with schizencephaly
- Look for PMG in congenital hemiplegia with epilepsy
- When associated with macrocephaly, think of macrocephaly, PMG, polydactyly, hydrocephalus (MPPH)

Image Interpretation Pearls

- Sylvian region most common location for PMG
- Open sylvian fissures with thick cortex → polymicrogyria

SELECTED REFERENCES

1. De Ciantis A et al: Ultra-high-field MR imaging in polymicrogyria and epilepsy. AJNR Am J Neuroradiol. 36(2):309-16, 2015
2. Desai NA et al: GPR56-Related Polymicrogyria: Clinicoradiologic Profile of 4 Patients. J Child Neurol. ePub, 2015
3. Smithers-Sheedy H et al: Neuroimaging findings in a series of children with cerebral palsy and congenital cytomegalovirus infection. Infect Disord Drug Targets. ePub, 2015
4. Squier W et al: Polymicrogyria: pathology, fetal origins and mechanisms. Acta Neuropathol Commun. 2:80, 2014
5. Barkovich AJ et al: A developmental and genetic classification for malformations of cortical development: update 2012. Brain. 135(Pt 5):1348-69, 2012
6. Judkins AR et al: Polymicrogyria includes fusion of the molecular layer and decreased neuronal populations but normal cortical laminar organization. J Neuropathol Exp Neurol. 70(6):438-43, 2011
7. Barkovich AJ: Current concepts of polymicrogyria. Neuroradiology. 52(6):479-87, 2010
8. Leventer RJ et al: Clinical and imaging heterogeneity of polymicrogyria: a study of 328 patients. Brain. 133(Pt 5):1415-27, 2010

https://CafePezeshki.IR

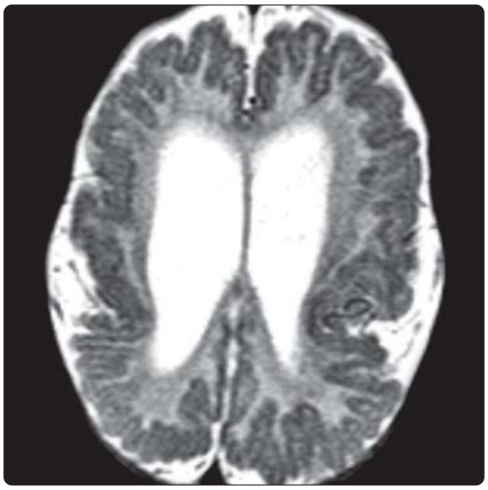

(Left) *Axial T1WI MR shows a large infolding of thickened cortex ⇨ with irregularity of the cortical-white matter junction in the posterior right frontal lobe. This is a characteristic appearance of focal polymicrogyria (PMG).* **(Right)** *Axial T2WI FSE MR shows diffuse PMG. Distinct microgyri can be seen in the individual gyri, but this particular case is also characterized by abnormally thin gyri separated by abnormally deep sulci.*

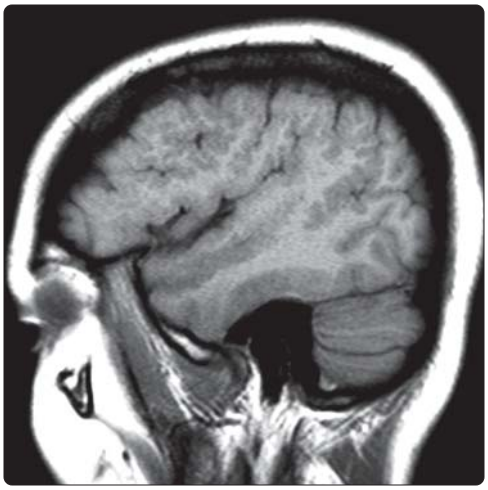

(Left) *Axial proton density MR in an asymptomatic adult shows multiple, small delicate gyri ⇨ in the posterior left frontal and parietal lobes. Compare with the coarse appearance of the prior image. PMG can have a spectrum of appearances on MR.* **(Right)** *Sagittal T1WI MR in the same patient shows the extent of the PMG involving most of the frontal and parietal lobes, as well as the superior temporal lobe. Most hemispheric PMG is centered in the sylvian fissure region.*

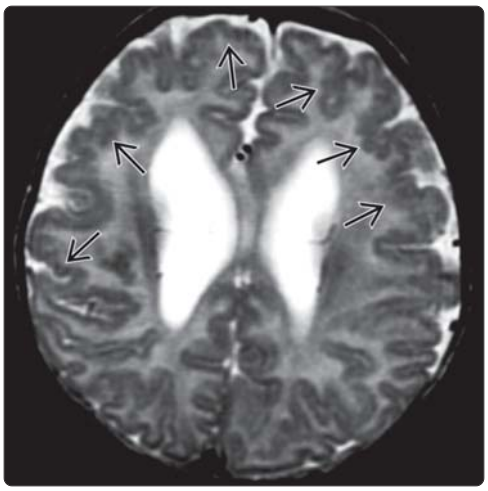

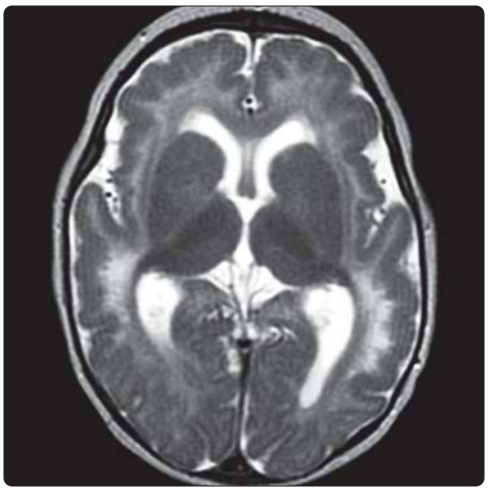

(Left) *Axial T2WI MR of a patient with bilateral frontal PMG shows multiple tiny irregularities ⇨ at the junction of the cortex and white matter throughout the frontal lobes. Volume of frontal white matter is diminished, and the frontal horns are large.* **(Right)** *Axial T2WI MR shows a patient with congenital CMV infection. PMG is present throughout much of the lateral frontal and temporal lobes with abnormally hyperintense underlying white matter.*

https://CafePezeshki.IR

KEY FACTS

TERMINOLOGY

- Disorders of cortical formation caused by arrested neuronal migration, resulting in thick 4-layer cortex and smooth brain surface

IMAGING

- Hourglass or figure 8 shape of cerebral hemispheres
- Truncated arborization of white matter
- 3 layers may be distinguished on T2WI in neonate
  - Outer cellular layer → may be relatively thin, smooth
  - Intervening cell-sparse layer
  - Deeper, thick layer of arrested neurons mimicking band heterotopia
- Posterior > anterior brain involvement in *LIS1*

TOP DIFFERENTIAL DIAGNOSES

- Band heterotopia (BH)
  - Significant overlap (considered mildest end of lissencephaly spectrum)
  - Overwhelmingly female, associated with *DCX* gene mutations
  - Outer cortical layer in BH has relatively normal sulcation and thickness
- Microcephaly with simplified gyral pattern
- "Cobblestone" lissencephalies (type 2 lissencephaly)
  - Congenital muscular dystrophies
- Immature brain

PATHOLOGY

- Caused by variety of gene alterations, resulting in spectrum of phenotypes
- *LIS1* gene → 17p13.3
  - Miller-Dieker syndrome
- *DCX* gene → Xq22.3-q23
- *RELN* gene → 7q22
  - Norman-Roberts syndrome
- *ARX* gene → Xp21.1
- *TUBA1A* gene → 12q12-q14.3

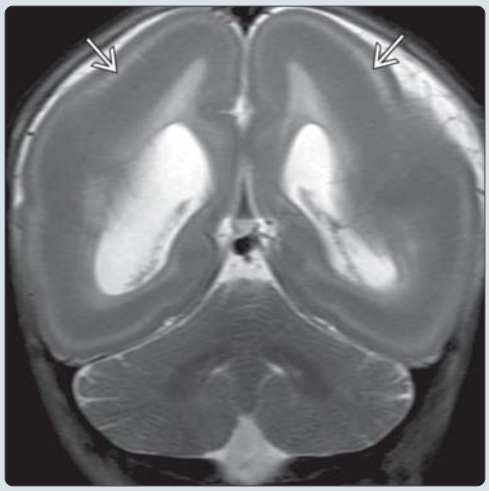

(Left) *Axial NECT scan in a child with type 1 lissencephaly shows shallow sylvian fissures ⇨ with thick, smooth cortex ⇨ showing virtually complete absence of sulci. Note the relative paucity of white matter.* **(Right)** *Coronal T2WI MR in another case of lissencephaly shows complete absence of cerebral sulcation, but the cerebellum is unaffected. A hyperintense cell-sparse zone ⇨ separates the thin cortical ribbon from the thicker band of disorganized neurons, which is in turn separated from the ventricles by white matter.*

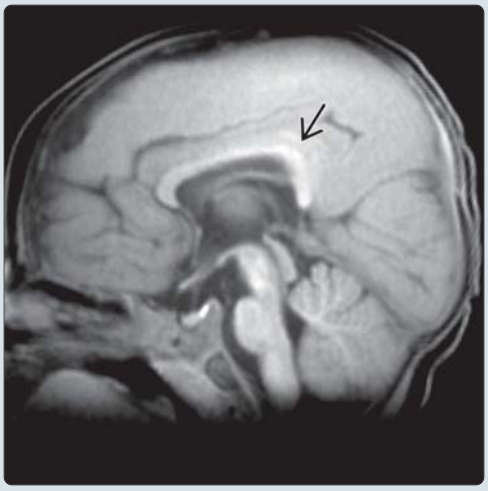

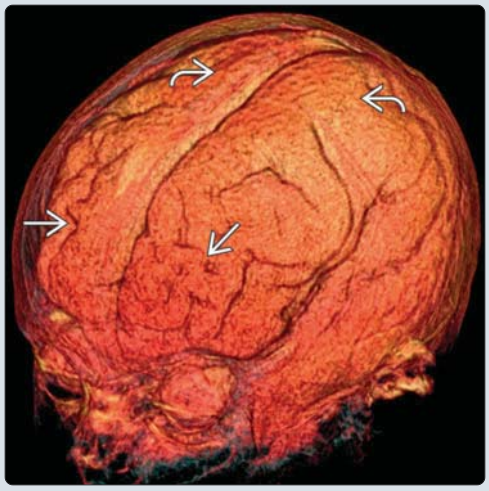

(Left) *Midline sagittal T1WI MR clearly shows relatively normal sulcation at frontal and occipital poles, with fewer sulci in between. Note the characteristic 90° angle ⇨ between the callosal body and splenium.* **(Right)** *Anterosuperior perspective of a volume-rendered surface-shaded reconstruction in the same infant shows the relative preservation of sulcation anteriorly ⇨ with many fewer cortical sulci over the vertex further posteriorly ⇨.*

https://CafePezeshki.IR

TERMINOLOGY

Abbreviations

- Lissencephaly (LIS)

Synonyms

- Classical LIS, type 1 LIS, pachygyria-agyria complex, X-linked LIS

Definitions

- Disorders of cortical formation caused by arrested neuronal migration, resulting in thick 4-layer cortex and smooth brain surface
- Significant overlap with band heterotopia (BH)
  - BH → overwhelmingly female, associated with *DCX* gene mutations
    - Considered mildest end of lissencephaly spectrum
  - Outer cortical layer in BH has relatively normal sulcation and thickness

IMAGING

General Features

- Best diagnostic clue
  - Absence or diminished number of cortical sulci throughout cerebral hemispheres with thick cortex
  - Hourglass or figure 8 shape of cerebral hemispheres
- Location
  - Cerebral hemispheres
- Size
  - Normocephalic to microcephalic

CT Findings

- NECT
  - Thick band of disorganized neurons often appears better defined than gray matter in normal infants
  - May see small midline calcifications in Miller-Dieker syndrome
  - May see periventricular calcifications in CMV-associated lissencephaly
- CECT
  - Large vessels in sylvian fissures

MR Findings

- T1WI
  - Small number of shallow sulci with broad intervening gyri
    - Smooth cortical surface
  - Mildly to moderately enlarged ventricles
  - Truncated arborization of white matter
  - Thick deep band of gray matter may resemble myelinated white matter
  - Small cerebellum and corpus callosum, absence of anterior limb of internal capsule in LIS associated with tubulin mutations
- T2WI
  - Best sequence for distinction of cortical layers in neonate
    - 3 layers may be distinguished
      - Outer cellular layer may be relatively thin, smooth
      - Intervening cell-sparse layer
      - Deeper thick layer of arrested neurons mimicking band heterotopia
  - Prominent vessels in shallow sylvian fissures
- T2* GRE
  - Midline calcification in Miller-Dieker
  - Periventricular and subcortical white matter calcifications in CMV-related lissencephaly
- MRS
  - ↓ N-acetylaspartate (NAA) in affected cortex

Ultrasonographic Findings

- Grayscale ultrasound
  - Late intrauterine documentation possible

Nuclear Medicine Findings

- PET
  - Inner cellular layer has higher glucose utilization than outer layer (fetal pattern)

Imaging Recommendations

- Best imaging tool
  - MR
- Protocol advice
  - Utilize T2WI for best distinction of cortical layers in neonate
  - Multiplanar reconstructed volume T1WI ideal in child with completed myelination
  - Surface-shaded volume rendering may provide unique perspective on undersulcation for clinicians

DIFFERENTIAL DIAGNOSIS

Band Heterotopia

- Double cortex
  - Band of smooth gray matter separated from cortex by layer of normal-appearing white matter (WM)
    - Overlying cortex has shallow sulci
- Complete or partial
- Overwhelmingly female

Microcephaly With Simplified Gyral Pattern

- Head circumference ≤ 3 standard deviations below normal
- Too few gyri and abnormally shallow sulci
- No tertiary sulci

"Cobblestone" Lissencephalies (Formerly Type 2 Lissencephaly, LIS2)

- Congenital muscular dystrophies
  - Fukuyama congenital muscular dystrophy, Walker-Warburg syndrome, muscle-eye-brain disease
- "Pebbly" surface of brain, cerebellar and ocular abnormalities, congenital muscular dystrophy

Immature Brain

- Sulci do not fully develop until ~ 40 weeks gestation

PATHOLOGY

General Features

- Etiology
  - Genetic or acquired
    - Mutations of genes encoding for proteins required for normal neuronal migration
    - CMV-infected cells can fail to migrate or arrest
- Genetics

https://CafePezeshki.IR

- Caused by variety of gene alterations, resulting in spectrum of phenotypes
  - *LIS1* gene → 17p13.3
    - Regulates microtubule motor protein cytoplasmic dynein
    - Defects lead to parietooccipital agyria, classical lissencephaly
  - *DCX* gene → Xq22.3-q23
    - Encodes for doublecortin (microtubule-binding) and stabilizing protein
    - Mutation in males leads to frontal agyria
    - Mutation in females leads to band heterotopia
  - *RELN* gene → 7q22
    - Encodes for reelin, extracellular matrix protein that regulates neuronal migration and synaptic plasticity
    - Mutations lead to Norman-Roberts syndrome → small cerebellum, hypoplastic brainstem, mild decrease of cortical sulci gyri
  - *ARX* gene → Xp21.1
    - Homeobox-containing gene
    - Mutations lead to frontal pachygyria, parietooccipital agyria, agenesis of corpus callosum, and ambiguous genitalia
  - *TUBA1A* gene → 12q12-q14.3
    - Encodes for microtubule constituent proteins
    - Mutations lead to perisylvian pachygyria, posterior pachygyria, dysgenetic internal capsule, cerebellar hypoplasia
- Associated abnormalities
  - Miller-Dieker syndrome
    - Cardiac, GI, and renal anomalies
    - Characteristic facial features → prominent forehead, upturned nares, thickened upper lip, hypertelorism, low ears, small jaw
  - Norman-Roberts syndrome
    - Low sloping forehead, prominent nasal bridge

Microscopic Features

- 4-layer cortex (*LIS1* and *DCX*)
  - Superficial molecular or marginal layer
  - Thin outer cortical layer of neurons (large, abnormal position)
  - "Cell-sparse" WM zone
  - Thick deep cortical layer of neurons (lack orderly arrangement)
- Hypoplastic corticospinal tracts

CLINICAL ISSUES

Presentation

- Most common signs/symptoms
  - Developmental delay and seizures
- Clinical profile
  - Global developmental delay and seizures
    - Severe and diffuse involvement → diagnosis in infancy
    - Limited involvement, diagnosed in later childhood
  - Females with BH may be minimally symptomatic, mild seizures only
  - Microcephaly in *ARX*, *RELN*, and *TUBA1A* associated with LIS

Demographics

- Age
  - Usually diagnosed early in life
  - Mild/partial cases may have delayed presentation
  - BH may be asymptomatic
- Gender
  - *DCX* gene mutations
    - Mothers → band heterotopia
      - BH > 90% female
    - Sons → lissencephaly
- Epidemiology
  - 1-4:100,000 live births

Natural History & Prognosis

- Significant mental retardation, motor deficits, seizures, early demise
- Exception, with focal subcortical BH, patients often lead normal life

Treatment

- Supportive

DIAGNOSTIC CHECKLIST

Consider

- Patterns of gyral abnormalities may provide insight into genetic defect

Image Interpretation Pearls

- When suspecting lissencephaly in neonate, verify gestational age
  - Especially important in assessing fetal MR or US
    - Agyric (smooth) cortex is normal up to 26 weeks
  - Look for specific signs on fetal studies
    - Presence or absence of parietooccipital fissure; poor development of sylvian fissure

Reporting Tips

- Be very hesitant to use term "band heterotopia" in males
- Describe regions of involvement to help in clinical management, classification
- "Pachygyria" is useful as descriptive term, not as diagnostic label
- Associated findings (corpus callosum, cerebellum, internal capsule) aid in finding genetic syndrome

SELECTED REFERENCES

1. Fry AE et al: The genetics of lissencephaly. Am J Med Genet C Semin Med Genet. 166C(2):198-210, 2014
2. Bahi-Buisson N et al: New insights into genotype-phenotype correlations for the doublecortin-related lissencephaly spectrum. Brain. 136(Pt 1):223-44, 2013
3. Poirier K et al: Mutations in TUBG1, DYNC1H1, KIF5C and KIF2A cause malformations of cortical development and microcephaly. Nat Genet. 2013 Jun;45(6):639-47. Epub 2013 Apr 21. Erratum in: Nat Genet. 45(8):962, 2013

https://CafePezeshki.IR

(Left) *Sagittal T1WI MR shows a smooth and featureless cortex in the supratentorial brain with a normal cerebellum and brainstem in this infant with the Miller-Dieker syndrome caused by larger deletions of the LIS1 gene.* **(Right)** *Axial NECT in another child with classic lissencephaly shows the lack of arborization of the otherwise clearly delineated white matter. Note the subtle low attenuation of the cell-sparse zone ➔ in the right occipital pole.*

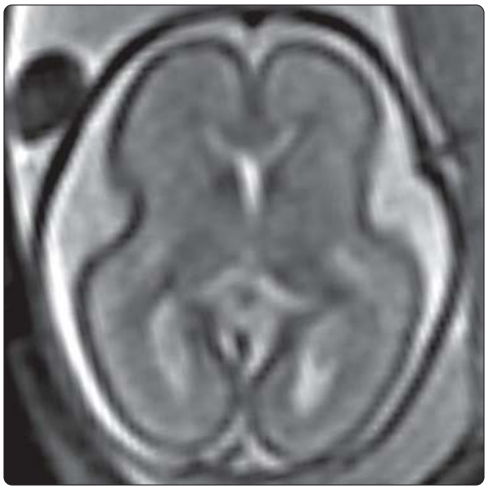

(Left) *Axial T2WI from a fetal MR exam at 22 weeks gestation shows an hourglass configuration of the cerebrum reminiscent of type 1 lissencephaly. However, this is normal at 22 weeks gestational age.* **(Right)** *Axial T1WI MR in another neonate with lissencephaly shows narrower but equally shallow sylvian fissures compared to the fetal MR. The slightly hyperintense signal deep to the cortex ➔ represents the deep zone of disorganized neurons.*

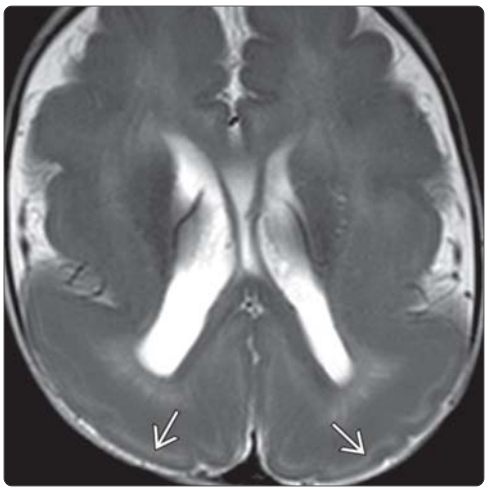

(Left) *Sagittal T2WI MR clearly shows the frontal predominance of pachygyria in this child with lissencephaly. The frontal pattern is characteristically seen in cases caused by mutations of the DCX gene.* **(Right)** *Axial T2WI MR in another child shows parietooccipital predominance of pachygyria, a pattern seen with TUBA1A and LIS1 gene mutations. Bright signal can be seen in the cell-sparse zone ➔ between the thick subcortical band of disorganized neurons and thin superficial cortex.*

https://CafePezeshki.IR

KEY FACTS

IMAGING

- Transmantle gray matter (GM) lining clefts
  - Look for dimple in wall of ventricle if cleft is narrow/closed
- Up to 1/2 of schizencephalies are bilateral
  - When bilateral, 60% are open-lipped on both sides
- Gray matter lining clefts may appear hyperdense
- Ca++ when associated with CMV or *COL4A1* mutations
- Prior to myelination T2WI more clearly defines lesion

TOP DIFFERENTIAL DIAGNOSES

- Encephaloclastic porencephaly
  - Lined by gliotic white matter (WM), not dysplastic GM
- Hydranencephaly
  - Residual tissue is supplied by posterior circulation
- Semilobar holoprosencephaly
  - Can mimic bilateral open-lip schizencephaly

PATHOLOGY

- Can be result of acquired in utero insult affecting neuronal migration
- 1/3 of children with schizencephaly have non-CNS abnormalities
- Infection (CMV), vascular insult, maternal trauma, toxin

CLINICAL ISSUES

- Unilateral: Seizures or mild motor deficit
- Bilateral: Developmental delay, paresis, microcephaly, spasticity
- Seizure more common with unilateral clefts
- Size of clefts and presence of associated malformative lesions govern severity of impairment

(Left) *Coronal graphic shows right closed-lip ⇨ and left open-lip ⇨ schizencephaly, both lined by gray matter. Note absence of septum pellucidum ⇨.* **(Right)** *Coronal T2FS MR shows bilateral schizencephaly. A closed-lip defect is seen on the right ⇨, extending from the pial surface to the ventricular outpouching ⇨, while a mildly open lip defect lined with dysplastic gray matter is present on the left ⇨. Note the abnormal vessels in the left-sided schizencephalic cleft ⇨.*

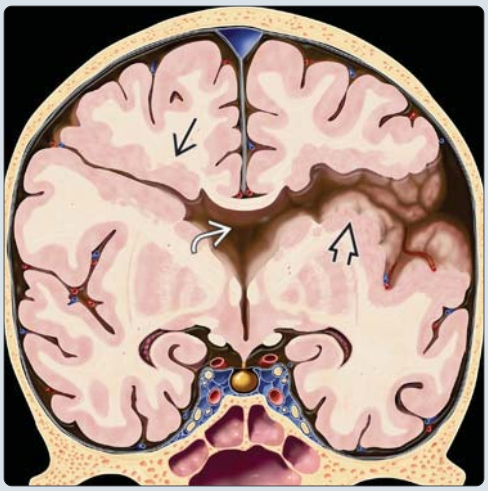

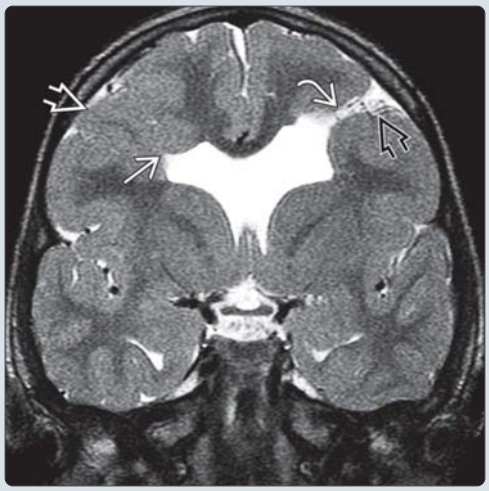

(Left) *Axial NECT in a 19-year-old male in the ER for trauma shows a "nipple" or outpouching of the left lateral ventricle ⇨ that extends into a full-thickness CSF cleft ⇨. The cleft is lined with heterotopic gray matter ⇨. This is a classic unilateral schizencephaly.* **(Right)** *Coronal T2WI shows large bilateral open-lip schizencephalic clefts ⇨.*

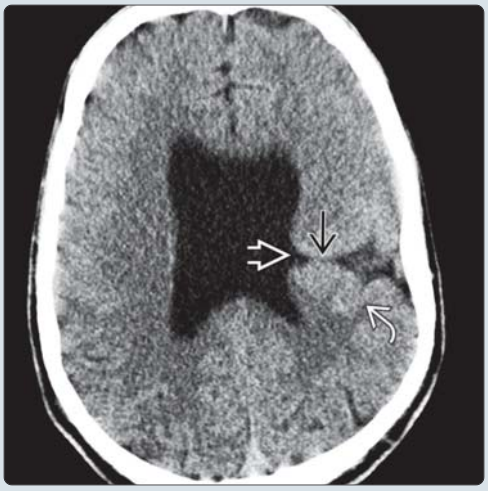

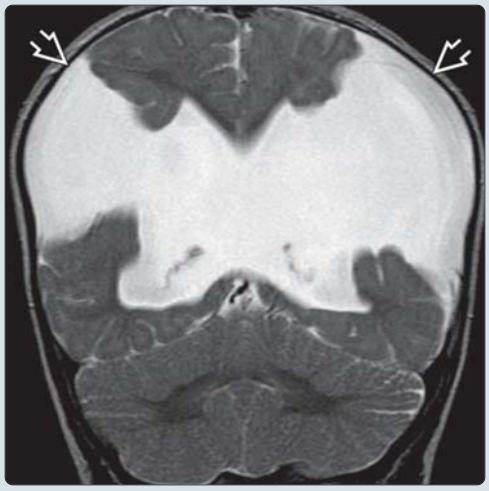

https://CafePezeshki.IR

TERMINOLOGY

Synonyms

- Agenetic porencephaly

Definitions

- Clefts in brain parenchyma that extend from cortical surface to ventricle (pia to ependyma), lined by dysplastic gray matter (GM)

IMAGING

General Features

- Best diagnostic clue
  - Transmantle gray matter lining clefts
    - Look for dimple in wall of ventricle if cleft is narrow/closed
- Location
  - Frontal and parietal lobes near central sulcus
- Size
  - Closed-lip (small defect) or open-lip (large defect)
- Morphology
  - Up to 1/2 of schizencephalies are bilateral
    - When bilateral, 60% are open-lipped on both sides

CT Findings

- NECT
  - Cleft of CSF density (in open-lip schizencephaly)
  - GM lining clefts may appear hyperdense
  - Dimple on lateral wall of lateral ventricle indicating ependymal margin of cleft
  - Ca++ when associated with cytomegalovirus (CMV)
  - Thinning and expansion of calvaria can be seen with large open-lipped clefts
- CECT
  - Large, primitive-appearing veins near cleft

MR Findings

- T1WI
  - Distinction of GM lining cleft can be difficult prior to myelination
  - Closed-lip → irregular tract of GM extending from cortical surface to ventricle
    - Lining GM can appear dysplastic → lumpy/bumpy on margin of cleft or at gray-white interface
  - Open lip → can be wide and wedge-shaped or with nearly parallel walls
    - GM lining cleft may be harder to discern than in closed-lip
- T2WI
  - Infolding of gray matter along transmantle clefts
    - Prior to myelination T2WI more clearly defines lesion
- FLAIR
  - Gliotic foci present in later insults
- T2* GRE
  - May show Ca++ when associated with CMV
- MRV
  - Developmental venous anomalies (DVAs) overlying cleft
- 3D surface rendered MR
  - Clearly shows relationship of adjacent gyri/sulci to cleft in cerebral mantle
- fMR: Functional reorganization of undamaged hemisphere reported

Ultrasonographic Findings

- Grayscale ultrasound
  - Diagnosable by fetal ultrasound and fetal MR; progressive changes have been reported

Nuclear Medicine Findings

- PET
  - Normal or ↑ glucose metabolism and perfusion of wall of cleft (normal gray matter activity)

Imaging Recommendations

- Best imaging tool
  - MR
- Protocol advice
  - < 9 months → rely on T2WI
  - > 9 months → rely on T1WI
  - Volumetric acquisitions that allow multiplanar reformatting and surface rendering

DIFFERENTIAL DIAGNOSIS

Encephaloclastic Porencephaly

- Cleft in brain due to insult after migration complete
- Lined by gliotic white matter (WM), not dysplastic GM

Hydranencephaly

- Destruction of tissue in middle and anterior cerebral artery territory
  - Residual tissue is supplied by posterior circulation → posterior fossa, occipital poles, medial temporal lobes
- Severe schizencephaly with hydrocephalus can strongly mimic; may be a continuum

Semilobar Holoprosencephaly

- Can mimic bilateral open-lip schizencephaly

PATHOLOGY

General Features

- Etiology
  - Can be result of acquired in utero insult affecting germinal zone prior to neuronal migration
    - Infection (CMV), vascular insult, maternal trauma, toxin
    - Reported with alloimmune thrombocytopenia
    - Experimental schizencephaly induced by mumps virus
- Genetics
  - Mutations of *COL4A1*, *COL4A2* have been associated with schizencephaly
    - Expressed in the basement membrane of blood vessels in many organs
    - Mutations are associated with small vessel disease affecting multiple organs
    - Weakness in vessel walls 2° to mutation may result in prenatal, perinatal, or postnatal hemorrhages
- Associated abnormalities
  - Septooptic dysplasia (SOD), de Morsier syndrome
    - Heterogeneous disorder characterized by hypoplasia of optic nerves and absent septum pellucidum
      - 45% have pituitary insufficiency

https://CafePezeshki.IR

- Schizencephaly seen in up to 35%, usually bilateral
- Septum pellucidum is absent in large percentage of schizencephaly cases, especially bilateral schizencephaly
- Frontal lobe dysplasia
- Hippocampal and callosal anomalies
- Contralateral polymicrogyria is common
- Periventricular heterotopia often seen adjacent to cleft

Staging, Grading, & Classification

- Type 1 (closed-lip)
  - 15-20%
- Type 2 (open-lip)
  - 80-85%

Gross Pathologic & Surgical Features

- Transmantle clefts with separated or apposed gray matter lining
- Thalami, corticospinal tracts may be atrophied or not formed

Microscopic Features

- Little if any glial scarring
- Loss of normal laminar architecture
- Pachygyria, polymicrogyria, or heterotopic gray matter

CLINICAL ISSUES

Presentation

- Most common signs/symptoms
  - Unilateral: Seizures or mild motor deficit ("congenital" hemiparesis)
  - Bilateral: Developmental delay, paresis, microcephaly, spasticity
    - Seizure more common with unilateral clefts
    - Faciopharyngoglossomasticatory diplegia
      - Automatic motility preserved, voluntary impaired
- Other signs/symptoms
  - Psychiatric disorders
  - Perisylvian syndrome
    - Pseudobulbar palsy

Demographics

- Epidemiology
  - 1.54/100,000; common with young parents, absent prenatal care
  - 1/3 of children with schizencephaly have non-CNS abnormalities
    - > 50% likely due to vascular disruption
      - Gastroschisis, bowel atresias, and amniotic band disruption sequence

Natural History & Prognosis

- Malformation is stable; development of epilepsy common
- Size of clefts and presence of associated malformative lesions govern severity of impairment

Treatment

- Treat seizures and hydrocephalus
  - Lesionectomy, hemispherectomy

DIAGNOSTIC CHECKLIST

Consider

- Image to confirm etiology of congenital hemiparesis or epilepsy
  - Perinatal stroke vs. unilateral schizencephaly

Image Interpretation Pearls

- Multiplanar imaging to avoid in-plane oversight of closed-lip clefts
  - If plane of imaging is same as plane of cleft, abnormality may be overlooked
- Contours of lateral walls of lateral ventricles should be smooth
  - Dimples may indicate subtle closed-lip schizencephaly
- Absence of septum pellucidum should prompt thorough investigation for schizencephaly &/or polymicrogyria
- Consider large bilateral open-lip schizencephaly when diagnosis is semilobar holoprosencephaly or hydranencephaly
- Clefts may by asymmetrical in size
  - Always look closely for small contralateral cleft

SELECTED REFERENCES

1. Halabuda A et al: Schizencephaly-diagnostics and clinical dilemmas. Childs Nerv Syst. 31(4):551-6, 2015
2. Nabavizadeh SA et al: Correlation of prenatal and postnatal MRI findings in schizencephaly. AJNR Am J Neuroradiol. Epub ahead of print, 2014
3. Choi HY et al: Long-term outcome of surgical treatment of patients with intractable epilepsy associated with schizencephaly. Acta Neurochir (Wien). 155(9):1717-24, 2013
4. Cui Z et al: Resection or multi-lobe disconnection for intractable epilepsy with open-lip schizencephaly. J Clin Neurosci. 20(12):1780-2, 2013
5. Dies KA et al: Schizencephaly: association with young maternal age, alcohol use, and lack of prenatal care. J Child Neurol. 28(2):198-203, 2013
6. da Rocha FF et al: Borderline personality features possibly related to cingulate and orbitofrontal cortices dysfunction due to schizencephaly. Clin Neurol Neurosurg. 110(4):396-9, 2008
7. Heuer GG et al: Anatomic hemispherectomy for intractable epilepsy in a patient with unilateral schizencephaly. J Neurosurg Pediatr. 2(2):146-9, 2008
8. Merello E et al: No major role for the EMX2 gene in schizencephaly. Am J Med Genet A. 146A(9):1142-50, 2008
9. Vinayan KP et al: A case of congenital bilateral perisylvian syndrome due to bilateral schizencephaly. Epileptic Disord. 9(2):190-3, 2007
10. Witters I et al: Prenatal diagnosis of schizencephaly after inhalation of organic solvents. Ultrasound Obstet Gynecol. 29(3):356-7, 2007
11. Huang WM et al: Schizencephaly in a dysgenetic fetal brain: prenatal sonographic, magnetic resonance imaging, and postmortem correlation. J Ultrasound Med. 25(4):551-4, 2006
12. Curry CJ et al: Schizencephaly: heterogeneous etiologies in a population of 4 million California births. Am J Med Genet A. 137(2):181-9, 2005
13. Cecchi C: Emx2: a gene responsible for cortical development, regionalization and area specification. Gene. 291(1-2):1-9, 2002
14. Dale ST et al: Neonatal alloimmune thrombocytopenia: antenatal and postnatal imaging findings in the pediatric brain. AJNR Am J Neuroradiol. 23(9):1457-65, 2002
15. Vandermeeren Y et al: Functional relevance of abnormal fMRI activation pattern after unilateral schizencephaly. Neuroreport. 13(14):1821-4, 2002
16. Takano T et al: Experimental schizencephaly induced by Kilham strain of mumps virus: pathogenesis of cleft formation. Neuroreport. 10(15):3149-54, 1999

https://CafePezeshki.IR

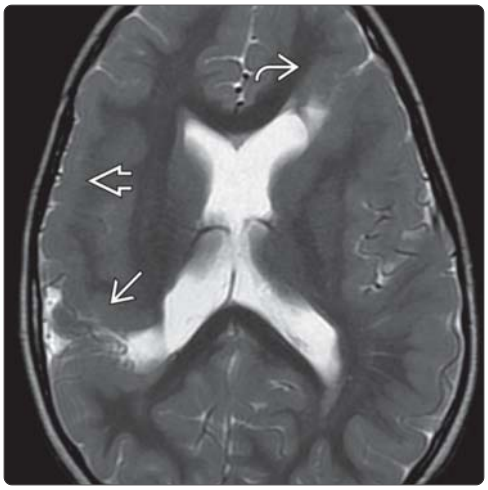

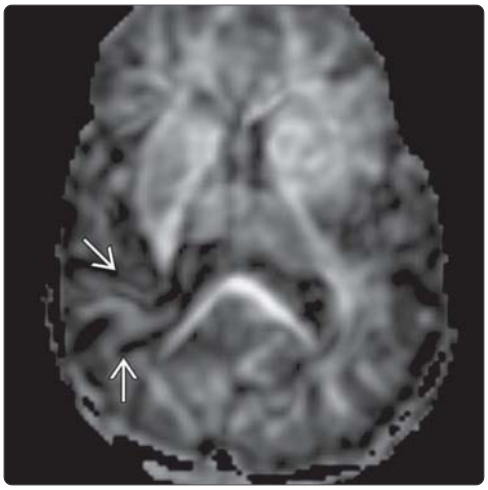

(Left) *Axial T2WI MR in a 2 year old with seizures and developmental delay shows 2 closed-lip schizencephalic clefts, 1 in the right parietal lobe ➡ and 1 in the left frontal lobe ⇨. Note the additional cortical dysplasia ➡ extending anteriorly along the frontal lobe from the right-sided cleft.* **(Right)** *Axial fractional anisotropy map from DTI in the same child shows disruption of white matter (WM) tracts at the site of the right parietal cleft ➡. This image is inferior to the WM distortion on the left.*

(Left) *Axial NECT shows a bat-wing configuration of the lateral ventricles due to bilateral large open-lipped schizencephaly. Note the dystrophic calcification bordering the right lateral ventricle wall ⇨, suggesting a history of intrauterine CMV infection as the source of this child's migrational abnormality.* **(Right)** *Axial T1WI MR in the same child shows the abnormally thick and featureless cortex lining the schizencephalic clefts ➡, as well as absence of the septum pellucidum.*

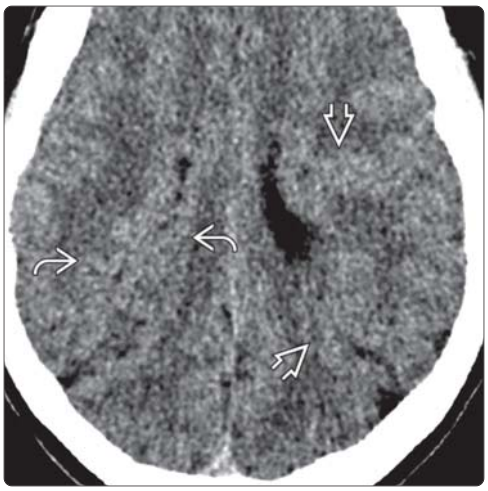

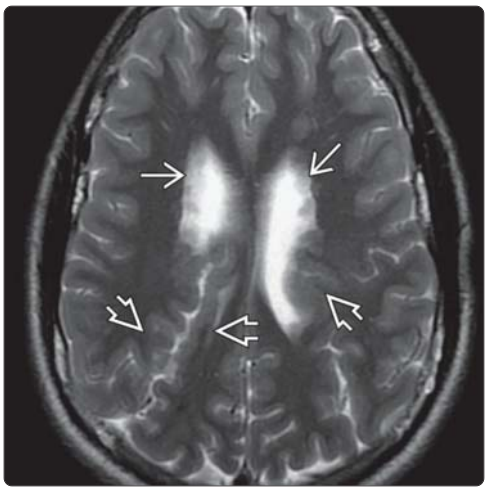

(Left) *Axial NECT in a 9 year old with seizures shows abnormal gray matter extending from the hemispheric surface to the lateral ventricle at the right frontoparietal junction ⇨. Additional regions of abnormal gray matter ➡ can be seen on the left.* **(Right)** *Axial T2WI MR in the same child shows more clearly that the thickened, irregular gray matter lines schizencephalic clefts in each hemisphere ➡. Additional foci of heterotopic gray matter ➡ can be seen in each lateral ventricle.*

https://CafePezeshki.IR

KEY FACTS

TERMINOLOGY

- Hemimegalencephaly (HMEG): Hamartomatous overgrowth of hemisphere
  - Probably misnomer as < 1 whole hemisphere often involved

IMAGING

- Large cerebral hemisphere, hemicranium
  - Posterior falx and occipital pole "swing" to contralateral side
  - Lateral ventricle usually large, misshapen ("pointed" frontal horn)
- Hypertrophied WM often hyperintense on T2/FLAIR (accelerated myelination)

PATHOLOGY

- Etiology: HMEG is prototype infantile tauopathy
  - Upregulation of phosphorylated tau
  - Postzygotic somatic mosaicism (only some cells have mutations; some/many parts of brain spared)
  - Activation of mTOR signaling pathway causes overgrowth of normal/abnormal cells
  - HMEG, focal cortical dysplasia (FCD2b) may be same disorder with different timing of somatic mutation
- Gross pathology
  - Enlarged hemisphere with abnormal, thick gyri
  - GM-WM junction indistinct ("blurred")
- Microscopic features of HMEG identical to FCD2b, TSC
  - Dysmorphic and megalocytic neurons, balloon cells
  - White matter hypertrophy, hypermyelination and gliosis

CLINICAL ISSUES

- Anticonvulsants usually ineffective (mTOR inhibitors may help)
- Anatomic or functional hemispherectomy

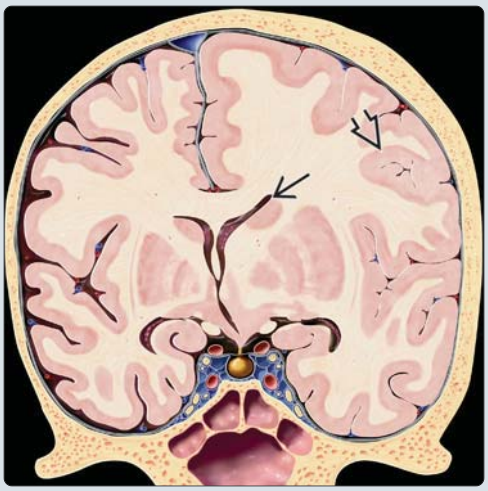

(Left) *Coronal graphic shows overgrowth of the left cerebral hemisphere. Note the shift of midline structures, excess of white matter (WM), thick flattened/dysmorphic gyri, and abnormal ipsilateral anterior horn.* **(Right)** *Axial NECT in a 4-year-old female with intractable seizures shows enlarged right hemisphere, hemicranium, with enlarged white matter in the corona radiata, and ipsilateral corpus callosum, as well as the fornix. The falx is displaced across the midline.*

(Left) *Axial T2WI in the same patient shows the enlarged hemisphere with hyperintense WM, enlarged deformed right ventricle, and thickened dysplastic cortex.* **(Right)** *Coronal T2WI shows the right hemisphere is enlarged, with the falx displaced across the midline. The ipsilateral frontal horn is deformed and pointed. The findings are those of classic HMEG.*

https://CafePezeshki.IR

TERMINOLOGY

Abbreviations

- Hemimegalencephaly (HMEG)

Synonyms

- HMEG probably misnomer as < 1 whole hemisphere often involved (so-called hemi-hemimegalencephaly)
- Dysplastic megalencephaly (generic for all forms of segmental brain overgrowth with cortical dysplasia)

Definitions

- Hamartomatous overgrowth of part/all of hemisphere
- Defect of cellular organization, neuronal migration

IMAGING

General Features

- Best diagnostic clue
  - Mild, moderate, or markedly enlarged dysplastic hemisphere or portion of hemisphere
    - Dysplastic cortex (commonly with diffuse or perisylvian polymicrogyria)
    - Abnormal white matter
  - Displaced posterior falx
  - Large lateral ventricle with abnormally shaped (pointed) frontal horn
- Location
  - Any lobe may be involved (frontal most common)
    - Infrequently involves ipsilateral cerebellum
- Size
  - Usually grossly enlarged, can be subtle
- Morphology
  - Variable, from lissencephaly to polymicrogyria

CT Findings

- NECT
  - Large cerebral hemisphere, hemicranium
  - Posterior falx and occipital pole "swing" to contralateral side
  - Lateral ventricle is large with abnormally shaped frontal horn
  - Dystrophic Ca++ of white matter (WM) or of thickened cortex
- CECT
  - Large vessels common

MR Findings

- T1WI
  - Thickened cortex
  - Frequently increased WM signal
    - "Accelerated myelination" → mineralization; disorganized heterotopic neurons cause T1 shortening
  - Neuronal heterotopias: Subpial, subcortical, or periventricular
  - Lateral ventricle is usually large and frontal horn is pointed
  - Uncommonly cerebellar tonsils herniate (bulky supratentorial brain tissue displaces tonsils)
- T2WI
  - Pachygyria, polymicrogyria
  - Size and signal intensity of affected hemisphere change over time
    - May atrophy and become hypointense with constant seizure activity
  - Margins between gray-white matter often blurred
    - Dysplastic neurons scattered throughout white matter
  - ± cerebellar hemiovergrowth, heterotopias
- FLAIR
  - Gliosis-like bright signal in white matter
- T2* GRE
  - Dystrophic calcifications
- DWI
  - Can show abnormal fiber tracts connecting hemispheres
    - Helpful for assessing residual connections after functional hemispherectomy
- T1WI C+
  - May have bizarre enhancement
  - Enhancement of primitive cortical veins, developmental venous anomalies
- MRS
  - With seizures, progressive ↓ NAA and ↑ creatine, choline, and myoinositol
- Magnetoencephalography (MEG)
  - Somatosensory maps predict severity of cortical lamination defects

Ultrasonographic Findings

- Grayscale ultrasound
  - Diagnosis can be made in fetus and neonate

Nuclear Medicine Findings

- PET
  - Glucose hypometabolism in 50%
- SPECT
  - Increased (during seizure) or decreased tracer uptake in affected side

Imaging Recommendations

- Best imaging tool
  - Multiplanar MR
- Protocol advice
  - Serial imaging may be required to document full extent of abnormality
    - Abnormal regions become more apparent with myelination of normal areas
  - Abnormal signal in WM may be best indicator of extent of abnormality
  - Status of contralateral hemisphere key for clinical decision-making

DIFFERENTIAL DIAGNOSIS

Focal Cortical Dysplasia Type 2

- Small or large areas with blurring of gray-white junction
- Hyperintensity in underlying white matter; often more extensive than seen on MR

Rasmussen Encephalitis

- Unilateral encephalitis with progressive atrophy
- Almost always unilateral

https://CafePezeshki.IR

Tuberous Sclerosis (TSC)

- HME of lobe or hemisphere = occasional manifestation
- Heavy burden of tubers can mimic HME
  - Bilaterally distributed

Gliomatosis Cerebri

- Diffusely infiltrating glioma
- Rare in children
  - Multicentric glioma more common

PATHOLOGY

General Features

- Etiology
  - Abnormal proliferation, migration, and differentiation of neurons
  - Embryology
    - Impaired "stop" sign during proliferation of neurons, glia in germinal matrices
    - Results in proliferation of too many cells of all types
      - Variable patterns of overgrowth reflect somatic mosaicism in presence of mutations
- Genetics
  - HMEG is prototype infantile tauopathy
    - Neuropathologic tetrad
      - Dysmorphic and megalocytic neurons
      - Activation of mTOR signaling pathway (causes overgrowth of normal/abnormal cells)
      - Postzygotic somatic mosaicism (only some cells have mutations; some/many parts of brain spared)
      - Upregulation of phosphorylated tau
  - HMEG and focal cortical dysplasia (FCD2b) may be same disorder with different timing of somatic mutation in mitotic cycles of neuroepithelium
    - Difference is size, extent of resulting cerebral lesions
    - FCD2b is anatomically "transmantle dysplasia," usually isolated
    - HMEG involves entire hemisphere or quadrant or major portion of telencephalon
      - Ipsilateral olfactory bulb, basal ganglia, diencephalic structures, as well as associated meninges, blood vessels, cranial nerves commonly affected
      - Ipsilateral brainstem enlargement, cerebellar enlargement/dysplasia
- Associated abnormalities
  - HMEG can be isolated or associated with neurocutaneous syndromes
    - Most common: Epidermal nevus syndromes (including Proteus)

Gross Pathologic & Surgical Features

- Large hemisphere, shallow sulci, fused and disorganized gyri
- Regional polymicrogyria, pachygyria, and heterotopias

Microscopic Features

- Microscopic features of HMEG are identical to those of TSC, FCD2a

CLINICAL ISSUES

Presentation

- Most common signs/symptoms
  - Seizures, developmental delay
  - Macrocrania
- Other signs/symptoms
  - Hemiparesis, hemihypertrophy
- Clinical profile
  - Most common = neonate/infant with severe epilepsy
  - Severe developmental delay and contralateral hemiparesis common

Demographics

- Age
  - Usually diagnosed during 1st year of life
- Epidemiology
  - ~ 3% of cortical dysplasias that are diagnosed by imaging

Natural History & Prognosis

- Intractable seizures with progressive hemiparesis
- Poor outcome → intractable seizures and developmental delay

Treatment

- Anticonvulsants usually ineffective
- mTOR inhibitor everolimus potential treatment
- Anatomic or functional hemispherectomy
  - Confirm normal contralateral hemisphere first
  - Anatomic hemispherectomy may require shunting of surgical cavity
    - Significant risk of shunt malfunctions

DIAGNOSTIC CHECKLIST

Consider

- Involved hemisphere may atrophy (from chronic seizures)

Image Interpretation Pearls

- Serial imaging shows remarkable signal transformation with myelin maturation
- Hemimegalencephaly is only condition in which increase in parenchymal volume is associated with increase in ipsilateral ventricle volume

Reporting Tips

- Goals of imaging → identify/quantify lesion, identify contralateral abnormalities

SELECTED REFERENCES

1. Re TJ et al: Magnetic Resonance Fiber Tracking in a Neonate with Hemimegalencephaly. J Neuroimaging. ePub, 2015
2. Sarnat HB et al: Timing in Neural Maturation: Arrest, Delay, Precociousness, and Temporal Determination of Malformations. Pediatr Neurol. 52(5):473-486, 2015
3. Santos AC et al: Hemispheric dysplasia and hemimegalencephaly: imaging definitions. Childs Nerv Syst. 30(11):1813-21, 2014
4. Sarnat HB et al: Infantile tauopathies: Hemimegalencephaly; tuberous sclerosis complex; focal cortical dysplasia 2; ganglioglioma. Brain Dev. ePub, 2014
5. Lee JH et al: De novo somatic mutations in components of the PI3K-AKT3-mTOR pathway cause hemimegalencephaly. Nat Genet. 44(8):941-5, 2012

https://CafePezeshki.IR

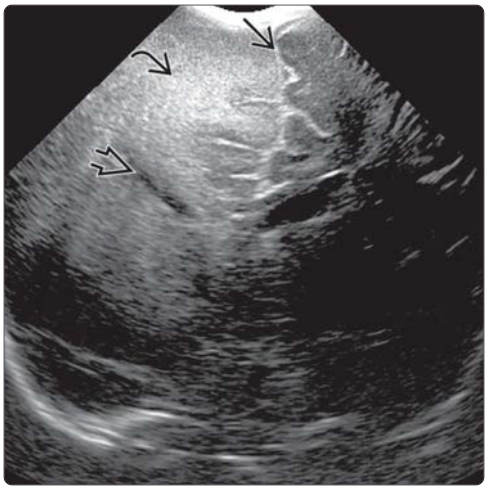

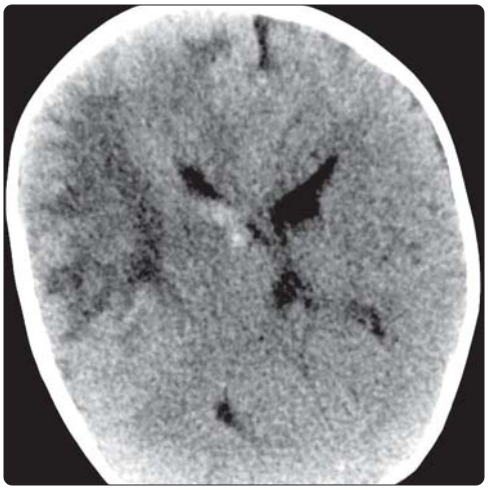

(Left) *Coronal ultrasound in a newborn with seizures shows an enlarged right hemisphere with hyperechoic WM ⇨ and an abnormally pointed right frontal horn ⇨. The interhemispheric fissure ⇨ is displaced across the midline.* **(Right)** *Axial NECT in the same patient shows the grossly enlarged right hemicranium with abnormally hypodense WM in the frontal and anterior parietal lobes.*

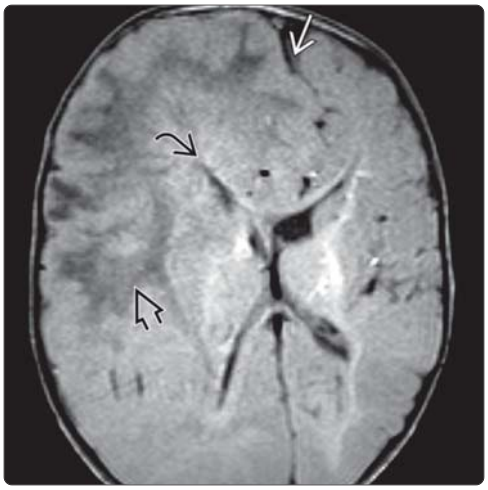

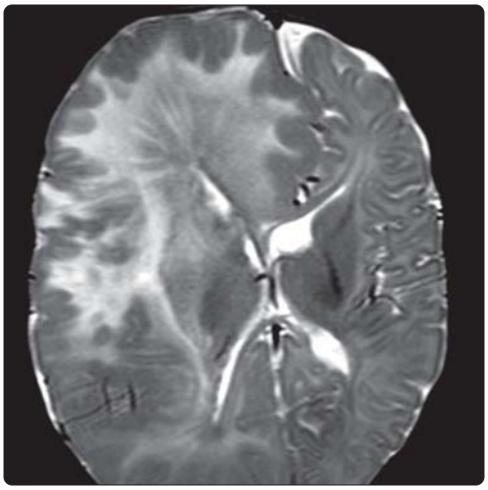

(Left) *Axial T1WI in the same patient shows the enlarged right hemisphere with marked displacement of the falx and interhemispheric fissure to the left ➡. The ipsilateral frontal horn is pointed ⇨ and the WM ⇨ is hypointense.* **(Right)** *T2WI in the same patient shows the WM is expanded and hyperintense compared to the normal left side. The overlying cortex appears dysplastic and the gray-white matter junction is indistinct.*

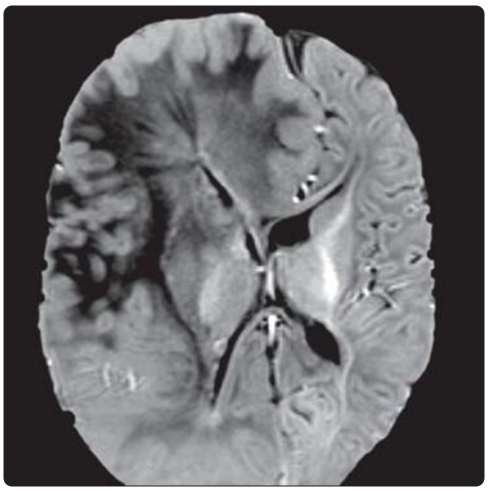

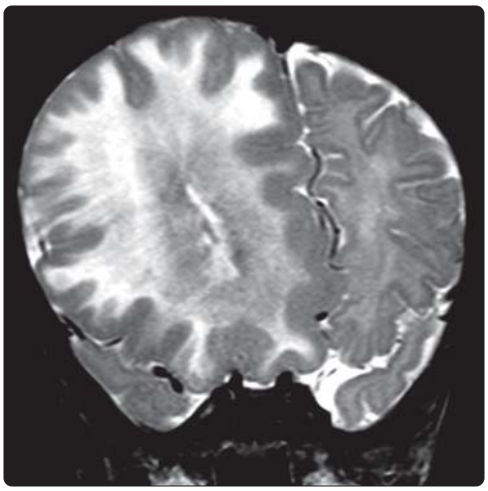

(Left) *Axial inversion recovery (IR) MR shows the cortex of the entire hemisphere is abnormal. The frontal and temporal cortex is polymicrogyric, while the parietal and occipital cortex is thickened and flattened.* **(Right)** *Coronal T2WI in the same patient emphasizes the size difference between the right and left hemispheres in this case of classic hemimegalencephaly. (Courtesy P. Rodriguez, MD.)*

https://CafePezeshki.IR

KEY FACTS

TERMINOLOGY

- Neurofibromatosis type 1 (NF1), von Recklinghausen disease, peripheral neurofibromatosis

IMAGING

- FASI on T2WI in 70-90% of preteen children
  - White matter (WM) lesions are hyperintense and typically poorly defined; no mass effect
  - WM lesions may also involve cerebellar white matter, globus pallidus, thalamus, brainstem
- Neoplasms
  - Plexiform neurofibromas
    - Sphenoid wing and occipital bone dysplasia found in association with plexiform tumors
  - Optic pathway gliomas
  - Parenchymal gliomas
- Vascular dysplasias → stenosis, moyamoya, aneurysm

PATHOLOGY

- Autosomal dominant; gene locus is chromosome 17q12
- Gene product is neurofibromin (negative regulator of RAS protooncogene)
  - Neurofibromin also regulates neuroglial progenitor function
  - Required for normal glial and neuronal development
  - Inactivated in NF-1 → tissue proliferation, tumor development
- FASIs related to (transient) intramyelinic edema

CLINICAL ISSUES

- ~ 50% have macrocephaly; in part 2° to ↑ WM volume
- OPG can cause progressive vision loss
- Café au lait spots are earliest finding
- Most common neurocutaneous and inherited tumor syndrome

(Left) *Axial graphic shows enlarged right middle cranial fossa, dysplastic sphenoid wing, and a large orbital/periorbital plexiform neurofibroma. Note the exophthalmos and buphthalmos of the involved globe.* **(Right)** *3D shaded surface display of a patient with neurofibromatosis type 1 (NF1) shows enlarged right orbit with sphenoid wing hypoplasia, markedly enlarged superior orbital fissure.*

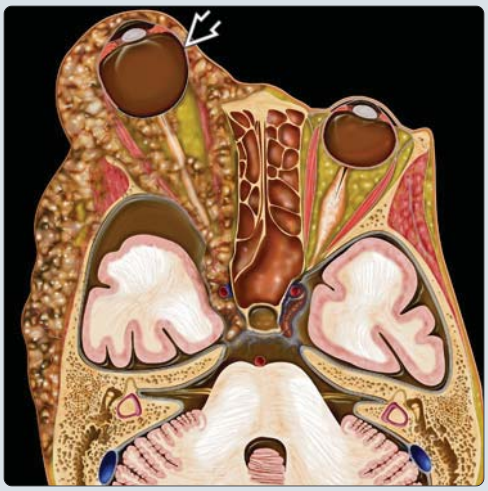

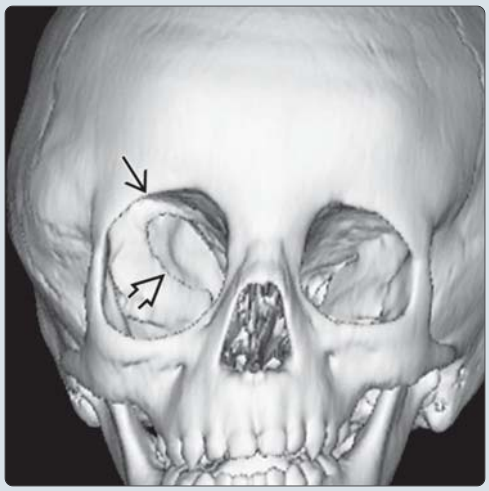

(Left) *Axial T2FS MR in an 18-month-old child shows an extensive plexiform neurofibroma infiltrating the scalp, orbit, and extending into the cavernous sinus through the SOF. Note the bag of worms appearance.* **(Right)** *T1 C+ FS scan in the same patient shows the plexiform neurofibroma enhances strongly, mildly heterogeneously.*

https://CafePezeshki.IR

TERMINOLOGY

Abbreviations

- Neurofibromatosis type 1 (NF1)

Synonyms

- von Recklinghausen disease, peripheral neurofibromatosis

Definitions

- Neurocutaneous disorder (phakomatosis) characterized by
  - Waxing/waning white matter (WM) lesions
    - Sometimes called focal areas of signal intensity (FASI), nonspecific bright foci, unidentified bright objects (UBOs)
  - Optic nerve glioma (ONG)
  - Optic pathway glioma (OPG): Chiasm/tract ± nerve
  - Other gliomas: Brainstem, cerebral hemisphere, basal ganglia
  - Neurofibromas/plexiform neurofibromas (PNF)
  - Vascular dysplasias
  - Hyperpigmented macules (café au lait spots)
  - Dysplastic skeletal lesions

IMAGING

General Features

- Best diagnostic clue
  - FASIs on T2WI in 70-90% of preteen children
  - Plexiform neurofibromas
  - Optic pathway gliomas
- Location
  - WM lesions may also involve cerebellar white matter, globus pallidus, thalamus, brainstem
  - Plexiform lesions often apparent on brain imaging
    - Scalp lesions over occiput
    - Skull base lesions extending into retropharynx
    - Orbital lesions extending from cavernous sinus through orbit into periorbital soft tissues
  - OPG in 15% → intraorbital optic nerves (ON), chiasm/hypothalamus, optic tracts; rarely into radiations
- Size
  - WM lesions: 2-20 mm
  - Chiasmatic glioma: 3-50 mm
  - Brainstem can show moderate to marked enlargement ("hamartoma")
    - Probably result of vacuolation
    - Less T1 hypointense and T2 hyperintense than brainstem glioma
    - Resolves in teen years/young adulthood
  - Plexiform lesions can be massive
- Morphology
  - WM lesions: Spherical/ovoid, often amorphous
  - ONG: Conform to and enlarge ON and chiasm; can be spherical in chiasm and hypothalamus

Radiographic Findings

- Radiography
  - Sphenoid wing and occipital bone dysplasia found in association with plexiform tumors

CT Findings

- NECT: Sphenoid dysplasia with associated enlargement of middle cranial fossa, ipsilateral proptosis
  - Enlarged optic nerve/chiasm
- CTA: Vascular dysplasias → stenosis, moyamoya, aneurysm

MR Findings

- T1WI
  - WM lesions usually isointense to surrounding tissue
    - Irregular hyperintensity may reflect myelin clumping or microcalcification
- T2WI
  - WM lesions are hyperintense and typically poorly defined; no mass effect, disappear by early 20s
    - T2WI may be more sensitive than FLAIR for WM lesions in cerebellum
  - ONG iso-/hyperintense to normal parenchyma
  - ↑ T2 signal and mild-moderate enlargement of hippocampi (uni- or bilateral)
- STIR
  - Excellent definition of plexiform/paraspinal neurofibromas
- DWI
  - ↑ ADC values in FASI compared to normal-appearing white matter (NAWM)
  - ↑ ADC values in NF NAWM compared to controls
    - Reflects accumulation of fluid within myelin sheath
  - ↓ FA in adult NF1 brains compared to healthy brains
- T1WI C+
  - WM lesions/FASI do not enhance
    - Enhancement raises concern for neoplasm
  - Plexiform lesions have variable enhancement
    - Less well defined than on STIR images
  - Visual pathway gliomas have variable enhancement
    - Significance of ↓ enhancement in response to treatment uncertain
- T1WI C+ FS
  - Best sequence for evaluation of ONG
- MRA
  - Useful in evaluation of vascular lesions
- MRS
  - Benefit in evaluation of WM lesions to distinguish from visual pathway glioma
    - WM lesions have relative preservation of NAA
    - Glioma have ↓ NAA with elevated choline

Angiographic Findings

- Most vascular lesions non-CNS, caused by vascular intimal proliferation
  - Aneurysms/AVMs, renal artery stenosis, aortic stenosis/coarctation; moyamoya

Imaging Recommendations

- Best imaging tool
  - MR
    - Benefit of routine surveillance imaging controversial
    - Coronal STIR sequences essential when imaging spine or head and neck
- Protocol advice
  - Include fat-saturated post-contrast imaging of orbits
  - Consider MRA if moyamoya suspected

https://CafePezeshki.IR

DIFFERENTIAL DIAGNOSIS

Demyelinating Disease

- Lesions of acute disseminated encephalomyelitis or multiple sclerosis mimic WM lesions of NF1

Viral Encephalitis

- Ebstein-Barr (EBV), cytomegalovirus (CMV)

Gliomatosis Cerebri

- If FASI are extensive; FASI lack mass effect

Mitochondrial Encephalopathies

- Pantothenate kinase-associated neurodegeneration (PKAN, Hallervorden-Spatz), Leigh syndrome, glutaric acidurias, Kearns-Sayre syndrome
- Often have lesions in basal ganglia or thalami that resemble WM lesions of NF1

Krabbe Disease (Globoid Cell Leukodystrophy)

- Can cause optic nerve enlargement mimicking ONG

PATHOLOGY

General Features

- Etiology
  - *G*ene product is neurofibromin (negative regulator of RAS protooncogene)
    - Inactivated in NF1 → tissue proliferation, tumor development
  - Neurofibromin also regulates neuroglial progenitor function
    - Required for normal glial and neuronal development
  - Oligodendrocyte myelin glycoprotein also embedded in *NF1* gene
- Genetics
  - AD; gene locus on chromosome 17q12
    - Penetrance = 100%
  - ~ 50% new mutations

Staging, Grading, & Classification

- 2 or more of the following fulfills diagnostic criteria for NF1
  - ≥ 6 café au lait spots measuring ≥ 15 mm in adults or 5 mm in children
  - ≥ 2 neurofibromas or 1 plexiform neurofibroma
  - Axillary/inguinal freckling
  - Visual pathway glioma
  - ≥ 2 iris hamartomas ("Lisch nodules")
  - Distinctive bony lesion (sphenoid wing dysplasia, thinning of long bone ± pseudoarthrosis)
  - 1st-degree relative with NF1

Gross Pathologic & Surgical Features

- Gliomas usually pilocytic astrocytomas
  - Frankly malignant in < 20%
- Slight ↑ incidence of medulloblastoma/ependymoma
- Rare subependymal glial nodules
  - Can result in CSF obstruction

Microscopic Features

- WM lesions (FASI)
  - Probably related to (transient) intramyelinic edema
  - No demyelination, axonal degeneration, or inflammation

CLINICAL ISSUES

Presentation

- Most common signs/symptoms
  - Café au lait spots are earliest finding
  - ~ 50% have macrocephaly; in part 2° to ↑ WM volume
  - OPG can cause progressive vision loss

Demographics

- Epidemiology
  - Incidence is 1:3,000-5,000
  - Most common neurocutaneous syndrome
  - Most common inherited tumor syndrome

Natural History & Prognosis

- Morbidity related to specific manifestations
  - OPG → vision loss/blindness, hypothalamic dysfunction
  - Plexiform NF → risk of sarcomatous degeneration
  - Paraspinal NF → kyphoscoliosis
  - Vascular stenoses → hypertension (renal artery), stroke
- FASI increase in number/size in 1st decade of life, regress afterwards; rarely seen in adults
- NF1-related learning disability in 40-60%
- Visual pathway gliomas in NF1 often have more indolent clinical course than sporadic optic glioma

Treatment

- Clinical observation
- Chemotherapy and radiation for OPG

DIAGNOSTIC CHECKLIST

Consider

- Absence of visible stigmata does not exclude NF1
- Be aware of potential for vascular lesions

SELECTED REFERENCES

1. Arnautovic A et al: Delayed diagnosis of childhood low-grade glioma: causes, consequences, and potential solutions. Childs Nerv Syst. ePub, 2015
2. Brossier NM et al: Improving outcomes for neurofibromatosis 1-associated brain tumors. Expert Rev Anticancer Ther. 15(4):415-23, 2015
3. Rodrigues AC Jr et al: Is magnetic resonance spectroscopy capable of detecting metabolic abnormalities in neurofibromatosis type 1 that are not revealed in brain parenchyma of normal appearance? Pediatr Neurol. 52(3):314-9, 2015
4. Billiet T et al: Characterizing the microstructural basis of "unidentified bright objects" in neurofibromatosis type 1: A combined in vivo multicomponent T2 relaxation and multi-shell diffusion MRI analysis. Neuroimage Clin. 4:649-58, 2014
5. Diggs-Andrews KA et al: Modeling cognitive dysfunction in neurofibromatosis-1. Trends Neurosci. 36(4):237-47, 2013
6. Gutmann DH et al: Neurofibromatosis type 1: modeling CNS dysfunction. J Neurosci. 32(41):14087-93, 2012
7. Pasmant E et al: Neurofibromatosis type 1: from genotype to phenotype. J Med Genet. 49(8):483-9, 2012
8. Staser K et al: Pathogenesis of plexiform neurofibroma: tumor-stromal/hematopoietic interactions in tumor progression. Annu Rev Pathol. 7:469-95, 2012
9. Stoker GE et al: Posterior vertebral column resection for the treatment of dystrophic kyphosis associated with type-1 neurofibromatosis: a case report and review of the literature. Spine (Phila Pa 1976). 37(26):E1659-64, 2012
10. Jouhilahti EM et al: The pathoetiology of neurofibromatosis 1. Am J Pathol. 178(5):1932-9, 2011
11. Cairns AG et al: Cerebrovascular dysplasia in neurofibromatosis type 1. J Neurol Neurosurg Psychiatry. 79(10):1165-70, 2008

https://CafePezeshki.IR

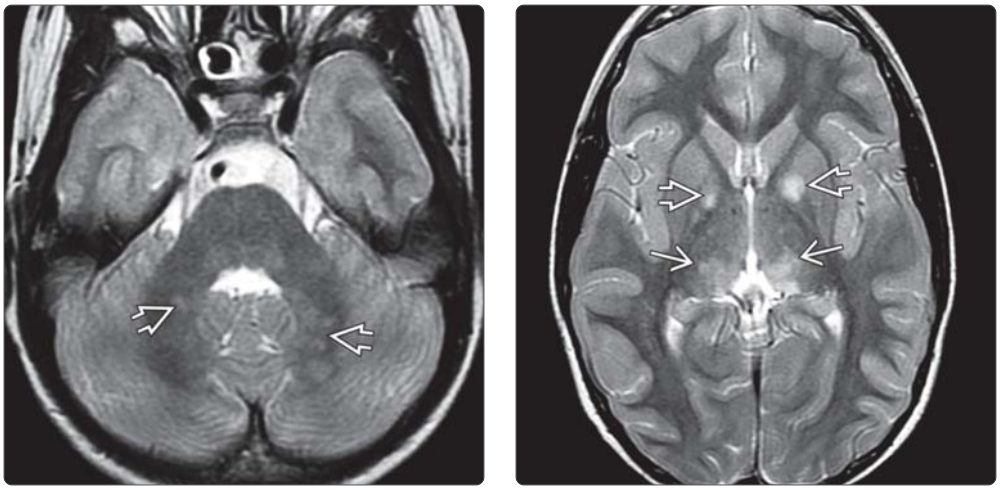

(Left) *Axial T2WI in a 7-year-old boy with NF1 snows multiple ill-defined hyperintense foci in both cerebral peduncles* ⇨. **(Right)** *More cephalad T2WI in the same patient shows hyperintense foci in both globi pallidi* ⇨ *as well as patchy hyperintensities in both thalami* ⇨. *Six years later, all the FASIs had completely disappeared.*

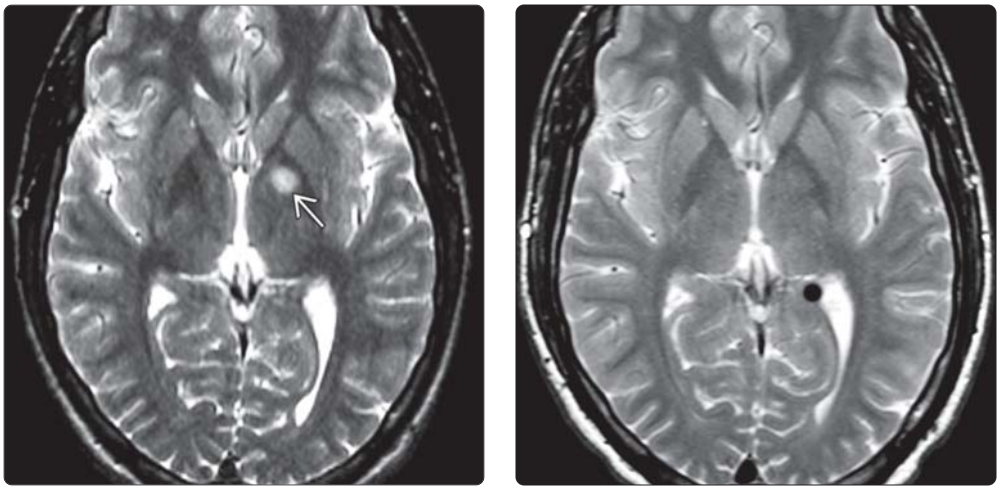

(Left) *T2WI in a 13-year-old boy with NF1 shows a single hyperintense focus* ⇨ *in the left globus pallidus.* **(Right)** *In the same patient 6 years later, T2WI is normal. The focus of abnormal signal intensity (FASI) has completely disappeared.*

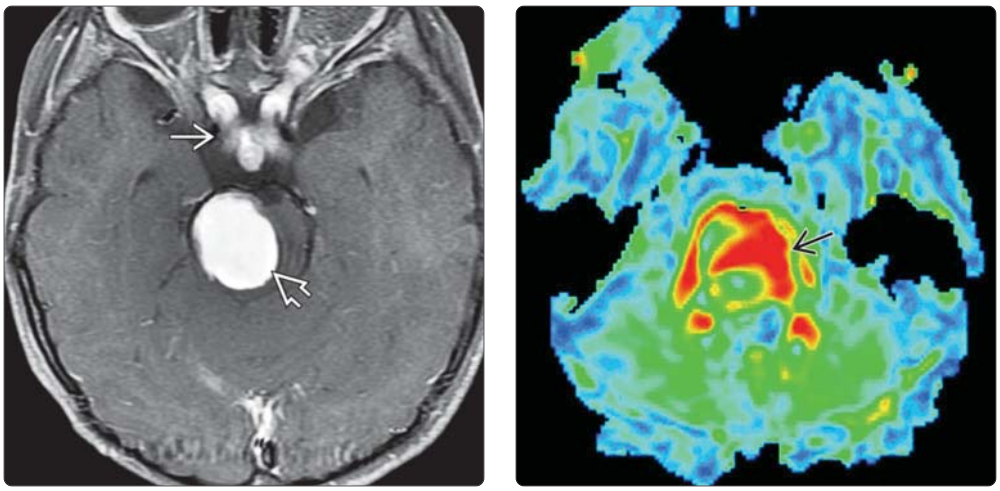

(Left) *Axial T1 C+ FS in a patient with NF1 shows an enhancing lesion in the pons* ⇨ *as well as enlarged, enhancing optic nerves/chiasm* ⇨. **(Right)** *Axial MR perfusion shows increased rCBV in the pons* ⇨. *The optic nerves and chiasm showed no increased rCBV. Biopsy of the pontine lesion showed pilocytic astrocytoma, WHO grade I, with no evidence for malignant degeneration. PAs are very vascular neoplasms and often exhibit a malignant-like spectrum on MRS, so don't be fooled.*

https://CafePezeshki.IR

Neurofibromatosis Type 2

KEY FACTS

TERMINOLOGY

- Familial cancer syndrome
  - Multiple cranial nerve (CN) schwannomas, meningiomas, and spinal tumors

IMAGING

- Best diagnostic clue: Bilateral vestibular schwannomas (VSs)
- Multiple extraaxial tumors
  - Schwannomas of CNs and spinal nerve roots
  - Meningiomas on dural surfaces (up to 50%)
- Intraaxial tumors
  - Ependymomas in spinal cord and brainstem (6%)
- Recommendation: Use high-resolution T1 C+ FS MR through basal cisterns to evaluate cranial nerves

TOP DIFFERENTIAL DIAGNOSES

- Schwannomatosis
- Multiple meningiomas
- Metastases

PATHOLOGY

- All neurofibromatosis type 2 (NF2) families have chromosome 22q12 abnormalities
- *NF2* gene encodes for merlin protein

CLINICAL ISSUES

- Usually presents between 2nd and 4th decades with hearing loss, ± vertigo
- Incidence: 1:25,000-30,000
- Life span substantially shortened by presence of meningiomas and by complications related to lower cranial neuropathies (i.e., aspiration)

DIAGNOSTIC CHECKLIST

- Carefully evaluate other cranial nerves in any new diagnosis of schwannoma or meningioma in child/adolescent/young adult

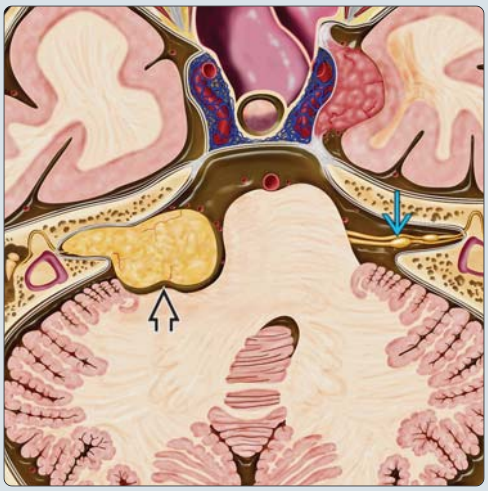

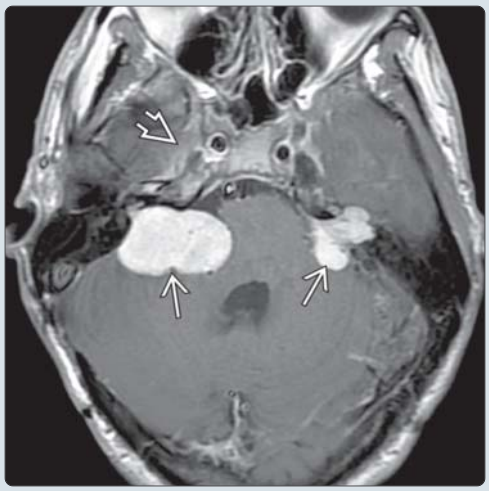

(Left) *Axial graphic shows bilateral cerebellopontine angle (CPA) schwannomas pathognomonic of neurofibromatosis type 2 (NF2). The tumor on the right is large and several small schwannomas are seen on the left vestibulocochlear nerves.* **(Right)** *Axial T1 C+ MR in a patient with typical NF2 shows bilateral vestibular schwannomas and a right cavernous sinus meningioma.*

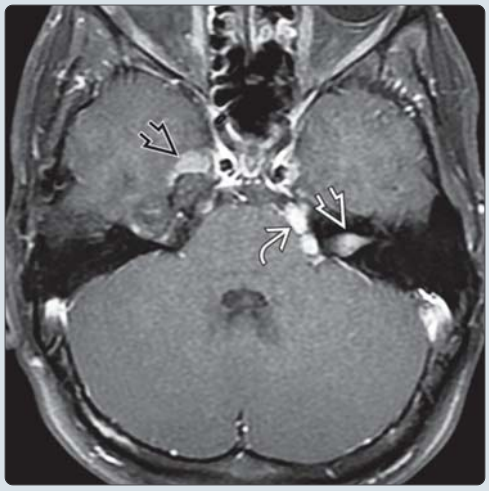

(Left) *Axial T2WI in a 14-year-old male with left sensorineural hearing loss shows a mass in the left internal auditory canal and another lesion in the right cavernous sinus. Note the small nodules along the right vestibular nerve.* **(Right)** *T1 C+ FS in the same patient shows the left IAC mass enhances, as does the right cavernous sinus lesion. In addition, 2 enhancing nodules are seen along the cisternal left trigeminal nerve. The patient was subsequently diagnosed with NF2.*

https://CafePezeshki.IR

TERMINOLOGY

Abbreviations

- Neurofibromatosis type 2 (NF2)
- Vestibular schwannoma (VS)

Synonyms

- Acoustic neurofibromatosis, central neurofibromatosis
- Multiple intracranial schwannomas, meningiomas, and ependymomas (MISME)

Definitions

- Familial cancer syndrome causing multiple cranial nerve (CN) schwannomas, meningiomas, and spinal tumors

IMAGING

General Features

- Best diagnostic clue
  - Bilateral vestibular schwannomas
- Location
  - Multiple extraaxial tumors
    - Schwannomas of CNs and spinal nerve roots
    - Meningiomas on dural surfaces (up to 50%)
  - Intraaxial tumors
    - Ependymomas in spinal cord and brainstem (6%)
- Size
  - Cranial nerve tumors typically symptomatic while still small but can achieve great size
- Morphology
  - Tumors grow spherically but accommodate to bony canals (e.g., internal auditory canal [IAC])
- Multiplicity of lesions
  - Schwannomas of other cranial nerves in 50%
    - CN5 most common; also CN3, CN12 common
  - Schwannoma of spinal nerves (up to 90%)
  - Meningiomas (often multiple)
  - Intramedullary ependymomas (spinal cord)
  - Cerebral calcifications
  - Posterior lens opacities (juveniles, in 60-80%)
  - Meningioangiomatosis
  - Glial microhamartomas

CT Findings

- NECT
  - Vestibular schwannoma
    - Cerebellopontine angle (CPA) mass ± widened IAC
    - Isodense to hyperdense
    - Rarely cystic/necrotic
  - Meningioma
    - High-density, dural-based mass(es)
  - Nonneoplastic cerebral Ca++ (uncommon)
    - Extensive choroid plexus Ca++
    - Cortical surface
    - Ventricular lining
- CECT
  - Cranial nerve tumor enhancement
  - Meningioma enhancement

MR Findings

- T1WI
  - Schwannomas
    - Hypointense to isointense
    - Rare cystic change
  - Meningiomas
    - Isointense to hypointense
    - Occasional hyperintense foci from Ca++
- T2WI
  - Schwannomas
    - Small intracanalicular lesions can be shown on high-resolution T2WI
  - Meningiomas
    - May incite significant adjacent edema
- T2* GRE
  - Shows nonneoplastic Ca++ to best advantage
- DWI
  - Some meningiomas have restricted diffusion
    - Characteristic of atypical or malignant meningioma
- T1WI C+
  - Schwannomas
    - Diffuse enhancement
    - Usually homogeneous
    - T1 C+ with fat saturation and thin-slice profile essential for identification of small CN tumors
    - Vestibular schwannomas typically "bulge" into CPA cistern from IAC
  - Meningiomas
    - Diffuse enhancement of tumor, may be plaque like
- MRS
  - Meningioma
    - Absent NAA peak, ↑ alanine, ± lactate
  - Schwannoma
    - Absent NAA peak, ↑ myoinositol, usually no lactate

Nonvascular Interventions

- Myelography
  - Will demonstrate multiple spinal tumorlets
    - Replaced by contrast-enhanced MR

Imaging Recommendations

- Best imaging tool
  - Contrast-enhanced MR
- Protocol advice
  - Use high-resolution T1 C+ FS MR through basal cisterns to evaluate cranial nerves
  - Evaluation for spinal disease is critical

DIFFERENTIAL DIAGNOSIS

Schwannomatosis

- Multiple schwannomas without vestibular tumors
- No cutaneous stigmata or meningiomas

Cerebellopontine Angle (CPA) Masses

- Arachnoid cyst
  - Follows CSF on all sequences
- Epidermoid
  - DWI easily distinguishes from arachnoid cyst
- Aneurysm
  - PICA/AICA/VA aneurysms may project into CPA
  - Pulsation artifact in phase-encoding direction
- Ependymoma

https://CafePezeshki.IR

- Extends into CPA from 4th ventricle

Multiple Meningiomas

- Recurrent or metastatic
- Secondary to radiation therapy

Metastases

- CNS primary
  - Glioblastoma, PNET-MB, germinoma, ependymoma
- Non-CNS primary

Inflammatory Disease

- Granulomatous disease: Sarcoidosis, tuberculosis
- Neuritis: Bell palsy, Lyme disease

PATHOLOGY

General Features

- Etiology
  - 50% of patients have known family history of NF2; 50% new mutations
  - Mutations cause truncated, inactivated merlin protein (**m**eosin-**e**rzin-**r**axidin-**l**ike protein)
  - Tumor cells are usually hemizygous or homozygous for *NF2* mutations
- Genetics
  - Autosomal dominant
  - All NF2 families have chromosome 22q12 abnormalities
  - Germline, somatic *NF2* gene mutations
    - *NF2* gene encodes for merlin protein
    - *NF2* gene functions: Links cytoskeleton and cell membranes; also tumor suppressor gene
    - Molecular pathway mTORC1 is affected; inhibitors may inhibit tumor growth
- Multiple schwannomas, meningiomas, ependymomas

Staging, Grading, & Classification

- NF2-associated schwannomas are WHO grade I
- Diagnostic criteria
  - Bilateral vestibular schwannomas or
  - 1st-degree relative with NF2 and 1 vestibular schwannoma or
  - 1st-degree relative with NF2 and 2 of the following
    - Neurofibroma
    - Meningioma
    - Glioma
    - Schwannoma
    - Posterior subcapsular lenticular opacity

Gross Pathologic & Surgical Features

- Schwannomas are round-ovoid encapsulated masses
- Meningiomas are unencapsulated but sharply circumscribed

Microscopic Features

- NF2-related schwannomas have higher proliferative activity than sporadic tumors but not necessarily more aggressive course

CLINICAL ISSUES

Presentation

- Most common signs/symptoms
  - Usually presents between 2nd and 4th decades with hearing loss, ± vertigo
    - Caution: 25% of patients over 50 years and 50% over 70 years who have bilateral VSs at initial presentation do not have NF2 mutations (and is therefore chance occurrence)
  - 1/3 of children with NF2 present with hearing loss, 1/3 present with other cranial nerve symptoms
  - May present with meningioma before vestibular schwannomas develop
    - Children presenting with meningioma should have testing for NF2
- Other signs/symptoms
  - Scoliosis, paraplegia, or neck pain from spinal lesions
- Clinical profile
  - Wishart type: Early onset, rapid progression before adulthood, more severe presentation
  - Gardner type: Later onset, less severe manifestations

Demographics

- Epidemiology
  - 1:25,000-30,000

Natural History & Prognosis

- Life span substantially shortened by presence of meningiomas and by complications related to lower cranial neuropathies (i.e., aspiration)
- VS progression in NF2 patients not undergoing active treatment
  - 31% at 1 year; 64% at 2 years, 79% at 3 years

Treatment

- Complete resection of CN8 schwannoma if feasible
  - Can be difficult as NF2 tumors tend to splay/envelop CNs instead of displacing them
  - Stereotaxic radiosurgery option increasing
- Subtotal microsurgical resection with functional cochlear nerve preservation in last hearing ear

DIAGNOSTIC CHECKLIST

Consider

- Carefully evaluate other cranial nerves in any new diagnosis of vestibular schwannoma or meningioma in child/adolescent
- Study entire neuraxis in suspected cases (multiple small, asymptomatic schwannomas on cauda equina common)

Image Interpretation Pearls

- Coronal thin-slice T1WI C+ FS MR to assess cranial nerves

SELECTED REFERENCES

1. Evans DG et al: Bilateral vestibular schwannomas in older patients: NF2 or chance? J Med Genet. ePub, 2015
2. Jethanamest D et al: Conservative management of vestibular schwannoma: Predictors of growth and hearing. Laryngoscope. ePub, 2015
3. Ferner RE et al: Longitudinal evaluation of quality of life in 288 patients with neurofibromatosis 2. J Neurol. 261(5):963-9, 2014
4. Giovannini M et al: mTORC1 inhibition delays growth of neurofibromatosis type 2 schwannoma. Neuro Oncol. 16(4):493-504, 2014
5. Matsuo M et al: Characterization of early onset neurofibromatosis type 2. Brain Dev. 36(2):148-52, 2014
6. Plotkin SR et al: Natural history of vestibular schwannoma growth and hearing decline in newly diagnosed neurofibromatosis type 2 patients. Otol Neurotol. 35(1):e50-6, 2014

https://CafePezeshki.IR

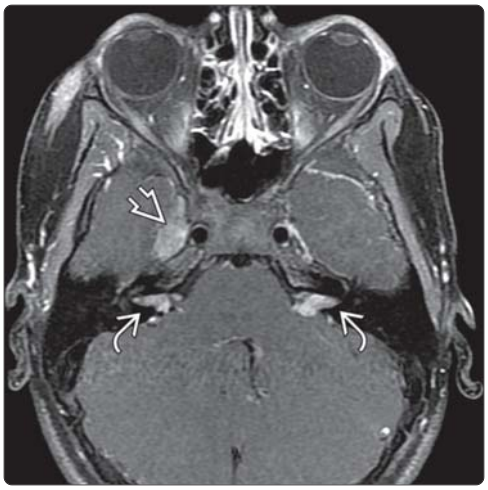

(Left) *Axial T1WI C+ FS MR of a 9 year old reveals small, enhancing vestibular schwannomas in the IAC-CPA bilaterally. An enhancing mass is also demonstrated in the right trigeminal cistern and found to be a trigeminal schwannoma.* **(Right)** *Axial T2WI FS MR in the same patient shows expansion and T2-hypointense signal in the right trigeminal cistern. The IAC/CPA masses are not well appreciated. This child was asymptomatic for these lesions.*

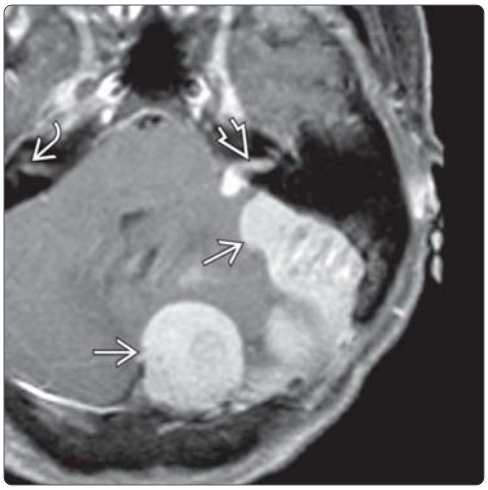

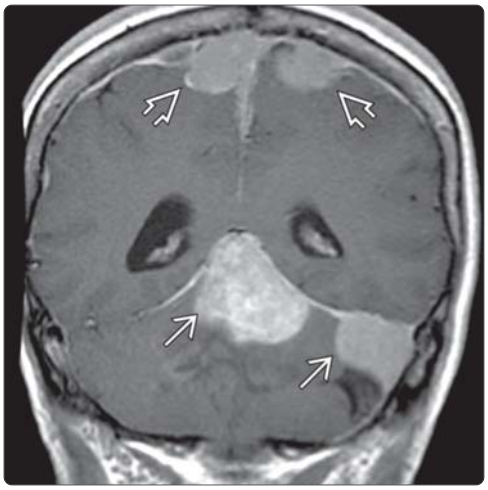

(Left) *Axial T1WI C+ MR of a 70-year-old woman with NF2 shows extensive meningiomatosis with dural-based masses in the posterior fossa. There is a small enhancing mass in the left IAC-CPA and a tiny, almost imperceptible one at the fundus of the right internal auditory canal.* **(Right)** *Coronal T1WI C+ MR shows the dural-based meningiomas in the posterior fossa and along the falx and convexities. In this patient, the meningiomatosis predominates over the schwannomas.*

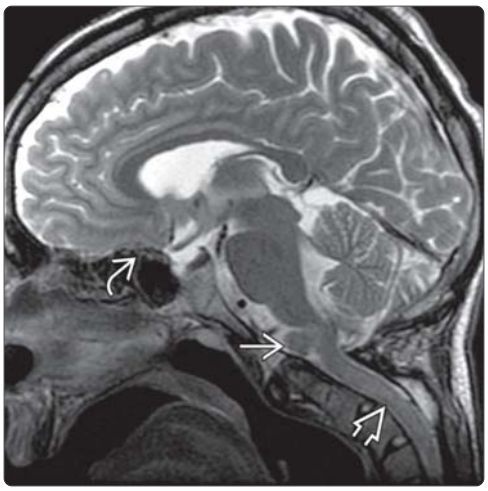

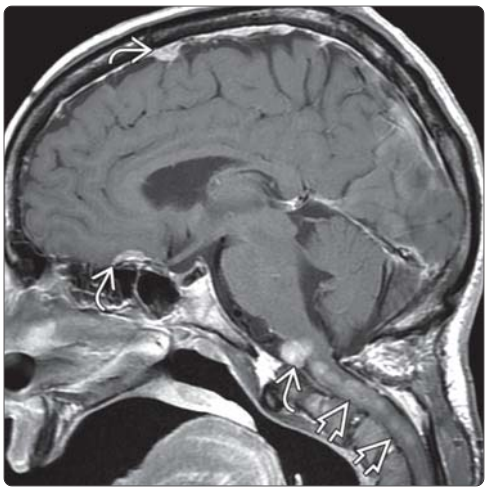

(Left) *Sagittal T2WI FS MR of the brain and the upper cervical spine shows "blistering" of the planum sphenoidale, an extraaxial mass in front of the medulla at the foramen magnum, and an enlarged, hyperintense cervical spinal cord.* **(Right)** *Sagittal T1WI C+ MR in the same patient shows multiple enhancing meningiomas and enhancing ependymoma of the upper cervical cord. A "swan neck" deformity is noted in the upper neck from prior multilevel laminectomies.*

https://CafePezeshki.IR

von Hippel-Lindau Syndrome

KEY FACTS

TERMINOLOGY

- Autosomal dominant familial syndrome with hemangioblastomas (HGBLs), clear cell renal carcinoma, cystadenomas, pheochromocytomas

IMAGING

- 2 or more CNS HGBLs or 1 HGBL plus visceral lesion or retinal hemorrhage
- HGBLs vary from tiny mass to very large with even larger associated cysts

TOP DIFFERENTIAL DIAGNOSES

- Vascular metastasis
- Solitary hemangioblastoma
- Pilocytic astrocytoma
- Hemispheric medulloblastoma in teenager or young adult
- Multiple AVMs in vascular neurocutaneous syndrome

PATHOLOGY

- von Hippel-Lindau (VHL) phenotypes, subtypes based on absence or presence of pheochromocytoma
  - Type 1: Low risk of pheochromocytoma
  - Type 2: High risk of pheochromocytoma
    - Type 2A (low risk of renal cell carcinoma)
    - Type 2B high risk of renal cell carcinoma)
    - Type 2C (familial pheochromocytoma without either HGBL or RCC)

CLINICAL ISSUES

- Earliest symptom in VHL often visual
  - Retinal HGBL, peak in teenage
- HGBLs → multiple periods of tumor growth (usually associated with increasing cyst size) separated by periods of arrested growth

DIAGNOSTIC CHECKLIST

- Follow NIH screening rules

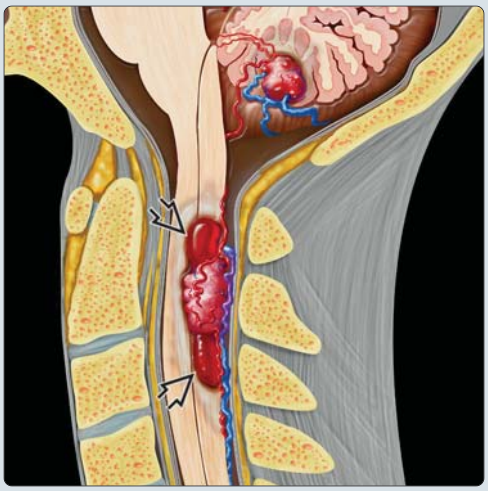

(Left) *Sagittal graphic shows 2 hemangioblastomas (HGBLs) in von Hippel-Lindau (VHL). In this patient, the spinal cord tumor has an associated cyst ⇨ and would cause myelopathy. The small cerebellar HGBL would be asymptomatic.* **(Right)** *Abdominal VHL lesions include bilateral renal cysts ⇨, carcinomas ⇨, pancreatic cysts ⇨, and adrenal pheochromocytoma ⇨.*

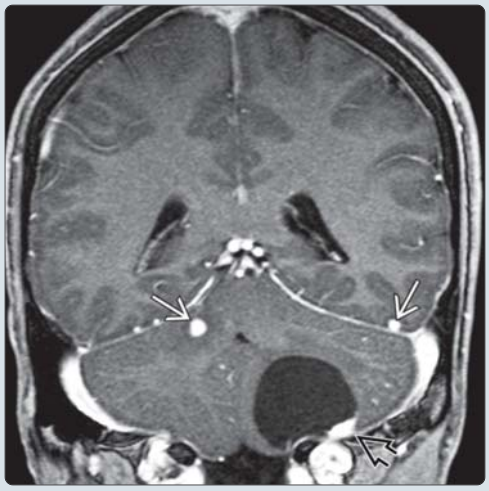

(Left) *Sagittal T1C+FS MR in a patient with VHL shows multiple cerebellar ⇨, spinal hemangioblastomas ⇨.* **(Right)** *Coronal T1C+FS in an asymptomatic 26-year-old male with pancreatic cysts and a family history of VHL shows 2 solid ⇨ and 1 cystic hemangioblastoma with a mural nodule ⇨.*

https://CafePezeshki.IR

TERMINOLOGY

Abbreviations

- von Hippel-Lindau (VHL) syndrome

Definitions

- Autosomal dominant familial syndrome with hemangioblastomas (HGBLs), clear cell renal carcinoma, cystadenomas, pheochromocytomas
  - Affects 6 different organ systems, including eye, ear, and central nervous system (CNS)
  - Involved tissues often have multiple lesions
  - Lesions → benign cysts, vascular tumors, carcinomas

IMAGING

General Features

- Best diagnostic clue
  - 2 or more CNS HGBLs; or 1 HGBL plus visceral lesion or retinal hemorrhage
- Location
  - HGBLs in VHL in 60-80% of patients
    - Typically multiple
    - 40-50% in spinal cord (posterior 1/2)
    - 44-72% cerebellum (posterior > anterior 1/2)
    - 10-25% brainstem (posterior medulla)
    - HGBLs arise from pia; if lesion is in deep white matter or in center of cord, it is not HGBL
  - Ocular angiomas
    - Found in 25-60% of *VHL* gene carriers
    - Cause retinal detachment, hemorrhage
  - Endolymphatic sac tumors (ELST)
    - Large T-bone mass; located posterior to internal auditory canal near vestibular aqueduct
- Size
  - HGBLs vary from tiny mass to very large with even larger associated cysts
- Morphology
  - HGBL may be solid, solid with central necrosis, or cystic with enhancing mural nodule

CT Findings

- NECT
  - HGBL: 2/3 → well-delineated cerebellar cyst with nodule
    - Nodule typically abuts pial surface
    - 1/3 solid, without cyst
  - ELST → permeative, destructive changes in petrous bone
- CECT
  - Intense enhancement of tumor nodule

MR Findings

- T1WI
  - HGBL: Mixed iso- to hypointense nodule, ± "flow voids"
  - Associated cyst iso- to slightly hyperintense to cerebrospinal fluid (CSF)
  - Cystadenoma of ELS: Heterogeneous hyper-/hypointense
- T2WI
  - HGBL: Hyperintense nodule, cyst
  - Cystadenoma of ELS: Hyperintense mass
- FLAIR
  - HGBL: Hyperintense cyst with variable edema
  - Cystadenoma of ELS: Hyperintense mass
- T2* GRE
  - HGBL: "Blooms" if hemorrhage present
- T1WI C+
  - HGBL: Tumor nodule enhances strongly; cyst wall does not enhance
  - Tiny asymptomatic enhancing nodules commonly found
  - Cystadenoma of ELS: Heterogeneous enhancement

Angiographic Findings

- Conventional
  - HGBL: DSA shows intensely vascular mass, prolonged stain
  - A-V shunting (early draining vein) common

Imaging Recommendations

- Best imaging tool
  - Brain: MR ± contrast
- Protocol advice
  - Scan entire brain and spine
- NIH recommendations
  - Contrast-enhanced MR of brain/spinal cord every 2 years from age 11 years
  - US of abdomen from 11 years, yearly
  - Abdominal CT from 20 years, yearly/every other year
  - MR of temporal bone if hearing loss/tinnitus/vertigo

DIFFERENTIAL DIAGNOSIS

Vascular Metastasis

- Usually solid, not cyst with nodule
- Some tumors (e.g., renal clear cell carcinoma) can resemble HGBL histopathologically

Solitary Hemangioblastoma

- 25-40% of HGBLs occur in VHL
- No *VHL* mutations, family history, other tumors or cysts

Pilocytic Astrocytoma

- Usually younger than VHL patients
- Tumor nodule lacks vascular flow voids (more characteristic of HGBL)
- Tumor nodule often does not abut pial or ependymal surface

Hemispheric Medulloblastoma in Teenager or Young Adult

- Rare; occur in peripheral cerebellar hemisphere
- May appear extraparenchymal
- Solid, gray matter intensity on T2WI

Multiple AVMs in Vascular Neurocutaneous Syndrome

- Osler-Weber-Rendu, Wyburn-Mason, etc.
- Small AVMs may resemble HGBL at angiography

PATHOLOGY

General Features

- Genetics
  - Autosomal dominant inheritance with high penetrance, variable expression

https://CafePezeshki.IR

  - 20% of cases due to new mutation
- Germline mutations of *VHL* tumor suppressor gene
  - Chromosome 3p25-26
  - Gene product: pVHL; inactivation of pVHL results in overexpression of hypoxia-inducible mRNAs, including vascular endothelial growth factor (VEGF)
  - Involved in cell cycle regulation, angiogenesis
  - Disease features vary depending on specific *VHL* mutations
  - Posterior distribution of HGBLs = result of tumor development during embryogenesis
    - Tumors are derived from embryonic multipotent cells

Staging, Grading, & Classification

- Capillary hemangioblastoma: WHO grade I

Gross Pathologic & Surgical Features

- HGBL seen as well-circumscribed, very vascular, reddish nodule
  - 75% at least partially cystic; fluid is amber colored

Microscopic Features

- 2 components in HGBL
  - Rich capillary network
  - Large, vacuolated stromal cells with clear cytoplasm

CLINICAL ISSUES

Presentation

- Most common signs/symptoms
  - VHL is clinically very heterogeneous; phenotypic penetrance: 97% at 65 years
    - Rate of new tumor development not constant, varies with age (peak at 30-34 years)
  - Retinal angiomas
    - Earliest symptom in VHL often visual; peak in teenage years
    - Retinal detachment, vitreous hemorrhages
  - Cerebellar HGBLs
    - Headache (obstructive hydrocephalus)
    - Peak 4th decade
    - Nearly 75% of symptom-producing tumors have associated cyst, peritumoral edema
  - Spinal cord HGBLs
    - Progressive myelopathy
    - 95% associated syrinx
  - ELSTs
    - Prevalence in VHL patients is 3.6%
    - Can be 1st presentation of VHL so need molecular testing
- Clinical profile
  - Diagnosis of VHL: Capillary hemangioblastoma in CNS/retina and 1 of typical VHL-associated tumors or previous family history
  - VHL phenotypes, subtypes based on absence or presence of pheochromocytoma
    - Type 1: Low risk of pheochromocytoma
    - Type 2: High risk of pheochromocytoma
      - Type 2A (low risk of renal cell carcinoma)
      - Type 2B high risk of renal cell carcinoma)
      - Type 2C (familial pheochromocytoma without either HGBL or RCC)

Demographics

- Age
  - VHL presents in young adults: Mean age of presentation
    - Retinal angioma: 25 years
    - Cerebellar HGBL, pheochromocytoma: 30 years
    - Endolymphatic sac tumor: 31 years
    - Renal carcinoma: 33 years
- Epidemiology
  - 1:35,000-50,000

Natural History & Prognosis

- Renal carcinoma proximal cause of death in 15-50%
- HGBLs → multiple periods of tumor growth (usually associated with increasing cyst size) separated by periods of arrested growth
- On average, new lesion develops every 2 years in VHL

Treatment

- Ophthalmoscopy yearly from infancy
- Physical/neurological examination yearly
- Surgical resection of symptomatic cerebellar/spinal hemangioblastoma
- Stereotactic radiosurgery provides tumor control in 70-90%
- Laser treatment of retinal angiomas

DIAGNOSTIC CHECKLIST

Consider

- Follow NIH screening rules
- Look for ELS tumors in VHL patients with dysequilibrium, hearing loss, or aural fullness

Image Interpretation Pearls

- Solitary HGBL in young patient may indicate VHL

SELECTED REFERENCES

1. Bausch B et al: Characterization of endolymphatic sac tumors and von Hippel-Lindau disease in the international ELST registry. Head Neck. ePub, 2015
2. Binderup ML et al: Risk of new tumors in von Hippel-Lindau patients depends on age and genotype. Genet Med. ePub, 2015
3. Gossage L et al: VHL, the story of a tumour suppressor gene. Nat Rev Cancer. 15(1):55-64, 2015
4. Kano H et al: Stereotactic radiosurgery for intracranial hemangioblastomas: a retrospective international outcome study. J Neurosurg. 1-10, 2015
5. Hanakita S et al: The long-term outcomes of radiosurgery for intracranial hemangioblastomas. Neuro Oncol. 16(3):429-33, 2014
6. Bamps S et al: What the neurosurgeon should know about hemangioblastoma, both sporadic and in Von Hippel-Lindau disease: A literature review. Surg Neurol Int. 4:145, 2013
7. Kim H et al: Meningeal supratentorial hemangioblastoma in a patient with von hippel-lindau disease mimicking angioblastic menigioma. J Korean Neurosurg Soc. 54(5):415-9, 2013
8. Lonser RR et al: Pituitary stalk hemangioblastomas in von Hippel-Lindau disease. J Neurosurg. 110(2):350-3, 2009
9. Jagannathan J et al: Surgical management of cerebellar hemangioblastomas in patients with von Hippel-Lindau disease. J Neurosurg. 108(2):210-22, 2008

https://CafePezeshki.IR

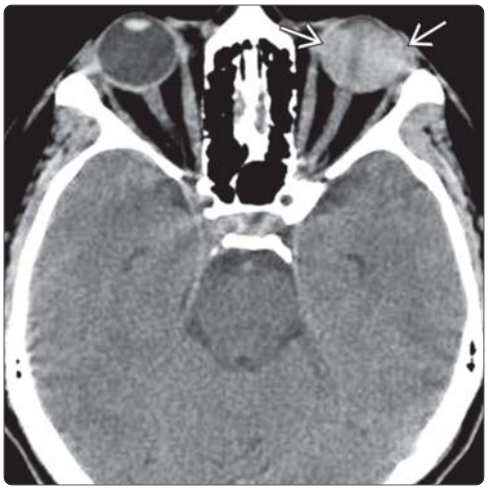

(Left) *Axial graphic depicts an endolymphatic sac tumor in a patient with VHL. The lesion is a lytic, vascular, hemorrhagic mass ⇨ that lies between the IAC, sigmoid sinus. Note the tendency to fistulize inner ear ⇨.* **(Right)** *Axial NECT scan in a 51-year-old female with known VHL and sensorineural hearing loss shows a classic feature of VHL, a hyperdense V-shaped hemorrhagic retinal detachment ⇨ caused by an underlying retinal HGBL ("angioma").*

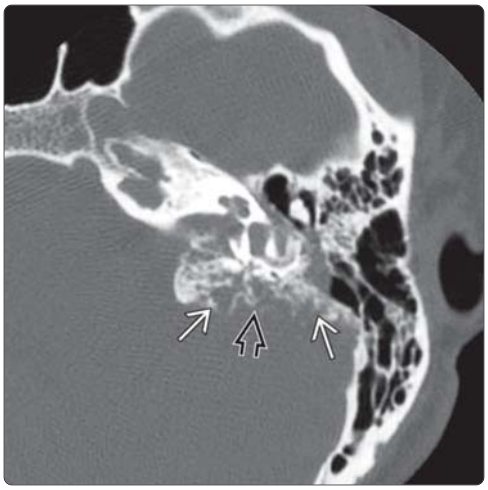

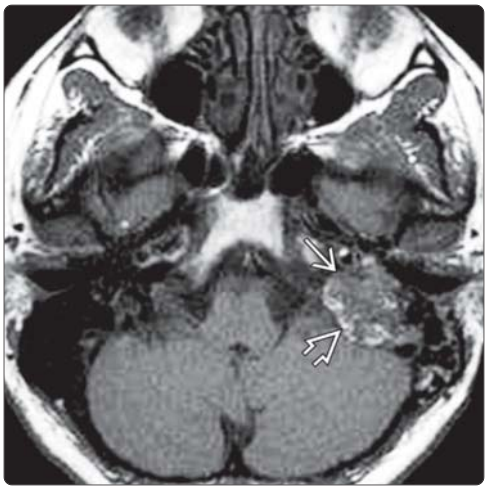

(Left) *Temporal bone CT in the same patient shows a lytic infiltrative lesion ⇨ along the left posterior petrous temporal bone. Note the preserved "spicules" of bone ⇨ within the lesion. Location and appearance are characteristic for endolymphatic sac tumors (ELST).* **(Right)** *Axial T1WI in the same patient shows that the lesion is mixed iso- ⇨ and hyperintense ⇨ relative to brain.*

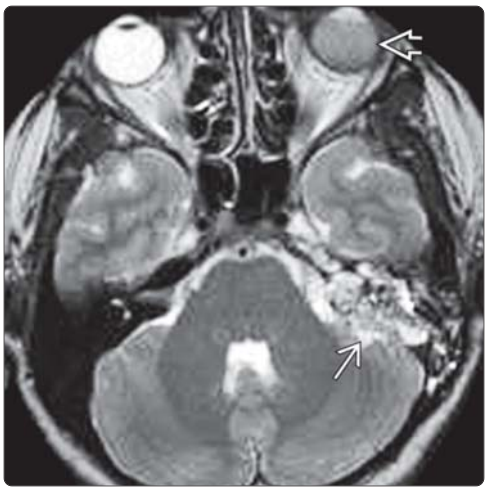

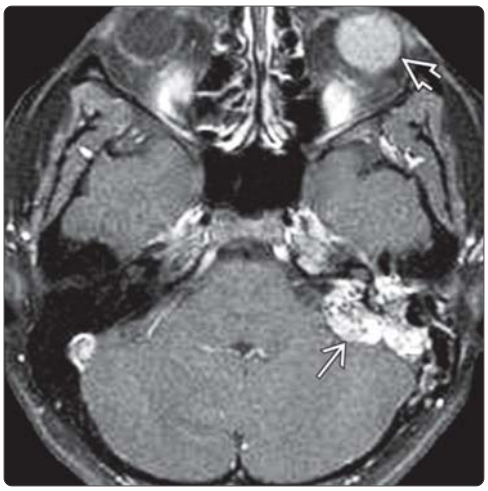

(Left) *T2WI in the same patient shows the lesion is heterogeneously hyperintense ⇨. Note the hypointensity in the left vitreous body ⇨ relative to the normal right globe.* **(Right)** *T1 C+ FS in the same patient shows that the lesion ⇨ enhances intensely but heterogeneously. The retinal hemorrhage ⇨ is hyperintense on T1. (Courtesy D. Shatzkes, MD.)*

https://CafePezeshki.IR

KEY FACTS

TERMINOLOGY

- Tuberous sclerosis complex (TSC)
- Multisystem genetic disorder with epilepsy, multiorgan tumors, and hamartomas
  - Spectrum of central nervous system (CNS) hamartomas; all contain dysplastic neurons and giant (balloon) cells
  - Caused by mutation in *TSC1* or *TSC2* gene
  - Now considered an infantile (developmental) tauopathy
    - Tau abnormally expressed in many of dysmorphic neurons and glial cells of TSC
    - Similar to focal cortical dysplasia 2

IMAGING

- Calcified subependymal nodules (SEN) (hamartomas)
- Subependymal giant cell astrocytoma (SEGA) (15%); most located at foramen of Monro
- Cortical/subcortical tubers (95%)
- White matter (WM) radial migration lines
- Cyst-like WM lesions (cystoid brain degeneration)
- Cortical/subcortical tubers: Early T1 ↑ but variable after myelin maturation
- SEN enhancement more visible on MR than on CT

TOP DIFFERENTIAL DIAGNOSES

- X-linked subependymal heterotopia
- TORCH syndromes
  - CMV with periventricular Ca++, typical WM lesions, polymicrogyria
- Taylor-type cortical dysplasia (FCD type 2)

PATHOLOGY

- Abnormal differentiation/proliferation of germinal matrix cells
- Mutations in TSC tumor suppressor genes cause abnormal cellular differentiation, proliferation

DIAGNOSTIC CHECKLIST

- FLAIR and T1 MT most sensitive sequences for diagnosis
- SEN (< 1.3 cm) vs. SEGA (> 1.3 cm, enlarging)

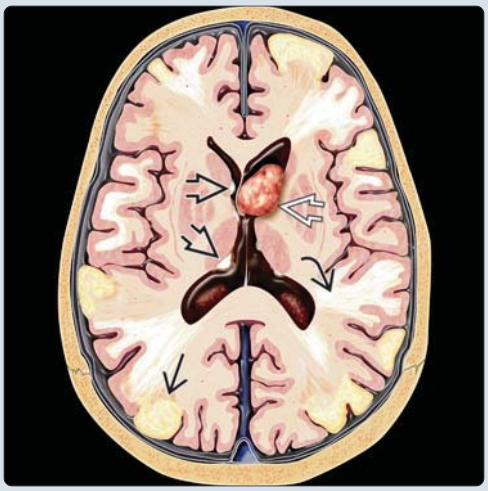

(Left) *Axial graphic of typical brain involvement in tuberous sclerosis complex shows a giant cell astrocytoma ➡ in the left foramen of Monro, subependymal nodules ➡, radial migration lines ➡, and cortical/subcortical tubers ➡.* **(Right)** *Axial FLAIR surveillance scan in a 14-year-old boy with known TSC shows a well-demarcated lobulated mass in the left frontal horn ➡, a subependymal giant cell astrocytoma. Note multiple expanded gyri with poor gray-white differentiation (tubers ➡), subcortical WM hyperintensities.*

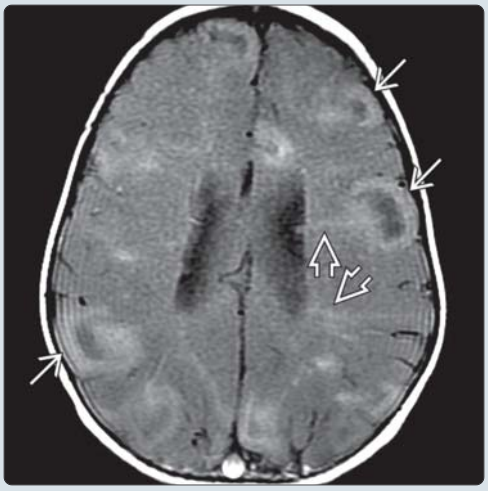

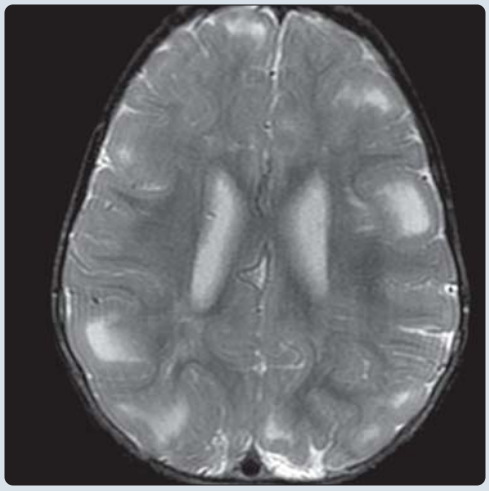

(Left) *Axial T1WI MR with magnetization transfer (MT) in a 13 month old shows classic findings of TS: Multiple cortical/subcortical tubers ➡ and white matter (WM) radial migration lines ➡. These lesions are well demonstrated as the signal from normal WM is suppressed by the MT pulse.* **(Right)** *Axial T2WI MR demonstrates tubers as T2-hyperintense lesions beneath expanded ("clubbed") gyri. The white matter radial migration lines are not well appreciated.*

https://CafePezeshki.IR

TERMINOLOGY

Abbreviations

- Tuberous sclerosis complex (TSC)

Synonyms

- Bourneville-Pringle syndrome

Definitions

- Multisystem genetic disorder with epilepsy, multiorgan tumors, and hamartomas
  - Spectrum of central nervous system (CNS) hamartomas; all contain dysplastic neurons and giant (balloon) cells
  - Caused by mutation in *TSC1* or *TSC2* gene
  - Now considered infantile (developmental) tauopathy
    - Tau abnormally expressed in many of dysmorphic neurons and glial cells of TSC

IMAGING

General Features

- Best diagnostic clue
  - Calcified subependymal nodules (hamartomas)
    - 98% have subependymal nodules (SENs)
- Location
  - Subependymal giant cell astrocytomas (SEGA) arise in 15%; most located at foramen of Monro
  - Cortical/subcortical tubers (95%)
    - Frontal > parietal > occipital > temporal > cerebellum
    - ↑ number of tubers → ↑ neurologic symptoms
  - White matter radial migration lines (WMRMLs)
    - Represent heterotopic glia with neurons along path of cortical migration from ventricle to cortex
  - Cyst-like white matter (WM) lesions (cystoid brain degeneration)
- Size
  - Thickened cortex, enlarged gyri associated with cortical/subcortical tubers
  - SEN that grows over time and measures > 1.3 cm = SEGA
- Morphology
  - Gyral expansion, sometime pyramidal shape
  - 20% have "potato eye" central depression

CT Findings

- NECT
  - SENs
    - Along caudothalamic groove > atrial > > temporal
    - 50% Ca++ (progressive after 1 year)
  - Tubers
    - Early: Low-density/Ca++ cortical/subcortical mass
    - Later: Isodense/Ca++ (50% by 10 years)
  - Ventriculomegaly common even without SEGA
- CECT
  - Enhancing/enlarging SEN suspicious for SEGA

MR Findings

- T1WI
  - Cortical/subcortical tubers: Early T1 ↑ but variable after myelin maturation
  - Focal lacune-like cysts (vascular etiology)
  - WMRMLs, tubers: Bright signal with magnetization transfer (MT) imaging
    - Use of MT increases sensitivity to small tuber detection
- T2WI
  - Variable signal (relative to myelin maturation)
- FLAIR
  - WMRMLs: Streaky linear or wedge shaped ↑ signal
  - FLAIR becomes more positive with age
- T2* GRE
  - Ca++ SEN more readily discerned; ↑ susceptibility on T2* SWI with age
- DWI
  - ↑ ADC values in epileptogenic tubers
  - ↑ ADC, ↓ FA in normal-appearing WM on DTI
- T1WI C+
  - SEN enhancement more visible on MR than on CT
    - 30-80% enhance (enlarging SEN at foramen of Monro: SEGA)
    - Other enhancing lesions followed (unless growing or obstructing CSF)
  - 3-4% of tubers enhance
- MRA
  - Rare aneurysms and dysplasias/moyamoya
- MRS
  - ↓ NAA/Cr, ↑ mI/Cr in subcortical tubers, SENs

Ultrasonographic Findings

- Grayscale ultrasound
  - Fetal documentation of rhabdomyoma: TSC confirmed in 96%
    - Identified as early as 20 weeks gestation

Imaging Recommendations

- Best imaging tool
  - MR with contrast
- Protocol advice
  - MR with contrast, ± NECT (document Ca++ SENs)
  - Yearly surveillance imaging if incompletely calcified SEGA or enhancing SEGA
    - Look for rapid growth, ± ventricular obstruction

DIFFERENTIAL DIAGNOSIS

X-Linked Subependymal Heterotopia

- Isointense to gray matter (GM) T1/T2+

(S)TORCH

- Cytomegalovirus (CMV): Periventricular Ca++, typical WM lesions, polymicrogyria

Taylor-Type Cortical Dysplasia (FCD Type 2)

- Also due to mTOR pathway mutation

PATHOLOGY

General Features

- Etiology
  - Abnormal differentiation/proliferation of germinal matrix cells
  - Migrational arrest of dysgenetic neurons
- Genetics
  - ~ 50% of TSC cases inherited
    - Autosomal dominant, high but variable penetrance

https://CafePezeshki.IR

  - De novo: Spontaneous mutation/germline mosaicism (60-85%)
  - Mutations in TSC tumor suppressor genes cause activation of mTOR protein → ↑ protein synthesis + cell proliferation
    - 2 distinct loci: *TSC1* (9q34) encodes "hamartin"; *TSC2* (16p13.3) encodes "tuberin"
- Associated abnormalities
  - Renal: Angiomyolipoma and cysts (40-80%)
  - Cardiac: Rhabdomyomas (50-65%); majority involute over time
  - Lung: Cystic lymphangiomyomatosis/fibrosis
  - Solid organs: Adenomas, leiomyomas
  - Skin: Ash leaf spots (majority), including scalp/hair; facial angiofibromas; shagreen patches
  - Extremities: Subungual fibromas (15-20%), cystic bone lesions, undulating periosteal new bone formation
  - Ocular: "Giant drusen" (50%), retinal astrocytomas (which may regress)
  - Dental pitting of permanent teeth in most adults

Staging, Grading, & Classification

- SEGA: WHO grade I

Gross Pathologic & Surgical Features

- Firm cortical masses ("tubers") with dimpling ("potato eye")

Microscopic Features

- Cortical dysplasia with balloon cells, dysmorphic neurons
- Myelin loss, vacuolation, and gliosis

CLINICAL ISSUES

Presentation

- Most common signs/symptoms
  - Neurologic manifestations most frequent (85%), major cause of morbidity/mortality
  - Classic clinical triad
    - Facial angiofibromas (90%), mental retardation (50-80%), seizures (Sz) (80-90%)
      - All 3 ("epiloia"): 30%
- Clinical profile
  - Sz (infantile spasms in very young), facial angiofibroma, hypopigmented skin lesions, mental retardation
  - Infant/toddler: Infantile spasms (20-30%), autism → bad prognosis
    - Infantile spasms occur before development of facial lesions, shagreen patches
  - Diagnostic criteria: 2 major or 1 major plus 2 minor
    - Major: Facial angiofibroma/forehead plaque, sub-/periungual fibroma, ≥ 3 hypomelanotic macules, shagreen patch, multiple retinal nodular hamartomas, cortical tuber, SEN, SEGA, cardiac rhabdomyoma, lymphangioleiomyomatosis, renal angiomyolipoma
    - Minor: Dental enamel pits, hamartomatous rectal polyps, bone cysts, cerebral WM radial migration lines (> 3 = major sign), gingival fibromas, nonrenal hamartoma, retinal achromic patch, confetti skin lesions, multiple renal cysts

Demographics

- Age
  - Diagnosed at any age
    - 1st year of life if infantile spasms or surveillance for positive family history
    - Child: Autistic-like behavior, mental retardation, seizures, or skin lesions
    - Adult diagnoses reported with demonstration of symptomatic SEGA on brain imaging
- Epidemiology
  - 1:6,000 live births

Treatment

- Surveillance MR every 1-3 years during childhood/adolescence
- Treat seizures: Infantile spasms respond to vigabatrin
- Resect isolated tubers if seizure focus or if able to identify seizure focus among many tubers
- SEGAs resected if obstructing foramen of Monro
- Oral rapamycin (inhibitor of mTOR protein signaling pathway) reported to cause regression of SEGA

DIAGNOSTIC CHECKLIST

Image Interpretation Pearls

- FLAIR and T1 MT most sensitive sequences for diagnosis
- T1WI readily documents early WM abnormalities (premyelin maturation)
- SEN differs from SEGA based on size
  - SEN < 1.3 cm
  - SEGA > 1.3 cm

SELECTED REFERENCES

1. Manoukian SB et al: Comprehensive imaging manifestations of tuberous sclerosis. AJR Am J Roentgenol. 204(5):933-43, 2015
2. Niwa T et al: Age-related changes of susceptibility-weighted imaging in subependymal nodules of neonates and children with tuberous sclerosis complex. Brain Dev. ePub, 2015
3. Sarnat HB et al: Infantile tauopathies: Hemimegalencephaly; tuberous sclerosis complex; focal cortical dysplasia 2; ganglioglioma. Brain Dev. ePub, 2014
4. Crino PB: Evolving neurobiology of tuberous sclerosis complex. Acta Neuropathol. 125(3):317-32, 2013
5. Wong M: Mammalian target of rapamycin (mTOR) pathways in neurological diseases. Biomed J. 36(2):40-50, 2013
6. Baskin HJ Jr: The pathogenesis and imaging of the tuberous sclerosis complex. Pediatr Radiol. 38(9):936-52, 2008
7. Luat AF et al: Neuroimaging in tuberous sclerosis complex. Curr Opin Neurol. 20(2):142-50, 2007
8. Makki MI et al: Characteristics of abnormal diffusivity in normal-appearing white matter investigated with diffusion tensor MR imaging in tuberous sclerosis complex. AJNR Am J Neuroradiol. 28(9):1662-7, 2007
9. Jansen FE et al: Diffusion-weighted magnetic resonance imaging and identification of the epileptogenic tuber in patients with tuberous sclerosis. Arch Neurol. 60(11):1580-4, 2003
10. Christophe C et al: MRI spectrum of cortical malformations in tuberous sclerosis complex. Brain Dev. 22(8):487-93, 2000
11. Baron Y et al: MR imaging of tuberous sclerosis in neonates and young infants. AJNR Am J Neuroradiol. 20(5):907-16, 1999
12. Griffiths PD et al: White matter abnormalities in tuberous sclerosis complex. Acta Radiol. 39(5):482-6, 1998

https://CafePezeshki.IR

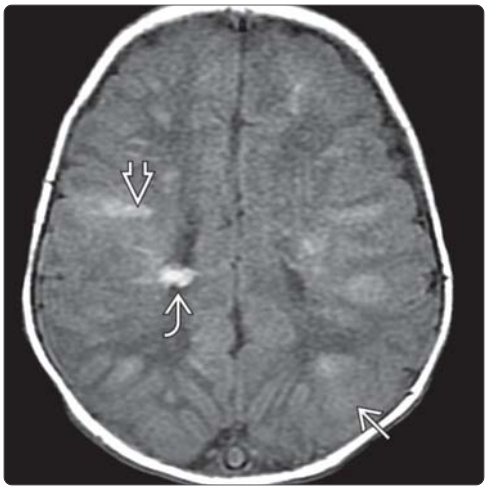

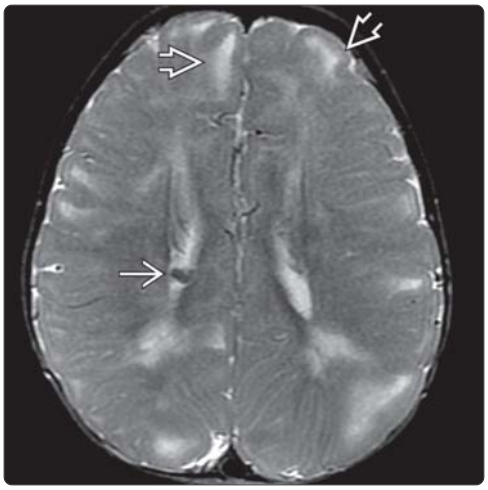

(Left) *Axial T1WI MR in a 13 day old nicely demonstrates multiple T1-bright subcortical tubers ⇨, WM radial migration lines ⇨, and a hyperintense subependymal nodule (SEN) ⇨. The unaffected, unmyelinated WM is hypointense.* **(Right)** *Axial T2WI MR in the same patient at 1 year of age shows T2-hypointense SEN ⇨ and multiple T2-bright tubers. Some abnormalities evident on the prior scan are not appreciated; some tubers not previously evident ⇨ are now seen.*

(Left) *Axial T2WI MR in a 1 month old shows multiple T2-hypointense SENs ⇨ originating from the walls of the lateral ventricles. The cortex of the right frontal lobe ⇨ is thickened and probably diffusely dysplastic.* **(Right)** *Axial NECT of a different patient demonstrates a calcified SEN ⇨ along the anterior margin of the atrium of the left lateral ventricle. A hypodense, probably cystic tuber ⇨ is appreciated in the inferior left frontal lobe.*

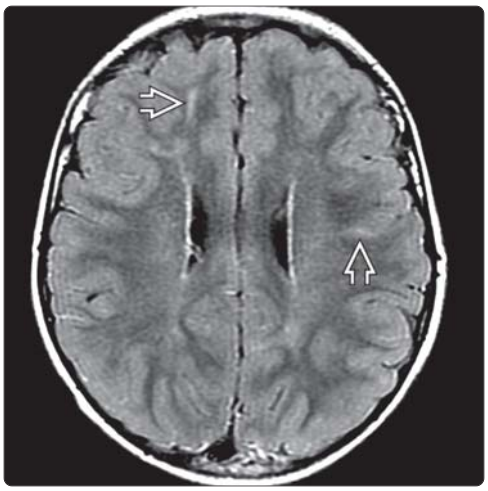

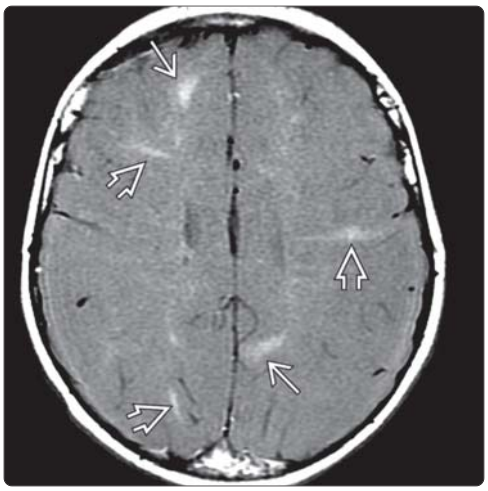

(Left) *Axial FLAIR MR shows multiple ill-defined, hyperintense bands ⇨ extending radially from the cortex to the lateral ventricle in this 6-year-old child.* **(Right)** *Axial T1WI MR with magnetization transfer (MT) in the same patient demonstrates multiple T1-bright lesions pathognomonic for subcortical tubers ⇨ and radial migration lines ⇨. The diagnosis of TS is much more easily and confidently made with the T1 with MT images than with the FLAIR images.*

https://CafePezeshki.IR

KEY FACTS

TERMINOLOGY

- Synonyms: Sturge-Weber-Dimitri, encephalotrigeminal angiomatosis

IMAGING

- Imaging features are pial angioma with sequelae of chronic venous ischemia
  - Pial angiomatosis unilateral (80%), bilateral (20%)
  - Cortical Ca++, atrophy, and enlarged ipsilateral choroid plexus
  - "Tram-track" calcification in cortex (not angioma)
- Early: Transient hyperperfusion → "accelerated" myelin maturation
- Late: Increased signal in region of gliosis and decreased cortical signal in regions of calcification
- Early: Serpentine leptomeningeal enhancement, pial angiomatosis of subarachnoid space
- SWI delineates enlarged, tortuous medullary white matter (WM) veins

PATHOLOGY

- Somatic mutation of *GNAQ* causes Sturge-Weber Syndrom (SWS) and nonsyndromic "port-wine" stains

CLINICAL ISSUES

- "Port-wine" stain, seizures, hemiparesis
- Rare: 1:20,000-50,000
- ↑ extent of lobar involvement and atrophy leading to increased likelihood of seizures
- Seizures cause further brain injury

DIAGNOSTIC CHECKLIST

- FLAIR C+ most sensitive sequence to detect pial angioma (especially in infancy)
- T2 hypointensity of white matter underlying angioma is clue to early diagnosis
- Identification of retinal angioma critical in subtle/early cases

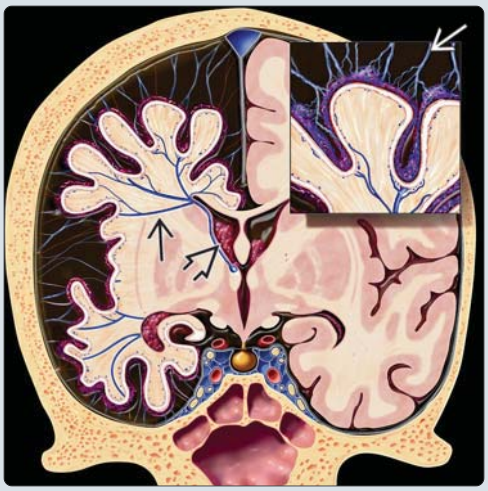

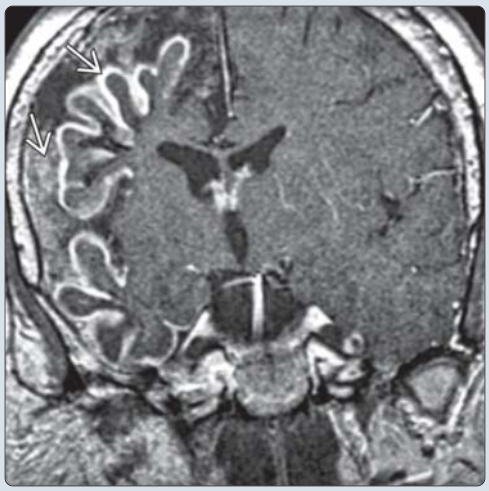

(Left) *Coronal graphic shows extensive pial angiomatosis surrounding affected gyri, prominent deep medullary collaterals shunt venous blood to deep system, enlarged ipsilateral choroid plexus, and atrophy of the right cerebral hemisphere.* **(Right)** *Coronal T1WI C+ MR shows extensive serpentine enhancement of thickened pia (pial angiomatosis) and enlarged subarachnoid space over the right cerebral hemisphere. Severe right-sided hemiatrophy is evident.*

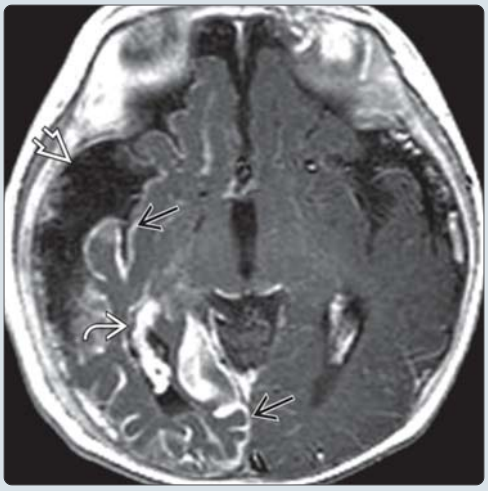

(Left) *Axial T1 C+ MR shows classic Sturge-Weber syndrome (SWS) with atrophy of the right hemisphere, enlargement of the ipsilateral choroid plexus, and an extensive pial angioma covering almost the entire surface of the hemisphere.* **(Right)** *More cephalad T1 C+ scan in the same patient shows similar findings. On this image, a cluster of dilated vessels in the subarachnoid space is also visible.*

https://CafePezeshki.IR

TERMINOLOGY

Abbreviations

- Sturge-Weber syndrome (SWS)

Synonyms

- Sturge-Weber-Dimitri, encephalotrigeminal angiomatosis

Definitions

- Usually sporadic congenital (but not inherited) malformation in which fetal cortical veins fail to develop normally
  - Imaging features are sequelae of progressive venous occlusion and chronic venous ischemia

IMAGING

General Features

- Best diagnostic clue
  - Cortical Ca++, atrophy, and enlarged ipsilateral choroid plexus
- Location
  - Pial angiomatosis unilateral (80%) or bilateral (20%)
  - Occipital > parietal > frontal/temporal lobes > diencephalon/midbrain > cerebellum

Radiographic Findings

- Radiography
  - "Tram-track" calcification

CT Findings

- NECT
  - Gyral/subcortical white matter (WM) Ca++
    - Ca++ not in leptomeningeal angioma
    - Progressive, generally posterior to anterior
  - Late
    - Cerebral atrophy
    - Hyperpneumatization of paranasal sinuses
    - Thick diploe
- CECT
  - Serpentine leptomeningeal enhancement
  - Ipsilateral choroid plexus enlargement usual
    - Choroidal fissure if frontal involvement
    - Trigonal glomus if posterior involvement

MR Findings

- T1WI
  - Early: ↑ WM volume subjacent to pial angiomatosis
  - Late: Atrophy of WM and gray matter
- T2WI
  - Early: Transient hyperperfusion → "accelerated" myelin maturation
  - Late: Increased T2 signal in region of gliosis and decreased cortical signal in regions of calcification
- FLAIR
  - Late: Gliosis in involved lobes
- T2* GRE
  - "Tram-track" gyral calcifications
  - SWI delineates enlarged, tortuous medullary WM veins
- DWI
  - Restricted diffusion in acute ischemia
- T1WI C+
  - Early: Serpentine leptomeningeal enhancement, pial angiomatosis of subarachnoid space
    - Amount of CE increases if MR performed during ictal period; mimics disease progression
  - Late: "Burnt out" → decreased pial enhancement, increased cortical/subcortical Ca++; atrophy
  - Engorged, enhancing choroid plexus
  - Susceptibility weighted imaging (SWI) superior to T1 C+ for identification of enlarged transmantle and periventricular veins
- MRA
  - Rare high-flow arteriovenous malformations
- MRV
  - Progressive sinovenous occlusion
    - Lack of superficial cortical veins
    - ↑ prominence deep collateral (medullary/subependymal) veins
- MRS
  - ↑ choline, ↓ NAA in affected areas
- Fat saturation: Orbital enhancement > 50%, best seen with T1 C+ fat saturation
  - Choroidal angioma, periorbital soft tissues, bony orbit, and frontal bone
- Susceptibility-weighted imaging: Useful for detection of cortical Ca++

Ultrasonographic Findings

- Pulsed Doppler
  - ↓ middle cerebral artery velocity

Angiographic Findings

- Conventional
  - Pial blush, rare arteriovenous malformation
  - Findings mostly venous: Paucity of normal cortical veins, extensive medullary and deep collaterals

Nuclear Medicine Findings

- PET
  - Progressive hypoperfusion, progressive glucose hypometabolism
- SPECT: Transient hyperperfusion (early), hypoperfusion (late)
  - Pattern inconsistent; may be smaller or larger than abnormality detected on CT/MR

Imaging Recommendations

- Best imaging tool
  - Enhanced MR
- Protocol advice
  - NECT to evaluate for calcification (may be more extensive than recognized on MR)
  - MR with contrast (assess extent, uni-/bilaterality, orbital involvement)
    - Contrast-enhanced FLAIR improves conspicuity of leptomeningeal angiomatosis
    - Perfusion may predict progression

DIFFERENTIAL DIAGNOSIS

Other Vascular Phakomatoses (Neurocutaneous Syndromes)

- Blue rubber bleb nevus syndrome

https://CafePezeshki.IR

- Multiple small, cutaneous venous malformations plus intracranial developmental venous anomalies
- Wyburn-Mason syndrome
  - Facial vascular nevus; visual pathway &/or brain arteriovenous malformation (AVM)
- Klippel-Trenaunay-Weber syndrome
  - Osseous/soft tissue hypertrophy, extremity vascular malformations
  - May be combined with some features of SWS
- PHACES
  - **P**osterior fossa malformations, **h**emangiomas, **a**rterial anomalies, **c**oarctation of aorta, **c**ardiac, **e**ye, and **s**ternal anomalies
- Meningioangiomatosis
  - Ca++ common; variable leptomeningeal enhancement; atrophy usually absent
  - May invade brain through Virchow-Robin perivascular spaces

Leptomeningeal Enhancement

- Meningitis, leptomeningeal metastases, and leukemia; encephalocraniocutaneous lipomatosis

PATHOLOGY

General Features

- Etiology
  - Somatic mutation of *GNAQ* causes SWS and nonsyndromic "port-wine" stains
  - Persistent fetal vasculature → deep venous occlusion/stasis → anoxic cortex
- Genetics
  - Usually sporadic: Probable somatic mutation or cutaneous mosaicism
    - Fibronectin (found in SWS "port-wine"-derived fibroblasts and SWS surgical brain samples) regulates angiogenesis and vasculogenesis
  - Very rarely familial but occasionally with other vascular phakomatosis
- Associated abnormalities
  - 50% have extracranial "port-wine" stains (torso or extremities), so evaluate for other vascular phakomatoses
- Upper facial nevus flammeus ± visceral angiomatosis
- Embryology
  - 4-8 weeks: Embryonic cortical veins fail to coalesce and develop → persistent primordial vessels
  - Visual cortex adjacent to optic vesicle and upper fetal face

Staging, Grading, & Classification

- Roach scale
  - Type 1: Facial, choroid + leptomeningeal
  - Type 2: Facial only, ± glaucoma
  - Type 3: Leptomeningeal angioma only (5% of all)

Microscopic Features

- Pial angioma = multiple, thin-walled vessels in enlarged sulci
- Cortical atrophy, Ca++
- Occasional underlying cortical dysplasia

CLINICAL ISSUES

Presentation

- Most common signs/symptoms
  - Upper facial nevus flammeus ("port-wine" stain) (98%), ± V2, V3
  - Eye findings especially with upper and lower lid nevus flammeus
    - Choroidal angioma (70%) → increased intraocular pressure/congenital glaucoma → buphthalmos
    - Retinal telangiectatic vessels, scleral angioma, iris heterochromia
  - Ipsilateral gingival hemangioma frequently affects maxilla or mandible
  - Seizures (75-90%), hemiparesis (30-66%)
  - Stroke-like episodes, neurological deficit, migraines
- Clinical profile
  - "Port-wine" stain, seizures, hemiparesis

Demographics

- Age
  - Facial lesion visible at birth
    - Pial angiomatosis may be occult if no facial lesion and no seizures to prompt imaging
  - Seizures develop in 1st year of life
    - Infantile spasms → tonic/clonic, myoclonic
- Epidemiology
  - Rare: 1:20,000-50,000

Natural History & Prognosis

- ↑ extent of lobar involvement and atrophy leading to increased likelihood of seizures
- Seizures cause further brain injury
- Progressive hemiparesis (30%), homonymous hemianopsia (2%)

Treatment

- Aggressive seizure management, ± resect affected lobes (hemisphere)
- Low-dose aspirin may decrease frequency of stroke-like episodes

DIAGNOSTIC CHECKLIST

Consider

- Child with facial nevus flammeus who reaches 2 years of age with normal neurological and MR exams probably does not have brain involvement

Image Interpretation Pearls

- FLAIR C+ most sensitive sequence to detect leptomeningeal angioma, especially in infancy

SELECTED REFERENCES

1. Dutkiewicz AS et al: A prospective study of risk for Sturge-Weber syndrome in children with upper facial port-wine stain. J Am Acad Dermatol. 72(3):473-80, 2015
2. Tripathi AK et al: Sturge-Weber syndrome: oral and extra-oral manifestations. BMJ Case Rep. 2015, 2015
3. Nakashima M et al: The somatic GNAQ mutation c.548G>A (p.R183Q) is consistently found in Sturge-Weber syndrome. J Hum Genet. 59(12):691-3, 2014
4. Ragupathi S et al: Sturge-Weber syndrome: CT and MRI illustrations. BMJ Case Rep. 2014, 2014

https://CafePezeshki.IR

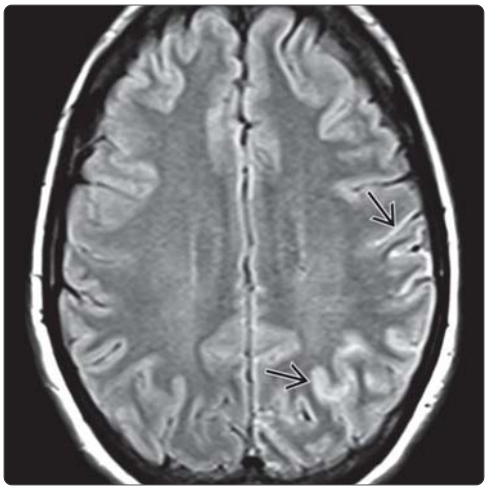

(Left) *Axial FLAIR in a 25-year-old female with a left-sided "port-wine" stain shows hyperintensity in the left parietooccipital sulci ("ivy" sign).* **(Right)** *Axial T1 C+ FS scan in the same patient shows an extensive pial angioma. Note the enlargement of the ipsilateral choroid plexus.*

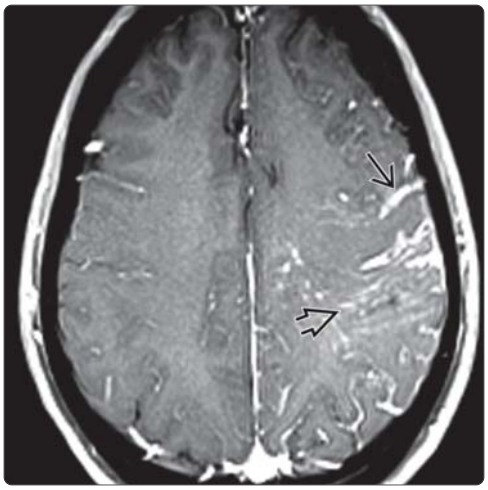

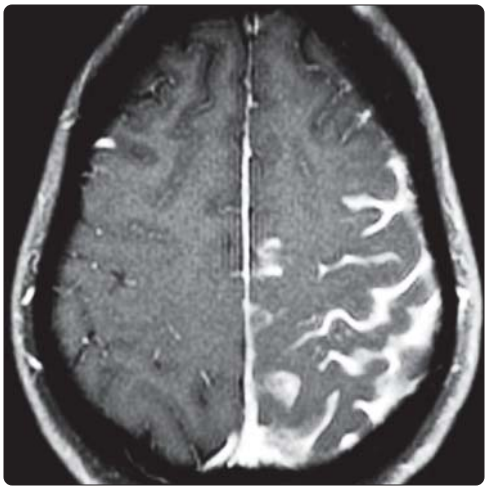

(Left) *More cephalad T1 C+ FS in the same patient shows the enhancing pial angioma filling the enlarged sulci. Also note the enlarged collateral medullary white matter veins that are draining the affected brain.* **(Right)** *T1 C+ FS scan in the same patient shows the enlarged convexity sulci are entirely filled with the intensely enhancing pial angioma.*

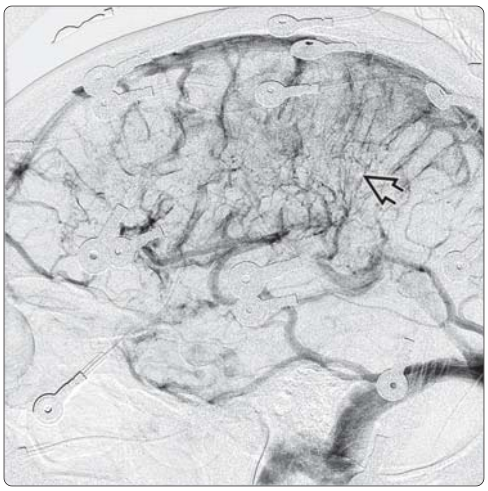

(Left) *Axial T2* SWI MIP in the same patient shows the enlarged, tortuous medullary white matter veins that drain centrally into enlarged subependymal veins.* **(Right)** *Lateral DSA, venous phase, of the left internal carotid angiogram performed as part of a Wada test for language localization shows a paucity of normal cortical veins with a prolonged vascular "blush" caused by contrast stasis in multiple enlarged medullary veins.*

https://CafePezeshki.IR

KEY FACTS

TERMINOLOGY

- Benign hamartomatous cortical, subcortical white matter (WM) lesion with leptomeningeal vascular malformation

IMAGING

- Cortical/subcortical WM mass characterized by calcification, enhancing meningovascular proliferation
  - 50% involve cortex (frontal, temporal lobes most common)
  - ~ 90% involve subcortical WM
  - NECT: Linear, gyriform, or nodular Ca++
- MR
  - T1WI: Cortex iso-, WM hypointense
  - T2/FLAIR: Cortex hypointense, WM hyperintense
  - T1C+: Slight gyriform enhancement

TOP DIFFERENTIAL DIAGNOSES

- Meningioma
- Oligodendroglioma
- Sturge-Weber disease
- Other: DNET, granuloma, parasites, ganglioglioma

PATHOLOGY

- Uncertain etiology
  - Hamartoma, meningioma invading brain, or vascular malformation
  - Neurofibromatosis (particularly NF2) in 50%
- Gross appearance
  - Vascular-appearing gyriform mass in cortex, subcortical WM
- Microscopic
  - Proliferation of meningothelial cells, irregularly branched blood in both cortex, subcortical WM
  - No malignant degeneration

CLINICAL ISSUES

- Gross total resection for treatment of seizure disorder; excellent prognosis with excision

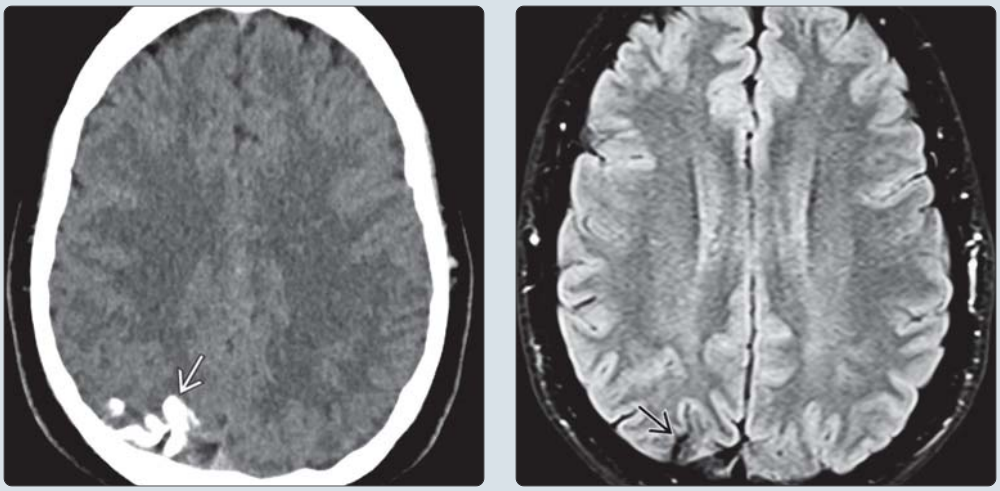

(Left) *Axial NECT scan in a 33-year-old male with longstanding seizures shows a calcified, gyriform mass in the high right posterior parietal lobe* ➡. **(Right)** *Axial FLAIR in the same patient shows the cortical mass is hypointense* ➡.

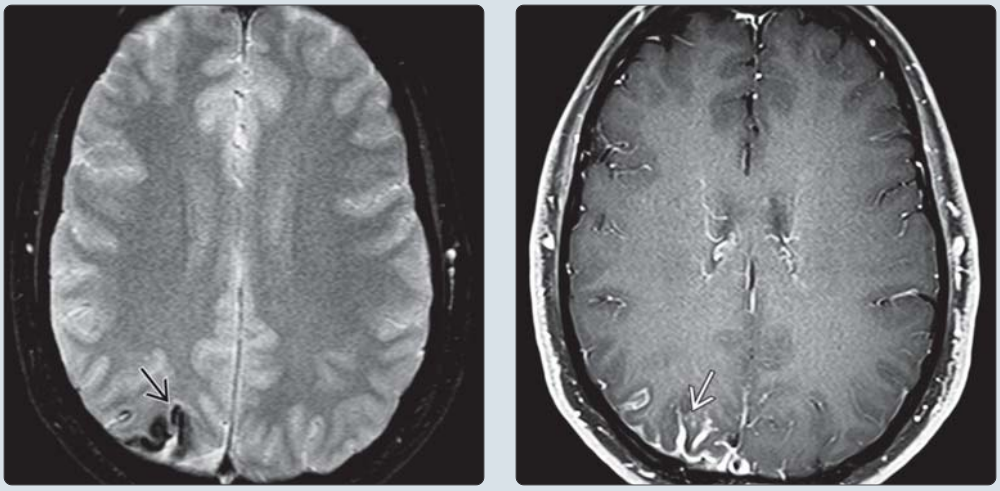

(Left) *T2* GRE shows blooming* ➡ *of the gyriform calcification and cortex.* **(Right)** *Axial T1 C+ FS MR shows serpentine gyriform enhancement of the mass* ➡. *There were no other lesions seen and no cutaneous abnormalities. This is a case of presumed (not surgically-proven) meningioangiomatosis.*

https://CafePezeshki.IR

TERMINOLOGY

Definitions

- Benign hamartomatous cortical, subcortical white matter (WM) lesion with leptomeningeal vascular proliferation

IMAGING

General Features

- Best diagnostic clue
  - Cortical/subcortical WM mass characterized by calcification, enhancing meningovascular proliferation
- Location
  - ~ 90% involve subcortical WM
  - 50% involve cortex (frontal, temporal lobes most common)
- Size
  - 1-4 cm (mean: ~ 2.5 cm)

CT Findings

- NECT
  - Solitary hyperdense, often calcified mass
    - Ca++ linear, gyriform, or nodular
  - Occasional: Hemorrhage and cysts
  - Little or no observable mass effect
- CECT
  - Little or no enhancement

MR Findings

- T1WI
  - Cortical component isointense to gray matter (GM)
    - WM component hypointense
- T2WI
  - Cortex hypointense, WM hyperintense
    - May demonstrate areas of signal void (Ca++)
    - ± hyperintense cysts
- FLAIR
  - Cortex hypointense, WM hyperintense
- T2* GRE
  - Hypointense ("blooms")
- T1WI C+
  - Cortex: Slight enhancement (gyriform)
  - WM: No enhancement

Imaging Recommendations

- Protocol advice
  - NECT to look for calcium; MR for signal intensity, enhancement characteristics

DIFFERENTIAL DIAGNOSIS

Lesions With Calcification and Cysts

- Meningioma
- Oligodendroglioma
- Granulomatous meningitis
  - Sarcoid, tuberculosis
- Parasitic diseases (cysticercosis)
- Ganglioglioma
- Sturge-Weber disease
- Dysembryoplastic neuroepithelial tumor

PATHOLOGY

General Features

- Etiology
  - Uncertain
    - Hamartoma, meningioma invading brain, or vascular malformation
- Associated abnormalities
  - Neurofibromatosis (NF) found in 1/2 of patients (particularly neurofibromatosis type 2 [NF2])
  - Meningioma (25%)

Gross Pathologic & Surgical Features

- Vascular-appearing cortical/subcortical mass
  - Serpentine pial vessels overlying lesion
- Psammomatous or serpentine Ca++

Microscopic Features

- Proliferation of meningothelial cells, irregularly branched blood in both cortex, subcortical WM
- Does not undergo malignant degeneration

CLINICAL ISSUES

Presentation

- Most common signs/symptoms
  - Intractable seizures, headaches
  - Often asymptomatic, found incidentally (especially with NF)
- Clinical profile
  - Children, young adults ± seizure disorder

Treatment

- Generally solitary, slow-growing
- Gross total resection for treatment of seizure disorder; excellent prognosis with excision

DIAGNOSTIC CHECKLIST

Image Interpretation Pearls

- Calcified cortical/subcortical WM mass ± gyriform enhancement

SELECTED REFERENCES

1. Aw-Zoretic J et al: Teaching NeuroImages: Meningioangiomatosis. Neurology. 84(2):e9-e10, 2015
2. Grabowski MM et al: Focal cortical dysplasia in meningioangiomatosis. Clin Neuropathol. 34(2):76-82, 2015
3. Sun Z et al: Three cases of sporadic meningioangiomatosis with different imaging appearances: case report and review of the literature. World J Surg Oncol. 13(1):89, 2015
4. Zhang C et al: Sporadic meningioangiomatosis with and without meningioma: analysis of clinical differences and risk factors for poor seizure outcomes. Acta Neurochir (Wien). 157(5):841-53, 2015
5. Li P et al: Multicystic meningioangiomatosis. BMC Neurol. 14:32, 2014
6. Jeon TY et al: Sporadic meningioangiomatosis: imaging findings with histopathologic correlations in seven patients. Neuroradiology. 55(12):1439-46, 2013
7. Alexiou GA et al: Meningioangiomatosis in a 5-year-old boy presenting with intractable seizures. Pediatr Neurosurg. 47(2):143-6, 2011
8. Kim NR et al: Allelic loss on chromosomes 1p32, 9p21, 13q14, 16q22, 17p, and 22q12 in meningiomas associated with meningioangiomatosis and pure meningioangiomatosis. J Neurooncol. 94(3):425-30, 2009
9. Kim NR et al: Childhood meningiomas associated with meningioangiomatosis: report of five cases and literature review. Neuropathol Appl Neurobiol. 28(1):48-56, 2002

https://CafePezeshki.IR

KEY FACTS

TERMINOLOGY

- Basal cell nevus syndrome (BCNS), nevoid basal cell carcinoma syndrome (NBCCS), Gorlin syndrome, Gorlin-Goltz syndrome
- BCNS: Hereditary tumor syndrome characterized by multiple basal cell epitheliomas (BCE)/basal cell carcinomas (BCC), odontogenic keratocysts, palmoplantar pits, dural Ca++, ± medulloblastoma

IMAGING

- Multiple jaw cysts, prominent dural Ca++, macrocephaly
- Keratocystic odontogenic tumors (KOT) in 80-90%
  - Most patients with BCNS have KOT; 5% of patients with KOT have BCNS
- Large, uni-/multilocular sharply marginated cysts containing unerupted teeth
- Early Ca++ of falx cerebri, tentorium, periclinoid ligaments (dural bridging), dura, pia, choroid plexus, and basal ganglia

TOP DIFFERENTIAL DIAGNOSES

- Prominent dural calcifications (physiologic, metabolic)
- Maxillary/mandibular cyst(s)
  - Ameloblastoma
  - Dentigerous or aneurysmal bone cyst
  - Cherubism
  - Giant reparative granuloma
  - Odontogenic myxoma
  - Maxillary sinus mucocele

PATHOLOGY

- Desmoplastic medulloblastoma seen in 4-20% (1-2% of patients with medulloblastomas have BCNS)
- Mutation of inactivated tumor suppressor genes *PTCH1*
  - < 2% risk of medulloblastoma
- *SUFU* mutations common in patients without *PTCH1* mutation
  - Risk of medulloblastoma 20x higher than *PTCH1*

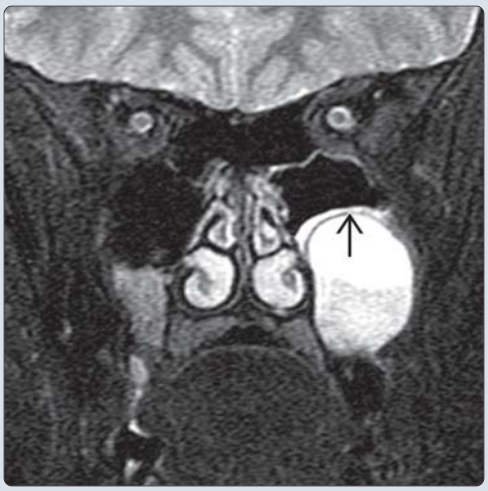

(Left) *Coronal T2WI MR of a classic BCNS shows a large, unilocular, T2-hyperintense cyst arising from the left maxillary alveolar ridge. The cyst bulges into the maxillary sinus, displacing the floor of the sinus and secretions superiorly. Distinguishing a sinus mucous retention cyst from an alveolar ridge/dental cyst is best done on coronal images.* **(Right)** *Coronal T1WI MR shows a T1-hypointense cystic mass. The floor of the sinus is less well characterized than on the coronal T2 image.*

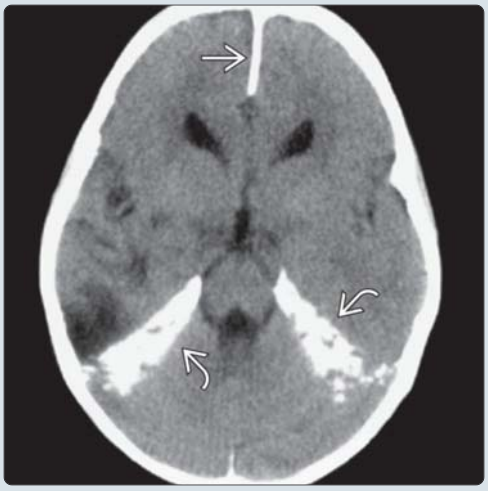

(Left) *Axial NECT of a 16 year old with BCNS reveals extensive lamellar calcifications of the falx cerebri and the tentorium cerebelli. A defect is evident in the right temporal lobe secondary to the resection of a convexity meningioma.* **(Right)** *Axial bone CT demonstrates a well-defined, expansile lesion in the angle of the mandible on the left. At surgery, pathologic exam showed the lesion to be an odontogenic keratocyst.*

https://CafePezeshki.IR

TERMINOLOGY

Abbreviations

- Basal cell nevus syndrome (BCNS)

Synonyms

- Nevoid basal cell carcinoma syndrome (NBCCS), Gorlin syndrome, Gorlin-Goltz syndrome

Definitions

- Hereditary tumor syndrome characterized by multiple basal cell epitheliomas (BCE)/basal cell carcinomas (BCC), keratocystic odontogenic tumors (KOT), palmoplantar pits, dural Ca++, ± medulloblastoma

IMAGING

General Features

- Best diagnostic clue
  - Multiple jaw cysts, prominent dural Ca++, macrocephaly
  - Other skeletal features: Hyperaerated paranasal sinuses, splayed/fused/bifid ribs, kyphoscoliosis, platybasia, Sprengel deformity of scapulae
- Location
  - Cysts: Mandible, maxilla
  - Ca++: Intracranial dura
- Size
  - Variable enlargement of mandible, maxilla

CT Findings

- NECT
  - Keratocystic odontogenic tumors (KOT) in 80-90%
    - Large, uni-/multilocular, sharply marginated cysts containing unerupted teeth
    - Mandible > maxilla
  - Early Ca++ of falx cerebri, tentorium, periclinoid ligaments (dural bridging), dura, pia, choroid plexus, and basal ganglia
  - ± ventriculomegaly
  - ± callosal dysgenesis
  - Cysts of all kinds common
- CECT
  - Look for
    - Desmoplastic medulloblastoma
    - Meningioma
    - Colloid cyst

MR Findings

- T1WI
  - KOT are hypointense to isointense, contain hypointensity representing unerupted tooth
  - Dural Ca++ difficult to observe on MR
  - Look for perineural spread as loss of perineural fat
- T2WI
  - KOT are hyperintense, contain hypointensity representing unerupted tooth
- T1WI C+
  - Cysts may show thin peripheral enhancing rim
  - Look for perineural spread of head and neck BCC using fat-saturated images

Nuclear Medicine Findings

- Bone scan
  - May show ↑ uptake

Imaging Recommendations

- Best imaging tool
  - MR to screen for medulloblastoma (especially if SUFU[+]), cystic jaw lesions
  - CT of face for oral surgery planning
- Protocol advice
  - Low mA 2-3 mm axial CT of face, including mandible, coronal reformats
  - Fat-saturated T2 and T1 C+ to diagnose jaw KOTs, perineural BCC spread

DIFFERENTIAL DIAGNOSIS

Prominent Dural Calcifications

- Physiologic (usually less striking than BCNS)
- Metabolic (hyperparathyroidism, long-term hemodialysis)

Keratocystic Odontogenic Tumors (Maxillary/Mandibular Cysts)

- Ameloblastoma
  - Bubbly appearing, solitary lesion may contain unerupted tooth
  - When large, associated enhancing soft tissue mass nearly always present
  - May have enhancing solid mural nodule
- Dentigerous cyst
  - Unilocular cyst surrounding tooth crown
  - No enhancing soft tissue
- Cherubism
  - Symmetrical cystic fibrous dysplasia of mandible
- Aneurysmal bone cyst
  - Multilocular, multiseptated mass in mandible
  - Enhancing soft tissues inside and outside of bony rim
- Giant reparative granuloma
  - Solitary mass, generally solid, does not contain unerupted tooth
- Odontogenic myxoma
  - Radiolucent areas with bony trabeculations
  - Well- or poorly defined margins, aggressive growth; benign histology
- Miscellaneous maxillary masses
  - Maxillary sinus mucocele: Contains no cysts or septa; smooth expansion of sinus walls
  - Incisor canal cyst: Small; found in midline anterior maxilla, posterior to incisors; water density/intensity
  - Globulomaxillary cyst: Small; located between lateral incisor and canine

PATHOLOGY

General Features

- Etiology
  - PATCHED (*PTCH1*) gene encodes sonic hedgehog (SHH) receptor and tumor suppressor protein defective in BCNS
- Genetics
  - Autosomal dominant: Complete penetrance, variable expression

https://CafePezeshki.IR

- de novo mutations (40%)
  - New mutations ↑ with advanced paternal age
- Mutation of inactivated tumor suppressor genes *PTCH1*
  - < 2% risk of medulloblastoma
- *SUFU* mutations common in patients without *PTCH1* mutation
  - Risk of medulloblastoma 20x higher than *PTCH1*
- Associated abnormalities
  - Neoplasms (mutation inactivated tumor suppressor genes)
    - Rare ameloblastoma and squamous cell cancer
    - Desmoplastic medulloblastoma: Seen in 4-20% (1-2% of patients with medulloblastomas have BCNS)
    - Cardiac, abdominal, and pelvic mesenchymal tumors
- 3x more common in mandible than in maxilla
  - Mainly in premolar and retromolar triangle area
- Usually multiple, small or large, unilocular or multilocular
- May cross midline

Staging, Grading, & Classification

- Need either 2 major or 1 major/2 minor criteria for diagnosis
- Major criteria: > 2 (or 1 < 30 years) basal cell carcinomas; > 10 basal cell nevi; KOT or polyostotic bone cyst; ≥ 3 palmar/plantar pits; lamellar or (< 20 years) falx Ca++; family history
- Minor criteria: Rib or vertebral anomalies, macrocrania/frontal bossing; cardiac or ovarian fibromas; mesenteric cysts; facial clefting (5-13%), hand (long fingers, short 4th metacarpal, polydactyly) or ocular anomalies; bridging of sella turcica, medulloblastoma

Gross Pathologic & Surgical Features

- KOT: Expansile mandible &/or maxillary cysts with unerupted tooth
  - Satellite cyst formation is common; may involve coronoid process
  - Maxillary canine/premolar area > retromolar

Microscopic Features

- KOT: Parakeratinized lining and ↑ epithelial growth factor receptor

CLINICAL ISSUES

Presentation

- Most common signs/symptoms
  - Jaw and maxilla deformity with pain
- Desmoplastic medulloblastoma in boys 2 years and younger (before syndrome apparent)
  - Beware: Irradiation induced ↑ number BCC
- BCE (75%) onset at puberty, resemble nevi or skin tags; BCC by 40 years
- Skin (other): Epidermal (kerato) cysts (55%), milia, fibromas, lipomas
- Palmar and plantar pits (> 85%): Usually noticed after childhood
- Multiple KOT that may fracture or become infected
- Dysmorphic facies, large head/brow, everted mandibular angle, hypertelorism, lip clefts common, macrosomia, tall stature
- Cognition normal if no malformations/tumors and no prior irradiation (mental retardation in 5%)

Demographics

- Age
  - Usually diagnosed during 1st decade of life
    - KOT usually forms before 7 years of age
- Gender
  - No predilection
- Ethnicity
  - No predilection
- Epidemiology
  - 1 in 57,000 (1 in 200 with BCC have syndrome, 1 in 5 if < 19 years old)
  - Most patients with BCNS have KOT; 5% of patients with KOT have BCNS

Natural History & Prognosis

- Develop enormous numbers of basal cell carcinomas
  - Especially fair skin, sun exposure, irradiation
  - Darkly pigmented skin protective, has smaller numbers of BCC

Treatment

- Surgery for KOT; surgery/chemotherapy, avoid radiotherapy for medulloblastoma

DIAGNOSTIC CHECKLIST

Consider

- When precocious dural Ca++ and KOT are detected

Image Interpretation Pearls

- Multiple mandibular cysts containing teeth or parts of teeth

SELECTED REFERENCES

1. Wehner MR et al: Timing of subsequent new tumors in patients who present with Basal cell carcinoma or cutaneous squamous cell carcinoma. JAMA Dermatol. 151(4):382-8, 2015
2. Manjima S et al: Multiple jaw cysts-unveiling the Gorlin-Goltz syndrome. Contemp Clin Dent. 6(Suppl 1):S102-5, 2015
3. Athar M et al: Sonic hedgehog signaling in Basal cell nevus syndrome. Cancer Res. 74(18):4967-75, 2014
4. Smith MJ et al: Germline mutations in SUFU cause Gorlin syndrome-associated childhood medulloblastoma and redefine the risk associated with PTCH1 mutations. J Clin Oncol. 32(36):4155-61, 2014
5. Sartip K et al: Neuroimaging of nevoid basal cell carcinoma syndrome (NBCCS) in children. Pediatr Radiol. 43(5):620-7, 2013
6. Romano M et al: Identification of a novel mutation in the PTCH gene in a patient with Gorlin-Goltz syndrome with unusual ocular disorders. Eur J Ophthalmol. 21(4):516-9, 2011
7. Garrè ML et al: Medulloblastoma variants: age-dependent occurrence and relation to Gorlin syndrome--a new clinical perspective. Clin Cancer Res. 15(7):2463-71, 2009

https://CafePezeshki.IR

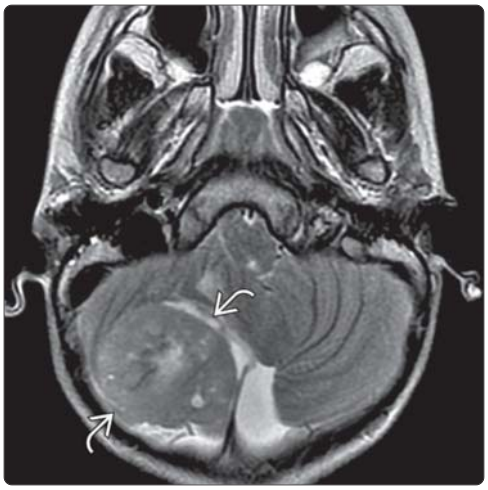

(Left) *Axial T2WI MR in a 3-year-old boy shows a well-defined T2-hypointense mass ➡ in the posterior right cerebellar hemisphere. Only slight edema surrounds the mass, which was proven to be a medulloblastoma at pathology.* **(Right)** *Axial NECT in the same patient, obtained preoperatively, reveals 2 small dural-based calcifications ➡. Such calcifications are not normal in a child of this age and should prompt a work-up for basal cell nevus syndrome (BCNS). BCNS was confirmed with a molecular genetic test.*

(Left) *Axial T1WI C+ FS MR in a 6-year-old child with known BCNS shows a small cystic mass in the anterior left maxillary ridge, consistent with an keratocystic odontogenic tumor. The cyst has a thin, faintly enhancing rim ➡ and an unerupted tooth medially. The MR was performed as a screening test for medulloblastoma.* **(Right)** *Axial T2WI FS MR in the same patient shows moderate hyperintensity of the lesion contents and a hypointense unerupted tooth ➡ medial to the lesion.*

(Left) *Coronal T2WI FS MR reveals a T2-hypointense mass filling the left nasal cavity and extending into ethmoid air cells ➡. This 19 year old with BCNS was radiated for medulloblastoma and developed a radiation-induced rhabdomyosarcoma.* **(Right)** *Coronal T1WI C+ FS MR shows moderate enhancement of the nasal mass, which infiltrates the dura above the roof of the ethmoid air cells ➡. A falx meningioma is also evident ➡.*

https://CafePezeshki.IR

KEY FACTS

TERMINOLOGY

- Hereditary hemorrhagic telangiectasia (HHT)
  - Rendu-Osler-Weber, Osler-Weber-Rendu syndrome
- Autosomal dominant disorder with widely distributed, multisystem angiodysplastic lesions
  - Mucocutaneous telangiectasias with AVMs in visceral organs (primarily lungs, brain, liver)

IMAGING

- Best diagnostic clue
  - Multiple pulmonary (pAVM) or cerebral arteriovenous malformations (cAVM) in patient with recurrent epistaxis
- MR
  - "Blooming" of capillary telangiectasias (SWI > GRE)
    - "Fluffy" enhancement on T1 C+
  - cAVM: Nest ("tangle") of flow voids, gliosis
- Useful: Multislice CT/CTA of lungs and liver

PATHOLOGY

- Genetically heterogeneous disorder caused by mutations in TGF-β/BMP signaling pathway
  - Endoglin (*ENG*) mutations cause HHT1
  - Activin A receptor type II-like 1 (*ACVRL1/ALK1*) mutations cause HHT2
  - *SMAD4* mutations cause the combined Juvenile Polyposis/HHT syndrome
- 3 types of vascular malformations in HHT
  - Most common: Capillary vascular malformation (61%)
    - Tangle of abnormal vessels
    - No shunt, no dilated feeding artery or draining vein
  - Nidus-type AVM: 43%
    - Dilated network of abnormal vessels
    - AV shunting (early draining vein)
  - Direct high-flow AVF: 12%
    - Shunt with absence of intervening nidus between feeding artery, draining vein

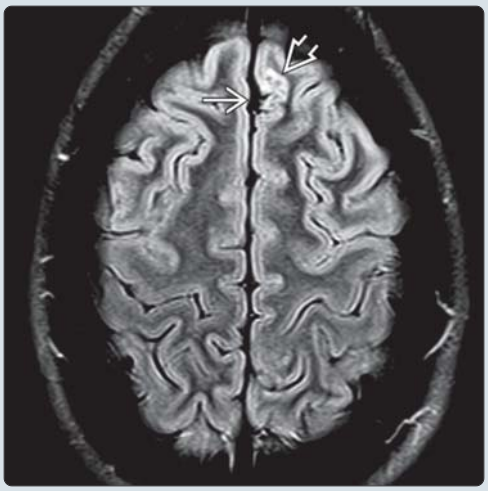

(Left) *Axial FLAIR MR in an 18-year-old male with family history of hereditary hemorrhagic telangiectasia (HHT) was obtained as part of routine screening. A small left medial frontal hyperintensity ⇨ with associated flow voids ⇨ is present.* **(Right)** *Axial T1 C+ MR in the same patient shows the lesion ⇨ enhances intensely.*

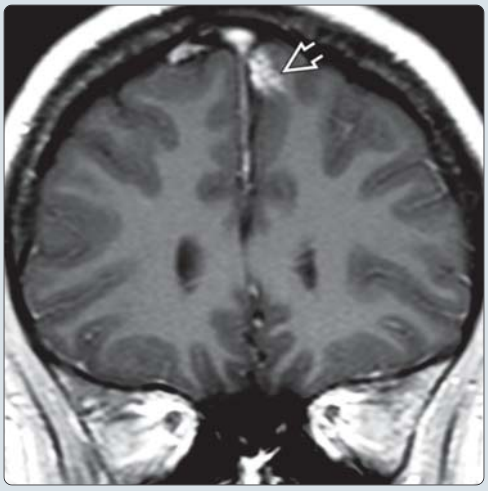

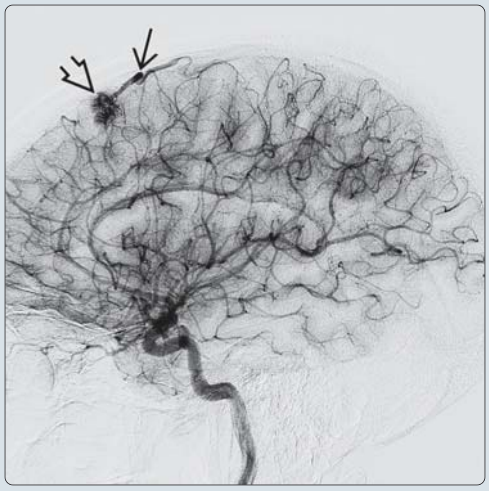

(Left) *Coronal T1 C+ scan in the same patient shows the lesion ⇨ has a somewhat "speckled" appearance.* **(Right)** *Lateral view of the left internal carotid DSA obtained in the same patient shows a small AVM nidus ⇨ with an early draining vein ⇨. Genetic profiling showed ENG mutation.*

https://CafePezeshki.IR

TERMINOLOGY

Abbreviations

- Hereditary hemorrhagic telangiectasia (HHT)

Synonyms

- Rendu-Osler, Rendu-Osler-Weber, Osler-Weber-Rendu syndrome

Definitions

- Autosomal dominant disorder with widely distributed, multisystem angiodysplastic lesions
  - Mucocutaneous telangiectasias and arteriovenous malformations (AVMs) in visceral organs (primarily lungs, brain, liver)

IMAGING

General Features

- Best diagnostic clue
  - Multiple pulmonary (pAVM) or cerebral arteriovenous malformation (cAVM) in patient with recurrent epistaxis
- Location
  - Capillary telangiectasias: Scalp, nasopharynx, orbit
  - Intracranial vascular malformations most often superficially located
- Size
  - Vascular malformations in HHT usually small ("micro-AVMs" or "capillary vascular malformations"), often incidental
- Morphology
  - Dilated tangle of vessels, "blooming" artifacts
- Number
  - Multiple vascular malformations: 44%

CT Findings

- NECT
  - Brain
    - AVM: Isodense serpentine vessels
    - Abscess: Low-density mass, iso-/hyperdense rim
- CECT
  - Brain
    - Strong, uniform, vascular nidus enhancement
    - Ring enhancement of abscesses (late cerebritis, early capsule stage)
    - DVA not rare (4%)
- CTA
  - Demonstrates feeders and draining veins of AVMs, AVFs
  - Visceral evaluation also needed

MR Findings

- T1WI
  - Nidus-type AVM: Flow voids common, ± hemorrhage
  - Capillary vascular malformations, DVA not visualized
- T2WI
  - cAVM: Flow voids ± hemorrhage, gliosis
- FLAIR
  - cAVM: Nest ("tangle") of flow voids, gliosis
- T2* GRE
  - "Blooming" of capillary malformations (SWI > GRE)
- T1WI C+
  - Capillary vascular malformation
    - Subcentimeter "fluffy" blush of enhancement without abnormal vascular dilation
    - Usually supratentorial, superficial
  - Delineates cAVM nidus, feeding arteries, and draining veins
- MRA
  - Demonstrates intermediate to large cAVMs
  - Capillary vascular malformations usually not visualized
- MRV
  - May demonstrate DVA

Angiographic Findings

- Vascular malformations shown in brain and nasal mucosa
  - Only 10-20% > 10 mm

Imaging Recommendations

- Best imaging tool
  - Brain: MR C+, T2* (SWI > GRE)
- Protocol advice
  - Brain: MR C+, T2* (SWI > GRE), MRA
    - Lungs, liver: Multislice CT/CTA useful

DIFFERENTIAL DIAGNOSIS

Nasal Mucosal "Blush"

- Prominent but normal nasal mucosal "blush" can mimic capillary telangiectasia

Multiple Intracranial AVMs Without HHT

- 50% associated with other vascular neurocutaneous syndrome (Wyburn-Mason, etc.)

Multiple Intracranial DVAs

- Less common than in blue rubber bleb nevus syndrome (BRBN)

Multiple Capillary Telangiectasias

- Can be found incidentally without HHT
- Capillary telangiectasias in HHT more common outside brain (e.g., mucosa)

Multiple Cavernous Malformations

- Familial cavernous malformation syndrome

PATHOLOGY

General Features

- Etiology
  - Genetically heterogeneous disorder caused by mutations in TGF-β/BMP signaling pathway
    - TGF-β regulates cell proliferation, differentiation, apoptosis, migration
    - Abnormal TGF-β signal transduction affects
      - Vasculogenesis
      - Angiogenesis
      - Endothelial cell properties
- Genetics
  - Endoglin (*ENG*) mutations cause HHT1
  - Activin A receptor type II-like 1 (*ACVRL1/ALK1*) mutations cause HHT2
    - *ENG, ACVRL1* mutations detected in 85% of HHT cases (roughly = percentages)

https://CafePezeshki.IR

- *SMAD4* mutations cause the combined Juvenile Polyposis/HHT syndrome
- 15% of patients with HHT have no mutation in *ENG, ACVRL1,* or *SMAD4*
  - 1% have missense mutations in bone morphogenetic 9 (*GDF2*) gene

Staging, Grading, & Classification

- Most cAVMs in HHT are low grade (Spetzler-Martin 1 or 2)

Gross Pathologic & Surgical Features

- Multiple telangiectasias of mucosa, dermis, viscera
- 3 types of vascular malformations in HHT
  - Most common: Capillary vascular malformations (61%)
    - Tangle of abnormal vessels but no shunt, no dilated feeding artery or draining vein
  - Nidus-type AVM: 43%
    - Dilated network of abnormal vessels
    - AV shunting (early draining vein)
  - Direct high-flow AVF: 12%
    - Shunt with absence of intervening nidus between feeding artery and draining vein
- Other associated vascular anomalies
  - DVA: 4.3%
  - Aneurysms: 2.4%
  - Cavernous malformation: 1%

Microscopic Features

- Smallest telangiectasias = focal dilatations of postcapillary venules that enlarge and extend through capillaries toward arterioles → AVF/AVM

CLINICAL ISSUES

Presentation

- Most common signs/symptoms
  - Recurrent epistaxis from nasal mucosal telangiectasias
    - 50% have nosebleeds by 10 years, 80-90% by 21 years; 95% lifetime
    - Wide variation in severity
- Other signs/symptoms
  - Telangiectasia locations
    - Lips
    - Mouth
    - Tongue
    - Around nails
- Clinical profile
  - HHT diagnosis based on combination of findings (Shovlin criteria)
    - Mucocutaneous telangiectasias
    - Spontaneous/recurrent episodes of epistaxis
    - Visceral involvement
    - Family history
  - Significant phenotypic variability
    - 70% of patients with pAVMs have HHT
      - Pulmonary, brain AVMs more common in HHT1
      - 5-15% of HHT patients have pAVMs
    - > 50% of patients with multiple cAVMs have HHT
      - 5-13% of HHT patients have cAVMs (usually late in life)
    - 2-17% of HHT patients have hepatic AVMs (depends on kindred)
      - Hepatic AVMs more common in HHT2
- Neurologic symptoms common
  - Intracranial bleed from AVM/AVF
  - TIA, stroke, abscess secondary to pAVMs

Demographics

- Age
  - Epistaxis typically begins by age 10
  - Most HHT patients are symptomatic by age 21
  - Skin lesions appear later (most by age 40)
- Epidemiology
  - Rare: 1-2:10,000

Natural History & Prognosis

- Epistaxis
  - Increases in frequency and severity
- HHT cAVMs have lower bleeding risk than sporadic AVMs
  - Rare cases may regress spontaneously
  - Significant lifetime risk of brain abscess or stroke if pAVM present
- GI bleeding limits lifespan when < 50 years old
  - Many require multiple transfusions and endoscopies
  - Heart failure with hepatic AVM: Poor prognosis

Treatment

- pAVMs: Excellent results with embolization
- cAVMs: Embolization vs. radiosurgery depending on size and location
- Mucosal telangiectasias (nose, GI tract): Laser coagulation
- Prophylactic antibiotics prior to all dental work if pAVM present
- IV iron useful if oral iron fails to maintain satisfactory level

DIAGNOSTIC CHECKLIST

Consider

- Screening brain MR in family members of HHT patients

Image Interpretation Pearls

- Most common cerebral vascular malformation in HHT patients = AVM (not telangiectasia)
- Brain abscess and ischemia uncommon but serious complication in HHT patients with pAVMs

SELECTED REFERENCES

1. Kim H et al: Hemorrhage rates from brain arteriovenous malformation in patients with hereditary hemorrhagic telangiectasia. Stroke. 46(5):1362-4, 2015
2. Krings T et al: Neurovascular Manifestations in Hereditary Hemorrhagic Telangiectasia: Imaging Features and Genotype-Phenotype Correlations. AJNR Am J Neuroradiol. ePub, 2015
3. McDonald J et al: Hereditary hemorrhagic telangiectasia: genetics and molecular diagnostics in a new era. Front Genet. 6:1, 2015
4. Shovlin CL: Circulatory contributors to the phenotype in hereditary hemorrhagic telangiectasia. Front Genet. 6:101, 2015
5. Tørring PM et al: Global gene expression profiling of telangiectasial tissue from patients with hereditary hemorrhagic telangiectasia. Microvasc Res. 99:118-126, 2015
6. Woodall MN et al: Cerebral vascular malformations in hereditary hemorrhagic telangiectasia. J Neurosurg. 120(1):87-92, 2014

https://CafePezeshki.IR

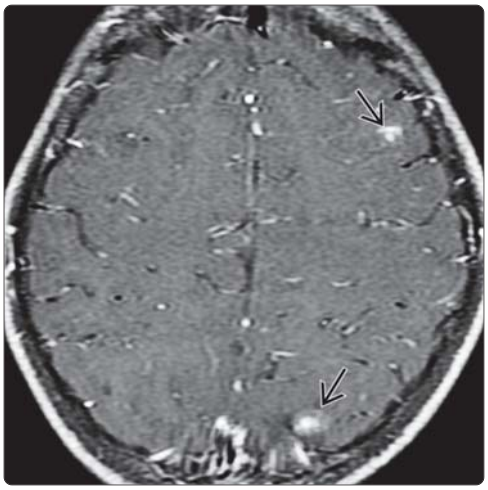

(Left) *A screening T1 C+ FS 3T MR scan was obtained in this 11-year-old female with a family history of HHT shows 2 tiny "fluffy" foci of enhancement consistent with capillary vascular malformations (sometimes called "micro-AVMS").* **(Right)** *More cephalad T1 C+ FS scan in the same patient shows 2 additional micro-AVMS. Sporadic multiple AVMs are uncommon. At least 50% of such cases are eventually proven to have HHT (usually HHT1).*

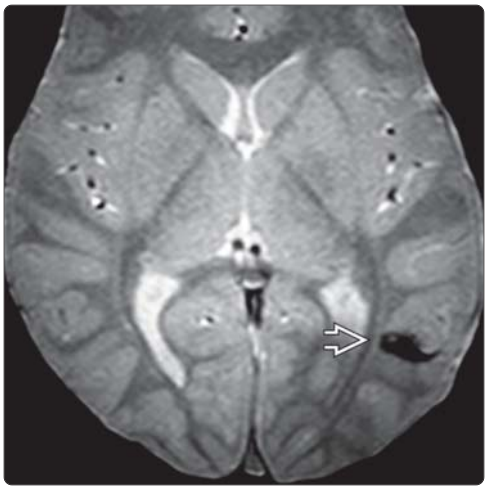

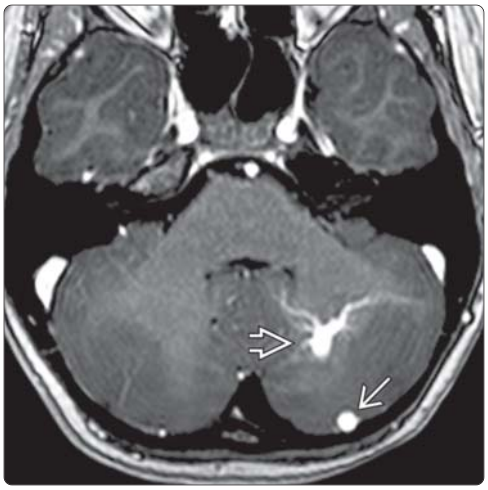

(Left) *Axial T2* GRE MR of a child with diagnosed HHT shows hypointensity in the left parietooccipital region due to susceptibility effects of a pial telangiectasia. Similar lesions were seen in the right cerebellum and left middle temporal sulci (not shown).* **(Right)** *Axial T1WI C+ SPGR MR in a child with diagnosed HHT shows a left cerebellar DVA draining into a posterior pial vein. Although not specific, DVAs are more common in HHT than in the general population.*

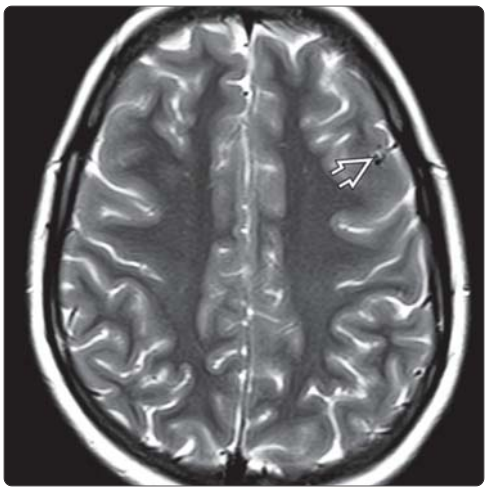

(Left) *Axial T2WI in a 16-year-old female with HHT1 who had a negative screening MR at age 9 shows a small round and linear "flow void" in the left frontal lobe.* **(Right)** *Axial CTA was obtained in the same patient. This shows a well-delineated tubular structure suggesting a vascular malformation. A pial arteriovenous fistula was found and resected at surgery. AVFs are the least common of the three major types of cerebral vascular malformations associated with HHT1.*

https://CafePezeshki.IR

KEY FACTS

TERMINOLOGY

- Rare congenital neurocutaneous syndrome characterized by ipsilateral scalp, eye, and brain abnormalities

IMAGING

- Unilateral cerebral hemispheric atrophy ipsilateral to scalp lipoma
- Intracranial (IC) lipomas in ~ 2 out of 3 patients
- Spinal lipomas/lipomatosis frequent; cervicothoracic > lumbar
- Polymicrogyria of temporal, parietal, &/or occipital lobes
- ± diffuse, ipsilateral leptomeningeal enhancement
- Scalp/intracranial lipomas

TOP DIFFERENTIAL DIAGNOSES

- Sturge-Weber syndrome
- Oculocerebrocutaneous syndrome
- Epidermal nevus syndrome
  - Ipsilateral epidermal nevus, hemimegalencephaly, facial lipoma, and hemihypertrophy
- Proteus syndrome
  - Progressive asymmetric, bilateral trunk/limb hypertrophy

PATHOLOGY

- Defect in development of mesenchymal tissues

CLINICAL ISSUES

- Nevus psiloliparus: Sharply demarcated focus of scalp alopecia overlying scalp lipoma
- Hallmark of encephalocraniocutaneous lipomatosis (ECCL)
- Newborn with nevus psiloliparus, scleral mass, and periocular papules
- Rare; ~ 54 reported cases (likely underreported)

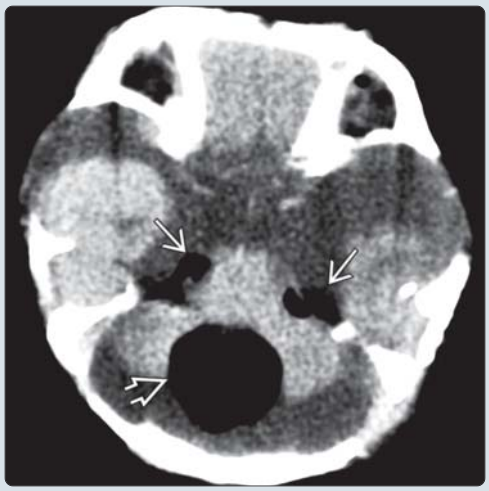

(Left) *Clinical photograph of a scalp shows the typical appearance of "nevus psiloliparus," a well-circumscribed area of scalp alopecia. The nevus overlies a lipoma and is the hallmark of encephalocraniocutaneous lipomatosis.* **(Right)** *Axial NECT scan in a 2 year old with encephalocraniocutaneous lipomatosis (ECCL) shows focal lipomas in both cerebellopontine angle (CPA) cisterns ➡ and the cisterna magna ➡.*

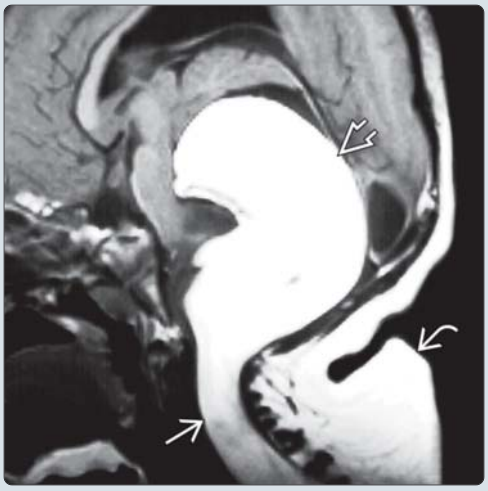

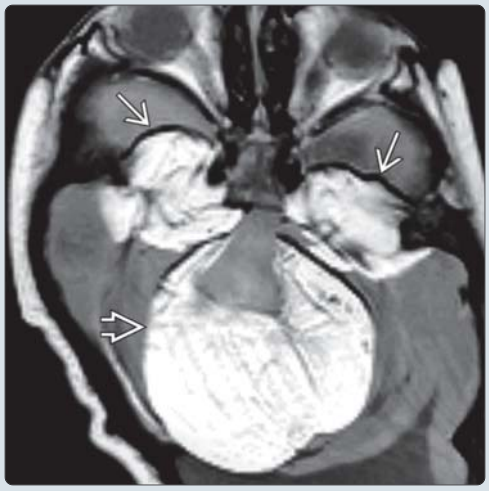

(Left) *Sagittal T1WI in the same patient obtained 3 years later shows a very large suboccipital lipoma ➡. The foramen magnum lipoma has massively increased in size and now occupies most of the posterior fossa ➡. The foramen magnum lipoma now extends inferiorly into the upper cervical spine ➡.* **(Right)** *Axial T1WI in the same patient shows how much the posterior fossa lipoma ➡ has increased in size compared to the baseline NECT. The CPA lipomas extend into Meckel caves ➡.*

https://CafePezeshki.IR

TERMINOLOGY

Abbreviations

- Encephalocraniocutaneous lipomatosis (ECCL)

Synonyms

- Haberland syndrome, Fishman syndrome

Definitions

- Rare congenital neurocutaneous syndrome characterized by ipsilateral scalp, eye, and brain abnormalities
- 1st described in 1970 by Catherine Haberland

IMAGING

General Features

- Best diagnostic clue
  - Unilateral cerebral hemispheric atrophy ipsilateral to scalp lipoma
  - Other frequent ipsilateral CNS abnormalities
    - Middle cranial fossa arachnoid cyst
    - Cortical dysplasia
    - Cortical Ca++
  - Intracranial (IC) lipomas in ~ 2 out of 3 patients
  - Spinal lipomas/lipomatosis frequent; cervicothoracic > lumbar
  - Rarely, CNS abnormalities limited to IC lipoma
- Location
  - Intracranial lipomas
    - CP angle, Meckel cave, foramen magnum
    - Usually ipsilateral to scalp lipoma; occasionally contra- or bilateral
  - All other CNS anomalies ipsilateral to scalp lipoma
- Morphology
  - Focal occipital lobe atrophy and occipital horn enlargement characteristic

CT Findings

- NECT
  - Hemispheric atrophy, ventriculomegaly
    - Ventriculomegaly primarily due to volume loss although hydrocephalus occasionally present
  - Low-density scalp lipoma (may be difficult to identify, particularly if at vertex)
  - ± cortical Ca++
    - Identified as early as 1st month of life, progressive
  - ± focal calvarial enlargement
    - Usually underlies scalp lipoma
- CECT
  - ± diffuse, ipsilateral leptomeningeal (LM) enhancement
- CTA
  - Arterial ectasias, pouches, and aneurysms described in older patients

MR Findings

- T1WI
  - Scalp/intracranial lipomas
  - Polymicrogyria of temporal, parietal, &/or occipital lobes
  - Scleral choristoma occasionally visible; heterogeneous with focal areas of hyperintensity
- T2WI
  - Cortical Ca++ hypointense
  - Lipomas hyperintense on T2 FSE
  - Arachnoid cysts isointense to CSF
- FLAIR
  - Nulling of signal from arachnoid cyst
- T2* GRE
  - "Blooming" of cortical Ca++
- DWI
  - Arachnoid cyst isointense to CSF
- T1WI C+
  - ± diffuse, ipsilateral leptomeningeal enhancement
- MRA
  - Arterial ectasias, pouches, and aneurysms described in older patients

Ultrasonographic Findings

- Ventriculomegaly reported on 3rd trimester US

Angiographic Findings

- Conventional
  - Arterial ectasias, pouches, and aneurysms described in older patients

Imaging Recommendations

- Best imaging tool
  - Contrast-enhanced MR
- Protocol advice
  - Multiplanar MR with fat saturation to identify scalp lipoma (may be missed on CT)
  - MRA may disclose vascular abnormalities

DIFFERENTIAL DIAGNOSIS

Sturge-Weber Syndrome (SWS)

- Unilateral hemispheric cerebral atrophy and cortical Ca++, LM enhancement ipsilateral to forehead port-wine nevus
  - CNS findings frequently posterior

Oculocerebrocutaneous Syndrome (OCCS)

- Characterized by unique cutaneous striated muscle hamartoma, cystic microphthalmia, and giant tectum absent vermis malformation
- Cortical dysplasia, agenesis of corpus callosum, and Dandy-Walker malformation frequently present
- Cutaneous, eye, and CNS anomalies usually ipsilateral but less consistently than ECCL

Epidermal Nevus Syndrome (ENS)

- Ipsilateral epidermal nevus, hemimegalencephaly, facial lipoma, and hemihypertrophy
- Occasional scleral choristoma

Proteus Syndrome

- Progressive asymmetric, bilateral trunk/limb hypertrophy
- Osteomas, lipomas, and pigmented nevi common
- CNS anomalies uncommon; hemimegalencephaly most common

PATHOLOGY

General Features

- Etiology
  - Defect in development of mesenchymal tissues

https://CafePezeshki.IR

  - Affects mostly neural crest cells surrounding brain and forming vessels
- Genetics
  - Sporadic
  - May survive autosomal lethal gene by somatic mosaicism
- ECCL considered distinct entity; however, some clinical/imaging overlap with SWS, OCCS, ENS, and proteus syndrome
- Embryology-anatomy
  - 3rd week gestation: Embryonic disc consists of ectoderm, mesoderm, entoderm
  - Neural tube develops from ectoderm during 3rd week gestation
  - 4th and 5th week gestation: Mesoderm forms mesenchymal sheath over brain and spinal cord → precursor blood vessels, bone, cartilage, and fat

Gross Pathologic & Surgical Features

- Brain: Cortical atrophy, white matter hypoplasia, ventriculomegaly, polymicrogyria, wallerian degeneration brainstem
  - Arterial ectasias, pouches, aneurysms described in older patients
- Leptomeninges: Thick, gray, gelatinous with excess underlying arteries, veins, and varicose capillaries
- Skull: Macrocranium with focal hyperostosis
- Scalp: Focal lipomatous thickening with overlying circumscribed alopecia
- Face: Multiple, tiny, white/purple/yellow periocular > perinasal papules

Microscopic Features

- Brain: Abnormal 4-layered cytoarchitecture, mineral concretions outer cortical lamina, scattered glial nodules
- Leptomeninges: Lipoangiomatosis
- Skull: Diploic replacement with mature fat cells
- Scalp: Benign lipoma > fibrolipoma expanding into dermis; absent hair follicles with preserved erector pili muscles
- Skin: Subcutaneous angiofibroma, fibrolipoma, or lipoma
- Eye: Corneal limbus/scleral choristoma
  - Other ocular abnormalities: Persistent hyaloid vasculature, coloboma, cloudy cornea, lens dislocation, ectopic pupils

CLINICAL ISSUES

Presentation

- Most common signs/symptoms
  - Nevus psiloliparus: Sharply demarcated focus of scalp alopecia overlying scalp lipoma
    - Hallmark of ECCL
- Other signs/symptoms
  - Ipsilateral ocular choristomas and periocular > perinasal papules; epibulbar dermoid
  - Macrocranium (unrelated to hydrocephalus)
  - Seizures, psychomotor delay, spastic hemiparesis
  - Infrequent scoliosis, foot deformities, sensorimotor deficits (2° to spinal lipoma)
- Clinical profile
  - Newborn/infant with nevus psiloliparus, scleral mass, and periocular papules; seizures in infants

Demographics

- Age
  - Newborn > infant presentation
  - Rare presentation in teen/adult patients with cutaneous, ocular lesions
- Gender
  - M = F
- Ethnicity
  - No racial or geographic predilection
- Epidemiology
  - Rare; ~ 54 reported cases (likely underreported)

Natural History & Prognosis

- Reported growth lipomas and ocular choristomas; remaining congenital abnormalities static
- Abnormal vasculature, aneurysms later in life
- Majority with variable degrees of psychomotor impairment and dependency
- Few reports of neurologically normal patients with nevus psiloliparus; nonsyndromic nevus psiloliparus vs. ECCL with minimal CNS involvement

Treatment

- Antiepileptics
- Shunt placement for hydrocephalus

DIAGNOSTIC CHECKLIST

Image Interpretation Pearls

- Considerable imaging overlap with SWS → search for scalp lipoma
- Low-density IC lipoma may be difficult to distinguish from CSF on CT

SELECTED REFERENCES

1. Bieser S et al: Grade II pilocytic astrocytoma in a 3-month-old patient with encephalocraniocutaneous lipomatosis (ECCL): Case report and literature review of low grade gliomas in ECCL. Am J Med Genet A. 167(4):878-81, 2015
2. Lin AW et al: Characteristic imaging findings in encephalocraniocutaneous lipomatosis. Neurology. 84(13):1384-5, 2015
3. Bauld H et al: Encephalocraniocutaneous Lipomatosis: A Case With Long Term Follow-up. Can J Neurol Sci. 41(1):106-8, 2014
4. Chandravanshi SL: Encephalocraniocutaneous lipomatosis: a case report and review of the literature. Indian J Ophthalmol. 62(5):622-7, 2014
5. Chiang CC et al: Clinical manifestation and neurosurgical intervention of encephalocraniocutaneous lipomatosis--a case report and review of the literature. Childs Nerv Syst. 30(1):13-7, 2014
6. Jain P et al: Encephalocraniocutaneous lipomatosis with neurocutaneous melanosis. J Child Neurol. 29(6):846-849, 2013
7. Lee RK et al: Encephalocraniocutaneous lipomatosis: a rare case with development of diffuse leptomeningeal lipomatosis during childhood. Pediatr Radiol. 42(1):129-33, 2012

https://CafePezeshki.IR

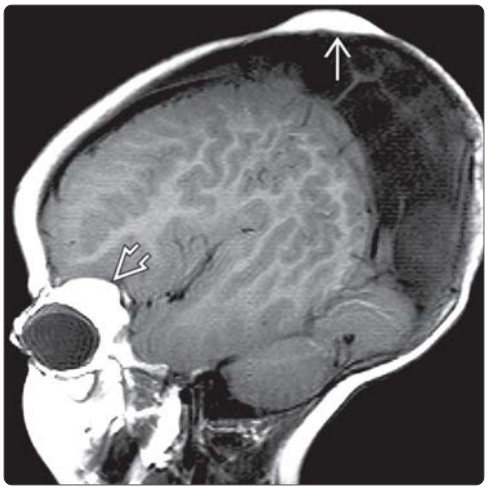

(Left) *Sagittal T1WI MR shows an ipsilateral scalp ⇨ and orbital ⇨ lipoma. The globe is buphthalmic with a scleral lipodermoid.* **(Right)** *Axial T2WI MR shows marked left ventriculomegaly with herniation of the ventricle through the choroidal fissure and hemispheric volume loss. The herniated ventricle is displacing the posterior aspect of the cerebral hemisphere ⇨ anteriorly, thereby compressing and distorting the hemispheric parenchyma.*

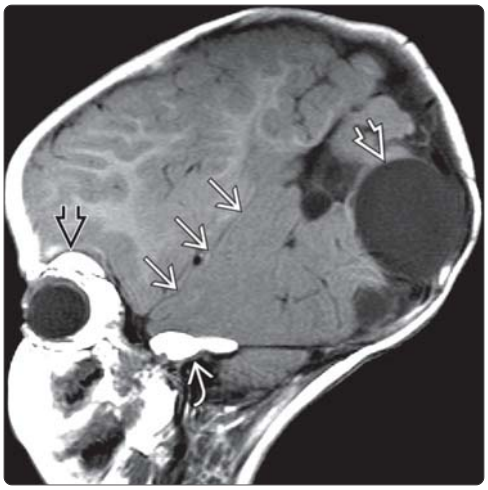

(Left) *Sagittal T1WI MR shows ipsilateral orbital ⇨ and middle cranial fossa ⇨ lipomas. The cerebral cortex ⇨ is distorted by the enlarged lateral ventricle. Note the intracranial cyst ⇨.* **(Right)** *Axial T1WI MR shows an intracranial lipoma in the interhemispheric fissure ⇨ and an extracranial lipoma ⇨ in subcutaneous fat. There is no hemispheric atrophy or ventriculomegaly. The patient is clinically normal. The findings may represent a forme fruste of ECCL.*

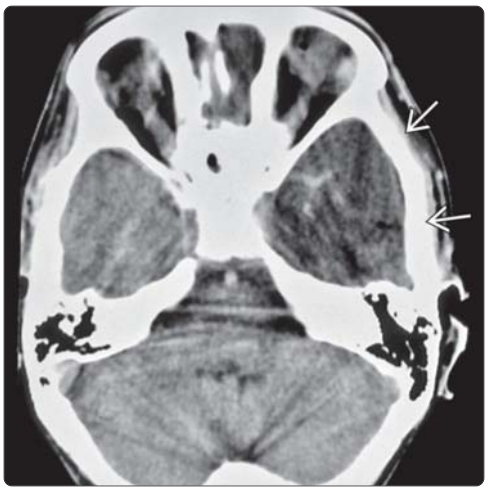

(Left) *Axial NECT shows a middle cranial fossa arachnoid cyst in a patient with ECCL. Note the expansion of the left middle cranial fossa ⇨ by the cyst. The cyst is ipsilateral to hemispheric atrophy and a scalp lipoma. Scalp lipoma is sometimes poorly seen by imaging.* **(Right)** *Sagittal T1WI MR shows large, subcutaneous lipomas ⇨ in the upper neck and the occipital area of the scalp. Note the small lipoma ⇨ immediately behind the cerebellar vermis.*

https://CafePezeshki.IR

KEY FACTS

TERMINOLOGY

- Lhermitte-Duclos disease (LDD)
  - Benign cerebellar lesion; unclear if neoplastic, malformative, or hamartomatous
- Multiple hamartoma syndrome (MHAM) → autosomal dominant, mutation in *PTEN* gene, associated with increased incidence of malignancy
  - MHAM = Cowden syndrome (CS); Cowden plus Lhermitte-Duclos (COLD) = MHAM with LDD
    - CS is most common phenotype of PTEN hamartoma tumor syndrome
  - LDD now considered manifestation of MHAM and a neurocutaneous syndrome

IMAGING

- Relatively well-defined cerebellar mass with striated/corduroy/tigroid/gyriform pattern
- LDD always in cerebellum and may be large → mass effect, tonsillar herniation, hydrocephalus

TOP DIFFERENTIAL DIAGNOSES

- Subacute cerebellar infarction
- Cerebellitis
- Unclassified cerebellar dysplasias
- Ganglioglioma
- Medulloblastoma

CLINICAL ISSUES

- Most common presentation: Headache, nausea and vomiting, ataxia, blurred vision
  - Can present in coma
- Shunting or surgical debulking for symptomatic patients with hydrocephalus

DIAGNOSTIC CHECKLIST

- If LDD, screen for MHAM; if MHAM, screen for LDD
- Long-term cancer screening needed, especially thyroid and breast (↑ malignancy in MHAM)

(Left) *Axial graphic shows thickened and irregular cerebellar folia in the right cerebellar hemisphere. This results in the enlargement of the hemisphere & mass effect upon the brainstem that are typical of Lhermitte-Duclos disease (LDD).* **(Right)** *Axial T2WI in a 76-year-old man with nonspecific headaches shows a hyperintense right cerebellar hemispheric mass. The widened "gyriform" folia ⇨ give the mass a distinctive striated appearance. Several dot-like flow voids ⇨ are present in-between the enlarged folia.*

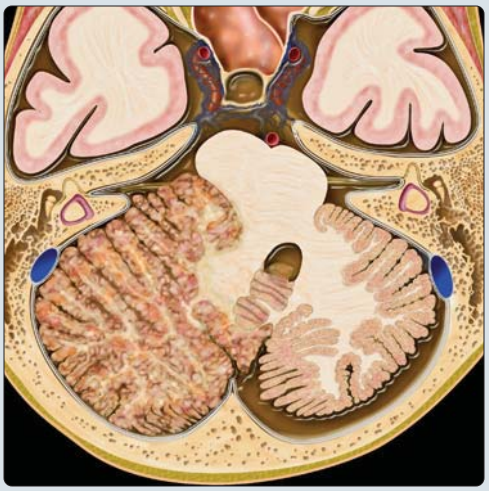

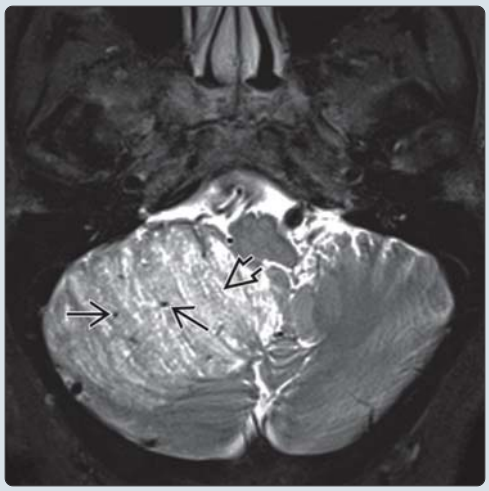

(Left) *Axial T1 C+ FS in the same patient shows the thickened folia do not enhance but the prominent flow voids seen on the T2WI show strong, uniform enhancement ⇨ suggesting they are vascular structures.* **(Right)** *Coronal T1 C+ scan in the same case shows the enhancing vessels ⇨ nicely. The findings were pathognomonic of LDD so the mass was not biopsied.*

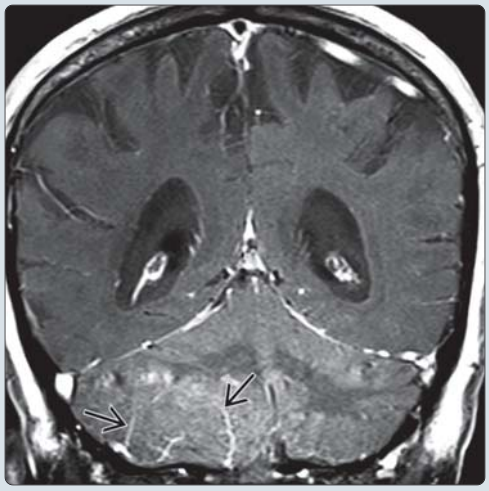

https://CafePezeshki.IR

TERMINOLOGY

Synonyms

- Lhermitte-Duclos disease (LDD)
  - Dysplastic cerebellar gangliocytoma, gangliocytoma dysplasticum, hamartoma of cerebellum
  - Hamartoblastoma, cerebelloparenchymal disorder 6, granule cell hypertrophy, granular cell hypertrophy, granulomolecular hypertrophy
  - Diffuse ganglioneuroma of cerebellar cortex, diffuse cerebellar hypertrophy, neurocytic blastoma, myelinated neurocytoma, purkingeoma
- Multiple hamartoma syndrome (MHAM)
  - Multiple hamartoma-neoplasia syndrome, Cowden disease, Cowden syndrome (CS), Cowden-Lhermitte-Duclos syndrome (COLD)

Definitions

- Lhermitte-Duclos disease → neurological manifestation of MHAM
  - Benign cerebellar lesion but unclear if neoplastic, malformative, or hamartomatous
  - Association between LDD and MHAM probably represents new neurocutaneous syndrome
- Multiple hamartoma syndrome
  - Autosomal dominant, variable expression, typically mutation in *PTEN* gene
  - Hamartomatous neoplasms of skin (90-100%), mucosa, GI tract, bones, CNS, eyes, and GU tract
  - Associated with increased incidence of malignancy

IMAGING

General Features

- Best diagnostic clue
  - Grossly thickened cerebellar folia with striated (tigroid) gyriform pattern
- Location
  - Always in cerebellum, usually unilateral
  - Often involves vermis, rarely brainstem
- Size
  - Size variable, may be large → mass effect, tonsillar herniation, hydrocephalus
- Morphology
  - Infiltrative but well demarcated

CT Findings

- NECT
  - Normal to high attenuation with striations
    - Occasionally cystic areas &/or calcifications
  - May compress 4th ventricle, cause obstructive hydrocephalus
- CECT
  - ± enhancement

MR Findings

- T1WI
  - Iso- to hypointense with striations
- T2WI
  - ↑ signal with characteristic iso- to hypointense striations
  - May have bizarre gyriform appearance
- FLAIR
  - ↑ signal with striations
  - May have hypointense cysts
- T2* GRE
  - Veins between folia
- DWI
  - ↑ signal on DWI usually due to ↑ T2 signal
    - Sometimes due to hypercellularity, ↑ axonal density
  - Low to ↑ ADC; ↑ ADC in white matter, cysts
  - May have ↑ fractional anisotropy (FA) in white matter
- PWI
  - May show areas of ↑ rCBV and rCBF
- T1WI C+
  - ± enhancement (increased vascularity in molecular layer and leptomeninges, predominantly venous)
- MRS
  - ↓ NAA, ↓ choline, ↓ myoinositol
  - Variable lactate, may show prominent peak

Nuclear Medicine Findings

- PET
  - ↑ uptake FDG PET and 11C-methionine PET
  - Report of ↑ CBF, ↓ OEF, and similar $CMRO_2$ compared to normal cerebral hemisphere

Imaging Recommendations

- Best imaging tool
  - MR with DWI, MRS, and contrast
- Protocol advice
  - Coronal T2 may be helpful
  - If LDD, initiate work-up for MHAM and screen for malignancies
  - If it enhances, consider differential diagnosis carefully

DIFFERENTIAL DIAGNOSIS

Subacute Cerebellar Infarction

- Mass effect, ↑ signal on DWI but vascular territory

Cerebellitis/Vasculitis

- Acute onset of symptoms

Unclassified Cerebellar Dysplasias

- Do not progress, hydrocephalus rare

Ganglioglioma

- May have bizarre appearance simulating LDD

Tuberous Sclerosis Complex

- Rarely mass-like cerebellar dysplastic lesions but other features of tuberous sclerosis complex

Medulloblastoma

- Lateral desmoplastic type may have somewhat striated appearance
- ↑ signal on DWI but most have marked ↑ Cho/NAA

Meningeal Metastases

- Nodular leptomeningeal enhancement

Meningeal Granulomatous Disease

- Nodular leptomeningeal enhancement

https://CafePezeshki.IR

PATHOLOGY

General Features

- Etiology
  - Unclear whether hamartomatous, neoplastic, or congenital malformative origin
    - Nonproliferation/absence of malignant transformation favors hamartomatous nature
- Genetics
  - Many have mutations of *PTEN* gene at 10q23.31 (tumor suppressor gene)
  - Activation of PTEN/AKT/mTOR pathway suggests role for mTOR in pathogenesis
- Associated abnormalities
  - Most patients with LDD likely have MHAM

Staging, Grading, & Classification

- WHO grade I

Gross Pathologic & Surgical Features

- Markedly enlarged cerebellar hemisphere/vermis
  - Wide, thick cerebellar folia have grossly gyriform appearance

Microscopic Features

- Widening of molecular cell layer → occupied by abnormal ganglion cells
- Absence of Purkinje cell layer
- Hypertrophy of granule cell layer
- ↓ volume of white matter
- Histologically may be confused with ganglion cell tumor

CLINICAL ISSUES

Presentation

- Most common signs/symptoms
  - Headache, nausea and vomiting, papilledema, unsteady gait, upper limb ataxia and dysmetria, blurred vision, lower cranial nerve palsies
- Other signs/symptoms
  - Sensory motor deficits, vertigo, neuropsychological deficits
- Clinical profile
  - If LDD, screen for MHAM; if MHAM, screen for LDD

Demographics

- Age
  - Any; most common between 20-40 years
- Gender
  - M ≈ F
- Ethnicity
  - No known predilection
- Epidemiology
  - ↑ degree of penetrance in family members

Natural History & Prognosis

- Many do not grow or grow only slowly
- If mass effect is not relieved prognosis is poor
- Post-surgery recurrences are rare but do occur

Treatment

- Options, risks, complications
  - Borders of lesion blend into normal surrounding cerebellum → total resection difficult
  - Shunting or surgical debulking for symptomatic patients with hydrocephalus

DIAGNOSTIC CHECKLIST

Consider

- Search for other features of MHAM when LDD is diagnosed and vice versa
- Long-term cancer screening needed (especially breast in women, thyroid in men and women)

Image Interpretation Pearls

- Relatively well-defined cerebellar mass with striated tigroid or gyriform pattern

SELECTED REFERENCES

1. Mester J et al: Cowden syndrome: recognizing and managing a not-so-rare hereditary cancer syndrome. J Surg Oncol. 111(1):125-30, 2015
2. Smpokou P et al: PTEN hamartoma tumour syndrome: early tumour development in children. Arch Dis Child. 100(1):34-7, 2015
3. Syngal S et al: ACG clinical guideline: Genetic testing and management of hereditary gastrointestinal cancer syndromes. Am J Gastroenterol. 110(2):223-62; quiz 263, 2015
4. Tan MH et al: RE: Cowden syndrome and PTEN hamartoma tumor syndrome: systematic review and revised diagnostic criteria. J Natl Cancer Inst. 106(6):dju130, 2014
5. Vanderver A et al: Characteristic brain magnetic resonance imaging pattern in patients with macrocephaly and PTEN mutations. Am J Med Genet A. 164A(3):627-33, 2014
6. Shinagare AB et al: Case 144: Dysplastic cerebellar gangliocytoma (Lhermitte-Duclos disease). Radiology. 251(1):298-303, 2009
7. Cianfoni A et al: Morphological and functional MR imaging of Lhermitte-Duclos disease with pathology correlate. J Neuroradiol. 35(5):297-300, 2008
8. Thomas B et al: Advanced MR imaging in Lhermitte-Duclos disease: moving closer to pathology and pathophysiology. Neuroradiology. 49(9):733-8, 2007
9. Abel TW et al: Lhermitte-Duclos disease: a report of 31 cases with immunohistochemical analysis of the PTEN/AKT/mTOR pathway. J Neuropathol Exp Neurol. 64(4):341-9, 2005

https://CafePezeshki.IR

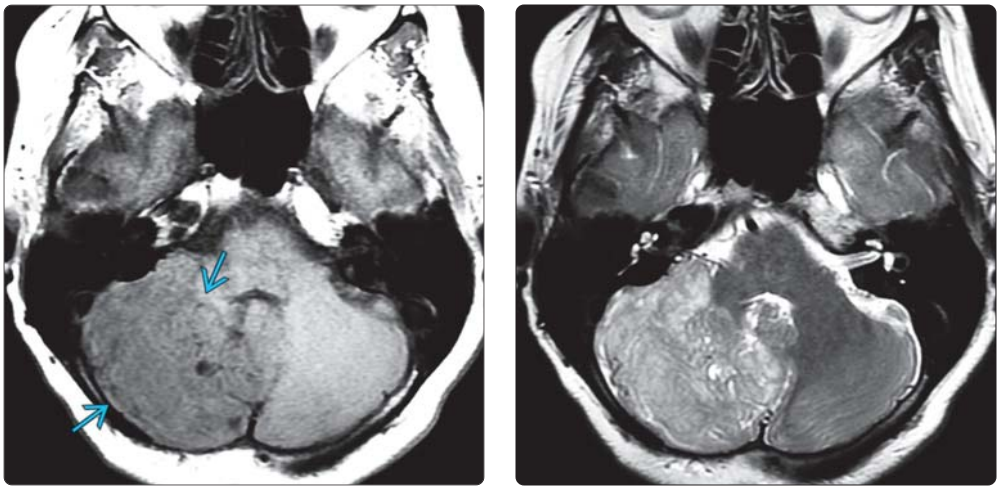

(Left) *Axial T1WI in a 57-year-old woman with headaches shows a mildly hypointense mass in the right cerebellar hemisphere ⇨ and vermis.* **(Right)** *T2WI in the same patient shows the mass is hyperintense and has a striated gyriform appearance.*

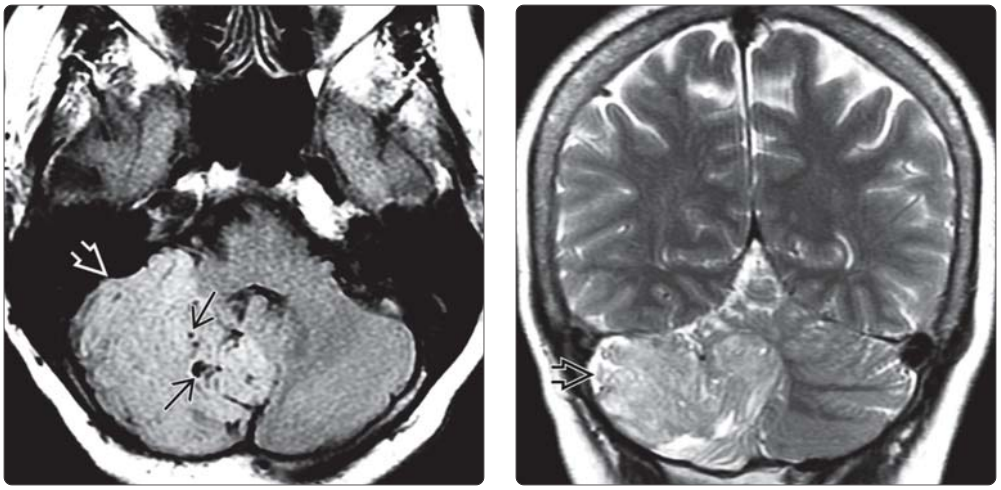

(Left) *Axial FLAIR scan in the same patient shows the mass ⇨ is hyperintense compared to the normal left cerebellar hemisphere. Several fluid-filled cysts within the mass suppress completely ⇨.* **(Right)** *Coronal T2WI shows the mass has a striped or tigroid pattern. The cerebellar folia are expanded ⇨ compared to the normal left cerebellum.*

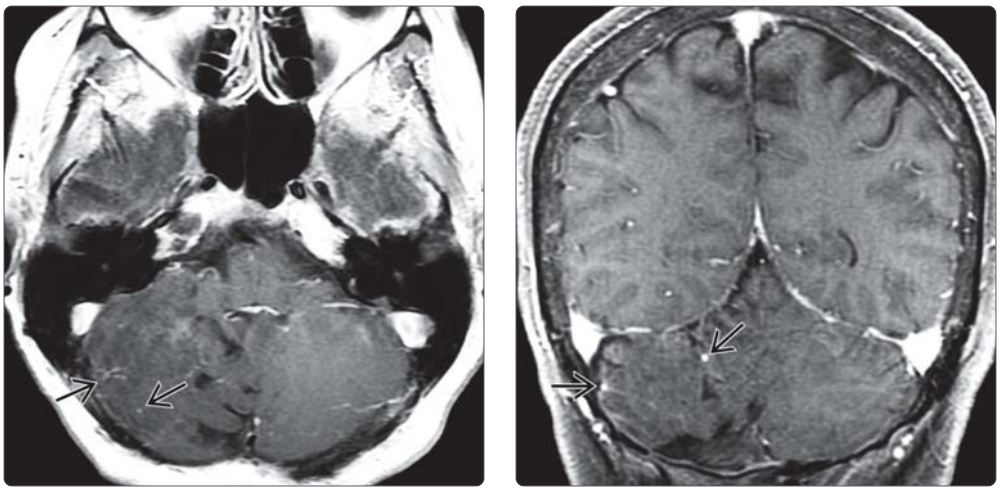

(Left) *T1 C+ MR in the same patient shows no enhancement of the mass, but punctate and linear enhancing foci ⇨ representing prominent vessels are seen.* **(Right)** *Corontal T1 C+ FS shows the enhancing vessels ⇨ but no enhancement of the mass itself. The preoperative diagnosis was cerebellar neoplasm. This is a biopsy-proven case of dysplastic cerebellar gangliocytoma (LDD). Further evaluation revealed Cowden disease and the need for active cancer surveillance was identified.*

https://CafePezeshki.IR

KEY FACTS

TERMINOLOGY

- Congenital phakomatosis characterized by giant &/or multiple melanocytic nevi (GCMN) of the skin in association with melanotic lesions of CNS
- CNS disease
  - Primary leptomeningeal melanocytic neoplasms (LMNs)
    - Can be circumscribed (usually adults) or diffuse (more often children)
    - Benign or malignant
  - Leptomeningeal melanocytosis (LMs): Excess of benign melanotic cells in leptomeninges (most frequently in children with neurocutaneous melanosis [NCM])
  - Leptomeningeal melanoma (LMm) or melanomatosis: Malignant melanoma of leptomeninges
- Genetic studies show NCM is a RASopathy

IMAGING

- GCMN + foci of T1 hyperintensity in amygdala, cerebellum, or cerebral cortex
- GCMN + diffuse leptomeningeal (LM) enhancement

CLINICAL ISSUES

- Criteria for diagnosis
  - Giant or multiple (≥ 3) cutaneous melanocytic nevi
  - Child: 6 cm body, 9 cm head maximal diameter
  - Cutaneous melanoma only in patients with benign meningeal lesions
  - Leptomeningeal melanoma only in patients with benign cutaneous lesions
- Sx NCM manifests by 2-3 years of age
- Asx NCM: Parenchymal melanosis often stable
- GCMN (isolated or NCM): 5-15% lifetime risk of malignant degeneration (melanoma)

DIAGNOSTIC CHECKLIST

- Normal MR does not exclude diagnosis NCM
- LMs cannot be distinguished from LMm by imaging

(Left) *Graphic shows localized dark (melanotic) pigmentation of the leptomeninges. Inset demonstrates extension of melanosis into the brain substance along the Virchow-Robin spaces* ⇨. **(Right)** *Axial T1WI MR of a 6 year old with benign parenchymal and leptomeningeal melanosis shows multiple foci of T1 shortening (hyperintense signal) in the amygdala* ⇨ *(indicates parenchymal involvement), and in the right ambient cistern* ⇨ *(indicates leptomeningeal disease).*

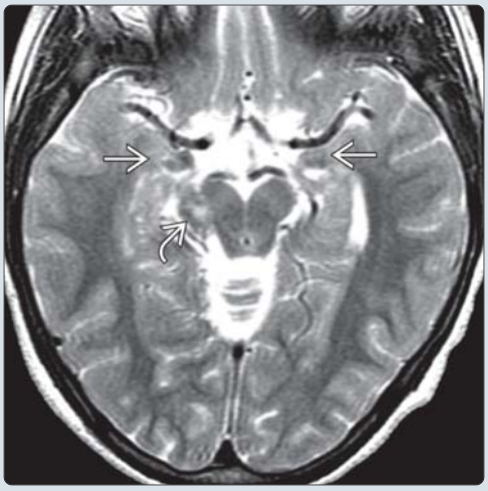

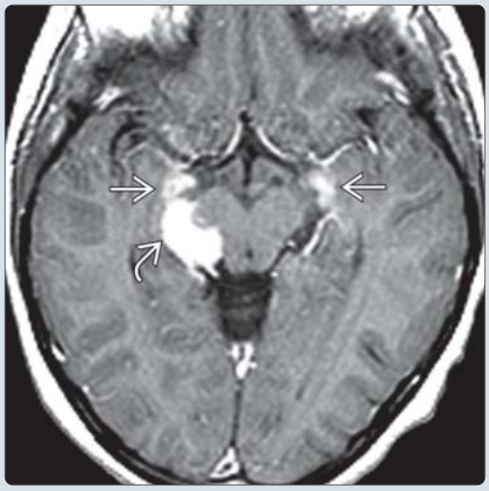

(Left) *Axial T2WI MR in the same patient reveals T2 shortening (hypointense signal) of the mass lesions in the amygdala* ⇨ *and the ambient cistern* ⇨. *Note that the abnormal signal is more difficult to see on T2-weighted images.* **(Right)** *Axial T1 C+ MR in the same patient demonstrates enhancement of the leptomeningeal lesion* ⇨. *The parenchymal lesions* ⇨ *do not enhance, and are actually slightly less conspicuous, as is often the case following contrast injection.*

https://CafePezeshki.IR

TERMINOLOGY

Abbreviations

- Neurocutaneous melanosis (NCM)

Definitions

- Congenital phakomatosis characterized by giant &/or multiple melanocytic nevi (GCMN) of the skin in association with melanotic lesions of CNS
  - CNS disease: Parenchymal
    - Melanosis or melanocytosis: Focal collection of benign melanotic cells
    - Malignant melanoma or melanomatosis (MM)
  - CNS disease: Leptomeningeal (LM)
    - Primary leptomeningeal melanocytic neoplasms (LMNs)
      - Can be circumscribed (usually adults) or diffuse (more often children)
      - Benign or malignant
      - Leptomeningeal melanocytosis (LMs): Excess of benign melanotic cells in leptomeninges (most frequently in children with NCM)
      - Leptomeningeal melanoma (LMm) or melanomatosis: Malignant melanoma of leptomeninges
  - Genetic studies show NCM is a RASopathy

IMAGING

General Features

- Best diagnostic clue
  - GCMN + foci of T1 hyperintensity in amygdala, cerebellum, or cerebral cortex
  - GCMN + diffuse LM enhancement
- Location
  - Parenchymal melanosis: Amygdala, cerebellum, basis pontis, thalami, base of frontal lobes
  - LMs or LMm: Diffuse LM involvement; rarely focal
  - MM: Temporal lobe most common
- Size
  - Parenchymal melanosis: < 1 cm
  - MM: Typically several cm
- Morphology
  - Parenchymal melanosis: Round or oval lesions, sometimes curvilinear in cortex
  - LMs/LMm: Linear or nodular (bulky)
  - MM: Large, round mass
- 64% symptomatic (Sx), patients with NCM (MM, LMm, ± LMs) have hydrocephalus
  - Communicating > noncommunicating
- Arachnoid cysts occasionally identified
- Spinal involvement (LM enhancement, intra- or extramedullary cyst, syrinx, arachnoiditis) in 20%
- Stable free radicals in melanin responsible for MR appearance

CT Findings

- NECT
  - Parenchymal melanosis: Normal or hyperdense
  - MM: Hyperdense mass with edema, mass effect; frequent necrosis/hemorrhage
- CECT
  - Parenchymal melanosis: No enhancement
  - LMs: Normal or diffuse LM enhancement
  - LMm: Diffuse LM enhancement
  - MM: Avid enhancement, often heterogeneous

MR Findings

- T1WI
  - Parenchymal melanosis: Hyperintense
  - LMs/LMm: Sulci/cisterns normal, iso- or hyperintense
  - MM: Mixed signal intensity; frequently hyperintense
- T2WI
  - Parenchymal melanosis: Mixed signal intensity, frequently hypointense; no edema, mass effect
  - LMs/LMm: Sulci/cisterns normal, iso- or hypointense
  - MM: Mixed signal intensity with edema, mass effect; frequent necrosis, hemorrhage
- FLAIR
  - LMm/LMs: Variable leptomeningeal hyperintensity
- T2* GRE
  - "Blooming" of hemorrhage and melanin
- T1WI C+
  - Parenchymal melanosis: No enhancement
  - LMs: Normal or diffuse LM enhancement
  - LMm: Diffuse LM enhancement
  - MM: Avid enhancement, often heterogeneous

Imaging Recommendations

- Best imaging tool
  - MR C+ brain and spine
- Protocol advice
  - MR screen for asymptomatic (Asx) infants with GCMN

DIFFERENTIAL DIAGNOSIS

T1-Hyperintense Mass

- Lipoma: Chemical shift artifact, extraaxial (subarachnoid) location
- Dermoid: Chemical shift artifact, extraaxial location, sharply demarcated, exerts mass effect
- Acute/subacute hemorrhage: Marked T2 hypointensity, mass effect/edema, neurological deficit
- Hemorrhagic, nonmelanotic neoplasms: Areas of marked T2 hypointensity, mass effect/edema

Diffuse Leptomeningeal Enhancement

- Carcinomatous meningitis/CSF seeding: History of 1° malignancy, linear/nodular LM enhancement
- Infectious meningitis (routine bacterial, TB, coccidioidomycosis): Basal cisterns, linear enhancement, signs/symptoms of meningitis; positive CSF cultures
- Noninfectious inflammation (sarcoidosis, Wegener granulomatosis): Linear/nodular enhancement

PATHOLOGY

General Features

- Genetics
  - NCM caused by postzygotic somatic mutations in codon 61 of *NRAS*
    - Both diffuse, circumscribed LMNs
    - BRAF mutations may play role in some NCM patients

https://CafePezeshki.IR

- Associated abnormalities
  - Association with cerebellar hypoplasia (< 10%)
    - Abnormal meningeal cells causally related to hindbrain malformation
    - Cerebellar melanosis always present with cerebellar hypoplasia
    - Dandy-Walker malformation occasionally seen
- Embryology
  - Neural crest-derived primordial cells migrate, differentiate into melanocytes in pia mater and basal layer of epidermis
  - Melanocytes in epidermis at 8-10 weeks gestation
  - Melanocytes in pia mater at 23 weeks gestation
- Anatomy
  - Melanocytes normally present in pia mater over convexities, base of brain, ventral brainstem, upper cervical cord, and lumbosacral spinal cord
  - Melanocytes normally surround blood vessels but do not extend into Virchow-Robin (VR) spaces

Staging, Grading, & Classification

- Criteria for diagnosis
  - Giant or multiple (≥ 3) cutaneous melanocytic nevi
    - Child: 6 cm body, 9 cm head maximal diameter
    - Adult: 20 cm maximal diameter
  - Cutaneous melanoma only in patients with benign meningeal lesions
  - Leptomeningeal melanoma only in patients with benign cutaneous lesions

Gross Pathologic & Surgical Features

- Parenchymal melanosis: Focal, abnormal pigmentation within brain
- LMs/LMm: Darkly pigmented, thickened pia mater
- MM: Pigmented mass, ± necrosis, hemorrhage
- GCMN: Giant or multiple pigmented, hairy nevi
  - Giant nevi comprise 66% (in NCM)
    - Lumbosacral > occipital, upper back
    - Involvement of head and neck occurs in 94%
    - Patients with nevi ≥ 50 cm at highest risk NCM
  - Multiple nevi comprise 34%

CLINICAL ISSUES

Presentation

- Most common signs/symptoms
  - ↑ intracranial pressure (seizures, vomiting, headache, macrocranium, CN6 palsy, lethargy)
  - Other signs/symptoms
    - Focal neurological deficit, psychiatric disturbance in rare older child/young adult presentation
- Clinical profile
  - Asymptomatic infant with GCMN (parenchymal melanosis)
    - Parenchymal melanosis may causes seizures
  - Infant/child with GCMN + signs/symptoms ↑ intracranial pressure (LMm, ± LMs, MM)
    - Histologically benign disease (LMs) may be symptomatic
- CSF (Sx NCM): ↑ protein, ↓ glucose, ± benign/malignant melanotic cells

Demographics

- Age
  - Sx NCM manifests by 2-3 years of age
- Epidemiology
  - NCM: Rare; 100+ reported cases
  - GCMN: 1:20,000 live births
    - Sx NCM: < 3% patients with GCMN
    - ~ 30% of patients with GCMN have parenchymal melanosis (Asx NCM)

Natural History & Prognosis

- Natural history
  - Asx NCM: Parenchymal melanosis often stable
    - Few reports of regression, and degeneration into MM
  - GCMN (isolated or NCM): 5-15% lifetime risk of malignant degeneration (melanoma)
- Prognosis
  - Asx NCM: Unknown; at risk developing Sx NCM
  - Sx NCM: Dismal; median survival 6.5 months after symptom onset
    - Prognosis equally poor for histologically benign (LMs) or malignant (LMm, MM) Sx NCM

Treatment

- Asx NCM: Screening with MR beginning 6 months of age
- Sx NCM: Shunt hydrocephalus (filter prevents peritoneal seeding)
  - Surgery, XRT, systemic/intrathecal chemotherapy
    - Palliative; no significant alteration course of NCM

DIAGNOSTIC CHECKLIST

Image Interpretation Pearls

- Normal MR does not exclude diagnosis of NCM
- LMs cannot be distinguished from LMm by imaging
  - Clinically irrelevant since Sx LMs and LMm have equally poor prognosis

SELECTED REFERENCES

1. Araújo C et al: Giant congenital melanocytic nevi and neurocutaneous melanosis. Case Rep Med. 2015:545603, 2015
2. Küsters-Vandevelde HV et al: Primary melanocytic tumors of the central nervous system: a review with focus on molecular aspects. Brain Pathol. 25(2):209-26, 2015
3. Bekiesinska-Figatowska M et al: Neurocutaneous melanosis in children with giant congenital melanocytic nevi. Clin Imaging. 38(2):79-84, 2014
4. van Engen-van Grunsven AC et al: Update on Molecular Pathology of Cutaneous Melanocytic Lesions: What is New in Diagnosis and Molecular Testing for Treatment? Front Med (Lausanne). 1:39, 2014
5. Jain P et al: Encephalocraniocutaneous lipomatosis with neurocutaneous melanosis. J Child Neurol. 29(6):846-9, 2013
6. Kinsler VA et al: Multiple congenital melanocytic nevi and neurocutaneous melanosis are caused by postzygotic mutations in codon 61 of NRAS. J Invest Dermatol. 133(9):2229-36, 2013
7. Alikhan A et al: Congenital melanocytic nevi: where are we now? Part I. Clinical presentation, epidemiology, pathogenesis, histology, malignant transformation, and neurocutaneous melanosis. J Am Acad Dermatol. 67(4):495, 2012
8. Ramaswamy V et al: Spectrum of central nervous system abnormalities in neurocutaneous melanocytosis. Dev Med Child Neurol. 54(6):563-8, 2012
9. Acosta FL Jr et al: Neurocutaneous melanosis presenting with hydrocephalus. Case report and review of the literature. J Neurosurg. 102(1 Suppl):96-100, 2005

https://CafePezeshki.IR

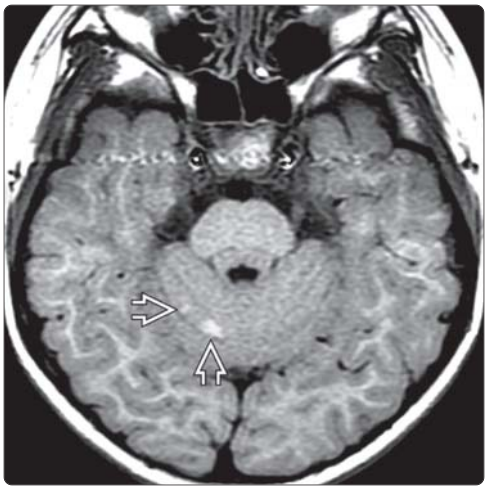

(Left) *Axial T1WI MR of a 4-year-old child with neurocutaneous melanosis (NCM) reveals 2 small deposits ➡ of T1-hyperintense melanin on the surface of the right cerebellar hemisphere.* **(Right)** *Axial T1WI MR shows foci of intrinsic high signal intensity ➡ in 2 regions of the cerebral cortex, representing cortical melanosis in the setting of NCM. These lesions are stable over the short term and do not appreciably change after administration of paramagnetic contrast.*

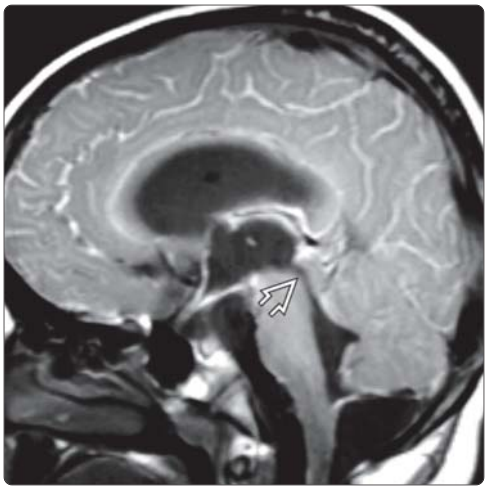

(Left) *Axial T1 C+ MR shows diffuse neurocutaneous melanosis in a 6-year-old child. The pial melanosis involves virtually the entire surface of the brain and enhances strongly and uniformly. Moderate to severe lateral ventriculomegaly is evident.* **(Right)** *Sagittal T1WI MR in the same patient reveals patent aqueduct of Sylvius ➡ and enlarged basilar cisterns. Thus, the hydrocephalus is of the extraventricular obstructive type. Diffusely abnormal leptomeningeal enhancement is evident.*

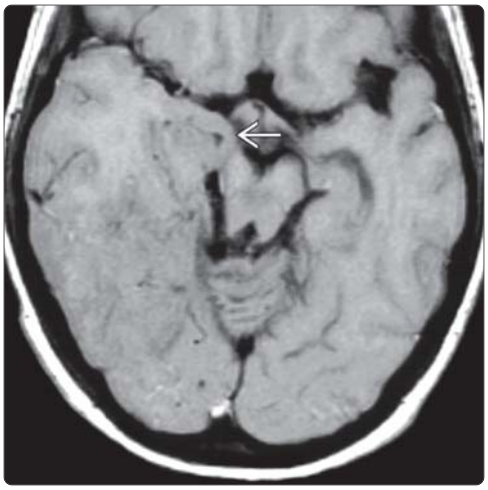

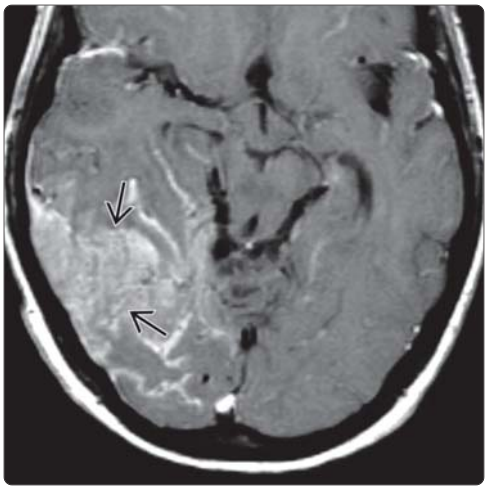

(Left) *Axial T1WI MR shows significant mass effect in the right posterior temporal and occipital lobes with effacement of the surface sulci. The uncus is herniated ➡. Only minimal hyperintensity is evident. Surgery disclosed extensive melanosis that had invaded the brain via the perivascular spaces.* **(Right)** *Axial T1WI C+ MR in the same patient shows a strongly enhancing superficial mass ⇨ that fills the adjacent sulci and extends deeply into the underlying brain parenchyma.*

https://CafePezeshki.IR

KEY FACTS

TERMINOLOGY

- Classic triad of callosal dysgenesis, infantile spasms, and chorioretinal lacunae but more complex with other major features

IMAGING

- Callosal agenesis: Complete (70%), partial (30%)
- Polymicrogyria: Frontal or perisylvian (~ 100%)
- Heterotopia: Periventricular (100%), subcortical (30%)
- Intracranial cysts: Midline > intraventricular; other extraaxial sites; choroid plexus; intraparenchymal
- Ocular coloboma
- Choroid plexus papillomas
- Hemispheric asymmetry
- Hypoplastic/dysplastic cerebellar hemispheres or vermis

TOP DIFFERENTIAL DIAGNOSES

- Congenital toxoplasmosis
- Congenital CMV

PATHOLOGY

- Females; males with chromosome 47 XXY
  - Probably de novo mutation on X chromosome
  - Dominant inheritance; hemizygous lethality in males

CLINICAL ISSUES

- Infantile spasms or other early-onset epilepsy, typically poorly controlled
- Chorioretinal lacunae: Only true pathognomonic feature (may be unilateral)
- 91% function at < 1-year level, 21% able to walk, 4% able to communicate
- Many need surgery for scoliosis

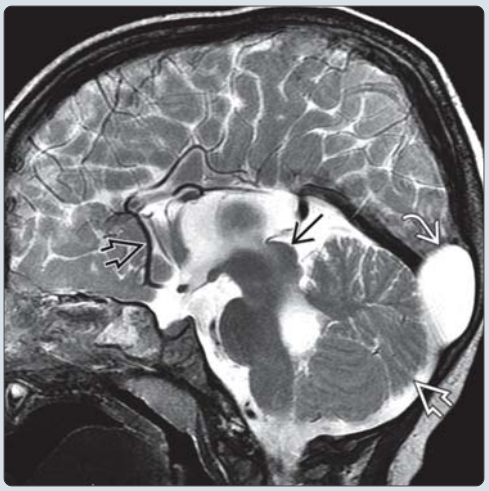

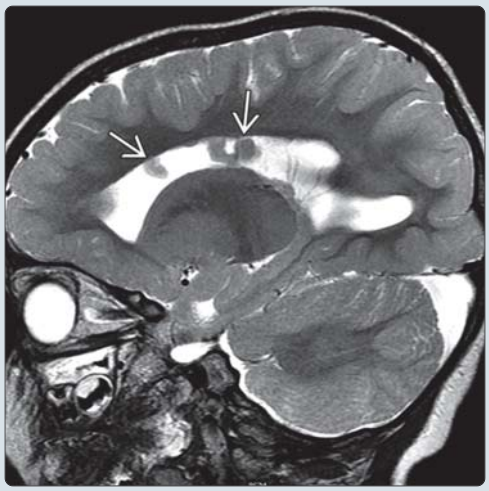

(Left) *Sagittal T2FS MR scan in a 4-year-old female with known Aicardi syndrome and coloboma with chorioretinal lacunae shows near complete agenesis of the corpus callosum with an azygous ACA ⇨. A retrocerebellar cyst ⇨ with elevation of the torcular is present. The vermis ⇨ and tectum ⇨ appear dysplastic.* **(Right)** *More lateral T2FS MR in the same patient shows multiple nodules of heterotopic gray matter ⇨ protruding into the lateral ventricle.*

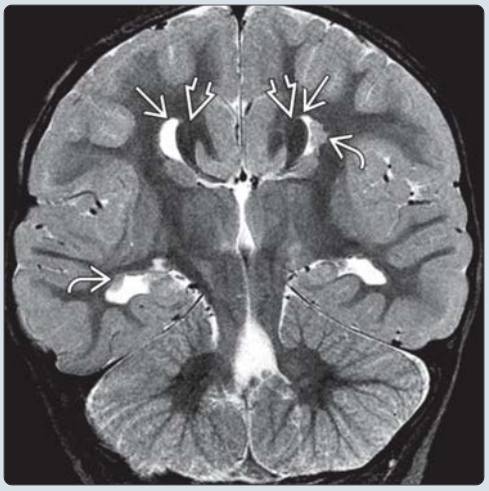

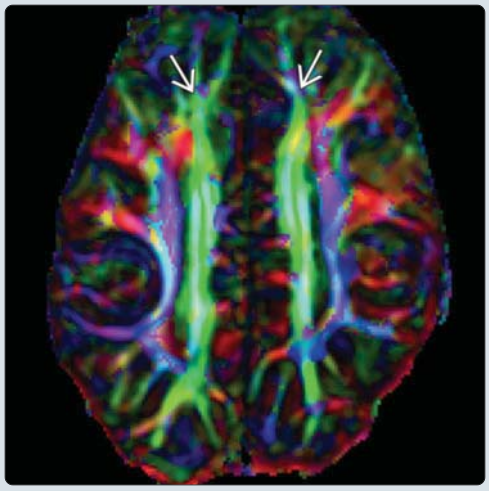

(Left) *Coronal T2FS scan in the same patient shows the characteristic "Viking helmet" ⇨ of corpus callosum dysgenesis. Prominent heavily myelinated Probst bundles ⇨ are present, as are multiple nodules of periventricular heterotopic gray matter ⇨.* **(Right)** *Axial color DTI in the same patient shows the prominent, parallel, and nonconverging Probst bundles in green ⇨.*

https://CafePezeshki.IR

TERMINOLOGY

Abbreviations

- Aicardi (AIC) syndrome

Definitions

- Classic triad of callosal dysgenesis, infantile spasms, and chorioretinal lacunae

IMAGING

General Features

- Best diagnostic clue
  - Major features
    - Callosal agenesis: Complete (70%), partial (30%)
    - Polymicrogyria: Frontal or perisylvian (~ 100%)
    - Heterotopia: Periventricular (100%), subcortical (30%)
    - Intracranial cysts: Midline > intraventricular; other extraaxial sites; choroid plexus; intraparenchymal
    - Ocular coloboma
    - Choroid plexus papillomas
  - Supporting features
    - Vertebral or rib abnormalities
    - Microphthalmia
    - Hemispheric asymmetry
  - Other reported CNS imaging findings
    - Hypoplastic/dysplastic cerebellar hemispheres or vermis
    - Enlarged cisterna magna
    - Increased tectal size
    - Optic nerve hypoplasia
    - Delayed myelination

Imaging Recommendations

- Best imaging tool
  - MR
- Protocol advice
  - Volumetric T1 in myelinated brains
  - High resolution T2 in infants
  - Contrast to diagnose choroid plexus papillomas

CT Findings

- NECT
  - No calcifications

DIFFERENTIAL DIAGNOSIS

Congenital Toxoplasmosis

- Calcifications, no polymicrogyria or heterotopia

Congenital Cytomegalovirus

- Calcifications, no heterotopia

Other Genetic Syndromes

- Microphthalmia with linear skin defects (MLS) shares some features, but eye lesions are not lacunae

PATHOLOGY

General Features

- Etiology
  - Unknown
- Genetics
  - Females; males with chromosome 47 XXY
    - Probably de novo mutation on X chromosome
    - Dominant inheritance; hemizygous lethality in males
- Associated abnormalities
  - Scoliosis secondary to costovertebral anomalies, often requiring surgery
  - ± distinct facial phenotype, ~ 25% microphthalmia
  - ± cleft lip and palate
  - Probable increased incidence of benign and malignant extra-CNS tumors
  - Probable increased incidence of vascular malformations/tumors

CLINICAL ISSUES

Presentation

- Most common signs/symptoms
  - Infantile spasms or other early onset epilepsy, typically poorly controlled
  - Chorioretinal lacunae: Only true pathognomonic feature (may be unilateral)
  - Majority have severe psychomotor retardation

Demographics

- Age
  - Most present in infancy; range is 3 days to 12 years
- Gender
  - Female almost exclusively, rare male 47 XXY
- Epidemiology
  - Early lethality in males → spontaneous abortion
  - Almost exclusively female after 2nd trimester

Natural History & Prognosis

- Median age of survival 18.5 ± 4 years

Treatment

- Symptomatic only

SELECTED REFERENCES

1. Lund C et al: Aicardi syndrome: an epidemiologic and clinical study in Norway. Pediatr Neurol. 52(2):182-6.e3, 2015
2. Crow YJ et al: Characterization of human disease phenotypes associated with mutations in TREX1, RNASEH2A, RNASEH2B, RNASEH2C, SAMHD1, ADAR, and IFIH1. Am J Med Genet A. 167A(2):296-312, 2015
3. Cuadrado E et al: Phenotypic Variation in Aicardi-Goutières Syndrome Explained by Cell-Specific IFN-Stimulated Gene Response and Cytokine Release. J Immunol. 194(8):3623-33, 2015
4. Kasasbeh AS et al: Palliative epilepsy surgery in Aicardi syndrome: a case series and review of literature. Childs Nerv Syst. 30(3):497-503, 2014
5. Pires CR et al: Aicardi syndrome: Neonatal diagnosis by means of transfontanellar ultrasound. World J Radiol. 6(7):511-4, 2014
6. Shetty J et al: Aicardi syndrome in a 47 XXY male - a variable developmental phenotype? Eur J Paediatr Neurol. 18(4):529-31, 2014
7. Steffensen TS et al: Cerebellar migration defects in aicardi syndrome: an extension of the neuropathological spectrum. Fetal Pediatr Pathol. 28(1):24-38, 2009
8. Hopkins B et al: Neuroimaging aspects of Aicardi syndrome. Am J Med Genet A. 146A(22):2871-8, 2008
9. Glasmacher MA et al: Phenotype and management of Aicardi syndrome: new findings from a survey of 69 children. J Child Neurol. 22(2):176-84, 2007
10. Grosso S et al: Aicardi syndrome with favorable outcome: case report and review. Brain Dev. 29(7):443-6, 2007
11. Palmér L et al: Aicardi syndrome: presentation at onset in Swedish children born in 1975-2002. Neuropediatrics. 37(3):154-8, 2006
12. Aicardi J: Aicardi syndrome. Brain Dev. 27(3):164-71, 2005

https://CafePezeshki.IR

KEY FACTS

TERMINOLOGY

- Li-Fraumeni syndrome (LFS)
- Autosomal dominant familial cancer syndrome
  - 75% of LFS have loss of function mutations in *TP53* tumor suppressor gene
  - Lifelong ↑ risk of osteosarcoma, soft tissue sarcoma, leukemia, breast cancer, brain tumors, melanoma, adrenal cortical tumors

IMAGING

- Astrocytoma: Cerebrum > cerebellum > spine
- Choroid plexus carcinoma: Lateral ventricle > > 4th ventricle

TOP DIFFERENTIAL DIAGNOSES

- Hereditary syndromes causing familial cancers, including brain tumors
- Tuberous sclerosis
- von Hippel-Lindau
- Medulloblastoma
- Basal cell nevus syndrome
- Turcot
- Neurofibromatosis type 1
- Carney complex
- Melanoma-astrocytoma syndrome

PATHOLOGY

- p53: Transcription factor important in apoptosis, cell cycle control; frequently mutated in tumors
- Breast cancer (24-30%), soft tissue sarcoma (12-18%), brain tumors (12-14%), bone sarcoma (12-13%), adrenocortical carcinoma (6%)

CLINICAL ISSUES

- Propensity to develop additional primary neoplasms
- BTs: High prevalence below 10 years of age

(Left) *A 38-year-old female with a history of breast cancer presented to the ER with several months of increasingly severe headache and visual difficulties. NECT scan shows a large hyperdense mass ⇨ in the right occipital region.* **(Right)** *Axial T1 C+ FS in the same patient shows a large, intensely enhancing right occipital mass ⇨.*

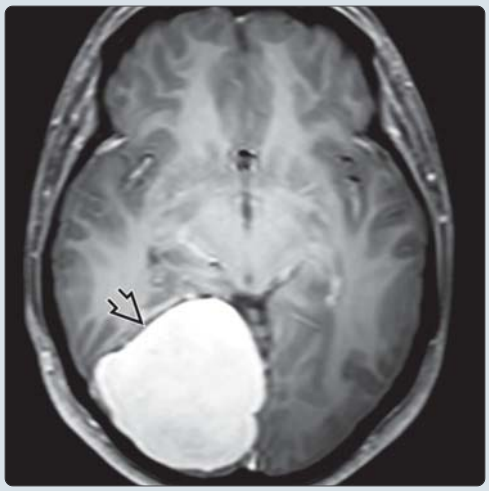

(Left) *Sagittal T1 C+ FS MR shows the well-demarcated, intensely enhancing mass ⇨ abuts the dura.* **(Right)** *Axial presurgical contrast-enhanced SPGR shows a subtle dural "tail" along the tentorium cerebelli ⇨. Preoperative diagnosis of meningioma was confirmed at surgery. Further evaluation disclosed TP53 germline mutation and Li-Fraumeni syndrome (LFS) was diagnosed.*

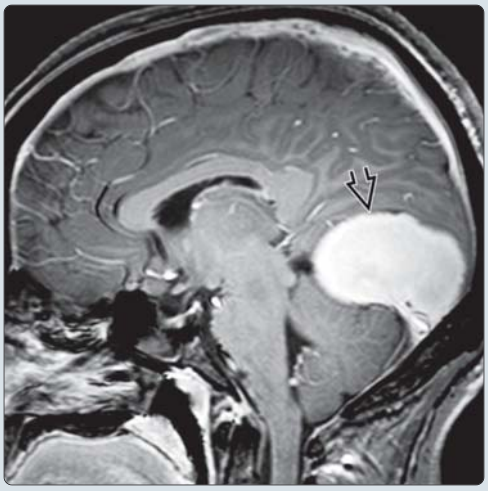

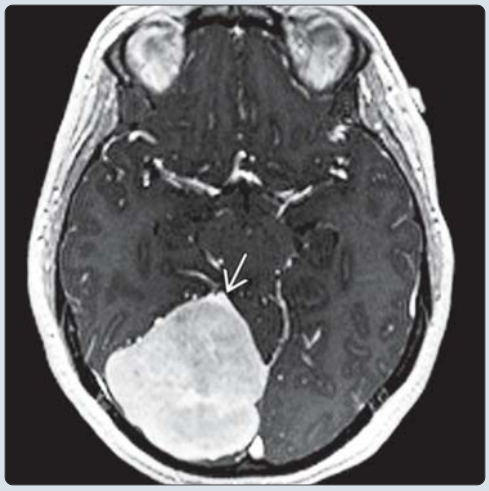

https://CafePezeshki.IR

TERMINOLOGY

Abbreviations

- Li-Fraumeni syndrome (LFS)
- Li-Fraumeni-like (LFL) syndromes

Synonyms

- Sarcoma, breast, leukemia, and adrenal syndrome

Definitions

- Autosomal dominant familial cancer syndrome
  - Lifelong ↑ risk of osteosarcoma, soft tissue sarcoma, leukemia, breast cancer, brain tumors, melanoma, adrenal cortical tumors
  - 75% of LFS have loss of function mutations in *TP53* tumor suppressor gene

IMAGING

General Features

- Best diagnostic clue
  - CNS tumor in child with 2 1st- and 2nd-degree relatives with cancer
- Location
  - Astrocytoma: Cerebrum > cerebellum > spine
  - Choroid plexus carcinoma (CPC): Lateral ventricle > > 4th ventricle

Imaging Recommendations

- Best imaging tool
  - MR with contrast

DIFFERENTIAL DIAGNOSIS

Hereditary Syndromes Causing Familial Cancers, Including Brain Tumors

- Neurofibromatosis type 1
  - Neurofibroma, optic glioma, astrocytoma
  - Rhabdomyosarcoma, parathyroid adenoma, pheochromocytoma, others
- Tuberous sclerosis
  - Ependymoma, giant cell astrocytoma
  - Renal angiomyolipoma/carcinoma
- von Hippel-Lindau
  - Hemangioblastoma (cerebellum, spinal cord)
  - Hemangioblastoma (pancreas, kidney); renal cell carcinoma, pheochromocytoma, papillary cystadenoma (epididymis)
- Basal cell nevus syndrome
  - Medulloblastoma
  - Basal cell nevi/carcinoma, ovarian carcinoma
- Carney complex
  - Melanotic schwannoma
  - Myxoma (eyelid, atrium), Sertoli cell tumor, pheochromocytoma, pituitary adenoma
- Melanoma-astrocytoma syndrome
  - Cerebral astrocytoma, other CNS tumors
  - Cutaneous malignant melanoma
- Turcot
  - Medulloblastoma, glioblastoma multiforme, astrocytoma, ependymoma
  - Colon cancer, basal cell carcinoma, gastric cancer

PATHOLOGY

General Features

- Etiology
  - Mutation in *TP53* suppressor gene (17p13); AD

Staging, Grading, & Classification

- LFS diagnostic clinical criteria
  - Proband with sarcoma diagnosed < 45 years **and** 1st- or 2nd-degree relative with any cancer diagnosed < 45 years or any sarcoma at any age
  - Or: Proband with multiple tumors (except multiple breast), 2 of which are in LFS spectrum, and 1st occurred ≤ 46 years
  - Or: Childhood adrenocortical carcinoma (50-100% have underlying *TP53* germline mutation); other suggestive tumors include choroid plexus carcinoma, rhabdomyosarcoma, or multiple childhood cancers
- LFL: 3 different schemes; most predictive is Chompet
  - Proband with sarcoma, brain tumor, breast cancer, or adrenocortical carcinoma (ACC) < 36 years
  - **And** 1 1st- or 2nd-degree relative with cancer < 46 years
  - **Or** proband with multiple primary tumors, 2 of which are sarcoma, brain tumor, breast cancer, or ACC

Gross Pathologic & Surgical Features

- Breast cancer (24-30%), soft tissue sarcoma (12-18%), BT (12-14%), bone sarcoma (12-13%), ACC (6%)
- Less frequent tumors: Lung, hematopoietic system, stomach, colorectum, skin, ovary

Microscopic Features

- Astrocytoma (50%), CPC (15%)
- Medulloblastoma, PNET less common

CLINICAL ISSUES

Demographics

- Age
  - BTs: High prevalence below 10 years of age
- Epidemiology
  - LFS 50% chance of cancer by age 40, 90% by age 60
  - Females 93% lifetime cancer risk, males 75%

Natural History & Prognosis

- Propensity to develop additional primary neoplasms

Treatment

- Total resection of tumors ± chemotherapy
- Avoid radiation: Risk of radiation-induced tumors

DIAGNOSTIC CHECKLIST

Consider

- Nearly all CPC have p53 germline mutations

SELECTED REFERENCES

1. Schlegelberger B et al: A child with Li-Fraumeni syndrome: Modes to inactivate the second allele of TP53 in three different malignancies. Pediatr Blood Cancer. ePub, 2015
2. Monsalve J et al: Imaging of cancer predisposition syndromes in children. Radiographics. 31(1):263-80, 2011

https://CafePezeshki.IR

KEY FACTS

IMAGING

- Multiple circumscribed, encapsulated masses following course of cranial or peripheral nerves **without** involvement of CN8
- MR C+ is mainstay of schwannomatosis imaging

TOP DIFFERENTIAL DIAGNOSES

- Neurofibromatosis type 2
- Sporadic schwannoma
- Neurofibromatosis type 1
- Sporadic neurofibroma

PATHOLOGY

- Germline mutation of *SMARCB1* gene
  - *SMARCB1* mutation is **not** found in sporadic (nonsyndromic schwannomas)
  - *SMARCB1* mutation is **not** found in NF2

CLINICAL ISSUES

- Incidence thought to be similar to NF2 (~ 1/40,000)
- Typically presents with pain, which may be disabling
  - In contradistinction to NF2, which more frequently presents with neurologic deficits
- Peak incidence between ages 30-60
  - Contrast with NF1 (typically diagnosed in 1st decade)
  - Contrast with NF2 (typically diagnosed in 2nd decade)
- **Normal** life expectancy
  - Contrast with NF2 (↓ life expectancy)

DIAGNOSTIC CHECKLIST

- In patient > 30 years of age
  - With **multiple nonvestibular schwannomas**
    - Consider diagnosis of schwannomatosis
    - **And** recommend high-resolution MR imaging of temporal bones/internal auditory canals to screen for NF2

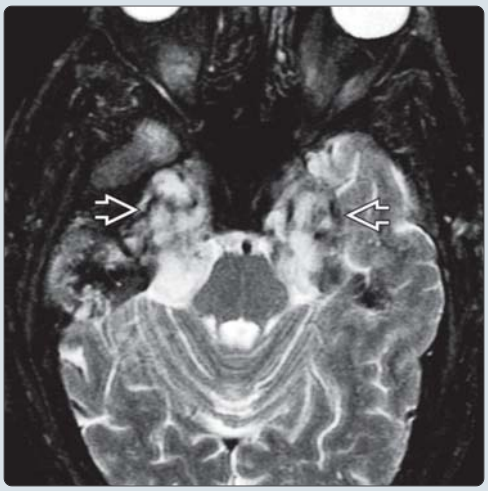

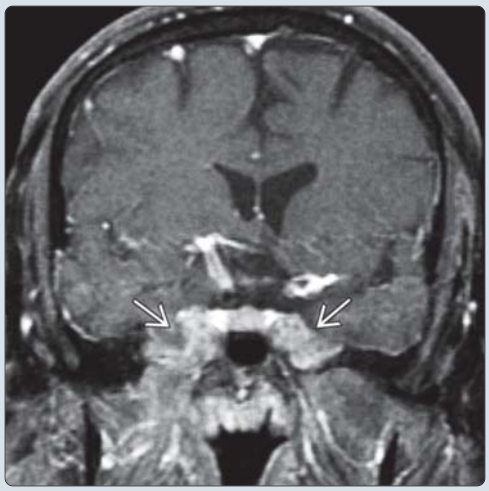

(Left) *Axial T2WI MR of a 47-year-old man with schwannomatosis reveals bulky, fusiform enlargement of the bilateral trigeminal nerves ⇨, which demonstrate heterogeneous increased T2 signal and exert mass effect on the pons without associated signal abnormality.* **(Right)** *Coronal T1WI C+ FS MR of the same patient reveals enhancing, globular masses ⇨ involving the bilateral trigeminal ganglia, which extend into the infrazygomatic masticator spaces via widened foramina ovale. IACs (not shown) were normal.*

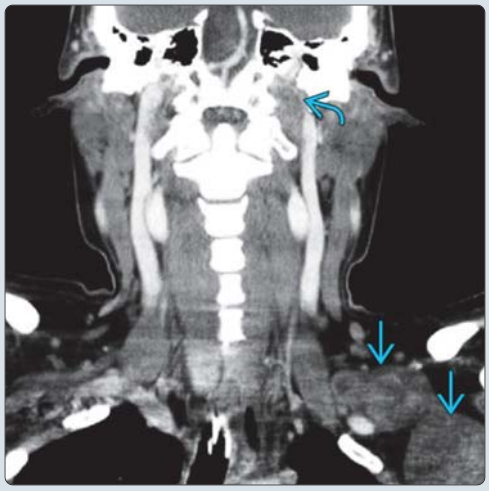

(Left) *Axial CECT of the neck in a 31-year-old woman with schwannomatosis shows a circumscribed, encapsulated, heterogeneously enhancing, submucosal mass ⇨ in the supraglottic larynx, which nearly completely effaces the laryngeal airway.* **(Right)** *Coronal reconstruction reveals additional heterogeneous density masses involving the left brachial plexus ⇨ and jugular foramen ⇨, compatible with numerous schwannomas in this patient with schwannomatosis.*

https://CafePezeshki.IR

TERMINOLOGY

Definitions

- Schwannomatosis: Multiple schwannomas of peripheral nervous system **without** involvement of vestibular nerves

IMAGING

General Features

- Best diagnostic clue
  - Multiple circumscribed, encapsulated masses following course of cranial or peripheral nerves **without** involvement of CN8

CT Findings

- NECT
  - Iso- to slightly hyperdense compared to brain
  - Look for effect on adjacent bone, foramina
    - Smooth enlargement
    - Thin, sclerotic,"surgical"-appearing margins
- CECT
  - Variable, often heterogenous enhancement

MR Findings

- Variable signal intensity on all sequences due to varying amounts of Antoni A and Antoni B regions
- Hyperintense on T2WI, PD, FLAIR, and STIR
- Intense, typically heterogeneous enhancement on T1WI C+

Imaging Recommendations

- Best imaging tool
  - MR C+ is mainstay of schwannomatosis imaging

PATHOLOGY

General Features

- Genetics
  - Complex, incompletely understood genetics involving germline involvement of *SMARCB1* gene, which is **NOT** found in sporadic, nonsyndromic schwannomas
    - Tumor supressor gene found on chromosome 22
    - Likely involves multi-hit mutation phenomenon involving *SMARCB1* and *NF2* genes in affected tissues

Staging, Grading, & Classification

- **Baseline criteria** (all 4 must be met)
  - Patients must not fulfill any existing sets of diagnostic criteria for NF2
  - No evidence of vestibular schwannoma on MR
  - No 1st-degree relative with NF2
  - No known constitutional *NF2* gene mutation
- **Definite** diagnosis
  - Age > 30 **AND** 2 or more nonintradermal schwannomas (1 histologically proven); **OR** 1 pathologically confirmed schwannoma **AND** 1st-degree relative meeting diagnostic criteria
- **Possible** diagnosis
  - Age < 30 **AND** 2 or more nonintradermal schwannomas (1 histologically proven); **OR** age > 45 **AND** 2 or more nonintradermal schwannomas (1 histologically proven); **OR** radiologic evidence of schwannoma **AND** 1st-degree relative meeting criteria for definite diagnosis
- **Segmental** schwannomatosis
  - Meets criteria for definite or possible schwannomatosis, but confined to 1 limb or 5 or fewer contiguous spinal elements

CLINICAL ISSUES

Presentation

- Most common signs/symptoms
  - Pain, typically neuropathic in quality; may be disabling
    - In contradistinction to NF2, which more frequently presents with neurologic deficits
  - Symptom onset typically in 2nd or 3rd decade of life
    - Compared to NF1 (1st decade) and NF2 (2nd decade)

Demographics

- Epidemiology
  - Reported incidence ranges from 1/40,000 to 1/1.7 million, probably closer to 1/40,000 (similar to NF2)

Natural History & Prognosis

- **NORMAL** life expectancy, unlike NF2 patients who have reduced life expectancy

Treatment

- Symptom control with pain management
- Surgical intervention only if spinal cord compression or symptoms clearly due to schwannoma
- No role for radiation therapy; evolving role of chemotherapy

DIAGNOSTIC CHECKLIST

Consider

- Patient may have schwannomatosis if
  - Age > 30
  - > 1 schwannoma
  - No vestibular schwannoma

Image Interpretation Pearls

- **DO NOT** favor diagnosis of schwannomatosis in patient younger than age 30 as vestibular schwannomas may not yet have developed
  - As patient age at time of diagnosis ↑, likelihood of schwannomatosis ↑ & likelihood of NF2 ↓

Reporting Tips

- In patient > 30 years of age, presence of multiple nonvestibular schwannomas should prompt radiologist to suggest diagnosis of schwannomatosis, as well as recommend high-resolution MR imaging of temporal bones/IACs to screen for NF2

SELECTED REFERENCES

1. Asai K et al: Familial schwannomatosis with a germline mutation of SMARCB1 in Japan. Brain Tumor Pathol. 32(3):216-220, 2015
2. Ioannidis P et al: Expanding schwannomatosis phenotype. J Neurooncol. 122(3):607-9, 2015
3. Koontz NA et al: Schwannomatosis: the overlooked neurofibromatosis? AJR Am J Roentgenol. 200(6):W646-53, 2013
4. Plotkin SR et al: Update from the 2011 International Schwannomatosis Workshop: from genetics to diagnostic criteria. Am J Med Genet A. 161(3):405-16, 2013
5. Hulsebos TJ et al: SMARCB1/INI1 maternal germ line mosaicism in schwannomatosis. Clin Genet. 77(1):86-91, 2010
6. Baser ME et al: Increasing the specificity of diagnostic criteria for schwannomatosis. Neurology. 66(5):730-2, 2006

https://CafePezeshki.IR

This page intentionally left blank

https://CafePezeshki.IR

PART I
SECTION 2

Trauma

Introduction to CNS Imaging, Trauma 134

Primary Effects of CNS Trauma

Scalp and Skull Injuries 140
Missile and Penetrating Injury 144
Epidural Hematoma, Classic 148
Epidural Hematoma, Variant 152
Acute Subdural Hematoma 156
Subacute Subdural Hematoma 160
Chronic Subdural Hematoma 164
Traumatic Subarachnoid Hemorrhage 168
Cerebral Contusion 172
Diffuse Axonal Injury 176
Subcortical Injury 180
Pneumocephalus 184
Abusive Head Trauma 188

Secondary Effects of CNS Trauma

Intracranial Herniation Syndromes 192
Post-Traumatic Brain Swelling 196
Traumatic Cerebral Ischemia/Infarction 200
Brain Death 204
Second Impact Syndrome 206
Traumatic Intracranial Arterial Dissection 208
Traumatic Carotid Cavernous Fistula 212
Chronic Traumatic Encephalopathy 214

https://CafePezeshki.IR

Approach to Head Trauma

General Considerations

Epidemiology: Trauma is the most common worldwide cause of death and disability in children and young adults. In these patients, neurotrauma is responsible for the vast majority of cases. In the USA and Canada, emergency departments (ED) treat more than 8 million patients with head injuries annually, representing 6-7% of all ED visits.

The vast majority of patients with head trauma are classified as having minimal or minor injury. Minimal head injury is defined as no neurologic alteration or loss of consciousness (LOC). Minor head injury or concussion is epitomized by a walking, talking patient with a Glasgow Coma Score (GCS) of 13-15 who has experienced LOC, amnesia, or disorientation.

Of all head-injured patients, ~ 10% sustain fatal brain injury whereas another 5-10% of neurotrauma survivors have permanent serious neurologic deficits. A number have more subtle deficits ("minimal brain trauma"), whereas 20-40% of patients have moderate disability.

Etiology and Mechanisms of Injury

The etiology of traumatic brain injury (TBI) varies according to patient age. Falls are the leading cause of TBI in children younger than 4 years and in elderly patients older than 75 years. Gunshot wounds are most common in adolescent and young adult males but relatively rare in other groups. Motor vehicle and auto-pedestrian collisions occur at all ages without gender predilection.

TBI can be a missile or nonmissile injury. Missile injury results from penetration of the skull, meninges, &/or brain by an external object (such as a bullet).

Nonmissile closed head injury (CHI) can be caused by direct blows or penetrating injuries. However, nonmissile CHI is a more common cause of neurotrauma. High-speed accidents exert significant acceleration/deceleration forces, causing the brain to move suddenly within the skull. Forcible impaction of the brain against the unyielding calvaria and hard, knife-like dura results in gyral contusion. Rotation and abrupt changes in angular momentum may deform, stretch, and damage long vulnerable axons, resulting in axonal injury.

Classification of Head Trauma

The most widely used **clinical** classification of brain trauma, the GCS, depends on the assessment of 3 features: Best eye, verbal, and motor responses. Using the GCS, TBI can be designated as mild (13-15), moderate (9-12), or severe (≤ 8).

TBI can also be divided pathoetiologically into primary and secondary injuries. Primary injuries occur at the time of initial trauma. Skull fractures, epi- and subdural hematomas, contusion, and axonal injuries are examples of primary traumatic injuries.

Secondary injuries occur later and include cerebral edema, perfusions, and brain herniations. Large arteries, such as the internal carotid, vertebral, and middle meningeal arteries, can be injured either directly at the time of initial trauma or indirectly as a complication of brain herniations.

How to Image Acute Head Trauma

Imaging is absolutely critical to the diagnosis and management of the patient with acute TBI. The goal of emergent imaging is 2-fold: (1) identify treatable injuries and (2) detect and delineate the presence of secondary injuries, such as herniation syndromes.

MDCT: Multidetector row CT (MDCT) is the "workhorse" of brain trauma imaging and is also used as a screening procedure in a wide variety of clinical settings. Whenever possible, helically acquired, thin-section, nonenhanced CT scans from the foramen magnum to the vertex with both soft tissue and bone algorithm should be obtained. Coronal and sagittal images reformatted from the axial source data are extremely helpful, especially in detecting thin peritentorial subdural hematomas. "Subdural" windowing (e.g., window width of 150-200 HU) of the soft tissue images on PACS (or film, if PACS is not available) is also highly recommended. The scout view should always be displayed and evaluated as part of the study.

Whole-body, CT-based studies for patients with multiple traumas are becoming increasingly more common. Soft tissue and bone algorithm reconstructions with multiplanar (usually coronal and sagittal) reformatted images of the spine are often included as part of the initial trauma evaluation.

CTA: CT angiography (CTA) is an appropriate modality in the setting of penetrating neck injury, cervical fracture/subluxation, skull base fractures that traverse the carotid canal or a dural venous sinus, and suspected vascular dissections.

MR: MR is generally a secondary modality most often used in the late acute or subacute stages of brain injury. It is helpful in detecting focal/regional/global perfusion alterations, assessing the extent of hemorrhagic and nonhemorrhagic injuries, and assisting in long-term prognosis. MR should also be considered if nonaccidental trauma is suspected either clinically or on the basis of initial CT scan findings.

Who and When to Image?

Many clinical studies have attempted to determine whom to image and when. Three major and widely used appropriateness criteria for imaging acute head trauma have been published: The American College of Radiology (ACR) Appropriateness Criteria, the New Orleans Criteria (NOC), and the Canadian Head CT Rule (CHCR).

The American College of Radiology has delineated and published updated appropriateness criteria for imaging head trauma. Emergent NECT in mild/minor CHI with the presence of a focal neurologic deficit &/or other risk factors is deemed very appropriate, as is imaging all traumatized children under 2 years of age.

Between 6-7% of patients with minor head injury have positive findings on head CT scans; most also have headache, vomiting, drug or alcohol intoxication, seizure, short-term memory deficits, or physical evidence of trauma above the clavicles. CT should be used liberally in these cases as well as in patients over 60 years of age and in children under the age of 2.

Repeat CT of patients with head injury should be obtained if there is sudden clinical deterioration, regardless of initial imaging findings. Delayed development or enlargement of both extra- and intraaxial hemorrhages typically occurs within 36 hours following the initial traumatic event.

Approach to Skull Base and Facial Trauma

Fractures involving the base of the skull (BOS) range from a solitary linear fracture to complex injuries involving the craniofacial bones. BOS fractures are often associated with intracranial injuries, such as cerebral contusion, intra- and

https://CafePezeshki.IR

extraaxial hemorrhages, and vascular or cranial nerve injuries. The objective of imaging patients with BOS &/or facial trauma is to depict the location and extent of the fractures and identify associated injuries to vital structures. Accurate imaging interpretation also aids in surgical planning and in the prevention of complications, such as CSF leak.

Skull Base Trauma

Anterior skull base (ASB) fractures: ASB trauma is frequently associated with sinonasal cavity &/or orbital injuries. The majority of these patients have facial fractures. Imaging should determine if the fractures cross the cribriform plate, traverse the frontal sinuses, and involve the orbital apex or optic canals.

Central skull base (CSB) fractures: Imaging patients with CSB trauma may involve the sphenoid bone, clivus, cavernous sinuses, and carotid canal. Injury to the internal carotid artery and CN 3, 4, 6 &/or the trigeminal nerve divisions can be present.

Temporal bone (T-bone) fractures: T-bone fractures can be oriented parallel (longitudinal) or perpendicular (transverse) to the petrous ridge. Longitudinal fractures are more common and traverse the mastoid and middle ear cavity, often disrupting the ossicles and extending into the squamous portion of the T-bone. Transverse fractures often cross the inner ear and extend into the occipital bone.

Imaging evaluation should include the determination of ossicular chain integrity, inner ear &/or facial nerve canal involvement, and whether the T-bone tegmen (roof) is transgressed.

Posterior skull base (PSB) fractures: Fractures of the occipital bones may be isolated or associated with transverse petrous T-bone fractures. PSB fractures may extend into the transverse or sigmoid sinuses, jugular foramen, or hypoglossal canal. Craniocervical junction injuries are also common in patients with trauma to the PSB.

Facial Trauma

Orbit fractures: There are 2 types of orbit fractures: (1) those that involve the orbital walls/rim and (2) so-called blowout fractures. Blowout fractures may involve the orbital floor (inferior blowout) or ethmoid (medial blowout), but the rim is intact. Imaging should determine if (1) there are other orbital or facial fractures and (2) whether there is entrapment of the inferior ± medial rectus muscles and fat.

Facial bone (Le Fort) fractures: There are 3 types of Le Fort fractures. Le Fort I is a horizontal fracture through the maxilla that involves the piriform aperture. Le Fort II is a pyramidal fracture that involves the nasofrontal junction, infraorbital rims, medial orbital walls, orbital floors, and the zygomaticomaxillary suture lines.

Le Fort III, a.k.a. craniofacial separation, consists of nasofrontal junction fractures that extend laterally through the orbital walls and zygomatic arches.

All 3 Le Fort fractures involve the pterygoid plates and often exhibit elements of more than 1 type of facial bone fracture.

Zygomaticomaxillary fractures: The prominent position of the zygomatic arch renders it susceptible to trauma. A zygomaticomaxillary complex (ZMC) fracture, formerly referred to as a "tripod fracture," has 4 involved articulations and 5 distinct fractures.

Imaging in ZMC fractures should determine how displaced/comminuted the fracture is, whether there is involvement of the orbital floor/apex &/or lamina papyracea, and how the lateral orbital wall is displaced.

Complex midfacial fracture: Complex midfacial fracture, or "facial smash injury," consists of multiple facial fractures that cannot be classified as 1 of the named patterns. It is important to determine the posterior displacement of the midface, as this is a highly cosmetically deforming injury. Associated injuries to the orbit &/or skull face must be delineated in detail.

Nasoorbitoethmoid (NOE) fracture: NOE fractures may disrupt the medial canthal tendon and extend into the lacrimal apparatus. Displacement or comminution of the bony fragments posteriorly into the ethmoid or superiorly into the anterior fossa should be identified.

Mandible fracture: Mandibular fractures can occur within or posterior to the teeth. The mandible essentially functions as a "ring of bone" and multiple, often bilateral, fractures are common. The fractures should be located, the degree/direction of fragment displacement identified, and the condyles evaluated for subluxation or dislocation. Involvement of the inferior alveolar canal and teeth should be determined.

Approach to Spine and Cord Trauma

Imaging Acute Spine Injuries

While radiographs are still used for evaluating the spine, MDCT has become the procedure of choice in rapidly assessing patients with possible spine injuries. In patients with moderate to severe injuries, obtaining large datasets that are subsequently parsed into C-, T-, and L-spine studies together with chest, abdomen, and pelvis is increasingly common.

Thin section axial images are easily reformatted into sagittal and coronal views. Both bone algorithm and soft tissue reconstructions are typically performed. CTA is a helpful adjunct if vascular injury is a risk (BOS fractures that cross carotid canal or dural venous sinus, cervical spine fractures that traverse foramen transversarium, posterior element subluxation, etc.). Emergent MR imaging is especially helpful in patients with suspected ligamentous complex damage, traumatic disc herniation, or cord injury.

Spine Fracture Classification

Craniovertebral junction: Initial evaluation in patients with suspected craniovertebral junction (CVJ) injury should begin with a focus on identification of craniocervical malalignment followed by delineation of specific fractures. These are classified by level and type of injury as well as potential for instability. Although an exhaustive description is beyond the scope of this text, a few selected fractures are briefly delineated here.

C1 fractures often involve the posterior arch. A Jefferson fracture is a vertical compression fracture in which both the anterior and posterior rings are disrupted and displaced radially. A combined lateral mass displacement (relative to C2 lateral masses) of ~ 7 mm indicates disruption of the transverse ligament and potential instability.

Odontoid fractures are classified anatomically into 3 types: Type I = avulsed tip, type II = transverse dens fracture above the C2 body, and type III fractures involve the superior portion

https://CafePezeshki.IR

New Orleans Criteria in Minor Head Injury

CT Indicated if GCS = 15 Plus Any of the Following
Headache
Vomiting
Patient > 60 years
Intoxication (drugs, alcohol)
Short-term memory deficits (anterograde amnesia)
Visible trauma above clavicles
Seizure

Thoracolumbar Injury Severity Score

	Description	Qualifier	Points
Injury Mechanism			
	Compression		
		Simple	1
		Lateral angulation > 15°	1
		Burst	1
	Translation/rotational		3
	Distraction		4
Posterior Ligamentous Complex			
	Intact		0
	Suspected/indeterminate for disruption		2
	Injured		3
Neuro Status			
	Nerve root involvement		2
	Cord, conus involvement (incomplete)		3
	Cord, conus involvement (complete)		2
	Cauda equina involvement		3

Score is a total of 3 components. Score ≤ 3 suggests nonoperative treatment, whereas score of 4 is indeterminate. Score ≥ 5 suggests operative treatment. For injury mechanism, the worst level is used and the injury is additive. An example is a distraction injury with burst without angulation is 1 (simple compression) + 1 (burst) + 4 (distraction) = 6 points. Modified from Vaccaro AR et al: Reliability of a novel classification system for thoracolumbar injuries: the Thoracolumbar Injury Severity Score. Spine (Phila Pa 1976). 31(11 Suppl):S62-9; discussion S104, 2006.

of the C2 body. Odontoid fractures are especially common in elderly osteoporotic patients who experience falls.

Cervical spine fracture classification: Cervical spine fractures are classified functionally, according to presumed mechanism of injury. Cervical hyperflexion injuries range from simple compression fractures and "clay shoveler fracture" (C7-T1 spinous process avulsion) to unstable injuries, such as posterior ligament disruption with anterior subluxation, bilateral interfacetal dislocation, and flexion teardrop fracture.

In cervical hyperflexion and rotation injury, unilateral facet dislocation (± fracture) is common. Forward displacement of a vertebra < 50% of the AP diameter of the body is typical. The articular pillars are fractured in hyperextension with rotation injury.

Cervical vertical compression injury can cause a Jefferson fracture. In cervical "burst" fractures, there is middle column involvement with bony retropulsion.

Thoracolumbar fracture classification: Multiple systems for classifying thoracolumbar fractures have been developed. In the increasingly popular thoracolumbar injury classification and severity score (TLICS), injury mechanism, integrity of the posterior ligamentous complex, and neurologic status are each scored. The total number of TLICS points is then used to guide treatment.

Selected References

1. Gordic S et al: Whole-body CT-based imaging algorithm for multiple trauma patients: radiation dose and time to diagnosis. Br J Radiol. 88(1047):20140616, 2015
2. Mietto BS et al: Neurotrauma and inflammation: CNS and PNS responses. Mediators Inflamm. 2015:251204, 2015
3. Readdy WJ et al: A review and update on the guidelines for the acute non-operative management of cervical spinal cord injury. J Neurosurg Sci. 59(2):119-28, 2015
4. Furlow B: Computed tomography imaging of traumatic brain injury. Radiol Technol. 84(3):273CT-94CT, 2013

https://CafePezeshki.IR

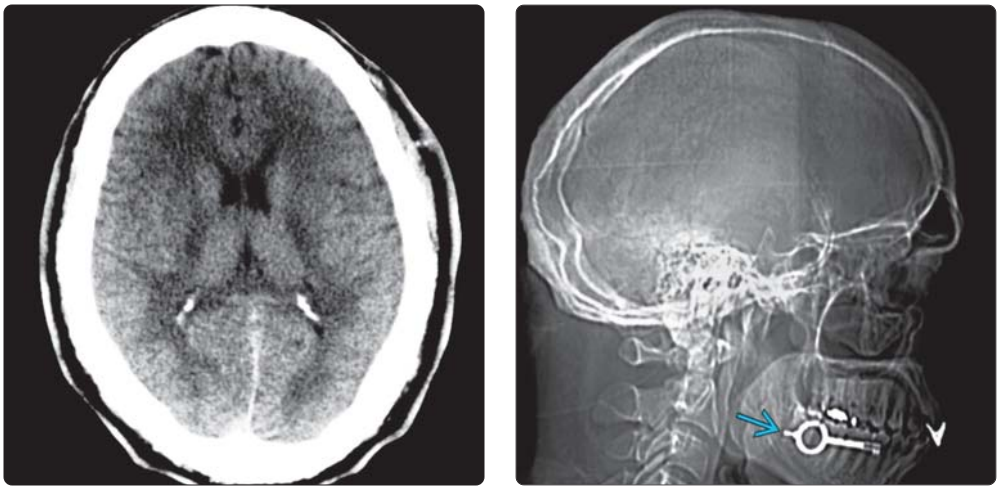

(Left) *NECT scan of a prisoner imaged for head trauma shows no gross abnormality.* **(Right)** *Scout view in the same patient shows a foreign object ⇨ (a handcuff key) in the prisoner's mouth. He faked the injury and was planning to escape, but the radiologist alerted the guards and thwarted the plan. This case illustrates the importance of looking at the scout view in every patient, especially those being imaged for trauma. (Courtesy J. A. Junker, MD.)*

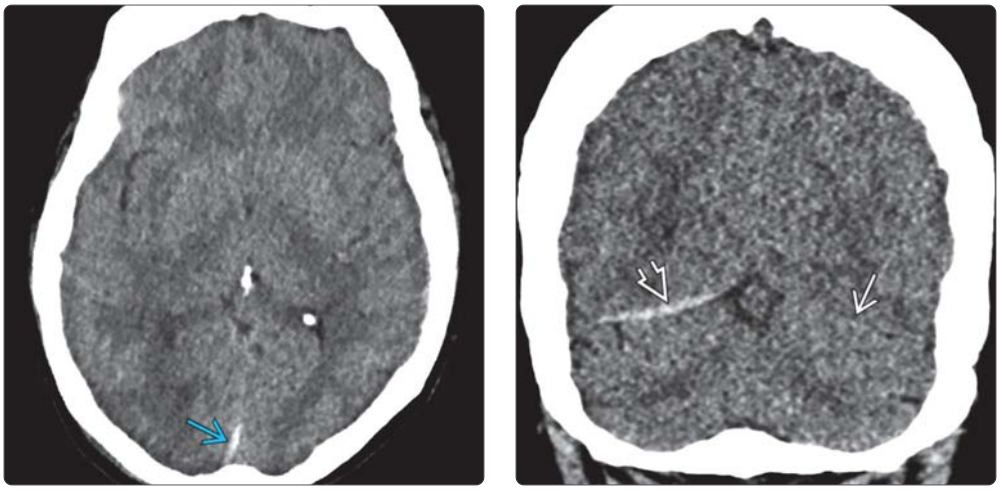

(Left) *Axial NECT scan in a 64-year-old female with a ground level fall shows only a small linear hyperdensity ⇨ adjacent to the falx cerebri and torcular Herophili. The scan was initially considered normal.* **(Right)** *Coronal NECT in the same patient was reformatted from the axial source data. Note thin peritentorial acute subdural hematoma ⇨, nicely contrasted with the nearly invisible, normal left side of the tentorium ⇨.*

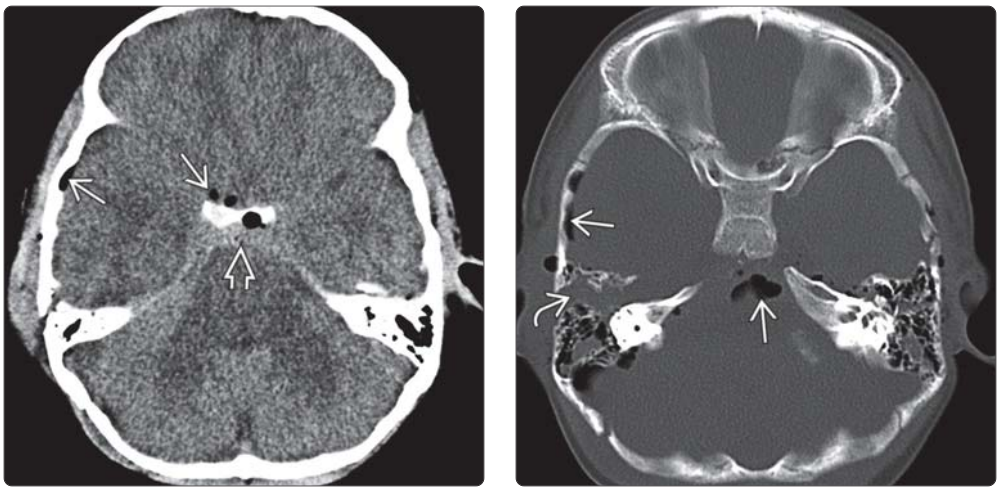

(Left) *NECT scan in a 3-year-old boy with severe head trauma shows brain swelling with obliteration of all sulci and subarachnoid cisterns, intracranial air ("pneumocephalus") ⇨, and subarachnoid hemorrhage ⇨.* **(Right)** *Bone CT in the same patient shows the importance of determining why intracranial air ⇨ is present. Multiple skull fractures are present, including a longitudinal fracture through the aerated right temporal bone ⇨.*

https://CafePezeshki.IR

(Left) *Coronal graphic shows 3 lines defining the 3 classic types of Le Fort fractures. Le Fort I (green) involves the maxilla and nasal aperture. Le Fort II (red), a.k.a. pyramidal fracture, extends upward across the maxilla and across the inferior orbital rim and nose. Le Fort III (black), a.k.a. craniofacial separation, extends through the orbits and zygomatic arches.* **(Right)** *3D CT shows a Le Fort I fracture ➡ through the maxillary alveolus and nose.*

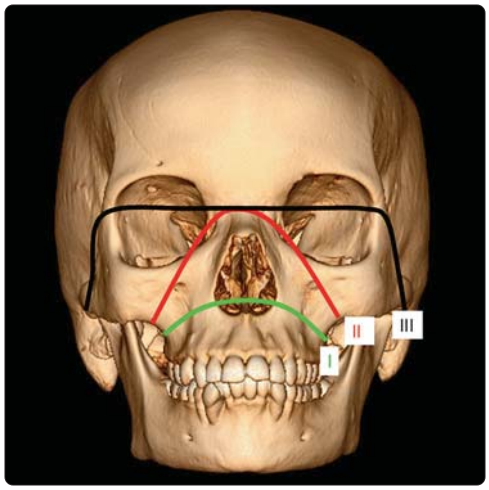

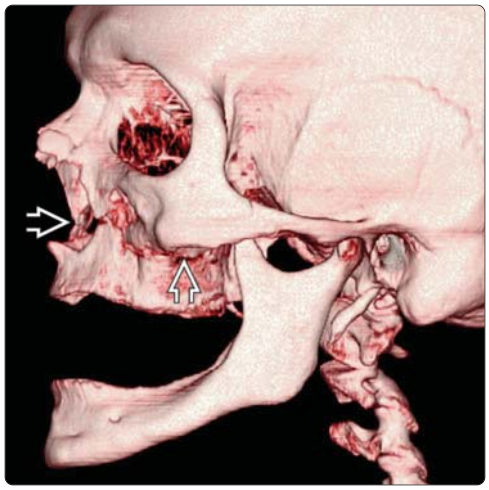

(Left) *Sagittal reformatted bone CT shows a Le Fort I fracture extending from maxillary alveolus ➡ into the posterior sinus wall and pterygoid plate ➡.* **(Right)** *3D CT shows a Le Fort II fracture through the nasofrontal junction ➡ that descends obliquely through the inferior orbital rim ➡. A Le Fort I fracture ➡ is also present through the maxillary alveolus and nose. A nondisplaced mandibular fracture ➡ is also present. It is common to have multiple types of facial fractures in the same patient.*

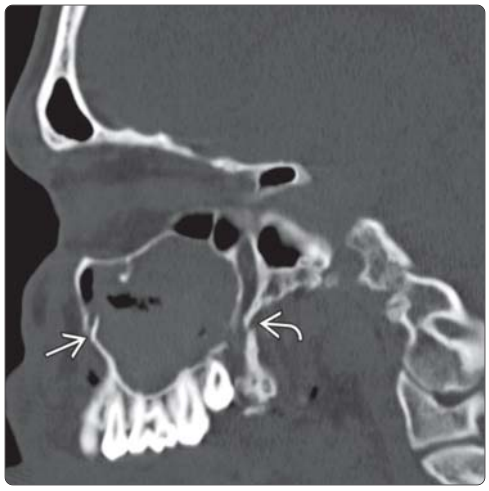

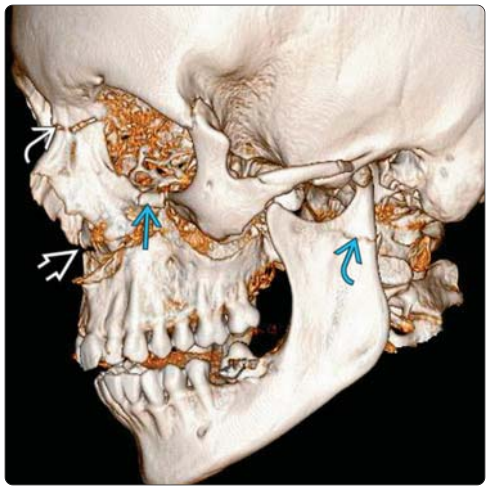

(Left) *3D CT shows a Le Fort III fracture with frontonasal diastasis ➡, orbital wall fracture ➡, and diastasis of the zygomaticofrontal suture ➡.* **(Right)** *Axial bone CT in a complex midface "smash" injury shows comminuted, depressed nasal bone and ethmoid fractures ➡, maxillary sinus fractures ➡, and zygoma fractures ➡.*

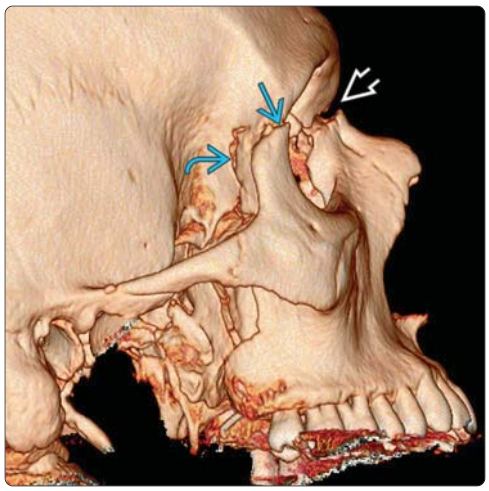

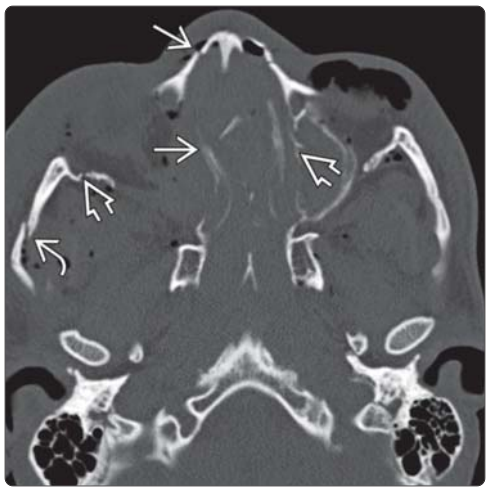

https://CafePezeshki.IR

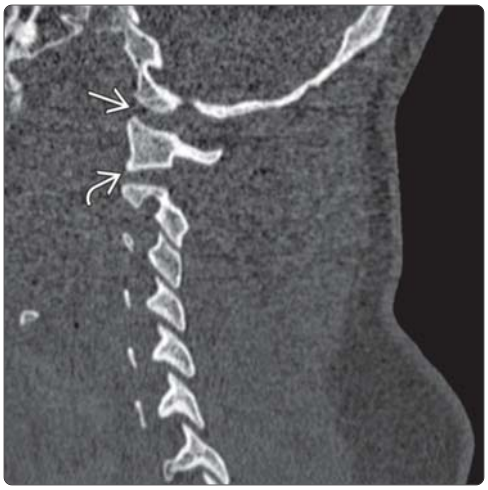

(Left) *Bone CT with sagittal reformatting shows that the anteroposterior alignment of the cervical spine appears normal. However, there is increased distance between the occipital condyle and C1 lateral mass* ➡ *as well as widening of the C1-C2 articulation* ➡. **(Right)** *Sagittal STIR scan in the same patient shows how MR better depicts soft tissue injuries. Widened occipital condyle-C1 and C1-C2 articulations with hyperintensity in both joints* ➡ *and posterior ligamentous C2-C4 injury* ➡ *are present.*

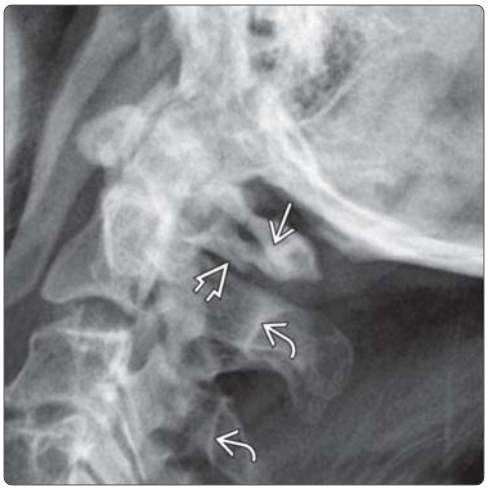

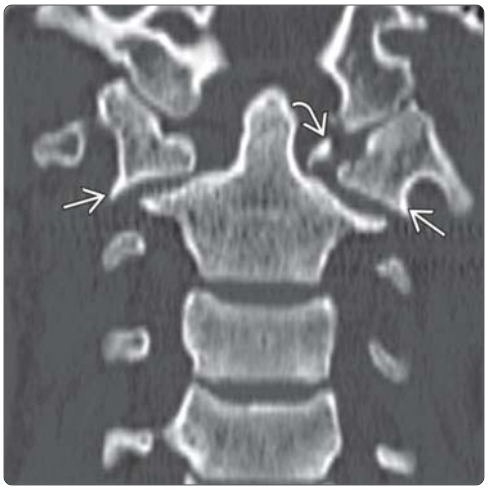

(Left) *Lateral radiograph of the upper cervical spine shows malalignment with the spinolaminar line of C1* ➡ *in front of C2 and C3* ➡. *Lucencies through the posterior C1 ring are fractures* ➡. **(Right)** *Coronal reformatted bone CT shows coronal displacement of both C1 lateral masses* ➡. *Also seen is a bony fragment due to transverse ligament tubercle avulsion* ➡.

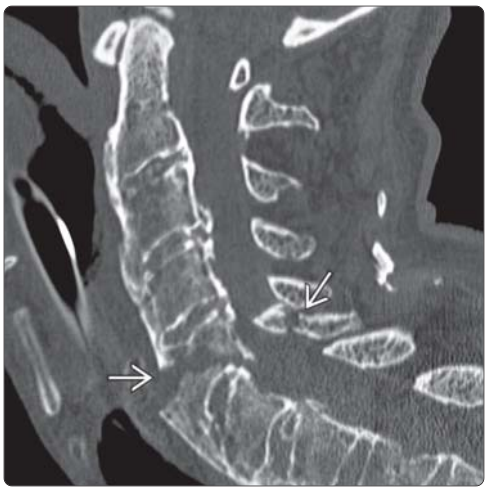

(Left) *Sagittal graphic shows an unstable cervical hyperflexion injury with disruption of the anterior* ➡ *and posterior* ➡ *longitudinal ligaments as well as the interspinous ligament* ➡, *traumatic disc herniation* ➡, *epidural hemorrhage, and cord injury.* **(Right)** *Sagittal reformatted bone CT of a cervical spine fracture in a patient with ankylosing spondylitis nicely shows the bone injuries* ➡ *but does not depict the extent of soft tissue damage. MR is complementary to multiplanar CT.*

https://CafePezeshki.IR

KEY FACTS

IMAGING

- **Cephalohematoma**
  - Subperiosteal hematoma
  - Between outer table of calvaria, periosteum
  - Does not cross sutures
  - Usually unilateral, small, and resolves spontaneously
- **Subgaleal hematoma**
  - Forms under aponeurosis (galea) of occipitofrontalis muscle
  - Not limited by sutures
  - May become very large
  - Can extend around entire circumference of skull
- **Fractures**
  - Calvarial fractures rarely, if ever, occur without overlying scalp hematoma
  - Base of skull fractures (temporal bone, clivus, sinuses, etc.): Look for extension into arterial or venous channel

TOP DIFFERENTIAL DIAGNOSES

- Vascular grooves
- Sutures
- Venous lakes
- Arachnoid granulations
- Wormian bones

CLINICAL ISSUES

- **Cephalohematoma**
  - Occurs in 1% of newborns
  - Usually caused by instrumented delivery
  - Diagnosed clinically; infrequently imaged
- **Subgaleal hematoma**
  - Common in head trauma
  - Occurs in all ages
  - Large expanding hematoma in infant can be life threatening

(Left) *Graphic shows the skull of a newborn, including the anterior fontanelle, coronal, metopic, and sagittal sutures. Cephalohematoma ⇨ is subperiosteal, focal, and limited by sutures. Subgaleal hematoma ➡ is under the scalp aponeurosis, much more extensive, and not bounded by sutures.* **(Right)** *Bone CT in a newborn with a traumatic delivery shows a linear skull fracture ⇨ and cephalohematoma ➡ overlying the parietal bone. Note that the cephalohematoma does not cross the sagittal suture ➡.*

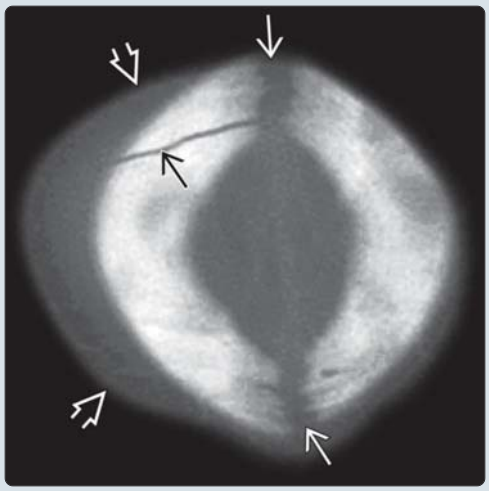

(Left) *Bone CT shows a diastatic fracture of the sagittal suture ⇨. A very large subgaleal hematoma ➡ extends around the entire circumference of the skull. The superior sagittal sinus is torn and the intracranial blood seen on soft tissue windows was a vertex venous epidural hematoma.* **(Right)** *T2WI MR scan in an abused infant shows a very large mixed acute/subacute subgaleal hematoma ➡ crossing the sutures and extending over the face/orbits.*

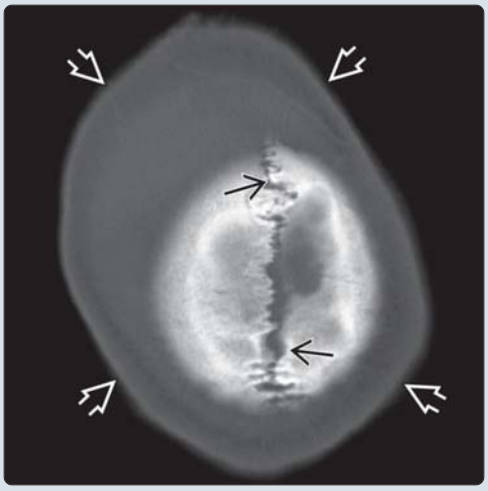

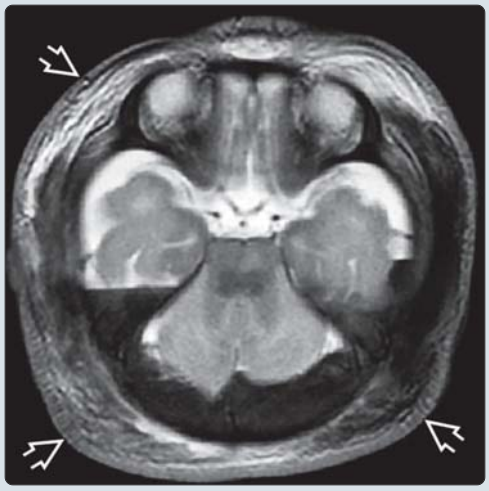

https://CafePezeshki.IR

TERMINOLOGY

Synonyms

- Scalp swelling, soft tissue swelling, scalp hematoma

Definitions

- Scalp injuries: Lacerations, hematomas
  - Laceration: Focal discontinuity in scalp
    - Variable extent and thickness
    - Foreign bodies, subcutaneous air common
  - Hematoma: Hemorrhage in or between scalp layers
- Skull injuries: Fractures

IMAGING

General Features

- Best diagnostic clue
  - Skull fracture vs. normal structure (e.g., suture or vascular groove): Rarely, if ever, occurs without overlying scalp "lumps and bumps"
  - Important to distinguish between 2 types of scalp hematoma
    - Cephalohematoma
    - Subgaleal hematoma
- Location
  - **Cephalohematoma**
    - Subperiosteal hematoma
      - Between outer table of calvaria, periosteum
      - Elevates periosteum
      - Does not cross sutures
      - Extracranial equivalent of intracranial epidural hematoma
      - Usually unilateral
  - **Subgaleal hematoma**
    - Hematoma under aponeurosis (galea) of occipitofrontalis muscle
    - External to periosteum
    - Not limited by sutures
  - **Fractures**
    - Calvarial
      - Rarely, if ever, occurs without overlying scalp hematoma
    - Base of skull (BOS) (including mastoids, sinuses)
      - Temporal bone, sphenoid bone, clivus, etc.
      - Look for extension into arterial or venous channel
- Size
  - **Cephalohematoma**
    - Rarely large (contained by periosteum)
  - **Subgaleal hematoma**
    - Can be extensive, even life threatening
    - Not limited by sutures
    - Often bilateral, often spreads diffusely around entire calvaria
  - **Fractures**
    - Size varies
    - Can be simple or comminuted
    - Can be closed or open
- Morphology
  - **Cephalohematoma**
    - Rounded
    - Half dome shape
  - **Subgaleal hematoma**
    - Diffuse, poorly demarcated
    - Usually circumferential, nonfocal
  - **Fractures**
    - Linear: Sharply marginated
      - Middle cranial fossa is most common site
    - Depressed: Inwardly depressed fragments
    - Elevated: Fragments lifted, usually rotated
    - Diastatic: Widens suture or synchondrosis
      - Usually in combination with linear skull fracture that extends into adjacent suture
      - Traumatic suture diastasis usually in children with severe BOS fractures
    - "Growing": Post-traumatic leptomeningeal cyst
      - Arachnoid, contused brain herniate through dural tear
      - Causes craniocerebral erosion
      - Growing skull fractures slowly widen with time
      - Can present months or years after trauma

Radiographic Findings

- No role in modern imaging of head trauma

CT Findings

- **Scalp injuries**
  - Cephalohematoma
    - Unilateral scalp mass limited by sutures
    - Chronic cephalohematomas may calcify
  - Subgaleal hematoma
    - Extensive soft tissue mass
    - May extend around entire circumference of skull
- **Skull fractures**
  - Linear skull fracture
    - Sharply marginated lucent line(s)
  - Depressed skull fracture
    - Comminuted fragments imploded inwardly
  - Elevated skull fracture
    - Elevated, rotated skull segment
  - Diastatic skull fracture
    - Widened suture or synchondrosis
    - Usually accompanied by linear skull fracture
  - "Growing" skull fracture
    - Difficult to detect in acute stage
    - Progressively widening, unhealing fracture
    - Lucent lesion with rounded, scalloped margins
    - Cerebrospinal fluid and soft tissue trapped within expanding fracture
    - Brain is usually encephalomalacic

MR Findings

- Used to evaluate complications, not acute manifestations

Angiographic Findings

- Consider CTA/MRA if
  - Fracture crosses carotid canal or dural venous sinus
  - Clivus fracture is present
    - High association with neurovascular injury
  - High-risk cervical injury
    - Cervical spine fracture &/or dislocation
    - Distraction injury

https://CafePezeshki.IR

- Penetrating neck trauma

Imaging Recommendations

- Best imaging tool
  - NECT
    - Obtain both soft tissue and bone algorithm reconstructions
    - Thin section multiplanar reconstructions for complex BOS fractures
    - 3D shaded surface display (SSD) CT
      - Especially useful for depressed, diastatic fractures
      - Helpful if complex facial fractures are present
  - CTA (high-risk injuries)
- Protocol advice
  - MR
    - Use T2* (GRE/SWI) for hemorrhage
    - DWI for ischemic complications

DIFFERENTIAL DIAGNOSIS

Normal Structures

- Vascular grooves
  - Well-corticated margins
  - Not as sharp or lucent as linear skull fractures
  - No adjacent scalp hematoma
- Sutures
  - In predictable locations (coronal, sagittal, mastoid, etc.)
  - ≤ 2 mm and no adjacent linear skull fracture
  - Densely corticated
  - Less distinct than fractures
- Venous lakes, arachnoid granulations
  - In predictable locations
    - Parasagittal
    - Adjacent to/within dural venous sinus
  - Often connect with vascular channel
  - Round/ovoid shape
  - Smooth, well corticated

Normal Variants

- Wormian bones
  - Common (≥ 1 in 50% of children)
  - Rare: Osteogenesis imperfecta
  - Typical locations (e.g., lambdoid suture)
  - No overlying soft tissue injury

CLINICAL ISSUES

Presentation

- Most common signs/symptoms
  - Scalp swelling
  - Soft ("boggy") scalp hematoma is associated with intracranial injury in head-injured children
- Other signs/symptoms
  - Vary with type and extent of brain injury

Etiology and Epidemiology

- **Cephalohematoma**
  - Occurs in 1% of newborns
  - Usually related to birth trauma
    - Instrumented delivery
    - Sometimes vacuum-assisted delivery
- **Subgaleal hematoma**
  - Common in head trauma
  - Occurs in all ages
- **Fractures**
  - Linear
    - Low-impact injury
    - Delivered over relatively wide surface area
  - Depressed
    - High-impact, high-energy direct blow
      - Often with blunt object
    - Force radiates centrifugally
    - Delivered over small surface

Natural History and Prognosis

- **Cephalohematoma**
  - Diagnosed clinically; infrequently imaged
  - Usually resolves spontaneously without treatment
  - Occasionally calcifies, causing firm palpable mass
  - Complications are rare
- **Subgaleal hematoma**
  - Large expanding hematoma in infant can be life threatening
- **Fractures**
  - Usually heal spontaneously
  - Complications
    - Vascular injury
    - Dura/arachnoid laceration ± cerebrospinal fluid leak
    - Cranial nerve injury
    - Leptomeningeal cyst (rare)

DIAGNOSTIC CHECKLIST

Consider

- CTA/MRA if high risk for vascular injury
  - Fracture crosses vascular channel, dural venous sinus

Image Interpretation Pearls

- Linear fracture vs. normal (e.g., suture or vascular groove): If no overlying soft tissue swelling is present, it is rarely, if ever, a skull fracture

SELECTED REFERENCES

1. Dayan PS et al: Risk of traumatic brain injuries in children younger than 24 months with isolated scalp hematomas. Ann Emerg Med. 64(2):153-62, 2014
2. Towards evidence-based emergency medicine: Best BETs from the Manchester Royal Infirmary. BET 1: What is the significance of a 'boggy' (soft) scalp haematoma in head-injured children? Emerg Med J. 31(1):78-9, 2014
3. Kichari JR et al: Massive traumatic subgaleal haematoma. Emerg Med J. 30(4):344, 2013
4. Marti B et al: Wormian bones in a general paediatric population. Diagn Interv Imaging. Epub ahead of print, 2013
5. Kim YI et al: Clinical comparison of the predictive value of the simple skull x-ray and 3 dimensional computed tomography for skull fractures of children. J Korean Neurosurg Soc. 52(6):528-33, 2012
6. Ciurea AV et al: Traumatic brain injury in infants and toddlers, 0-3 years old. J Med Life. 4(3):234-43, 2011
7. Werner EF et al: Mode of delivery in nulliparous women and neonatal intracranial injury. Obstet Gynecol. 118(6):1239-46, 2011
8. Sillero Rde O: Massive subgaleal hematoma. J Trauma. 65(4):963, 2008

https://CafePezeshki.IR

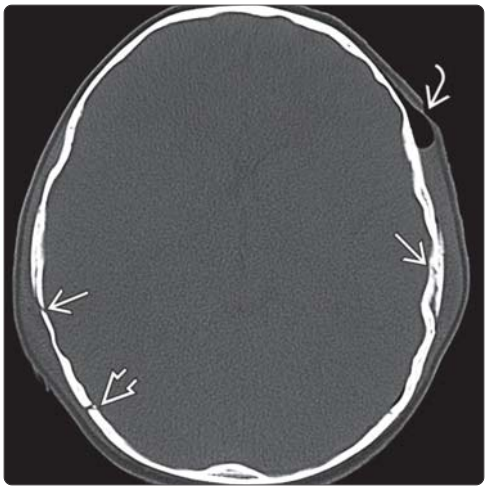

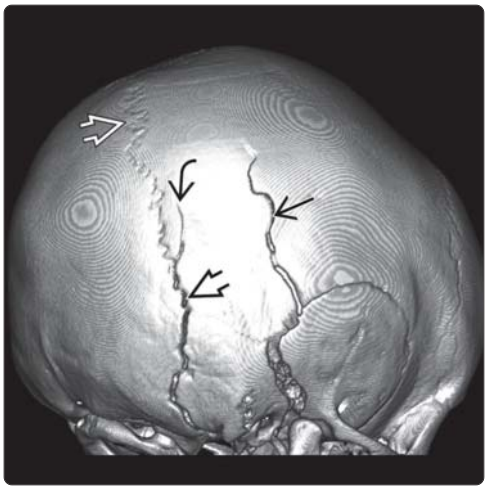

(Left) *Bone CT shows scalp laceration and soft tissue swelling overlying bilateral linear skull fractures. The right lambdoid suture is diastatic.* **(Right)** *3D shaded surface display in the same patient shows the right calvarial linear skull fracture. Another linear fracture is present that extends into the right lambdoid suture causing a diastatic fracture. The lambdoid suture cephalad to the fracture appears more normal.*

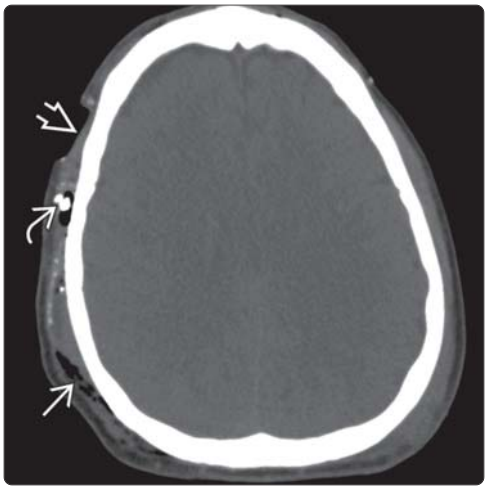

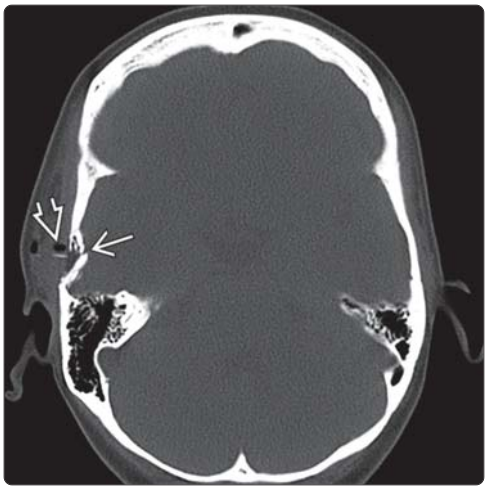

(Left) *NECT scan in a patient with head trauma while bicycling on a gravel road without a helmet shows a lacerated, avulsed scalp, extensive subcutaneous air, and multiple hyperdense foreign bodies ("road rash").* **(Right)** *Axial NECT scan with bone algorithm reconstruction and wide window display shows a depressed, comminuted skull fracture involving the right squamous temporal bone. Note the subcutaneous air and soft tissue hematoma overlying the fracture.*

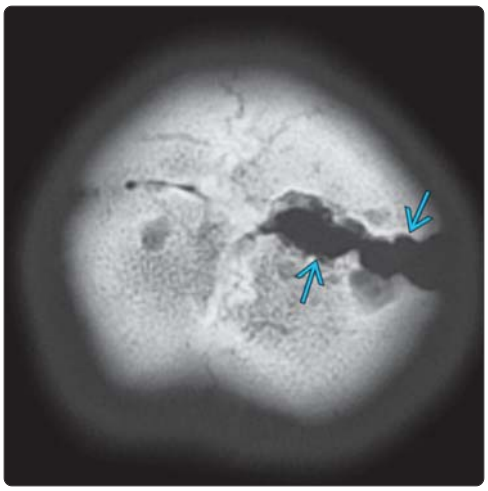

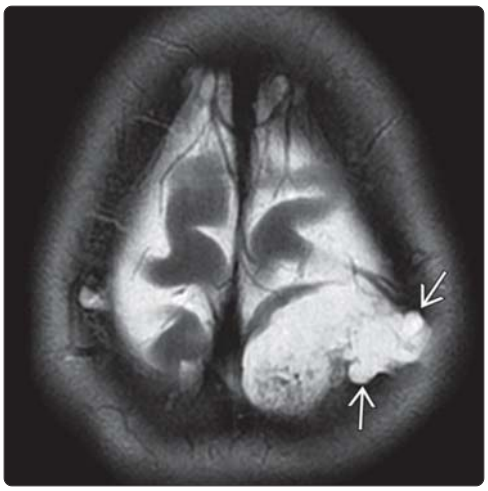

(Left) *Axial NECT scan in a patient with a "growing" skull fracture shows widened fracture with scalloped margins.* **(Right)** *Axial T2WI in the same patient shows a lobulated CSF collection filling the "growing" fracture. CSF pulsations have widened and scalloped the calvaria.*

https://CafePezeshki.IR

KEY FACTS

TERMINOLOGY

- Impalement injury

IMAGING

- Single or multiple intracranial foreign bodies, missile tract, pneumocephalus, entry ± exit wound
- Extent of injury extremely variable depending on
  - Size, shape, and number of projectiles
  - Projectile velocities
  - Entry/exit site(s) and course through brain
- Entry site → embedded bullet and bone fragments
- Epidural, subdural, subarachnoid hemorrhage
- Hemorrhagic tract through brain
- Intracerebral, intraventricular hemorrhage
- Ischemia and infarction
- Brain herniation
- Nuclear medicine brain death scanning with cerebral perfusion agents can be confirmatory test
- Best imaging tool → NECT ± CTA
- Vascular injury

CLINICAL ISSUES

- Prognosis ranges from brain death to full recovery
- High morbidity and mortality

DIAGNOSTIC CHECKLIST

- Injury is most severe when
  - Missile is large and traveling at high velocities
  - If it fragments through tissue early in its path
- Reporting tips
  - Determine entry site
  - Assess missile path
  - Evaluate for exit site and secondary ricochet paths
  - Consider vascular injury

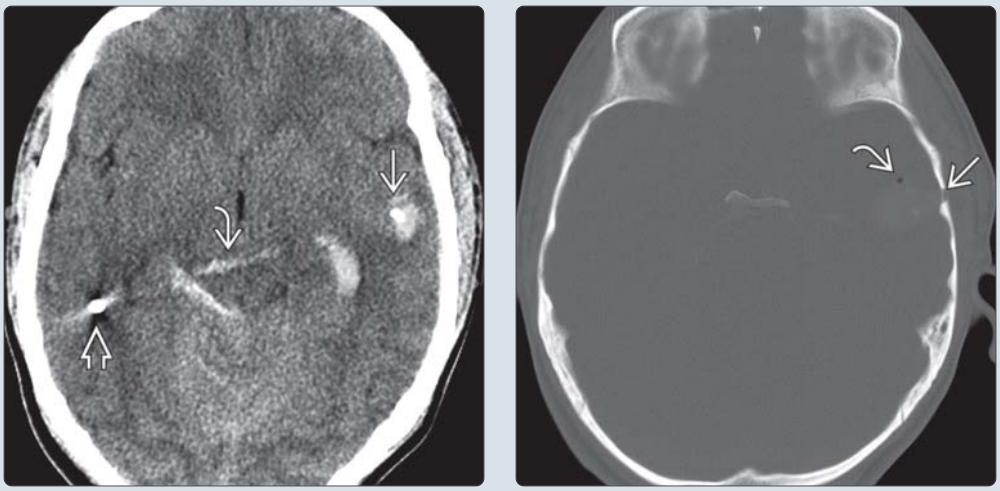

(Left) *Axial NECT shows a small-caliber, low-velocity injury. A bullet fragment is present in the left temporal lobe ➡ with minimal adjacent hemorrhage. A narrow hemorrhagic tract extends through the midbrain ➡ with a 2nd fragment imbedded in the right temporal lobe ➡. Regional subarachnoid and intraventricular blood are also seen.* **(Right)** *Axial bone CT demonstrates the tiny entry site in the squamous temporal bone ➡, with a focus of underlying intracranial air ➡.*

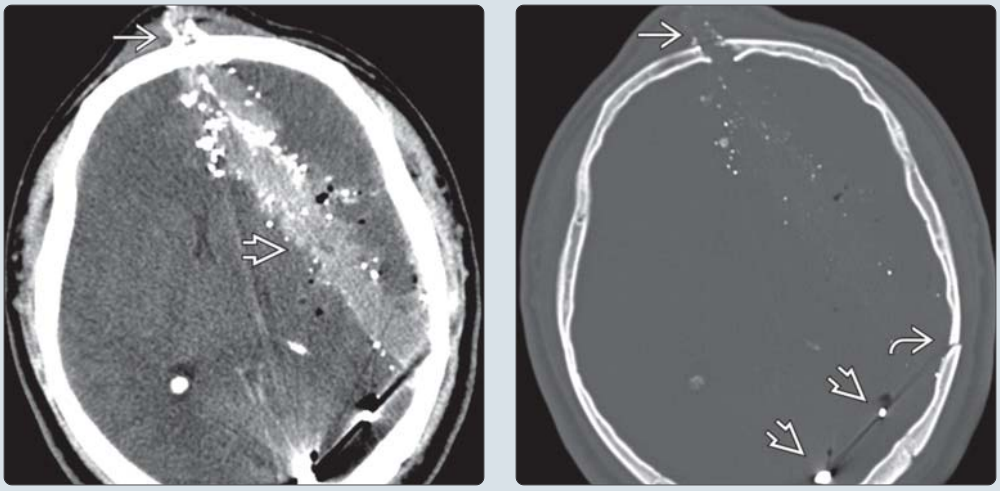

(Left) *Axial NECT shows a large-caliber, high-velocity injury with a frontal entry site ➡ and a wide oblique hemorrhagic tract ➡ that extends to the left temporoparietal region. There is sulcal effacement and midline shift to the right.* **(Right)** *Axial bone CT shows the frontal entry site ➡ and left parietal fracture ➡. Multiple bone and bullet fragments and foci of air are noted along the tract. Ricocheted metallic fragments ➡ are seen posteriorly, away from the primary trajectory.*

https://CafePezeshki.IR

TERMINOLOGY

Synonyms

- Impalement injury
- Stabbing injury

Definitions

- Cranial trauma from high-velocity projectile (typically gunshot wound [GSW]) or impalement with sharp object

IMAGING

General Features

- Best diagnostic clue
  - Single or multiple intracranial foreign bodies, missile tract, pneumocephalus, entry ± exit wound
- Location
  - Supra- or infratentorial, affecting cerebral/cerebellar hemispheres or brainstem
- Size
  - Small linear tract if small caliber and low velocity
  - Large linear tract if large caliber and high velocity
- Morphology
  - Extremely variable depending on
    - Size, shape, number of projectiles
    - Projectile velocities
    - Entry/exit site(s), course through brain
  - Skull fracture(s)
    - Entry site → embedded bullet and bone fragments
    - Exit site → if high enough velocity
    - Pneumocephalus
  - Intracranial hemorrhage
    - Epidural, subdural, subarachnoid hemorrhage
    - Hemorrhagic tract through brain
    - Intracerebral, intraventricular hemorrhage
  - Vascular injury
    - Pseudoaneurysm, dissection, arteriovenous fistula (AVF), spasm
  - CSF leak
  - Secondary effects
    - Ischemia and infarction
    - Brain herniation

CT Findings

- NECT
  - Best assessment of extent of soft tissue injury
  - Identify entrance and exit wounds
- Bone CT
  - Osseous entry and exit sites and pneumocephalus shown to better advantage
  - Metallic fragments easier to evaluate
- CTA
  - Evaluate for pseudoaneurysm, dissection, or traumatic AVF

MR Findings

- T1WI
  - Variable signal (hemorrhage, foreign bodies, air)
- T2WI
  - Edema from pressure wave
  - Variable signal (hemorrhage, foreign bodies, air)
- T2* GRE
  - "Blooming" from hemorrhage, as well as susceptibility artifact from foreign bodies, air
- DWI
  - Secondary infarction
- MRA
  - Evaluate for pseudoaneurysm, dissection, or traumatic AVF
- MRV
  - Venous injury or thrombosis if missile tract crosses or tears interdural veins or lacerates sinus
  - Dural sinus thrombosis: Reported incidence < 5% with penetrating trauma

Angiographic Findings

- Conventional
  - Traumatic intracranial aneurysms in atypical locations
    - Proximal to or beyond circle of Willis and major arterial bifurcations
  - Extracranial pseudoaneurysms vary in size, configuration
    - Small saccular lesions
    - Fusiform dilatations
    - Large paravascular collections with huge cavitating hematomas
  - Other possible injuries
    - Traumatic direct carotid cavernous fistulas, dural AVFs involving meningeal vessels
    - Extracranial AVFs
    - Arterial dissection
  - Vascular spasm from projectile velocity or subarachnoid hemorrhage

Nuclear Medicine Findings

- Nuclear medicine brain death scanning with cerebral perfusion agents can be confirmatory test

Imaging Recommendations

- Best imaging tool
  - NECT
- Protocol advice
  - NECT ± CTA
  - Consider MR/MRA/MRV
  - Conventional cerebral angiography depending on type of trauma and degree of injury

DIFFERENTIAL DIAGNOSIS

Nonprojectile Intracranial Injury

- Contusion
- Axonal injury

PATHOLOGY

General Features

- Etiology
  - Pressure wave in front of missile crushes/stretches/disintegrates tissue, creates temporary cavitation
- General pathology comments
  - Appearance and degree of injury highly variable
  - Traumatic aneurysms account for < 1% of all intracranial aneurysms

https://CafePezeshki.IR

Gross Pathologic & Surgical Features

- Highly variable depending on severity of trauma

Microscopic Features

- Highly variable
  - Ranges from axonal transection to axonal edema
  - Vascular transection to luminal injury

CLINICAL ISSUES

Presentation

- Most common signs/symptoms
  - Highly variable depending on type and degree of traumatic injury
    - Motor deficits
    - Cranial nerve palsies
    - Visual field defects
- Other signs/symptoms
  - Post-traumatic seizures

Demographics

- Age
  - Any age can be affected, but younger patients involved more often
- Gender
  - M > F
- Ethnicity
  - Some studies document higher frequency of intentional assault injury among certain minority groups
- Epidemiology
  - Highly variable; incidence higher in inner cities and combat situations
    - May be influenced by regional legislation and social attitudes toward gun control
  - Accidental
  - Intentional
    - Self-inflicted/suicidal
      - Percent increase with age
    - Assault/homicidal intent

Natural History & Prognosis

- Prognosis ranges from brain death to full recovery
  - High morbidity and mortality
    - Most fatalities occur within 1st day
- Poor outcomes associated with
  - Transventricular or bihemispheric central type of trajectory → predictive of high morbidity/mortality
  - Low Glasgow coma scale (GCS) value at presentation
  - High head abbreviated injury score (AIS)
  - Pupil irregularity
  - Low blood pressure
  - Older patient
- Good outcomes associated with tangential gunshot wounds
  - Bullet fragments do not penetrate inner table of skull
    - Skull fracture and intracranial hemorrhage can still be present

Treatment

- Options, risks, complications
  - Dependent upon type and degree of injury
- Debridement
  - Penetrating objects may be left in place
- Decompressive craniectomy
- CSF diversion to control hydrocephalus
  - Especially in setting of infratentorial injury
- Intracranial pressure control

DIAGNOSTIC CHECKLIST

Consider

- Could there be associated vascular injury and aneurysm formation
- Post-traumatic pseudoaneurysm may be overlooked on CT (often obscured by hemorrhagic contusion)

Image Interpretation Pearls

- Injury is most severe when missile is large and traveling at high velocity and if it fragments through tissue early in its path

Reporting Tips

- Determine entry site
- Assess missile path
  - Determine extent of wound, including bone fragmentation and ricochet paths
- Evaluate for exit site and secondary ricochet paths
- Consider vascular injury

SELECTED REFERENCES

1. Grossbach AJ et al: Impalement brain injury from steel rod causing injury to jugular bulb: Case report and review of the literature. Brain Inj. 1-5, 2014
2. Elserry T et al: Image guided surgery in the management of craniocerebral gunshot injuries. Surg Neurol Int. 4(Suppl 6):S448-54, 2013
3. Syrmos N et al: Dealing with the surgical and medical challenges of penetrating brain injuries. Case Rep Surg. 2013:209750, 2013
4. Kazim SF et al: Management of penetrating brain injury. J Emerg Trauma Shock. 4(3):395-402, 2011
5. Agarwalla PK et al: An historical context of modern principles in the management of intracranial injury from projectiles. Neurosurg Focus. 28(5):E23, 2010
6. Finley CJ et al: The demographics of significant firearm injury in Canadian trauma centres and the associated predictors of inhospital mortality. Can J Surg. 51(3):197-203, 2008
7. Kim H et al: Intentional traumatic brain injury in Ontario, Canada. J Trauma. 65(6):1287-92, 2008
8. McNett M: A review of the predictive ability of Glasgow Coma Scale scores in head-injured patients. J Neurosci Nurs. 39(2):68-75, 2007
9. Aryan HE et al: Gunshot wounds to the head: gang- and non-gang-related injuries and outcomes. Brain Inj. 19(7):505-10, 2005
10. Coşar A et al: Craniocerebral gunshot wounds: results of less aggressive surgery and complications. Minim Invasive Neurosurg. 48(2):113-8, 2005
11. Kim KA et al: Vector analysis correlating bullet trajectory to outcome after civilian through-and-through gunshot wound to the head: using imaging cues to predict fatal outcome. Neurosurgery. 57(4):737-47; discussion 737-47, 2005

https://CafePezeshki.IR

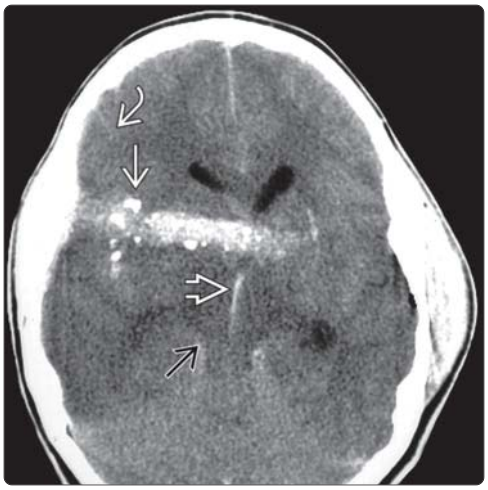

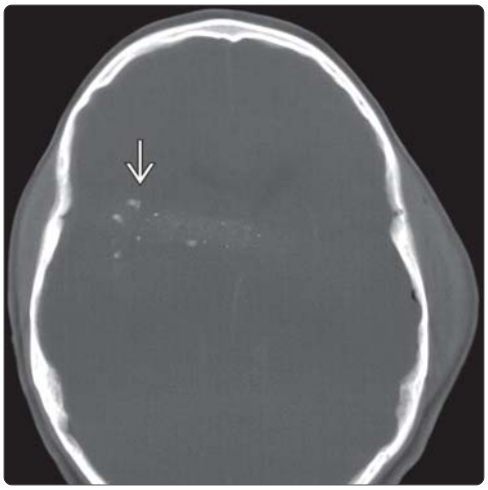

(Left) *Axial NECT shows extensive hemorrhage along the small-caliber missile trajectory from right to left ➡, crossing both basal ganglia. Scattered subarachnoid blood ➡ and minimal intraventricular blood ➡ are seen, along with diffuse sulcal effacement and early transtentorial herniation ⇨. (Right) Axial bone CT in the same patient confirms the presence of intracranial bullet and bone fragments on the right ➡ near the entry site.*

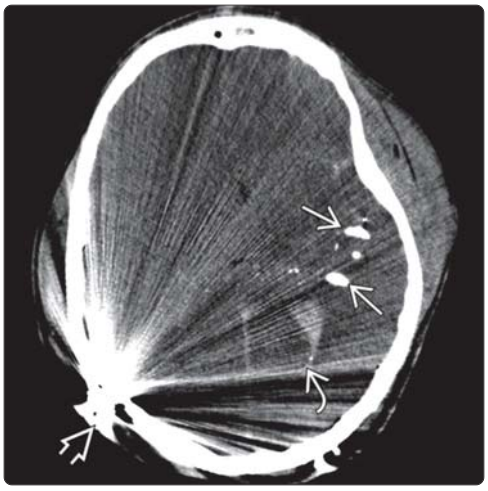

(Left) *Axial NECT scan in a 15-year-old male with a high-caliber gunshot wound shows diffuse brain swelling, hemorrhage in the left occipital horn ➡. Multiple small metallic fragments are present under the entrance wound in the left temporal lobe ➡. The deformed bullet lies under the right parietal galea ➡ where it ultimately lodged after losing velocity.* **(Right)** *More cephalad scan shows large left temporal subgaleal hematoma with extracranial ➡ and intracranial ⇨ bullet fragments.*

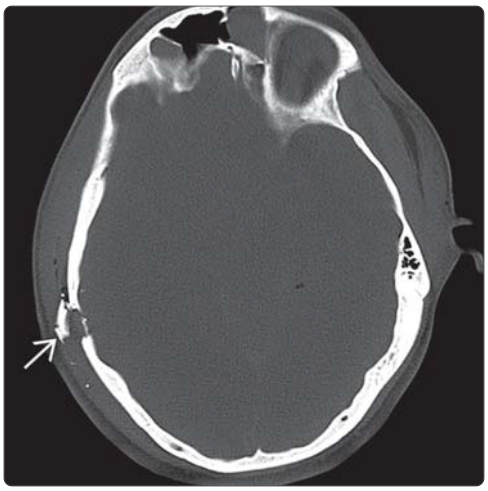

(Left) *Bone CT scans show the blown-out right posterior temporal skull fracture ➡ marking the site of the exit wound.* **(Right)** *More cephalad scan shows the multiple extra- and intracranial bullet fragments. The patient had a Glasgow coma scale (GCS) of 3 at the scene and expired shortly after admission. Further investigation disclosed the patient had been shot in an argument over a drug deal. As 90% of people are right-handed, left-sided GSWs are not often self-inflicted.*

https://CafePezeshki.IR

KEY FACTS

TERMINOLOGY

- Blood collection between skull and dura

IMAGING

- NECT
  - Hyperdense, biconvex, extraaxial collection
  - > 95% unilateral, supratentorial
  - Does not cross sutures unless venous or sutural diastasis/fracture is present
  - Compresses/displaces underlying brain, subarachnoid space
  - Low-density "swirl" sign: Active/rapid bleeding with unretracted clot
  - 1/3-1/2 have other significant lesions
- Bone CT
  - Skull fracture in 90-95%

TOP DIFFERENTIAL DIAGNOSES

- Subdural hematoma
- Neoplasm
- Infection/inflammation
- Extramedullary hematopoiesis

PATHOLOGY

- Arterial (90-95%)
  - Arterial epidural hematoma (EDH) is most often near middle meningeal artery groove fracture
- Venous EDH (5-10%)
  - Fracture is adjacent to dural sinus
  - Common sites: Vertex, anterior middle cranial fossa

CLINICAL ISSUES

- Classic "lucid interval"
  - ~ 50% of cases
- Good outcome if promptly recognized and treated
- Some EDHs < 1 cm may be managed nonoperatively
  - Anterior middle fossa epidural hematoma is usually venous, benign

(Left) *Coronal graphic illustrates swirling acute hemorrhage from a laceration of the middle meningeal artery by an overlying skull fracture. The epidural hematoma displaces the dura inward as it expands.* **(Right)** *Axial NECT scan in a 47-year-old man with head trauma shows a classic biconvex (lentiform) uniformly hyperdense epidural hematoma (EDH) ➡ in the right middle fossa. Bone CT (not shown) disclosed a nondisplaced skull fracture underlying the hematoma.*

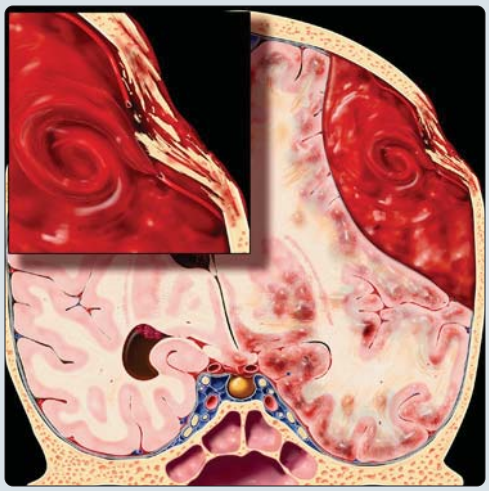

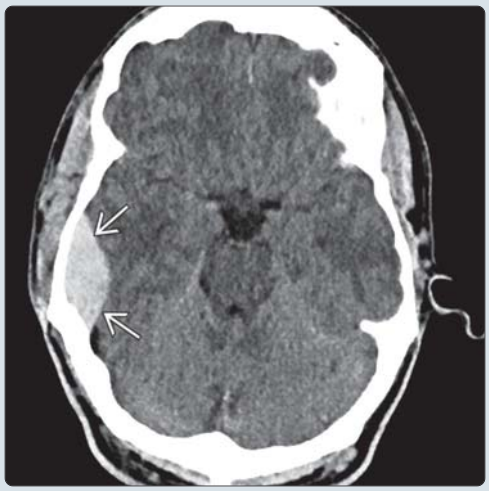

(Left) *Coronal scan reformatted from the axial date nicely demonstrates the classic middle cranial fossa acute EDH ➡.* **(Right)** *Sagittal NECT scan reformatted from the axial source date in the same patient shows the classic biconvex configuration of the acute middle fossa EDH ➡ is present in all 3 major imaging planes.*

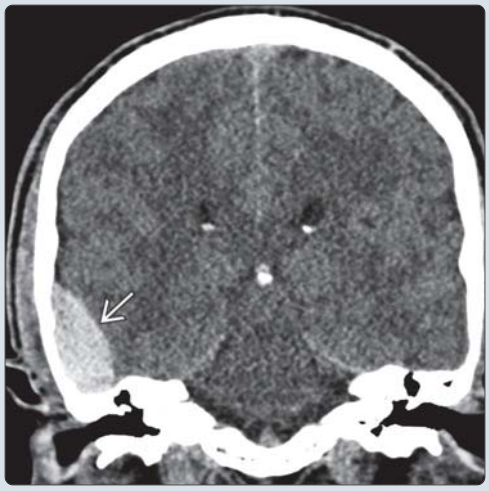

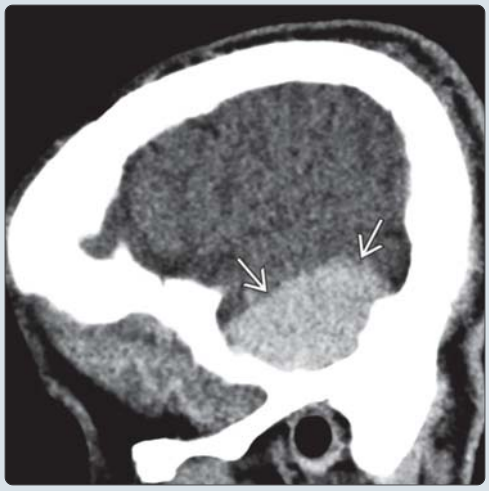

https://CafePezeshki.IR

TERMINOLOGY

Abbreviations

- Epidural hematoma (EDH)

Definitions

- Blood collection between inner table of skull and outer (periosteal) layer of dura

IMAGING

General Features

- Best diagnostic clue
  - Hyperdense, biconvex, extraaxial collection on NECT
- Location
  - Epidural space (between skull and dura)
  - Nearly all EDHs occur at impact (coup) site
    - 90-95% arterial
    - 90-95% adjacent to skull fracture
    - 90-95% unilateral (bilateral rare)
  - Supratentorial (90-95%)
    - 65% temporoparietal, 35% frontal/parietooccipital
  - 5-10% in posterior fossa
  - Venous EDH (5%)
- Size
  - Variable; rapid expansion is typical
    - Attains maximum size within 36 hours
  - Slower accumulation of blood in venous EDH
- Morphology
  - Biconvex or lentiform extraaxial collection
  - Arterial EDHs usually do not cross sutures
    - Exception: If sutural diastasis/fracture is present
    - Compresses/displaces underlying brain, subarachnoid space
  - Venous EDH
    - Adjacent to venous sinus crossed by fracture
      - Skull base, vertex
      - Anterior middle fossa
    - May "straddle" sutures, dural attachments
      - Can cross falx, tentorium
    - Dural sinus displaced, usually not occluded
  - 1/3-1/2 have other significant lesions
    - Mass effect, secondary herniations common
    - Contrecoup subdural hematoma
    - Cerebral contusions

CT Findings

- NECT
  - Acute: 2/3 hyperdense, 1/3 mixed density
    - Acute EDH with retracted clot = 60-90 HU
    - Low-density "swirl" sign: Active/rapid bleeding with unretracted clot
    - Medial hyperdense margin: Displaced dura
  - Air in EDH (20%) suggests sinus or mastoid fracture
  - Vertex EDH is easily overlooked
  - Chronic EDH → hypo-/mixed density
  - CT "comma" sign
    - EDH plus subdural hematoma
    - Often temporoparietal or temporoparietooccipital
    - Important to identify → treated as 2 separate surgical entities
- CECT
  - Acute: May show contrast extravasation (rare)
  - Chronic: Peripheral dural enhancement from neovascularization, granulation
- Bone CT
  - Skull fracture in 95%

MR Findings

- T1WI
  - Acute: Isointense with brain
  - Subacute/early chronic: Hyperintense
  - Black line between EDH and brain: Displaced dura
- T2WI
  - Acute: Variable hyper- to hypointense
  - Early subacute: Hypointense
  - Late subacute/early chronic: Hyperintense
  - Black line between EDH and brain: Displaced dura
- T1WI C+
  - Venous EDH: Look for displaced dural sinus by hematoma
  - Spontaneous (nontraumatic) EDH: Enhancement of hemorrhagic epidural mass
- MRV
  - Assess venous sinus integrity
  - Hematoma may displace venous sinus, impede flow

Angiographic Findings

- Diagnostic
  - Avascular mass effect; displaced cortical arteries
  - If middle meningeal artery (MMA) laceration present
    - May form arteriovenous fistula → "tram-track" sign
      - Simultaneous opacification of MMA, both middle meningeal veins
  - Venous EDH: Look for displaced dural sinus

Imaging Recommendations

- Best imaging tool
  - NECT with bone CT for traumatic cases
  - MR + MRV if venous EDH suspected
- Protocol advice
  - Consider MR if EDH straddles dural compartments or sinuses on NECT

DIFFERENTIAL DIAGNOSIS

Acute Subdural Hematoma (aSDH)

- EDH and SDH may coexist
- Acute SDH is usually crescentic (occasionally biconvex)
- Crosses sutures but limited by dural attachments

Neoplasm

- Meningioma
- Soft tissue component (subperiosteal) of osseous mass
  - Metastasis, lymphoma, primary sarcoma
- Dural-based mass
  - Metastases, lymphoma, mesenchymal tumor

Infection/Inflammation

- Subperiosteal extension of osseous inflammatory lesion
- Epidural empyema secondary to osteomyelitis
- Soft tissue from granulomatous osseous lesion
  - Tuberculosis

https://CafePezeshki.IR

Extramedullary Hematopoiesis

- History of blood dyscrasia

PATHOLOGY

General Features

- Etiology
  - Trauma most common
    - Fracture lacerates vessel
      - Arterial (90-95%), venous (5-10%)
    - Arterial EDH is most often near MMA groove fracture
    - Venous EDH is usually near fracture that crosses dural sinus
  - Nontraumatic
    - Coagulopathy, thrombolysis, vascular malformation, neoplasm, epidural anesthesia, Paget disease of skull
    - "Spontaneous" EDH is rare; may arise from skull metastases
- Associated abnormalities
  - Skull fracture in 95%, may cross MMA groove
  - Subdural/subarachnoid hemorrhage, contusion

Gross Pathologic & Surgical Features

- EDH is a subperiosteal hematoma
  - Outer dural layer function as periosteum of inner calvaria
- Hematoma collects between calvaria and outer dura
  - Rarely crosses sutures
    - Exception: Venous EDH, large hematoma with diastatic fracture
- "Vertex" EDH (rare)
  - Usually venous: Linear or diastatic fracture crosses superior sagittal sinus
- 20% have blood in both epidural and subdural spaces at surgery or autopsy

CLINICAL ISSUES

Presentation

- Most common signs/symptoms
  - Classic "lucid interval": ~ 50% of cases
    - Initial brief loss of consciousness (LOC)
    - Subsequent asymptomatic time between LOC and symptom/coma onset
  - Headache, nausea, vomiting, seizures, focal neurological deficits (e.g., field cuts, aphasia, weakness)
  - Mass effect/herniation common
    - Pupil-involving CN3 palsy, somnolence, ↓ consciousness, coma
- Clinical profile
  - Alcohol and other intoxications are associated with ↑ incidence of EDH

Demographics

- Age
  - More common < 20 years; extremely rare in elderly
  - Uncommon in infants
- Gender
  - M:F = 4:1
- Epidemiology
  - 1-4% of imaged head trauma patients
  - 5-15% of patients with fatal head injuries

Natural History & Prognosis

- Factors affecting rate of growth
  - Arterial vs. venous, rate of extravasation
  - Occasionally decompresses through fracture into scalp
  - Tamponade
- Delayed development or enlargement common
  - 10-25% of cases within first 36 hours
- Good outcome if promptly recognized and treated
  - Overall mortality is ~ 5%
  - Bilateral EDHs have higher mortality and morbidity
    - 15-20% mortality rate
- Increased mortality in posterior fossa EDH (26%)
  - Can have delayed symptom onset secondary to slower expansion from lower venous pressure

Treatment

- Prompt recognition and appropriate treatment are essential
  - Poor outcome often related to delayed referral, diagnosis, or operation
- Most EDHs are surgically evacuated
  - Options: Endovascular/endoscopic if poor surgical candidate
  - Mixed-density acute EDHs require earlier, more aggressive treatment
- Some EDHs < 1 cm with no cerebral edema are managed nonoperatively
  - Repeat CT in first 36 hours to monitor for change
    - 23% enlarge within 36 hours
    - Mean enlargement: 7 mm
  - Anterior middle fossa EDHs are venous and usually do not require surgery
- Complications: Mass effect, edema, herniations

DIAGNOSTIC CHECKLIST

Image Interpretation Pearls

- NECT is highly sensitive
  - Coronal CT reconstructions to evaluate vertex EDH
- Use bone CT to look for fracture
- Consider CTV if fracture is near venous sinus

SELECTED REFERENCES

1. Kumar PM et al: Epidural hematoma secondary to solitary skull metastasis from an ovarian carcinoma. Asian J Neurosurg. 9(2):112-4, 2014
2. Le Roux P et al: Race against the clock: overcoming challenges in the management of anticoagulant-associated intracerebral hemorrhage. J Neurosurg. 121 Suppl:1-20, 2014
3. Maxwell WL: Traumatic brain injury in the neonate, child and adolescent human: an overview of pathology. Int J Dev Neurosci. 30(3):167-83, 2012
4. Gean AD et al: Benign anterior temporal epidural hematoma: indolent lesion with a characteristic CT imaging appearance after blunt head trauma. Radiology. 257(1):212-8, 2010
5. De Souza M et al: Nonoperative management of epidural hematomas and subdural hematomas: is it safe in lesions measuring one centimeter or less? J Trauma. 63(2):370-2, 2007

https://CafePezeshki.IR

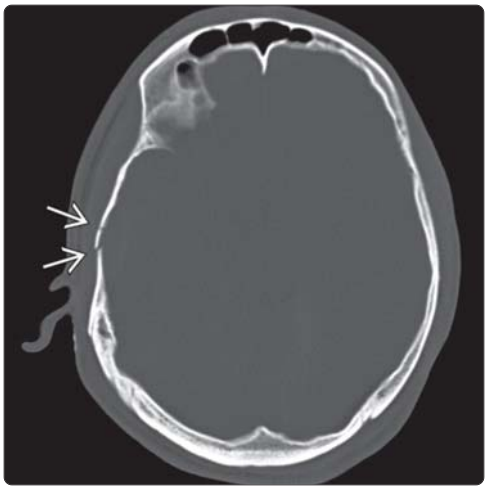

(Left) *Axial bone CT demonstrates a portion of a comminuted fracture about the pterion* ➡. **(Right)** *Axial NECT in the same case reveals a small yet classic biconvex epidural hematoma* ➡ *underlying the skull fracture. There is also a posterior falcine subdural hematoma tracking along the tentorium* ➡ *and superior sagittal sinus* ⇨.

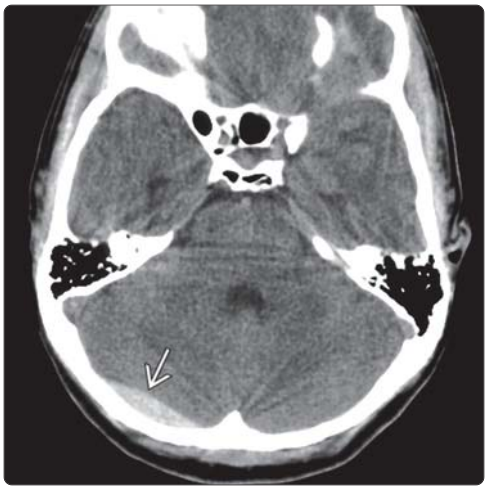

(Left) *Axial NECT demonstrates a biconvex venous epidural hematoma that extends both below* ➡ *the tentorium as well as above it.* **(Right)** *Axial NECT in the same patient demonstrates a biconvex venous epidural hematoma that extends both above* ➡ *and below the tentorium.*

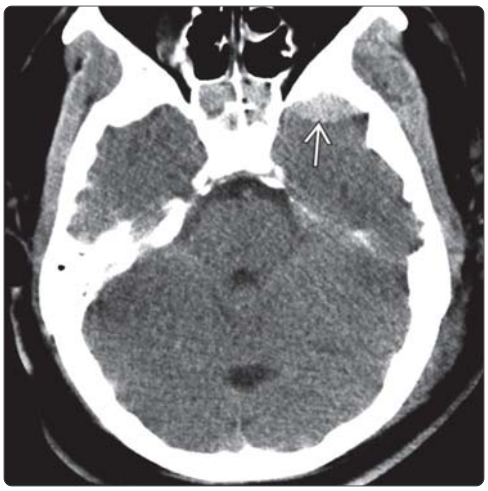

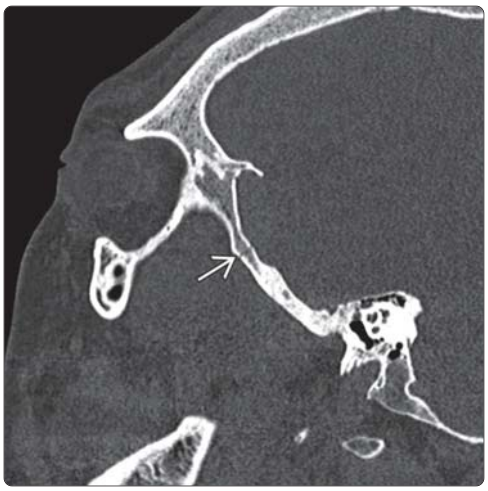

(Left) *Axial NECT shows an anterior middle fossa epidural hematoma* ➡. **(Right)** *Sagittal bone CT shows a nondisplaced linear fracture* ➡ *that crosses the greater sphenoid wing. Such epidural hematomas cross the sphenoparietal sinus, are usually venous, and typically do not require surgery.*

https://CafePezeshki.IR

KEY FACTS

TERMINOLOGY

- "Typical" epidural hematoma (EDH)
  - Arterial laceration
  - 90-95% supratentorial (temporoparietal most common)
  - Biconvex, unilateral
- Atypical EDH
  - Unusual etiology
  - Unusual location
  - Unusual shape or density

IMAGING

- Venous EDH (10% of EDHs)
  - Fracture (linear, diastatic) crosses dural venous sinus
  - Skull base, vertex
  - Easily overlooked
  - Coronal, sagittal reformats key to diagnosis
- Anterior Temporal EDH (10% of EDHs)
  - Middle cranial fossa
    - In front of--not lateral to--temporal lobe
  - Fracture crosses sphenoparietal sinus
  - Generally asymptomatic (1-2 cm, stable size)
  - No reported cases requiring surgery
- Vertex EDH (1-2% of EDHs)
  - Fracture crosses, lacerates superior sagittal sinus
  - Accumulates slowly
  - Symptoms often delayed
  - Easily overlooked, size underestimated on axial CT
  - Coronal, sagittal reformatted images key
- Clival EDH (< 1% of EDHs)
  - Lacerates clival venous plexus
  - Self-limited; dura tightly attached, so rarely large
  - Asymptomatic unless associated vascular, cranial nerve injury
  - Biconvex hyperdensity immediately posterior to clivus
  - Sagittal reformatted images key to diagnosis

(Left) *Axial graphic depicts different basilar skull fractures that cross, and may injure, important vascular structures. Note the linear skull fracture crossing the right transverse sinus. The lacerated sinus causes a venous EDH to accumulate. The injured sinus often thromboses, as is depicted here.* **(Right)** *Axial NECT scan in a 26-year-old man who fell 10 meters onto his head shows a large left temporal lobe contusion. A small biconvex hyperdense fluid collection is seen adjacent to the right transverse sinus.*

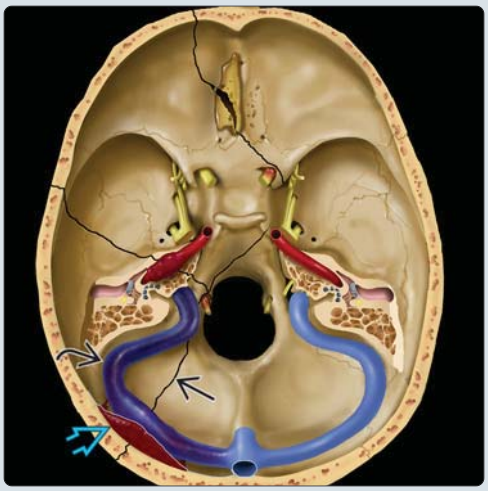

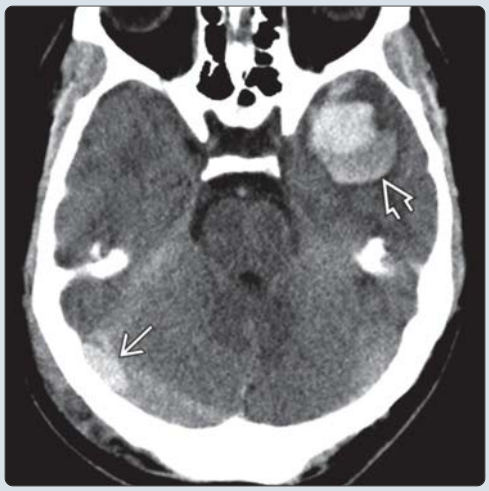

(Left) *Bone CT in the same patient shows a diastatic fracture through the right lambdoid suture.* **(Right)** *Sagittal CT venogram shows that the transverse sinus is elevated and displaced anteriorly by a hyperdense venous EDH. Note that the venous EDH lies both above and below the site of dural attachment. Venous EDHs commonly cross dural attachments, whereas classic arterial EDHs rarely do.*

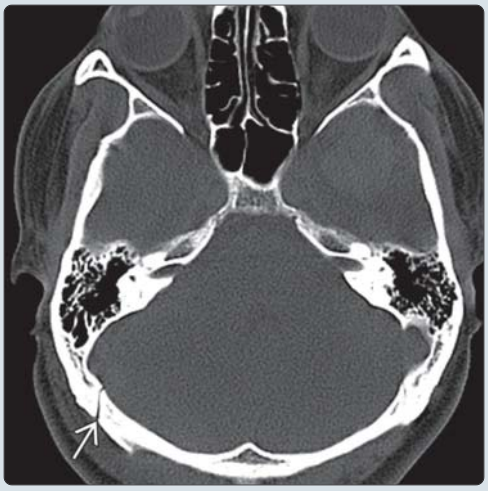

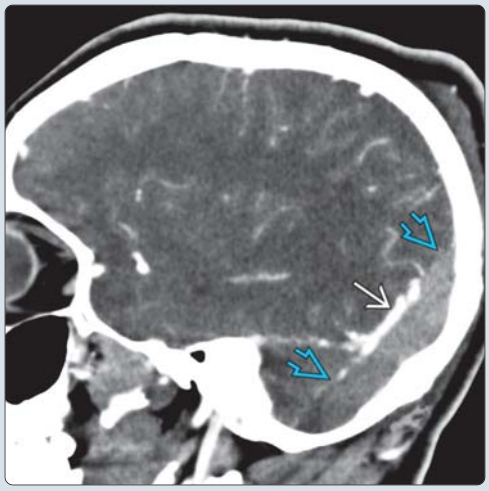

https://CafePezeshki.IR

TERMINOLOGY

Definitions

- Typical EDH
  - Arterial laceration
  - 90-95% supratentorial (temporoparietal most common)
  - Lateral temporoparietal location
  - Biconvex, unilateral
- Atypical EDH
  - Unusual etiology
    - Venous, not arterial
  - Unusual location
    - Anterior middle cranial fossa EDH
    - Vertex EDH
    - Clival EDH
  - Unusual shape or density
    - Venous EDH may decompress into dural sinus
    - Initially hyperdense but may become mostly hypodense

IMAGING

Venous EDH

- 10% of all EDHs
- Fracture (linear, diastatic) crosses dural venous sinus
- Most common sites
  - Skull base, vertex
  - Can cross dural attachments
  - Often crosses sutures
- Imaging
  - Easily overlooked
  - Coronal, sagittal reformats key to diagnosis
  - CTA/CTV helpful

Anterior Temporal EDH

- Not uncommon (10% of all EDHs)
- Etiology
  - Fracture crosses sphenoparietal sinus
  - Anterior middle cranial fossa
    - In front of (not lateral to) temporal lobe
  - Anatomically limited
    - Laterally by sphenoparietal suture
    - Medially by orbital fissure
- Clinical
  - Generally asymptomatic
  - No reported cases requiring surgery
- Imaging
  - Virtually all have associated skull fractures (use thin sections, bone algorithm)
    - 57% greater sphenoid wing
    - 43% zygomaticomaxillary
  - Size
    - Stable; do not enlarge with time
    - 1-2 cm maximum diameter

Vertex EDH

- Uncommon (1-2% of EDHs)
  - Usually venous
- Linear &/or diastatic fracture
  - Crosses superior sagittal sinus
  - Usually crosses midline
- Clinical
  - Accumulates slowly
  - Symptoms often delayed
- Imaging
  - Easily overlooked; size is underestimated on axial CT
  - Coronal, sagittal reformatted images key
  - CTV/MR with MRV helpful

Clival EDH

- Very rare (< 1% of EDHs)
- Linear skull fracture crosses basisphenoid
  - Lacerates clival venous plexus
  - Self-limited; dura tightly attached, so rarely large
- Clinical
  - Asymptomatic unless associated vascular or cranial nerve injury
- Imaging
  - Biconvex hyperdensity posterior to clivus
  - Sagittal reformatted images key to diagnosis

DIFFERENTIAL DIAGNOSIS

Subdural Hematoma

- Usually crescentic (not biconvex)
- Confined by dural attachments of falx or tentorium
- Can coexist with EDH

Hyperdense Neoplasm

- Trauma history absent
- Hyperdense neoplasms include
  - Meningioma
  - Lymphoma
  - Metastasis

Dural Pseudotumors

- IgG4-related disease
- Histiocytoses
- Infection (tuberculosis)

SELECTED REFERENCES

1. Cikla U et al: Vertex epidural hematoma and triplegia. Neurol India. 62(4):437-8, 2014
2. Xiao B et al: Could a traumatic epidural hematoma on early CT tell us about its future development? A multi-center retrospective study in China. J Neurotrauma. ePub, 2014
3. Yamada SM et al: Delayed post-traumatic large subgaleal hematoma caused by diastasis of rhomboid skull suture on the transverse sinus. Childs Nerv Syst. ePub, 2014
4. Skadorwa T et al: Distinct strategies in the treatment of epidural hematoma in children: clinical considerations. Pediatr Neurosurg. 49:166-71, 2013
5. Balik V et al: Posterior fossa extradural haematomas. Cent Eur Neurosurg. 71(4):167-72, 2010
6. Gean AD et al: Benign anterior temporal epidural hematoma: indolent lesion with a characteristic CT imaging appearance after blunt head trauma. Radiology. 257(1):212-8, 2010

https://CafePezeshki.IR

(Left) *Axial graphic depicts the dural venous sinuses at the skull base. The sphenoparietal sinuses ⇨ curve around the greater sphenoid wing, then drain into the cavernous sinus. The clival venous plexus ⇨ is usually septated, so venous EDHs in this location are typically limited.* **(Right)** *Axial NECT scan (top) shows a small biconvex EDH ➡ anterior to the left temporal lobe. Bone CT (below) shows a nondisplaced linear fracture ➡ through the greater sphenoid wing.*

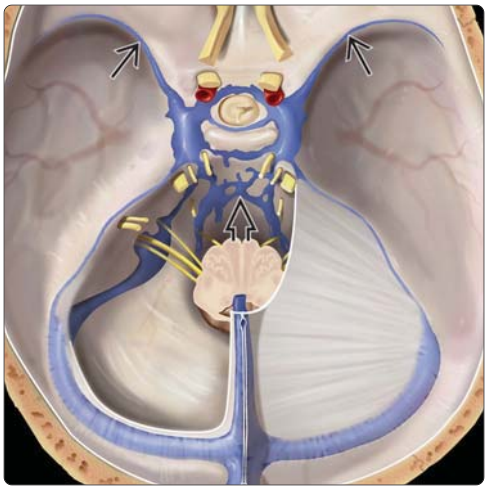

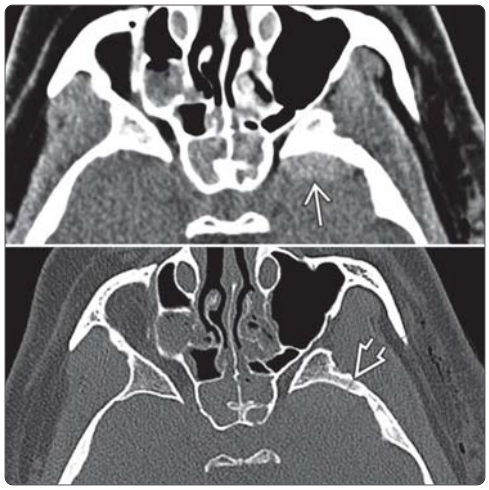

(Left) *Axial NECT scan shows a typical anterior temporal epidural hematoma ➡.* **(Right)** *Follow-up NECT scan in the same patient 24 hours later shows that the anterior temporal EDH ➡ is unchanged in size but now appears mostly hypodense. This is not caused by rapid bleeding; it is most likely caused by decompression of the EDH into the lacerated sphenoparietal sinus.*

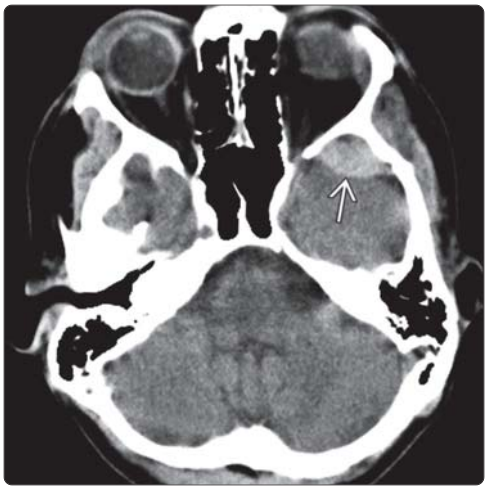

(Left) *Axial NECT scan in a 19-year-old man with basilar skull fractures shows a small biconvex EDH ➡ posterior to the clivus.* **(Right)** *Sagittal CT venogram in the same patient demonstrates the small clival EDH ⇨ under the enhancing clival venous plexus ➡.*

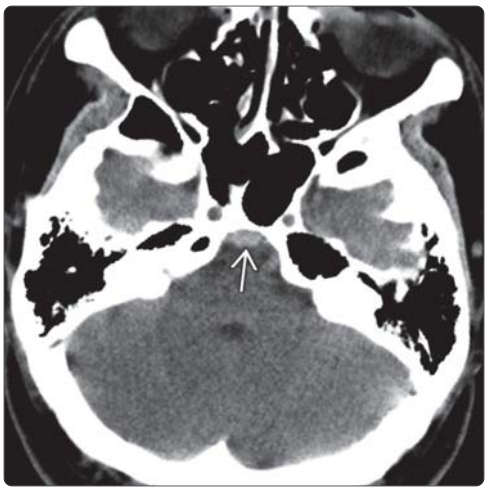

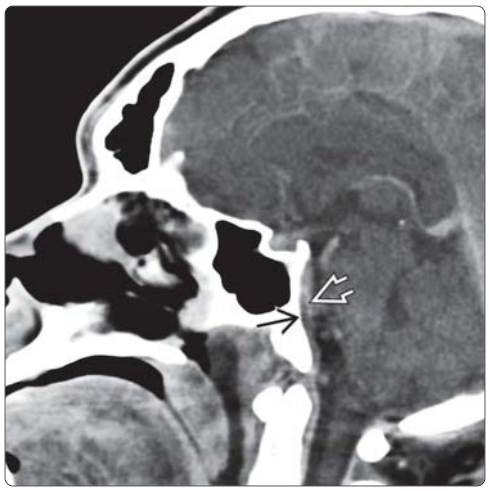

https://CafePezeshki.IR

(Left) *Axial NECT scan in a 57-year-old man shows a biconvex EDH ➡ over the left frontal convexity of the brain.* **(Right)** *Coronal NECT scan reformatted from the axial data in the same patient shows the vertex EDH ➡.*

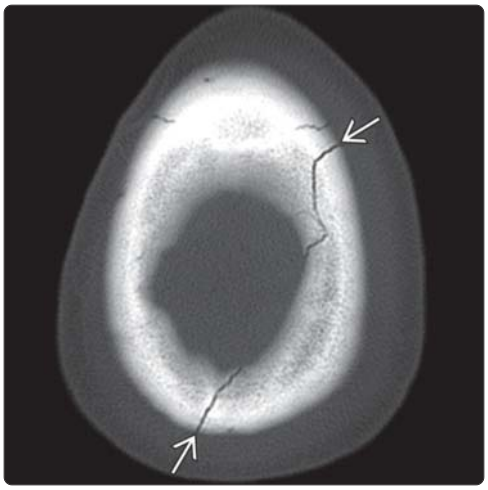

(Left) *Axial bone CT in the same patient shows a linear fracture ➡ that crosses the midline.* **(Right)** *Two hours later, the patient deteriorated. Axial CT venogram shows the vertex EDH has enlarged, narrowing the superior sagittal sinus (SSS) ➡ which also appears somewhat irregular in configuration. The EDH now contains hypodense foci ➡, suggesting ongoing acute hemorrhage into the epidural space.*

(Left) *Coronal reformatted CTV shows the vertex EDH ➡ is much larger and now crosses the midline. The SSS ➡, is displaced inferiorly from the calvaria and appears severely compressed. An "empty delta" sign is present, suggesting the SSS is at least partially thrombosed.* **(Right)** *Sagittal CTV nicely shows the expanding vertex EDH, which now appears to have 2 adjacent compartments ➡. Venous EDH was evacuated at surgery and the torn, partially thrombosed SSS repaired.*

https://CafePezeshki.IR

KEY FACTS

TERMINOLOGY

- Acute blood in/between inner border cell layer of dura, arachnoid

IMAGING

- NECT as initial screening study
  - Use both bone, soft tissue algorithms
  - Use both standard brain, wide windows (150HU)
  - Coronal, sagittal reformatted scans best for detecting small subdural hematomas (SDHs)
- Findings
  - Crescentic hyperdense extraaxial collection
    - Spreads diffusely over cerebral convexity
    - Often extends along falx, tentorium
  - Inward displacement of cortical veins, sulci
  - May cross sutures, not dural attachments

TOP DIFFERENTIAL DIAGNOSES

- Other subdural fluid collections
  - Mixed SDH (acute on chronic/subacute SDH)
    - Hyperdense foci in pockets of iso-, hypodense fluid
  - Subdural hygroma
    - Clear CSF, no encapsulating membranes
  - Subdural effusion
    - Near CSF density
  - Subdural empyema
    - Peripheral enhancement, hyperintensity on FLAIR; restricted diffusion on DWI
- Acute epidural hematoma (typically crescentic)

PATHOLOGY

- Trauma most common cause
- Nontrauma (spontaneous) more common in elderly

DIAGNOSTIC CHECKLIST

- Inform responsible clinician if unsuspected finding
- Multiplanar reconstructions, wide windows best for subtle acute SDHs

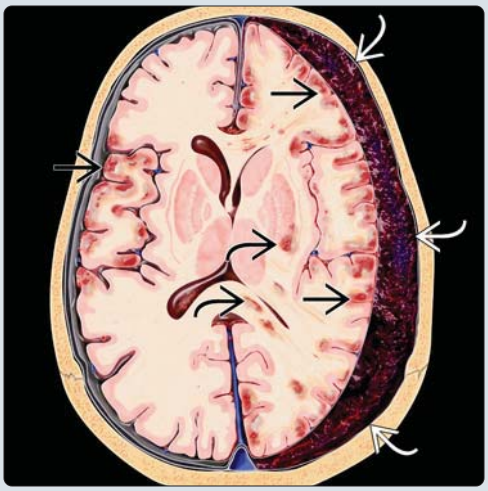

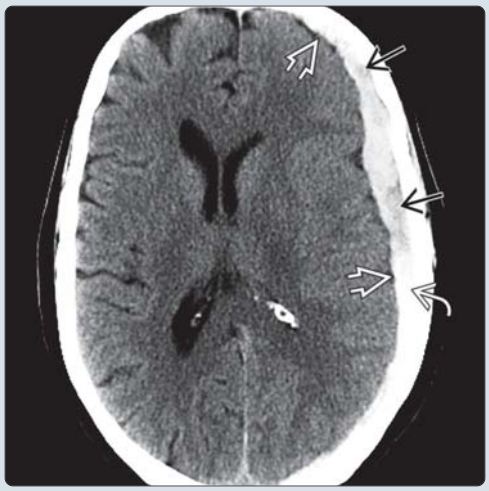

(Left) *Graphic shows acute subdural hematoma (aSDH) compressing the left hemisphere and lateral ventricle, resulting in midline shift. Coexisting cortical contusions and axonal injuries are common in aSDHs.* **(Right)** *Axial NECT in a 58-year-old woman with head trauma shows a classic aSDH extending over the left convexity and compressing the underlying subarachnoid space. The subtle hypodense foci within the hyperdense aSDH represent unclotted blood and risk for rapid hematoma expansion.*

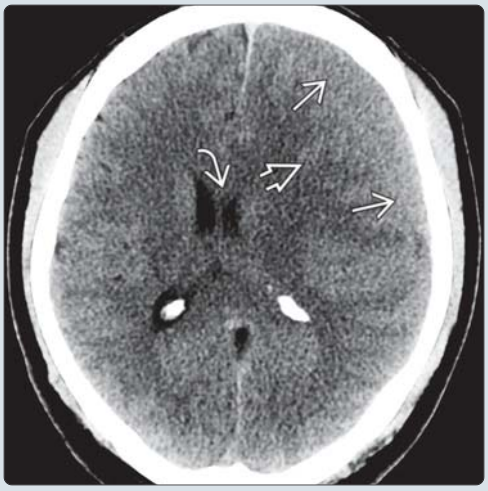

(Left) *Occasionally, acute SDHs are isodense to the underlying brain. Note the aSDH with mass effect, inward displacement of the underlying gray-white interface, and left-to-right subfalcine herniation of the lateral ventricles.* **(Right)** *More cephalad NECT scan in the same patient again shows the isodense aSDH. The underlying sulci are completely effaced. Compare this appearance of "absent sulci" with the normal-appearing CSF-filled sulci over the right hemisphere.*

https://CafePezeshki.IR

TERMINOLOGY

Abbreviations

- Acute subdural hematoma (aSDH)

Definitions

- Acute blood in or between inner border cell layer of dura and arachnoid

IMAGING

General Features

- Best diagnostic clue
  - CT: Crescentic, hyperdense, extraaxial collection spread diffusely over affected hemisphere
- Location
  - Between arachnoid and inner border cell layer of dura
  - Supratentorial convexity > interhemispheric, peritentorial
- Morphology
  - Crescent-shaped extraaxial fluid collection
  - May cross sutures, not dural attachments
  - May extend along falx, tentorium, and anterior and middle fossa floors

CT Findings

- NECT
  - Hyperacute SDH (≤ 6 hours) may have heterogeneous density or hypodensity
  - aSDH (6 hours to 3 days)
    - aSDH: 60% homogeneously hyperdense
    - 40% mixed hyper-, hypodense with active bleeding (swirl sign), torn arachnoid with CSF accumulation, clot retraction
    - Rare: Isodense aSDH (coagulopathy, anemia with Hgb < 8-10 g/dL)
    - If no new hemorrhage, density decreases ± 1.5 HU/day
- CECT
  - Inward displacement of cortical veins, gray-white interface
  - Dura and membranes enhance when subacute

MR Findings

- T1WI
  - Hyperacute (< 12 hours): Iso- to mildly hyperintense
  - Acute (12 hours to 2 days): Mildly hypointense
- T2WI
  - Hyperacute: Mildly hyperintense
  - Acute: Hypointense
- FLAIR
  - Typically hyperintense to CSF
  - Signal intensity varies depending on relative T1 and T2 effects
    - Acute hematomas can be isointense to CSF due to T2 shortening effects of intracellular methemoglobin
  - Often most conspicuous sequence
- T2* GRE
  - Hypointense unless hyperacute
- DWI
  - Heterogeneous signal (nonspecific)
  - May differentiate extraaxial empyema (marked central hyperintensity) from hemorrhage
- T1WI C+
  - Enhancement of displaced cortical veins
  - Hematoma doesn't enhance (delayed scans sometimes show minimal)
- MR signal of SDH is quite variable
  - Often evolves in similar fashion to intraparenchymal hemorrhage
  - Recurrent hemorrhage common; results in acute and chronic blood products even at initial exam
  - SDH signal is variable due to recurrent hemorrhage; difficult to age accurately
  - Pia-arachnoid membrane tears can lead to CSF leakage into SDH collections and may alter signal intensity by CSF dilution

Angiographic Findings

- CTA
  - Mass effect from extraaxial collection; veins displaced from inner table of skull
  - DSA only if underlying vascular lesion suspected on CTA

Imaging Recommendations

- Best imaging tool
  - NECT as initial screening study
    - Use both bone, soft tissue algorithms
    - Use both standard brain, wide windows (150HU)
    - Coronal, sagittal reformatted scans best for detecting small SDHs
  - MR is more sensitive but rarely used
    - Better depicts extent, age(s) of SDH
    - ± additional findings of traumatic brain injury

DIFFERENTIAL DIAGNOSIS

Other Subdural Collections

- Subdural hygroma
  - Clear CSF, no encapsulating membranes
- Subdural effusion
  - Xanthochromic fluid secondary to extravasation of plasma from membrane or meningitis
  - Near CSF density
- Empyema: Peripheral enhancement, hyperintensity on FLAIR; restricted diffusion on DWI

Epidural Hematoma

- Biconvex extraaxial collection
- Often associated with fracture
- May cross dural attachments, limited by sutures

Pachymeningopathies (Thickened Dura)

- Chronic meningitis (may be indistinguishable)
- Neurosarcoid: Often lumpy-bumpy appearance
- Postsurgical (e.g., shunt)
- Intracranial hypotension
  - "Slumping" midbrain, tonsillar herniation

Tumor

- Dural-based enhancing masses
  - Meningioma, lymphoma, leukemia, metastases
  - Mass like, not crescentic

https://CafePezeshki.IR

- ± skull and extracranial soft tissue involvement

Chemical Shift Artifact (MR)

- Marrow or subcutaneous fat may "shift," appear intracranial, and mimic T1 hyperintense SDH
  - Seen with ↑ field of view or ↓ bandwidth
  - Worse with higher field strength MR

PATHOLOGY

General Features

- Etiology
  - Trauma most common cause
    - Tearing of bridging cortical veins as they cross subdural space to drain into dural sinus
    - Nonimpact (falls) as well as direct injury
    - Trauma may be minor, particularly in elderly
      - Often recurrent with initial subclinical episodes
  - Nontraumatic (spontaneous) acute subdural hematoma (aSDH) is less common in nonelderly
    - Dissection of intraparenchymal hematoma into subarachnoid, then subdural space
    - Aneurysm rupture
    - Vascular malformations: Dural arteriovenous fistula, arteriovenous malformation (AVM), cavernoma
      - Typically other hemorrhages present (parenchymal &/or subarachnoid)
    - Moyamoya (greater propensity for hemorrhage in adults, ischemia in children)
    - Dural invasion by tumor with secondary hemorrhage (prostate cancer)
    - Spontaneous hemorrhage with severe coagulopathy
  - Predisposing factors
    - Atrophy
    - Ventricular shunting (→ increased traction on superior cortical veins)
    - Anticoagulation, intrinsic or extrinsic coagulopathy (e.g., alcohol abuse)
- Associated abnormalities
  - > 70% have other significant associated traumatic lesions
  - If mass effect, shift > aSDH thickness, suspect underlying edema/excitotoxic injury

Gross Pathologic & Surgical Features

- "Currant jelly" crescent-shaped hematoma
- Membranes/granulation tissue develop later

Microscopic Features

- Outer membrane of proliferating fibroblasts and capillaries
  - Fragile capillaries may become source of recurrent hemorrhage
- Inner membrane (made up of dural fibroblasts or border cells) forms fibrocollagenous sheet

CLINICAL ISSUES

Presentation

- Most common signs/symptoms
  - Most commonly following trauma
  - Varies from asymptomatic to loss of consciousness
    - "Lucid" interval in aSDH: Initially awake, alert patient loses consciousness a few hours after trauma
    - Patients with early symptomatic presentation (< 4 hours) and advanced age have poor prognosis
  - Other symptoms (focal deficit, seizure) from mass effect, diffuse brain injury, secondary ischemia
  - Coagulopathy or anticoagulation increase risk and extent of hemorrhage

Demographics

- Any age, more common in elderly
- No gender predilection
- Epidemiology
  - Found in 30% of autopsy cases following craniocerebral trauma

Natural History & Prognosis

- Can grow slowly with increased mass effect if untreated
- Compresses and displaces underlying brain
- Recurrent hemorrhage common; in children, raises suspicion of nonaccidental trauma

Treatment

- Poor prognosis (35-90% mortality)
  - Emergency preoperative high-dose mannitol may improve outcome
- Surgically relevant features (especially in elderly)
  - Maximum hematoma thickness (≥ 10 mm), midline shift
- Lethal if hematoma volume > 8-10% of intracranial volume

DIAGNOSTIC CHECKLIST

Consider

- NECT initial screen
- MR if degree of mass effect &/or symptoms are greater than expected for size of SDH
  - Helps identify extent of traumatic brain injury
  - MR to evaluate nontraumatic causes
- In child with recurrent or mixed-age hemorrhage, suspect nonaccidental trauma

Image Interpretation Pearls

- Wide window settings for CT increases conspicuity of subtle SDH
- FLAIR, T2* usually most sensitive sequences for SDH
- CT density and MR intensity vary with age and degree of recurrent hemorrhage and contribution of CSF (arachnoid tears)

SELECTED REFERENCES

1. Coombs JB et al: Acute spontaneous subdural hematoma in a middle-aged adult: case report and review of the literature. J Emerg Med. 47(3):e63-8, 2014
2. Evans JA et al: A simple tool to identify elderly patients with a surgically important acute subdural haematoma. Injury. ePub, 2014
3. Monea AG et al: The biomechanical behaviour of the bridging vein-superior sagittal sinus complex with implications for the mechanopathology of acute subdural haematoma. J Mech Behav Biomed Mater. 32:155-65, 2014
4. Godlewski B et al: Retrospective analysis of operative treatment of a series of 100 patients with subdural hematoma. Neurol Med Chir (Tokyo). 53(1):26-33, 2013

https://CafePezeshki.IR

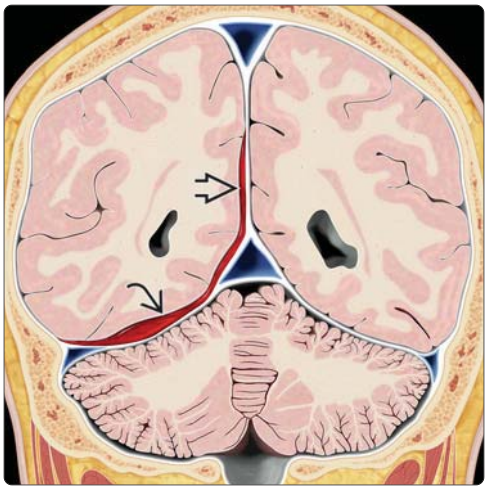

(Left) *Coronal graphic depicts thin aSDH layering along the falx and tentorium. Such aSDHs may be difficult to identify on axial images alone. Multiplanar reconstructions are very helpful in identifying small thin aSDHs.* **(Right)** *Axial NECT scan in a 31-year-old man with minor trauma shows subtle hyperdensity along the tentorium and inferior falx near the confluence of the venous sinuses.*

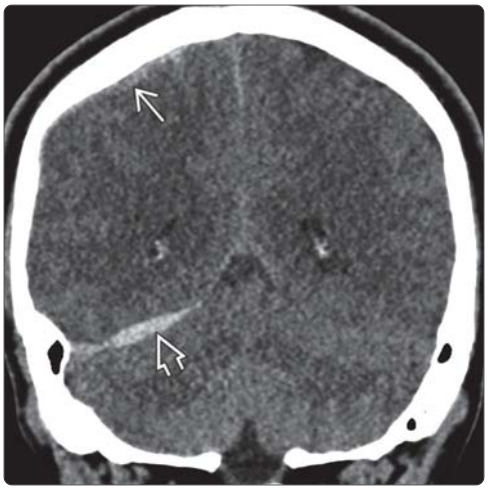

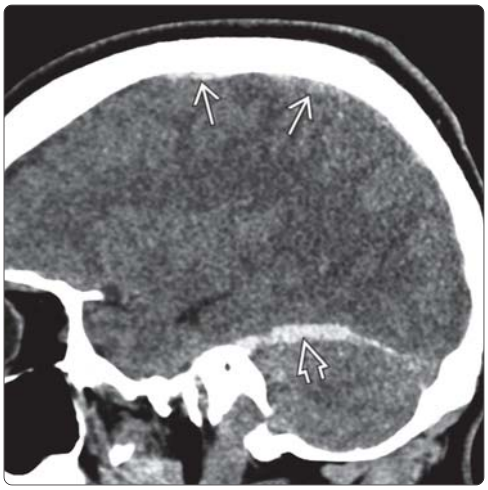

(Left) *Coronal reformatted scan from the axial data in the same patient shows the small acute peritentorial SDH. A small subtle convexity aSDH is seen here and was not visible on the axial scan.* **(Right)** *Sagittal reformatted image in the same patient shows the peritentorial aSDH and the subtle convexity aSDH that was invisible on the axial study.*

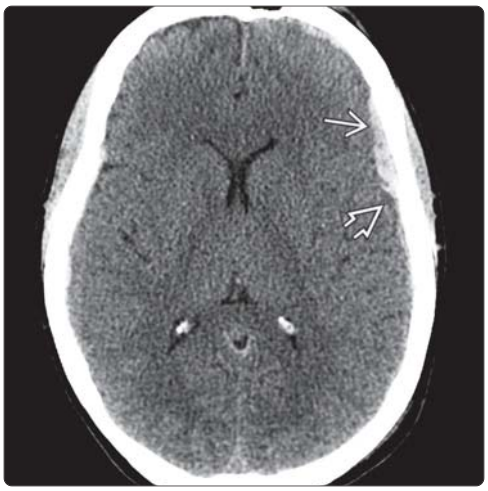

(Left) *Axial NECT scan in a 30-year-old man with head trauma shows a small mixed density aSDH over the left frontal and parietal lobes. Subtle hypodensity within the aSDH was concerning for rapid accumulation of unclotted blood.* **(Right)** *The patient (same case) deteriorated 5 hours later. The aSDH has expanded significantly, and there are multiple foci of hypodensity within the hematoma indicating rapid bleeding. Note the subfalcine herniation of the lateral ventricles.*

https://CafePezeshki.IR

KEY FACTS

TERMINOLOGY

- Subacute (~ 3 days to 3 weeks) collection
  - In subdural space (between arachnoid and dura or within inner border cell layer)
  - Partially liquified clot, resorbing blood products
  - Surrounded by granulation tissue ("membrane")

IMAGING

- Crescent-shaped, iso- to hypodense extraaxial collection
  - Spreads diffusely over hemisphere
  - May be of same density as underlying cortex
  - Look for inwardly displaced "dots" of cerebrospinal fluid (CSF)
- May cross sutures, not dural attachments
- T1 iso- to hyperintense
- T2 hyperintense
- Does not suppress on FLAIR
- DWI may show "double layer" appearance
- General imaging recommendations
  - NECT initial screen
  - Consider CECT for membranes/loculations
  - MR is more sensitive for SDH, detecting additional traumatic brain injuries

TOP DIFFERENTIAL DIAGNOSES

- Other subdural collections
  - Effusion
  - Hygroma
  - Empyema
- Pachymeningopathies (thickened dura)
  - Look for other signs of intracranial hypotension
- Chronic dural sinus thrombosis
- Tumor

PATHOLOGY

- Traumatic stretching/tearing of bridging cortical veins as they cross subdural space
- Trauma may be minor (particularly in elderly)

(Left) *Axial graphic shows a typical subacute subdural hematoma (sSDH) ➡. Inset shows the traversing "bridging" vein ⇨ and developing membranes ➡. These are often related to relatively minor trauma in the elderly.* **(Right)** *SDHs decrease by ~ 1.5 HU/day. By 7-10 days, blood in the hematoma becomes isodense with cortex. By about 10-14 days, it is hypodense compared to adjacent brain.*

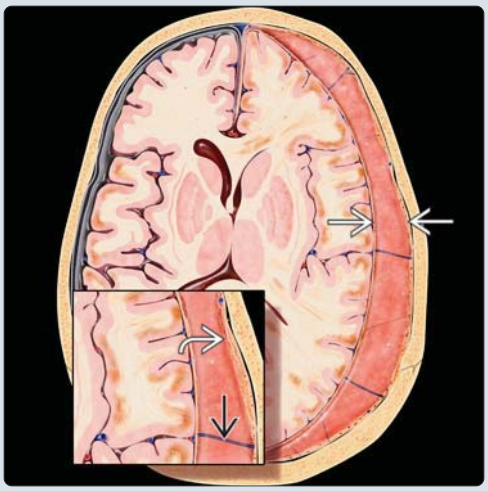

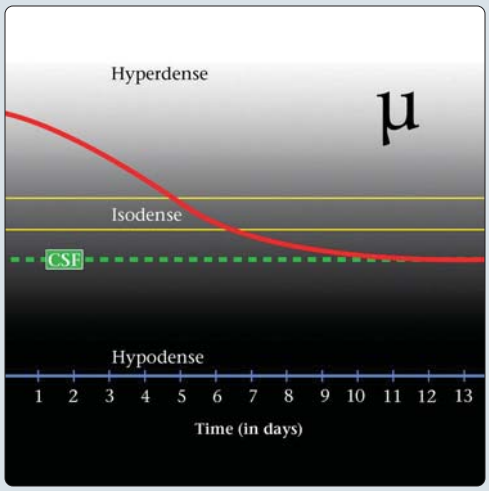

(Left) *Axial NECT scan shows a right sSDH ➡ that is isodense with the underlying cortex. Note the inward displacement of "dots" of CSF ⇨ in compressed, underlying sulci. The gray-white matter (GM-WM) interface ➡ is "buckled" inwards (compared with normal-appearing left side).* **(Right)** *Bilateral "balanced" isodense sSDHs ➡ are present in the case. Note that both GM-WM interfaces are inwardly displaced & the underlying sulci are compressed. A displaced "dot" of CSF ⇨ is seen under the left sSDH.*

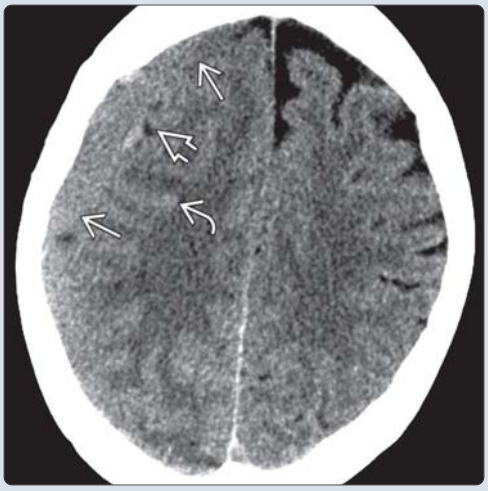

https://CafePezeshki.IR

TERMINOLOGY

Abbreviations

- Subacute subdural hematoma (sSDH)

Definitions

- Subacute (~ 3 days to 3 weeks) collection of partially liquified clot, resorbing blood products surrounded by granulation tissue ("membrane")

IMAGING

General Features

- Best diagnostic clue
  - Crescent-shaped, iso- to hypodense on CT, extraaxial collection that spreads diffusely over hemisphere
- Location
  - Between arachnoid and dura or within inner border cell layer of dura
- Morphology
  - Crescent-shaped extraaxial fluid collection
  - May cross sutures, not dural attachments
  - May extend along falx and tentorium
  - Compresses and displaces underlying brain surface, cortical vessels, and subarachnoid space fluid
    - Sulci are often effaced
  - Recurrent, mixed-age hemorrhage is common and raises suspicion of nonaccidental trauma in children
  - CT density and MR signal intensity vary with age and organization of hemorrhage

CT Findings

- NECT
  - Iso- to hypodense; may be same density as underlying cortex
  - Gray-white matter (GM-WM) junction is displaced medially
  - Surface sulci do not reach inner calvarial table
  - May see line of displaced/compressed sulci as "dots" of cerebrospinal fluid (CSF)
  - Density varies depending on stage of evolution
    - Progression from hyperdense (acute SDH) to isodense (sSDH) to hypodense (chronic SDH) over ~ 3 weeks
    - Recurrent hemorrhage can result in mixed density hematomas
- CECT
  - Dura and membranes enhance
  - Inward displacement of enhancing cortical vessels

MR Findings

- T1WI
  - Typically iso- (early sSDH) to hyperintense (late sSDH)
- T2WI
  - Varies; becomes more hyperintense with time (extracellular methemoglobin)
  - May see linear hypointensity due to membranes that predispose to repeated hemorrhage
- PD/intermediate
  - Variable signal: Iso- to hyperintense, depending on protein content or rebleed into collection and relative T1 and T2 contributions
- FLAIR
  - Signal varies depending on relative contribution of T1 and T2 effects
  - Typically does not suppress
    - Prominent T1 shortening often results in bright FLAIR signal
    - May be hypointense (early sSDH) due to T2 shortening effects
    - Early subacute hematomas, if small, can be nearly "invisible" on FLAIR
      - Look carefully for mass effect, sulcal effacement, &/or vessel displacement
- T2* GRE
  - Susceptibility artifact ("blooming") common
- DWI
  - Signal intensity varies with hematoma age
    - Crescentic high intensity with low intensity rim next to brain
      - "Double layer" appearance
      - Hyperintense band indicates relatively fresh bleeding from outer membrane
    - Hyperintense foci suggest solid clots
- T1WI C+
  - Enhancing and thickened dura is common
  - Enhancing membranes may be seen
    - Suggest unstable SDH prone to rehemorrhage
    - Delayed scans may show contrast diffusion into SDH
- Signal on MR often parallels that of intracerebral hematoma
  - Exceptions reported for early subacute hematomas
  - T2/FLAIR may be hyperintense in early sSDH
- Early MR is favored as most concurrent injuries are more conspicuous in early subacute phase

Imaging Recommendations

- Best imaging tool
  - NECT as initial screen
  - Consider CECT for membranes/loculations
  - MR is more sensitive for SDH
    - Can show additional findings of traumatic brain injury
- Protocol advice
  - Add FLAIR, DWI, and GRE to MR protocol for hemorrhage/trauma indications

DIFFERENTIAL DIAGNOSIS

Other Subdural Collections

- Effusion
  - MR: Typically follows CSF signal
  - Often related to meningitis, postop, or intracranial hypotension
- Empyema
  - MR: Peripheral enhancement; DWI+
  - Often related to sinus infection or penetrating injury
- Hygroma
  - MR: Follows CSF signal; no membranes
  - Results from tear in arachnoid; without hemorrhage

Pachymeningopathies (Thickened Dura)

- Chronic meningitis (may be indistinguishable)
- Postsurgical (shunt, etc.)
- Intracranial hypotension

https://CafePezeshki.IR

- "Slumping" midbrain; tonsillar herniation
- Sarcoid (often nodular, more lumpy-bumpy appearance)

Chronic Dural Sinus Thrombosis

- Diffuse dural thickening and enhancement

Tumor

- Meningioma, lymphoma, leukemia, metastases
- Dural-based enhancing mass ± skull involvement

Chemical Shift Artifact

- Marrow or subcutaneous fat may "shift" → can appear intracranial and mimic T1 hyperintense SDH

PATHOLOGY

General Features

- Etiology
  - Traumatic stretching and tearing of bridging cortical veins as they cross subdural space
  - Trauma may be minor, particularly in elderly
  - Mechanisms of enlargement
    - Rehemorrhage
    - Serum protein exudation

Gross Pathologic & Surgical Features

- Membranes: Granulation tissue with resorbing blood products
- Outer membrane related to hematoma enlargement with repetitive hemorrhages
- Inner membrane related to liquefaction of subdural hematoma

CLINICAL ISSUES

Presentation

- Most common signs/symptoms
  - Range from asymptomatic to loss of consciousness
- Other signs/symptoms
  - Headaches, seizures, focal neurological deficit

Demographics

- Age
  - Young and elderly
- Gender
  - M > F
- Epidemiology
  - SDH is found in 10-20% of patients imaged and 30% of autopsy cases following craniocerebral trauma

Natural History & Prognosis

- Can spontaneously resolve or enlarge
- Older age and brain atrophy are contributory factors in conversion of traumatic SDH into subacute and chronic SDH
- Higher recurrence rate for skull base location SDH compared with convexity SDH

Treatment

- Surgical drainage indicated if growing/symptomatic
- Resection of membranes, if present
- "Separated" morphology has highest rehemorrhage rates

DIAGNOSTIC CHECKLIST

Consider

- Contrast enhancement if suspected isodense SDH to look for membrane formation/loculations
- MR with DWI to assess for presence of membranes

Image Interpretation Pearls

- Remember: MR signal of SDH is quite variable
  - Generally (but not always) evolves in pattern similar to intracerebral hemorrhage
- Enhancement is helpful to differentiate sSDH and chronic SDH from pachymeningopathies
- If sSDHs present without trauma history, evaluate coagulation status and look for signs of intracranial hypotension

SELECTED REFERENCES

1. Kolias AG et al: Chronic subdural haematoma: modern management and emerging therapies. Nat Rev Neurol. 10(10):570-578, 2014
2. Kompheak H et al: Surgery for bilateral large intracranial traumatic hematomas: evacuation in a single session. J Korean Neurosurg Soc. 55(6):348-52, 2014
3. Godlewski B et al: Retrospective analysis of operative treatment of a series of 100 patients with subdural hematoma. Neurol Med Chir (Tokyo). 53(1):26-33, 2013
4. Nayil K et al: Subdural hematomas: an analysis of 1181 Kashmiri patients. World Neurosurg. 77(1):103-10, 2012
5. Tehli O et al: Subdural hematomas and emergency management in infancy and childhood: a single institution's experience. Pediatr Emerg Care. 27(9):834-6, 2011
6. Kemp AM et al: What neuroimaging should be performed in children in whom inflicted brain injury (iBI) is suspected? A systematic review. Clin Radiol. 64(5):473-83, 2009
7. Souirti Z et al: Spontaneous bilateral subacute subdural hematoma revealing intracranial hypotension. Neurosciences (Riyadh). 14(4):384-5, 2009
8. Duhem R et al: [Main temporal aspects of the MRI signal of subdural hematomas and practical contribution to dating head injury.] Neurochirurgie. 52(2-3 Pt 1):93-104, 2006
9. Kuwahara S et al: Diffusion-weighted imaging of traumatic subdural hematoma in the subacute stage. Neurol Med Chir (Tokyo). 45(9):464-9, 2005
10. Kuwahara S et al: Subdural hyperintense band on diffusion-weighted imaging of chronic subdural hematoma indicates bleeding from the outer membrane. Neurol Med Chir (Tokyo). 45(3):125-31, 2005
11. Mori K et al: Delayed magnetic resonance imaging with GdD-DTPA differentiates subdural hygroma and subdural effusion. Surg Neurol. 53(4):303-10; discussion 310-1, 2000

https://CafePezeshki.IR

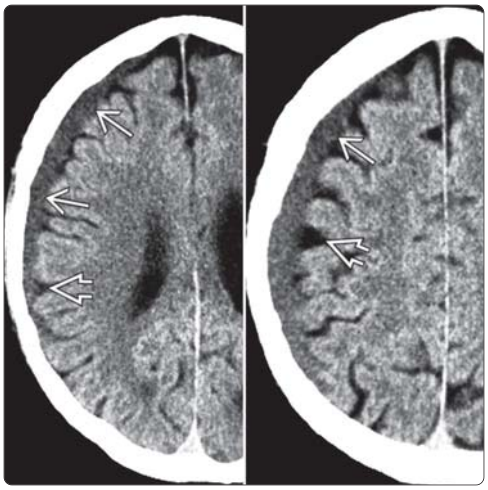

(Left) *NECT scan in an elderly patient with a late sSDH and moderate cortical atrophy shows the difference between the nearly isodense SDH* ⇨ *and the hypodense CSF in the underlying compressed subarachnoid spaces* ⇨. **(Right)** *SDHs of different ages are common in elderly anticoagulated patients. The right SDH is subacute (isodense with underlying brain), and the left-sided collection is more chronic-appearing. Note the severe compression of the underlying brain and sulci. The falx is partially calcified.*

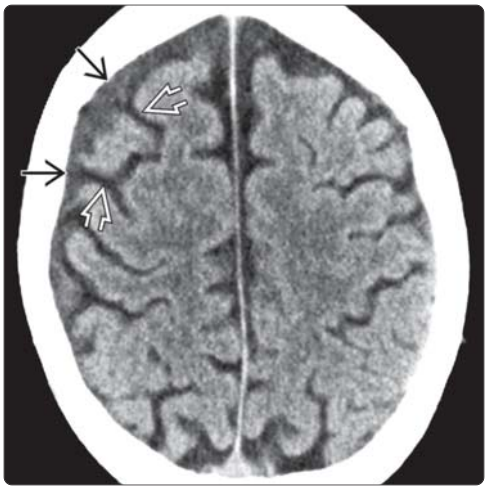

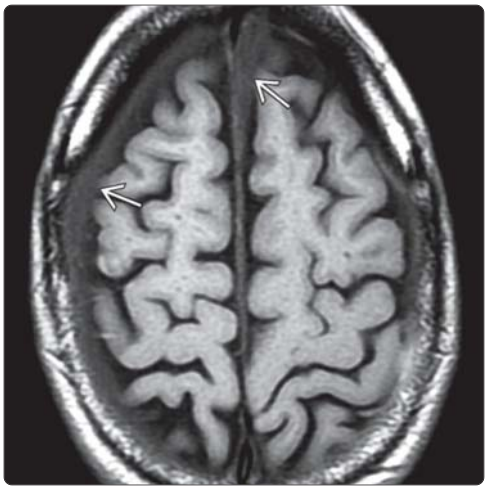

(Left) *Axial NECT scan in a 59-year-old man with seizures and no definite history of head trauma shows a right frontal extraaxial fluid collection* ⇨ *that is slightly hyperdense relative to CSF in the underlying sulci* ⇨. **(Right)** *T1WI MR in the same patient shows there are bilateral subdural collections* ⇨ *that appear slightly hyperintense compared with CSF. This is a typical MR finding in subacute SDHs.*

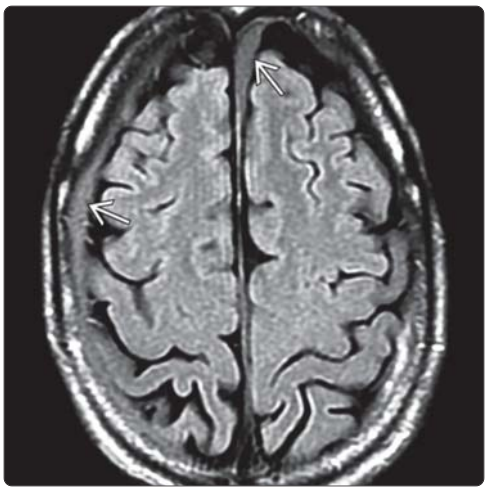

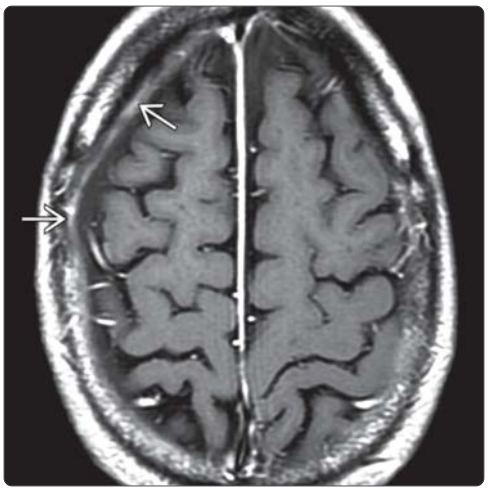

(Left) *FLAIR scan in the same patient shows that the subacute fluid collections* ⇨ *do not suppress, illustrating their difference compared with normal CSF.* **(Right)** *T1 C+ scan in the same patient shows that the outer membrane of the sSDH enhances* ⇨. *Findings are consistent with late subacute subdural hematomas.*

https://CafePezeshki.IR

KEY FACTS

TERMINOLOGY

- Chronic subdural hematoma (cSDH)
- Chronic (> 3 weeks to months) subdural blood products
  - Mixed chronic and acute hemorrhage is common

IMAGING

- Crescent-shaped extraaxial collection
  - Spreads diffusely over affected hemisphere
  - Surrounded by enhancing membranes
  - Often septated, loculated, with fluid-fluid levels
  - Recurrent, mixed-age hemorrhage is common and raises suspicion of nonaccidental trauma in children
- Imaging recommendations
  - NECT is good initial screen
  - Use wide window settings (150-200 HU)
  - MR better demonstrates cSDH

TOP DIFFERENTIAL DIAGNOSES

- Subdural hygroma
- Subdural effusion
- Subdural empyema

PATHOLOGY

- Serosanguineous fluid
- Encapsulated by granulation tissue: "Neomembranes" with fragile capillaries
- 5% multiloculated with fluid-blood density levels

CLINICAL ISSUES

- Treatment
  - Surgical drainage with resection of membranes
- Older age, brain atrophy are contributory factors in conversion of traumatic SDH into cSDH
- Recurrence risk varies with type
  - Separated SDH has highest risk
  - Large > small preoperative collections
  - Residual postoperative volume > 80 mL

(Left) *Axial graphic depicts pathology of classic chronic subdural hematoma (SDH) with the formation of thin internal ⇨, thicker external ⇨ membranes. Note the stretched bridging veins ⇨ crossing the SDH, top-to-bottom gradation of fluid from serosanguinous to more proteinaceous contents.* **(Right)** *Axial NECT depicts chronic SDH (cSDH) as crescentic hypodense extraaxial fluid collection ⇨ over the left hemisphere. Stretched cortical veins ⇨ are faintly visible as they cross the SDH.*

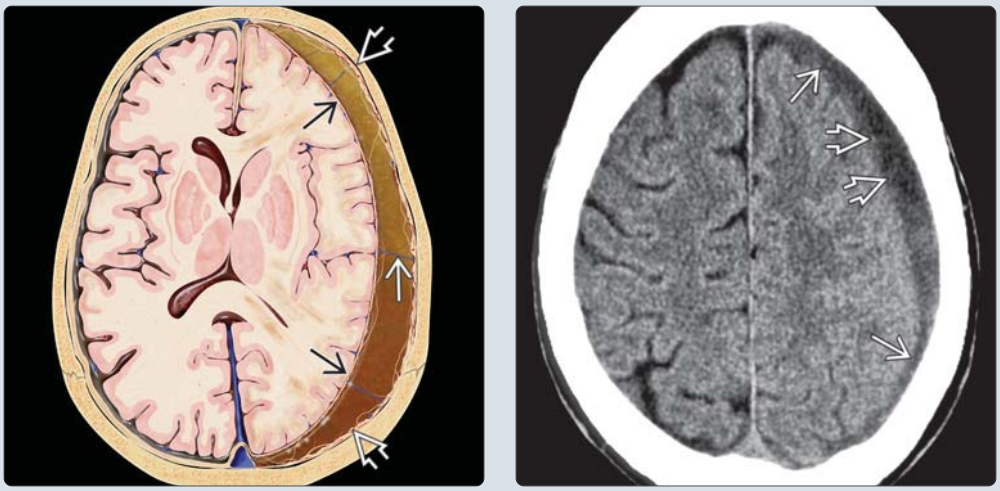

(Left) *Axial graphic depicts "mixed" subdural hematoma. Numerous loculations ⇨ that contain hemorrhages of multiple ages are present. Note the fluid-fluid levels with mixed acute, subacute blood ⇨. Rehemorrhage into preexisting subacute &/or chronic SDH is common.* **(Right)** *Axial NECT shows classic left-sided "mixed" SDH ⇨. Note the multiple loculations and fluid-fluid levels ⇨ formed by acute rehemorrhage into preexisting loculated chronic SDH.*

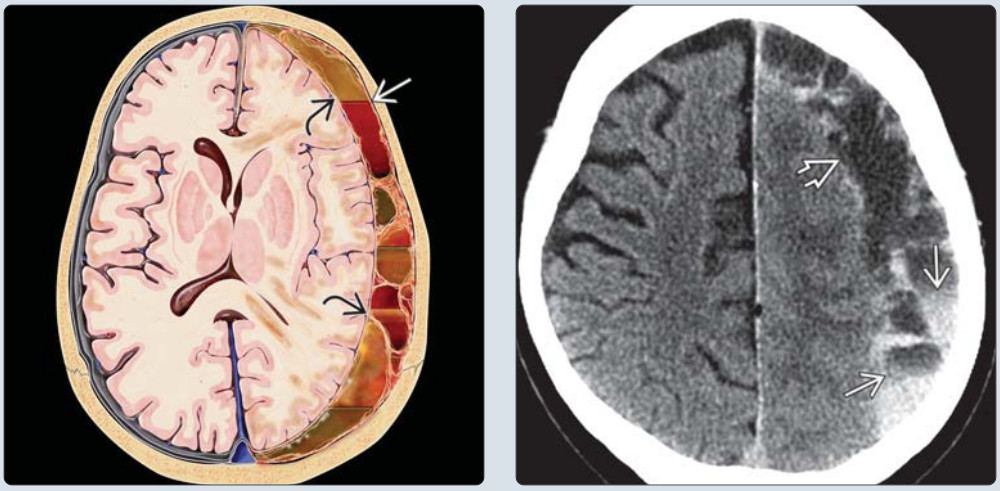

https://CafePezeshki.IR

TERMINOLOGY

Abbreviations

- Chronic subdural hematoma (cSDH)

Definitions

- Chronic (> 3 weeks to months) collection of blood products in subdural space
  - May have foci of more acute hemorrhage ("mixed" SDH)

IMAGING

General Features

- Best diagnostic clue
  - Crescent-shaped, multiseptated, extraaxial collection with enhancing surrounding membranes that spreads diffusely over affected hemisphere
- Location
  - Potential space between inner layer of dura mater and arachnoid
  - Supratentorial convexity is most common
- Morphology
  - Crescent-shaped extraaxial fluid collection
  - May cross sutures, not dural attachments
  - May extend along falx and tentorium
  - Compresses and displaces underlying brain surface, cortical vessels, and subarachnoid space fluid
  - Often septated, with internal membranes
  - Calcification in 1-2%
  - Enhancement of encapsulating membranes
  - Recurrent, mixed-age hemorrhage is common and raises suspicion of nonaccidental trauma in children
  - CT density and MR signal intensity vary with age and organization of hemorrhage

CT Findings

- NECT
  - Density varies, depending on stage of evolution
    - Typically follows cerebrospinal fluid (CSF) density
    - Progression from hyperdense (acute SDH) to isodense (subacute SDH) to hypodense (cSDH) over ~ 3 weeks
    - Progressive increase in density &/or size of cSDH from 3 weeks to 3 months; likely from rebleed of fragile neocapillaries in outer membrane
    - Eventual resorption in most cSDHs > 3 months (outer membrane stabilizes and is thus not prone to rebleed)
  - Calcification can be seen along periphery of chronic collections, typically those present for many years
- CECT
  - Inward displacement of enhancing cortical vessels
  - Enhancement of dura and membranes

MR Findings

- T1WI
  - Variable, depending on stage of evolution
    - Isointense to CSF if stable/chronic
    - Hyperintense with rebleed or ↑ protein
- T2WI
  - Variable, depending on stage of evolution
    - Isointense to CSF if stable/chronic
    - Hypointense with rebleed
  - T2-hypointense signal is seen in majority of cSDHs (73%) and is related to repeat hemorrhage
  - Membranes usually hypointense
- PD/intermediate
  - Iso- to hyperintense, depending on protein content or rebleed into collection
- FLAIR
  - Hyperintense to CSF in most cases
    - Depends on inherent T1 and T2 signal characteristics &/or presence of protein
  - Usually most sensitive sequence for detection of SDH
- T2* GRE
  - Hypointense signal from subacute-chronic blood products
  - May be hyperintense from T2 effects
- DWI
  - Variable signal
  - Hyperintense outer membranes suggest predisposition to repeated hemorrhage
- T1WI C+
  - Peripheral &/or dural enhancement
  - Delayed scans show contrast diffusion into SDH
- Signal of SDH is quite variable on MR
  - Generally evolves in pattern similar to intracerebral hemorrhage

Imaging Recommendations

- Best imaging tool
  - NECT is good initial screen
  - MR better demonstrates cSDH
    - cSDH is frequently hyperintense (due to methemoglobin) on T1, T2, PD, FLAIR
  - MR is uniquely suited to evaluate nonaccidental trauma cases, since differing ages of blood products are better characterized
    - Membranes and clot are better demonstrated on MR
      - Thickened or extensive neomembranes or clot with mass effect are indications for cSDH evacuation and membranectomy
- Protocol advice
  - Use wide window settings (150-200 HU) to identify small SDH

DIFFERENTIAL DIAGNOSIS

Subdural Hygroma

- Clear CSF (surgery/trauma tears arachnoid)
- No blood; no encapsulating membranes
- No enhancement

Subdural Effusion

- Usually occurs as complication of meningitis
- Plasma exudate, not CSF

Subdural Empyema

- Pus accumulated in subdural space
- Peripheral enhancement
- Restricted diffusion (hyperintense) centrally

Pachymeningopathies (Thickened Dura)

- Chronic meningitis (may be indistinguishable)
- Postsurgical (shunt, etc.)

https://CafePezeshki.IR

- Intracranial hypotension ("slumping" midbrain, tonsillar herniation)
- Sarcoid (nodular, "lumpy-bumpy")

Tumors

- Meningioma, lymphoma, leukemia, metastases
- Metastatic lesions may also result in SDH, particularly breast and prostate cancers and melanoma metastases
- Dural-based enhancing mass
- ± skull involvement

Chemical Shift Artifacts

- Marrow or subcutaneous fat may "shift"; can appear intracranial and mimic T1-hyperintense SDH
- Seen with ↑ field of view or ↓ bandwidth

PATHOLOGY

General Features

- Etiology
  - SDH most commonly results from traumatic stretching and tearing of bridging cortical veins as they cross subdural space to drain into dural sinus
  - Chronic SDH
    - Develops over 2-3 weeks
    - May continue to enlarge
    - May resolve spontaneously if membrane stabilizes
    - DWI may show hyperintense band that suggests fresh hemorrhage and propensity for enlargement
  - Mechanisms for SDH enlargement
    - Rehemorrhage
    - Serum protein exudation
- Associated abnormalities
  - Trauma is most common cause

Staging, Grading, & Classification

- Blood in subdural space incites tissue reaction resulting in organization and resorption of hematoma
- Chronic SDH may be classified by internal architecture
  - Homogeneous/laminar
    - Homogeneous content; may be laminar with thin layer of fresh blood along inner membrane
  - Separated
    - Hematocrit level
    - Sometimes content gradually changes ("gradated")
  - Trabecular
    - Heterogeneous with internal septa
    - Thickened or calcified capsule

Gross Pathologic & Surgical Features

- Serosanguineous fluid
- Encapsulated by granulation tissue: "Neomembranes" with fragile capillaries
- 5% multiloculated with fluid-blood density levels
- Cycle of recurrent bleeding → coagulation → fibrinolysis

Microscopic Features

- Outer membrane formed by proliferating fibroblasts and capillaries; fragile capillaries are hypothesized as source of recurrent hemorrhage in cSDH
- Inner membrane formed by dural fibroblasts or border cells; forms fibrocollagenous sheet

CLINICAL ISSUES

Presentation

- Most common signs/symptoms
  - Varies from asymptomatic to loss of consciousness
    - Lucid interval in acute SDH: Initially awake and alert patient who loses consciousness a few hours after trauma
  - Other symptoms from mass effect, diffuse brain injury, secondary ischemia

Demographics

- Age
  - Any age but elderly most at risk
  - Chronic SDH is most common type of intracranial hemorrhage in elderly
- Epidemiology
  - SDH is found in 10-20% of patients who are imaged and 30% of autopsy cases following head trauma

Natural History & Prognosis

- Extent of primary brain injury is most important factor affecting outcome
- Older age, brain atrophy are contributory factors in conversion of traumatic SDH into cSDH
- ~ 15% of cSDHs recur
  - Recurrence rate
    - Higher for skull base location SDH compared with convexity SDH
    - Higher with bilateral SDHs
    - High for separated SDH, low for trabeculated SDH
    - Low if preoperative volume < 115 mL, residual postoperative volume < 80 mL

Treatment

- Surgical drainage with resection of membranes
- Recurrence risk of cSDH varies with type
  - Separated SDH has highest risk; thickened or calcified membrane almost never rehemorrhages

DIAGNOSTIC CHECKLIST

Image Interpretation Pearls

- Enhancement may help differentiate chronic SDH from pachymeningopathies
- If no history of trauma, consider underlying vascular lesion or dural metastases

SELECTED REFERENCES

1. Kolias AG et al: Chronic subdural haematoma: modern management and emerging therapies. Nat Rev Neurol. 10(10):570-578, 2014
2. Tseng JH et al: Risk factors for chronic subdural hematoma after a minor head injury in the elderly: a population-based study. Biomed Res Int. 2014:218646, 2014

https://CafePezeshki.IR

(Left) *NECT in an elderly patient with multiple falls shows a "bubbly" fluid collection with loculations and multiple blood-fluid levels* ➡. **(Right)** *CTA in the same patient shows the "bubbly" crescentic fluid collection. Note the inward displacement of brain with compressed sulci and displaced cortical veins* ➡.

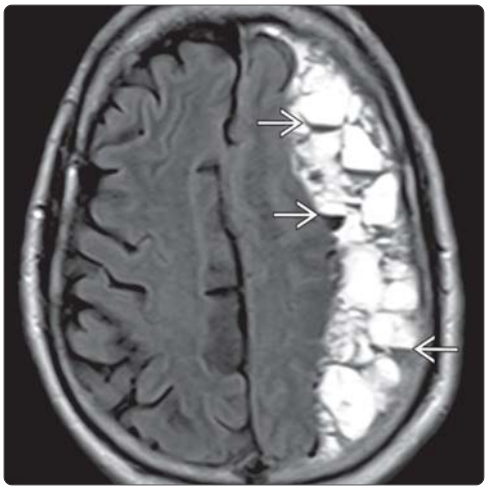

(Left) *Coronal T1WI MR in the same patient shows that the loculated pouches of fluid* ➡ *are mostly hyperintense. A few hypointense pockets of more acute hemorrhage* ⇨ *are present within the loculations.* **(Right)** *Axial FLAIR is dramatic, showing that the hyperintense loculations contain numerous hypointensities* ➡ *layering in the dependent portions of the pockets. The appearance suggests acute on chronic ("mixed") subdural hematoma.*

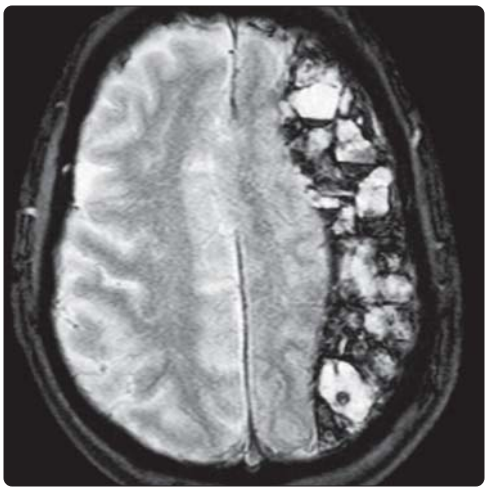

(Left) *T2* GRE MR scan shows multiple hypointense "blooming" foci, consistent with hemorrhage into a chronic loculated subdural hematoma.* **(Right)** *T1WI C+ FS MR shows some enhancement around the margins of the cSDH* ➡, *consistent with a membrane of organizing granulation tissue.*

https://CafePezeshki.IR

KEY FACTS

TERMINOLOGY

- Blood within subarachnoid spaces
  - Contained between pia and arachnoid membranes

IMAGING

- High density on CT, hyperintensity on FLAIR

TOP DIFFERENTIAL DIAGNOSES

- Nontraumatic SAH
- Meningitis: Cellular and proteinaceous debris
- Carcinomatosis meningitis
- Pseudosubarachnoid hemorrhage
- Gadolinium administration
- High-inspired oxygen

PATHOLOGY

- Associated with contusions, subdural or epidural hematoma, diffuse axonal injury

CLINICAL ISSUES

- Headache, emesis, decreased consciousness
- Trauma is most common cause of SAH
- Outcome is related in logistic regression analysis to
  - Admission Glasgow Coma Scale score
  - Amount of subarachnoid blood
- Isolated tSAH, no other injuries usually benign
- Poor prognosis if associated with other intracranial injuries
- Vasospasm develops earlier than with aneurysmal SAH
- Associated with ↓ neuropsychologic profiles, worse vocational outcomes in 1 year follow-up

DIAGNOSTIC CHECKLIST

- Isolated supratentorial sulcal blood common
- Hyperdense blood in interpeduncular cistern may be only manifestation of subtle SAH

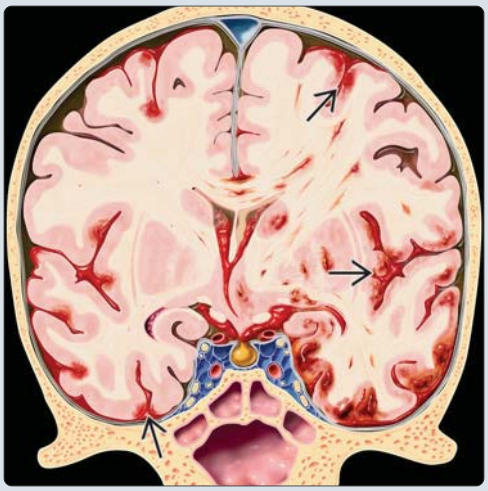

(Left) *Coronal graphic depicts findings in a severe traumatic brain injury. Closed head trauma has resulted in multiple gyral contusions and subarachnoid hemorrhage. Most tSAHs occur adjacent to parenchymal brain injuries and are found centered around the sylvian fissures, inferior frontotemporal, and convexity sulci.* **(Right)** *Axial NECT in a patient with head trauma and tSAH demonstrates focal hyperdense collections in a few left posterior frontal sulci bordering the interhemispheric fissure.*

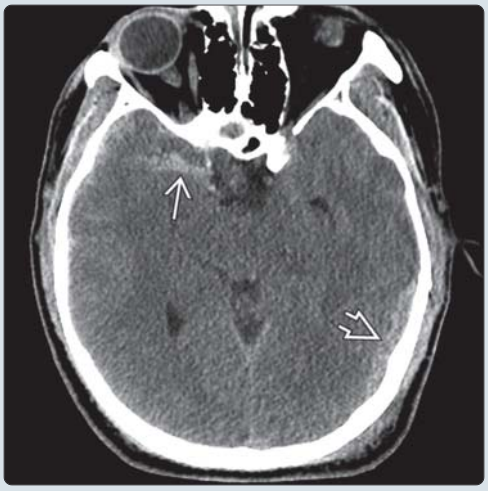

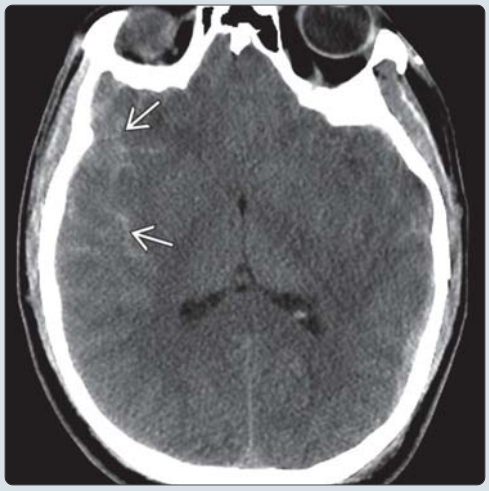

(Left) *Axial NECT scan in a 28-year-old man with closed head injury shows tSAH in the right sylvian fissure. Note the absence of blood in the adjacent suprasellar cistern, a more common site for aneurysmal SAH. A left parietal epidural hematoma is also present. Traumatic SAH often occurs in combination with other injuries.* **(Right)** *Axial NECT scan in the same patient shows the typical curvilinear configuration of tSAH in the sulci of the right temporal lobe.*

https://CafePezeshki.IR

TERMINOLOGY

Abbreviations

- Traumatic subarachnoid hemorrhage (tSAH)

Definitions

- Blood within subarachnoid spaces
  - Contained between pia and arachnoid membranes

IMAGING

General Features

- Best diagnostic clue
  - High density on NECT
  - Sulcal-cisternal FLAIR hyperintensity (in trauma patient)
- Location
  - Can be focal or diffuse
    - Focal SAH adjacent to contusion, subdural/epidural hematoma, fracture, laceration
      - Sylvian fissure, inferior frontal subarachnoid spaces most common
      - Isolated convexity sulci (adjacent to contusion)
    - Diffusely in subarachnoid space &/or basal cisterns
    - Layering on tentorium

CT Findings

- NECT
  - High density in subarachnoid space(s)/cisterns
  - Hyperdense blood in interpeduncular cistern may be only manifestation of subtle SAH
  - Identical to aneurysmal SAH except for location
    - Adjacent to contusions, subdural hematoma
    - Convexity sulci > basal cisterns

MR Findings

- T1WI
  - Hyperintense to ventricular CSF ("dirty" CSF)
- T2WI
  - Isointense to CSF (not detected)
- FLAIR
  - Hyperintense sulci/cisterns; more sensitive, less specific than CT
- T2* GRE
  - Occasionally hypointense
- DWI
  - Evaluation of tSAH-induced spasm
    - Restricted diffusion in areas of ischemia

Angiographic Findings

- Conventional DSA
  - Exclusion of aneurysm, evaluation of tSAH-induced spasm: CTA replaces DSA
  - Beaded appearance of spasm-involved vessels
    - From 2-3 days to 2 weeks after trauma

Imaging Recommendations

- Best imaging tool
  - NECT; FLAIR for subtle SAH

DIFFERENTIAL DIAGNOSIS

Nontraumatic SAH (ntSAH)

- Ruptured aneurysm
  - Causes 80-90% of all ntSAH
  - Aneurysm identified on DSA, CTA, MRA in > 90%
- Ruptured dissecting aneurysm
- Arteriovenous malformation (AVM)
  - Account for 15% of ntSAH
  - Identified on DSA, CTA, MRA
- Perimesencephalic venous hemorrhage
  - Limited to basal cisterns: Clot around basilar artery
  - Normal DSA, CTA, MRA
- Cerebral infarction with reperfusion hemorrhage
  - Presence of known infarct
- Anticoagulation therapy
  - Long-term warfarin (Coumadin) therapy; usually unrecognized mild head trauma
  - Alcohol abuse as cause of abnormal coagulation
- Blood dyscrasia
  - Usually known preexisting entity
- Eclampsia (pregnancy-induced hypertension)
  - Reported complication, eclampsia symptomatology
- Spinal vascular malformation
  - Spontaneous
  - Negative initial and repeat cerebral DSA
  - MR: Spinal SAH, cord edema
  - MRA and DSA to establish diagnosis

Meningitis: Cellular and Proteinaceous Debris

- Dirty CSF on CT
- Hyperintensity on FLAIR due to T1 shortening and failure of signal nulling

Carcinomatosis Meningitis

- Cellular CSF prevents FLAIR CSF nulling

Pseudosubarachnoid Hemorrhage

- Severe cerebral edema → diffusely hypodense brain
- Dura, circulating blood in arteries/venous sinuses look relatively hyperdense compared to adjacent brain

Gadolinium Administration

- IV contrast for routine-enhanced MR may cause FLAIR hyperintensity
  - Stroke, high-grade gliomas, or meningiomas (neoplasm surfaces contact subarachnoid spaces/ventricles)
  - CSF changes more evident close to pathology &/or hemisphere involved

High-Inspired Oxygen

- 100% O_2 during general anesthesia
  - May cause incomplete nulling of subarachnoid CSF
  - Hyperintense sulcal CSF on FLAIR
  - Ventricular CSF not affected

PATHOLOGY

General Features

- Etiology
  - Tearing of vessels in subarachnoid space
  - Traumatic dissecting aneurysm → basal cisternal SAH

https://CafePezeshki.IR

  - Most often from vertebral artery dissection
  - Suspect with basilar skull fracture
  - Mimics aneurysmal SAH
- Genetics
  - *APOE* ε4 allele predisposes to poor outcome after traumatic brain injury (TBI), SAH, and hemorrhagic stroke
- Associated abnormalities
  - Contusions, subdural or epidural hematoma, diffuse axonal injury

Staging, Grading, & Classification

- Grade 1: Thin tSAH ≤ 5 mm
- Grade 2: Thick tSAH > 5 mm
- Grade 3: Thin tSAH with mass lesion(s)
- Grade 4: Thick tSAH with mass lesion(s)

Gross Pathologic & Surgical Features

- Acute blood in sulci/cisterns
- Autopsy studies show
  - Bleeding from cortical arteries/veins
  - Leakage from surface contusions

Microscopic Features

- Evolutionary hemoglobin changes are different than described for intracerebral hematoma
  - Much slower progression, delayed degradation
  - Most likely secondary to high ambient oxygen tension of subarachnoid CSF

CLINICAL ISSUES

Presentation

- Most common signs/symptoms
  - Headache, emesis, decreased consciousness
- Other signs/symptoms
  - May ↑ risk of corrected Q-T prolongation on ECG, ventricular tachycardia, sudden death
- Clinical profile
  - Trauma, not ruptured aneurysm, is most common cause of SAH

Demographics

- Age
  - Median = 43 years (standard deviation = 21.1 years)
- Gender
  - M:F = 2:1 for sustaining traumatic brain injury
- Epidemiology
  - tSAH found in 33% with moderate TBI, 60% with severe TBI
  - Found in almost all cases at autopsy
  - tSAH-associated vasospasm in 2-10% of cases
- Risk factors for TBI
  - Young age, low income, chronic alcohol/substance abuse
  - Prior episodes of TBI

Natural History & Prognosis

- Outcome related in logistic regression analysis to
  - Admission Glasgow Coma Scale score
  - Amount of subarachnoid blood
- Isolated tSAH in setting of mild TBI
  - Course typically benign
  - If no other significant trauma, can be managed without follow-up imaging/ICU admission
- Poor prognosis if associated with other intracranial injuries
  - Amount of tSAH on initial CT correlates with delayed ischemia, poor outcome
  - 46-78% of moderate to severe TBI associated with tSAH result in
    - Increased morbidity, leading to severe disability and persistent vegetative state
    - Increased mortality as high as 2x
- Acute hydrocephalus
  - Rare; usually obstruction of aqueduct or 4th ventricular outlet by clotted SAH
  - Obstructive, noncommunicating hydrocephalus
    - Asymmetric ventricular dilatation
- Delayed hydrocephalus
  - Defective CSF resorption
  - Obstructive communicating hydrocephalus
    - Symmetric ventricular dilatation
  - Observed in 11.96% of TBI patients after 3-month follow-up interval
  - No correlation between location of tSAH and development of hydrocephalus
- Vasospasm
  - Develops earlier with tSAH than with aneurysmal SAH
  - Peaks 7-10 days after injury
  - Threat remains up to 2 weeks
  - Uncommon cause of post-traumatic infarct
- Associated with ↓ neuropsychologic profiles, worse vocational outcomes in 1-year follow-up

Treatment

- Supportive therapy is primary treatment
  - Intubation, supplemental oxygen, IV fluids, therapy of altered vital signs
  - Sedatives; medications for pain, nausea, and vomiting
  - Anticonvulsants for seizures
- Nimodipine (calcium channel blocker) may prevent vasospasm and its complications

DIAGNOSTIC CHECKLIST

Image Interpretation Pearls

- tSAH is often accompanied by additional injuries
- Isolated supratentorial sulcal blood is common
- Hyperdense blood in interpeduncular cistern may be only manifestation of subtle SAH

SELECTED REFERENCES

1. Rubino S et al: Outpatient follow-up of nonoperative cerebral contusion and traumatic subarachnoid hemorrhage: does repeat head CT alter clinical decision-making? J Neurosurg. 121(4):944-9, 2014
2. Servadei F et al: Traumatic Subarachnoid Hemorrhage. World Neurosurg. ePub, 2014
3. Quigley MR et al: The clinical significance of isolated traumatic subarachnoid hemorrhage. J Trauma Acute Care Surg. 74(2):581-4, 2013
4. Yuh EL et al: Magnetic resonance imaging improves 3-month outcome prediction in mild traumatic brain injury. Ann Neurol. 73(2):224-35, 2013

https://CafePezeshki.IR

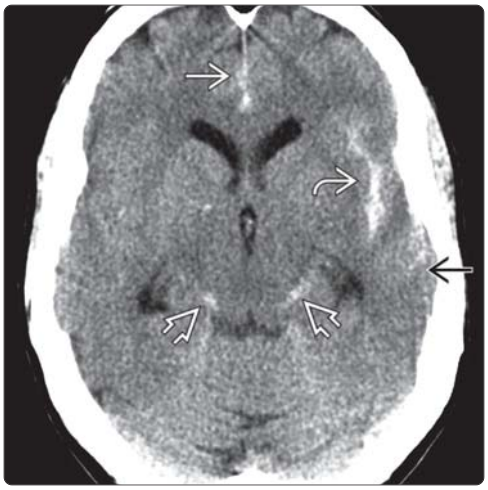

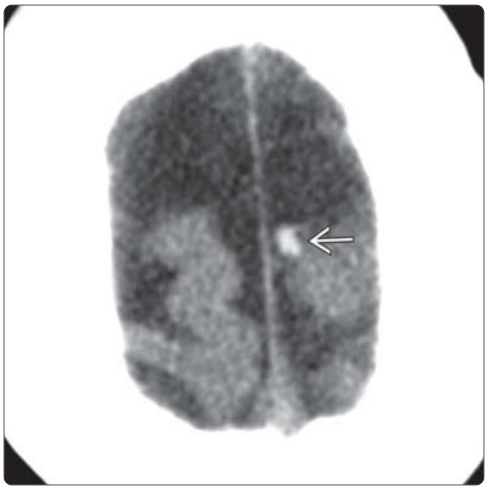

(Left) *Axial NECT shows hyperdense traumatic subarachnoid hemorrhage within the sulci, left sylvian fissure, ambient cisterns, and interhemispheric fissure.* **(Right)** *Axial NECT reveals a small collection of hyperdensity along a left frontal medial sulcus, representing traumatic subarachnoid hemorrhage.*

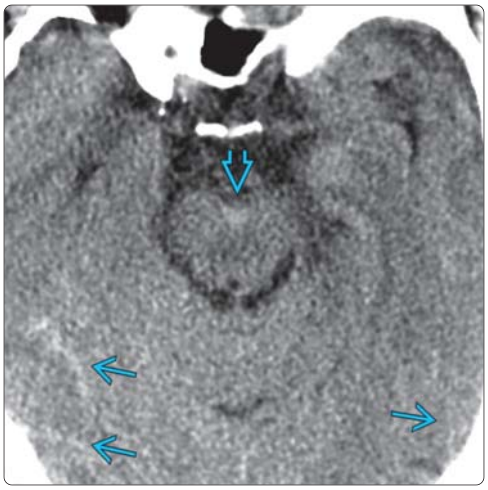

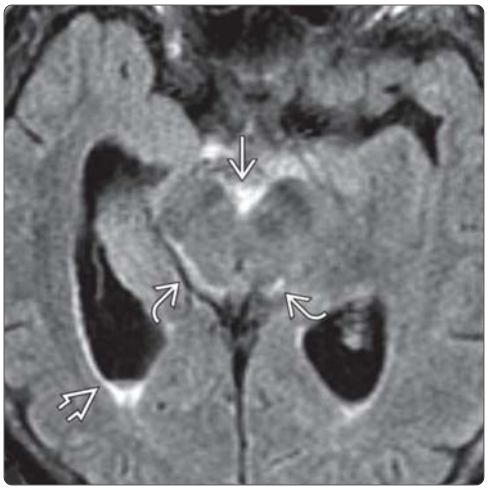

(Left) *Axial NECT demonstrates collections of hyperdensity within a few sulci and the interpeduncular cistern from tSAH.* **(Right)** *Axial FLAIR MR shows abnormal CSF hyperintensity within the interpeduncular cistern and ambient/quadrigeminal cisterns. It also reveals a small amount of layering-dependent hemorrhage within the right occipital horn.*

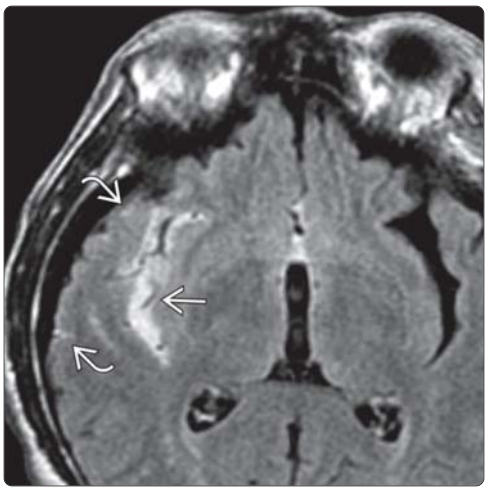

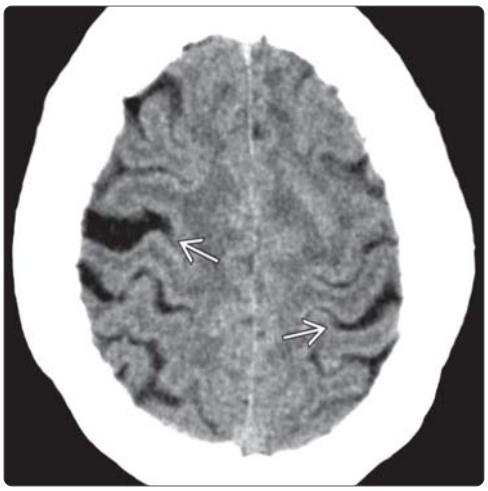

(Left) *Axial FLAIR MR demonstrates tSAH as an abnormal CSF hyperintensity within the right sylvian fissure, as well as within a few right sulci.* **(Right)** *Axial NECT shows widening of bilateral sulci, right more than left, by a CSF-isodense process due to subacute to chronic SAH.*

https://CafePezeshki.IR

Cerebral Contusion

KEY FACTS

TERMINOLOGY

- Brain surface injuries involving gray matter and contiguous subcortical white matter

IMAGING

- Best diagnostic clue: Patchy hemorrhages within edematous background
- Characteristic locations: Adjacent to irregular bony protuberance or dural fold
- Anterior inferior frontal lobes and anterior inferior temporal lobes most common
- FLAIR: Best for hyperintense cortical edema and subarachnoid hemorrhage
- GRE: Hypointense hemorrhagic foci "bloom"
- Best imaging tool
  - CT to detect acute hemorrhagic contusions, other intracranial lesions, and herniations
  - MR to detect presence and delineate extent of lesions
- Coup: Direct injury to brain beneath impact site
- Contrecoup: Injury opposite impact site; usually more severe than coup

TOP DIFFERENTIAL DIAGNOSES

- Infarct
- Venous sinus thrombosis
- Cerebritis
- Low-grade neoplasm
- Transient postictal changes

PATHOLOGY

- Inflammation → worsening/enlarging lesions

CLINICAL ISSUES

- Initial symptom: Confusion → obtundation
- Central goal: Prevent and treat secondary injury
- Mass effect and herniation may require evacuation

(Left) *Coronal graphic illustrates the pathology of closed head injury. Note the hemorrhagic foci involving gray matter of several contused gyri ⇨, axonal and deep gray injuries, and traumatic subarachnoid hemorrhage ⇨ in the basal cisterns and sylvian fissure.* **(Right)** *Graphics depict the most common sites of cerebral contusions in red. Less common sites are shown in green. The most common locations of all are the anteroinferior frontal and temporal lobes.*

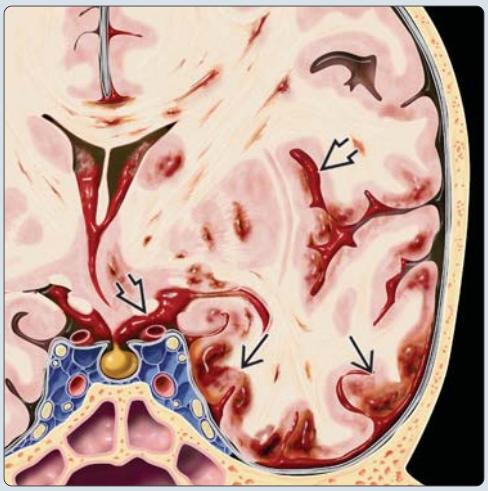

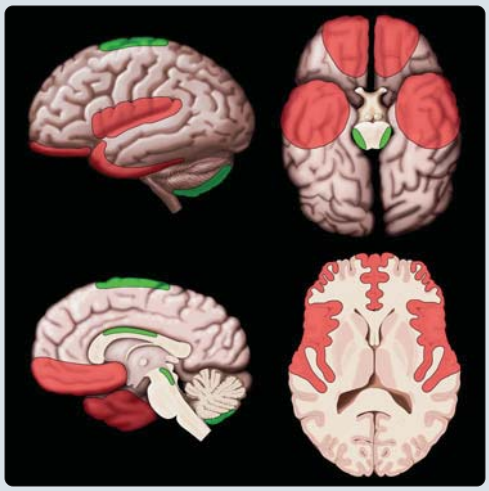

(Left) *Gross pathology of the brain from a patient who died from a severe closed head injury shows bifrontal, temporal hemorrhagic contusions ⇨, as well as traumatic subarachnoid hemorrhage in the suprasellar cistern ⇨. (Courtesy R. Hewlett, MD.)* **(Right)** *NECT scan shows extensive frontotemporal contusions ⇨ and traumatic subarachnoid hemorrhage ⇨ in a patient with severe brain injury.*

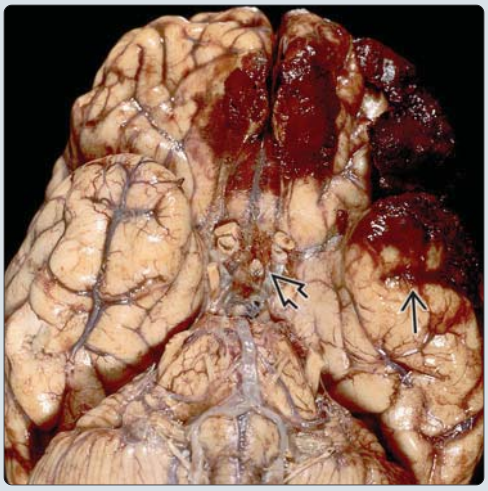

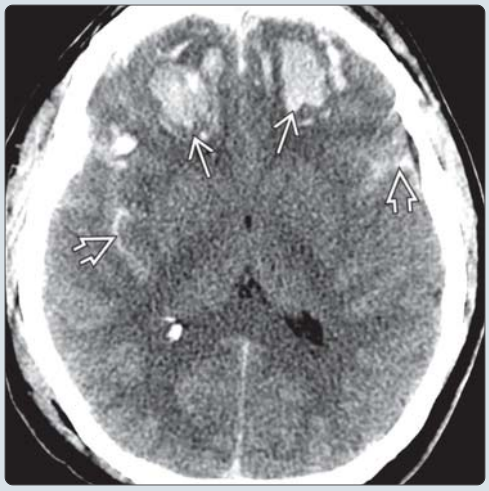

https://CafePezeshki.IR

TERMINOLOGY

Definitions

- Brain surface injuries involving gray matter and contiguous subcortical white matter

IMAGING

General Features

- Best diagnostic clue
  - Patchy hemorrhages within edematous background
- Location
  - Characteristic locations: Adjacent to irregular bony protuberance or dural fold
    - Anterior inferior frontal lobes and anterior inferior temporal lobes most common
    - 25% parasagittal ("gliding" contusions)
  - Less common locations
    - Parietal/occipital lobes, posterior fossa
  - Coup: Direct injury to brain beneath impact site
  - Contrecoup: Injury opposite impact site; usually more severe than coup
- Morphology
  - Early: Patchy, ill-defined, superficial foci of punctate or linear hemorrhage along gyral crests
  - 24-48 hours: Existing lesions enlarge and become more hemorrhagic; new lesions may appear
  - Chronic: Encephalomalacia with volume loss
  - Multiple, bilateral lesions in 90% of cases

CT Findings

- NECT
  - Early: Patchy, ill-defined, low-density edema with small foci of hyperdense hemorrhage
  - 24-48 hours
    - Edema, hemorrhage, and mass effect often increase
    - New foci of edema and hemorrhage may appear
    - Petechial hemorrhage may coalesce
  - Chronic
    - Become isodense, then hypodense
    - Encephalomalacia with volume loss
  - Secondary lesions
    - Herniations/mass effect with secondary infarction
    - Hydrocephalus due to hemorrhage
- Perfusion CT
  - More sensitive than NECT in detection of cerebral contusions (87.5% vs. 39.6%, respectively)

MR Findings

- T1WI
  - Acute: Inhomogeneous isointensity and mass effect
  - Chronic: Focal or diffuse atrophy
- FLAIR
  - Acute: Best for hyperintense cortical edema and subarachnoid hemorrhage (SAH)
  - Chronic
    - Hyperintense demyelination and microglial scarring
    - Hypointense hemosiderin staining
    - Hypointense cavitation (cystic encephalomalacia)
- T2* GRE
  - Acute: Hypointense hemorrhagic foci "bloom"
  - Chronic: Hypointense hemosiderin deposits
- DWI
  - Hyperintense in areas of cell death
  - Decreased apparent diffusion coefficient (ADC) correlates with poor outcome
  - Diffusion tensor imaging sometimes shows white matter damage when CT, routine MR appear normal
- MRS
  - ↓ NAA, ↑ choline

Nuclear Medicine Findings

- SPECT Tc-99m HMPAO imaging
  - Depicts focal changes in 53% with mild injury
  - Negative in 1st month predicts good outcome
    - Positive can predict poor clinical outcome

Imaging Recommendations

- Best imaging tool
  - CT to detect acute hemorrhagic contusions, other intracranial lesions, and herniations
  - MR to detect presence and delineate extent of lesions
- Protocol advice
  - FLAIR for edema and SAH; GRE for hemorrhagic foci

DIFFERENTIAL DIAGNOSIS

Infarct

- No trauma history
- Characteristic acute onset focal neurologic deficit
- Vascular distribution: Spares frontal and temporal poles

Venous Sinus Thrombosis

- Edema and hemorrhage adjacent to occluded sinus

Cerebritis

- No trauma history
- Herpes typically involves medial temporal lobe

Low-Grade Neoplasm

- No trauma history
- Solitary nonhemorrhagic lesion
- No predilection for anterior frontal or temporal lobes

Transient Postictal Changes

- No trauma history
- Preceding or ongoing seizure activity
- May be hyperintense on DWI; can enhance acutely

PATHOLOGY

General Features

- Etiology
  - Stationary head struck by object
    - Direct injury beneath impact site
    - Contusion is rare without fracture
  - Moving head: Motor vehicle crash, falls
    - Differential accel-/deceleration and rotational forces on portions of brain with different densities
    - Gliding injury: Cortex anchored to dura by arachnoid granulations; subcortical tissue glides more than cortex
  - Traffic injuries are main cause in young adults (20–40 years)

https://CafePezeshki.IR

- Falls are main cause in infants (0–4 years) and elderly (≥ 70 years)
- Associated abnormalities
  - Soft tissue injuries in 70% of patients
  - Subdural hematoma (SDH), traumatic SAH, intraventricular hemorrhage
  - Skull fracture at coup site

Gross Pathologic & Surgical Features

- Contusions
  - Edema along gyral crests
  - Petechial hemorrhages (most evident in 24-48 hours)
  - Small hemorrhages may coalesce into hematoma
  - Delayed hematomas may develop 24-48 hours later
- Lacerations
  - Intracerebral hematoma with "burst" lobe
  - SDH communicates with hematoma via lacerated brain, torn pia-arachnoid
- Liquefaction and encephalomalacia in chronic phase

Microscopic Features

- Capillary disruption → blood extravasation: RBCs cause visible hemorrhage, plasma leads to edema
- Perivascular hemorrhage, ↑ pinocytic activity of endothelial cells, and cytotoxic edema of astroglial cells
- Higher levels of serum protein S100B and IL-6 correlate with ultrastructural changes of endothelial cells

Cellular Features

- Chemokine, nitric oxide activation occurs early
  - Inflammatory response → neutrophil oxidative burst → proteolytic and neurotoxic enzyme release
  - Neuroinflammation mediated by cyto-/chemokines, complement
    - Contributes to secondary ischemic damage, contusion enlargement
  - CNS cells synthesize distinct chemokines
    - Chemokine CCL2 is highly expressed early in pericontusional area
    - Chemokine CXCL8 (a.k.a. IL-8) is highly expressed as late inflammatory mediator
  - Inflammatory processes contribute to pericontusional cytotoxic injury via astrocytic activation with capillary vessel compression and leukocyte accumulation → microvascular occlusion
- Blood-brain barrier failure aided by proinflammatory factor activation and matrix metalloproteinases
- Injured cortex upregulates peroxisome proliferator-activated receptor α (PPAR-α) binding activity and protein expression
  - Peaks 24–72 hours post-injury; PPAR-α agonists protect against excessive oxidative stress and inflammation in traumatic brain injury (TBI) and stroke

CLINICAL ISSUES

Presentation

- Most common signs/symptoms
  - Varies with severity; from mild confusion to obtundation
    - ± Cerebral dysfunction, seizures

Demographics

- Age
  - Children:adults = 2:1; highest risk between 15-24 years
- Gender
  - M:F = 3:1
- Epidemiology
  - Annual cerebral contusion incidence is 200 per 100,000 brain trauma-related hospitalizations
  - Contusion is 2nd most common primary traumatic neuronal injury (44%); diffuse axonal injury (DAI) is most common
  - 1.4 million suffer TBI each year in USA; 50,000 die and 80,000 experience long-term disability
  - TBI causes 6.5% of deaths in USA (32 per 100,000)

Natural History & Prognosis

- Varies with extent of primary injury
- Outcome is critically dependent on extent of brain damage that evolves after initial insult
  - Secondary lesions: Hypoxia, hypotension, ischemia, brain edema, and ↑ intracranial pressure
- Highest mortality rate: Elderly population
  - Linear increase of 40-50% in odds of poor outcome for every 10 years of age
- 90% of patients survive injury
  - ~ 25% have significant residual complaints
- Temporal and especially brainstem contusions are independent risk factors for poor outcome
- In severe TBI, 63% have good clinical outcome, 32% have excellent clinical outcome

Treatment

- Central goal: Prevent or rapidly treat secondary injury
- Mitigate secondary effects of ↑ intracranial pressure, perfusion disturbances

DIAGNOSTIC CHECKLIST

Consider

- Repeat exam recommended if initial exam negative but symptoms persist for 24-48 hours

Image Interpretation Pearls

- Inferior anterior frontal lobes most often injured
- Mixed-density contusions can be mistaken for common artifacts caused by orbital roof

SELECTED REFERENCES

1. Aquino C et al: Magnetic resonance imaging of traumatic brain injury: a pictorial review. Emerg Radiol. ePub, 2014
2. DeQuesada IM 2nd et al: Neuroimaging of acute traumatic brain injury: emphasis on magnetic resonance imaging and prognostic factors. Semin Roentgenol. 49(1):64-75, 2014
3. Iaccarino C et al: Patients with brain contusions: predictors of outcome and relationship between radiological and clinical evolution. J Neurosurg. 120(4):908-18, 2014
4. Prieto-Valderrey F et al: Utility of diffusion-weighted magnetic resonance imaging in severe focal traumatic brain injuries. Med Intensiva. 37(6):375-382, 2013

https://CafePezeshki.IR

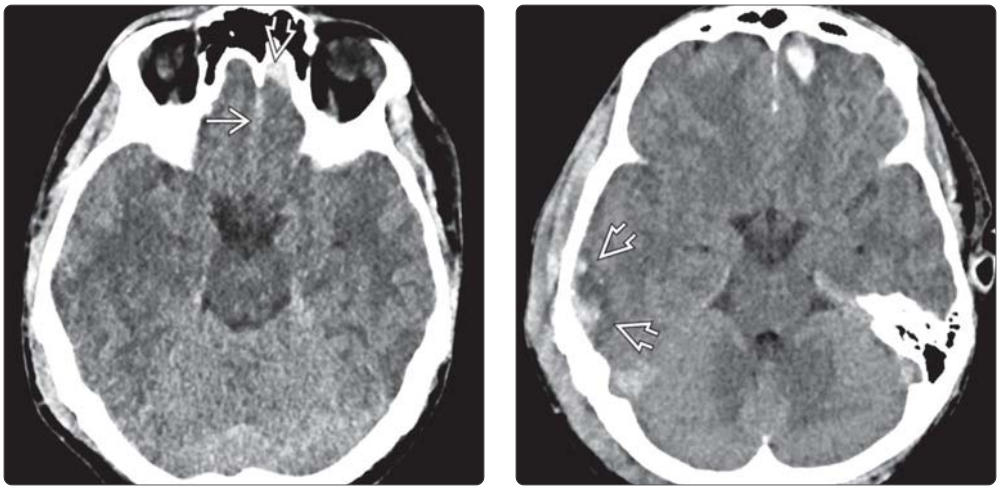

(Left) *Initial axial NECT scan in a 24-year-old man with severe closed head injury and GCS of 8 on admission shows only a focal contusion in the left inferior frontal lobe* ⇨ *and a small amount of subarachnoid hemorrhage (SAH) in the inferior interhemispheric fissure* ⇨. **(Right)** *Repeat NECT scan 6 hours later shows interval appearance of cortical contusions along the surface of the right temporal lobe* ⇨. *Cortical contusions commonly "bloom" (i.e., become more conspicuous) on follow-up imaging studies.*

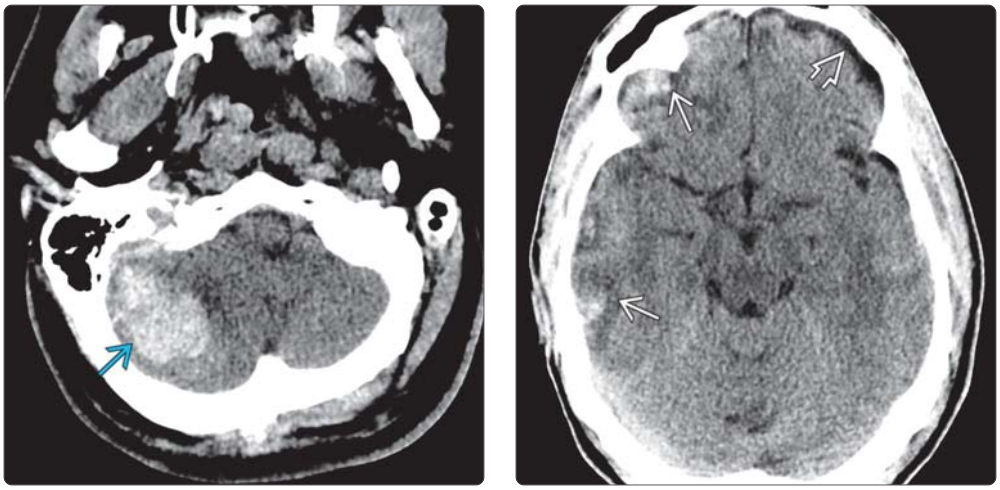

(Left) *Axial NECT reveals a coup hemorrhagic contusion of the right cerebellar hemisphere. The contusion has coalesced into a focal hematoma* ⇨. **(Right)** *NECT scan 24 hours after head trauma shows frontotemporal contusions* ⇨ *and left inferior frontal subdural hygroma* ⇨.

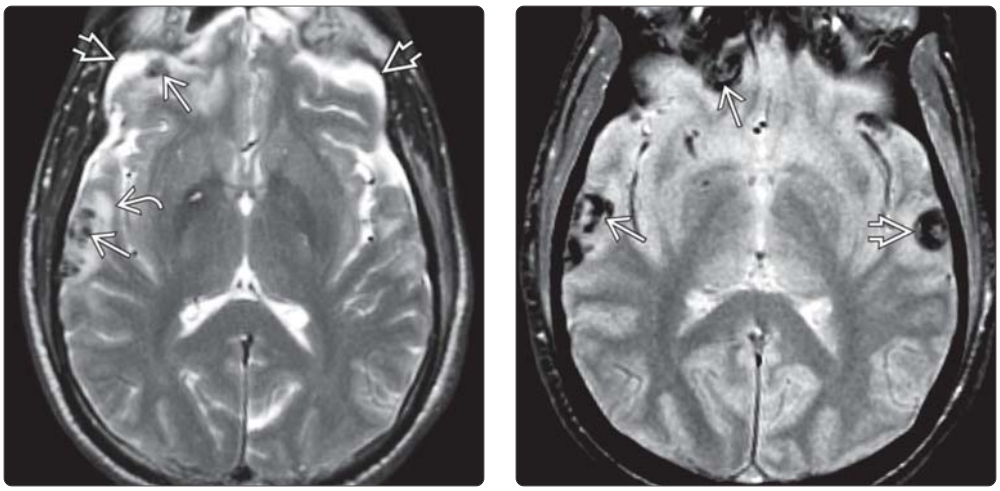

(Left) *T2WI in the same patient obtained immediately after the CT scan shows contusions* ⇨ *with perilesional edema* ⇨ *and small bilateral subdural hygromas* ⇨. **(Right)** *T2* GRE in the same patient shows "blooming" of right frontotemporal contusions* ⇨. *A left temporal contusion* ⇨ *is apparent that was not evident on the T2WI.*

https://CafePezeshki.IR

KEY FACTS

TERMINOLOGY

- Traumatic axonal stretch injury

IMAGING

- General features
  - Can be hemorrhagic or nonhemorrhagic
    - Microbleeds important imaging marker for diffuse axonal injury (DAI)
    - Intraventricular hemorrhage correlates with DAI
  - Location
    - Subcortical/deep WM, corpus callosum
    - Deeper brain involvement = ↑ severity, poor prognosis
- NECT often normal (50-80%)
- MR
  - FLAIR: Hyperintense foci
  - T2*GRE: Hypointense "blooming" foci (hemorrhage)
  - SWI: Depicts significantly more DAI foci than GRE
  - DWI: May show restricted diffusion

PATHOLOGY

- Closed head injury (CHI)
  - Sudden deceleration, abrupt changes in angular momentum
- Cortex, WM have different densities, rotate at different speeds in CHI
  - Axons stretched (rarely disconnected or "sheared")
  - Occurs at interfaces between tissues of differing density
- 80% of lesions are microscopic, nonhemorrhagic

DIAGNOSTIC CHECKLIST

- Consider DAI if
  - Low GCS, minimal findings on NECT
- Remember
  - The deeper the abnormalities, the more severe the brain injury
  - Remember: Visible lesions are "tip of iceberg"

(Left) *Sagittal graphic illustrates multiple diffuse axonal injury hemorrhagic foci within the corpus callosum and brainstem.* **(Right)** *Graphics depict the most common sites of axonal injury in red. Frequent but relatively less common locations are shown in green. Injury to the midbrain/upper pons (purple) is uncommon but often lethal. In general, the deeper the abnormalities, the more severe the injury.*

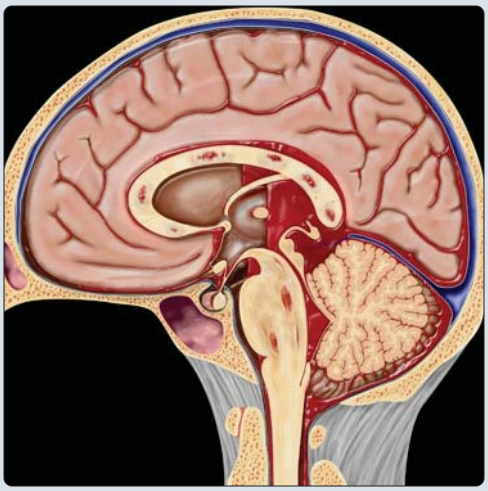

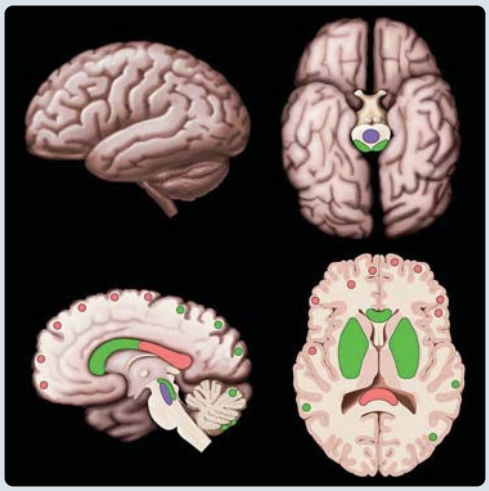

(Left) *Axial NECT scan in a 25-year-old man involved in a high-impact MVA shows multiple hemorrhagic foci in the subcortical WM ⇨, external ⇨ and internal ⇨ capsules, basal ganglia ⇨, and thalami ⇨. Blood is also present in the 3rd and lateral ventricles.* **(Right)** *More cephalad NECT scan in the same patient shows punctate peripheral hemorrhages in the subcortical WM ⇨. Traumatic subarachnoid hemorrhage is also present.*

https://CafePezeshki.IR

TERMINOLOGY

Abbreviations

- Diffuse axonal injury (DAI)

Definitions

- Traumatic axonal stretch injury

IMAGING

General Features

- Best diagnostic clue
  - Microbleeds (important imaging marker for DAI)
  - Punctate lesions at corticomedullary junction, corpus callosum, deep gray matter, brainstem
- Location
  - Gray-white matter (GM-WM) interface (67%), especially frontotemporal lobes
  - Corpus callosum (20%); 3/4 involve splenium, posterior body
  - Brainstem, especially dorsolateral midbrain and upper pons (poor prognosis)
  - Less common
    - Deep GM, internal/external capsule, tegmentum, fornix, corona radiata, cerebellar peduncles
- Size
  - Punctate to 15 mm
- Morphology
  - Punctate, round, ovoid foci; often hemorrhagic
  - Nearly always multiple bilateral lesions

CT Findings

- NECT
  - Often normal (50-80%)
    - > 30% with negative CT have positive MR
  - Nonhemorrhagic: Small, hypodense foci
  - Hemorrhagic: Small, hyperdense foci (20-50%)
    - 10-20% evolve to focal mass lesion
    - Repeat scans often reveal "new" lesions

MR Findings

- T1WI
  - Usually normal
- T2WI
  - Nonhemorrhagic: Hyperintense foci
  - Hemorrhagic: Hypointense foci
- FLAIR
  - Nonhemorrhagic DAI: Hyperintense foci
  - Hemorrhagic DAI: Hypointense foci
- T2* GRE
  - Most sensitive "routine" sequence
    - Microbleeds may be visible only on GRE
    - Hypointense foci (susceptibility from blood products)
  - SWI
    - Depicts significantly more DAI foci than GRE
- DWI
  - May show foci of restricted diffusion
  - Diffusion tensor imaging (DTI)
    - Fractional anisotropy (FA) maps document integrity and direction of white matter tracts
    - Damage to WM may be visible on FA maps
    - DTI "tractograms" allow delineation of WM tract disruption pattern
      - Detect abnormalities when routine imaging, including GRE, is normal
- MRS
  - Normal-appearing brain
    - ↓ N-acetyl aspartate in WM 2° to neuronal injury
    - ↑ choline in GM suggestive of inflammation
  - Abnormal NAA/Cr and Cho/Cr accurately predicts outcomes in
    - Normal-appearing brain (85%)
    - Visibly injured brain (67%)

Nuclear Medicine Findings

- PET
  - Hypometabolism in cingulate gyrus, lingual gyrus, and cuneus
    - Dysfunction of above regions plays key role in neuropsychologic deficits
- SPECT
  - May show focal perfusion abnormalities

Imaging Recommendations

- Best imaging tool
  - MR for detection
- Protocol advice
  - Nonhemorrhagic: FLAIR + DWI ± DTI tractography
  - Hemorrhagic: SWI best (use T2* GRE if not available)

DIFFERENTIAL DIAGNOSIS

Multifocal Nonhemorrhagic Lesions

- Aging: No trauma history; leukoaraiosis and lacunes
- Demyelinating disease: Ovoid, may enhance

Multifocal Hemorrhagic Lesions

- Cerebral amyloid angiopathy: Elderly, normotensive
- Chronic hypertension: Older, hypertensive
- Cavernous malformations: Mixed-age hemorrhages
- Hemorrhagic tumors: Enhancing masses

PATHOLOGY

General Features

- Etiology
  - Overlying cortex moves at different speed in relation to underlying deep brain structures
    - Results in axonal stretching, particularly where brain tissues of different density intersect
  - Trauma-induced forces of inertia
    - Differential acceleration/deceleration and rotational/angular forces
    - Head impact not required
  - Axons stretched, rarely disconnected or "sheared" (only in most severe injury)
  - Effect on nondisruptively injured axons
    - Traumatic depolarization, ion fluxes, spreading depression, and excitatory amino acid release
    - Metabolic alterations with accelerated glycolysis and lactate accumulation
    - Cellular swelling, cytotoxic edema, and apoptosis
  - Corpus callosum injury

https://CafePezeshki.IR

  - Believed due to rotational shear/strain forces
  - Posterior falx prevents tissue displacement, allowing greater tensile stresses locally

Staging, Grading, & Classification

- Adams and Gennarelli staging
  - Stage 1: Frontal and temporal lobe GM/WM interface lesions (mild traumatic brain injury [TBI])
  - Stage 2: Lesions in lobar WM and corpus callosum (moderate TBI)
  - Stage 3: Lesions of dorsolateral midbrain and upper pons (severe TBI)
- Increasing severity of traumatic force correlates with deeper brain involvement

Gross Pathologic & Surgical Features

- Multiple, small, round, ovoid, linear lesions

Microscopic Features

- 80% of lesions are microscopic, nonhemorrhagic
  - Visible lesions are "tip of iceberg"
- Impaired axoplasmic transport, axonal swelling
- Axonal swelling 2° to "axotomy" and "retraction" balls
- Microglial clusters
- Macro-, microbleeds (torn penetrating vessels = diffuse vascular injury)
- Wallerian degeneration

CLINICAL ISSUES

Presentation

- Most common signs/symptoms
  - Transient LOC, retrograde amnesia in mild TBI
  - LOC at moment of impact: Moderate to severe TBI
  - Immediate coma typical
    - Persistent vegetative state in severe cases
    - Slow recovery in many cases
  - Greater impairment than with cerebral contusions, intracerebral hematoma, extraaxial hematomas
- Clinical profile
  - Suggestive in patient with clinical symptoms disproportionate to imaging findings
  - Most common primary traumatic neuronal injury (48%)
    - Usually in setting of high-velocity MVA
    - Admission GCS may not correlate with outcome

Demographics

- Age
  - Any, but most common in 15-24 year olds
  - May occur in utero if pregnant woman subjected to sufficient force
- Gender
  - Men 2x as likely to sustain traumatic brain injury; peaks at 20–24 years
- Epidemiology
  - 2,000,000 traumatic brain injuries annually in USA
  - Leading cause of death/disability in children and young adults
  - ~ 50% of all primary intraaxial traumatic brain lesions in moderate and severe TBI
  - 80-100% autopsy prevalence in fatal injuries
  - Survivors incur annual cost of > $40,000,000,000 (~ 0.5% of GNP)

Natural History & Prognosis

- Spectrum of severity: Mild to severe
  - Mild TBI most common: Clinical abnormalities may persist for months or longer
    - Headache, memory and mild cognitive impairment, personality change (post-concussion syndrome)
- Severe DAI rarely causes death
  - > 90% remain in persistent vegetative state (brainstem spared)
  - Prognosis worsens as number of lesions increases
- 10% of patients who return to normal function do so within 1 year
  - May experience prolonged symptoms
- Brainstem damage (pontomedullary rent) associated with immediate or early death
- Neurocognitive deficits thought to persist in 100% of severe, 67% of moderate, and 10% of mild TBI
  - Figures may significantly underestimate sequelae of mild and moderate TBI

Treatment

- No real treatment; supportive therapy
- Treatment of comorbidities: Herniation, hemorrhage(s), hydrocephalus, seizures

DIAGNOSTIC CHECKLIST

Consider

- Consider DAI if symptoms are disproportionate to imaging findings

Image Interpretation Pearls

- Best detected by FLAIR (nonhemorrhagic) or SWI (hemorrhagic)

SELECTED REFERENCES

1. Mechtler LL et al: Advanced neuroimaging of mild traumatic brain injury. Neurol Clin. 32(1):31-58, 2014
2. Liu J et al: Diffuse axonal injury after traumatic cerebral microbleeds: an evaluation of imaging techniques. Neural Regen Res. 9(12):1222-30, 2014
3. Mata-Mbemba D et al: Intraventricular Hemorrhage on Initial Computed Tomography as Marker of Diffuse Axonal Injury after Traumatic Brain Injury. J Neurotrauma. ePub, 2014
4. Moen KG et al: Traumatic axonal injury: the prognostic value of lesion load in corpus callosum, brain stem, and thalamus in different magnetic resonance imaging sequences. J Neurotrauma. 31(17):1486-96, 2014
5. Perez AM et al: Longitudinal white matter changes after traumatic axonal injury. J Neurotrauma. 31(17):1478-85, 2014
6. Xiong KL et al: Diffusion tensor imaging and magnetic resonance spectroscopy in traumatic brain injury: a review of recent literature. Brain Imaging Behav. ePub, 2014
7. Clayton EH et al: Transmission, attenuation and reflection of shear waves in the human brain. J R Soc Interface. 9(76):2899-910, 2012
8. Matsukawa H et al: Intraventricular hemorrhage on computed tomography and corpus callosum injury on magnetic resonance imaging in patients with isolated blunt traumatic brain injury. J Neurosurg. 117(2):334-9, 2012

https://CafePezeshki.IR

(Left) *Axial NECT scan in a 26-year-old woman involved in a high-impact MVA shows only a small linear hemorrhage in the corpus callosum ➡. GCS was 6 at the accident scene.* **(Right)** *Because of the discrepancy between the lack of findings on NECT and the low GCS, MR was obtained. FLAIR scan shows hyperintensity in the corpus callosum ➡ and subcortical WM ➡.*

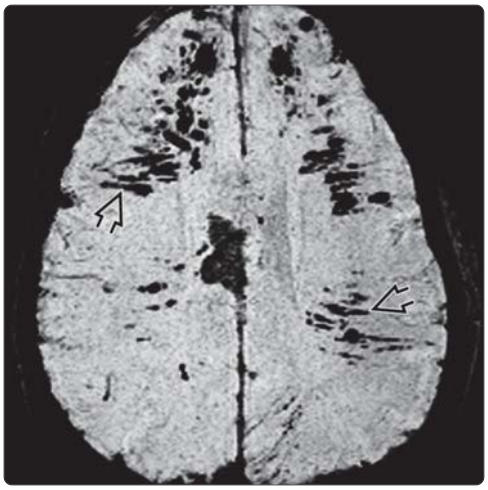

(Left) *T2* GRE scan in the same patient shows multiple punctate and linear "blooming" hypointense foci in the subcortical and deep white matter ➡ and corpus callosum ➡.* **(Right)** *Axial SWI with MIP shows innumerable punctate and linear hypointense foci ➡ that follow the course of the axons within the corona radiata.*

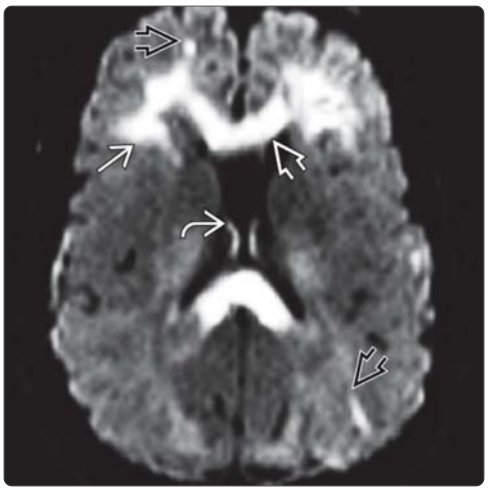

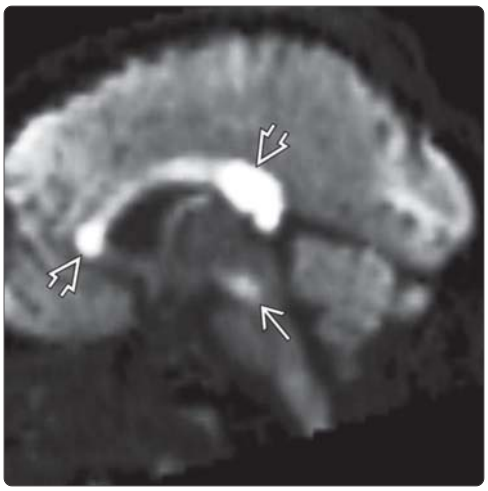

(Left) *Axial DWI in the same patient shows intense restriction in the frontal white matter ➡ as well as throughout the corpus callosum ➡, both fornices ➡, and subcortical WM ➡.* **(Right)** *Midline sagittal DWI in the same patient shows the intense restricted diffusion throughout the corpus callosum ➡. A smaller focus of restricted diffusion is present in the midbrain ➡.*

https://CafePezeshki.IR

KEY FACTS

TERMINOLOGY

- Subcortical injury (SCI): Deep DAI lesions of brainstem, basal ganglia, thalamus, and regions around 3rd ventricle
- IVH: Hemorrhage within ventricular system
- CH: Hemorrhage localized to choroidal plexus

IMAGING

- SCI: FLAIR most sensitive → hyperintense foci
- IVH: Hyperdense intraventricular blood; fluid-heme level common
- CH: Localized hyperdense choroidal hemorrhage

TOP DIFFERENTIAL DIAGNOSES

- SCI: Cavernous malformation, lacunar infarcts, small vessel ischemia
- IVH: None
- CH: Normal calcification may mask small hemorrhages

PATHOLOGY

- SCI: Most commonly induced by shear-strain forces that disrupt penetrating &/or choroidal vessels
- IVH: Disruption of subependymal veins
- CH: Traumatic shear forces damage to choroid tissue

CLINICAL ISSUES

- SCI: Profound neurologic deficits
- IVH: Obtundation, seizures
- CH: Can lead to IVH

DIAGNOSTIC CHECKLIST

- Delayed development of deep lesions common
  - Initial scan may show only diffuse brain swelling
  - Focal lesions often appear 24-48 hours later
- Remember: The deeper the lesion, the more severe the injury

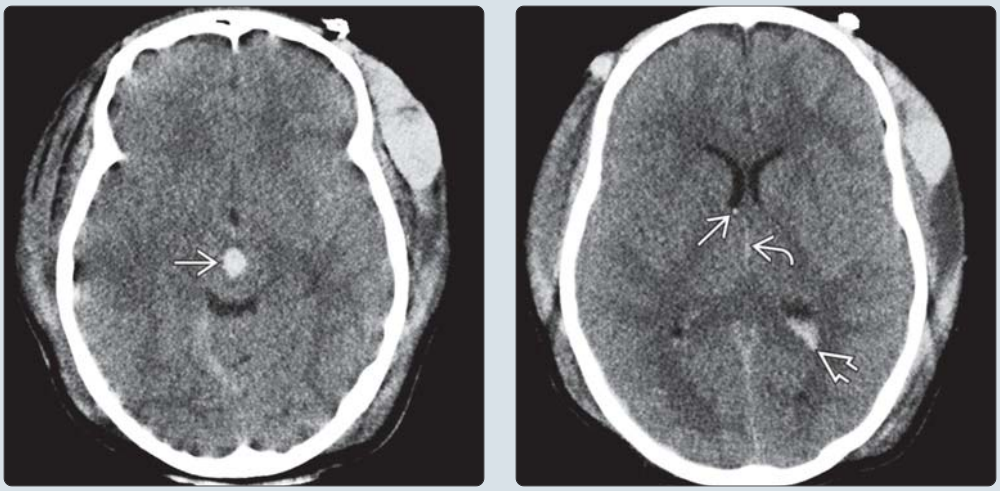

(Left) *Initial axial NECT in a 17-year-old girl involved in a high-speed MVA demonstrated only diffuse brain swelling (not shown). Because of persisting low GCS, repeat scan was obtained 24 hours later, showing a focal midbrain hemorrhage.* **(Right)** *More cephalad scan shows a punctate hemorrhage in the right fornix and in the 3rd and lateral ventricles. The patient expired 1 week later. The presence of deep lesions and intraventricular hemorrhage (IVH) indicate severe subcortical injury.*

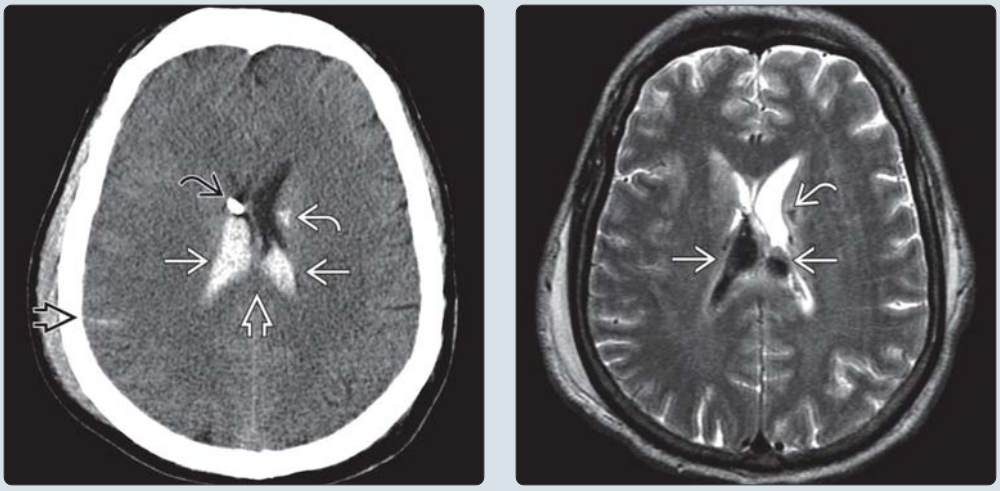

(Left) *Axial NECT in a patient with subcortical injury shows a hyperdense choroidal hemorrhage within choroid plexus substance of both ventricles. Note the subarachnoid hemorrhage, corpus callosum DAI, left caudate hemorrhagic DAI, and a ventriculostomy tube tip.* **(Right)** *Axial T2WI MR in the same patient shows hypointense hemorrhages distending the choroid plexi. A left caudate hemorrhagic DAI is again seen.*

https://CafePezeshki.IR

TERMINOLOGY

Abbreviations

- Subcortical injury (SCI)

Definitions

- Traumatic lesions of brainstem (BS), basal ganglia (BG), thalamus, and ventricles, composed of
  - Deep diffuse axonal injury (DAI)-type SCI lesions
  - Intraventricular hemorrhage (IVH)
  - Choroid hemorrhage (CH)

IMAGING

General Features

- Best diagnostic clue
  - SCI: Punctate hemorrhages
  - IVH: Hyperdense intraventricular CSF on NECT, fluid-heme level common
  - CH: Hyperdense, enlarged choroid on NECT
- Location
  - SCI: BS, BG, thalamus, and regions around 3rd ventricle
    - Most within thalamus and putamen
  - IVH: Intraventricular spaces
  - CH: Localized within choroid tissue
- Size
  - SCI: Limited to size of structure involved
  - IVH: Can fill/expand ventricles
  - CH: Limited to size of choroid involved
- Morphology
  - SCI: Petechial, linear, globular
  - IVH: Can cast ventricle
  - CH: Shape of choroid involved

CT Findings

- NECT
  - SCI: Often normal; petechial hyperdense foci
    - Deep nuclei, dorsolateral BS, periaqueductal
    - Rarely overt hemorrhage
  - IVH
    - Hyperdense intraventricular blood
    - May fill, even expand, ventricle
    - Fluid-heme level common
  - CH: Localized hyperdense choroidal hemorrhage

MR Findings

- T1WI
  - SCI: Acutely isointense
  - IVH: Fluid-heme level common
- T2WI
  - SCI: Acutely hyperintense
  - IVH: Fluid-heme
- FLAIR
  - SCI: Most sensitive sequence → hyperintense foci
  - IVH: Detection comparable to CT in acute stage
- T2* GRE
  - SCI: Susceptibility of petechial hemorrhage
- DWI
  - SCI: Foci of restricted diffusion
    - ↓ apparent diffusion coefficient (ADC)
    - Damage to white matter reduces anisotropy: Visible on FA maps
    - DTI "tractograms" allow delineation of pattern of white matter tract disruption
    - Detects abnormalities when routine imaging, including GRE, are normal
- SWI
  - Depicts significantly more DAI foci than GRE

Imaging Recommendations

- Best imaging tool
  - SCI: MR > > > CT
    - Protocol analogous to DAI
  - ICH/CH: NECT > MR
    - Protocol analogous to subarachnoid hemorrhage (SAH)
- Protocol advice
  - SCI: FLAIR and GRE
  - ICH/CH
    - CT = NECT
    - MR = FLAIR and GRE

DIFFERENTIAL DIAGNOSIS

Subcortical Injury

- Cavernous malformation: Symptoms without trauma
- Lacunar infarcts: Located in central tegmentum of pons/BS
- Small vessel ischemia

Intraventricular Hemorrhage

- ± choroid plexus hemorrhage

Choroid Hemorrhage

- Normal calcification may mask small hemorrhages

PATHOLOGY

General Features

- Etiology
  - SCI: Most commonly induced by shear-strain forces that disrupt penetrating &/or choroidal vessels
    - Usually very small, typically nonhemorrhagic
  - SCI: Less commonly
    - Dorsolateral BS impacts tentorial incisura with violent brain motion
    - Anterorostral BS damaged with sudden craniocaudal brain displacement
  - IVH
    - Disruption of subependymal veins (most common)
    - Bleeding from choroid plexus
    - Shearing injuries
    - Basal ganglia/intracerebral hemorrhage with rupture into ventricles
    - Isolated IVH in absence of parenchymal hematoma is unusual
  - CH: Traumatic shear forces damage to choroid tissue
- Associated abnormalities
  - SCI: All stages of DAI present (without exception), cerebral contusion, intracranial hemorrhages
  - IVH: DAI, deep GM/BS/intracerebral hemorrhage, SAH, cerebral contusion, hydrocephalus
  - CH: DAI, SAH, cerebral contusion

https://CafePezeshki.IR

Staging, Grading, & Classification

- SCI: BS injury (BSI)
  - Primary injury: Direct result of trauma
    - DAI; most common primary BSI
    - Direct laceration/contusion; rare
    - Multiple primary petechial hemorrhages; not associated with more superficial DAI
    - Pontomedullary rent or separation; may occur without widespread brain injury
  - Secondary injury: Indirect result of trauma, most common cause of BSI; usually herniation
- SCI: When BSI → BS hemorrhage
  - Group 1: Midline rostral anterior BS, posterior to interpeduncular cistern (69%)
    - Associated with anterior impact; 71% survival
  - Group 2: Misc foci of acute BS hemorrhage (18%)
    - Associated with transtentorial herniation and BS compression; 88% survival
  - Group 3: Any BS hemorrhage
    - Associated with transtentorial herniation and BS compression; 100% mortality

Gross Pathologic & Surgical Features

- SCI
  - Usually nonhemorrhagic, yet more often hemorrhagic than other primary intraaxial injuries
  - 2° to rich network of perforating vessels in basal ganglia and thalamus
- IVH
  - Gross blood collected within ventricular system
  - Blood-CSF level common
    - Layering, rather than clot formation, likely relates to intrinsic antithrombotic CSF properties due to high concentrations of fibrinolytic activators
  - May cast/expand involved ventricle
- CH: Hemorrhagic choroid tissue

CLINICAL ISSUES

Presentation

- Most common signs/symptoms
  - SCI: Profound neurologic deficits
    - Low initial Glasgow coma scale scores; coma
  - IVH: Obtundation, seizures

Demographics

- Age
  - Any, but most common in 15–24 year olds
- Gender
  - Men 2x as likely to sustain traumatic brain injury (TBI); peaks at 20–24 years
- Epidemiology
  - SCI: In 5-10% TBI, 3rd most common primary traumatic neuronal injury
  - IVH: Present in 60% of patients with corpus callosal DAI, 12% in patients without

Natural History & Prognosis

- SCI: Severely injured patients
  - Poor prognosis, often die soon after trauma
  - Regain consciousness very slowly and retain permanent neurological impairment/disability
- SCI: May proceed to BS hemorrhage
  - Associated with high mortality
- IVH
  - Gradually clears as resorbed, although patients > 20 cc of blood do poorly
  - Hydrocephalus rare manifestation
    - Early: CSF outlet obstruction
      - Obstructive, noncommunicating
      - Asymmetric ventricular dilatation
    - Late: Arachnoid dysfunction of CSF resorption
      - Obstructive, communicating hydrocephalus
      - Symmetric ventricular dilatation
  - Hemorrhagic dilation of 4th ventricle: Ominous predictor with 100% reported mortality
  - At baseline, predicts 2x increase in mortality
    - Does not predict functional outcome
- CH: Can lead to IVH

Treatment

- SCI
  - Supportive therapy
  - Treatment considerations of indirect/associated abnormalities: Herniation, hematoma, hydrocephalus, seizures, etc.
- IVH
  - Ventriculostomy
  - Excellent results following r-TPA thrombolytic therapy
    - Effective and safe, despite preexisting multiple hemorrhagic intracranial injuries
  - Repeat NECT to evaluate for hydrocephalus, treatment complications

DIAGNOSTIC CHECKLIST

Consider

- PSCI results from severe trauma: Often highly complex cases with a multitude of abnormal findings
  - When you think you have finished reviewing the case, look at everything 1 more time

Image Interpretation Pearls

- Delayed development of visible lesions common

SELECTED REFERENCES

1. Corrigan JD et al: Components of traumatic brain injury severity indices. J Neurotrauma. 31(11):1000-7, 2014
2. Laouchedi M et al: Deafferentation in thalamic and pontine areas in severe traumatic brain injury. J Neuroradiol. ePub, 2014
3. Liu J et al: Diffuse axonal injury after traumatic cerebral microbleeds: an evaluation of imaging techniques. Neural Regen Res. 9(12):1222-30, 2014
4. Sharp DJ et al: Network dysfunction after traumatic brain injury. Nat Rev Neurol. 10(3):156-66, 2014
5. Fox WC et al: Contemporary imaging of mild TBI: the journey toward diffusion tensor imaging to assess neuronal damage. Neurol Res. 35(3):223-32, 2013

https://CafePezeshki.IR

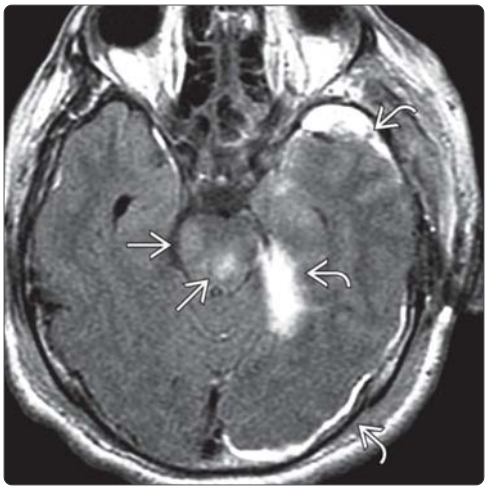

(Left) *Axial FLAIR MR demonstrates subcortical injury diffuse axonal injury (DAI) lesions in the midbrain. There are also subdural hematomas. Not shown are DAI of bilateral cerebral peduncles, as well as the left caudate, internal capsule, and anterior lentiform nuclei. Also not seen are bifrontal and bitemporal hemorrhagic cortical contusions.* **(Right)** *Axial DWI MR in the same patient shows diffusion abnormality of the midbrain Subcortical injury (SCI) DAI lesions. Note the subdural hematomas.*

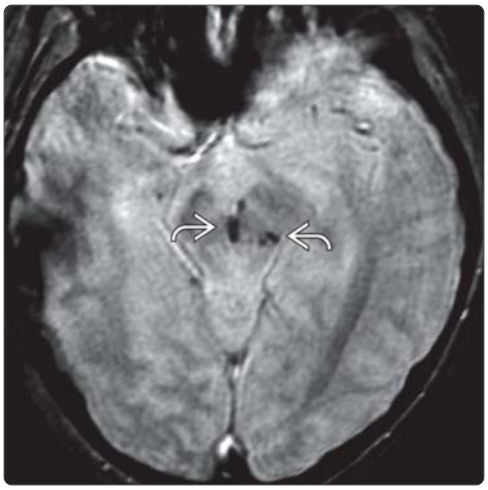

(Left) *Axial T2* GRE MR shows susceptibility of SCI DAI hemorrhage involving the midbrain and left cerebral peduncle. The patient had corresponding hemiplegia.* **(Right)** *Axial FLAIR MR in the same patient reveals more SCI DAI lesions involving the right lentiform nuclei, left thalamus, and corpus callosum.*

(Left) *Axial NECT shows a hyperdense hemorrhagic subcortical diffuse axonal injury lesion of the right middle cerebellar peduncle/cerebellar hemisphere.* **(Right)** *Axial FLAIR MR in this case also reveals hyperintense subcortical injury of the tectum (on this slice, inferior colliculi) and adjacent vermis. There is also a right temporal lobe hemorrhagic contusion, as well as subarachnoid hemorrhage within many of the sulci and the interpeduncular fossa.*

https://CafePezeshki.IR

Pneumocephalus

KEY FACTS

TERMINOLOGY
- Presence of air or gas within skull

IMAGING
- Can occur in any compartment
  - Epidural
  - Subdural
  - Subarachnoid
  - Parenchyma (pneumatocele), ventricles, intravascular
- CT: Very low density (-1,000 HU)
- MR: Foci of absent signal on all sequences, "blooms" on T2*
- Best imaging tool: NECT

PATHOLOGY
- Mechanism: Dural tear allows abnormal communication and air introduction
- Most common etiology: Trauma (74%)
  - Present in 3% of all skull fractures, 8% of paranasal sinus fractures
- Other common causes: Postsurgical
- Rare: Infection, tumor

CLINICAL ISSUES
- Most common symptom: Headache
- Mortality (15%)
- Most common complication: CSF leak (50%)
- Infection (25%): Meningitis, epidural abscess, cerebritis, brain abscess
- Most often resolves on its own after removal of primary etiology

DIAGNOSTIC CHECKLIST
- Pneumocephalus usually not problem: Find out what's causing it
- Intravenous air usually of no clinical significance

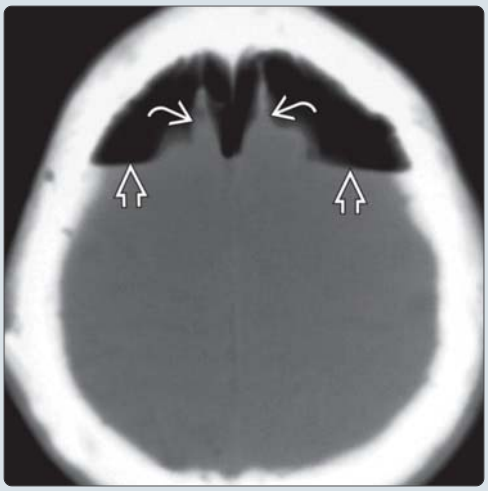

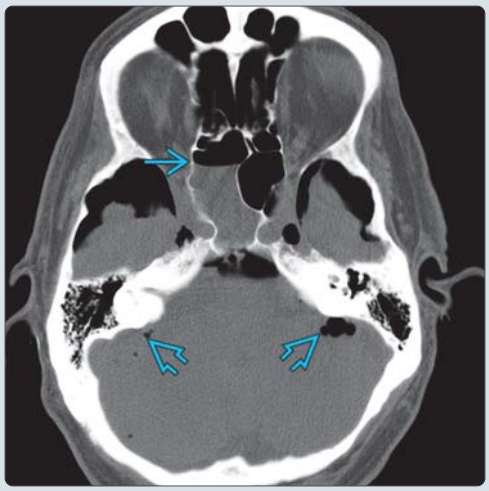

(Left) *Axial NECT shows subdural air with air-fluid levels. "Pointing" of the frontal lobes, with compression and separation of the frontal lobes by subdural air, is sometimes called the "Mount Fuji" sign. This finding indicates tension pneumocephalus and can be a surgical emergency.* **(Right)** *Axial NECT in a 71-year-old man with skull base fractures (not shown) demonstrates an air-fluid level in the sphenoid sinus, multiple "spots and dots" of subarachnoid air, and bilateral middle fossa subdural air.*

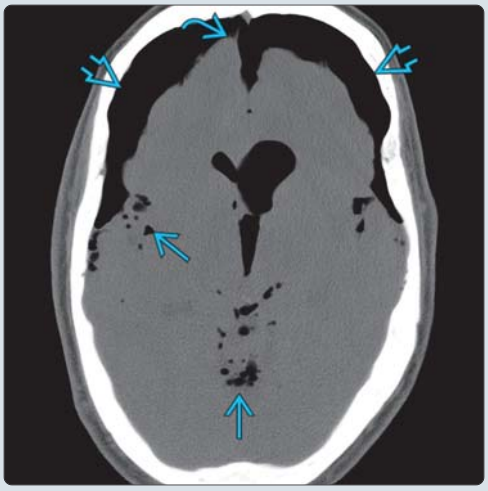

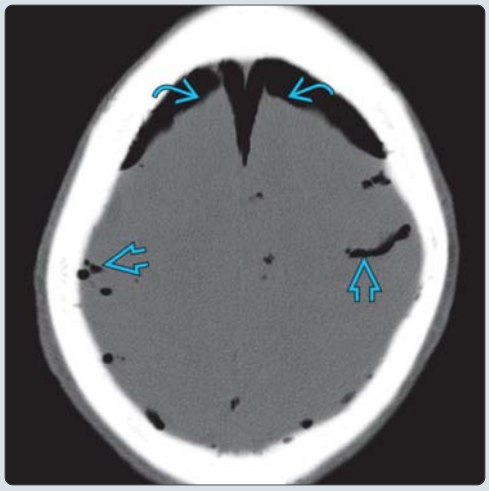

(Left) *More cephalad scan in the same patient shows large, bifrontal, subdural air collections with a right "Mount Fuji" sign. Air is also present in the 3rd ventricle and frontal horns of the lateral ventricles. "Spots and dots" of air are in the subarachnoid spaces.* **(Right)** *Axial NECT through the vertex in the same patient shows the "pointed" frontal lobes and widened interhemispheric fissure. The curvilinear foci and dots of air are in the convexity sulci.*

https://CafePezeshki.IR

TERMINOLOGY

Synonyms

- Pneumatocele (when focal)

Definitions

- Presence of air or gas within skull (always abnormal)

IMAGING

General Features

- Best diagnostic clue
  - Air anywhere within cranium
- Location
  - Can occur in any compartment
    - Extracerebral: Epidural, subdural, subarachnoid
    - Intracerebral: Brain parenchyma, cerebral ventricles
    - Intravascular: Arteries, veins, venous sinuses
- Size
  - Variable: Tiny to huge collection(s)
- Morphology
  - Focal to diffuse

CT Findings

- NECT
  - Very low density (-1,000 HU)
  - Epidural pneumocephalus
    - Remains localized
    - Does not move with changes of head position
  - Subdural pneumocephalus
    - Confluent, often forms air-fluid level(s)
    - Moves with changes of head position
    - May see cortical veins stretched within subdural air
  - Tension pneumocephalus
    - "Mount Fuji" sign
      - Subdural air separates/compresses frontal lobes, creates widened interhemispheric space between frontal lobe tips, mimicking silhouette of Mount Fuji
    - ± mass effect (frontal horns of lateral ventricles displaced posteriorly)
  - Subarachnoid pneumocephalus
    - Multifocal, nonconfluent
    - Droplet-shaped, often within sulci
  - Intraventricular pneumocephalus
    - Rarely in isolation
  - Intravascular air most often venous; arterial rare, usually fatal

MR Findings

- T2WI
  - Sinusitis, mastoiditis
- T1WI C+
  - Any causative enhancing mass
    - Neoplasm eroding through skull typically causes dural thickening; may cause pneumocephalus if air-containing structure is breached
- MR: Foci of absent signal on all sequences, "blooms" on T2*
  - Any compartment
  - Iatrogenic
    - Ventriculostomy procedure: Also increased FLAIR signal along tract
    - ICP monitor placement
    - Invasive subdural electrodes

Imaging Recommendations

- Best imaging tool
  - NECT
- Protocol advice
  - Evaluate variable windows at PACS workstation

DIFFERENTIAL DIAGNOSIS

Traumatic

- Associated with other findings of trauma
- May also be found within any compartment

Iatrogenic

- Most often after surgical procedure
- Expected pneumocephalus seen in affected compartments and nondependent subarachnoid space
- May see intravascular, cavernous sinus following vascular access procedure; asymptomatic
- Susceptibility from hardware

Infectious

- Rare sequela of gas-producing infection

PATHOLOGY

General Features

- Etiology
  - Mechanism: Dural tear allows abnormal communication and air introduction via 2 possible events
    - Ball-valve mechanism from straining, coughing, sneezing, Valsalva
    - Vacuum phenomenon caused by CSF loss
  - Most common etiology = trauma
    - Blunt trauma produces skull &/or paranasal sinus fractures
    - Air cell involvement: Frontal > ethmoid > sphenoid > mastoid
    - Penetrating: GSW, knife, penetrable foreign bodies
  - Surgery (2nd most common)
    - Prevalence varies; almost universal with supratentorial surgery
    - Hypophysectomy
    - Paranasal sinus surgery
      - Functional endoscopic sinus surgery (FESS) → cribriform plate
  - Neoplasm invading into/from sinus
    - Osteoma: Frontal > ethmoid
    - Pituitary adenoma
    - Mucocele: Most often frontal
    - Epidermoid
    - Meningioma
  - Infection from gas-forming organism
    - Extension from mastoiditis, sinusitis
    - Aerobic, anaerobic, or mixed infectious organisms
  - Iatrogenic
    - Shunt placement/manipulation
    - ICP monitor placement

https://CafePezeshki.IR

  - Invasive subdural electrodes for localization of seizure foci and functional mapping
  - Tension pneumocephalus
    - Most commonly after neurosurgical evacuation of subdural hematoma
    - Lumbar drain placement, skull base surgery, paranasal sinus and posterior fossa surgery in sitting position
    - Use of nitrous oxide during anesthesia
  - Rarely, open neural tube defect
- Associated abnormalities
  - CSF leak secondary to
    - Fracture: Cribriform plate, sphenoid sinus, mastoid air cells

Gross Pathologic & Surgical Features

- Air within skull
- Concomitant dural tear
- Direct communication outside ↔ inside established
  - Air is transmitted, forming pneumocephalus

CLINICAL ISSUES

Presentation

- Most common signs/symptoms
  - Headache
  - Acute: Most patients present within 4-5 days of inciting event
  - Chronic: Delay of several years reported
  - Tension: Headaches, ↓ level of consciousness, lateralizing deficits

Demographics

- Age
  - None; specific causes may have age prevalence
- Gender
  - None; specific causes may have gender prevalence
- Ethnicity
  - None; specific causes may have ethnic prevalence
- Epidemiology
  - Pneumocephalus present in 3% of all skull fractures, 8% of paranasal sinus fractures
  - 100% of patients undergoing supratentorial surgery have pneumocephalus in first 48 hours
  - Tension pneumocephalus: 2.5-16% prevalence following chronic subdural hematoma evacuation

Natural History & Prognosis

- Mortality (15%)
- Intravascular pneumocephalus
  - If trauma induced, associated with mortal injury
  - If no history of trauma or intracranial/intrathecal procedure
    - Usually venous, 2° to intravenous catheterization
    - Often seen within cavernous sinus
    - Patient will be asymptomatic
    - **Frequent** cause of consternation for on-call radiologists/residents
    - **Of no clinical concern**
- Tension pneumocephalus
  - Intracranial pressure rises as volume of air increases
  - Requires treatment
- Complications
  - Most common: CSF leak (50%)
  - Infection (25%): Meningitis, epidural abscess, cerebritis, brain abscess

Treatment

- Becomes an issue for air transport of trauma patients
  - Under normal flying conditions with ↓ cabin pressure, intracranial air volume will ↑ by ~ 30% at normal maximum cabin altitude of 8,000 feet
  - ↑ in ICP dependent upon both initial air volume and rate of change in cabin altitude
  - Intracranial air volume of 30 cc = estimated worst case ↑ of ICP from sea level to max altitude = 10 mm Hg → 31.8 mm Hg
  - Sea-level pressure should be maintained during air transport of patients with suspected intracranial air
- Pneumocephalus most often resolves on its own after removal of etiology
- Administration of normobaric supplemental O_2 significantly ↑ rate at which pneumocephalus resolves after craniotomy
  - At room air (21% FiO_2)
    - Resolves 31% per 24 hours
  - With nonrebreather mask delivering 68% FiO_2
    - Resolves 65% per 24 hours
- Tension pneumocephalus
  - Burr holes, craniotomy, needle aspirations, ventriculostomy, administration of 100% oxygen, and closure of dural defects
  - Mixed success rates

DIAGNOSTIC CHECKLIST

Image Interpretation Pearls

- Pneumocephalus usually not problem: Find out what's causing it
- Intravascular/cavernous sinus air without trauma or intracranial/intrathecal procedure generally of no clinical significance

SELECTED REFERENCES

1. Pulickal GG et al: Tension pneumocephalus. Singapore Med J. 55(3):e46-8, 2014
2. Youngblood SC et al: Pneumocephalus Resulting from Basilar Skull Fracture. Anesthesiology. ePub, 2014
3. Lütjens G et al: Akinetic mutism and parkinsonism due to subdural and intraventricular tension pneumocephalus. J Neurol Surg A Cent Eur Neurosurg. Epub ahead of print, 2013
4. Sweni S et al: Tension pneumocephalus: a case report with review of literature. Emerg Radiol. 20(6):573-8, 2013
5. Oh JH et al: Spontaneous pneumocephalus. Emerg Med J. 27(3):220, 2010
6. Sinclair AG et al: Imaging of the post-operative cranium. Radiographics. 30(2):461-82, 2010
7. Michel SJ: The Mount Fuji sign. Radiology. 232(2):449-50, 2004

https://CafePezeshki.IR

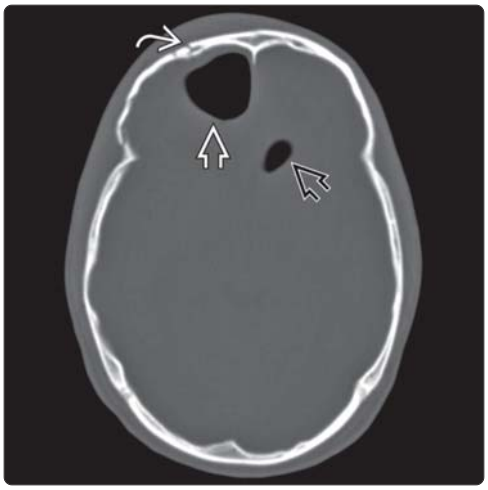

(Left) *Axial bone CT demonstrates a fracture of the right frontal bone* ⇨ *with an associated underlying focal air collection* ⇨*, as well as intraventricular air in the left frontal horn* ⇨*. Pneumocephalus may be described as "pneumatocele" when focal.* **(Right)** *Axial bone CT in a child with multiple fractures* ⇨ *shows air in the arteries that comprise the circle of Willis* ⇨*. Intraarterial air generally portends a grave prognosis.*

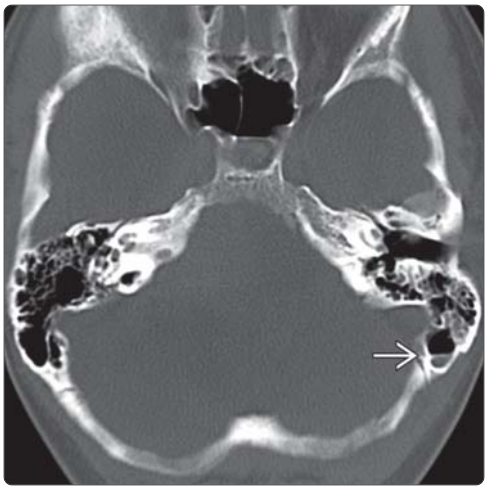

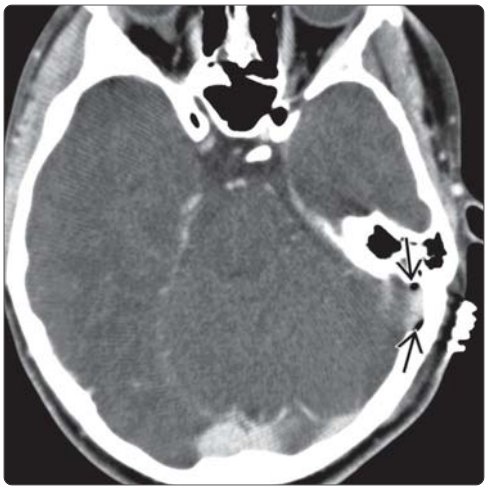

(Left) *Bone reconstruction of head CT in a patient with head trauma and skull base fractures shows a mastoid air-fluid level in the left temporal bone* ⇨*.* **(Right)** *Source image from a CTA in the same patient shows epidural air* ⇨ *around the left transverse sinus. The dural venous sinuses are intact without evidence for associated epidural hematoma.*

(Left) *Axial NECT following cardiac ablation and severe air embolism shows multiple foci of intraparenchymal gas* ⇨*, probably within cortical arteries and penetrating branches.* **(Right)** *Axial NECT in the same patient obtained 12 hours later shows that most of the air has resorbed and diffuse cerebral edema has ensued.*

https://CafePezeshki.IR

KEY FACTS

TERMINOLOGY

- Intentionally inflicted injury
- Abusive head trauma (AHT), inflicted head injury, nonaccidental head injury

IMAGING

- Plays key role in early diagnosis
  - Disparate brain injuries relative to proffered history
- Skeletal survey, NECT as initial primary imaging tools
  - Detection/characterization of intracranial hemorrhage
  - Detection/characterization of fractures
- MR
  - Delayed (24-72 hours) for detection of parenchymal injuries, demonstration of unexplained, different-aged subdural hemorrhages (SDHs)
    - Use T1WI, T2WI, T2*/SWI (best sequence varies with SDH age)
    - DWI key for identification of parenchymal insult
    - Use T1W1 C+ to detect subdural membranes of cSDH
    - Sagittal/coronal best for small peritentorial SDHs

PATHOLOGY

- Direct impact injury
  - Skull fractures
  - Underlying brain injury
- Violent "to and fro" shaking
  - Diffusely distributed subdural hematomas
  - Cortical contusions, axonal injury, parenchymal lacerations
- Ischemic injury
  - Global hypoxic brain injury
  - Territorial infarcts
  - Excitotoxic edema

CLINICAL ISSUES

- 17-25:100,000 annual incidence
  - Most common cause of traumatic death in infancy

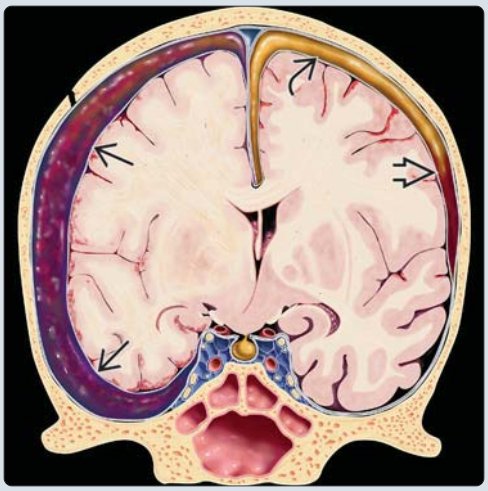

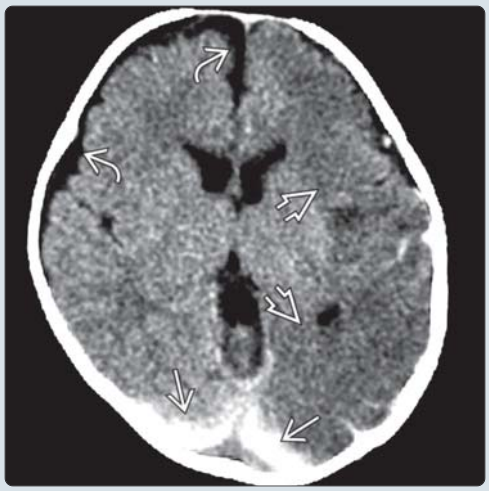

(Left) *Coronal graphic of AHT shows an acute SDH over the right hemisphere and a smaller left subdural hemorrhage (SDH) with "hematocrit" effect producing layering of blood products. Other injuries (traumatic subarachnoid hemorrhage [SAH], cortical contusions) are illustrated and are common in AHT.* **(Right)** *Axial NECT in suspected AHT shows varied attenuation SDHs with low attenuation right, bilateral high attenuation SDHs. Note the diffuse edema involving almost the entire left hemisphere.*

(Left) *Axial T1WI MR in an infant with AHT shows subacute right SDH extending into the interhemispheric fissure and a more chronic-appearing left subdural collection (cSDH vs. hygroma).* **(Right)** *Axial T2WI MR in the same patient shows hypointensity in the dependent portion of the right SDH with "hematocrit effect", suggesting a more acute component to the hematoma (hematohygroma). Hematohygromas may also arise from a single traumatic event.*

https://CafePezeshki.IR

TERMINOLOGY

Abbreviations

- Abusive head trauma (AHT)
  - Reflects various potential injury mechanisms

Synonyms

- Inflicted head injury; nonaccidental head injury

Definitions

- Intentionally inflicted brain injury

IMAGING

General Features

- Best diagnostic clue
  - Multiple brain injuries disproportionately severe relative to proffered history
    - Spectrum of findings, including scalp injuries, skull fractures, intracranial hemorrhages, cerebral contusions, shear injuries, ischemic brain injury, retinal hemorrhages

CT Findings

- NECT
  - Primary imaging tool in initial evaluation of suspected AHT
  - Sensitive in detection and characterization of fractures
    - Helical technique with multiplanar reformatting and 3D surface modeling is essential in order to detect fractures in axial plane
  - Highly sensitive in detection and characterization of intracranial hemorrhage
    - Subdural hemorrhage (SDH): > 50% of cases
      - Dominant feature of AHT
      - Over cerebral convexities, in interhemispheric fissure, overlying tentorium
    - Subarachnoid hemorrhage (SAH): ≤ 50% of cases
      - Commonly associated with SDH
      - More common in sulci over convexities; differs from SAH associated with aneurysms, which is more common in basal cisterns
    - Intraventricular hemorrhage (IVH)
    - Epidural hemorrhage (EDH) uncommon in child abuse
    - Shear injuries
      - Typical locations include corticomedullary junction, brainstem, corpus callosum
      - May not be hemorrhagic
    - Cortical contusions
      - Surface of frontal and temporal lobes
      - Hyperattenuating; develop "halo" of edema over 1st few days
      - Focal atrophy chronically
    - Parenchymal brain laceration (PBL)
      - Subcortical cleft ± hematocrit level
      - Parietal, temporal, convexity
      - Strongly suggestive of AHT
  - Ischemic injury
    - Varies from global hypoxic brain injury to individual vascular territory infarction
    - Actual etiology uncertain
    - Reversal sign: White matter appears more dense than gray matter
      - Indicates severe (irreversible) injury
  - Subdural hygromas can develop 12-36 hours after injury
    - CSF-attenuation subdural collections of CSF that leak from subarachnoid space
    - Most resolve without direct treatment
    - Should be considered imaging proxy for AHT in children < 2y
- CTA
  - Helpful in detection of arterial injuries complicating abuse
    - Vascular injuries may manifest in delayed fashion

MR Findings

- T1WI
  - Variable signal of blood products
    - SDH most often bright
    - Sagittal/coronal plane best for detecting small SDH along tentorium, over convexities
  - May see hyperintensity of cortical ribbon → petechial hemorrhage vs. laminar necrosis
- T2WI
  - Ischemic insult (hypoxic ischemic injury, HII) in neonates and infants manifest as loss of cortical ribbon
    - SDH dark → bright
- PD/intermediate
  - Very sensitive in detection of small SDHs, PBLs
  - Often identifies periventricular injury better than FLAIR or T2WI in neonates and infants
- DWI
  - Key sequence for identification of acute brain insult, including PBLs and DAI
- T1WI C+
  - May demonstrate enhancing membranes
- MRA
  - May identify/characterize arterial injury
- MRS
  - ↓ NAA, ↑ Cho/Cr ratio, ↓ Cr, ↑ lactate/lipid peaks are poor prognostic indicators
    - May be normal in first 24 hours
- SWI/T2*
  - Highly sensitive for presence of blood products (± for chronic SDH)
    - May help detect sites of prior injury, including PBLs
  - Beware: Chronic blood products in subdural compartments may show NO blooming or dephasing
- May be difficult to obtain MR in acute setting
  - More difficult to monitor unstable patient
  - Requires sedation/anesthesia
- Delayed (24-72 hours) MR may be most sensitive for detection of parenchymal injuries
- Post-traumatic hygroma follows CSF signal intensity

Imaging Recommendations

- Best imaging tool
  - NECT with multiplanar reformats for acute assessment
    - Avoid strong dating language
    - Use serial imaging (CT/MR)
- Protocol advice

https://CafePezeshki.IR

- Multiplanar reformats to assess for fractures, SDH, EDH, parenchymal injuries
- MR at 24-72 hours
  - Sagittal/coronal T1WI, T2WI, T2*/SWI for subtle peritentorial SDH (depends on age of SDH)
  - T2* (SWI) for hemorrhagic injuries
    - Note: cSDH may lack susceptibility ("blooming")
  - DWI to assess parenchymal injuries (DAI, PBL, HII)
  - Use IV contrast to characteristic cSDH
  - MRA/MRV to assess vascular injury
- Consider adding cervical spine MR, especially in children < 1-2y

DIFFERENTIAL DIAGNOSIS

Accidental Trauma

- Appropriate history for degree of injury
  - Brain parenchymal injury less common than with AHT

Mitochondrial Encephalopathies

- Glutaric acidurias (types 1 and 2), Menkes syndrome

Overshunting

- "Passive" subdurals secondary to collapse of ventricular system

Meningitis

- Subdural empyemas or sympathetic effusions

Coagulopathies

- Intracranial hemorrhage from normal activities

Neuroblastoma

- May present with "raccoon eyes," mimicking skull base fracture
- Epidural metastatic disease can mimic SDH

Leukemia

- Highly cellular hyperdense leptomeningeal metastases can mimic hemorrhage

PATHOLOGY

General Features

- Etiology
  - Varied mechanisms
    - Direct impact injury: Direct blow to cranium or impact of skull on object
      - Skull fractures and injury to immediately underlying brain
      - Note: Lack of impact is common in AHT
  - Shaking injury: Violent "to and fro" shaking of head
    - Diffusely distributed subdural hematomas, SAH
  - Intracranial venous thrombosis not associated with SDH in neonates, infants, children

CLINICAL ISSUES

Presentation

- Most common signs/symptoms
  - Discordance between stated history and degree of injury
    - "Killer couch": Injuries commonly attributed to infant rolling off couch onto floor
  - Retinal hemorrhage in up to 96%
- Other signs/symptoms
  - Presentation with "apnea" (33-45%), unexplained seizures, "unable to rouse"

Demographics

- Age
  - Median: 2.2-4.6 months
- Epidemiology
  - 17-25:100,000 annual incidence
  - Most common cause of traumatic death in infancy: 1,200 deaths per year in USA
  - Risk factors
    - < 1 year, prematurity, twin, male, physical handicap, stepchild
    - Young parents, ↓ socioeconomic status
      - 1/3 of perpetrators under influence of alcohol or drugs

Natural History & Prognosis

- Mortality: 15-38% (60% if coma at presentation)
- Neurologic deficits include acquired microcephaly (93%), early post-traumatic seizures (79%), late post-traumatic epilepsy (> 20%), poor visual outcome (20-65%)

Treatment

- Notification to local Child Protection Agency mandated in USA/Canada/Australia/some European countries
  - Multidisciplinary child abuse team intervention

DIAGNOSTIC CHECKLIST

Consider

- Inborn error of metabolism or bleeding dyscrasia may simulate nonaccidental injury
  - Appropriately investigating these possibilities both improves patient care and clarifies criminal investigation

Image Interpretation Pearls

- Avoid imprecise/strong dating language on initial NECT
- Look for combination of hemispheric brain edema and bilateral or interhemispheric SDH
- Serial imaging helps establish SCH age (CT/MR)
- In children <2y, subdural hygroma is a proxy for trauma
- Presence of PBLs specific for AHT

SELECTED REFERENCES

1. Kleinman PK (ed): Diagnostic Imaging of Child Abuse, 3e, Cambridge Press 2015
2. Greeley CS: Abusive head trauma: a review of the evidence base. AJR Am J Roentgenol. 204(5):967-73, 2015
3. Hsieh KL et al: Revisiting neuroimaging of abusive head trauma in infants and young children. AJR Am J Roentgenol. 204(5):944-52, 2015
4. Wittschieber D et al: Subdural hygromas in abusive head trauma: pathogenesis, diagnosis, and forensic implications. AJNR Am J Neuroradiol. 36(3):432-9, 2015
5. Kadom N et al: Usefulness of MRI detection of cervical spine and brain injuries in the evaluation of abusive head trauma. Pediatr Radiol. 44(7):839-48, 2014
6. Pekarsky AR et al: Skeletal surveys and head computed tomographies in the evaluation of child abuse: refining practice patterns. J Pediatr. 164(6):1250-2, 2014
7. Bradford R et al: Serial neuroimaging in infants with abusive head trauma: timing abusive injuries. J Neurosurg Pediatr. 12(2):110-9, 2013
8. John SM et al: Patterns of structural head injury in children younger than 3 years: A ten-year review of 519 patients. J Trauma Acute Care Surg. 74(1):276-281, 2013

https://CafePezeshki.IR

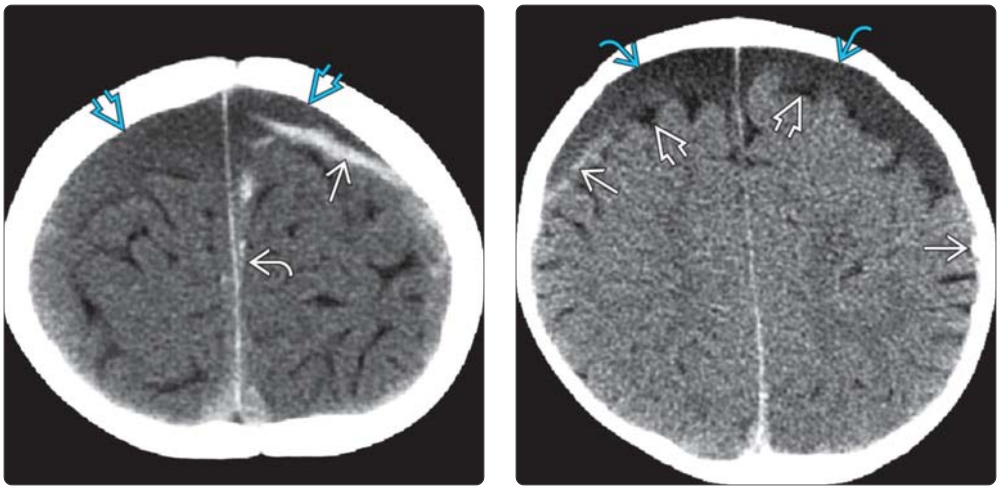

(Left) *Axial NECT shows mixed low ➡ and high attenuation ⇨ SDHs in an infant with inflicted injury. Extension into the interhemispheric fissure ➡ is a common finding in such cases.* **(Right)** *Findings of mixed-attenuation SDHs in child abuse can be subtle. Axial NECT shows large, bifrontal, low attenuating SDHs ⇨ with hyperattenuating components ➡. Note the hypoattenuating "dots" of CSF ➡ in compressed, displaced sulci underlying the chronic SDHs.*

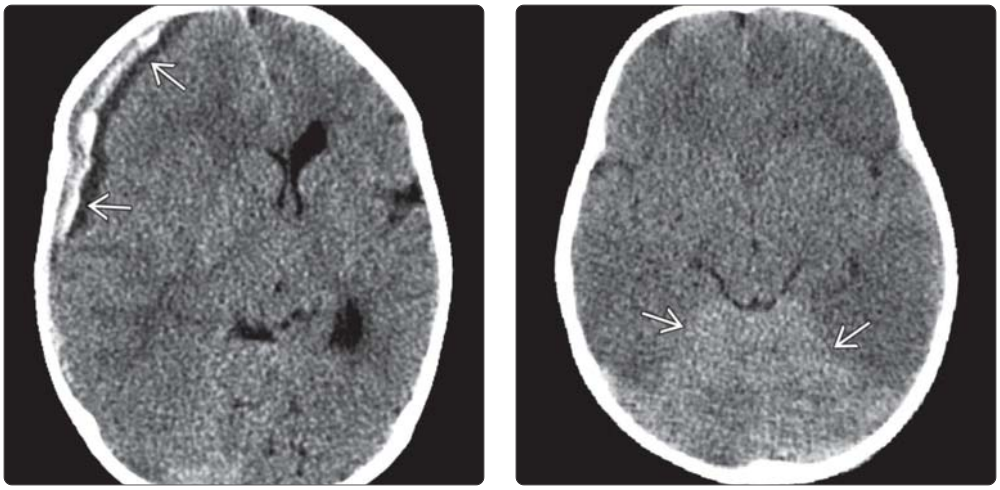

(Left) *Axial NECT in an abused infant shows mixed attenuation right frontotemporal SDHs ➡. Note that the mass effect underlying the SDHs is much greater than the thickness of the SDHs, indicating right hemispheric swelling. Excitotoxic brain injury can occur with repeated concussions ("2nd impact syndrome"). While this is more common in athletes, it also occurs in AHT.* **(Right)** *Bilateral diffuse brain swelling in AHT makes the normally perfused cerebellum ➡ appear white ("reversal" sign).*

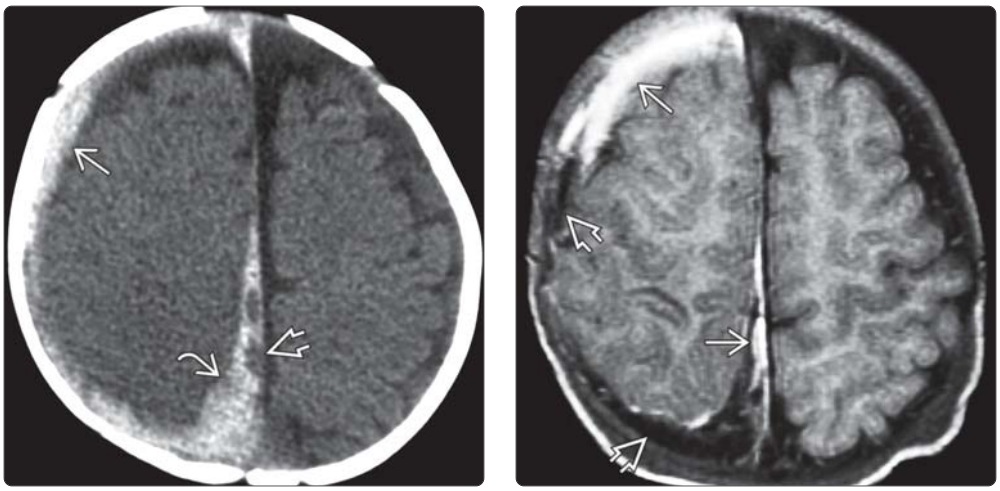

(Left) *Axial NECT scan in an infant with suspected AHT shows an extensive right-sided mixed attenuation SDH ➡ that extends into the interhemispheric fissure ➡. Some loculated hypoattenuating pockets ➡ suggest different-aged hematomas may be present.* **(Right)** *T1WI (same case) shows 2 different-aged subdural hematomas. Late subacute hematoma is hyperintense ➡; more acute blood is hypointense ➡. "Differing age" SDHs are suggestive of AHT.*

https://CafePezeshki.IR

KEY FACTS

TERMINOLOGY

- Brain displaced from 1 compartment into another

IMAGING

- Subfalcine herniation
  - Cingulate gyrus displaced under falx
  - Ipsilateral ventricle compressed and displaced across midline
  - Contralateral ventricle dilated
- Unilateral descending transtentorial herniation (DTH)
  - Temporal lobe displaced medially into incisura
  - Encroaches on, then effaces suprasellar cistern
- Bilateral DTH ("central herniation")
  - Both temporal lobes herniated into tentorial hiatus
  - Diencephalon crushed against skull base
  - Suprasellar cistern, CSF spaces obliterated
  - Midbrain/pons displaced inferiorly
- Ascending transtentorial herniation
  - Cerebellum displaced up through incisura
  - Quadrigeminal cistern, tectum flattened
- Tonsillar herniation
  - Tonsils impacted into foramen magnum
  - Cisterna magna obliterated
- Transalar herniation
  - Ascending (middle fossa mass) or descending (frontal mass)
  - Brain, middle cranial artery (MCA) herniated across sphenoid wing
- Transdural/transcranial herniation
  - Brain extruded through dural/skull defect

TOP DIFFERENTIAL DIAGNOSES

- Intracranial hypotension

DIAGNOSTIC CHECKLIST

- DWI, T2* for ischemic, hemorrhagic complications

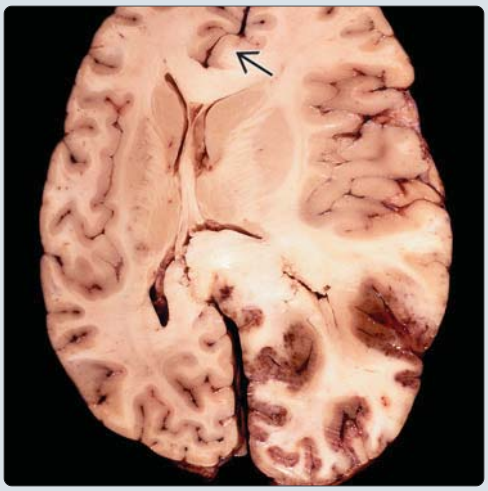

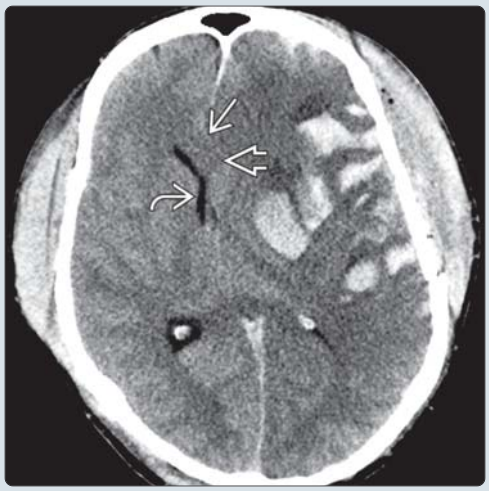

(Left) *Axial gross pathology section through the ventricles in a patient who died of multiple traumatic injuries shows findings of severe subfalcine herniation. Ventricles are displaced across the midline, and the cingulate gyrus ⇨ is herniated under the falx. Left PCA infarct occurred secondary to descending transtentorial herniation. (Courtesy R. Hewlett, MD.)* **(Right)** *Axial NECT in severe trauma shows subfalcine herniation ➡ with severely compressed left ➡ and slightly dilated right lateral ventricle ➡.*

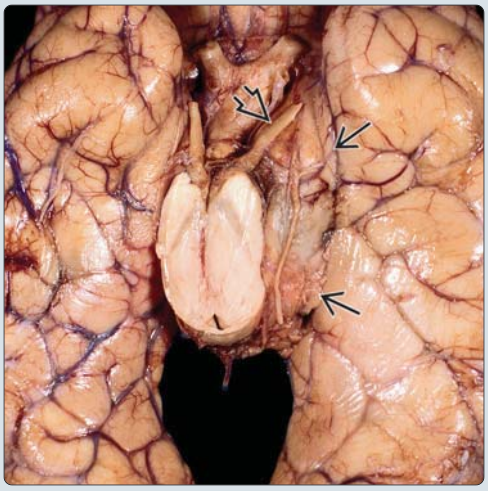

(Left) *Submentovertex gross pathology shows findings of unilateral descending transtentorial herniation. Undersurface of herniated temporal lobe shows "grooving" ⇨ from impaction against the tentorium. Note the 3rd nerve compression ⇨ and midbrain displacement. (Courtesy R. Hewlett, MD.)* **(Right)** *Axial NECT in a patient with CHI injury shows changes of left descending transtentorial herniation, with uncus ➡ and hippocampus ➡ herniated into the suprasellar cistern. The right side of the cistern is preserved.*

https://CafePezeshki.IR

TERMINOLOGY

Abbreviations

- Subfalcine herniation (SFH)
- Descending transtentorial herniation (DTH)

Definitions

- Herniation of brain from 1 compartment (normally separated by calvarial &/or dural boundaries) to another

IMAGING

General Features

- Best diagnostic clue
  - Several herniation types (findings vary)
    - SFH: Lateral, 3rd ventricles displaced across midline
    - DTH: Temporal lobe displaced over and into tentorial incisura
- Subfalcine herniation
  - Most common herniation
  - Cingulate gyrus displaced under falx
  - Ipsilateral ventricle compressed and displaced across midline
  - Complications
    - Early: Contralateral ventricle enlarged secondary to obstruction at foramen of Monro
    - Late: Anterior cerebral arteries (ACAs) displaced → compressed against free edge of falx → occlusion → secondary infarct
- Unilateral DTH
  - 2nd most common herniation
  - Medial temporal lobe displaced medially into incisura
    - Early/mild DTH: Uncus effaces ipsilateral suprasellar cistern
    - Moderate DTH: Hippocampus effaces ipsilateral quadrigeminal cistern
      - Displaces, mildly compresses midbrain
    - Severe DTH: Medial temporal lobe, temporal horn displaced inferiorly into upper CPA cistern
      - Suprasellar cistern obliterated
  - Complications
    - Contralateral midbrain compressed against tentorium, may cause Kernohan notch
      - Ipsilateral hemiplegia ("false localizing" sign)
      - Supratentorial mass causes compression of **contralateral** peduncle against tentorial edge
    - Midbrain (Duret) hemorrhages
    - Posterior cerebral artery (PCA) displaced inferiorly over free edge of tentorium
      - PCA kinking/occlusion leads to secondary occipital infarct
- Bilateral DTH ("central herniation")
  - Less common; seen with severe supratentorial mass effect(s)
  - Both temporal lobes herniated into tentorial hiatus
  - Optic chiasm/diencephalon crushed against skull base
  - Midbrain displaced inferiorly
    - Anterior inferior 3rd ventricle displaced posteriorly behind dorsum sella
    - Angle between midbrain and pons becomes more acute
  - Complications
    - Penetrating basal arteries occlusion → basal infarcts
- Ascending transtentorial herniation
  - Less common than descending herniation
  - Cerebellum displaced up through incisura
  - Quadrigeminal cistern compressed, tectum flattened
  - Complications
    - Aqueduct obstruction → hydrocephalus
- Tonsillar herniation
  - Most common herniation seen with posterior fossa mass
  - Tonsils pushed inferiorly, impacted into foramen magnum
    - Displacement > 5 mm
    - Tonsil folia become vertically oriented
  - Cisterna magna obliterated
  - Complications
    - 4th ventricle obstruction → hydrocephalus
- Transalar herniation
  - Rare
  - Brain, middle cranial artery (MCA) herniated across sphenoid wing
  - Ascending or descending
    - Ascending: Middle cranial fossa/temporal lobe mass displaces sylvian fissure, MCA, up/over sphenoid wing
    - Descending: Anterior fossa/frontal lobe mass forces gyrus rectus posteroinferiorly over sphenoid wing, displaces sylvian fissure/MCA backward
  - Complication
    - MCA compressed against sphenoid → infarct
- Transdural/transcranial herniation
  - Rare
    - Sometimes called "brain fungus"
    - Can be life threatening
  - Brain, vessels herniated through dural &/or skull defect
  - Trauma (skull fracture lacerates dura), craniotomy
  - ↑ intracranial pressure (ICP) forces brain through dura ± subgaleal extension

CT Findings

- NECT
  - Ventricles displaced; sulci/cisterns obliterated

MR Findings

- T1WI
  - Best anatomic definition
- T2WI
  - Best for complications (e.g., edema, infarcts, hydrocephalus)
- T2* GRE
  - Best for hemorrhagic foci (e.g., Duret hemorrhages)
- DWI
  - Secondary ischemia/infarcts
- DTI
  - ± corticospinal tract disruption
  - Kernohan notch → loss of FA

Imaging Recommendations

- Best imaging tool
  - NECT is best rapid screen
  - Multiplanar MR for complications
- Protocol advice

https://CafePezeshki.IR

- Add DWI, T2* (GRE), SWI for ischemic, hemorrhagic complications

DIFFERENTIAL DIAGNOSIS

Intracranial Hypotension (IH)

- Brain "pulled," not "pushed" down
- Pituitary gland often engorged
- Dural thickening, enhancement often present

Chiari 1

- Congenital anomaly with low-lying tonsils
- Brain otherwise normal

PATHOLOGY

General Features

- Etiology
  - Trauma most common clinical setting
  - Mass lesions, large infarcts, and inflammatory lesions
  - Hemorrhage, extracellular fluid, or added tissue accumulate within closed space
  - CSF spaces (cisterns, ventricles) initially compressed
  - Intracranial volume cannot be accommodated
    - Gross mechanical displacement of brain, vessels → herniation
  - Secondary effects exacerbate severity of primary injuries
  - Herniations, ↑ ICP, altered cerebral hemodynamics → ischemia and infarction
    - PCA occlusion → occipital infarct most common
    - ACA occlusion → distal (cingulate gyrus) infarcts
    - Perforating vessels → basal ganglia, capsule infarcts
    - Midbrain Duret hemorrhage can occur from stretching/tearing of pontine perforators
- Associated abnormalities
  - Secondary obstructive hydrocephalus
  - Ischemia, hemorrhage, necrosis

Gross Pathologic & Surgical Features

- Grossly swollen, edematous brain
- Gyri compressed and flattened against calvaria
- Sulci effaced

CLINICAL ISSUES

Presentation

- Most common signs/symptoms
  - Focal neurologic deficit
    - Contralateral hemiparesis
    - Ipsilateral pupil-involving CN3 palsy
    - Ipsilateral hemiplegia
      - Kernohan notch → compression of opposite cerebral peduncle against tentorium
      - "False localizing" signs
  - Decreased mental status or obtundation

Natural History & Prognosis

- Brain death if ICP continues to rise, mass effect progresses unabated

Treatment

- Mitigate secondary effects
- Removal of mass or decompressive craniectomy
- Prolonged post-traumatic brain hypersensitivity
  - May offer potential "therapeutic window"
  - Possible use of neuroprotective agents

DIAGNOSTIC CHECKLIST

Consider

- IH syndrome
  - Can mimic some features of herniations caused by supratentorial mass
    - Common features
      - "Slumping" midbrain
      - "Closed" midbrain-pontine angle
      - Tonsillar herniation
      - ± subdural hematomas
    - Distinguishing features in IH
      - Brain appears "pulled" down, not "pushed" down
      - Dural thickening, enhancement
      - Pituitary engorgement

Image Interpretation Pearls

- Use DWI, T2* sequences in brain trauma, suspected herniation

SELECTED REFERENCES

1. Wu H et al: The Diagnosis and Surgical Treatment of Central Brain Herniations Caused by Traumatic Bifrontal Contusions. J Craniofac Surg. ePub, 2014
2. Arbour RB: Early metabolic/cellular-level resuscitation following terminal brain stem herniation: implications for organ transplantation. AACN Adv Crit Care. 24(1):59-78, 2013
3. Bor-Seng-Shu E et al: Posttraumatic refractory intracranial hypertension and brain herniation syndrome: cerebral hemodynamic assessment before decompressive craniectomy. Biomed Res Int. 2013:750809, 2013
4. Young GB: Impaired consciousness and herniation syndromes. Neurol Clin. 29(4):765-72, 2011
5. Kalita J et al: Brain herniations in patients with intracerebral hemorrhage. Acta Neurol Scand. 119(4):254-60, 2009
6. Hussain SI et al: Brainstem ischemia in acute herniation syndrome. J Neurol Sci. 268(1-2):190-2, 2008
7. Marupaka SK et al: Atypical Duret haemorrhages seen on computed tomography. Emerg Med Australas. 20(2):180-2, 2008
8. Timms C et al: Brainstem distortion from postoperative cerebellar herniation through a dural and bony defect. J Clin Neurosci. 15(9):1050-1, 2008
9. Yoo WK et al: Kernohan's notch phenomenon demonstrated by diffusion tensor imaging and transcranial magnetic stimulation. J Neurol Neurosurg Psychiatry. 79(11):1295-7, 2008

https://CafePezeshki.IR

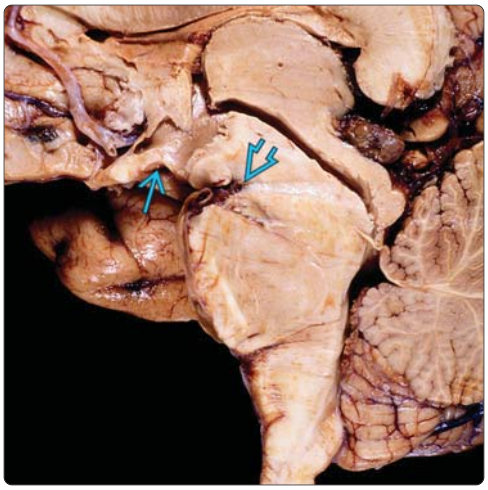

(Left) *Sagittal autopsy demonstrates findings of complete bilateral descending transtentorial herniation with the optic chiasm and 3rd ventricle ⇨ draped over the sella. The midbrain is displaced inferiorly and the angle with pons is decreased ⇨. (Courtesy R. Hewlett, MD.)* **(Right)** *Sagittal MP RAGE T1WI obtained just prior to death in a patient with complete central herniation shows inferior displacement of midbrain, pons, and cerebellar tonsils. (Courtesy R. Hewlett, MD.)*

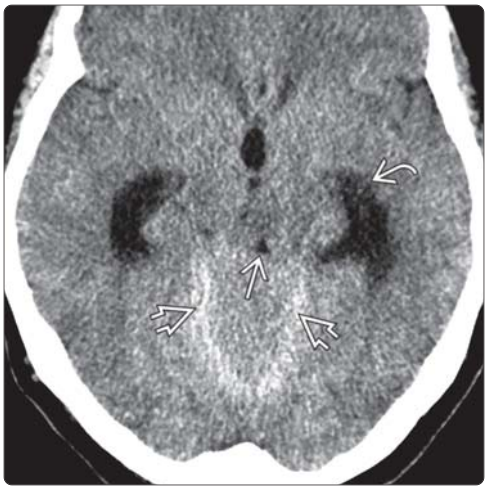

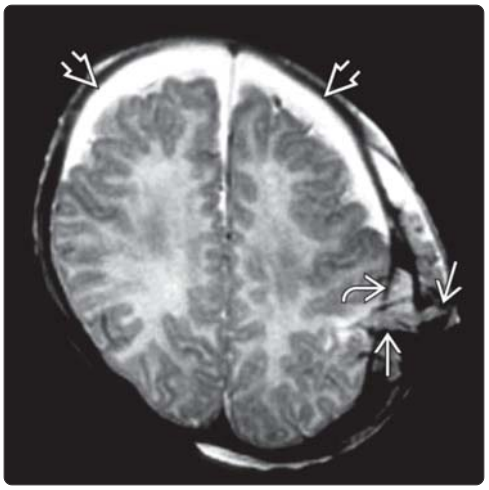

(Left) *Axial NECT shows findings of ascending transtentorial herniation. The vermis is displaced superiorly through the tentorial incisura ⇨, flattening and compressing the tectal plate ⇨. The aqueduct is obstructed, causing acute hydrocephalus with transependymal CSF flow ⇨.* **(Right)** *Axial T2WI MR in an infant with a left parietal skull fracture shows transcalvarial herniation of the brain and accompanying vessels ⇨ through torn dura ⇨. Bilateral chronic SDHs are present ⇨.*

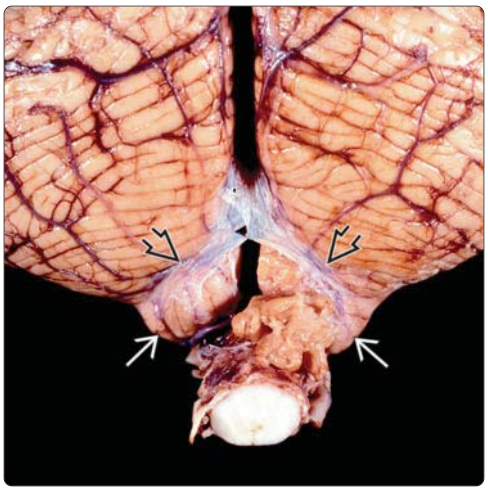

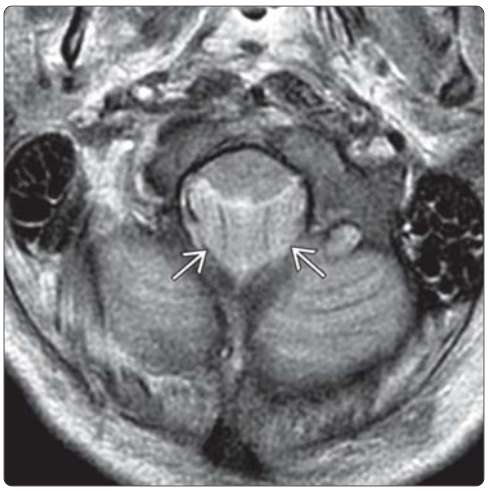

(Left) *Gross pathology of an autopsied brain seen posteriorly shows bilateral tonsillar herniation. Note the grooving of tonsils ⇨ from impaction against the foramen magnum as the tonsils ⇨ are forced inferiorly into the upper cervical spine. (Courtesy R. Hewlett, MD.)* **(Right)** *Axial T2WI MR shows severe tonsillar herniation with both tonsils ⇨ displaced inferiorly, filling the cisterna magna and displacing the upper cervical spinal cord anteriorly.*

https://CafePezeshki.IR

KEY FACTS

TERMINOLOGY

- Vasogenic edema (VE), cytotoxic edema (CTE), cerebral edema (CE), diffuse brain swelling (DBS)
- 2 basic forms of brain edema in trauma: VE and CTE (often coexist)
  - VE: Extracellular edema, follows blood-brain barrier (BBB) breakdown
  - CTE: Intracellular (closed barrier) edema

IMAGING

- Compressed ventricles, effaced sulci
- Vasogenic more prominent in WM, cytotoxic more prominent in GM
- Secondary effects of CE
  - Brain herniation(s)
  - Vascular compression → infarction
- DWI together with ADC differentiates VE from CTE
  - CTE: Cellular swelling (↑ signal on DWI, ↓ ADC)
  - VE: Increased extracellular brain water (↑ ADC)
- Brain edema accompanied by ↑ ICP, ↑ pulsatility index, ↓ blood flow velocity within 24 hours → poor prognosis
- Disturbed cerebral autoregulation during 1st 48 hours correlates with poor outcome

TOP DIFFERENTIAL DIAGNOSES

- Anoxic encephalopathy
- Metabolic encephalopathy
- Pressure-related edema

CLINICAL ISSUES

- Goal = maintain cerebral perfusion pressure (CPP) without inducing hydrostatic vasogenic edema
- DBS more common in children than adults

DIAGNOSTIC CHECKLIST

- Consider hypoxia as contributing factor

(Left) *Axial NECT demonstrates acute left periatrial hemorrhage ⇨ with minimal surrounding vasogenic edema. Note diffuse sulcal effacement, midline shift to the right, and early trapping of the right lateral ventricle ⇨.* **(Right)** *Axial T2WI MR in the same patient demonstrates left periatrial hemorrhage with increased surrounding edema. Interval left craniectomy is noted with extracalvarial herniation of brain parenchyma ⇨. Edema related to the splenium of the corpus callosum ⇨ is also noted.*

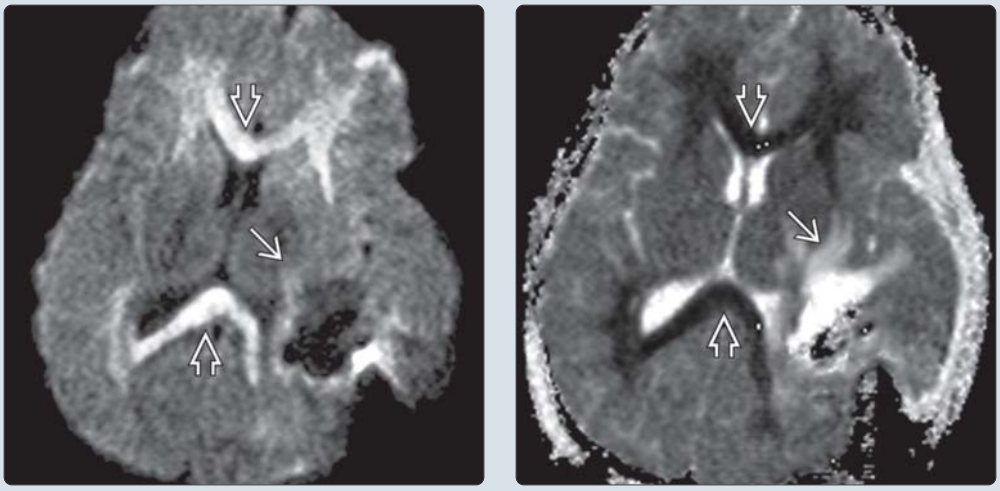

(Left) *Axial DWI MR demonstrates increased signal in the corpus callosum and cerebral white matter ⇨, consistent with edema. Edema is also noted around the left periatrial hematoma ⇨.* **(Right)** *Axial ADC in the same patient demonstrates corresponding hypointensity in the corpus callosum and cerebral white matter ⇨, confirming cytotoxic edema. Bright signal on ADC surrounding the left periatrial hemorrhage reflects increased diffusivity, characteristic of vasogenic (not cytotoxic) edema ⇨.*

https://CafePezeshki.IR

TERMINOLOGY

Synonyms

- Vasogenic edema (VE), cytotoxic edema (CTE), cerebral edema (CE), diffuse brain swelling (DBS)

Definitions

- Brain, CSF, and blood coexist in closed intracranial compartment
  - To maintain normal ICP, ↑ pressure in 1 compartment must be balanced by ↓ in others (Monro-Kellie doctrine)
- CE (secondary effect of trauma, ischemia) is dynamic process involving glutamate-mediated excitotoxicity, cell damage
- 2 basic forms of brain edema in trauma: VE and CTE often coexist
  - VE: Extracellular edema, follows blood-brain barrier (BBB) breakdown
  - CTE: Intracellular (closed barrier) edema

IMAGING

General Features

- Best diagnostic clue
  - Compressed ventricles, effaced sulci due to focal or diffuse increase in brain water
- Location
  - Vasogenic more prominent in white matter (WM); cytotoxic more prominent in gray matter (GM)
    - Often coexist
- Morphology
  - Compressed ventricles, effaced sulci
  - Secondary effects of CE
    - Brain herniation(s)
    - Vascular compression → infarction

Radiographic Findings

- Radiography
  - ± fractures, split sutures

CT Findings

- NECT
  - Compressed ventricles, effaced sulci
  - Low-attenuation brain parenchyma: WM > GM
    - Subcortical WM less resistant to fluid accumulation than GM
    - Loss of GM-WM interfaces
  - Vasogenic edema more prominent in WM
  - Cytotoxic edema more prominent in GM
  - ↓ supratentorial perfusion with preservation of infratentorial perfusion → "white cerebellum" sign
  - Multifocal hemorrhages often present
- CECT
  - Usually no enhancement unless BBB disrupted
- Xenon CT
  - Edema is major contributor to brain swelling
  - Cerebral blood volume actually decreases in proportion to cerebral blood flow

MR Findings

- T1WI
  - Hypointense edema
- T2WI
  - Hyperintense edema
- FLAIR
  - Hyperintense edema
  - Less useful in newborn due to normally ↑ water content of neonatal brain
- T2* GRE
  - ± blood products
- DWI
  - DWI together with ADC differentiates VE from CTE
    - CTE: Cellular swelling (↓ ADC)
    - VE: Increased extracellular brain water (↑ ADC)
  - Diffusion tensor imaging (DTI): ↓ diffusion anisotropy early, when MR/DWI still normal
  - DTI identifies traumatic penumbra, potentially salvageable brain
- T1WI C+
  - Patchy enhancement if BBB breakdown
- MRA
  - ± decreased flow ("thinned" arteries)
  - Vascular obstruction (compression or dissection during herniation) → post-traumatic infarction
- MRV
  - Sinus compression with severe edema
- MRS
  - ↓ NAA, elevated Cho (membrane breakdown), presence of lactate predicts poor prognosis
- Perfusion: ↓ brain perfusion with progressive ↑ ICP

Ultrasonographic Findings

- Pulsed Doppler
  - Brain edema accompanied by ↑ ICP, ↑ pulsatility index, ↓ blood flow velocity within 24 hours → poor prognosis
  - Moving correlation index between mean arterial BP and ICP = PRx (measures cerebral vasomotor reactivity)
    - PRx < 0.3 = intact reactivity; PRx > 0.3 = impaired reactivity
    - Disturbed cerebral autoregulation during first 48 hours correlates with poor outcome

Angiographic Findings

- Conventional
  - Slow arteriovenous transit if ↑ ICP

Nuclear Medicine Findings

- PET
  - PET/SPECT: ↓ rCBV, hypometabolism (dependent upon timing)

Imaging Recommendations

- NECT performed due to accessibility in critically ill trauma patients
- DWI with ADC maps (or DTI) important to differentiate VE, CTE
- Multiplanar MR allows characterization of acquired cerebral herniations
  - Subfalcine (cingulate), tonsillar, uncal, transtentorial (central ascending, central descending, lateral), transalar, external

https://CafePezeshki.IR

DIFFERENTIAL DIAGNOSIS

Anoxic Encephalopathy

- Hypoxic-ischemic encephalopathy, drowning, cardiopulmonary arrest

Metabolic Encephalopathy

- Uremia, mitochondrial disorders

Pressure-Related Edema

- Posterior reversible encephalopathy syndrome
  - Hypertensive encephalopathy, cyclosporine/FK506 encephalopathy, L-asparaginase, eclampsia
  - Predominantly VE in subcortical WM parietooccipital regions
- Venous obstruction with ↑ venous pressure

Meningitis/Encephalitis

- Diffuse sulcal effacement, leptomeningeal ± parenchymal enhancement

PATHOLOGY

General Features

- Etiology
  - Vasogenic edema
    - ↑ BBB permeability
    - Endothelial tight junctions disrupted → leakage of proteins/Na++/water → fluid shift into extracellular spaces
    - Primarily WM, myelin (major association bundles, relative sparing of commissural/projection fibers)
  - Cytotoxic edema
    - Intracellular (closed barrier) edema
    - Energy failure → loss of Na++/K homeostasis
    - Intracellular water uptake causes cell swelling, compression of extracellular space
  - Other brain water disturbances
    - Hydrocephalic (interstitial)
    - Hydrostatic (congestive)
    - Hypo-osmotic

Gross Pathologic & Surgical Features

- ↑ brain water, obliteration of cisterns/ventricles/sulci

Microscopic Features

- Extracellular fluid of cortex neuropil → swelling and shrinkage of pre-/postsynaptic structures, synaptic disassembly
- Effects of hypoxia and cell death

CLINICAL ISSUES

Presentation

- Most common signs/symptoms
  - Altered consciousness
  - Coma
- Clinical profile
  - < 2 years old: Inflicted injury in 80%
  - Teens and adults: Motor vehicle crash, assaults
    - Car crashes, especially auto without seat belts, motorcyclists/bicyclists without helmets
  - > 65 years old: Accidental falls

Demographics

- Age
  - DBS more common in children than adults
- Gender
  - M:F = 1.6-2:1
- Ethnicity
  - African American, Native Americans overrepresented
- Epidemiology
  - 1.5 million traumatic brain injuries per year (USA)
    - Highest incidence in children < 5 years old

Natural History & Prognosis

- Slowly expanding lesions can be accommodated without elevated ICP
- Rapid expansion (trauma, rapid tumor growth, abscess) → rapid rise of ICP
  - Followed by "cascade" of sequelae (e.g., excitotoxin release) → cell death
- Post-traumatic edema generally resolves within 2 weeks, atrophy (due to cellular death) ensues

Treatment

- Goal = maintain cerebral perfusion pressure (CPP) without inducing hydrostatic vasogenic edema
  - ↑ CPP in selected patients with intact cerebral vasomotor reactivity
- Decompressive surgery
- Osmotherapy, neuroprotective agents, steroids, all controversial

DIAGNOSTIC CHECKLIST

Consider

- Hypoxia as contributing factor

Image Interpretation Pearls

- Image timing crucial: VE (1st hours) replaced by CTE

SELECTED REFERENCES

1. Alves JL: Blood-brain barrier and traumatic brain injury. J Neurosci Res. 92(2):141-7, 2014
2. Lu H et al: The apparent diffusion coefficient does not reflect cytotoxic edema on the uninjured side after traumatic brain injury. Neural Regen Res. 9(9):973-7, 2014
3. Paiva WS et al: Delayed unilateral traumatic brain swelling in a child. J Pediatr Neurosci. 9(2):169-71, 2014
4. Wu H et al: The Diagnosis and Surgical Treatment of Central Brain Herniations Caused by Traumatic Bifrontal Contusions. J Craniofac Surg. ePub, 2014
5. Bor-Seng-Shu E et al: Posttraumatic refractory intracranial hypertension and brain herniation syndrome: cerebral hemodynamic assessment before decompressive craniectomy. Biomed Res Int. 2013:750809, 2013
6. Ren W et al: Occludin and connexin 43 expression contribute to the pathogenesis of traumatic brain edema. Neural Regen Res. 8(29):2703-12, 2013
7. Greve MW et al: Pathophysiology of traumatic brain injury. Mt Sinai J Med. 76(2):97-104, 2009
8. Tollard E et al: Experience of diffusion tensor imaging and 1H spectroscopy for outcome prediction in severe traumatic brain injury: Preliminary results. Crit Care Med. 37(4):1448-55, 2009
9. Galloway NR et al: Diffusion-weighted imaging improves outcome prediction in pediatric traumatic brain injury. J Neurotrauma. 25(10):1153-62, 2008

https://CafePezeshki.IR

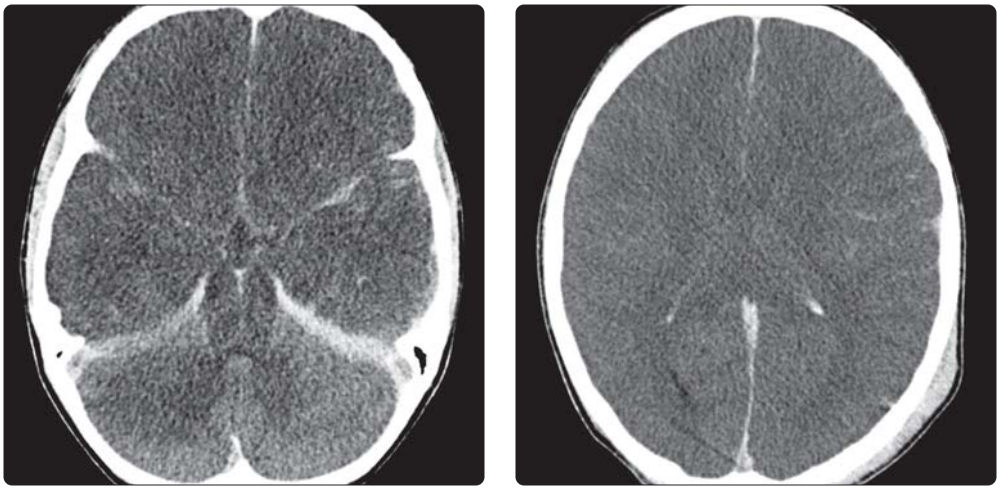

(Left) *Axial NECT in a 3-year-old boy who was not belted into a child car seat and was ejected during a high-impact MVA shows that the cerebral hemispheres are diffusely hypodense without gray-white differentiation. Some subarachnoid and peritentorial subdural blood is present.* **(Right)** *More cephalad scan in the same patient shows complete lack of gray-white differentiation. The lateral ventricles are compressed and almost inapparent. There is severe post-traumatic brain swelling.*

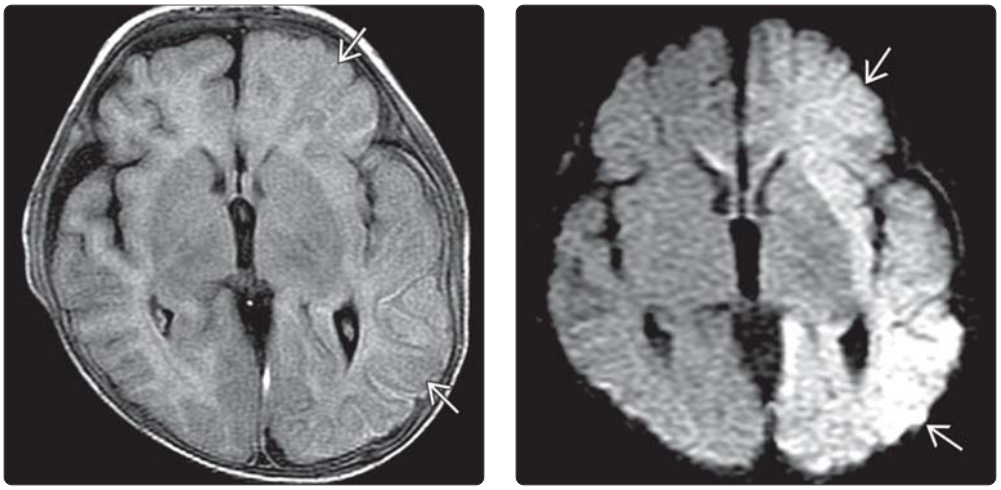

(Left) *Axial T1WI shows left hemispheric brain swelling in a child with nonaccidental head trauma. Note the sulcal effacement and diffuse signal loss ➡ of the left hemispheric cortical gray matter.* **(Right)** *Axial DWI MR in the same patient shows left hemispheric edema ➡ involving the cortex, subcortical, and periventricular white matter in a nonvascular distribution.*

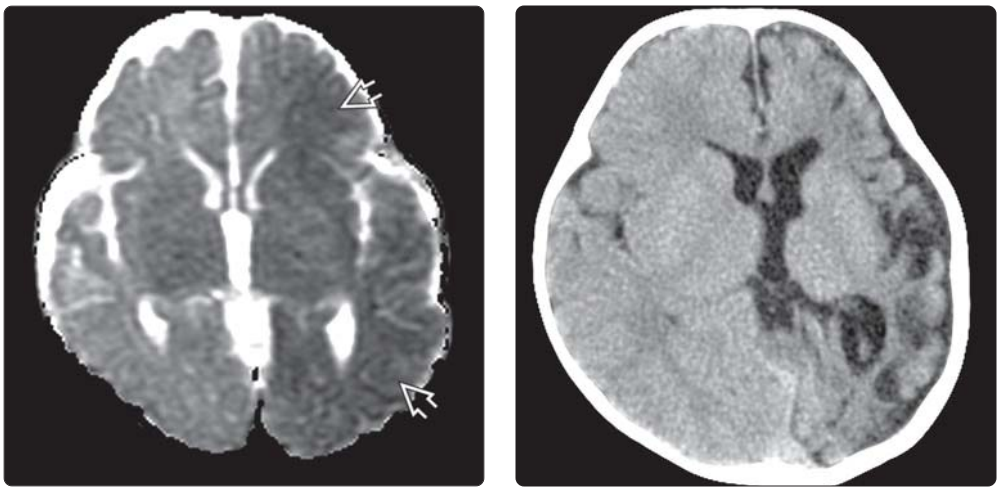

(Left) *Axial ADC map shows extensive left hemispheric decreased ADC ➡ in the same toddler, confirming cytotoxic edema.* **(Right)** *Axial NECT at follow-up shows volume loss of the left hemicranium with compensatory enlargement of the ventricular system secondary to atrophy of the cortex and underlying white matter, particularly posteriorly. Infants with repeated inflicted brain injury are especially prone to excitotoxic injury in the brain underlying SDHs.*

https://CafePezeshki.IR

KEY FACTS

TERMINOLOGY

- Post-traumatic cerebral ischemia (PTCI)
- Hemodynamic alterations induced by traumatic brain injury (TBI)
  - Can be local, regional, generalized perfusion alteration(s)

IMAGING

- Best diagnostic clue: Restricted diffusion
- Most commonly occurs in PCA vascular distribution
  - MCA, ACA, vertebrobasilar relatively common
  - Less common: Perforating, cerebellar arteries
- Best imaging tool: MR + DWI/ADC
  - Diffusion most sensitive sequence
  - Midsagittal imaging to evaluate for herniation

TOP DIFFERENTIAL DIAGNOSES

- Nontraumatic ischemia/infarction
- Vascular (multi-infarct) dementia
- Atherosclerotic occlusion
- Subarachnoid-induced vasospasm

PATHOLOGY

- Primary TBI = direct damage at time of trauma
- Secondary brain injury occurs after initial trauma
  - Due to systemic responses to initial injuries
  - PTCI may be most common cause of secondary brain injury in setting of severe TBI
  - 2° injuries often more devastating than 1° TBI
  - 2° injury can occur after negative initial imaging
- Mechanical shift of brain with herniation across falx &/or tentorium → 80-90% of PTCI

CLINICAL ISSUES

- Most common sign: GCS ≤ 8
- Symptoms often delayed 12-24 hours to several weeks
- PTCI occurs in 1.9-10.4% of craniocerebral trauma
- Ischemic damage present in 90% of fatal TBI deaths

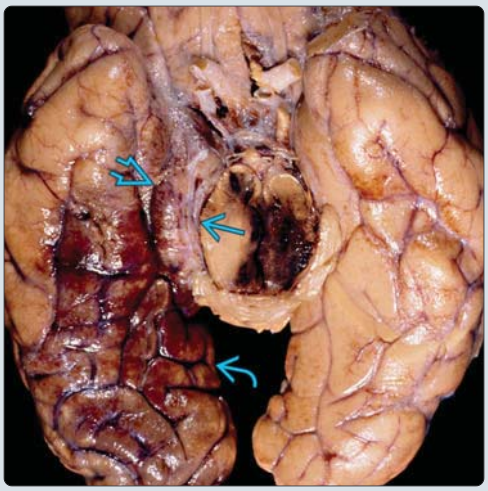

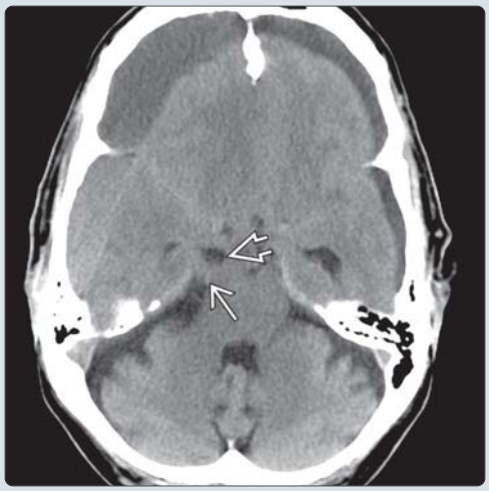

(Left) *Submentovertex view of autopsied brain in a patient with uncal herniation ⇨ and occlusion of the adjacent posterior cerebral artery ⇨ against the tentorium shows a secondary hemorrhagic infarct in the ipsilateral occipital lobe ⇨. (Courtesy R. Hewlett, MD.)* **(Right)** *Axial NECT in a patient with a large mixed-age SDH shows herniation of the right uncus ⇨ and compression of the ipsilateral PCA ⇨.*

(Left) *Lateral DSA shows an inferiorly displaced PCA ⇨ secondary to descending transtentorial herniation of the adjacent temporal lobe. Note the points at which the herniated PCA passes over the edge of the tentorium ⇨. The distal PCA is severely kinked and narrowed ⇨. Worsening herniation will occlude the PCA and result in secondary infarction.* **(Right)** *Axial NECT scan in a patient with severe bifrontal traumatic contusions shows a right PCA infarct ⇨.*

https://CafePezeshki.IR

TERMINOLOGY

Abbreviations

- Post-traumatic cerebral ischemia (PTCI)

Definitions

- Hemodynamic alterations induced by traumatic brain injury (TBI)
  - Can be local, regional, generalized perfusion alteration(s)

IMAGING

General Features

- Best diagnostic clue
  - Restricted diffusion
- Location
  - Most commonly occurs in PCA vascular distribution
    - MCA, ACA, vertebrobasilar relatively common
    - Less common: Perforating arteries, cortical/subcortical, cerebellar

CT Findings

- NECT
  - Initial primary lesions of TBI
    - Hyperdense traumatic subarachnoid hemorrhage, subdural hematoma, &/or epidural hematoma
    - Hypodense contusion, ± dense hemorrhagic foci
    - Diffuse axonal injury
    - Calvarial fractures
  - Subsequent secondary hypodense ischemia
    - Downward transtentorial herniation → PCA occlusion
    - Subfalcine → ACA occlusion
    - Central → basal perforating vessel occlusions
- CT perfusion
  - May reveal changes in CBF, CBV, time to peak, &/or mean transit time

MR Findings

- T1WI
  - Acute ischemia: Hypointense
  - Sagittal best to evaluate for herniation(s)
- T2WI
  - Acute ischemia: Hyperintense
- FLAIR
  - Acute ischemia: Hyperintense
- T2* GRE
  - Best for imaging any hemorrhagic foci
- DWI
  - Restricted diffusion
  - Often multiple; may separate DWI negative moderate TBI from DWI positive severe TBI
- MRA
  - Vessel occlusion, regional hypoperfusion
- MRS
  - TBI: ↓ NAA/Cr & ↑ lactate; persistent abnormalities prognostic
- MR perfusion
  - T2* sensitive echo-planar MR with 1st-pass gadolinium bolus
    - May reveal hypoperfusion changes in relative CBF, CBV, time to peak, &/or mean transit time

Angiographic Findings

- DSA
  - May show vessel displacement, occlusion from herniations
  - ± vasospasm 2º to traumatic SAH

Nuclear Medicine Findings

- SPECT: Tc-99m HMPAO
  - Very sensitive for cortical ischemia
  - Demonstrates high sensitivity and specificity within initial 48 hours for infarction

Imaging Recommendations

- Best imaging tool
  - MR + DWI/ADC
- Protocol advice
  - Diffusion most sensitive sequence
  - Midsagittal imaging to evaluate for herniation

DIFFERENTIAL DIAGNOSIS

Nontraumatic Ischemia/Infarction

- Appears identical; no trauma history

Vascular (Multi-Infarct) Dementia

- Elderly; no trauma history

Atherosclerotic Occlusion

- Elderly; typical location in proximal ICA

SAH-Induced Vasospasm

- Usually in setting of ruptured aneurysm

PATHOLOGY

General Features

- Etiology
  - Motor vehicle accidents most common cause of PTCI
  - Variety of mechanisms account for PTCI
    - Direct vascular compression by mass effects
    - Systemic hypoperfusion
    - Vascular injury, embolization
    - Cerebral vasospasm from traumatic SAH
    - Venous congestion at craniectomy site
  - 2 most common mechanisms
    - Mechanical shift of brain with herniation across falx &/or tentorium → 80-90% of PTCI
    - Result of intracranial space-occupying lesion
  - PTCI relationship with inciting brain injury
    - Primary TBI = direct damage at time of trauma
    - Secondary brain injury occurs after initial trauma
      - Due to systemic responses to initial injuries
      - Most 2° injuries result from ↑ ICP, cerebral herniations
      - 2° injuries often more devastating than those sustained from primary injuries
      - PTCI may be most common cause of secondary brain injury in setting of severe TBI
- Associated abnormalities
  - Intracranial hemorrhages, calvarial fractures, contusions, diffuse axonal injury

https://CafePezeshki.IR

Gross Pathologic & Surgical Features

- Profound global or regional cerebral hypoperfusion occurs in most patients with Glasgow Coma Scores (GCS) ≤ 8
- Specific infarctions (in order of prevalence)
  - PCA: Compression of PCA against rigid tentorial edge from medial temporal lobe herniation
  - ACA: Subfalcine herniation of cingulate gyrus compresses 1 or both ACAs &/or their branches
  - MCA: Gross herniation or severe cerebral edema
  - Lenticulostriate, thalamoperforating arteries
    - Compression of perforating arteries against skull base
    - Gross mass effects also stretching/attenuation of these small perforating vessels
  - Cortical/subcortical: Direct compression from overlying masses; 2 mechanisms
    - Direct pressure effects limit arterial flow
    - Local venous drainage compression occurs
    - Both often result in hemorrhagic infarcts
  - Superior cerebellar artery
    - Ascending or descending transtentorial herniation compresses artery against tentorium
  - PICA: Compression of artery from tonsillar herniation

Microscopic Features

- Blood-brain barrier disruption with vasogenic edema
- Excitatory amino acids induce cellular swelling → cytotoxic edema
- Overproduction of free radicals and apoptosis
- Neurotransmitter release, metabolic perturbation, and membrane depolarization → ion dysfunction
  - PTCI impedes return of ion homeostasis, contributing to development of ↑ ICP
- Inflammatory processes → massive astrocytic activation with leukocyte accumulation and capillary vessel compression → microvascular occlusion

CLINICAL ISSUES

Presentation

- Most common signs/symptoms
  - Most common sign: GCS ≤ 8
  - No reliable clinical findings indicate presence of traumatic cerebral ischemia
  - Neurological signs from brain injury obscure focal findings that may be from secondary ischemia
- Clinical profile
  - Symptoms often delayed 12-24 hours to several weeks
  - Varies greatly with type of injury

Demographics

- Age
  - Children:adults = 2:1 (aged 15-24 at highest risk)
- Gender
  - M:F = 2:1
- Epidemiology
  - TBI: Leading cause of death and disability in children and adults
  - 2 million traumatic brain injuries annually in USA
  - Survivors incur annual cost of > $40 billion (~ 0.5% of GNP)
  - TBI causes ~ 50,000 deaths and 235,000 hospitalizations annually in USA
  - PTCI occurs in 1.9-10.4% of craniocerebral trauma
  - Ischemic damage present in 90% of fatal TBI deaths

Natural History & Prognosis

- Poor prognosis: Presence of subdural hematoma, brain swelling/edema, traumatic SAH
- Good prognosis: Patients with none or only 1 poor prognostic factor
- Presence of blunt cerebral vascular injury and treatment with factor VIIa are risk factors for developing PTCI
- Outcome: 50% die or are left in persistent vegetative state

Treatment

- Treatment of comorbidities: Herniation, hemorrhage(s), hydrocephalus, seizures
- Cerebral perfusion **must** be monitored to detect secondary cerebral ischemia following TBI
- Herniation &/or diffuse swelling may require craniectomy

DIAGNOSTIC CHECKLIST

Consider

- Cause of ischemia

Image Interpretation Pearls

- Secondary brain injury can occur after negative primary radiologic evaluation
- May occur hours to days or even weeks after admission

SELECTED REFERENCES

1. Wang WH et al: Risk factors for post-traumatic massive cerebral infarction secondary to space-occupying epidural hematoma. J Neurotrauma. 31(16):1444-50, 2014
2. Paiva WS et al: Occlusion of the anterior cerebral artery after head trauma. World J Radiol. 5(5):226-8, 2013
3. Tawil I et al: Posttraumatic cerebral infarction: incidence, outcome, and risk factors. J Trauma. 64(4):849-53, 2008

https://CafePezeshki.IR

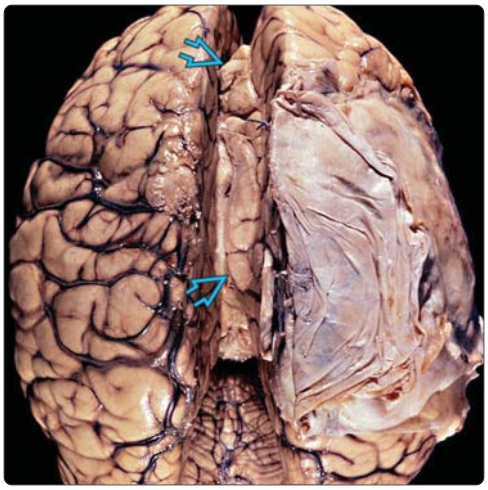

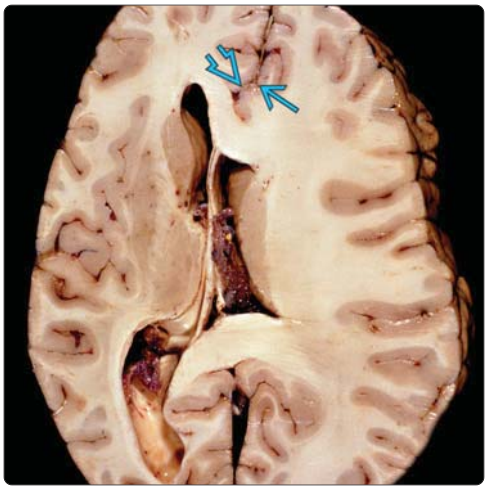

(Left) *Axial autopsy shows severe herniation of the medial cerebral hemisphere under the falx cerebri ⇨. This herniation can cause secondary ACA occlusion.* **(Right)** *Axial autopsy of severe subfalcine herniation shows cingulate gyrus herniation ⇨. The accompanying ACA can be compressed against the inferior falx ⇨, causing a secondary distal ACA infarct.*

(Left) *Axial NECT shows severe subfalcine herniation caused by a malignant left MCA infarction ⇨. Note hypodensity in the cingulate gyrus ⇨.* **(Right)** *More cephalad axial NECT in the same case again shows the left MCA infarct ⇨. The distal cingulate gyrus infarction ⇨ is caused by the severe subfalcine herniation.*

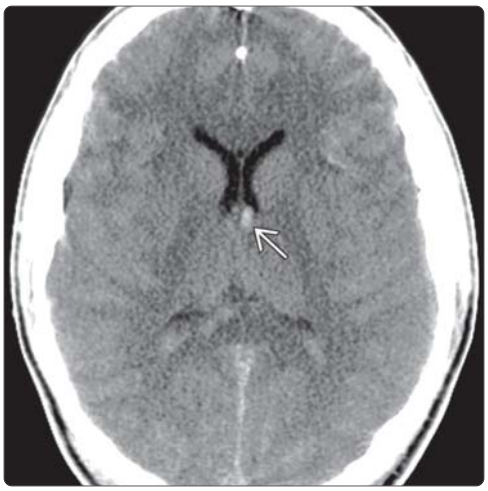

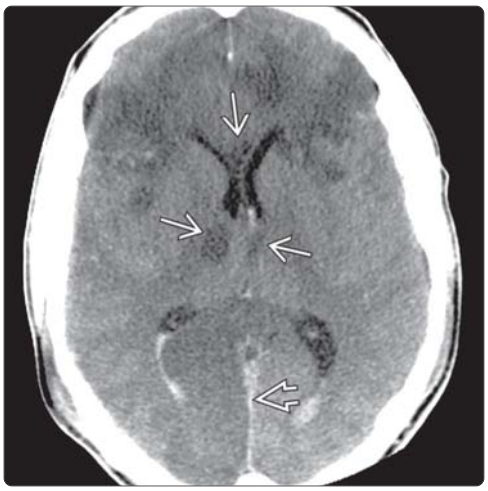

(Left) *Axial NECT in a patient involved in a high-speed MVA shows hemorrhage in the left fornix ⇨ and diffuse brain swelling with sulcal obliteration.* **(Right)** *Follow-up scan in the same case 1 week later shows a right PCA infarct ⇨ and multiple hypodensities ⇨ in the basal ganglia and corpus callosum genu caused by central herniation, compression of multiple perforating arteries against the skull base.*

https://CafePezeshki.IR

KEY FACTS

TERMINOLOGY

- Brain death (BD); death by neurological criteria (DNC)
- Complete, irreversible cessation of brain function

IMAGING

- No flow in intracranial arteries or venous sinuses
  - No intravascular enhancement on CT or MR
  - "Light bulb" sign on radionuclide study
- Diffuse cerebral edema
  - Gyri swollen, ventricles/cisterns compressed
  - Gray-white matter borders effaced

TOP DIFFERENTIAL DIAGNOSES

- Reversible diffuse cerebral edema
  - Drug overdose
  - Status epilepticus (clinically can mimic BD)
  - Acute metabolic dysfunction (e.g., fulminant hepatic failure)
- Technical difficulty
  - Missed bolus (nuclear study, CTA)
  - Dissection (catheter angiography)
  - Vasospasm (catheter angiography)
- Massive cerebral infarction/edema

PATHOLOGY

- Severe cell swelling, ↑ intracranial pressure (ICP)

CLINICAL ISSUES

- Complex assessment, often misunderstood by nonspecialists and families
  - DNC highly reliable with
    - Experienced examiners
    - Using established criteria
- Imaging may confirm but does not substitute for clinical criteria
- Reversible causes of coma must be excluded
- Remember: BD is primarily clinical diagnosis, legal criteria vary

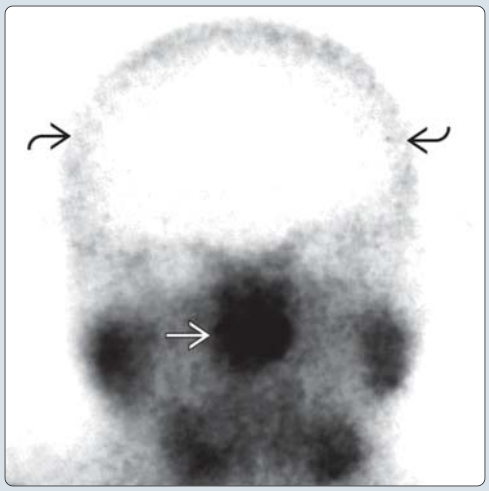

(Left) *Axial NECT shows complete loss of gray-white matter differentiation and diffuse sulcal and gyral effacement in this patient with diffuse cerebral edema and clinical brain death. The lateral ventricles are also effaced posteriorly* ➡. **(Right)** *Anteroposterior Tc-99m HMPAO scan shows the classic "light bulb"* ⇨ *and "hot nose" signs* ➡ *related to lack of intracerebral blood flow in brain death. No radionuclide is seen in the intracranial arteries or veins. (Courtesy B. Vomocil, MD.)*

(Left) *Antemortem axial T2WI in a 50-year-old woman with CBD obtained just before death shows small ventricles and swollen gyri with near-complete obliteration of the surface sulci.* **(Right)** *Submentovertex MIP of MRA in the same patient shows flow only in extracranial branches of the external carotid arteries* ➡. *No flow is present in the intracranial vasculature.*

https://CafePezeshki.IR

TERMINOLOGY

Abbreviations

- Brain death (BD); death by neurological criteria (DNC)

Definitions

- Complete, irreversible cessation of brain function

IMAGING

General Features

- Best diagnostic clue
  - No flow in intracranial arteries or venous sinuses on Tc-99m ECD (Neurolite)
- Imaging may confirm but does not substitute for clinical criteria

CT Findings

- NECT
  - Diffuse cerebral edema (GM-WM borders effaced)
    - White cerebellum sign (sometimes called cerebellar "reversal" sign with density of cerebellum >> hemispheres)
    - Pseudosubarachnoid appearance due to venous congestion in effaced sulci
  - Swollen gyri; compressed ventricles/cisterns
- CTA
  - Useful confirmatory or add-on test for BD
  - Does not replace neurological testing
  - No intravascular enhancement

MR Findings

- T1WI
  - Hypointense, swollen cortex ± gray-white matter differentiation lost
  - Sulci, cisterns obliterated
- T2WI
  - Cortex hyperintense, gyri swollen
- T2* GRE
  - Cortical, medullary veins hypointense
    - Stagnant flow with deoxyhemoglobin
- DWI
  - Hemispheric high signal, severe ADC drop

Angiographic Findings

- Conventional
  - No intracranial flow
  - Contrast stasis (ECA fills, supraclinoid ICA does not)

Nuclear Medicine Findings

- Tc-99m-labeled exametazime scintigraphy
  - Absent intracranial uptake ("light bulb" sign)
  - Increased extracranial activity ("hot nose" sign)

Imaging Recommendations

- Best imaging tool
  - EEG plus bedside scintigraphy (Neurolite)

DIFFERENTIAL DIAGNOSIS

Reversible Diffuse Cerebral Edema

- Drug overdose
- Status epilepticus (clinically can mimic BD)
- Acute metabolic dysfunction (e.g., fulminant hepatic failure)

Technical Difficulty

- Missed bolus (Nuclear study, CTA)
- Dissection (catheter angiography)
- Vasospasm (catheter angiography)

Massive Cerebral Infarction/Edema

- "Malignant" MCA infarct can mimic BD

PATHOLOGY

General Features

- Etiology
  - Severe cell swelling, ↑ intracranial pressure (ICP)
  - Markedly elevated ICP, ↓ cerebral blood flow
    - If ICP > end-diastolic pressure in cerebral arteries, diastolic reversal occurs
    - If ICP > systolic pressure, blood flow ceases

Gross Pathologic & Surgical Features

- Markedly swollen brain with severely compressed sulci
- Bilateral descending transtentorial herniation
  - Downward displacement of diencephalon
  - "Grooving" of temporal lobes by tentorial incisura

CLINICAL ISSUES

Presentation

- Most common signs/symptoms
  - Profound coma (GCS = 3) with "known cause"
  - Reversible causes of coma must be excluded
- Clinical profile
  - Complex assessment, often misunderstood by nonspecialists and families
    - DNC highly reliable with experienced examiners using established criteria
  - Brain death is primarily a clinical diagnosis; legal criteria vary
  - Ancillary studies help confirm clinical diagnosis

SELECTED REFERENCES

1. Burkle CM et al: Why brain death is considered death and why there should be no confusion. Neurology. 83(16):1464-9, 2014
2. Flamm AL et al: Family members' requests to extend physiologic support after declaration of brain death: a case series analysis and proposed guidelines for clinical management. J Clin Ethics. 25(3):222-37, 2014
3. Shemie SD et al: International guideline development for the determination of death. Intensive Care Med. 40(6):788-97, 2014
4. Taylor T et al: Computed tomography (CT) angiography for confirmation of the clinical diagnosis of brain death. Cochrane Database Syst Rev. 3:CD009694, 2014
5. Spinello IM: Brain Death Determination. J Intensive Care Med. ePub, 2013
6. Wijdicks EF et al: Evidence-based guideline update: determining brain death in adults: report of the Quality Standards Subcommittee of the American Academy of Neurology. Neurology. 74(23):1911-8, 2010
7. Wijman CA et al: Prognostic value of brain diffusion-weighted imaging after cardiac arrest. Ann Neurol. 65(4):394-402, 2009

https://CafePezeshki.IR

KEY FACTS

TERMINOLOGY

- Dysautoregulation/second impact syndrome
- Repeated head trauma within "window of vulnerability" before brain recovers from initial concussive injury
- Can result in catastrophic brain swelling with permanent disability or death

IMAGING

- Thin, acute subdural hematoma (aSDH)
  - Disproportionate mass effect
    - Degree of midline (subfalcine) shift more than accounted for by thickness of aSDH
- Swollen, hypodense cerebral hemisphere under aSDH
  - Underlying sulci compressed, then obliterated
- Best imaging tools
  - NECT as initial screening
  - MR with T2*, DWI

TOP DIFFERENTIAL DIAGNOSES

- Acute subdural hematoma (without underlying dysautoregulation)
- Nonaccidental trauma (child abuse)

PATHOLOGY

- Thin subdural hematoma
- Underlying brain swollen, hyperemic
  - ± secondary infarcts
  - ± uncal, central, tonsillar herniations

CLINICAL ISSUES

- Severe headache
- Vomiting
- May have dramatic, sudden collapse, coma
- Most common in
  - Adolescent males involved in high-impact sports
  - Abused infants
  - Elderly patients with repeated falls, head impacts

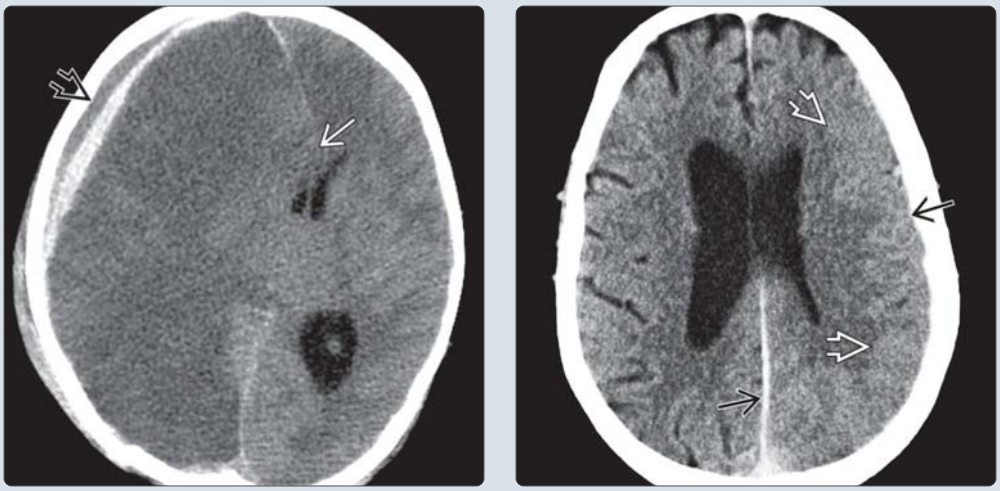

(Left) *Axial NECT in an abused infant with repeated inflicted head trauma shows a mixed-density right SDH. The underlying right hemisphere is diffusely swollen and hypodense. Note disproportionate mass effect, subfalcine herniation compared to relatively thin SDH.* **(Right)** *Axial NECT in an elderly patient with repeated falls and head trauma shows a thin aSDH. Underlying cortex is swollen with disproportionate mass effect on left lateral ventricle.*

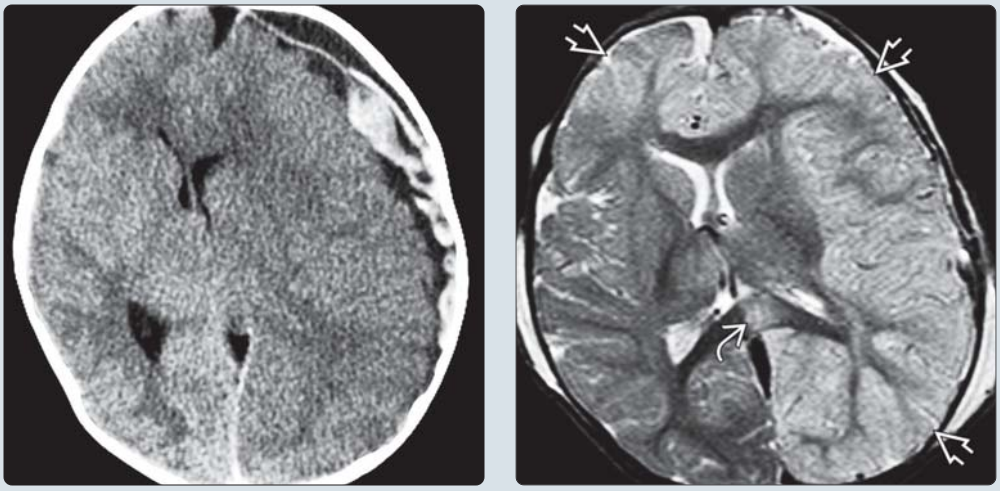

(Left) *Axial NECT in an abused infant shows mixed acute, subacute/chronic SDH overlying a swollen, hypodense hemisphere.* **(Right)** *Axial fat-suppressed T2WI in the same case two days later, after evacuation of the SDH, shows swollen hyperintense cortex underlying bilateral SDHs. Note hyperintensity in the corpus callosum splenium. Findings are consistent with excitotoxic injury.*

https://CafePezeshki.IR

TERMINOLOGY

Abbreviations

- Second impact syndrome (SIS)

Synonyms

- Dysautoregulation

Definitions

- Repeated head trauma within "window of vulnerability" before brain recovers from initial concussive injury
- Can result in catastrophic brain swelling with permanent disability or death

IMAGING

General Features

- Best diagnostic clue
  - Thin, acute subdural hematoma (aSDH)
  - Disproportionate mass effect
    - More midline shift than can be attributed to aSDH
    - Swelling of ipsilateral cerebral hemisphere
  - Brain swelling may be sudden, catastrophic

CT Findings

- NECT
  - Small, thin aSDH (usually ≤ 0.5 cm)
    - Crescent-shaped, hyper- or mixed-density aSDH
      - May have hypodense foci if actively bleeding
  - Mass effect disproportionate to size of aSDH
    - Degree of midline (subfalcine) shift more than accounted for by thickness of aSDH
  - Swollen, hypodense cerebral hemisphere under aSDH
    - Underlying sulci compressed, then obliterated
    - Gray-white matter initially preserved
    - Unilateral (uncal) descending transtentorial herniation
  - Progressive brain swelling → basal cisterns effaced
    - Complete central herniation
    - Midbrain distorted, compressed inferiorly

MR Findings

- T1WI
  - aSDH iso-/mixed intensity
  - Underlying cortex swollen, hypointense
- T2WI
  - Gyri swollen, hyperintense
  - Underlying sulci compressed
- FLAIR
  - Cortex hyperintense
- T2* GRE
  - Usually negative for intraparenchymal hemorrhage
- DWI
  - Gyri show restricted diffusion
- MRS
  - Decreased NAA

Imaging Recommendations

- Best imaging tool
  - NECT as initial screening
- Protocol advice
  - MR with T2*, DWI

DIFFERENTIAL DIAGNOSIS

Acute Subdural Hematoma (Without Underlying Dysautoregulation)

- Mass effect, midline shift proportionate to width of aSDH
- Usually no history of repetitive head injury

Nonaccidental Trauma (Child Abuse)

- Repeated injuries with mixed acute, subacute SDHs
- If underlying brain swelling is disproportionate to SDH size
  - Swelling of subjacent brain may be sudden, catastrophic
  - May represent a type of SIS with dysautoregulation

PATHOLOGY

General Features

- Etiology
  - Previous head injury opens "window of vulnerability"
    - If second injury (impact) before brain heals completely, SIS may result
  - Loss of autoregulation of CBF → vascular engorgement → ↑ ICP → brain herniation
    - May represent excitotoxic brain injury with increased release, leakage, or decreased reuptake of glutamate

Gross Pathologic & Surgical Features

- Thin subdural hematoma
- Underlying brain swollen, hyperemic
  - ± secondary infarcts
  - ± uncal, central, tonsillar herniations

CLINICAL ISSUES

Presentation

- Most common signs/symptoms
  - Severe headache
  - Vomiting
  - Variable consciousness
  - May have dramatic, sudden collapse, coma

Demographics

- Most common: Adolescent males involved in high-impact sports
- Other
  - Abused infants
  - Elderly patients with repeated falls, head impacts

Natural History & Prognosis

- Generally poor

SELECTED REFERENCES

1. McKee AC et al: The neuropathology of sport. Acta Neuropathol. 127(1):29-51, 2014
2. Harmon KG et al: American Medical Society for Sports Medicine position statement: concussion in sport. Br J Sports Med. 47(1):15-26, 2013
3. Weinstein E et al: Second impact syndrome in football: new imaging and insights into a rare and devastating condition. J Neurosurg Pediatr. 11(3):331-4, 2013
4. Cantu RC et al: Second-impact syndrome and a small subdural hematoma: an uncommon catastrophic result of repetitive head injury with a characteristic imaging appearance. J Neurotrauma. 27(9):1557-64, 2010
5. Wetjen NM et al: Second impact syndrome: concussion and second injury brain complications. J Am Coll Surg. 211(4):553-7, 2010

https://CafePezeshki.IR

KEY FACTS

TERMINOLOGY

- Dissection
  - Intramural hematoma extends along vessel wall
- Dissecting aneurysm
  - Dissection + aneurysmal dilation contained by adventitia
- Pseudoaneurysm
  - Lumen contained by thrombus outside vessel wall

IMAGING

- Location
  - Often adjacent to falx, skull, tentorium, or region of significant motion
  - Posterior circulation most common
    - Vertebral arteries most common site (72%)
    - Extension into basilar artery rare
  - Anterior circulation uncommon
    - Supraclinoid internal carotid artery
    - Distal, more peripheral (A2, M2, P2, and beyond) where vessel contacts dura or skull
- NECT: Basal subarachnoid hemorrhage
  - Looks like aneurysmal SAH
  - In unusual locations, more extensive than tSAH
- MR: Hyperintense hematoma + central "flow void"
  - "Target" or "crescent" sign
- CTA/MRA/DSA
  - Enlarged vessel due to dissecting aneurysm or mural thrombus
  - Long segment narrowing or tapered occlusion
  - Intraluminal flap (± on DSA/MRA; best seen on DSA)
  - ± dissecting aneurysm (irregular, wide-neck; at side wall, usually not at vessel bifurcations)

TOP DIFFERENTIAL DIAGNOSES

- Atherosclerosis
- Vasospasm
- Vasculitis
- Fibromuscular dysplasia (FMD)

(Left) *Axial NECT scan in a 29-year-old female involved in a high-speed MVA shows SAH ⇨ surrounding the lower medulla.* **(Right)** *More cephalad NECT scan in the same patient shows extensive SAH filling the basal cisterns, outlining the midbrain. Note the enlargement of the temporal horns ⇨ indicating early extraventricular obstructive hydrocephalus.*

(Left) *Slightly oblique lateral DSA in the same patient shows focal fusiform enlargement of the left vertebral artery ⇨ suggesting a dissecting pseudoaneurysm may be the etiology for the subarachnoid hemorrhage.* **(Right)** *Oblique 3D color shaded surface display in the same patient shows the focal right dissecting aneurysm ⇨ as well as a 2nd dissecting aneurysm along the distal right vertebral artery ⇨. The patient had a cardiac arrest after the DSA and expired.*

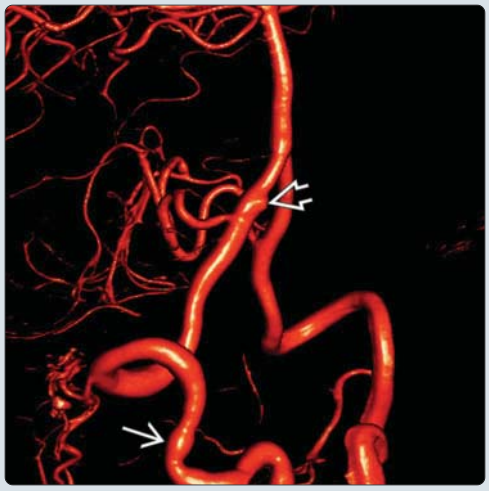

https://CafePezeshki.IR

TERMINOLOGY

Synonyms

- Traumatic dissection and pseudoaneurysm

Definitions

- Dissection: Intramural hematoma extends along vessel wall
- Intimal extension
  - Intimal flap
  - True and false lumen
- Arterial transection
  - Extension through adventitia
- Dissecting aneurysm: Aneurysmal dilation of vessel due to dissection, contained only by adventitia
  - Hematoma between media/adventitia common
- Pseudoaneurysm: Lumen contained only by thrombus outside vessel wall

IMAGING

General Features

- Best diagnostic clue
  - NECT: Basal extensive subarachnoid hemorrhage (SAH) mimics aneurysmal SAH, but often more extensive than traumatic SAH or in unusual locations
  - MR: Hyperintense crescent in vessel wall with central or eccentric flow void on axial T1WI and T2WI ("target" or "crescent" sign)
    - Subarachnoid hyperintensity on FLAIR due to hemorrhage
    - Enlarged vessel due to dissecting aneurysm or mural thrombus
  - MRA, CTA, DSA
    - Long segment narrowing or tapered occlusion
    - Intraluminal flap on MRA/CTA source images
    - ± irregular, eccentric side wall dissecting aneurysm
      - Usually not at bifurcation
- Location
  - Often occurs at contact points with falx, skull, tentorium, or at region of significant motion
  - Posterior circulation most common
    - Vertebral arteries most common (72%)
    - Posterior inferior cerebellar artery (PICA) occurs, but less common
    - Extension into basilar artery rare
  - Anterior circulation uncommon
    - Supraclinoid internal carotid artery
    - Otherwise, more peripheral (A2, M2, P2, and beyond)
      - Usually where vessel contacts dura or skull
- Morphology
  - Tapered stenosis with occlusion
  - Irregular vessel narrowing
  - Fusiform irregular dilatation or focal dissecting aneurysm
  - Intimal flap and double (true and false) lumen
  - Intramural hematoma

CT Findings

- NECT
  - Basal SAH mimics aneurysmal SAH but is more extensive than typical traumatic SAH
    - Atypical SAH located in upper interhemispheric fissure, along tentorium
  - Acute embolic infarct
    - Hypodensity in vascular distribution
    - Hemorrhagic conversion, gyral hyperdensity
  - Basal skull fracture in some cases
- CTA
  - Tapered narrowing &/or occlusion
  - False lumen and flap visible in minority of cases
  - CTA source images show intraluminal flap and vessel wall thickening
  - Irregular dissecting aneurysm: Fusiform or wide-neck

MR Findings

- T1WI
  - Acute thrombus within vessel may be hypointense on T1WI
  - Subacute = hyperintense crescentic intramural hematoma
  - Absent or decreased flow void
- T2WI
  - "Target" or "crescent" sign: Central or eccentric intraluminal flow void surrounded by hyperintense dot in vessel wall
  - Acute infarct hyperintense
    - ± hemorrhagic conversion (hypointense on T2WI, T2*)
- FLAIR
  - Hyperintense CSF: SAH
  - Hyperintense acute infarct
- DWI
  - Hyperintensity in acute infarct
- MRA
  - Amorphous mild hyperintensity in wall of vessel (intramural hematoma) partially surrounds more marked flow-related hyperintensity but may obscure detail
    - PC MRA may better characterize lumen
  - Decreased flow may be manifested by decreased caliber and intensity of lumen of vessels distal to dissection, especially on 3D TOF

Angiographic Findings

- Conventional
  - Tapered narrowing or occlusion
  - Irregular lumen or intimal flap
  - Focal aneurysmal dilatation is usually wide-neck, irregular, triangular in shape, occurring in unusual locations
  - Embolic occlusion of distal branches

Imaging Recommendations

- Best imaging tool: MR and MRA
- Protocol advice
  - Initial NECT important to assess for SAH
  - MR/MRA → CTA if MRA equivocal
  - Conventional angiography indicated when clinical suspicion is high, but MR/MRA is negative, &/or for therapeutic intervention

https://CafePezeshki.IR

DIFFERENTIAL DIAGNOSIS

Atherosclerosis

- Luminal irregularity and stenosis most marked in cavernous carotid artery, vertebral and basilar arteries
  - No aneurysmal dilatation
- Focal and eccentric when involves pial branches
- Mural calcification on NECT, CTA, or MRA source images

Vasospasm

- Smooth narrowing usually centered at vessel bifurcation
- Most severe where SAH is greatest
- No aneurysmal dilatations

Vasculitis

- Short or long segment smooth narrowing not centered on vessel bifurcations
- Regions of narrowing alternate with normal vessel lumen or mild aneurysmal dilatation
- Isolated aneurysmal dilatation less common

Fibromuscular Dysplasia (FMD)

- Rarely intracranial, virtually always in association with extracranial involvement
  - Internal carotid artery opposite C2 in 2/3 of cases
- Alternating zones of focal narrowing and aneurysmal dilatation
  - Corrugated pipe appearance
- Long segment stenosis or aneurysmal dilatation
- May be cause of spontaneous dissection
  - Visualization of vessel wall on MR needed to differentiate between FMD and dissection ± FMD
  - FMD produces focal vessel wall thickening without hemorrhage or calcification

Spontaneous (Nontraumatic) Basal SAH

- Ruptured aneurysm
- Benign perimesencephalic SAH

PATHOLOGY

General Features

- Etiology
  - Skull base fracture
  - Direct injury to intracranial vessel from contact with falx, tentorium, skull
  - Vulnerability of intracranial vertebral artery to longitudinal extension
    - Stretching from hyperextension or rotational neck movement
  - Shearing type injury at motion segments: Supraclinoid ICA, MCAs
  - Minor injury often overlooked in history
- Associated abnormalities
  - Fibromuscular dysplasia, arterial fenestrations
  - Collagen disorders, rheumatoid arthritis
  - Metabolic/genetic disorders: Angiolipomatosis, Marfan, α-1-antitrypsin deficiency

CLINICAL ISSUES

Presentation

- Most common signs/symptoms
  - Headache, obtundation, CN3 palsy

Demographics

- Epidemiology
  - 1.5-10% of SAH

Natural History & Prognosis

- If vessel patent, may resolve spontaneously
- Acute emboli is common complication in acute phase
- Rupture is very common with dissecting aneurysm or pseudoaneurysm

Treatment

- Anticoagulation to prevent progressive thrombosis and embolization with distal infarction
- Angioplasty and stent treatment for severely stenotic lesion
- Endovascular occlusion usually of parent vessel or stent/coils or stent graft without adequate collaterals
- Surgical occlusion, wrapping, or bypass

DIAGNOSTIC CHECKLIST

Consider

- Dissection when young patient presents with acute "spontaneous" infarction
  - Inquire about mild trauma or falls in 24 hours prior to onset of symptoms
- Dissecting aneurysm at unusual locations: Pericallosal, distal MCA, distal PCA, not at branch points

Image Interpretation Pearls

- Look for "target" sign in internal carotid or vertebral artery on images at or just below skull base

SELECTED REFERENCES

1. Kansagra AP et al: Current trends in endovascular management of traumatic cerebrovascular injury. J Neurointerv Surg. 6(1):47-50, 2014
2. Prasad V et al: Pipeline endovascular reconstruction of traumatic dissecting aneurysms of the intracranial internal carotid artery. J Neurointerv Surg. 6(10):e48, 2014
3. Ro A et al: Pathomorphological differentiation between traumatic rupture and nontraumatic arterial dissection of the intracranial vertebral artery. Leg Med (Tokyo). 16(3):121-7, 2014
4. Rahme RJ et al: Spontaneous cervical and cerebral arterial dissections: diagnosis and management. Neuroimaging Clin N Am. 23(4):661-71, 2013
5. Cohen JE et al: Single-center experience on endovascular reconstruction of traumatic internal carotid artery dissections. J Trauma Acute Care Surg. 72(1):216-21, 2012
6. Santos-Franco JA et al: Dissecting aneurysms of the vertebrobasilar system. A comprehensive review on natural history and treatment options. Neurosurg Rev. 31(2):131-40; discussion 140, 2008
7. Chen CJ et al: Multisection CT angiography compared with catheter angiography in diagnosing vertebral artery dissection. AJNR Am J Neuroradiol. 25(5):769-74, 2004

https://CafePezeshki.IR

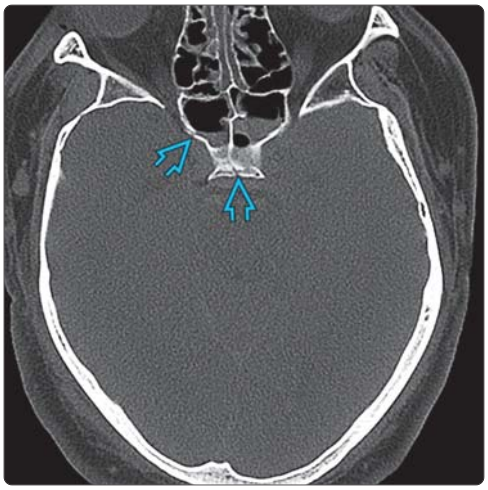

(Left) *Axial NECT scan in a 19-year-old male involved in a high speed MVA shows diffuse subarachnoid blood in the basal cisterns ➡. No other traumatic injuries were present.* **(Right)** *Axial NECT with bone algorithm in the same patient shows fluid in the sphenoid sinuses with basilar skull fractures ⇨.*

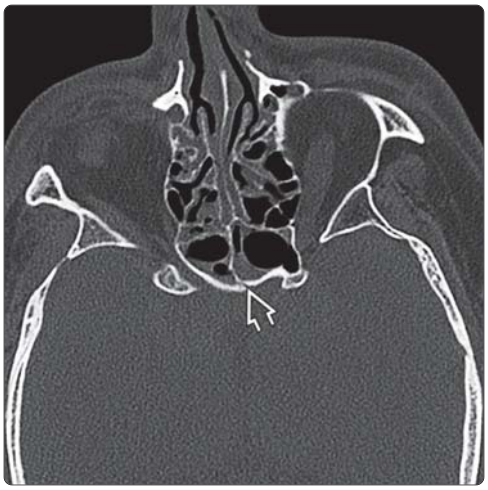

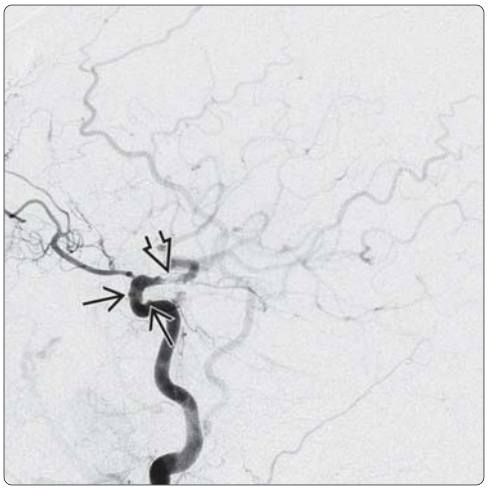

(Left) *Facial bone CT in the same patient shows another fracture crossing the sphenoid bone ➡.* **(Right)** *Because of the SAH and basilar skull fractures, a DSA was performed to evaluate for vascular injury. The cavernous ICA shows several irregular outpouchings ⇨ consistent with tiny traumatic pseudoaneurysms. The supraclinoid ICA is narrowed, irregular, and filled with thrombus ⇨.*

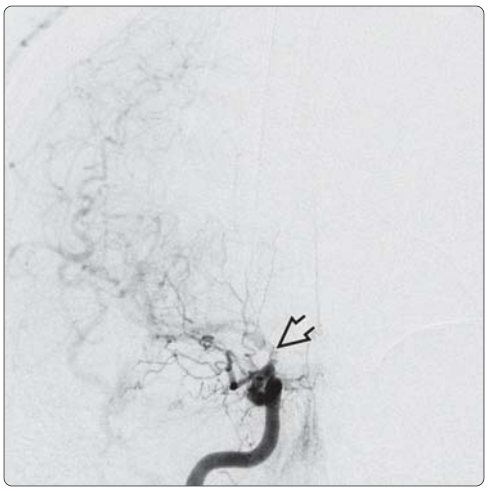

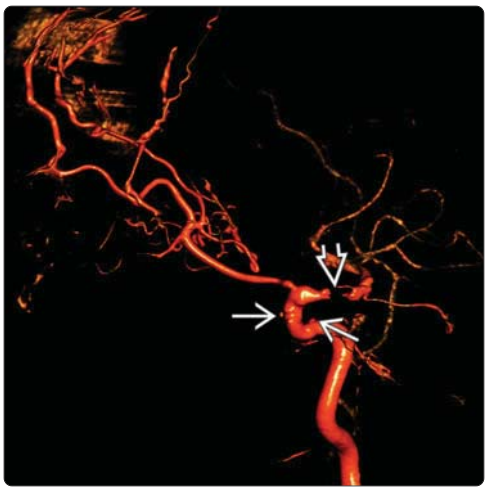

(Left) *AP view of the DSA shows the partially opacified, irregular, thrombus-filled supraclinoid ICA ⇨.* **(Right)** *Lateral DSA with shaded surface displace shows the cavernous ICA outpouchings ➡ and the irregular, severely narrowed supraclinoid ICA ➡. Multiple traumatic pseudoaneurysms with supraclinoid ICA dissection.*

https://CafePezeshki.IR

KEY FACTS

TERMINOLOGY

- Direct carotid cavernous fistula (CCF), high-flow CCF
- Single-hole tear/transection of cavernous internal carotid artery (ICA) with arteriovenous shunt into cavernous sinus (CS)

IMAGING

- General features
  - Proptosis, dilated superior ophthalmic vein (SOV) and CS, extraocular muscle (EOM) enlargement
  - Skull base fracture involving sphenoid bone/carotid canal ↑ likelihood of ICA injury
- MRA: ↑ flow-related signal in CS and SOV
- CT/CTA may be suggestive; should proceed to DSA to confirm and treat
- DSA is definitive
  - Early filling of CS + outflow pathways including retrograde filling of SOV, angular + facial veins
  - Reduced or absent antegrade flow in ICA beyond fistula, depending on size of ICA tear

TOP DIFFERENTIAL DIAGNOSES

- Indirect CCF
  - Low-flow CCF, CS dural arteriovenous fistula (dAVF)

CLINICAL ISSUES

- Bruit, pulsating exophthalmos, orbital edema/erythema, ↓ vision, glaucoma, headache
- Hemispheric ischemia if ↓ flow in ICA beyond CCF
- Focal deficits → cranial nerves 3-6
- Endovascular treatment options include
  - Transarterial-transfistula balloon embolization
  - Transvenous embolization
  - Pipeline/covered stent placement
  - ICA sacrifice

(Left) *Coronal graphic depicts a carotid cavernous fistula (CCF). The right cavernous sinus ⇨ is enlarged by numerous dilated arterial and venous channels.* **(Right)** *CECT scan shows classic findings of CCF. The right cavernous sinus ⇨ is enlarged and the ipsilateral superior ophthalmic vein ⇨ is more than 4x the size of the left superior ophthalmic vein ⇨.*

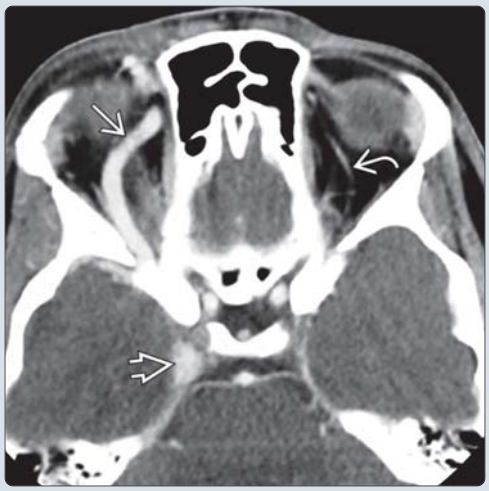

(Left) *T2WI shows typical MR findings of CCF with an enlarged right cavernous sinus ⇨ containing numerous abnormal "flow voids" ⇨.* **(Right)** *Lateral DSA in CCF shows opacification of the cavernous sinus in the arterial phase. Also outlined are many of the venous outflow pathways of the cavernous sinus, including the superior ophthalmic veins ⇨, superior and inferior petrosal sinuses ⇨, and pterygoid and pharyngeal venous plexi ⇨.*

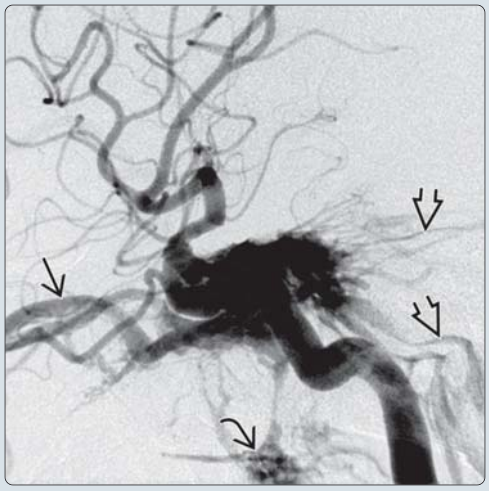

https://CafePezeshki.IR

TERMINOLOGY

Abbreviations

- Carotid cavernous fistula (CCF)

Synonyms

- Direct CCF, high-flow CCF

Definitions

- Single-hole tear/transection of cavernous internal carotid artery (ICA) with arteriovenous shunt into cavernous sinus (CS)

IMAGING

General Features

- Best diagnostic clue
  - Proptosis, dilated superior ophthalmic vein (SOV) and CS, extraocular muscle (EOM) enlargement

CT Findings

- NECT
  - Skull base fracture involving sphenoid bone/carotid canal ↑ likelihood of ICA injury
  - Proptosis, enlarged SOV, CS, and EOMs
    - "Dirty" orbital fat secondary to edema
  - Subarachnoid hemorrhage (SAH) from associated trauma or arterialized flow into cortical veins
- CECT
  - Dilated SOV and CS
  - ↑ enhancement of EOMs, patchy enhancement of intraorbital fat

MR Findings

- T1WI C+
  - Same as CECT
- MRA
  - ↑ flow-related signal in CS and SOV
  - Signal loss in ICA secondary to turbulent flow

Ultrasonographic Findings

- Doppler: Reversal of flow in dilated SOV (intra- to extracranial)

Angiographic Findings

- Conventional
  - Early filling of CS + outflow pathways including
    - Retrograde filling of SOV, angular + facial veins
    - Contralateral CS
    - Petrosal sinuses → internal jugular vein(s)
  - Reduced or absent antegrade flow in ICA beyond fistula depending on size of ICA tear

Imaging Recommendations

- Best imaging tool
  - DSA is definitive
  - CT/CTA may be suggestive: Should proceed to DSA to confirm and treat
- Protocol advice
  - DSA: Magnification, high frame rate to visualize exact site of shunt
  - CTA: Thin-section scans with reformations

DIFFERENTIAL DIAGNOSIS

Indirect CCF

- a.k.a. low-flow CCF, CS dural arteriovenous fistula (dAVF)

EOM Enlargement

- Graves ophthalmopathy
- Inflammatory pseudotumor, neoplasm

PATHOLOGY

General Features

- Etiology
  - Skull base fracture with bony fragment injuring ICA
  - Stretch injury of vessel wall between fixed points at foramen lacerum and anterior clinoid process
- Associated abnormalities
  - Arterialized flow in CS with retrograde venous reflux
    - Superior/inferior ophthalmic veins → proptosis, chemosis, ↑ intraocular pressure → ↓ retinal perfusion pressure → blindness
    - Cortical veins → increased SAH risk
  - Reduced antegrade flow in ICA beyond fistula → hemispheric ischemia

CLINICAL ISSUES

Presentation

- Most common signs/symptoms
  - May present days to weeks post trauma
  - Bruit, pulsating exophthalmos, orbital edema/erythema, ↓ vision, glaucoma, headache
  - Hemispheric ischemia if ↓ flow in ICA beyond CCF
  - Severe/rapid vision loss, SAH → emergency
  - Focal deficits → cranial nerves 3-6

Natural History & Prognosis

- Endovascular options include
  - Transarterial-transfistula detachable balloon embolization
  - Transvenous embolization
  - Pipeline stent across ICA tear
  - ICA sacrifice with coils or detachable balloons (if patient tolerates lack of antegrade flow beyond fistula or passes balloon test occlusion)

DIAGNOSTIC CHECKLIST

Image Interpretation Pearls

- Enlarged SOV and CS, proptosis, intraorbital edema

Reporting Tips

- CT/MR may be suggestive, but DSA is required for definitive diagnosis and treatment

SELECTED REFERENCES

1. Chi CT et al: Direct traumatic carotid cavernous fistula: angiographic classification and treatment strategies. Study of 172 cases. Interv Neuroradiol. 20(4):461-75, 2014
2. Aralasmak A et al: Venous drainage patterns in carotid cavernous fistulas. ISRN Radiol. 2014:760267, 2014

https://CafePezeshki.IR

KEY FACTS

TERMINOLOGY

- Definition
  - Neurodegenerative disease 2º to repetitive concussive/subconcussive head injuries
- Abbreviations
  - Chronic traumatic encephalopathy (CTE)
- Synonyms
  - Dementia pugilistica ("punch-drunk")
  - Postconcussion syndrome

IMAGING

- MR
  - Age-inappropriate volume loss
    - Voxel-based morphometry shows disproportionate involvement of medial temporal lobes
  - Nonspecific T2/FLAIR punctate, confluent hyperintensities in deep, periventricular WM
  - DTI shows reduced FA, increased MD with loss of WM integrity
    - Uncinate and superior/inferior longitudinal fasciculi
  - T2* shows microbleeds in ~ 10%
- PET
  - Temporoparietal hypometabolism on FDG-PET
  - PET imaging ligands for phosphorylated tau may be in vivo biomarker

PATHOLOGY

- Etiology
  - Repetitive head trauma
  - Contact sports (football, soccer, hockey, boxing, wrestling, mixed martial arts, etc.)
  - Battlefield exposure to blast waves generated by IEDs
- Gross: Likened to octogenarian Alzheimer patient
- Microscopic: Neurofibrillary tangles, Aβ plaques

CLINICAL ISSUES

- Cognitive dysfunction, memory loss
- Variable mood, personality, behavior disorders

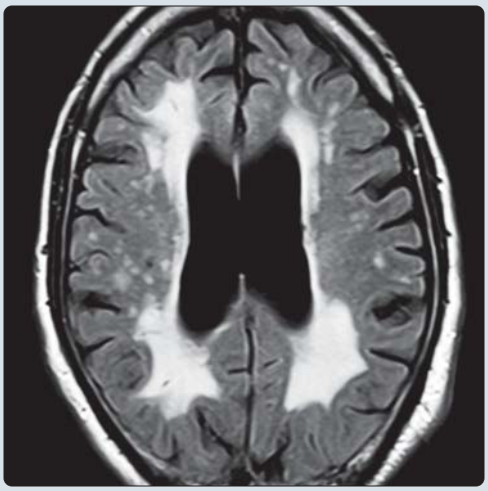

(Left) *Axial FLAIR scan in a middle-aged former professional athlete with early-onset dementia shows diffuse bihemispheric volume loss with extensive confluent and punctate hyperintensities in the subcortical and deep cerebral white matter (WM).* **(Right)** *Axial T2* SWI scan in the same patient shows numerous punctate "blooming" foci in the subcortical and deep WM ⇨, consistent with microbleeds in this case of clinically diagnosed chronic traumatic encephalopathy (CTE).*

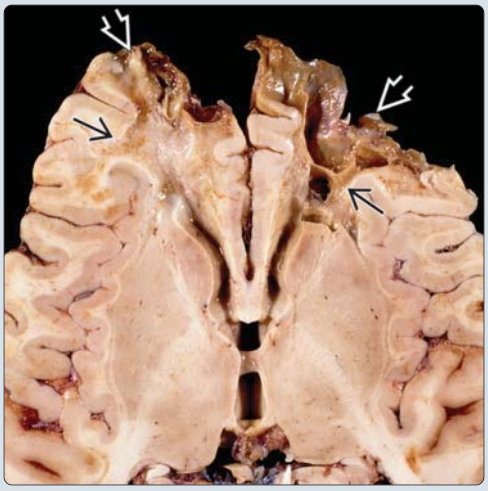

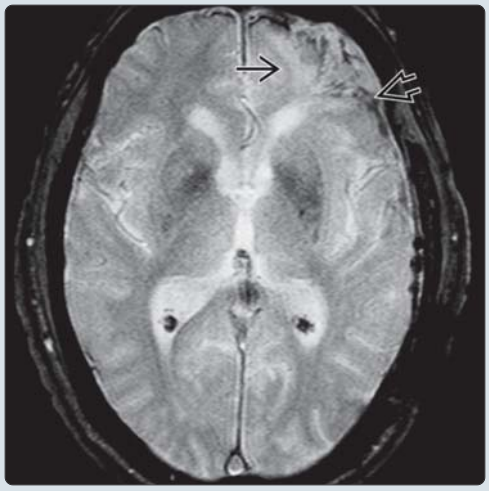

(Left) *Autopsy in a patient who survived a single episode of severe head injury shows remote effects of head trauma. Note the bifrontal encephalomalacia ⇨ and extensive gliosis in the subcortical WM ⇨. Note absence of microbleeds.* **(Right)** *Axial T2* GRE in an elderly patient with a single episode of moderate head trauma shows left frontal encephalomalacia and gliosis ⇨ with superficial siderosis of the adjacent cortex ⇨. Note the absence of microbleeds in this case.*

https://CafePezeshki.IR

TERMINOLOGY

Abbreviations

- Chronic traumatic encephalopathy (CTE)

Synonyms

- Dementia pugilistica
  - Old term originally applied to boxer's dementia
- "Punch-drunk" syndrome
- Postconcussion syndrome

Definitions

- Neurodegenerative disease induced by repetitive concussive and subconcussive head injuries

IMAGING

General Features

- Best diagnostic clue
  - Variable age-inappropriate volume loss
    - Ventricular volume ↑
    - Progressive, continues beyond initial injury
  - Findings resemble Alzheimer dementia
- Location
  - Generalized atrophy but especially medial temporal lobes (hippocampus, amygdala, uncus)

CT Findings

- Volume loss with increased ventricle to brain ratio

MR Findings

- T1WI
  - Age-inappropriate volume loss
    - Generalized increase in ventricles, sulci
  - Voxel-based morphometry shows disproportionate involvement of medial temporal lobes
- T2WI
  - Nonspecific punctate, confluent hyperintensities in deep, periventricular WM
- FLAIR
  - Nonspecific punctate, confluent hyperintensities in deep, periventricular WM
- T2* GRE
  - Microbleeds in ~ 10% of CTE cases
  - SWI shows susceptibility foci in subcortical, deep WM
- DWI
  - Reduced FA, increased MD with loss of WM integrity
    - Uncinate and superior/inferior longitudinal fasciculi
    - Fornix
    - Cingulum
    - Hippocampus

Nuclear Medicine Findings

- Temporoparietal hypometabolism in PET
- May show signs of persistent chronic neuroinflammation
- PET imaging ligands for phosphorylated tau may be in vivo biomarker

Imaging Recommendations

- Best imaging tool
  - 3T MR with SWI, voxel-based morphometry

DIFFERENTIAL DIAGNOSIS

Normal Aging Brain

- Mild increase in ventricle to brain ratio
- Generalized volume loss (not disproportionate medial temporal lobes)
- Few to no "blooming black dots" on T2* (GRE or SWI)

Alzheimer Disease

- Both AD, CTE show accumulation of tau aggregates
  - CTE more superficial cortical layers, around deep sulci
- May be indistinguishable from CTE on standard imaging studies

PATHOLOGY

General Features

- Etiology
  - Repetitive head trauma
    - Contact sports (football, soccer, hockey, boxing, wrestling, mixed martial arts, etc.)
    - Battlefield exposure to blast waves generated by IEDs
  - Tauopathy
    - Coexisting Aβ pathology common
  - Long-term sequelae
    - Excitotoxicity
    - Apoptosis
    - Inflammation
    - Demyelination and WM pathology

Gross Pathologic & Surgical Features

- Likened to octogenarian Alzheimer patient
- Frontotemporal volume loss
  - Associational neocortex involvement common
- Cavum septi pellucidi often torn or septated

Microscopic Features

- Neurofibrillary tangles
- Aβ plaques
- Diffuse neuronal loss

CLINICAL ISSUES

Presentation

- Most common signs/symptoms
  - Cognitive dysfunction, memory loss
  - Impaired executive function
  - Variable mood, personality, behavior disorders
  - Paranoia, panic attacks

SELECTED REFERENCES

1. Bramlett H et al: Long-Term Consequences of Traumatic Brain Injury: Current Status of Potential Mechanisms of Injury and Neurologic Outcomes. J Neurotrauma. ePub, 2014
2. Sundman MH et al: Examining the relationship between head trauma and neurodegenerative disease: A review of epidemiology, pathology and neuroimaging techniques. J Alzheimers Dis Parkinsonism. 4, 2014
3. Saigal R et al: The Long-term Effects of Repetitive Mild Head Injuries in Sports. Neurosurgery. 75 Suppl 4:S149-55, 2014

https://CafePezeshki.IR

This page intentionally left blank

https://CafePezeshki.IR

PART I
SECTION 3

Subarachnoid Hemorrhage and Aneurysms

Subarachnoid Hemorrhage & Aneurysms Overview 218

Subarachnoid Hemorrhage

Aneurysmal Subarachnoid Hemorrhage 220
Perimesencephalic Nonaneurysmal SAH 224
Convexal Subarachnoid Hemorrhage 226
Superficial Siderosis 228

Aneurysms

Saccular Aneurysm 232
Pseudoaneurysm 236
Vertebrobasilar Dolichoectasia 238
ASVD Fusiform Aneurysm 240
Non-ASVD Fusiform Aneurysm 242
Blood Blister-Like Aneurysm 244

https://CafePezeshki.IR

Subarachnoid Hemorrhage

Overview: The subarachnoid spaces (SASs) are CSF-filled spaces between the arachnoid (on the outside) and the pia (on the inside). Focal expansions of the SASs at the base of the brain and around the brainstem, tentorial incisura, and foramen magnum form the brain cisterns.

The SASs are anatomically unique as they surround the entire brain, spinal cord, and spinal nerve roots and contain all the major brain arteries and cortical veins.

Acute extravasation of blood into the CSF spaces between the arachnoid membrane and pia can be caused by arterial leaks or torn veins. Blood can also extend into the SASs from parenchymal hemorrhage that ruptures through the cortex and pia, spilling into the adjacent SAS.

Trauma, "burst" aneurysm, vascular malformations, and amyloid angiopathy are potential causes of subarachnoid hemorrhage (SAH). The most common cause of SAH is trauma. Traumatic subarachnoid hemorrhage (tSAH) occurs when hemorrhage from contused brain or lacerated cortical vessels extends into sulci adjacent to the injury.

Aneurysmal subarachnoid hemorrhage (aSAH): nontraumatic "spontaneous" SAH represents about 5% of all acute "strokes." The most common cause of nontraumatic SAH is a ruptured intracranial saccular ("berry") aneurysm (aSAH). Because most saccular aneurysms are located either on the circle of Willis or at the middle cerebral artery bifurcation, the most common locations for aSAH are the suprasellar cistern and sylvian fissures.

Aneurysmal SAH can be focal or diffuse. Attempts to determine the precise anatomic location of a suspected intracranial aneurysm based on the distribution of SAH are necessarily imprecise. Anterior interhemispheric aSAH is typically associated with rupture of a superiorly directed ACoA aneurysm. aSAH seen primarily in the posterior fossa cisterns &/or 4th ventricle suggests a PICA aneurysm. MCA bi- or trifurcation aneurysm may cause focal hemorrhage in the adjacent sylvian fissure.

Perimesencephalic nonaneurysmal subarachnoid hemorrhage (pnSAH): An uncommon but important cause of SAH, pnSAH is a clinically benign variant that is probably venous in origin. pnSAH is confined to the cisterns around the midbrain and anterior to the pons.

Convexal subarachnoid hemorrhage (cSAH): An uncommon subset of nontraumatic SAH occurs over the dorsolateral surface ("convexity") of the cerebral hemispheres. The basal and perimesencephalic cisterns are typically spared. cSAH typically affects just one sulcus or a grouping of adjacent sulci. Common etiologies in older adults are amyloid angiopathy or vasculitis while vasculitis and reversible cerebral vasoconstriction syndrome are common causes in patients < 60 years old. Cortical vein occlusion with cSAH occurs at all ages.

Superficial siderosis (SS): Chronic, recurrent SAH results in hemosiderin deposition on the pia and cranial nerves. The brain, brainstem, cerebellum, and spinal cord can all be affected, although the posterior fossa is most commonly involved.

The classic clinical presentation of SS is in an adult with a history of trauma or surgery, who presents with ataxia and bilateral sensorineural hearing loss. A history of aSAH is uncommon. SS is best identified on T2* (GRE or SWI).

Aneurysms and Arterial Ectasias

Terminology and overview: The word "aneurysm" comes from the combination of 2 Greek words meaning "across" and "broad." Hence, brain arterial aneurysms are widenings or dilatations of intracranial arteries.

Intracranial aneurysms are generally classified by their phenotypic appearance. Saccular or "berry" aneurysms are the most common type. Fusiform aneurysms are focal dilatations that involve the entire circumference of a vessel and extend for relatively short distances. Ectasias refer to generalized arterial enlargement without focal dilatation and are not true aneurysms.

Saccular aneurysm: As the name implies, saccular aneurysms (SAs) are focal sac- or berry-like arterial dilatations. The vast majority are acquired lesions, the result of an underlying genetically based susceptibility plus superimposed mechanical stresses on vessel walls. SAs lack the 2 strongest layers of blood vessel walls, the internal elastic lamina and the muscular layer. The aneurysm sac itself consists of only intima and adventitia.

Most SAs arise at major blood vessel bifurcations, where hemodynamic stresses are highest. The vast majority of intracranial aneurysms are located on the circle of Willis plus the middle cerebral artery bi- or trifurcation. 90% are "anterior circulation" aneurysms, i.e., on the internal carotid artery and its branches. The posterior communicating artery is considered part of the anterior circulation; the vertebrobasilar artery and branches constitute the "posterior circulation."

Pseudoaneurysm: Pseudoaneurysms (PAs) are focal arterial dilatations not contained by layers of the normal arterial wall. They are often irregularly shaped and generally arise on vessels distal to the circle of Willis.

A pseudoaneurysm develops when a completely disrupted blood vessel hemorrhages. A paravascular hematoma forms and then cavitates, establishing a communication with the parent vessel wall. The wall of a PA thus consists only of organized clot. Pseudoaneurysms are much less common than either SAs or fusiform aneurysms. PAs are acquired lesions caused by trauma, infection or inflammation ("mycotic" aneurysm), drug abuse, and neoplasm ("oncotic" aneurysm).

Blood blister-like aneurysm: Blood blister-like aneurysms (BBAs) are eccentric hemispherical outpouchings that can develop at any location. Most commonly found on the greater curvature of the supraclinoid internal carotid artery, they are lined only by a thin layer of adventitia. They are difficult to detect, difficult to treat, and prone to rupture at smaller size and younger age than typical saccular aneurysms.

Fusiform aneurysms: Fusiform aneurysms can be atherosclerotic (common) or nonatherosclerotic (rare). They involve long, nonbranching vessel segments and are seen as more focal circumferential outpouchings from an ectatic vessel. Fusiform aneurysms are more common in the vertebrobasilar (posterior) circulation.

Vertebrobasilar dolichoectasia: Fusiform enlargement or ectasia, also called arteriectasis, is commonly seen in patients with advanced atherosclerotic disease. Less commonly, fusiform ectasias occur with collagen-vascular disorders and non-ASVD arteriopathies.

https://CafePezeshki.IR

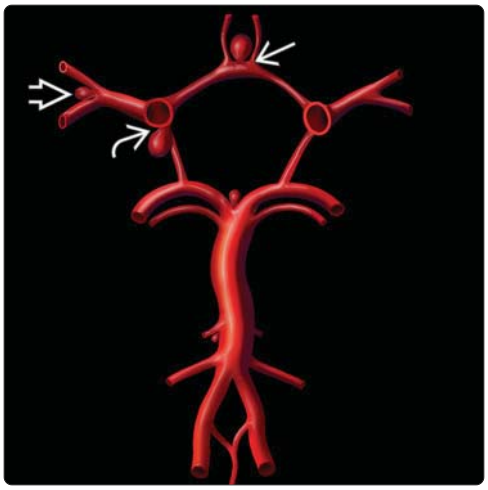

(Left) *Diagram depicts the circle of Willis with relative prevalence of intracranial saccular aneurysms. Most are "anterior circulation" with 1/3 occurring on the ACoA ⇨ and 1/3 at the internal carotid/PCoA junction ⇨. 15-20% are found at the MCA bi- or trifurcation ⇨. Only 10% occur on the "posterior circulation."* **(Right)** *Circle of Willis dissected from an autopsied brain shows a classic unruptured IC-PCoA saccular aneurysm ⇨. (Courtesy B. Horten, MD.)*

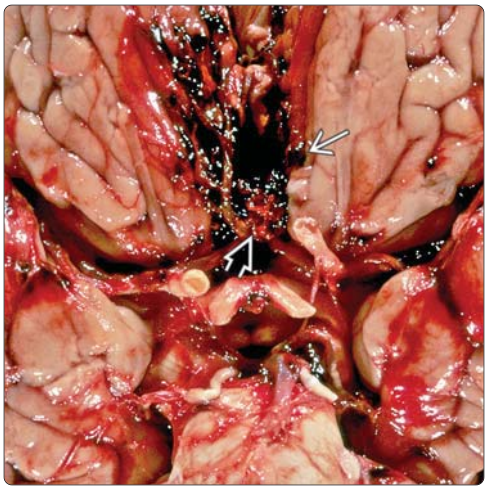

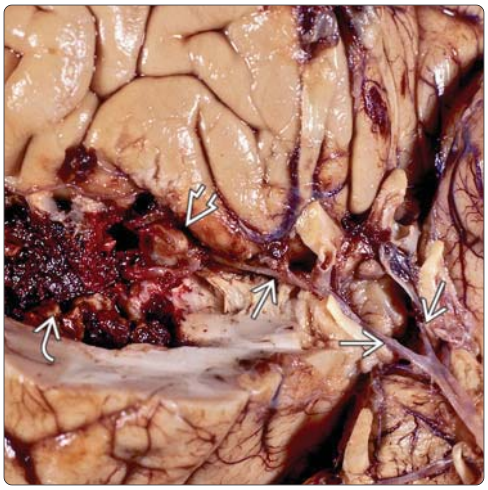

(Left) *Autopsied brain shows a small ruptured ACoA aneurysm ⇨ with extensive focal clot in the interhemispheric fissure ⇨. Diffuse SAH is also present. (Courtesy B. Horten, MD.)* **(Right)** *This patient died of cerebral ischemia several days after rupture of a saccular MCA aneurysm ⇨, which is surrounded by clot in the sylvian fissure ⇨. Note the extreme narrowing of the M1 MCA segment and both posterior cerebral arteries, indicative of severe vasospasm ⇨. (Courtesy R. Hewlett, MD.)*

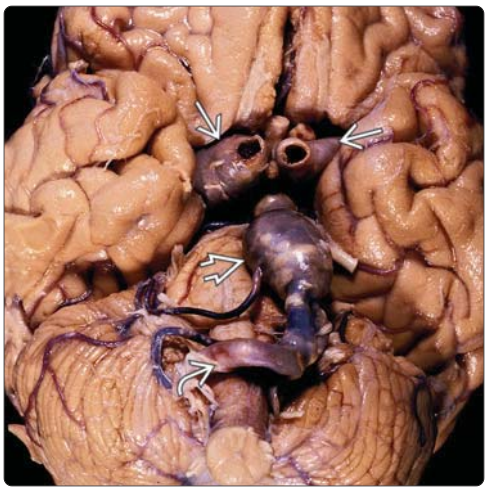

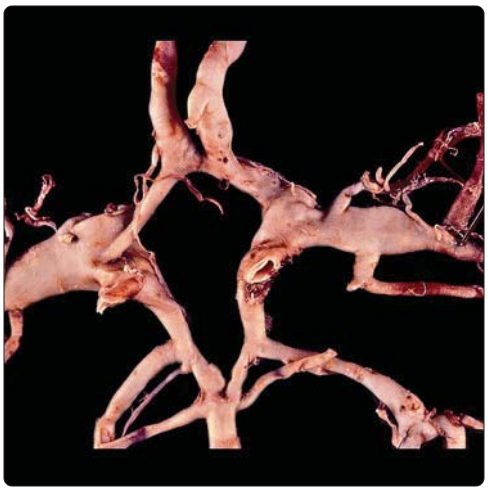

(Left) *Gross pathology shows atherosclerotic fusiform ectasias of the vertebrobasilar system ⇨, as well as both internal carotid arteries and M1 MCA segments ⇨. Focal enlargement of the basilar artery represents a fusiform aneurysm ⇨ caused by ASVD. (Courtesy R. Hewlett, MD.)* **(Right)** *Nonatherosclerotic fusiform ectasias of the M1, A1, A2, and PCoAs are seen in a patient with HIV-associated vasculopathy. (Courtesy L. Rourke, MD.)*

https://CafePezeshki.IR

KEY FACTS

TERMINOLOGY

- SAH caused by ruptured aneurysm (aSAH)
  - Saccular (SA) > > dissecting aneurysm (DA)

IMAGING

- CT/CTA
  - Hyperdense sulci on NECT
  - Distribution varies with aneurysm location
  - Suprasellar cistern (IC-PCoA, ACoA aneurysms)
  - Sylvian fissure (middle cerebral artery [MCA] bifurcation)
  - Prepontine, CPA cisterns (posterior inferior cerebellar artery [PICA], BA bifurcation SA or vertebral DA)
  - CTA 90-95% positive if aneurysm ≥ 2 mm
- MR/MRA
  - FLAIR hyperintense sulci, cisterns (nonspecific)
  - "Blooms" on T2* GRE
  - TOF MRA 85-95% sensitive for aneurysms ≥ 3 mm
- DSA
  - Used if CTA negative
  - If endovascular treatment is option

TOP DIFFERENTIAL DIAGNOSES

- Nonaneurysmal SAH
- "Pseudo-SAH"
- Reversible cerebral vasoconstriction syndrome (RCVS)

CLINICAL ISSUES

- Sudden onset severe headache
  - "Thunderclap/worst headache of life"
- 50% mortality
  - Vasospasm 1-3 weeks post aSAH
- 20% rebleed within 1st 2 weeks
- Treatment
  - Coil embolization ("coiling") generally > clipping

DIAGNOSTIC CHECKLIST

- Diffuse low-density brain makes normal arteries look hyperdense, can mimic aSAH

(Left) *Axial graphic through the midbrain depicts SAH in red throughout the basal cisterns. Given the diffuse distribution of SAH without focal hematoma, statistically the most likely location of the ruptured aneurysm is the ACoA.* **(Right)** *Axial NECT scan in a 63-year-old man found down in a parking lot shows diffuse SAH ➡ throughout the basal cisterns. Note the enlargement of both temporal horns of the lateral ventricles ➡ consistent with early extraventricular obstructive hydrocephalus.*

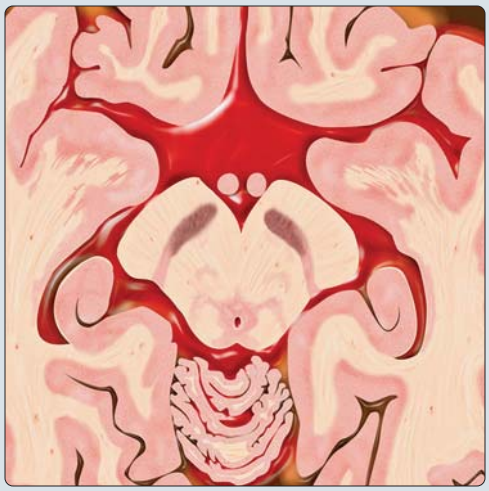

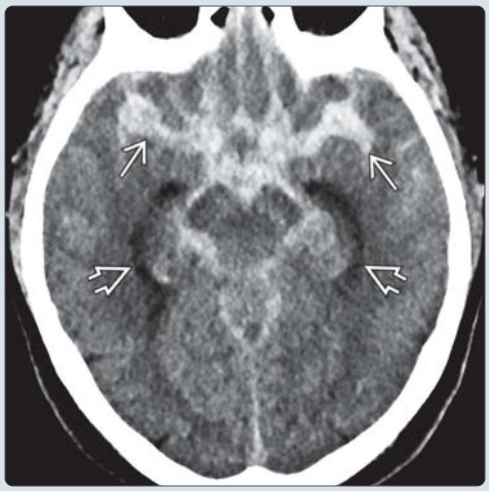

(Left) *Coronal MIP image of the CTA obtained in the same patient shows a saccular aneurysm ➡ projecting superiorly from the anterior communicating artery.* **(Right)** *Coronal shaded surface display of the DSA obtained in the same patient nicely demonstrates the "culprit" aneurysm ➡. The lesion was successfully coiled after this diagnostic DSA was performed.*

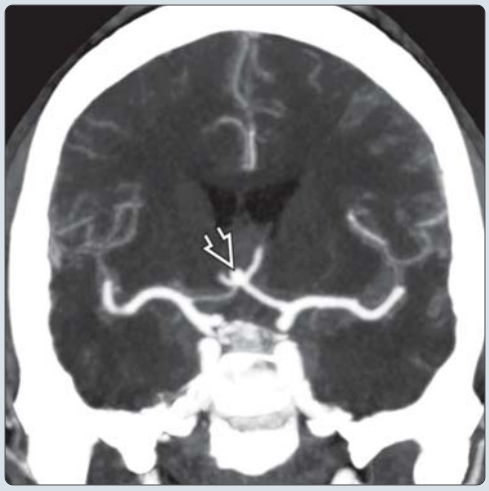

https://CafePezeshki.IR

TERMINOLOGY

Abbreviations

- Aneurysmal subarachnoid hemorrhage (aSAH)

Definitions

- Extravasation of blood into subarachnoid space
  - Usually from ruptured saccular aneurysm
  - Less common: Intracranial dissection, dissecting aneurysm

IMAGING

General Features

- Best diagnostic clue
  - Hyperdense basal cisterns, sulci on NECT
- Location
  - Suprasellar, basal, sylvian, interhemispheric cisterns
    - ± intraventricular hemorrhage (IVH)
  - aSAH distribution depends on location of saccular aneurysm (SA)
    - aSAH highest near site of rupture
      - Anterior communicating artery (ACoA) aneurysm → anterior interhemispheric fissure
      - Middle cerebral artery (MCA) aneurysm → sylvian fissure
      - Basilar tip, superior cerebellar artery (SCA), posterior inferior cerebellar artery (PICA) SA, or vertebral artery (VA) dissecting aneurysm (DA) → prepontine cistern, foramen magnum, 4th ventricle
    - "Culprit" aneurysm sometimes seen as filling defect within hyperdense aSAH
  - SAs typically located at bifurcation points along intradural ICA, circle of Willis (COW), MCA
    - 90% located on anterior circulation: ACoA, posterior communicating artery (PCoA), MCA, carotid terminus, carotid-ophthalmic, superior hypophyseal
    - 10% on posterior circulation: Basilar tip, PICA, anterior inferior cerebellar artery (AICA), SCA
  - DAs: Intradural V4 VA segment most common
  - Blood blister aneurysm (BBA)
    - Dorsal supraclinoid ICA
    - Rarely MCA, basilar artery

CT Findings

- NECT
  - 95% positive in first 24 hours, < 50% by 1 week
  - "Effaced" sylvian fissure if subacute, filled with isodense SAH
  - Hydrocephalus common, may occur early
  - ± intraparenchymal hemorrhage at site of ruptured aneurysm
- CTA
  - 90-95% positive if aneurysm ≥ 2 mm

MR Findings

- T1WI
  - Acute aSAH is isointense to CSF
  - CSF may appear mildly hyperintense ("dirty")
- T2WI
  - Difficult to see on T2WI (hyperintense)
- FLAIR
  - Hyperintense
    - More sensitive than CT but less specific
- T2* GRE
  - Striking sulcal "blooming"
- DWI
  - May see foci of restricted diffusion if vasospasm
- MRA
  - TOF MRA 85-95% sensitive for aneurysms ≥ 3 mm

Angiographic Findings

- CTA has high sensitivity, specificity for detecting ruptured aneurysm(s)
  - Best in initial diagnosis of SAH, patient triage
- Conventional 4-vessel angiogram still gold standard
  - Must image
    - Both ICA circulations
    - Both VAs or dominant VA + reflux to contralateral PICA
  - SA
    - Saccular outpouching at arterial branch point
    - Look for Murphy teat = site of rupture
    - Look for additional aneurysms (20% multiple)
      - If > 1 aneurysm, then biggest, most irregular ± adjacent vasospasm is likely source of bleed
  - DA
    - Irregular ± dilated or stenotic V4 segment of VA
  - BBA
    - Smooth/irregular bleb/dome-shaped outpouching
    - Not associated with major vessel branch point
    - Most common along supraclinoid ICA
  - DSA negative in 15% of aSAH; repeat positive < 5%
    - Evaluate ECAs (to exclude dural AV fistula [dAVF])
    - SA may not be seen on initial DSA if optimal projection not obtained, spontaneous partial or complete aneurysm thrombosis, &/or presence of vasospasm
    - Consider repeating DSA in 5-7 days

Imaging Recommendations

- Best imaging tool
  - NECT + multiplanar CTA
- Protocol advice
  - Proceed to DSA if NECT consistent with aSAH but CTA negative
  - Consider MR if DSA + CTA negative
  - Likelihood of aneurysm in patient who is CT negative, LP positive, CTA negative is low

DIFFERENTIAL DIAGNOSIS

Nonaneurysmal SAH

- Perimesencephalic SAH
  - Small SAH, localized to interpeduncular cistern
  - Presumed venous etiology with low recurrence rate
- Traumatic subarachnoid hemorrhage
  - Adjacent to contusions, subdural hematomas
  - Rarely from intracranial dissection or rupture of traumatic pseudoaneurysm
- Subarachnoid hemorrhage, NOS
  - Vascular malformation: Arteriovenous malformation (AVM), cavernous hemangioma

https://CafePezeshki.IR

Reversible Cerebral Vasoconstriction Syndrome (RCVS)

- Clinical: "Thunderclap" headache
- SAH typically in cortical sulci vs. basal cisterns with aSAH

"Pseudo-SAH"

- Hypodense brain: Severe cerebral edema
- Hyperdense CSF: Intrathecal contrast; meningitis

PATHOLOGY

General Features

- Etiology
  - Saccular aneurysms
    - Berry aneurysms: Congenital deficiency of internal elastic lamina and tunica media at arterial branch points → focal vessel wall weakness
      - ↑ risk: Familial intracranial aneurysms (5% of cases), adult polycystic kidney disease, aortic coarctation
    - May be related to high-flow arteriopathy along feeding vessel of AVM or, less commonly, dAVF
    - ↑ aneurysm rupture risk if female, smoker, HTN
  - Fusiform aneurysms
    - Dissection from trauma, hypertension, ASVD
    - Underlying arteriopathy including fibromuscular dysplasia (FMD), Marfan, Ehlers-Danlos, infection
    - Mycotic
  - Blood-blister aneurysm: All layers absent (contained in fibrous cap)
- Associated abnormalities
  - Vasospasm
    - Caused by blood breakdown products, apolipoprotein-E genotype, endothelin-1 release from CSF leukocytes
    - 70% develop angiographic evidence of vasospasm
    - 30% have clinically apparent vasospasm
    - Starts ~ day 3-4 post SAH; peaks ~ 7-9 days, lasts ~ 12-16 days
  - Cerebral salt-wasting syndrome
    - Excessive renal Na+ excretion → hyponatremia, hypovolemia
  - Terson syndrome
    - Intraocular (retinal, vitreous) hemorrhage associated with SAH secondary to rapid ↑ intracranial pressure

Staging, Grading, & Classification

- Clinical grading: Hunt and Hess (H&H) grade 0-5
  - 0: No SAH (unruptured aneurysm)
  - 1: No symptoms, minimal headache, slight nuchal rigidity
  - 2: Moderate to severe headache, nuchal rigidity
    - No neurologic deficit except CN palsy
  - 3: Drowsy, minimal neurologic deficit
  - 4: Stuporous, moderate/severe hemiparesis
  - 5: Coma, decerebrate rigidity, moribund appearance
- Fisher CT grading
  - 1: No SAH visible
  - 2: Diffuse, thin layer (< 1 mm)
  - 3: Localized clot or thick layer (> 1 mm)
  - 4: Intraventricular blood

Gross Pathologic & Surgical Features

- Blood in basal cisterns, sulci, and ventricles

CLINICAL ISSUES

Presentation

- Most common signs/symptoms
  - Sudden "thunderclap/worst headache of life"
  - 10% preceded by "sentinel hemorrhage" = self-limiting SAH + headache in preceding days/weeks

Demographics

- Age
  - Peak = 40-60 years
- Gender
  - M:F = 1:2
- Epidemiology
  - Aneurysms cause 85% of spontaneous SAHs
  - Incidence ~ 9.9 per 100,000 population

Natural History & Prognosis

- 50% mortality; 20% rebleed within first 2 weeks
- Clinical outcome inversely proportional to initial H&H or WFNS grade
- Vasospasm + ischemia → delayed morbidity, mortality
  - Severity correlates with amount of SAH (Fisher CT grade); inverse correlation with patient age
- 90% hydrocephalus at presentation
  - ~ 10% require permanent CSF diversion

Treatment

- Ruptured aneurysm
  - Coil embolization ("coiling"), if anatomy favorable
    - Lower rates of acute adverse events; long-term, all cause morbidity
  - Microneurosurgical clipping
    - Proven effective over decades but invasive, higher morbidity/mortality compared with coiling
    - 1 study: Death or dependence at 1 year = 23.7% with coiling vs. 30.7% with clipping
- Vasospasm
  - Ca++ antagonists, "triple-H" therapy (hypervolemia, hemodilution, hypertension)
  - Endovascular: Intraarterial Ca++ antagonist ("chemical angioplasty"), balloon angioplasty
- Hydrocephalus
  - Temporary or permanent CSF diversion

SELECTED REFERENCES

1. Ramgren B et al: CT angiography in non-traumatic subarachnoid hemorrhage: the importance of arterial attenuation for the detection of intracranial aneurysms. Acta Radiol. ePub, 2014
2. Farzad A et al: Emergency diagnosis of subarachnoid hemorrhage: an evidence-based debate. J Emerg Med. 44(5):1045-53, 2013
3. Froehler MT: Endovascular treatment of ruptured intracranial aneurysms. Curr Neurol Neurosci Rep. 13(2):326, 2013
4. Rana AK et al: Likelihood of aneurysmal subarachnoid haemorrhage in patients with normal unenhanced CT, CSF xanthochromia on spectrophotometry and negative CT angiography. J R Coll Physicians Edinb. 43(3):200-6, 2013

https://CafePezeshki.IR

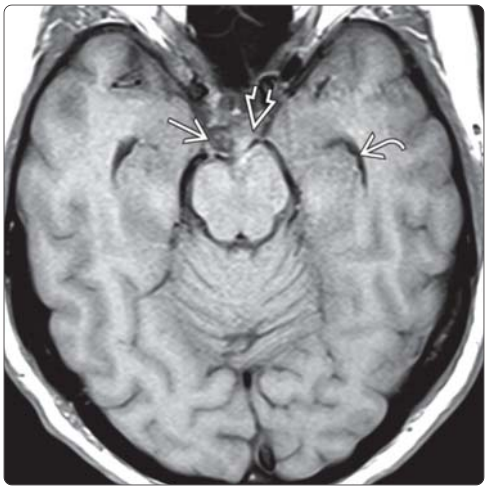

(Left) *Sagittal T1WI illustrates typical findings of acute aneurysmal SAH. Note "dirty" CSF ➡ that appears isointense with adjacent brain. The normal basilar artery "flow void" ➡ is surrounded by the SAH.* **(Right)** *Axial T1WI in the same patient shows a nice contrast between the isointense (with brain) "dirty" CSF ➡ and the more normal-appearing hypointense ("dark") CSF in the cistern ➡ and temporal horns ➡.*

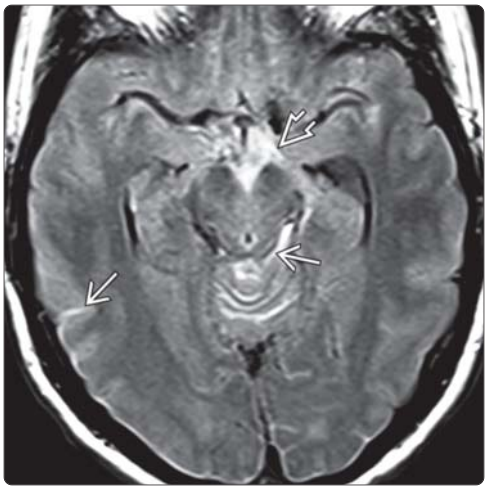

(Left) *Normal CSF suppresses on FLAIR. FLAIR scan in the same patient shows CSF in the suprasellar cistern ➡ is abnormally hyperintense. Sulcal-cisternal hyperintensity is also seen in the left perimesencephalic and superior cerebellar cisterns as well as the parietooccipital subarachnoid spaces ➡.* **(Right)** *Axial NECT in an 83-year-old man found down shows diffuse SAH, seen here as hyperdense fluid ➡ in virtually all the visualized sulci. CSF-blood level ➡ is also present in the lateral ventricles.*

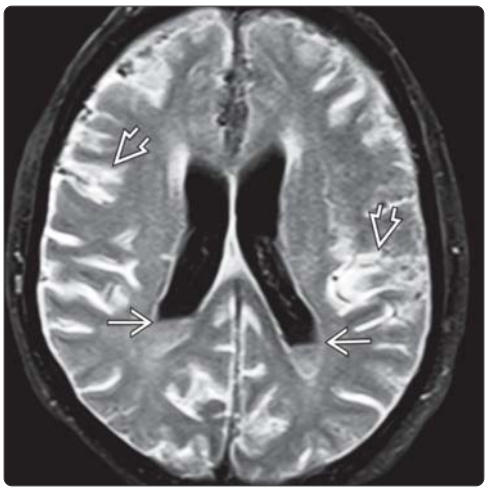

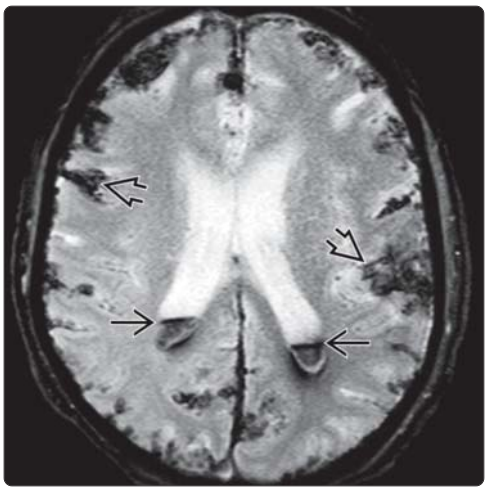

(Left) *FLAIR scan obtained 2 days later in the same patient shows diffuse sulcal hyperintensity ➡ and normally suppressed CSF in the lateral ventricles with blood-fluid level ➡.* **(Right)** *Axial GRE scan in the same patient shows blood in the sulci as "blooming" hypointensities ⇨. The blood-CSF level ⇨ in the lateral ventricles is also clearly seen.*

https://CafePezeshki.IR

Perimesencephalic Nonaneurysmal SAH

KEY FACTS

TERMINOLOGY

- SAH centered immediately anterior to midbrain ± pons
- No source demonstrated at CTA/DSA/MRA

IMAGING

- NECT: Hyperdense prepontine, perimesencephalic CSF
  - Often involves interpeduncular, ambient, quadrigeminal cisterns
  - ± thin extension into posterior suprasellar, proximal sylvian/interhemispheric fissures
  - Does not extend into distal sylvian, interhemispheric fissures
- CTA used to exclude basilar tip aneurysm
- MR
  - T1: Iso- to hyperintense
  - T2 variable (iso- to hyper-) intensity compared to CSF
  - FLAIR: Hyperintense prepontine, perimesencephalic CSF

TOP DIFFERENTIAL DIAGNOSES

- Aneurysmal SAH
- Traumatic SAH
- Artifact: FLAIR

PATHOLOGY

- Most likely from ruptured perimesencephalic/prepontine vein
  - More common if basal vein of Rosenthal small, drains into veins other than Galen
- 5% of pnSAHs have other etiologies
  - Basilar bifurcation aneurysm, dissection most common
  - Other: Trauma, dAVF, spinal cord vascular malformation, vascular neoplasm

CLINICAL ISSUES

- Benign course: Rebleed rare (< 1%); no vasospasm

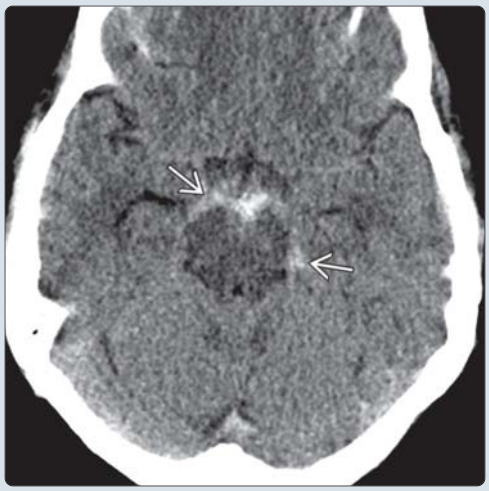

(Left) *Axial graphic shows a classic pnSAH. Hemorrhage is confined to the interpeduncular fossa and ambient (perimesencephalic) cisterns ➡. The source is usually venous in pnSAHs, unlike in aneurysmal SAHs.* **(Right)** *Axial NECT of a 49-year-old woman in the ER with a "thunderclap" headache shows SAH around the midbrain in the perimesencephalic cisterns ➡. Note the absence of blood in the sylvian fissures and anterior suprasellar subarachnoid space.*

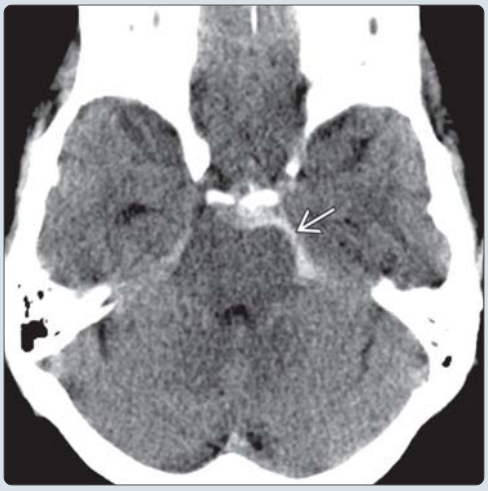

(Left) *Axial NECT in the same patient shows the subarachnoid blood ➡ extends inferiorly in front of the pons.* **(Right)** *Coronal CTA in the same patient with reconstructed view through the basilar artery bifurcation shows no evidence for aneurysm. The high density in the vessels is easily discernible even with the presence of significant SAH. DSA (not shown) confirmed the absence of aneurysm. This case illustrates classic findings in pnSAH.*

https://CafePezeshki.IR

TERMINOLOGY

Abbreviations

- Perimesencephalic nonaneurysmal subarachnoid hemorrhage (pnSAH)

Synonyms

- Benign perimesencephalic SAH

Definitions

- SAH centered immediately anterior to midbrain ± pons
- No source demonstrated at angiography

IMAGING

General Features

- Best diagnostic clue
  - Hyperdense prepontine, perimesencephalic CSF
- Location
  - Subarachnoid cisterns around midbrain and anterior to pons
  - Often involves interpeduncular, ambient, quadrigeminal cisterns
  - Some thin extension into posterior suprasellar, proximal sylvian/interhemispheric fissures
  - Does not extend into distal sylvian, interhemispheric fissures
  - May have small amount of blood in occipital horns but no frank IVH

CT Findings

- NECT
  - High attenuation anterior to pons and around midbrain

MR Findings

- T1WI
  - Iso- to hyperintense CSF around midbrain
- T2WI
  - Variable; iso- to hypointense blood in CSF
- FLAIR
  - Hyperintense
    - May be mimicked by CSF pulsation artifact
- T2* GRE
  - Hypointense, "blooming"

Angiographic Findings

- CTA/MRA/DSA
  - No source of hemorrhage identified on CTA
  - DSA generally not required to confirm diagnosis

Imaging Recommendations

- Best imaging tool
  - NECT best screening for pnSAH
  - CTA to exclude basilar tip aneurysm
  - DSA optional
  - MR/MRA may confirm SAH or cause; may negate need for repeat DSA
- Protocol advice
  - NECT with CTA
  - MR/MRA may help confirm diagnosis
  - Consider cervical MR to exclude rare spinal vascular source

DIFFERENTIAL DIAGNOSIS

Aneurysmal SAH

- More extensive hemorrhage
- Basilar bifurcation aneurysm may have pnSAH pattern

Traumatic SAH

- Perisylvian, convexity more common than perimesencephalic pattern

Artifact: FLAIR

- Incomplete CSF suppression
  - > 50% O_2 concentration
- Pulsation artifact

PATHOLOGY

General Features

- Etiology
  - Most likely from ruptured perimesencephalic/prepontine vein
    - More common if basal vein of Rosenthal small, drains into veins other than Galen
  - 5% of pnSAHs have other etiologies
    - Basilar bifurcation aneurysm, dissection most common
    - Other: Trauma, dAVF, spinal cord vascular malformation, vascular neoplasm

Gross Pathologic & Surgical Features

- Clotted blood in perimesencephalic cisterns

CLINICAL ISSUES

Presentation

- Most common signs/symptoms
  - Headache (usually Hunt/Hess grade 1 or 2)

Demographics

- Age: 40-60 years
- Gender: M = F
- Epidemiology
  - Majority of angiogram-negative SAH

Natural History & Prognosis

- Benign course: Rebleed rare (< 1%); no vasospasm
- More extensive pnSAH may develop hydrocephalus

SELECTED REFERENCES

1. Marder CP et al: Subarachnoid hemorrhage: beyond aneurysms. AJR Am J Roentgenol. 202(1):25-37, 2014
2. Buyukkaya R et al: The relationship between perimesencephalic subarachnoid hemorrhage and deep venous system drainage pattern and calibrations. Clin Imaging. 38(3):226-30, 2014
3. Kapadia A et al: Nonaneurysmal perimesencephalic subarachnoid hemorrhage: diagnosis, pathophysiology, clinical characteristics and long-term outcome. World Neurosurg. ePub, 2014
4. Kim YW et al: Nonaneurysmal subarachnoid hemorrhage: an update. Curr Atheroscler Rep. 14(4):328-34, 2012
5. Kong Y et al: Perimesencephalic subarachnoid hemorrhage: risk factors, clinical presentations, and outcome. Acta Neurochir Suppl. 110(Pt 1):197-201, 2011

https://CafePezeshki.IR

Convexal Subarachnoid Hemorrhage

KEY FACTS

TERMINOLOGY

- Unique type of SAH
  - Localized to sulci over top ("convexity") of brain

IMAGING

- NECT: Hyperdensity in 1 or several adjacent dorsolateral convexity sulci
  - Spares basal, perimesencephalic cisterns
- MR
  - Sulcal CSF replaced by isointense fluid in convexity sulcus ("dirty CSF")
  - Hyperintense sulcus on FLAIR
  - GRE, SWI show "blooming" in affected sulci

TOP DIFFERENTIAL DIAGNOSES

- Aneurysmal subarachnoid hemorrhage (aSAH)
- Perimesencephalic nonaneurysmal subarachnoid hemorrhage (pnSAH)
- Traumatic subarachnoid hemorrhage (tSAH)

PATHOLOGY

- Most common etiology varies with age
  - Elderly patients: Amyloid angiopathy, venous thrombosis, vasculitis
  - Middle aged: Reversible cerebral vasoconstriction syndrome (RCVS), vasculitis, vein thrombosis
  - Young adults, children: Drugs, vasculitis, vein/dural sinus thrombosis

CLINICAL ISSUES

- 7% of all spontaneous (nontraumatic) SAH
- Most common: Middle-aged female
- Presentation varies with age
  - < 60 years of age: Sudden "thunderclap" headache (e.g., RCVS)
  - > 60 years of age: Transient sensory, motor symptoms, less intense headache (CAA)

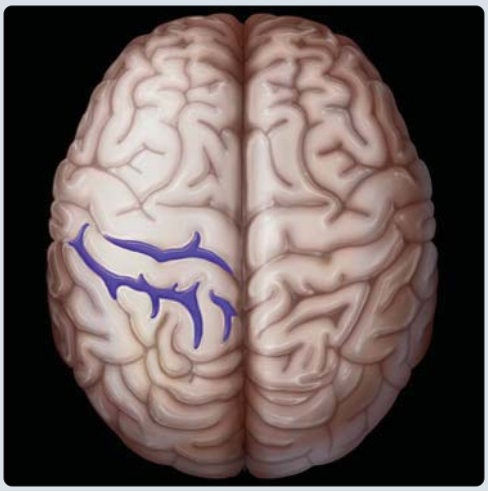

(Left) *Graphic of brain seen from above shows convexal subarachnoid hemorrhage (SAH) in blue affecting adjacent sulci but sparing the basal cisterns.* **(Right)** *Axial NECT in a 28-year-old woman with severe headache following delivery shows focal subarachnoid hemorrhage ➔ over the right cerebral convexity.*

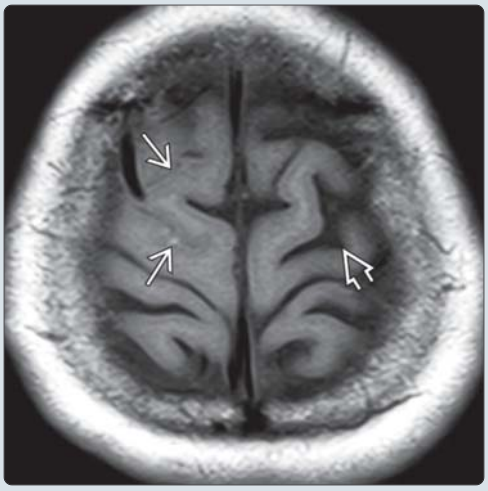

(Left) *Axial T1WI MR in the same patient shows "dirty" fluid filling, effacing the normal sulcal CSF in the right convexity sulci ➔ (compare to normal hypointense signal intensity in the contralateral sulci ➔).* **(Right)** *Axial FLAIR MR in the same patient shows hyperintense right convexity sulci ➔ (contrast with the normal suppressed hypointense CSF over the left convexity). Postpartum vasculopathy was diagnosed at DSA (not shown).*

https://CafePezeshki.IR

TERMINOLOGY

Abbreviations

- Subarachnoid hemorrhage (SAH)
- Convexal subarachnoid hemorrhage (cSAH)

Definitions

- Unique type of SAH
  - SAH localized to sulci over top ("convexity") of brain

IMAGING

General Features

- Best diagnostic clue
  - Hyperdensity in 1 or several dorsolateral convexity sulci on NECT
  - Hyperintense sulcus on FLAIR MR
- Location
  - Top, upper sides of brain
  - Unilateral > bilateral

CT Findings

- Often faint hyperdensity in 1 or more adjacent convexity sulci
- Spares basal, perimesencephalic cisterns

MR Findings

- T1WI
  - Sulcal CSF replaced by isointense fluid in convexity sulcus ("dirty CSF")
- T2WI
  - Hyperintensity of acute blood difficult to perceive
- FLAIR
  - Focal sulcal hyperintensity
- T2* GRE
  - GRE, SWI show "blooming" in affected sulci
  - Look for other findings
    - Occluded cortical vein, dural sinus
    - Microbleeds, superficial siderosis (amyloid angiopathy)

Angiographic Findings

- May show findings of vasculitis, dural sinus/cortical vein occlusion
- Sequential studies may show reversible cerebral vasoconstrictions (RCVS)

Imaging Recommendations

- Best imaging tool
  - NECT as screening
  - MR with T2* (GRE, SWI)

DIFFERENTIAL DIAGNOSIS

Aneurysmal Subarachnoid Hemorrhage (aSAH)

- aSAH typically centered in suprasellar/central basal cisterns
- More diffuse, spreads peripherally

Perimesencephalic Nonaneurysmal Subarachnoid Hemorrhage (pnSAH)

- pnSAH around midbrain, in front of pons
- May spread into posterior suprasellar cistern, proximal sylvian fissures
- Does not extend into distal sylvian, interhemispheric fissures

Traumatic Subarachnoid Hemorrhage (tSAH)

- Cortical contusions common with tSAH
- Anterior inferior temporal, frontal lobes most common sites
  - Hemorrhage is in sulci adjacent to contusions
  - Sylvian fissure blood common

PATHOLOGY

General Features

- Etiology
  - Most common etiology varies with age
    - Elderly patients: Amyloid angiopathy, venous thrombosis, vasculitis
    - Middle aged: Reversible cerebral vasoconstriction syndrome (RCVS), vasculitis, vein thrombosis
    - Young adults, children: Drugs, vasculitis, vein/dural sinus thrombosis
  - Less common causes of cSAH
    - PRES
    - Coagulopathy
    - Ruptured superficial vascular malformation
    - Hemorrhagic neoplasm
  - Rare causes of cSAH
    - Neoplasm
    - Septi emboli

CLINICAL ISSUES

Presentation

- 2 main clinical presentations by patient age
  - < 60 years of age: RCVS with sudden "thunderclap" headache
    - May have "trigger" (vasoactive, sympathomimetic agents, stimulants, etc.)
  - > 60 years of age: CAA with transient sensory, motor symptoms, less intense headache

Demographics

- 7% of all spontaneous (nontraumatic) SAH
- Most common: Middle-aged female

Natural History & Prognosis

- Varies with etiology

DIAGNOSTIC CHECKLIST

Image Interpretation Pearls

- Look for subtle effacement or "fuzzing" of convexity sulci
- Look for etiology of cSAH (i.e., hyperdense clot in cortical vein or dural sinus)

SELECTED REFERENCES

1. Mangla R et al: Cerebral convexity subarachnoid hemorrhage: various causes and role of diagnostic imaging. Emerg Radiol. ePub, 2014
2. Marder CP et al: Subarachnoid hemorrhage: beyond aneurysms. AJR Am J Roentgenol. 202(1):25-37, 2014

https://CafePezeshki.IR

KEY FACTS

TERMINOLOGY

- Chronic, recurrent SAH
  - Causes hemosiderin deposition on surfaces of brain, brainstem, cranial nerves (CNs), spinal cord

IMAGING

- Nonenhanced CT findings
  - Slightly hyperdense rim over brain surface
  - High-density line most evident along brainstem
  - **Caveat**: Do not mistake high-density rim on brain surfaces (not cisterns) as acute SAH
- MR findings
  - T2* (GRE, SWI) most sensitive to hemosiderin deposition
  - Contours of brain and cranial nerves "outlined by black" (hypointense rim) on T2 or T2* GRE MR images
  - CN8 often appears darker, thicker than normal
- If diagnosis of superficial siderosis (SS) is made, must search for cause of recurrent SAH
  - Image entire neuraxis to look for potential bleeding sources
    - Whole brain MR with contrast and MRA
    - Total spine MR if brain negative for underlying lesion

TOP DIFFERENTIAL DIAGNOSES

- "Bounce point" artifact
- Brain surface vessels
  - Usually surface veins, enhance (SS doesn't)
- Neurocutaneous melanosis (usually cutaneous nevi)

PATHOLOGY

- Causes of recurrent SAH with SS
  - Cerebral amyloid angiopathy
  - Bleeding CNS neoplasm
  - Vascular malformations, aneurysms
  - Surgery, trauma
  - CSF hypovolemia syndromes

(Left) *Axial graphic shows darker brown hemosiderin staining on all surfaces of the brain, meninges, and cranial nerves. Notice that cranial nerves 7 and 8 in the cerebellopontine angle-internal auditory canal ⇨ are particularly affected.* **(Right)** *Axial T2WI in a 64-year-old female with bilateral sensorineural hearing loss for 3 years shows a thin "black" line coating the surface of the cerebellum, especially notable over the flocculi ⇨.*

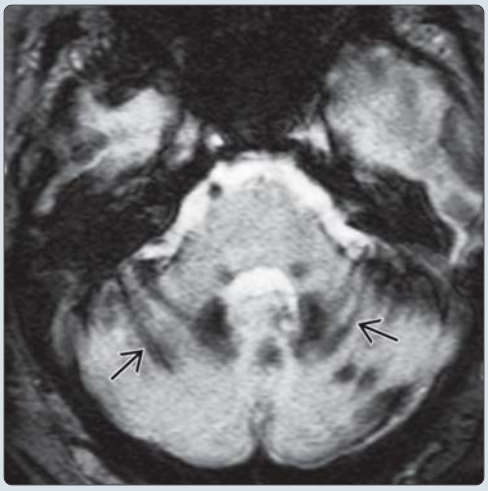

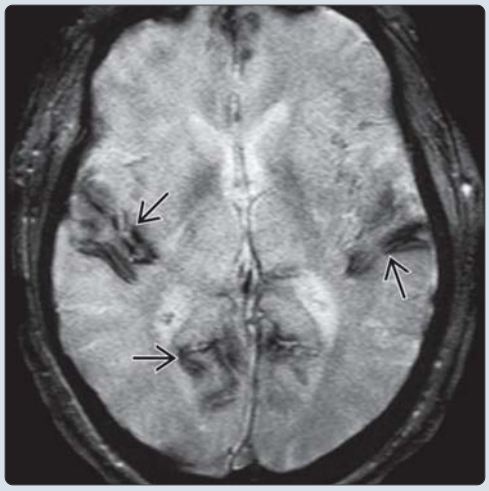

(Left) *Axial T2* GRE scan in the same patient shows the extensive hemosiderin deposition over the cerebellar folia as curvilinear thick "black lines" ⇨.* **(Right)** *More cephalad scan in the same patient shows prominent superficial siderosis ⇨ along the sylvian fissures, medial occipital lobes.*

https://CafePezeshki.IR

TERMINOLOGY

Abbreviations

- Superficial siderosis (SS), subarachnoid hemorrhage (SAH)

Synonyms

- Siderosis, central nervous system siderosis

Definitions

- Chronic, recurrent SAH → hemosiderin deposition on pial surfaces of brain, brainstem, cranial nerves (CNs), spinal cord

IMAGING

General Features

- Best diagnostic clue
  - Surface of brain, CNs outlined by hypointense rim on T2 or T2* GRE MR images
- Location
  - Cerebral hemispheres, cerebellum, brainstem, cranial nerves, spinal cord may all be variably affected
- Size
  - Curvilinear low signal along CNS surfaces varies in thickness but usually ≤ 2 mm
- Morphology
  - Curvilinear dark lines on CNS surfaces

CT Findings

- NECT
  - Cerebral and cerebellar atrophy
    - Especially marked in posterior fossa
      - Cerebellar sulci often disproportionately large
  - CN8 may be hyperdense
  - Slightly hyperdense rim over brain surface
    - Brainstem changes most evident
    - CT relatively insensitive to SS compared to MR
    - **Caveat**: Do not mistake high-density rim on brain surfaces (not cisterns) as acute SAH
- CECT
  - No enhancement typical

MR Findings

- T1WI
  - Hyperintense signal may be seen on CNS surfaces
- T2WI
  - High-resolution, thin-section T2 MR of CPA-IAC
    - CN8 appears darker, thicker than normal
    - Adjacent cerebellar structures, brainstem show low signal surfaces
    - Less easily seen than on T2* GRE images
  - In diffuse disease, ventricles and choroid plexus, brain, brainstem, cerebellum, and cervical spinal cord surfaces all have hypointense hemosiderin rim
  - Vermian and cerebellar atrophy most prominent
- FLAIR
  - Dark border on local surface of brain, brainstem, cerebellum, and cranial nerves
- T2* GRE
  - More sensitive to hemosiderin than standard T2 sequence
  - "Blooming" dark signal along pia, subpial brain
    - Deposition thicker, more conspicuous on GRE, SWI than T2WI
    - May show ventricular ependyma, choroid plexus deposition
  - Look for "blooming" black dots in parenchyma (may indicate cerebral amyloid angiopathy)
- T1WI C+
  - Does not enhance

Imaging Recommendations

- Best imaging tool
  - Brain MR
    - Once diagnosis of SS is made, look for cause of recurrent SAH
    - Whole brain MR without and with contrast +MRA
    - Then total spine MR if brain negative for underlying lesion (e.g., spinal ependymomas may cause recurrent SAH, superficial siderosis)
    - Note: MR findings do not correlate with clinical severity of disease
- Protocol advice
  - Brain MR
    - Unenhanced MR with FLAIR
    - If SS suspected, add T2* (GRE, SWI) sequences to confirm
  - Image entire neuraxis to look for potential bleeding sources

DIFFERENTIAL DIAGNOSIS

"Bounce Point" Artifact

- Mismatch between repetition time (TR) and inversion time (TI) on inversion recovery T1 and FLAIR sequences
  - Imaging clue: Not present on all sequences

Brain Surface Vessels

- Usually surface veins
- Linear, focal area of low signal on brain surface
- Enhance on T1C+ (SS doesn't)

Neurocutaneous Melanosis

- Congenital syndrome
- Large or multiple cutaneous melanocytic nevi
- Benign or malignant pigment cell tumors of leptomeninges may be low signal on surface of brain
- T1 high signal diffusely in pia-arachnoid
- T2 low signal diffusely in pia-arachnoid
- Typically enhances on T1C+

Meningioangiomatosis

- Hamartomatous proliferation of meningeal cells that may extend into underlying cerebral cortex
- Leptomeninges are thick, infiltrated with fibrous tissue
- Usually calcified
- Enhances on T1C+

PATHOLOGY

General Features

- Etiology
  - Repeated SAH deposits hemosiderin on meningeal lining of CNS

https://CafePezeshki.IR

- Affects brain, brainstem, cerebellum, cranial nerves, spinal cord
  - Hemosiderin is cytotoxic to neurons
    - "Free" iron with excess production of hydroxyl radicals is best current hypothesis explaining cytotoxicity
  - CN8 is extensively lined with CNS myelin, which is supported by hemosiderin-sensitive microglia
    - Increased exposure in CPA cistern
- Associated abnormalities
  - Look carefully for causes of recurrent SAH
    - Aneurysm
    - Arteriovenous or cavernous malformation
    - Cerebral amyloid angiopathy
    - Bleeding CNS neoplasm
    - Trauma, surgery
    - CSF hypovolemia syndromes

Gross Pathologic & Surgical Features

- Dark brown discoloration of pia, ependyma, subpial tissue
- Causes of recurrent SAH found in ~ 70%
  - Dural pathology (70%)
    - Traumatic cervical nerve root avulsion
    - CSF cavity lesion (surgical cavity) with "fragile" neovascularity most common
  - Bleeding neoplasms (20%)
    - Ependymoma, oligodendroglioma, astrocytoma, etc.
  - Vascular abnormalities (10%)
    - Arteriovenous malformation (AVM) or aneurysm
    - Multiple cavernous malformations near brain surface
  - Cerebra; amyloid angiopathy

Microscopic Features

- Hemosiderin staining of meninges and subpial tissues to 3 mm depth
- Thickened leptomeninges
- Cerebellar folia: Loss of Purkinje cells and Bergmann gliosis

CLINICAL ISSUES

Presentation

- Most common signs/symptoms
  - Bilateral sensorineural hearing loss (SNHL) in 95%
  - Mimics cerebellar degenerative disorder
    - Progressive cerebellar ataxia
    - Pyramidal signs
- Clinical profile
  - Past history of trauma or intradural surgery common
    - Past history of SAH rare
  - Classic presentation is adult patient with bilateral SNHL, ataxia
  - Seen less commonly as late complication of treated childhood cerebellar tumor
- Laboratory
  - CSF from lumbar puncture
    - High protein (100%)
    - Xanthochromic (75%)
- Other symptoms
  - Ataxia (88%)
  - Bilateral hemiparesis
  - Hyperreflexia, bladder disturbance, anosmia, dementia, and headache
  - Presymptomatic phase averages 15 years

Demographics

- Age
  - Broad range: 14-77 years
- Gender
  - M:F = 3:1
- Epidemiology
  - Rare chronic progressive disorder
  - 0.15% of patients undergoing MR

Natural History & Prognosis

- Bilateral worsening SNHL and ataxia within 15 years of onset
- Deafness almost certain if unrecognized
- 25% bedridden in years after 1st symptom
  - Result of cerebellar ataxia, myelopathic syndrome, or both

Treatment

- Treat source of bleeding
  - Surgically remove source of bleeding (surgical cavity, tumor)
  - Endovascular therapy for AVM and aneurysm
- Cochlear implantation for SNHL

DIAGNOSTIC CHECKLIST

Consider

- Remember that SS is effect, not a cause
- Look for source of recurrent SAH in spine or brain
- MR findings do not correlate with severity of patient's symptoms
  - MR diagnosis may be made in absence of symptoms

Image Interpretation Pearls

- CNS surfaces, including cranial nerves, appear "outlined in black" on T2 MR

Reporting Tips

- Describe individual findings of SS
- Describe any possible sites of chronic SAH
- If no site of SAH visible, recommend full spine MR in search of SAH site
  - Treatment of SAH site may arrest progression of associated symptoms

SELECTED REFERENCES

1. Calvo M et al: [Diffuse superficial siderosis of the central nervous system: four case reports and review of the literature.] Rev Neurol. 59(8):354-8, 2014
2. Pikis S et al: Superficial siderosis of the central nervous system secondary to spinal ependymoma. J Clin Neurosci. ePub, 2014
3. Charidimou A et al: Cortical superficial siderosis and intracerebral hemorrhage risk in cerebral amyloid angiopathy. Neurology. 81(19):1666-73, 2013
4. Wang J et al: Superficial siderosis of the central nervous system: MR findings with susceptibility-weighted imaging. Clin Imaging. 35(3):217-21, 2011
5. 1: Kumar N. Neuroimaging in superficial siderosis: an in-depth look. AJNR Am J Neuroradiol. 2010 Jan;31(1):5-14. Epub 2009 Sep 3. Review. PubMed PMID: 19729538. Neuroradiol. 2010 Jan;31(1):5-14. Epub 2009 Sep 3. Review. PubMe

https://CafePezeshki.IR

(Left) *Axial T2* GRE scan in a 51-year-old male with bilateral sensorineural hearing loss and remote history of resection of a left frontal oligodendroglioma shows hypointensity coating the medulla ⇨ cerebellar flocculi ⇨, CNs 9-11 ⇨, and staining the 4th ventricle choroid plexus ⇨.* **(Right)** *More cephalad scan in the same patient shows superficial siderosis (SS) of the 7th and 8th CNs ⇨ as well as the ependyma of the 4th ventricle ⇨.*

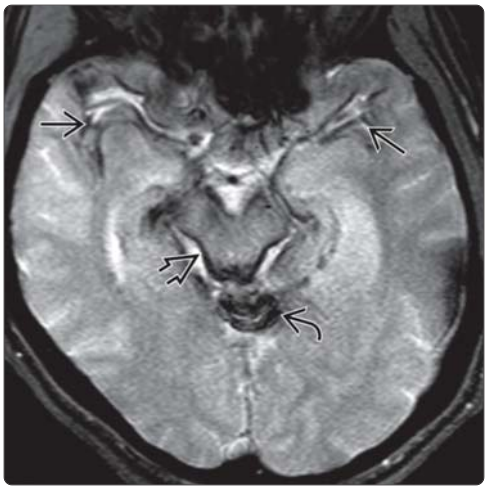

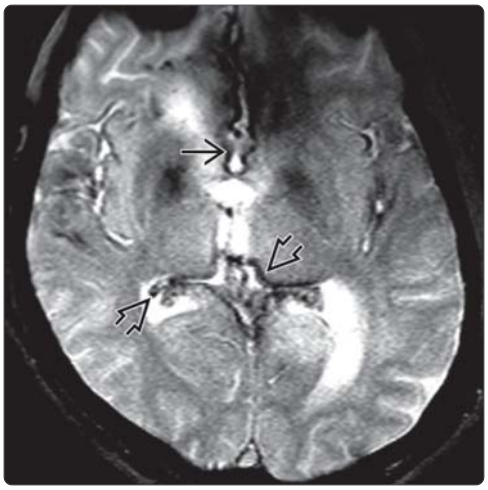

(Left) *More cephalad T2*GRE scan in the same patient shows diffuse SS along both sylvian fissures ⇨ and coating the midbrain ⇨, top of the vermis ⇨.* **(Right)** *More cephalad T2* GRE scan shows coating along the surfaces of both sylvian fissures as well as the interhemispheric fissure ⇨. Note the hemosiderin staining the ependyma, choroid plexi of the lateral ventricles ⇨.*

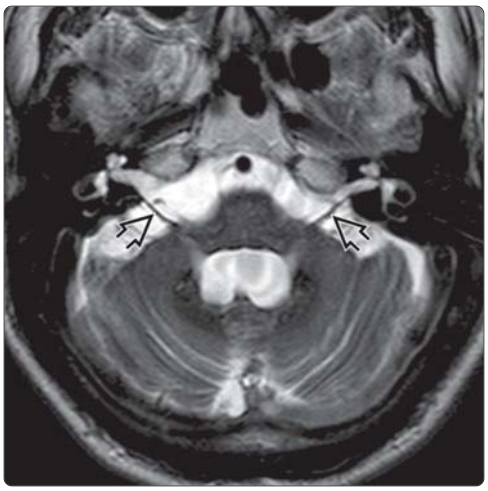

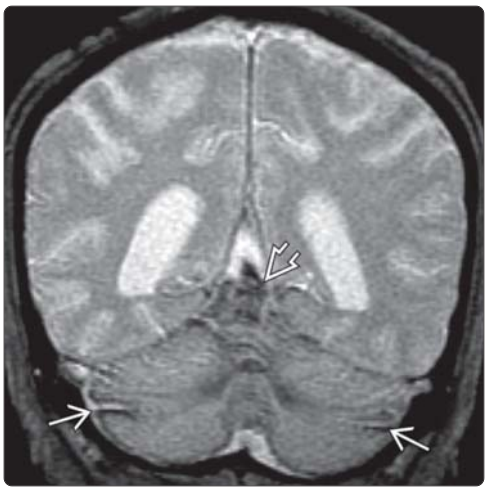

(Left) *Axial T2WI in a 60-year-old male with progressive ataxia, bilateral sensorineural hearing loss exhibits SS seen here as "thicker, blacker" CN8s ⇨. Note the cerebellar atrophy with large 4th ventricle, prominent folia.* **(Right)** *Sometimes SS is limited to the posterior fossa. Coronal T2* GRE demonstrates extensive superficial siderosis in the posterior fossa. "Blooming" of the hemosiderin on the surfaces is seen as a hypointense outline. The superior vermis ⇨ as well as the cerebellar folia ⇨ are involved.*

https://CafePezeshki.IR

KEY FACTS

TERMINOLOGY

- Intracranial saccular aneurysm (SA)
- Outpouching affecting only part of arterial circumference
  - Lacks internal elastic lamina ± tunica media

IMAGING

- Round/lobulated arterial outpouching
  - Usually arises from bifurcations of circle of Willis (COW), supraclinoid ICA, MCA, cerebellar arteries
  - 90% occur in anterior circulation
  - 10% posterior circulation: Basilar tip, cerebellar arteries (PICA most common)
  - Rare (< 1%): Trigeminal artery, vertebrobasilar junction fenestration
- Ruptured SAs result in SAH
- May have mural Ca++
- Sensitivity of multislice CTA > 95% for SA > 2 mm
- 3D TOF: > 90% sensitive for aneurysms ≥ 3 mm

TOP DIFFERENTIAL DIAGNOSES

- Vessel loop
- Vessel infundibulum
- Fusiform aneurysm
- Flow void MR mimic (e.g., aerated anterior clinoid)

CLINICAL ISSUES

- Vast majority of unruptured SAs are asymptomatic
  - 2-6% incidental finding at autopsy, imaging
- 80-90% of nontraumatic SAH caused by ruptured SA
- Treatment
  - Endovascular coiling vs. surgical clipping
  - 22.6% relative, 6.9% absolute risk ↓ for coiling vs. surgery for ruptured aneurysms
  - ↓ morbidity, mortality, and hospital costs; quicker recovery for unruptured aneurysms

(Left) *Most common sites for SAs are ACoA ➡ and IC-PC junction ➡. MCA bifurcation ➡ and basilar tip ➡ are other frequent sites.* **(Right)** *Graphic illustrates rupture of an ACoA aneurysm ➡ with active extravasation from a superiorly directed bleb (Murphy teat). An additional posterior communicating artery SA ➡ and tiny bleb at the left MCA bifurcation ➡ are seen. Patients with SAs have a 20% chance of having > 1 aneurysm.*

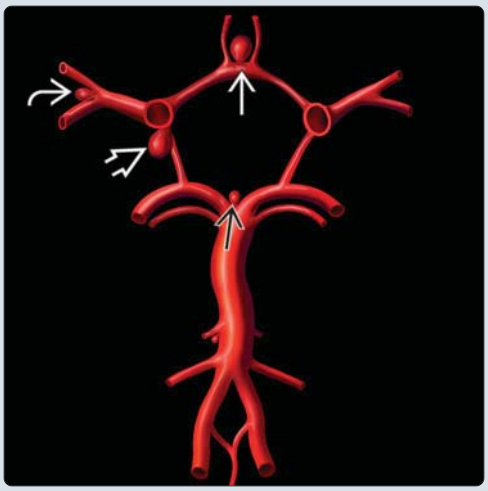

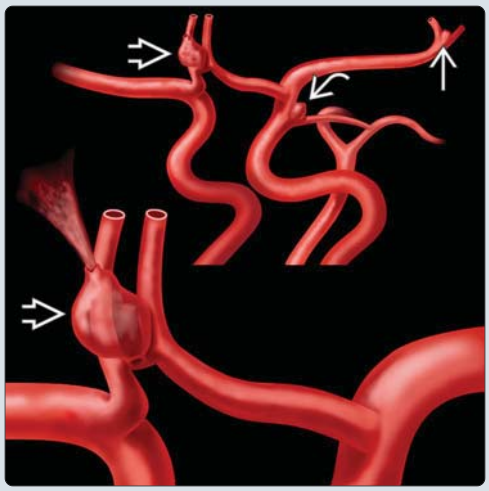

(Left) *A 63-year-old man was found down in a parking lot and brought to the ER. Axial NECT scan showed diffuse subarachnoid hemorrhage ➡ with a focal hematoma ➡ in the anteroinferior aspect of the interhemispheric fissure.* **(Right)** *Coronal MIP of the CTA in the same patient shows a 4 mm saccular aneurysm ➡ projecting upwards from the anterior communicating artery.*

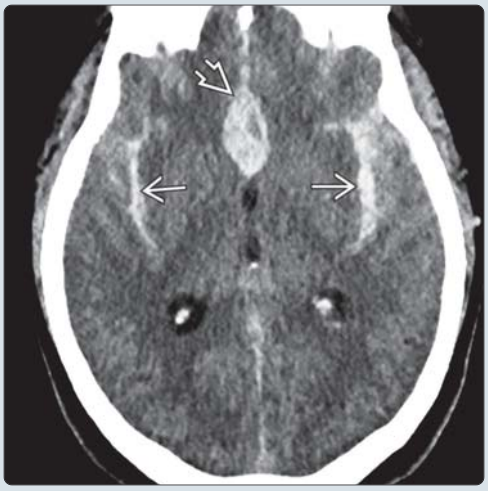

https://CafePezeshki.IR

TERMINOLOGY

Abbreviations

- Intracranial saccular aneurysm (SA)

Synonyms

- Berry aneurysm, true aneurysm

Definitions

- Arterial outpouching affecting only part of arterial circumference
  - Lacks internal elastic lamina ± tunica media

IMAGING

General Features

- Best diagnostic clue
  - Round/lobulated arterial outpouching
    - Usually arises from bifurcations of circle of Willis (COW), supraclinoid ICA, MCA, cerebellar arteries
- Location
  - 90% occur in anterior circulation
    - ACoA, PCoA, MCA bifurcation, carotid terminus most common sites
    - Other: Paraclinoid ICA, superior hypophyseal, anterior choroidal artery (AChA)
  - 10% posterior circulation: Basilar tip, cerebellar arteries (PICA most common)
  - Rare (< 1%): Trigeminal artery, vertebrobasilar junction fenestration
  - Vessel bifurcation > side wall aneurysm (e.g., blood blister-like aneurysm)
- Size
  - Small (< 3 mm) to giant (> 2.5 cm)
- Morphology
  - Round, ovoid daughter lobe(s)
  - Narrow or wide necked
  - Branch vessel may be incorporated into aneurysm neck (can preclude coil embolization)

CT Findings

- NECT
  - Ruptured SAs result in subarachnoid hemorrhage (SAH)
    - Pattern of SAH may help localize SA location
  - If SA contains thrombus → hyperdense to brain
  - May have mural Ca++
- CECT
  - Lumen of patent SA enhances uniformly
  - Completely thrombosed SA may have rim enhancement
- CTA
  - Sensitivity of multislice CTA > 95% for SA > 2 mm
  - Look for > 1 aneurysm, as SA is multiple in 20% of patients
  - Look for associated SAH vasospasm if ruptured SA
  - Alternative to DSA as 1st imaging technique in SAH

MR Findings

- T1WI
  - Patent aneurysm (signal varies)
    - 50% have flow void
    - 50% iso-/heterogeneous signal (slow/turbulent flow, saturation effects, phase dispersion)
  - Partially/completely thrombosed aneurysm
    - Signal depends on age of thrombus
    - Common: Mixed signal, laminated thrombus
    - Hypointense + "blooming" on susceptibility sequences (GRE, SWI)
- T2WI
  - Typically hypointense (flow void)
  - May be laminated with very hypointense rim
- FLAIR
  - Acute SAH: High signal in sulci, cisterns
- DWI
  - May see restricted diffusion secondary to ischemia from SAH vasospasm
  - Thromboembolic events from intraaneurysmal thrombus (rare)
- T1WI C+
  - Slow flow in patent lumen may enhance
  - Increased phase artifact in patent SAs
- MRA
  - 3D TOF: > 90% sensitive for aneurysms ≥ 3 mm
  - Short T1 substances, such as subacute hemorrhage, may simulate flow on TOF MRA

Angiographic Findings

- Conventional DSA
  - Technique
    - Bilateral carotid + dominant vertebral artery injections with reflux to contralateral PICA or "4 vessel" cerebral DSA required
    - Cross-compression of contralateral carotid may be needed for evaluation of ACoA
    - Rotational DSA with 3D surface-shaded display (SSD) reconstructions may be helpful, but prone to artifact depending on window settings
  - Rare: Contrast extravasation with active SAH
  - Look for Murphy teat (bleb at site of recent rupture) vs. daughter lobe (smaller outpouching from aneurysm fundus, likely indicating focal wall weakness, ↑ future rupture risk)

Imaging Recommendations

- Best imaging tool
  - NECT + CTA for work-up of SAH
  - CTA or MRA for screening of high-risk groups
- Protocol advice
  - Dual energy direct bone removal CT angiography for evaluation of skull base/paraclinoid SA
  - 3D SSD reconstructions helpful to visualize ACoA and MCA bifurcation

DIFFERENTIAL DIAGNOSIS

Vessel Loop

- Use multiple projections

Vessel Infundibulum

- < 3 mm, conical, vessel arises directly from apex
- Commonly at posterior communicating artery (PCoA) and anterior choroidal artery (AChA) origins

https://CafePezeshki.IR

Fusiform Aneurysm

- Sausage-shaped morphology with separate inflow, outflow pathways
- Long segment, usually located distal to COW
- Can be secondary to ASVD
- Often pseudoaneurysm etiology
  - Trauma, mycotic, vasculitic, connective tissue disease

Flow Void (MR Mimic)

- Aerated anterior clinoid or supraorbital cell

PATHOLOGY

General Features

- Etiology
  - SA development and rupture risk reflect complex combination of inherited susceptibility + acquired mechanically mediated vessel wall stresses
  - Abnormal vascular hemodynamics → ↑ wall stress
    - Flow-related "bioengineering fatigue" in vessel wall more likely with asymmetric COW → ↑ development of SA at site of anomaly
      - Aplastic A1 segment, persistent trigeminal artery
      - No definite relationship with arterial fenestrations
- Genetics
  - Familial intracranial aneurysms (FIAs)
    - No known heritable connective tissue disorder
    - Occur in "clusters" (1st-order relatives)
    - Younger patients, no female predominance compared to sporadic SAs
    - Consider screening with CTA or MRA
- Associated abnormalities
  - ↑ SA incidence in patients with
    - Fibromuscular dysplasia (FMD): Autosomal dominant, sporadic
  - Bicuspid aortic valve
  - Autosomal dominant polycystic kidney disease (10% have SA)
  - Intracranial AVM: Feeding pedicle ("flow related") aneurysms in 30%
    - May regress after treatment of AVM

Gross Pathologic & Surgical Features

- Round/lobulated sac, thin or thick wall, ± SAH

Microscopic Features

- Disrupted/absent internal elastic lamina
- Muscle layer absent
- May have "teat" of fragile adventitia

CLINICAL ISSUES

Presentation

- Most common signs/symptoms
  - Vast majority of unruptured SA are asymptomatic
    - Cranial neuropathy uncommon (e.g., pupil-involving CN3 palsy from PCoA aneurysm)
    - TIA/stroke from thromboembolic events secondary to intraaneurysmal thrombus (rare)
  - 80-90% of nontraumatic SAH caused by ruptured SA
    - Headache (typical = "thunderclap")
- Clinical profile
  - 2 common scenarios
    - Middle-aged patient with "worst headache of life" from ruptured SA → SAH
    - Incidental finding on imaging performed for unrelated symptoms in patient of any age

Demographics

- Age
  - ↑ incidence of SA with age; rare in children
- Gender
  - M < F (especially with multiple aneurysms)
- Epidemiology
  - 2-6% incidental finding of unruptured SA at autopsy
  - Annual risk of de novo aneurysm formation = 0.8% in patients with previous SA

Natural History & Prognosis

- Rupture risk
  - Size: Low risk of SA rupture if < 7 mm
  - Growth, rupture risk for unruptured aneurysms
    - Growth rate = 3.9% per year
    - 1.8% per year rupture risk
  - ~ 20% of ruptured unsecured SA rebleed within 2 weeks, 50% in 6 months
  - Shape: Daughter lobe likely ↑ risk of future SAH; Murphy teat = site of recent rupture and possible rebleed if untreated
  - ↑ in females with history of HTN, smoking

Treatment

- Endovascular coiling
  - Ruptured SA: 22.6% relative, 6.9% absolute risk ↓ for coiling vs. surgery (1 study)
  - Unruptured SA: Coiling vs. clipping
    - ↓ morbidity, mortality, and hospital costs; shorter hospital stay; quicker recovery
- Surgical clipping
  - Lower SA recurrence risk compared with coiling, although rebleeding risk is low with either Rx
  - May have advantage in MCA and other SA where branch vessel arising from SA must be preserved

DIAGNOSTIC CHECKLIST

Consider

- Blood blister-like aneurysm if negative CTA in patient with SAH → perform DSA
- Perimesencephalic bleed in patient with blood localized to interpeduncular cistern

Image Interpretation Pearls

- Diffuse SAH without focal hematoma → ACoA is most likely site of ruptured SA
- Absence of sylvian fissures may be clue to subacute (isodense) SAH

SELECTED REFERENCES

1. Bor AS et al: Clinical, radiological, and flow-related risk factors for growth of untreated, unruptured intracranial aneurysms. Stroke. 46(1):42-8, 2015

https://CafePezeshki.IR

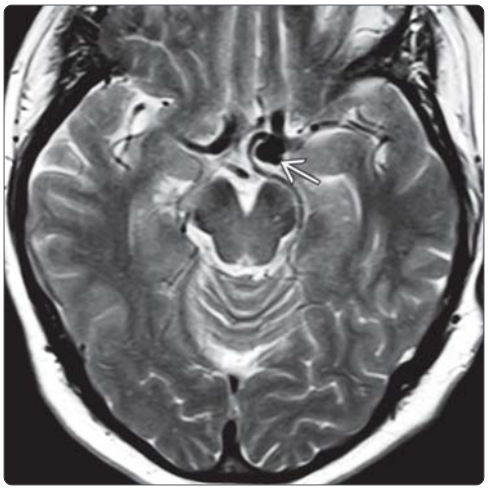

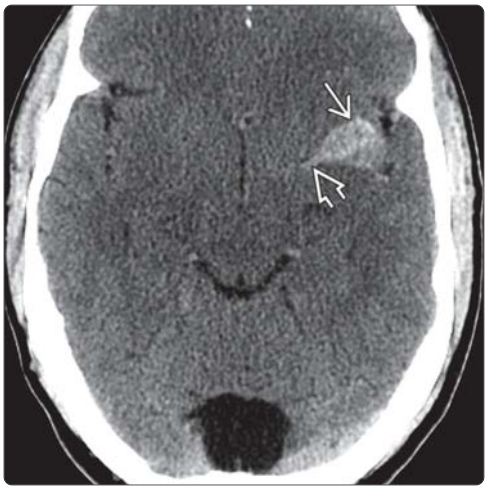

(Left) *Patent saccular aneurysms are seen as rounded hypointense "flow voids" on MR. This saccular aneurysm at the distal ICA bifurcation ➡ was found incidentally on the T2WI of this elderly patient.* **(Right)** *Thrombosed SAs can appear very hyperdense. This patient presented in the ER with sudden onset of right hemiparesis. NECT scan, obtained as the initial study in the standard stroke protocol, shows an ovoid hyperdensity ➡ with what appears to be thrombus in the left proximal MCA ➡.*

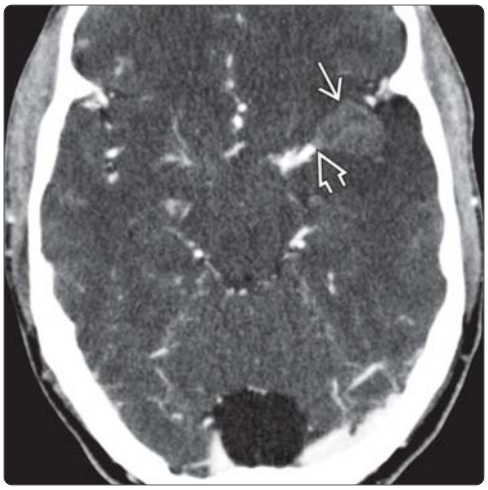

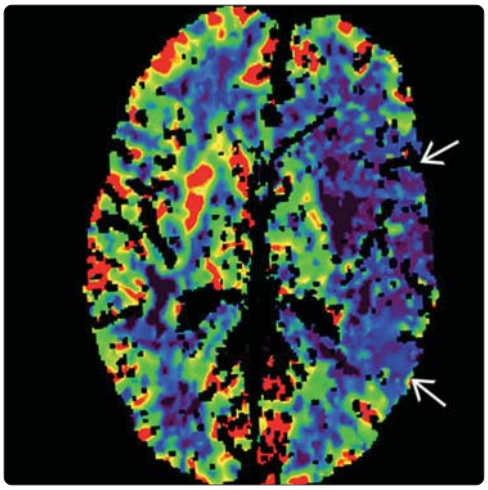

(Left) *Source image from the CTA in the same patient shows abrupt "cut-off" of the left MCA ➡ and nonfilling of a large, completely thrombosed saccular aneurysm ➡.* **(Right)** *CT perfusion study in the same patient shows markedly decreased cerebral blood flow in the left MCA distribution ➡. The basal ganglia (supplied by lenticulostriate branches from the unoccluded proximal MCA) are spared. Cerebral infarction can be caused by distal migration of clot from a thrombosed SA.*

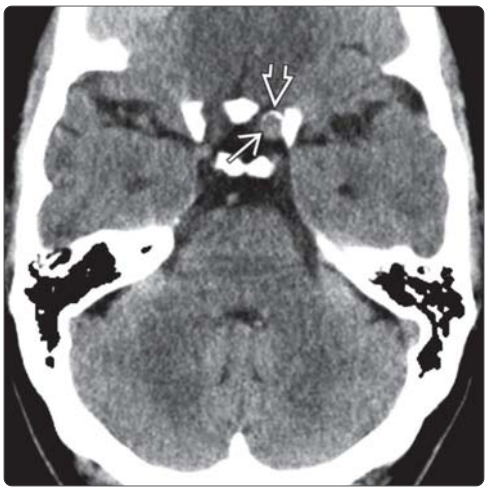

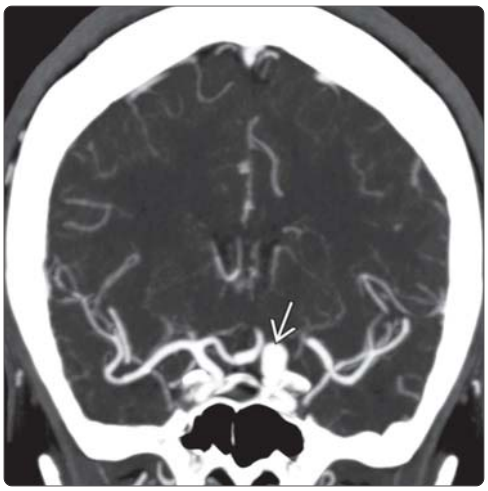

(Left) *Some aneurysms exhibit mural calcification. NECT scan shows an incidentally discovered SA, seen here as a well-demarcated rounded hyperdensity ➡ with a peripheral rim of calcification ➡.* **(Right)** *CTA was subsequently performed in the same patient. Coronal MIP shows a patent saccular aneurysm ➡ at the terminal bifurcation of the left ICA.*

https://CafePezeshki.IR

Pseudoaneurysm

KEY FACTS

TERMINOLOGY

- Focal arterial dilatation not contained by layer(s) of normal arterial wall

IMAGING

- General features
  - Irregular, lobulated or fusiform arterial outpouching
    - At atypical site for true (saccular) aneurysm
- NECT
  - Focal hematoma adjacent to vessel
- CTA
  - Focal, often irregular dilatation of vessel
- T1WI: Hematoma signal varies with clot age
- GRE: Hypointense

TOP DIFFERENTIAL DIAGNOSES

- Saccular aneurysm
- Dissecting aneurysm

PATHOLOGY

- Etiology
  - Trauma (penetrating or blunt)
  - Infection, inflammation ("mycotic" aneurysm)
  - Drug abuse, neoplasm ("oncotic" aneurysm)
  - Spontaneous dissection, underlying vasculopathy
  - XRT, surgery for H&N cancer ("carotid blow-out")

CLINICAL ISSUES

- Interval between initial injury, Sx varies from few days to several months
- PA rupture → sudden headache with SAH, parenchymal hematoma
- Other: Delayed stroke/SAH/parenchymal bleed following CHI

DIAGNOSTIC CHECKLIST

- Enhancing focus within hematoma may represent pseudoaneurysm

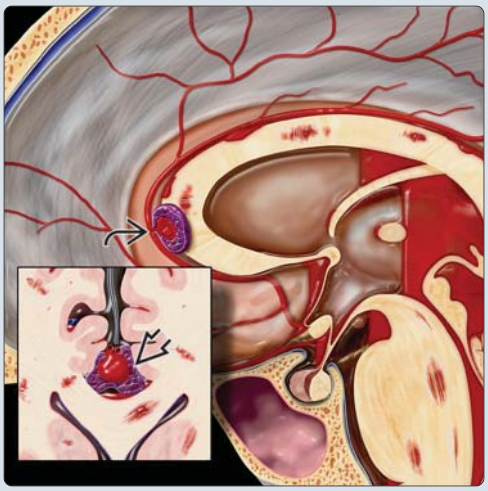

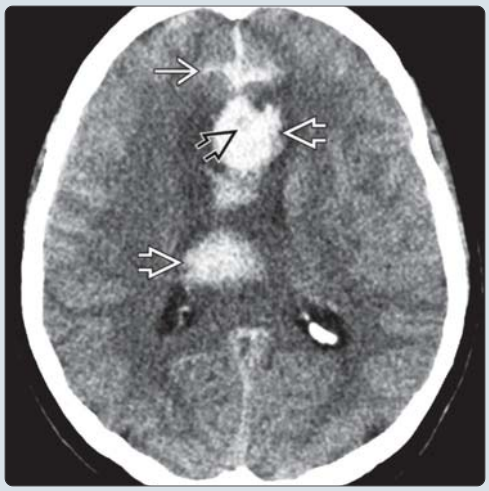

(Left) *Sagittal graphic shows sequelae of closed head injury. A pseudoaneurysm of distal ACA is seen. Note lesion is contained by cavitated clot ⇨ that communicates with the ACA ⇨.* **(Right)** *Axial NECT in a 52-year-old woman with sudden onset of severe headache 2 weeks following closed head injury shows subarachnoid hemorrhage ⇨ and focal hematomas within the corpus callosum ⇨. A subtle focus of relative hypodensity ⇨ is present within the genu clot.*

(Left) *Emergent CTA in the same patient was obtained and disclosed an irregular, contrast-filled lobulated outpouching of the anterior cerebral artery ⇨.* **(Right)** *Sagittal CTA reformatted from the axial source data in the same patient nicely depicts the source of the callosal hematoma ⇨. A bleeding traumatic pseudoaneurysm ⇨ was found at surgery.*

https://CafePezeshki.IR

TERMINOLOGY

Definitions

- Focal arterial dilatation not contained by layer(s) of normal arterial wall
  - Complete disruption of arterial wall

IMAGING

General Features

- Best diagnostic clue
  - Irregular, often fusiform arterial outpouching at atypical site for SA
- Location
  - Intracranial
    - Distal MCA, ACA, PCA, distal to circle of Willis
    - Petrous/cavernous ICA , vertebral artery (VA)
- Morphology
  - Often irregular ± fusiform shape

CT Findings

- NECT
  - Focal hematoma adjacent to vessel
  - Base of skull fx ± other CT signs of trauma (e.g., contusion, DAI, extraaxial hemorrhage)
- CTA
  - Focal often irregular vessel dilatation
    - Confined by adjacent hematoma

MR Findings

- T1WI
  - Hematoma signal varies with clot age
  - ± associated flow void within hematoma
- T2* GRE
  - Hypointense
- T1WI C+
  - Pseudoaneurysm enhances strongly
- MRA
  - Contrast-enhanced MRA recommended
    - Subacute hematoma may obscure pseudoaneurysm with TOF MRA

Angiographic Findings

- DSA
  - Lobulated or fusiform arterial outpouching
  - Pseudoaneurysm, distal parent vessel may fill/empty slowly → decreased perfusion

Imaging Recommendations

- Best imaging tool
  - CTA with multiplanar recons ± shaded surface display (SSD)
  - DSA for definitive diagnosis ± endovascular Rx

DIFFERENTIAL DIAGNOSIS

Saccular Aneurysm

- Circle of Willis > VA or distal ICA branches

Dissecting Aneurysm

- VA > ICA
- Contained by vessel wall (media, adventitia)

Active Extravasation (Other Causes)

- CTA shows focal enhancement within hematoma but often not contiguous with adjacent vessels

PATHOLOGY

General Features

- Etiology
  - Inciting event weakens arterial wall, which subsequently ruptures
    - Paravascular hematoma forms
    - Hematoma cavitates, communicates with residual lumen
    - PA wall consists of cavitated clot, fibrous tissue
  - Causes
    - Trauma (penetrating or blunt)
    - Infection, inflammation ("mycotic" aneurysm)
    - Drug abuse, neoplasm ("oncotic" aneurysm)
    - Spontaneous dissection, underlying vasculopathy
    - XRT, surgery for H&N cancer ("carotid blow-out")

Gross Pathologic & Surgical Features

- Purplish mass of organized hematoma

Microscopic Features

- Wall disruption, necrosis
- ± inflammatory or neoplastic cells

CLINICAL ISSUES

Presentation

- Most common signs/symptoms
  - PA rupture → sudden headache with SAH, parenchymal hematoma
    - Interval between initial injury, Sx varies from few days to several months
    - Delayed ischemia, infarction common
- Clinical profile
  - Patient with delayed stroke/SAH/parenchymal bleed following closed head injury (CHI)

DIAGNOSTIC CHECKLIST

Consider

- Pseudoaneurysm in patient who develops delayed hematoma following CHI

Image Interpretation Pearls

- Enhancing focus within hematoma may represent pseudoaneurysm

SELECTED REFERENCES

1. Ramgren B et al: CT angiography in non-traumatic subarachnoid hemorrhage: the importance of arterial attenuation for the detection of intracranial aneurysms. Acta Radiol. ePub, 2014
2. Sailer AM et al: Diagnosing intracranial aneurysms with MR angiography: systematic review and meta-analysis. Stroke. 45(1):119-26, 2014
3. Amenta PS et al: Successful treatment of a traumatic carotid pseudoaneurysm with the Pipeline stent: Case report and review of the literature. Surg Neurol Int. 3:160, 2012

https://CafePezeshki.IR

KEY FACTS

TERMINOLOGY

- Extensive ectatic, elongated vertebrobasilar artery (VBA)
- Usually associated with decreased blood flow velocity

IMAGING

- General findings
  - Irregular, elongated, tortuous VBA
  - Usually 6-12 mm, can be giant (> 2.5 cm)
  - Focal arterial dilatation = fusiform aneurysm
- CT
  - Hyperdense tortuous enlarged vessel, Ca++ common
  - Enlarged lumen enhances, intramural thrombus does not
- MR
  - Signal varies with flow, presence/age of thrombus
  - Dynamic CE MRA best
  - 3D TOF inadequate (slow flow saturation effects)

TOP DIFFERENTIAL DIAGNOSES

- Fusiform aneurysm, ASVD
- Giant serpentine aneurysm
- Nonatherosclerotic fusiform vasculopathy
- Dissecting aneurysm

CLINICAL ISSUES

- Peak age = 7th, 8th decades
- Often asymptomatic
  - Vertebrobasilar TIAs
  - Progressive cranial nerve compression less common
  - Rare: Hemorrhage, hydrocephalus

DIAGNOSTIC CHECKLIST

- Slow complex flow → heterogeneous signal, TOF artifact
- Dynamic contrast-enhanced CTA/MRA or DSA necessary to delineate true lumen

(Left) *Autopsied brain seen from below shows ectatic, very tortuous basilar artery ⇨ with extensive yellow plaques of atherosclerosis. No focal areas of dilatation are seen, so this is vertebrobasilar dolichoectasia, a relatively common finding in elderly patients. (Courtesy R. Hewlett, MD.)* **(Right)** *Sagittal T1WI MR in a 76-year-old man with headaches shows a very elongated, unusually ectatic basilar artery ⇨. The basilar tip elevates and indents the 3rd ventricle ⇨.*

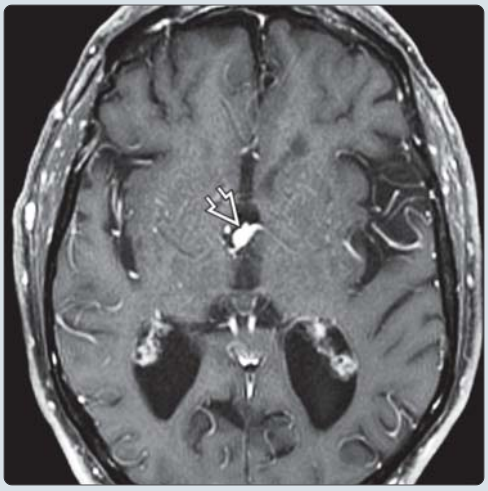

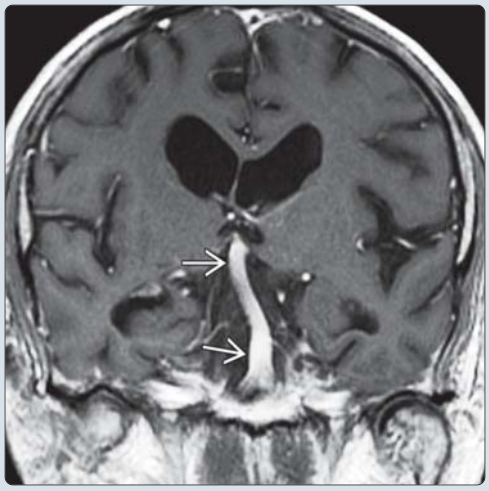

(Left) *Axial T1 C+ FS MR shows the strongly enhancing basilar bifurcation ⇨ as it indents the inferior 3rd ventricle.* **(Right)** *Coronal T1 C+ MR shows the extremely ectatic, elongated basilar artery ⇨ characteristic of typical vertebrobasilar dolichoectasia.*

https://CafePezeshki.IR

TERMINOLOGY

Abbreviations

- Vertebrobasilar dolichoectasia (VBD)

Synonyms

- Fusiform vertebrobasilar ectasia

Definitions

- Extensive ectatic, elongated vertebrobasilar artery (VBA)
  - Usually associated with decreased blood flow velocity

IMAGING

General Features

- Best diagnostic clue
  - Irregular, tortuous VBA ± long segment nonfocal fusiform arterial enlargement
- Location
  - Basilar > dominant vertebral or both vertebral arteries
    - Other arteries (e.g., PICA, often involved)
- Size
  - Usually moderate (6-12 mm)
    - May be giant (> 2.5 cm diameter)
- Morphology
  - Diffuse or multifocal ectatic vessel
    - If focal dilatation = atherosclerotic fusiform aneurysm

CT Findings

- NECT
  - Hyperdense tortuous enlarged vessel
    - Thickened walls, Ca++ common
    - Thrombus common
- CECT
  - Enlarged lumen enhances
    - Intramural thrombus/plaque does not
- CTA
  - Enlarged tubular ± focal fusiform vertebrobasilar arteries with tortuosity

MR Findings

- T1WI
  - Signal varies with flow, presence/age of thrombus
- T2WI
  - Lumen, thrombus hypointense
- FLAIR
  - Slow flow may cause intraluminal hyperintensity
- T1WI C+
  - Lumen enhances intensely
    - Pulsation artifact common
- MRA
  - Dynamic CE MRA best
  - 3D TOF inadequate (slow-flow saturation effects)

Imaging Recommendations

- Best imaging tool
  - Dynamic contrast-enhanced CTA/MRA
- Protocol advice
  - CTA/MRA (2D TOF &/or contrast-enhanced) for vessel delineation
  - T2/FLAIR for brainstem delineation

DIFFERENTIAL DIAGNOSIS

Fusiform Aneurysm

- Focal elongated aneurysmal outpouching
- Often superimposed on VBD

Giant Serpentine Aneurysm

- Round/oval mass
- Tortuous lumen, variable thrombus
- Delineation of outer wall morphology on T1, T2, or CT is crucial

Nonatherosclerotic Fusiform Vasculopathy

- Younger patient with inherited vasculopathy, inflammatory disease
- Anterior > posterior circulation

Dissecting Aneurysm

- Vertebral > basilar artery
- Lacks changes of ASVD, Ca++
- Usually more focal or with narrowing

CLINICAL ISSUES

Presentation

- Most common signs/symptoms
  - Often asymptomatic
    - Vertebrobasilar TIAs
    - Progressive cranial nerve compression less common
    - Rare: Hemorrhage, hydrocephalus

Demographics

- Incidence estimate 1.3%
- Peak age = 7th, 8th decades

Natural History & Prognosis

- Slow progressive increasing ectasia
  - May become symptomatic or develop symptoms of other ASVD
- Subarachnoid hemorrhage uncommon
  - Usually with associated focal fusiform aneurysm

DIAGNOSTIC CHECKLIST

Image Interpretation Pearls

- Slow complex flow may have heterogeneous signal, saturation artifacts
- Dynamic contrast-enhanced CTA/MRA or DSA necessary to delineate true lumen

SELECTED REFERENCES

1. Grasso G et al: Dolichoectasia of the vertebrobasilar complex causing neural compression. Surg Neurol Int. 5:20, 2014
2. Yuan YJ et al: Research progress on vertebrobasilar dolichoectasia. Int J Med Sci. 11(10):1039-48, 2014
3. Serrone JC et al: Vertebrobasilar fusiform aneurysms. Neurosurg Clin N Am. 25(3):471-84, 2014
4. Förster A et al: Fluid Attenuated Inversion Recovery Vascular Hyperintensities Possibly Indicate Slow Arterial Blood Flow in Vertebrobasilar Dolichoectasia. J Neuroimaging. ePub, 2014
5. Takeuchi S et al: Dolichoectasia involving the vertebrobasilar and carotid artery systems. J Clin Neurosci. 16(10):1344-6, 2009

https://CafePezeshki.IR

KEY FACTS

TERMINOLOGY

- Atherosclerotic fusiform aneurysm (ASVD FA)
- ASVD → abnormal dilation, tortuosity of intracranial arteries
- Aneurysms with separate inflow, outflow ostia

IMAGING

- Exaggerated arterial ectasia(s) + focal fusiform/saccular enlargement
  - Long segment irregular fusiform or ovoid arterial dilatation
  - Usually large (> 2.5 cm), may be giant
  - Vertebrobasilar > carotid circulation
- CT: Hyperdense, Ca++ common
- MR: Signal varies flow, presence/age of hematoma
  - Lumen, intramural clot often heterogeneous
  - Residual lumen enhances, intramural clot does not
  - Prominent phase artifact common
- Noncontrast 3D TOF inadequate due to flow saturation, phase dispersion
- Dynamic contrast-enhanced MRA for aneurysm delineation, T2 for brainstem delineation

CLINICAL ISSUES

- Peak age: 7th to 8th decades
- Presentation
  - Ischemic stroke > compressive symptoms (cranial neuropathy)
    - Ranges from TIA to catastrophic pontine ischemia, "locked-in" syndrome
- Unlike saccular aneurysms, rupture with subarachnoid hemorrhage (SAH) and headache rare

DIAGNOSTIC CHECKLIST

- DSA or contrast-enhanced CTA/MRA necessary to delineate patent lumen
- Slow/complex flow in residual lumen → heterogeneous signal
- Consider dissecting aneurysm, non-ASVD etiology if younger patient

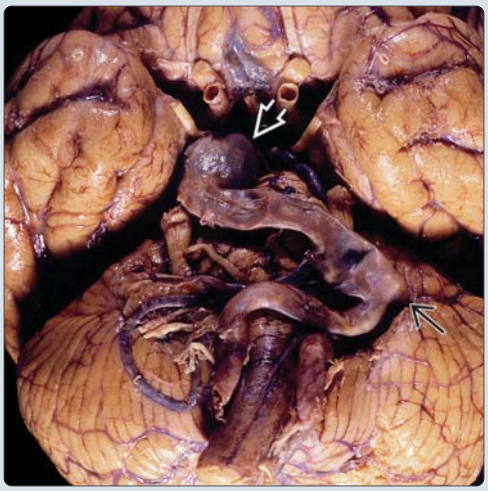

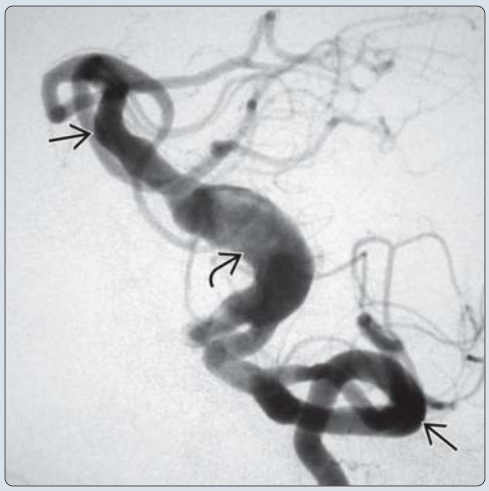

(Left) *Autopsy shows a very tortuous vertebrobasilar artery with an atherosclerotic fusiform aneurysm that extends from the vertebral artery junction ⇨ to the distal basilar bifurcation ⇨. (Courtesy R. Hewlett, M.D.)* **(Right)** *Oblique DSA in the same patient 2 years later shows dolichoectasia of the proximal distal vertebral arteries ⇨. A fusiform ASVD aneurysm lies between the arterial ectasias. The residual lumen is indicated ⇨. The aneurysm had enlarged but also partially thrombosed, leading to mild TIAs.*

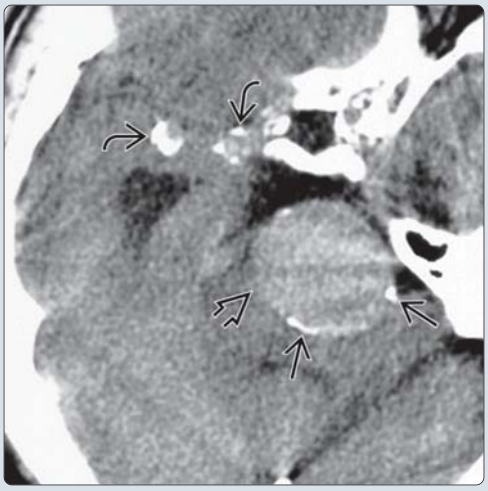

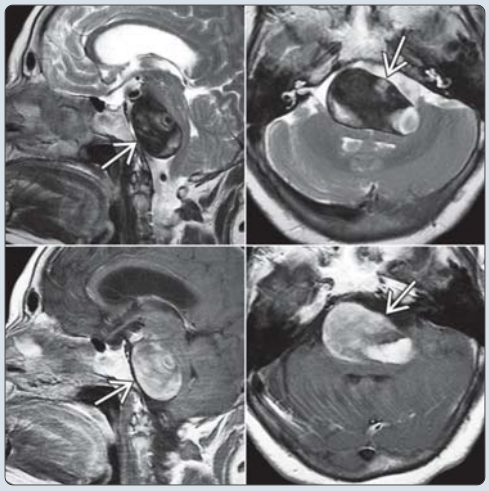

(Left) *NECT scan shows typical hyperdense atherosclerotic fusiform aneurysm ⇨ with mural calcifications ⇨. Note extensive calcification of the internal carotid, right middle cerebral arteries ⇨.* **(Right)** *Series of MR images shows the bizarre appearance of classic atherosclerotic fusiform vertebrobasilar aneurysm ⇨. (Courtesy M. Hartel, MD.)*

https://CafePezeshki.IR

TERMINOLOGY

Abbreviations

- Atherosclerotic fusiform aneurysm (ASVD FA)

Synonyms

- Giant fusiform aneurysm, megacolichobasilar artery

Definitions

- ASVD → abnormal dilation, tortuosity of intracranial arteries
  - Aneurysms with separate inflow, outflow ostia

IMAGING

General Features

- Best diagnostic clue
  - Long segment fusiform/ovoid arterial dilatation
- Location
  - Vertebrobasilar > carotid circulation
- Size
  - Usually large (> 2.5 cm), may be giant
- Morphology
  - Solitary/multifocal generalized dolichoectasia
  - Focal fusiform aneurysmal dilatation

CT Findings

- NECT
  - Hyperdense thrombus, isodense residual lumen
    - Ca++ common
- CECT
  - Residual lumen enhances; intramural clot does not
- CTA
  - Exaggerated arterial ectasia(s) + focal fusiform enlargement

MR Findings

- T1WI
  - Signal varies with degree of flow, presence/age of hematoma
- T2WI
  - Lumen, intramural clot often hypointense but heterogeneous
- T1WI C+
  - Residual lumen enhances intensely
    - Prominent phase artifact common
- MRA
  - Noncontrast 3D TOF inadequate due to slow flow, saturation, phase dispersion effects

Imaging Recommendations

- Best imaging tool
  - Dynamic contrast-enhanced MRA or CTA
- Protocol advice
  - Dynamic contrast-enhanced MRA
  - T2, DWI (brainstem compression/edema, infarcts)

DIFFERENTIAL DIAGNOSIS

Atherosclerotic Dolichoectasia

- No focal fusiform/saccular dilatation

Giant Serpentine Aneurysm (GSA)

- Large, partially thrombosed mass with layered clot, no definable neck
- More common in MCA or PCA

Nonatherosclerotic Fusiform Vasculopathy

- Younger patient (inherited vasculopathy, immune disorder)

Dissecting Aneurysm

- Vertebral > basilar artery
- Lacks changes of ASVD in other vessels

PATHOLOGY

General Features

- Etiology
  - ASVD usual cause of basilar FA in older adults

Gross Pathologic & Surgical Features

- Generalized ASVD with focally dilated fusiform arterial ectasia(s)
- Thickened intima, intramural/intraluminal thrombus

CLINICAL ISSUES

Presentation

- Most common signs/symptoms
  - Ischemic stroke > compressive symptoms (cranial neuropathy)
    - Ranges from TIA to catastrophic pontine ischemia, "locked-in" syndrome
  - Unlike saccular aneurysms, rupture with subarachnoid hemorrhage (SAH) and headache rare

Demographics

- Peak age: 7th to 8th decades

Natural History & Prognosis

- After formation, ASVD FAs have aggressive growth course
  - Progressive enlargement, thrombosis → ↑ TIAs, stroke
  - Steady worsening of presenting signs, symptoms

Treatment

- Endovascular: Coils, flow-diverting stents (e.g., pipeline)

DIAGNOSTIC CHECKLIST

Consider

- Dissecting aneurysm, non-ASVD etiology if younger patient

Image Interpretation Pearls

- Slow/complex flow → heterogeneous signal
- DSA or contrast-enhanced CTA/MRA to delineate patent lumen

SELECTED REFERENCES

1. Serrone JC et al: Vertebrobasilar fusiform aneurysms. Neurosurg Clin N Am. 25(3):471-84, 2014
2. Graziano F et al: Vertebro-basilar junction aneurysms: a single centre experience and meta-analysis of endovascular treatments. Neuroradiol J. 27(6):732-41, 2014
3. Yuh SJ et al: Dolichoectasia of the vertebral basilar and internal carotid arteries: A case report and literature review. Surg Neurol Int. 4:153, 2013

https://CafePezeshki.IR

KEY FACTS

TERMINOLOGY

- Fusiform elongations occurring in absence of generalized intracranial ASVD
  - Usually caused by inherited/acquired vasculopathy

IMAGING

- General features
  - Long segment of tubular, fusiform, or ovoid arterial dilatation
  - Can be solitary or multifocal
  - Carotid, vertebrobasilar equally affected
  - Multiple lesions common
- CT
  - Hyperdense; Ca++ common
  - Strong, uniform enhancement (unless significant thrombus)
- MR
  - Mixed signal intensity (varies with flow, presence/age of hematoma)
  - May require dynamic contrast-enhanced MRA for accurate delineation
  - T2WI delineates outer wall of aneurysm and intraluminal or mural thrombus
  - DWI may show restriction from distal embolic complications
- CTA, DSA, MRA
  - Elongated, ectatic vessel ± more focal aneurysmal outpouching
  - Long, nonbranching vessel segments

PATHOLOGY

- Etiology
  - Collagen vascular disorders (i.e., SLE)
  - Viral, other infectious agents (e.g., varicella, HIV)
  - Inherited (e.g., Marfan, Ehlers-Danlos, neurofibromatosis type 1)
  - Drug abuse, neoplasm (e.g., atrial myxoma)

(Left) *Dissected circle of Willis in a hemophiliac child with HIV shows nonatherosclerotic fusiform vasculopathy involving multiple vessels, most striking in the MCAs. (Courtesy L. Rourke, MD.)* **(Right)** *Coronal MIP view of a CTA in a 25-year-old HIV positive man with a history of multiple strokes shows calcific vasculopathy with a fusiform aneurysm of the left distal ICA, proximal ACA, and MCA ➡.*



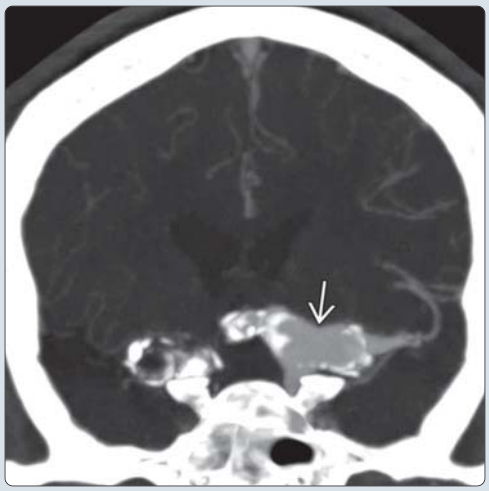

(Left) *Axial T2WI MR in the same patient shows the "flow void" of the left MCA fusiform aneurysm ➡. The right MCA is also enlarged but completely thrombosed ➡. Note encephalomalacia from a remote right MCA territorial infarct ➡.* **(Right)** *Anteroposterior view with SSD of the left carotid DSA in the same patient shows the fusiform aneurysmal vasculopathy ➡.*

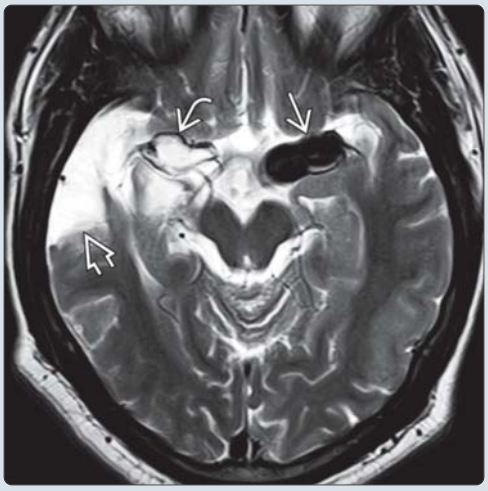

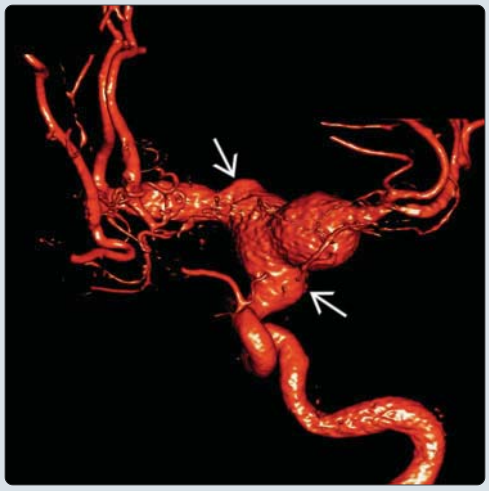

https://CafePezeshki.IR

TERMINOLOGY

Abbreviations

- Non-ASVD fusiform aneurysm/vasculopathy (FA)

Definitions

- Fusiform elongations occurring in the absence of generalized intracranial ASVD
  - Usually caused by inherited/acquired vasculopathy

IMAGING

General Features

- Best diagnostic clue
  - Long segment tubular, fusiform, or ovoid arterial dilatation(s)
- Location
  - Long, nonbranching vessel segments
    - Carotid, vertebrobasilar equally affected
    - Multiple lesions common

CT Findings

- NECT
  - Hyperdense; Ca++ common
- CECT
  - Lumen enhances strongly, clot does not

MR Findings

- T1WI
  - Elongated, tortuous flow void
  - Mixed signal intensity common, varies with
    - Flow velocity, direction, turbulence
    - ± clot (laminated layers of organized thrombus)
- T2WI
  - Mixed signal intensity (varies with flow, presence/age of hematoma)
- FLAIR
  - Slow flow can be hyperintense
- DWI
  - May show restriction from distal embolic complications
- T1WI C+
  - Residual lumen enhances strongly
- MRA
  - May require dynamic contrast-enhanced MRA for accurate lumen delineation

Angiographic Findings

- DSA
  - Solitary/multifocal ectasias, ± focal aneurysmal outpouchings

Imaging Recommendations

- Best imaging tool
  - CTA or MR + contrast-enhanced MRA

DIFFERENTIAL DIAGNOSIS

Vertebrobasilar Dolichoectasia

- Older patient with ASVD in other cranial vessels

Giant Serpentine Aneurysm

- Large, partially thrombosed mass

Atypical Saccular Aneurysm

- Looks identical to fusiform aneurysm

Pseudoaneurysm

- May look identical to fusiform aneurysm

PATHOLOGY

General Features

- Etiology
  - Collagen vascular disorders (i.e., SLE)
  - Viral, other infectious agents (e.g., varicella, HIV)
  - Drug abuse, neoplasm (e.g., atrial myxoma)
  - Inherited (e.g., Marfan, Ehlers-Danlos, neurofibromatosis type 1)

Staging, Grading, & Classification

- Type 1: Typical dissecting aneurysm
- Type 2: Segmental ectasias due to viral, neurocutaneous syndrome, radiation
- Type 3: Dolichoectatic dissecting aneurysms
- Type 4: Atypically located saccular aneurysm (i.e., lateral wall, unrelated to branching zones)

Gross Pathologic & Surgical Features

- Focally dilated fusiform arterial ectasia(s)

CLINICAL ISSUES

Presentation

- Most common signs/symptoms
  - Pain, SAH > TIA, cranial neuropathy in dissection from collagen disorder etiology
  - Commonly asymptomatic or TIA/stroke in viral and neurocutaneous etiology

Natural History & Prognosis

- Type 1: Rebleed common
- Type 2: Benign clinical course
- Type 3: Slow but progressive enlargement
- Type 4: Rerupture risk high

Treatment

- Dependent upon underlying cause, expected natural history, location, and anatomy
- Often combined surgical, endovascular measures

DIAGNOSTIC CHECKLIST

Consider

- Non-ASVD fusiform aneurysm in young patient with dilated intracranial vessels

SELECTED REFERENCES

1. Arentzen M et al: Cerebrovascular events in HIV-infected patients: an analysis of a cohort of 3203 HIV+ patients during the times of cART. Int J Neurosci. ePub, 2014
2. Delgado Almandoz JE et al: Successful endovascular treatment of three fusiform cerebral aneurysms with the Pipeline Embolization Device in a patient with dilating HIV vasculopathy. J Neurointerv Surg. 6(2):e12, 2014
3. Nanney AD 3rd et al: Intracranial aneurysms in previously irradiated fields: literature review and case report. World Neurosurg. 81(3-4):511-9, 2014
4. Bonkowsky J et al: Cerebral vasculopathy with aneurysm formation in HIV-infected young adults. Neurology. 68(8):623; author reply 623, 2007

https://CafePezeshki.IR

KEY FACTS

TERMINOLOGY

- Blood blister-like aneurysm (BBA)
  - Broad-based bulge at nonbranch point

IMAGING

- Half-dome or blood blister-like shape
- Supraclinoid internal carotid artery (ICA) most common site
  - Rarely MCA, ACA, ACoA, basilar artery
  - Usually small (< 6 mm; mean: 3 mm)
- NECT: Subarachnoid hemorrhage (SAH)
- CTA: Frequently subtle so CTA often called negative
- Best imaging tool: High-resolution DSA
  - Obtain multiple obliques ± 3D DSA

TOP DIFFERENTIAL DIAGNOSES

- Saccular aneurysm (SA)
- Vasospasm
- Atherosclerotic vascular disease (ASVD)
- Vessel infundibulum

PATHOLOGY

- Focal arterial wall defect covered with fibrous tissue
  - ± thin layer of adventitia (pseudoaneurysm)

CLINICAL ISSUES

- Middle-aged patient often with angiogram negative SAH
- Fragile, difficult to treat
  - BBAs tend to rupture earlier, at smaller size than SA
  - Higher rebleed rate compared to SA
  - High risk of BBA rupture, ICA laceration during surgery
  - Small size, wide-neck make coiling difficult
  - Flow-diverter stents often preferred

DIAGNOSTIC CHECKLIST

- Angiogram negative SAH may be caused by BBA
- Look for subtle dome or bulging of supraclinoid ICA when SA is not seen in patient with SAH

(Left) *Sagittal graphic shows a blood blister-like aneurysm (BBA) arising from the dorsal (superolateral) wall of a supraclinoid internal carotid artery (ICA). The BBA is covered only by a thin fibrous wall.* **(Right)** *Reformatted lateral view of the CTA in a patient with subarachnoid hemorrhage (SAH) on NECT scan shows a small broad-based contrast-filled hemispheric bulge along the greater curvature of the ICA. (Courtesy C. D. Phillips, MD.)*

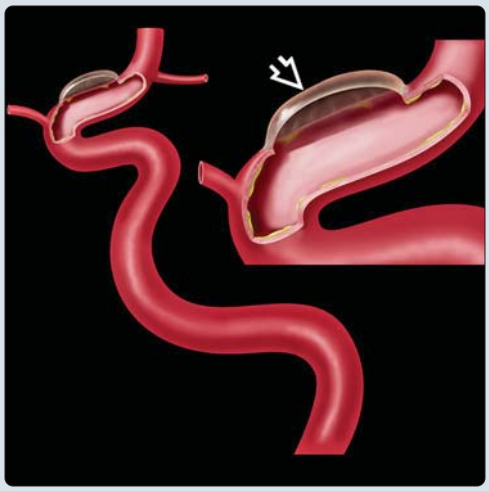

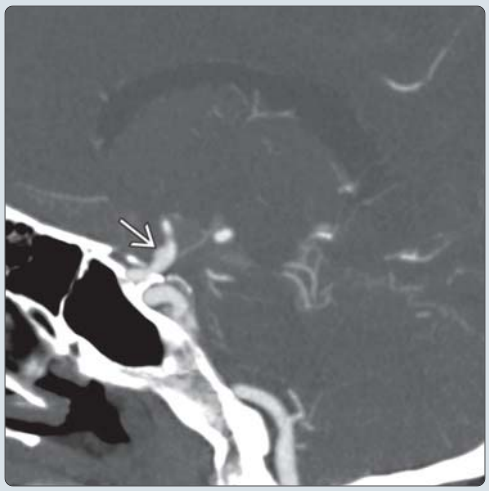

(Left) *Lateral DSA in the same patient shows the classic appearance of a blood blister-like aneurysm and confirms the CTA finding of a focal broad-based hemispheric bulge.* **(Right)** *Lateral right ICA DSA shows a small hemispherical bulge along the ventral paraclinoid ICA in a patient with SAH. Adjacent irregularity of the ICA lumen more distally likely reflects associated dissection or ASVD. There is vasospasm involving the ACA and a PCoA infundibulum.*

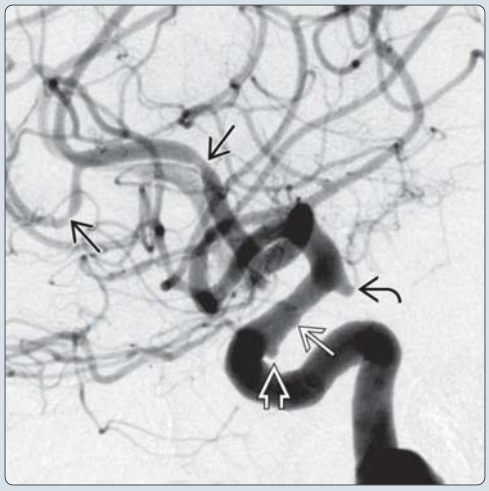

https://CafePezeshki.IR

TERMINOLOGY

Abbreviations

- Blood blister-like aneurysm (BBA)

Definitions

- Broad-based bulge at nonbranch point
  - Supraclinoid internal carotid artery (ICA) > > MCA, ACA, basilar artery

IMAGING

General Features

- Best diagnostic clue
  - Small, broad-based, hemispherical bulge on anterosuperior (dorsal) wall of supraclinoid ICA
  - Rapid change in size/morphology on follow-up angiograms
- Location
  - Nonbranching sites on supraclinoid ICA most common (dorsal wall > ventral)
  - MCA (M1), ACA (A1), anterior communicating artery, basilar artery (rare)
- Size
  - Usually small (< 6 mm; mean: 3 mm)
- Morphology
  - Half-dome or blood blister-like shape

CT Findings

- NECT
  - Aneurysmal subarachnoid hemorrhage (aSAH)
- CTA
  - ± asymmetric bulging of supraclinoid ICA
  - Frequently subtle so CTA often called negative

MR Findings

- FLAIR
  - Hyperintense CSF if SAH present
- MRA
  - ± visualized on high-resolution MRA

Angiographic Findings

- Conventional DSA
  - BBAs often small, subtle
  - Slight irregularity/small focal hemispherical bulge of arterial wall at characteristic location
  - Multiple projections ± 3D DSA helpful

Imaging Recommendations

- Best imaging tool
  - High-resolution DSA
    - Obtain multiple obliques ± 3D DSA

DIFFERENTIAL DIAGNOSIS

Saccular Aneurysm (SA)

- True aneurysm, typically at arterial bifurcation

Vasospasm

- Usually symmetrical, concentric narrowing of vessel

Atherosclerotic Vascular Disease (ASVD)

- Common in patients with BBA, difficult to distinguish

Vessel Infundibulum

- Funnel-shaped vessel origin; < 3 mm
- Common at posterior communicating artery (PCoA), anterior choroidal artery (AChA) origins

PATHOLOGY

General Features

- Etiology
  - ASVD with ulceration, hematoma formation
  - ICA dissection, arteriosclerosis, hypertension

Gross Pathologic & Surgical Features

- Focal arterial wall defect covered with fibrous tissue
  - ± thin layer of adventitia (pseudoaneurysm)

CLINICAL ISSUES

Presentation

- Most common signs/symptoms
  - "Thunderclap" headache 2° to SAH
- Clinical profile
  - Middle-aged patient with angiogram negative SAH

Demographics

- Gender
  - M:F = 1:2
- Epidemiology
  - 1-6% of all intracranial aneurysms resulting in SAH

Natural History & Prognosis

- More aggressive behavior, more intraoperative complications than SA
  - Tends to rupture earlier, at smaller size than SA
  - Higher rebleed rate compared with SA

Treatment

- Fragile, difficult to treat
  - Clipping, wrapping carry high rupture risk
    - BBA avulsion, ICA laceration
    - High risk of BBA rupture during dissection (45%)
- Endovascular
  - Small size, wide-neck make coiling difficult
  - Flow-diverter stents feasible alternative

DIAGNOSTIC CHECKLIST

Image Interpretation Pearls

- Angiogram negative SAH may be caused by BBA
  - Consider early repeat DSA as rebleed risk higher than with typical saccular aneurysm
  - Look for subtle dome or bulging of supraclinoid ICA when SA is not seen in patient with SAH

SELECTED REFERENCES

1. Gonzalez AM et al: Blood blister-like aneurysms: single center experience and systematic literature review. Eur J Radiol. 83(1):197-205, 2014
2. Peschillo S et al: Blister-like aneurysms of middle cerebral artery: a multicenter retrospective review of diagnosis and treatment in three patients. Neurosurg Rev. ePub, 2014

https://CafePezeshki.IR

PART I
SECTION 4

Stroke

Stroke Overview 248

Nontraumatic Intracranial Hemorrhage

Evolution of Intracranial Hemorrhage 254
Spontaneous Nontraumatic Intracranial Hemorrhage 258
Hypertensive Intracranial Hemorrhage 262
Remote Cerebellar Hemorrhage 266
Germinal Matrix Hemorrhage 268

Atherosclerosis and Carotid Stenosis

Intracranial Atherosclerosis 272
Extracranial Atherosclerosis 276
Arteriolosclerosis 280

Nonatheromatous Vasculopathy

Aberrant Internal Carotid Artery 284
Persistent Carotid Basilar Anastomoses 288
Sickle Cell Disease, Brain 290
Moyamoya 294
Primary Arteritis of the CNS 298
Miscellaneous Vasculitis 302
Reversible Cerebral Vasoconstriction Syndrome 306
Vasospasm 308
Systemic Lupus Erythematosus 312
Cerebral Amyloid Disease 316
CADASIL 320
Behçet Disease 324
Susac Syndrome 326
Fibromuscular Dysplasia 328

https://CafePezeshki.IR

Cerebral Ischemia and Infarction

Hydranencephaly	330
White Matter Injury of Prematurity	332
Term Hypoxic Ischemic Injury	336
Adult Hypoxic Ischemic Injury	340
Hypotensive Cerebral Infarction	344
Childhood Stroke	348
Cerebral Hemiatrophy	352
Acute Cerebral Ischemia-Infarction	354
Subacute Cerebral Infarction	358
Chronic Cerebral Infarction	362
Multiple Embolic Cerebral Infarctions	366
Fat Emboli Cerebral Infarction	367
Lacunar Infarction	368
Cerebral Hyperperfusion Syndrome	372
Dural Sinus Thrombosis	376
Cortical Venous Thrombosis	380
Deep Cerebral Venous Thrombosis	384
Dural Sinus and Aberrant Arachnoid Granulations	388

https://CafePezeshki.IR

Introduction

Stroke is a generic term that describes the clinical event of a sudden onset of neurologic deficit secondary to cerebrovascular disease. Stroke has 4 main etiologies, including cerebral infarction (80%), intraparenchymal hemorrhage (15%), nontraumatic subarachnoid hemorrhage (5%), and venous infarction (approximately 1%). Clinically, ischemic infarction is the most common etiology and will be the main topic of this introduction. The principal cause of cerebral infarction is atherosclerosis and its sequelae.

Ischemic Infarction

There are 3 major clinical ischemic stroke subtypes based upon the classification from a multicenter clinical trial (trial of drug ORG 10172 in acute stoke treatment [TOAST]). These 3 subtypes include large artery/atherosclerotic infarctions, cardioembolic infarctions, and small vessel occlusion (lacunar) infarctions.

Large artery/atherosclerotic strokes represent approximately 40% of strokes and can arise from thrombosis at the site of a plaque or from emboli produced at the plaque that lodge downstream. The most common site of atherosclerotic plaque is at the carotid bifurcation with involvement of the distal common carotid artery and the 1st 2 cm of the internal carotid artery. The most frequently occluded intracranial vessel is the middle cerebral artery (MCA). Other common locations for atherosclerotic plaque include the carotid siphon and proximal anterior and middle cerebral arteries. The vertebral and basilar arteries are also commonly involved by atherosclerosis.

Cardioembolic disease accounts for 15-25% of ischemic strokes. Risk factors include myocardial infarction, ventricular aneurysm, atrial fibrillation or flutter, cardiomyopathy, and valvular heart disease.

Lacunar infarcts are small in size (< 15 mm), typically in the basal ganglia and thalamus, and account for 15-30% of all strokes. They are often multiple and are due to embolic, atheromatous, or thrombotic lesions in the single penetrating end arterioles that supply the deep gray nuclei, including the lenticulostriate and thalamoperforating arteries. Other common locations for lacunar infarcts include the internal capsule, pons, and corona radiata.

Intraparenchymal Hemorrhage

Intraparenchymal hemorrhage represents ~ 15% of all strokes and includes multiple etiologies. Hypertensive hemorrhage is the most common etiology, representing ~ 40-60% of all primarily intracranial hemorrhages. Other etiologies include amyloid angiopathy in elderly patients, as well as vascular malformations, vasculitis, drugs, and bleeding diathesis.

Risk factors for hemorrhagic stroke include increasing age, hypertension, smoking, excessive alcohol consumption, prior ischemic stroke, abnormal cholesterol, and anticoagulant medications.

Although the MR physics related to hemorrhage are complex, the stages are generally accepted as hyperacute, acute, early subacute, late subacute, and chronic.

Nontraumatic Subarachnoid Hemorrhage

Nontraumatic subarachnoid hemorrhage is typically related to an aneurysm (75%) or a vascular malformation, such as an arteriovenous malformation or cavernous angioma. Nonaneurysmal "perimesencephalic" subarachnoid hemorrhage is uncommon.

Venous Infarction

Dural sinus or cerebral vein occlusion is rare, representing less than 1% of strokes. Venous thrombosis risk factors include pregnancy, trauma, dehydration, infection, oral contraceptives, coagulopathies, malignancies, collagen vascular diseases, and protein C and S deficiencies. Venous infarcts occur in only ~ 50% of venous thrombosis cases, and can be differentiated from arterial infarcts by the location of the ischemia. Superior sagittal sinus thrombosis typically results in T2/FLAIR hyperintense parasagittal lesions, while thrombosis of the transverse sinus often results in T2/FLAIR hyperintensities in the posterior temporal lobe. Additionally, venous infarcts more commonly present with associated hemorrhage. Contrast-enhanced CT is useful to identify the "empty-δ" sign representing thrombus within a major dural sinus, typically the superior sagittal or transverse sinus.

Approach to Stroke Imaging

Cerebral ischemia results from significantly decreased blood flow to selected areas or the entire brain. Stroke progresses in stages from ischemia to actual infarction. In the most common situation, MCA occlusion, there is a densely ischemic central core and a less densely ischemic "penumbra." The central core is usually irreversibly damaged unless reperfusion is quickly established, whereas the cells within the penumbra may remain viable but at risk for several hours. Current stroke therapies attempt to rescue the "at-risk" cells.

Currently, acute stroke protocols vary among different institutions. The exact protocol is often based on the availability of CT vs. MR, technology/software, time of stroke, physician expertise, and the possibility of neurointervention. Typically, stroke neurologists work with neuroradiologists to devise a plan that best serves the patient's needs.

Most stroke protocols begin with a noncontrast head CT to evaluate for hemorrhage or mass, which directly affects treatment decisions. Additionally, > 1/3 MCA territory hypodensity at presentation is considered by most to be a contraindication to thrombolysis, as it is associated with a greater risk of fatal hemorrhage. CTA is useful to evaluate for large vessel occlusion. When available, CT perfusion is an excellent way to evaluate for large vessel ischemia.

MR with diffusion-weighted imaging (DWI) is particularly useful for acute ischemia when CT perfusion is negative and the clinical suspicion for stroke remains. MR is also the primary imaging tool when the clinical question includes a posterior fossa or brainstem lesion. MR with perfusion imaging (PWI) has been found extremely helpful in guiding therapy when available.

Most stroke protocols use 3-hour and 6-hour windows for treatment of nonhemorrhagic ischemic stroke. If the patient presents within 6 hours after the initial onset of symptoms, an unenhanced CT is typically the initial study of choice to exclude a mass or hemorrhage. If there is a hemorrhage or mass, no thrombolytic therapy is initiated. If there is no hemorrhage or mass and the patient is within 3 hours after onset of symptoms, the patient is eligible for intravenous (IV) thrombolysis. If the patient is between 3 and 6 hours of onset, either a CTA with CT perfusion or an MR with DWI and PWI is performed to determine if they are eligible for treatment. If the patient has an intracranial thrombus with a penumbra,

https://CafePezeshki.IR

Five Stages of Intraparenchymal Hemorrhage

Stage	Time (Range)	Blood Products	T1	T2
Hyperacute	< 24 hours	Oxyhemoglobin	Isointense	Bright
Acute	1-3 days (hours to days)	Deoxyhemoglobin	Isointense	Dark
Early subacute	> 3 days (days to 1 week)	Intracellular methemoglobin	Bright	Dark
Late subacute	> 7 days (1 week to months)	Extracellular methemoglobin	Bright	Bright
Chronic	> 14 days (≥ months)	Hemosiderin	Dark	Dark

intraarterial (IA) thrombolysis or IA thrombectomy is recommended. If there is no penumbra, IA therapy may not benefit the patient, so each case is evaluated individually.

The effective therapeutic window for the posterior circulation is thought to be longer than the 3-6-hour window, but the exact time is variable and depends on collateral circulation. Therefore, patients with vertebrobasilar thrombosis are evaluated individually for risk vs. benefit of IA thrombolysis or thrombectomy.

Ischemic Penumbra

Ischemic stroke results in a core of tissue that has undergone irreversible injury. The ischemic penumbra is the area of brain that may be salvageable with appropriate therapy. The penumbra typically surrounds the ischemic core and is supported by collateral circulation.

The ischemic penumbra can be identified by a combination of MR diffusion (DWI) and perfusion imaging (PWI). DWI is the most reliable estimate of the ischemic core and generally correlates with irreversible injury. However, with early reperfusion following thrombolysis, some reversal of DWI can be observed. PWI evaluates the presence of a penumbra. With MR, the mismatch between the DWI and PWI defines the penumbra. This model provides a practical means to estimate the ischemic penumbra. In general, if there is no diffusion/perfusion mismatch, therapy may be ineffective.

With the newer CT perfusion techniques, an ischemic penumbra may also be measured with CT.

With the urgency of acute stroke, MR may be impractical. However, with new faster MR protocols and the superiority of MR to CT in detecting small vessel ischemia and brainstem ischemia, MR may be a preferred technique.

CT Perfusion (pCT)

Cerebral perfusion refers to the tissue-level blood flow in the brain. This flow is evaluated by 3 main parameters at pCT: Cerebral blood flow (CBF), cerebral blood volume (CBV), and mean transit time (MTT).

CBF is defined as the volume of blood moving through a given unit volume of brain per unit time. CBF uses units of milliliters of blood per 100 g of brain tissue per minute. Studies suggest that CBF is a reasonable marker for the ischemic penumbra.

CBV is defined as the total volume of blood in a given unit volume of brain. This includes blood in the tissues as well as blood in the large-capacitance vessels, such as arteries, arterioles, capillaries, venules, and veins. CBV uses units of milliliters of blood per 100 g of brain tissue. Some studies suggest that CT perfusion-acquired CBV is a reasonably reliable marker of the ischemic core.

MTT is defined as the average of the transit time of blood through a given brain region. The transit time of blood through the brain parenchyma varies depending on the distance traveled between arterial inflow and venous outflow. MTT equals CBV/CBF.

CBF/CBV mismatch correlates with stroke enlargement in untreated or unsuccessfully treated patients. Those patients with a CBF/CBV match or those with early complete recanalization do not exhibit progression of the ischemic stroke.

The general treatment guidelines for pCT are as follows. If there is a CBF/CBV mismatch, with a larger CBF suggesting an ischemic penumbra, the patient is likely a good candidate for therapy. Many treatment guidelines suggest that a ≥ 20% CBF/CBV mismatch should be present to consider thrombolysis. Some authors propose that if there is no mismatch between CBV and CBF, treatment is unlikely to benefit the patient.

CT Perfusion Interpretation Pearls

The MTT is the most sensitive parameter for perfusion deficits. Although it is generally elevated due to a thromboembolic process, it may be elevated in a patient with significant arterial atherosclerotic narrowing. In early ischemia, MTT is elevated and CBF is decreased. However, the CBV can be preserved or even elevated due to capillary bed dilatation in very early ischemia. Once a CBF threshold is reached, CBV starts to decline. This results in the ischemic core, which has a matched decrease in CBF and CBV, whereas a mismatch between CBF and CBV suggests a penumbra.

Differential Diagnosis

When considering **stroke** in a **child** or **young adult**, several possible etiologies should be addressed, including arterial dissection, vascular malformation with hemorrhage, drug abuse, or clotting disorder. In **young children**, other possibilities include congenital heart disease with emboli and idiopathic progressive arteriopathy of childhood (moyamoya disease).

In a middle-aged or older **adult**, the typical stroke etiologies include arterial thromboembolism, hypertensive hemorrhage, and cerebral amyloid angiopathy.

When evaluating a **hemorrhagic stroke**, etiologies in **children** include vascular lesions, hematologic disorder, vasculopathy, and venous infarct. In a **young adult**, considerations include vascular malformations, drug abuse, and less commonly venous occlusions or vasculitis. In **older adults**, common considerations for intracranial hemorrhage include hypertensive hemorrhage, neoplasm, cerebral amyloid angiopathy, and, less commonly, dural sinus/cerebral venous occlusion and coagulopathy.

https://CafePezeshki.IR

(Left) *Graphic shows the cortical MCA distribution in red. MCA distribution typically involves the majority of the lateral surface of the hemisphere, including the frontal, temporal, and parietal lobes. In addition, the majority of the lenticulostriate arteries arise from the M1 segment and supplies the basal ganglia.* **(Right)** *Axial CT shows a large left MCA distribution infarct ➡ with involvement of the basal ganglia ⇨, indicating involvement of the lenticulostriate perforating arteries, which typically arise from the M1 segment.*

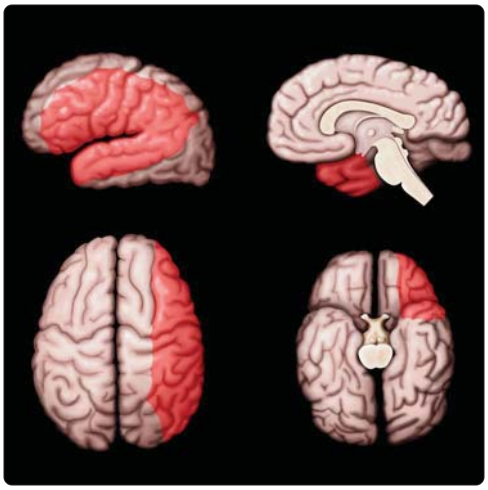

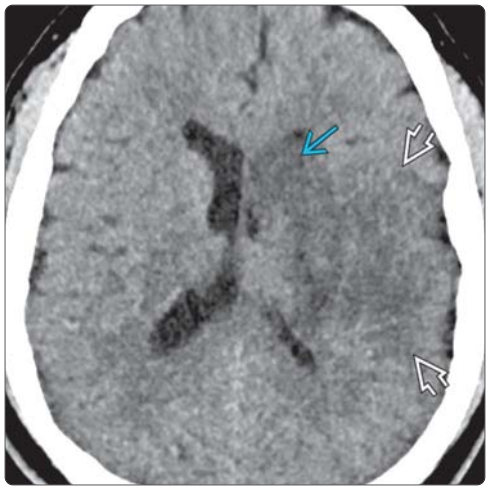

(Left) *Graphic shows the ACA cortical vascular territories in green. The ACA supplies the medial anteroinferior frontal lobe, the anterior 2/3 of the medial hemisphere surface, and a variable amount of territory over the cerebral convexity. The corpus callosum is also typically supplied primarily by the ACA branches: Callosal perforating, pericallosal, and posterior splenial branches.* **(Right)** *Axial DWI MR shows diffusion restriction in the left ACA distribution ➡ within the medial parafalcine frontal lobe.*

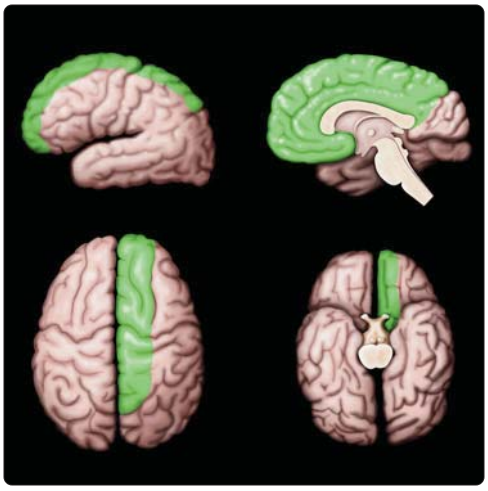

(Left) *Graphic shows the typical PCA vascular territory, including the occipital lobes, inferior temporal lobes, and medial posterior 1/3 of the interhemispheric brain. Patients with PCA ischemia most commonly present with visual complaints. Large vessel/atherosclerotic strokes represent ~ 40% of strokes. The carotid bifurcation is the most common site of atherosclerotic plaque.* **(Right)** *Axial DWI MR shows diffusion restriction ⇨ in the occipital lobe related to PCA ischemia. DWI is the most sensitive MR sequence for acute ischemia.*

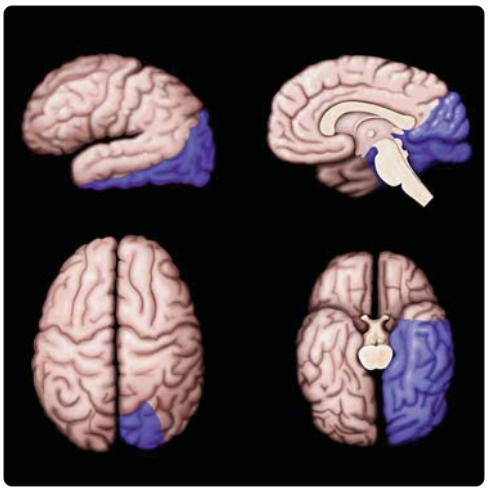

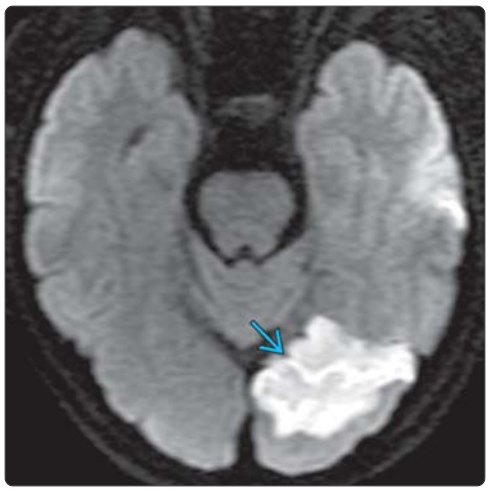

https://CafePezeshki.IR

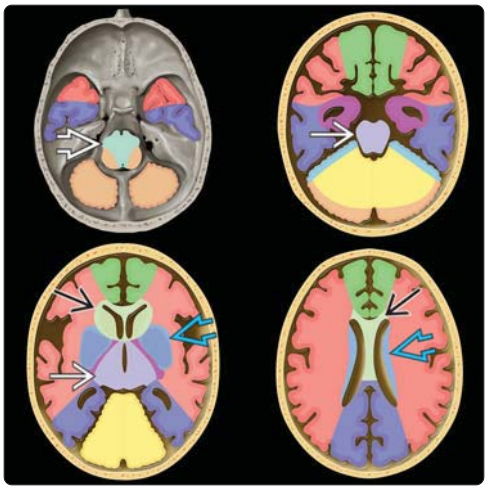

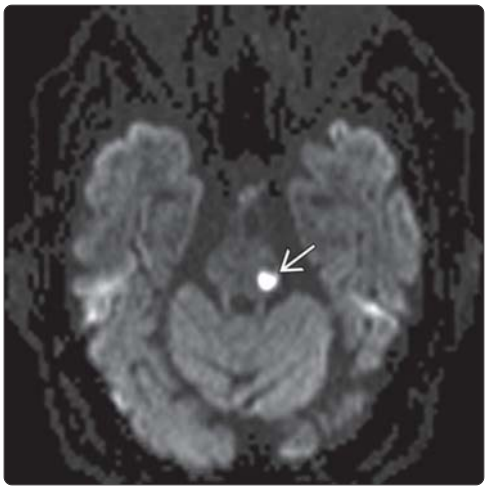

(Left) *Axial graphic shows the major penetrating artery distributions. The pontine and thalamic perforating arteries ➡, as well as the medullary perforators ➡, arise from the vertebrobasilar system. The medial ➡ and lateral ➡ lenticulostriate arteries arise from the anterior circulation and supply the basal ganglia. The choroidal arteries are shown in magenta.* **(Right)** *Axial DWI MR shows diffusion restriction related to acute ischemia ➡ in a pontine-perforating artery distribution.*

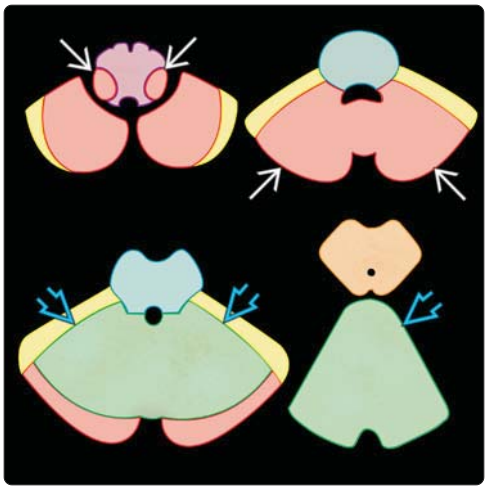

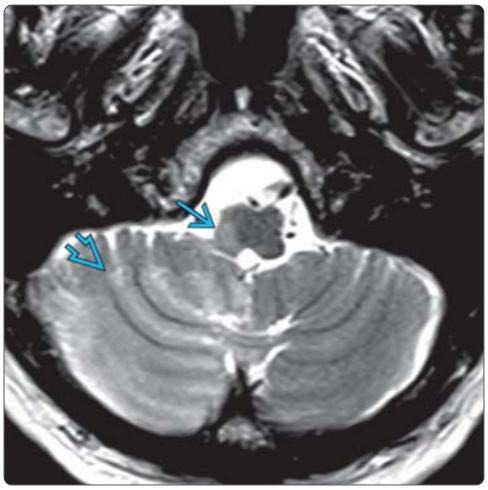

(Left) *Axial graphic shows the cerebellar artery distributions. The superior cerebellar artery (SCA) ➡ (green) supplies the superior cerebellum. The posterior inferior cerebellar artery (PICA) (peach) ➡ supplies the majority of the inferior cerebellum and lateral medulla. The anterior inferior cerebellar artery (AICA) (yellow) supplies the petrosal surface of the cerebellum.* **(Right)** *Axial T2WI MR shows hyperintensity in the right inferior cerebellum ➡ and lateral medulla ➡ related to a PICA infarct from a vertebral artery embolus.*

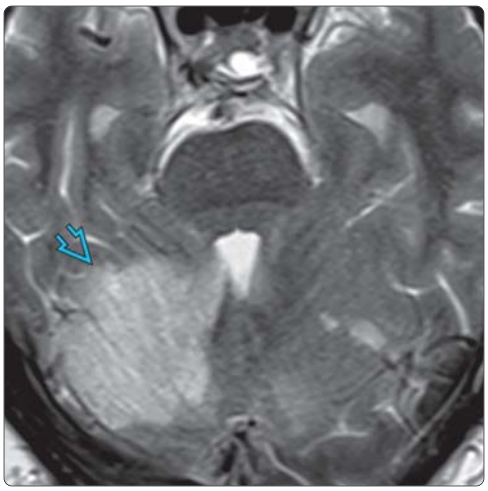

(Left) *Axial T2WI MR shows hyperintensity and local mass effect in the right superior cerebellum ➡ related to an acute SCA infarct. SCA infarcts may involve the superior cerebellum and the upper lateral pons.* **(Right)** *Axial DWI MR image shows acute diffusion restriction ➡ in the anterior, inferior cerebellum laterally in an AICA distribution. AICA primarily supplies the ventral pons and petrosal surface of the cerebellar hemispheres, the brachium pontis, flocculus, and inner ear as well as CN7 and CN8.*

https://CafePezeshki.IR

(Left) *Whole brain graphics show the major arterial supply to the hemispheres. The MCA (red) supplies the lateral aspects of the frontal and temporal lobes. The ACA (green) supplies the medial hemispheres. The PCA (purple) supplies the occipital lobes and inferior temporal lobes. The watershed zone ⇨ is the border between the major vascular territories.* **(Right)** *Axial DWI MR shows restriction in left MCA territory with preservation of the basal ganglia. The MCA territory is the most common location for ischemic stroke.*

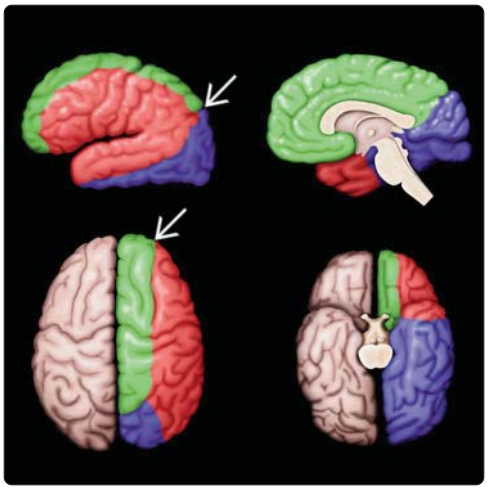

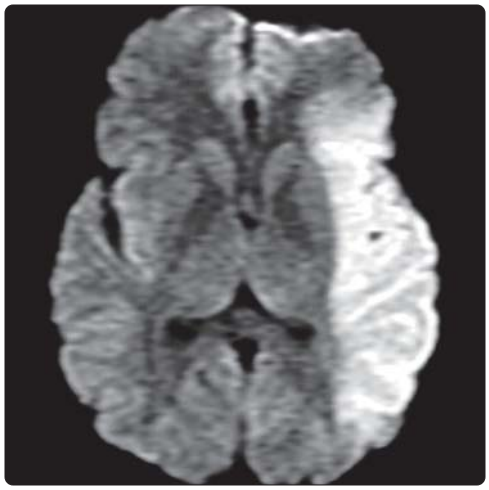

(Left) *Axial CT perfusion CBF color map shows a large area of decreased blood flow ⇨ in the left hemisphere related to hyperacute MCA ischemia.* **(Right)** *Axial CT perfusion CBV color map in the same patient shows a much smaller area of decreased blood volume ⇨. The CBV is a marker for the ischemic core. This CBF/CBV mismatch correlates with the presence of a large ischemic penumbra, which suggests the patient would benefit from intraarterial thrombolytic therapy or clot retrieval.*

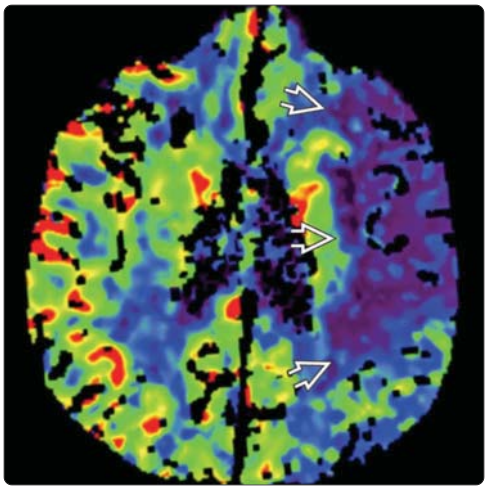

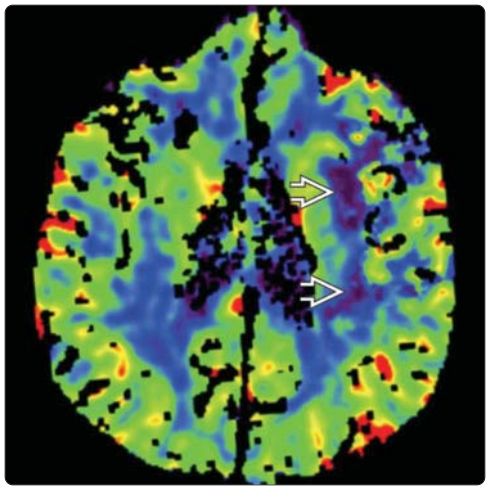

(Left) *Lateral gross pathology shows a chronic MCA infarct with hemorrhage and encephalomalacia in the frontal operculum ⇨ and temporal lobe ⇨.* **(Right)** *Axial FLAIR MR shows multiple hyperintense foci ⇨ in the watershed zones between the major cerebral artery territories (MCA, PCA, and ACA) related to acute ischemia from hypoperfusion. The posterior confluence where all 3 vascular distributions meet together at the vertex ⇨ is especially vulnerable to cerebral hypoperfusion.*

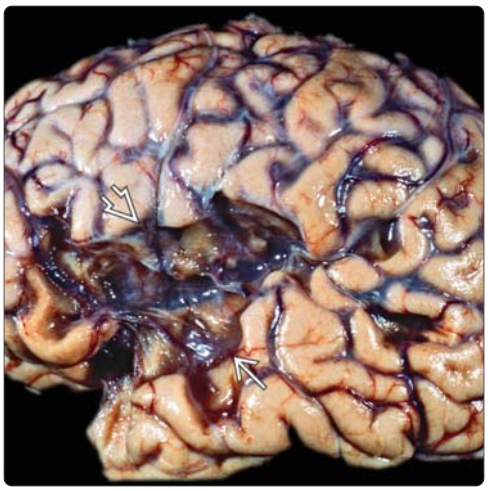

https://CafePezeshki.IR

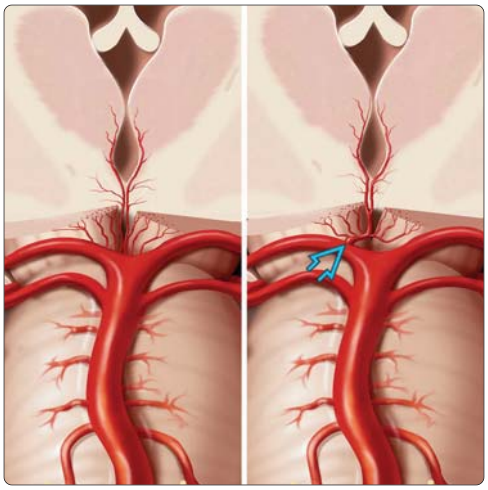

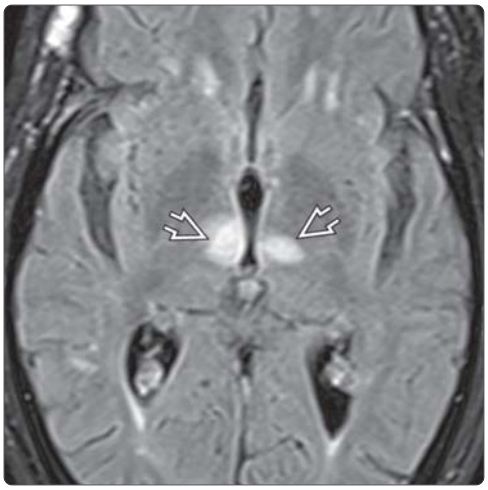

(Left) *Coronal oblique graphic of the rostral basilar artery shows (left panel) the typical arterial supply to the medial thalami by multiple PCA and basilar tip perforators. Right panel shows the anatomic variant, artery of Percheron ⇨, in which a single large perforating artery from P1 supplies bilateral thalami and the medial midbrain.* **(Right)** *Axial FLAIR MR shows hyperintensity in the bilateral medial thalami ⇨ related to an acute artery of Percheron infarct. Extension to the medial midbrain is often present.*

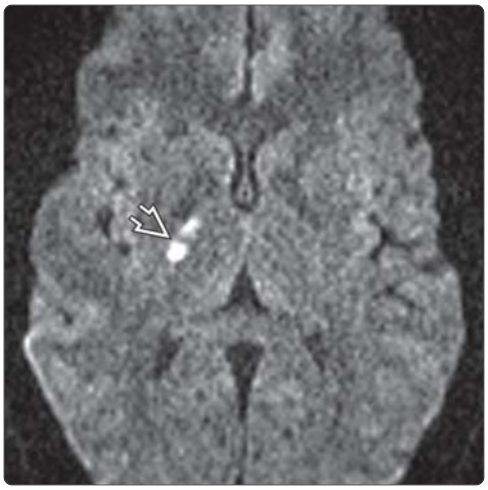

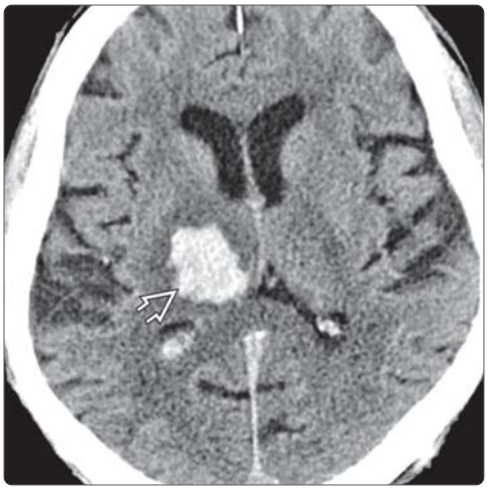

(Left) *Axial DWI MR shows hyperintensity related to acute ischemia in the posterior limb of the internal capsule ⇨ in an anterior choroidal artery distribution. The anterior choroidal artery typically supplies the lateral midbrain, uncus, thalamus, posterior limb of internal capsule, and the optic tract. The posterior choroidal artery typically supplies the pulvinar, thalamus, medial temporal lobe, splenium, and choroid plexus.* **(Right)** *Axial CT shows a classic thalamic hypertensive hemorrhage ⇨, the 2nd most common cause of stroke.*

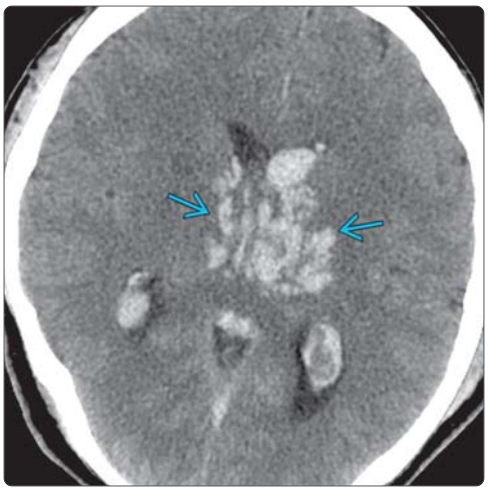

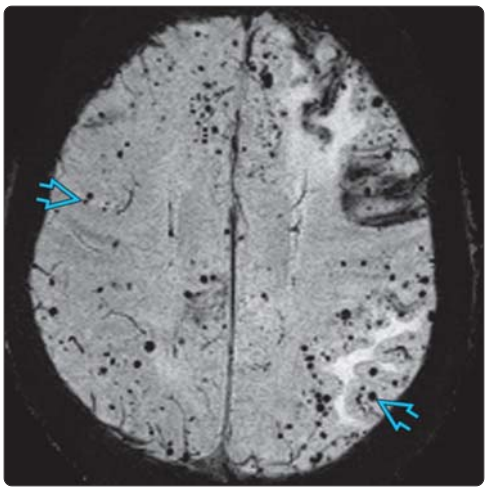

(Left) *Axial CT shows bilateral thalamic hemorrhage ⇨ related to deep venous thrombosis. Venous thrombosis risk factors include pregnancy, trauma, dehydration, infection, oral contraceptives, coagulopathies, malignancies, collagen vascular diseases, and protein C and S deficiencies.* **(Right)** *Axial SWI MR image in an elderly patient shows extensive susceptibility artifact related microhemorrhages ⇨ in the bilateral hemispheres. Pattern is typical of cerebral amyloid angiopathy.*

https://CafePezeshki.IR

KEY FACTS

IMAGING

- Hyperdense (50-70 HU) mass on CT; peripheral edema develops over 1st days
- Hematoma matures more slowly in center (core) than in periphery
- MR: Intracranial hemorrhage staging based on T1 and T2 signal characteristics
  - MR as sensitive as CT in hyperacute phase and more sensitive in subacute and chronic phase
  - MR signal change proceeds peripherally to centrally

PATHOLOGY

- Very common: Hypertension (HTN), cerebral amyloid angiopathy, trauma, hemorrhagic vascular malformations
- Common: Infarct with reperfusion, coagulopathy, blood dyscrasia, drug abuse, tumor (glioma, metastases)

CLINICAL ISSUES

- Incidence: ~ 30-40 per 100,000
- HTN, ↑ age most important risk factors
- Prognosis depends on size, initial level of consciousness, and location
  - 35-52% dead at 1 month (50% of whom died in first 2 days); 59% dead at 1 year
- Intracerebral hematoma (ICH) with warfarin use correlates with higher mortality (2x as high at 3 months)
- Rate of anticoagulant-related ICH has increased over last decades (up to 20%)
- HTN (90%), vomiting (50%), ↓ consciousness (50%), headache (40%), seizures (10%)

DIAGNOSTIC CHECKLIST

- Marked heterogeneity of acute hematoma on CT predicts hematoma growth and ↑ mortality
- Swirl sign, contrast extravasation, and enhancement indicate hematoma growth and ↑ mortality
- Fluid-fluid levels → question of underlying coagulopathy

(Left) *Axial graphic shows the evolution of parenchymal hemorrhage from hyperacute ⇨ (intracellular oxy-Hgb) to acute ➡ (intracellular deoxy-Hgb with surrounding edema) . Early ⇨ and late subacute (intra- and extracellular met-Hgb respectively) are followed by a chronic cystic cavity ⇨ with a hemosiderin stain.* **(Right)** *Axial NECT shows a hyperdense mass related to an acute left cerebellar hemorrhage ➡ with minimal surrounding edema in a patient with hypertension.*

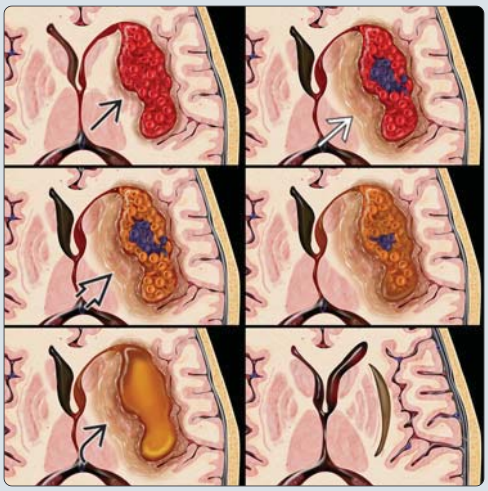

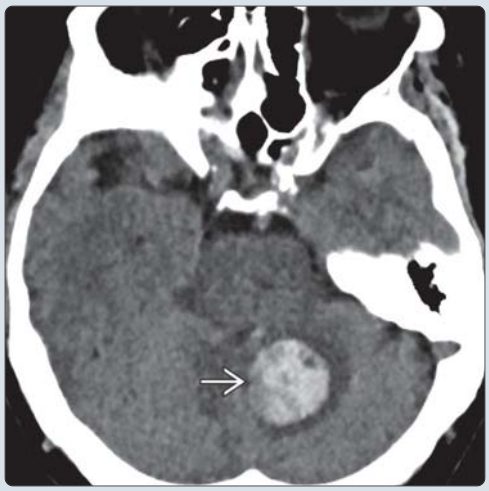

(Left) *Axial T1WI MR in the same patient shows the cerebellar hemorrhage ➡ is predominantly isointense and mildly hypointense to the surrounding brain parenchyma, indicating hyperacute blood products.* **(Right)** *Axial T2WI MR in the same patient shows the hyperacute hemorrhage to be hyperintense to the surrounding brain parenchyma with a peripheral hypointense rim ⇨. Intraparenchymal hemorrhage evolves from peripheral to central with the central core maturing more slowly.*

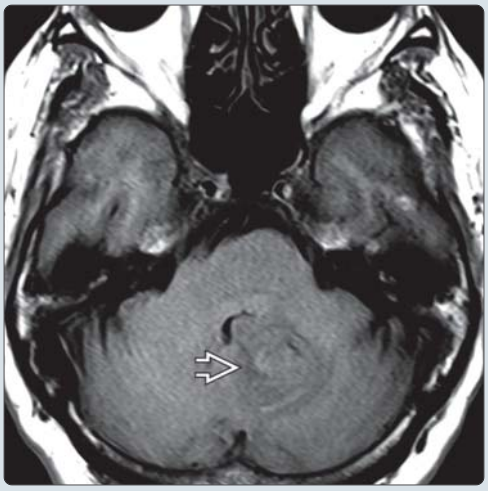

https://CafePezeshki.IR

TERMINOLOGY

Abbreviations

- Intracerebral hematoma (ICH)

Synonyms

- Intraparenchymal hemorrhage

IMAGING

General Features

- Best diagnostic clue
  - Hyperdense (50-70 HU) mass on CT; peripheral edema develops over 1st few days
  - Hematoma matures more slowly in center (core) than in periphery
  - MR: ICH staging based on T1 and T2 signal
  - MR as sensitive as CT in hyperacute phase and more sensitive in subacute and chronic phases
- Location
  - Supratentorial > infratentorial brain
- Size
  - Near microscopic to very large; solitary >> multiple
- Morphology
  - Ovoid; larger hematomas have more irregular shape and heterogeneous attenuation

CT Findings

- NECT
  - Hyperacute and acute: Hyperdense mass (0-3 days)
    - Immediate: Heterogeneous with 40-60 HU
    - CT density increases to 60-80 HU over first few hours secondary to clot formation and retraction
    - Clot maturation can increase density to 80-100 HU in hematoma core
    - Isodense if Hgb < 8-10 (hemophilia, renal failure)
    - Fluid-fluid levels seen in larger hematomas, mostly with coagulopathies or anticoagulation
    - Edema and mass effect initially mild (< 3 hours)
    - Swirl sign: Extraaxial collection with hyperdense clot and smaller hypodense area in swirled configuration (implies active bleeding)
  - Subacute: 3-10 days
    - Progressive attenuation loss (↓ 1.5 HU/day)
    - Edema peaks at ~ 5 days
    - Isodense in 1-4 weeks, dependent on original size
  - Chronic: > 10 days
    - Residua: ↓ attenuation foci (37%), no visible residua (27%), slit-like lesions (25%), Ca++ (10%)
- CECT
  - Active bleeding: Contrast pooling; CTA "spot" sign
  - Subacute-chronic: Rim enhancement (3 days to 1 month)
  - Chronic: Enhancement disappears (2-6 months)

MR Findings

- T1WI
  - Hyperacute (< 24 hours): Isointense to mildly hypointense
  - Acute (~ 1-3 days): Isointense to mildly hypointense
  - Early subacute (~ 3-7 days): ↑ signal periphery, isointense center
  - Late subacute/early chronic (~ 1-2 weeks/4 weeks): Diffuse ↑ signal
  - Late chronic (> 1 month): Iso- to hypointense
- T2WI
  - Hyperacute: Hyperintense, may have subtle hypointense rim, hyperintense peripheral edema
  - Acute: Markedly hypointense, increased edema
  - Early subacute: ↓ hypointensity, ↑ edema
  - Late subacute/early chronic: Progressive central signal increase, peripheral hypointensity
  - Late chronic: Hypointense rim or cleft, no edema
- FLAIR
  - Same as on T2WI
    - May show subarachnoid extension of hemorrhage
- T2* GRE
  - Hyperacute: Typically hypointense margin; differentiates hemorrhage from other masses
  - Acute: Marked diffuse hypointensity
  - Early subacute: Hypointensity (> T2WI and FLAIR)
  - Late subacute/early chronic: Increasing low signal rim
  - Late chronic: Persistent marked hypointense nodule or cleft due to glial hemosiderin staining
- DWI
  - Signal on DWI strongly affected by underlying T2 signal (T2 shine through and T2 "black out")
  - ADC shows diffusion restriction in core during hyperacute, acute, and early subacute phase
- T1WI C+
  - Peripheral enhancement can develop within a few days and persist for months
- SWI (susceptibility weighted imaging)
  - ↑ sensitivity for microscopic hemorrhage than GRE

Imaging Recommendations

- Best imaging tool
  - Initial diagnosis: NECT or MR
  - Staging/work-up: MR, MRA/MRV, or CTA/CTV
  - Angiography if no clear cause

DIFFERENTIAL DIAGNOSIS

Fat-Containing Lesions

- Lipoma, dermoid
- Mimics subacute ICH (↑ T1WI, ↑ T2WI)
- Chemical shift artifact, lack of edema, loss of intensity on fat-saturated images confirm diagnosis

Calcified Lesions

- Dural plaque, thrombosed aneurysm, meningioma
- Hypointense on T2WI and GRE, variable on T1WI

Proteinaceous Fluid Collections

- Colloid cyst, Rathke cleft cyst, craniopharyngioma
- Mildly hyperintense on T1WI, hypointense on T2WI

PATHOLOGY

General Features

- Etiology
  - Very common: HTN, cerebral amyloid angiopathy (CAA), trauma, hemorrhagic vascular malformations

https://CafePezeshki.IR

- Common: Infarct with reperfusion, coagulopathy, blood dyscrasia, drug abuse, tumor
- Less common: Dural sinus thrombosis, eclampsia, endocarditis with septic emboli, fungal infection (aspergillosis, mucormycosis), encephalitis
- Genetics
  - ICH can occur sporadically or with familial syndromes (familial CAA, familial cavernous malformations)
- Associated abnormalities
  - Vasogenic edema forms rapidly, peaks at ~ 5 days
  - May decompress into ventricles/subarachnoid space

Staging, Grading, & Classification

- No consistent definition of hematoma stages for MR
  - Hyperacute: < 24 hours; acute: ~ 1-3 days; early subacute: ~ 3-7 days; late subacute: ~ 1-2 weeks; chronic ~ > 1 month

Gross Pathologic & Surgical Features

- Acute to early subacute: Blood-filled cavity surrounded by vasogenic edema, inflammation
- Early subacute to early chronic: Organizing clot, vascularized wall
- Late chronic: Hemosiderin scar with gliosis

Microscopic Features

- Immediate
  - Water-rich liquid hematoma; 95-98% oxy-Hgb
- Hyperacute
  - RBCs contain diamagnetic oxy-Hgb
  - High water content (↑ T2 and ↓ T1)
  - Peripheral vasogenic edema begins
- Acute
  - Deoxy-Hgb in intact RBCs
    - Paramagnetic deoxy-Hgb with 4 unpaired electrons in intact RBC causes field gradient across cell membrane → ↓ T2WI and GRE
    - Paramagnetic center of Hgb inaccessible to water molecules → no T1 shortening
  - Severe edema
- Early subacute
  - Deoxy-Hgb in intact RBCs oxidized to paramagnetic met-Hgb with 5 unpaired electrons
    - Susceptibility induced gradient across cell membrane → T2WI and GRE hypointensity
  - Met-Hgb formation begins at hematoma periphery → T1 hyperintensity initially seen at margin
- Late subacute-early chronic
  - RBC lysis → release met-Hgb into extracellular space → loss of gradient across RBC membrane
    - Loss of magnetic heterogeneity and increased water content → ↑ T2WI and FLAIR intensity
  - Persistent dipole-diploe interaction → T1 shortening
  - Edema and mass effect decrease
- Chronic
  - Lysed RBCs and clot taken up by macrophages
  - Met-Hgb converted into ferritin and hemosiderin
  - Residual cysts, clefts with hemosiderin scar, persist indefinitely in areas with intact blood-brain barrier
  - Edema, inflammation resolve

CLINICAL ISSUES

Presentation

- Most common signs/symptoms
  - HTN (90%), vomiting (50%), ↓ consciousness (50%), headache (40%), seizures (10%)
- Clinical profile
  - HTN, ↑ age most important risk factors
  - Increasing incidence of anticoagulation-related ICH

Demographics

- Incidence
  - ~ 30/100,000 (USA); 37/100,000 (Europe)
- Age
  - Risk increases with age (mean 63 [USA], 70 [Europe])
- Gender
  - Men < 65 years have 3.4x higher risk; > 65 years: No significant gender difference
- Ethnicity
  - Higher risk of ICH for African Americans (3.8x higher risk) and Hispanics (2.6x higher risk) compared with Caucasians

Natural History & Prognosis

- 1 or more rebleeds occur in 1/4 of cases
  - Rebleed: Increased mortality
    - 70% died with 2nd or 3rd ICH
- Prognosis depends on size, initial level of consciousness, and location
  - Higher mortality with posterior fossa and lobar hemorrhage than with deep hemorrhage
  - Ventricular extension: Higher mortality for lobar hemorrhage, but lower mortality for thalamic bleeds
  - ICH with warfarin use correlates with higher mortality (2x as high at 3 months)
- 20% independent at 6 months

Treatment

- Surgical evacuation as needed

DIAGNOSTIC CHECKLIST

Image Interpretation Pearls

- MR more sensitive, more accurate staging of ICH
- Large area of surrounding vasogenic edema more commonly seen with underlying neoplasm
- Marked heterogeneity of acute hematoma on CT predicts hematoma growth and mortality
- Swirl sign, contrast extravasation, and enhancement indicate hematoma growth and ↑ mortality
- Fluid-fluid levels: Question of underlying coagulopathy

SELECTED REFERENCES

1. Sampath Kumar NS et al: Multiple spontaneous hypertensive intracerebral hemorrhages. J Stroke Cerebrovasc Dis. 24(1):e25-7, 2015
2. Toyoda K et al: Seeking best medical treatment for hyperacute intracerebral hemorrhage. Neurology. ePub, 2014
3. van Etten ES et al: Incidence of symptomatic hemorrhage in patients with lobar microbleeds. Stroke. 45(8):2280-5, 2014
4. Silvera S et al: Spontaneous intracerebral hematoma on diffusion-weighted images: influence of T2-shine-through and T2-blackout effects. AJNR Am J Neuroradiol. 26(2):236-41, 2005

https://CafePezeshki.IR

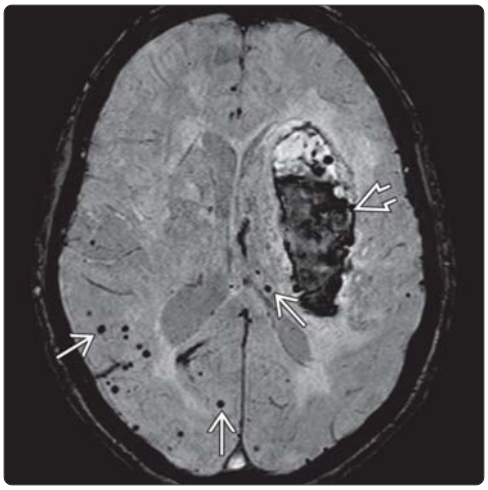

(Left) *Axial T2WI MR shows a large hypertensive hemorrhage in the left basal ganglia, which shows early subacute blood products that are predominantly hypointense* ⇨ *with surrounding edema* ⇨*. The anterior aspect of the hemorrhage shows hyperintense signal suggesting more acute blood products* ⇨*.* **(Right)** *Axial SWI shows the hypointense hemorrhage* ⇨ *and multiple other foci of susceptibility (from hemosiderin) related to remote microhemorrhages* ⇨ *from chronic hypertension.*

(Left) *Axial T1WI MR shows hemorrhages in an amyloid angiopathy patient. There is a hyperacute* ⇨ *(isointense) and an acute/early subacute* ⇨ *(hyperintense) left posterior hemorrhage as well as a late subacute (hyperintense) right temporal hemorrhage* ⇨*.* **(Right)** *Axial T2WI MR shows heterogeneous bright signal in the hyperacute* ⇨ *portion and low signal in the acute/early subacute* ⇨ *portion of the posterior hemorrhage. The late subacute* ⇨ *hemorrhage has bright T1 and T2 signal intensity.*

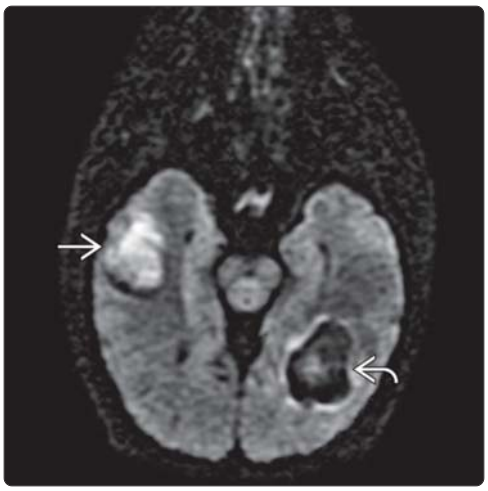

(Left) *Axial DWI MR 21 hours after initial imaging shows that the signal on DWI is mostly determined by underlying T2 effects with T2 shine through* ⇨ *in the right subacute hemorrhage and T2 blackout* ⇨ *in the acute/early subacute hemorrhage.* **(Right)** *Axial ADC shows that signal on DWI is mostly determined by underlying T2 effects. Only the acute/early subacute hemorrhage shows low signal on ADC* ⇨*, while increased diffusivity is seen in the late subacute right temporal hemorrhage* ⇨*.*

https://CafePezeshki.IR

KEY FACTS

TERMINOLOGY

- Primary intraparenchymal hemorrhage (pICH)
- Acute nontraumatic intracranial hemorrhage (ICH)

IMAGING

- Acute round or oval intracerebral hematoma
- Subcentimeter "microbleeds" to massive ICH
- Hematoma location for common causes of pICH
  - HTN: Basal ganglia > thalamus > pons > cerebellum
  - Amyloid angiopathy: Lobar
  - Arteriovenous malformation (AVM): Any location
  - Cavernous malformation: Any location
  - Venous sinus thrombosis: Subcortical white matter
  - Neoplasm: Any location
- Recommended imaging protocol
  - If HTN with striatocapsular hematoma → stop
  - If atypical hematoma → CTA or MR/MRA
  - Atypical hematoma or unclear history: MR (T2*, DWI, C+)
  - If standard study suggests vascular etiology → CTA/MRA
  - If concern for venous infarct → CTV/MRV

PATHOLOGY

- Pediatric patients, < 18 years old: Vascular malformation (~ 50%) > hematologic disorders, vasculopathy, venous infarct, neoplasm
- Young adults, < 45 years old: Vascular malformation, drug abuse, venous thrombosis, PRES, vasculitis, neoplasm
- Adults > 45 years old: HTN, amyloid > neoplasm (primary or metastatic), venous infarct, coagulopathy

CLINICAL ISSUES

- ICH causes ~ 15% of acute strokes
- Treatment: Control of ICP, hydrocephalus
- Surgical evacuation when clinically indicated
- If positive spot sign indicates active bleeding, predicts hematoma expansion and poor outcome
- 1-year mortality approaches 60%

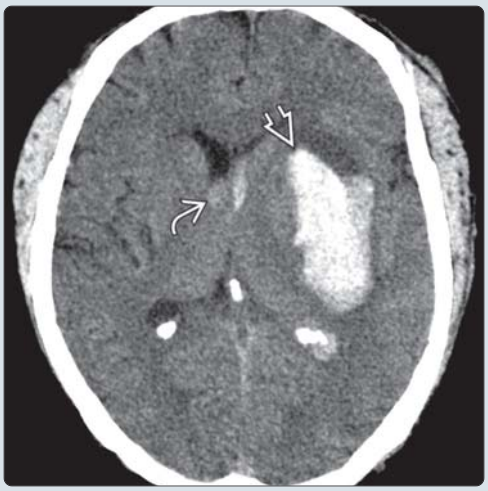

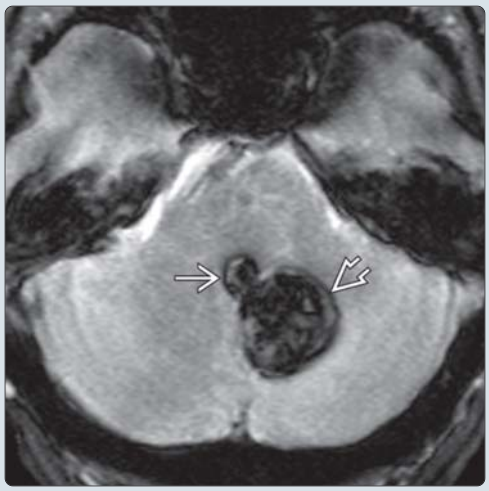

(Left) *Axial CT shows a hyperdense hematoma centered in the left external capsule and putamen ⇨ with associated edema and mass effect, as well as intraventricular extension of hemorrhage ⇨. This is the most common location for a hypertensive hemorrhage.* **(Right)** *Axial GRE MR in a 71-year-old male shows an acute hypertensive hemorrhage in the left cerebellar hemisphere ⇨ with extension to the 4th ventricle ⇨. The posterior fossa accounts for ~ 10% of all hypertensive hemorrhages.*

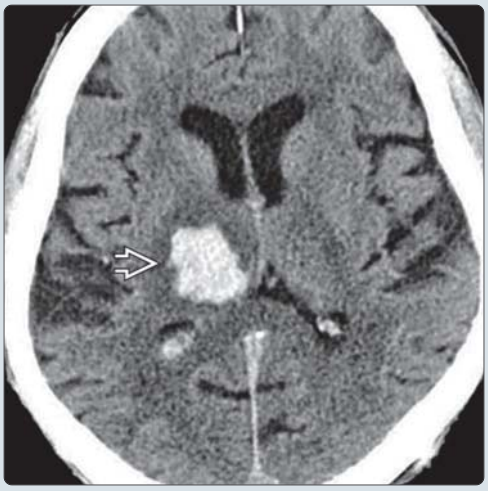

(Left) *Axial CT in a 58-year-old hypertensive female shows a hyperdense hemorrhage ⇨ in the right thalamus with surrounding edema. No additional imaging is required in this patient.* **(Right)** *Axial CT in this 5 year old shows a large frontal lobe hemorrhage ⇨ with surrounding edema and mass effect. Additional imaging revealed an underlying cavernous malformation. In children, vascular lesions represent ~ 50% of all intracranial hemorrhages.*

https://CafePezeshki.IR

TERMINOLOGY

Synonyms

- Primary intraparenchymal hemorrhage (pICH), hemorrhagic stroke

Definitions

- Acute nontraumatic intracranial hemorrhage (ICH)
  - Etiology often initially unknown

IMAGING

General Features

- Best diagnostic clue
  - Acute nontraumatic intracerebral hematoma
- Location
  - Varies with etiology
    - Hypertension (HTN): Deep gray matter (basal ganglia, thalamus), pons, cerebellar hemisphere
    - Amyloid angiopathy: Lobar
    - Arteriovenous malformation (AVM): Any location
    - Cavernous malformation: Any location, common in brainstem
    - Venous sinus thrombosis: Subcortical white matter (WM) adjacent to occluded sinus
    - Neoplasm: Any location, posterior fossa common
- Size
  - Subcentimeter "microbleeds" to massive hemorrhage
- Morphology
  - Typically round or oval; often irregular when large
  - Patterns with HTN and amyloid angiopathy
    - Acute parenchymal hematoma
    - Multiple subacute/chronic "microbleeds" in deep gray matter (HTN > amyloid) &/or subcortical white matter (amyloid > HTN)
    - Microbleeds often seen only on GRE or SWI MR

CT Findings

- NECT
  - Acute hyperdense round/elliptical mass
  - May be mixed iso-/hyperdense
  - May have fluid-fluid level
    - Coagulopathy
    - Brisk bleeding
    - Bleed into cystic mass
  - Peripheral low density (edema)
  - Deep (ganglionic) ICH may rupture into ventricles
- CTA
  - Often nonrevealing
  - ± underlying vascular malformation (AVM, aneurysm)
  - Look for dural sinus venous thrombosis

MR Findings

- T1WI
  - Hyperacute (< 24 hours)
    - Isointense center (oxygenated Hgb)
    - Isointense periphery (deoxygenated Hgb, clot-tissue interface)
    - Hypointense rim (vasogenic edema)
- T2WI
  - Hyperacute (< 24 hours)
    - Hyperintense, heterogeneous center
    - May have subtle hypointense periphery
    - Hyperintense rim of edema
- T2* GRE
  - Hypointense
  - Multifocal hypointense lesions ("black dots")
    - Basal ganglia (BG) and thalami suggests HTN
    - Subcortical WM suggests amyloid angiopathy
- DWI
  - T2 shine through common; may see "DWI restriction" in core
- T1WI C+
  - May enhance if underlying neoplasm, vascular malformation
- MRA
  - Often normal, look for vascular lesion
- MRV
  - Look for dural sinus thrombosis

Angiographic Findings

- DSA, often negative
  - Look for dural sinus occlusion, "stagnating vessels" (thrombosed AVM)

Imaging Recommendations

- Best imaging tool
  - Screening: NECT
    - If patient with HTN and BG hematoma → stop
    - Consider CTA to exclude underlying vascular lesion
  - Standard MR (include T2*, SWI, DWI)
    - If no clear cause of hemorrhage, or atypical appearance on CT
    - If T2* shows multifocal "black dots" → stop
    - T1WI C+ to assess for underlying tumor
    - If standard study suggests vascular etiology → MRA/CTA
  - Follow-up: Repeat MR if etiology unclear ± DSA if initial MRA/CTA negative
- Protocol advice
  - Atypical hematoma or unclear history: MR (with T2*, SWI, DWI, T1WI C+)
  - Add MRV if concern for venous infarct

DIFFERENTIAL DIAGNOSIS

Hypertensive Intracranial Hemorrhage

- Patients usually older
- BG hematoma most common location

Vascular Malformation

- AVM, cavernous malformation most common
- ICH rate in AVMs of BG or thalamus (9.8% per year) much higher than AVMs in other locations

Cerebral Amyloid Angiopathy

- Older patients (70 years old, normotensive)
- Usually lobar hemorrhage
- Microbleeds ("black dots") on T2* peripheral location

Underlying Neoplasm

- Causes 2-15% of nontraumatic ICHs
- Primary (glioblastoma) or metastasis

https://CafePezeshki.IR

- Typically shows enhancement

Venous Thrombosis

- May result in hemorrhagic venous infarct
- Risk factors: Dehydration, pregnancy, oral contraceptives

Anticoagulation

- "Growing" hematoma, fluid-fluid levels common
- Check history

Drug Abuse

- May have hypertensive striatocapsular hemorrhage
- Uncommon = pseudoaneurysm rupture into cerebrum

Vasculitis

- Often results in subarachnoid hemorrhage (SAH) rather than ICH
- Patients usually younger

Dural AVF (With Cortical Venous Drainage)

- Dilated venous "flow voids"

Ruptured Pseudoaneurysm

- Mycotic (endocarditis)
- Traumatic
- Vasculopathy

PATHOLOGY

General Features

- Etiology
  - Pediatric patients, < 18 years old: Vascular malformation (~ 50%) > hematologic disorders, vasculopathy, venous infarct, neoplasm
  - Young adults, < 45 years old: Vascular malformation, drug abuse, venous thrombosis, PRES, vasculitis, neoplasm
  - Adults > 45 years old: HTN, amyloid > neoplasm (primary or metastatic), venous infarct, coagulopathy
- Genetics
  - MMP-9, cytokine gene expression ↑ after acute spontaneous ICH
  - Apolipoprotein E (*APOE*) gene and its ε2 and ε4 alleles are strongly associated with ICH

Staging, Grading, & Classification

- Clinical "ICH score" correlates with 30-day mortality
  - Admission GCS
  - > 80 years old, ICH volume
  - Infratentorial
  - Presence of intraventricular hemorrhage

Gross Pathologic & Surgical Features

- Findings range from petechial "microbleeds" to gross parenchymal hematoma

Microscopic Features

- Coexisting microangiopathy common in amyloid, HTN

CLINICAL ISSUES

Presentation

- Most common signs/symptoms
  - 90% of patients with recurrent pICH are hypertensive
  - Large ICHs present with sensorimotor deficits, impaired consciousness

Demographics

- Age
  - Any age
- Epidemiology
  - Parenchymal hemorrhage causes ~ 15% of acute strokes

Natural History & Prognosis

- Prognosis related to location, size of ICH
- Hematoma enlargement common in first 24-48 hours
  - Risk factors: EtOH, low fibrinogen, coagulopathy, irregularly shaped hematoma
- 20-30% of patients die within 48 hours despite intervention
- Edema associated with poor outcome
- Mortality: 30-55% in 1st month
- 1-year mortality approaches 60%
- 30% rebleed within 1 year
- Most survivors have significant deficits
- Incidence ~ 25 per 100,000 per year worldwide
- If positive spot sign indicates active bleeding, predicts hematoma expansion and poor outcome

Treatment

- Control of ICP, hydrocephalus
- Surgical evacuation when clinically indicated

DIAGNOSTIC CHECKLIST

Consider

- Consider underlying etiology for hemorrhage (AVM, amyloid, neoplasm, drug use, etc.)

Image Interpretation Pearls

- Unexplained ICH → search for microbleeds on T2* MR
- Fluid-fluid level, iso-/mildly hyperdense clot may indicate coagulopathy

SELECTED REFERENCES

1. Alexander MD et al: Association between Venous Angioarchitectural Features of Sporadic Brain Arteriovenous Malformations and Intracranial Hemorrhage. AJNR Am J Neuroradiol. ePub, 2015
2. Kranz PG et al: Spontaneous brain parenchymal hemorrhage: an approach to imaging for the emergency room radiologist. Emerg Radiol. 22(1):53-63, 2015
3. Sampath Kumar NS et al: Multiple spontaneous hypertensive intracerebral hemorrhages. J Stroke Cerebrovasc Dis. 24(1):e25-7, 2015
4. Ciura VA et al: Nontraumatic acute intraparenchymal hemorrhage: algorithm for workup and differential diagnosis. Semin Roentgenol. 49(1):112-26, 2014
5. Koivunen RJ et al: Predictors of early mortality in young adults after intracerebral hemorrhage. Stroke. 45(8):2454-6, 2014
6. Caceres JA et al: Intracranial hemorrhage. Emerg Med Clin North Am. 30(3):771-94, 2012
7. Hanley DF: Intraventricular hemorrhage: severity factor and treatment target in spontaneous intracerebral hemorrhage. Stroke. 40(4):1533-8, 2009
8. Kumar R et al: Spontaneous intracranial hemorrhage in children. Pediatr Neurosurg. 45(1):37-45, 2009
9. van Beijnum J et al: Outcome after spontaneous and arteriovenous malformation-related intracerebral haemorrhage: population-based studies. Brain. 132(Pt 2):537-43, 2009
10. Chao CP et al: Cerebral amyloid angiopathy: CT and MR imaging findings. Radiographics. 26(5):1517-31, 2006
11. Qureshi AI et al: Spontaneous intracerebral hemorrhage. N Engl J Med. 344(19):1450-60, 2001

https://CafePezeshki.IR

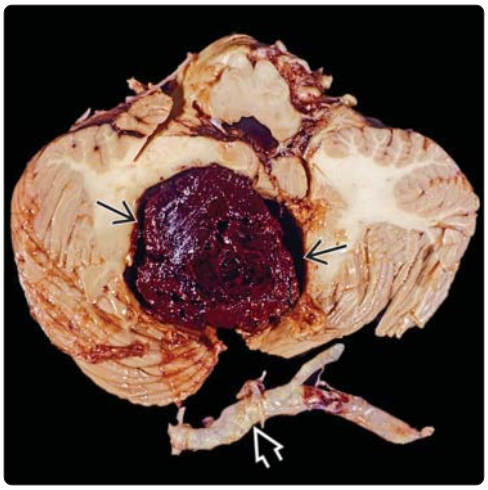

(Left) *Axial CT image in a 73-year-old male shows an acute frontal and parietal lobe hemorrhage. MR showed underlying enhancement and biopsy disclosed metastatic disease related to melanoma.* **(Right)** *Axial gross pathology, sectioned through the middle of the cerebellum, shows an acute spontaneous intraparenchymal hemorrhage. Note the atherosclerosis in the basilar artery. No underlying lesion was identified in this patient with chronic hypertension. (Courtesy R. Hewlett, MD.)*

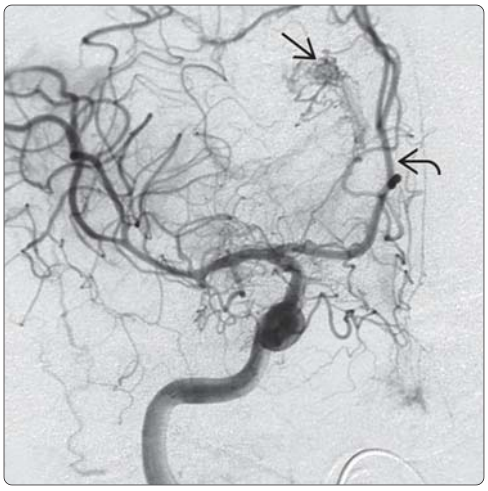

(Left) *Axial NECT shows what appears to be a classic hypertensive striatocapsular hemorrhage with intraventricular extension. However, in this young patient, underlying etiologies must be considered, including drug abuse & vascular lesions.* **(Right)** *Anteroposterior DSA from a right internal carotid artery injection shows an avascular mass in the basal ganglia (hematoma) with midline shift of the anterior cerebral artery. There is a cluster of abnormal arteries (AVM) fed by a large anterior choroidal artery.*

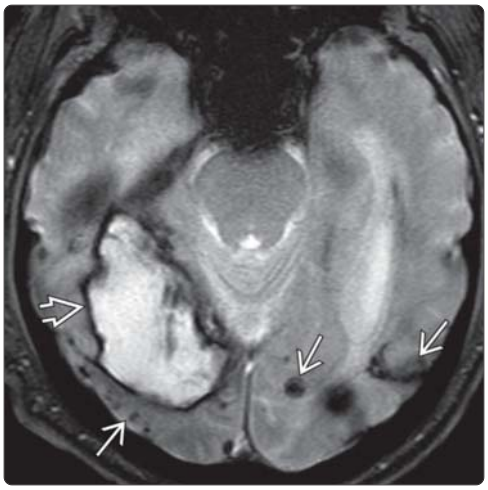

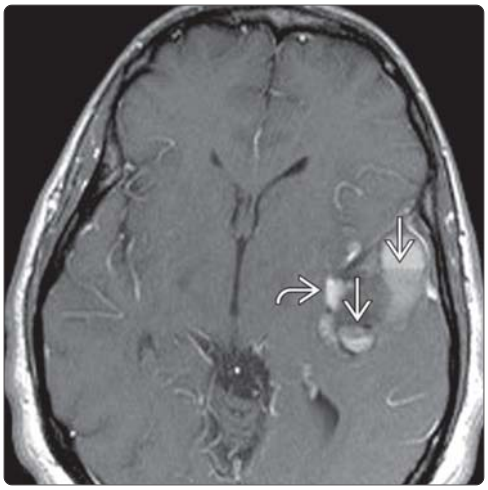

(Left) *Axial GRE image shows a large occipital lobe hemorrhage and multiple other foci of susceptibility artifact or "blooming," related to hemosiderin deposition in this elderly patient with cerebral amyloid disease. The MR was done to exclude an underlying mass.* **(Right)** *Axial T1WI C+ MR shows lobular cerebral hematoma in the left temporal lobe. Note fluid-fluid levels in the hematoma from brisk bleeding. The more avidly enhancing region in sulcus represented pseudoaneurysm.*

https://CafePezeshki.IR

KEY FACTS

TERMINOLOGY

- Hypertensive intracranial hemorrhage (hICH)
- Acute nontraumatic intracerebral hemorrhage (ICH) 2° to systemic hypertension
- 2nd most common cause of stroke

IMAGING

- Initial screen = NECT in patients with HTN
- CT: Acute round or oval hyperdense mass
  - Striatocapsular: Putamen/external capsule (60-65%)
  - Thalamus (15-25%)
  - Pons, cerebellum (10%)
- Multifocal "microbleeds" (1-5%)
- Heterogeneous density (coagulopathy, active bleed)
- Other findings: Intraventricular extension, mass effect, hydrocephalus, herniation
- MR signal intensity (varies with age of clot)
  - Hyperacute (< 24 hours): T1WI iso-hypo/T2WI hyper
  - Acute (~ 1-3 days): T1WI iso-hypo/T2WI hypo
  - Subacute (days): T1WI hyper/T2WI hypo-hyper
  - Chronic (weeks-months): T1WI hyper/T2WI hypo

TOP DIFFERENTIAL DIAGNOSES

- Cerebral amyloid angiopathy
- Hemorrhagic neoplasm
- Coagulopathy
- Deep cerebral venous thrombosis
- Drug abuse (especially in young patient)
- Vascular malformation (rare in elderly)

CLINICAL ISSUES

- HTN single most important risk factor for **all** types of stroke
- 10-15% of stroke patients have hICH
- 40-50% of nontraumatic ICHs caused by hICH
- HTN most common cause of spontaneous ICH in patients 45-70 years old
- 10-15% of hypertensive patients with spontaneous ICH have underlying aneurysm or AVM

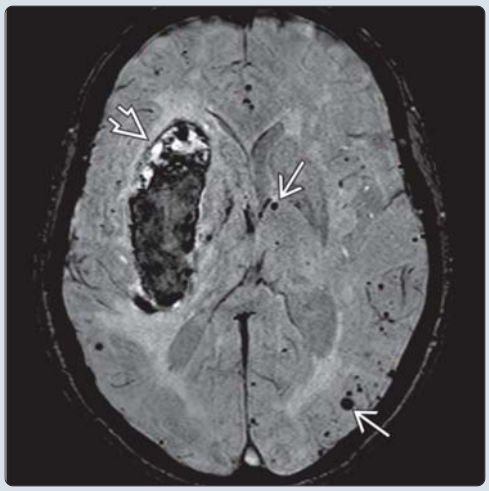

(Left) *Axial CT in a 61-year-old female with a history of hypertension shows the classic appearance of a left basal ganglia hemorrhage involving the putamen and external capsule (striatocapsular). Note the additional areas of periventricular hypodensity ⇨ likely related to chronic small vessel ischemia.* **(Right)** *Axial SWI image shows a large hypertensive basal ganglia hemorrhage ⇨, as well as multiple foci of susceptibility artifact ⇨ from hemosiderin deposition related to microhemorrhages from chronic hypertension.*

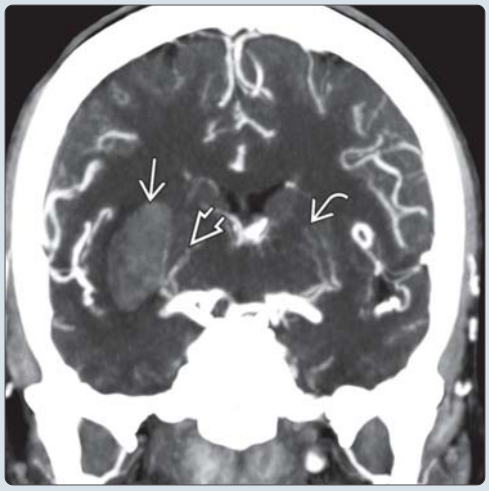

(Left) *Axial graphic shows a classic acute hypertensive basal ganglia/external capsule hemorrhage with dissection into the lateral ventricle. Hemorrhage extends through the foramen of Monro to the 3rd ventricle.* **(Right)** *A coronal CTA in a young patient with a right basal ganglia hemorrhage ⇨ shows displacement of the lenticulostriate arteries ⇨ medially, compared to the normal left side ⇨ by the hematoma. There is no spot sign that would indicate active bleeding. No underlying vascular lesion is present.*

https://CafePezeshki.IR

TERMINOLOGY

Abbreviations

- Hypertensive intracranial hemorrhage (hICH)

Synonyms

- Stroke, hypertensive hemorrhage

Definitions

- Acute nontraumatic intracerebral hemorrhage (ICH) secondary to systemic hypertension (HTN)

IMAGING

General Features

- Best diagnostic clue
  - Round or oval hyperdense mass in basal ganglia (BG) or thalamus in patients with hypertension
- Location
  - Striatocapsular: Putamen/external capsule (60-65%)
  - Thalamus (15-25%)
  - Pons, cerebellum (10%)
  - Lobar (5-10%)
- Size
  - Subcentimeter ("microbleeds") to several centimeters
- Morphology
  - Typically rounded or oval
  - 2 distinct patterns seen with hICH
    - Acute focal hematoma
    - Multiple subacute/chronic "microbleeds" (1-5%)

CT Findings

- NECT
  - Round or oval hyperdense parenchymal mass
  - Heterogeneous density if coagulopathy or active bleeding
  - Intraventricular extension of hemorrhage common
  - Mass effect, hydrocephalus, herniation common
- CECT
  - No enhancement in acute hICH
- CTA
  - Avascular mass effect in acute hICH
  - No underlying vascular lesion

MR Findings

- T1WI
  - Varies with age of clot
    - Hyperacute hematoma (< 24 hours)
      - Oxyhemoglobin (Hgb) (iso-/hypointense)
    - Acute hematoma (~ 1 to 3 days)
      - DeoxyHgb (iso-/hypointense)
    - Early subacute hematoma (~ 3 to 7 days)
      - Intracellular metHgb (hyperintense)
    - Late subacute hematoma (week to months)
      - Extracellular metHgb (hyperintense)
    - Chronic hematoma
      - Hypointense (± hyperintense center)
- T2WI
  - Appearance of hematoma varies with stage
    - Hyperacute hematoma (< 24 hours)
      - OxyHgb (hyperintense)
    - Acute hematoma (~ 1 to 3 days)
      - DeoxyHgb (hypointense)
    - Subacute hematoma (3-7 days)
      - Intracellular metHgb (hypointense)
    - Late subacute hematoma (week to months)
      - Extracellular metHgb (hyperintense)
    - Chronic hematoma (months)
      - Hemosiderin (hypointense)
    - Remote hematoma (months to years)
      - Hypointense hemosiderin scar ± central hyperintense cavity
  - "White matter (WM) hyperintensities" are hICH risk markers
- T2* GRE
  - Multifocal hypointense lesions ("black dots") in deep grey nuclei and peripheral WM
    - Common with longstanding HTN
    - Also seen with amyloid angiopathy (more peripheral)
- DWI
  - Hypo- or mixed hypo-/hyperintense (early hematoma)
- T1WI C+
  - Typically no enhancement with acute hematoma
  - Contrast extravasation = active hemorrhage
- MRA
  - Negative

Angiographic Findings

- Conventional
  - DSA usually normal if history of HTN with deep ganglionic hemorrhage
    - May show avascular mass effect
    - Rare: "Bleeding globe" microaneurysm on lenticulostriate artery (LSA)
  - Coexisting vascular abnormalities
    - Increased prevalence of unruptured intracranial aneurysms

Imaging Recommendations

- Best imaging tool
  - Initial screen = NECT in patients with HTN
  - If atypical age or history, consider MR with T2* or CTA
  - If hyperacute ischemic "stroke" suspected, MR with T2* and DWI
  - If MR shows classic hematoma with coexisting multifocal "black dots," most likely amyloid angiopathy or chronic HTN
  - If MR shows atypical hematoma, MRA or CTA
  - If MRA or CTA inconclusive, consider DSA

DIFFERENTIAL DIAGNOSIS

Cerebral Amyloid Angiopathy

- Lobar > > basal ganglionic hemorrhage
- Usually elderly, often normotensive
- Only 5-10% of hICHs are lobar, but HTN is so common that it is always consideration

Hemorrhagic Neoplasm

- Metastases and primary (e.g., GBM)
- Typically older adult or elderly

https://CafePezeshki.IR

Venous Thrombosis

- May have history of dehydration, flu, pregnancy, birth control pills
- May present as lobar hematoma
- Look for hyperdense dural sinus (not always present)

Deep Cerebral Venous Thrombosis

- Less common than dural sinus or cortical vein thrombosis
- Look for hyperdense internal cerebral veins, intraventricular hemorrhage
- Look for hypodense bilateral thalami

Coagulopathy

- Elderly patients on anticoagulant therapy

Drug Abuse

- Cocaine and other drugs may cause sudden ↑ HTN
- Be suspicious if unexplained BG bleed in young patient

Vascular Malformation

- Patients usually normotensive, younger
- Most common is cavernous malformation
  - Look for "black dots" (multiple lesions) on T2* (GRE, SWI) scans
- Less common = thrombosed hemorrhagic AVM or dAVF or MCA aneurysm

PATHOLOGY

General Features

- Etiology
  - Chronic HTN with atherosclerosis, lipohyalinosis, fibrinoid necrosis, abrupt wall rupture ± pseudoaneurysm formation
  - "Bleeding globe" (penetrating lenticulostriate pseudoaneurysm)
  - Diffuse "microbleeds" common

Gross Pathologic & Surgical Features

- Large ganglionic hematoma ± IVH
- Subfalcine herniation, hydrocephalus (common)
- Coexisting small chronic hemorrhages, ischemic lesions (common)

Microscopic Features

- Severe arteriosclerosis with lipohyalinosis
- May see may see small fibrosed pseudoaneurysm or fibrous balls (fibrosed miliary aneurysm)

CLINICAL ISSUES

Presentation

- Most common signs/symptoms
  - 10-15% of stroke patients have hICH
  - Large ICHs present with sensorimotor deficits, impaired consciousness
- Clinical profile
  - HTN single most important risk factor for **all** types of stroke
  - Major risk factor = HTN (increases risk of ICH 4x)

Demographics

- Age
  - Adults, most common elderly
- Gender
  - Males > females
- Ethnicity
  - Higher incidence in African Americans
- Epidemiology
  - 40-50% of primary nontraumatic ICHs caused by hypertensive hemorrhage
  - HTN most common cause of spontaneous ICH in patients 45-70 years
  - 10-15% of all stroke cases; associated with highest mortality rate
  - 10-15% of hypertensive patients with spontaneous ICH have underlying aneurysm or AVM

Natural History & Prognosis

- Presence of microbleeds on MR is strong predictor of future hICH
- Bleeding can persist for up to 6 hours following ictus
- Neurologic deterioration common within 48 hours
  - Increasing hematoma, edema
  - Hydrocephalus
  - Herniation syndromes
- Recurrent hICH in 5-10% of cases, usually different location
- Prognosis related to location, size of hICH
- 80% mortality in massive hICH with IVH
- 1/3 of survivors are severely disabled

Treatment

- Control of ICP and hydrocephalus

DIAGNOSTIC CHECKLIST

Consider

- Does patient have history of poorly controlled systemic HTN
- Could there be underlying coagulopathy, hemorrhagic neoplasm, or vascular malformation
- Consider substance abuse in young patients with unexplained hICH

Image Interpretation Pearls

- Underlying cause of lobar ICH is often difficult to determine
- Subarachnoid extension of hematoma on CT is usually indicative of nonhypertensive etiology; consider lobar ICH caused by vascular abnormality

SELECTED REFERENCES

1. Koivunen RJ et al: Incidence, risk factors, etiology, severity and short-term outcome of non-traumatic intracerebral hemorrhage in young adults. Eur J Neurol. 22(1):123-32, 2015
2. Marsh EB et al: Predicting symptomatic intracerebral hemorrhage versus lacunar disease in patients with longstanding hypertension. Stroke. 45(6):1679-83, 2014
3. Shams S et al: Cerebral Microbleeds: Different Prevalence, Topography, and Risk Factors Depending on Dementia Diagnosis-The Karolinska Imaging Dementia Study. AJNR Am J Neuroradiol. ePub, 2014
4. Wilson D et al: Advances in understanding spontaneous intracerebral hemorrhage: insights from neuroimaging. Expert Rev Neurother. 14(6):661-78, 2014

https://CafePezeshki.IR

(Left) *Axial CT in a 55-year-old male who presented to the ER with an acute stroke shows a hemorrhage in the right temporal lobe and external capsule with surrounding edema and mass effect.* **(Right)** *Coronal CTA in the same patient shows a large MCA aneurysm ➡ as the etiology for this patient's acute hemorrhage. CTA is often key in evaluation of an acute hemorrhage in a patient with an atypical history or an unusual hemorrhage location.*

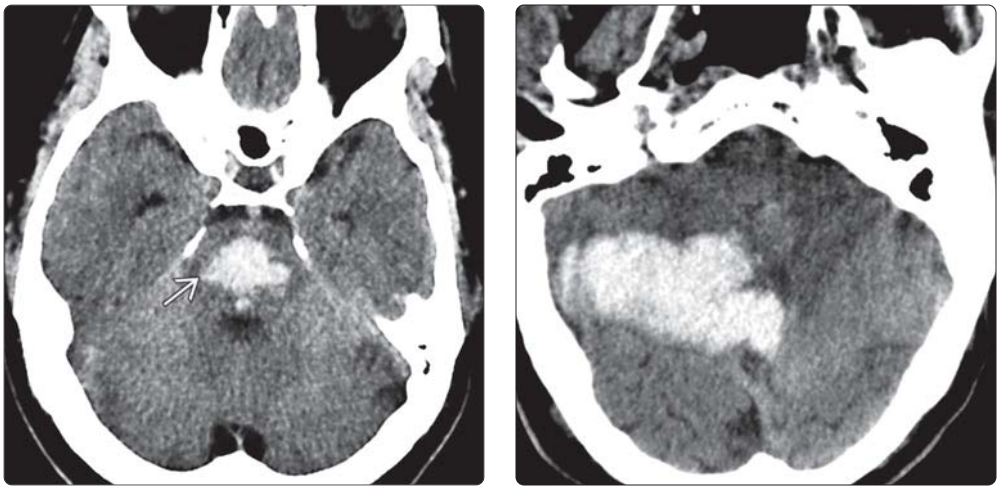

(Left) *NECT scan in a 52-year-old hypertensive man with sudden onset of multiple cranial neuropathies shows a pontine hemorrhage ➡.* **(Right)** *NECT scan in an elderly hypertensive man shows a right cerebellar hemorrhage. The posterior fossa (pons, cerebellum) is a relatively uncommon location for hypertensive hemorrhages, yet it is the 3rd most common overall site (after the basal ganglia and thalami).*

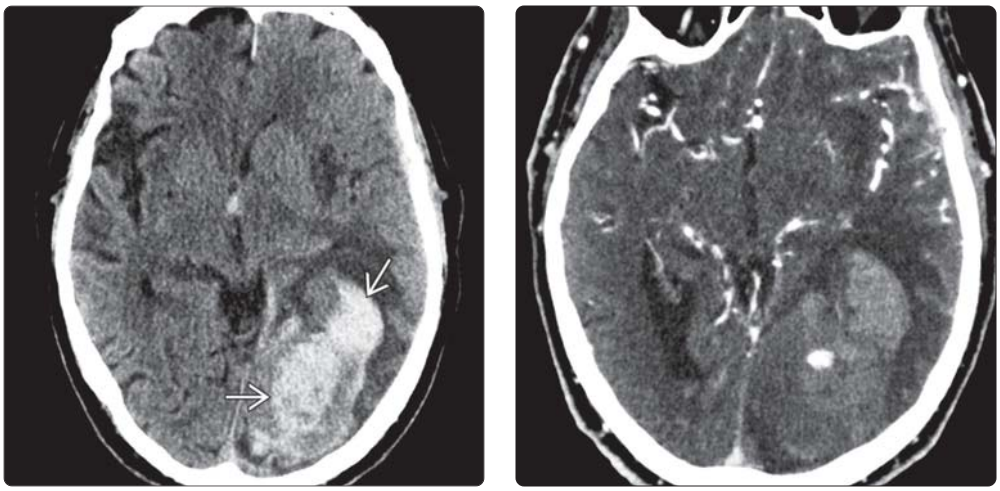

(Left) *NECT scan in an 80-year-old man in the ER with a "brain attack" shows a heterogeneous acute left occipital hematoma ➡. Lobar hemorrhages account for just 5-10% of hypertensive bleeds.* **(Right)** *Because of the unusual appearance and location of the hematoma, emergent CTA was performed in the same patient. Contrast extravasation into the hematoma ("spot" sign) indicates active bleeding. Surgery disclosed an actively bleeding hemorrhagic metastasis (adenocarcinoma).*

https://CafePezeshki.IR

KEY FACTS

TERMINOLOGY

- Remote cerebellar hemorrhage (RCH)
  - Typically after supratentorial craniotomy
  - Less often after spinal surgery
  - Remote to primary surgical site
  - No underlying pathologic lesion

IMAGING

- General features
  - "Zebra" sign (blood layered over cerebellar folia)
  - Location varies (in/over hemisphere, vermis)
  - Subarachnoid &/or superficial parenchymal bleed
  - Contralateral to side of surgery (29%)
  - Ipsilateral (22%), bilateral (33%), vermis only (9%)
- Imaging recommendations
  - NECT initial screen, ± CTA to exclude other etiology
  - MR ± contrast, ± MRA
  - Include T2* (GRE ± SWI)

TOP DIFFERENTIAL DIAGNOSES

- Hypertensive hemorrhage
- Coagulopathy-related spontaneous hemorrhage
- Neoplasm with hemorrhage

PATHOLOGY

- CSF hypovolemia → inferior cerebellar displacement "sagging" → vein stretching, bleeding
- RCH usually seen in immediate postoperative period
- Most occur within hours to 1 day postoperatively

CLINICAL ISSUES

- True incidence unknown (~ at 0.1-0.6% of supratentorial craniotomies)
  - Most often after aneurysm surgery, temporal lobectomy for epilepsy or mass resection
- Occasionally asymptomatic, occult (not imaged)
- Death/disability in ~ 50% of cases
- RCH is typically self-limited

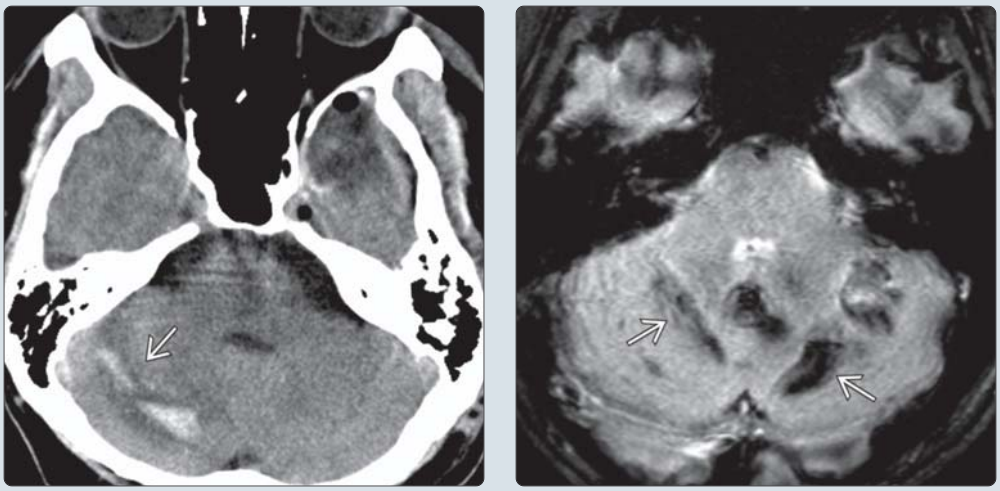

(Left) *Axial CT shows acute hemorrhage ➡ in the right cerebellum related to remote cerebellar hemorrhage (RCH) in a young patient who had a left temporal lobectomy. The etiology is thought to be related to CSF hypovolemia resulting in inferior displacement of the cerebellum and secondary venous injury.* **(Right)** *Axial GRE MR image in RCH shows the typical susceptibility artifact or "blooming" ➡ related to recent hemorrhage. The hemorrhage may be unilateral, bilateral, or isolated to the vermis.*

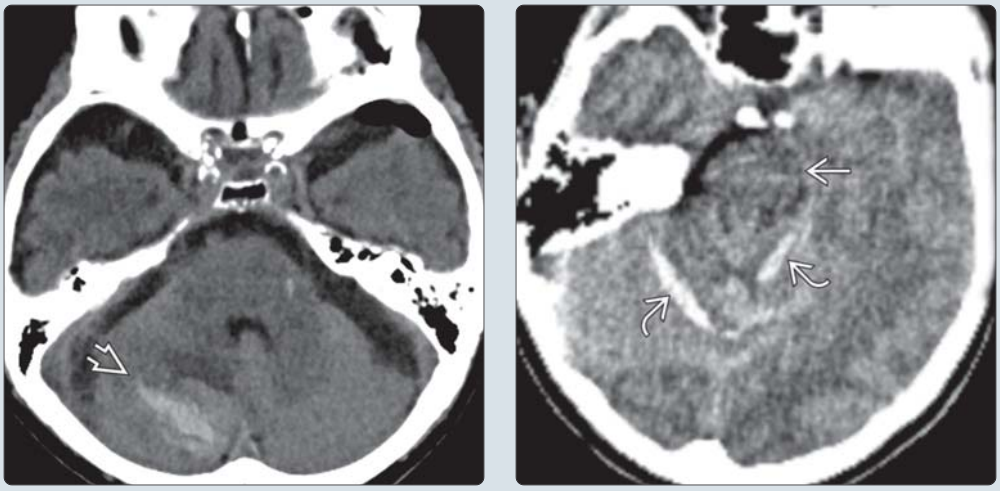

(Left) *Axial CT shows right RCH ➡ in this 86 year old who underwent left sided burr holes and catheter placement for drainage of a left subdural hygroma. This hemorrhage was found incidentally. Most patients need no intervention for RCH.* **(Right)** *Axial CT in a patient doing poorly immediately after surgery for meningioma resection shows linear cerebellar hemorrhages bilaterally ➡ along the folia, known as the "zebra" sign. This is a common pattern seen in RCH. Cisternal effacement is also present ➡.*

https://CafePezeshki.IR

TERMINOLOGY

Abbreviations

- Remote cerebellar hemorrhage (RCH)

Definitions

- Cerebellar hemorrhage following CNS surgery, typically supratentorial
  - Remote to primary surgical site
  - No underlying pathologic lesion
  - CSF drainage → cerebellar "sagging" → vein stretching, bleeding
- Less commonly may occur after spinal surgery

IMAGING

General Features

- Best diagnostic clue
  - "Zebra" sign (blood layered over cerebellar folia)
    - Following supratentorial craniotomy or spinal surgery
- Location
  - Sublocation in cerebellum varies
  - Subarachnoid &/or superficial parenchymal bleed
- Morphology
  - Superior cerebellar folia most common pattern

CT Findings

- NECT
  - Hyperdense

MR Findings

- T1WI
  - Varies with age/stage of hematoma
- T2WI
  - Usually mixed hypo-/hyperintense
- T2* GRE
  - Useful to confirm hemorrhage ("blooms")
    - T2* most sensitive for parenchymal blood
    - SWI more sensitive than GRE
- T1WI C+
  - No enhancement
- MRA
  - Negative

Angiographic Findings

- DSA negative for underlying vascular etiology
- No cortical venous/dural sinus occlusion

Imaging Recommendations

- Best imaging tool
  - NECT initial screen, ± CTA
  - MR with and without contrast, MRA
    - Include GRE and SWI
- Protocol advice
  - MRI with T2*, gadolinium, plus vascular imaging (MRA &/or DSA)

DIFFERENTIAL DIAGNOSIS

Hypertensive Hemorrhage

- Basal ganglia > thalamus > pons/cerebellum > lobar
- Lobar > superficial/foliar pattern
- T2* may reveal microbleeds elsewhere

Coagulopathy-Related Spontaneous Hemorrhage

- Iatrogenic: Warfarin, heparin, aspirin
- Disseminated intravascular coagulation

Neoplasm With Hemorrhage

- Metastases > primary neoplasm
- Vasogenic edema, nodular enhancement

Vascular Malformation

- Cavernous malformation
- AVM, dAVF

Cerebral Amyloid Angiopathy

- Lobar hemorrhage is typical
- Rarely involves cerebellum

PATHOLOGY

General Features

- Etiology
  - CSF (cerebrospinal fluid) hypovolemia is likely cause
    - May lead to "brain sagging," occlusion/tearing of bridging veins
    - Result = hemorrhagic venous infarct

Gross Pathologic & Surgical Features

- Hemorrhagic necrosis without underlying vascular malformation or tumor

CLINICAL ISSUES

Presentation

- Most common signs/symptoms
  - ↓ consciousness, seizures in postoperative period
  - Cerebellar signs
    - From primary bleed or herniation (less common)
  - Can be asymptomatic
    - Discovered incidentally on postoperative imaging

Treatment

- Intervention for RCH rarely indicated

DIAGNOSTIC CHECKLIST

Consider

- MR initial evaluation after screening NECT ± CTA

Image Interpretation Pearls

- Cerebellar bleed in a patient with history of craniotomy or spinal surgery is likely RCH

SELECTED REFERENCES

1. Mallio CA et al: Bilateral remote cerebellar haemorrhage after spinal surgery: a case study and review of the literature. Brain Inj. 28(9):1216-22, 2014
2. Smith R et al: Remote cerebellar hemorrhage following supratentorial cerebrovascular surgery. J Clin Neurosci. 21(4):673-6, 2014
3. Borkar SA et al: Remote site intracranial haemorrhage: a clinical series of five patients with review of literature. Br J Neurosurg. 27(6):735-8, 2013
4. Thangasamy SJ et al: Remote cerebellar hemorrhage as an unusual complication of supratentorial surgery. A case report and literature review. Neuroradiol J. 24(5):779-82, 2011

https://CafePezeshki.IR

KEY FACTS

IMAGING

- Cerebral: Blood products in subependymal region, usually involving caudothalamic notch
- Cerebellar: Blood products on cerebellar surface, usually caudal
- US is standard of care: Sensitive but not specific and user dependent
- MR most sensitive and specific; important, though, to weigh risks of transport

TOP DIFFERENTIAL DIAGNOSES

- Deep venous thrombosis with hemorrhage
- Arterial ischemic infarction
- Isolated choroid plexus hemorrhage
- Isolated intraventricular hemorrhage

PATHOLOGY

- Germinal matrix hemorrhage (GMH): Rupture of gray matter capillaries
- PHI: Venous hemorrhagic infarction likely due to GMH ± IVH compressing vein in ventricular wall
- Hydrocephalus
- Periventricular leukomalacia (high association with GMH + IVH)
- Selective neuronal necrosis (pontine > thalamus, basal ganglia, hippocampus)
- Grade 1: GMH (typically caudothalamic notch)
- Grade 2: GMH + IVH
- Grade 3: GMH + IVH + ventriculomegaly
- Grade 4 (PHI): Hemorrhagic periventricular venous infarction

CLINICAL ISSUES

- Most common < 32 weeks gestation age, < 1,500 g
- Rare > 34 weeks gestation age
- ~ 90% of GM bleeds occur in ≤ 3 days
- Maximal extent reached ≤ 5 days
- Hydrocephalus is most important consequence

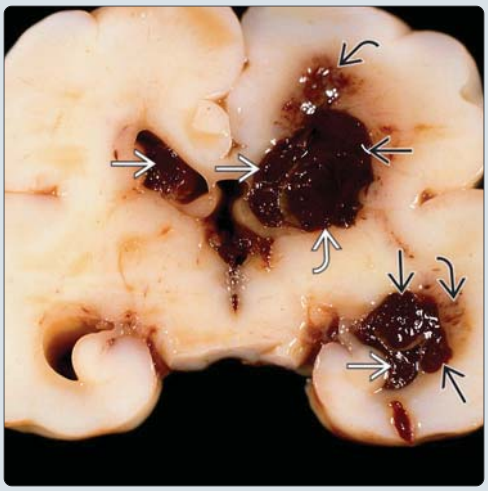

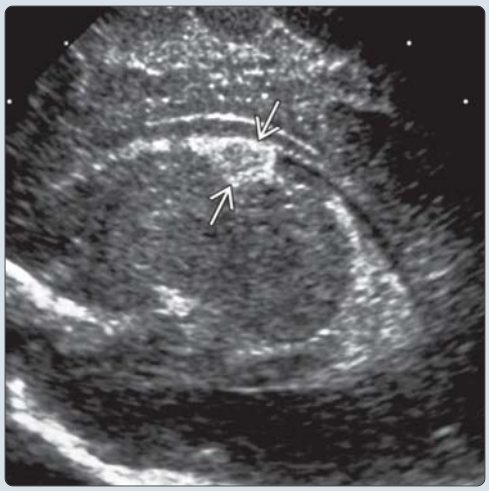

(Left) *Coronal gross pathology section shows a left germinal matrix hemorrhage (GMH) with intraventricular extension and associated PHI in both the left frontal and temporal lobes. Note the clotted blood extending outward from the left lateral ventricle into the medullary veins.* **(Right)** *Sagittal transfontanelle ultrasound in a premature infant shows a focus of increased echogenicity in the caudothalamic notch without intraventricular extension, consistent with a grade 1 GMH.*

(Left) *Axial T2 MR image shows a small focus of hemorrhage in the left germinal matrix and along the right lateral ventricle in this premature infant with a history of oligohydramnios and a grade 2 GMH.* **(Right)** *Axial SWI MR in the same premature infant shows hypointensity or "blooming" related to hemorrhage in the left germinal matrix and within the lateral ventricles. GMH typically occurs in premature infants less than 32 weeks gestational age.*

https://CafePezeshki.IR

TERMINOLOGY

Abbreviations

- Germinal matrix hemorrhage (GMH)

Synonyms

- Grade 4 GMH = periventricular hemorrhagic infarction (PHI)
- Cerebellar GMH = external granular layer hemorrhage
- Germinal matrix = ventricular + subventricular zone (SVZ)

Definitions

- Germinal matrix
  - Highly vascular, neural tube-derived structure
    - Dynamic; varies both temporally, spatially
  - Contains multiple cell types
    - Neural stem cells
    - Restricted neural progenitor cells
    - Ependymal cells
    - Premigratory/migrating neurons, glia

IMAGING

General Features

- Best diagnostic clue
  - Cerebral: Blood products in subependymal region, usually involving caudothalamic notch
    - ± intraventricular hemorrhage
    - ± choroid plexus bleed (often associated with GMH + intraventricular hemorrhage [IVH])
    - ± ventriculomegaly
    - ± PHI
  - Cerebellar: Blood products on cerebellar surface
- Location
  - Cerebral GMH: Hemorrhage into GM along lateral ventricular wall, most commonly caudothalamic notch
  - Cerebellar GMH: Hemorrhage into cerebellar GM over cerebellar hemisphere + vermian surface
  - PHI: Hemorrhage in periventricular white matter adjacent to GM in caudothalamic notch in venous distribution
- Size
  - Variable

CT Findings

- NECT
  - High attenuation due to blood products

MR Findings

- T1WI
  - Blood products initially isointense but become hyperintense after ~ 3 days
- T2WI
  - Blood products hypointense (hyperacute blood that is hyperintense on T2 not currently reported due to typical delay in MR > 12 hours)
  - Become centrally hyperintense with hypointense rim as they evolve
- T2* GRE
  - Blood products "bloom"
- DWI
  - Signal variable (low T2 drives signal down, low ADC drives signal up)
  - ADC low due to clotted blood

Ultrasonographic Findings

- Grayscale ultrasound
  - Subependymal mass with ↑ echogenicity
    - Typically caudothalamic notch
    - ± intraventricular echogenicity, ventriculomegaly
- Color Doppler
  - Helps differentiate echogenic choroid plexus from avascular echogenic hemorrhage

Imaging Recommendations

- Best imaging tool
  - US is standard of care: Sensitive but not specific and user dependent
  - MR most sensitive and specific; important, though, to weigh risks of transport
- Protocol advice
  - US: High-frequency probe, multiple focal points

DIFFERENTIAL DIAGNOSIS

Deep Venous Thrombosis With Hemorrhage

- Typically > 34 weeks gestation age (GA)
- Hemorrhage can occur in caudothalamic notch at site where terminal vein joins choroid vein to form internal cerebral vein

Arterial Ischemic Infarction

- No blood products on MR, arterial vascular distribution

Isolated Choroid Plexus Hemorrhage

- No blood products in ventricular wall

Isolated Intraventricular Hemorrhage

- Typically > 34 weeks GA; no blood products in ventricular wall

White Matter Injury of Prematurity

- Involves periventricular and deep white matter; no "blooming" on gradient-echo imaging

Ventriculitis

- No blood products on MR

PATHOLOGY

General Features

- Etiology
  - GMH: Rupture of GM capillaries may occur in relation to many factors
    - Altered cerebral blood flow (CBF) caused by
      - Rapid volume expansion
      - Hypercarbia
      - ↑ hemoglobin or blood glucose
      - Hypoxic-ischemic events
    - Increase in cerebral venous pressure (delivery, heart failure, positive pressure ventilation, etc.)
    - Coagulopathy
    - Capillary fragility
    - Deficient vascular support
    - Increased fibrinolytic activity
    - Hypoxic-ischemic injury

https://CafePezeshki.IR

- PHI: Venous hemorrhagic infarction likely due to GMH ± IVH compressing terminal vein
- Associated abnormalities
  - Hydrocephalus
  - Periventricular leukomalacia (high association with GMH + IVH)
  - Selective neuronal necrosis (pontine > thalamus, basal ganglia, hippocampus)

Staging, Grading, & Classification

- Papile (based on head ultrasound)
  - Grade 1: GMH (typically caudothalamic notch)
  - Grade 2: GMH + IVH
  - Grade 3: GMH + IVH + ventriculomegaly
  - Grade 4: GMH + IVH + ventriculomegaly + parenchymal extension
- Volpe (based on head ultrasound)
  - Grade 1: GMH + IVH < 10% ventricular area on parasagittal view
  - Grade 2: GMH + IVH 10-50% ventricular area on parasagittal view
  - Grade 3: GMH + IVH > 50% ventricular area on parasagittal view
  - Periventricular echodensity (probable PHI)

Gross Pathologic & Surgical Features

- GMH originates in subependymal GM
- PHI = venous hemorrhagic infarction

Microscopic Features

- Normally 2.54 ± 0.56 mm thick at 23-24 weeks GA, decreasing to 1.73 ± 0.71 mm at 29-30 weeks GA, and only 0.50 ± 0.26 mm at 35-36 weeks GA
- Subependymal hemorrhage in GM, typically caudothalamic notch if > 28 weeks GA
- Hemorrhage occurs in prominent endothelial-lined vessels similar to capillary venule or small venule
- ± obliterative arachnoiditis secondary to IVH and spread into subarachnoid space

CLINICAL ISSUES

Presentation

- Most common signs/symptoms
  - Silent > stuttering decline > catastrophic decline
    - Stuttering over hours to days
      - Altered consciousness, hypotonia, abnormal eye movements, abnormal respiration
    - Catastrophic over minutes to hours
      - Coma, flaccid &/or fixed pupils, apnea, seizures, decerebrate posturing
  - Most common presentation of GMH + IVH
    - Premature infant with respiratory distress syndrome on mechanical ventilation
- Other signs/symptoms
  - Drop in hematocrit

Demographics

- Age
  - Most common < 32 weeks GA, < 1,500 g
  - Rare > 34 weeks GA
  - Can occur in utero

Natural History & Prognosis

- > 20 weeks GM gives rise to oligodendrocytes and astrocytes
- Blood products have adverse effect on maturing SVZ cells on oligodendrocyte precursors
- ~ 90% of GM bleeds occur in ≤ 3 days
- Maximal extent reached ≤ 5 days
- Short-term prognosis
  - Grades 1 and 2: Mortality and incidence of posthemorrhagic ventriculomegaly < 15% if > 750 g
  - Grade 3: Mortality < 35% and incidence of posthemorrhagic ventriculomegaly > 75%
  - PHI: Mortality up to 45%, and incidence of posthemorrhagic ventriculomegaly > 80%
- Incidence of long-term neurological sequelae
  - Grade 1: 15%
  - Grade 2: 25%
  - Grade 3: 50%
  - PHI: 75%

Treatment

- Supportive, rarely shunting of secondary hydrocephalus
- Current emphasis on prevention

SELECTED REFERENCES

1. Brouwer AJ et al: Early and late complications of germinal matrix-intraventricular haemorrhage in the preterm infant: what is new? Neonatology. 106(4):296-303, 2014
2. Klebe D et al: Acute and delayed deferoxamine treatment attenuates long-term sequelae after germinal matrix hemorrhage in neonatal rats. Stroke. 45(8):2475-9, 2014
3. Coen RW: Preventing Germinal Matrix Layer Rupture and Intraventricular Hemorrhage. Front Pediatr. 1:22, 2013
4. Okazaki M et al: Delayed germinal matrix hemorrhage induced by ventriculoperitoneal shunt insertion for congenital hydrocephalus. J Neurosurg Pediatr. 12(1):67-70, 2013
5. Del Bigio MR: Cell proliferation in human ganglionic eminence and suppression after prematurity-associated haemorrhage. Brain. 134(Pt 5):1344-61, 2011
6. Tsitouras V et al: Infantile posthemorrhagic hydrocephalus. Childs Nerv Syst. 27(10):1595-608, 2011
7. O'Leary H et al: Elevated cerebral pressure passivity is associated with prematurity-related intracranial hemorrhage. Pediatrics. 124(1):302-9, 2009
8. Roze E et al: Risk factors for adverse outcome in preterm infants with periventricular hemorrhagic infarction. Pediatrics. 122(1):e46-52, 2008
9. Volpe JJ. Neurology of the Newborn. 5th ed. Philadelphia, PA: Saunders, 2008
10. Bassan H et al: Neurodevelopmental outcome in survivors of periventricular hemorrhagic infarction. Pediatrics. 120(4):785-92, 2007
11. Kadri H et al: The incidence, timing, and predisposing factors of germinal matrix and intraventricular hemorrhage (GMH/IVH) in preterm neonates. Childs Nerv Syst. 22(9):1086-90, 2006
12. Morioka T et al: Fetal germinal matrix and intraventricular hemorrhage. Pediatr Neurosurg. 42(6):354-61, 2006
13. Kinoshita Y et al: Volumetric analysis of the germinal matrix and lateral ventricles performed using MR images of postmortem fetuses. AJNR Am J Neuroradiol. 22(2):382-8, 2001
14. Blankenberg FG et al: Sonography, CT, and MR imaging: a prospective comparison of neonates with suspected intracranial ischemia and hemorrhage. AJNR Am J Neuroradiol. 21(1):213-8, 2000
15. Papile LA et al: Incidence and evolution of subependymal and intraventricular hemorrhage: a study of infants with birth weights less than 1,500 gm. J Pediatr. 92(4):529-34, 1978

https://CafePezeshki.IR

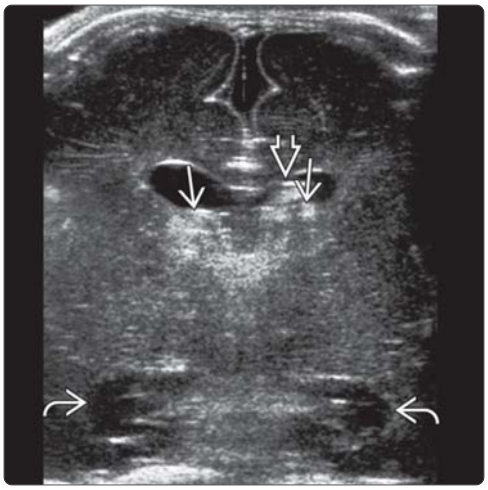

(Left) *Coronal ultrasound in a premature infant shows increased echogenicity in the bilateral caudothalamic notch due to GMH, intraventricular extension of blood, and enlargement of the lateral ventricles, including the temporal horns, diagnostic of a grade 3 germinal matrix hemorrhage (GMH).* **(Right)** *Axial T1WI MR in a premature infant with a grade 3 hemorrhage shows large bilateral GMHs and an extensive mixed intensity intraventricular clot with persistent right lateral ventricle enlargement.*

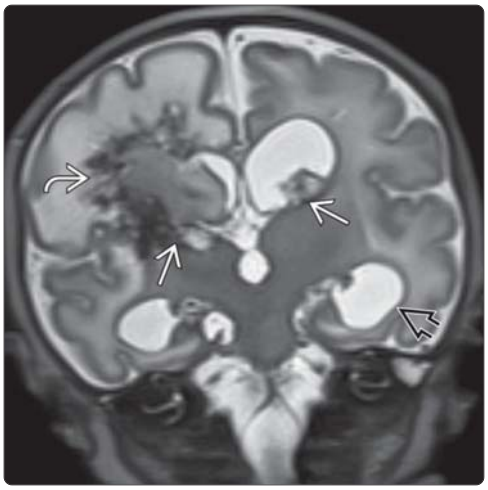

(Left) *Coronal T2 HASTE MR in a fetus of 23 weeks gestational age shows decreased signal along the inferomedial surface of the left cerebellar hemisphere, consistent with a cerebellar GMH.* **(Right)** *Coronal T2 HASTE MR in a 33-week premature infant shows bilateral germinal matrix hemorrhages and associated ventriculomegaly. The right germinal matrix hemorrhage has extended into the right frontal lobe with surrounding edema in this patient with a grade 4 GMH.*

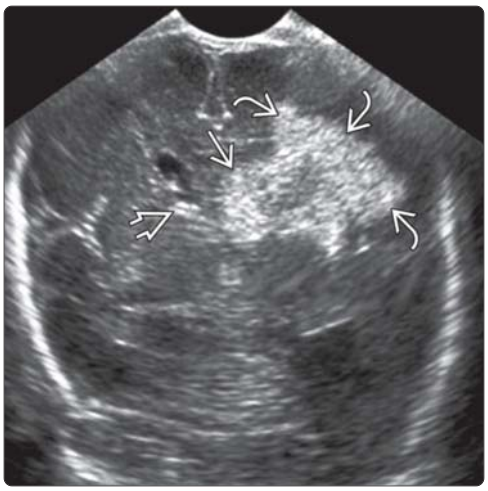

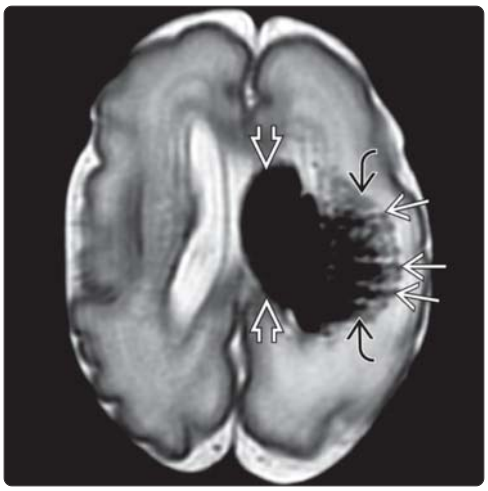

(Left) *Coronal transfontanelle ultrasound in a premature infant shows a small increased echogenicity due to GMH in the right caudothalamic notch. The GMH on the left is obscured by the intraventricular extension and very echogenic associated PHI.* **(Right)** *Axial T2WI MR in the same infant shows hypointense hemorrhage in the ventricle and the associated PHI. Note the radiating pattern of the medullary venous thrombosis in the PHI.*

https://CafePezeshki.IR

KEY FACTS

TERMINOLOGY

- Intracranial atherosclerotic vascular disease (ASVD)
- Intracranial atherosclerotic stenosis (ICAS)

IMAGING

- Gold standard is now high-resolution MR (HRMR) with direct vessel wall imaging
  - HRMR vessel wall imaging >> depicting lumen (DSA, CTA, MRA)
- Imaging findings (HRMR)
  - Crescent shaped or eccentric thickening
  - May show asymmetric hyperintensity of intraplaque hemorrhage on T1WI
  - Noncircumferential, short segment, irregular enhancement
- CTA/MRA/DSA
  - Visualizes lumen, not wall
  - Warfarin-aspirin symptomatic intracranial disease (WASID) method for calculating ICAS
    - % stenosis = [1- (diameter stenosis/diameter normal)] x 100
  - Focal stenosis, luminal irregularities in cortical vessels can mimic vasculitis
    - Most common cause of vasculitic-like appearance at angiography in middle-aged/older patient is intracranial ASVD

TOP DIFFERENTIAL DIAGNOSES

- Vasculitis/arteritis
- Vasospasm
- Dissection
- Nonocclusive thrombus or embolus

CLINICAL ISSUES

- Disease burden of intracranial ASVD greatly underestimated
- Most common cause of intracranial vascular stenosis in adults
- Independent correlation with T2/FLAIR hyperintensities

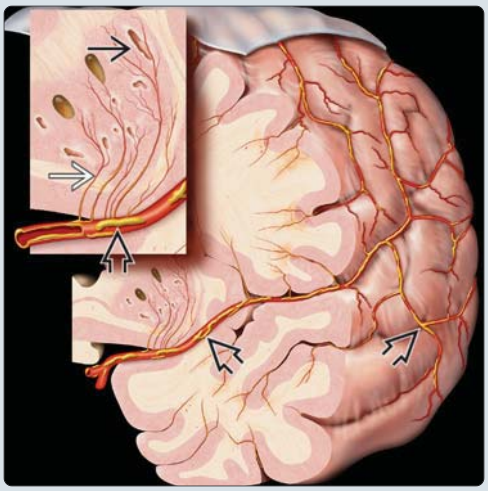

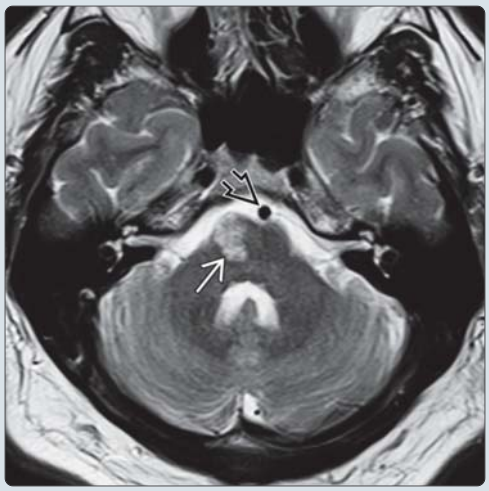

(Left) *Coronal graphic shows atherosclerotic plaques (ASVD) involving the major intracranial arteries and their branches. Inset shows penetrating (lenticulostriate) arteries and lacunar infarcts. ASVD plaques are typically short segment, irregular, noncircumferential, and may enhance.* **(Right)** *Axial T2WI shows a typical pontine perforating artery infarct. The basilar artery "flow void" appears normal.*

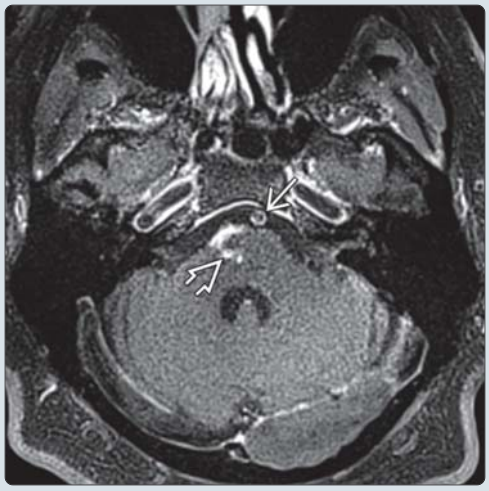

(Left) *Axial thin-section 3T T1FS MR in the same patient shows a crescent of hyperintensity in the wall of the basilar artery suggesting intraplaque hemorrhage.* **(Right)** *Thin-section 3T T1C+FS MR in the same patient shows enhancement of the subacute infarct. A partial rim of crescentic enhancement crescentic in the basilar artery wall is also present, consistent with chronic inflammation within an ASVD plaque.*

https://CafePezeshki.IR

TERMINOLOGY

Abbreviations

- Intracranial atherosclerotic vascular disease (ASVD)
- Intracranial atherosclerotic stenosis (ICAS)

Definitions

- Narrowing or ectasia of intracranial arteries secondary to ASVD

IMAGING

General Features

- Best diagnostic clue
  - ASVD plaque in vessel wall directly visualized with high-resolution MR (HRMR)
    - HRMR vessel wall imaging >> depicting lumen (DSA, CTA, MRA)
    - Crescent shaped or eccentric thickening
    - ± intraplaque hemorrhage, enhancement
  - Stenotic intracranial artery on CTA/MRA/DSA
    - Visualizes lumen, not wall
  - Less common: Dolichoectasia
    - Enlargement/tortuosity without stenosis
- Location
  - Distal basilar artery (BA), cavernous/supraclinoid ICA most common
  - Less common sites
    - Circle of Willis (COW)
    - MCA rare (2% of cases) **but** high stroke risk
- Morphology
  - Usually eccentric, irregular thickening ± ulceration, hemorrhage

CT Findings

- NECT
  - Mural Ca++
- CTA
  - MDR CTA has high sensitivity/specificity
    - In patients with > 50% stenosis or occlusion of large arteries
    - Caveat: Mural Ca++ may ↓ specificity

MR Findings

- T1WI
  - Decreased/absent flow void
  - Also seen in slow flow
    - Proximal (extracranial) stenosis, dissection
  - HRMR may show crescentic, asymmetric hyperintensity of intraplaque hemorrhage
- T2WI
  - Decreased/absent flow void
- FLAIR
  - Slow flow or occlusion may appear hyperintense
    - "Dot" sign (slow flow in distal branches)
  - Intracranial ASVD independently associated with progressively greater white matter hyperintensity (WMH) burden
- T1WI C+ FS
  - HRMR may demonstrate noncircumferential, short segment, irregular enhancement
  - May demonstrate contrast filling mural ulcerations
- MRA
  - 3D time of flight (TOF) contrast-enhanced MRA
  - Focal stenosis, ectasia, or irregularity
    - 3D TOF may overestimate stenosis
      - Secondary to spin saturation
      - Poor evaluation for slow, in-plane flow
    - Enhanced MRA less affected by spin saturation (also faster)
    - Combined with CTA, sensitivity/specificity ~ DSA
  - CTA > MRA for evaluation of in-stent restenosis
  - Dolichoectasia may also cause reduced flow

Angiographic Findings

- DSA may show
  - Focal stenosis, luminal irregularities
  - Thrombosis, occlusion
  - Ectasia/elongation
  - "Giant" serpentine/fusiform aneurysms (less common)
- Measuring ICAS
  - Warfarin-aspirin symptomatic intracranial disease (WASID) method
    - % stenosis = [1- (diameter stenosis/diameter normal)] x 100
    - For MC, intracranial vertebral and basilar arteries use most severe degree of stenosis vs. diameter of proximal artery at its widest, nontortuous normal segment

Imaging Recommendations

- Best imaging tool
  - Gold standard is now HRMR with direct vessel wall imaging
  - DSA/CTA/MRA depict lumen, not wall
- Protocol advice
  - High-resolution thin-section 3T pre- and post-contrast-enhanced T1 FS
  - CTA or MRA for proximal intracranial stenoses

DIFFERENTIAL DIAGNOSIS

Vasculitis/Arteritis

- Usually involves smaller (tertiary) branches
- More likely associated with hemorrhage
- Can be primary or secondary
- Often associated with systemic disease
- Elevated ESR, autoimmune parameters

Vasospasm

- Subarachnoid hemorrhage related, maximal 7 days post bleed
- Drug-related (sympathomimetics)

Moyamoya

- Usually involves distal ICA and proximal COW with relative sparing of basilar artery
- Frequently bilateral

Dissection

- Smooth tapering
- T1 hyperintense crescent = thrombus, best seen with fat-sat sequences

https://CafePezeshki.IR

- Younger patients
- Can have minimal or no history of trauma

Nonocclusive Thrombus or Embolus

- Appearance of rounded, central nonopacification with peripheral enhancing rim on contrast study

PATHOLOGY

General Features

- Etiology
  - Probably multiple etiologies
    - Lipid hypothesis
      - High plasma LDL leads to LDL-cholesterol deposition in intima
    - Response to injury hypothesis
      - Focal endothelial change or intimal injury leads to platelet aggregation and plaque formation
    - Unifying hypothesis
      - Endothelial injury leads to increased permeability of LDL; plaques grow by thrombus formation on plaque surface and transendothelial leakage of plasma lipids
  - Smoking associated with intracranial atherosclerosis
  - Atherosclerosis is systemic, multifactorial disease
  - Intracranial atherosclerosis associated with atherosclerosis of carotids, coronaries, aorta, renal arteries, iliofemoral system

Gross Pathologic & Surgical Features

- Earliest macroscopic finding: Intimal fatty streaks
- Fibrous atheromatous plaques contain
  - Smooth muscle cells, monocytes, other leukocytes
  - Connective tissue: Collagen, elastic fibers, proteoglycans
  - Intra- and extracellular lipid deposits
  - Angiogenesis produces new capillaries at plaque periphery
    - Leads to intraplaque hemorrhage and ulceration
    - Hemorrhage leads to dystrophic ferrocalcinosis (seen as calcification on CT, as iron on MR)
- Arterial narrowing due to plaque
  - Flow limiting beyond 50% ICAS
  - Ischemic symptoms depend on collaterals
    - Slow occlusion leads to more collaterals, fewer symptoms
    - Rapid occlusion (from thrombosis or emboli) does not permit time for collaterals to develop, infarct likely
- Arterial irregularity from disrupted endothelium may form thrombogenic surface leading to thrombosis or emboli

Microscopic Features

- Intracranial plaque components
  - Lipid, fibrous tissue, calcium
  - Chronic inflammatory markers (e.g., IL-6)

CLINICAL ISSUES

Presentation

- Most common signs/symptoms
  - Transient ischemic attack, due to emboli, severe stenosis, progressive occlusion
  - Plaque rupture usually leads to stroke
  - Vascular stenosis leads to stuttering ischemia from intermittent thrombosis

Demographics

- Age
  - Older age
- Gender
  - M = F
- Epidemiology
  - Disease burden of intracranial ASVD underestimated
    - 3rd most common cause of thromboembolic stroke, after carotid and cardiac sources
    - Basis for cerebral thromboembolism in over 90%
  - Most common cause of intracranial vascular stenosis in adults
  - ↑ prevalence in black, Asian, Hispanic, Indian populations
    - 15-30% of strokes in blacks, 30-50% in Asians

Natural History & Prognosis

- Poor; progressive disease unless treated aggressively
  - High risk of recurrent stroke

Treatment

- Low saturated fat and cholesterol diet and exercise
- Cholesterol lowering drugs ("statins") if lifestyle interventions are insufficient
- Plaque stabilization ("statins") may decrease stroke
- Angioplasty &/or stenting in some cases

DIAGNOSTIC CHECKLIST

Consider

- CTA &/or MRA as excellent screening tool
- High-resolution vessel wall imaging

SELECTED REFERENCES

1. Ahn SH et al: Isolated MCA disease in patients without significant atherosclerotic risk factors: a high-resolution magnetic resonance imaging study. Stroke. 46(3):697-703, 2015
2. Park JH et al: Association of intracranial atherosclerotic stenosis with severity of white matter hyperintensities. Eur J Neurol. 22(1):44-52, e2-3, 2015
3. Battistella V et al: Intracranial atherosclerotic disease. Eur J Neurol. 21(7):956-62, 2014
4. Gao T et al: Mechanisms of ischemic stroke in patients with intracranial atherosclerosis: A high-resolution magnetic resonance imaging study. Exp Ther Med. 7(5):1415-1419, 2014
5. Ryu CW et al: High-resolution MRI of intracranial atherosclerotic disease. Neurointervention. 9(1):9-20, 2014
6. Turan TN et al: Intracranial atherosclerosis: correlation between in-vivo 3T high resolution MRI and pathology. Atherosclerosis. 237(2):460-3, 2014
7. Holmstedt CA et al: Atherosclerotic intracranial arterial stenosis: risk factors, diagnosis, and treatment. Lancet Neurol. 12(11):1106-14, 2013
8. Samuels OB et al: A standardized method for measuring intracranial arterial stenosis. AJNR Am J Neuroradiol. 21(4):643-6, 2000

https://CafePezeshki.IR

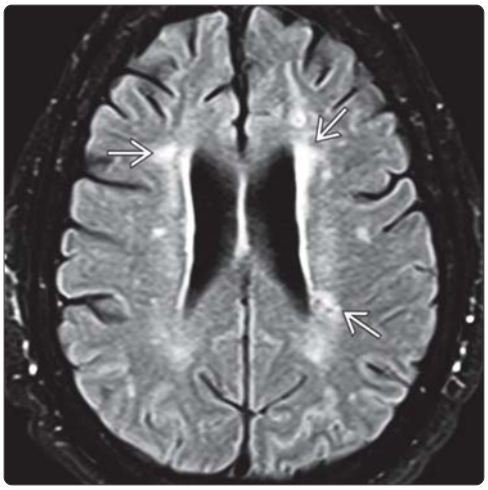

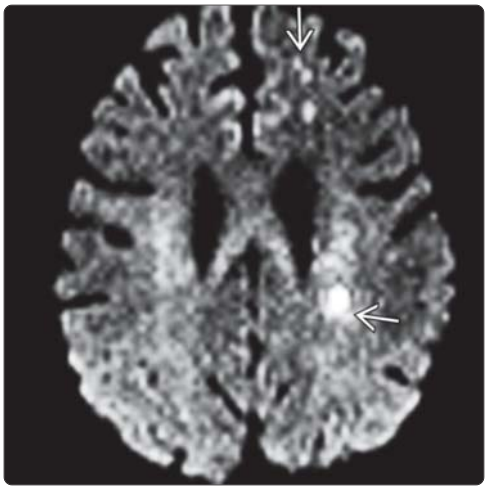

(Left) *A 68-year-old male in the ER with acute stroke symptoms had a negative NECT (not shown). MR shows extensive focal and confluent hyperintensities ➡ in the coronal radiata and deep periventricular white matter (WM) of both hemispheres.* **(Right)** *Axial DWI in the same patient shows several foci of restricted diffusion ➡ that "line up" along the periventricular deep WM of the left hemisphere.*

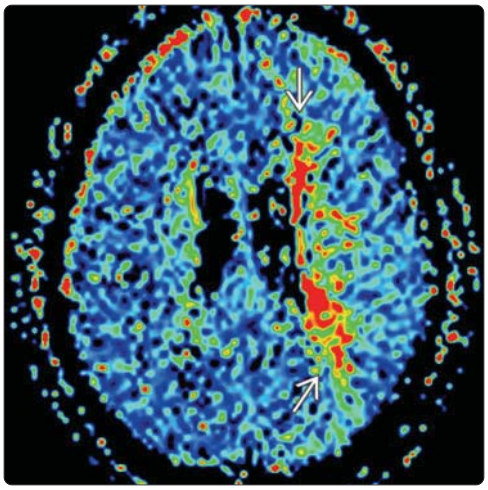

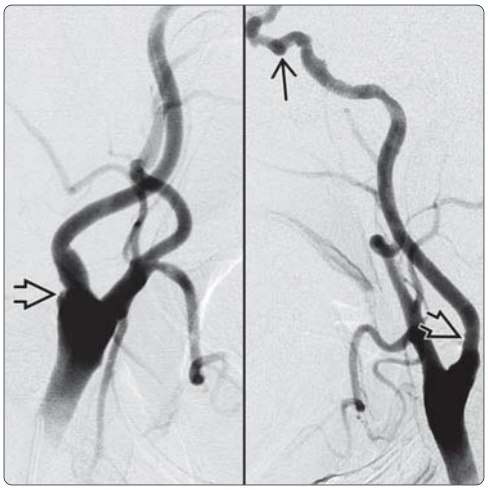

(Left) *MR perfusion in the same patient shows no evidence for a major territorial infarct. However, there is prolonged mean transit time (MTT) ➡ in the internal watershed zone of the left hemisphere deep cerebral WM.* **(Right)** *Because the MR perfusion scan suggested deep watershed zone ischemia, a DSA was performed. While there are some minor irregularities of both proximal internal carotid arteries ⇨, no flow-limiting stenoses were identified. The most severe disease affects the left cavernous ICA ⇨.*

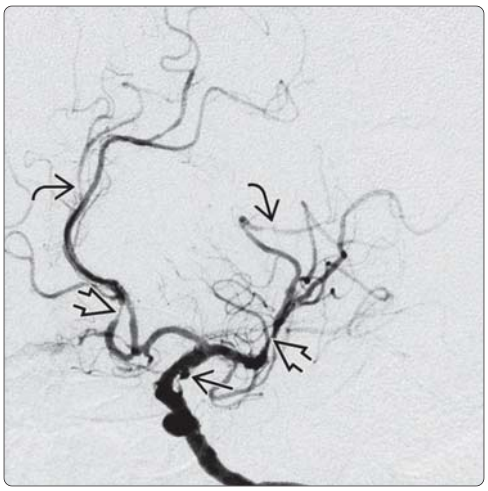

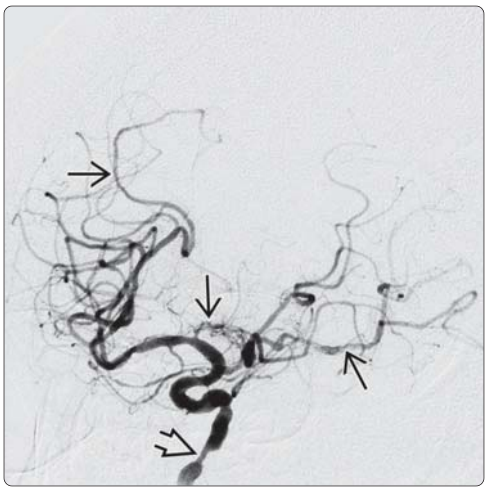

(Left) *Oblique view of the intracranial left ICA shows irregularities in the cavernous/supraclinoid segments ⇨. High-grade stenosis of the M2 and A2 segments are present ⇨. Note the irregularities of more peripheral branches ⇨.* **(Right)** *Oblique view of the right intracranial ICA shows a high-grade stenosis of the cavernous segment ⇨, as well as multifocal areas of irregularity and narrowing of more distal vessels ⇨. The findings in this case are those of severe intracranial ASVD.*

https://CafePezeshki.IR

KEY FACTS

TERMINOLOGY

- Degenerative process resulting from plasma lipid deposition in arterial walls

IMAGING

- Smooth/irregular narrowing of proximal ICA
- Ca++ in arterial walls
- ICA, vertebrobasilar arteries most common sites
- Single diameter thresholds for CTA: 2.2mm (50% stenosis), 1.3mm (70% stenosis)
- Protocol advice
  - Color Doppler US as initial screen
  - CTA/MRA or contrast MRA
  - Consider DSA prior to carotid endarterectomy, in equivocal cases or if CTA/MRA shows "occlusion"

PATHOLOGY

- NASCET method: % stenosis = (normal lumen - minimal residual lumen)/normal lumen, x 100
- Mild (< 50%), moderate (50-70%), severe (70-99%)
- Intraplaque hemorrhage is independent stroke risk factor

CLINICAL ISSUES

- CEA if symptomatic carotid stenosis ≥ 70% (NASCET)
- Symptomatic moderate stenosis (50-69%) also benefits from CEA (NASCET)
- Asymptomatic patients benefit even with stenosis of 60% (ACAS)
- Carotid stenting depends on preop risk factors
- Signs/symptoms (can be asymptomatic)
  - Carotid bruit, TIA, stroke (may be silent)

DIAGNOSTIC CHECKLIST

- DSA remains gold standard but acceptable noninvasive preoperative imaging includes any 2
  - US, CTA, TOF or enhanced MRA
- Late-phase DSA important to rule out pseudoocclusion
  - High-grade stenosis with "string" sign

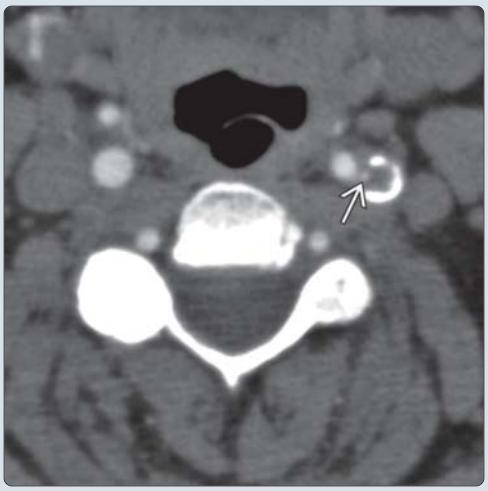

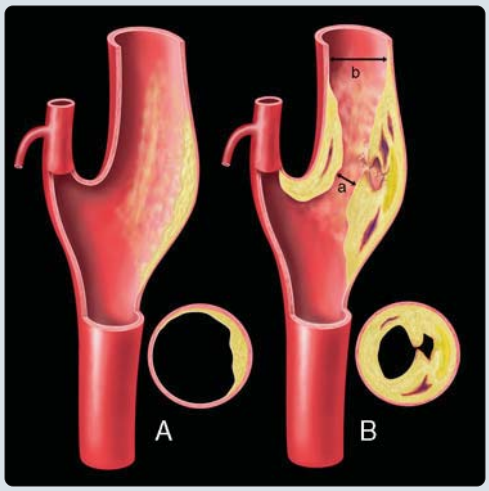

(Left) *Axial CTA shows a severe stenosis of the proximal left ICA with a small residual lumen ➡. Note the typical peripheral mural calcification and the lower density lipid-rich core of the more central soft plaque in the left ICA.* **(Right)** *Graphic shows the mild form of ASVD (A) with "fatty streaks" & slight intimal thickening. The severe form (B) is characterized by intraplaque hemorrhage, ulceration, & platelet thrombi. NASCET calculation for % of stenosis = (b-a)/b x 100 where b = normal ICA lumen & a = minimal residual ICA lumen.*

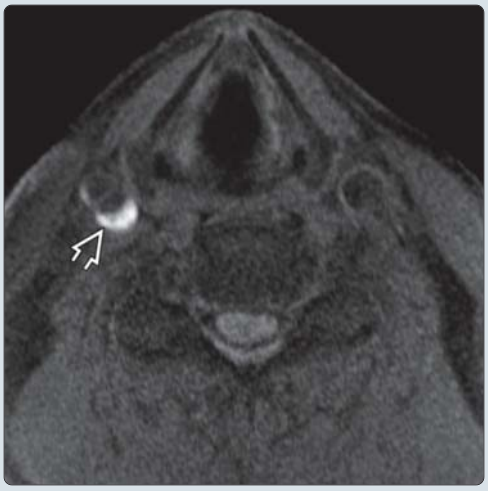

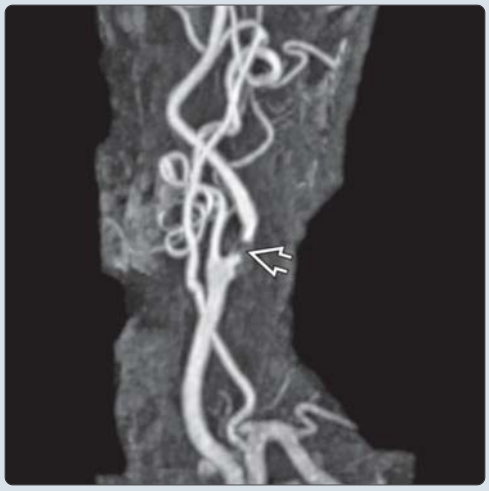

(Left) *Axial MP-RAGE sequence shows intraplaque hemorrhage ➡ in the right ICA as a hyperintense crescent. Intraplaque hemorrhage is an independent stroke risk factor, regardless of ICA percent stenosis. (Courtesy JS McNally, MD, PhD.)* **(Right)** *Coronal oblique MRA shows signal loss as a "flow gap" in the left internal carotid artery ➡ indicating severely restricted flow, typically > 95% stenosis. The patient underwent an emergency left carotid endarterectomy.*

https://CafePezeshki.IR

TERMINOLOGY

Abbreviations

- Atherosclerotic vascular disease (ASVD)

Definitions

- Degenerative process resulting from plasma lipid deposition in arterial walls

IMAGING

General Features

- Best diagnostic clue
  - Smooth or irregular narrowing of proximal ICA
  - Ca++ deposition in arterial walls
- Location
  - ICA, vertebrobasilar arteries most common sites
    - Proximal ICA, common carotid bifurcations
  - Affects large/medium/small arteries, arterioles
- Size
  - Ranges from microscopic lipid deposition to fatty streaks to gross plaque
    - Generally 0.3-1.5 cm in diameter
- Morphology
  - Begins initially as smooth, slight eccentric thickening of vessel intima
  - Progresses to more focal and prominent eccentric thickening (subintimal macrocyte and smooth muscle cell deposition)
  - Subintimal hemorrhage from "new vessels" further narrows lumen
  - Ulceration with rupture of fibrous cap and intima occurs, resulting in "ulcerated plaque"

CT Findings

- NECT
  - Ca++ in vessel walls
  - Large plaques may show low-density foci (soft plaque)
  - Ectasia, tortuosity, fusiform vessel dilatation
- CTA
  - CTA as accurate as DSA for ICA stenosis
  - Visualizes degree of stenosis vs. occlusion
  - CTA can characterize plaque composition
    - Shows hemorrhage, ulceration, fibrous cap
    - Use MPR and MIP reconstructions
    - Detection of ulceration: Up to 94% sensitivity, 99% specificity

MR Findings

- T1WI
  - Wall thickening, luminal narrowing
  - Absence of "flow void"
    - May occur if vessel occluded or severely stenotic
  - Hyperintense in plaque hemorrhage
- T1WI C+ FS
  - High-resolution ICA imaging with dedicated surface coils can characterizes plaque composition
  - Hemorrhage/plaques with a higher percentage of lipid-rich/necrotic core
    - Independently associated with a thin or ruptured fibrous cap ("at risk" plaque)
- MRA
  - 2D TOF or contrast enhanced
  - Degree of stenosis visualized
  - Signal loss may occur if high-grade (> 95%) stenosis
    - Severe narrowing causes "flow gap"

Ultrasonographic Findings

- Grayscale imaging allows visualization of noncalcified (hypoechoic) or calcified (hyperechoic) plaque in vessel wall
- Hypoechoic plaques are independent risk factors for stroke; strong correlation with ↑ lipoprotein(s)
- Doppler measures flow velocity; peak systolic velocity is best single parameter for quantifying stenosis
- Spectral analysis allows evaluation of waveform; morphologic changes in waveform occur with ↑ stenosis
- Color Doppler may detect high-grade occlusions more reliably than conventional Doppler

Angiographic Findings

- Identifies degree of stenosis, morphology of plaque, tandem stenoses, potential collateral pathways as coexisting pathology (i.e., aneurysm)
- Plaque surface irregularity associated with increased risk of stroke at all degrees of stenosis
- Tandem lesions (distal stenoses) present in ~ 2% of patients with significant cervical ICA lesions
- Hemodynamic effect of tandem stenoses additive: If both lesions are severe enough to ↓ flow separately
  - If only 1 tandem lesion is critical, flow is governed by more severe lesion
- Late phase DSA important in high-grade stenosis or suspected occlusion to rule out "pseudoocclusion"

Imaging Recommendations

- Best imaging tool
  - DSA remains gold standard → acceptable noninvasive preoperative imaging includes any 2 of following: US, CTA, TOF, or contrast MRA
    - Exception: Late-phase DSA remains important in suspected high-grade stenosis or occlusion to rule out pseudoocclusion
- Protocol advice
  - Color Doppler US as initial screen
  - CTA/MRA or contrast MRA
  - Consider T1WI FS or MPRAGE for intraplaque hemorrhage
  - Consider DSA prior to carotid endarterectomy in equivocal cases or if CTA/MRA shows "occlusion"

DIFFERENTIAL DIAGNOSIS

Dissection

- Typically spares carotid bulb; no calcification
- Seen in young or middle-aged groups
- Smoother, longer narrowing without intracranial involvement

Fibromuscular Dysplasia

- "String of beads" > > long-segment stenosis

Vasospasm

- Usually iatrogenic (catheter-induced), transient

https://CafePezeshki.IR

PATHOLOGY

General Features

- Etiology
  - 3 main hypotheses
    - Lipid hypothesis: Relates ASVD to high-plasma LDL levels causing LDL-cholesterol deposits in arterial intima
    - Response to injury hypothesis: ASVD is initiated by focal endothelial damage that initiates platelet aggregation and plaque formation
    - Unifying theory: Suggests that endothelial injury is accompanied by increased permeability to macromolecules, such as LDL
  - Other factors include, diet, genes, mechanical stress (e.g., wall shear, anatomic variations), inflammation, hyperhomocysteinemia
  - Complex, multifactorial process; pathogenesis remains controversial
    - Likely a combination of lipid retention, inflammation, neoangiogenesis
  - Intraplaque hemorrhage is independent stroke risk factor
  - ASVD likely interaction of genetic and environmental factors, likely no single cause
  - Irregular plaques correlate with higher stroke risk
  - Good collaterals correlates with lower stroke risk
  - Significant ICA narrowing seen in 20-30% of ICA territory strokes vs. 5-10% of general population
- Genetics
  - Probably multigenic
  - Plaques develop faster in those with genetic predisposition and acquired risk factors (HTN, smoking, type 2 diabetes, obesity)

Staging, Grading, & Classification

- Methods for calculating degree of stenosis vary: NASCET, ACAS, ECST, and VACSG
- NASCET method: % stenosis = (normal lumen - minimal residual lumen)/normal lumen, x 100
  - Mild (< 50%), moderate (50-69%), severe (70-99%)
- Single diameter thresholds for CTA: 2.2mm (50% stenosis), 1.3mm (70% stenosis)

Gross Pathologic & Surgical Features

- 2 well-accepted lesions described: Atheromatous plaque and fatty streak
  - Atheromatous plaque: Most important, principal cause of arterial narrowing in adults
  - Fatty streak: Precursor of atheromatous plaque; present universally in children, even in 1st year
- Intimal fatty streaks are earliest macroscopically visible lesions
- Plaques are whitish-yellow, protrude intraluminally, vary in size

Microscopic Features

- Fibroatheromatous plaques, develop after lipid deposition
- Plaques contain cells (monocytes/macrophages, leukocytes, smooth muscle), connective tissue, intra-/extracellular lipid deposits
- Necrotic core of lipid, cholesterol, cellular debris, lipid-laden foam cells, and fibrin form within plaque
- Neovascularization may lead to vessel rupture, intraplaque hemorrhage, and ulceration
- Atheromatous plaque may rupture (fibrous cap weakens and fractures); may lead to distal embolization

CLINICAL ISSUES

Presentation

- Most common signs/symptoms
  - Variable: Asymptomatic, carotid bruit, TIA, stroke (may be silent)
- Clinical profile
  - Stroke risk factors: Smoking, hypertension, diabetes, obesity, hypercholesterolemia, advanced age

Demographics

- Age
  - Usually middle-aged to elderly
- Gender
  - M > F
- Ethnicity
  - African Americans at highest risk for ASVD
- Epidemiology
  - Leading cause of morbidity, mortality in USA
  - ASVD is largest risk factor for stroke
  - Ischemic stroke → up to 40% of deaths in elderly
  - Stroke occurs in > 70% of patients with ICA occlusion
  - 90% of large, recent infarcts are caused by thromboemboli
  - Epidemiological, experimental evidence that increased dietary lipid (cholesterol, saturated fat) and smoking correlate with atherosclerosis

Treatment

- Carotid endarterectomy (CEA) if symptomatic carotid stenosis ≥ 70% (NASCET)
- Symptomatic moderate stenosis (50-69%) also benefits from CEA (NASCET)
- ICA stenting depends on preoperative risk factors

DIAGNOSTIC CHECKLIST

Consider

- For patients undergoing CEA, adequacy of collateral circulation is critical; consider MRA or DSA
- To calculate degree of stenosis on DSA, ≥ 2 projections are required to profile plaque adequately

SELECTED REFERENCES

1. de Rotte AA et al: Plaque Components in Symptomatic Moderately Stenosed Carotid Arteries Related to Cerebral Infarcts: The Plaque At RISK Study. Stroke. ePub, 2015
2. McNally JS et al: Intraluminal thrombus, intraplaque hemorrhage, plaque thickness, and current smoking optimally predict carotid stroke. Stroke. 46(1):84-90, 2015
3. Narumi S et al: Carotid Plaque Characterization Using 3D T1-Weighted MR Imaging with Histopathologic Validation: A Comparison with 2D Technique. AJNR Am J Neuroradiol. ePub, 2015
4. Gupta A et al: CT Angiographic Features of Symptom-Producing Plaque in Moderate-Grade Carotid Artery Stenosis. AJNR Am J Neuroradiol. ePub, 2014
5. Kaproth-Joslin KA et al: The essentials of extracranial carotid ultrasonographic imaging. Radiol Clin North Am. 52(6):1325-42, 2014

https://CafePezeshki.IR

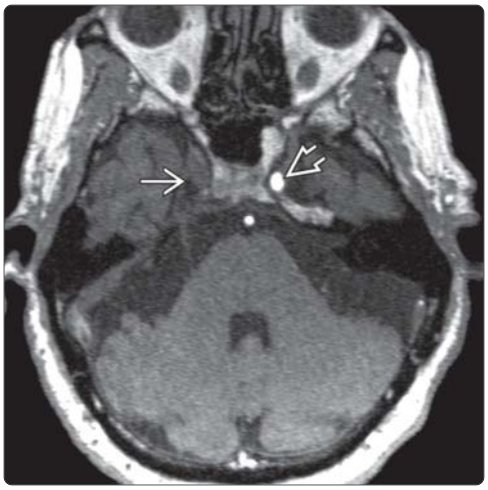

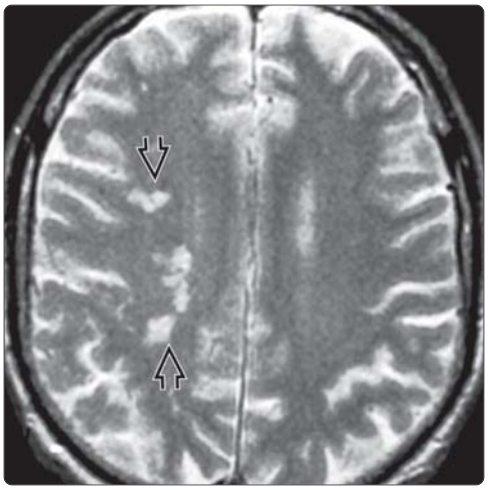

(Left) *Axial MRA shows a lack of flow in the right cavernous ICA ⇨. Note the normal flow related enhancement of the left cavernous ICA ⇨.* **(Right)** *Axial T2 MR image in the same patient shows a vertical line of white matter hyperintensities ⇨. These lesions form a rosary-like pattern and are along the deep white matter watershed zone where the cortical penetrating arteries meet the deep perforating arteries from the circle of Willis. They should alert the radiologist to the possibility of a flow-limiting lesion, often related to carotid ASVD.*

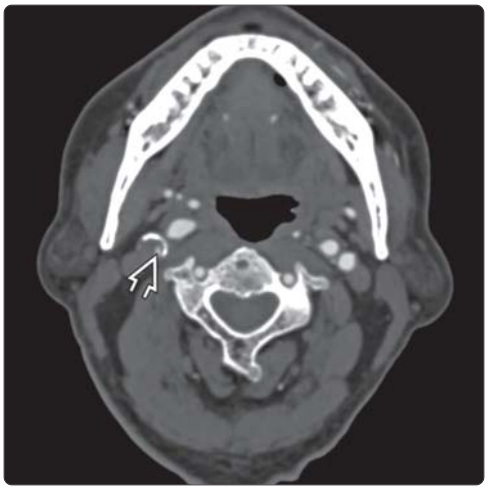

(Left) *Axial CTA shows a severe right common carotid artery stenosis with a very small residual lumen ⇨. Although DSA is considered the gold standard for evaluation of carotid stenosis, there is a linear relationship between CTA and DSA measurements of percent stenosis by NASCET criteria.* **(Right)** *Lateral DSA shows severe, short segment stenosis ⇨ of the right ICA. This patient would be amenable to an endovascular carotid stent or carotid endarterectomy.*

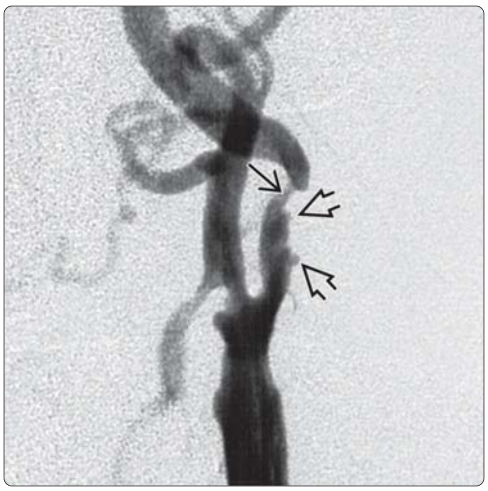

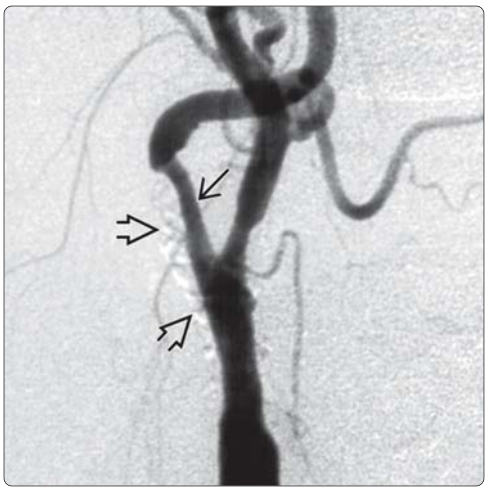

(Left) *Lateral angiography in a patient with left hemisphere TIAs shows a high-grade stenosis ⇨ distal to the left ICA bulb. Multiple irregularities in the atherosclerotic plaque are seen here as outpouchings of contrast ⇨. Irregularity is an independent risk factor for thromboembolic stroke, making this an "at risk" plaque.* **(Right)** *Lateral angiography in the same patient shows long-segment stenosis of the right ICA origin ⇨. Note the subtraction artifact from dense wall calcification ⇨.*

https://CafePezeshki.IR

KEY FACTS

TERMINOLOGY

- Sclerosis of small-sized arteries (arterioles)
  - Common with chronic hypertension (HTN) &/or diabetes
  - May lead to vascular dementia (VaD)

IMAGING

- Multifocal white matter (WM) hypodensity on CT
- Patchy/confluent ↑ T2/FLAIR hyperintensities
  - Broad or confluent base with ventricles
  - Periventricular > deep > juxtacortical involvement
- Findings nonspecific
  - Large number of causes other than arteriopathy
  - Demyelination, infection, inflammatory, drug related, metabolic, age-related
- Caused by several types of arteriopathy
  - Arteriolosclerosis
  - Chronic hypertension (more basal ganglia, periventricular white matter involvement)
  - Diabetes mellitus (more peripheral involvement)

TOP DIFFERENTIAL DIAGNOSES

- Age-related white matter changes
- Perivascular (Virchow-Robin) spaces (PVSs)
- Demyelinating disease
- VaD
- Cerebral autosomal dominant arteriopathy with subcortical infarcts and leukoencephalopathy (CADASIL)
- Cerebral amyloid angiopathy (CAA)

CLINICAL ISSUES

- Clinical and radiographic picture overlaps
  - Multi-infarct (vascular) dementia: Caused by arteriolosclerosis &/or multiple infarcts
  - Subcortical arteriosclerotic encephalopathy (SAE; Binswanger disease)

DIAGNOSTIC CHECKLIST

- Use FLAIR, T2* (GRE, SWI) sequences in all elderly patients
  - Look for microbleeds (HTN, CAA)

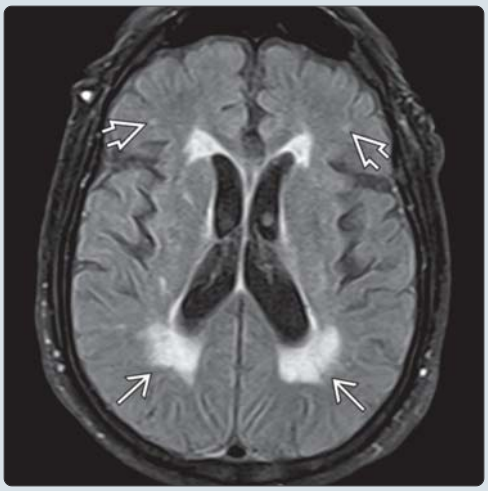

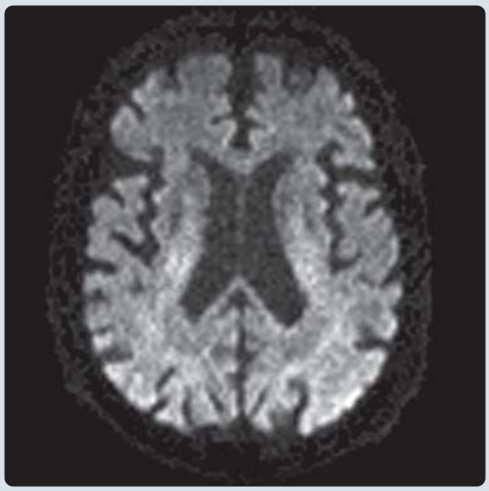

(Left) *Axial FLAIR MR image shows mild atrophy and confluent periventricular ⇨ and punctate subcortical ⇨ white matter hyperintensity typical for arteriolosclerosis (chronic small vessel disease) in this elderly patient with mild cognitive impairment.* **(Right)** *Axial DTI trace image shows no areas of diffusion restriction to suggest acute ischemia in this elderly patient. Arteriolosclerosis may mask an acute ischemic event, so DWI or DTI sequences are helpful to exclude acute ischemia in this patient population.*

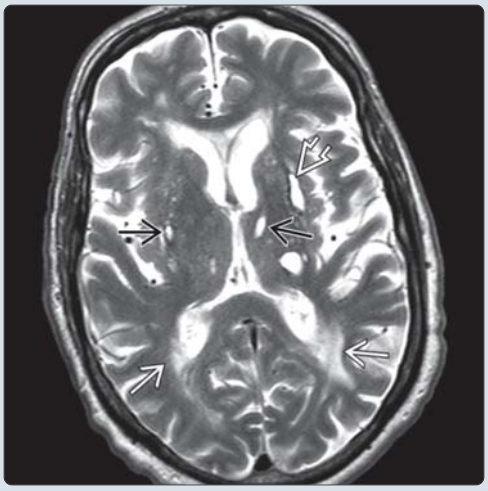

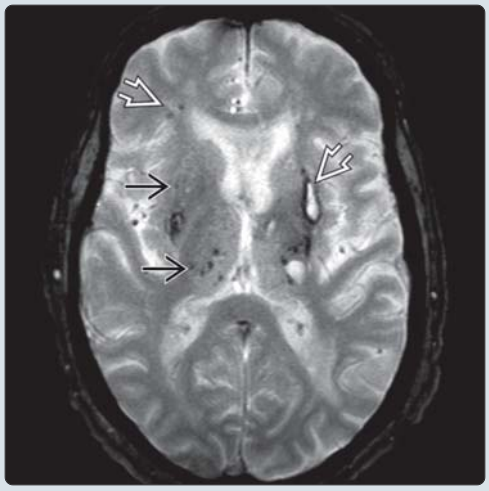

(Left) *Axial T2 MR image in a patient with chronic hypertension shows confluent regions of periventricular hyperintensity ⇨ related to arteriolosclerosis. There are chronic lacunar infarcts ⇨ and a chronic hypertensive basal ganglia hemorrhage ⇨.* **(Right)** *Axial GRE MR image shows hypointensity related to hemosiderin along the chronic hypertensive hemorrhage. Multiple foci of susceptibility artifact or "blooming" are seen in the deep gray nuclei ⇨ and white matter ⇨ related to microhemorrhages from chronic hypertension.*

https://CafePezeshki.IR

TERMINOLOGY

Synonyms

- Small vessel disease, microvascular disease, microangiopathy
- Imaging correlate = leukoaraiosis or periventricular leukoencephalopathy

Definitions

- Sclerosis of small-sized arteries (arterioles)
  - Commonly from chronic HTN, hypercholesterolemia &/or diabetes mellitus (DM)
  - May lead to vascular dementia

IMAGING

General Features

- Best diagnostic clue
  - White matter (WM) hypodensity (rarefaction) on CT
  - Patchy/confluent hyperintensity on T2WI/FLAIR
- Location
  - Periventricular white matter (PVWM) and deep WM
    - Broad or confluent base with ventricle
    - Periventricular (particularly along atria of lateral ventricles) > deep > subcortical involvement
  - Basal ganglia (BG)
    - More BG involvement with chronic HTN
    - More peripheral WM involvement
      - Diabetes mellitus, cerebral amyloid angiopathy
- Size
  - Varies, progresses with age
  - Range: Punctate to large confluent
- Morphology
  - Bilateral patchy or confluent

CT Findings

- NECT
  - Multifocal/confluent ill-defined hypodense areas that spare cortex
  - Broad or confluent base with ventricles
    - Periventricular > deep > juxtacortical involvement
- CECT
  - No enhancement

MR Findings

- T1WI
  - Patchy or confluent hypointense foci
- T2WI
  - Ill-defined hyperintensities, typically ≥ 5 mm
- PD/intermediate
  - Patchy or confluent hyperintense foci
- FLAIR
  - Most conspicuous sequence for hyperintensities
  - Significance of PVWM hyperintensities is controversial
    - Findings are nonspecific and occur with normal aging
    - Likely due to several types of arteriopathy, many of which are combined
      - Arteriolosclerosis
      - Chronic hypertension &/or diabetes mellitus
      - Cerebral amyloid angiopathy
      - Cerebral autosomal dominant arteriopathy with subcortical infarcts and leukoencephalopathy (CADASIL)
- T2* GRE
  - Multifocal "black dots" or susceptibility artifact, more commonly seen with chronic hypertension, amyloid angiopathy
- DWI
  - No associated restriction, unless acute lesion
- T1WI C+
  - Nonenhancing
- MRS
  - Reduced N-acetyl aspartate (NAA), NAA/Cr
- ± generalized atrophy (large ventricles, sulci)
- Extensive/confluent lesions found in 2-6% of normal elderly

Angiographic Findings

- Small and larger vessel arterial stenoses

Nuclear Medicine Findings

- PET/SPECT: In absence of atrophy, rCBF/rMRGlu usually normal

Imaging Recommendations

- Best imaging tool
  - MR
- Protocol advice
  - MR with FLAIR, DWI, T2* (GRE or SWI)

DIFFERENTIAL DIAGNOSIS

Age-Related White Matter Changes

- Significant overlap with normal, mild cognitive impairment (MCI) and demented elderly
- Other risk factors (HTN, DM) common

Perivascular (Virchow-Robin) Spaces (PVSs)

- Variable size, well delineated
- Most common around anterior commissure, deep white matter
- Signal, attenuation like CSF
- Peripheral high signal on FLAIR can be seen with both PVSs (in up to 25%) and with lacunar infarcts

Demyelinating Disease

- MS > ADEM
- Usually ovoid, periventricular
- Callososeptal interface involved (rare with ASVD)
- Younger patient population

Vascular Dementia (VaD) Overlaps With Arteriolosclerotic Disease

- Cognitive impairment
  - Multi-infarct dementia (MID)
  - Subcortical arteriosclerotic encephalopathy (Binswanger-type vascular dementia)
    - Longstanding hypertension, progressive decline in mental function, gait disturbances, ± minor strokes
    - Clinical diagnosis, not an imaging diagnosis
- Large and small infarcts

CADASIL

- Younger patient (≤ 40) with PVWM hyperintensities

https://CafePezeshki.IR

- Stronger predilection for anterior temporal and frontal lobe involvement

Cerebral Amyloid Angiopathy (CAA)

- Amyloid deposition in walls of small to medium-sized arteries and arterioles
- Lobar hemorrhages and microhemorrhages characteristic
- T2* GRE and SWI sequences key to diagnosis

PATHOLOGY

General Features

- Etiology
  - Hypertensive occlusive disease of small penetrating arteries
    - Results in white matter lesions and lacunar infarcts
- Genetics
  - General risk factors for peripheral/cerebral vascular diseases
    - *APOE*E4* alleles
    - Angiotensinogen gene promoter
  - CADASIL
    - *NOTCH3* mutations
- Associated abnormalities
  - Microangiopathy-related cerebral damage = PVWM hyperintensities, lacunar infarcts
  - PVWM hyperintensities on imaging does not always have pathologic correlate

Staging, Grading, & Classification

- European Task Force on Age-Related White Matter Changes (ARWMC) rating scale for MR and CT (for ill-defined lesions ≥ 5 mm)
  - White matter lesions
    - 0 = no lesions (including symmetrical caps, bands)
    - 1 = focal lesions
    - 2 = beginning confluence of lesions
    - 3 = diffuse involvement, ± U-fibers
  - Basal ganglia lesions
    - 0 = no lesions
    - 1 = 1 focal lesion (≥ 5 mm)
    - 2 = > 1 focal lesion
    - 3 = confluent lesions

Gross Pathologic & Surgical Features

- Generalized volume loss with prominent sulci and ventricles
- Periventricular and deep WM spongiosis
- Multifocal lacunar infarcts often present

Microscopic Features

- Normal age-related changes
- Imaging PVWM hyperintensities have spectrum of histopathologic correlates
  - Degenerated myelin (myelin "pallor")
  - Axonal loss with increased extracellular fluid
  - Gliosis, spongiosis
  - Lipofibrohyalinolysis with small vessel occlusions
  - Dilated perivascular spaces

CLINICAL ISSUES

Presentation

- Most common signs/symptoms
  - Broad range
    - May be normal, have mild cognitive impairment or dementia
- Clinical profile
  - Older patient with cerebrovascular risk factors (hypertension, hypercholesterolemia, diabetes, etc.)

Demographics

- Age
  - PVWM hyperintensities almost universal after 65 years
  - Lacunar infarcts in 1/3 of asymptomatic healthy patients > 65 years
- Gender
  - M = F
- Epidemiology
  - Vascular dementia (VaD): 3rd most common cause of dementia (after Alzheimer disease, Lewy body disease), accounts for 15% of cases
  - VaD is caused by arteriolosclerosis &/or multiple cortical/subcortical infarcts

Treatment

- Modification of known cerebrovascular risk factors

DIAGNOSTIC CHECKLIST

Consider

- Use FLAIR, T2* (GRE, SWI) sequences in elderly patients
- GRE/SWI hypointensities suggest chronic hypertension or amyloid
- More peripheral location suggests amyloid
- Anterior temporal lobe involvement in middle-aged patient suggests CADASIL

Image Interpretation Pearls

- Many causes of PVWMs other than arteriopathy (demyelination, infection, inflammatory, toxic, metabolic)
- Clinical and imaging findings overlap with multi-infarct (vascular) dementia, subcortical arteriosclerotic encephalopathy (Binswanger disease)

SELECTED REFERENCES

1. Bertelson JA et al: Neuroimaging of dementia. Neurol Clin. 32(1):59-93, 2014
2. Bridges LR et al: Blood-brain barrier dysfunction and cerebral small vessel disease (arteriolosclerosis) in brains of older people. J Neuropathol Exp Neurol. 73(11):1026-33, 2014
3. Craggs LJ et al: Microvascular pathology and morphometrics of sporadic and hereditary small vessel diseases of the brain. Brain Pathol. 24(5):495-509, 2014
4. Neltner JH et al: Arteriolosclerosis that affects multiple brain regions is linked to hippocampal sclerosis of ageing. Brain. 137(Pt 1):255-67, 2014
5. Roh JH et al: Recent updates on subcortical ischemic vascular dementia. J Stroke. 16(1):18-26, 2014
6. Erten-Lyons D et al: Neuropathologic basis of white matter hyperintensity accumulation with advanced age. Neurology. 81(11):977-83, 2013
7. Schreiber S et al: Blood brain barrier breakdown as the starting point of cerebral small vessel disease? - New insights from a rat model. Exp Transl Stroke Med. 5(1):4, 2013
8. Smith EE et al: Cerebral microinfarcts: the invisible lesions. Lancet Neurol. 11(3):272-82, 2012

https://CafePezeshki.IR

(Left) *Axial noncontrast CT shows diffuse atrophy and extensive confluent periventricular and subcortical hypodensity ➡ typical for severe arteriolosclerosis in this elderly patient with dementia.* **(Right)** *Axial CT at the level of the corona radiata shows extensive involvement of the white matter ➡ by arteriolosclerosis (chronic small-vessel ischemia) in this patient with longstanding hypertension and a clinical diagnosis of vascular dementia (Binswanger-type).*

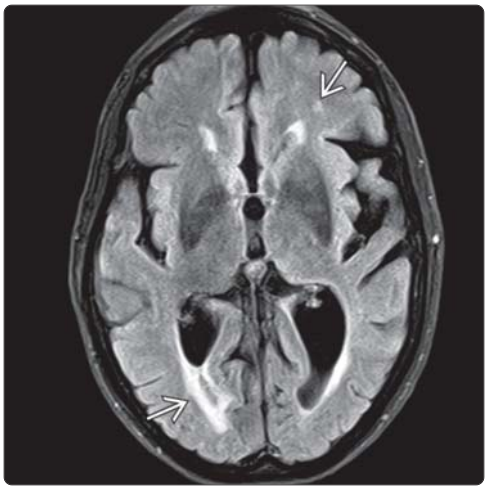

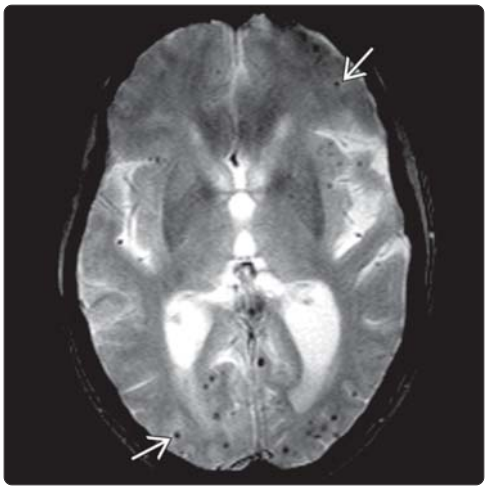

(Left) *Axial FLAIR MR image shows mild periventricular and subcortical white matter hyperintensity ➡ related to arteriolosclerosis in a 51-year-old woman with cerebral amyloid angiopathy.* **(Right)** *Axial GRE image shows the typical peripheral distribution of hypointensity or "blooming" related to susceptibility artifact from blood products in the cortex and subcortical white matter ➡ of this patient with amyloid angiopathy. Note the relative sparing of the deep gray nuclei.*

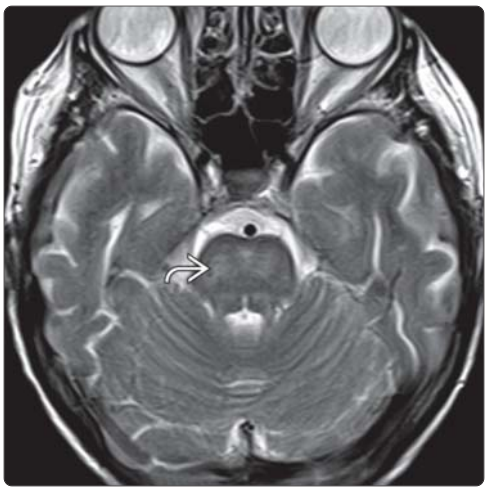

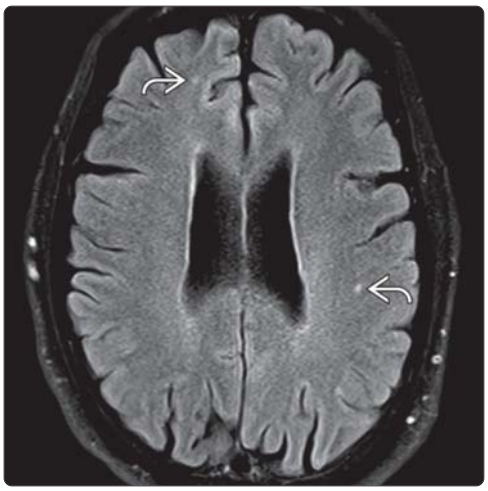

(Left) *Axial T2 MR image shows the typical patchy central hyperintensity in the pons related to arteriolosclerosis in ➡ in this patient with a history of hypertension.* **(Right)** *Axial FLAIR MR image in a 65-year-old normotensive man shows a few punctate foci of hyperintensity ➡ in the subcortical white matter. Note the mild diffuse volume loss, a typical finding in normal aging.*

https://CafePezeshki.IR

KEY FACTS

TERMINOLOGY

- Aberrant internal carotid artery (AbICA): Congenital vascular anomaly resulting from failure of formation of extracranial ICA with arterial collateral pathway

IMAGING

- Appearance of AbICA on thin section (< 1 mm) temporal bone CT is diagnostic
- AbICA appears as tubular lesion crossing middle ear from posterior to anterior
- Enlarged inferior tympanic canaliculus important observation
- Caution: Do not mistake AbICA for glomus tympanicum paraganglioma

TOP DIFFERENTIAL DIAGNOSES

- Vascular middle ear lesion
  - Glomus tympanicum paraganglioma
  - Dehiscent jugular bulb
  - Lateralized internal carotid artery

PATHOLOGY

- Best explanation: "Alternative blood flow" theory
  - Persistence of pharyngeal artery system means C1 portion of ICA is absent
  - Mature arterial collateral system compensates for absent C1 and vertical petrous ICA segments
  - Ascending pharyngeal artery → inferior tympanic artery → caroticotympanic artery → posterolateral aspect of horizontal petrous ICA
- 30% of AbICA have persistent stapedial artery

CLINICAL ISSUES

- Typically asymptomatic and discovered at time of routine physical exam, during middle ear surgery, or as incidental imaging finding
- Associated symptoms: Pulsatile tinnitus and conductive hearing loss
- No treatment is best treatment

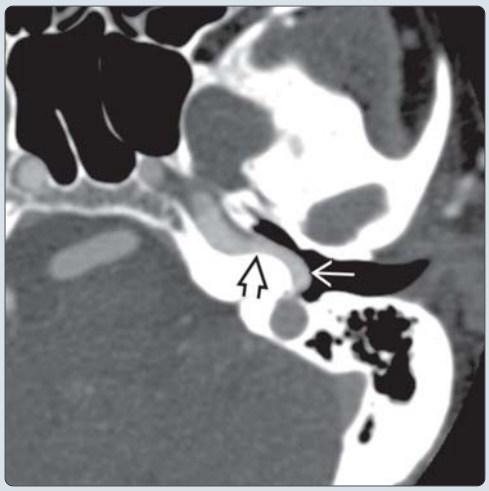

(Left) *Axial graphic of the left temporal bone illustrates a classic AbICA ➡ rising along the posterior cochlear promontory and crossing along the medial middle ear wall to rejoin the horizontal petrous ICA ⇨. At the point of reconnection to the horizontal petrous ICA, stenosis ➡ is often present.* **(Right)** *Axial CTA image through the middle ear shows the looping aberrant internal carotid ➡ on the low cochlear promontory. Note the caliber change ⇨ as the AbICA rejoins the normal horizontal segment of the ICA.*

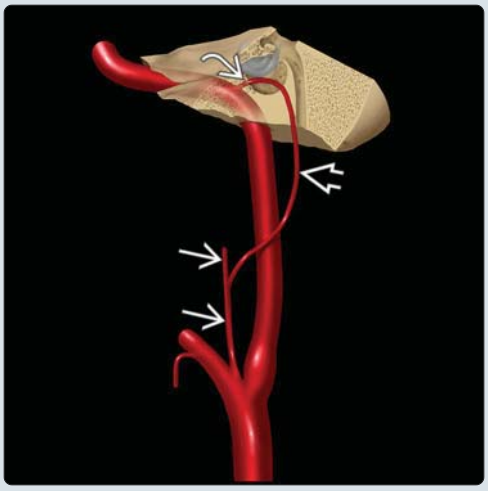

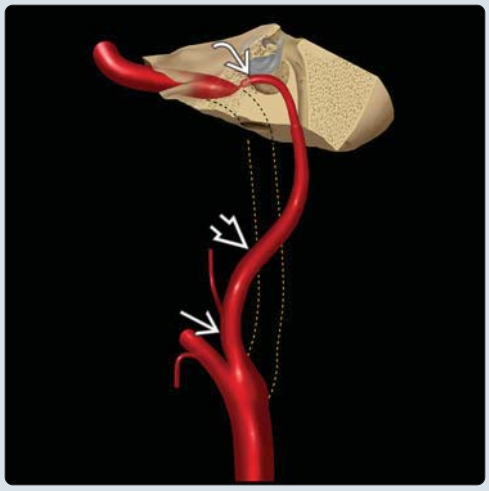

(Left) *Lateral graphic of a normal adult cervical and petrous ICA reveals the inferior tympanic artery ➡ branching off the ascending pharyngeal artery ➡, passing into the T-bone to anastomose with the very small caroticotympanic artery ➡ on the cochlear promontory.* **(Right)** *Lateral graphic depicts failure of the cervical ICA to develop (dotted lines), with the ascending pharyngeal ➡, inferior tympanic ➡, and caroticotympanic ➡ arteries providing an alternative collateral arterial channel resulting in an AbICA.*

https://CafePezeshki.IR

TERMINOLOGY

Abbreviations

- Aberrant internal carotid artery (AbICA)

Synonyms

- Aberrant carotid artery

Definitions

- Congenital vascular anomaly resulting from failure of formation of extracranial ICA with arterial collateral pathway

IMAGING

General Features

- Best diagnostic clue
  - Tubular structure running horizontally through middle ear cavity from posterior to anterior
- Location
  - Enters posterior middle ear through enlarged inferior tympanic canaliculus
    - Posterior and lateral to expected site of petrous carotid canal
  - Courses anteriorly across cochlear promontory to join horizontal petrous ICA through dehiscent carotid plate
  - Most commonly unilateral
- Size
  - Smaller than horizontal petrous ICA
- Morphology
  - Tubular morphology is key observation

CT Findings

- CECT
  - Enhancement equivalent to other arteries
    - **Caution**: Glomus tympanicum paraganglioma also enhances: Use morphology to differentiate tubular AbICA from ovoid paraganglioma
- Bone CT
  - Appearance of AbICA on thin section (< 1 mm) temporal bone CT is diagnostic
  - Axial bone CT
    - AbICA appears as tubular lesion crossing middle ear from posterior to anterior
    - **Enlarged inferior tympanic canaliculus** is important observation
      - Anteromedial to stylomastoid foramen and mastoid segment of facial nerve
    - Smaller AbICA often stenotic at point of reconnection with horizontal petrous ICA
    - Carotid foramen and vertical segment of petrous ICA are absent
  - Coronal bone CT
    - AbICA appears as round, soft tissue lesion on cochlear promontory
      - Single slice looks disturbingly like glomus tympanicum paraganglioma
      - **Caution**: Do not mistake AbICA for glomus tympanicum paraganglioma
      - Tubular nature of AbICA is key observation
    - Inferior tympanic canaliculus is vertical tube posterolateral to normal location of vertical segment of petrous ICA
      - Rises at coronal level of round window niche
  - If **persistent stapedial artery** associated
    - Absent foramen spinosum
    - Enlarged anterior tympanic segment of CN7 canal
- CTA
  - Diagnostic for AbICA
  - Usually not necessary, as CT alone is diagnostic

MR Findings

- Conventional MR does not reliably identify AbICA
- MRA source images and reformatted images show aberrant nature of vessel
  - AbICA enters skull base posterior and lateral, compared to normal contralateral side
  - Frontal reformat: Petrous segment of ICA extends laterally instead of medially
    - In left ear, AbICA looks like 7
    - In right ear, AbICA looks like reverse 7

Angiographic Findings

- Frontal view: Petrous segment of ICA extends laterally instead of medially
- Lateral view: Absent extracranial course of suprabifurcation ICA (C1 segment)
  - Smaller caliber vessels arise from bifurcation posteriorly, looping back to horizontal segment of petrous ICA
    - Stenosis may be present at site of reconnection between AbICA and horizontal petrous ICA
- Conventional angiography no longer necessary to confirm imaging diagnosis
  - CTA or MRA sufficient if uncertainty arises from bone CT images

Imaging Recommendations

- Best imaging tool
  - T-bone CT: Tubular morphology and posterolateral position diagnostic
    - Contrast CT or CTA not necessary
- Protocol advice
  - Bone CT: < 1 mm axial and coronal images
  - If MR is used, MRA is critical component

DIFFERENTIAL DIAGNOSIS

Glomus Tympanicum Paraganglioma

- Otoscopy: Pink/red, pulsatile, retrotympanic mass
- Bone CT: Focal ovoid mass on cochlear promontory
- MR: T1WI C+ enhancing mass

Lateralized Internal Carotid Artery

- Otoscopy: Vague, vascular hue deep behind tympanic membrane
- Bone CT: Dehiscent lateral wall of petrous ICA genu

Petrous Internal Carotid Artery Aneurysm

- Otoscopy: Negative unless large
- Bone CT: Focal, smooth, petrous ICA canal expansion
  - ICA has normal course but focal ovoid, expansile portion
- CTA or MRA is diagnostic of nonthrombosed aneurysm

https://CafePezeshki.IR

Dehiscent Jugular Bulb

- Otoscopy: Gray-blue retrotympanic mass in posteroinferior quadrant
- Bone CT: Focal absence of sigmoid plate
  - "Bud" from superolateral jugular bulb enters middle ear as a "mass"

Cholesterol Granuloma in Middle Ear

- Otoscopy: Blue-black retrotympanic mass
- Bone CT: Appears identical to acquired cholesteatoma
- MR: High signal on T1 and T2 without contrast suggests diagnosis

Congenital Cholesteatoma in Middle Ear

- Otoscopy: White-tan retrotympanic mass
- Bone CT: Multilobular soft tissue middle ear mass medial to ossicles
- MR: Low T1, high T2 signal mass; DWI restricted diffusion

PATHOLOGY

General Features

- Etiology
  - Etiology of AbICA is controversial
  - Best explanation: "Alternative blood flow" theory
    - Persistence of pharyngeal artery system means C1 portion of ICA is absent
    - Mature arterial collateral system compensates for absent C1 and vertical petrous ICA segments
      - Ascending pharyngeal artery → inferior tympanic artery → caroticotympanic artery → posterolateral aspect of horizontal petrous ICA
  - Results of absent extracranial ICA C1 segment
    - Ascending pharyngeal, inferior tympanic, and caroticotympanic arteries enlarge
    - Inferior tympanic canaliculus enlarges to accommodate enlarged inferior tympanic artery
    - Bony margin of posterolateral horizontal petrous ICA canal is penetrated at site of caroticotympanic artery origin
- Associated abnormalities
  - 30% of AbICAs have **persistent stapedial artery**
    - Enlarged anterior tympanic segment of CN7 canal
    - Absent ipsilateral foramen spinosum

Gross Pathologic & Surgical Features

- Pulsatile aberrant artery is found in middle ear cavity

Microscopic Features

- Histologically normal artery

CLINICAL ISSUES

Presentation

- Most common signs/symptoms
  - Most commonly asymptomatic
    - Discovered at time of routine physical exam, during middle ear surgery, or as incidental imaging finding
  - Associated symptoms
    - Pulsatile tinnitus (PT) (pulse-synchronous sound)
      - May be subjective (only patient hears) or objective (patient and clinician hear)
      - Subjective PT: Pulsatile sound may transmit directly through cochlear promontory to basal turn of cochlea
      - Objective PT: When stenosis present at junction of AbICA and normal horizontal petrous ICA
    - Conductive hearing loss
    - Vertigo, otalgia rare
  - Otoscopy: Retrotympanic pink-red mass
    - Inferior aspect of tympanic membrane
    - May mimic paraganglioma

Demographics

- Age
  - Average at presentation: 38 years
- Gender
  - M < F in single study (N = 16)
- Epidemiology
  - Very rare disorder

Natural History & Prognosis

- No long-term sequelae reported with AbICA
- Poor prognosis results only if misdiagnosis → biopsy
  - Pseudoaneurysm may require endovascular repair
- If tinnitus is loud, AbICA can be debilitating

Treatment

- **No treatment** is best treatment
- Greatest risk is misdiagnosis leading to biopsy
- Most patients have minor symptoms that do not require treatment
- Persistent stapedial artery does not need to be treated

DIAGNOSTIC CHECKLIST

Image Interpretation Pearls

- Radiologist must remain firm on imaging diagnosis despite clinical impression of paraganglioma
  - Biopsy or attempted resection of misdiagnosed AbICA can be disastrous
    - Hemorrhage, stroke, or death may result from vessel injury

Reporting Tips

- Report diagnosis; offer no differential diagnosis
- Equivocal report such as "cannot exclude paraganglioma" may lead to surgical intervention

SELECTED REFERENCES

1. Becker C et al: The clinical impact of aberrant internal carotid arteries in children. Int J Pediatr Otorhinolaryngol. 78(7):1123-7, 2014
2. Honkura Y et al: Surgical treatment for the aberrant internal carotid artery in the middle ear with pulsatile tinnitus. Auris Nasus Larynx. 41(2):215-8, 2014
3. Glastonbury CM et al: Lateralized petrous internal carotid artery: imaging features and distinction from the aberrant internal carotid artery. Neuroradiology. 54(9):1007-13, 2012
4. Hatipoglu HG et al: A case of a coexisting aberrant internal carotid artery and persistent stapedial artery: the role of MR angiography in the diagnosis. Ear Nose Throat J. 90(5):E17-20, 2011
5. Sauvaget E et al: Aberrant internal carotid artery in the temporal bone: imaging findings and management. Arch Otolaryngol Head Neck Surg. 132(1):86-91, 2006

https://CafePezeshki.IR

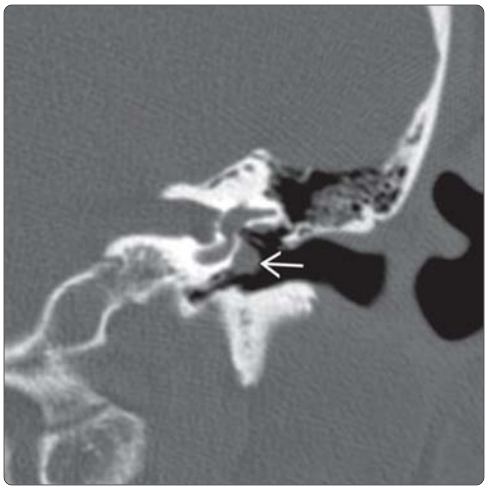

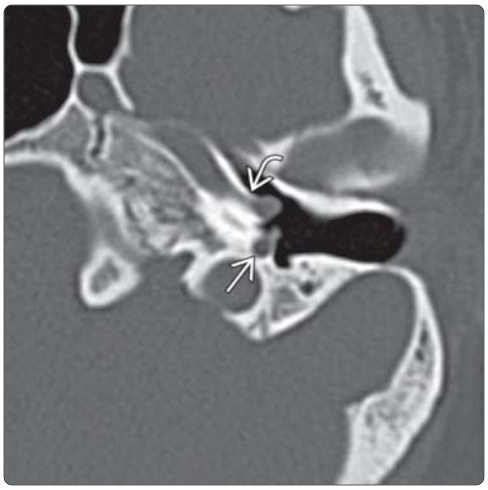

(Left) *Coronal left T-bone CT at the level of the oval window shows the AbICA as a "mass" located on the cochlear promontory resembling a glomus tympanicum paraganglioma. Accidental biopsy of AbICA may have devastating consequences.* **(Right)** *Axial bone CT reveals a smaller caliber aberrant internal carotid artery (AbICA) entering the middle ear cavity through an enlarged inferior tympanic canaliculus, coursing across the middle ear on cochlear promontory, and reentering the horizontal petrous ICA.*

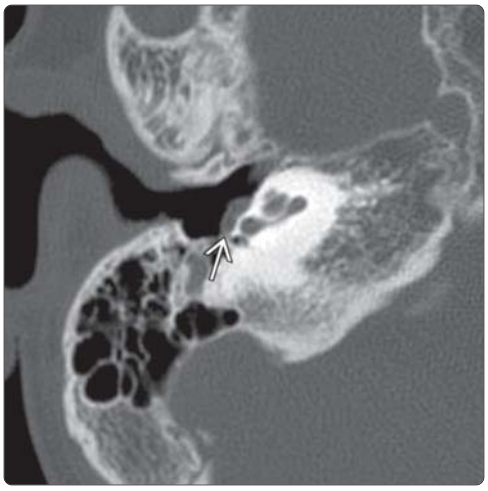

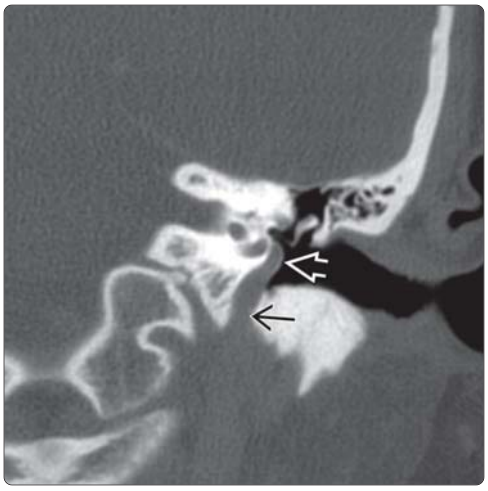

(Left) *Axial bone CT of the right ear shows the AbICA entering the posteromedial middle ear cavity and looping across the low cochlear promontory in this young adult with a vascular retrotympanic mass. Its tubular shape can help prevent a misdiagnosis.* **(Right)** *Coronal bone CT of the left ear shows the posterior aspect of an AbICA with its enlarged inferior tympanic canaliculus and looping course up onto the cochlear promontory. The tubular configuration of the vessel is diagnostic.*

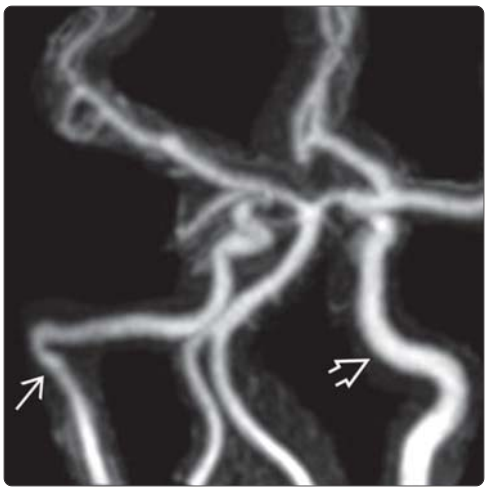

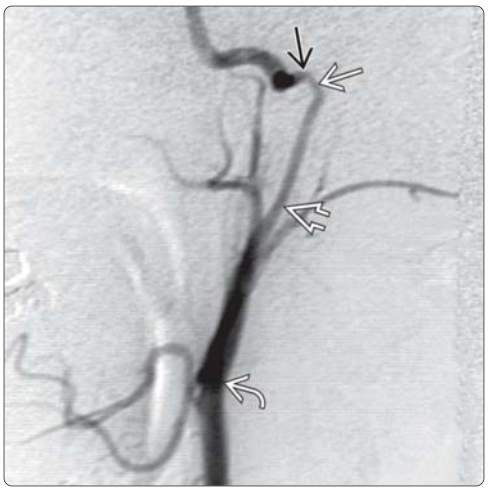

(Left) *Frontal oblique MRA image shows a right AbICA with a characteristic reverse 7 shape. Note the typical configuration of the contralateral normal ICA.* **(Right)** *Lateral internal carotid angiography of an AbICA reveals that the normal extracranial ICA is replaced by an enlarged collateral circuit, which includes the ascending pharyngeal, inferior tympanic, and caroticotympanic arteries. Note the caliber change from the AbICA to the horizontal petrous ICA.*

https://CafePezeshki.IR

KEY FACTS

TERMINOLOGY

- Persistent carotid basilar anastomoses (PCBA)
- Persistence of normally transient embryonic-type arterial supply from carotid to basilar system
- 4 types, named according to anatomic relationship to cranial or spinal nerves

IMAGING

- Prominent unusual vessel between internal carotid artery (ICA) and basilar artery (BA)
  - Levels distributed from tentorial hiatus to below foramen magnum, at specific nerve levels (CN5, CN8, CN12; C1-C3)
- Persistent trigeminal artery (PTA); from intracavernous ICA and BA
  - Most common (0.1-0.2%)
- Persistent otic artery (POA); from petrous ICA to BA through internal auditory canal (IAC)
  - Very rare
- Persistent hypoglossal artery (PHA); from cervical ICA (C1-C2 level) to BA
  - Rare (0.03-0.09%)
- Proatlantal intersegmental artery (PIA); from cervical ICA (C2-C3 level), or rarely external carotid artery (ECA) to vertebral artery between C1 and occiput
  - 3rd most common

TOP DIFFERENTIAL DIAGNOSES

- ICA origin of posterior cerebral artery (PCA)
- Secondary anastomoses

PATHOLOGY

- Named according to parallel CN

CLINICAL ISSUES

- Asymptomatic; no treatment (unless aneurysms)

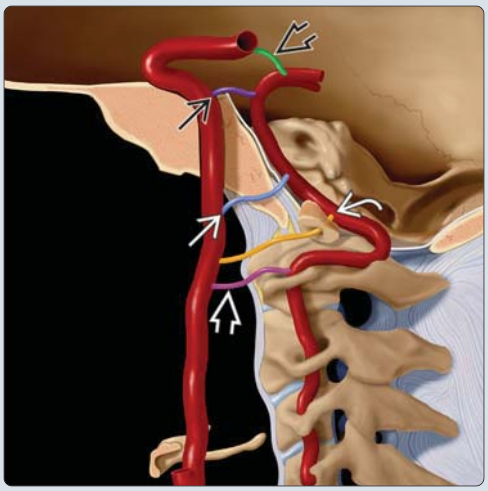

(Left) *Sagittal graphic shows anastomoses between the ICA and VA. A normal PCoA ⇨ connects PCA with the supraclinoid ICA. The PTA ⇨ connects the cavernous ICA and BA. The POA ⇨ connects the petrous ICA to the BA through the IAC. The PHA ⇨ connects the cervical ICA and the VA through the hypoglossal canal. The proatlantal artery ⇨ connects the cervical ICA and the VA at the C1 through C3 level.* **(Right)** *Sagittal MRA shows a PTA ⇨ connecting the proximal ICA siphon ⇨ with the mid-BA ⇨.*

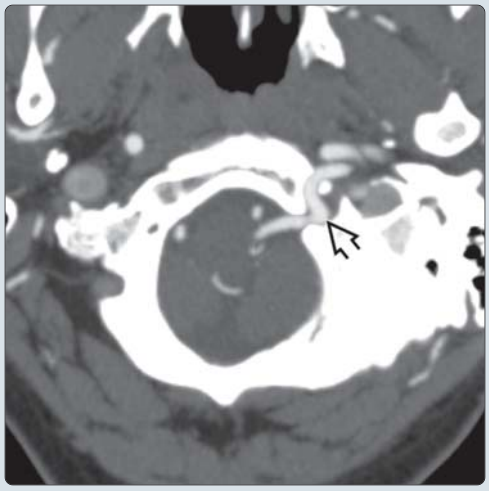

(Left) *Axial CTA shows the classic appearance of a PTA ⇨ connecting the left internal carotid artery ⇨ to the basilar artery ⇨. A PTA is the most common type of persistent carotid basilar anastomoses occurring in 0.1-0.2% of cases. These are typically incidental findings, unless they are associated with other vascular lesions.* **(Right)** *Axial CTA shows a PHA ⇨ extending through the left hypoglossal canal and paralleling the CN12. The PHA connects the cervical ICA to the BA.*

https://CafePezeshki.IR

TERMINOLOGY

Abbreviations

- Persistent carotid basilar anastomoses (PCBA)

Synonyms

- Vestigial carotid-basilar anastomoses

Definitions

- Persistence of normally transient embryonic-type arterial supply from carotid to basilar system

IMAGING

General Features

- Best diagnostic clue
  - Abnormal internal carotid artery (ICA)-basilar artery (BA) connection below level of posterior communicating artery (PCoA)
- Location
  - From sellar to occipitovertebral level
- Morphology
  - Persistent trigeminal artery (PTA), from intracavernous ICA to BA, most common (0.1-0.2%)
    - Saltzman type 1: PTA supplies distal BA, PCoAs usually absent; proximal BA usually hypoplastic
    - Saltzman type 2: PTA fills superior cerebellar arteries, PCAs supplied via patent PCoAs
  - Persistent otic artery (POA), from petrous ICA to BA through internal auditory canal (IAC); rare
    - Vertebral arteries (VAs) absent or hypoplastic
  - Persistent hypoglossal artery (PHA), from cervical ICA (C1-C2 level) to BA; rare (0.03-0.09%)
    - Parallels CN12 in hypoglossal canal
  - Proatlantal intersegmental artery (PIA); from cervical ICA (C2-C3 level), or rarely external carotid artery (ECA) to VA between C1 and occiput (3rd most common)
    - Most caudal of PCBAs; VAs absent or hypoplastic

CT Findings

- CECT
  - Large caliber vessel between BA and ICA
- CTA
  - Delineates presence and course of vascular anomaly, associated abnormalities (e.g., saccular aneurysm)

MR Findings

- T2WI
  - Prominent unusual vessel between ICA and BA
    - Levels distributed from tentorial hiatus to below foramen magnum, presumably at specific nerve levels (CN5, 8, 12; C1-C3)
- MRA
  - Depicts unusual vessel, its origin, course, and vertebrobasilar connection
  - Associated arterial anomalies (e.g., aneurysm)

Angiographic Findings

- Performed for other reasons (e.g., subarachnoid hemorrhage); shows vestigial artery and arterial flow

Imaging Recommendations

- Best imaging tool: MR and MRA or CTA

DIFFERENTIAL DIAGNOSIS

ICA Origin of Posterior Cerebral Artery (PCA)

- a.k.a. "fetal" origin of PCA (10-30% of cases)
- Common: Above sella, PCoA prominent, P1 segment of PCA hypoplastic/absent

Secondary Anastomoses

- To feed AV fistula
- To compensate for arterial occlusion/agenesis

PATHOLOGY

General Features

- Etiology
  - Failure of regression of primitive or embryonic arterial connections
- Associated abnormalities
  - 25% prevalence of other vascular anomalies
    - Controversial: Aneurysm (15%)
    - Rare: Carotid-cavernous fistula, arteriovenous malformation, arterial fenestration, moyamoya, neurofibromatosis type 1
    - Very rare: Absent CC/ICA, proximal subclavian artery, BA; aorta coarctation
- Embryology
  - Early transient segmental connections from ICA supply BA before intersegmental VAs develop
  - Named by cranial/spinal nerve they parallel
- Anatomy
  - Anatomic change in arterial supply associated with reorganized arterial pattern (hypoplastic/missing arterial segments)

CLINICAL ISSUES

Presentation

- Most common signs/symptoms
  - Incidental finding at imaging or subarachnoid hemorrhage (SAH)
    - Rarely trigeminal neuralgia or pituitary dysfunction

Natural History & Prognosis

- Asymptomatic; no treatment (unless aneurysms)

SELECTED REFERENCES

1. Ladner TR et al: Resolution of trigeminal neuralgia by coil embolization of a persistent primitive trigeminal artery aneurysm. J Neurointerv Surg. 6(3):e22, 2014
2. Teraa M et al: Preserved distal flow in a proximally occluded internal carotid artery due to a persistent proatlantal artery. J Vasc Surg. 59(2):527, 2014
3. Bai M et al: Persistent trigeminal artery/persistent trigeminal artery variant and coexisting variants of the head and neck vessels diagnosed using 3 T MRA. Clin Radiol. 68(11):e578-85, 2013
4. Meckel S et al: The persistent trigeminal artery: development, imaging anatomy, variants, and associated vascular pathologies. Neuroradiology. 55(1):5-16, 2013
5. Vasović L et al: Trigeminal artery: a review of normal and pathological features. Childs Nerv Syst. 28(1):33-46, 2012
6. Vasović L et al: Proatlantal intersegmental artery: a review of normal and pathological features. Childs Nerv Syst. 25(4):411-21, 2009

https://CafePezeshki.IR

KEY FACTS

TERMINOLOGY

- Abnormality in hemoglobin (Hgb) → change in shape ("sickling") → ↑ "stickiness" of erythrocytes (RBCs) → capillary occlusions, ischemia, infarctions, premature RBC destruction (hemolytic anemia)

IMAGING

- Best diagnostic clue
  - Cerebral infarct(s) in African American child
  - Moyamoya (MM, secondary)

TOP DIFFERENTIAL DIAGNOSES

- Vasculitis
- Other causes of MM (inherited and secondary)

PATHOLOGY

- Point mutation hemoglobin β gene, Chr 11p15.5: Glutamate → valine substitution
- Sickled RBCs adhere to endothelium → fragmentation of internal elastic lamina, degeneration of muscularis → large vessel vasculopathy ± aneurysm formation

CLINICAL ISSUES

- Stroke
  - 17-26% of all patients with sickle cell disease (SCD)
  - 18x ↑ risk if transcranial Doppler velocities ICA/MCA > 200 cm/s
  - Peak incidence 1st decade of life
- 20% of children have white matter (WM) infarcts on MR without overt neurologic deficits = "silent infarcts"
  - 14x ↑ risk of stroke
- Regular blood transfusions keep Hgb S < 30%
  - ↓ stroke by up to 75%

DIAGNOSTIC CHECKLIST

- Always consider SCD in African American child with cerebral infarction

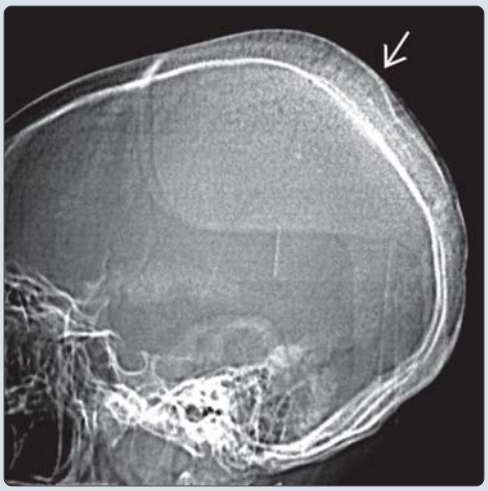

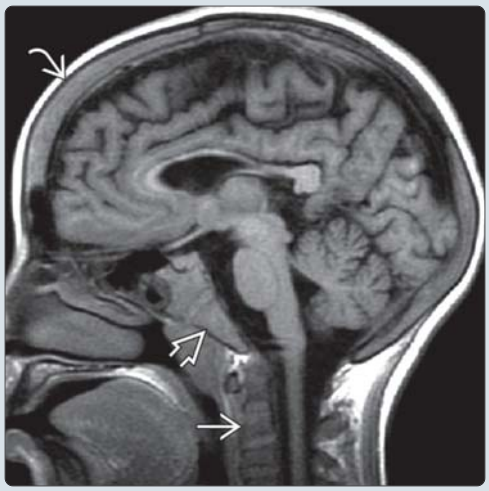

(Left) *Lateral scout image from a CT examination shows marked diploic thickening due to red marrow hyperplasia, causing a hair on end appearance.* **(Right)** *Sagittal T1WI MR shows calvarial thickening and ↓ marrow signal intensity secondary to red marrow hyperplasia caused by chronic anemia. Loss of normal T1-hyperintense fatty marrow is also seen in the clivus and cervical spine. Iron deposition from repeat transfusions can also contribute to marrow signal abnormality.*

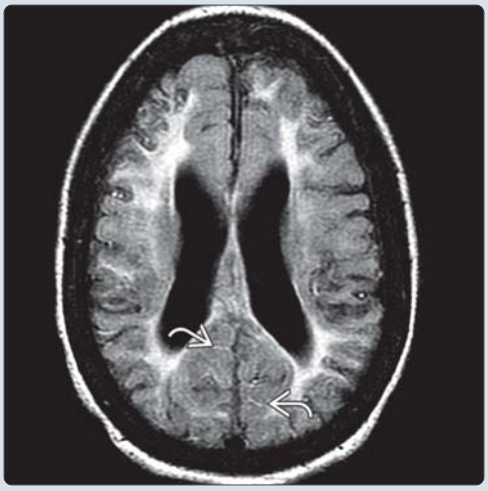

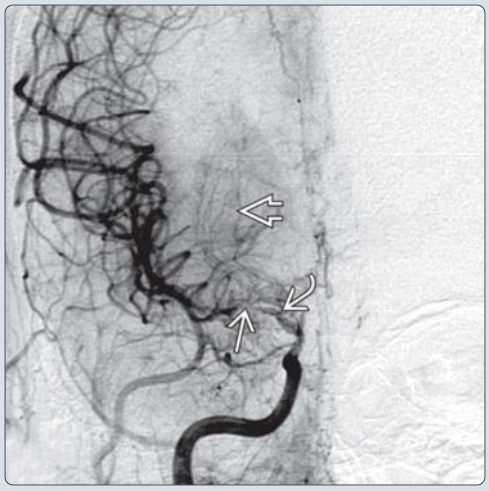

(Left) *Axial FLAIR MR shows considerable brain atrophy and signal hyperintensity due to chronic ischemic brain injury. Note the presence of "ivy" sign, branching abnormal hyperintensity in the cerebral sulci. The "ivy" sign is thought to occur secondary to slow collateral flow in engorged pial vessels.* **(Right)** *DSA AP view from a right ICA injection shows secondary moyamoya with enlarged lenticulostriate arteries resulting in a "puff of smoke" in this SCD patient with severe MCA and distal ICA stenosis.*

https://CafePezeshki.IR

TERMINOLOGY

Abbreviations

- Sickle cell disease (SCD)

Definitions

- Abnormality in hemoglobin (Hgb) → change in shape ("sickling") → increased "stickiness" of erythrocytes (RBCs) → capillary occlusions, ischemia, infarctions, premature RBC destruction (hemolytic anemia)

IMAGING

General Features

- Best diagnostic clue
  - Cerebral infarct(s) in African American child
  - Secondary moyamoya (MM)
    - Narrowing of distal internal carotid arteries (ICA) or proximal anterior cerebral arteries (ACA), middle cerebral arteries (MCA)
    - Lenticulostriate collaterals in basal ganglia (BG)
- Location: ICAs, deep white matter (WM), cortex, bone marrow
- Cognitive impairment does not correlate with imaging findings
- Decreased gray matter volume in SCD children

Radiographic Findings

- Radiography
  - Thick skull with expanded diploic space
  - Opacified paranasal sinuses

CT Findings

- NECT
  - Hypodense gray or WM infarct(s) → diffuse atrophy
  - Rare: Subarachnoid (SAH) or intraventricular hemorrhage (IVH) from SCD-related aneurysm or MM
- CECT: Punctate enhancement BG from MM collaterals
- CTA: Stenosis of distal ICA, proximal circle of Willis (COW)

MR Findings

- T1WI
  - Hemorrhagic infarcts may be seen
  - Punctate flow voids in BG correspond to MM collaterals
  - Decreased signal, expanded marrow (↑ red marrow)
- T2WI
  - Cortical, deep WM infarcts
    - Often in ACA/MCA watershed distribution
    - Associated with reduced subcortical volumes
- FLAIR
  - Multifocal hyperintensities ± "ivy" sign of MM
- DWI: Diffusion restriction in acute infarcts
- PWI
  - ↑ cerebral blood flow (CBF) early: Adaptive response to anemia
  - ↓ CBF, ↑ mean transit time (MTT), ↑ time to peak (TTP) with arterial sludging, progressive COW narrowing
  - Arterial spin labeling (ASL) may be useful; assess CBF without use of contrast material
- T1WI C+: Vascular stasis and leptomeningeal collaterals in MCA territory with proximal MCA stenosis
- MRA
  - Enlarged, tortuous arteries early
    - Theory: Adaptive response to anemia and ↑ cerebral perfusion
  - Frequent eventual development of MM
  - Aneurysms in atypical locations
- MRS: ↑ lactate, ↓ NAA, ↓ Cho, ↓ Cr in areas of infarction (lactate seen only in acute infarctions)

Ultrasonographic Findings

- Transcranial Doppler (TCD): Hyperdynamic flow distal ICA/MCA secondary to proximal stenosis
  - Time-averaged mean velocities > 200 cm/s → high risk of ischemic stroke
  - Velocities between 170-200 cm/s, conditional

Angiographic Findings

- MM: Stenosis of distal ICA, proximal COW with BG and ECA → ICA collaterals
  - Association between MM with persistent primitive carotid-basilar arterial communications
- Fusiform aneurysms
- Periprocedural risk of stroke higher than other populations: Hydrate, transfuse before catheter study

Nuclear Medicine Findings

- PET, SPECT: Focal areas of ↓ brain perfusion described

Imaging Recommendations

- Best imaging tool
  - MR/MRA ± DSA
- Protocol advice
  - DWI differentiates acute infarcts from chronic
  - Turbulent dephasing due to anemia, rapid flow can mimic stenosis on "bright blood" MRA: Use lowest possible TE for "bright blood" MRA or "black blood" MRA if stenosis suspected

DIFFERENTIAL DIAGNOSIS

Vasculitis

- Idiopathic, infectious, autoimmune, substance abuse
- Classic imaging findings: Cortical and deep WM infarcts and parenchymal hemorrhage

Moyamoya (MM)

- Primary MM
  - Idiopathic, inherited
- Other causes of secondary MM
  - NF1, Down syndrome, radiation therapy, connective tissue disease, prothrombotic states

Thick Skull With Expanded Diploe

- Other chronic anemias (thalassemia)

PATHOLOGY

General Features

- Etiology
  - Abnormal hemoglobin (Hgb S) becomes "stiff" when deoxygenated → RBCs become sickle-shaped
  - Sickled RBCs lose pliability to traverse capillaries → vascular occlusion ("crisis"), cell destruction (hemolysis)

https://CafePezeshki.IR

- Sickled RBCs adhere to endothelium → fragments internal elastic lamina, degenerates muscularis → large vessel vasculopathy ± aneurysm formation
- Genetics
  - Point mutation of hemoglobin β gene, Chr 11p15.5: Glutamate → valine substitution
  - SCD: Autosomal recessive, both β-globin affected
  - Sickle cell trait: 1 β-globin affected → mild disease
    - Carrier
    - ↑ resistance to malaria (hence prevalence)
- Associated abnormalities
  - Anemia, reticulocytosis, granulocytosis
  - Susceptibility to pneumococcal infection (due to malfunctioning spleen)
  - Occasionally causes pseudotumor cerebri

Gross Pathologic & Surgical Features

- Bone, brain, renal, and splenic infarcts; hepatomegaly

Microscopic Features

- Severe anemia with sickled cells on smear
- Vascular occlusions due to masses of sickled RBCs

CLINICAL ISSUES

Presentation

- Most common signs/symptoms
  - Focal neurologic deficit
- Other signs/symptoms
  - Children: Learning difficulties, headache, psychiatric symptoms
- Clinical profile
  - African American child with stroke
- Stroke
  - 17-26% of all patients with SCD
  - 11% by age 20, 24% by age 45
  - 75% ischemic, 25% hemorrhagic
  - 20% of children have WM infarcts on MR but no overt neurologic deficit = "silent infarcts"
    - TCD usually normal
    - Associated with mild cognitive impairment
    - 14x ↑ risk of stroke consistent with patients with normal MR
  - 18x ↑ risk of stroke if TCD velocity of ICA or MCA > 200 cm/s
- Bone infarcts, avascular necrosis during crisis
- Osteomyelitis, especially *Salmonella*
- Gross hematuria from renal papillary necrosis and ulceration
- Splenic infarction from exposure to high altitude (e.g., flying)
- Infections common, especially *Pneumococcus* after splenic infarction

Demographics

- Age
  - Children = adults
  - Stroke risk highest from 2-5 years of age
- Gender: No predilection
- Ethnicity: Found primarily in African Americans and their decendents
- Epidemiology
  - Birth prevalence in African Americans: 1/375
  - Birth prevalence of sickle cell trait: 1/12
  - Primary cause of stroke in African American children
  - Incidence of cerebral lesions (MR) in patients with sickle cell trait: 10-19%

Natural History & Prognosis

- Unrelenting, severe hemolytic anemia beginning at few months of age after Hgb S replaces Hgb F (fetal)
- Cognitive dysfunction occurs even in absence of cerebral infarctions
- Repeated ischemic events → strokes with worsening motor and intellectual deficits
- Patients usually live to adulthood albeit with complications
- Prognosis poor for SCD without transfusions

Treatment

- Screening TCD
  - Detection ↑ velocity (> 200 cm/s)prompts brain MR and treatment with regular blood transfusions
  - Regular blood transfusions keep Hgb S < 30%
    - ↓ incidence of stroke by up to 75%
    - ↓ intimal hyperplasia COW vessels
- Hydroxyurea: ↓ incidence of painful crises and acute chest syndrome; may improve TCD velocities
  - Induces Hgb F, which ↓ vaso-occlusion and hemolysis
- Penicillin prophylaxis; pneumococcal vaccine
- Bone marrow transplantation is only curative therapy
  - Available only to few who have HLA-matched donor
- On horizon: Stem cell-based therapies

DIAGNOSTIC CHECKLIST

Image Interpretation Pearls

- Always consider SCD in African American child with cerebral infarction

SELECTED REFERENCES

1. Andreotti C et al: The Association of Cytokine Levels With Cognitive Function in Children With Sickle Cell Disease and Normal MRI Studies of the Brain. J Child Neurol. ePub, 2014
2. Chen R et al: A Prospective Longitudinal Brain Morphometry Study of Children with Sickle Cell Disease. AJNR Am J Neuroradiol. ePub, 2014
3. Helton KJ et al: Magnetic resonance imaging/angiography and transcranial Doppler velocities in sickle cell anemia: results from the SWiTCH trial. Blood. 124(6):891-8, 2014
4. Mackin RS et al: Neuroimaging abnormalities in adults with sickle cell anemia: associations with cognition. Neurology. 82(10):835-41, 2014
5. Thust SC et al: Neuroimaging findings in sickle cell disease. Br J Radiol. 87(1040):20130699, 2014
6. Arkuszewski M et al: Sickle cell anemia: reference values of cerebral blood flow determined by continuous arterial spin labeling MRI. Neuroradiol J. 26(2):191-200, 2013
7. Behpour AM et al: Cerebral blood flow abnormalities in children with sickle cell disease: a systematic review. Pediatr Neurol. 48(3):188-99, 2013
8. DeBaun MR et al: Silent cerebral infarcts: a review on a prevalent and progressive cause of neurologic injury in sickle cell anemia. Blood. 119(20):4587-96, 2012
9. Al-Kandari FA et al: Regional cerebral blood flow in patients with sickle cell disease: study with single photon emission computed tomography. Ann Nucl Med. 21(8):439-45, 2007
10. Oguz KK et al: Sickle cell disease: continuous arterial spin-labeling perfusion MR imaging in children. Radiology. 227(2):567-74, 2003

https://CafePezeshki.IR

(Left) *Axial FLAIR MR shows a characteristic appearance of the brain in sickle cell disease (SCD) with bilateral deep white matter and cortical (on right) infarcts with foci of cystic encephalomalacia. The infarcts are linearly arranged in the AP plane, a pattern consistent with watershed infarction.* **(Right)** *Axial T2WI MR in the same patient shows asymmetry of the internal carotid arteries (ICA) with ↓ caliber on the right, the side with greater brain injury. Vessel narrowing is a result of sickle cell vasculopathy.*

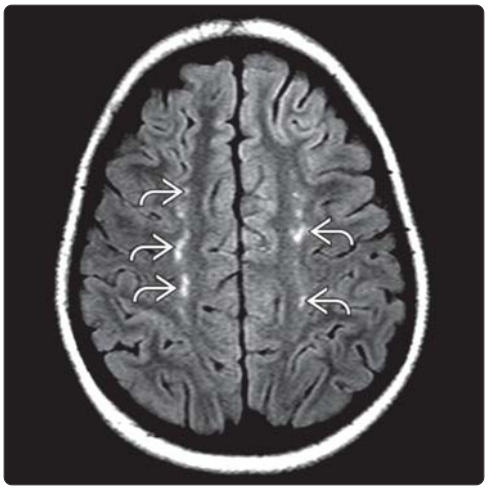

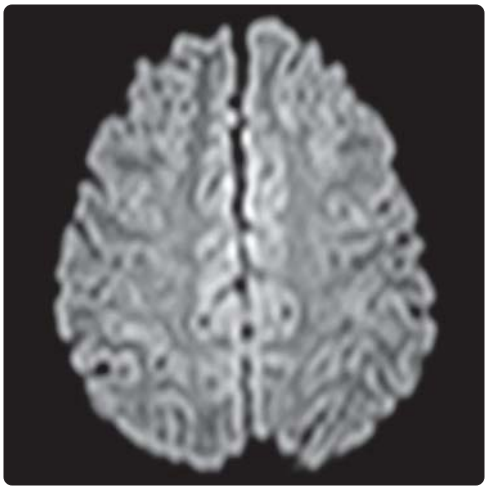

(Left) *Axial FLAIR MR in an asymptomatic teenager with SCD shows multiple, small foci of increased signal in the deep white matter watershed.* **(Right)** *Axial DWI MR in the same patient shows no reduced diffusion to suggest acute infarction; the infarcts are "silent." There is MR evidence of infarct without overt neurologic abnormality and usually normal ICA/MCA velocities on transcranial Doppler. Such patients often have mild cognitive impairment and are at increased risk of stroke.*

(Left) *MRA collapsed view does not demonstrate narrowing of the distal ICAs, proximal ACAs, or proximal MCAs. The vessels are mildly enlarged and tortuous, thought to occur as a pathophysiologic response to anemia and ↑ cerebral perfusion. This progressive vasculopathy eventually results in large and small vessel injury.* **(Right)** *MRA in the same patient shows a proximal basilar artery aneurysm. Patients with SCD are at ↑ risk of aneurysm, often in atypical locations.*

https://CafePezeshki.IR

KEY FACTS

TERMINOLOGY

- Progressive narrowing of distal ICA/proximal circle of Willis (COW) vessels with secondary collateralization
  - Collateral vessels → cloud-like "puff of smoke" (moyamoya) at angiography
- Moyamoya disease (MMD) = primary (idiopathic) moyamoya
  - Marked East-West gradient (more common in Japan, Korea)
- Moyamoya pattern of collaterals = secondary to many etiologies

IMAGING

- Best diagnostic clue: Attenuated COW with multiple tiny basal ganglia "flow voids" on MR
- Best imaging tool: T1MRC+/MRA; DSA for delineating vascular details

PATHOLOGY

- Moyamoya disease
  - RNF213 polymorphism in 95% of familial East Asian population, 79% of sporadic
    - Correlated with early onset, severe form of MMD
- Secondary moyamoya (many causes)
  - Syndromic (e.g., NF1), inflammatory states, prothrombotic states, premature aging, congenital mesenchymal defects, suprasellar irradiation in childhood

CLINICAL ISSUES

- Bimodal age peaks (5-10 years and 2nd peak during 4th decade)
- Most frequent cause of stroke in Asian children
- Presentation
  - Children: Recurrent TIAs; hemorrhage rare
  - Adults: TIAs, infarcts, hemorrhage (20%), migraines

(Left) *Coronal graphic shows severe tapering of both distal internal carotid arteries* ⇨ *and strikingly enlarged lenticulostriate arteries* ⇨ *coursing through basal ganglia. This is the puff of smoke (moyamoya) pattern.* **(Right)** *Coronal T2WI in a 3-year-old female with MMD shows severely attenuated supraclinoid internal carotid arteries* ⇨*. An acute cortical infarct is present in the right MCA distribution* ⇨*.*

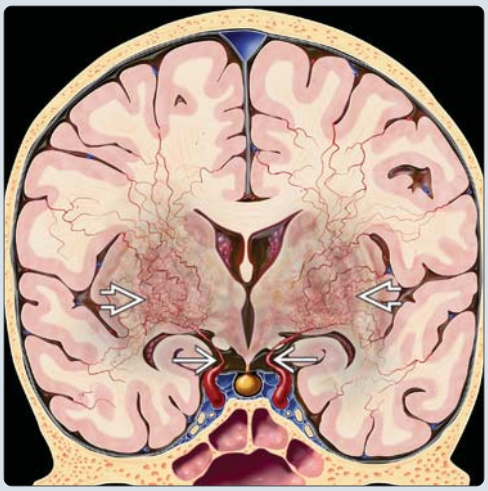

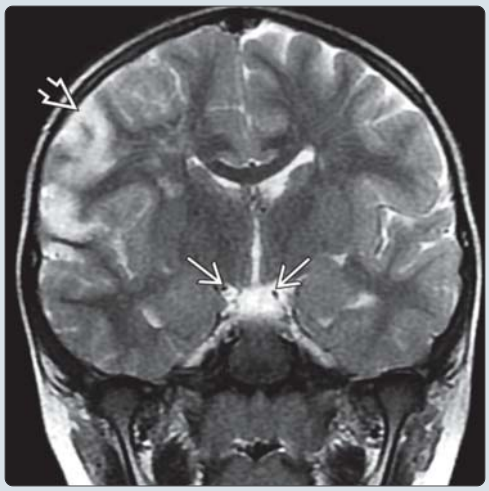

(Left) *Axial T2WI in the same patient shows tiny, almost inapparent "flow voids" of the right MCA branches in the sylvian fissure* ⇨*. The acute cortical infarct has produced marked gyral edema, swelling* ⇨*. Note the tiny "squiggly" flow voids* ⇨ *from the basal collateral vessels.* **(Right)** *Coronal MIP of the time-of-flight MRA in the same patient shows the severely attenuated supraclinoid internal carotid arteries* ⇨ *and the puff of smoke appearance of the basal collateral vessels* ⇨*.*

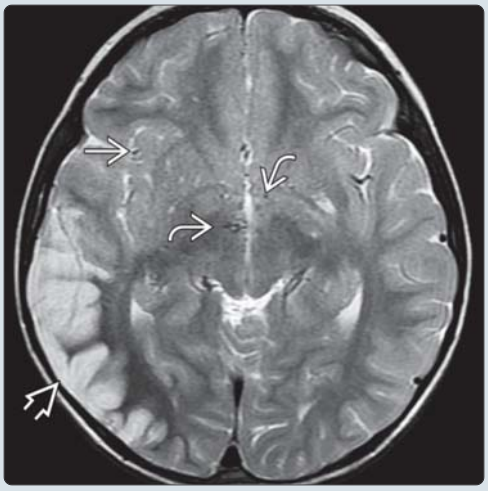

https://CafePezeshki.IR

TERMINOLOGY

Abbreviations

- Moyamoya disease (MMD)

Synonyms

- Idiopathic progressive arteriopathy of childhood, spontaneous occlusion of circle of Willis (COW)

Definitions

- Progressive bilateral stenosis or occlusion of terminal internal carotid artery (ICA)/proximal COW with abnormal vascular network at base of brain
  - Compensatory development of collateral vascular network = "puff of smoke"
- Primary (idiopathic) moyamoya = moyamoya disease
  - More common Japan, Korea
- Secondary (acquired) moyamoya
  - Cranial radiation
  - Atherosclerosis
  - Neurofibromatosis

IMAGING

General Features

- Best diagnostic clue: Attenuated COW with multiple tiny basal ganglia "flow voids" on MR
- Location: Supraclinoid ICA/COW; anterior > > posterior circulation
- Size: Large vessel occlusion
- Morphology: "Puff of smoke" (moyamoya in Japanese)
  - Cloud-like lenticulostriate and thalamostriate collaterals on angiography

CT Findings

- NECT
  - Children: 50-60% show anterior > posterior atrophy
  - Adults can present with intracranial hemorrhage
- CECT: Enhancing dots (large lenticulostriates) in BG and abnormal net-like vessels at base of brain
- CTA: Abnormal COW and net-like collaterals
- Xe-133 CT: ↓ cerebral reserve with acetazolamide challenge

MR Findings

- T1WI: Multiple dot-like flow voids in BG
- T2WI
  - ↑ signal in small vessel cortical and white matter infarcts
  - Collateral vessels = net-like cisternal filling defects
- FLAIR
  - Bright sulci = leptomeningeal "ivy" sign
    - Slow-flowing engorged pial vessels, thickened arachnoid membranes
    - Correlates with decreased cerebral vascular reserve
- T2* GRE
  - Hemosiderin if prior hemorrhage
  - Asymptomatic microbleeds occasionally seen in adults
- DWI: Very useful for "acute on chronic" disease
- T1WI C+
  - Lenticulostriate collaterals → enhancing "dots" in BG and net-like thin vessels in cisterns
  - Leptomeningeal enhancement (contrast-enhanced "ivy" sign) ↓ after effective bypass surgery
- MRA: Narrowed distal ICA and proximal COW vessels, ± synangiosis
- MRV: Some vasculopathies may also involve veins
- MRS: Lactate in acutely infarcted tissue
  - NAA/Cr and Cho/Cr ratios frontal white matter improve/increase after revascularization
- PWI: ↓ perfusion in deep hemispheric white matter, relative ↑ perfusion in posterior circulation

Ultrasonographic Findings

- Grayscale: Reduction of ICA lumen size
- Pulsed Doppler
  - Doppler spectral waveforms in ICA show no flow (occluded) or high resistance (stenotic) flow pattern
  - ↑ end-diastolic flow velocity, ↓ vascular resistance in external CA (ECA) collaterals
- Color Doppler: Aliasing suggests stenoses
- Power Doppler: Contrast injection improves visualization of slow-flow stenotic vessels and collaterals

Angiographic Findings

- Conventional
  - Predominantly (not exclusively) anterior circulation
    - Narrow proximal COW and ICA (earliest)
    - Lenticulostriate and thalamoperforator collaterals (intermediate)
    - Transdural and transosseous EC-IC collaterals (late)
  - Dilatation and branch extension of anterior choroidal artery predicts adult hemorrhagic events

Nuclear Medicine Findings

- PET: ↓ hemodynamic reserve capacity
- SPECT I-123-iomazenil: Neuronal density preserved if asymptomatic, ↓ if symptomatic

Imaging Recommendations

- Best imaging tool: MR C+/MRA
- DSA for mapping collaterals, grading
- Protocol advice
  - Contrast improves detection: Synangiosis, collaterals
  - Catheter angiography defines anatomy of occlusions prior to bypass
- Diagnostic criteria: MR/MRA or catheter angiography
  - Stenosis/occlusion of terminal ICA or proximal ACA and MCA
  - Abnormal vascular network/flow voids in BG
  - Bilateral; unilateral findings presumptive

DIFFERENTIAL DIAGNOSIS

"Ivy" Sign

- Leptomeningeal metastases, subarachnoid hemorrhage, meningitis, increased inspired oxygen

Punctate Foci in Basal Ganglia

- Cribriform lacunar state: No enhancement

Severely Attenuated Circle of Willis

- Subarachnoid hemorrhage, meningitis, tumor encasement

https://CafePezeshki.IR

PATHOLOGY

General Features

- Etiology
  - Moyamoya disease
    - RNF213 polymorphism in 95% of familial East Asian population, 79% of sporadic
      - Correlated with early onset, severe form of MMD
  - Secondary moyamoya
    - Down syndrome, tuberous sclerosis, sickle cell disease, connective tissue disease, progeria, NF1
      - NF1 with suprasellar tumor and radiation is disastrous
    - Morning glory syndrome; syndromes with aneurysms, cardiac and ocular defects
    - Inflammatory: CNS angiitis (of childhood), basal meningitis, atherosclerosis, H&N infections
    - Vasculopathies and prothrombotic states: XRT, Kawasaki, anticardiolipin antibody, factor V Leiden, polyarteritis nodosa, Behçet, SLE
- Epidemiology: Moyamoya disease
  - Incidence in Japan: 1:100,000
  - Incidence in North America, Europe: 0.1:100,000
  - 10-15% familial

Staging, Grading, & Classification

- Staging criteria (after Suzuki)
  - Stage 1: Narrowing of ICA bifurcation
  - Stage 2: ACA, MCA, PCA dilated
  - Stage 3: Maximal basal collaterals; small ACA/MCA
  - Stage 4: Fewer collaterals (vessels); small PCA
  - Stage 5: Further ↓ collaterals; absent ACA/MCA/PCA
  - Stage 6: Extensive ECA-pial collaterals

Gross Pathologic & Surgical Features

- Increased perforating (early) and ECA-ICA (late) collaterals in atrophic brain
- Hemorrhage (subarachnoid, intraventricular > parenchymal) adults
- Increased saccular aneurysms (especially basilar in adults)

Microscopic Features

- Intimal hyperplasia, medial layer thinness
- Excessive infolding, "waving" of internal elastic lamina
- Periventricular pseudoaneurysms (cause of hemorrhage)

CLINICAL ISSUES

Presentation

- Most common signs/symptoms
  - Children: Transient ischemic attacks (TIAs), alternating hemiplegia (exacerbated by crying), headache
  - Adults: TIAs, cerebral infarct, or hemorrhage
    - Hemorrhagic presentation more common in Asian adults
- Other signs/symptoms
  - Children: Developmental delay, poor feeding, chorea
- Clinical profile
  - Children more likely to have TIAs and to progress; adults more likely to infarct (but slower progression)
  - Children more likely to have ipsilateral anterior plus posterior circulation involvement

Demographics

- Age
  - Bimodal age peaks (5-10 years and 2nd peak during 4th decade)
- Gender
  - M:F = 1:1.8; in familial cases, M:F = 1:5
- Most frequent cause of stroke in Asian children

Natural History & Prognosis

- Progressive narrowing, collateralization, and ischemia
- Prognosis depends on etiology, ability to form collaterals, age/stage at diagnosis
- Pediatric cases usually advance to stage 5 within 10 years of onset
  - Infantile moyamoya progresses faster
  - Pediatric cases present with stroke
- Hemorrhagic moyamoya more common in older patients with large collateral vessels
  - Has poorer outcome

Treatment

- Moyamoya disease
  - Indirect bypass: Encephalo-duro-arterio-synangiosis (EDAS) more effective in children
    - 5-year risk of ipsilateral stroke post EDAS = 15%
  - Direct bypass: Superficial temporal artery-middle cerebral artery (STA-MCA) more common in adults
- Anticoagulation; correct/control prothrombotic states and inflammatory etiologies
- Hypertransfusion for sickle cell-related moyamoya
- Perivascular sympathectomy or superior cervical ganglionectomy (adults)

DIAGNOSTIC CHECKLIST

Consider

- Seek secondary causes of moyamoya

Image Interpretation Pearls

- Enhanced asymmetric atrophy found on childhood CT, look for abnormal vascular pattern
- Adult moyamoya can present with IC hemorrhage

Reporting Tips

- Successful revascularization = ↓ basal collaterals, ↑ flow in MCA branches, ↑ caliber of STA (direct bypass)

SELECTED REFERENCES

1. Acker G et al: Distinct clinical and radiographic characteristics of moyamoya disease amongst European Caucasians. Eur J Neurol. ePub, 2015
2. Fujimura M et al: Diagnosis of moyamoya disease: international standard and regional differences. Neurol Med Chir (Tokyo). 55(3):189-93, 2015
3. Guey S et al: Moyamoya disease and syndromes: from genetics to clinical management. Appl Clin Genet. 8:49-68, 2015
4. Kim T et al: Morphology and related hemodynamics of the internal carotid arteries of moyamoya patients. Acta Neurochir (Wien). ePub, 2015
5. Derdeyn CP: Direct bypass reduces the risk of recurrent hemorrhage in moyamoya syndrome, but effect on functional outcome is less certain. Stroke. 45(5):1245-6, 2014
6. Strother MK et al: Cerebrovascular collaterals correlate with disease severity in adult North American patients with moyamoya disease. AJNR Am J Neuroradiol. Epub ahead of print, 2014
7. Wang C et al: Delayed cerebral vasculopathy following cranial radiation therapy for pediatric tumors. Pediatr Neurol. 50(6):549-56, 2014

https://CafePezeshki.IR

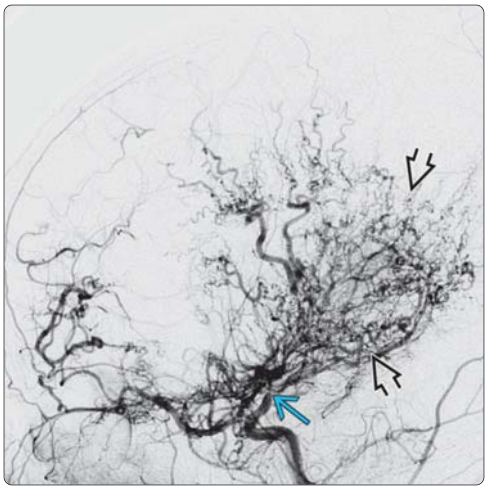

(Left) *Axial MIP of time-of-flight MRA shows normal petrous, cavernous ICAs. There are almost no visible MCA branches of the right supraclinoid ICA, which is severely narrowed. Only a few distal vessels of the left MCA are seen, and there is a "flow gap" between the left supraclinoid ICA and proximal MCA.* **(Right)** *Lateral DSA of the right ICA injection in the same patient shows abrupt termination of its supraclinoid segment. The innumerable tiny, tortuous collateral vessels are the "puff of smoke" (moyamoya).*

(Left) *AP view of the left vertebral injection in the same patient shows it supplies additional tiny, tortuous collaterals at the base of the brain.* **(Right)** *Lateral DSA in the same patient shows the collaterals (moyamoya vessels) are supplied primarily by thalamoperforating and medial choroidal branches.*

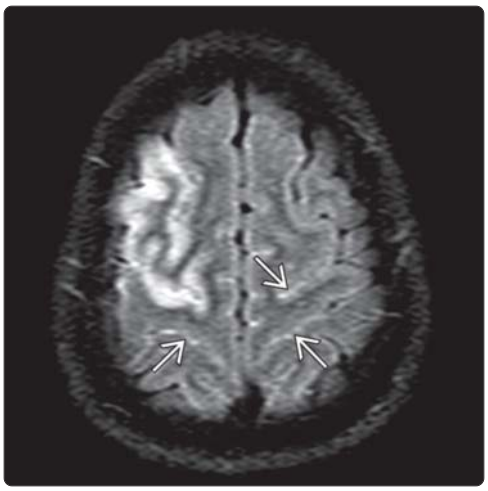

(Left) *Axial FLAIR MR in a 12 year old with sudden left hemiplegia shows an acute right MCA territory infarct. Hyperintense signal in the cerebral sulci represents the "ivy" sign, caused by slow flow in engorged pial collaterals.* **(Right)** *Anteroposterior DSA of right ICA injection in the same patient shows severe focal narrowing of proximal MCA and occluded ACA. Lenticulostriates and thalamoperforator arteries are enlarged. Collateral flow from the posterior choroidal artery is also present.*

https://CafePezeshki.IR

KEY FACTS

TERMINOLOGY

- Primary arteritis of CNS (PACNS)
  - No evidence of secondary (systemic) vasculitis
  - May involve intracranial arteries of any size
- 2 features essential for histopathologic diagnosis
  - Inflammation and necrosis of blood vessel wall

IMAGING

- CT
  - Look for secondary signs of vasculitis (ischemia, infarction)
  - Hypodensities on CT
  - Especially basal ganglia, subcortical white matter
- MR (high resolution)
  - Multifocal punctate, linear hyperintensities on T2/FLAIR
  - Vessel wall imaging with thin-section, high-resolution (3T) T1 C+
    - Circumferential, smooth, long segment
  - ± patchy parenchymal enhancement, restricted diffusion
  - DWI variable (may restrict)
- DSA
  - Once considered imaging gold standard
  - "Beaded" arteries (irregular stenoses, dilatations) on DSA
    - Peripheral branches > COW
  - Less common: Long-segment stenoses, pseudoaneurysms, occlusions

PATHOLOGY

- Brain biopsy may be required to confirm diagnosis
  - 75-80% sensitive
  - Negative biopsy does not exclude primary arteritis of CNS

CLINICAL ISSUES

- Wide age range (mean: ~ 42 years)

DIAGNOSTIC CHECKLIST

- Atherosclerosis is by far most common cause of vasculitis-like DSA pattern in older adults, not PACNS

(Left) *Coronal oblique graphic illustrates alternating segmental areas of narrowing and dilatation of the opercular and superficial MCA branches, as well as patchy multifocal ischemia within the underlying brain from primary arteritis of the CNS.* **(Right)** *Micropathology, low-power H and E section from the autopsy of a 71-year-old woman with multifocal T2 and FLAIR brain hyperintensities (not illustrated) shows intimal and adventitial necrosis and inflammatory changes, characteristic for CNS vasculitis.*

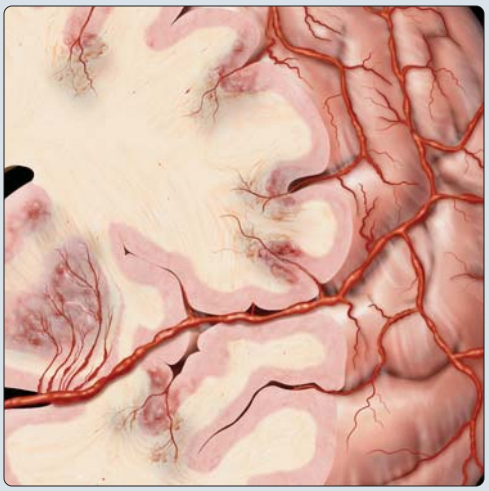

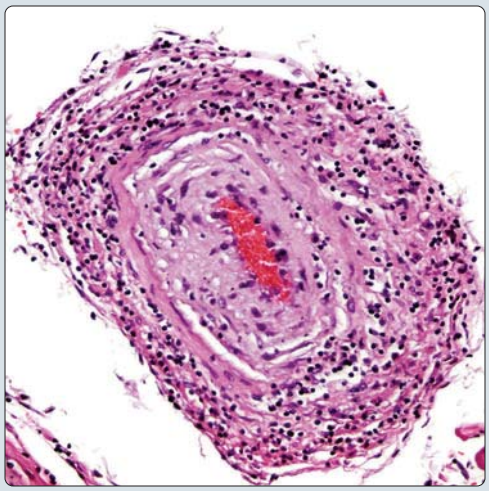

(Left) *Lateral DSA in a 34-year-old woman with multiple strokes shows markedly irregular posterior cerebral artery ⇨ with alternating areas of stenosis and dilatation.* **(Right)** *Thin-section T1 C+ FS in the same patient shows enhancement in the wall of the left PCA ⇨. Wall enhancement can occur in both vasculitis and atherosclerosis with chronic inflammation. Although this patient was a smoker and had cardiovascular risk factors, the young age and clinical features were most consistent with vasculitis.*

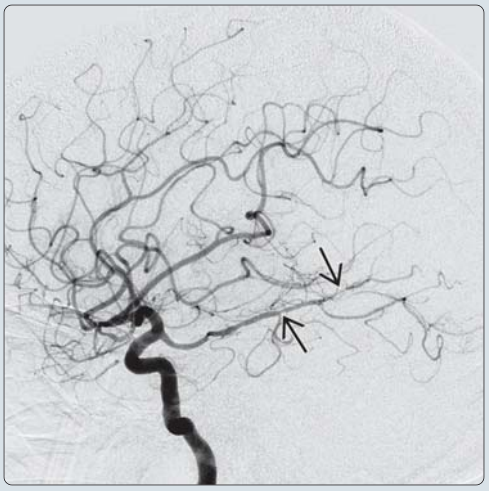

https://CafePezeshki.IR

TERMINOLOGY

Abbreviations

- Primary arteritis of CNS (PACNS)

Synonyms

- Vasculitis, vasculopathy

Definitions

- 2 cardinal features required for histopathologic diagnosis of vasculitis
  - Inflammation and necrosis of blood vessel wall
- PACNS: Arteritis confined to intracranial CNS without evidence for systemic vasculitis

IMAGING

General Features

- Best diagnostic clue
  - Circumferential, smooth, long-segment vessel wall enhancement
  - "Beaded" arteries (irregular stenoses, dilatations) on DSA
    - Nonspecific (intracranial atherosclerotic vascular disease (ASVD) > vasculitis)
  - Note: Imaging work-up can be normal; requires clinical/laboratory correlation
- Location
  - Pathologically leptomeningeal arteries and veins are affected, but involves intracranial vessels of any size
  - Brain is primary site, but spinal cord can also be involved
- Size
  - Degree of vessel narrowing may range from normal or minimally stenotic to completely occluded
- Morphology
  - Areas of smooth or slightly irregularly shaped stenoses alternating with dilated segments
  - Nonspecific (appearance similar to other vasculitides)

CT Findings

- NECT
  - Relatively insensitive; often normal
  - May see secondary signs, such as ischemia or infarction
    - Multifocal low-density areas especially in basal ganglia, subcortical white matter
  - May see hemorrhage (less typical)
- CECT
  - May see patchy areas of enhancement

MR Findings

- T1WI
  - Multifocal deep gray and subcortical hypointensities
- FLAIR
  - Multifocal deep gray and subcortical hyperintensities
- T2* GRE
  - May show petechial hemorrhage
- DWI
  - Restricted diffusion in acute stages
- T1WI C+
  - High-resolution MR can show vessel wall enhancement
  - May see patchy areas of parenchymal enhancement
    - Smooth, linear, circumferential
- MRA
  - Relatively insensitive, most often normal
  - May see some classic angiographic signs if larger vessels involved

Angiographic Findings

- DSA
  - Typical: Alternating stenosis with dilatation primarily involving 2nd-, 3rd-order branches
  - Less common: Long-segment stenoses, pseudoaneurysms, occlusions
  - Consider: Imaging renal arteries to evaluate for systemic vasculitis

Imaging Recommendations

- Best imaging tool
  - Vessel wall imaging with thin-section, high-resolution (3T) T1 C+
  - DSA once considered gold standard for imaging
    - Nonspecific (ASVD much more common than vasculitis)
- Protocol advice
  - 3T thin-section pre-, post-contrast T1WI to visualize vessel wall
  - DSA if lab studies positive, MR/MRA negative, and high clinical suspicion
  - CTA/MRA is useful for screening; spatial resolution insufficient for subtle disease

DIFFERENTIAL DIAGNOSIS

Intracranial Atherosclerotic Vascular Disease (ASVD)

- Advanced patient age
- Typical distribution (carotid siphon, proximal intracranial vessels)

Systemic CNS Vasculitis

- Secondary CNS involvement of systemic vasculitis, polyarteritis, SLE are most common
- DSA appearance indistinguishable from PACNS

Reversible Cerebral Vasoconstriction Syndrome

- Reversible; posterior circulation, watershed
- Can appear identical on DSA

Vasospasm

- Temporal relationship to subarachnoid hemorrhage
- Proximal trunks (COW) > peripheral branches

Intravascular Lymphoma

- Lacks vessel wall enhancement
- Hemorrhage more common

PATHOLOGY

General Features

- Etiology
  - Unknown
- Brain biopsy may be required to confirm diagnosis
  - Definite diagnosis made from mononuclear inflammation of vessel wall
  - 75-80% sensitive; negative biopsy does not necessarily exclude PACNS

https://CafePezeshki.IR

- Diagnosis can be established on clinical grounds, typical findings on DSA, and other investigatory grounds excluding other diseases
- Must be distinguished from other causes of CNS inflammation and noninflammatory vascular disease

Staging, Grading, & Classification

- PACNS: Highly heterogeneous group of vasculitides limited to CNS
  - Spectrum from granulomatous angiitis of CNS (GACNS) to benign angiopathy of central nervous system (BACNS) to reversible vasoconstrictive syndrome (RCVS)
  - BACNS, RCVS have more favorable outcome; all have indistinguishable angiographic appearance
- Clinical manifestations of CNS vasculitides may be identical
  - Acute onset, headache, normal to mildly abnormal CSF findings; female predominance in BACNS, RCVS
  - Focal weakness, seizures, hemorrhage, confusion, memory disorders, altered consciousness can be seen in each
  - Despite "benign" designation in BACNS and RCVS, some patients sustain significant neurological damage
  - Histories of heavy nicotine or caffeine use, OTC cold remedy use, and oral contraceptive or estrogen replacement
  - Precise relationship (if any) of these exposures remains unclear

Gross Pathologic & Surgical Features

- Characterized by ischemic lesions and small petechial hemorrhages
- Vessels of any size can be involved
- May see venulitis with parenchymal hemorrhages

Microscopic Features

- Mononuclear inflammation with necrosis of blood vessel walls is PACNS hallmark
- Variable degree of granulomatous and nongranulomatous angiitis of small vessels
- Typically involves media and adventitia of small leptomeningeal arteries and veins

CLINICAL ISSUES

Presentation

- Most common signs/symptoms
  - Stroke from vascular involvement (stenoses, occlusion, aneurysm)
  - Headache is also common
- Clinical profile
  - Clinical presentation is highly variable: Focal to diffuse manifestations and acute to chronic evolution
  - Subacute presentation over weeks or months is typical (mean = 5 months to diagnosis)
  - Headache and mental status change with focal deficits
  - No evidence of secondary vasculitis or other diseases mentioned in differential diagnosis should arouse suspicion

Demographics

- Age
  - Childhood to adulthood
  - Mean age ~ 42 years; range from age 3 to elderly
  - BACNS, RCVS patients tend to be young women
- Gender
  - Distribution of PACNS is nearly equal between sexes, with perhaps slight male predominance
- Epidemiology
  - Rare

Natural History & Prognosis

- Prognosis greatly improved with early recognition and therapy
- Delay in diagnosis may lead to additional morbidity
- PACNS: More likely to develop symptoms subacutely and remain undiagnosed for months
- BACNS: More likely to have relatively acute presentations and be diagnosed within weeks of onset
- Untreated PACNS: Risk of permanent cognitive dysfunction
- Often diagnosed posthumously; high index of suspicion is necessary to make correct diagnosis in timely basis

Treatment

- Few controlled studies on treatment of vasculitis, with considerable variation among centers on current therapeutic regimens
- Therapy typically comprises aggressive immunosuppressive approach
- High-dose steroid therapy with prolonged course and gradual taper controls disease in most cases
- Close monitoring of patients mandatory
- Without treatment, patients with PACNS tend to have progressively downhill courses often leading to death
- BACNS, RCVS patients may respond to less aggressive corticosteroid and Ca++ channel blocker therapy

DIAGNOSTIC CHECKLIST

Consider

- DSA when clinical suspicion of PACNS is strong, regardless of findings on MR

Image Interpretation Pearls

- Atherosclerosis is by far most common cause of vasculitis-like DSA pattern in older adults, not PACNS

SELECTED REFERENCES

1. Miller TR et al: Reversible cerebral vasoconstriction syndrome, part 2: diagnostic work-up, imaging evaluation, and differential diagnosis. AJNR Am J Neuroradiol. ePub, 2015
2. Rodriguez-Pla A et al: Primary angiitis of the central nervous system in adults and children. Rheum Dis Clin North Am. 41(1):47-62, viii, 2015
3. Salvarani C et al: Adult primary central nervous system vasculitis treatment and course: Analysis of 163 patients. Arthritis Rheumatol. ePub, 2015
4. Vera-Lastra O et al: Primary and secondary central nervous system vasculitis: clinical manifestations, laboratory findings, neuroimaging, and treatment analysis. Clin Rheumatol. 34(4):729-38, 2015
5. Abdel Razek AA et al: Imaging spectrum of CNS vasculitis. Radiographics. 34(4):873-94, 2014
6. Miller DV et al: Biopsy findings in primary angiitis of the central nervous system. Am J Surg Pathol. 33(1):35-43, 2009
7. Molloy ES et al: Primary angiitis of the central nervous system. Curr Treat Options Neurol. 9(3):169-75, 2007
8. MacLaren K et al: Primary angiitis of the central nervous system: emerging variants. QJM. 98(9):643-54, 2005
9. Carolei A et al: Central nervous system vasculitis. Neurol Sci. 24 Suppl 1:S8-S10, 2003
10. West SG: Central nervous system vasculitis. Curr Rheumatol Rep. 5(2):116-27, 2003

https://CafePezeshki.IR

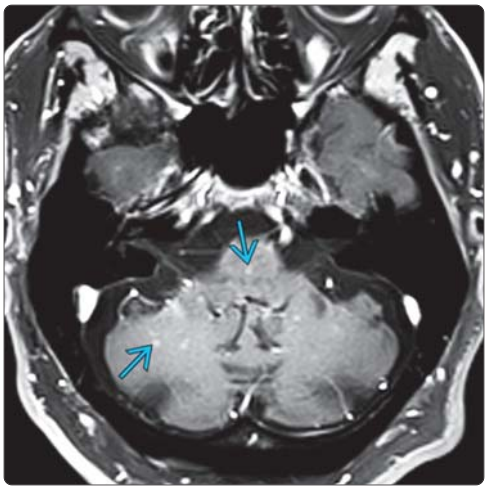

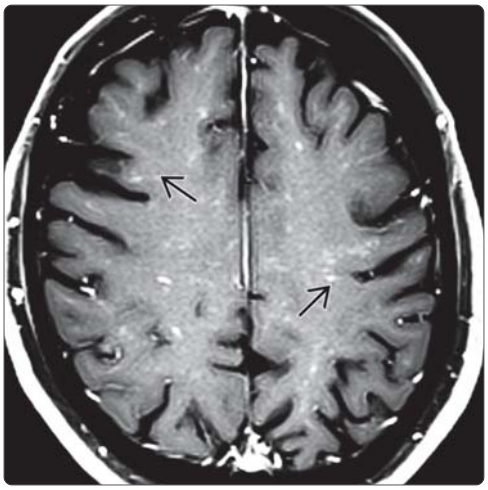

(Left) *Axial T1 C+ FS scan in a patient with progressive ataxia and slowly worsening diplopia for 6 years shows multifocal punctate and linear enhancing foci ⇨ in the medulla and cerebellar hemispheres.* **(Right)** *More cephalad T1 C+ FS scan in the same patient shows innumerable linear and dot-like areas of enhancement ⇨ in the subcortical and deep white matter of both hemispheres.*

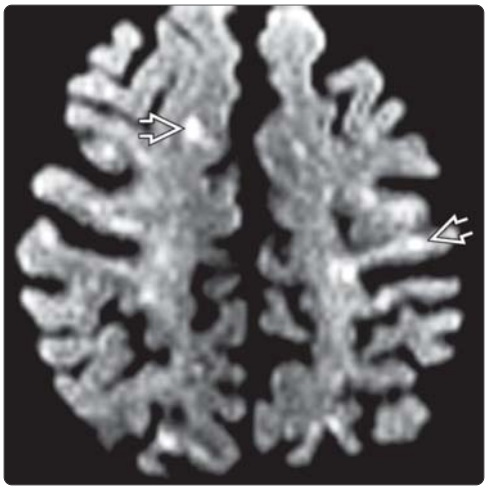

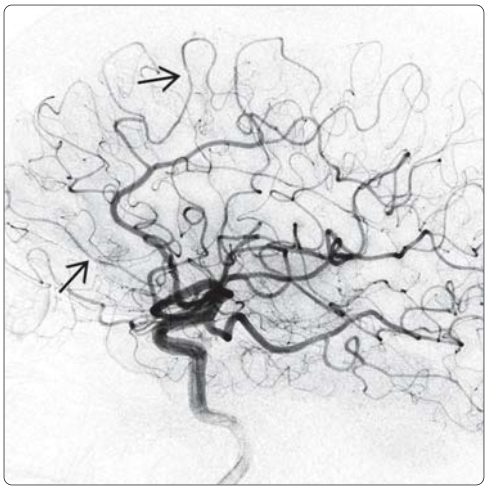

(Left) *DWI in the same patient shows multiple small rounded and linear foci of restricted diffusion ⇨.* **(Right)** *Lateral DSA of the internal carotid angiogram subsequently obtained shows subtle areas of irregular narrowing ⇨ in distal cortical arteries suggestive of vasculitis.*

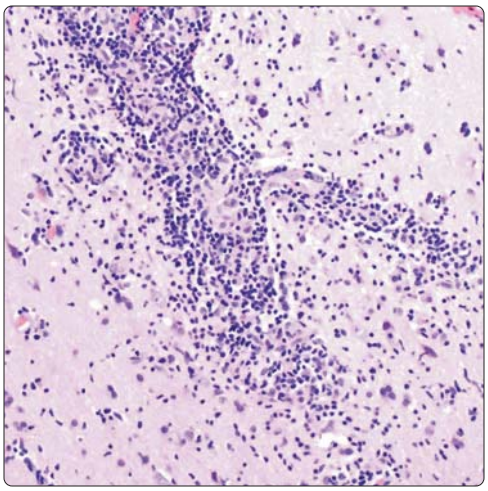

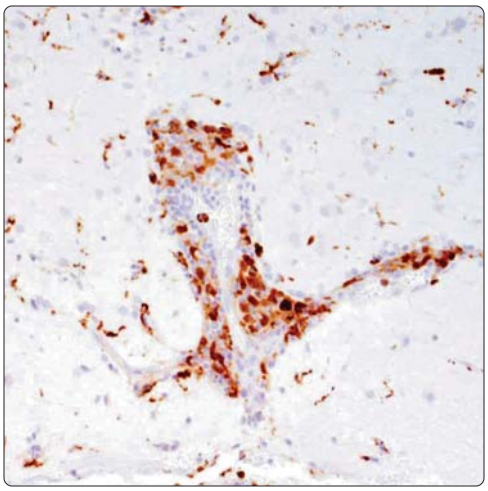

(Left) *Micrograph with H&E stain of the biopsy obtained in the same patient shows necrosis and inflammatory infiltrate thickening the wall of this penetrating cortical artery.* **(Right)** *Immunohistochemistry in the same patient is positive for CD68 T-cell lymphocytes. The final histopathologic diagnosis was PACNS.*

https://CafePezeshki.IR

KEY FACTS

TERMINOLOGY

- Heterogeneous group of CNS disorders
  - Characterized by nonatheromatous inflammation and necrosis of blood vessel walls
  - Both arteries, veins may be affected

IMAGING

- CTA/MRA useful screening; spatial resolution usually insufficient for subtle disease
- MR
  - Basal ganglia, cortex, subcortical WM
    - Multifocal hypodensities/T2 hyperintensities
    - Look for secondary signs (ischemia/infarction)
  - High-resolution (3T, thin-section) T1C+ may demonstrate wall enhancement
    - Smooth, concentric
    - Long segment
    - Distal involvement (e.g., M2, M3, M4 branches > intracranial ICA or BA)
    - Multiple vessels usually affected
- DSA
  - Findings nonspecific (visualizes lumen, not vessel wall)
    - Multifocal areas of smooth or slightly irregular-shaped stenoses alternating with dilated segments
    - May occur in intracranial vessels of any size
    - Major differential diagnosis = intracranial atherosclerosis

TOP DIFFERENTIAL DIAGNOSES

- Intracranial atherosclerotic vascular disease
- Arterial vasospasm
- Reversible cerebral vasoconstriction syndrome

PATHOLOGY

- Vessel wall inflammation, necrosis common to all vasculitides

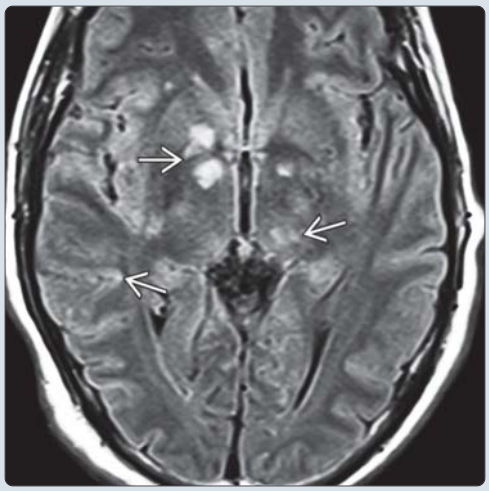

(Left) *Coronal oblique graphic shows vasculitis with medium vessel changes ⇨ and parenchymal changes seen as multifocal areas of edema, infarction, and scattered hemorrhages within the basal ganglia and at the gray-white junction.* **(Right)** *Axial FLAIR scan in a case of secondary CNS vasculitis shows multiple hyperintense foci in the basal ganglia, thalami, and cortex ⇨.*

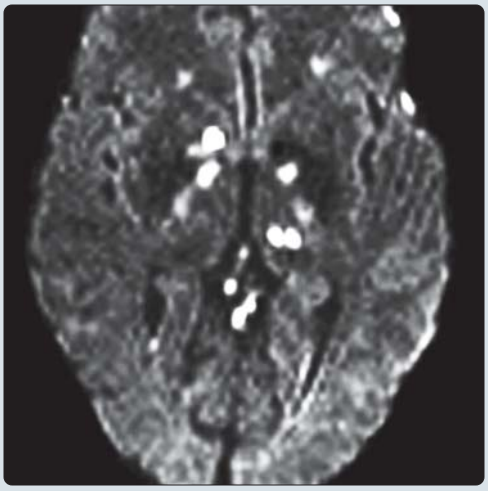

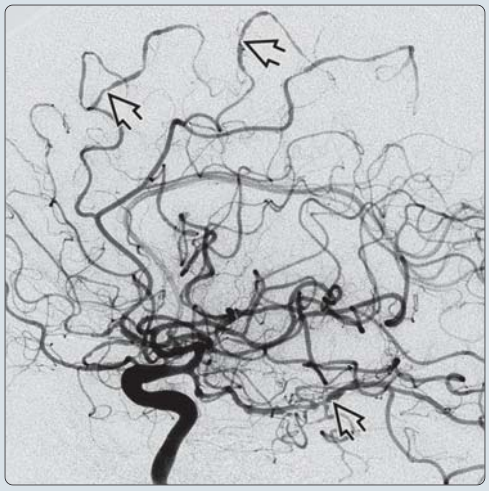

(Left) *Axial DWI MR in the same case shows multiple small foci of restricted diffusion in the basal ganglia, thalami, and cortex.* **(Right)** *Lateral view of the internal carotid angiogram obtained in the same case shows multiple cortical vessels ⇨ with alternating areas of stenosis and dilatation ("beading"). The findings are consistent with multiple infarcts secondary to infectious (streptococcal) vasculitis.*

https://CafePezeshki.IR

TERMINOLOGY

Synonyms

- Inflammatory vasculopathy (more general term indicating any vascular pathology with inflammation)
- Arteritis (specifies arterial inflammation)
- Angiitis (inflammation of either arteries or veins)

Definitions

- Heterogeneous group of CNS disorders characterized by nonatheromatous inflammation and necrosis of blood vessel walls
- Involves either arteries or veins

IMAGING

General Features

- Best diagnostic clue
  - Irregularities, stenoses, and vascular occlusions in pattern atypical for atherosclerotic disease
  - Imaging work-up can be normal; need clinical/laboratory correlation
- Location
  - Arteries and veins affected; occurs in intracranial vessels of any size
- Size
  - Degree of vessel narrowing may range from normal/minimally stenotic to occluded
- Morphology
  - Classic appearance: Multifocal areas of smooth or slightly irregular-shaped stenosis alternating with dilated segments
  - Variety of angiographic appearances depending on etiology, including vascular irregularities, stenoses, aneurysms, and occlusions

MR Findings

- T1WI
  - Can be normal early; ± multifocal cortical/subcortical hypointensities
- T2WI
  - Multifocal hyperintensities
- FLAIR
  - Subcortical, basal ganglia hyperintensities
- T2* GRE
  - May show hemorrhage
- DWI
  - Can see restricted diffusion in acute stage
- T1WI C+
  - May see patchy areas of parenchymal enhancement
  - High-resolution (3T, thin-section) T1C+ may demonstrate wall enhancement
    - Smooth, concentric
    - Long segment
    - Distal involvement (e.g., M2, M3, M4 branches > intracranial ICA or BA)
    - Multiple vessels usually affected
- MRA
  - May see some classic angiographic signs if larger vessels involved/vascular occlusion; may be normal

Angiographic Findings

- Conventional
  - Alternating stenosis and dilatation primarily involving 2nd, 3rd order branches
  - Less common: Long segment stenoses, pseudoaneurysms

Imaging Recommendations

- Best imaging tool
  - High-resolution contrast-enhanced MR with vessel wall imaging
  - DSA if MR/MRA negative
- Protocol advice
  - DSA if lab studies positive, MR/MRA negative
  - CTA/MRA useful screening; spatial resolution may be insufficient for subtle disease

DIFFERENTIAL DIAGNOSIS

Intracranial Atherosclerotic Vascular Disease

- Advanced patient age
- Typical distribution (carotid siphon, proximal intracranial vessels); extracranial manifestations of disease

Arterial Vasospasm

- Temporal relationship to subarachnoid hemorrhage (SAH)
- Involves proximal vasculature

Reversible Cerebral Vasoconstriction Syndrome

- Thunderclap headache ± subarachnoid hemorrhage
- Can mimic vasculitis on angiography
- Resolves with verapamil infusion

PATHOLOGY

General Features

- Etiology
  - Pattern of vessel wall inflammation, necrosis common to all vasculitides
  - Can be primary or secondary, caused by broad spectrum of infectious/inflammatory agents, drugs, etc.
  - Bacterial meningitis
    - Infarction due to vascular involvement seen in 25%
    - *Haemophilus influenzae* most common organism; common in children
  - Tuberculous meningitis
    - Vessels at skull base most commonly involved (i.e., supraclinoid ICA and M1-producing occlusions and stenoses)
  - Mycotic arteritis (*Aspergillus*, cocci, etc.)
    - Actinomyces may invade vessel walls leading to hemorrhage
    - Narrowing of basal cerebral or cortical vessels on angiography
  - Viral arteritis
    - Herpes simplex most common in North America
    - HIV-associated vasculitis increasing, especially in children
  - Syphilis arteritis
    - 2 forms: Syphilitic meningitis and gummatous vasculitis
    - Diffuse vasculitis involves cortical arteries and veins

https://CafePezeshki.IR

  - Gummatous vasculitis usually affects proximal MCA branches
- Polyarteritis nodosa
  - Most common systemic vasculitis to involve CNS (though late)
  - Microaneurysms due to necrosis of internal elastic lamina in 75%
- Cell-mediated arteritides
  - Giant cell arteritis (granulomatous infiltration of arterial walls)
  - Takayasu (primarily involves aorta, great vessels, branches)
  - Temporal arteritis (systemic; involves temporal, other extracranial arteries)
- ANCA associated (formerly Wegener)
  - May cause intracerebral and meningeal granulomas or vasculitis
  - CNS involved in 15-30% due to direct invasion from nose/sinuses
  - Chronic systemic arteritis involving lungs, kidneys, and sinuses
- Sarcoid (CNS involvement in 3-5% of cases)
  - Can extend along perivascular spaces, involve penetrating arteries
  - Meningitis, vasculitis involving vessels at base of brain
- Granulomatous angiitis (PACNS)
  - Primary angiitis isolated to CNS (idiopathic)
  - Manifest as multiple intracranial stenoses
- Collagen vascular disease (SLE, rheumatoid, scleroderma)
  - SLE: Most likely to involve CNS
  - Vasculitis relatively uncommon (variable findings; range from small vessel irregularities/stenoses/occlusions to fusiform aneurysms)
  - CVA seen in 50% due to cardiac disease or coagulopathy
- Drug abuse vasculitis
  - Drug can injure vessels directly or secondarily (usually hypersensitivity to contaminants)
  - Associated with both legitimate and illegal "street" drugs, including amphetamines, cocaine, heroin, and phenylpropanolamine and ergots
- Radiation
  - Acute arteritis produces transient white matter edema
  - Chronic changes more severe with vessel obliteration and brain necrosis, leukomalacia, mineralizing microangiopathy, and atrophy
  - Effects compounded with concomitant chemotherapy
- Moyamoya disease
  - Sometimes referred to as "idiopathic progressive arteriopathy of childhood"
  - Moyamoya is angiographic pattern, not specific disease; may be acquired or inherited
  - Any slowly progressive occlusion of supraclinoid ICAs may develop moyamoya pattern
  - Pattern has been reported with NF, atherosclerosis, radiation therapy
  - Prognosis depends upon rapidity and extent of vascular occlusions, as well as development of effective collaterals

Gross Pathologic & Surgical Features

- Characterized by ischemic lesions and small petechial hemorrhages
- Vessels of any size can be involved
- May see venulitis with parenchymal hemorrhages

Microscopic Features

- Inflammation and necrosis of blood vessel walls

CLINICAL ISSUES

Presentation

- Most common signs/symptoms
  - Stroke related to manifestations of vascular involvement (stenosis, occlusion, aneurysm)
  - Patients presenting with symptoms suggestive of vasculitis require brain neuroimaging, lumbar puncture, and angiography, but only biopsy allows definite diagnosis

Demographics

- Epidemiology
  - Atherosclerosis is by far most common cause of vasculitis-like angiographic pattern in adults
  - CNS vasculitis occurs in variety of clinical settings, some of which exhibit distinct age preference, others tissue tropism

Natural History & Prognosis

- Varies depending upon etiology; typically progressive if untreated

Treatment

- Most patients with CNS vasculitis are treated aggressively with combination of steroids, immunosuppressive medications

DIAGNOSTIC CHECKLIST

Consider

- Diagnosis is frequently made on basis of clinical presentation, brain MR, and cerebral angiography without pathologic confirmation

SELECTED REFERENCES

1. Guellec D et al: ANCA-associated vasculitis in patients with primary Sjögren's syndrome: Detailed analysis of 7 new cases and systematic literature review. Autoimmun Rev. ePub, 2015
2. Powers WJ: Primary Angiitis of the Central Nervous System: Diagnostic Criteria. Neurol Clin. 33(2):515-526, 2015
3. Rodriguez-Pla A et al: Primary angiitis of the central nervous system in adults and children. Rheum Dis Clin North Am. 41(1):47-62, viii, 2015
4. Abdel Razek AA et al: Imaging spectrum of CNS vasculitis. Radiographics. 34(4):873-94, 2014
5. Chiang F et al: Varicella zoster CNS vascular complications. A report of four cases and literature review. Neuroradiol J. 27(3):327-33, 2014
6. John S et al: CNS vasculitis. Semin Neurol. 34(4):405-12, 2014
7. Larivière D et al: Extra- and intracranial cerebral vasculitis in giant cell arteritis: an observational study. Medicine (Baltimore). 93(28):e265, 2014
8. Obusez EC et al: High-resolution MRI vessel wall imaging: spatial and temporal patterns of reversible cerebral vasoconstriction syndrome and central nervous system vasculitis. AJNR Am J Neuroradiol. 35(8):1527-32, 2014

https://CafePezeshki.IR

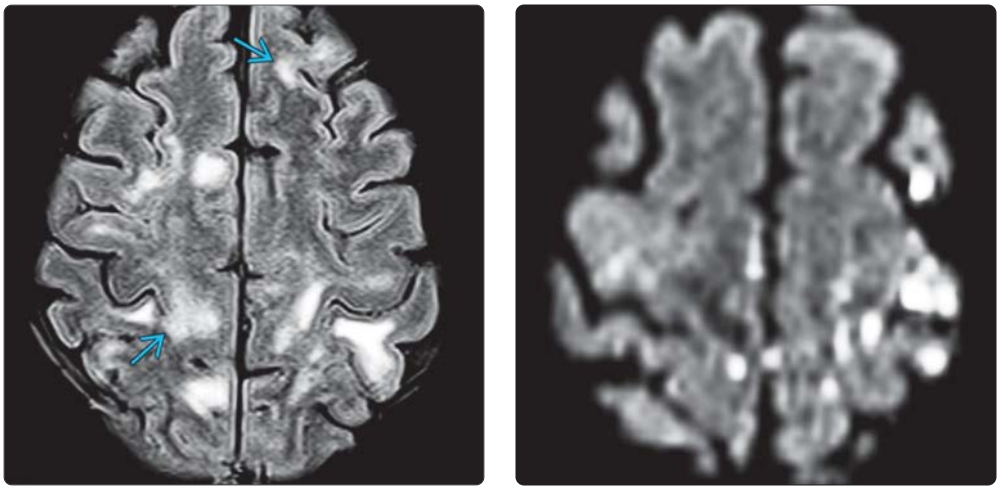

(Left) *Axial FLAIR scan in a patient with polyarteritis nodosa, confusion, and then obtundation shows multifocal cortical and subcortical hyperintensities ⇨ in both hemispheres.* **(Right)** *DWI in the same case shows multiple small foci of restricted diffusion in the cortex and subcortical white matter.*

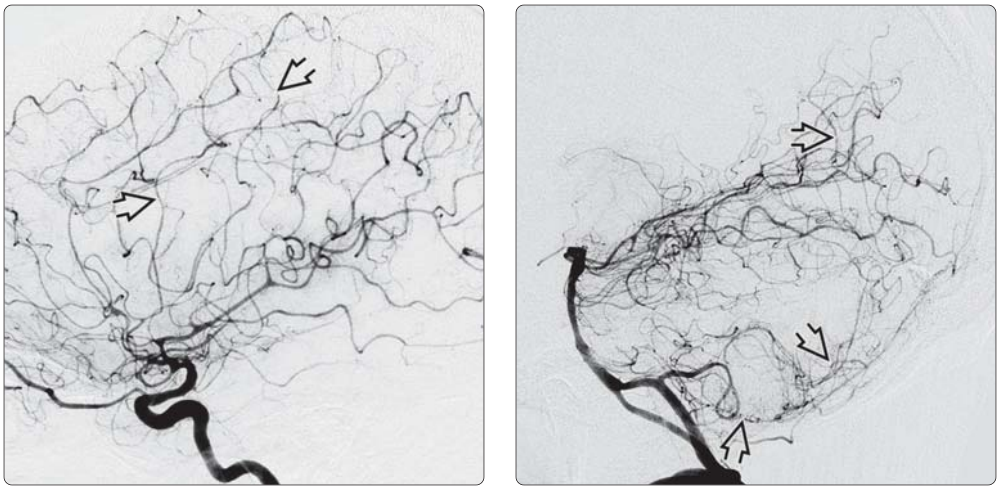

(Left) *Lateral DSA in the same case shows multifocal areas of vessel irregularity and constriction ⇨ in the distal left middle and anterior cerebral arteries giving the cortical vessels a "beaded" appearance.* **(Right)** *Lateral DSA of the left vertebral artery angiogram shows similar "beaded" appearance with multiple small areas of irregular stenosis ⇨. Findings are consistent with intracranial arteritis.*

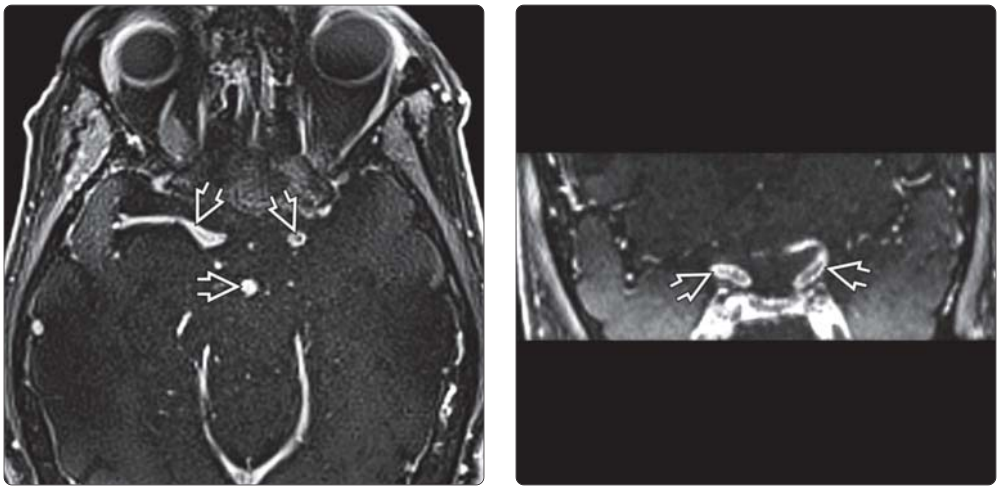

(Left) *Axial T1 C+ FS MR in a patient with ANCA-positive vasculitis shows marked circumferential and linear enhancement of the left internal carotid, M1 middle cerebral, and distal basilar arteries ⇨.* **(Right)** *Coronal T1 C+ FS scan in the same patient shows striking enhancement of the supraclinoid internal carotid arteries ⇨. Vessel wall enhancement can occur in ASVD but is typically not this smooth, concentric, and linear.*

https://CafePezeshki.IR

KEY FACTS

TERMINOLOGY

- Reversible cerebral vasoconstriction syndrome (RCVS), a.k.a. Call-Fleming syndrome
- Group of disorders characterized by
  - Reversible, multifocal cerebral artery vasoconstrictions
  - Severe headaches ± focal neurological deficits

IMAGING

- Acute/recurrent headaches with vasculitic pattern (DSA)
- DSA = crucial for diagnosis (100% sensitive)
  - Involves large, medium-sized arteries
  - Diffuse, multifocal, segmental narrowing
  - Sometimes "string of beads" or "sausage strings"
- NECT often negative
  - Small cortical subarachnoid hemorrhage (SAHs) (20%) ± parenchymal hemorrhage
- CTA/MRA: May be normal if subtle changes (10%)
  - Diffuse segmental arterial constriction in 90%
- TCD: ↑ arterial velocities in MCA, ICA, ACA

PATHOLOGY

- Thought to represent transient disturbance in control of cerebral vascular tone → vasoconstriction → ischemia, stroke, death
- Spontaneous (1/3 of cases) or precipitated by
  - Postpartum state
  - Exposure to vasoactive substances
- Can be associated with posterior reversible encephalopathy syndrome (PRES)

CLINICAL ISSUES

- Symptoms: Severe, acute "thunderclap" headache
  - Often recurrent (95%)
  - Ischemia/stroke (visual disturbance, aphasia, hemiparesis)
- Treatment
  - Discontinuation of vasoactive medications
  - Vasodilators (e.g., Ca++ antagonists)

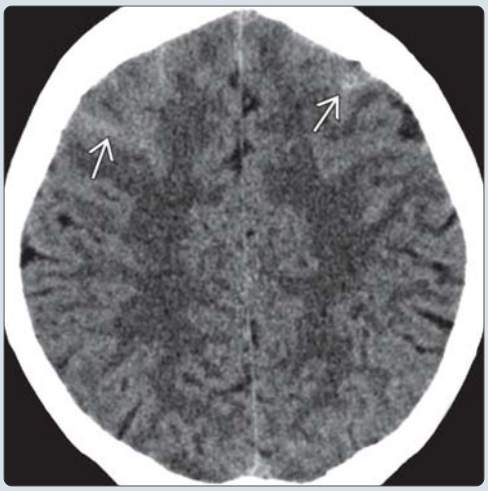

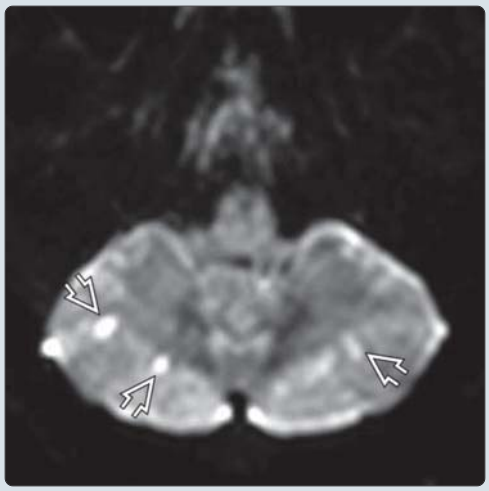

(Left) *Axial NECT in a female patient with acute onset of severe headache shows limited cortical subarachnoid hemorrhage (SAH) in the sulci of the frontal lobes ⇨. DSA was performed to exclude a vascular lesion and showed multifocal arterial narrowings (not shown) related to RCVS.* **(Right)** *Axial DWI trace image shows multiple foci of hyperintensity ⇨ related to acute ischemia in this patient with RCVS who presented with an acute onset of a "thunderclap" headache. Ischemia is a common complication of RCVS.*

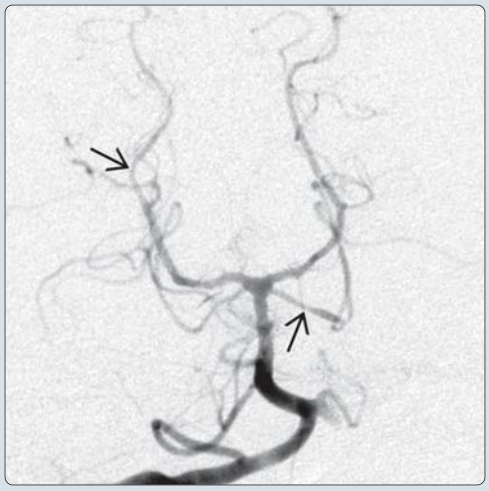

(Left) *Anteroposterior right vertebral artery DSA shows diffuse luminal irregularity and focal stenoses involving the basilar artery and posterior cerebral and superior cerebellar arteries ⇨. Similar changes were seen in the anterior circulation (not shown). The patient was treated with IA verapamil over the next 10 days.* **(Right)** *DSA repeated 2 weeks later shows significant interval resolution of the posterior circulation vasospasm. There are a few foci ⇨ of mild residual stenoses still evident.*

https://CafePezeshki.IR

TERMINOLOGY

Abbreviations

- Reversible cerebral vasoconstriction syndrome (RCVS)

Definitions

- Group of disorders characterized by
  - Reversible, multifocal cerebral artery vasoconstriction
  - Severe headaches (HA) ± focal neurological deficits

IMAGING

General Features

- Best diagnostic clue
  - Acute onset, usually recurrent HA with vasculitic pattern on DSA

CT Findings

- NECT
  - May see small cortical subarachnoid hemorrhage (SAH) in 20% of parenchymal hemorrhages
  - Cortical ± subcortical hypodensity secondary to ischemia/stroke
- CTA
  - May be normal or can see undulations of large/medium-sized arteries

MR Findings

- FLAIR
  - May see uni- or bilateral cortical SAH
  - Focal regions of ↑ signal secondary to stroke
- DWI
  - Most sensitive for regions of ischemia/stroke
- MRA
  - May be normal if subtle changes (10%); require DSA for diagnosis
  - Diffuse segmental arterial constriction in 90%

Ultrasonographic Findings

- Transcranial Doppler (TCD): ↑ arterial velocities consistent with vasospasm + ↓ luminal diameter of MCA, ICA, ACA in 70%

Angiographic Findings

- Crucial for diagnosis (100% sensitive)
- Diffuse, multifocal, segmental narrowing of large/medium-sized arteries
- Occasional dilated segments may appear like string of beads or sausage strings

DIFFERENTIAL DIAGNOSIS

Cerebral Vasculitis

- Similar angiographic appearance; clinical onset more insidious, CSF abnormalities
- e.g., primary angiitis of central nervous system (PACNS), systemic lupus, infection, sarcoidosis

SAH

- Aneurysm, dural fistula, trauma, arteriovenous malformation

PATHOLOGY

General Features

- Etiology
  - Thought to represent transient disturbance in control of cerebral vascular tone → vasoconstriction → ischemia, stroke, death
- Associated abnormalities
  - Occurs spontaneously (1/3 of cases) or may be precipitated by
    - Postpartum state
    - Exposure to vasoactive substances
      - Cannabis, cocaine, ecstasy, amphetamine derivatives, LSD
      - Selective serotonin reuptake inhibitors (SSRIs)
      - Nasal decongestants, pseudoephedrine
      - Ergotamine tartrate, bromocriptine, sumatriptan
    - Pheochromocytoma, bronchial carcinoid tumor

CLINICAL ISSUES

Presentation

- Most common signs/symptoms
  - Severe, acute onset ("thunderclap") headache
    - Often recurrent (95%)
    - Mimics SAH secondary to ruptured aneurysm
- Other signs/symptoms
  - Ischemia/stroke may result in visual disturbance, aphasia, hemiparesis
  - Seizures

Natural History & Prognosis

- Stroke occurs in 7-54%
- M:F = 1:2
- Up to 10% permanent disability
- Can be associated with posterior reversible encephalopathy syndrome (PRES)
- Vascular abnormalities resolve within several months

Treatment

- Discontinuation of vasoactive medications
- Vasodilators (e.g., Ca++ antagonists) PO/IV/IA infusion

DIAGNOSTIC CHECKLIST

Consider

- RCVS in patient with history of thunderclap headache but no SAH or limited cortical SAH

Image Interpretation Pearls

- Interval DSA may show improvement with vasodilator Rx

SELECTED REFERENCES

1. Kass-Hout T et al: A novel approach to diagnose reversible cerebral vasoconstriction syndrome: a case series. J Stroke Cerebrovasc Dis. 24(1):e31-7, 2015
2. Marder CP et al: Multimodal imaging of reversible cerebral vasoconstriction syndrome: a series of 6 cases. AJNR Am J Neuroradiol. 33(7):1403-11, 2012
3. Ducros A et al: The clinical and radiological spectrum of reversible cerebral vasoconstriction syndrome. A prospective series of 67 patients. Brain. 130(Pt 12):3091-101, 2007

https://CafePezeshki.IR

KEY FACTS

TERMINOLOGY

- Reversible stenosis of intracranial arteries
- Caused by exposure to blood breakdown products
  - Contraction of vascular smooth muscle
  - Histological changes in vessel wall

IMAGING

- General features (CTA/MRA/DSA)
  - Typically occurs 4-14 days after subarachnoid hemorrhage (SAH)
  - Smooth, relatively long segmental stenoses
  - Seen as arterial luminal irregularity/undulations
  - Multiple arteries, usually > 1 vascular territory
- CT perfusion
  - ↑ time to peak (TTP), ↑ mean transit time (MTT)
  - ↓ cerebral blood flow (CBF) in areas of hypoperfusion
- Transcranial Doppler (TCD)
  - ↑ mean flow velocity
  - Due to ↓ arterial cross-sectional area

TOP DIFFERENTIAL DIAGNOSES

- Non-SAH causes of vasospasm
  - Meningitis
  - Acute hypertensive encephalopathy (PRES)
  - Reversible cerebral vasoconstriction syndrome (RCVS)
  - Migraine headache
- Vasculitis
- Atherosclerosis

CLINICAL ISSUES

- Delayed ischemic neurological deficit (DIND)
  - ~ 1 week after SAH is typical
- Management
  - "Triple H" therapy
  - Endovascular (chemical or balloon angioplasty)

(Left) *Autopsied case of ruptured MCA aneurysm* ⇨ *with subarachnoid hemorrhage (SAH) in a patient who survived several days shows severe vasospasm of the parent MCA* ⇨. **(Right)** *Axial NECT in a 43-year-old male in the ER with "worst headache of life" shows diffuse subarachnoid hemorrhage* ⇨ *in the basal cisterns, especially in the left sylvian fissure.*

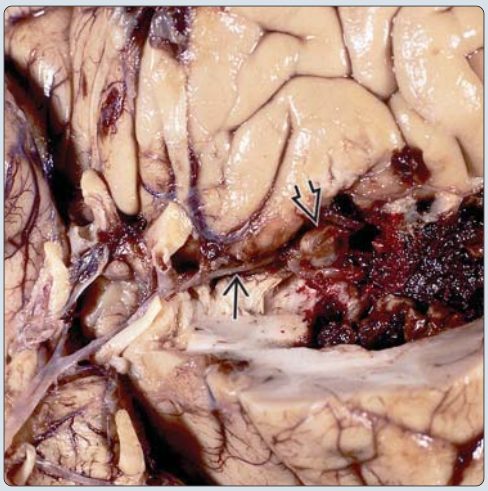

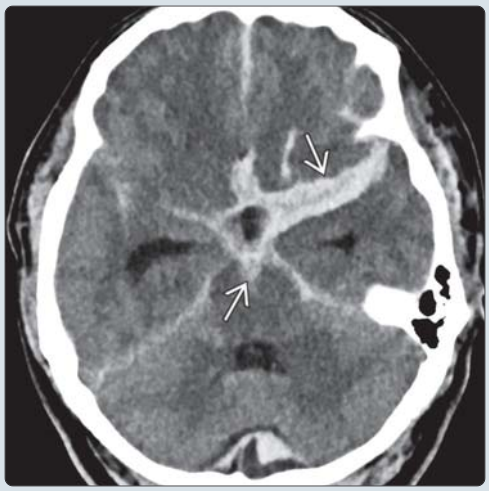

(Left) *CT angiogram in the same patient shows a lobulated aneurysm* ⇨ *at the left distal ICA bifurcation.* **(Right)** *Four days after emergency clipping of the aneurysm, the patient became drowsy and developed right-sided weakness. AP DSA of the left internal carotid artery shows mass effect, vasospasm* ⇨, *seen here as narrowing of the proximal ACA and MCA. The patient responded well to intraarterial infusion of verapamil.*

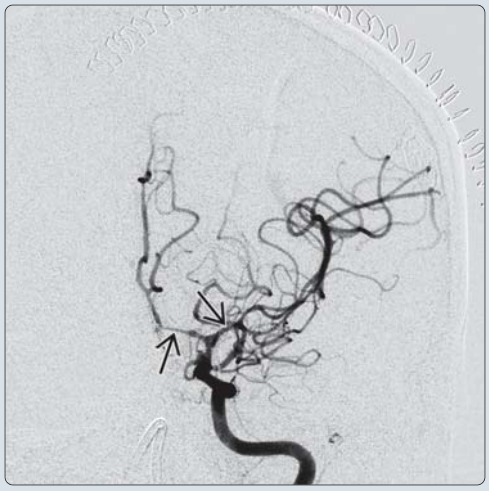

https://CafePezeshki.IR

TERMINOLOGY

Synonyms

- Subarachnoid hemorrhage (SAH) vasospasm

Definitions

- Exposure to blood breakdown products → reversible stenosis of intracranial arteries
  - Contraction of vascular smooth muscle
  - Histological changes in vessel wall

IMAGING

General Features

- Best diagnostic clue
  - Segmental stenoses (CTA/MRA/DSA)
    - Typically 4-14 days after SAH
- Location
  - Affects any intradural (subarachnoid) artery
  - Worst vasospasm typically adjacent to site of ruptured aneurysm (highest concentration of SAH)

Imaging Recommendations

- Best imaging tool
  - Gold standard is DSA (100% sensitive but nonspecific)
    - May follow with intraarterial (IA) therapy
  - TCD useful as bedside monitoring/screening tool
- Protocol advice
  - Multi-territorial vascular involvement is typical
  - Visualize both carotids, dominant vertebral artery

CT Findings

- NECT
  - May see residual SAH
  - Otherwise normal (unless ischemia/stroke)
  - Hypodensity in involved vascular territory may herald ischemia/infarction
  - Differentiate from retraction edema
    - Adjacent to surgical clip
    - Not confined to vascular territory
- CTA
  - Screening tool for involvement of large vessels
    - Circle of Willis, M1 segment, basilar artery
  - Attenuation/stenosis of arteries
    - Typically multi-territorial but asymmetric
  - Insensitive for smaller vessels (e.g., M2, distal segments)
- CT perfusion (pCT)
  - Hypoperfusion
    - ↑ time to peak (TTP), ↑ mean transit time (MTT)
    - ↓ cerebral blood flow (CBF)
    - Preservation of cerebral blood volume (CBV) may indicate adequacy of collateral flow
  - May miss distal vasospasm if pCT limited to 2 slices
    - Whole brain pCT recommended

MR Findings

- DWI
  - Most sensitive for vasospasm sequelae
    - If ischemia proceeds to infarction
- MRA
  - Not usually utilized for screening
  - CT more easily performed in patients in ICU S/P SAH
  - Vessel stenosis → signal void on TOF imaging
    - Depends on vasospasm severity

Ultrasonographic Findings

- Transcranial Doppler (TCD)
  - Poiseuille law: ↑ mean flow velocity occurs due to ↓ arterial cross-sectional area from vasospasm/stenosis
  - Low frequency transducer used to evaluate larger arteries at base of brain
  - Transtemporal window absent in 10% patients
  - > 80% accuracy for vasospasm detection if
    - Mean velocity in MCA > 120 cm/s, basilar artery > 70 cm/s
    - Lindegaard ratio (mean MCA velocity to extracranial ICA velocity) > 3
  - Sensitivity ~ 60% (operator dependent)
  - Specificity > 95% (in patients with known SAH)
  - Upward trends in mean velocities may be more indicative of vasospasm than absolute values

Angiographic Findings

- Arterial luminal irregularity/undulations
- Smooth, relatively long-segment stenoses
  - Multiple arteries, > 1 vascular territory typical

DIFFERENTIAL DIAGNOSIS

Meningitis

- Sulcal/cisternal enhancement

Acute Hypertensive Encephalopathy (PRES)

- Posterior > anterior circulation

Reversible Cerebral Vasoconstriction Syndrome (RCVS), Migraine Headaches

- Transient, may look identical

Vasculitis

- Can look identical to vasospasm, RCVS; typically shorter segmental stenoses/"beading" in vasculitis
- Absence of SAH on NECT is typical (SAH secondary to vasculitis is rare)
  - Subacute SAH may be iso-/hypodense on NECT; CSF analysis may help to detect blood breakdown products
- Inflammatory markers in serum, CSF often elevated

Atherosclerosis (ASVD)

- Usually older patients
- Short > long-segment stenoses
- Cavernous/extracranial ICA, vertebral artery often affected

PATHOLOGY

General Features

- Etiology
  - SAH vasospasm most commonly seen after aneurysm rupture
    - Other causes of SAH (e.g., trauma, AVM rupture) may also cause vasospasm
    - Diffuse nonaneurysmal SAH has potential for vasospasm similar to aSAH but < pnSAH
  - Exact pathophysiology is unknown

https://CafePezeshki.IR

- Causation is likely multifactorial
- Coating of vessel walls with blood breakdown products (e.g., oxyHgb) → release of free radicals from vessel wall
- Release of factors, including serotonin, angiotensin, prostaglandins, thromboxane, protein kinase C, phospholipase C and A2
- Possible role of ↓ nitric oxide activity from endothelium, ↑ endothelin-1 activity

Staging, Grading, & Classification

- Fisher CT score corresponds to risk of vasospasm development
  - 1: No SAH
  - 2: Small SAH, < 1 mm vertical layers
  - 3: Extensive SAH, > 1 mm vertical layers
  - 4: Intraventricular hemorrhage (IVH)

Microscopic Features

- Prolonged exposure of vessel wall to blood components → thickening of tunica media, intimal edema, subintimal cellular proliferation with muscle cells and fibroblasts

CLINICAL ISSUES

Presentation

- Most common signs/symptoms
  - Majority of patients with vasospasm are asymptomatic
  - Vasospasm is significant source of morbidity and mortality in patients with SAH
  - Delayed ischemic neurological deficit (DIND) ~ 1 week after SAH is typical
  - Focal neurological deficit(s): Motor, language, vision
- Other signs/symptoms
  - Altered mental status, ↓ level of consciousness

Demographics

- Age
  - Any age; more common in younger patients
- Epidemiology
  - 30,000 people per year have SAH in USA
  - 70% of patients after aneurysmal SAH develop some degree of vasospasm detectable by DSA; only 30% symptomatic

Natural History & Prognosis

- ~ time course of vasospasm following SAH
  - D3-4: Vasospasm begins
  - D7-10: Vasospasm peaks
  - D14-21: Vasospasm subsides
- Hyperacute vasospasm occurs in 10% of patients (onset < 48 hours from SAH)
- Aggressive treatment/prophylaxis in SAH patients can prevent stroke, death from ischemic sequela

Treatment

- Medical management
  - "Triple H" therapy = hypertension, hemodilution, hypervolemia
  - Oral or IV Ca++ antagonists (e.g., nimodipine)
  - Magnesium
- Endovascular
  - Chemical angioplasty: IA infusion of Ca++ antagonist has superseded papaverine
    - Less technically demanding than balloon angioplasty; can treat smaller distal vessels
    - Duration of effect may be up to 24 hours; additional IA treatments may be needed
    - Relatively low-risk: Side effect = hypotension, which could exacerbate hypoperfusion
  - Balloon angioplasty
    - Progressive dilatation of larger basal arteries: Intradural ICA and vertebral arteries, basilar artery, MCA (M1 ± M2 segments), ACA (A1 segment), PCA (P1 segment)
    - 1% risk of fatal vessel rupture, thromboembolic stroke, vessel dissection
  - Intracisternal thrombolytic therapy
    - Several clinical trials have shown moderate success; not widely accepted Rx
    - Recombinant tPA infused via ventriculostomy to lyse blood in subarachnoid spaces → ↓ breakdown to oxyHgb → prevent vasospasm

DIAGNOSTIC CHECKLIST

Consider

- Vasospasm as etiology of clinical deterioration, ischemic changes on NECT 4-14 days after aneurysmal SAH

Image Interpretation Pearls

- TCD is insensitive to changes in vessels beyond intradural ICA, M1, A1, and basilar arteries
  - Should proceed to DSA if involvement of more distal vessels suspected (e.g., pericallosal aneurysm rupture, nonaneurysmal SAH)

SELECTED REFERENCES

1. Bacigaluppi S et al: Diagnosis of cerebral vasospasm and risk of delayed cerebral ischemia related to aneurysmal subarachnoid haemorrhage: an overview of available tools. Neurosurg Rev. ePub, 2015
2. Fontana J et al: Dynamic Autoregulatory Response After Aneurysmal Subarachnoid Hemorrhage and Its Relation to Angiographic Vasospasm and Clinical Outcome. Neurocrit Care. ePub, 2015
3. Hollingworth M et al: Results of an International Survey on the Investigation and Endovascular Management of Cerebral Vasospasm and Delayed Cerebral Ischemia. World Neurosurg. ePub, 2015
4. Walcott BP et al: Diffuse patterns of nonaneurysmal subarachnoid hemorrhage originating from the Basal cisterns have predictable vasospasm rates similar to aneurysmal subarachnoid hemorrhage. J Stroke Cerebrovasc Dis. 24(4):795-801, 2015
5. Jones J et al: Cerebral vasospasm patterns following aneurysmal subarachnoid hemorrhage: an angiographic study comparing coils with clips. J Neurointerv Surg. ePub, 2014
6. Eddleman CS et al: Endovascular options in the treatment of delayed ischemic neurological deficits due to cerebral vasospasm. Neurosurg Focus. 26(3):E6, 2009

https://CafePezeshki.IR

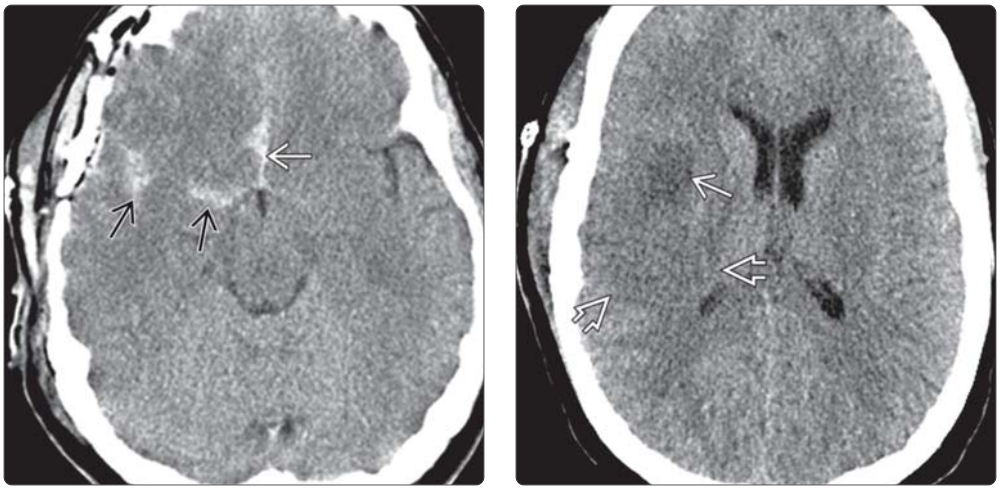

(Left) *Axial NECT in a patient S/P resection of a sphenoidal ridge meningioma complicated by significant intraoperative hemorrhage shows SAH in the right sylvian fissure ⇨ and anterior interhemispheric fissure ➡. (Right) Axial NECT obtained 10 days later when the patient developed hemiparesis shows a focal area of low attenuation in the right frontal lobe ➡, consistent with infarction. There is blurring of both the superficial and deep gray-white interface ➡ adjacent to the infarct.*

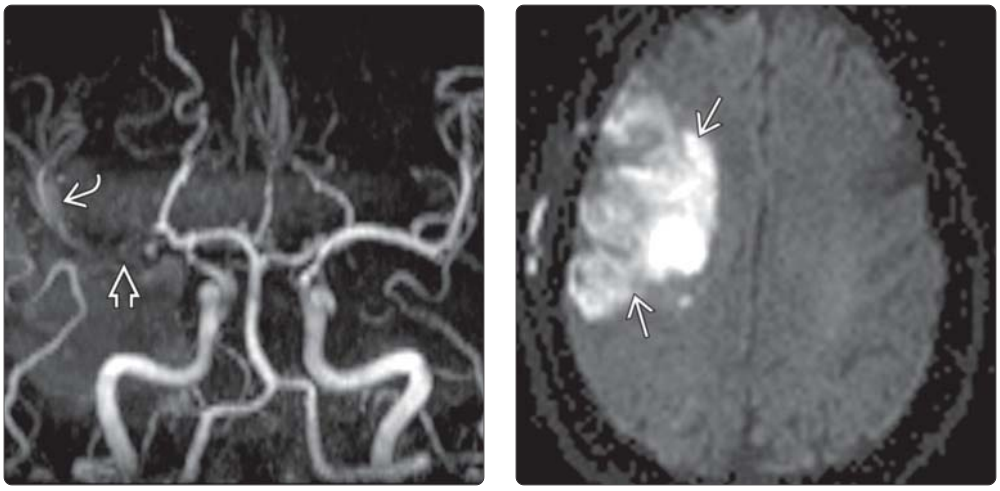

(Left) *Anteroposterior 3D TOF MRA MIP image in the same patient shows no signal from flow-related enhancement along the right M1 segment ➡. The M2 vessels ➡ are attenuated compared with the left side, suggestive of reduced flow.* **(Right)** *Axial DTI MR shows a large area of ischemia/infarction in the right frontal lobe ➡. The constellation of imaging findings along with the delayed clinical deterioration 10 days after documented SAH made vasospasm the most likely etiology.*

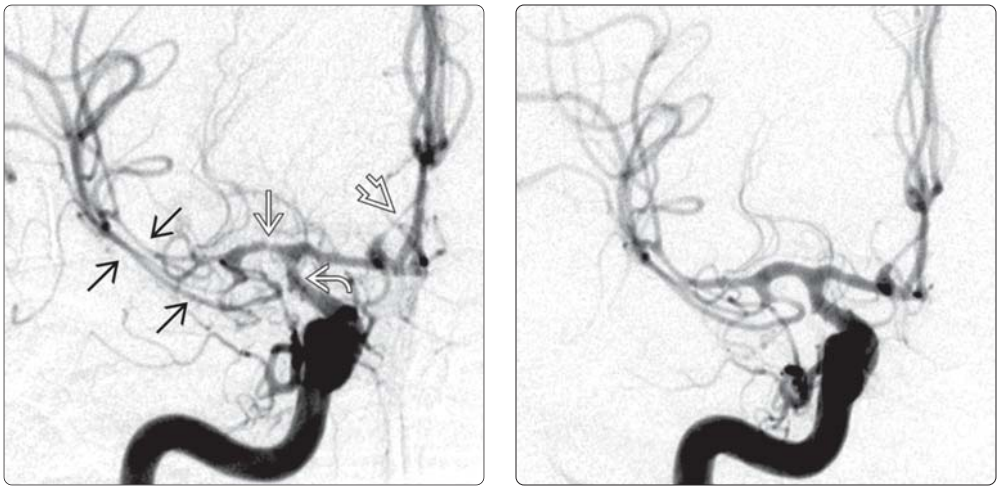

(Left) *AP right ICA DSA confirms the presence of severe vasospasm involving the right M1 ➡ and M2 ⇨ segments, as well as the right A2 segment ➡ and carotid terminus ➡.* **(Right)** *DSA after infusion of 25 mg verapamil into the right ICA shows significant increase in caliber of all vasospastic segments. The patient underwent additional IA verapamil treatments in the ensuing days. Recurrence of vasospasm after chemical angioplasty is to be expected whereas balloon angioplasty is more durable.*

https://CafePezeshki.IR

KEY FACTS

TERMINOLOGY

- Systemic lupus erythematosus (SLE), neuropsychiatric (NPSLE), CNS lupus
- Multisystem autoimmune disorder that affects respiratory, cardiovascular, GI, GU, musculoskeletal systems and CNS
  - CNS involved in up to 75%

IMAGING

- 4 general patterns
  - New infarcts (associated with ↑ anticardiolipin, ↑ lupus anticoagulant antibodies)
  - Focal areas of hyperintensity, primarily in gray matter (GM)
  - Multiple T2WI hyperintensities (microinfarctions)
  - Extensive, reversible white matter (WM) changes (cerebral edema)
- Multifocal WM microinfarcts, cerebral atrophy common
- Mild SLE: PET/SPECT more sensitive than MR
- Restricted diffusion (cytotoxic edema) in ischemia/infarct
- Increased diffusion (vasogenic edema) in vasculopathy
- Acute/active CNS lesions may enhance

TOP DIFFERENTIAL DIAGNOSES

- Multiple sclerosis (MS), Susac syndrome
- Lyme encephalopathy
- Arteriolosclerosis (microvascular disease)
- Other vasculitides (e.g., PACNS)

CLINICAL ISSUES

- Cerebral involvement may precede full-blown SLE picture or may develop during course of disease
- SLE associated with antiphospholipid syndrome (APS), posterior reversible encephalopathy syndrome (PRES), Lupus-related myelitis, Libman-Sacks endocarditis, emboli

DIAGNOSTIC CHECKLIST

- Negative brain MR does not exclude cerebral lupus
- Role of imaging in SLE: Assess acute neurologic deficits

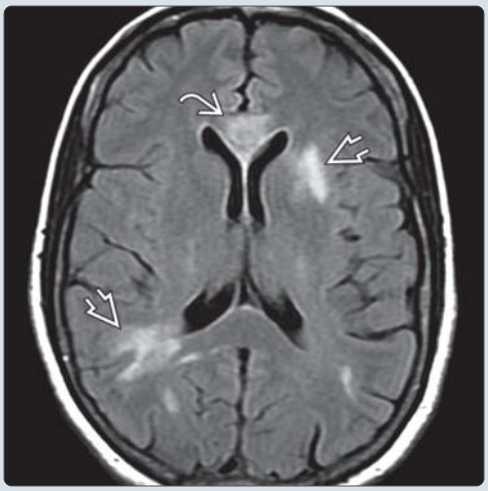

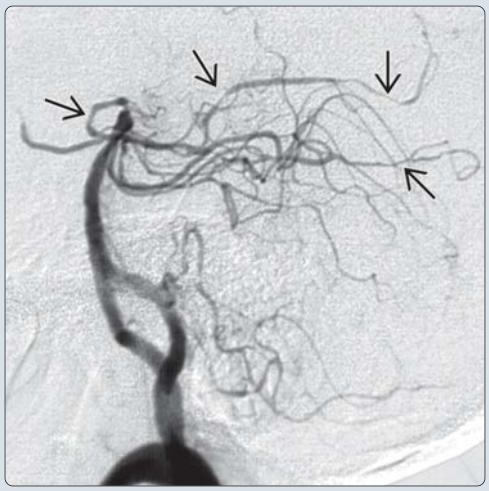

(Left) *Axial FLAIR MR image in an SLE patient with new neurologic symptoms. Note the multiple foci of FLAIR hyperintensity in the white matter ⇨ and the corpus callosum ⇨. This patient also had antiphospholipid syndrome, which is common in SLE patients.* **(Right)** *Lateral vertebrobasilar DSA shows multifocal stenoses ⇨ typical of a nonspecific vasculitis. This is uncommonly seen with lupus, which is more of a small-vessel vasculitis than other inflammatory vasculitides. DSA is often normal in SLE patients.*

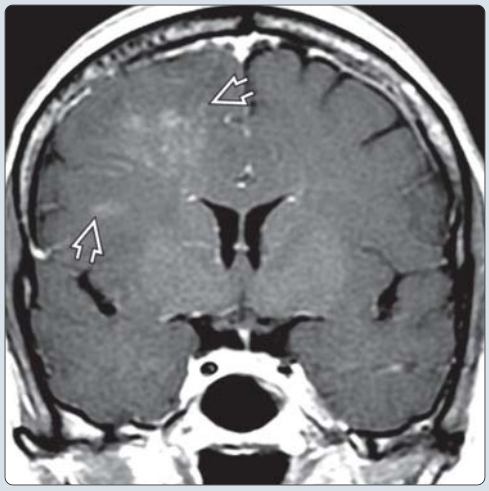

(Left) *Axial FLAIR MR in a 52-year-old female with neuropsychiatric symptoms shows a large hyperintense frontal lobe lesion ⇨.* **(Right)** *Coronal T1 C+ MR image in the same patient shows linear enhancement throughout the frontal lobe ⇨. Biopsy disclosed CNS lupus vasculitis. While imaging of SLE is nonspecific, there are often multiple white matter hyperintensities as well as multifocal infarcts. Migratory edematous regions are also often seen.*

https://CafePezeshki.IR

TERMINOLOGY

Abbreviations

- Systemic lupus erythematosus (SLE), "lupus"
- Neuropsychiatric SLE (NPSLE), CNS SLE

Definitions

- Multisystem autoimmune disorder
  - CNS involved in up to 75% (CNS lupus or NPSLE)

IMAGING

General Features

- Best diagnostic clue
  - Most common finding = small multifocal white matter (WM) lesions
  - Focal infarcts of various sizes
  - Symptomatic "migratory" edematous areas
- Location
  - WM, gray matter (GM)
    - Frontal, parietal subcortical WM most common
- Morphology
  - Rounded or patchy lesions

CT Findings

- NECT
  - May be normal
  - Scattered patchy cortical/subcortical hypodensities common
  - Diffuse atrophy common
  - May see focal infarcts, cerebral calcification
  - May see cerebral edema (lupus cerebritis)
    - Can be life-threatening

MR Findings

- T2WI
  - 4 patterns of involvement
    - Focal infarcts (↑ anticardiolipin, ↑ lupus anticoagulant antibodies)
    - Multiple T2WI hyperintensities (microinfarctions)
    - Focal areas of hyperintensity, primarily in GM
    - Diffuse steroid-responsive subcortical lesions (associated ↑ antineurofilament antibodies)
  - Acute lesions on T2WI suggesting active NPSLE
    - New infarct, discrete GM lesions, diffuse GM hyperintensities, cerebral edema
- FLAIR
  - Multifocal WM hyperintensities
- DWI
  - Restricted diffusion (cytotoxic edema) in ischemia/infarct
  - Increased diffusion (vasogenic edema) in vasculopathy
- T1WI C+
  - Acute/active CNS lesions may enhance
- MRV
  - May show dural venous sinus thrombosis
    - Especially in antiphospholipid syndrome
- MRS
  - ^{1}H-MRS in NPSLE patients
  - ↓ N-acetyl aspartate in lesions, as well as normal-appearing WM/GM
  - ↑ choline related to disease activity, stroke, inflammation, chronic WM disease
  - No ↑ in lactate → anaerobic metabolism is not fundamental characteristic of NPSLE

Angiographic Findings

- CTA/MRA/DSA rarely detects cerebral lupus vasculitis

Nuclear Medicine Findings

- PET
  - Parietooccipital hypometabolism = most conspicuous finding in MR-negative NPSLE
- Tc-99m ethyl cysteinate dimer brain SPECT
  - Sensitive tool for early detection of brain abnormalities in SLE (more sensitive than MR)
  - Relatively nonspecific regional cerebral cortical hypoperfusion
    - Most hypoperfused areas: Parietal, frontal, and temporal lobes (MCA territory)
  - Positive findings also seen in patients without neuropsychiatric signs/symptoms

Imaging Recommendations

- Protocol advice
  - MR with T2, FLAIR, DWI
  - Consider PET in NPSLE if standard MR normal

DIFFERENTIAL DIAGNOSIS

Arteriolosclerosis

- Caused by diabetes, HTN, hypercholesterolemia
- T2WI hyperintense lesions within deep GM (basal ganglia, thalamus), centrum semiovale
- Diffuse, confluent regions of periventricular hyperintense WM involvement (leukoaraiosis)

Multiple Sclerosis (MS)

- Hyperintense T2 WM lesions on T2WI
- Periventricular WM (callososeptal interface)
- SLE lesions not confined to periventricular WM, favor gray-white junction or involve cortex/deep nuclei

Antiphospholipid Antibody Syndrome (Non-SLE)

- Spontaneous fetal loss, thrombocytopenia
- Early stroke, recurrent arterial + venous thromboses
- Infarcts of various sizes and T2 hyperintense WM foci

Lyme Encephalopathy

- Hyperintense periventricular WM lesions on T2WI
- May enhance, resemble MS or ADEM

Susac Syndrome

- Microangiopathy of unknown etiology
- Triad of HA/encephalopathy, branch retinal artery occlusions, hearing loss
- Deep WM, corpus callosum multifocal hyperintense lesions on T2WI, FLAIR
  - Central CC > callososeptal interface
  - May enhance (acute)
  - Central callosal "holes" in subacute/chronic

https://CafePezeshki.IR

Other Vasculitides

- Primary angiitis of CNS, polyarteritis nodosa (PAN), Wegener granulomatosis, Behçet disease, syphilis, Sjögren syndrome

PATHOLOGY

General Features

- Etiology
  - Pathogenesis of NPSLE is likely multifactorial
  - Diffuse neuropsychiatric symptoms
    - Neuronal dysfunction mediated by antibodies: Anti-neuronal, anti-ribosomal P-protein, and anti-cytokines
  - Focal neurologic symptoms
    - Circulating immune complexes → vascular injury
    - Endothelial cell activation by cytokines and complement activation → occlusive vasculopathy
    - Antiphospholipid antibodies (APL-Ab) → macro- and microvascular thrombosis
  - Late stage SLE: Accelerated atherosclerosis
    - ↑ intravascular complement turnover and APL-Ab
- Genetics
  - Genetic predisposition to SLE
    - HLA-DR2, HLA-DR3, null complement alleles
    - Congenital deficiencies of complement (C4, C2)
- Associated abnormalities
  - Lupus-related myelitis (transverse myelitis)
  - Libman-Sacks endocarditis, emboli
  - APS
  - Posterior reversible encephalopathy syndrome (PRES)

Gross Pathologic & Surgical Features

- Cortical atrophy, infarcts, hemorrhage
- Vasculitis → CNS ischemia or hemorrhage (intraparenchymal/subarachnoid)
- Edema → reversible leukoencephalopathy
- WM degeneration, myelin vacuolation of spinal cord

CLINICAL ISSUES

Presentation

- Most common signs/symptoms
  - CNS involvement in up to 75% of cases
    - Migraine, seizures, stroke, chorea
    - Transverse myelopathy, cranial neuropathies, aseptic meningitis
    - Psychosis, mood disorders, acute confusional state, cognitive dysfunction
  - Subclinical CNS disease in SLE: Transient event
- Clinical profile
  - Multisystem autoimmune disorder that affects respiratory, cardiovascular, GI, GU, musculoskeletal systems and CNS
  - Cerebral involvement may precede full-blown SLE picture or may develop during course of disease
    - Most frequently within first 3 years
  - Diffuse psychiatric or focal neurologic symptoms
  - Movement disorders (chorea, parkinsonism)
  - Significant overlap with antiphospholipid antibody syndrome (APS)
    - 25-40% of SLE patients have APS

Demographics

- Age
  - All age groups affected; peak incidence in young adulthood (20-45)
- Gender
  - Strong female predominance (as high as 5:1 during childbearing years)
- Ethnicity
  - High prevalence in African American women
- Epidemiology
  - Incidence of SLE (USA): 14.6-50.8 in 100,000 people
  - CNS lupus affects 30-40% of SLE patients

Natural History & Prognosis

- Neurologic complications worsen prognosis of SLE
  - Transient neurologic deficits, chronic brain injury
- SLE patients with APL-Ab have additional risk for neuropsychiatric events
- Mortality rate in NPSLE: 7-40%

Treatment

- Immunosuppressive agents (steroids, cyclophosphamide) for suspected vasculitis
- Lifelong anticoagulation for APL-Ab-mediated thromboembolic events
- Intrathecal methotrexate plus dexamethasone in severe cases
- Primary prevention of accelerated ASVD and narrowing of blood vessels: Prophylactic aspirin, lipid-lowering drugs

DIAGNOSTIC CHECKLIST

Consider

- Difficult to differentiate active from old NPSLE lesions
- Obtain MR with DWI within 24 hours of neurologic event onset

Image Interpretation Pearls

- Most important role of imaging in NPSLE: Assessment of acute focal (stroke-like) neurologic deficits
  - Lupus-related CNS vasculitis
  - Thromboembolic events due to vasculopathy or endocarditis (Libman-Sacks)
  - APL-Ab-mediated thrombosis
  - Microangiopathy (including thrombotic thrombocytopenic purpura)
  - Accelerated ASVD
- Negative brain MR does not exclude cerebral lupus

SELECTED REFERENCES

1. Saison J et al: Systemic lupus erythematosus-associated acute transverse myelitis: manifestations, treatments, outcomes, and prognostic factors in 20 patients. Lupus. 24(1):74-81, 2015
2. Kaichi Y et al: Brain MR findings in patients with systemic lupus erythematosus with and without antiphospholipid antibody syndrome. AJNR Am J Neuroradiol. 35(1):100-5, 2014
3. Steup-Beekman GM et al: Neuropsychiatric manifestations in patients with systemic lupus erythematosus: epidemiology and radiology pointing to an immune-mediated cause. Ann Rheum Dis. 72 Suppl 2:ii76-9, 2013
4. Curiel R et al: PET/CT imaging in systemic lupus erythematosus. Ann N Y Acad Sci. 1228:71-80, 2011

https://CafePezeshki.IR

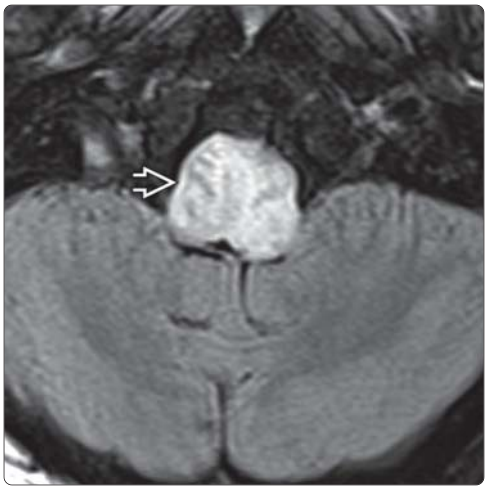

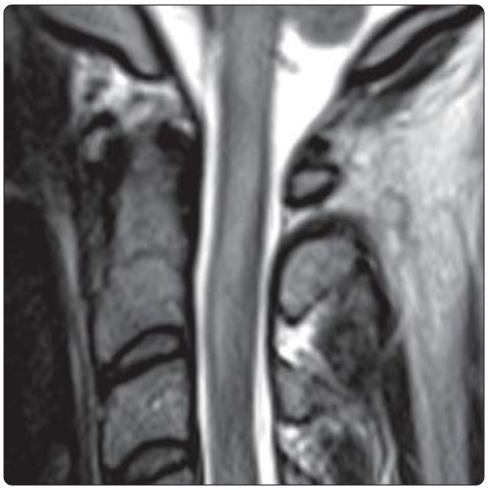

(Left) *Axial FLAIR image in a 32-year-old female with CNS lupus shows marked enlargement and hyperintensity of the medulla ⇨. Following treatment, her symptoms and imaging findings completely resolved.* **(Right)** *Sagittal T2 MR image shows hyperintensity in the cervical spinal cord related to systemic lupus erythematosus (SLE) myelitis, a type of transverse myelitis.*

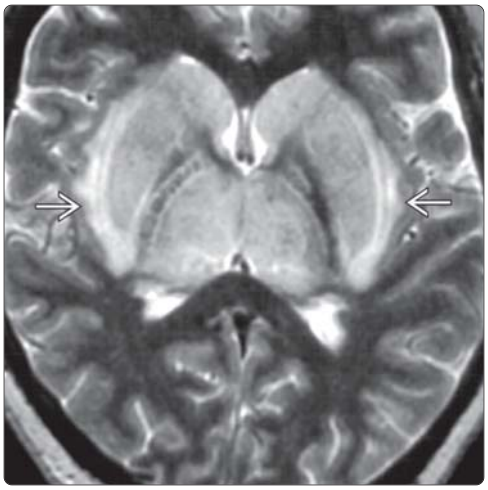

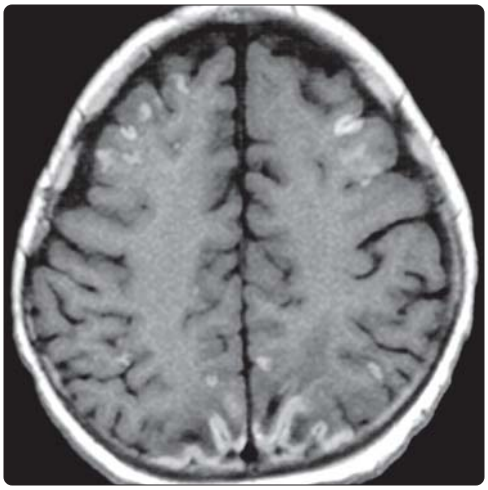

(Left) *Axial T2 MR shows extensive hyperintensity in the basal ganglia, which appear edematous. Note the hyperintensity in the external and extreme capsules ⇨ due to 1 form of NPSLE, probably a neurotoxic response related to antineuronal antibodies.* **(Right)** *Axial T1WI MR shows multifocal areas of gyriform hyperintensity in the occipital cortex, as well as the frontal gray matter near the anterior watershed zone due to PRES, a secondary complication of systemic renal involvement from lupus.*

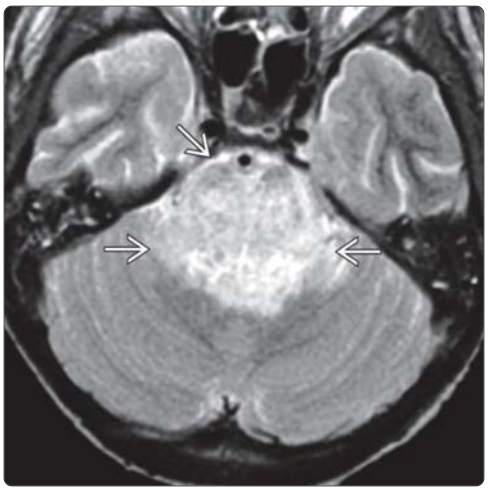

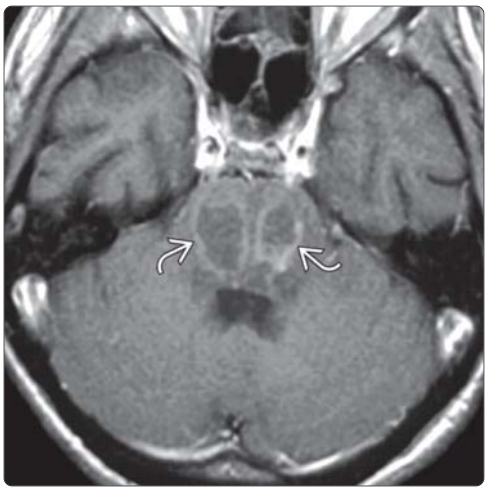

(Left) *Axial T2WI MR shows hyperintensity in the enlarged pons and middle cerebellar peduncles ⇨ in this unusual variant of lupus vasculitis. Although small-vessel vasculitis commonly involves the posterior fossa, it is usually a multifocal peripheral pattern.* **(Right)** *Axial T1WI C+ MR in the same patient shows 2 regions of ring enhancement ⇨ in the central pons due to areas of ischemic necrosis. Lupus vasculitis, which this patient has, is uncommon. Necrotic infarcts in lupus are even less common.*

https://CafePezeshki.IR

KEY FACTS

TERMINOLOGY

- Cerebral amyloid deposition occurs in 3 morphologic varieties
  - Common: Cerebral amyloid angiopathy (CAA)
  - Uncommon: Mass-like lesion ("amyloidoma")
  - Rare: Inflammatory; diffuse (encephalopathic) white matter (WM) involvement

IMAGING

- General findings
  - Normotensive demented patient
  - Lobar hemorrhage(s) of different ages
  - Multifocal "black dots" on T2* or SWI MR
- Protocol advice
  - NECT = best initial screening (for acute hemorrhage)
  - MR with T2* &/or SWI

TOP DIFFERENTIAL DIAGNOSES

- Multifocal "black dots" on T2/T2* MR
  - Hypertensive microhemorrhages
  - Multiple cavernous malformations (type 4)
  - Ischemic stroke with microhemorrhage
  - Diffuse axonal injury
  - Hemorrhagic metastases
  - Posterior reversible encephalopathy syndrome (PRES)

CLINICAL ISSUES

- CAA: Common cause of "spontaneous" lobar hemorrhage in elderly
  - Causes up to 15-20% of primary intracranial hemorrhage (ICH) in patients > 60 years old
  - Stroke-like clinical presentation with "spontaneous" lobar ICH
  - Chronic: Can cause vascular dementia
- CAA common in elderly patients with dementia
  - 2/3 normotensive, 1/3 hypertensive
  - 40% with subacute dementia/overt Alzheimer (overlap common)

(Left) *Axial graphic shows an acute hematoma with a blood-fluid level. Multiple microbleeds and old lobar hemorrhages are also typical findings in cerebral amyloid disease.* **(Right)** *Axial SWI MR in a 70-year-old man with cognitive impairment and acute visual changes shows multiple lobar hemorrhages and microhemorrhages related to cerebral amyloid angiopathy (CAA). SWI and T2* sequences are the most sensitive sequences for identifying microhemorrhages characteristic of CAA.*

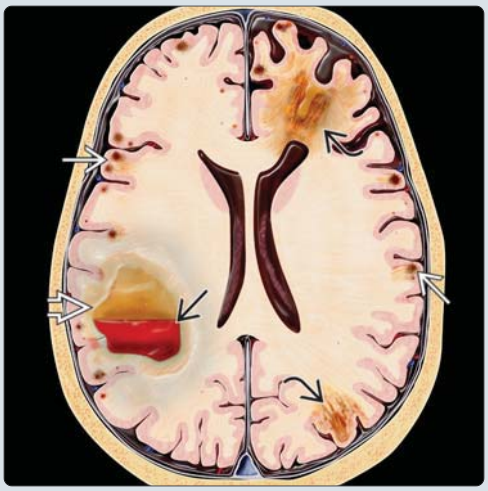

(Left) *Axial CT image in a 72-year-old woman with no history of hypertension shows an acute right occipital lobe hemorrhage.* **(Right)** *Axial GRE MR in the same patient shows multiple foci of susceptibility artifact "blooming" related to microhemorrhages in a typical location for CAA. CAA patients most often present with acute focal neurologic deficits related to the lobar hemorrhage. Patients also present with cognitive impairment related to the microhemorrhages.*

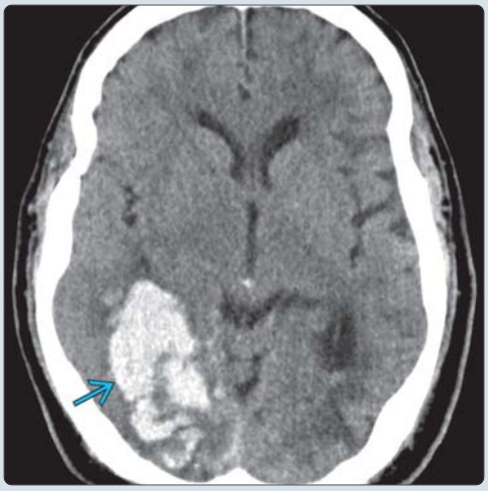

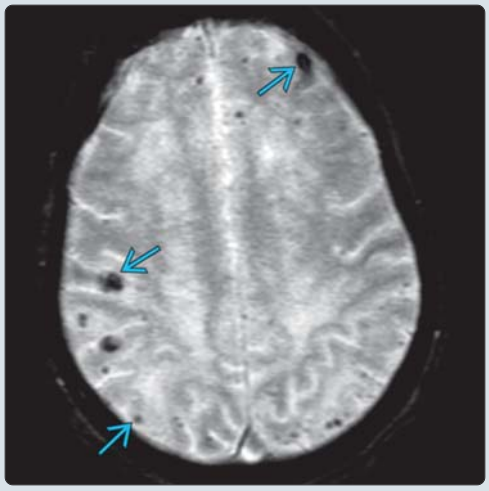

https://CafePezeshki.IR

TERMINOLOGY

Abbreviations

- Cerebral amyloid angiopathy (CAA)

Synonyms

- "Congophilic angiopathy," cerebral amyloidosis

Definitions

- CAA is common cause of "spontaneous" lobar hemorrhage in elderly
- Cerebral amyloid deposition occurs in 3 morphologic varieties
  - CAA (common)
  - Amyloidoma (uncommon)
  - Inflammatory CAA: Amyloid β-related angiitis (ABRA) with diffuse white matter (WM) inflammatory involvement (rare)

IMAGING

General Features

- Best diagnostic clue
  - Normotensive demented patient with
    - Lobar hemorrhage(s) of different ages
    - Multifocal cortical/subcortical microhemorrhages "black dots" on T2*
- Location
  - Cortical/subcortical WM (gray-white junction)
  - Parietal + occipital lobes most common at autopsy; also frontal + temporal on imaging
  - Less common in brainstem, deep gray nuclei, cerebellum, hippocampus
- Size
  - Acute lobar hemorrhage tends to be large
  - Hypointense foci on dark T2*/susceptibility sequences ("blooming") seen with chronic microbleeds, but not specific for CAA
    - Microbleeds and macrobleeds may represent distinct entities in CAA
- Morphology
  - Acute hematomas are large, often irregular, with dependent blood sedimentation

CT Findings

- NECT
  - Patchy or confluent cortical/subcortical hematoma with irregular borders, surrounding edema
  - Hemorrhage may extend to subarachnoid space or into ventricles
  - May present with convexal subarachnoid hemorrhage
  - Rare: Gyriform Ca++
  - Generalized atrophy common

MR Findings

- T1WI
  - Lobar hematoma (signal varies with age of clot)
- T2WI
  - Acute hematoma iso-/hypointense
    - 1/3 have old hemorrhages (lobar, petechial) seen as multifocal punctate "black dots"
  - Focal or patchy/confluent WM disease associated in nearly 70%
  - Rare form: Nonhemorrhagic diffuse inflammatory with confluent WM hyperintensities
    - Acute white matter vasogenic edema may be seen in acute inflammatory forms
      - Can mimic posterior reversible encephalopathy syndrome (PRES) on imaging
    - Asymmetric pattern and multiple microbleeds are suggestive
    - Lack typical PRES predisposing factors (e.g., hypertensive crisis, immunosuppressive drugs)
    - Acute inflammatory CAA = steroid responsive
- T2* GRE
  - Multifocal "black dots"
- T1WI C+
  - CAA, lobar hemorrhages usually do not enhance
  - Amyloidoma (focal, nonhemorrhagic mass[es])
    - Mass effect generally minimal/mild
    - May show moderate/striking enhancement, mimic neoplasm
    - Often extends medially to lateral ventricular wall with fine radial enhancing margins
    - Rare: Patchy, infiltrating
  - Inflammatory (ABRA)
    - May see sulcal/cisternal enhancement
- Susceptibility weighted imaging (SWI)
  - Multifocal hypointensities (microbleeds) similar to T2* GRE, but more sensitive

Nuclear Medicine Findings

- 99m Tc-ECD SPECT: Decreased cerebral perfusion
- PET amyloid imaging agents (carbon 11-labeled Pittsburgh Compound B [11C PiB])
  - Demonstrate Aβ accumulation

Imaging Recommendations

- Best imaging tool
  - NECT = best initial screening study (for acute hemorrhage)
  - MR with T2* or SWI for nonacute evaluation (dementia)

DIFFERENTIAL DIAGNOSIS

Hypertensive Microhemorrhages

- Deep structures (basal ganglia, thalami, cerebellum) > cortex, subcortical WM
- Often coexists with CAA
- Younger patients than CAA (< 65 years old)

Multiple Cavernous Malformations

- Look for "locules" of blood with fluid-fluid levels or multiple ages of hemorrhage
- Often dense on CT due to calcification

Ischemic Stroke With Microhemorrhage

- Multifocal hemosiderin deposits
  - Found in 10-15% of patients with acute ischemic strokes
- Hemorrhagic lacunar infarcts

Other Causes of Multifocal "Black Dots"

- Traumatic diffuse axonal injury
  - History of trauma

https://CafePezeshki.IR

- Location in corpus callosum, subcortical/deep white matter, brainstem
- Hemorrhagic metastases
  - Location similar to CAA (gray-white junction)
  - Variable enhancement, edema
- Metallic microemboli from artificial heart valves
- PRES
  - Associated with acute hypertensive crisis or immunosuppressive therapy in most
  - Symmetric lesions more typical
- CADASIL
  - Usually nonhemorrhagic
  - Most common site = cortical-subcortical (up to 27% in thalami/brainstem)

PATHOLOGY

General Features

- Etiology
  - CAA caused by accumulation of aggregated Aβ in small vessels
  - Amyloidosis = rare systemic disease caused by extracellular deposition of β-amyloid
  - 10-20% of cases are localized form, including CNS
  - Can be primary/idiopathic
  - Can be secondary (associated with dialysis, medullary thyroid cancer, type 2 diabetes)
- Genetics
  - Sporadic (amyloid β-protein type)
    - Most common
    - APOE*E4 allele associated with CAA-related hemorrhage
    - Older patients, ± Alzheimer disease
  - Hereditary cerebral hemorrhage with amyloidosis
    - Autosomal dominant inheritance
    - Amyloid precursor protein encoded by *APP* gene on chromosome 21
    - Types include Dutch, British, Flemish, Italian, etc.
    - More severe and earlier onset than sporadic form

Staging, Grading, & Classification

- WHO classification of amyloidoses
  - Primary systemic amyloidosis
  - Secondary amyloidosis
  - Hereditary systemic amyloidosis
  - Hemodialysis-related systemic amyloidosis
  - Medullary thyroid carcinoma
  - Type 2 diabetes

Gross Pathologic & Surgical Features

- Lobar hemorrhage(s)
- Multiple small cortical hemorrhages

Microscopic Features

- Interstitial, vascular/perivascular deposits of amorphous protein
  - Shows apple-green birefringence when stained with Congo red, viewed under polarized light
  - 3 components
    - Fibrillar protein component (varies/defines amyloidosis type)
    - Serum amyloid P
    - Charged glycosaminoglycans (ubiquitous)
- Microaneurysms, fibrinoid necrosis, hyaline thickening
- 15% have CAA-related perivascular inflammation

CLINICAL ISSUES

Presentation

- Most common signs/symptoms
  - Acute: Stroke-like clinical presentation with "spontaneous" lobar intracranial hemorrhage
  - Chronic: Dementia (CAA)
- Clinical profile
  - CAA common in demented elderly patients
    - 2/3 normotensive, 1/3 hypertensive
    - 40% with subacute dementia/overt Alzheimer (overlap common)

Demographics

- Age
  - Usually older when sporadic (> 60 years old)
  - Inflammatory CAA younger
    - May mimic PRES with acute edema, but steroid responsive
- Gender
  - No gender predilection
- Epidemiology
  - 1% of all strokes
  - Causes up to 15-20% of primary ICH in patients > 60 years old
  - Frequency of CAA in elderly
    - ~ 20-40% of normal elderly (autopsy)
    - ~ 90% in patients with Alzheimer disease
    - Common in Down syndrome

Natural History & Prognosis

- Multiple, recurrent hemorrhages
- Progressive cognitive decline

Treatment

- Evacuate focal hematoma if patient < 75 years old, no intraventricular hemorrhage, not parietal
- Consider immunosuppressive therapy in inflammatory CAA
- Adverse prognostic factors: Low Glasgow coma scale scores, APOE4 allele

DIAGNOSTIC CHECKLIST

Consider

- GRE (T2*) &/or SWI in all elderly

SELECTED REFERENCES

1. Beitzke M et al: Contribution of convexal subarachnoid hemorrhage to disease progression in cerebral amyloid angiopathy. Stroke. ePub, 2015
2. Domingues R et al: Diagnostic evaluation for nontraumatic intracerebral hemorrhage. Neurol Clin. 33(2):315-328, 2015
3. Esiri M et al: Cerebral amyloid angiopathy, subcortical white matter disease and dementia: literature review and study in OPTIMA. Brain Pathol. 25(1):51-62, 2015
4. Yamada M: Cerebral amyloid angiopathy: emerging concepts. J Stroke. 17(1):17-30, 2015
5. Shams S et al: Cerebral microbleeds: different prevalence, topography, and risk factors depending on dementia diagnosis-the Karolinska Imaging Dementia study. AJNR Am J Neuroradiol. ePub, 2014
6. Mittal S et al: Susceptibility-weighted imaging: technical aspects and clinical applications, part 2. AJNR Am J Neuroradiol. 30(2):232-52, 2009

https://CafePezeshki.IR

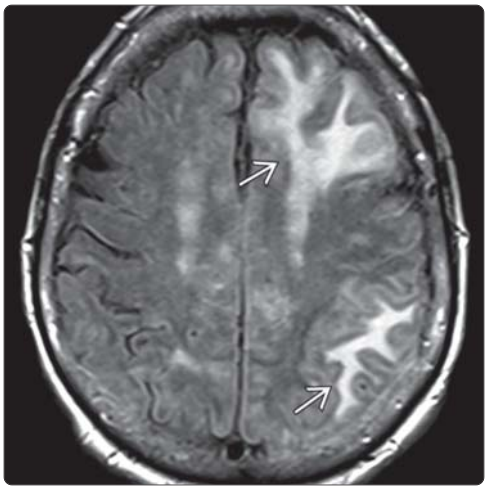

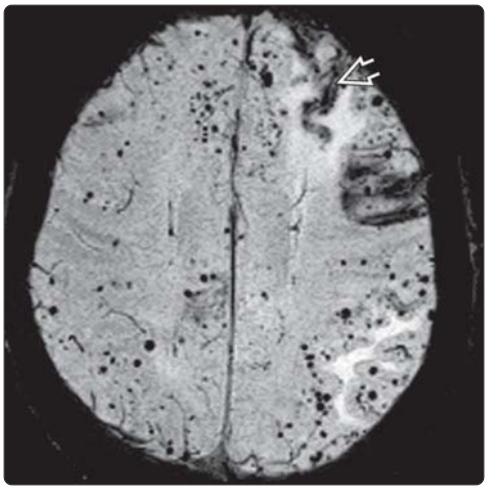

(Left) *Axial FLAIR MR image in an 82-year-old woman with acute onset of neurologic deficits shows hyperintensity in the left frontal and parietal lobes ⇨, not seen on prior imaging.* **(Right)** *Axial SWI image in the same patient shows extensive foci of susceptibility artifact, "blooming" related to microhemorrhages throughout the brain parenchyma typical of CAA. Linear hypointensity ⇨ is related to superficial siderosis. Inflammatory amyloid was diagnosed at biopsy. She responded well to corticosteroid treatment.*

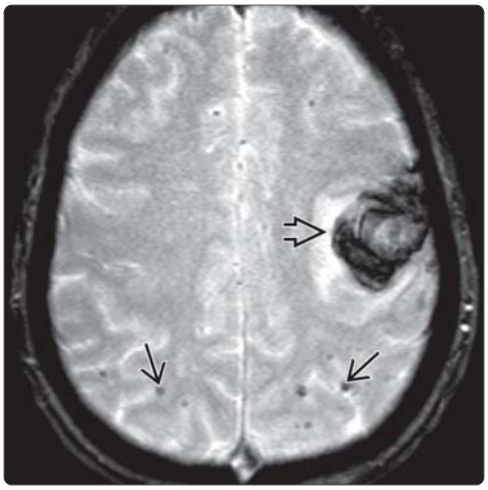

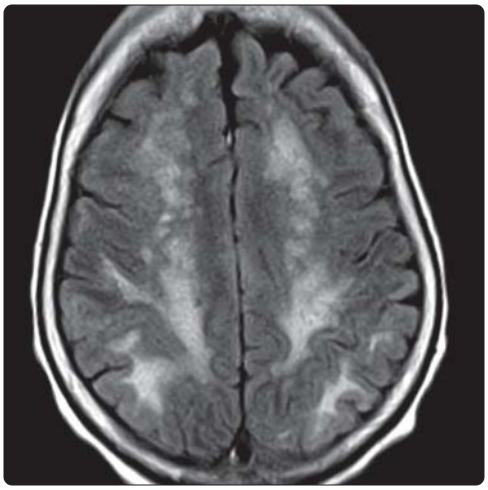

(Left) *Axial T2* GRE shows a left hemispheric lobar hematoma ⇨. Note the multifocal "black dots" ⇨, whose peripheral location is highly suggestive of amyloid angiopathy.* **(Right)** *Axial FLAIR MR image in a 73 year old with CAA shows the typical confluent white matter lesions seen in cerebral amyloid angiopathy and arteriolosclerosis (chronic microvascular ischemia). SWI (not shown) confirmed the multiple microhemorrhages typical of CAA.*

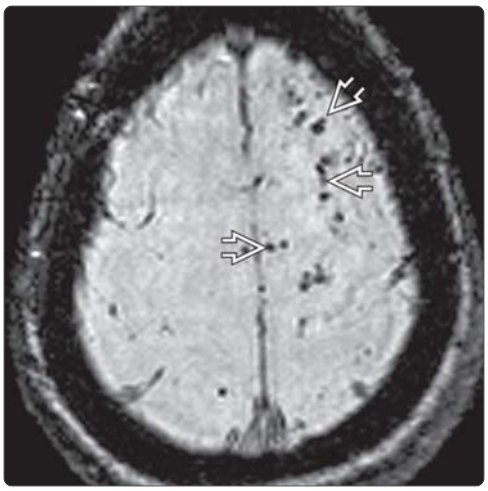

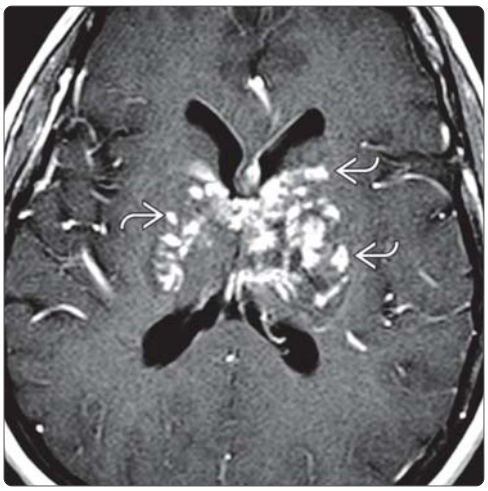

(Left) *Axial SWI shows hypointensities in the cortex and along the pial surfaces ⇨ in this patient with CAA.* **(Right)** *Axial T1 C+ MR shows innumerable small foci of enhancement ⇨ with mild mass effect in the basal ganglia bilaterally and periventricular white matter, following a perivascular distribution. A minority of amyloidosis cases present in this fashion, with "amyloidomas" that mimic neoplastic or possibly atypical infectious/inflammatory etiologies.*

https://CafePezeshki.IR

CADASIL

KEY FACTS

TERMINOLOGY

- Cerebral autosomal dominant arteriopathy with subcortical infarcts and leukoencephalopathy (CADASIL)
- Hereditary small-vessel disease due to mutations in *NOTCH3* gene on chromosome 19, which causes stroke in young to middle-aged adults

IMAGING

- Diffuse white matter (WM) hyperintensities = leukoaraiosis, early finding
- Multiple lacunar infarcts
- Anterior temporal pole, external capsule and paramedian superior frontal lobe highly sensitive and specific locations
- Diffusion restriction in acute lacunar infarcts
- Protocol Advice: MR with T2, FLAIR, and DWI

TOP DIFFERENTIAL DIAGNOSES

- Arteriolosclerosis, MELAS, subcortical arteriosclerotic encephalopathy (SAE), primary angiitis of CNS

PATHOLOGY

- Autosomal dominant disease with mutation in *NOTCH3* results in arteriopathy affecting penetrating cerebral and leptomeningeal arteries

CLINICAL ISSUES

- Most frequent hereditary small-vessel disease of the brain
- TIA/stroke or migraine with aura often initial presentation
- TIA or stroke most common manifestation of disease (60-85% of all patients)
  - Often absence of traditional risk factors
- Migraines, if present, often precede other findings
- Average onset of stroke slightly earlier for men, but not significantly different (M = 50.7, F = 52.5)
- Clinical differential diagnosis includes multiple sclerosis, dementia, and CNS vasculitis
- No specific therapy, supportive therapy to reduce stroke and myocardial infarct risk

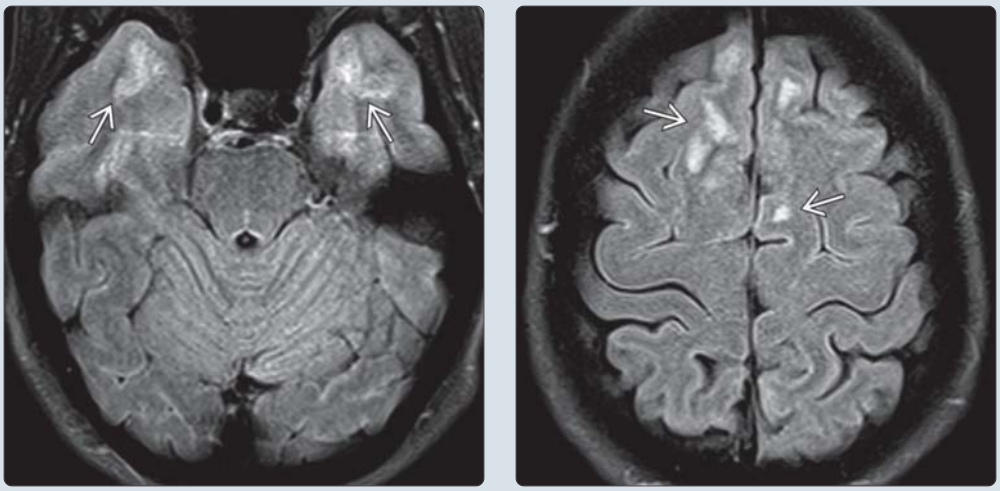

(Left) *Axial FLAIR MR of a young patient with migraines shows focal hyperintensity ➡ in the anterior temporal lobes highly suggestive of CADASIL. NOTCH3 mutation confirmed CADASIL.* **(Right)** *Axial FLAIR MR in the same patient shows additional subcortical hyperintense foci in the paramedian superior frontal lobes ➡, which is a highly sensitive and specific location for lesions in patients with CADASIL, in addition to the anterior temporal lobes and external capsule.*

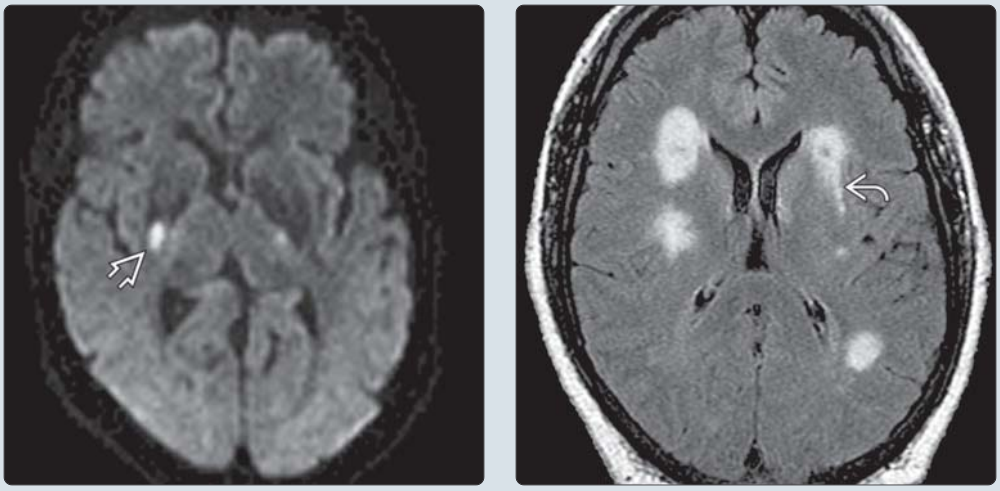

(Left) *Axial DWI trace image in a young adult female with no vascular risk factors shows an acute lacunar ➡ infarct in the right basal ganglia. CADASIL was diagnosed by the presence of a NOTCH3 mutation.* **(Right)** *Axial FLAIR MR shows multiple hyperintense white matter lesions with involvement of the external capsule ➡. External capsule disease location is characteristic for CADASIL and rarely seen with the more common arteriolosclerosis.*

https://CafePezeshki.IR

TERMINOLOGY

Abbreviations

- Cerebral autosomal dominant arteriopathy with subcortical infarcts and leukoencephalopathy (CADASIL)

Definitions

- Hereditary small-vessel disease due to mutations in *NOTCH3* gene on chromosome 19, which causes stroke in young to middle-aged adults

IMAGING

General Features

- Best diagnostic clue
  - Characteristic subcortical lacunar infarcts and leukoencephalopathy in young/middle-aged adults
- Location
  - Anterior temporal lobe, external capsule, paramedian superior frontal lobe highly sensitive and specific
  - Lacunar infarcts in basal ganglia (BG) and subcortical location
    - BG > frontal > parietal > anterior temporal lobes
  - Most common involvement in order of frequency
    - Younger patients: Frontal lobe, parietal lobe, external capsule, anterior temporal lobe
    - Older patients: Additionally posterior temporal and occipital lobes often involved
  - Cerebral cortex is generally spared
- Size
  - Multiple infarcts of various sizes, typically lacunar

CT Findings

- NECT
  - Subcortical and BG hypodense lesions

MR Findings

- T1WI
  - 2 types of lesions
    - Large, coalescent, isointense WM lesions
    - Small, well-delineated, hypointense lesions that spare cortex
  - Loss of contrast between grey matter and white matter in early stages of CADASIL
- T2WI
  - Diffuse white matter hyperintensities (WMHs) = leukoaraiosis, early finding
  - Discrete hyperintense lacunar infarctions
  - Anterior temporal pole and paramedian superior frontal lobe highly sensitive and specific
- FLAIR
  - Discrete hyperintense lacunar infarcts and WMHs
- T2* GRE
  - Microhemorrhages in 25-50% of patients, ↑ with age
- DWI
  - Diffusion restriction in acute lacunar infarcts
- PWI
  - Reduced CBF and CBV in areas of WM signal abnormality without significant MTT changes
    - ↓ CBF may precede WM signal abnormality
  - Decreased hemodynamic reserve after acetazolamide challenge in areas of WM signal abnormality

Angiographic Findings

- Digital subtraction angiogram is normal in CADASIL

Nuclear Medicine Findings

- PET
  - 18F-FDG PET: ↓ cortical and subcortical glucose metabolism

Imaging Recommendations

- Protocol advice
  - MR with T2, FLAIR, and DWI

DIFFERENTIAL DIAGNOSIS

Arteriolosclerosis

- Older patients, typically > 50 years
- Periventricular and deep WM T2/FLAIR hyperintensities
- Cerebrovascular risk factors: Hypertension, hypercholesterolemia, diabetes

MELAS

- **M**itochondrial **e**ncephalomyopathy with **l**actic **a**cidosis and **s**troke-like episodes
- Younger age, mean age onset 15 years
- Bilateral, multifocal, cortical, and subcortical FLAIR hyperintense lesions
- Normal to increased ADC values within 48 hours of neurological deficit of abrupt onset should raise possibility of MELAS, especially if conventional MR images show infarct-like lesions
- Lesions disappear with clinical improvement, and ADC returns to normal (tissue recovery)

Subcortical Arteriosclerotic Encephalopathy (SAE)

- Type of vascular dementia, associated with hypertension
- Multiple lacunar infarcts in lenticular nuclei, pons, thalamus, internal capsule, and caudate nuclei
- Diffuse, confluent periventricular WM involvement

Primary Angiitis of CNS

- Lumen irregularities in distal cerebral arteries on digital subtraction angiogram

Hypercoagulable States

- Antiphospholipid antibodies, protein S deficiency
  - Stroke in young and middle-aged adults, with high rate of recurrence
- "Antiphospholipid syndrome": Early stroke, recurrent arterial and venous thromboses, spontaneous fetal loss, thrombocytopenia
- Cortical and lacunar infarcts of various sizes
- T2 WMHs, dural sinus thrombosis
- Abnormal angiogram: Vasculitis-like findings and stenoses at origin of great vessels

PATHOLOGY

General Features

- Etiology
  - Autosomal dominant disease with mutation in *NOTCH3* results in arteriopathy affecting penetrating cerebral and leptomeningeal arteries

https://CafePezeshki.IR

- Narrowed lumen of affected vessels results in ↓ CBF and metabolism
  - In CADASIL patients with minor WMHs, cerebral vasodilatory capacity preserved but ↓ total CBF
- Genetics
  - Point mutations in *NOTCH3* gene on chromosome 19p13 with autosomal dominant transmission
    - *NOTCH3* codes for large transmembrane receptor physiologically expressed in vascular smooth muscle cell
    - Extracellular domain has 34 epidermal growth factor repeats (EGFR) with 6 cysteine residues
    - More than 150 CADASIL mutations are described
      - Mutations result in odd number of cysteine residues on affected EGFR
  - De novo mutations have been reported
- Associated abnormalities
  - Small vessels of other organs (skin, muscle, liver, spleen) affected, but clinical manifestations are predominantly cerebral

Gross Pathologic & Surgical Features

- Features characteristic of chronic small artery disease
  - Diffuse myelin pallor; periventricular and centrum semiovale WM rarefaction
  - WM and BG lacunar infarcts
  - Dilated perivascular spaces
  - Macroscopic appearance of cortex shows atrophy

Microscopic Features

- Specific arteriopathy of small penetrating cerebral and leptomeningeal arteries characterized by
  - Arterial wall thickening (→ luminal stenosis) with normal endothelium
  - Nonamyloid extracellular granular osmiophilic deposits in media extending into adventitia
  - Morphologically altered smooth muscle cells, which can disappear from vessel wall
- Widespread cortical apoptosis, especially of layer 3 and 5

CLINICAL ISSUES

Presentation

- Most common signs/symptoms
  - TIA/stroke or migraine with aura often initial presentation
  - TIA or stroke most common manifestation of disease (60-85% of all patients)
    - Average age of onset: 41-49 years, range: 20-58 years
    - Often absence of traditional risk factors
    - Most have recurrent strokes
    - Often recurrent lacunar strokes
  - Migraine with aura (often atypical) (20-40%)
    - When present often 1st manifestation at younger age than TIA/stroke
    - Average age 25-30 years, with earlier onset in women (1-10 years earlier than men)
  - Cognitive deficits common, increase with age
    - Almost 90% have executive dysfunction, often associated with changes in memory and attention
  - Behavioral disturbances common (75%)
    - Depression (46%), disturbed sleep (45%), irritability/lability (43%), apathy (41%)
  - Seizures (5-10%); may be related to stroke rather than primary manifestation of CADASIL
- Clinical profile
  - Large variations in clinical presentation
  - Young or middle-aged patient often 1st presenting with migraines with aura or TIA/stroke

Demographics

- Age
  - Onset of ischemic symptoms in mid-adulthood
    - MR changes appear at average age of 30 years and precede stroke/TIA by 10-15 years
    - Migraines, if present, often precede other findings
- Gender
  - No gender preference, but prognosis/life expectancy different for females and males
- Epidemiology
  - Prevalence is unknown
    - Over 500 families described worldwide
    - Small study in Scotland found minimum prevalence of 1.98/100,000
      - Predicted prevalence of about 4/100,000
      - Likely underestimates true prevalence due to variety of factors
  - Most frequent hereditary brain small-vessel disease

Natural History & Prognosis

- Average age of stroke onset slightly earlier for men but not significantly different (M = 50.7, F = 52.5 years)
- Disease progression typically more rapid in men with earlier death

Treatment

- No specific therapy for CADASIL, supportive care

DIAGNOSTIC CHECKLIST

Consider

- Awareness of clinical and radiological features of CADASIL in young and middle-aged adults allows early diagnosis
- Consider CADASIL in acute unexplained encephalopathy

Image Interpretation Pearls

- Imaging hallmark: Subcortical WMHs and lacunar infarcts
- Characteristic WMHs seen on MR often before onset of symptoms
- Temporal WM involvement suggests CADASIL in a young adult

SELECTED REFERENCES

1. Ayrignac X et al: Adult-onset genetic leukoencephalopathies: A MRI pattern-based approach in a comprehensive study of 154 patients. Brain. 138(Pt 2):284-92, 2015
2. Bianchi S et al: CADASIL in central Italy: a retrospective clinical and genetic study in 229 patients. J Neurol. 262(1):134-41, 2015
3. De Guio F et al: White matter edema at the early stage of cerebral autosomal-dominant arteriopathy with subcortical infarcts and leukoencephalopathy. Stroke. 46(1):258-61, 2015
4. Chabriat H et al: Cadasil. Lancet Neurol. 8(7):643-53, 2009

https://CafePezeshki.IR

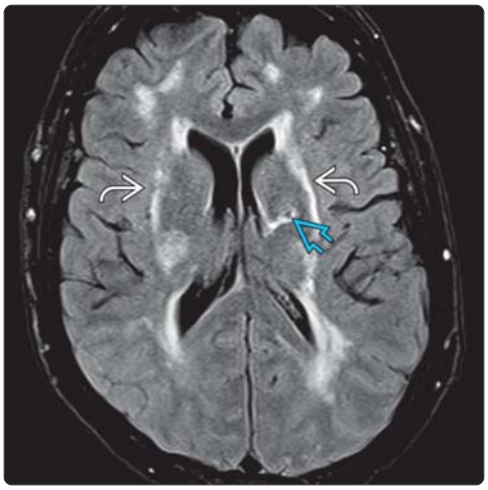

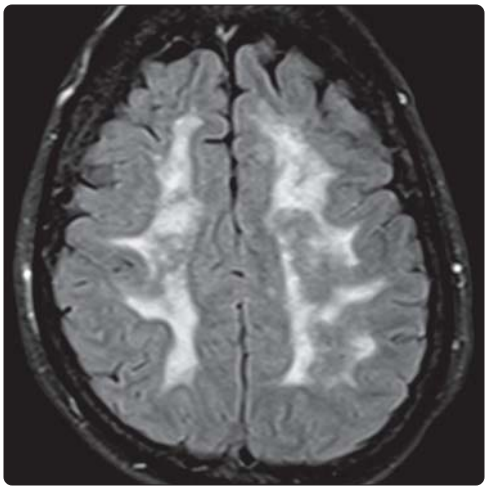

(Left) *Axial FLAIR MR in a 40-year-old female with CADASIL shows extensive white matter hyperintensities with involvement of the external capsules* ➡ *as well as a chronic left basal ganglia lacunar infarct* ⇨. **(Right)** *Axial FLAIR MR in the same patient shows diffuse white matter disease. Diffuse white matter disease with associated lacunar infarcts should raise suspicion for CADASIL in a young patient.*

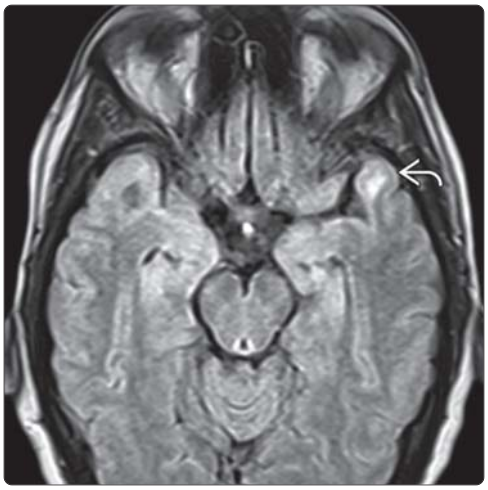

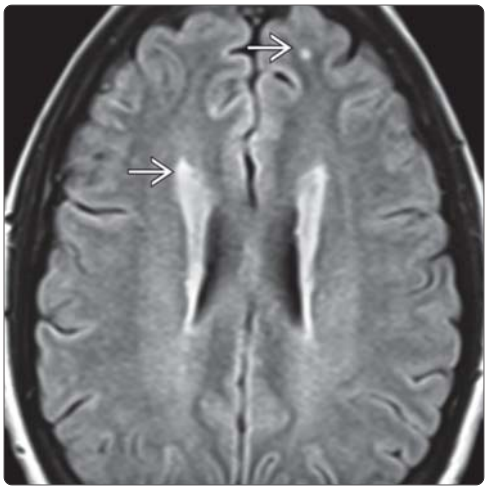

(Left) *Axial FLAIR MR through the temporal lobes shows focal subcortical white matter hyperintensities* ➡, *very early changes in a 31-year-old patient with genetically proven CADASIL and migraines with visual auras as the only symptom.* **(Right)** *Axial FLAIR MR in the same patient shows nonspecific hyperintensities* ➡ *in the frontal and periventricular white matter. These white matter lesions are often seen before the onset of symptoms.*

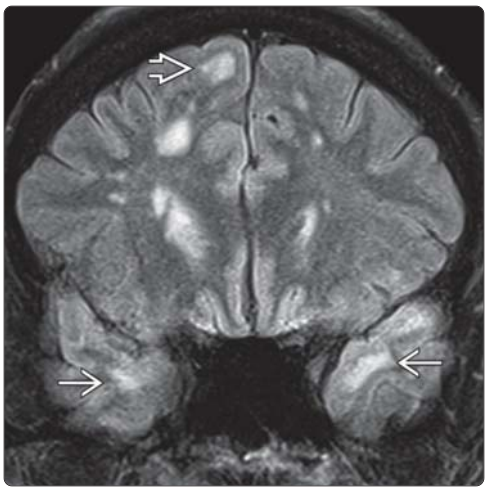

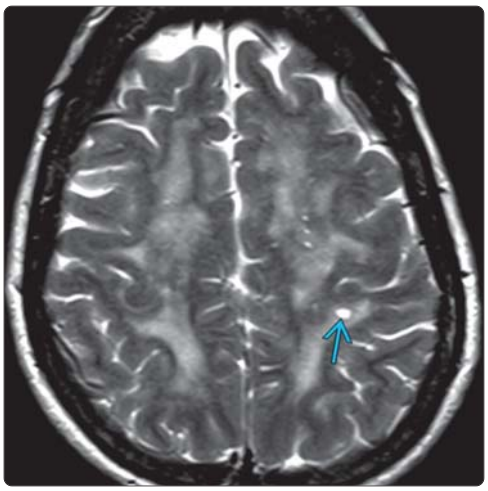

(Left) *Coronal FLAIR image shows multiple hyperintense white matter lesions in the anterior temporal lobes* ➡, *frontal lobes* ⇨ *and periventricular location in this 38-year-old male with CADASIL. This disease affects the smooth muscle cells in penetrating cerebral and leptomeningeal arteries.* **(Right)** *Axial T2 MR in a patient with CADASIL shows extensive confluent white matter disease as well as a chronic lacunar infarct* ⇨. *CADASIL is the most common hereditary small vessel disease of the brain.*

https://CafePezeshki.IR

KEY FACTS

TERMINOLOGY

- Chronic, idiopathic relapsing-remitting multisystem vascular-inflammatory disease characterized by recurrent orogenital ulcerations and uveitis
  - CNS involved in up to 20-25% of patients

IMAGING

- Best diagnostic clue: T2 hyperintense brainstem lesion in patient with oral and genital ulcers
  - Midbrain > pons > basal ganglia (BG) > thalami > white matter
  - Focal or multifocal lesions
  - May see expansion of involved structures acutely
- T2WI: Hyperintense lesions
- T1WI C+: Patchy enhancement typical
- ↓ NAA in acute lesions
  - NAA may normalize when lesions resolve
- May see atrophy of involved structures chronically

TOP DIFFERENTIAL DIAGNOSES

- Gliomatosis cerebri
- ADEM
- Primary CNS lymphoma
- Vasculitis
- Multiple sclerosis

CLINICAL ISSUES

- Neurologic deficit (hemiparesis), headache, seizure common presenting features
- Young adults, median age: 40 years

DIAGNOSTIC CHECKLIST

- Consider Behçet disease in young adult with brainstem or deep gray nucleus lesion
- Enhancement pattern may help differentiate Behçet disease from other etiologies

(Left) *Axial FLAIR MR image shows abnormal hyperintensity and mild expansion of the left ventral midbrain ➡ and patchy hyperintensity in the right midbrain ➡ in this 35-year-old man with neuro-Behçet disease. This chronic, relapsing idiopathic multisystem vascular-inflammatory disease is also characterized by oral and genital ulcers.* **(Right)** *Axial T1 C+ MR image in the same patient shows enhancement of the large midbrain lesion ⇨. Imaging typically mimics neoplasm, vasculitis, and demyelination.*

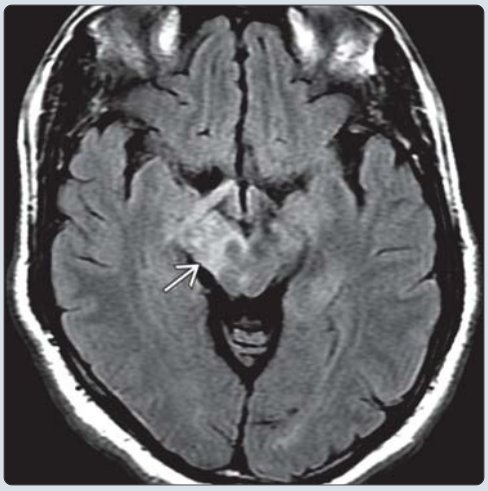

(Left) *Axial FLAIR MR image in the same patient 2 years later shows resolution of the left midbrain lesion and development of a large right midbrain lesion ➡ involving the cerebral peduncle. A relapsing-remitting clinical course is typical.* **(Right)** *Axial T2WI MR shows hyperintensity in the pons with mild expansion ➡ in a young man with oral ulcers and a clinical diagnosis of Behçet disease. Other lesions were present in the midbrain and basal ganglia. Thalamic and white matter involvement is less common in this disease.*

https://CafePezeshki.IR

TERMINOLOGY

Synonyms

- Neuro-Behçet disease

Definitions

- Chronic, idiopathic relapsing-remitting multisystem vascular-inflammatory disease characterized by recurrent orogenital ulcerations and uveitis
  - CNS involved in up to 20-25% of patients

IMAGING

General Features

- Best diagnostic clue
  - T2-hyperintense brainstem lesion in young adult with oral and genital ulcers
- Location
  - Brainstem is most common location
    - Ventral midbrain (cerebral peduncles) and pons typically involved
  - Basal ganglia (BG) commonly involved
  - May involve thalami and white matter (WM)
  - Rarely affects spinal cord, mesial temporal lobes
  - Additional nonparenchymal form with vessel involvement: Sinus thrombosis > > arterial occlusion, aneurysm
- Size
  - Variable
- Morphology
  - May enlarge involved structures acutely
  - Focal or multifocal lesions

Imaging Recommendations

- Best imaging tool
  - Contrast-enhanced MR

CT Findings

- NECT: Often normal
  - May see subtle hypointense lesions

MR Findings

- T1WI: Isointense or hypointense lesions
- T2WI: Hyperintense lesions
  - May see expansion of involved structures
- FLAIR: Hyperintense lesions
- DWI: Variable; acute lesion may show restriction
- T1 C+: Patchy enhancement common
- MRS: ↓ NAA in acute lesions

DIFFERENTIAL DIAGNOSIS

Gliomatosis Cerebri

- T2 hyperintense mass with enlargement of involved structures
- Typically no enhancement

ADEM

- T2 hyperintense lesions in subcortical WM and deep gray nuclei after viral prodrome or vaccination
- Brainstem involvement uncommon

Primary CNS Lymphoma

- Enhancing lesions typically abut ependymal surfaces
- Often T2 hypointense, DWI positive

Vasculitis

- T2 hyperintense lesions, often supratentorial
- Diffusion restriction acutely
- Variable enhancement

Multiple Sclerosis

- Callososeptal interface lesions most common
- Ventral brainstem lesions less common

PATHOLOGY

General Features

- Etiology
  - Multisystem, vascular-inflammatory disease of unknown origin
- Associated abnormalities
  - Patients with CNS disease typically have orogenital ulcerations and uveitis

Microscopic Features

- Perivascular infiltration with inflammatory cells ± signs of necrosis

CLINICAL ISSUES

Presentation

- Most common signs/symptoms
  - Neurologic deficit (hemiparesis), headache, seizure
  - Neurologic involvement typically months to years after systemic disease (Initial presentation in 5%)
- Clinical profile
  - CSF studies: Pleocytosis and ↑ protein levels

Demographics

- Age
  - Young adults typically, 20-40 years; also reported in children
- Gender
  - M > F in neuro-Behçet
- Epidemiology
  - 5-25% of patients have CNS involvement

Treatment

- Corticosteroids and immunosuppressive therapy

DIAGNOSTIC CHECKLIST

Consider

- Behçet disease in young adult with brainstem or deep gray nucleus lesion

SELECTED REFERENCES

1. Miller JJ et al: Neuro-behçet disease and autoinflammatory disorders. Semin Neurol. 34(4):437-43, 2014
2. Noel N et al: Long-term outcome of neuro-Behçet's disease. Arthritis Rheumatol. 66(5):1306-14, 2014
3. Farahangiz S et al: Magnetic resonance imaging findings and outcome of neuro-Behçet's disease: the predictive factors. Int J Rheum Dis. 15(6):e142-9, 2012

https://CafePezeshki.IR

KEY FACTS

TERMINOLOGY

- Microangiopathy of brain, retina, and cochlea

IMAGING

- T2 hyperintense corpus callosum (CC) lesions in patient with clinical triad
  - Encephalopathy, bilateral hearing loss, and branch retinal artery occlusions
- Multifocal T2 hyperintensities similar to MS
  - More often round, mid-callosal rather than callososeptal location
- May involve brainstem, basal ganglia, thalamus, subcortical white matter, centrum semiovale
- Lesions may show acute diffusion restriction
- Variable enhancement of lesions and leptomeninges

TOP DIFFERENTIAL DIAGNOSES

- Multiple sclerosis
- ADEM
- Systemic lupus erythematosus
- Vasculitis

PATHOLOGY

- Microinfarctions in cerebral cortex that are generally not seen on imaging
- No demyelination seen on pathology

CLINICAL ISSUES

- 20-40 years old
- Usually self-limited (2-4 years) but may lead to permanent deafness or blindness

DIAGNOSTIC CHECKLIST

- Most patients do not exhibit entire triad (up to 97% at time of presentation)
- Complete triad seen after 2 weeks or after 2 years
- Consider Susac syndrome in patients with corpus callosum lesions and clinical triad

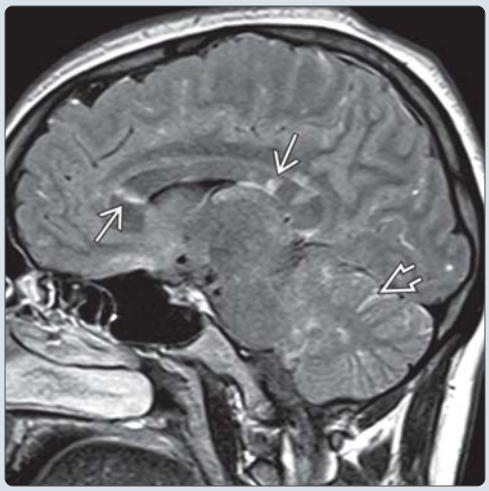

(Left) *Axial FLAIR MR image shows multiple hyperintensities ⇨ in corpus callosum of this 27-year-old female patient with Susac syndrome who presented with headache and confusion. The classic clinical triad includes encephalopathy, bilateral hearing loss, & branch retinal artery occlusions.* **(Right)** *Sagittal FLAIR C+ MR image (same patient) shows classic involvement ⇨ of corpus callosum body with hyperintense lesions. Note leptomeningeal enhancement ⇨, which may be seen in up to 50% of patients.*

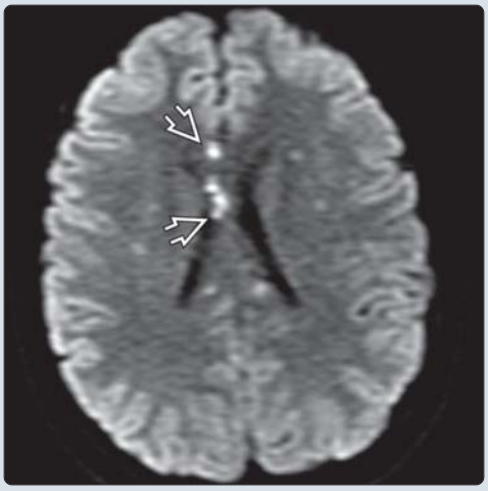

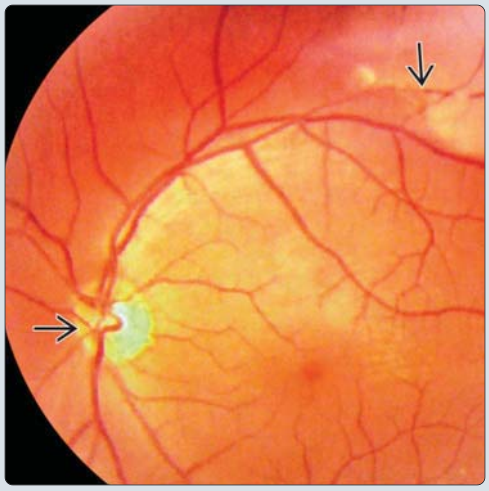

(Left) *Axial DWI trace image shows multiple hyperintense lesions ⇨, many of which had corresponding low ADC values representing true diffusion restriction. Acute lesions may mimic vasculitis.* **(Right)** *Funduscopic examination shows multiple retinal artery branch occlusions and irregularities ⇨, classic for Susac syndrome. Susac syndrome is often mistaken for multiple sclerosis on imaging studies. Its etiology is uncertain but most likely represents an autoimmune microangiopathy, not a demyelinating disorder.*

https://CafePezeshki.IR

TERMINOLOGY

Synonyms

- Retinocochleocerebral vasculopathy, formerly known as small infarctions of cochlear, retinal, and encephalic tissue (SICRET syndrome)

Definitions

- Microangiopathy of brain, retina, and cochlea

IMAGING

General Features

- Best diagnostic clue
  - T2 hyperintense corpus callosum (CC) lesions in patient with clinical triad
  - Encephalopathy, bilateral hearing loss, and branch retinal artery occlusions
- Location
  - Body and splenium of CC, middle layers, classically
  - May involve brainstem, basal ganglia (BG), thalamus, subcortical white matter (WM), centrum semiovale

Imaging Recommendations

- Best imaging tool
  - Contrast-enhanced MR

CT Findings

- NECT
  - Often normal
  - May exclude other causes of hearing loss, encephalopathy

MR Findings

- T2WI
  - Multifocal T2 hyperintensities similar to those seen in multiple sclerosis (MS)
    - More often round, mid-callosal rather than located at callososeptal interface
  - May see lesions in brainstem, BG, thalamus, subcortical WM, centrum semiovale
- FLAIR
  - Round, punched-out, hyperintense callosal lesions
- DWI
  - Callosal lesions may show diffusion restriction acutely (microinfarcts)
- T1WI C+
  - Variable enhancement of WM lesions
  - Variable leptomeningeal enhancement
- DTI: Decreased fractional anisotropy (FA) in WM tracts, particularly CC

DIFFERENTIAL DIAGNOSIS

Multiple Sclerosis

- Most common misdiagnosis, with similar appearance of callosal WM lesions
- Typically periventricular and callososeptal interface location

ADEM

- Viral prodrome or post vaccination, monophasic
- T2 hyperintense lesions in BG and WM

Systemic Lupus Erythematosus

- Multifocal WM T2 hyperintensities, vasculitic features

Vasculitis

- DWI +, FLAIR hyperintense lesions
- Does not involve the corpus callosum

PATHOLOGY

Microscopic Features

- No demyelination seen on pathology
- Normal axon density, reactive glial changes
- Microinfarctions in cerebral cortex, generally not seen on imaging

CLINICAL ISSUES

Presentation

- Most common signs/symptoms
  - Bilateral hearing loss (cochlear)
    - May be unilateral or asymmetric
    - May be associated with tinnitus, vertigo, unsteady gait, nausea, vomiting, and nystagmus
  - Encephalopathy (headaches most common, often severe or migrainous)
  - Branch retinal artery occlusions
- Other signs/symptoms
  - Memory impairment, confusion, behavioral disturbances, ataxia, dysarthria, paranoid psychosis, occasional mutism
  - CSF: High protein and lymphocytic pleocytosis
- Clinical differential diagnosis: Migraine headaches, Ménière disease (bilateral sensorineural hearing loss)

Demographics

- Age: 20-40 years old
- Gender: F >>> M

Natural History & Prognosis

- Usually self-limited (2-4 years) but may lead to permanent deafness or blindness

Treatment

- Immunosuppressants and antithrombotics

DIAGNOSTIC CHECKLIST

Consider

- Most patients do not exhibit entire triad (up to 97% at time of presentation)
- Complete triad may be seen after 2 weeks or after 2 years

Image Interpretation Pearls

- Consider Susac syndrome in patients with corpus callosum lesions and clinical triad

SELECTED REFERENCES

1. Greco A et al: Susac's syndrome--pathogenesis, clinical variants and treatment approaches. Autoimmun Rev. 13(8):814-21, 2014
2. Dörr J et al: Characteristics of Susac syndrome: a review of all reported cases. Nat Rev Neurol. 9(6):307-16, 2013
3. Mateen FJ et al: Susac syndrome: clinical characteristics and treatment in 29 new cases. Eur J Neurol. 19(6):800-11, 2012
4. Do TH et al: Susac syndrome: report of four cases and review of the literature. AJNR Am J Neuroradiol. 25(3):382-8, 2004

https://CafePezeshki.IR

KEY FACTS

TERMINOLOGY

- Fibromuscular dysplasia (FMD)
  - Arterial disease of unknown etiology
  - Overgrowth of smooth muscle, fibrous tissue
  - Affects medium/large arteries

IMAGING

- Renal artery is most common overall site (~ 75%)
- Cervicocranial FMD (~ 70%)
  - ICA (30-50%) > ECA > vertebral arteries (10-20%)
  - Carotid bifurcation is typically spared
  - > 50% of cases are bilateral
  - Intracranial rare (supraclinoid ICA, MCA)
- CTA
  - Arterial luminal irregularity or "beading" ± stenosis or aneurysm (rare)
- DWI-MR
  - Most sensitive for ischemic sequela of FMD
- DSA
  - Type 1 (85%): Classic "string of beads" = medial fibroplasia
  - Type 2 (10%): Long, tubular stenosis = intimal fibroplasia
  - Type 3 (5%): Asymmetric outpouching from 1 side of artery = periadventitial fibroplasia

TOP DIFFERENTIAL DIAGNOSES

- Atherosclerosis
- Standing waves
- Nonatherosclerotic vasculopathies

CLINICAL ISSUES

- Symptoms: HTN, stroke, dissection
- Treatment
  - Antiplatelet ± anticoagulant Rx to reduce risk of thromboembolic sequela (stroke)
  - Balloon angioplasty
  - Covered stent, arterial reconstruction for aneurysm

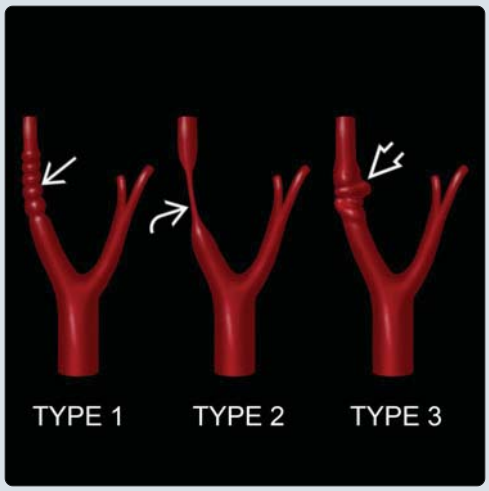

(Left) *Sagittal CTA shows a classic appearance of FMD in a 40-year-old female following trauma. There is type I FMD in the cervical carotid artery with alternating areas of constriction and dilatation. C1-C2 is the most common location. Note the typical sparing of the carotid bulb.* **(Right)** *Carotid bifurcation graphic shows the principal subtypes of FMD. Type 1 appears as alternating areas of constriction and dilatation, type 2 as tubular stenosis, and type 3 as focal corrugations ± a diverticulum.*

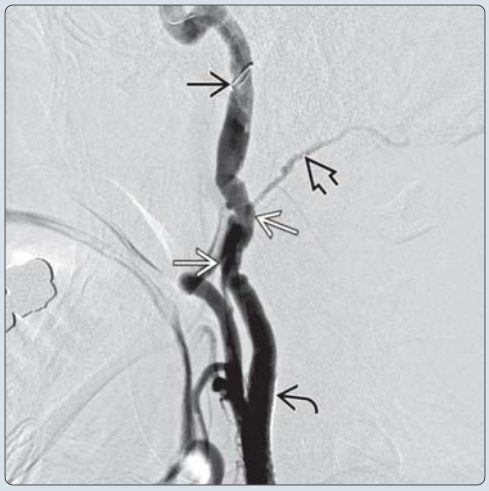

(Left) *Oblique DSA of the left carotid artery shows ASVD stenosis of the carotid bulb. Note the mural calcification seen as faint subtraction artifact. Superiorly, the ICA shows luminal irregularity and beading, consistent with FMD. Additional FMD involvement of an ECA branch is evident.* **(Right)** *Lateral DSA after carotid stenting across the ASVD stenosis shows a distal protection device in situ. Note the irregularity of the ICA and occipital artery due to FMD.*

https://CafePezeshki.IR

TERMINOLOGY

Abbreviations

- Fibromuscular dysplasia (FMD)

Definitions

- Arterial disease of unknown etiology
  - Overgrowth of smooth muscle, fibrous tissue
  - Affects medium/large arteries

IMAGING

General Features

- Best diagnostic clue
  - Luminal irregularity ("beaded") arteries in young/middle-aged patient
- Location
  - Renal artery = most common site overall (~ 75%)
  - Craniocervical arteries (~ 70%)
    - ICA (30-50%) > ECA > vertebral arteries (10-20%)
    - > 50% of cases have bilateral involvement
    - Spare the carotid bifurcation
  - Intracranial rare (supraclinoid ICA, MCA)
- Morphology
  - Arterial luminal corrugations, classic "string of beads" appearance
    - ± arterial stenosis, aneurysm

CT Findings

- CTA
  - Arterial luminal irregularity or "beading"
    - ± stenosis or aneurysm (uncommon)
    - Mural Ca++ absent

MR Findings

- DWI
  - Most sensitive for ischemic sequela of FMD
- MRA
  - May see "string of beads" appearance

Ultrasonographic Findings

- Color Doppler
  - Visible ridges or thickening of carotid wall ± stenosis

Angiographic Findings

- 3 subtypes with distinctive appearances on DSA
  - Type 1 (85%): Classic "string of beads" = medial fibroplasia
  - Type 2 (10%): Long, tubular stenosis = intimal fibroplasia
  - Type 3 (5%): Asymmetric outpouching from 1 side of artery = periadventitial fibroplasia

DIFFERENTIAL DIAGNOSIS

Atherosclerosis

- Usually older patients
- Typically short segment stenosis (not "string of beads"), associated with mural Ca++

Arterial "Standing Waves"

- Oscillations from normal retrograde flow during cardiac cycle, unknown etiology
- Appears as transient "string of beads"
  - Very regular periodicity, smoothness differentiate from FMD

Nonatherosclerotic Vasculopathies

- Takayasu, giant cell arteritis

PATHOLOGY

General Features

- Etiology
  - Unknown; thought to be dysplastic rather than degenerative or inflammatory
- Associated abnormalities
  - Intracranial saccular aneurysms in ~ 10%
  - Spontaneous dissection (20% in ICA)
  - Thromboembolic sequela due to disturbed flow → thrombus formation
    - TIA or stroke in 15-20%

Microscopic Features

- Overgrowth of smooth muscle cells and fibrous tissue in arterial wall

CLINICAL ISSUES

Presentation

- Most common signs/symptoms
  - Hypertension due to renal involvement (stenosis)
- Other signs/symptoms
  - Craniocervical FMD
    - Stenosis → TIA/stroke
    - Dissection ± stroke
    - Aneurysm → mass effect on adjacent structures, rupture (rare)

Demographics

- Age
  - Onset of symptoms: 25-50 years old
- Gender
  - M:F = 1:9 (most common subtype)

Natural History & Prognosis

- Slow progression of arterial irregularities ± stenoses

Treatment

- Antiplatelet ± anticoagulant Rx to reduce risk of thromboembolic sequela (stroke)
- Balloon angioplasty of stenoses
- Covered stent, arterial reconstruction for aneurysm

DIAGNOSTIC CHECKLIST

Consider

- FMD in younger patients with HTN, stroke, dissection
- Head CTA/MRA in FMD patients to exclude associated intracranial aneurysm(s)

SELECTED REFERENCES

1. Persu A et al: European consensus on the diagnosis and management of fibromuscular dysplasia. J Hypertens. 32(7):1367-78, 2014
2. Olin JW et al: The United States registry for fibromuscular dysplasia: results in the first 447 patients. Circulation. 125(25):3182-90, 2012

https://CafePezeshki.IR

KEY FACTS

TERMINOLOGY

- Absence of cerebral hemispheres with intact thalamus, brainstem, cerebellum, skull/meninges
  - Associated space filled with CSF ("water bag brain")
  - Probably caused by in utero vascular occlusion, infection, or trauma after 1st trimester

IMAGING

- Absent cerebrum with fluid-filled cranial vault
- Thalamus, cerebellum, brainstem, falx intact
- Temporal, occipital lobe remnants common
- Macrocephaly

TOP DIFFERENTIAL DIAGNOSES

- Severe hydrocephalus
- Alobar holoprosencephaly (HPE)
- Severe bilateral open-lip schizencephaly
- Cystic encephalomalacia

PATHOLOGY

- In utero compromise of anterior cerebral circulation
- Implicated: Anoxia, infection, thrombophilic states, maternal toxin exposure, radiation, genetic factors, twin-twin transfusion

CLINICAL ISSUES

- Newborn with macrocephaly, developmental failure, calvarial transillumination
  - Hyperirritability, hyperreflexia, seizures
- Neurological function limited to brainstem
- Prognosis: Death in infancy; prolonged survival rare
- Ventricular shunt treats macrocephaly

DIAGNOSTIC CHECKLIST

- Intact falx distinguishes hydranencephaly from alobar HPE
- Thin cortical mantle along inner table distinguishes severe hydrocephalus from hydranencephaly

(Left) *Coronal graphic shows classic features of hydranencephaly. The cerebral hemispheres are nearly absent, but the thalami, brainstem, and cerebellum are intact. The falx cerebri ⇨ appears to "float" in a CSF-filled rostral cranial vault.* **(Right)** *Axial NECT shows cerebral hemispheres replaced by CSF with no cortical mantle appreciated except in the medial temporal lobes ⇨. The posterior fossa and diencephalic structures supplied by the posterior cerebral circulation are intact.*

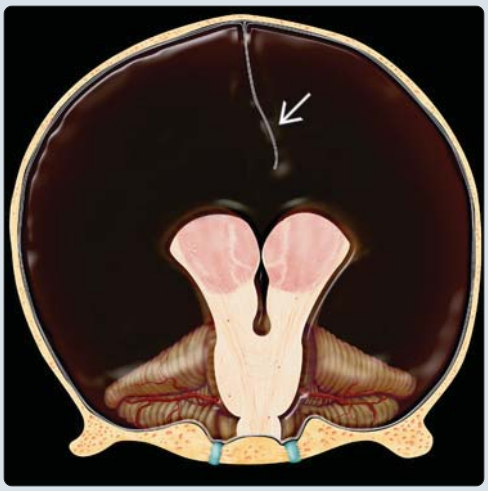

(Left) *Sagittal T1WI in a newborn with macrocephaly shows hydranencephaly. No cortical mantle is visible. CSF fills virtually all of the expanded supratentorial spaces. The brainstem and cerebellum appear normal.* **(Right)** *Coronal T1 MR in the same patient shows the expanded, CSF-filled spaces with only tiny amounts of residual brain present ⇨. Note that the CSF appears somewhat heterogeneous due to pulsation. (Courtesy A. Illner, MD.)*

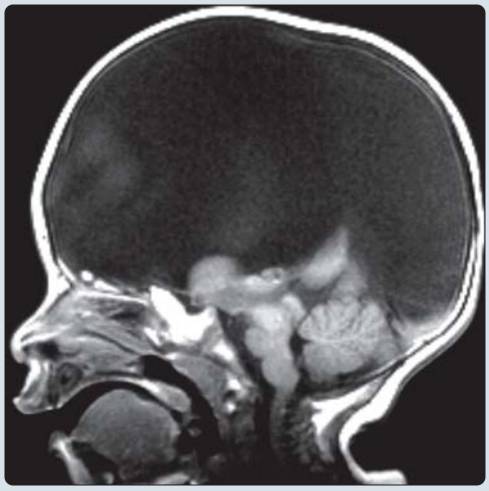

https://CafePezeshki.IR

TERMINOLOGY

Definitions

- Absence of cerebral hemispheres with intact thalamus, brainstem, cerebellum, skull/meninges
  - Associated space filled with CSF
  - Probably caused by in utero vascular occlusion, infection, or trauma after 1st trimester
- Hemihydranencephaly: Rare unilateral form

IMAGING

General Features

- Best diagnostic clue
  - Absent cerebrum with fluid-filled cranial vault
  - Falx cerebri and posterior fossa structures intact
- Location
  - Cerebral hemispheres
- Morphology
  - "Water bag" brain
- Thalamus, cerebellum, brainstem, falx intact
- Medial temporal, occipital lobe remnants common

CT Findings

- Fluid-filled cranial vault
- Macrocephaly

MR Findings

- Absent cerebral mantle
- Falx cerebri partially/completely intact
- No gliosis in remaining brain structures

Ultrasonographic Findings

- Anechoic cranial vault

Other Modality Findings

- CTA, MRA: Atretic, stenotic, occluded, malformed or normal supraclinoid carotids and branch vessels
- Prenatal US/MR: Severe hemorrhage may precede hydranencephaly

Imaging Recommendations

- Best imaging tool
  - Prenatal US allows therapeutic intervention
  - Postnatal MR best delineates extent of destruction

DIFFERENTIAL DIAGNOSIS

Severe Hydrocephalus

- Thin cortical mantle compressed against inner table

Alobar Holoprosencephaly (HPE)

- Fused midline structures; absent falx

Severe Bilateral Open-Lip Schizencephaly

- Perisylvian transmantle cleft lined by abnormal gray matter

Cystic Encephalomalacia

- Scattered cerebral cavities, gliosis

PATHOLOGY

General Features

- Etiology
  - In utero compromise of anterior cerebral circulation
  - Brain injury results in liquefactive necrosis by 20-27 weeks gestation
  - Implicated: Anoxia, infection, thrombophilic states, maternal toxin exposure, radiation, genetic factors, twin-twin transfusion
  - *COL4A1* mutations with large prenatal hemorrhages
- Genetics
  - Sporadic
  - Rare autosomal recessive syndromes
    - Fowler: Hydranencephaly, fetal akinesia, CNS vasculopathy
    - Microhydranencephaly: Hydranencephaly, microcephaly, small body (Chr 16p13.3-12.1)
- Associated abnormalities
  - Few reports: Vascular malformations, renal dysplasia

Gross Pathologic & Surgical Features

- Leptomeningeal-lined, fluid-filled "sacs" in lieu of cerebral hemispheres

Microscopic Features

- Hemosiderin-laden macrophages over remnant brain

CLINICAL ISSUES

Presentation

- Most common signs/symptoms
  - Macrocephaly (intact choroid plexus secretes CSF)
- Other signs/symptoms
  - Hyperirritability, hyperreflexia, seizures
- Clinical profile
  - Newborn with macrocephaly, developmental failure, calvarial transillumination

Demographics

- Age: Diagnosis usually made in 1st few weeks of life
- Epidemiology: < 1:10,000 births; 10x ↑ teenage moms

Natural History & Prognosis

- Neurological function limited to brainstem
- Progressive hydrocephalus requiring CSF diversion

Treatment

- Ventriculoperitoneal shunt treats macrocephaly
- Endoscopic coagulation of choroid plexus

DIAGNOSTIC CHECKLIST

Image Interpretation Pearls

- Intact falx distinguishes hydranencephaly from alobar HPE
- Thin cortical mantle along inner table distinguishes severe hydrocephalus from hydranencephaly

SELECTED REFERENCES

1. Kim SY et al: Endoscopic coagulation of choroid plexus in hydranencephaly. J Korean Neurosurg Soc. 55(6):375-8, 2014
2. Pavone P et al: Hydranencephaly: cerebral spinal fluid instead of cerebral mantles. Ital J Pediatr. 40(1):79, 2014
3. Cecchetto G et al: Looking at the missing brain: hydranencephaly case series and literature review. Pediatr Neurol. 48(2):152-8, 2013
4. Sepulveda W et al: Prenatal sonography in hydranencephaly: findings during the early stages of disease. J Ultrasound Med. 31(5):799-804, 2012

https://CafePezeshki.IR

KEY FACTS

TERMINOLOGY

- White matter injury of prematurity (WMIP) is not the same as germinal matrix hemorrhage (GMH)
  - In WMIP, primary injury is to white matter; in GMH, primary injury is to vessels in germinal matrix
- Periventricular leukomalacia (PVL) = WMIP, but term WMIP is used to emphasize that not all white matter injury is periventricular
- Encephalopathy of prematurity = WMIP and associated neuronal/axonal abnormalities

IMAGING

- Best early ultrasound (US) clue: Hyperechoic "flare" with loss of normal tissue echo texture
- Best early MR clue: T1 hyperintensity and decreased diffusion (bright DWI, low ADC) in affected areas
  - Acute DWI abnormality > T1 and T2 abnormality, also acute DWI > chronic injury visible on MR
- Best late MR clue: White matter volume loss, sometimes gliosis or ventriculomegaly
- White matter cavitation has become rare in modern neonatal ICUs

TOP DIFFERENTIAL DIAGNOSES

- Normal periventricular halo
- Infection
- Inborn errors of metabolism

PATHOLOGY

- Primarily initiating factors: Inflammation (due to maternal infection/postnatal sepsis) and ischemia

CLINICAL ISSUES

- Typically silent
- Severity and extent of brain abnormalities = destructive processes and developmental disturbances

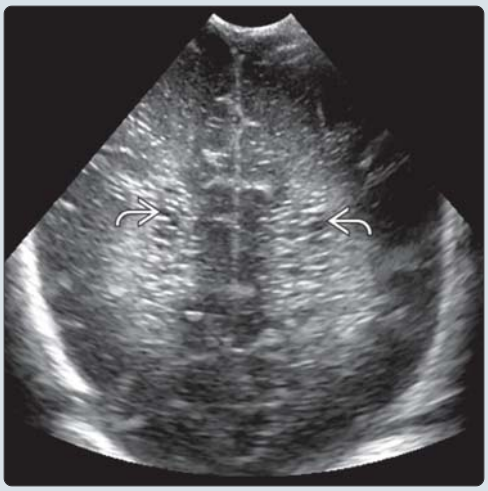

(Left) *Oblique transfontanelle cranial ultrasound in a 34 week gestational age (GA) infant at 17 days old shows diffusely increased echogenicity throughout the white matter with subtle regions of cavitation, usually called cystic change.* **(Right)** *Axial T2WI MR in the same 34-week GA infant 1 day later better illustrates the severity and extent of the white matter injury. More extensive white matter cavitation (cystic regions) are clearly identified.*

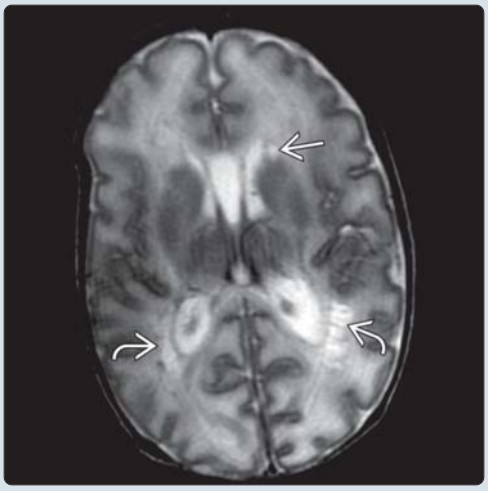

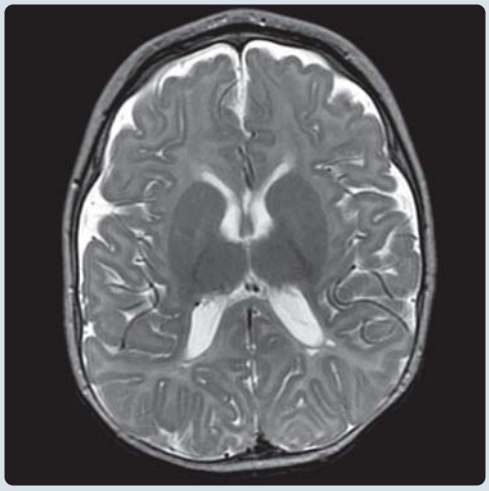

(Left) *Axial T1WI MR in the same 34-week GA infant at 18 days old shows cavitary white matter injury in the peritrigonal regions and, to a lesser degree, adjacent to the left frontal horn.* **(Right)** *Axial T2WI MR in the same infant at 3 months old shows almost complete collapse of the cavities, resulting in ex vacuo ventricular enlargement and white matter volume loss. On follow-up at 2 years old, this child has mild spastic diplegia and mild language delay.*

https://CafePezeshki.IR

TERMINOLOGY

Abbreviations

- White matter injury of prematurity (WMIP), hypoxic-ischemic encephalopathy (HIE), hypoxic-ischemic injury (HII), periventricular leukomalacia (PVL), very low birth weight (VLBW)

Definitions

- WMIP is not the same as germinal matrix hemorrhage (GMH)
  - In WMIP, primary injury is to white matter; in GMH, primary injury is to vessels in germinal matrix
- PVL = WMIP, but term WMIP is used here to emphasize that not all white matter injury is periventricular
- VLBW = infant ≤ 1,500 g (1-5% of all births)
- Encephalopathy of prematurity = WMIP and associated neuronal/axonal abnormalities

IMAGING

General Features

- Best diagnostic clue
  - Best early ultrasound (US) clue: Hyperechoic "flare" with loss of normal tissue echo texture
  - Best early MR clue: T1 hyperintensity and decreased diffusivity (bright DWI, low ADC) in affected areas
  - Best late MR clue: WM volume loss, sometimes with gliosis/ventriculomegaly
  - WM cavitation has become rare in modern neonatal ICUs
- Location
  - Focal (most common peritrigonal) or diffuse WM
  - Thalami (may be secondary to WM injury)
  - Often associated with inferomedial cerebellar hemorrhage
- Size
  - Most WM lesions are 3 mm or less
- Morphology
  - Chronic: WM volume loss
    - ↓ WM volume (especially corpus callosum [CC])
    - Undulating ventricular borders
    - Secondary ventriculomegaly (variable severity)
    - ± cortical and deep gray volume loss
    - ± pontine and cerebellar volume loss

CT Findings

- NECT
  - Insensitive to nonhemorrhagic WMIP

MR Findings

- T1WI
  - Early
    - May be normal, often underestimates extent of injury
    - WM ↓ T1 signal: Diffuse (edema or ischemia) or focal (cavitation)
    - Focal WM ↑ T1 signal (myelin breakdown products, hemorrhage, or microglial activation) ± cavitation
  - Late: Morphological changes as above
- T2WI
  - Early
    - May be normal, often underestimates extent of injury
    - WM ↑ T2 signal: Diffuse (edema or ischemia) or focal (cavitation)
    - Focal WM ↓ T2 signal (myelin breakdown products, hemorrhage, or microglial activation)
  - Late: Morphological changes as above, gliosis (if injury occurred > 24-26 weeks gestational age)
- FLAIR
  - Early: Insensitive to injury
  - Late: Same as T2 but ↑ sensitivity to periventricular gliosis
- T2* GRE
  - Blooming at sites of hemorrhage
- DWI
  - Most sensitive in acute stage
  - ↑ signal and ↓ ADC in areas of recent injury, but time course for DWI and ADC evolution and normalization not known
  - Acute DWI abnormality larger in size than acute or chronic T1 and T2 abnormalities
- MRS
  - ↑ lactate
  - ↓ NAA (normal in premature infants)
  - ↑ excitatory neurotransmitters
  - **Caveat**: Small amounts of lactate are often seen in WM and CSF of uninjured premature neonates

Ultrasonographic Findings

- Grayscale ultrasound
  - Early: Focal or diffuse increased echogenicity, most prominent adjacent to frontal horns and trigone
  - Subacute: ± cavitation (may take ~ 7-10 days to appear)
  - Late: Cavities often collapse; WM volume loss, secondary ventriculomegaly

Imaging Recommendations

- Best imaging tool
  - MR with DWI
    - Most sensitive and specific imaging modality
    - Benefits must be balanced with risk of transport to MR
    - ↑ sensitivity and ↑ specificity to type of injury (ischemia, hemorrhage vs. edema) compared to US
  - Head US
    - Still screening tool of choice: Inexpensive and can be performed bedside, but ↓ sensitivity and specificity compared to MR
- Protocol advice
  - Current practice parameter recommendations
    - Screening head US in all infants GA < 30 weeks at 7-14 days old and at 36-40 corrected GA
  - MR
    - When US is abnormal: MR ASAP to clarify scope of injury and aid in prognosticating, include DWI
    - At discharge for at-risk VLBW neonates with normal screening cranial sonograms

DIFFERENTIAL DIAGNOSIS

Normal Periventricular Halo

- Normal hyperechoic "blush" posterosuperior to ventricular trigones, seen on parasagittal sonography

https://CafePezeshki.IR

- Suspect WMIP if echogenicity is asymmetric, coarse, globular, or more hyperechoic than glomi of choroid plexus

Infection

- Congenital CMV infection: Microcephaly, calcifications, WM edema, ± polymicrogyria, DWI negative
- *Citrobacter*, frontal lobes
- Enteroviruses (especially echovirus, parechovirus)

Inborn Errors of Metabolism

- Urea cycle disorders, mitochondrial disorders

PATHOLOGY

General Features

- Etiology
  - Primarily initiating factors: Inflammation (due to maternal infection/postnatal sepsis) and ischemia
  - Unique risk factors of premature brain
    - Intrinsic vulnerability of immature oligodendroglia and subplate neurons to free radicals, excitotoxicity, and cytokines
    - Abundant microglia
    - Impaired cerebrovascular autoregulation → pressure-passive cerebral circulation
    - Periventricular vascular anatomical and physiological factors (arterial end zones)
  - Primary injury to WM ± subplate neurons
  - Currently unclear if more widespread neuronal/axonal abnormalities primary or secondary to resulting growth disturbances/WM injury
- Associated abnormalities
  - Intraventricular hemorrhage

Staging, Grading, & Classification

- Focal: Localized necrosis in deep WM with loss of all cellular components
  - Macroscopic: Cysts ≥ 1-2 mm (< 5% of VLBW infants, also called cystic PVL)
  - Microscopic: Cysts not resolved by current imaging, evolve to glial scar
- Diffuse: Marked astrogliosis and microgliosis, abnormal promyelinating oligodendrocyte maturation (results in hypomyelination, volume loss)

CLINICAL ISSUES

Presentation

- Most common signs/symptoms
  - Acute: Typically silent, ± perirolandic sharp waves on EEG; need to consider risk and screen
- Clinical profile
  - Mother: Poor antepartum care, preterm premature rupture of membranes, chorioamnionitis, preeclampsia, group B strep
  - Preterm neonate: VLBW, intraventricular hemorrhage, respiratory distress syndrome type 1, hypocarbia, hypotension, sepsis, anemia, apnea

Demographics

- Age
  - Incidence of WMIP in VLBW infants is < 20% (down from 50% in 2001)
  - Worldwide ~ 5% of preterm infants have WMIP
- Gender
  - M > F
- Epidemiology
  - VLBW → < 20% incidence (higher if associated with intraventricular hemorrhage)
  - Gestational age < 33 weeks → higher incidence
  - > 50% of patients with cystic WMIP or grade 3 intraventricular hemorrhage develop cerebral palsy

Natural History & Prognosis

- Severity and extent of brain abnormalities = destructive processes + developmental disturbances
- Spastic diplegia/quadriplegia, seizures, microcephaly, blindness, deafness in severe cases
- Poor outcome if intraventricular hemorrhage with WMIP, WMIP with volume loss, widespread infarction, or seizures
- Spastic diplegia (associated with cystic WMIP)
- Cognitive deficits in absence of motor deficits (associated with noncystic WMIP and cerebellar injury)
  - Many have impaired working memory and attention deficits
  - Basis of cognitive deficits may be due to thalamic, cerebellum, as well as cerebral cortical involvement

Treatment

- Prenatal care significantly reduces preterm birth (35% down to 8%)
- Supportive

DIAGNOSTIC CHECKLIST

Image Interpretation Pearls

- Cranial ultrasound underestimates WMIP
- As with HII of term, injuries evolve over time

SELECTED REFERENCES

1. Herzog M et al: Impact of risk factors other than prematurity on periventricular leukomalacia. A population-based matched case control study. Eur J Obstet Gynecol Reprod Biol. 187:57-9, 2015
2. Zammit C et al: Cerebral white matter injuries following a hypoxic/ischemic insult during the perinatal period: pathophysiology, prognostic factors, and future strategy of treatment approach. A minireview. Curr Pharm Des. 21(11):1418-25, 2015
3. Hart AR et al: Diffusion-weighted imaging and magnetic resonance proton spectroscopy following preterm birth. Clin Radiol. 69(8):870-9, 2014
4. de Vries LS et al: Imaging the premature brain: ultrasound or MRI? Neuroradiology. 55 Suppl 2:13-22, 2013
5. de Vries LS et al: Value of sequential MRI in preterm infants. Neurology. 81(24):2062-3, 2013
6. Chau V et al: Postnatal infection is associated with widespread abnormalities of brain development in premature newborns. Pediatr Res. 71(3):274-9, 2012
7. Xu D et al: MR spectroscopy of normative premature newborns. J Magn Reson Imaging. 33(2):306-11, 2011

https://CafePezeshki.IR

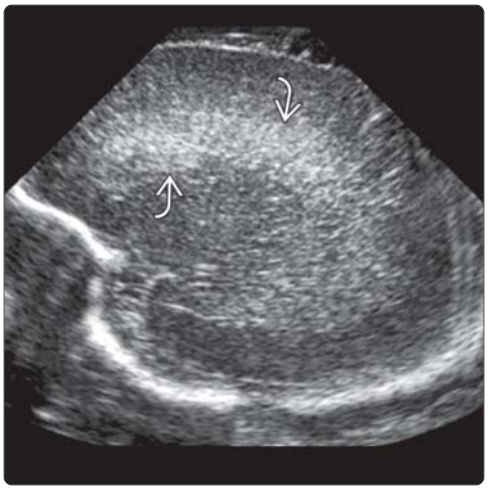

(Left) *Sagittal oblique transfontanelle cranial ultrasound in a 3-day-old premature infant shows hazy increased echogenicity or hyperechoic "flare" throughout the hemispheric white matter.* **(Right)** *Sagittal oblique cranial ultrasound in the same infant a few days later shows the development of small cavitations within the hyperechoic white matter. The lesions progressed to large areas of cavitation in the injured white matter during the next week (not shown).*

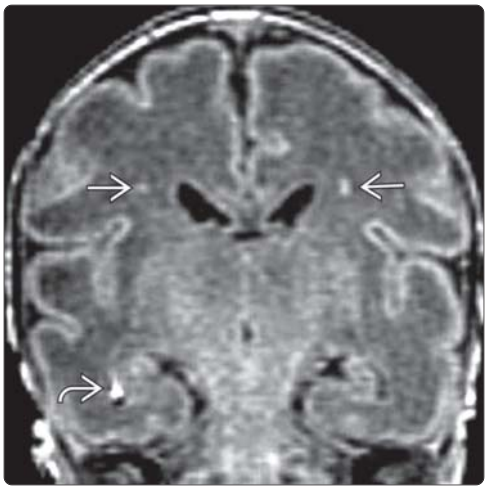

(Left) *Coronal T1WI MR shows bilateral foci of white matter injury in the deep white matter. This type of white matter injury of prematurity (WMIP) is far more common than the cavitary type, which has become uncommon with modern perinatal care in the neonatal ICU. Note the incidental germinal matrix hemorrhage in the right temporal lobe.* **(Right)** *Sagittal T1WI MR shows multiple foci of WMIP in the deep white matter in this child born at 27 weeks. The sulcation pattern is very immature.*

(Left) *Coronal T1WI MR shows bilateral WMIP. This is the most common location (deep white matter), which is why the term periventricular leukomalacia has been replaced. Note the small cerebellum (normal), which grows more in later gestation and postnatally.* **(Right)** *Axial T1WI MR shows very little sulcation in this 26-week prematurely born baby. The deep peritrigonal WMIP is a common location; the left-sided one is large. The foci around the frontal horns are germinal zones.*

https://CafePezeshki.IR

KEY FACTS

TERMINOLOGY

- Hypoxic-ischemic injury (HII): Imaging pattern of injury due to acquired global arterial hypoperfusion (though many factors can increase vulnerability and potential injury)
- Hypoxic-ischemic encephalopathy (HIE): Clinical syndrome defined in term or near-term neonates

IMAGING

- Profound HII: Low ADC in ventrolateral (VL) thalamus ± corticospinal tract (CST) in posterior limb internal capsule (PLIC)
- Partial HII: VL thalamus and CST in PLIC spared, cortical injury maximal at depths of sulci
- Bright DWI and ↓ ADC occur early, even when T1WI/T2WI normal
- Injuries evolve over time: DWI and ADC abnormality can ↑ in size and severity over 1st few days due to delayed cell death; DWI and ADC normalize or ↑ around 7-10 days
- US and CT insensitive, particularly after therapeutic hypothermia

TOP DIFFERENTIAL DIAGNOSES

- Venous injury
  - Edema, hemorrhage, or ischemia in venous distribution
- Hypoglycemia
  - Predominantly posterior distribution, check glucose
- Mitochondrial disorders
- Urea cycle disorders
- Other inborn errors in metabolism
  - Especially isolated sulfite oxide deficiency, molybdenum cofactor deficiency
- Kernicterus (accentuated by sepsis, hypoxia)

CLINICAL ISSUES

- Treatment: Hypothermia to 33.5°C for 72 hours

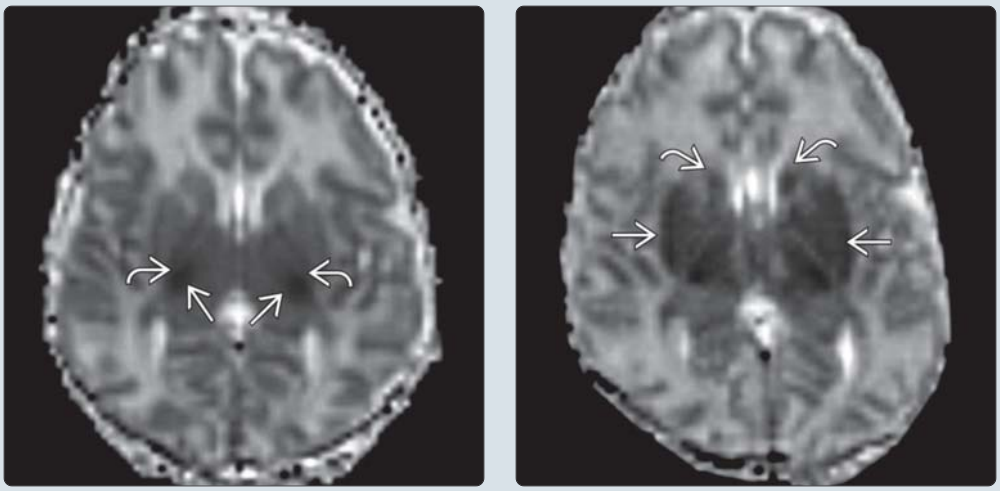

(Left) *Axial ADC map in a 1-day-old neonate with an Apgar score of 0 at 5 minutes shows marked ADC decrease involving the ventrolateral thalami and CST in posterior limb internal capsule (PLIC) bilaterally. This case was proven to be profound hypoxic-ischemic injury (HII).* **(Right)** *Axial ADC in the same neonate at 4 days old shows the ADC decrease to now involve the bilateral caudate and lentiform nuclei. The delayed appearance of ADC abnormalities suggests that delayed necrosis has occurred in the interval.*

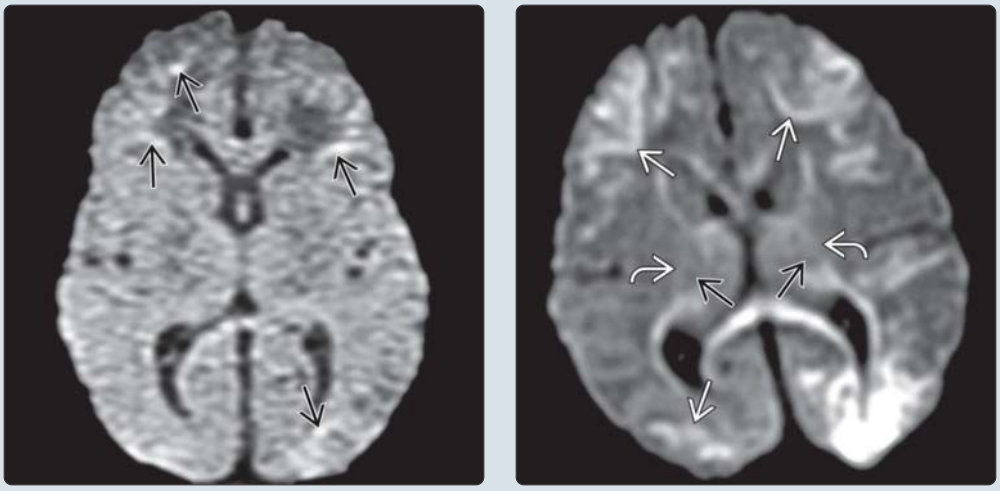

(Left) *Axial DWI MR of a 1-day-old neonate presenting with seizures shows scattered small foci of increased signal intensity, primarily at the depths of sulci. This infant was diagnosed with partial HII.* **(Right)** *Axial DWI MR in the same neonate at age 3 days shows marked progression of the extent and severity of the DWI abnormality suggesting delayed necrosis. Note the involvement of the depths of sulci, as well as the sparing of ventrolateral thalamus and corticospinal tract in PLIC.*

https://CafePezeshki.IR

TERMINOLOGY

Abbreviations

- Hypoxic-ischemic injury (HII), hypoxic-ischemic encephalopathy (HIE)

Synonyms

- Hypoxic-ischemic insult, perinatal or birth asphyxia, asphyxia neonatorum

Definitions

- HII: Imaging pattern of injury due to acquired global arterial hypoperfusion (though many factors can increase vulnerability and potential injury)
  - Not all with HII meet clinical criteria for HIE
- HIE: Clinical syndrome defined in term or near-term neonates
  - Not all with HIE have HII on imaging
- Profound HII: Complete or nearly complete cessation of blood flow to brain
- Partial HII: Less severe reduction of cerebral blood flow

IMAGING

General Features

- Best diagnostic clue
  - Profound HII: Low ADC in ventrolateral thalamus (VLT) ± corticospinal tract (CST) in posterior limb internal capsule (PLIC)
  - Partial HII: VLT and CST in PLIC spared, cortical injury maximal at depths of sulci
- Location
  - Profound HII
    - VLT and CST in PLIC
    - ± perirolandic cortex, other cortical regions (in cortex depths of sulci more involved than apices of gyri), white matter, hippocampi, midbrain, dorsal brainstem, superior vermis
    - Subacute: Entire thalamus and basal ganglia may become involved
  - Partial HII
    - VLT + CST in PLIC spared
    - Bilateral symmetric or asymmetric involvement of cortex and subcortical white matter usually maximal at sulcal depths

CT Findings

- NECT
  - Insensitive
  - Profound HII: Deep gray nuclei may be indistinct due to ↓ attenuation
  - Partial HII: Loss of gray-white distinction

MR Findings

- T1WI
  - Profound HII
    - Subacute (beginning ~ 3 days): ↑ signal in VLT, ± posterolateral putamen, ± perirolandic cortex at depths of sulci, loss of normal ↑ signal of CST in PLIC
  - Partial HII
    - Subacute: ↑ signal depths of sulci starting ~ 3 days
- T2WI
  - Profound HII
    - Acute: Blurring of deep gray nuclei ± cortical margins
    - Subacute: ↓ signal in VLT ± posterolateral putamen starting ~ 6 days, ↑ signal in white matter
    - Chronic: ↑ signal ± volume loss in VLT, ± posterolateral putamen, ± other areas of gliosis and volume loss
  - Partial HII
    - Acute: Blurring of cortical margins
    - Subacute: ↑ signal in white matter
    - Chronic: Variable volume loss and gliosis
- T2* GRE
  - Rarely blooming to suggest hemorrhage directly related to HII
- DWI
  - Bright DWI and ↓ ADC occur early, even when T1WI/T2WI normal
  - Injuries evolve over time: DWI and ADC abnormality can ↑ in size and severity over 1st few days due to delayed cell death; DWI normalizes and ADC normalizes or ↑ around 7-10 days
  - Less sensitive after therapeutic hypothermia
- MRA
  - Typically normal or loss of signal due to turbulent flow in small neonatal arteries
- MRV
  - Typically normal, often focal narrowing in superior sagittal sinus due to moulding
- MRS
  - ↓ NAA correlates with worse prognosis
  - ↑ α-glutamate/glutamine peaks in basal ganglia (BG) correlate with ↑ severity of injury
  - ↑ lactate correlates with worse prognosis

Ultrasonographic Findings

- Grayscale ultrasound
  - Insensitive, may see ↑ echogenicity in injured areas
- Color Doppler
  - ↓ resistive indices in severe profound HII
  - Good to rule out clot in circle of Willis

Imaging Recommendations

- Best imaging tool
  - Combined DWI and MRS: Extremely sensitive for early ischemic necrosis
    - Be aware that therapeutic hypothermia may reduce early sensitivity to injury
- Protocol advice
  - In milder injuries, DWI may take 24 hours to become abnormal
    - To ↑ sensitivity to subtle injury, look at ADC as well as DWI and consider ↑ b values

DIFFERENTIAL DIAGNOSIS

Venous Injury

- Edema, hemorrhage, or ischemia in venous distribution
- Not global arterial hypoperfusion = technically not HII

Hypoglycemia

- Predominantly posterior distribution, check glucose
- Exacerbates hypoxic-ischemic injury

https://CafePezeshki.IR

Mitochondrial Disorders

- Consider if history benign
- Pattern can be identical to HII

Urea Cycle Disorders

- Pattern of BG and thalamus involvement different

Other Inborn Errors in Metabolism

- Many have BG abnormalities; thalamus uncommon

Kernicterus

- Accentuated by sepsis, hypoxia
- Mimics profound injury, acute on T1WI; has confirmed hyperbilirubinemia
- Globus pallidus (not putamen or thalamus)

PATHOLOGY

General Features

- Etiology
  - Profound HII
    - Sentinel event: Equivalent to cardiorespiratory arrest
    - Severe lack of blood flow and O_2 for minutes to ~ 1 hour
    - Injury maximal to areas with high metabolic demand
  - Partial HII
    - No sentinel event, therefore less well understood
    - Moderate lack of blood flow and oxygen for hours to days; persistent or intermittent
    - Redistribution of blood flow to areas of high metabolic demand → sparing of these regions
  - Asphyxia triggers cascade of cellular biochemical events → abnormal function, edema, or death of cell
    - Extracellular glutamate accumulates, activates postsynaptic excitatory amino acid receptors
    - Postsynaptic receptor distribution changes with development → different damage patterns at different gestational ages
  - Many chances for cell loss
    - Primary neuronal (death at time of insult)
    - Reactive cell death (reperfusion injury hours or days later)
    - Seizure-related cell injury
- Genetics
  - Seek inborn errors of metabolism if apparent HII with normal Apgar or if > 1 HII child in family
    - Isolated sulfite oxidase deficiency, molybdenum cofactor deficiency present early, imaging findings similar to HII
    - Differentiate by clinical course
- Associated abnormalities
  - Maternal: Infection, preeclampsia, diabetes, cocaine
  - Infant: ↓ gestational age, ↓ Hgb, growth retardation, ↓ Ca++/glucose, sepsis, hyperthermia, seizures, congenital heart disease; ↑ urine S100B protein
  - Ischemia often multiorgan (e.g., cardiac, renal)

Staging, Grading, & Classification

- Sarnat stage (based on clinical and EEG findings)

Gross Pathologic & Surgical Features

- Profound HII: Hippocampal, BG, thalamic, perirolandic atrophy
- Partial HII: Ulegyria, gliosis, and atrophy with sparing perirolandic region

CLINICAL ISSUES

Presentation

- Most common signs/symptoms
  - Sarnat I (mild): Hyperalert/irritable, mydriasis, ↑ HR, EEG normal
  - Sarnat II (mod): Lethargy, hypotonia, miosis, ↓ HR, seizure (SZ)
  - Sarnat III (severe): Stupor, flaccid, reflexes absent, SZ

Demographics

- Age
  - Near or full term in immediate prenatal, intrapartum, and postnatal period
- Epidemiology
  - HIE: Up to 2/1,000 (0.2%) live births

Natural History & Prognosis

- Varies from normal outcome (Sarnat I) to spastic quadriparesis, developmental delay, microcephaly, and SZ (Sarnat III)
- Profound HII (VL thalamus injury): Extrapyramidal cerebral palsy, high mortality, high morbidity
- Partial HII: Spastic quadriparesis

Treatment

- Resuscitation, correct fluid, and electrolyte imbalance
- Treat seizures
- Therapeutic hypothermia: Cool to 33.5°C for 72 hours

DIAGNOSTIC CHECKLIST

Consider

- Prenatal HII with in utero injury and recovery or inborn errors of metabolism if atypical clinical presentation

Image Interpretation Pearls

- DWI critical, but evolves over time: Can be normal < 1 day, ↑ in severity over days, then normalize ~ 1 week

SELECTED REFERENCES

1. Bell E et al: Magnetic resonance imaging (MRI) and prognostication in neonatal hypoxic-ischemic injury: a vignette-based study of Canadian specialty physicians. J Child Neurol. 30(2):174-81, 2015
2. Dinan D et al: Easily overlooked sonographic findings in the evaluation of neonatal encephalopathy: lessons learned from magnetic resonance imaging. Semin Ultrasound CT MR. 35(6):627-51, 2014
3. Rollins N et al: Predictive value of neonatal MRI showing no or minor degrees of brain injury after hypothermia. Pediatr Neurol. 50(5):447-51, 2014
4. Gano D et al: Evolution of pattern of injury and quantitative MRI on days 1 and 3 in term newborns with hypoxic-ischemic encephalopathy. Pediatr Res. 74(1):82-7, 2013
5. Shankaran S et al: Childhood outcomes after hypothermia for neonatal encephalopathy. N Engl J Med. 366(22):2085-92, 2012
6. Okereafor A et al: Patterns of brain injury in neonates exposed to perinatal sentinel events. Pediatrics. 121(5):906-14, 2008
7. Vermeulen RJ et al: Diffusion-weighted and conventional MR imaging in neonatal hypoxic ischemia: two-year follow-up study. Radiology. 249(2):631-9, 2008

https://CafePezeshki.IR

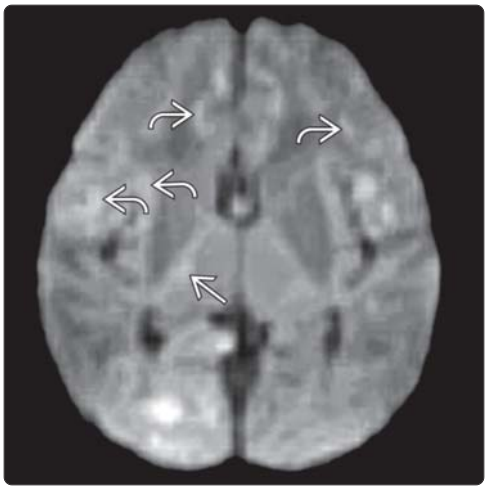

(Left) *Axial DWI MR in a neonate with profound HII shows ↑ signal in the right VL thalamus (VLT)/corticospinal tract (CST) region ➡ with multiple other foci of cortical/subcortical increased signal. Note the depths of sulci ➡ are often preferentially involved in profound HII.* **(Right)** *Axial ADC map in the same neonate better demonstrates the low ADC in the VLT ➡ and CST ➡ with multiple other regions of cortical/subcortical white matter involved. ADC shows neonatal injury better than DWI.*

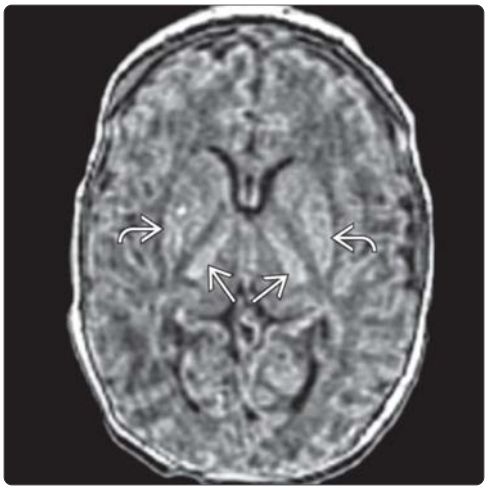

(Left) *Axial T1WI MR of a 9-day-old neonate who suffered birth injury and has profound HII shows increased signal intensity bilaterally in the VLT ➡ and putamina ➡.* **(Right)** *Axial T2WI MR in the same infant 6 months later is shown. The diffuse cystic encephalomalacia seen here goes beyond the visualized DWI/ADC abnormalities seen on the neonatal MR, suggesting processes of delayed cell death continued after the neonatal period.*

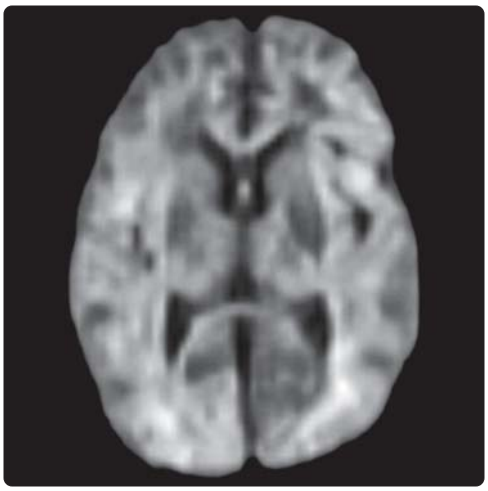

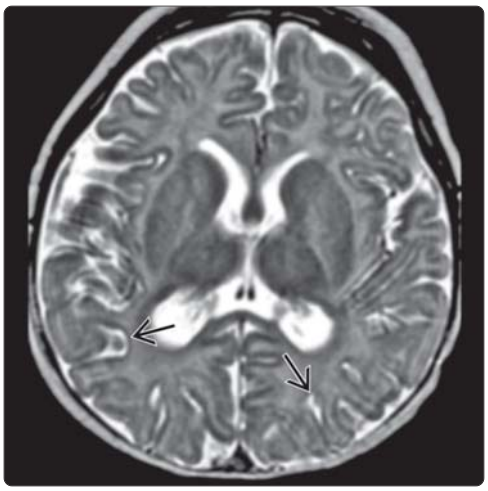

(Left) *Axial DWI MR in an infant with partial HII shows diffuse cortical white matter and deep gray increased signal with sparing of the VLT and CST.* **(Right)** *Axial T2WI MR in the same infant at 6 months shows diffuse volume loss with scattered subtle areas of cortical thinning at the depths of sulci ⇨, indicating that regions of marked decreased diffusion as seen on the previous image do not always progress to frank cystic encephalomalacia.*

https://CafePezeshki.IR

KEY FACTS

TERMINOLOGY

- Hypoxic ischemic injury (HII) includes global hypoxic ischemic injury, global anoxic injury, cerebral hypoperfusion injury
  - Etiologies: Cardiac arrest, cerebrovascular disease, drowning, asphyxiation

IMAGING

- Injury patterns highly variable depending on brain maturity, severity and length of insult
  - Mild to moderate: Watershed zone infarcts
  - Severe: Gray matter structures (basal ganglia, thalami, cortex, cerebellum, hippocampi)
- MR best to assess overall extent of injury within hours after HII event
  - DWI: 1st modality to be positive (within hours)
  - DWI: Restriction in deep nuclei ± cortex
  - T2/FLAIR: ↑ signal in cerebellum, basal ganglia, cortex
  - Acute changes not reliably identified with T2
- MRS: More sensitive and indicative of severity of injury in first 24 hours after HII
  - ↑ lactate, ↑ glutamine-glutamate

TOP DIFFERENTIAL DIAGNOSES

- Ischemic territorial infarction
- Traumatic cerebral edema
- Toxic/metabolic disorder
- Acute hypertensive encephalopathy, PRES
- Creutzfeldt-Jakob disease
- MELAS

PATHOLOGY

- Common underlying process regardless of cause
  - ↓ CBF and ↓ blood oxygenation
  - Switch from oxidative phosphorylation to anaerobic metabolism
  - Glutamate-related cytotoxic processes

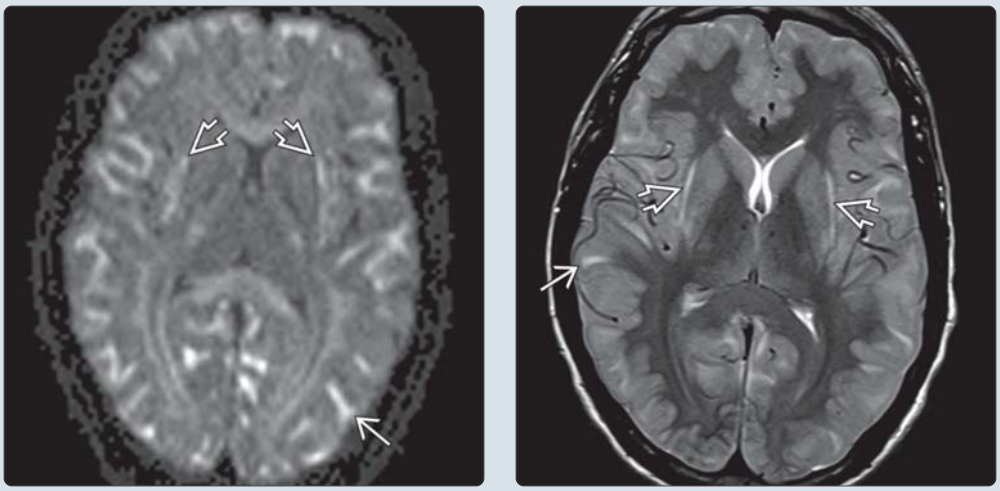

(Left) *Axial DTI trace image in a 21-year-old unresponsive man shows extensive hyperintensity related to cytotoxic edema throughout the cortex and subcortical white matter (WM) ➡ as well as the external capsules ➡ in this patient with severe HII.* **(Right)** *Axial T2 MR in the same patient shows hyperintensity throughout the cortex, subcortical WM ➡, and the external capsules ➡. Complete effacement of the sulci is related to gyral swelling. Involvement of the visual and sensorimotor cortex is common in severe HII.*

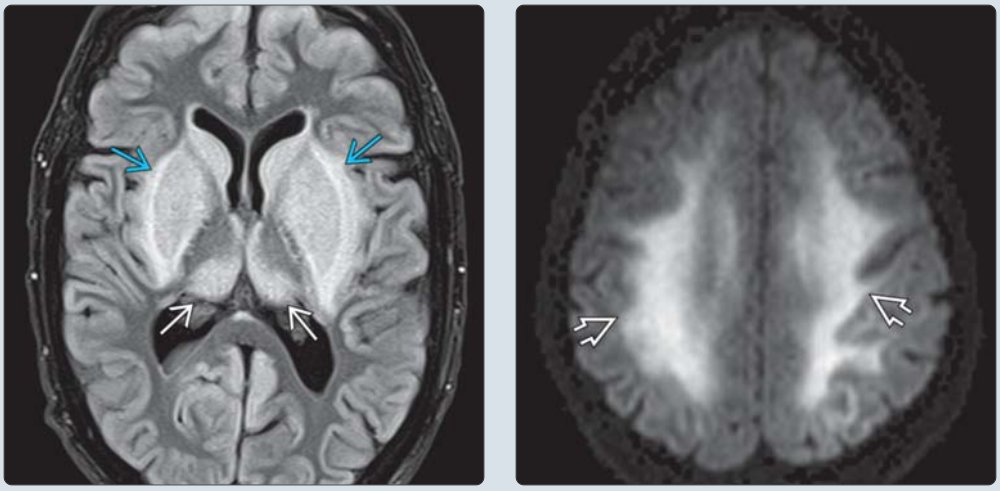

(Left) *Axial FLAIR MR shows symmetric hyperintensity of the basal ganglia ➡ and thalami ➡ in this patient status post cardiac arrest. T2 and FLAIR images typically become positive in the early subacute period (> 24 hours to 2 weeks) with increased signal and swelling of the injured GM structures.* **(Right)** *Axial DTI trace image shows extensive WM hyperintensity ➡ related to cytotoxic edema in this 43-year-old woman with mild to moderate HII. DWI signal abnormalities may pseudonormalize by the end of the 1st week.*

https://CafePezeshki.IR

TERMINOLOGY

Synonyms

- Hypoxic ischemic injury (HII), hypoxic ischemic encephalopathy (HIE)

Definitions

- Includes various etiologies of injury: Global hypoxic ischemic injury, global anoxic injury, cerebral hypoperfusion injury

IMAGING

General Features

- Best diagnostic clue
  - Symmetric T2/FLAIR hyperintensity in deep gray nuclei ± cortex
- Location
  - Mild to moderate: Watershed zone infarcts
  - Severe: Gray matter (GM) structures (basal ganglia [BG], thalami, cerebral cortex [sensorimotor and visual], cerebellum, hippocampi)
    - Cerebellar injury tends to be more common in older patients; Purkinje cells are sensitive to ischemia
  - Injury patterns are highly variable depending on brain maturity, severity and length of insult

CT Findings

- NECT
  - Diffuse cerebral edema with effacement of CSF-containing spaces
  - Decreased cortical gray matter attenuation with loss of normal gray-white differentiation
  - Decreased bilateral BG attenuation
  - Reversal or white cerebellum sign indicates severe injury with poor prognosis

MR Findings

- T1WI
  - Normal to very subtle abnormalities
  - BG may show T1 hyperintensity
  - Gray matter signal abnormalities may persist into end of 2nd week
  - Chronic stages show cortical pseudolaminar necrosis
- T2WI
  - Normal to very subtle abnormalities in first 24 hours
  - BG typically show T2 hyperintensity
  - Gray matter signal abnormalities may persist into end of 2nd week
  - Chronic stages show residual BG hyperintensity
- FLAIR
  - Symmetric hyperintensity in deep gray nuclei ± cortex
- DWI
  - 1st imaging modality to become positive, within hours after HII event
    - ↑ signal in cerebellar hemispheres, BG, cerebral cortex
  - DWI abnormalities pseudonormalize by end of 1st week
  - ADC is reduced in hyperacute phase following HII event due to influx of water from extra- to intracellular space
    - ADC values are reduced in severe white matter (WM) and in some severe BG and thalamic injury
    - ADC values may pseudonormalize or even be high initially in some less severe but clinically significant injuries
    - Abnormal ADC values pseudonormalize during 2nd week, whereas fractional anisotropy (FA) values continue to decrease
  - DTI: FA may be abnormal
    - Low FA may reflect breakdown in WM organization
    - Moderate BG/thalamic injury may result in atrophy but not overt infarct due to delayed apoptosis (may account for normal early ADC values)
      - Accompanying low FA within some severe and all moderate gray matter lesions → associated with significant later impairment
- PWI
  - In rat models, luxury perfusion immediately follows resuscitation from HII several hours of cortical and striatal mild hypoperfusion followed by hyperemia
- MRS
  - More sensitive and more indicative of injury severity in first 24 hours after HII
    - ↑ lactate at 1.3 ppm, ↑ glutamine-glutamate peak at 2.3 ppm
    - ↑ lactate after 24 hours portends poor neurologic outcome
    - NAA is usually normal in acute setting and declines 48 hours after acute injury

Imaging Recommendations

- Best imaging tool
  - MR, particularly DWI/DTI, is most sensitive modality to show abnormalities after ictus
- Protocol advice
  - DTI/DWI are most sensitive
  - Acute ischemic cerebral changes cannot be reliably identified with T2/FLAIR sequences
  - T2*GRE/SWI helpful to detect petechial or subarachnoid hemorrhage

DIFFERENTIAL DIAGNOSIS

Acute Cerebral Ischemia-Infarction

- Wedge-shaped T2 hyperintensity in vascular distribution
- DWI positive acutely

Traumatic Cerebral Edema/Ischemia

- Compressed ventricles and effaced sulci due to combination of vasogenic edema in WM and cytotoxic edema in GM → herniation of brain
- Vascular compression can lead to infarction

Toxic/Metabolic Disorder

- Selective vulnerability of GM to energy depletion
  - Carbon monoxide: T2 hyperintense GP ± subcortical WM
  - Methanol: Hyperintense putamen ± hemorrhagic necrosis
  - Mitochondrial encephalopathy: Symmetric BG abnormality
  - Drugs (heroin; methylenedioxymethamphetamine [MDMA], a.k.a. ecstasy): T2 hyperintense GP

https://CafePezeshki.IR

Acute Hypertensive Encephalopathy, PRES

- Predominantly vasogenic edema in subcortical WM of bilateral parietooccipital regions
- May involve deep gray nuclei

Creutzfeldt-Jakob Disease (CJD)

- Progressive T2 hyperintensity in BG, thalamus, and cerebral cortex
- FLAIR hyperintensity in cortex in sporadic CJD
- DWI: Restriction in deep gray nuclei and cortex; may resolve late in disease

MELAS

- **M**itochondrial myopathy, **e**ncephalopathy with **l**actic **a**cidosis, and **s**troke-like episodes
- Uncommon cause of childhood stroke
- Swollen T2 hyperintense gyri; crosses vascular distributions
- Spares subcortical and deep white matter

PATHOLOGY

Staging, Grading, & Classification

- Common underlying process regardless of cause of injury
  - Diminished cerebral blood flow and reduced blood oxygenation
  - Brain ischemia due to cardiac arrest or cerebrovascular disease and 2° to hypoxia due to ↓ blood flow
    - Switch from oxidative phosphorylation to anaerobic metabolism: ↓ ATP, ↑ lactate
    - Release of presynaptic glutamate → activation of NMDA receptors → triggers cytotoxic processes
      - Severe energy depletion → cell necrosis; lesser energy depletion → apoptosis
- Sites of brain injury determined by maturity of brain, severity of hypoxic-ischemic insult, and duration
- Selective vulnerability: Patterns of injury reflect dysfunction of selected excitatory neuronal circuits depleted most rapidly
  - Areas with highest concentrations of glutamate or excitatory amino acid receptors (GM) are more susceptible to injury
  - Areas with greatest energy demands become energy deficient
  - Cell death may not be evident until days after initial insult
- Delayed white matter injury: Postanoxic leukoencephalopathy
  - 2-3 weeks after HII in 2-3% of patients
  - Clinical stability followed by acute neurologic decline, most (75%) recover
- Brain-damaging effects of hypoxic-ischemia are age-dependent but do not increase linearly with advancing age and development
  - Immature brain is less resistant to HII than its adult counterpart
  - Intermediate age groups are more tolerant to HII than either very young or more mature ages
- Mechanism behind reduced diffusion during ischemia is thought to be caused by cytotoxic edema, which results from breakdown of cellular membrane Na/K pump system
  - As cytotoxic edema develops → shift of water from extracellular to intracellular space
  - Cell membrane remains intact, no overall ↑ in tissue water; **initially**: ↑ FA, ↓ ADC, normal T2
- Shorter intervals of HII primarily damage cerebral cortex and hippocampus, while longer periods result in more extensive damage and can be associated with cavitary lesions of cerebral hemispheres
  - Cavitary lesions, vertical band-like distribution of noncavitary lesions, mineralization more common in immature brain
- Patterns associated with poor clinical outcome: Diffuse cortical and deep gray matter pattern, medial occipital with perirolandic involvement, precentral gyrus involvement, diffuse white matter involvement, brainstem, cerebellar &/or hippocampal involvement

CLINICAL ISSUES

Presentation

- Most common signs/symptoms
  - Etiologies: Cardiac arrest, cerebrovascular disease, drowning, asphyxiation
  - Hypoxia in cases of near drowning involves putamen and caudate nucleus

Natural History & Prognosis

- Death or profound long-term neurologic disability
  - Neurological sequela, such as cerebral palsy and epilepsy

Treatment

- Supportive care; however, this does not prevent ongoing injury following causative insult
- Hypothermia
- Excitatory amino acid antagonists

DIAGNOSTIC CHECKLIST

Image Interpretation Pearls

- If MR is negative in first 24 hours, repeat exam at 2-4 days to exclude delayed injury

Reporting Tips

- Important to describe extent of cortical and deep gray matter involvement

SELECTED REFERENCES

1. Tekes A et al: Apparent diffusion coefficient scalars correlate with near-infrared spectroscopy markers of cerebrovascular autoregulation in neonates cooled for perinatal hypoxic-ischemic injury. AJNR Am J Neuroradiol. 36(1):188-93, 2015
2. Ghei SK et al: MR imaging of hypoxic-ischemic injury in term neonates: pearls and pitfalls. Radiographics. 34(4):1047-61, 2014
3. Muttikkal TJ et al: MRI patterns of global hypoxic-ischemic injury in adults. J Neuroradiol. 40(3):164-71, 2013
4. White ML et al: Anatomical patterns and correlated MRI findings of non-perinatal hypoxic-ischaemic encephalopathy. Br J Radiol. 86(1021):20120464, 2013
5. Wu O et al: Comatose patients with cardiac arrest: predicting clinical outcome with diffusion-weighted MR imaging. Radiology. 252(1):173-81, 2009
6. Huang BY et al: Hypoxic-ischemic brain injury: imaging findings from birth to adulthood. Radiographics. 28(2):417-39; quiz 617, 2008
7. Schaefer P. Stroke and cerebral ischemia. In Edelman R: Clinical Magnetic Resonance Imaging. 3rd ed. Philadelphia: Saunders Elsevier. 1454–98, 2006

https://CafePezeshki.IR

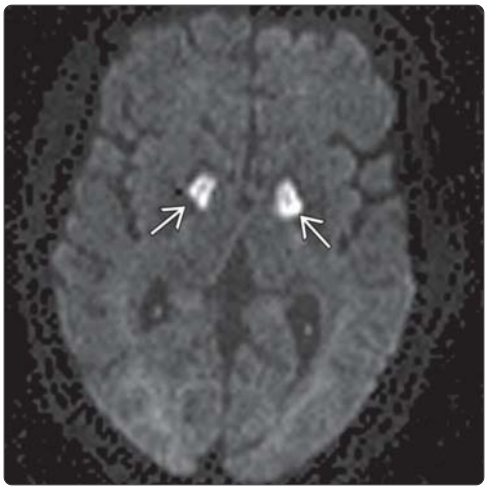

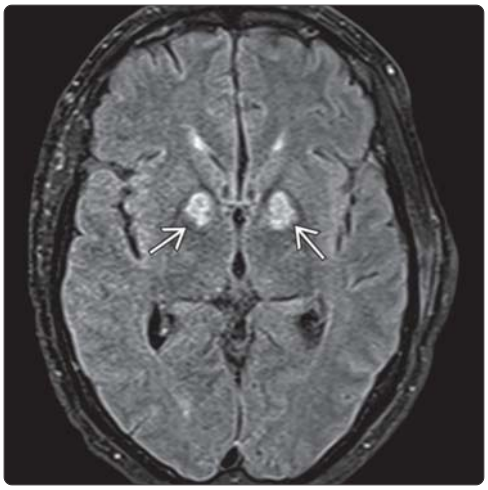

(Left) *Axial DTI MR shows symmetric increased signal in the globi pallidi* ➡ *in this patient with severe anoxic injury. DTI is the earliest modality to become positive within the 1st few hours after a hypoxic-ischemic event.* **(Right)** *Axial FLAIR MR in the same patient shows symmetric hyperintensity in the globi pallidi* ➡. *Imaging differential considerations in this patient include carbon monoxide poisoning and drugs of abuse such as heroin and methylenedioxymethampheta mine (MDMA), a.k.a. ecstasy.*

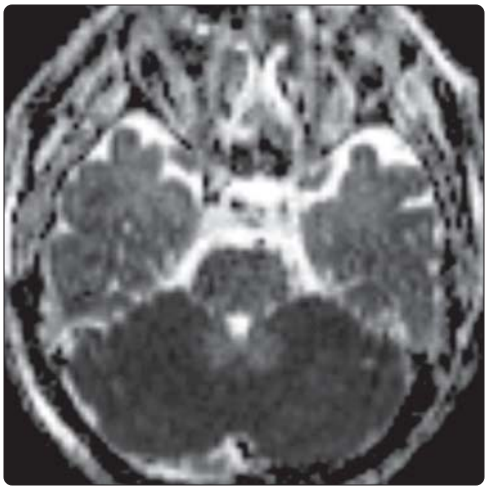

(Left) *Axial DWI MR demonstrates diffusely increased signal in bilateral cerebellar hemispheres* ➡. *Severe hypoxic ischemic injury can affect the cerebellum in the adult population. The Purkinje cells are exquisitely sensitive to ischemic damage. Immature Purkinje cells protects the cerebellar cortex in the neonatal population.* **(Right)** *Axial ADC shows corresponding diffusely decreased signal in bilateral cerebellar hemispheres related to cytotoxic edema.*

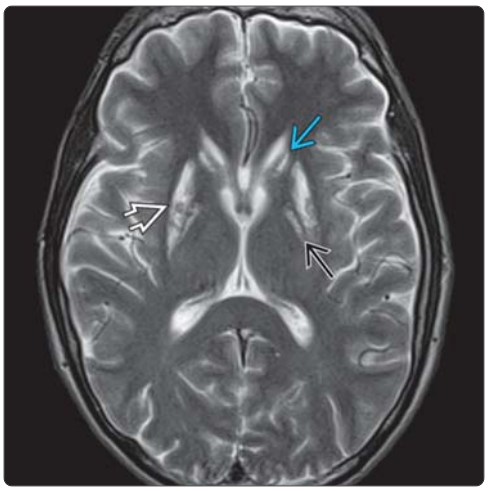

(Left) *Axial NECT shows diffuse cerebral parenchymal hypodensity with obscuration of the gray-white interfaces* ➡. *There is poor delineation of the deep gray nuclei* ➡. *The sulci & gyri are completely effaced. When hyperdensity of the cerebellum is seen, this indicates severe injury and a poorer prognosis.* **(Right)** *Axial T2 MR shows the chronic sequelae of severe HII in this 26-year-old man with hyperintensity & atrophy of the basal ganglia, including the caudate heads* ➡, *putamina* ➡, *& globi pallidi* ➡.

https://CafePezeshki.IR

KEY FACTS

TERMINOLOGY

- Hypotensive cerebral infarction (HCI)
  - Infarction resulting from insufficient cerebral blood flow to meet metabolic demands (low-flow state)
  - 2 types of border zone or watershed infarcts
    - Border zone between major arterial territories
      - Typically at cortex, gray-white matter junctions
    - Border zone between perforating arteries
      - Typically in deep white matter (WM)

IMAGING

- Best imaging tool
  - MR with DWI/ADC ± pMR
- Cortical border zone
  - Between major arterial territories
  - Typically at gray-white matter junctions
  - Hypodensity between vascular territories
- White matter border zone
  - Between perforating arteries
  - Typically in deep WM (centrum semiovale)
  - ≥ 3 lesions
  - Linear AP orientation → string of pearls appearance
  - If unilateral, look for stenosis of major vessel
- Imaging recommendations
  - MR + GRE, DWI, MRA (both cervical, intracranial)
  - ± pMR (may show ↓ CBF to affected areas)
  - NECT, pCT, CTA if MR not available
  - CTA/DSA > MRA for determining total vs. near-occlusion of ICA

TOP DIFFERENTIAL DIAGNOSES

- Acute embolic cerebral infarction(s)
- Arteriosclerosis ("small vessel disease")
- Posterior reversible encephalopathy (PRES)
- Vasculitis
- Pseudolaminar necrosis (other causes [e.g., Reye, lupus, etc.])

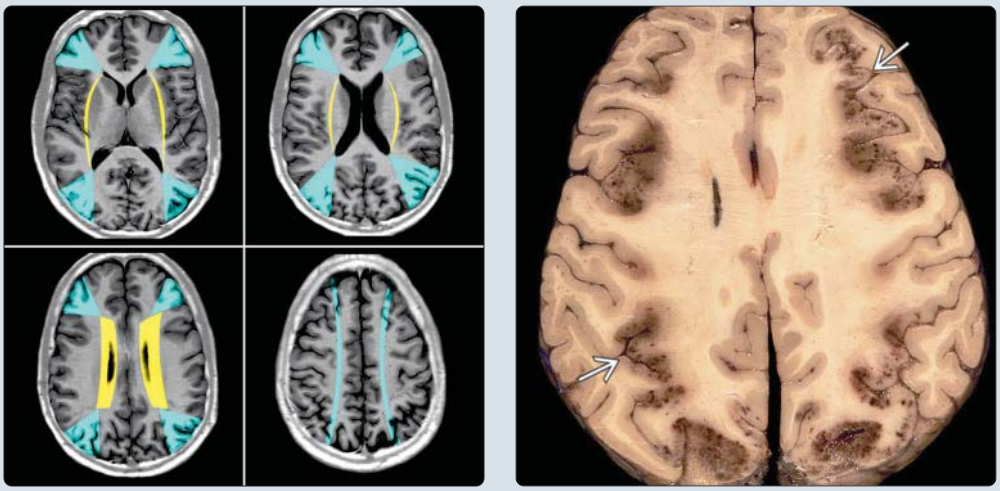

(Left) *T1WI show 2 watershed (WS) zones. External WS zones are depicted in turquoise. Yellow lines indicate internal (deep white matter [WM]) watershed zones between perforating arteries and major territorial vessels.* **(Right)** *Axial gross pathology shows classic external (cortical) watershed infarcts ➡ from cerebral hypoperfusion. The patient survived several days, allowing for petechial hemorrhagic transformation to occur.*

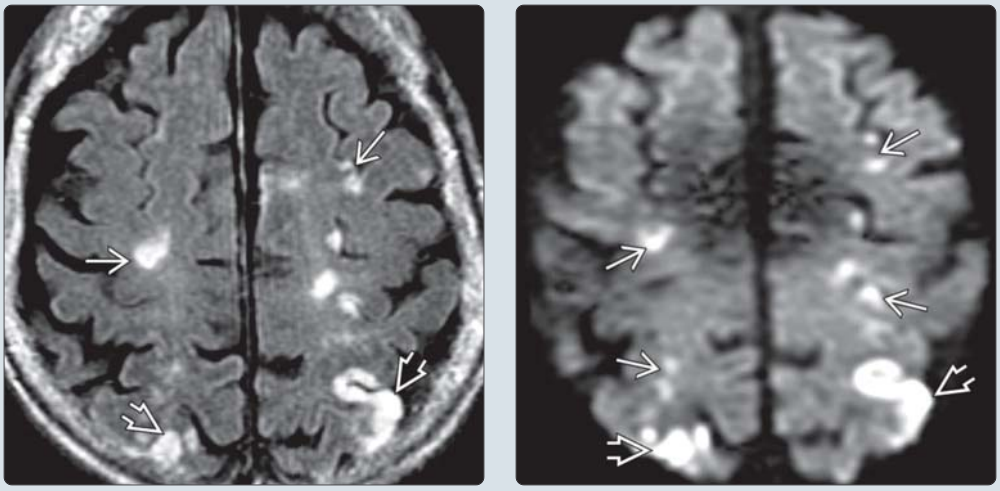

(Left) *Axial FLAIR MR in a patient with transient global hypoperfusion secondary to a hypotensive episode shows multifocal hyperintensities along the cortical watershed zone ➡. Changes are most severe at the confluence of the ACA, PCA, and MCA cortical vascular territories ➡.* **(Right)** *DWI in the same patient shows corresponding areas of restricted diffusion in the cortical watershed zones bilaterally ➡, most severe at the trivascular confluence ➡. The diagnosis was hypotensive watershed cerebral infarctions.*

https://CafePezeshki.IR

TERMINOLOGY

Abbreviations

- Hypotensive cerebral infarction (HCI)

Synonyms

- Border zone or watershed infarction

Definitions

- Infarction resulting from insufficient cerebral blood flow (CBF) to meet metabolic demands (low-flow state)

IMAGING

General Features

- Best diagnostic clue
  - Restricted diffusion on DWI/ADC
- Location
  - 2 types
    - Border zone between major arterial territories
      - Typically at gray-white matter junctions
    - Border zone between perforating arteries
      - Typically in deep white matter
  - Supratentorial structures in severe perinatal asphyxia
  - Bilateral abnormalities in global hypoxic-ischemic (HIE) events (with underlying vascular stenoses + relative hypoperfusion) can lead to unilateral presentations
- Morphology
  - Cortically based, wedge-shaped abnormality at border zone between vascular territories
  - Deep white matter (WM) watershed with rosary or string of pearls/beads appearance
    - Multiple round foci in linear orientation within centrum semiovale
  - Pseudolaminar necrosis = curvilinear, gyriform, cortical T1 shortening
  - Diffuse supratentorial abnormality (global HIE)

CT Findings

- NECT
  - Major arterial border zone infarcts
    - Hypodensity at gray-white matter junction between vascular territories
    - Severe (i.e., global HIE)
      - Usually significant hemodynamic compromise (i.e., hypotension)
      - Most all supratentorial gray-white matter junctions effaced
      - Basal ganglia (BG), thalami affected
      - Occasionally isolated to BG ± hippocampus
    - "White" cerebellum (sometimes called cerebellar reversal sign)
      - Cerebellum appears relatively hyperdense compared to supratentorial hypodensity
  - Deep WM watershed infarcts
    - ≥ 3 deep WM lesions within centrum semiovale
    - String of pearls appearance
      - Linear orientation in AP (front to back) direction
      - Parallel to lateral ventricle
      - Can resemble multiple emboli
    - Can be unilateral
      - Look for major vessel stenosis on side of infarcts
    - Bilateral if bilateral vessel stenoses ± significant hemodynamic event
- CECT
  - Enhancement in subacute HCI
- CTA
  - Use to determine complete vs. near-complete ICA occlusion
- CT perfusion
  - CBF ↓ in affected areas

MR Findings

- T1WI
  - Acute: Hypointense, swollen gyri ± BG
  - Subacute: Gyriform cortical hyperintensity = pseudolaminar necrosis
    - Usually with global HIE
- T2WI
  - Hyperintensity in involved areas
  - CSF cisterns/sulci compressed if severe
- FLAIR
  - Thrombosed vessels often hyperintense
  - More sensitive to early infarction
- DWI
  - Restricted diffusion (hyperintense on DWI, hypointense ADC)
    - Distinguishes cytotoxic from vasogenic edema
    - Helpful for evaluation following intraoperative anoxia
  - Global HIE may be diffusely hyperintense
    - Creates nearly "pseudonormal" appearance
- T1WI C+
  - Subacute infarcts enhance
    - Gyriform pattern common
    - ± basal ganglia
- MRA
  - Major vessel stenoses predispose to watershed infarction following hypotensive event
- MRS
  - ↑ lactate, ↓ NAA ± lactate doublet (intermediate TE)

Angiographic Findings

- DSA may delineate predisposing conditions for watershed infarct
  - Significant extracranial, major intracranial vessel stenosis

Imaging Recommendations

- Best imaging tool
  - MR + GRE, MRA, DWI
- Protocol advice
  - MR + DWI, MRA (both cervical, intracranial), ± pMR
  - NECT, pCT, CTA if MR unavailable

DIFFERENTIAL DIAGNOSIS

Cerebral Infarction (Acute, Multiple Embolic)

- Often bilateral, multiterritorial
- May also occur at border zones

Arteriosclerosis ("Small Vessel Disease")

- Scattered, multifocal lesions
- No specific predilection for watershed
- Confluent lesions around lateral ventricle atria
  - Common in chronic hypertension

https://CafePezeshki.IR

Posterior Reversible Encephalopathy (PRES)

- Usually does not restrict (vasogenic edema)
- Usually cortical/subcortical PCA distribution
- Less commonly can involve watershed zones, BG

Vasculitis

- Often subcortical
- Patchy enhancement in cortex, subcortical WM, BG

Pseudolaminar Necrosis (Other Causes)

- Associations with numerous other entities
  - Reye, lupus, central pontine myelinolysis, immunosuppressive therapy
- Petechial hemorrhage ("hemorrhagic transformation") in subacute thrombolic infarct

PATHOLOGY

General Features

- Etiology
  - Global brain injury due to disruption of perfusion or oxygenation
  - Causes include severe prolonged hypotension, cardiac arrest with resuscitation, profound asphyxia, and carbon monoxide inhalation
  - Major vessel stenoses predispose patient to infarcts at "border zone" between vascular territories during times of hemodynamic compromise
    - Deep WM infarcts (rosary pattern) correlate well with clinical hemodynamic compromise
    - Associated with proximal ICA stenosis/occlusion
  - Embolic infarcts also occur at border zones and thus complicate clinical and radiographic picture
    - Cortical border zone infarcts occur in 3.2% in patients with cardiac embolic sources
      - Compared to 3.6% in those with severe ICA obstruction
    - Directed embolization may account for many embolic-type, border zone infarcts (directional flow at bifurcations occurs from vessel size imbalances in circle of Willis)
- Border zone infarction → encephalomalacic brain ± "ulegyria"

Staging, Grading, & Classification

- Pattern classifications
  - Cortical border zone infarcts (bi- or unilateral)
  - Deep WM infarcts (penetrating artery watershed zone)
  - Cortical pseudolaminar necrosis
  - Predominately deep gray nuclei

Gross Pathologic & Surgical Features

- Pale, swollen brain; gray-white matter boundaries "smudged"
- Encephalomalacia (chronic)

Microscopic Features

- After 4 hours: Eosinophilic neurons with pyknotic nuclei
- 15-24 hours: Neutrophils invade, necrotic nuclei look like eosinophilic "ghosts"
- 2-3 days: Blood-derived phagocytes
- 1 week: Reactive astrocytosis, ↑ capillary density
- End result: Fluid-filled cavity lined by astrocytes
- Pseudolaminar necrosis affects 3rd, 5th, and 6th cortical layers

CLINICAL ISSUES

Presentation

- Most common signs/symptoms
  - Altered mental status, coma
- Clinical profile
  - Patient with high-grade ICA stenosis, transient hypotension leading to acute cerebral infarction
  - Resuscitated patient with profound asphyxia or prolonged systemic hypotension

Demographics

- Age
  - Any age
- Gender
  - No gender predilection
- Epidemiology
  - Hypotensive infarcts account for 0.7-3.2% of infarcts

Natural History & Prognosis

- Experimental literature suggests isolated hypoxic injury tolerated better than hypoxia complicated by hypotension
- Clinical outcome usually poor; depends on degree of injury
- Diffusion abnormalities restricted to deep nuclei without involvement of cerebral cortex suggest milder injury, and significant neurological recovery can occur

Treatment

- Treatment of underlying conditions
  - Correction of hypotension as rapidly as possible
  - Revascularization of major vessel stenoses

DIAGNOSTIC CHECKLIST

Consider

- MRA, CTA of cervical, intracranial vessels as proximal large vessel disease often present in setting of hypotensive infarction

Image Interpretation Pearls

- "Rosary" or "string of beads" appearance in centrum semiovale highly specific for hemodynamic compromise

SELECTED REFERENCES

1. Greer DM et al: Neuroprognostication of hypoxic-ischaemic coma in the therapeutic hypothermia era. Nat Rev Neurol. 10(4):190-203, 2014
2. van der Eerden AW et al: White matter changes in comatose survivors of anoxic ischemic encephalopathy and traumatic brain injury: comparative diffusion-tensor imaging study. Radiology. 270(2):506-16, 2014
3. Phipps MS et al: Orthostatic hypotension among outpatients with ischemic stroke. J Neurol Sci. 314(1-2):62-5, 2012
4. Moore MJ et al: Reducing the gray zone: imaging spectrum of hypoperfusion and hypoxic brain injury in adults. Emerg Radiol. 17(2):123-30, 2010
5. Chen CJ et al: Multi-Slice CT angiography in diagnosing total versus near occlusions of the internal carotid artery: comparison with catheter angiography. Stroke. 35(1):83-5, 2004
6. Derdeyn CP et al: Severe hemodynamic impairment and border zone–region infarction. Radiology. 220(1):195-201, 2001

https://CafePezeshki.IR

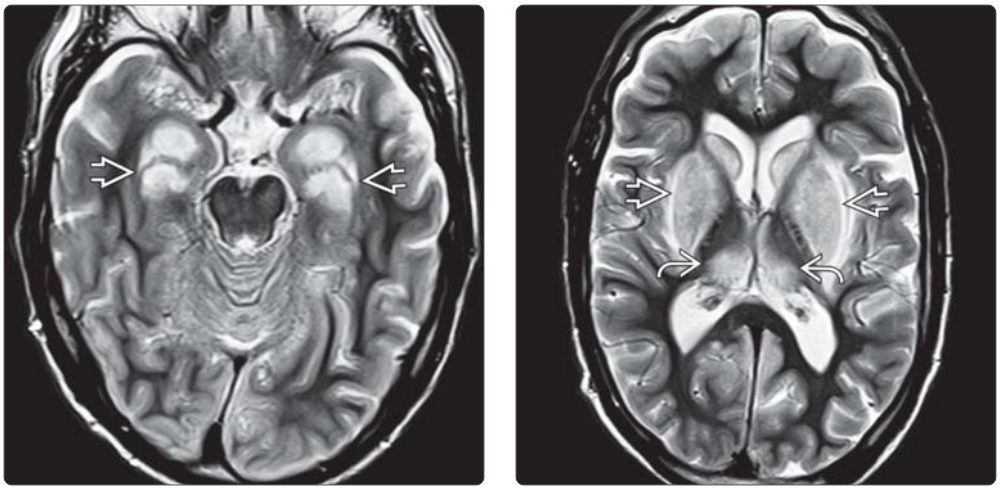

(Left) *Axial T2WI in a 53-year-old man who suffered a cardiac arrest with prolonged resuscitation shows symmetric hyperintensity in both hippocampi ⇨. While not as noticeable, the cortical gray matter is also diffusely hyperintense.* **(Right)** *More cephalad T2WI in the same patient shows symmetric hyperintensity in the basal ganglia ⇨ and both thalami ⇨.*

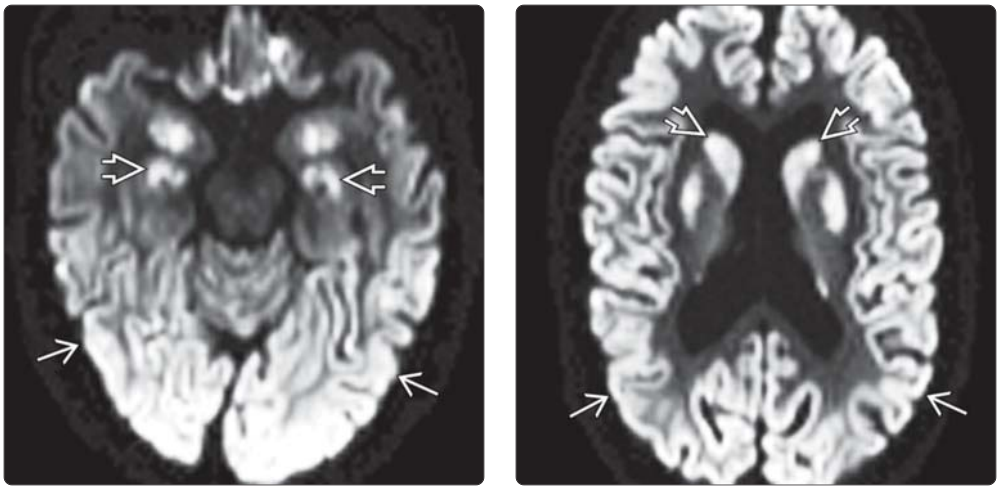

(Left) *DWI in the same patient shows symmetric diffusion restriction in the hippocampi ⇨ and cortex ⇨.* **(Right)** *More cephalad DWI shows restricted diffusion in the basal ganglia ⇨. The symmetric diffusion restriction in the cortex ⇨ greatly accentuates the gray-white interface.*

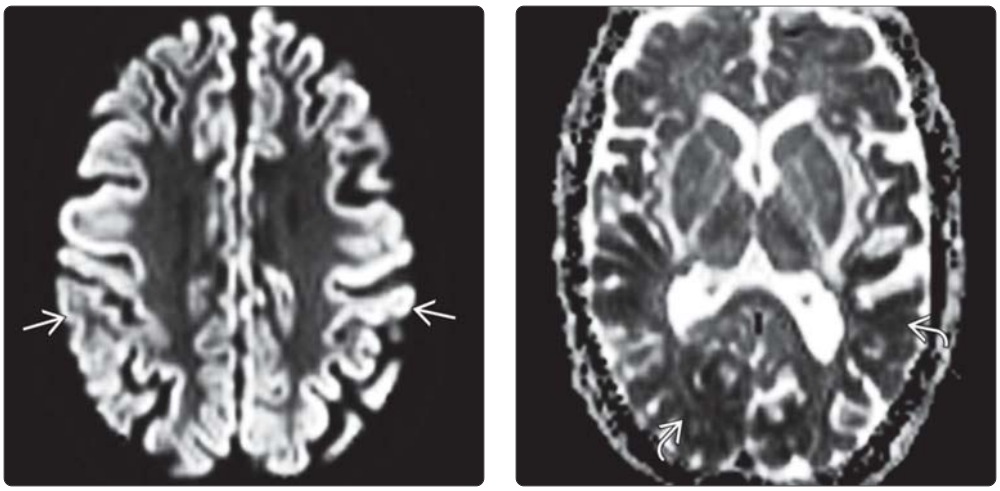

(Left) *More cephalad image through the corona radiata shows the "super bright" cortex ⇨. The restricted diffusion is so severe and symmetric that it can be overlooked.* **(Right)** *ADC in the same patient through the basal ganglia shows that the restricted diffusion probably also involves the subcortical and deep white matter ⇨ in addition to the cortex and basal ganglia.*

https://CafePezeshki.IR

KEY FACTS

TERMINOLOGY

- Acute alteration of neurologic function due to loss of vascular integrity

IMAGING

- Best imaging
  - MR with diffusion, perfusion, MRA
  - MRV if MRA negative and DWI positive
  - Can do emergent "limited" MR (FLAIR, DWI, SWI)
- Imaging findings
  - CT
    - "Insular ribbon" sign = loss of distinction of insular cortex
    - Hyperdense MCA sign (HMCAS) = increased density of thrombosed MCA
    - Look for calcified emboli (suggests heart disease)
    - ± CTA
  - MR
    - DWI is most sensitive imaging sequence for ischemic injury
    - Perfusion studies can identify ischemic penumbra
    - FLAIR may show intravascular signal
    - Arterial wall imaging may identify vasculopathy

PATHOLOGY

- Etiology
  - Most common: Cardiac disease (25-50%)
  - Other: Sickle cell (200-400x increased risk), trauma
  - No underlying cause discovered in > 33% of cases

CLINICAL ISSUES

- Under-recognized as significant source of morbidity in pediatric population
  - Can be mistaken for seizure (postictal), migraine
  - Children with stroke often have delayed presentation
  - High risk of recurrence (20-40%), especially with calcified emboli

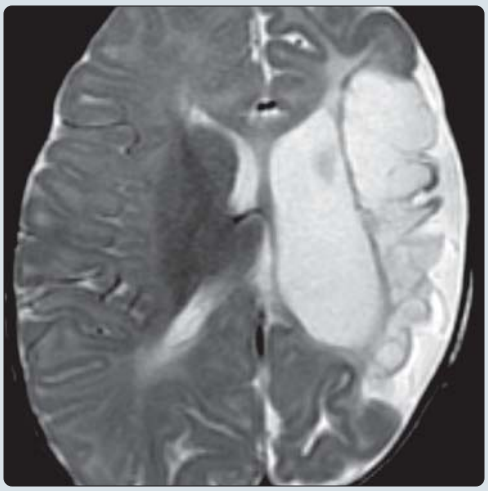

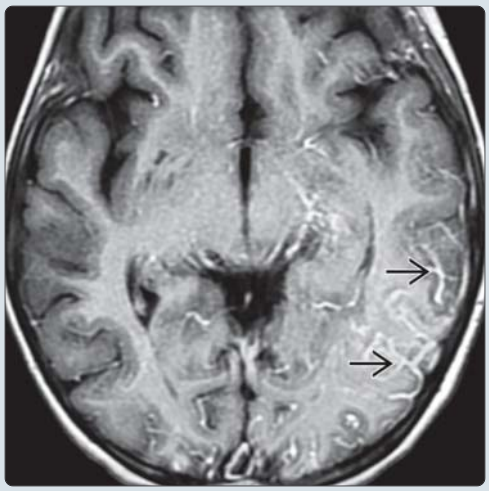

(Left) *Axial T2WI MR shows mature encephalomalacia in the vascular territory of the left MCA in this 4 month old with left hand preference. Handedness should not be apparent before 12-18 months.* **(Right)** *Axial T1WI C+ MR shows the characteristic "climbing ivy" sign of enhancing sulcal arteries ⇨ in a child with moyamoya vasculopathy secondary to sickle cell disease. Slow flow in MCA branches distal to the stenosis allows T1 shortening from contrast to overcome flow void effects.*

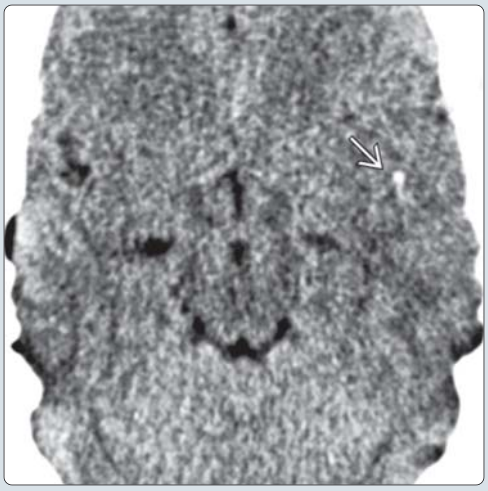

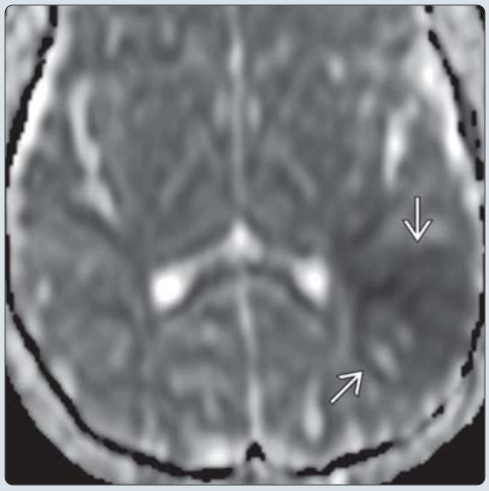

(Left) *Axial NECT in 15 year old with difficulty speaking and right hand weakness shows a hyperdense MCA ⇨. The patient presented 12 hours after symptom onset and was treated with aspirin only.* **(Right)** *Axial ADC in the same teenager shows reduced diffusion ⇨ in the distal left MCA territory. Encephalomalacia developed, but the patient had a normal neurologic exam 6 months later. Children often have a much greater capacity for neurologic recovery than adults, even with similar imaging findings.*

https://CafePezeshki.IR

TERMINOLOGY

Synonyms

- Cerebral infarct, cerebral ischemia

Definitions

- Acute alteration of neurologic function due to loss of vascular integrity
  - Can be arterial or venous
  - Can be hemorrhagic or nonhemorrhagic

IMAGING

General Features

- Best diagnostic clue
  - Edema, restricted diffusion in affected territory
- Location
  - Proximal and distal middle cerebral artery (MCA) territory is most commonly affected
- Morphology
  - Stroke caused by arterial occlusion often conforms to arterial territory
  - Venous territories typically less well recognized

CT Findings

- NECT
  - Decreased attenuation of affected gray matter (GM)
    - "Insular ribbon" sign
      - Loss of distinction of insular cortex
  - Hyperdense MCA sign (HMCAS)
    - Increased density of thrombosed MCA
  - Hemorrhagic conversion of stroke
    - Cortical hemorrhage often petechial
    - White matter (WM) or deep nuclear hemorrhage often mass-like
      - Hematoma within infarcted tissue
  - Hyperdense dural sinus in venous thrombosis
    - "Delta" sign
- CECT
  - Enhancement of infarcted territory typically occurs after 5-7 days
  - Enhancement of sagittal sinus wall around nonenhancing clot
    - "Empty delta" sign
- CTA
  - Invaluable for demonstrating focal vascular abnormalities in acute setting
  - Can clearly show arterial occlusion/stenosis
  - Can be used to assess effect of treatment on vessel
    - Restoration of vascular integrity may not correlate with return of neurologic function

MR Findings

- T1WI
  - Gyral swelling and hypointensity in affected territory
  - Loss of normal vascular flow void
    - Entry slice artifact can cause false-positive
    - Irregular signal can be seen in normal veins due to slow flow
- T1WI FS
  - Use of fat saturation allows confident identification of crescent of mural hematoma in dissected vessel
    - Use in combination with MRA
- T2WI
  - Edema evident in affected territory after 12-24 hours of arterial occlusion
- FLAIR
  - More sensitive than T2WI for ischemia-induced cytotoxic edema
    - Hyperintense after 6-12 hours
  - Also shows loss of normal arterial flow voids
    - "Climbing ivy" sign = bright vessels in sulci distal to arterial occlusion (slow flow)
      - Same effect is seen with T1WI C+
      - Classically seen in moyamoya disease
- T2* GRE
  - Sensitive for detection of blood products, especially hemosiderin
    - May impact clinical decision making for acute therapy
- DWI
  - Most sensitive imaging sequence for ischemic injury
  - Diffusion restriction seen within 45 minutes of arterial occlusion
  - Apparent diffusion coefficient (ADC) mapping essential to avoid false-positive from T2 shine through
- PWI
  - Can provide valuable information regarding region at risk in setting of acute stroke
  - Ischemic penumbra = region with diminished perfusion not yet infarcted (perfusion-diffusion mismatch)
  - May define brain salvageable with acute stroke therapy
  - Arterial spin-labeling techniques hold promise for standardized perfusion imaging without contrast administration
- T1WI C+
  - Can provide earliest sign of proximal arterial occlusion = enhancement of arteries in territory distal to occlusion
    - Collateral flow to distal vascular bed is slower
    - Normal flow void caused by rapid arterial flow is outweighed by T1 shortening effect of contrast
  - Arterial wall imaging (3D acquisition, 1 mm spin-echo with contrast) may identify vasculopathy
- MRA
  - Sensitive in detection of arterial occlusion and stenosis in large and medium-sized cerebral vessels
- MRV
  - Can demonstrate focal occlusion, stenosis, or response to treatment
- MRS
  - ↑ lactate is hallmark of ischemia/infarct

Ultrasonographic Findings

- Grayscale ultrasound
  - Affected territory hyperechoic in acute/subacute stage
- Color Doppler
  - Direct Doppler evaluation ideal for surveillance of vascular occlusion in neonate with open sutures
  - Transcranial Doppler evaluation of circle of Willis through temporal squamosa
    - Increased velocities can predict stenoses detectable by MRA

https://CafePezeshki.IR

- Used as screening tool in children with sickle cell anemia

Angiographic Findings

- Catheter angiography rarely necessary in acute evaluation of childhood stroke
  - Only justified if contemplating endovascular therapy
- Best modality for detailed evaluation of primary arteriopathies

Imaging Recommendations

- Best imaging tool
  - MR with diffusion, perfusion, MRA
    - MRV if MRA negative and DWI positive
  - Can do emergent "limited" MR (FLAIR, DWI, SWI)

DIFFERENTIAL DIAGNOSIS

Mitochondrial Encephalopathies

- Mitochondrial myopathy, encephalopathy, lactic acidosis, and strokelike episodes syndrome (MELAS), myoclonic epilepsy with ragged red fibers (MERRF)

Encephalitis

- Viral encephalitides, ADEM, cerebritis

Toxins

- Carbon monoxide poisoning, ethylene glycol

PATHOLOGY

General Features

- Etiology
  - No underlying cause discovered in > 33% of cases
- Associated abnormalities
  - Cardiac disease (25-50%), sickle cell (200-400x increased risk), trauma
  - Chemotherapy, sepsis

Gross Pathologic & Surgical Features

- Pathologic findings similar to adults
- Anterior circulation > posterior; left > right

CLINICAL ISSUES

Presentation

- Most common signs/symptoms
  - Focal deficit often masked by lethargy, coma, irritability
  - Seizure = deficit often attributed to postictal state
- Other signs/symptoms
  - Speech difficulties, gait abnormality
  - Preceding transient events occur in 25%
- Under-recognized as significant source of morbidity in pediatric population
  - Children with stroke typically present in delayed fashion (> 24 hours)
    - Poor recognition/understanding of symptoms by child, caregiver, physician

Demographics

- Age
  - Incidence/mortality greatest in infants < 1 year old
- Gender
  - Boys > girls
- Epidemiology
  - 2-3/100,000 per year in USA
  - Mortality: 0.6/100,000
  - "Stroke belt"
    - Higher incidence in southeastern United States
  - Recent head/neck injury or infection increases odds ratio for stroke
  - Recognize syndromes with vasculopathy (NF1, PHACE, sickle cell disease)

Natural History & Prognosis

- Recurrence (20-40%)
- Capacity for recovery much greater than in adults
  - Fewer concomitant risk factors
  - Better quality of collateral vessels

Treatment

- Clinical window of opportunity/benefit much narrower than in adults
- Aspirin is mainstay of chronic therapy for fixed vascular lesions and vasculopathies
- Transfusion therapy for at-risk children with sickle cell disease
- Thrombolytic therapy has been used in a small number of cases
  - Higher than acceptable risk of hemorrhage
  - Use is mitigated by good outcome with less aggressive therapy in many cases

DIAGNOSTIC CHECKLIST

Consider

- Always consider stroke when evaluating a child with new onset seizure

Reporting Tips

- Be sure to investigate for hemorrhagic complications

SELECTED REFERENCES

1. Amlie-Lefond C et al: Factors Associated with the Presentation of Moyamoya in Childhood. J Stroke Cerebrovasc Dis. ePub, 2015
2. Hamilton W et al: Cost and Outcome in Pediatric Ischemic Stroke. J Child Neurol. ePub, 2015
3. Kirton A et al: Paediatric stroke: pressing issues and promising directions. Lancet Neurol. 14(1):92-102, 2015
4. Miteff CI et al: Acute 'limited' magnetic resonance imaging in childhood stroke-an illustrative case. Emerg Radiol. ePub, 2015
5. Ahmadzadeh KL et al: Pediatric stroke presenting as a seizure. Case Rep Emerg Med. 2014:838537, 2014
6. Singhal NS et al: Role of trauma and infection in childhood hemorrhagic stroke due to vascular lesions. Neurology. 81(6):581-4, 2013
7. Hills NK et al: Recent trauma and acute infection as risk factors for childhood arterial ischemic stroke. Ann Neurol. 72(6):850-8, 2012

https://CafePezeshki.IR

(Left) *A teenage male with a history of multiple surgeries for repair of supravalvular pulmonary stenosis and aortic valve stenosis complicated by bacterial endocarditis had sudden onset of right hemiparesis. NECT scan shows an ovoid calcification ➡ in the right sylvian fissure and a second calcific density in the left occipital lobe ➡.* **(Right)** *Coronal MIP view of the CT angiogram obtained immediately after the NECT scan shows the calcific density ➡ straddles the terminal ICA bifurcation.*

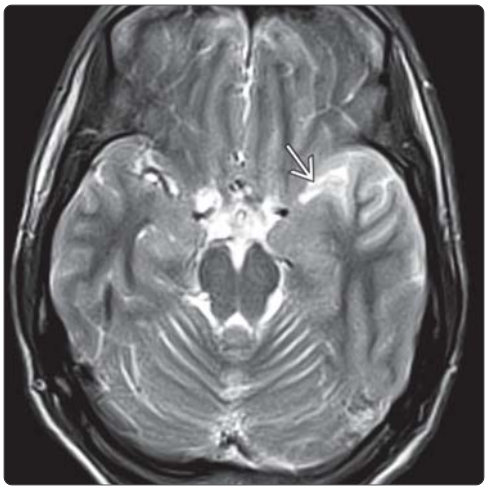

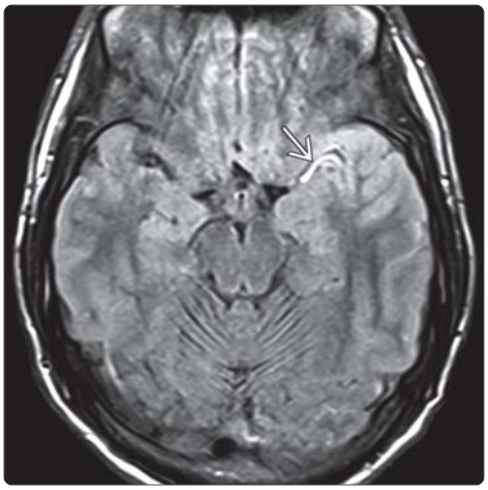

(Left) *Axial T2WI in the same patient shows absent "flow void" in the horizontal segment of the left MCA ➡ compared to the normal right MCA.* **(Right)** *Axial FLAIR in the same patient shows intravascular signal in the left M1 MCA ➡ consistent with slow flow.*

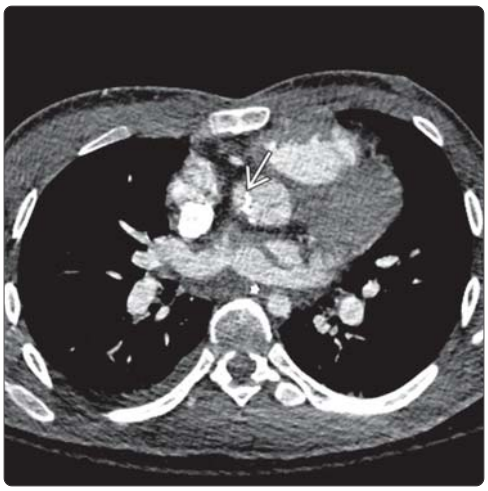

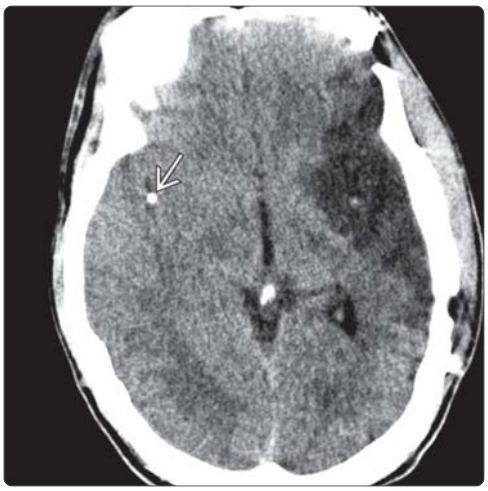

(Left) *Axial CT angiogram of the chest shows calcification of the noncoronary aortic cusp ➡. The patient underwent repeat aortic valve replacement.* **(Right)** *Despite the surgery, the patient represented 1 month later with acute onset of left-sided weakness. A new calcified embolus is present in the right sylvian fissure ➡. Pediatric strokes are often caused by cardiac disease (25-50%).*

https://CafePezeshki.IR

Cerebral Hemiatrophy

KEY FACTS

TERMINOLOGY
- Cerebral hemiatrophy (CH)
- Dyke-Davidoff-Masson syndrome (DDMS)

IMAGING
- General findings
  - Unilateral cerebral atrophy
  - Ipsilateral paranasal sinuses, mastoid hyperpneumatized
  - Ipsilateral calvarial thickening
- Associated findings
  - Ipsilateral cerebral peduncle, thalamus atrophic (wallerian degeneration)
  - ± crossed cerebellar atrophy/diaschisis
- MR may be helpful for etiology of hemiatrophy
  - Vascular/infectious insult
  - Encephalomalacia/gliosis
  - Corresponding T2/FLAIR hyperintensity

TOP DIFFERENTIAL DIAGNOSES
- Sturge-Weber syndrome
- Rasmussen encephalitis
- Hemimegalencephaly
- Large MCA infarction

PATHOLOGY
- In utero/early childhood (< 3 years) hemispheric insult
  - Unilateral
  - Usually vascular, traumatic, less commonly infectious
  - Lack of ipsilateral brain growth
  - Calvarial diploic spaces, sinuses expand inward

CLINICAL ISSUES
- Contralateral hemiplegia/hemiparesis
- Facial asymmetry, mental retardation
- Hemispherectomy for intractable seizures
  - 85% success rate if performed early

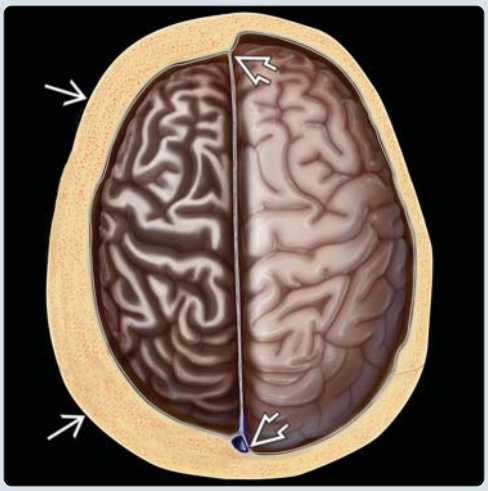

(Left) *Graphic depicts Dyke-Davidoff-Masson syndrome. The right hemisphere is shrunken and atrophic with a thickened overlying calvaria. If the insult occurs early in development, the falx will be inserted off midline.* **(Right)** *Coronal T1WI C+ FS MR shows an atrophic right hemisphere. The falx inserts off midline, and the left temporal bone is expanded and the mastoid ridge is elevated. The calvaria is thickened compared to the normal left side. (Courtesy M. Edwards-Brown, MD.)*

(Left) *Axial T2 MR image in a 16 year old with seizures and hemiparesis shows the classic features of Dyke-Davidoff-Masson syndrome with left hemisphere volume loss, thickened calvaria, and a markedly enlarged frontal sinus.* **(Right)** *Axial FLAIR MR in the same patient shows cortical atrophy and white matter gliosis. Note the enlarged lateral ventricle and the thickened calvaria. Lack of ipsilateral brain growth causes calvarial thickening and enlargement and hyperpneumatization of the paranasal sinuses.*

https://CafePezeshki.IR

TERMINOLOGY

Abbreviations

- Cerebral hemiatrophy (CH)

Synonyms

- Dyke-Davidoff-Masson syndrome (DDMS)

Definitions

- Syndrome of hemiplegia, seizures, facial asymmetry, and mental retardation

IMAGING

General Features

- Best diagnostic clue
  - Unilateral cerebral atrophy plus
    - Ipsilateral calvarial thickening
    - Ipsilateral paranasal sinuses, mastoid hyperpneumatized
- Location
  - 70% left hemisphere predominance
  - Right hemisphere ↑ perfusion may be protective in first 3 years of life

Imaging Recommendations

- Best imaging tool
  - NECT + bone CT

Radiographic Findings

- Radiography
  - Unilateral calvarial thickening
  - Ipsilateral expansion of paranasal sinuses, mastoid air cells
  - Elevation of ipsilateral greater sphenoid wing, petrous ridge

CT Findings

- NECT
  - Cerebral hemiatrophy
    - Enlarged sulci, CSF spaces
    - Ipsilateral enlarged ventricles
  - Ipsilateral hyperpneumatization
    - Paranasal sinuses
    - Mastoid air cells
  - ± contralateral mild compensatory hemispheric hypertrophy
- Bone CT
  - Ipsilateral calvaria may be thickened

MR Findings

- MR may be helpful for etiology of hemiatrophy
  - Hyperintensity on T2/FLAIR
  - Encephalomalacia, gliosis (vascular or infectious insult)
- Wallerian degeneration
  - Ipsilateral cerebral peduncle, thalamic atrophy

DIFFERENTIAL DIAGNOSIS

Sturge-Weber Syndrome

- Facial port wine stain + ipsilateral atrophy
- Pial angioma + dystrophic cortical Ca++
- Ipsilateral choroid plexus enlarged
- Skull, sinuses, mastoid may resemble DDMS

Rasmussen Encephalitis

- Rare cause of focal intractable seizures
- Hemiatrophy centered in medial temporal lobe, around sylvian fissure
- No calvarial features of DDMS

Hemimegalencephaly

- Hamartomatous overgrowth of cerebral hemisphere
- Smaller side is normal

Large MCA Infarction

- Atrophy limited to MCA distribution
- Insult after significant calvarial growth has occurred
- Lacks DDMS calvarial changes

PATHOLOGY

General Features

- Etiology
  - In utero/early childhood, unilateral hemispheric insult
    - Usually vascular, traumatic, or less commonly infectious
  - Lack of ipsilateral brain growth
    - Calvarial diploic spaces, sinuses expand inward
- Associated abnormalities
  - Crossed cerebellar atrophy/diaschisis

CLINICAL ISSUES

Presentation

- Most common signs/symptoms
  - Contralateral hemiplegia/hemiparesis
  - Seizures, mental retardation

Demographics

- Age
  - Any age
  - Insult typically in utero or early childhood (< 3 years old)
- Gender
  - Males (70%), females (30%)
  - Males may be functionally more "hemispherically asymmetric"

Treatment

- Hemispherectomy for intractable seizures
  - 85% success rate if performed early

SELECTED REFERENCES

1. Biçici V et al: Dyke-Davidoff-Masson syndrome in adulthood: A 50-year diagnostic delay. Neurology. 83(12):1121, 2014
2. Park KI et al: Dyke-davidoff-masson syndrome: cases of two brothers and literature review. J Epilepsy Res. 4(1):24-7, 2014
3. Slon V et al: Dyke-Davidoff-Masson syndrome in a 6,000-year old skull. Neuroradiology. 54(12):1413-5, 2012
4. Atalar MH et al: Cerebral hemiatrophy (Dyke-Davidoff-Masson syndrome) in childhood: clinicoradiological analysis of 19 cases. Pediatr Int. 49(1):70-5, 2007
5. Unal O et al: Left hemisphere and male sex dominance of cerebral hemiatrophy (Dyke-Davidoff-Masson Syndrome). Clin Imaging. 28(3):163-5, 2004

https://CafePezeshki.IR

KEY FACTS

TERMINOLOGY

- Interrupted blood flow to brain resulting in cerebral ischemia/infarction with variable neurologic deficit

IMAGING

- Major artery (territorial) infarct
  - Generally wedge-shaped; both gray matter (GM), white matter (WM) involved
- Embolic infarcts
  - Often focal/small, at GM-WM interface
- NECT
  - Hyperdense vessel = clot ("dense MCA" sign)
  - Loss of GM-WM distinction in first 3 hours (50-70%)
    - "Insular ribbon" sign: GM-WM interface lost
    - "Disappearing basal ganglia" sign
  - Calcified embolus
    - Don't miss this (high risk of recurrent stroke)
- CTA: Excellent for major vessel occlusions
- pCT: CBF/CBV "mismatch" estimates penumbra
- MR
  - Parenchymal ± intraarterial FLAIR hyperintensity
  - ↑ intensity on DWI with corresponding ↓ on ADC
  - ↓ CBF, CBV on perfusion MR

TOP DIFFERENTIAL DIAGNOSES

- Hyperdense vessel mimics
- Parenchymal hypodensity (nonvascular causes)

PATHOLOGY

- Severely ischemic core
  - CBF < (6-8 cm^3)/(100 g/min)
- Peripheral penumbra
  - CBF between (10-20 cm^3)/(100 g/min)

CLINICAL ISSUES

- 2nd most common cause of death worldwide
- #1 cause of morbidity in USA
- IV thrombolysis (< 3 hours of symptom onset)

(Left) *Coronal graphic illustrates left M1 occlusion. Proximal occlusion affects the entire MCA territory, including the basal ganglia (perfused by lenticulostriate arteries ⇨). Acute ischemia is often identified by subtle loss of the gray-white interfaces with blurring of the basal ganglia and an "insular ribbon" sign on the initial CT.* **(Right)** *NECT scan in a 46-year-old man shows a very "dense" left MCA ⇨ compared to the normal minimally hyperdense right MCA ⇨.*

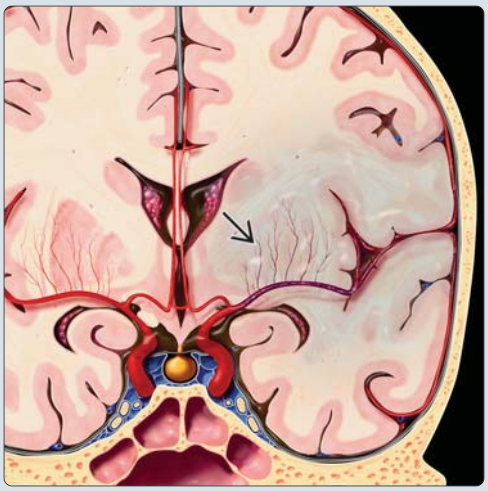

(Left) *Coronal MIP view of the CTA in the same patient shows a proximal left MCA occlusion ⇨. Minimal filling of the distal MCA branches ⇨ is occurring via collaterals from the ACA and PCA.* **(Right)** *Axial CT perfusion shows decreased cerebral blood flow in the left MCA distribution ⇨.*

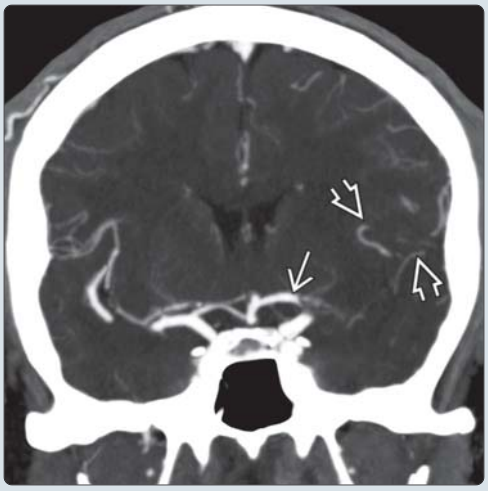

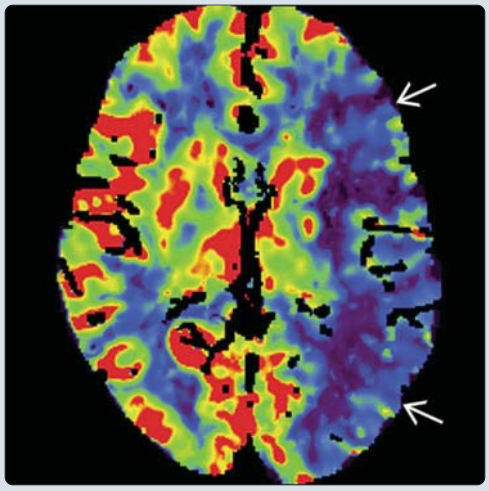

https://CafePezeshki.IR

TERMINOLOGY

Synonyms

- Stroke, cerebrovascular accident (CVA), brain attack

Definitions

- Interrupted blood flow to brain resulting in cerebral ischemia/infarction with variable neurologic deficit

IMAGING

General Features

- Best diagnostic clue
  - High signal on DWI with corresponding low signal on ADC (reduced diffusivity)
  - Decreased cerebral blood flow (CBF) and cerebral blood volume (CBV) on CT or MR perfusion
- Location
  - ≥ 1 vascular territories or at border-zones ("watershed")
- Size
  - Dependent on degree of compromise and collateral circulation
- Morphology
  - Territorial infarct
    - Conforms to arterial territory
    - Generally wedge-shaped, both gray matter (GM) and white matter (WM) involved
  - Embolic infarcts (often focal, at GM/WM interface)

CT Findings

- NECT
  - Hyperdense vessel (high specificity, low sensitivity)
    - Represents acute thrombus in cerebral vessel(s)
    - Hyperdense M1 MCA in 35-50%
    - "Dot" sign: Occluded MCA branches in sylvian fissure (16-17%)
  - Loss of GM-WM distinction in 1st 3 hours (50-70%)
    - Obscuration of deep gray nuclei
    - Loss of cortical "ribbon"
  - Parenchymal hypodensity
    - If > 1/3 MCA territory initially, larger lesion usually develops later
    - Temporary transition to isodensity (up to 54%) at 2-3 weeks post ictus (CT "fogging")
  - Gyral swelling, sulcal effacement appears between12-24 hours
  - "Hemorrhagic transformation" in 15-45%
    - Delayed onset (24-48 hours) most typical
    - Can be gross (parenchymal) or petechial
  - Calcified embolus
    - Round/ovoid hyperdensity in vessel lumen or sulcus
    - Source: Heart (calcific valvular disease) > cervical ASVD
    - High risk for recurrent strokes
- CECT
  - Enhancing cortical vessels: Slow flow or collateralization acutely
  - Absent vessels: Occlusion
  - Perfusion CT (pCT): Assess ischemic core vs. penumbra; identify patients who benefit most from revascularization
    - pCT calculates CBF, CBV, time to peak (TTP); deconvolution can give mean transit time (MTT)
  - Cortical/gyral enhancement after 48-72 hours
- CTA: Identify occlusions, dissections, stenoses, status of collaterals

MR Findings

- T1WI
  - Early cortical swelling and hypointensity, loss of GM-WM borders
- T2WI
  - Cortical swelling, hyperintensity develops by 12-24 hours
  - May normalize 2-3 weeks post ictus (MR "fogging")
- FLAIR
  - Parenchymal hyperintensity appears (6 hours post ictus) while other sequences normal
  - Intraarterial FLAIR hyperintensity is early sign of major vessel occlusion or slow flow
- T2* GRE
  - Detection of acute blood products
  - Arterial "blooming" (thrombosed vessel) from clot susceptibility
  - May see susceptibility from Ca++ embolus
- DWI
  - Hyperintense (cytotoxic edema)
    - Improves hyperacute stroke detection to 95%
    - Usually correlates to "infarct core" (final infarct size); some diffusion abnormalities reversible (TIA, migraine)
    - May have reduced sensitivity in brainstem and medulla in first 24 hours
    - Restriction typically lasts 7-10 days
      - High signal can persist up to 2 months post ictus
      - After 10 days, T2 effect may predominate over low ADC: T2 "shine-through"
  - Corresponding low signal on ADC maps
    - May normalize after tissue reperfusion
    - Hyper- or isointensity on ADC map (T2 "shine-through") may mimic diffusion restriction
  - Distinguish cytotoxic from vasogenic edema in complicated cases
    - May be helpful to evaluate new deficits after tumor resection
- PWI
  - Dynamic contrast bolus or arterial spin labeled techniques
    - Maximum slope gives relative CBF, CBV
    - Deconvolution gives absolute values
  - Bolus-tracking T2* gadolinium perfusion imaging (PWI) with CBV map
    - ↓ perfusion; 75% larger than DWI abnormality
    - DWI/PWI "mismatch": Penumbra or "at-risk" tissue
- T1WI C+
  - Variable enhancement patterns evolve over time
    - Hyperacute: Intravascular enhancement (stasis from slow antegrade or retrograde collateral flow)
    - Acute: Meningeal enhancement (pial collateral flow appears in 24-48 hours, resolves over 3-4 days)
    - Subacute: Parenchymal enhancement (appears after 24-48 hours, can persist for weeks/months)
- MRA: Major vessel occlusions, stenoses, status of collaterals
- MRS: Elevated lactate, decreased NAA

https://CafePezeshki.IR

- Conventional MR sequences positive in 70-80%
  - Restricted diffusion improves accuracy to 95%
- Diffusion tensor imaging (DTI)
  - Multidirectional diffusion-weighted images; at least 6 directions can be used to calculate DTI trace and ADC maps
    - Higher spatial resolution
  - May be more sensitive for small ischemic foci, emboli, cortical strokes

Angiographic Findings

- Conventional: Vessel occlusion (cut-off, tapered, "tram track")
  - Slow antegrade flow, retrograde collateral flow
- Neurointerventional: IA fibrinolytic therapy for treatment of selected acute nonhemorrhagic stroke within 6-hour window
  - IA mechanical clot removal with retriever device

Imaging Recommendations

- Best imaging tool
  - MR + DWI, T2* GRE
- Protocol advice
  - NECT as initial study to exclude hemorrhage/mass
    - CT perfusion and CTA if available
  - MR with DWI, FLAIR, GRE ± MRA, PWI
  - DSA with thrombolysis in selected patients

DIFFERENTIAL DIAGNOSIS

Hyperdense Vessel Mimics

- High hematocrit (polycythemia)
- Microcalcification in vessel wall
- Diffuse cerebral edema makes vessels appear relatively hyperdense
- Normal circulating blood always slightly hyperdense to normal brain

Parenchymal Hypodensity (Nonvascular Causes)

- Infiltrating neoplasm (e.g., astrocytoma)
- Cerebral contusion
- Inflammation (cerebritis, encephalitis)
- Evolving encephalomalacia
- Dural venous thrombosis with parenchymal venous congestion and edema
- Seizure

PATHOLOGY

General Features

- Etiology
  - Many causes (thrombotic vs. embolic, dissection, vasculitis, hypoperfusion)
  - Early: Critical disturbance in CBF
    - Severely ischemic core has CBF < (6-8 cm^3)/(100 g/min) (normal ~ [60 cm^3]/[100 g/min])
    - Oxygen depletion, energy failure, terminal depolarization, ion homeostasis failure
    - Bulk of final infarct → cytotoxic edema, cell death
  - Later: Evolution from ischemia to infarction depends on many factors (e.g., hyperglycemia influences "destiny" of ischemic brain tissue)
  - Ischemic penumbra CBF between (10-20 cm^3)/(100 g/min)
    - Theoretically salvageable tissue
    - Target of thrombolysis, neuroprotective agents
- Associated abnormalities
  - Cardiac disease, prothrombotic states
  - Additional stroke risk factors: C-reactive protein, homocysteine

Gross Pathologic & Surgical Features

- Acute thrombosis of major vessel
- Pale, swollen brain; GM-WM boundaries blurred

CLINICAL ISSUES

Presentation

- Most common signs/symptoms
  - Focal acute neurologic deficit
  - Paresis, aphasia, decreased mental status

Demographics

- Age
  - Usually older adults
  - Consider underlying disease (sickle cell, moyamoya, NF1, cardiac, drugs) in children, young adults
- Epidemiology
  - 2nd most common cause of death worldwide
  - #1 cause of morbidity in USA

Natural History & Prognosis

- Clinical diagnosis inaccurate in 15-20% of strokes
- Malignant MCA infarct (coma, death)
  - Up to 10% of all stroke patients
  - Fatal brain swelling with increased ICP

Treatment

- "Time is brain": IV rTPA window < 3 hours
  - IA window < 6 hours
- Patient selection most important factor in outcome
  - Symptom onset < 6 hours
  - No parenchymal hematoma on CT
  - < 1/3 MCA territory hypodensity

DIAGNOSTIC CHECKLIST

Consider

- DWI positive for acute stroke only if ADC correlates
- Rarely, ischemia or seizure may mimic tumor or encephalitis

SELECTED REFERENCES

1. Audebert HJ et al: Brain imaging in acute ischemic stroke—MRI or CT? Curr Neurol Neurosci Rep. 15(3):6, 2015
2. Copen WA: Multimodal imaging in acute ischemic stroke. Curr Treat Options Cardiovasc Med. 17(3):368, 2015
3. Walker BS et al: Calcified Cerebral Emboli, A "Do Not Miss" Imaging Diagnosis: 22 New Cases and Review of the Literature. AJNR Am J Neuroradiol. ePub, 2014

https://CafePezeshki.IR

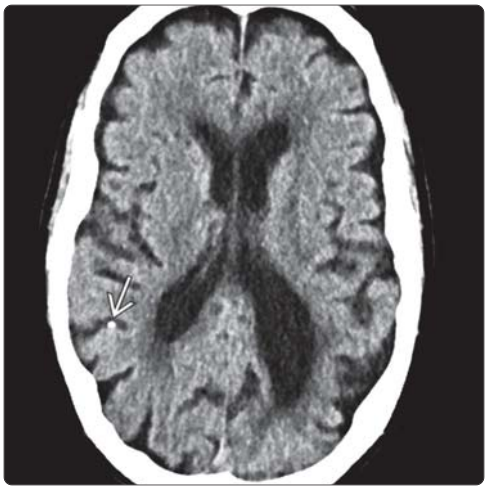

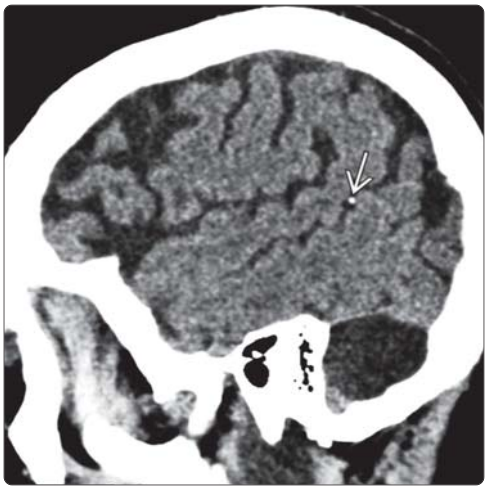

(Left) *Axial NECT in an 89-year-old male who had several visits to the ER for several falls ("rule out subdural hematoma") shows a calcified cerebral embolus ➡ in a right hemisphere sulcus.* **(Right)** *Sagittal reformatted NECT scan in the same patient shows the location in the right superior temporal sulcus ➡. The patient was subsequently shown to have calcific mitral valve disease. Calcified cerebral emboli carry a high risk of repeated stroke.*

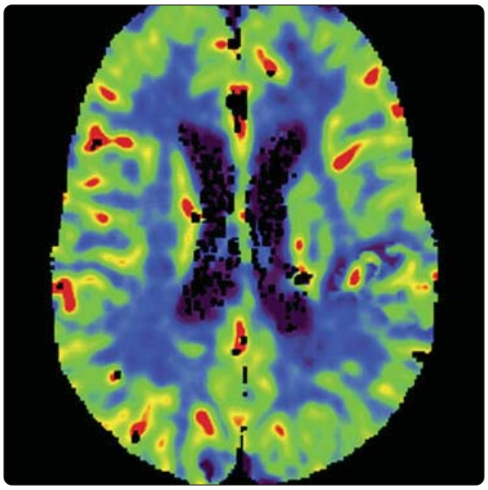

(Left) *Axial NECT scan for a "brain attack" patient in the ER with sudden onset aphasia is normal.* **(Right)** *Axial CT perfusion was obtained immediately following the NECT scan. The cerebral blood volume appears grossly normal.*

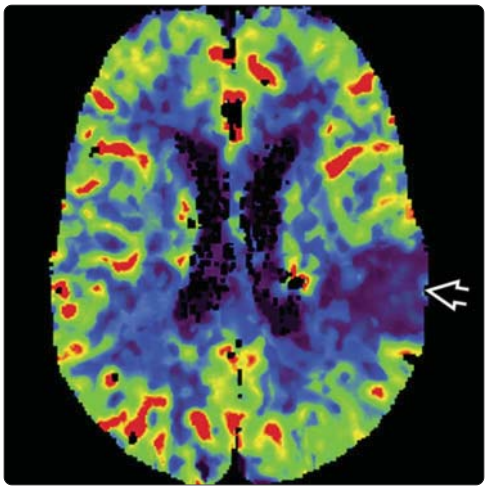

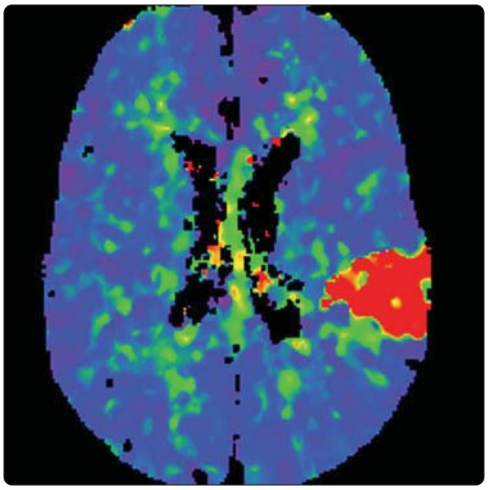

(Left) *Axial CBF map in the same patient shows markedly reduced perfusion in the posterior division of the left middle cerebral artery ➡.* **(Right)** *Time to drain in the same patient shows severely reduced TTD, consistent with acute ischemia without infarction. IV TPA was administered and the symptoms resolved.*

https://CafePezeshki.IR

KEY FACTS

TERMINOLOGY

- Subacute infarction ~ 2-14 days following initial ischemic event

IMAGING

- Best diagnostic clue: Gyral edema and enhancement within basal ganglia and cortex
- Typically wedge-shaped abnormality involving gray and white matter within vascular distribution
- Hemorrhagic transformation of initially ischemic infarction occurs in 20-25% of MCA occlusions, usually by 48-72 hours
- "2-2-2" rule = enhancement begins at 2 days, peaks at 2 weeks, disappears by 2 months
- MRS: ↑ lactate, ↓ NAA within infarcted tissue
- DWI: ↑ diffusion restriction, ↓ ADC initially, reversing as it proceeds into/through subacute stage
- "Fogging" effect = normal T2WI with striking enhancement on T1WI C+ 1-2 weeks following ictus

TOP DIFFERENTIAL DIAGNOSES

- Neoplasm
- Venous infarction
- Encephalitis/cerebritis

CLINICAL ISSUES

- Acute onset focal neurologic deficit
- Elderly patient with typical risk factors: Hypertension, diabetes, smoking history, obesity, hypercholesterolemia
- 1st month after infarction, mortality predominantly from neurologic complications; 1:4 die of recurrent stroke event
- Acute anticoagulation after 1st infarction reduces mortality

DIAGNOSTIC CHECKLIST

- Enhancement is key to defining subacute stage of cerebral infarction
- Subacute ischemia often mimics neoplasm
  - Recommend short-term follow-up to ensure expected course of evolution

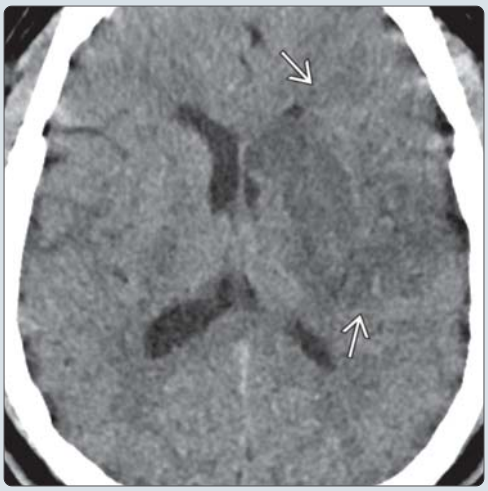

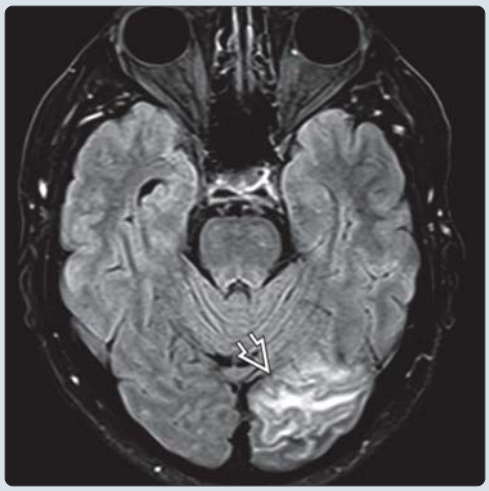

(Left) *Axial CT obtained 48 hours after initial onset of weakness and speech difficulties shows the classic appearance of an early subacute cerebral infarct. Note the wedge-shaped, low-density area ➡ involving both the gray and white matter in the left MCA distribution.* **(Right)** *Axial FLAIR MR in a 58-year-old man 1 week after onset of visual changes shows classic imaging of a subacute infarct with hyperintensity in the cortex and subcortical white matter of the occipital lobe ➡ in a PCA distribution.*

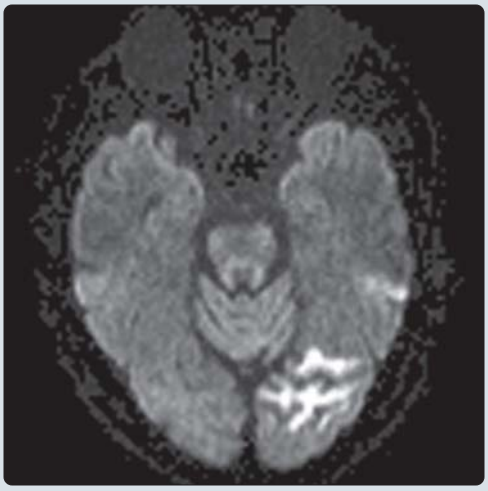

(Left) *Axial DWI image in the same patient shows hyperintensity within the left PCA distribution. The hyperintensity represents a combination of true diffusion restriction and T2 shine through.* **(Right)** *Axial T1 C+ MR in the same patient shows gyriform enhancement along the cortex of the occipital lobe ➡. This enhancement may be seen as early as 2 days and may last up to 2 months after the patient's initial ischemic event. Without clinical history, imaging may mimic a tumor, venous infarct, or cerebritis.*

https://CafePezeshki.IR

TERMINOLOGY

Abbreviations

- Subacute stroke, subacute cerebrovascular accident (CVA)

Definitions

- Focal brain necrosis following obstruction of blood flow to localized area of brain
- Subacute infarct ~ 2-14 days following initial ischemic event
- May occur ± hemorrhagic transformation (HT)

IMAGING

General Features

- Best diagnostic clue
  - Gyral edema, enhancement in basal ganglia/cortex
  - Look for hemorrhagic transformation
    - Typically occurs in 20-25% of cases 2-7 days after acute event
- Location
  - Cerebral hemispheres, brainstem, cerebellum in territorial vascular distribution
- Size
  - Extremely variable
  - Ranges from focal ("lacunes") to global (hemispheric)
- Morphology
  - Variable depending on location, size, etiology
  - Typically wedge shaped; involves both gray and white matter
    - Recognizable vascular distribution

CT Findings

- NECT
  - Wedge-shaped area of ↓ attenuation involving gray and white matter
  - Mass effect initially ↑, then ↓ by 7-10 days; often less than expected given lesion size as acuity resolves
  - Hemorrhagic transformation of ischemic infarct occurs in 20-25% of MCA occlusions, usually by 48-72 hours
    - Common locations are basal ganglia and cortex
    - Hemorrhagic foci detected in majority of medium/large subacute infarcts
- CECT
  - Enhancement typically patchy or gyral
  - May appear as early as 2-3 days after ictus; persists up to 8-10 weeks
  - "2-2-2" rule = enhancement begins at 2 days, peaks at 2 weeks, disappears by 2 months
- CTA
  - Evidence of subacute occlusion correlates strongly, independently with poor clinical outcome
    - Significantly worse discharge National Institutes of Health Stroke Scale (NIHSS) score
- CT perfusion
  - More useful in acute > subacute stroke
    - Helpful in predicting tissue outcome
  - Significant difference between infarct and peri-infarct tissue for both rCBF, rCBV

MR Findings

- T1WI
  - Hypointense edema with mass effect
  - HT: Signal changes of hemorrhage
  - May see gyriform ↑ signal (pseudolaminar necrosis)
- T2WI
  - Hyperintense edema with mass effect
  - "Fogging" effect = normal T2WI with striking enhancement on T1WI C+ 1-2 weeks following ictus
  - HT: Signal changes of evolving hemorrhage
  - Early wallerian degeneration can occur
    - Look for well-defined hyperintense band in corticospinal tract
- FLAIR
  - Hyperintense edema with mass effect
  - Hyperintensity ("dot" sign) in slow-flowing/occluded vessels
  - By 1 week, final infarct volume corresponds to FLAIR-defined abnormality
- T2* GRE
  - May see blooming if HT has occurred
- DWI
  - ↑ diffusion restriction, ↓ ADC initially, reversing as it proceeds into/through subacute stage
  - DWI, T1WI C+ complement each other in detecting subacute infarcts
    - Early subacute can be ↑ DWI and ↓ T1 C+
- T1WI C+
  - Intravascular enhancement in initial 48 hours; disappears at 3-4 days as vessels recanalize
  - Parenchymal enhancement (typically patchy or gyral)
    - May appear as early as 2-3 days after ictus
    - Can persist up to 8-10 weeks
- MRA
  - Vessel occlusion (large vessel)
- MRS
  - ↑ lactate, ↓ NAA within infarcted tissue
  - In subacute and chronic infarction, lactate/choline and NAA/choline ratios correlate with outcome
- MR T2* perfusion
  - ↓ rCBV of acute infarct increases in subacute stage, reflecting reperfusion hyperemia
  - Decreases again in chronic stage

Angiographic Findings

- Conventional
  - May see intraluminal thrombus &/or vessel occlusion
  - Slow antegrade flow with delayed arterial emptying
  - Slow retrograde filling through collateral vessels
  - "Bare" areas = regions of nonperfused or slowly perfused brain tissue

Nuclear Medicine Findings

- Diminished/absence of perfusion with SPECT or PET
- HMPAO SPECT may show reflow hyperemia after reperfusion in acute and subacute stages

Imaging Recommendations

- Best imaging tool
  - MR with DWI, T2*, T1WI C+
  - Consider CT or MR perfusion (more helpful in acute stroke)
- Protocol advice
  - CT and MR: C+ for assessing subacute age

https://CafePezeshki.IR

DIFFERENTIAL DIAGNOSIS

Neoplasm

- DWI: Vasogenic ("tumoral") edema instead of cytotoxic edema
- Enhancing mass instead of patchy, gyral enhancement
- Will not regress on follow-up imaging

Venous Infarction

- Nonarterial distribution
- Venous instead of arterial occlusion, typically major dural sinus
- More commonly hemorrhagic, primarily affecting white matter instead of cortex
- Different clinical presentation/setting (trauma, hypercoagulable states, pregnancy, dehydration)

Encephalitis/Cerebritis

- DWI: Strong restriction
- Nonvascular distribution
- Gyriform, ring-enhancing patterns (late cerebritis)
- Different clinical presentation

PATHOLOGY

General Features

- Etiology
  - Prolonged cerebral ischemia
  - Duration and severity of ischemic insult determines cellular viability
  - Less commonly, may be result of infectious etiologies
    - Sequelae of meningitis (bacterial, mycobacterial, etc.)
  - May also be result of inflammatory diseases, such as vasculopathy, angiitis, etc.
  - Uncontrolled, unilateral, supratentorial expanding lesions can cause descending tentorial herniation → ischemic infarction of occipital lobe
  - Ischemia/infarction involves typical vascular territories or watershed (border zone) distributions depending on etiology
  - Other factors: Adequacy of collateral blood supply, degree, duration, and distribution of flow reduction
- Genetics
  - Hypercholesterolemia, diabetes, hypertension, and homocysteine increase stroke risk

Gross Pathologic & Surgical Features

- Blurring of gray-white matter demarcation
- Mass effect with narrowing of sulci, displacement of adjacent structures
- Softening of ischemic tissues from water retention

Microscopic Features

- Fragmentation of axons and early disintegration of myelin sheaths; loss of oligodendrocytes, astrocytes
- 48 hours: Neutrophils begin to pass through vessel walls into brain tissue
- 72-96 hours: Macrophages aggregate around vessels
- 2 weeks: Macrophages are the predominate reactive cells

CLINICAL ISSUES

Presentation

- Most common signs/symptoms
  - Acute onset focal neurologic deficit
  - ~ 50% of patients with infarction → permanent neurologic deficits have preceding TIAs
- Clinical profile
  - Elderly patient with typical risk factors: Hypertension, diabetes, smoking history, obesity, hypercholesterolemia, etc.

Demographics

- Age
  - Usually > 55 years
  - Women often slightly older than men at presentation
- Gender
  - Females often more disabled after age adjustment
  - Fatality rates similar
- Epidemiology
  - Highest cause of USA adult morbidity
  - 3rd cause of USA adult mortality

Natural History & Prognosis

- 1st month after infarction, mortality predominantly from neurologic complications
  - 1:4 die of recurrent stroke event
- Later mortality from respiratory, cardiovascular causes

Treatment

- To improve long-term survival, aggressive management of pulmonary and cardiac disease is critical
- Acute anticoagulation after 1st infarction reduces mortality
- Current research: Therapeutic hypothermia and gene therapy (antiapoptotic protein BCL-2) during acute stroke event

DIAGNOSTIC CHECKLIST

Consider

- Is affected area another space-occupying pathology (i.e., tumor)
- Recommend short-term follow-up to ensure expected course of evolution

Image Interpretation Pearls

- Enhancement is key to defining subacute stage of cerebral infarction
- Appearance on DWI/ADC often helpful

SELECTED REFERENCES

1. Zöllner JP et al: Changes of pH and energy state in subacute human ischemia assessed by multinuclear magnetic resonance spectroscopy. Stroke. 46(2):441-6, 2015
2. Brunner IC et al: Plasticity and response to action observation: a longitudinal FMRI study of potential mirror neurons in patients with subacute stroke. Neurorehabil Neural Repair. 28(9):874-84, 2014
3. Ntaios G et al: Acute imaging does not improve ASTRAL score's accuracy despite having a prognostic value. Int J Stroke. 9(7):926-31, 2014
4. Qiao Y et al: Intracranial plaque enhancement in patients with cerebrovascular events on high-spatial-resolution MR images. Radiology. 271(2):534-42, 2014
5. Drier A et al: Prediction of subacute infarct size in acute middle cerebral artery stroke: comparison of perfusion-weighted imaging and apparent diffusion coefficient maps. Radiology. 265(2):511-7, 2012

https://CafePezeshki.IR

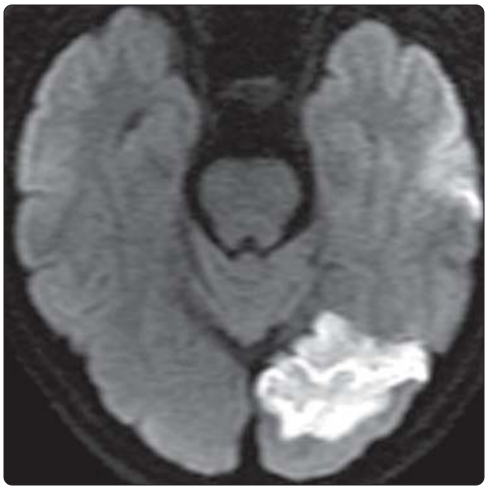

(Left) *Axial CT in 61 year old 3 days following symptoms shows a hypodense subacute PCA infarct in the left occipital lobe with involvement of the cortex and subcortical white matter* ➡ *with no hemorrhagic transformation.* **(Right)** *Axial DWI in the same patient shows DWI restriction (with corresponding ADC hypointensity, not shown). True restricted diffusion persists several days after stroke onset and gradually reverses with DWI hypointensity and ADC hyperintensity shine through.*

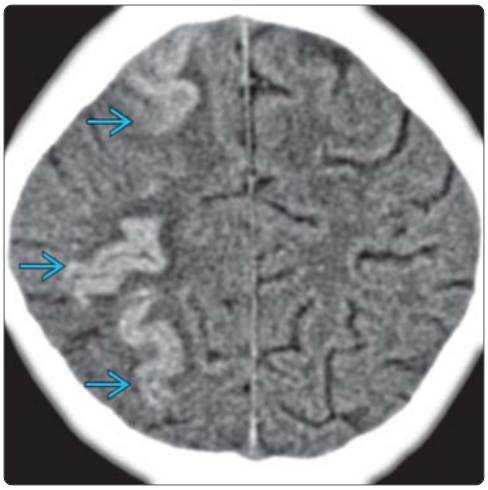

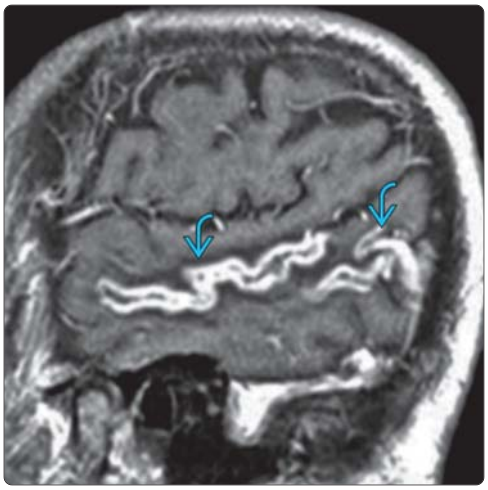

(Left) *Axial CT demonstrates gyriform hyperdensity* ➡ *related to cortical pseudolaminar necrosis/hemorrhagic transformation in a right hemispheric watershed infarct.* **(Right)** *Sagittal T1 C+ MR shows well-defined gyriform enhancement* ➡ *in the right MCA distribution. Note the lack of mass effect in this late subacute infarct. The major differential considerations for a subacute infarct include neoplasm and cerebritis. Repeat imaging may be necessary to exclude neoplasm.*

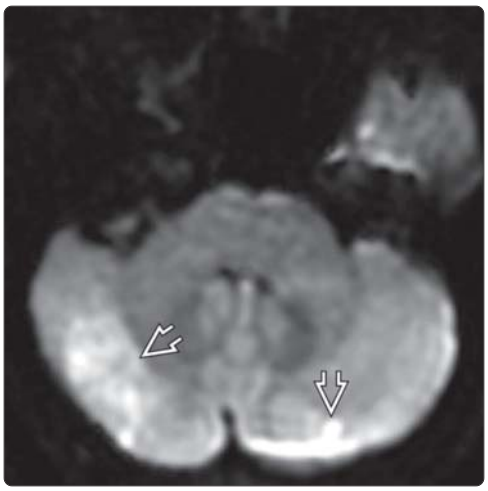

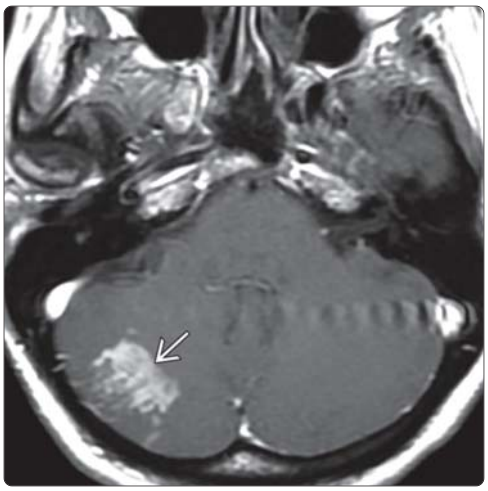

(Left) *Axial DWI MR 5 days after a posterior circulation infarct shows high signal* ➡ *due to restricted diffusion in bilateral cerebellar hemispheres. DWI scans can be hyperintense up to 7-10 days following acute stroke onset.* **(Right)** *Axial T1 C+ in the same patient shows patchy enhancement in the right cerebellar hemisphere* ➡ *in this 45-year-old woman with an abnormal cardiac valve resulting in embolic disease in multiple vascular distributions. Cardioembolic disease represents 15-25% of major strokes.*

https://CafePezeshki.IR

KEY FACTS

IMAGING

- Volume loss with gliosis along affected margins
- Classic: Wedge-shaped area of encephalomalacia
- Territorial infarction
  - Involves brain supplied by major cerebral artery
- Watershed infarction
  - Involves brain **between** main vascular territories
- Lacunar infarction(s)
  - Most common in basal ganglia/thalami, deep white matter (WM)

TOP DIFFERENTIAL DIAGNOSES

- Porencephalic cyst
- Arachnoid cyst
- Postsurgical/post-traumatic encephalomalacia
- Low-attenuating tumors

PATHOLOGY

- Volume loss, gliosis are pathological hallmarks

CLINICAL ISSUES

- Elderly patient with typical risk factors
- Focal neurologic deficit
  - Varies depending on size, location of cerebral infarction (CI)
- Stroke severity most consistent predictor of 30 day mortality after stroke
- Lacunar stroke most common stroke subtype associated with vascular dementia

DIAGNOSTIC CHECKLIST

- Evaluate for associated acute infarcts in same or different vascular territory
- Evaluate for underlying cause
  - CTA/MRA of extra-/intracranial vasculature
  - If negative, consider cardiac source
- Evaluate for risk factors

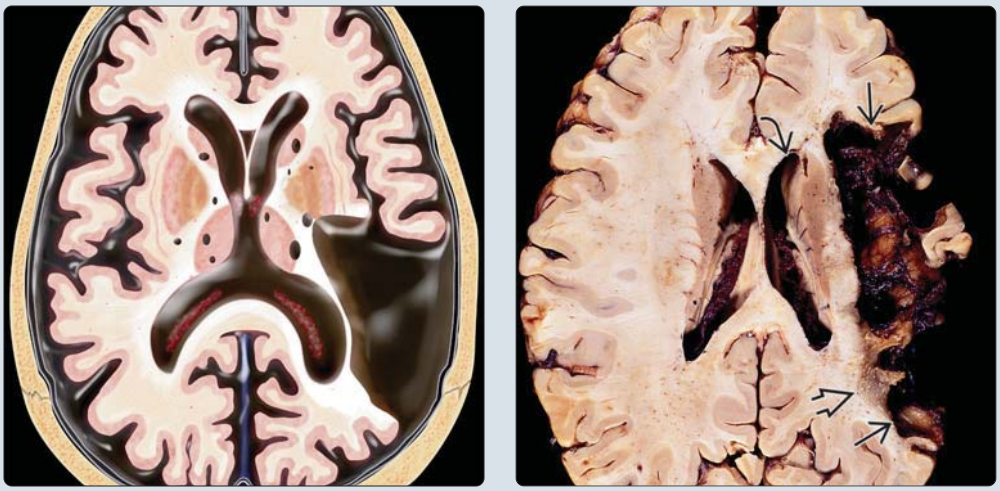

(Left) *Axial graphic shows chronic infarct involving the posterior left MCA territory. Infarct is lined with gliotic (WM). Small lacunar infarctions and atrophy also depicted.* **(Right)** *Axial gross pathology, sectioned through the midventricular level, shows a chronic left middle cerebral artery infarct with encephalomalacia in the classic MCA vascular distribution. Note the adjacent WM gliosis and the mild compensatory enlargement of the left lateral ventricle. (Courtesy R. Hewlett, MD.)*

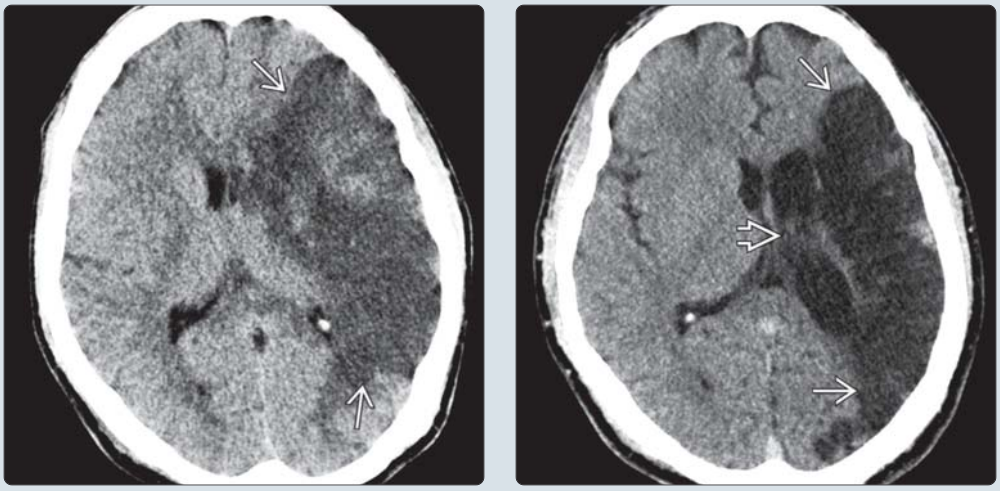

(Left) *Axial NECT scan 2 days after large territorial infarction in the left MCA territory shows wedge-shaped hypodensity involving both cortex, white matter, and basal ganglia. Moderate mass effect is present, with subfalcine herniation of the lateral ventricles.* **(Right)** *Follow-up scan 2 months later shows findings of chronic infarct. The mass effect has resolved completely and there is frank encephalomalacia in the left MCA territory. The left lateral ventricle shows compensatory enlargement.*

https://CafePezeshki.IR

TERMINOLOGY

Abbreviations

- Cerebral infarction (CI)

Synonyms

- Old ischemic stroke
- Postinfarction encephalomalacia

Definitions

- End result of prolonged cerebral ischemia

IMAGING

General Features

- Best diagnostic clue
  - Volume loss with gliosis along affected margins
- Location
  - Cerebral hemispheres, brainstem, cerebellum
  - Territorial infarction involves brain tissue supplied by major cerebral artery
    - Common sites
      - Supratentorial: MCA, ACA, PCA distribution
      - Infratentorial: BA, PICA distribution
  - Watershed (border zone) infarction involves brain tissue **between** main vascular territories
  - Lacunar infarctions are small infarcts in deep penetrating artery distributions
    - Typically located in basal ganglia/thalami, white matter (WM)
- Size
  - Extremely variable
    - Ranging from focal ("lacunes") to lobar or global (hemispheric)
- Morphology
  - Extremely variable depending on location, size, etiology of vascular insult
  - Classic: Wedge-shaped area of encephalomalacia

CT Findings

- NECT
  - Focal, well-delineated, low-attenuation areas in affected vascular distribution
  - Adjacent sulci become prominent; ipsilateral ventricle enlarges
  - Wallerian degeneration may be present
  - Dystrophic Ca++ may very rarely occur in infarcted brain
- CECT
  - No enhancement
- CTA
  - May see lack of flow in affected vessel

MR Findings

- T1WI
  - Isointense to CSF in affected areas
  - Adjacent sulci become prominent; ipsilateral ventricle enlarges
  - Wallerian degeneration may be present
- T2WI
  - Isointense to CSF in affected areas
  - Borders of infarction may show ↑ signal secondary to gliosis/spongiosis
  - Differentiation of subacute from chronic infarction on standard SE/FSE sequences may be difficult due to prolonged relaxation times in both
- FLAIR
  - Low signal in encephalomalacic area
  - Hyperintense gliotic white matter at margins
- T2* GRE
  - May see hemosiderin staining in gliotic areas or along borders of infarction
- DWI
  - No restriction; increased diffusivity (↑ signal on ADC)
- T1WI C+
  - No enhancement
- MRA
  - May see lack of flow in affected vessel
- MRS
  - Shows loss of NAA peak in affected area

Angiographic Findings

- Conventional
  - May see lack of flow in affected vessel and its vascular territory

Imaging Recommendations

- Best imaging tool
  - CT or MR
- Protocol advice
  - No contrast necessary if imaging typical (i.e., lack of mass effect or volume loss)

DIFFERENTIAL DIAGNOSIS

Porencephalic Cyst

- Congenital cyst typically seen in younger age groups
- Also lined by gliotic white matter

Arachnoid Cyst

- No gliotic margins
- Usually in locations atypical for vascular territory
- Intact gray matter lining brain, displaced by cyst

Postoperative/Post-Traumatic Encephalomalacia

- History and associated findings help to distinguish
- May see leptomeningeal cyst in post-traumatic setting

Low-Attenuation Tumors

- Typically shows mass effect
- Usually slightly hyperdense/intense compared to CSF

PATHOLOGY

General Features

- Etiology
  - Prolonged cerebral ischemia
  - Duration and severity of ischemic insult determines cellular viability
    - Results of CI vary with sensitivity of individual cell types to ischemia
    - Other factors include adequacy of collateral blood supply, degree, duration, and distribution of flow reduction
  - Most CI caused by territorial, watershed, lacunar infarcts

https://CafePezeshki.IR

- Less commonly result of infectious/inflammatory etiologies
  - Sequelae of meningitis (bacterial, mycobacterial, etc.)
  - Vasculopathy, angiitis, etc.
- Rare
  - Unilateral descending tentorial herniation
  - May cause secondary ischemic infarction of occipital lobe
- Genetics
  - Hypercholesterolemia, diabetes, hypertension, homocysteine ↑ stroke risk

Gross Pathologic & Surgical Features

- Volume loss and gliosis pathological hallmarks
- Liquefaction resulting in cyst formation
- Cystic areas traversed by trabeculations of blood vessels, surrounded by firm glial tissue
- Typically in main vascular territories or watershed (border zone) distribution depending on etiology

Microscopic Features

- Fibrillary gliosis along margin of infarction
- Macrophages may persist in interstices of infarcts; some may contain hemosiderin

CLINICAL ISSUES

Presentation

- Most common signs/symptoms
  - Focal neurologic deficit with history of acute onset
- Clinical profile
  - Elderly patient with typical risk factors
    - Hypertension, diabetes, smoking history, obesity, hypercholesterolemia, etc.

Demographics

- Age
  - Usually > 55
- Gender
  - Women typically older than men
  - Females often more disabled after age adjustment
  - Fatality rates similar
- Epidemiology
  - 2nd or 3rd leading cause of death in Western world (after noncerebral cardiovascular disease and cancer)
  - Major cause of long-term disability
  - 1 in 5 with 1st stroke will survive to 10 years
  - Estimates in USA range from 760,000-780,000 annually; contributes to ~ 150,000 deaths/year
  - Estimated 5,800,000 stroke survivors in USA

Natural History & Prognosis

- Varies greatly depending on size of CI and degree of neurologic deficit
- Stroke severity most consistent predictor of 30 day mortality after stroke
- Mortality rates in USA declined dramatically in 1970s and 1980s, but plateaued by 1990s
- Stroke mortality in USA predicted to ↑ 3x as fast as general population over next 30 years
- Lacunar stroke most common stroke subtype associated with vascular dementia

Treatment

- Acute anticoagulation after 1st infarction associated with reduced mortality
- To improve long-term survival after CI, aggressive management of pulmonary and cardiac disease critical

DIAGNOSTIC CHECKLIST

Consider

- Could lesion be arachnoid cyst or porencephalic cyst

Image Interpretation Pearls

- Look for signs of volume loss in vascular territory
- Evaluate for associated acute infarcts in same or different vascular territory

Reporting Tips

- Evaluate for underlying cause
  - Multiple infarcts in different vascular territories
    - Suggests cardioembolic source or vasculitis
  - Bilateral watershed infarcts
    - Hypoperfusion event
  - Unilateral watershed infarct
    - Hypoperfusion event and ipsilateral carotid stenosis
  - Infarct in setting of trauma
    - Evaluate for dissection

SELECTED REFERENCES

1. Sikiö M et al: MRI Texture Analysis and Diffusion Tensor Imaging in Chronic Right Hemisphere Ischemic Stroke. J Neuroimaging. ePub, 2014
2. Allen LM et al: Sequence-specific MR imaging findings that are useful in dating ischemic stroke. Radiographics. 32(5):1285-97; discussion 1297-9, 2012
3. Bagher-Ebadian H et al: Predicting final extent of ischemic infarction using artificial neural network analysis of multi-parametric MRI in patients with stroke. PLoS One. 6(8):e22626, 2011
4. Danaei G et al: The preventable causes of death in the United States: comparative risk assessment of dietary, lifestyle, and metabolic risk factors. PLoS Med. 6(4):e1000058, 2009
5. Donnan GA et al: Penumbral selection of patients for trials of acute stroke therapy. Lancet Neurol. 8(3):261-9, 2009
6. Elkind MS: Outcomes after stroke: risk of recurrent ischemic stroke and other events. Am J Med. 122(4 Suppl 2):S7-13, 2009
7. Lloyd-Jones D et al: Heart disease and stroke statistics–2009 update: a report from the American Heart Association Statistics Committee and Stroke Statistics Subcommittee. Circulation. 2009 Jan 27;119(3):480-6. Erratum in: Circulation. 119(3):e182, 2009
8. Roberts CS et al: Additional stroke-related and non-stroke-related cardiovascular costs and hospitalizations in managed-care patients after ischemic stroke. Stroke. 40(4):1425-32, 2009
9. Donnan GA et al: Stroke. Lancet. 371(9624):1612-23, 2008
10. Mark VW et al: Poststroke cerebral peduncular atrophy correlates with a measure of corticospinal tract injury in the cerebral hemisphere. AJNR Am J Neuroradiol. 29(2):354-8, 2008
11. Muñoz Maniega S et al: Changes in NAA and lactate following ischemic stroke: a serial MR spectroscopic imaging study. Neurology. 71(24):1993-9, 2008
12. Glodzik-Sobanska L et al: Prefrontal N-acetylaspartate and poststroke recovery: a longitudinal proton spectroscopy study. AJNR Am J Neuroradiol. 28(3):470-4, 2007
13. De Simone T et al: Wallerian degeneration of the pontocerebellar fibers. AJNR Am J Neuroradiol. 26(5):1062-5, 2005
14. Saito K et al: Mechanisms of bihemispheric brain infarctions in the anterior circulation on diffusion-weighted images. AJNR Am J Neuroradiol. 26(4):809-14, 2005
15. Hankey GJ: Long-term outcome after ischaemic stroke/transient ischaemic attack. Cerebrovasc Dis. 16 Suppl 1:14-9,16, 2003
16. Hardie K et al: Ten-year survival after first-ever stroke in the perth community stroke study. Stroke. 34(8):1842-6, 2003

https://CafePezeshki.IR

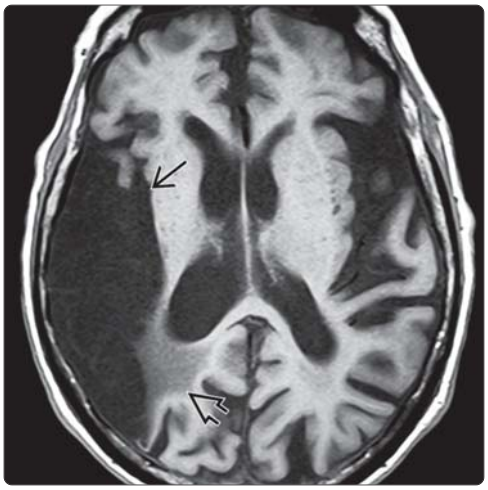

(Left) *Axial NECT scan shows classic chronic right MCA infarct ⇨. The encephalomalacic brain is low density and the ipsilateral right ventricle is enlarged.* **(Right)** *T1WI in the same patient shows the area of encephalomalacic brain ⇨ is the same signal intensity as CSF in the adjacent ventricle. Gliotic WM ⇨ bordering the infarct is hypointense to normal WM.*

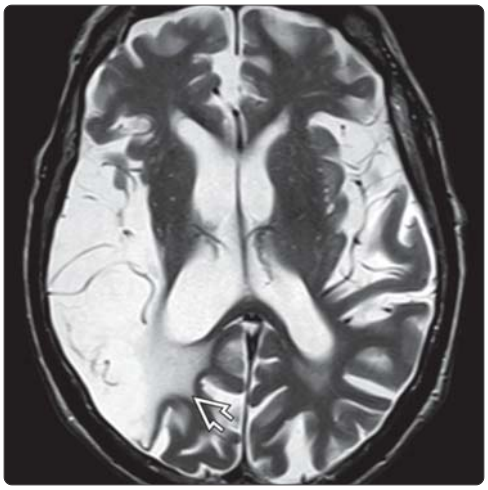

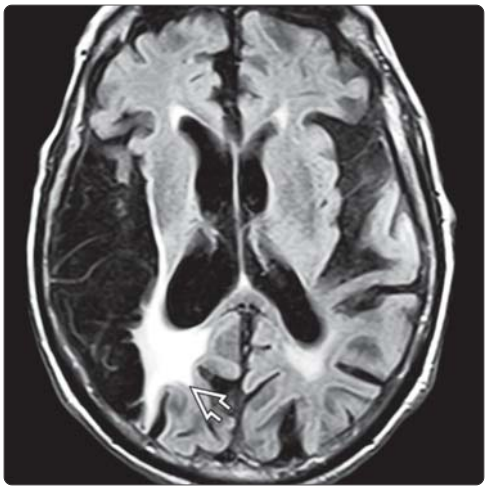

(Left) *Axial T2WI in the same patient shows the chronic infarct is isointense with CSF but the gliotic brain ⇨ adjacent to the stroke is slightly less hyperintense.* **(Right)** *FLAIR MR in the same patient shows the cystic encephalomalacia caused by the stroke suppresses completely while the adjacent gliotic WM ⇨ remains hyperintense.*

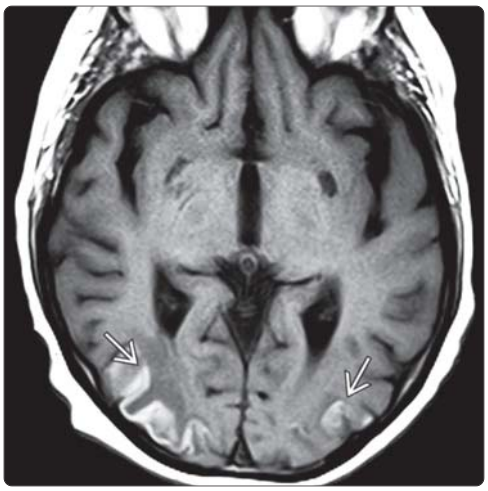

(Left) *Axial NECT scan in a patient with visual difficulties, remote history of stroke shows bioccipital hypodensities ⇨.* **(Right)** *Axial T1WI in the same patient shows hypointense occipital WM with gyriform T1 shortening ⇨. This represents residua of hemorrhagic transformation in the chronic bioccipital infarct.*

https://CafePezeshki.IR

KEY FACTS

TERMINOLOGY

- Infarcts in multiple arterial distributions from embolic source, often cardiac origin

IMAGING

- Best imaging clue: DWI restriction in multiple vascular distributions
- NECT: Multiple regions of low attenuation, loss of gray-white differentiation
- T2/FLAIR: Multiple supratentorial and infratentorial regions of hyperintensity, often in a vascular distribution
  - May be of different ages
- Embolic infarcts tend to involve terminal cortical branches, producing wedge-shaped infarcts
- Cardiac echocardiography may show valve vegetations, intracardiac filling defect, or atrial or ventricular septal defect
- Best imaging tool: MR with DWI, FLAIR, T1WI C+

TOP DIFFERENTIAL DIAGNOSES

- Hypotensive cerebral infarction
- Multiple sclerosis
- Parenchymal metastases
- Vasculitis

CLINICAL ISSUES

- Multiple focal neurologic complaints not conforming to singular vascular distribution
- Peripheral signs of emboli, such as splinter hemorrhages or paradoxical emboli
- Cardiac source most common etiology of multiple embolic infarcts
  - May be septic or benign
- Carotid artery disease may cause multiple embolic infarct, if associated with variant PCA origin
- Cardiac and vascular evaluation → treat underlying disease

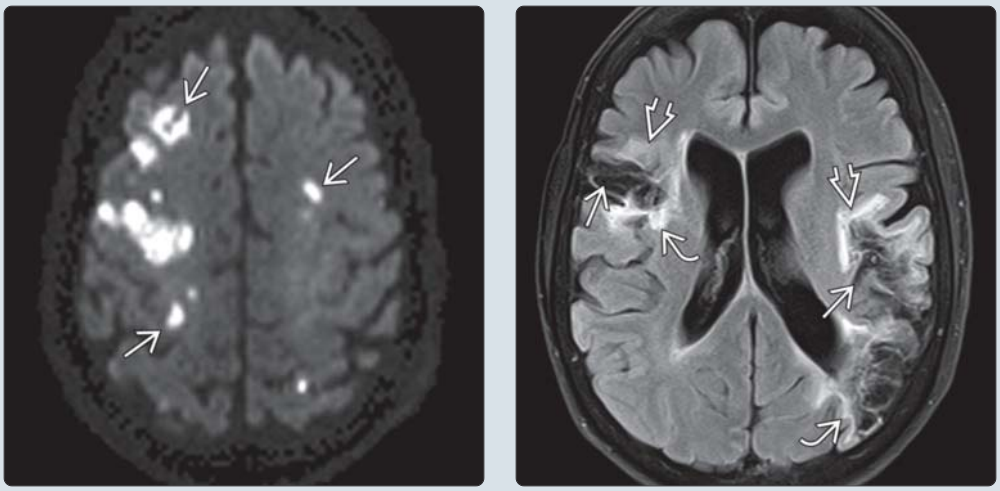

(Left) *Axial DTI trace image shows multiple regions of diffusion hyperintensity related to acute MCA distribution ischemia in bilateral hemispheres in a patient with embolic disease from a cardiac source.* **(Right)** *Axial FLAIR MR image shows bilateral chronic MCA distribution ischemia related to untreated atrial fibrillation. Note the areas of encephalomalacia with surrounding gliosis, typical of chronic ischemia.*

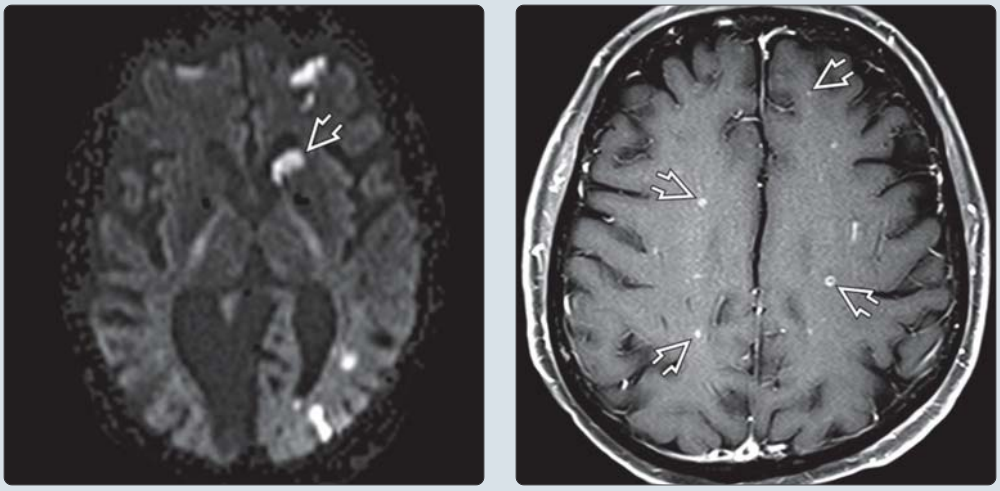

(Left) *Axial DTI trace shows acute ischemia in the left hemisphere in multiple vascular distributions. Note the involvement of the recurrent artery of Heubner from the ACA distribution (head of caudate), as well as the MCA and PCA territories, in this patient with severe internal carotid artery atherosclerotic disease and a fetal origin PCA.* **(Right)** *Axial T1 C+ FS MR shows multiple foci of enhancement in bilateral hemispheres related to septic emboli in a patient with cardiac valve vegetations.*

https://CafePezeshki.IR

KEY FACTS

TERMINOLOGY

- Acute stroke related to fat emboli

IMAGING

- Acute ischemia with appropriate clinical history
  - Long bone or pelvic fractures, cardiac surgery, joint replacement surgery
- Often mimics thromboembolic stroke
- Commonly affects both gray and white matter (WM)
  - May affect deep and periventricular WM
  - May affect deep gray nuclei
- May involve typical vascular territory
- May mimic "watershed" infarct
- NECT: Typically negative acutely
  - "Hypodense MCA" sign related to fat within MCA
- T2WI: Multiple small, scattered hyperintense foci
- DWI: Acute diffusion restriction

TOP DIFFERENTIAL DIAGNOSES

- Acute cerebral ischemia-infarction
- Acute hypertensive encephalopathy, PRES
- Vasculitis

PATHOLOGY

- Fat emboli can pass through pulmonary capillaries without shunting lesions and result in systemic embolization (brain, kidneys most commonly)

CLINICAL ISSUES

- Fat embolism syndrome: Pulmonary, CNS, and cutaneous manifestations
  - Hypoxia, deteriorating mental status, petechiae
- Neurological dysfunction varies from confusion to encephalopathy with coma and seizures
- Uncommon but potentially life-threatening
- Fat embolism syndrome after fractures: Up to 2.2%

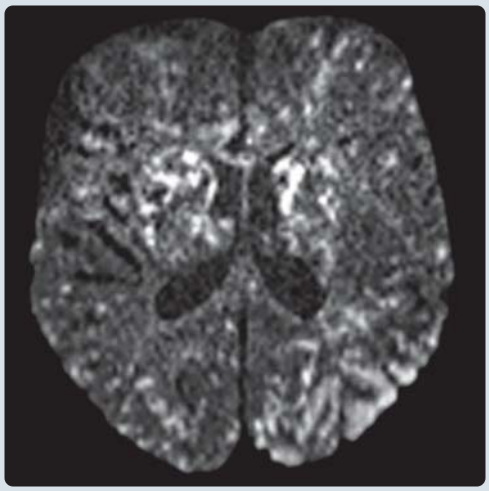

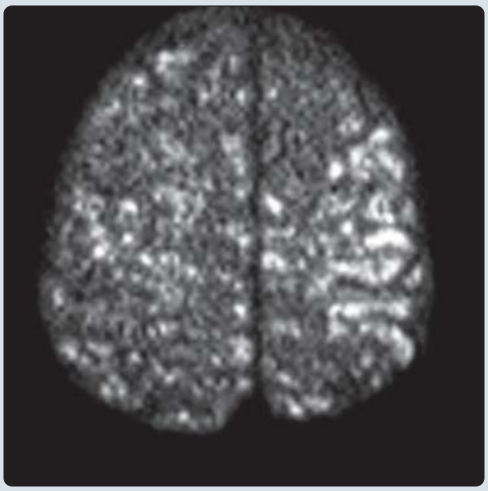

(Left) *Axial DWI MR shows innumerable punctate foci of restriction throughout the white matter and gray matter of this 68 year old with mental status changes status post hip surgery. Note the extensive involvement of the basal ganglia and thalami.* **(Right)** *Axial DWI in the same patient shows the extensive foci of restriction related to acute ischemia from the patient's fat emboli. Note the more focal involvement of the left MCA territory with frontal and temporal lobe involvement.*

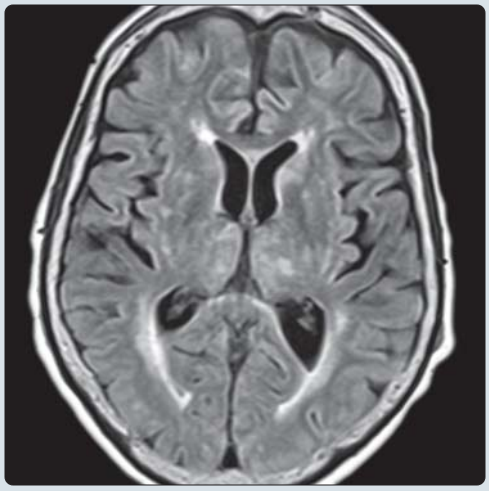

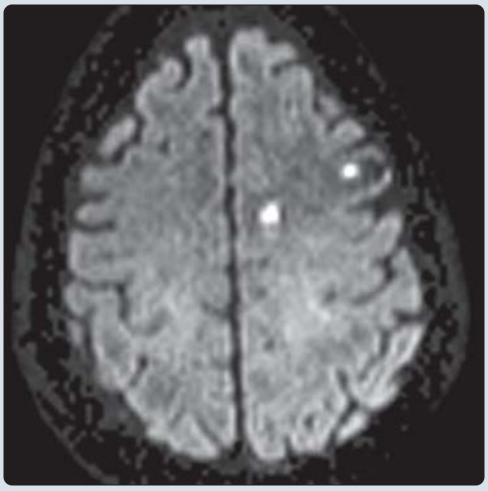

(Left) *Axial FLAIR MR in the same patient shows minimal abnormal hyperintensities in the deep gray nuclei and periventricular white matter. Diffusion imaging is the most sensitive sequence for acute stroke imaging.* **(Right)** *Axial DTI trace image shows 2 punctate foci of restriction related to fat emboli in this 39-year-old trauma patient with bilateral acetabular fractures. DTI may be more sensitive than DWI in acute ischemia. Imaging of fat emboli often mimics a typical thromboembolic stroke.*

https://CafePezeshki.IR

KEY FACTS

TERMINOLOGY

- Small, deep cerebral infarcts located in basal ganglia and thalamus, pons, or cerebral white matter (WM), ≤ 15 mm

IMAGING

- Commonly deep gray nuclei, especially putamen, thalamus, caudate nuclei; internal capsule, pons
  - Other locations include deep and periventricular WM
- Range in size from microscopic to 15 mm
- Because of small size, most acute lacunar infarcts are not seen on CT scans
- Acute: T2/FLAIR increased signal
- Chronic: FLAIR central low signal with increased peripheral signal (gliosis)
- DWI: Restricted diffusion (hyperintense) if acute/subacute
  - May show small lesions otherwise undetectable
- Prominent perivascular spaces are main imaging differential diagnosis

PATHOLOGY

- Embolic, atheromatous, or thrombotic lesions in long, single penetrating end arterioles supplying deep cerebral gray matter
- Size of lacunar infarct depends on level of occlusion and anatomy of affected vessel

CLINICAL ISSUES

- Many different presentations, depending on size, location, number
- Most lacunar infarctions are clinically "silent," often subtle neurological deficits that may go unnoticed by patient and physician
- Typical risk factors for cerebrovascular disease: Hypertension, diabetes, smoking history, obesity, hypercholesterolemia, etc.
- Lacunar infarcts account for up to 25% of all strokes
- Lacunar stroke is most common stroke subtype associated with vascular dementia

(Left) *Axial graphic illustrates numerous bilateral lacunar infarcts within the thalami and basal ganglia, the most common locations. Also shown are prominent perivascular (Virchow-Robin) spaces, a common normal variant.* **(Right)** *Axial FLAIR MR shows multiple chronic lacunar infarcts in the periventricular white matter with central hypointense encephalomalacia and mild peripheral hyperintense gliosis in a patient with chronic hypertension. Note the hyperintensity related to chronic small vessel ischemia.*

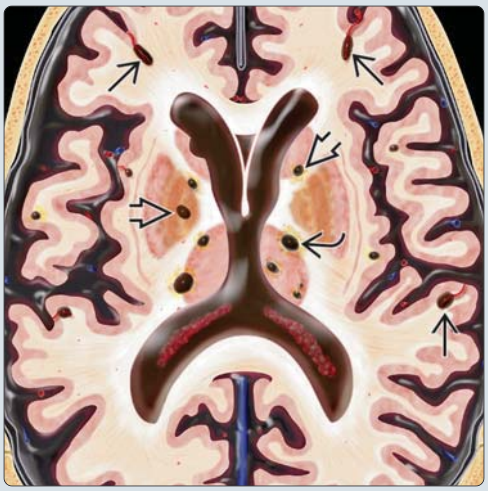

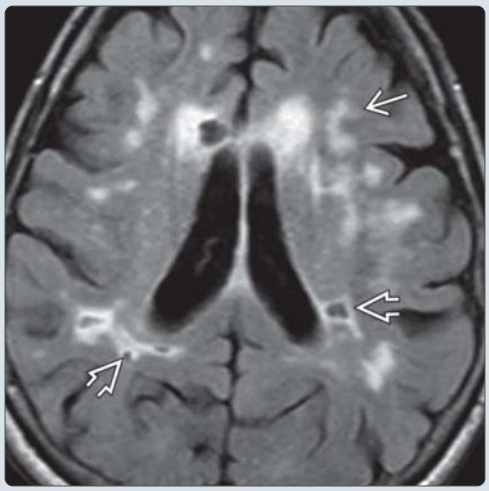

(Left) *Axial DWI MR image shows focal diffusion hyperintensity related to an acute lacunar infarct in the pons, a common location for lacunar infarcts. Risk factors for lacunar infarcts include hypertension, diabetes, smoking history, obesity, and hypercholesterolemia.* **(Right)** *Axial FLAIR MR shows a chronic lacunar infarct in the right thalamus with central encephalomalacia and mild peripheral gliosis. The surrounding gliosis and typical location can help differentiate a chronic lacunar infarct from a perivascular space.*

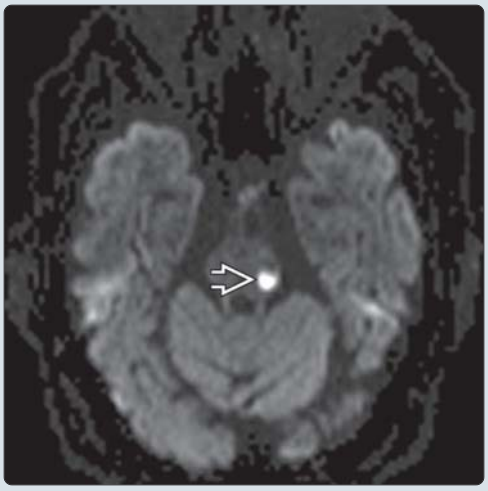

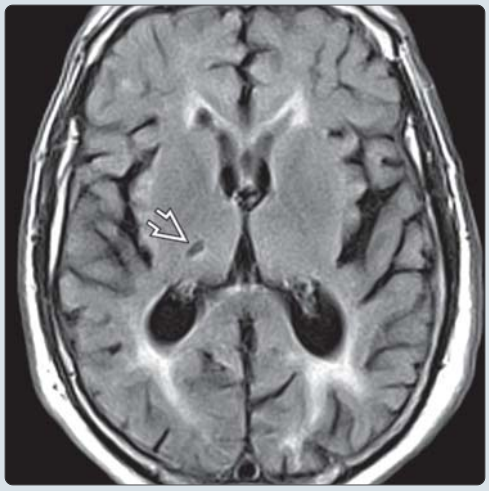

https://CafePezeshki.IR

TERMINOLOGY

Synonyms

- Lacunar infarction (LI), lacunar stroke
- "Lacunes"

Definitions

- Small, deep cerebral infarcts typically located in basal ganglia (BG) and thalamus, pons, or cerebral white matter (WM), ≤ 15 mm in size
- From Latin word "lacuna," meaning hole
  - Used to describe small focus of encephalomalacia
- "L'état lacunaire" or "lacunar state" = multifocal BG lacunar infarcts with surrounding gliosis

IMAGING

General Features

- Best diagnostic clue
  - Small, well-circumscribed areas of parenchymal abnormality (encephalomalacia) in BG, thalamus, WM
- Location
  - Commonly deep gray nuclei, especially putamen, thalamus, caudate nuclei; internal capsule, pons
  - Can be in other locations
    - Cerebral WM in patients > 65 years
    - Cerebral autosomal dominant arteriopathy with subcortical infarcts and leukoencephalopathy (CADASIL) characteristically has subcortical lacunar infarcts
- Size
  - Commonly 3 mm to 15 mm
  - Majority < 8 mm
- Morphology
  - Typically round or ovoid

CT Findings

- NECT
  - When small, may not be seen on CT scans
  - Small, well-circumscribed areas of low (CSF) attenuation
  - Usually seen in setting of more extensive WM disease; typically multiple
- CECT
  - May enhance if late acute/early subacute

MR Findings

- T1WI
  - Small, well-circumscribed, hypointense foci
- T2WI
  - Small, well-circumscribed, hyperintense foci
- FLAIR
  - Acute: Increased signal
  - Chronic: Central cystic portion suppresses (low signal) with increased peripheral signal (gliosis)
- DWI
  - Restricted diffusion (hyperintense) if acute/subacute
  - May show lesions not seen on standard sequences
- PWI
  - Abnormal PWI seen in 2/3 of cases
- T1WI C+
  - May enhance if late acute/early subacute
- MRA
  - Normal

Imaging Recommendations

- Best imaging tool
  - NECT for chronic lacunes; MR with DWI for acutely symptomatic patient
  - MR better to distinguish lacunar infarcts from perivascular spaces
- Protocol advice
  - MR with DWI if acute

DIFFERENTIAL DIAGNOSIS

Prominent Perivascular Spaces

- Normal variant resulting from accumulation of interstitial fluid within enlarged Virchow-Robin spaces
- Found in all areas, but tend to cluster around anterior commissure and in cerebral WM
- Similar to CSF signal on all pulse sequences
- Found in patients of all ages
- Increase in size and frequency with advancing age
- Up to 25% have slight halo of ↑ signal on FLAIR or T2WI
- Can expand, occur in clusters (mimic neoplasm)

État Criblé

- Multiple enlarged Virchow-Robin spaces most commonly in basal ganglia
- Blood vessels in état criblé are thickened, ectatic, with sclerotic walls
- Perivascular tissues may show reactive astrocytosis and isomorphic gliosis with glial fibers extending along degenerated axons

Neurocysticercosis

- May mimic benign intraparenchymal cysts
- Imaging findings vary with developmental stage of cyst, as well as host response
- Solitary in 20-50%; when multiple, usually small number of cysts
- Inflammatory response around cyst may seal sulcus, making lesions appear intraaxial

PATHOLOGY

General Features

- Etiology
  - Embolic, atheromatous, or thrombotic lesions in long, single penetrating end arterioles supplying deep cerebral gray matter and WM
    - Size of LI depends on level of occlusion and anatomy of affected vessel
  - Some studies suggest chronic endothelial dysfunction in cerebral small vessel disease and LI
    - Subtle WM blood-brain barrier dysfunction in patients with LI, but not with cortical ischemic strokes
  - Endothelial prothrombotic changes may be important in mediating ischemic leukoaraiosis phenotype
- Genetics
  - Usually sporadic
  - May occur secondary to genetic disorder CADASIL
- Associated abnormalities

https://CafePezeshki.IR

- Most lacunar infarctions are clinically "silent," often subtle neurological deficits that may go unnoticed by patient and physician
- Small vessel cerebrovascular disease is important vascular cause of cognitive impairment

Gross Pathologic & Surgical Features

- Similar to other types of cerebral infarction
- Earliest visible change is slight discoloration and softening of affected area
- Within 48-72 hours necrosis is well established, and there is softening, disintegration of ischemic area with circumlesional swelling
- As resolution proceeds, liquefaction results in cyst formation; more apparent in lesions of larger size
- Cysts may be traversed by trabeculations of blood vessels and are surrounded by firm glial tissue

Microscopic Features

- Gliosis along margin of infarction
- Hypertensive hyalinization of supplying arterioles
- Pigmented macrophages can be found in some lacunes, suggesting possible hemorrhagic component

CLINICAL ISSUES

Presentation

- Most common signs/symptoms
  - Many different presentations, depending on size, location, number
  - Variable symptoms, ranging from clinically "silent" to focal neurologic deficit to cognitive impairment to dementia
    - In a study of patients ≥ 65 years 23% had isolated lacunar infarcts
      - 66% of these were single, 89% clinically silent
  - Significant correlation between pure motor strokes and presence of LI in internal capsule
  - About 1/4 of patients with classic lacunar syndrome have nonlacunar infarcts on MR
  - Responsible LI seen in ~ 60% of cases in lacunar syndromes
- Clinical profile
  - Elderly, hypertensive patient
  - Typical risk factors for cerebrovascular disease: Hypertension (HTN), diabetes (DM), smoking history, obesity, hypercholesterolemia, etc.

Demographics

- Age
  - Usually > 55 years, prevalence increases with age
  - Patients with coronary artery or peripheral vascular disease are at risk for infarcts at younger age
  - Patients with CADASIL present slightly earlier, with TIA/stroke-like symptoms, beginning at ~ 45 years; cognitive decline can start as early as age 35 years
- Gender
  - Not gender specific
- Epidemiology
  - Lacunar infarcts account for up to 25% of all strokes
  - Strong association with systemic hypertension
  - Lacunar stroke is most common stroke subtype associated with vascular dementia
  - Statistically significant incidence of isolated ipsilateral carotid stenosis in patients with LI located in carotid territory

Natural History & Prognosis

- Clinically "silent" to focal neurological deficit
- HTN and DM are significant risk factors for recurrent lacunar infarction
- Many patients with LI have good functional outcomes after 5 years
  - Increased risk of mortality, stroke recurrence, physical and cognitive decline with initial severe strokes and additional vascular risk factors
- **Early** mortality and stroke recurrence less common than nonlacunar infarcts; no difference after 1 month
- Silent infarcts more than double risk of subsequent strokes and dementia
- Presence of multiple LIs may be important prognostic indicator both for functional recovery, as well as higher rate of recurrence

Treatment

- Typical treatment is targeted toward underlying etiology of vasculopathy
- More studies on mechanisms, prevention, and treatment are needed to provide specific guidance on long-term management of LI patients
  - Risk-factor modification is likely to play large part in therapeutic interventions targeted at this stroke subtype

DIAGNOSTIC CHECKLIST

Consider

- Are "lacunes" really Virchow-Robin spaces
- Is there a treatable embolic source

Image Interpretation Pearls

- To be classified as LI, location must be end-artery territory and lesion must be smaller than 15 mm

SELECTED REFERENCES

1. Dhamoon MS et al: Long-term disability after lacunar stroke: Secondary prevention of small subcortical strokes. Neurology. ePub, 2015
2. Hart RG et al: Predictors of stroke recurrence in patients with recent lacunar stroke and response to interventions according to risk status: secondary prevention of small subcortical strokes trial. J Stroke Cerebrovasc Dis. 23(4):618-24, 2014
3. Kitagawa K et al: Association between carotid stenosis or lacunar infarction and incident dementia in patients with vascular risk factors. Eur J Neurol. ePub, 2014
4. Palacio S et al: Lacunar strokes in patients with diabetes mellitus: risk factors, infarct location, and prognosis: the secondary prevention of small subcortical strokes study. Stroke. 45(9):2689-94, 2014
5. Staals J et al: Stroke subtype, vascular risk factors, and total MRI brain small-vessel disease burden. Neurology. 83(14):1228-34, 2014
6. De Reuck J et al: The classic lacunar syndromes: clinical and neuroimaging correlates. Eur J Neurol. 15(7):681-4, 2008
7. Jackson C et al: Are lacunar strokes really different? A systematic review of differences in risk factor profiles between lacunar and nonlacunar infarcts. Stroke. 36(4):891-901, 2005
8. Vermeer SE et al: Silent brain infarcts and the risk of dementia and cognitive decline. N Engl J Med. 348(13):1215-22, 2003

https://CafePezeshki.IR

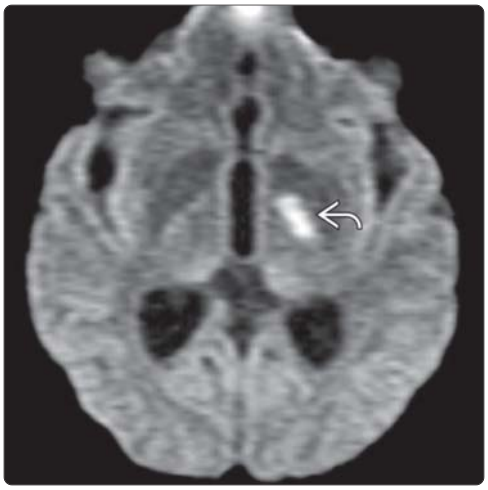

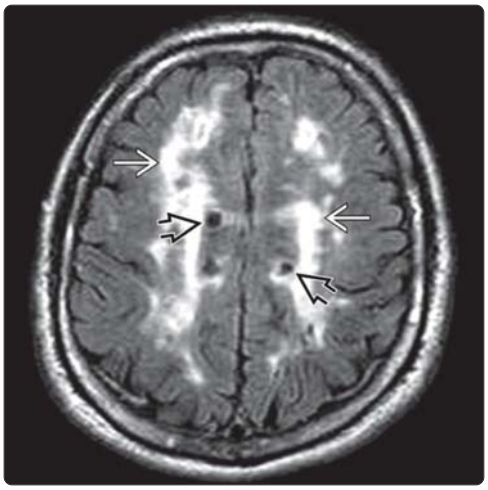

(Left) *Axial DWI MR shows hyperintensity related to an acute lacunar infarct involving the corticospinal tracts in the posterior limb of the internal capsule. Lacunar infarcts in this location have a high association with motor deficits, though the majority are clinically silent.* **(Right)** *Axial FLAIR MR shows extensive confluent white matter signal abnormality related to chronic small vessel ischemia (arteriolosclerosis). There are also multiple chronic lacunar infarcts in this young adult with CADASIL.*

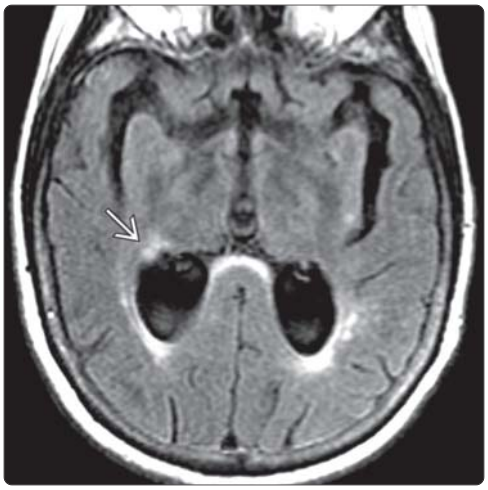

(Left) *Axial FLAIR MR shows bilateral periventricular hyperintensity, as well as a focal hyperintensity, along the lateral thalamus related to an acute lacunar infarction. Lacunar infarcts are highly associated with vascular dementia.* **(Right)** *Axial DWI MR in the same patient shows hyperintensity related to acute ischemia. Without diffusion weighted imaging, it would be impossible to distinguish this acute lacune from an area of chronic small vessel disease, which commonly coexist.*

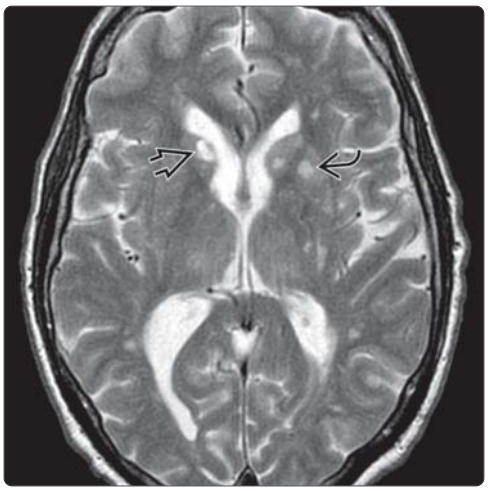

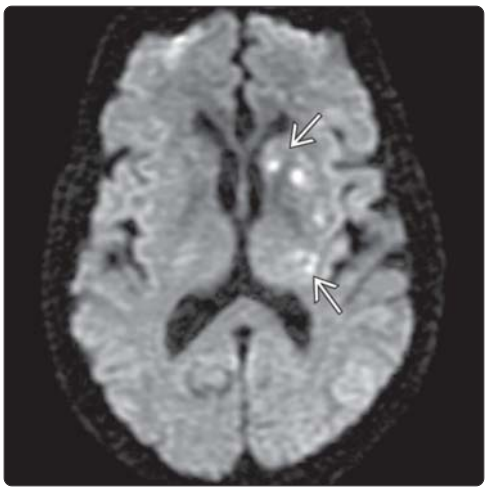

(Left) *Axial T2 MR image shows a classic appearance of multiple chronic lacunar infarcts in the basal ganglia, the most common location for this type of infarct. Note the bilateral involvement of the caudate heads and the left putamen.* **(Right)** *Axial DWI MR shows multiple foci of diffusion restriction related to multiple acute lacunar infarcts in this young adult with a drug abuse history. Drug abuse and arterial dissections are common risk factors for acute strokes in young patients.*

https://CafePezeshki.IR

KEY FACTS

TERMINOLOGY

- Rare (1-3%) disorder most commonly occurring as complication of cerebral revascularization
  - Other etiologies less common
    - Status epilepticus
    - MELAS
- Major increase in ipsilateral cerebral blood flow (CBF) well above normal metabolic demands

IMAGING

- Ipsilateral gyral swelling, sulcal effacement in post-CEA patient
- ↑ CBF, CBV on perfusion MR (pMR), perfusion CT (pCT)

TOP DIFFERENTIAL DIAGNOSES

- Acute cerebral ischemia-infarction
- Status epilepticus
- MELAS
- Acute hypertensive encephalopathy, PRES
- Hypercapnia

PATHOLOGY

- Cerebral hyperperfusion syndrome (CHS) probably caused by maladaptive autoregulatory mechanisms, altered cerebral hemodynamics
  - "Normal perfusion pressure breakthrough"
  - Rapid restoration of normal perfusion following revascularization → hyperperfusion in previously underperfused brain

CLINICAL ISSUES

- ~ 3% of post-CEA patients develop CHS
- Classic: Triad of unilateral headache, neurologic deficit and seizures
  - Variable cognitive impairment
  - Ipsilateral face, eye pain

DIAGNOSTIC CHECKLIST

- Need to distinguish stroke/TIA from CHS

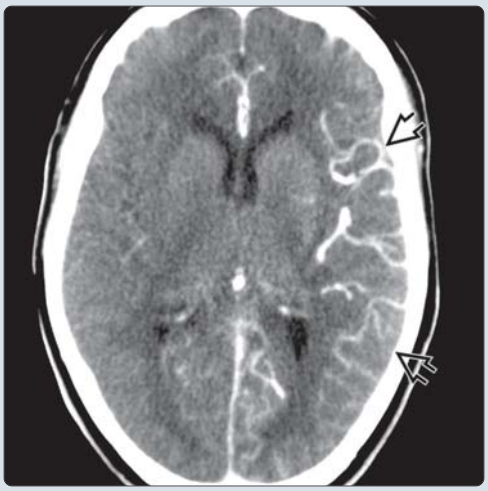

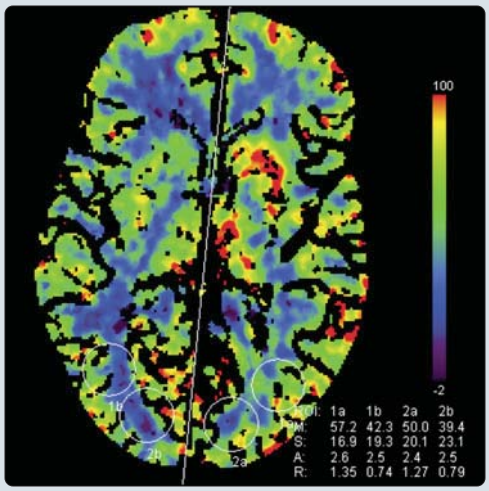

(Left) *A 56-year-old male with > 70% stenosis of his proximal left cervical ICA underwent carotid endarterectomy. A few hours after surgery, he became acutely confused and developed right-sided weakness. Perfusion source image shows markedly increased vasculature in the left hemisphere* ⇨. **(Right)** *CT perfusion obtained in the same patient appears relatively normal but CBF on the left (2a, 2b ROIs) is increased compared to the right side.*

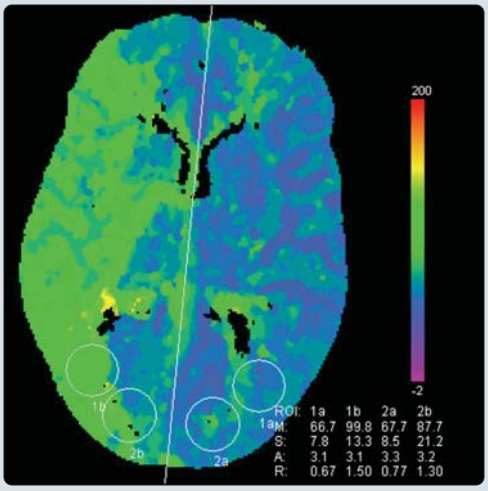

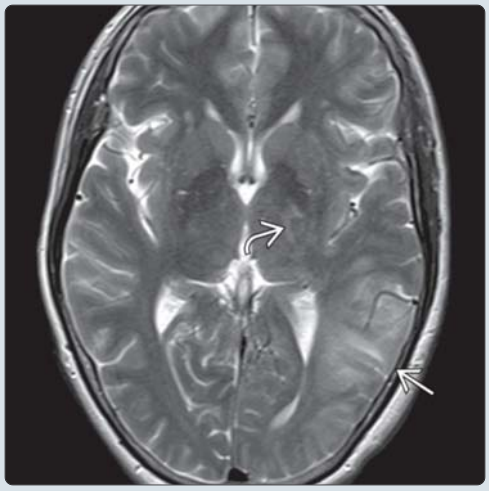

(Left) *TTP in the same patient is even more striking. The abnormal side is not the right MCA distribution (green), but is the left side (blue) where the TTP is markedly shortened.* **(Right)** *Axial T2WI in the same patient shows gyral swelling, sulcal effacement, and hyperintensity in the left temporal and parietooccipital cortex/subcortical white matter* ⇨, *basal ganglia* ⇨. *DWI (not shown) was normal. This is a classic example of postcarotid endarterectomy hyperperfusion syndrome.*

https://CafePezeshki.IR

TERMINOLOGY

Abbreviations

- Cerebral hyperperfusion syndrome (CHS)

Synonyms

- Postcarotid endarterectomy hyperperfusion
- Luxury perfusion

Definitions

- Rare (1-3%) disorder most commonly occurring as complication of cerebral revascularization
  - Mildly ↑ CBF common after carotid endarterectomy (CEA), typically asymptomatic
  - CHS defined as ≥ 100% increase in rCBF compared to preoperative values
- Major increase in ipsilateral CBF well above normal metabolic demands
  - Usually following carotid revascularization procedure
  - May occur in other settings (e.g., status epilepticus, MELAS)

IMAGING

General Features

- Best diagnostic clue
  - Ipsilateral gyral swelling, sulcal effacement in post-CEA patient
  - ↑ CBF, CBV on perfusion MR (pMR), perfusion CT (pCT)
- Size
  - Variable
- Morphology
  - Follows vascular distribution

Imaging Recommendations

- Best imaging tool
  - MR with DWI, PWI
  - SPECT
- Protocol advice
  - Add T2* (GRE or SWI) to look for hemorrhage

CT Findings

- NECT
  - Gyral swelling
  - Cortical effacement
  - ± hypodensity (may occur without attenuation alterations)
  - Frank hemorrhage in < 1%
- CECT
  - Prominent vessels with ↑ intravascular enhancement
  - May demonstrate contrast extravasation in severe cases (rare)

MR Findings

- T1WI
  - Cortical swelling
  - ± mild hypointensity
  - Sulci effaced
- T2WI
  - Gyral swelling, hyperintensity
- FLAIR
  - Hyperintense cortex
  - Hyperintensity in subarachnoid spaces on post-contrast FLAIR reported 2° to BBB disruption
- T2* GRE
  - Frank hemorrhage in < 1%
  - "Blooming" on GRE or SWI
- DWI
  - Usually normal as edema is vasogenic, not cytotoxic
  - ~ 25% show small foci of restricted diffusion compared to preoperative DWI
- PWI
  - Elevated CBV, CBF
  - Prolonged MTT
    - Side-to-side difference of 3 seconds predictive of CHS
- T1WI C+
  - May be normal
  - May show slightly increased prominence of cerebral vessels
  - Parenchymal enhancement in severe cases
- MRA
  - Preoperative ↓ signal intensity in MCA may identify patients at risk for CHS

Other Modality Findings

- SPECT
  - N-isopropyl-p-I-123-iodoamphetamine or I-123-iomazenil SPECT
    - Shows hyperperfusion in ipsilateral cerebral hemisphere after surgery
    - Can be detected even in asymptomatic patients
    - May be correlated with long-term neuronal damage that CT, MR do not detect
    - May be associated with crossed cerebellar diaschisis

DIFFERENTIAL DIAGNOSIS

Acute Cerebral Ischemia-Infarction

- Time-to-peak/mean transit time prolonged (not decreased)
- Typically shows restriction on DWI (CHS often negative)

Status Epilepticus

- Metabolic hyperperfusion in affected brain
- History of seizure helpful but may not be available

Acute Hypertensive Encephalopathy, PRES

- Failed autoregulation → hyperperfusion → endothelial injury/vasogenic edema
- Predilection for posterior circulation
- Markedly elevated blood pressure (many etiologies)
  - Eclampsia, preeclampsia
  - Chemotherapy
  - Renal failure
  - Hemolytic uremic syndrome/thrombotic thrombocytopenic purpura
  - Drug abuse (especially cocaine)

MELAS

- Acute oxidative phosphorylation defect
- Stroke-like episodes related to vasogenic edema, hyperperfusion, neuronal damage
- Cortical hyperintensity, enhancement
- Perform MRS in unaffected region, look for lactate

https://CafePezeshki.IR

Hypercapnia

- Carbon dioxide is potent stimulator of CBF
- Vasodilatory effect on cerebral vasculature

PATHOLOGY

General Features

- Etiology
  - Cognitive impairment after CEA/stenting may result from
    - Cerebral embolization during dissection, stenting
    - Global cerebral hypoperfusion during carotid cross-clamping
    - Cerebral hyperperfusion syndrome
  - CHS probably caused by maladaptive autoregulatory mechanisms, altered cerebral hemodynamics
    - "Normal perfusion pressure breakthrough"
      - Chronic ischemia → impaired autoregulation
      - Loss of normal vasoconstriction
      - "Resistance" vessels become chronically dilated
      - Rapid restoration of normal perfusion following revascularization → hyperperfusion in previously underperfused brain

CLINICAL ISSUES

Presentation

- Classic: Triad of unilateral headache, neurologic deficit and seizures
- Other signs/symptoms
  - Variable cognitive impairment
  - Face, eye pain

Demographics

- Age
  - For postendarterectomy CHS, generally older patients
  - For other etiologies (e.g., seizure, MELAS), any age
- Epidemiology
  - ~ 3% of post-CEA patients develop mild CHS
  - Covariate clinical risk factors
    - Age
    - Hypertension (especially postoperative)
    - Diabetes
    - Bilateral lesions
    - Extent of ICA stenosis
      - High grade > low grade
    - Presence of contralateral carotid occlusion or high-grade stenosis
    - Duration of cross-clamping
    - Diminished carotid reserve
    - Poor collateral blood flow
    - Decreased cerebrovascular reactivity to acetazolamide challenge

Natural History & Prognosis

- Neurological emergency
  - If not treated promptly/adequately, can cause death or severe disability
- If no intracranial hemorrhage
  - Usually reversible
  - No major tissue destruction
  - May result in persistent mild cognitive impairment
- 1% of CHS with intracranial hemorrhage
  - Poor prognosis

Treatment

- Prevention
  - Minimize intraoperative cerebral ischemia
  - Consider continuing postoperative anesthesia/continuous sedation
  - Strict postoperative blood pressure control

DIAGNOSTIC CHECKLIST

Consider

- Post-CEA/carotid artery stenting patient with neurologic deficit
  - Need to distinguish stroke/transient ischemic attack from CHS

SELECTED REFERENCES

1. Cano EJ et al: Asymmetric brain edema after cardiac transplantation: cerebroautoregulatory failure and relative hyperperfusion. Transplant Proc. 47(1):194-7, 2015
2. Fujimura M et al: Quantitative analysis of early postoperative cerebral blood flow contributes to the prediction and diagnosis of cerebral hyperperfusion syndrome after revascularization surgery for moyamoya disease. Neurol Res. 37(2):131-8, 2015
3. Horie N et al: De novo ivy sign indicates postoperative hyperperfusion in moyamoya disease. Stroke. 45(5):1488-91, 2014
4. Rafiq MK et al: Cerebral hyperperfusion syndrome. Pract Neurol. 14(1):64-6, 2014
5. Brantley HP et al: Hyperperfusion syndrome following carotid artery stenting: the largest single-operator series to date. J Invasive Cardiol. 21(1):27-30, 2009
6. Grunwald IQ et al: Hyperperfusion syndrome after carotid stent angioplasty. Neuroradiology. 51(3):169-74, 2009
7. Kuroda H et al: Prediction of cerebral hyperperfusion after carotid endarterectomy using middle cerebral artery signal intensity in preoperative single-slab 3-dimensional time-of-flight magnetic resonance angiography. Neurosurgery. 64(6):1065-71; discussion 1071-2, 2009
8. Medel R et al: Hyperperfusion syndrome following endovascular cerebral revascularization. Neurosurg Focus. 26(3):E4, 2009
9. Moulakakis KG et al: Hyperperfusion syndrome after carotid revascularization. J Vasc Surg. 49(4):1060-8, 2009
10. Tseng YC et al: Prediction of cerebral hyperperfusion syndrome after carotid stenting: a cerebral perfusion computed tomography study. J Comput Assist Tomogr. 33(4):540-5, 2009
11. Hirooka R et al: Magnetic resonance imaging in patients with cerebral hyperperfusion and cognitive impairment after carotid endarterectomy. J Neurosurg. 108(6):1178-83, 2008
12. Fukuda T et al: Prediction of cerebral hyperperfusion after carotid endarterectomy using cerebral blood volume measured by perfusion-weighted MR imaging compared with single-photon emission CT. AJNR Am J Neuroradiol. 28(4):737-42, 2007
13. Park KY et al: Cortical sulcal effacement on brain CT associated with cerebral hyperperfusion after carotid artery stenting. J Neurol Sci. 260(1-2):83-6, 2007

https://CafePezeshki.IR

(Left) *Anteroposterior view of DSA shows abrupt occlusion of the left middle cerebral artery just distal to its origin ⇨ in a patient with a sudden onset of right-sided weakness and stroke-like symptoms. Little collateral filling of the distal MCA is seen.* **(Right)** *After superselective catheterization of the left MCA and infusion of tissue plasminogen activator for 2 hours, normal circulation was restored, as shown on this anteroposterior DSA.*

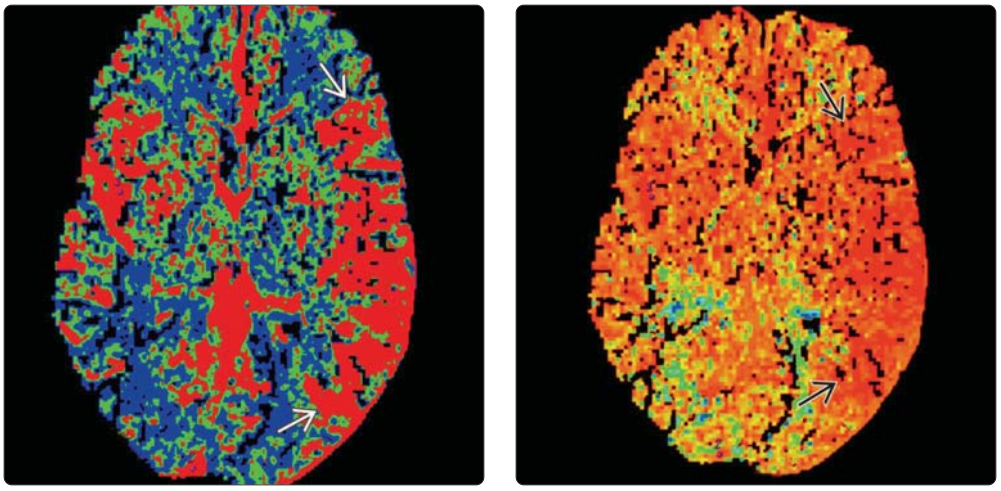

(Left) *Following restoration of normal blood flow in the previously occluded left MCA, the patient experienced worsening right-sided weakness and throbbing headache. This axial MR perfusion study shows elevated (red area ➡), not decreased, CBF in the left temporal and parietal lobes.* **(Right)** *Axial MR perfusion in the same patient shows elevated cerebral blood volume ⇨.*

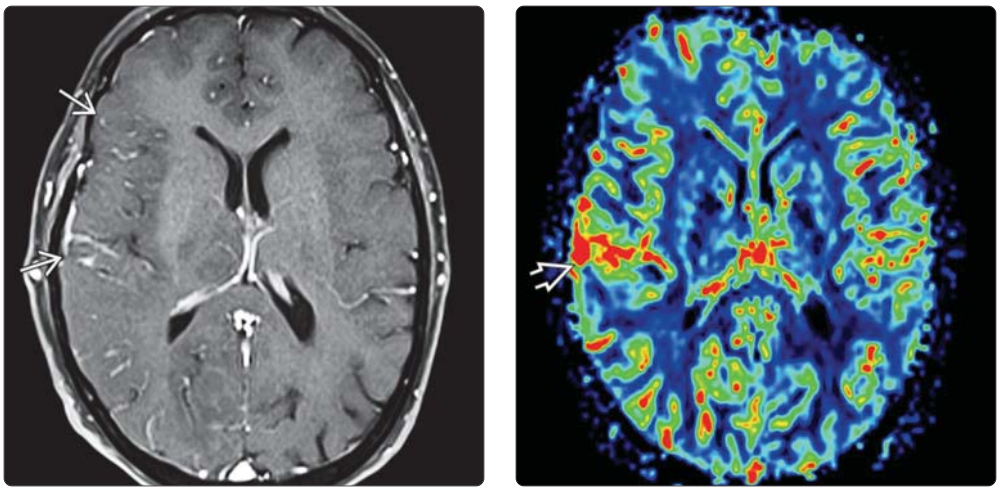

(Left) *Cerebral hyperperfusion in status epilepticus is illustrated by this T1C+FS scan in a 52-year-old female with left-sided weakness following prolonged seizure. Note the increased intravascular, sulcal enhancement in the right temporal lobe compared to the left hemisphere ➡.* **(Right)** *pMR in the same patient shows increased CBF in the right temporal lobe ➡, corresponding to the increased intravascular enhancement noted on the T1C+FS MR.*

https://CafePezeshki.IR

KEY FACTS

IMAGING

- General features
  - "Empty delta" sign on CECT, T1WI C+ MR
- CT
  - Hyperdense sinus on NECT (usually > 70 HU)
  - ± hyperdense cortical veins ("cord" sign)
  - CTV: Filling defect (thrombus) in dural sinus
- MR
  - Hypointense thrombus "blooms" on T2* GRE
  - Absence of flow in occluded sinus on 2D TOF MRV
- Protocol recommendations
  - NECT, CECT scans ± CTV as initial screening
  - If CTs negative, MR + MRV (T2*, DWI, T1WI C+)
  - If MRV equivocal, DSA is gold standard

TOP DIFFERENTIAL DIAGNOSES

- Normal (arteries, veins normally slightly hyperdense)
- High hematocrit (newborns, polycythemia)
- Dural sinus hypoplasia/aplasia
  - No "blooming"; collaterals/venous infarcts absent
- "Giant" arachnoid granulations
  - Round/ovoid, not elongated like thrombus
- Acute subdural hematoma
  - Blood layered on tentorium can mimic transverse sinus (TS) thrombosis

DIAGNOSTIC CHECKLIST

- Review MRV source images
  - Exclude pseudoocclusions (e.g., hypoplastic TS)
- Review T1 images to exclude false-negative MRV
- Review NECT to exclude dense thrombus as false-negative CECT or CTV
- Brain looks normal
  - Does not exclude CVT
- DSA helpful if noninvasive imaging inconclusive
- Chronic thrombosis may enhance
  - Recanalization or granulation tissue enhances

(Left) *Sagittal graphic shows thrombosis of the superior sagittal sinus ➡ and straight sinus ➡. Inset in the upper left reveals a thrombus in the superior sagittal sinus in cross section ("empty delta" sign) ➡ seen on contrast-enhanced imaging.* **(Right)** *NECT scan in a 25-year-old male with progressively increasing headaches shows hyperdensity in the right transverse ➡ and straight sinuses ➡. Both internal cerebral veins are hyperdense ➡ and the right thalamus ➡ is hypodense and edematous.*

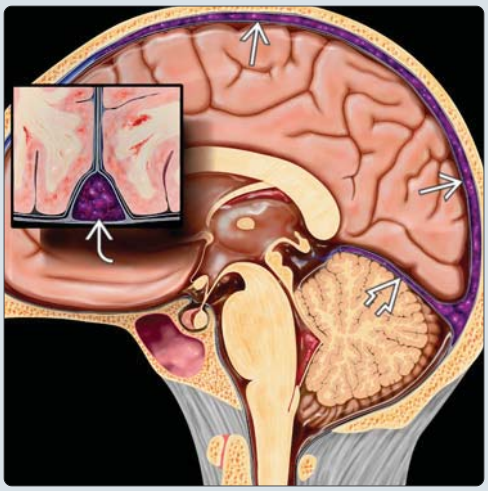

(Left) *Axial source image from a CTV in the same patient shows the dura around the superior axial sinus enhances ➡, but its clot-filled lumen ➡ does not ("empty delta" sign).* **(Right)** *Sagittal reformatted view of the CTV in the same patient shows extensive nonenhancing thrombus in the superior sagittal ➡ and straight ➡ sinuses. The internal cerebral veins ➡ are occluded and do not enhance. Findings indicate extensive dural sinus, deep vein thrombosis.*

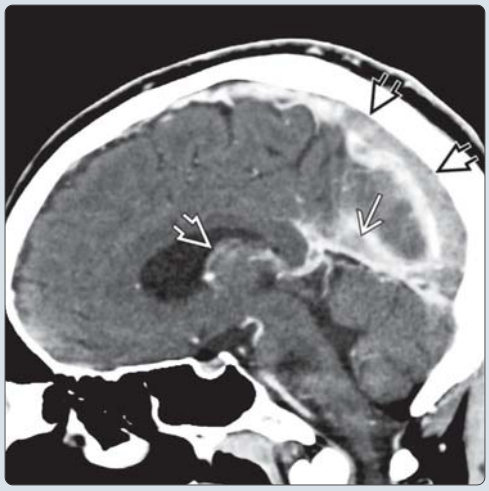

https://CafePezeshki.IR

TERMINOLOGY

Abbreviations

- Dural sinus thrombosis (DST)
  - Chronic dural sinus thrombosis (cDST)
- Cerebral vein thrombosis (CVT)

Definitions

- Thrombotic occlusion of intracranial dural sinuses

IMAGING

General Features

- Best diagnostic clue
  - Hyperdense (65-70 HU) on NECT
  - **"Empty delta" sign** on CECT, T1WI C+ MR
- Location
  - Thrombus in dural sinus ± adjacent cortical vein(s)

CT Findings

- NECT
  - Early imaging findings often subtle
  - Hyperdense sinus (compare to carotid arteries)
    - Usually > 65 HU (74 ± 9 HU vs. 53 ± 7 in normal)
    - Distinguish thrombus vs. hyperdense sinus from high hematocrit (HCT)
      - HU:HCT ratio in thrombus 1.9 ± 0.32 vs. 1.33 ± 0.12 nonthrombus
  - ± hyperdense cortical veins (**"cord" sign**)
  - ± venous infarct (50%)
    - Cortical/subcortical petechial hemorrhages, edema
    - Straight sinus (SS) ± internal cerebral veins (ICV) occlusion
      - Thalami/basal ganglia hypodense, swollen
- CECT
  - **"Empty delta" sign** (25-30%)
    - Enhancing dura surrounds nonenhancing thrombus
  - "Shaggy," enlarged/irregular veins (collateral channels)
- CTA/CTV
  - Filling defect (thrombus) in dural sinus
    - Caution: Acute clot can be hyperdense, obscured on CECT/CTV
      - Always include NECT for comparison

MR Findings

- T1WI
  - Acute thrombus: Isointense with brain
  - Subacute thrombus: Hyperintense
  - Chronic thrombus: Isointense
  - Normal variations in dural sinus flow may mimic thrombosis; vascular exam (CTV or MRV) more reliable to confirm suspected DST
- T2WI
  - Acute thrombus: Hypointense
    - Caution: Hypointense thrombus can mimic normal sinus "flow void"
  - Subacute thrombus: Hyperintense
  - Chronic thrombus: Hyperintense
    - Longstanding thrombosed sinus eventually appears isointense
  - Venous infarct: Mass effect with mixed hypo-/hyperintense signal in adjacent parenchyma
- PD/intermediate
  - Loss of normal flow voids
  - More sensitive than T2WI
- FLAIR
  - Clot signal varies
  - Venous ischemia/infarcts hyperintense
- T2* GRE
  - Hypointense thrombus usually **"blooms"**
  - ± hypointense petechial hemorrhages
- DWI
  - 40% have hyperintense clot in occluded vessel (usually T2 "shinethrough" effect)
  - DWI/ADC findings in parenchyma variable, heterogeneous
    - Mixture of vasogenic, cytotoxic edema
      - Cytotoxic edema may precede vasogenic edema
      - Parenchymal abnormalities may be reversible
- T1WI C+
  - Acute, subacute DST: Dura enhances, clot doesn't ("empty delta" sign)
  - cDST: longstanding clot can enhance
    - Organized fibrous tissue ± recanalization
      - Potential source of false-negative interpretation
    - Look for "squiggly" vessels
- MRV
  - 2D TOF or contrast MRV
  - Absence of flow in occluded sinus on 2D TOF MRV
    - Frayed or shaggy appearance of venous sinus
    - Abnormal collateral channels (e.g., enlarged medullary veins)
  - T1 hyperintense (subacute) clot can masquerade as flow on MRV; evaluate standard sequences, source images to exclude artifacts
    - Potential cause of false-negative MRV
  - Flow gaps on MIPs must be reviewed on source images to exclude hypoplastic sinus variants, particularly for transverse and sigmoid sinus
    - Potential source of false-positive interpretation on MIPs
  - Contrast-enhanced MRV (CE-MRV) shows thrombus, small vein detail, collaterals much better than 2D TOF
  - Phase contrast MRV not limited by T1 hyperintense thrombus
- SWI shows "blooming" clot
  - Caution: Cortical and deep veins are normally hypointense (deoxyhemoglobin)
  - Look for prominent medullary veins (slow collateral flow in some cases of DST)

Angiographic Findings

- Occlusion of involved sinus
- Slow flow in adjacent patent cortical veins
- Collateral venous drainage develops

Imaging Recommendations

- Best imaging tool
  - NECT, CECT scans ± CTV as initial screening
  - MR, MRV (include T2*, DWI, T1WI C+)
- Protocol advice

https://CafePezeshki.IR

- If CT/CECT/CTV negative, MR with MRV
- If MRV equivocal, cerebral angiography

DIFFERENTIAL DIAGNOSIS

Normal

- Arteries, veins normally slightly hyperdense on NECT

High Hematocrit

- Common in newborns (low density brain, physiologic polycythemia)
- Polycythemia vera (both arteries, veins equally hyperdense)

Dural Sinus Hypoplasia-Aplasia

- Congenital hypoplastic/aplastic transverse sinus
  - Transverse sinus flow gaps (31%); nondominant sinus
  - Right transverse sinus dominant (59%), left dominant (25%), codominant (16%)
- "High-splitting" tentorium

"Giant" Arachnoid Granulations

- Round/ovoid filling defect (clot typically long, linear)
- Cerebrospinal fluid (CSF) density/signal intensity
- Normal in 24% of CECT, 13% of MR
  - Transverse sinus most common location by imaging, left > right
  - Superior sagittal sinus most common location for arachnoid granulations on histopathology (lateral lacunae, not well seen by imaging)

Acute Subdural Hematoma

- Layered blood on tentorium cerebelli may mimic transverse sinus thrombosis

PATHOLOGY

General Features

- Etiology
  - Wide spectrum of predisposing causes
    - Trauma, infection, inflammation
    - Pregnancy, oral contraceptives
    - Metabolic (dehydration, thyrotoxicosis, cirrhosis)
    - Hematological (coagulopathy)
    - Collagen-vascular disorders (APLA syndrome)
    - Vasculitis (Behçet)
  - Most common pattern
    - Thrombus forms in dural sinus
    - Clot propagates into cortical veins
    - Venous drainage obstructed, venous pressure elevated
    - Blood-brain barrier breakdown with vasogenic edema, hemorrhage
    - Venous infarct with cytotoxic edema
- Genetics
  - Resistance to activated protein C (typically due to factor 5 Leiden mutation): Most common cause of sporadic CVT
  - Protein S deficiency
  - Prothrombin (factor II) gene mutation
- Associated abnormalities
  - Dural AV fistula; venous occlusive disease may be underlying etiologic factor

Staging, Grading, & Classification

- **Venous ischemia grading**
  - Type 1: No abnormality
  - Type 2: Hyperintense on T2/FLAIR; no enhancement
  - Type 3: Hyperintense on T2/FLAIR; enhancement
  - Type 4: Hemorrhage or venous infarction

Gross Pathologic & Surgical Features

- Sinus occluded, distended by acute clot
- Thrombus in adjacent cortical veins
- Edematous adjacent cortex; petechial hemorrhage

Microscopic Features

- Thrombosis of veins, proliferative fibrous tissue in chronic thromboses

CLINICAL ISSUES

Presentation

- Most common signs/symptoms
  - Clinical diagnosis often elusive
    - Most common = headache
    - Other = nausea, vomiting ± neurologic deficit

Demographics

- Age
  - Any age can be affected
- Gender
  - F > M
- Epidemiology
  - Venous accounts for 1% of acute strokes

Natural History & Prognosis

- Extremely variable: Asymptomatic to coma, death
  - Up to 50% of cases progress to venous infarction
  - Can be fatal if severe brain swelling, herniation

Treatment

- In-patient heparin followed by out-patient warfarin (Coumadin)
- In more severe cases, endovascular mechanical thrombectomy ± local heparin infusion

DIAGNOSTIC CHECKLIST

Consider

- Angiography for patients with suspected chronic DST
- Venous filling defect from arachnoid granulation

SELECTED REFERENCES

1. Coutinho JM et al: Cerebral venous thrombosis in the absence of headache. Stroke. 46(1):245-7, 2015
2. Lizé F et al: Septic cavernous sinus thrombosis secondary to acute bacterial sinusitis: A retrospective study of seven cases. Am J Rhinol Allergy. 29(1):7-12, 2015
3. Bonneville F: Imaging of cerebral venous thrombosis. Diagn Interv Imaging. 95(12):1145-50, 2014
4. Buyck PJ et al: CT density measurement and H:H ratio are useful in diagnosing acute cerebral venous sinus thrombosis. AJNR Am J Neuroradiol. 34(8):1568-72, 2013
5. Gala NB et al: Current endovascular treatment options of dural venous sinus thrombosis: a review of the literature. J Neurointerv Surg. 5(1):28-34, 2013
6. Black DF et al: Cerebral venous sinus density on noncontrast CT correlates with hematocrit. AJNR Am J Neuroradiol. 32(7):1354-7, 2011

https://CafePezeshki.IR

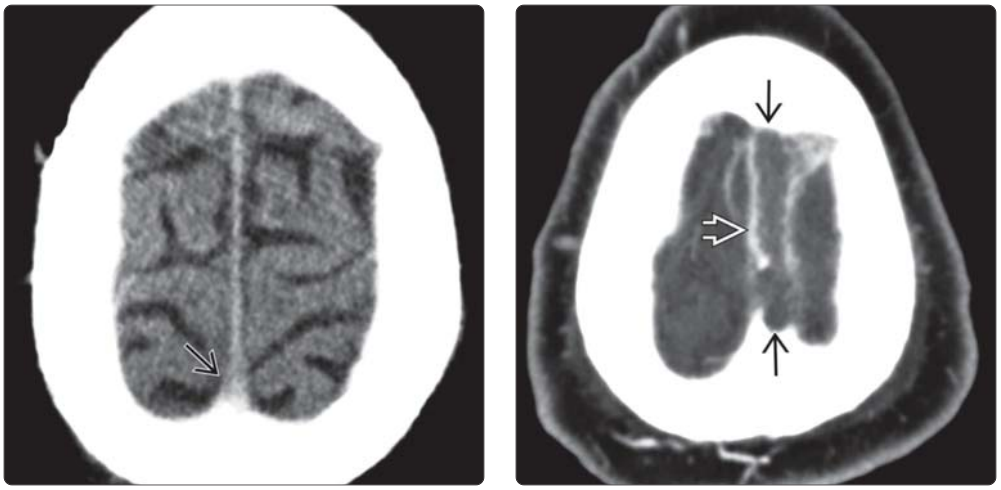

(Left) *NECT scan in a 68-year-old male with a 2-day history of headache and confusion shows no definite abnormality. The superior sagittal sinus ⇨ measured 60 HU.* **(Right)** *Axial CT venogram in the same patient shows nonenhancing thrombus ⇨ filling the entire SSS. The dural walls of the SSS enhance ⇨.*

(Left) *T2WI in the same patient shows hypointensity in the SSS ⇨ and cortical veins ⇨ mimicking normal "flow voids."* **(Right)** *T2* GRE in the same patient shows "blooming" thrombus in the SSS ⇨ and cortical veins ⇨. Acute thrombus can mimic normal "flow voids" on T2WI, but susceptibility-weighted scans (GRE or SWI) easily depict the intraluminal clots.*

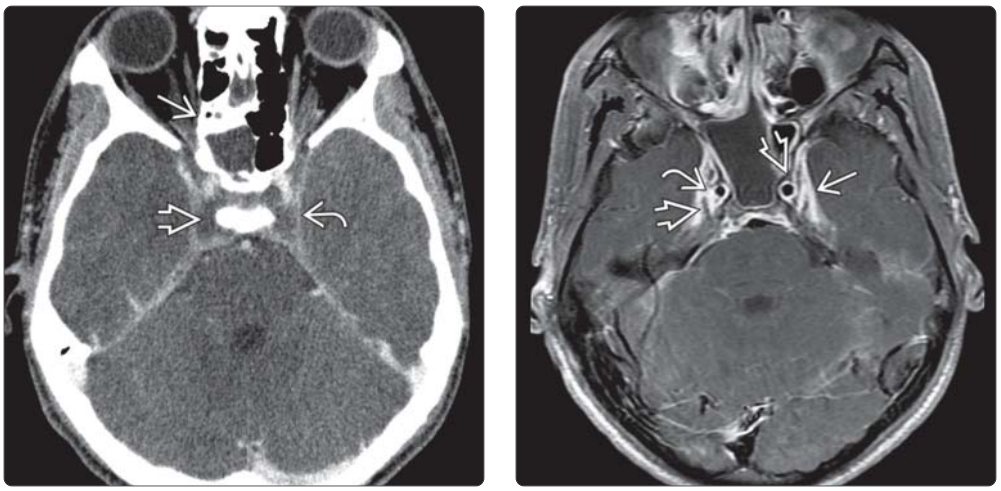

(Left) *Cavernous sinus thrombosis can be difficult to diagnose. Most cases occur as complications from severe sphenoid sinusitis ⇨ and are seen as nonenhancing clot ⇨ contained by the enhancing dural walls ⇨.* **(Right)** *Axial T1C+FS MR in the same patient shows the nonenhancing clot ⇨ in the enhancing dural walls ⇨ and internal septae ⇨ of the CS. Patients with CS thrombophlebitis almost always have headache, cranial nerve palsies, and sphenoid sinusitis.*

https://CafePezeshki.IR

KEY FACTS

TERMINOLOGY

- Cortical/cerebral venous thrombosis (CVT)
- Dural sinus thrombosis (DST)
- CVT with DST > isolated CVT without DST

IMAGING

- NECT
  - "Cord" sign (hyperdense vein)
  - Involved veins usually enlarged (distended with clot), irregular
  - ± petechial parenchymal hemorrhage, edema
- CECT
  - If DST, "empty delta" sign (25-30% of cases)
  - CTV: Thrombi may be seen as filling defects
- MR
  - Acute thrombus isointense on T1WI
  - Hypointense on T2WI (can mimic flow void)
  - T2* GRE best (clot usually blooms)
- 2D time of flight (TOF) MRV
  - Thrombus seen as sinus discontinuity, loss of vascular flow signal
  - Subacute thrombus T1 hyperintense (mimics patent flow on MIP)
- Imaging recommendations
  - NECT, CECT scans ± CTV
  - If CT negative → MR/MRV with T1WI C+, GRE
  - If MR is equivocal → DSA (gold standard)

TOP DIFFERENTIAL DIAGNOSES

- Normal (circulating blood slightly hyperdense)
- Anatomic variant (hypoplastic segment can mimic DST)

CLINICAL ISSUES

- Most common symptom is headache

DIAGNOSTIC CHECKLIST

- If "convexal" subarachnoid hemorrhage is seen, consider CVT

(Left) *Autopsy case shows thrombus in several cortical veins ⇨, the pathologic basis for the "cord" sign. (Courtesy E.T. Hedley-Whyte, MD.)* **(Right)** *Axial NECT scan in a patient with thrombosis of the superior sagittal sinus shows dense clot ⇨ filling and expanding the SSS. Thrombus is seen in a vein ⇨ over the cerebral convexity. Most (but not all) cortical vein thrombi occur as extension from clot in an adjacent dural venous sinus.*

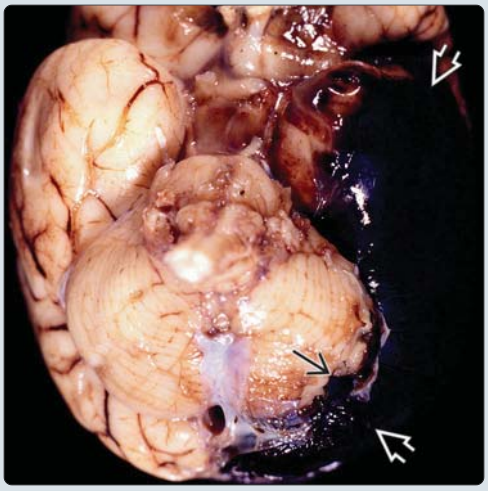

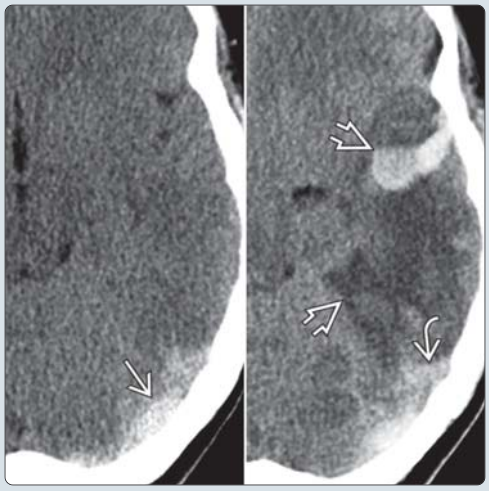

(Left) *Autopsy case of transverse sinus thrombosis ⇨ that occluded the vein of Labbé shows extensive hemorrhagic venous infarction of the temporal, parietal, and occipital lobes ⇨. (Courtesy R. Hewlett, MD.)* **(Right)** *This 23-year-old woman presented in the ER with "migraine headache." Initial NECT scan (left) was called normal. Note the hyperdense thrombus in left TS ⇨. CT 1 day later (right) shows vein of Labbé thrombosis ⇨ and a large left temporal lobe hemorrhagic venous infarct ⇨.*

https://CafePezeshki.IR

TERMINOLOGY

Abbreviations

- Cortical/cerebral venous thrombosis (CVT)
- Dural sinus thrombosis (DST)

Definitions

- Superficial cerebral venous thrombosis
  - Usually with DST but isolated CVT without DST can occur

IMAGING

General Features

- Best diagnostic clue
  - "Cord" sign on NECT, T2* GRE
- Location
  - Cortical veins (unnamed)
    - Anastomotic vein of Labbé
    - Anastomotic vein of Trolard
  - Can be solitary, multiple
- Morphology
  - Veins usually enlarged (distended with clot), irregular
  - Linear, cigar-shaped thrombus

CT Findings

- NECT
  - Hyperdense cortical vein ("cord" sign) ± DST
  - Parenchymal abnormalities common
    - Petechial hemorrhage, edema
    - Hypodensity in affected vascular distribution
  - Need NECT to exclude false-negative CTV
    - Thrombus dense, can mimic enhancement
- CECT
  - If DST present
    - "Empty delta" sign (25-30% of cases)
  - "Shaggy," irregular enhancing veins (collateral channels)
- CTV
  - Thrombus seen as filling defect in cortical veins
  - Abnormal collateral channels (e.g., enlarged medullary veins)
  - Negative CTV does not exclude CVT
    - Limited value for chronic CVT
      - Organizing thrombosis also enhances
    - Limited value for nonocclusive thrombus
    - Optimize technique using thin slice (0.6 mm) MDCT with venous phase enhancement and dedicated sagittal and coronal MPR (1-2 mm)
    - Thick slice (3-5 mm) sliding or overlapping MIPs in sagittal and coronal planes
    - Concurrent NECT important to exclude false-negative CTV due to intrinsically dense thrombus
    - Subacute and chronic thromboses can enhance: Potential false-negative

MR Findings

- T1WI
  - Thrombus is isointense early, hyperintense later
  - ± venous infarct
    - Gyral swelling, edema hypointense
    - Iso- to slightly hyperintense foci if hemorrhagic
- T2WI
  - Thrombus hypointense acutely, hyperintense much later
    - Acute clot can mimic flow void
  - Venous infarct
    - Gyral swelling, edema hyperintense
    - Hypointense foci if hemorrhagic
- FLAIR
  - Thrombus usually hyperintense
  - Parenchymal edema hyperintense
- T2* GRE
  - GRE most sensitive sequence for thrombus
    - Hypointense ("black"), cord-like
  - SWI not as helpful due to intrinsic hypointensity of normal veins
- DWI
  - DWI/ADC varies with ischemia, type of edema, hemorrhage
    - Distinguishes cytotoxic from vasogenic edema
- T1WI C+
  - Thin (1 mm) 3D volume acquisition
  - Acute/early subacute clot: Peripheral enhancement outlines clot
  - Late clot: Thrombus, fibrous tissue often enhances
  - Venous infarct: Patchy enhancement
- MRV
  - 2D time of flight (TOF) MRV depicts thrombus as sinus discontinuity, loss of vascular flow signal
    - May see abnormal collateral channels (e.g., enlarged medullary veins)
    - Occluded veins at time of diagnosis may predict low rate of vessel recanalization 2 or 3 months later
  - Contrast-enhanced MRV (CE-MRV)
    - Faster; better depicts nonenhancing thrombus and small veins than TOF
  - TOF limitations
    - T1 hyperintense thrombus (subacute) may mimic patent flow on MIP (false-negative MRV)
    - Must evaluate source images and conventional MR sequences to exclude potential false-negatives
  - Phase contrast MRV: T1 hyperintense thrombus not misrepresented as flow

Ultrasonographic Findings

- Transcranial Doppler (TCD) ultrasound
  - Monitor venous flow velocities at ICU bedside
  - Follow therapy as decreasing velocities
  - Caveat: Normal venous velocities in serial measurements do not exclude diagnosis of CVT

Angiographic Findings

- Conventional DSA, venous phase
  - More accurate than MR, particularly for isolated cortical vein thrombosis
  - Considered gold standard
  - Chronic thromboses challenging due to enhancement from recanalization/organizing thrombus
- Interventional: Treatment with thrombolytics &/or mechanical declotting

Imaging Recommendations

- Best imaging tool
  - NECT, CECT ± CTV

https://CafePezeshki.IR

- MR with T1WI C+, GRE if CTV negative but high suspicion
- DSA is gold standard
- Protocol advice
  - If CT negative → MR with T1WI C+, GRE, MRV
  - If MR, MRV equivocal → DSA

DIFFERENTIAL DIAGNOSIS

Normal

- Circulating blood normally mildly hyperdense on NECT

Anatomic Variant

- Congenital hypoplasia can mimic DST
- Vein of Trolard, Labbé, superficial middle cerebral vein (SMCV) have reciprocal size relationship
  - If 2 are prominent, 3rd usually hypoplastic

"Giant" Arachnoid Granulation

- Can mimic DST
- Round/ovoid filling defect (clot is long, linear)
- CSF density, signal intensity

Cerebral Hemorrhage

- Mimics venous infarct
- Amyloid
- Cerebral contusion
- Hypertensive

PATHOLOGY

General Features

- Etiology
  - No cause identified in 20-25% of cases
  - Wide spectrum of predisposing causes (> 100 identified)
    - Trauma, infection, inflammation, malignancy
    - Pregnancy, oral contraceptives
    - Metabolic (dehydration, thyrotoxicosis, cirrhosis, hyperhomocysteinemia, etc.)
    - Hematological (coagulopathy)
    - Collagen-vascular disorders (e.g., APLA syndrome)
    - Vasculitis (e.g., Behçet)
    - Drugs (androgens, MDMA "ecstasy")
  - Most common pattern
    - Thrombus initially forms in dural sinus
    - Clot propagates into cortical veins
    - Venous drainage obstructed → ↑ venous pressure
    - Blood-brain barrier breakdown with vasogenic edema, hemorrhage
    - Venous infarct with cytotoxic edema ensues
  - Isolated CVT without DST occurs but is uncommon

Gross Pathologic & Surgical Features

- Sinus occluded, distended by acute clot
- Thrombus in adjacent cortical veins
- Adjacent cortex edematous, usually with petechial hemorrhage

Microscopic Features

- Thrombus in cortical vein(s) and sinus(es)

CLINICAL ISSUES

Presentation

- Most common signs/symptoms
  - Clinical diagnosis often difficult, elusive
    - Headache (95%)
    - Seizure (47%), paresis (43%), papilledema (41%)
    - Altered consciousness (39%), comatose (15%)
    - Isolated intracranial hypertension (20%)
  - Focal neurologic deficits variable (depends on location)

Demographics

- Age
  - Any
- Gender
  - M < F
- Epidemiology
  - 1% of acute strokes

Natural History & Prognosis

- Extremely variable outcome; asymptomatic to death
  - Good outcome associated with isolated intracranial hypertension presentation, "delta" sign on CT (leading to earlier diagnosis)
  - Poor outcome associated with papilledema, altered consciousness, coma, age > 33 years, diagnostic delay > 10 days, intracerebral hemorrhage, involvement of straight sinus
- Up to 50% of cases progress to venous infarction
  - Overall mortality = 10%; recurrence as high as 12%

DIAGNOSTIC CHECKLIST

Consider

- If "convexal" subarachnoid hemorrhage is seen, consider CVT

Image Interpretation Pearls

- Include T2* GRE sequence on MR/MRV

SELECTED REFERENCES

1. Altinkaya N et al: Diagnostic value of T2*-weighted gradient-echo MRI for segmental evaluation in cerebral venous sinus thrombosis. Clin Imaging. 39(1):15-9, 2015
2. Coutinho JM et al: Cerebral venous thrombosis in the absence of headache. Stroke. 46(1):245-7, 2015
3. Singh R et al: Isolated cortical vein thrombosis: case series. J Neurosurg. 1-7, 2015
4. Coutinho JM et al: Isolated cortical vein thrombosis: systematic review of case reports and case series. Stroke. 45(6):1836-8, 2014
5. Khosravi M et al: Cord sign: cortical venous thrombosis evolving to a ring enhancing lesion. Br J Neurosurg. 27(1):139-40, 2013
6. Shivaprasad S et al: Neurological picture. Vein of Labbe thrombosis by CT and MRI. J Neurol Neurosurg Psychiatry. 83(12):1168-9, 2012
7. Verma R et al: Subarachnoid haemorrhage as the initial manifestation of cortical venous thrombosis. BMJ Case Rep. 2012, 2012
8. Black DF et al: Cerebral venous sinus density on noncontrast CT correlates with hematocrit. AJNR Am J Neuroradiol. 32(7):1354-7, 2011
9. Rathakrishnan R et al: The clinico-radiological spectrum of isolated cortical vein thrombosis. J Clin Neurosci. 18(10):1408-11, 2011

https://CafePezeshki.IR

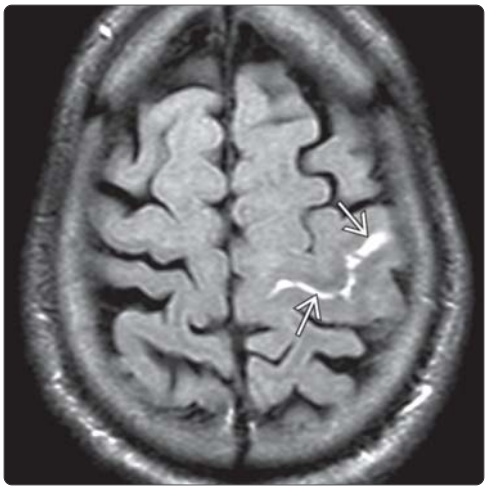

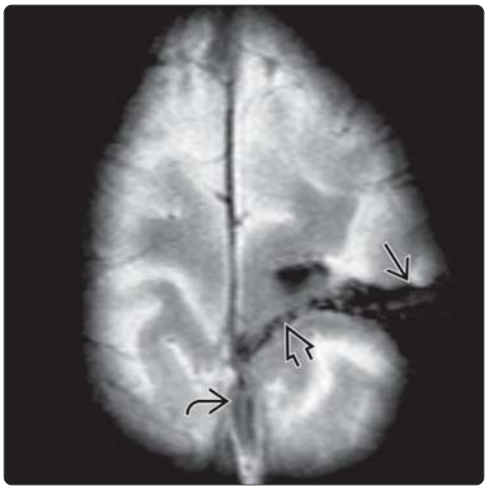

(Left) *FLAIR scan in a patient in the ER with headaches and convexal SAH on NECT (not shown) discloses hyperintense signal in the left central sulcus* ⇨. **(Right)** *T2* scan in the same patient shows the source of the convexal subarachnoid hemorrhage (SAH)* ⇨ *is a thrombosed a cortical vein* ⇨. *Note that the superior sagittal sinus* ⇨ *demonstrates no corresponding "blooming," suggesting that the thrombosed vein occurred in isolation, without involvement of other venous structures.*

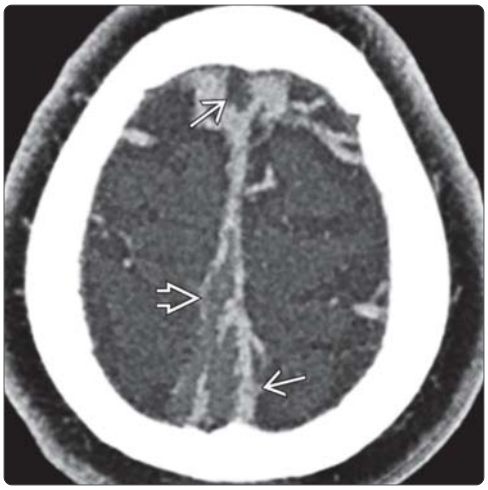

(Left) *NECT scan in a 62-year-old female with headache and left-sided weakness shows a hyperdense superior sagittal sinus (measured 72 HU)* ⇨. *A hyperdense cortical vein is also present ("cord sign")* ⇨. **(Right)** *CTV in the same patient shows nonenhancing thrombus in the SSS ("empty delta sign")* ⇨ *as well as the cortical vein* ⇨.

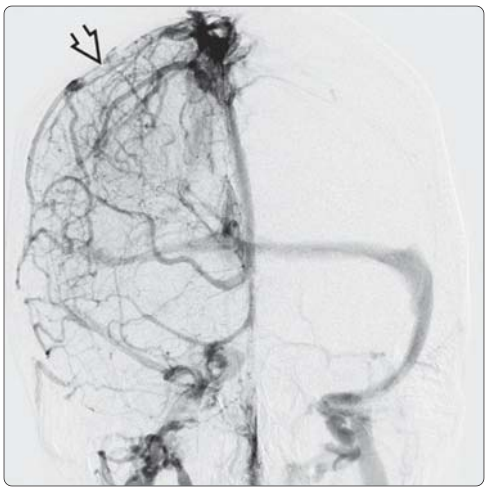

(Left) *Sagittal CTV shows nonenhancing thrombus* ⇨ *in the partially occluded SSS as well as in the adjacent cortical vein* ⇨. **(Right)** *Right internal carotid DSA, venous phase, AP view, confirms nonenhancing thrombus* ⇨ *in a prominent vein of Trolard.*

https://CafePezeshki.IR

KEY FACTS

TERMINOLOGY

- Thrombotic occlusion of deep cerebral veins
  - Usually affects both ICVs ± vein of Galen (VOG), straight sinus (SS)
  - Often occurs with more widespread deep sinus thrombosis

IMAGING

- NECT
  - Hyperdense ICV ± VOG, SS
  - Hypodense thalami/basal ganglia (BG), loss of gray-white matter interfaces
    - Variable loss of deep gray-white interfaces
    - Thalami seem to "disappear" into background WM hypodensity
  - ± petechial hemorrhages
- CECT
  - Loss of ICV enhancement, presence of enlarged collateral channels
  - "Shaggy," irregular veins (collateral channels) in deep WM, around tentorium
- MR
  - Acute clots hypointense on T2WI, "bloom" on T2*
  - Deep (medullary) WM veins prominent, tortuous on SWI
- Protocol advice
  - If CT/CECT/CTV scans negative → MR with MRV
  - If MRV equivocal → DSA

TOP DIFFERENTIAL DIAGNOSES

- Other bithalamic/basal ganglia lesions
  - Neoplasm (e.g., bithalamic astrocytoma)
  - Nonvenous ischemia (e.g., artery of Percheron infarct)
  - Toxic/metabolic disorders (e.g., carbon monoxide poisoning)

CLINICAL ISSUES

- Venous thrombosis = 1-2% of strokes
- ICV thrombosis = 10% of venous "strokes"

(Left) *Axial graphic depicts thrombosis of both ICVs and SS ⇨ with secondary hemorrhage in the choroid plexus and thalami ⇨. Edema in the thalami, basal ganglia, and deep cerebral white matter are common findings. Linear WM medullary veins ⇨ may become engorged and enhance.* **(Right)** *NECT in a 32-year-old female with severe headache shows hyperdense internal cerebral veins (ICVs) ⇨. Both thalami are edematous, symmetrically isodense ⇨ (normally hyperdense) compared to the surrounding white matter.*

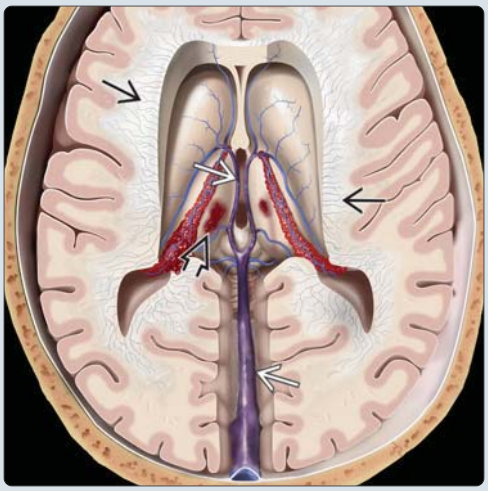

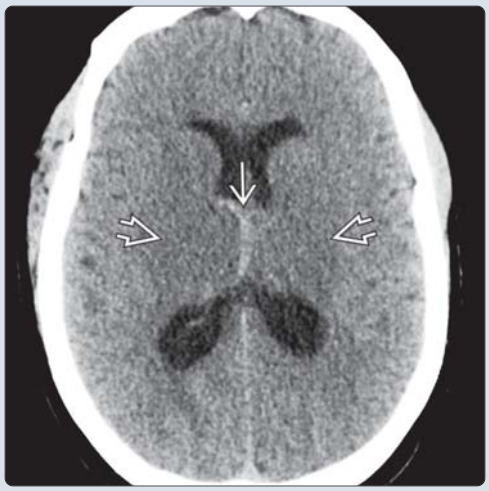

(Left) *More inferior NECT in the same patient shows the vein of Galen ⇨ and straight sinus ⇨ are also thrombosed and hyperdense (measured 70 HU).* **(Right)** *Lateral DSA, venous phase, in the same patient shows normal opacification of the superior sagittal sinus and transverse sinus. The ICVs, vein of Galen, and straight sinus are thrombosed and do not fill with contrast. Deep (Galenic system) venous occlusion.*

https://CafePezeshki.IR

TERMINOLOGY

Abbreviations

- Deep cerebral venous thrombosis (DCVT)
- Internal cerebral vein (ICV) thrombosis

Definitions

- Thrombotic occlusion of deep cerebral veins
  - Usually affects both ICVs ± vein of Galen (VOG), straight sinus (SS)
  - Often with widespread dural sinus thrombosis (DST)

IMAGING

General Features

- Best diagnostic clue
  - Hyperdense ICV ± VOG, SS ± bithalamic hypodensity
    - Loss of deep gray-white matter interfaces
    - Thalami seem to "disappear" into background WH hypodensity
- Location
  - ICV ± VOG, SS, basal veins of Rosenthal
  - Bilateral ICV thrombosis > > unilateral
  - Edema (venous congestion)
    - Deep gray nuclei, internal capsule, medullary white matter (WM)
    - Variable involvement of midbrain, upper cerebellum

CT Findings

- NECT
  - Hyperdense ICVs ± SS, DST
  - Variable parenchymal abnormalities
    - Hypodense thalami/basal ganglia (BG), loss of gray-white matter interfaces
    - ± petechial hemorrhages
- CECT
  - "Empty delta" sign (if DST)
  - "Shaggy," irregular veins (collateral channels) in deep WM, around tentorium
- CTV
  - Loss of ICV enhancement, presence of enlarged collateral channels
  - Limited value in chronic cases as organizing thrombosis also enhances

MR Findings

- T1WI
  - Clot: Early T1 isointense, later hyperintense
  - Venous hypertension: Hypointense swelling of thalami, basal ganglia
  - Venous infarct: Hypointense edema, may be hemorrhagic
- T2WI
  - Acute thrombus hypointense, mimics flow voids
  - Hyperintense swelling of thalami, basal ganglia common
    - Corresponds to vasogenic ± cytotoxic edema
  - Venous infarct: Parenchymal swelling, hyperintense edema, may be hemorrhagic
- FLAIR
  - High signal in occluded veins
  - Best demonstrates hyperintense BG edema
- T2* GRE
  - Thrombus is hypointense, "blooms"
  - SWI shows engorged, prominent deep WM (medullary) veins
  - Variable petechial hemorrhages
- DWI
  - Variable findings
  - BG/thalami may restrict early, normalize later
  - Thrombus, hemorrhages may restrict
- T1WI C+
  - Acute/early subacute clot: Peripheral enhancement outlines clot
  - Late clot: Thrombus, fibrous tissue often enhances
  - Venous stasis in deep WM (medullary) veins seen as linear enhancing foci radiating outward from ventricles
  - Venous edema/hypertension: No enhancement
  - Parenchymal venous infarct: Patchy enhancement
- MRV
  - 2D time of flight (TOF) MRV shows "missing" ICVs, variably absent signal in VOG, SS
    - May see abnormal collateral channels
  - Contrast-enhanced MRV (CE-MRV)
    - Faster; better depicts nonenhancing thrombus and small veins than TOF
  - TOF limitations
    - T1 hyperintense thrombus falsely appears as patent flow on MIP
    - Always evaluate source images and conventional MR sequences
  - Phase contrast MRV: T1 hyperintense thrombus not misrepresented as flow

Angiographic Findings

- Conventional
  - DSA more accurate than MR
  - Normal deep cerebral veins are always present on angiography
    - In DCVT, occluded ICVs do not opacify ("absent")
    - Collateral venous channels (e.g.,medullary veins) enlarge
- Interventional: Treatment with thrombolytics &/or mechanical declotting

Imaging Recommendations

- Best imaging tool
  - NECT, CECT ± CTV venogram
  - Conventional DSA if intervention planned
- Protocol advice
  - If CT/CECT/CTV scans negative → MR with MRV
  - If MRV equivocal → DSA

DIFFERENTIAL DIAGNOSIS

Nonvenous Ischemic Injury

- Arterial occlusion
  - Artery of Percheron cerebral ischemia
  - Top of basilar cerebral infarction
- Global hypoxia

Primary CNS Lymphoma

- T2 hyperintense, enhancing mass(es)
- Along ependymal surfaces (thalami > basal ganglia)

https://CafePezeshki.IR

- Normal venous system

Bithalamic Astrocytoma

- T2 hyperintense mass in deep gray nuclei
- Normal venous system
- Elevated choline, decreased NAA
- Vasogenic not cytotoxic edema

Carbon Monoxide Poisoning

- T2 hyperintense deep gray nuclei, often globus pallidus
- Normal venous system
- Positive carboxyhemoglobin
- Classic cherry red skin is rare

PATHOLOGY

General Features

- Etiology
  - No cause identified in 20-25% of cases
  - Wide spectrum of causes (> 100 identified)
    - Trauma, infection, inflammation
    - Pregnancy, peripartum period
    - Metabolic (dehydration, thyrotoxicosis, cirrhosis, etc.)
    - Hematological (coagulopathy)
    - Collagen-vascular disorders (e.g., APLA syndrome)
    - Vasculitis (e.g., Behçet)
    - Drugs (oral contraceptives, androgens, ecstasy)
    - Ulcerative colitis
  - Most common sequence
    - Thrombus initially forms in dural sinus
    - Clot propagates into cortical veins
    - Venous drainage obstructed, venous pressure elevated
    - Blood-brain barrier breakdown with vasogenic edema, hemorrhage
    - Venous infarct with cytotoxic edema ensues
- Genetics
  - Factor 5 Leiden mutation is most common cause of sporadic CVT

Staging, Grading, & Classification

- Venous ischemia
  - Type 1: No abnormality
  - Type 2: High signal on T2WI/FLAIR; no enhancement
  - Type 3: High signal on T2WI/FLAIR; enhancement present
  - Type 4: Hemorrhage or venous infarction

Gross Pathologic & Surgical Features

- ICVs occluded, distended by acute clot
- Venous hypertension ensues
- Adjacent thalami edematous with variable hemorrhage

Microscopic Features

- Thrombus in occluded vessels

CLINICAL ISSUES

Presentation

- Most common signs/symptoms
  - Headache, nausea, vomiting
    - ± neurologic deficit, seizure

Demographics

- Age
  - Any age
    - Especially elderly, debilitated patients
    - Pregnant, peripartum women, women on BCPs
- Gender
  - F > M
- Epidemiology
  - Venous thrombosis causes 1-2% of strokes
  - ICV thrombosis = 10% of venous "strokes"

Natural History & Prognosis

- Clinical diagnosis of CVT often elusive
- Outcome of CVT extremely variable, from asymptomatic to death
  - Majority have no residual deficits at 16 months
  - Subgroup (13%) have poor outcome
  - Predictors of death/dependence
    - Hemorrhage on admission CT
    - DWI demonstration of cytotoxic edema (infarction)

Treatment

- Heparin ± rTPA
- Endovascular thrombolysis

DIAGNOSTIC CHECKLIST

Consider

- DSA in equivocal cases and for intervention

Image Interpretation Pearls

- Early imaging findings subtle, often overlooked
- Obtain NECT concurrently with CTV
- "Flow voids" on T2 do not rule out DCVT
- 2D TOF MRV should not be interpreted without benefit of standard imaging sequences
- Nonvisualization of deep venous system on CTA/MRA/DSA always abnormal

SELECTED REFERENCES

1. Barboza MA et al: Intracranial venous collaterals in cerebral venous thrombosis: clinical and imaging impact. J Neurol Neurosurg Psychiatry. ePub, 2015
2. Coutinho JM et al: Cerebral venous thrombosis in the absence of headache. Stroke. 46(1):245-7, 2015
3. Bonneville F: Imaging of cerebral venous thrombosis. Diagn Interv Imaging. 95(12):1145-50, 2014
4. Linn J et al: Noncontrast CT in deep cerebral venous thrombosis and sinus thrombosis: comparison of its diagnostic value for both entities. AJNR Am J Neuroradiol. 30(4):728-35, 2009
5. Linn J et al: Diagnostic value of multidetector-row CT angiography in the evaluation of thrombosis of the cerebral venous sinuses. AJNR Am J Neuroradiol. 28(5):946-52, 2007
6. Rodallec MH et al: Cerebral venous thrombosis and multidetector CT angiography: tips and tricks. Radiographics. 26 Suppl 1:S5-18; discussion S42-3, 2006

https://CafePezeshki.IR

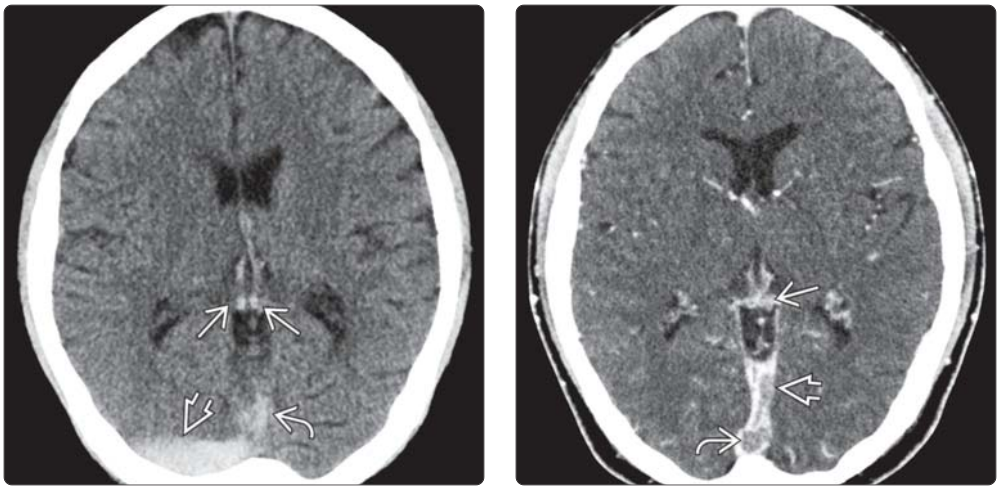

(Left) *NECT in a 25-year-old male with headache and drowsiness shows hyperdense ICVs and straight and transverse sinuses. The thalami have "faded" into the background and are isodense with surrounding white matter.* **(Right)** *CTV in the same patient shows nonenhancing thrombus in the ICVs, straight sinus, and torcular.*

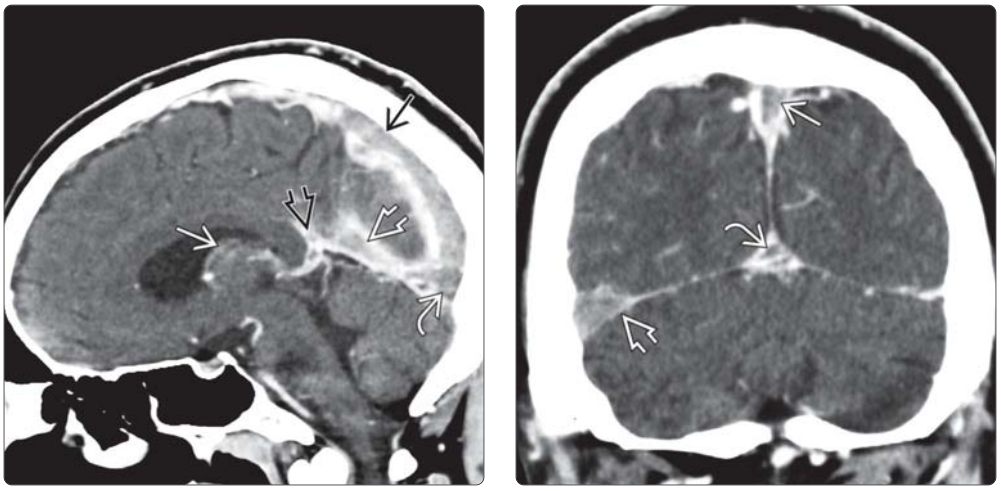

(Left) *Sagittal scan in the same patient reformatted from the axial source data shows extensive nonenhancing thrombus in the ICVs, as well as the vein of Galen, straight sinus torcular, and superior sagittal sinus.* **(Right)** *Coronal CTV shows thrombus in the SSS, torcular, and right transverse sinus.*

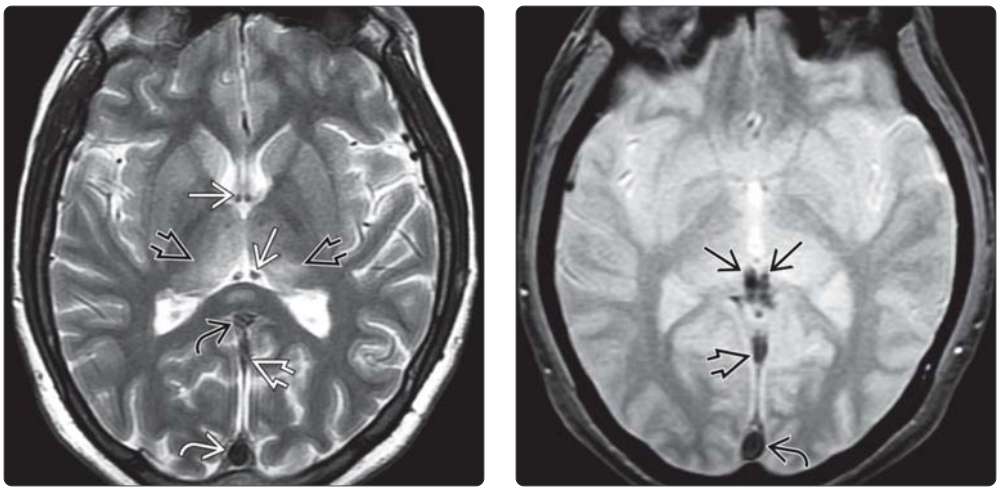

(Left) *Axial T2WI in the same patient shows bithalamic edema. Acute thrombus in the ICVs, vein of Galen, straight sinus, and torcular is hypointense, mimicking "flow voids."* **(Right)** *T2* GRE scan in the same patient shows "blooming" acute thrombus in the ICVs, straight sinus, and torcular.*

https://CafePezeshki.IR

KEY FACTS

TERMINOLOGY

- Arachnoid granulation (AG)
  - Defined as enlarged arachnoid villi projecting into major dural venous sinus lumen
- Aberrant arachnoid granulation (AbAG)
  - Defined as AG that penetrates dura, but fails to reach venous sinus, typically in sphenoid or temporal bone

IMAGING

- Intrasinus AG: Well-circumscribed, discrete, filling defect in venous sinus ± inner calvarial table erosion
  - CECT: Nonenhancing; density like CSF
  - MR: T1/T2 intensity follows CSF; FLAIR often hyperintense
- AbAG: Multiple focal outpouches in sphenoid bone or temporal bone
  - Sphenoid bone location: Greater wing
  - Temporal bone location: Posterior wall or tegmen
  - CT: Multiple smooth pits in sphenoid or T-bone
  - MR: T1 and T2 intensity follows CSF

TOP DIFFERENTIAL DIAGNOSES

- Dural sinus hypoplasia-aplasia
- Transverse-sigmoid sinus pseudolesion
- Dural sinus thrombosis
- Dural arteriovenous fistula

CLINICAL ISSUES

- Intrasinus AG: Asymptomatic with rare exception
- Aberrant AG: Mostly asymptomatic
  - If large with rupture, **CSF leak** ± meningitis possible
  - Sphenoid bone: CSF leak → sphenoid fluid → rhinorrhea
  - T-bone: CSF leak → middle ear-mastoid fluid → otorrhea
  - Large AG may have associated **cephalocele** (± seizure)
  - **Meningitis** may complicate CSF leak
- Treatment
  - Intrasinus AG: No treatment required
  - Aberrant AG: No treatment unless CSF leak present

(Left) *Graphic shows a giant arachnoid granulation (AG) projecting from subarachnoid space into transverse sinus. CSF core ➡ extends into the AG and is separated by arachnoid cap cells from the venous sinus endothelium ➡. Giant AGs often contain prominent venous channels ➡ and septations.* **(Right)** *Axial CECT shows a giant arachnoid granulation cluster at the transverse-sigmoid venous sinus junction ➡. The 1st imaging interpretation of this finding mistakenly suggested venous sinus thrombosis.*

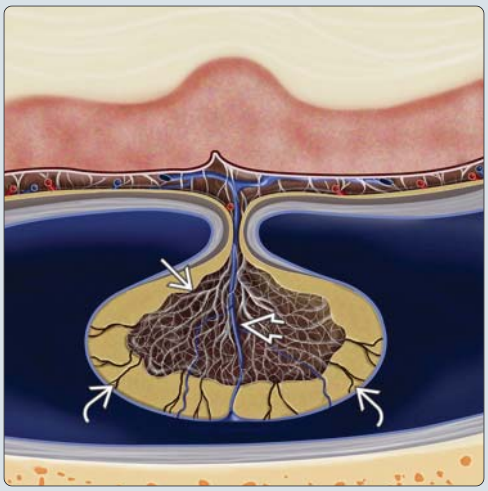

(Left) *Axial T1WI MR in the same patient reveals the multiple giant arachnoid granulations ➡ as low signal within the transverse and proximal sigmoid sinuses. The medial low signal line ➡ is the dura.* **(Right)** *Lateral internal carotid artery angiogram in same patient clearly depicts multiple giant arachnoid granulations in the transverse ➡ and proximal sigmoid ➡ venous sinuses. No intrasinus pressure gradient was present across the lesion.*

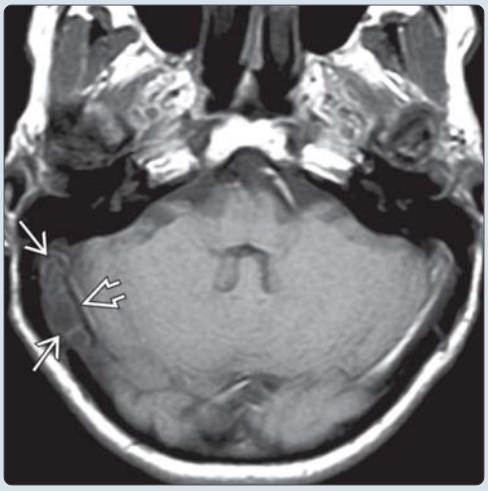

https://CafePezeshki.IR

TERMINOLOGY

Abbreviations

- Arachnoid granulation (AG)
- Aberrant arachnoid granulation (AbAG)

Synonyms

- Pacchionian depressions, granulations, or bodies
- When large → "giant" arachnoid granulation
- When in sphenoid bone and T-bone → AbAG

Definitions

- Arachnoid villi: Termed used to describe smaller AG
- AG: Enlarged arachnoid villi projecting into major dural venous sinus lumen
- AbAG: AG that penetrated dura, but fails to reach venous sinus, typically in sphenoid or temporal bone
  - Also referred to as arachnoid pits or osteodural defects

IMAGING

General Features

- Best diagnostic clue
  - Intrasinus AG: Discrete filling defect in venous sinus ± inner calvarial table erosion
    - CECT: Nonenhancing; similar density to CSF
    - MR: T1/T2 intensity follows CSF; often hyperintense on FLAIR
  - AbAG: Multiple focal outpouches in sphenoid bone, often greater wing
    - Bone CT: Multiple smooth pits in sphenoid bone
    - MR: T1 and T2 intensity follows CSF
- Location
  - Most common location: Transverse sinus
  - Other locations: Sigmoid, sagittal, or straight sinus
  - AbAG location: Sphenoid bone, often greater wing, or lateral sinus wall
    - T bone: Posterior wall or tegmen tympani
- Size
  - 5-15 mm size range
  - If > 15 mm, called "giant AG"
- Morphology
  - Single or multiple ovoid lesions
  - Focal osseous pits in inner table of calvaria

CT Findings

- NECT
  - Intrasinus AG isodense with CSF
  - CSF pulsations may result in erosion or scalloping of inner table
  - AbAG: Focal osseous erosions in sphenoid bone
    - If large, may appear multilocular; mimic cystic bone lesion
- CECT
  - Nonenhancing, ovoid focal filling defect within venous sinus
  - Isodense to CSF
  - AbAG: CSF density with subtle rim (dural) enhancement
- CT venogram
  - Focal filling defect within venous sinus

MR Findings

- T1WI
  - Venous sinus defect isointense to CSF
- T2WI
  - Hyperintense (like CSF)
  - Surrounded by normal flow void of major venous sinus
  - AbAG: High signal outpouching into sphenoid bone
    - If large, may see arachnoid pouch bulging into sphenoid sinus lumen
      - Arachnoid strands seen as low signal lines within pouch
    - Larger lesions may have **CSF leak** into sphenoid sinus
      - Fluid levels seen in sphenoid sinus if leak present
    - Larger lesions may have **cephalocele** associated
- T1WI C+
  - Intrasinus AG: Ovoid without enhancement surrounded by enhancing blood in dural sinus
    - Veins, septae may enhance
  - AbAG: Nonenhancing foci in sphenoid bone
- MRV
  - Intrasinus AG
    - Source images show focal signal loss in location of AG
    - MRV reformation shows focal defect in affected sinus

Imaging Recommendations

- Best imaging tool
  - Intrasinus AG: Enhanced MR with MRV
  - AbAG: Bone CT of skull base
    - Enhanced MR focused to sphenoid bone area

DIFFERENTIAL DIAGNOSIS

Dural Sinus Hypoplasia-Aplasia

- Congenital hypoplastic-aplastic transverse sinus
- "High-splitting" tentorium

Transverse-Sigmoid Sinus Pseudolesion

- Asymmetric complex flow phenomenon in sinus mimics lesions
- Not present on all sequences; MRV sorts out

Dural Sinus Thrombosis

- Long-segment region of ↓ venous sinus flow
- NECT: Hyperdense
- CECT: Nonenhancing clot in venous sinus lumen
- MR: Hyperintense on T1 or lack of flow void on T2
  - T1 C+: Nonenhancing clot in venous sinus lumen

Dural AV Fistula

- MR: Recanalized, irregular transverse-sigmoid sinuses
  - MRA: Enlarged, feeding external carotid artery branches; early venous drainage
- Angio: Enlarged, feeding external carotid artery branches

PATHOLOGY

General Features

- Etiology
  - Intrasinus AG: Normal variant enlarged arachnoid villi
    - Penetrates dura overlying venous sinus
    - Arachnoid cap cells in margin of AG responsible for CSF resorption

https://CafePezeshki.IR

- Aberrant AG: AG that penetrates dura, but fails to reach venous sinus in sphenoid or temporal bone
  - CSF pulsations enlarge AbAG causing arachnoid pouch bulging
  - Bulging arachnoid pouch penetrates subjacent structures (dura, then underlying bone)
  - If pouch stretches to point of rupture, CSF enters air cells if involved
    - Sphenoid bone-sphenoid sinus: CSF leak → sphenoid fluid → rhinorrhea
    - Temporal bone-air cells: CSF leak → middle ear-mastoid fluid → otorrhea
    - Cephalocele possible in larger AbAG

Gross Pathologic & Surgical Features

- AG: Smooth arachnoid granulation projecting into venous sinus or subarachnoid space
- Aberrant AG: Osteodural defects in lateral sphenoid sinus wall or greater wing of sphenoid

Microscopic Features

- Enlarged arachnoid villi
- Central core of loose connective tissue with CSF
- Peripheral zone of dense connective tissue
- Projects through dura of venous sinus wall

CLINICAL ISSUES

Presentation

- Most common signs/symptoms
  - Intrasinus AG: Asymptomatic with rare exception
    - If suspect giant AG in venous sinus causing venous hypertension with headache, angiography with pressure measurements needed
    - In most cases, no pressure gradient across giant AG in dural venous sinus found
  - Aberrant AG: Mostly asymptomatic
    - If CSF pulsations enlarge AbAG in sphenoid sinus or temporal bone wall, CSF leak ± meningitis possible
      - Sphenoid sinus wall rupture: Rhinorrhea
      - Temporal bone air cell rupture: Otorrhea
    - If significant cephalocele occurs, seizure possible
- Other signs/symptoms
  - Benign intracranial hypertension in obese middle-aged females with rhinorrhea
    - Look for aberrant AG in the sphenoid bone adjacent to sphenoid sinus

Demographics

- Age
  - ↑ in frequency with ↑ age; ≥ 40 years
- Epidemiology
  - Intrasinus AG: 25% CECT or T2WI MR
  - Aberrant AG: Rare to see with imaging
    - Sphenoid bone: < 2%
    - Temporal bone: < 1%

Natural History & Prognosis

- Intrasinus AG: Remains asymptomatic
- Aberrant AG: May remain small
  - If enlarge in response to CSF pulsations may penetrate dura, bone and air cells
    - CSF leak, cephalocele, or meningitis may result

Treatment

- Intrasinus AG: No treatment required
- Aberrant AG: No treatment needed unless enlarged with resulting CSF leak
  - Can follow large, asymptomatic AbAG
  - If CSF leak present into sphenoid sinus or temporal bone, surgical dural repair necessary
    - Surgical repair prevents meningitis possibility

DIAGNOSTIC CHECKLIST

Consider

- If **intrasinus giant AG** with history of headache, consider angiogram to look for intrasinus pressure gradient
- If **aberrant AG** presents in lateral wall **sphenoid bone**, look for fluid in sphenoid sinus as evidence for CSF leak
  - Also use MR to evaluate for possible associated cephalocele
- If **aberrant AG** found in posterior wall of **temporal bone**, look for fluid in mastoid air cells as evidence for CSF leak

Image Interpretation Pearls

- Intrasinus AG
  - Confirm AG remains CSF density (as seen with CECT or CT angiogram) and intensity (as seen with T1 and T2 MR sequences)
  - Make sure proximal and distal venous sinus is normal from imaging perspective
- Aberrant AG in lateral sphenoid sinus wall or posterior wall temporal bone
  - If large or multiple, look for evidence of CSF leak

SELECTED REFERENCES

1. Battal B et al: Brain herniations into the dural venous sinuses or calvarium: MRI of a recently recognized entity. Neuroradiol J. 27(1):55-62, 2014
2. De Keyzer B et al: Giant arachnoid granulations mimicking pathology. A report of three cases. Neuroradiol J. 27(3):316-21, 2014
3. Settecase F et al: Spontaneous lateral sphenoid cephaloceles: anatomic factors contributing to pathogenesis and proposed classification. AJNR Am J Neuroradiol. 35(4):784-9, 2014
4. La Fata V et al: CSF leaks: correlation of high-resolution CT and multiplanar reformations with intraoperative endoscopic findings. AJNR Am J Neuroradiol. 29(3):536-41, 2008
5. Lloyd KM et al: Imaging of skull base cerebrospinal fluid leaks in adults. Radiology. 248(3):725-36, 2008
6. Schuknecht B et al: Nontraumatic skull base defects with spontaneous CSF rhinorrhea and arachnoid herniation: imaging findings and correlation with endoscopic sinus surgery in 27 patients. AJNR Am J Neuroradiol. 29(3):542-9, 2008
7. Amlashi SF et al: Intracranial hypertension and giant arachnoid granulations. J Neurol Neurosurg Psychiatry. 75(1):172, 2004
8. Liang L et al: Normal structures in the intracranial dural sinuses: delineation with 3D contrast-enhanced magnetization prepared rapid acquisition gradient-echo imaging sequence. AJNR Am J Neuroradiol. 23(10):1739-46, 2002
9. Casey SO et al: Prevalence of arachnoid granulations as detected with CT venography of the dural sinuses. AJNR Am J Neuroradiol. 18(5):993-4, 1997
10. Leach JL et al: Normal appearance of arachnoid granulations on contrast-enhanced CT and MR of the brain: differentiation from dural sinus disease. AJNR Am J Neuroradiol. 17(8):1523-32, 1996
11. Roche J et al: Arachnoid granulations in the transverse and sigmoid sinuses: CT, MR, and MR angiographic appearance of a normal anatomic variation. AJNR Am J Neuroradiol. 17(4):677-83, 1996

https://CafePezeshki.IR

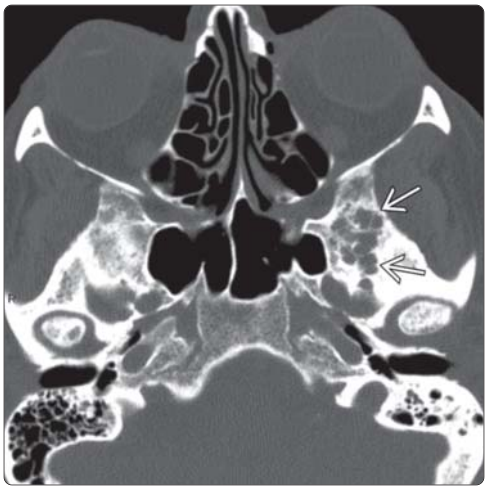

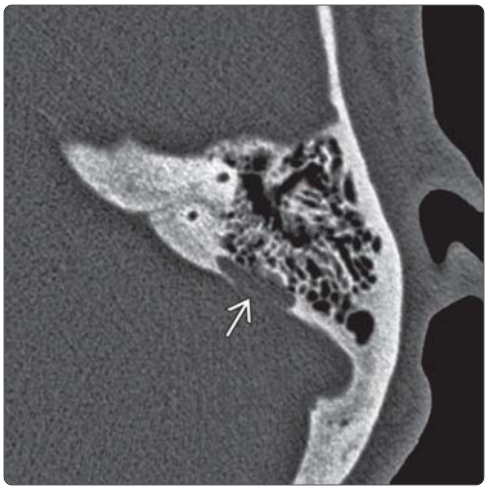

(Left) *Axial bone CT through the midsphenoid sinus shows multiple ovoid bony defects in the greater wing of sphenoid bone ⇨ representing aberrant arachnoid granulations (arachnoid pits). These arachnoid granulations may enlarge from CSF pulsations.* **(Right)** *Axial left ear T-bone CT reveals an example of incidental aberrant arachnoid granulation ⇨ in posteromedial tegmen mastoideum. No CSF in the mastoid is present.*

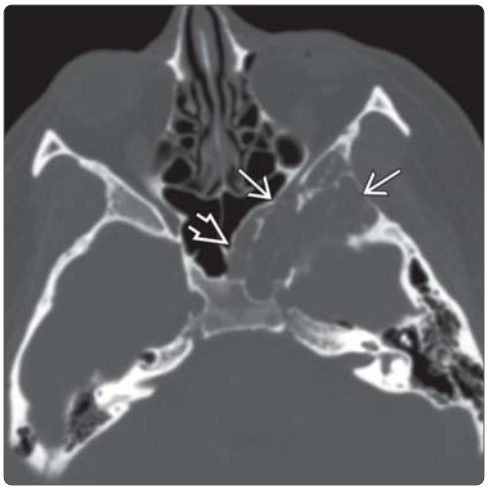

(Left) *Axial bone CT reveals a multilocular lesion in the left greater wing of the sphenoid ⇨ and basisphenoid ⇨. The most likely etiology of this lesion is CSF pulsations enlarging aberrant arachnoid granulations.* **(Right)** *Coronal CT cisternography in the same patient reveals contrast leaking ⇨ from the subarachnoid space into the giant aberrant arachnoid granulations.*

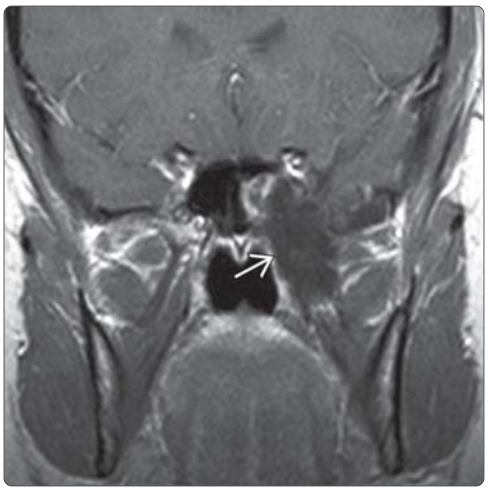

(Left) *Axial T2WI MR in the same patient demonstrates CSF signal within the greater wing of the sphenoid bone ⇨ and basisphenoid ⇨. Arachnoid outpouching with arachnoid stranding ⇨ can be seen within the giant aberrant arachnoid granulations.* **(Right)** *Coronal T1WI C+ MR in the same patient shows fluid within the expanded pterygoid wing of sphenoid ⇨. This represents CSF within an arachnoid pouch filling giant aberrant arachnoid granulations.*

https://CafePezeshki.IR

This page intentionally left blank

https://CafePezeshki.IR

PART I
SECTION 5

Vascular Malformations

Vascular Malformations Overview 394

CVMS With AV Shunting

Arteriovenous Malformation 396
Dural AV Fistula 400
Pial AV Fistula 404
Vein of Galen Aneurysmal Malformation 406

CVMS Without AV Shunting

Developmental Venous Anomaly 410
Sinus Pericranii 416
Cavernous Malformation 420
Capillary Telangiectasia 424

https://CafePezeshki.IR

General Considerations

Cerebrovascular malformations (CVMs) of the brain are a heterogeneous group of disorders that represent morphogenetic errors affecting arteries, capillaries, veins, or various combinations of vessels.

The presentation, natural history, and management approaches to CVMs depend on their type, location, size, and hemodynamic characteristics. Some CVMs such as venous or capillary malformations are almost always clinically silent and therefore usually identified at imaging or autopsy. Others, such as arteriovenous and cavernous malformations, may hemorrhage unexpectedly and without warning.

Terminology

Without a uniform consensus, there is much confusion regarding the nomenclature of brain CVMs. They have variously been called angiomas, hemangiomas, developmental anomalies, malformations, and hamartomas. For example, venous vascular malformations have been termed venous angiomas, venous anomalies, venous malformations, and developmental venous anomalies (DVAs). Cavernous malformations have been called cavernous angiomas, cavernous hemangiomas, and "cavernomas" in the literature.

Using accurate terminology when discussing brain vascular malformations is important. Two major groups of vascular anomalies are recognized: Vascular malformations and hemangiomas. All cerebrovascular malformations ("angiomas") are malformative lesions. In contrast, "hemangiomas" are true proliferating, vasoformative neoplasms and, in the most recent WHO classification "blue book," are included with the mesenchymal, nonmeningothelial tumors.

Hemangiomas are benign vascular neoplasms, not malformations, and can be capillary or cavernous. Most intracranial hemangiomas are found in the skull, meninges, and dural venous sinuses while most vascular malformations occur in the brain parenchyma. Therefore, the term hemangioma should be reserved for vasoproliferative neoplasms and not used to describe vascular malformations. In this text, CVMs are included in this section; hemangiomas are considered as neoplasms and included elsewhere.

Epidemiology

The overall prevalence of brain CVMs is difficult to estimate as accurate epidemiologic data are scarce. Cushing and Bailey found vascular anomalies constituted about 1% of all intracranial tumors. Using ICD-9 codes, hospital admission rates for CVMs have been calculated as approximately 1.5-1.8 cases per 100,000 person-years. CVMs are estimated to cause about 5% of all nontraumatic intracranial hemorrhages.

With modern imaging, and especially with contrast-enhanced MR, CVMs are found in up to 8-10% of imaged patients. Most (venous and capillary malformations) are asymptomatic and found incidentally.

Embryology

Development of the human fetal vascular system occurs via 2 related processes: Vasculogenesis and angiogenesis. Vasculogenesis begins with de novo differentiation of endothelial cells from mesoderm-derived precursors called hemangioblasts. Islands of hemangioblasts form an outer rim of endothelial cell precursors ("angioblasts") and an inner core of hematopoietic stem cells.

Angioblasts form capillary-like tubules that constitute the primitive vascular plexus. This embryonic vascular network is then remodeled by a process of sprouting, progressive anastomosis, and retrogressive differentiation. Endothelial cells differentiate into arterial and venous types preceded, and guided by, migrating activated pericytes during definitive organization of the growing vessel wall.

Angiogenesis is regulated by a number of intercell signaling and growth factors. Some of these include Ang-1, Ang-2, Tie2, VEGF, PDGF, and TGF-β1, among others. Mutations in components of the angiogenetic system have been associated with the development of various CVMs.

Classification

In general, CVMs have been traditionally classified by histopathology and, more recently, by embryology and molecular genetics. With the advent of neurovascular interventional procedures, CVMs have also been classified by a practical, more functional approach.

Histopathologic Classification

Most neuropathology texts classify CVMs into 4 major types: (1) Arteriovenous malformation, (2) venous angioma, (3) capillary telangiectasia, and (4) cavernous malformation. The histopathologic classification is used in this book.

Embryologic Classification

Lasjaunias et al have proposed an embryonic, "metameric" approach to classifying vascular malformations that accounts for the known relationship between some brain and cutaneous vascular malformations. They termed these "cerebral arterial metameric syndromes" or "CAMS." For example, a CAMS1 syndrome links AVMs in the prosencephalon with those of the nose and orbit. Hence a CAMS1 patient may have a neurocutaneous AVM in the nose or retina and a brain parenchymal AVM.

Molecular Classification

The identification of underlying causal genes in familial forms of CVMs has allowed the definition of an ever-increasing number of these disorders at the molecular level. Specific mutations in some genes (e.g., *CCM1/KRIT1*, *CCM2/MGC4607*, *CCM3/PDCD10*) cause autosomal dominantly inherited cavernous malformation syndromes (CCM1, CCM2, and CCM3). Some patients with brain AVMs also have cutaneous capillary malformations attributable to *RASA1* gene mutations. Hereditary hemorrhagic telangiectasias (HHT) result from several mutations, among them the endoglin gene (*ENG*) in HHT1. Whether cavernous and venous malformations are "molecularly distinct" or only "phenotypically distinct" lesions that result from the same *CCM* gene mutations is controversial.

Functional Classification

Endovascular radiologists have proposed a functional, highly practical system that divides all CVMs into 2 basic categories: (1) CVMs that display arteriovenous shunting and (2) CVMs without AV shunting. The former category includes arteriovenous malformations and fistulae; the latter is basically everything else (venous, capillary, cavernous malformations). The former are amenable to intervention; the latter are either left alone or treated surgically.

https://CafePezeshki.IR

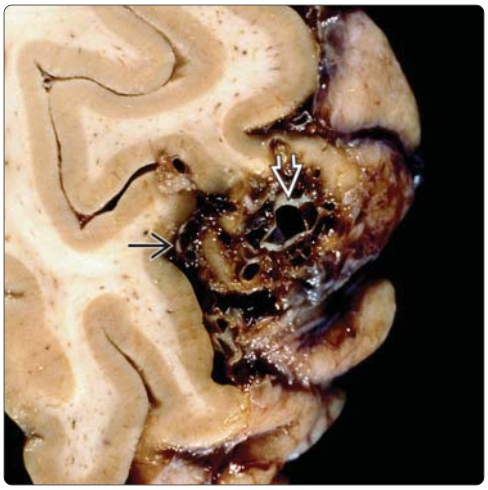

(Left) *Autopsied brain depicts an unruptured arteriovenous malformation (AVM). Multiple thin-walled vessels form the AVM nidus. A larger vessel may represent an intranidal aneurysm. (Courtesy R. Hewlett, MD).* **(Right)** *Autopsy of a thrombosed carotid-cavernous fistula, another type of CVM that displays AV shunting, shows multiple enlarged, arterialized venous channels. (Courtesy B. Horten, MD.)*

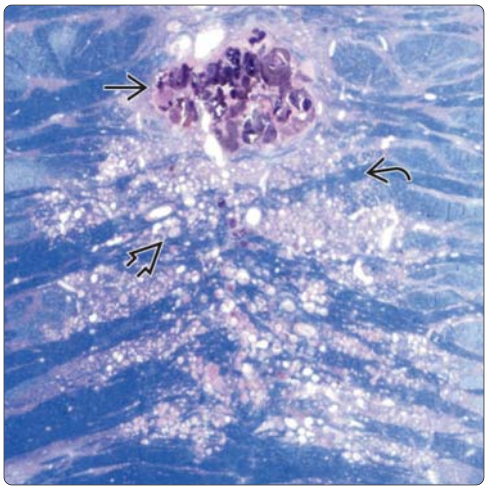

(Left) *Autopsied case cut in the axial plane shows a large pontine capillary telangiectasia. Note the transverse pontine fibers crossing through the telangiectasia without interruption or distortion. (Courtesy B. Horten, MD.)* **(Right)** *Low-power micropathology demonstrates a mixed pontine cavernous-capillary malformation. Normal white matter is interspersed with a cavernous malformation and multiple tiny thin-walled vessels. (Courtesy AFIP.)*

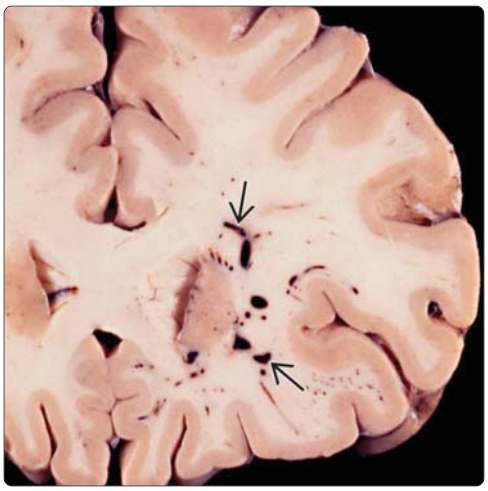

(Left) *Coronal autopsied brain shows an incidental DVA in the frontal lobe adjacent to the lateral ventricle. Note enlarged venous channels with normal white matter in-between. (Courtesy M. Castillo, MD.)* **(Right)** *Clinical photograph of a patient with hereditary hemorrhagic telangiectasis and multiple episodes of severe epistaxis shows innumerable small capillary telangiectasias of the skin and scalp, nasal, and oral mucosa.*

https://CafePezeshki.IR

KEY FACTS

TERMINOLOGY

- Pial vascular malformation of brain
  - Artery → vein shunting, no intervening capillary bed

IMAGING

- General features
  - Supratentorial (85%), posterior fossa (15%)
- CT/CTA
  - Iso-/hyperdense serpentine vessels ± Ca++
  - Arterial feeders, nidus, draining veins enhance
- MR
  - "Bag of worms"/tangle of serpiginous "honeycomb" flow voids
  - No intervening normal brain in AVM nidus
  - Minimal/no mass effect
  - ± high signal (gliosis) on FLAIR
  - T2* GRE "blooming" if hemorrhage present
- DSA: Best delineates internal angioarchitecture, 3 components of AVM
  - Enlarged feeding arteries
  - Nidus of tightly packed vascular channels
  - Dilated draining veins
- Intranidal "aneurysm" > 50%
- Flow-related aneurysm on feeding artery (10-15%)

TOP DIFFERENTIAL DIAGNOSES

- Glioblastoma with AV shunting
- Dural AV fistula

CLINICAL ISSUES

- Annual hemorrhage risk varies widely
  - Overall annual hemorrhage risk 2-4% (cumulative)
  - But ≤ 1% for unruptured, superficially-located nidi with superficial venous drainage
  - ≥ 30% for ruptured, deep-seated nidi with extensive deep venous drainage

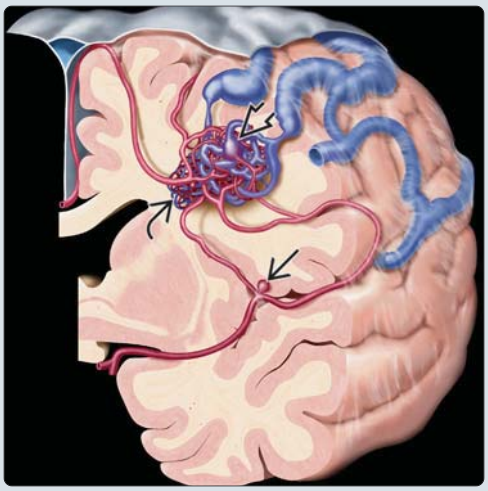

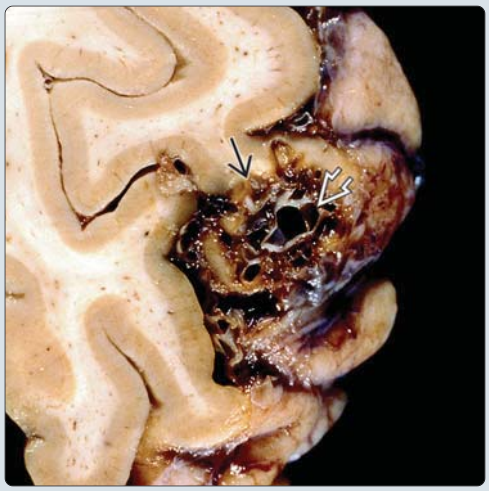

(Left) *Coronal graphic shows a classic cerebral arteriovenous malformation (AVM). Note the nidus ⇨ with intranidal aneurysm ⇨ and enlarged feeding arteries with a "pedicle" aneurysm ⇨.* **(Right)** *Autopsy case demonstrates a classic AVM. The nidus ⇨ contains no normal brain in between the tightly paced vessels. A thin-walled intranidal aneurysm ⇨ is present. (Courtesy R. Hewlett, MD.)*

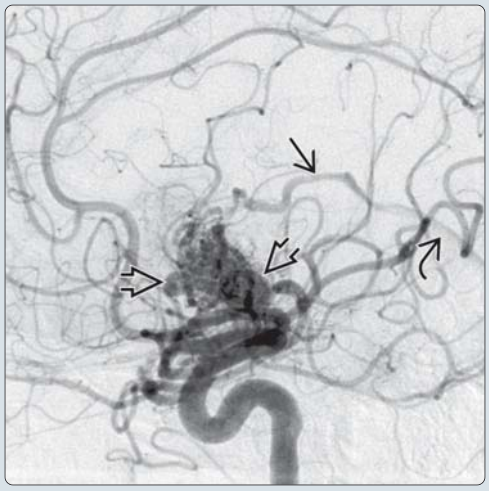

(Left) *Axial NECT (left) shows classic serpentine hyperdensities ⇨ of an unruptured AVM. CECT (right) shows strong uniform enhancement ⇨. Wedge-shaped configuration is typical.* **(Right)** *Lateral DSA of a classic AVM shows a nidus composed of tightly packed vessels ⇨. No intranidal or feeding pedicle aneurysms are present. Note the early deep venous drainage into the internal cerebral vein ⇨ and straight sinus ⇨.*

https://CafePezeshki.IR

TERMINOLOGY

Abbreviations

- Arteriovenous malformation (AVM)

Definitions

- Pial vascular malformation with direct artery → vein (AV) shunting, no intervening capillary bed

IMAGING

General Features

- Best diagnostic clue
  - "Bag of worms" (flow voids) on MR with minimal/no mass effect
- Location
  - May occur anywhere in brain
    - Supratentorial (85%), posterior fossa (15%)
  - 98% solitary, sporadic
    - Multiple AVMs rare, usually syndromic
- Size
  - Varies from microscopic to giant
  - Most symptomatic AVMs are 3-6 cm
- Morphology
  - 3 components
    - Enlarged feeding arteries
    - Nidus of tightly packed, enlarged vascular channels
    - Dilated draining veins
  - No normal brain in between

CT Findings

- NECT
  - May be normal (if AVM very small)
  - Iso-/hyperdense serpentine vessels
  - Ca++ in 25-30%
  - AVM bleed → parenchymal, intraventricular hemorrhage > > subarachnoid hemorrhage
  - Status postembolization: Liquid embolics appear hyperdense within nidus
- CECT
  - Strong enhancement of arterial feeders, nidus, draining veins
- CTA
  - Depicts enlarged arteries, draining veins

MR Findings

- T1WI
  - Signal varies with flow rate, direction, presence/age of hemorrhage
  - Tightly packed mass: "Honeycomb" of flow voids
- T2WI
  - Tangle of serpiginous, "honeycomb" flow voids
  - Variable hemorrhage
  - Little/no brain inside nidus
    - Some gliotic, high signal tissue may be present
- FLAIR
  - Flow voids ± surrounding high signal (gliosis)
- T2* GRE
  - "Blooming" if hemorrhage present
- T1WI C+
  - Strong enhancement of nidus, draining veins
  - Rapid flow may not enhance ("flow void")
- MRA
  - Helpful for gross depiction of flow, post embo/XRT
  - Does not depict detailed angioarchitecture

Angiographic Findings

- DSA best delineates internal angioarchitecture
- Use high frame rate, ↑ volume + rate of contrast injection per acquisition
- Depicts 3 components of AVMs
  - Enlarged arteries ± flow-related aneurysm(s)
  - Nidus of tightly packed vessels ± intranidal aneurysm(s)
  - Early draining veins ± venous stenoses due to high-flow venopathy (may ↑ intracranial hemorrhage [ICH] risk)
- 27-32% have "dual" arterial supply (pial, dural)

Imaging Recommendations

- Best imaging tool
  - DSA with high frame rate acquisitions ± superselective catheterization
- Protocol advice
  - Standard MR (include Gd-MRA, GRE sequences)

DIFFERENTIAL DIAGNOSIS

Glioblastoma With AV Shunting

- GBM enhances (tumor blush on DSA), has mass effect
- Some parenchyma between vessels

Thrombosed ("Cryptic") AVM

- Cavernous angioma
- Calcified neoplasm
- Oligodendroglioma
- Low-grade astrocytoma

Dural AV Fistula (dAVF)

- AV shunts within wall of patent ± partially thrombosed dural venous sinus, parallel venous channel, or adjacent cortical vein
- Most common location = transverse/sigmoid sinuses
- Differentiate from pial AVM by
  - Location: Nidus intimately related to dural venous sinus
  - Predominant blood supply is from dural (meningeal) arteries > > pial artery
    - e.g., middle and posterior meningeal arteries, artery of falx cerebelli, tentorial branches of cavernous ICA, occipital artery, artery of Davidoff and Schechter
  - Some parasitization of pial supply possible with larger dAVFs
  - Flow-related aneurysm are rare

PATHOLOGY

General Features

- Etiology
  - Dysregulated angiogenesis
    - Vascular endothelial growth factors (VEGFs), receptors mediate endothelial proliferation, migration
    - Cytokine receptors mediate vascular maturation, remodeling
- Genetics
  - Sporadic AVMs have multiple up-/down-regulated genes

https://CafePezeshki.IR

- Homeobox genes, such as *HOXD3* and *HOXB3*, involved in angiogenesis may malfunction
- Single nucleotide polymorphisms on p21 locus of chromosome 9 may predict clinical, angiographic AVM features
- Syndromic AVMs (2% of cases)
  - Multiple AVMs in *HHT1* (endoglin gene mutation)
  - Cerebrofacial arteriovenous metameric syndromes (CAMS) have orbit/maxillofacial + intracranial AVMs
- Associated abnormalities
  - Flow-related aneurysm on feeding artery (10-15%)
  - Intranidal "aneurysm" > 50%
  - Vascular "steal" may cause ischemia in adjacent brain
    - PET studies may show hemodynamic impairment

Staging, Grading, & Classification

- Spetzler-Martin (SM) scale
  - Sum of following estimates surgical risk from 1-5
    - Size
      - Small (< 3 cm) = 1
      - Medium (3-6 cm) = 2
      - Large (> 6 cm) = 3
    - Location
      - In "noneloquent" area = 0
      - Involves "eloquent" brain = 1
      - "Eloquent" = sensorimotor cortex, visual cortex, hypothalamus, thalamus, internal capsule, brainstem, cerebellar peduncles, deep nuclei
    - Venous drainage
      - Superficial only = 0
      - Deep = 1
- Lawton modified SM scale based on microsurgical outcomes
  - Grade III heterogeneous, divided into subtypes
    - Small AVM with both eloquent, deep venous drainage (Grade III-)
    - Medium-sized AVM with deep venous (Grade III) or eloquent (Grade III+)
    - Large AVM (grade III*)

Gross Pathologic & Surgical Features

- Wedge-shaped, compact mass of tangled vessels

Microscopic Features

- Wide phenotypic spectrum
  - Feeding arteries usually enlarged, but mature (may have some wall thickening)
  - Enlarged draining veins (may have associated varix, stenosis)
  - Nidus
    - Conglomeration of numerous tiny AV shunts
    - Thin-walled dysplastic vessels (no capillary bed)
    - Disorganized collagen, variable muscularization
    - No intervening normal brain (may have some gliosis)
  - Perinidal capillary network (PNCN)
    - Nidus surrounded by dilated capillaries in brain tissue 1-7 mm outside nidus border
    - Vessels in PNCN 10-25x larger than normal capillaries

CLINICAL ISSUES

Presentation

- Most common signs/symptoms
  - Headache with hemorrhage (50-60%)
  - Seizure (15-25%)
  - Focal neurologic deficit (10-25%)
- Clinical profile
  - Young adult with spontaneous (nontraumatic) ICH

Demographics

- Age
  - Peak presentation: 20-40 years (25% by age 15)
- Gender
  - M = F
- Epidemiology
  - Most common symptomatic cerebral vascular malformation (CVM)
  - Prevalence of sporadic AVMs: 0.04-0.52%

Natural History & Prognosis

- Brain AVMs have wide range of morphologies, angioarchitecture
  - Annual hemorrhage risk varies widely
    - Overall annual hemorrhage risk 2-4% (cumulative)
    - But ≤ 1% for unruptured, superficially-located nidi with superficial venous drainage
    - ≥ 30% for ruptured, deep-seated nidi with extensive deep venous drainage

Treatment

- Embolization
- Microneurosurgical resection
- Stereotactic radiosurgery

DIAGNOSTIC CHECKLIST

Consider

- MR of vascular-appearing lesion that has brain parenchyma in between flow voids may be vascular neoplasm, not AVM

Image Interpretation Pearls

- Look carefully for pedicle, intranidal aneurysms
- Look for subtle early draining veins; may be only clue to diagnosis of largely thrombosed AVMs

SELECTED REFERENCES

1. Ding D: Pathobiology of cerebral arteriovenous malformations: correlating genetic polymorphisms to clinical presentation and nidus angioarchitecture. Cerebrovasc Dis. 38(1):75, 2014
2. Gaballah M et al: Intraoperative cerebral angiography in arteriovenous malformation resection in children: a single institutional experience. J Neurosurg Pediatr. 13(2):222-8, 2014
3. Jeon HJ et al: Surgical outcomes after classifying Grade III arteriovenous malformations according to Lawton's modified Spetzler-Martin grading system. Clin Neurol Neurosurg. 124:72-80, 2014
4. Mohr JP et al: Medical management with or without interventional therapy for unruptured brain arteriovenous malformations (ARUBA): a multicentre, non-blinded, randomised trial. Lancet. 383(9917):614-21, 2014
5. Shankar JJ et al: Angioarchitecture of brain AVM determines the presentation with seizures: proposed scoring system. AJNR Am J Neuroradiol. 34(5):1028-34, 2013

https://CafePezeshki.IR

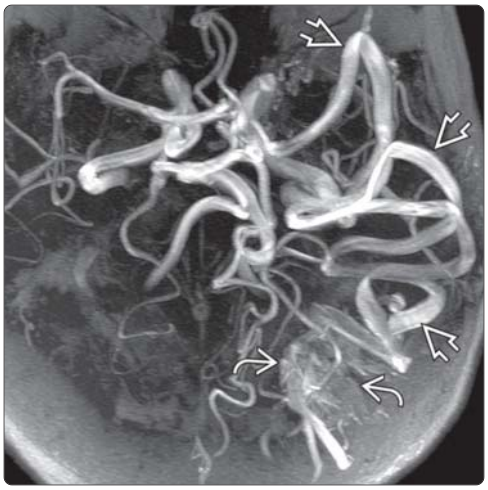

(Left) *Axial TOF MRA MIP in a 38-year-old patient with a worsening headache and visual disturbance shows a left parietooccipital AVM ⇨ with massively dilated MCA feeding arteries ⇨.* **(Right)** *Axial T1WI C+ MR in the same patient shows avid enhancement of the nidus ⇨ and enlarged superficial draining veins ⇨. Note that a portion of the nidus ⇨ and feeding arteries ⇨ appear as flow voids due to the high flow within the vessels. Phase artifact ⇨ propagation across the image is striking.*

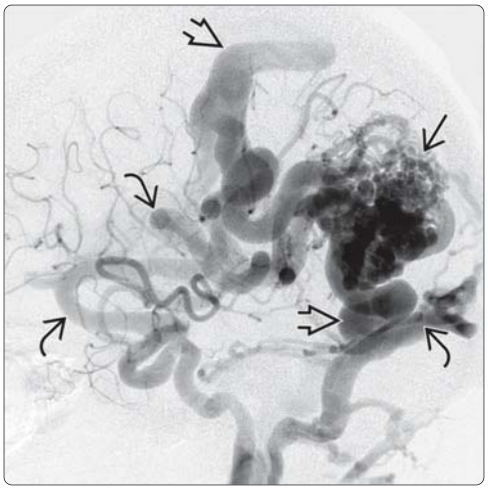

(Left) *Axial FLAIR MR shows "honeycomb" flow voids representing the AVM nidus ⇨. Large serpentine flow voids anterior to the nidus are MCA feeding arteries ± draining veins ⇨. Note only mild mass effect on the trigone of the left lateral ventricle relative to the size of the lesion. Some high signal adjacent to the nidus ⇨ likely represents gliosis.* **(Right)** *Lateral ICA DSA in the same patient shows enlarged MCA feeders ⇨, dilated/tortuous superficial draining veins ⇨, and AVM nidus ⇨.*

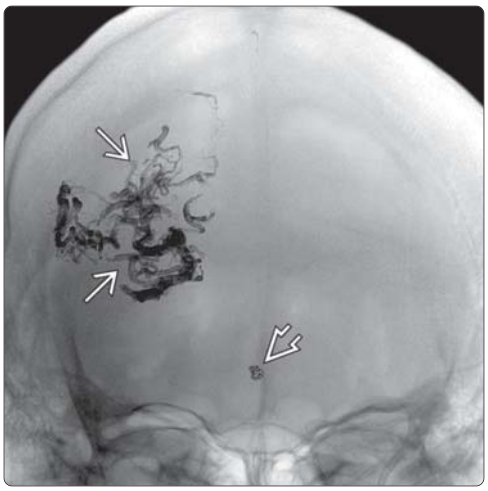

(Left) *Oblique left ICA 3D DSA shows enlarged anterior cerebral artery ⇨ supplying a frontal AVM ⇨. Note flow-related aneurysm of the anterior communicating artery ⇨, a potential cause of future ICH.* **(Right)** *Posteroanterior unsubtracted image, after 3 sessions of staged embolization of multiple ACA and MCA feeders, shows an onyx cast within the nidus and adjacent feeding arteries ⇨. The ACoA flow-related aneurysm was coiled ⇨ prior to embolization of the ACA feeders.*

https://CafePezeshki.IR

KEY FACTS

IMAGING

- Location: Dural sinus wall
  - Posterior fossa >> supratentorial
  - Can involve any dural sinus (TS/SS most common)
- NECT
  - Usually normal
  - ICH if outlet vein thrombosed or flow-related aneurysm, venous pouch ruptures
- Bone CT
  - Dilated transosseous calvarial vascular channels
  - ± enlarged foramen spinosum
- MR
  - Isointense thrombosed sinus ± flow voids on T1/T2WI
  - Thrombosed dural sinus blooms on T2*
  - May show parenchymal hemorrhage in dAVF with cortical venous drainage
  - FLAIR: Isointense thrombosed sinus ± adjacent edema if venous congestion or ischemia present
- MR/CTA: Network of tiny (crack-like) vessels in wall of thrombosed dural venous sinus

TOP DIFFERENTIAL DIAGNOSES

- Hypoplastic transverse-sigmoid sinus
- Sigmoid sinus-jugular foramen pseudolesion
- Thrombosed dural sinus
- Dural sinus stenosis

PATHOLOGY

- Adult dAVFs are usually acquired, not congenital
- Can occur in response to trauma, venous sinus thrombosis
- Pathological activation of neoangiogenesis

CLINICAL ISSUES

- 10-15% of all cerebrovascular malformations with AV shunting
- Adult >> child
- Prognosis depends on location, venous drainage pattern
- Treatment options: Endovascular, surgery, stereotaxic XRT

(Left) *Graphic depicts dAVF with thrombosed transverse sinus. Multiple transosseous branches from the external carotid artery supplying innumerable tiny arteriovenous fistulae in the dural wall.* **(Right)** *Mass-like surgical specimen from a resected dAVF in the transverse sinus wall shows innumerable crack-like vessels. (Courtesy R. Hewlett, MD.)*

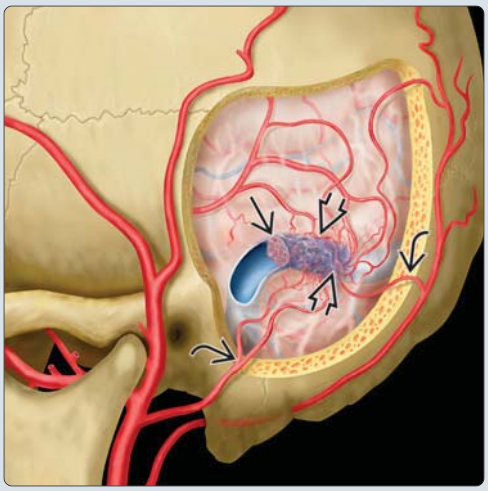

(Left) *Lateral view of an external carotid DSA depicts typical angiographic findings of dAVF. The ipsilateral transverse sinus is occluded and there are multiple prominent branches from the posterior auricular artery supplying a dAVF in the TS wall. The occipital artery is markedly enlarged.* **(Right)** *Selective injection of the OA in the same patient nicely demonstrates the mass-like dAVF in the occluded TS. Note innumerable enlarged transosseous branches that pass intracranially to supply the dAVF.*

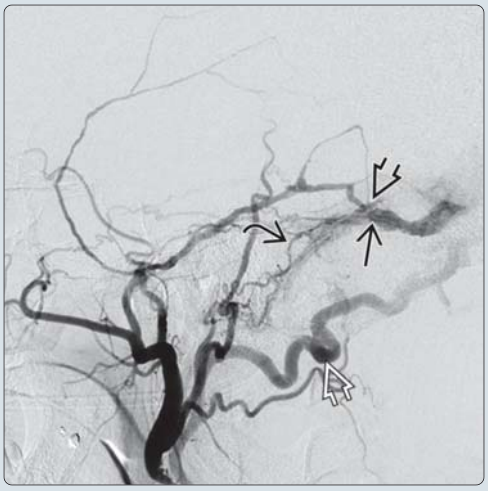

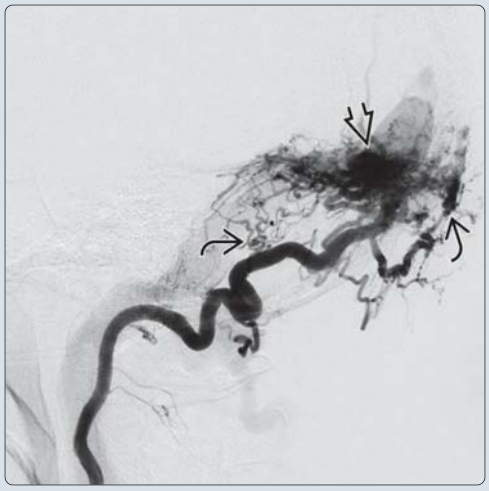

https://CafePezeshki.IR

TERMINOLOGY

Abbreviations

- Dural arteriovenous fistula (dAVF)

Synonyms

- Dural arteriovenous shunt (dAVS)

Definitions

- Heterogeneous group of lesions with common angioarchitecture (AV shunts in dural venous sinus wall)

IMAGING

General Features

- Best diagnostic clue
  - MR/CTA: Network of tiny (crack-like) vessels in wall of thrombosed dural venous sinus
  - DSA: Predominant arterial supply from meningeal arteries
  - Bone CT: Dilated transosseous calvarial vascular channels, enlarged foramen spinosum
- Location
  - Posterior fossa >> supratentorial
  - Can involve any dural venous sinus
    - Most common (35-40%) = transverse sinus (TS) + sigmoid sinus (SS)
    - Other common sites = cavernous sinus (CS), superior sagittal sinus (SSS), superior petrosal sinus (SPS)

CT Findings

- NECT
  - May see dilated vascular channels in skull from transosseous feeding arteries
  - Ipsilateral enlargement of foramen spinosum
    - Contains middle meningeal artery that commonly supplies dAVFs
  - Look for complications: Subarachnoid hemorrhage, cerebral edema (venous hypertension)
- CECT
  - May see tortuous feeding arteries ± flow-related aneurysms (uncommon), draining veins
  - Involved dural venous sinus completely/partially thrombosed or stenotic
- CTA
  - Standard 3D CTA may be useful in depicting gross angioarchitecture
  - 320-row detector dynamic 4D-CTA allows volumetric imaging, detailed spatial/temporal resolution

MR Findings

- T1WI
  - Isointense thrombosed dural sinus ± flow voids
- T2WI
  - Isointense thrombosed sinus ± flow voids
  - Focal hyperintensity in adjacent brain
    - Look for retrograde leptomeningeal venous drainage
    - Look for venous perfusion abnormalities
- FLAIR
  - Isointense thrombosed sinus ± adjacent edema (if venous ischemia/congestion)
- T2* GRE
  - Thrombosed dural sinus "blooms"
  - Rare: Parenchymal hemorrhage
    - Usually if cortical venous drainage present
    - Look for thrombosed draining veins
- DWI
  - Normal unless venous infarct or ischemia present
- T1WI C+
  - Chronically thrombosed sinus usually enhances
- MRA
  - Useful for gross depiction of angioarchitecture, dynamics
  - TOF MRA may be negative with small or slow-flow shunts
- MRV
  - Depicts occluded parent sinus, collateral flow
  - 3D phase contrast MRA with low VENC can identify fistula, feeding arteries, flow reversal in draining veins

Angiographic Findings

- Conventional
  - Multiple arterial feeders are typical
    - Dural/transosseous branches from ECA most common
    - Tentorial/dural branches from ICA, VA
    - Parasitization of pial arteries with larger dAVFs
  - Arterial inflow into parallel venous channel ("recipient pouch") common
  - Involved dural sinus often thrombosed or stenotic
  - Flow reversal in dural sinus/cortical veins correlates with progressive symptoms, risk of hemorrhage
  - Tortuous engorged pial veins ("pseudophlebitic" pattern) with venous congestion/hypertension (clinically aggressive)
  - High-flow venopathy → progressive stenosis, outlet occlusion, hemorrhage

Imaging Recommendations

- Best imaging tool
  - DSA ± superselective catheterization of dural, transosseous feeders
- Protocol advice
  - Screening MR, contrast-enhanced MRA
  - DSA to delineate vascular supply, venous drainage

DIFFERENTIAL DIAGNOSIS

Pial AVM

- Congenital vascular lesion with intraaxial nidus and no intervening normal brain parenchyma
- Predominant pial arterial supply, parasitization of dural supply possible (opposite to dAVF)

Sigmoid Sinus-Jugular Foramen Pseudolesion

- Slow or asymmetric flow creates variable signal on MR sequences
- Use MRV with multiple encoding gradients to clarify

Thrombosed Dural Sinus

- Collateral/congested venous drainage can mimic dAVF
- Can be spontaneous, traumatic, infectious (thrombophlebitis)

Dural Sinus Stenosis

- May have prominent collateral draining veins

https://CafePezeshki.IR

PATHOLOGY

General Features

- Etiology
  - Adult dAVFs are usually acquired, not congenital
    - Often idiopathic
    - Can occur in response to trauma, venous sinus thrombosis
  - Infant dAVFs are congenital and usually associated with enlargement of dural venous sinuses
  - Pathological activation of neoangiogenesis
    - Proliferating capillaries within granulation tissue in dural sinus obliterated by organized thrombi
    - Budding/proliferation of microvascular network in inner dura connects to plexus of thin-walled venous channels, creating microfistulae
    - High bFGF, VEGF expression in dAVFs
- Associated abnormalities
  - Cortical venous drainage associated with edema, encephalopathy
  - Venous hypertension may lead to developmental delay in children
  - Arterialized flow in cortical veins/dural sinuses → high-flow venopathy, ↑ risk of ICH, encephalopathy

Staging, Grading, & Classification

- Cognard classification of intracranial dAVFs correlates venous drainage pattern with risk of ICH
  - Grade 1: In sinus wall, normal antegrade venous drainage (low risk; benign clinical course)
  - Grade 2A: In wall, reflux into sinus (but not cortical veins)
  - Grade 2B: Retrograde drainage into cortical veins (10-20% hemorrhage)
  - Grade 3: Direct cortical venous drainage, no venous ectasia (40% hemorrhage)
  - Grade 4: Direct cortical venous drainage, venous ectasia (65% hemorrhage)
  - Grade 5: Spinal perimedullary venous drainage (progressive myelopathy)

Gross Pathologic & Surgical Features

- Multiple enlarged dural arteries converge on wall of thrombosed dural sinus
- Cortical draining veins enlarged (± with stenoses, dilatation, tortuosity)

Microscopic Features

- Arterialized veins with irregular intimal thickening, variable loss of internal elastic lamina

CLINICAL ISSUES

Presentation

- Most common signs/symptoms
  - Clinical manifestations related to location, presence/absence of venous hypertension
    - TS-SS = pulsatile tinnitus
    - Cavernous sinus = pulsatile exophthalmos, CNs 3, 4, 6 neuropathy
    - Infant dAVF: Developmental delay, ↑ head circumference
  - Uncommon: Encephalopathic symptoms (venous hypertension, ischemia/thrombosis)
    - Progressive dementia
- Clinical profile
  - Middle-aged patient with pulse-synchronous tinnitus

Demographics

- Age
  - Adult >> child
    - Usually presents in middle-aged patients
    - Pediatric dAVFs rare, high mortality
- Epidemiology
  - 10-15% of all cerebrovascular malformations with AV shunting

Natural History & Prognosis

- Depends on location, venous drainage pattern
  - 98% of dAVFs without retrograde venous drainage have benign course
  - dAVFs with retrograde venous drainage have aggressive clinical course

Treatment

- Conservative: Observation ± carotid compression technique
- Treatment options if (1) hemorrhage risk exists or (2) for types 1 and 2A with debilitating pulsatile tinnitus
  - Embolization of arterial feeders with particulate or liquid agents, coil embolization of recipient venous pouch/sinus
  - Surgical skeletonization of involved dural venous sinus

DIAGNOSTIC CHECKLIST

Consider

- DSA for definitive exclusion of dAVF in patient with objective pulsatile tinnitus

Image Interpretation Pearls

- MR + MRA may be normal in small dAVF
- **Always** examine bilateral ICAs, ECAs, and vertebral arteries when performing DSA to exclude dAVF

SELECTED REFERENCES

1. Tian B et al: Four-dimensional computed tomography angiographic evaluation of cranial dural arteriovenous fistula before and after embolization. Eur J Radiol. ePub, 2015
2. Zaidi HA et al: Multimodal treatment strategies for complex pediatric cerebral arteriovenous fistulas: contemporary case series at Barrow Neurological Institute. J Neurosurg Pediatr. 1-10, 2015
3. Appaduray SP et al: Pediatric dural arteriovenous malformations. J Neurosurg Pediatr. 14(1):16-22, 2014
4. D'Orazio F et al: 320-Row Detector Dynamic 4D-CTA for the Assessment of Brain and Spinal Cord Vascular Shunting Malformations. A Technical Note. Neuroradiol J. 27(6):710-7, 2014
5. Hacein-Bey L et al: Natural history, current concepts, classification, factors impacting endovascular therapy, and pathophysiology of cerebral and spinal dural arteriovenous fistulas. Clin Neurol Neurosurg. 121:64-75, 2014
6. Shin NY et al: Venous angioarchitectural features of intracranial dural arteriovenous shunt and its relation to the clinical course. Neuroradiology. 55(9):1119-27, 2013

https://CafePezeshki.IR

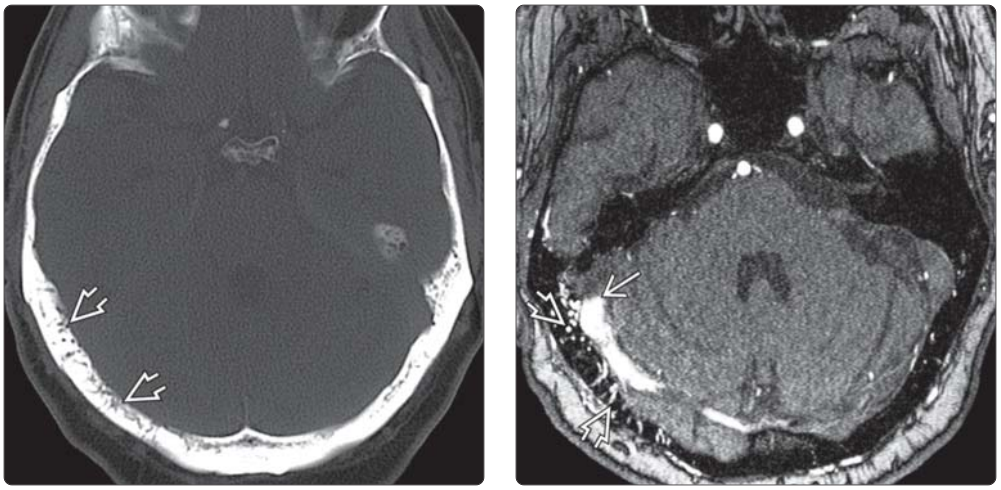

(Left) *Axial bone CT in a patient with tinnitus shows multiple enlarged transosseous vascular channels ➡ in the squama of the right occipital bone.* **(Right)** *Contrast-enhanced MRA in the same patient shows right dural sinus thrombosis ➡, multiple enhancing transosseous vascular channels ➡ characteristic of posterior fossa dAVF.*

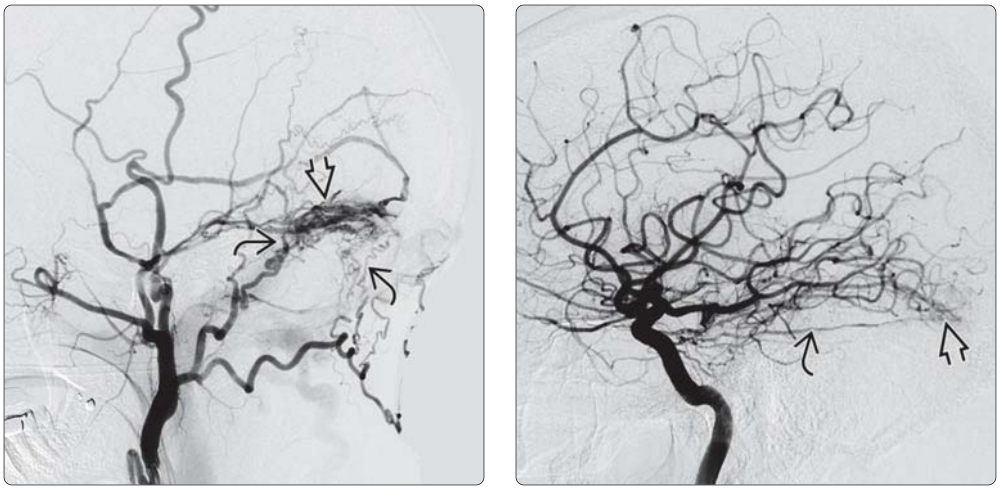

(Left) *Lateral view of an external carotid DSA in a patient with tinnitus shows a dAVF ➡ in a thrombosed transverse sinus supplied by multiple transosseous feeding vessels ➡ from the posterior auricular and occipital arteries.* **(Right)** *Selective internal carotid angiogram in the same patient shows an enlarged meningohypophyseal trunk ➡ that arises from the cavernous ICA and also supplies the dAVF ➡.*

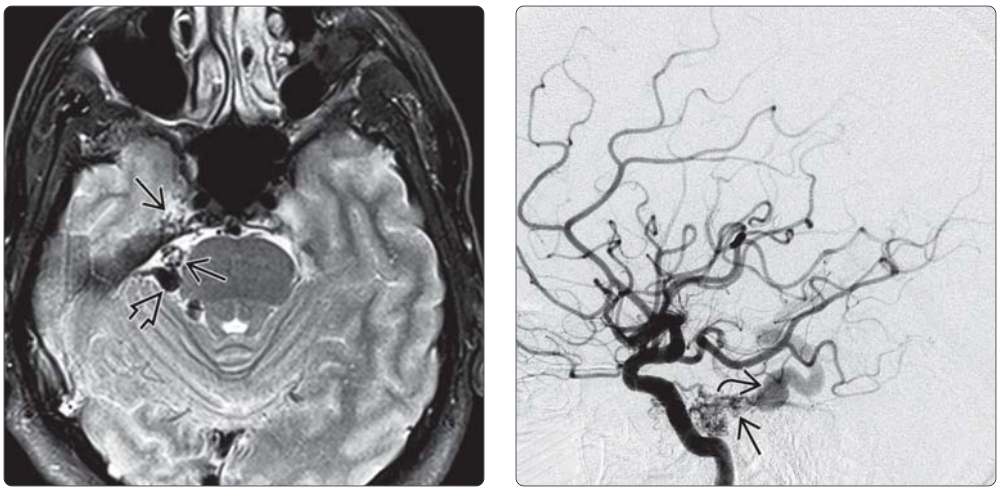

(Left) *Axial T2WI in a 48-year-old man with right-sided trigeminal neuralgia shows a tangle of vessels ➡ in Meckel cave and cerebellopontine angle cistern associated with a prominent "flow void" ➡.* **(Right)** *Lateral view of the internal carotid angiogram in the same patient shows that the tangle of vessels ➡ is supplied by enlarged dural branches of the ICA and fistulizes directly into an enlarged "early draining" vein ➡.*

https://CafePezeshki.IR

Pial AV Fistula

KEY FACTS

TERMINOLOGY

- Pial vascular malformation with direct arteriovenous (AV) shunting
  - One or more pial (cortical) arteries connects to single venous channel
  - No intervening capillary bed or nidus
  - May occur anywhere in brain, spinal cord
  - Can lie on surface/within brain or at ependyma
- Rare (1-2% of all brain vascular malformations)

IMAGING

- CT: Iso-/hyperdense serpentine vessels ± Ca++
  - Arterial feeder(s), draining veins enhance
- DSA
  - Dilated feeding artery drains directly into enlarged vein
  - ± confluence of arteries just before fistulous connection
  - No intervening nidus

TOP DIFFERENTIAL DIAGNOSES

- Arteriovenous malformation (AVM)
- Dural AV fistula
- Vein of Galen aneurysmal malformation

PATHOLOGY

- Enlarged mature arteries, variceal draining veins
- Draining veins are "arterialized" with thickened walls
  - May have variceal "aneurysms" ± high-flow venopathy, stenosis

CLINICAL ISSUES

- Much higher hemorrhage risk than AVM
- Spontaneous obliteration may be more common, especially in infants
- Embolization curative if draining vein occluded at fistulous site

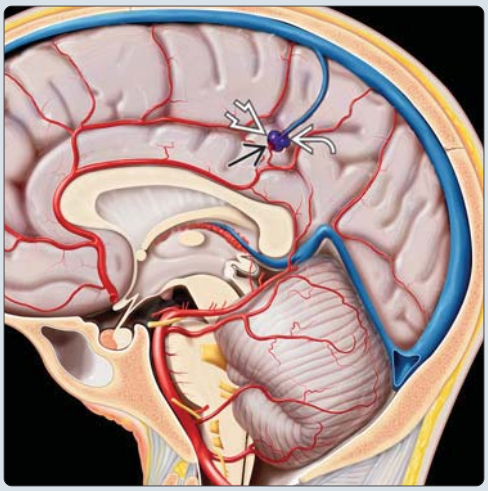

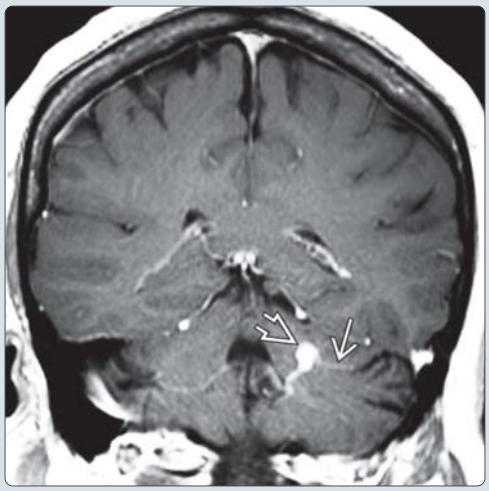

(Left) *Graphic depicts direct pial arteriovenous fistula seen here as abrupt change in vessel caliber from feeding arteries to a dilated, somewhat variceal-appearing draining vein. No intervening nidus is present, contrasting pial AVF from AVM.* **(Right)** *Coronal T1C+ MR shows a cerebellar pAVF with single arterial feeder draining into a venous varix.*

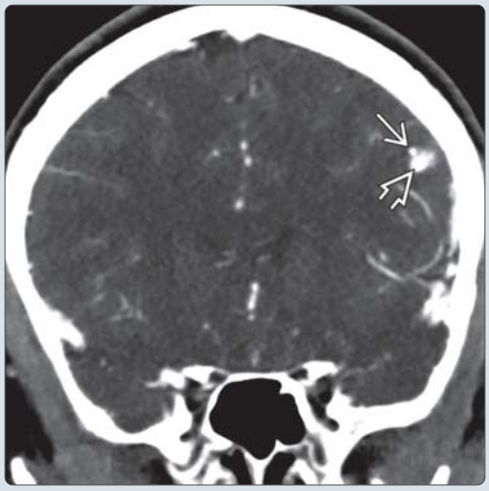

(Left) *Axial CT angiogram in a patient with HHT shows an enlarged vessel lying in a sulcus along the brain surface.* **(Right)** *Coronal CTA in the same case shows a small cluster of tiny arteries draining into a dilated vein. Pial AVF was found at surgery.*

https://CafePezeshki.IR

TERMINOLOGY

Abbreviations

- Pial arteriovenous fistula (pAVF)

Definitions

- Pial vascular malformation with direct arteriovenous (AV) shunting
  - One or more pial (cortical) arteries connects to single venous channel
  - No intervening capillary bed or nidus
- Rare (1-2% of all brain vascular malformations)

IMAGING

General Features

- Best diagnostic clue
  - Dilated cortical artery, draining vein without focal nidus
- Location
  - On cortical surface, within brain parenchyma
  - May occur anywhere in brain, spinal cord
    - Rare in posterior fossa

CT Findings

- NECT
  - Iso-/hyperdense serpentine vessels
- CTA
  - Shows arterial feeder(s), draining vein/varix

MR Findings

- T2WI
  - Dilated serpiginous flow voids
  - Variable hemorrhage
- T2* GRE
  - ± "blooming" hypointense blood products

Angiographic Findings

- Delineates angioarchitecture
  - Fistula at site of abrupt change in vessel caliber
- Dilated feeding artery
  - Single > multiple
    - ± confluence of arteries just before fistulous connection
  - Drains directly into enlarged vein
- No intervening nidus
- Single draining vein (± varix)

Imaging Recommendations

- Best imaging tool
  - DSA best delineates angioarchitecture
- Protocol advice
  - CTA/CE MRA best noninvasive method

DIFFERENTIAL DIAGNOSIS

Arteriovenous Malformation (AVM)

- Has definite nidus composed of microscopic AV shunts
  - Nidus: A few millimeters to several centimeters in size
  - May have large fistulous connections within nidus
  - Angiomatous matrix of small vascular channels on DSA
- Much more common than pAVF

Dural AV Fistula (dAVF)

- AV shunts within wall of patent/partially thrombosed dural venous sinus (DVS)
- Drainage to dural sinus
- Differentiate from pial AVF by
  - Fistulas intimately related to DVS, within DVS wall
  - Predominant blood supply is from dural (meningeal) arteries > > pial artery
    - e.g., anterior, middle, and posterior meningeal arteries, tentorial branches of cavernous ICA, PCA, occipital artery, ascending pharyngeal artery

Vein of Galen Aneurysmal Malformation

- Mural type is pAVF of vein of Galen
- Merely a difference in location
  - Supply from medial posterior choroidal branches to prosencephalic vein
  - Drainage via straight sinus or persistent falcine sinus

PATHOLOGY

General Features

- Etiology
  - Factors of pAVMs: Dysregulated angiogenesis
  - Trauma
- Genetics
  - Sporadic pAVFs, like pAVMs, may have multiple up-/down-regulated genes
  - Syndromic pAVFs associated with *HHT1* (endoglin gene) mutation

Gross Pathologic & Surgical Features

- Draining veins are "arterialized"
  - Thickened walls ± stenosis of high-flow venopathy
  - May have variceal "aneurysms"

CLINICAL ISSUES

Presentation

- Most common signs/symptoms
  - Headache
  - Cranial bruit

Natural History & Prognosis

- ↑ ↑ hemorrhage risk compared to AVM
  - Mortality of > 60% if managed conservatively

Treatment

- Embolization
  - Curative if draining vein occluded at fistulous site
- Microsurgical disconnection

SELECTED REFERENCES

1. Sugimoto T et al: Effectiveness of intraoperative indocyanine green videoangiography in direct surgical treatment of pediatric intracranial pial arteriovenous fistula. J Neurosurg Pediatr. 15(1):55-9, 2015
2. Jouibari MF et al: Pial arteriovenous fistula with giant varices: report of two cases with good surgical outcome. J Cerebrovasc Endovasc Neurosurg. 16(2):98-103, 2014
3. Lin N et al: Non-galenic arteriovenous fistulas in adults: transarterial embolization and literature review. J Neurointerv Surg. ePub, 2014
4. Jabbour P et al: Endovascular treatment of cerebral dural and pial arteriovenous fistulas. Neuroimaging Clin N Am. 23(4):625-36, 2013

https://CafePezeshki.IR

KEY FACTS

TERMINOLOGY

- Vein of Galen malformation (VGAM)
- Arteriovenous fistula between deep choroidal arteries, embryonic median prosencephalic vein
- High flow through MPV prevents formation of vein of Galen → VGAM is misnomer

IMAGING

- Best diagnostic clue: Large midline varix (MPV) in neonate/infant
- Embryonic falcine sinus drains MPV in 50%

TOP DIFFERENTIAL DIAGNOSES

- Vein of Galen aneurysmal dilatation (VGAD)
- Childhood dural arteriovenous fistula
- Complex developmental venous anomaly (DVA)
- Giant aneurysm

PATHOLOGY

- Most common extracardiac cause of high-output cardiac failure in newborn
- Associated abnormalities
  - Hydrocephalus
  - Cerebral ischemia/atrophy

CLINICAL ISSUES

- Age: Neonatal presentation most common
- Prognosis related to volume of shunt, timing/success treatment
  - Single or staged transarterial embolization (TAE) at 4-5 months
- Brain damage or multisystem organ failure at presentation are contraindications to treatment

(Left) *Graphic depicts vein of Galen malformation. Enlarged posterior choroidal arteries ⇨ drain into a dilated median prosencephalic vein (MPV) of Markowski ⇨. The MPV drains into the superior sagittal sinus via an embryonic falcine sinus ⇨; the straight sinus is absent.* **(Right)** *CECT scan in a newborn with high-output congestive heart failure shows a massive VGAM ⇨ draining into an enlarged falcine sinus ⇨, causing obstructive hydrocephalus.*

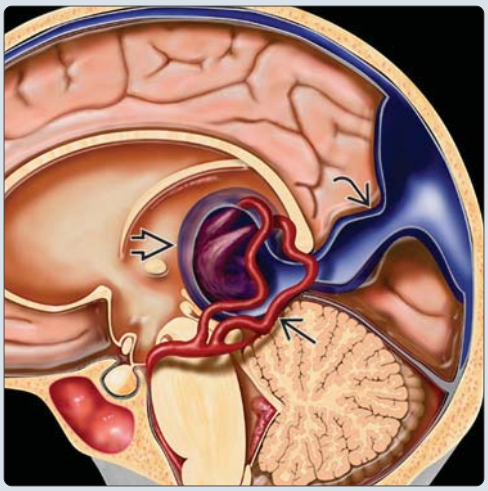

(Left) *Sagittal T2WI shows prominent arteries ⇨ supplying an enlarged median prosencephalic vein ⇨. Note enlarged falcine sinus ⇨, absence of straight sinus.* **(Right)** *DSA in the same patient shows that the VGAM ⇨ is supplied by multiple direct arterial fistulas ⇨.*

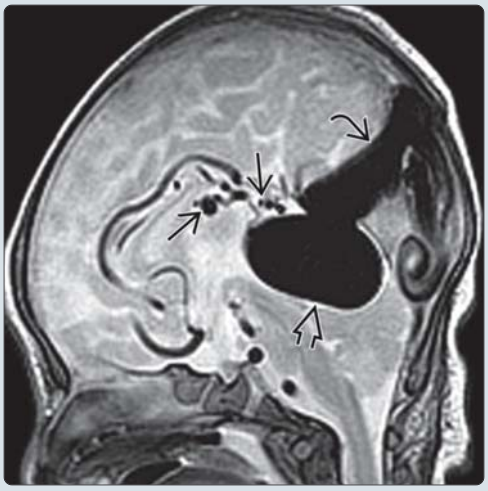

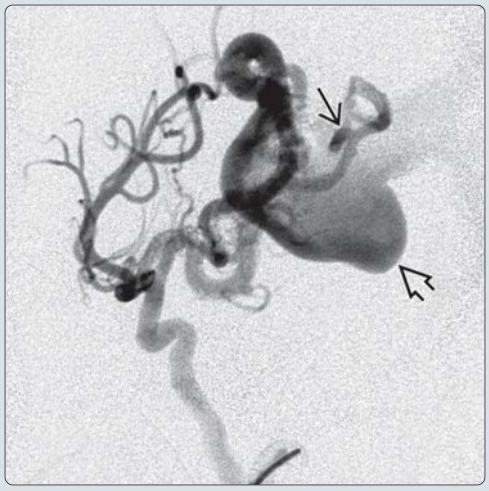

https://CafePezeshki.IR

TERMINOLOGY

Abbreviations

- Vein of Galen (VofG), vein of Galen aneurysmal malformation (VGAM), median prosencephalic vein (MPV) of Markowski

Synonyms

- Vein of Galen "aneurysm," galenic varix

Definitions

- Arteriovenous fistula (AVF) between pericallosal/deep choroidal arteries and embryonic MPV (precursor of VofG)
- High flow through MPV prevents formation of vein of Galen; VGAM is misnomer

IMAGING

General Features

- Best diagnostic clue: Large midline varix (MPV) in neonate/infant
- Location: Quadrigeminal plate cistern
- Size: Few to several cm
- Morphology: Tubular or spherical varix

Radiographic Findings

- Chest radiograph: Congestive heart failure (CHF)
  - Cardiomegaly, pulmonary edema

CT Findings

- NECT
  - MPV mildly hyperdense to brain
  - Hydrocephalus
  - Subcortical white matter (WM) hypodensity and Ca++ → chronic venous ischemia
  - Intracranial (IC) hemorrhage (rare)
- CECT
  - Vascular enhancement feeding arteries, MPV
- CTA
  - Delineates feeding arteries, venous drainage

MR Findings

- T1WI
  - MPV: Flow void or heterogeneous due to fast or turbulent flow
    - Hyperintense foci: Thrombus
    - Phase artifact from fast, turbulent flow
  - Hyperintense foci within brain: Ca++, ischemia
  - Sag: Tectal compression, tonsillar herniation
- T2WI
  - MPV: Flow void or heterogeneous due to fast or turbulent flow
  - Flow voids from feeding arteries around MPV
  - Ischemic foci poorly seen in unmyelinated infant brain
- DWI: Restriction in acute ischemia/infarction
- MRA: Delineates arterial feeders
- MRA C+: Shows arterial and venous anatomy together
- MRV: Delineates MPV and venous anatomy
- Fetal MR: Can identify brain and other end-organ injury
- Significant injury seen on antenatal or postnatal imaging is contraindication to aggressive therapy

Ultrasonographic Findings

- Grayscale ultrasound
  - Mildly echogenic midline mass
- Color Doppler
  - Arterialized flow within MPV
- Antenatal US: VGAM identified in 3rd trimester
  - ↑ resistance middle cerebral artery → vascular steal
  - Cardiac dilatation, hydrops fetalis = poor prognosis

Angiographic Findings

- Common arterial feeders
  - Medial and lateral posterior choroidal arteries
  - Pericallosal arteries
- Venous anatomy
  - Embryonic falcine sinus drains MPV in 50%
    - Associated with absent straight sinus
  - Variable absence, stenoses of other sinuses
  - Reflux into pial venous system ↑ risk IC hemorrhage
    - Requires urgent treatment
  - Venous drainage from central brain structures typically not through MPV but superior petrosal and cavernous sinuses

Imaging Recommendations

- Best imaging tool
  - MR with MRA/MRV
  - Catheter angiogram ideally performed with 1st embolization (4-5 months of age)
- Protocol advice
  - MRA C+ may obviate need for MRV

DIFFERENTIAL DIAGNOSIS

Vein of Galen Aneurysmal Dilatation (VGAD)

- Arteriovenous malformation (AVM) with venous drainage into true vein of Galen
- Less common than VGAM
- Typically does not present before 3 years of age

Childhood Dural Arteriovenous Fistula

- High-flow fistulas: Neonatal presentation similar to VGAM
- Frequent giant aneurysms, venous varices
- External carotid artery → torcular, transverse, or superior sagittal sinus
- Spontaneous thrombosis may occur after delivery

Complex Developmental Venous Anomaly

- Dilatation of veins draining normal brain parenchyma
- No nidus or AV shunting
- Associated with blue rubber bleb nevus syndrome

Giant Aneurysm

- Not associated with venous abnormalities
- "Onion skin" layers in wall

PATHOLOGY

General Features

- Embryology
  - Normal
    - Choroid arterial tributaries drain to single temporary midline vein (MPV)

https://CafePezeshki.IR

  - MPV normally regresses during 11th week of gestation
  - By 12 weeks joins internal cerebral/basal veins to form VofG
  - Abnormal
    - MPV fails to degenerate
    - Primitive arteriovenous fistulous connects persist, forming VGAM
  - Week 5: Arterial supply to choroid plexus established from meninx primitiva
  - Week 10: Internal cerebral veins (ICVs) annex drainage of choroid plexus → regression MPV
  - Caudal MPV persists, joins ICVs to form vein of Galen
- Etiology
  - AVF of choroidal arteries and MPV
  - ↑ flow through fistula prevents normal regression MPV
- Genetics: Sporadic
  - Rare reports of hereditary vascular dysplasia syndromes
- Epidemiology
  - Rare: < 1% of cerebral vascular malformations
  - Up to 30% of pediatric vascular malformations
  - Most common extracardiac cause of high-output cardiac failure in newborns
- Associated abnormalities
  - Venous occlusion, stenosis
    - Primary atresia vs. occlusion 2° to increased pressure, flow
    - Provides right heart protection
  - Cerebral ischemia/atrophy
    - Arterial steal
    - Chronic venous hypertension
  - Hydrocephalus
    - ↓ CSF resorption 2° to ↑ venous pressure
    - ± cerebral aqueduct obstruction
  - Atrial septal defects; aortic coarctation

Staging, Grading, & Classification

- Lasjaunias system
  - Type I: Choroidal type (multiple choroidal arteries enter anterior MPV via tributary veins)
  - Type II: Mural type (single/multiple fistulas at inferolateral wall of MPV)
- Mortazavi system (0-1 no urgency, treat in 1 stage endovascular; 2 = urgent endovascular, treat in stages; 3 = consider endovascular treatment or palliation, treat in stages)
  - Arterial feeders
    - Any feeders other than P1-2, thalamoperforators, choroidal basilar = 0
    - Any of the following: P1-2, thalamoperforators, choroidal, basilar = 1
  - Clinical symptoms
    - No heart failure = 0
    - Heart failure = 1
  - Age
    - ≥ 5 months = 0
    - < 5 months = 1

Gross Pathologic & Surgical Features

- Malformations of structures adjacent to MPV
  - Pineal gland, tela choroidea of 3rd ventricle

Microscopic Features

- Thickened wall of MPV, ± Ca++

CLINICAL ISSUES

Presentation

- Most common signs/symptoms
  - Neonate: High-output CHF, cranial bruit
  - Infant: Macrocranium (hydrocephalus)
  - Older child, adult (rare): Headache, IC hemorrhage
- Other signs/symptoms
  - Developmental delay, failure to thrive, seizure, end-organ failure

Demographics

- Age: Neonatal presentation most common
  - Rarely diagnosed after age 3
- Gender: M:F = 2:1

Natural History & Prognosis

- Without treatment, death from intractable heart and multisystem failure occurs in neonates
- Prognosis related to volume of shunt, timing/success treatment
- High venous pressures in utero may result in significant injury to brain

Treatment

- Brain damage or multisystem organ failure at presentation is contraindication to treatment
- Medical therapy for CHF until 4-5 months of age
  - Failure therapy warrants earlier neurointervention
- Single or staged transarterial embolization (TAE) at 4-5 months
- Treatment for hydrocephalus controversial

DIAGNOSTIC CHECKLIST

Image Interpretation Pearls

- Imaging appearance diagnostic in appropriate clinical setting

Reporting Tips

- Report progressive brain injury on MRs

SELECTED REFERENCES

1. Pop R et al: Flow control using Scepter(TM) balloons for Onyx embolization of a vein of Galen aneurysmal malformation. Childs Nerv Syst. 31(1):135-40, 2015
2. Mortazavi MM et al: Vein of Galen aneurysmal malformations: critical analysis of the literature with proposal of a new classification system. J Neurosurg Pediatr. 12(3):293-306, 2013
3. Jagadeesan BD et al: Susceptibility-weighted imaging: a new tool in the diagnosis and evaluation of abnormalities of the vein of Galen in children. AJNR Am J Neuroradiol. 33(9):1747-51, 2012

https://CafePezeshki.IR

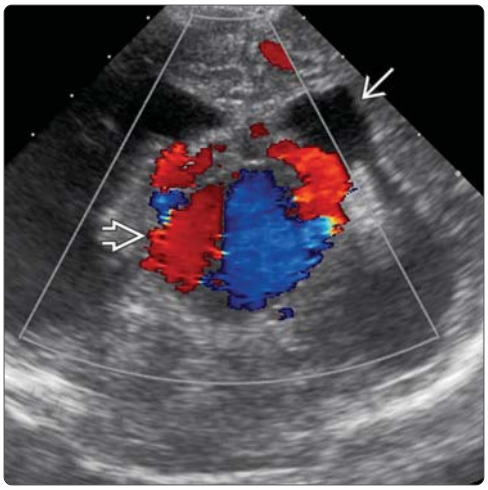

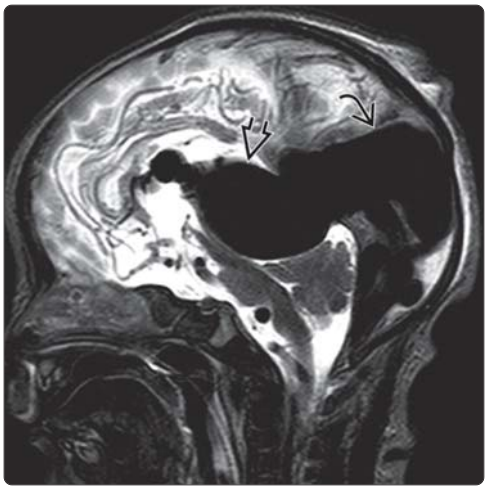

(Left) *Coronal color Doppler US in a newborn with high output CHF shows a large midline mass ⇨ with bidirectional flow. Note hydrocephalus ⇨.* **(Right)** *Sagittal T2WI in the same patient shows a huge VGAM with enlarged midline prosencephalic vein ⇨ and falcine sinus ⇨ supplied by multiple choroidal feeders.*

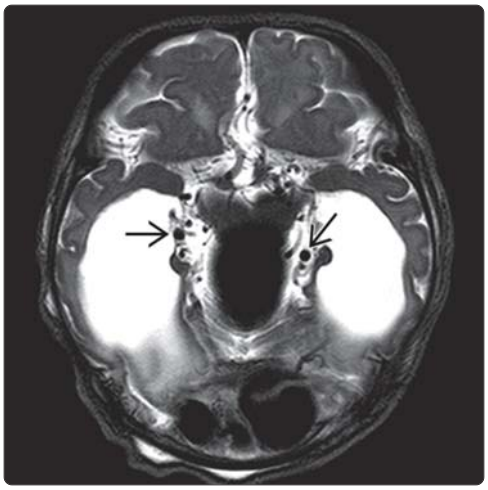

(Left) *Axial T2WI shows severe obstructive hydrocephalus and the enlarged, dilated "flow voids" ⇨ from the choroidal feeding arteries.* **(Right)** *Coronal T2WI shows the choroidal feeders ⇨ surrounding the massively enlarged median prosencephalic vein ⇨.*

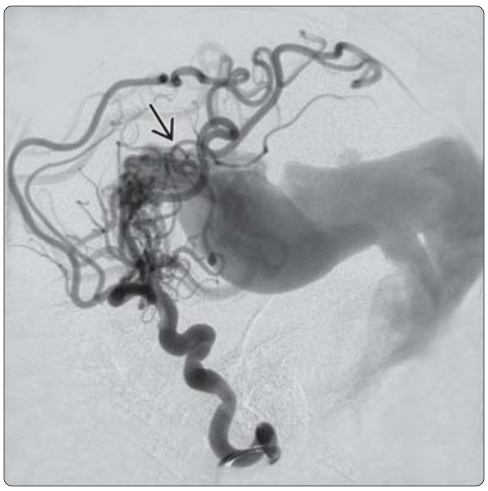

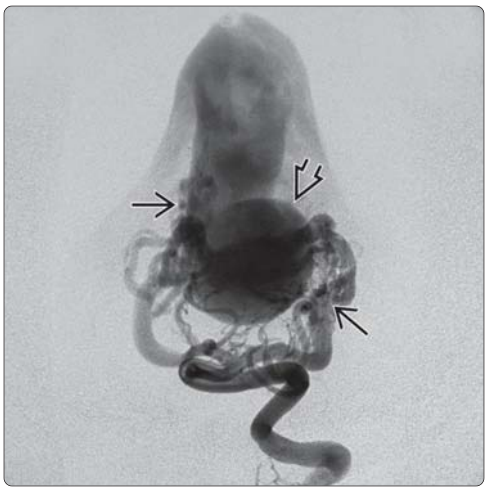

(Left) *Lateral DSA of internal carotid injection in the same patient shows multiple enlarged anterior cerebral artery branches ⇨ supplying the VGAM.* **(Right)** *AP view of the vertebrobasilar DSA in the same patient nicely demonstrates the markedly enlarged posterior cerebral arteries and their choroidal branches ⇨ that drain directly into the VGAM ⇨. (Courtesy S. Blaser, MD.)*

https://CafePezeshki.IR

KEY FACTS

TERMINOLOGY

- Congenital cerebral vascular malformation with mature venous elements
- May represent anatomic variant of otherwise normal venous drainage

IMAGING

- General features
  - Umbrella-like collection of enlarged medullary (white matter) veins ("Medusa head")
  - At angle of ventricle
  - Numerous linear or dot-like enhancing foci
  - Converge on single enlarged "collector" vein
  - "Collector" vein drains into dural sinus/deep ependymal vein
  - Usually solitary, variable size (< 2-3 cm)
  - Hemorrhage may occur if mixed malformation or draining vein thromboses
- CT often normal; enlarged "collector" vein may appear hyperdense
- MR
  - Variable signal depending on size, flow
  - Hypointense on SWI (BOLD effect in draining veins)
  - Strong enhancement

TOP DIFFERENTIAL DIAGNOSES

- Mixed vascular malformation (usually cavernoma)
- Vascular neoplasm
- Dural sinus thrombosis (chronic)

PATHOLOGY

- 15-20% coexisting cavernous &/or capillary malformations
- Blue rubber bleb nevus syndrome (BRBNS)
- Sulcation-gyration disorders (may cause epilepsy)
- Cervicofacial venous or lymphatic malformation (CAMS-3)

(Left) *Coronal oblique graphic depicts classic DVA with umbrella-like "Medusa head" of enlarged medullary (deep white matter) veins ⇨ converging on a dilated transcortical "collector" vein ⇨, which drains into the superior sagittal sinus ⇨.* **(Right)** *Gross pathology shows an incidental finding of DVA, seen here as scattered enlarged venous channels ⇨ near the frontal horn of the lateral ventricle. Normal white matter is seen between the venous tributaries. Note the absence of hemorrhage. (Courtesy R. Hewlett, MD.)*

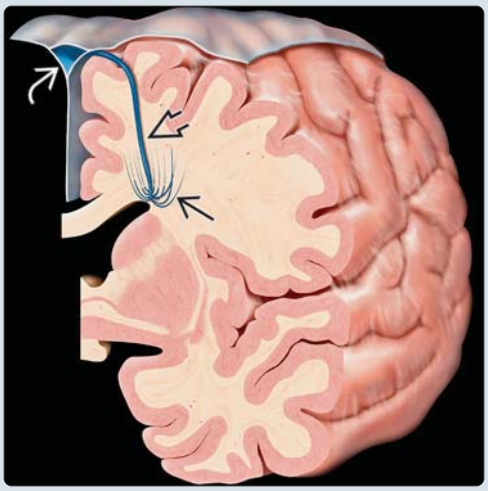

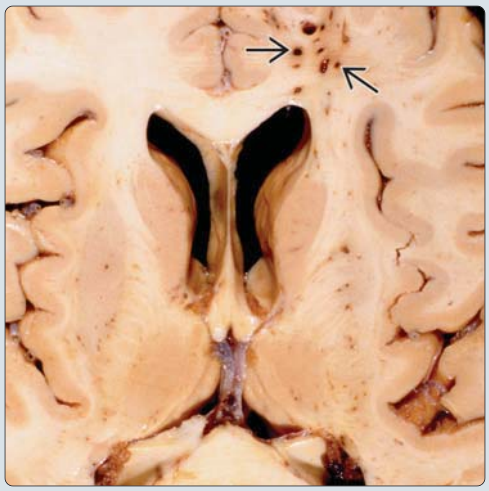

(Left) *Lateral DSA, venous phase, shows classic "Medusa head" of DVA with numerous enlarged medullary veins ⇨ converging on an enlarged transcortical "collector" vein ⇨.* **(Right)** *3D shaded surface rendering in the same patient elegantly depicts the classic "Medusa head" of a DVA ⇨. (Courtesy P. Lasjaunias, MD.)*

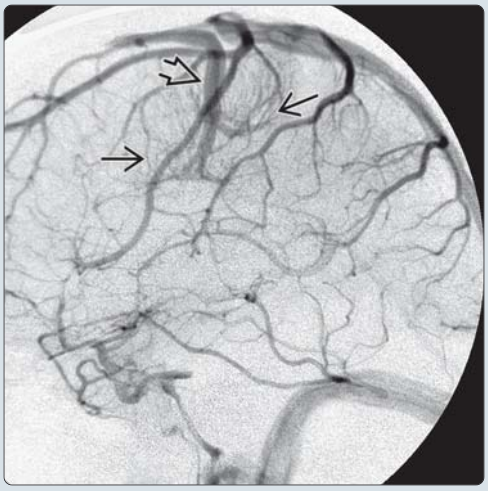

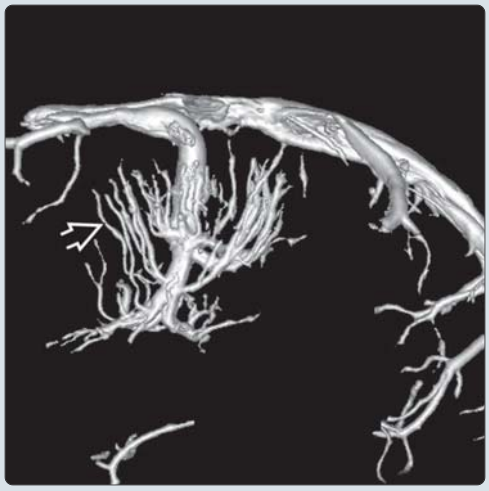

https://CafePezeshki.IR

TERMINOLOGY

Abbreviations

- Developmental venous anomaly (DVA)

Synonyms

- Venous angioma

Definitions

- Congenital cerebral vascular malformation with mature venous elements
- May represent anatomic variant of otherwise normal venous drainage

IMAGING

General Features

- Best diagnostic clue
  - "Medusa head" (dilated medullary white matter veins)
- Location
  - At angle of ventricle
    - Most common site: Near frontal horn
    - Other: Adjacent to 4th ventricle
- Size
  - Varies (may be extensive), but usually < 3 cm
- Morphology
  - Umbrella-like collection of enlarged medullary (white matter) veins
  - Large "collector" vein drains into dural sinus or deep ependymal vein
  - Usually solitary
    - Can be multiple in blue rubber bleb nevus syndrome

CT Findings

- NECT
  - Usual: Enlarged "collector" vein may appear hyperdense; this is not pathological
  - Occasional: Ca++ if mixed cavernous malformation (CM)
  - Rare: Acute parenchymal hemorrhage (if draining vein spontaneously thromboses)
- CECT
  - Numerous linear or dot-like enhancing foci
    - Well-circumscribed, round/ovoid, enhancing areas on sequential sections
    - Converge on single enlarged tubular draining vein
    - Occasionally seen as linear structure in single slice

MR Findings

- T1WI
  - Can be normal if DVA is small
  - Variable signal depending on size, flow
    - Flow void
  - Hemorrhage may occur if mixed malformation or draining vein thromboses
- T2WI
  - ± flow void
  - ± blood products
- FLAIR
  - Usually normal; may show hyperintense region if venous ischemia or hemorrhage present
- T2* GRE
  - May be hypointense ("blooms") on GRE if large or if coexisting CM with hemorrhage
  - Hypointense on SWI (BOLD effect in draining veins)
    - If high flow, deoxyhemoglobin reduced; may be isointense
- DWI
  - Usually normal or slightly increased diffusivity in drainage area
  - Rare: Acute venous infarct seen as hyperintense area of reduced diffusion
- PWI
  - Nearly 80% demonstrate perfusion abnormalities
    - Increased cerebral blood flow (CBF)
    - Increased cerebral blood volume (CBV)
    - Increased mean transit time (MTT)
- T1WI C+
  - Strong enhancement
    - Stellate, tubular vessels converge on "collector" vein
    - "Collector" vein drains into dural sinus/ependymal vein
- MRA
  - Arterial phase usually normal
  - Contrast-enhanced MRA may demonstrate slow-flow DVA
- MRV
  - Delineates "Medusa head" and drainage pattern
- MRS
  - Normal

Angiographic Findings

- DSA
  - Arterial phase normal in > 95% of cases
  - Capillary phase usually normal (rare: Prominent "blush" ± AV shunt)
  - Venous phase: "Medusa head"
  - < 5% atypical (transitional form of venous-arteriovenous malformation with enlarged feeders, AV shunting)

Nuclear Medicine Findings

- 75% of cases show hypometabolism in adjacent brain parenchyma

Imaging Recommendations

- Best imaging tool
  - T1 C+ MR plus SWI, MRV
- Protocol advice
  - Include T2* sequence (GRE, SWI)

DIFFERENTIAL DIAGNOSIS

Mixed Vascular Malformation (Usually Cavernoma)

- Hemorrhage often associated

Vascular Neoplasm

- Enlarged medullary veins
- Mass effect, usually enhances

Dural Sinus Thrombosis (Chronic)

- Chronic thrombosis → venous stasis
- Medullary veins enlarge as collateral drainage

Sturge-Weber Syndrome

- May develop strikingly enlarged medullary, subependymal, choroid plexus veins

https://CafePezeshki.IR

- Coexisting facial angioma

Venous Varix (Isolated)

- Occurs, but is rare without associated DVA

Demyelinating Disease

- Rare: Active, aggressive demyelination may have prominent medullary veins

PATHOLOGY

General Features

- Etiology
  - Does not express growth factors
  - Expresses structural proteins of mature angiogenesis
- Genetics
  - Approximately 50% inherited as autosomal dominant
  - Mutations in chromosome 9p
    - Segregates pedigrees with skin, oral and GI mucosa, brain venous malformations
- Associated abnormalities
  - 15-20% of those with DVAs have coexisting cavernous &/or capillary malformations
  - Blue rubber bleb nevus syndrome (BRBNS)
  - Sinus pericranii (cutaneous sign of underlying venous anomaly)
  - Sulcation-gyration disorders (may cause epilepsy)
  - Cervicofacial venous or lymphatic malformation (CAMS-3)
    - Embryology
      - Arrested medullary vein development at time when normal arterial development nearly complete
      - Developmental arrest results in persistence of large primitive embryonic deep white matter veins

Gross Pathologic & Surgical Features

- Radially oriented dilated medullary veins
- Venous radicals are separated by normal brain
- Enlarged transcortical or subependymal draining vein

Microscopic Features

- Dilated thin-walled vessels diffusely distributed in normal white matter (no gliosis)
- Occasional: Thickened, hyalinized vessel walls
- 20% have mixed histology (CM most common), may hemorrhage
- Variant: "Angiographically occult" DVA with malformed, compactly arranged vessels with partly degenerated walls

CLINICAL ISSUES

Presentation

- Most common signs/symptoms
  - Usually asymptomatic
  - Uncommon
    - Headache
    - Seizure (if associated with cortical dysplasia)
    - Hemorrhage with focal neurologic deficit (if associated with cavernous malformation or thrombosis)
- Clinical profile
  - Asymptomatic patient with DVA found incidentally on MR

Demographics

- Age
  - All ages
- Gender
  - M = F
- Ethnicity
  - No known predilection
- Epidemiology
  - Most common cerebral vascular malformation at autopsy
  - 60% of cerebral vascular malformations
  - 2.5-9% prevalence on contrast-enhanced MR scans

Natural History & Prognosis

- Hemorrhage risk: 0.15% per lesion per year
  - Stenosis or thrombosis of draining vein increases hemorrhage risk
  - Coexisting cavernous malformation increases hemorrhage risk

Treatment

- Solitary venous anomaly: None (attempt at removal may cause venous infarction)
- Histologically mixed venous anomaly: Determined by coexisting lesion

DIAGNOSTIC CHECKLIST

Consider

- DVAs contain (and provide main venous drainage for) intervening normal brain

Image Interpretation Pearls

- If you are not seeing 1 or 2 DVAs per month in usual outpatient setting, you are probably overlooking them
- If you are not doing much contrast-enhanced MR, you are probably missing incidental DVAs

SELECTED REFERENCES

1. Harrison G et al: Gamma Knife Stereotactic Radiosurgery for Trigeminal Neuralgia Caused by a Developmental Venous Anomaly. Stereotact Funct Neurosurg. 93(2):110-113, 2015
2. Agarwal A et al: Spontaneous thrombosis of developmental venous anomaly (DVA) with venous infarct and acute cerebellar ataxia. Emerg Radiol. 21(4):427-30, 2014
3. Horsch S et al: Developmental venous anomaly in the newborn brain. Neuroradiology. Epub ahead of print, 2014
4. Iv M et al: Association of developmental venous anomalies with perfusion abnormalities on arterial spin labeling and bolus perfusion-weighted imaging. J Neuroimaging. Epub ahead of print, 2014
5. Jung HN et al: Diffusion and perfusion MRI findings of the signal-intensity abnormalities of brain associated with developmental venous anomaly. AJNR Am J Neuroradiol. Epub ahead of print, 2014
6. Larvie M et al: Brain Metabolic Abnormalities Associated with Developmental Venous Anomalies. AJNR Am J Neuroradiol. ePub, 2014
7. Griffiths D et al: Thrombosis of a developmental venous anomaly causing venous infarction and pontine hemorrhage. J Stroke Cerebrovasc Dis. 22(8):e653-5, 2013

https://CafePezeshki.IR

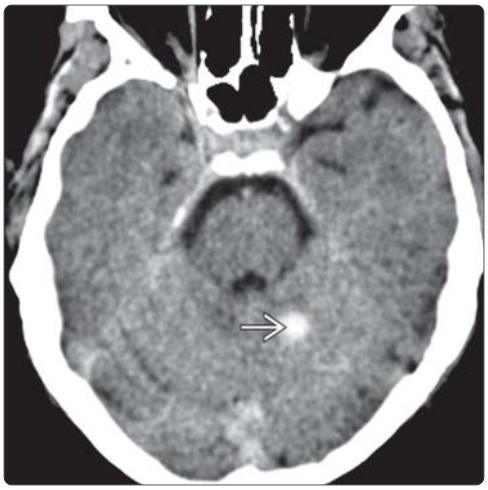

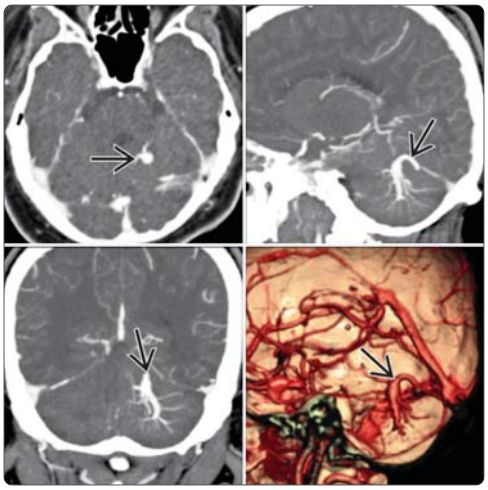

(Left) *Axial NECT shows a well-delineated hyperdensity in the left cerebellar hemisphere* ➡. **(Right)** *CTA with axial, sagittal, and coronal views and a 3D reconstruction in the same patient elegantly demonstrates the DVA* ⇨.

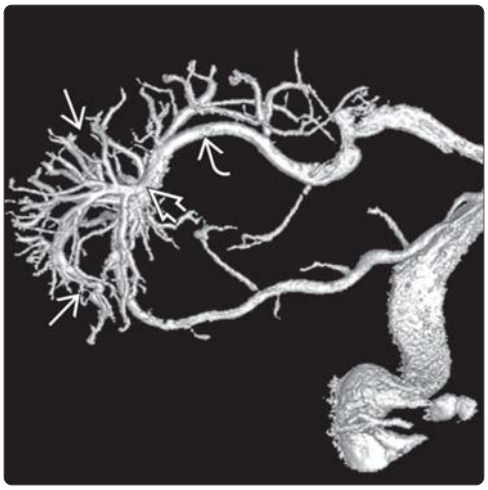

(Left) *Lateral 3D DSA rendered from the late venous phase of an internal carotid angiogram shows a large frontal DVA* ➡ *that drains into a septal tributary* ➡ *of the internal cerebral vein* ➡. *(Courtesy P. Lasjaunias, MD.)* **(Right)** *Anteroposterior 3D DSA shows a large right cerebellar DVA* ➡ *draining into an enlarged precentral cerebellar vein* ➡. *(Courtesy P. Lasjaunias, MD.)*

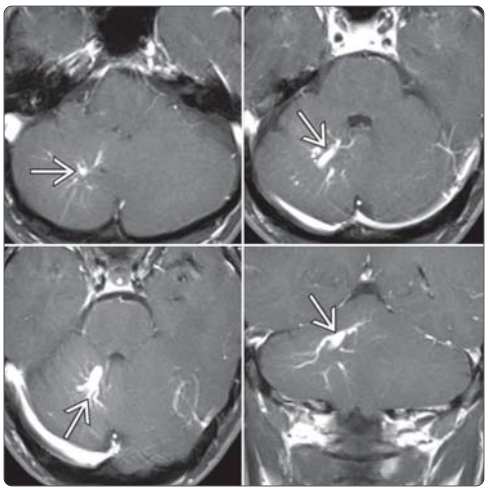

(Left) *Series of axial and coronal T1 C+ scans shows a large cerebellar DVA* ➡, *an incidental finding in this asymptomatic patient.* **(Right)** *AP DSA venous phase in the same patient shows the DVA with the "Medusa head"* ⇨ *of dilated veins and the large collector vein* ⇨.

https://CafePezeshki.IR

(Left) *DVAs can be associated with cortical dysplasia. Axial T2WI in a 32-year-old female with headaches shows left frontal cortical dysplasia adjacent to some prominent "flow voids".* **(Right)** *Axial T1 C+ FS in the same patient shows a giant left frontal venous angioma. The large tubular structure in the interhemispheric fissure is a large varix.*

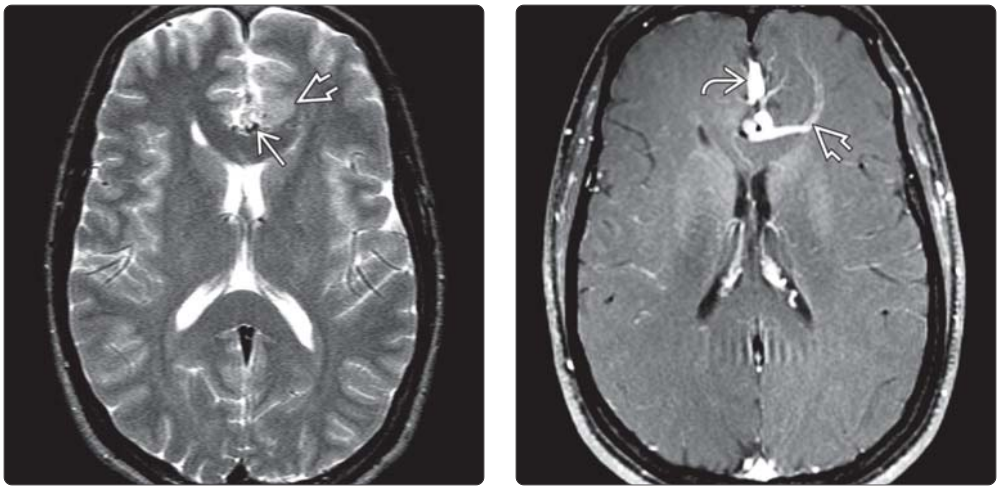

(Left) *Coronal T1 C+ MR in the same patient shows the large DVA draining into the interhemispheric varix.* **(Right)** *Sagittal T1 C+ MR in the same patient shows there are at least 2 large DVA "collector veins" draining into a large interhemispheric venous varix.*

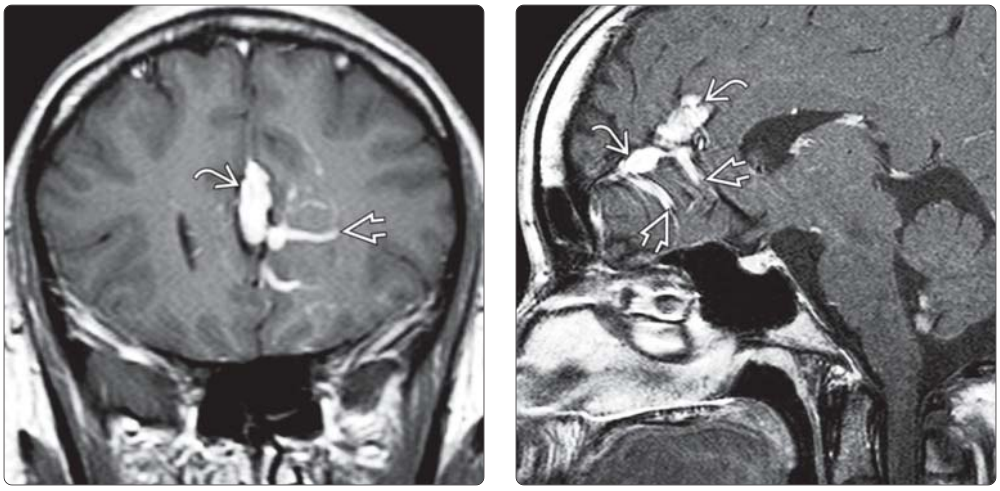

(Left) *Lateral DSA, early venous phase, in the same patient shows the enlarged medullary veins ("Medusa head") of the DVA. The large collector veins are beginning to fill with contrast.* **(Right)** *Late venous phase shows the giant varix draining the DVA empties into a markedly enlarged inferior sagittal sinus. The entire anterior third of the superior sagittal sinus is hypoplastic or absent, with the SSS originating near the coronal suture at the confluence of a prominent cortical vein.*

https://CafePezeshki.IR

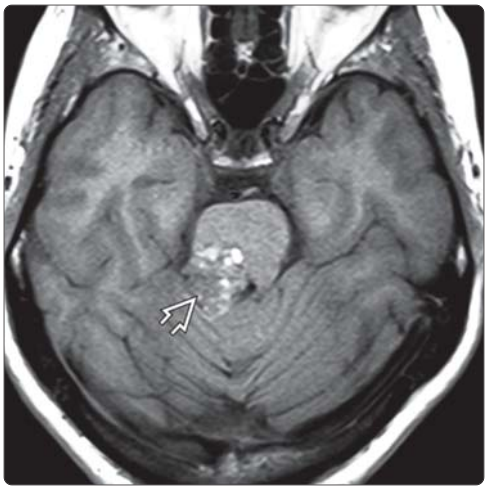

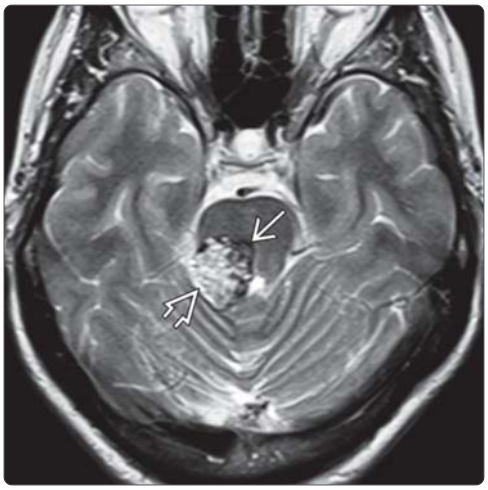

(Left) *Cerebral DVAs are frequently mixed with cavernous malformations. Axial T1WI shows a mixed signal intensity ("popcorn lesion") dorsally exophytic mass in the right midbrain* ➡. **(Right)** *T2WI in the same patient shows heterogeneous signal in the lesion* ➡, *which is surrounded by a very hypointense hemosiderin rim* ➡ *suggesting this is most likely a cavernous malformation.*

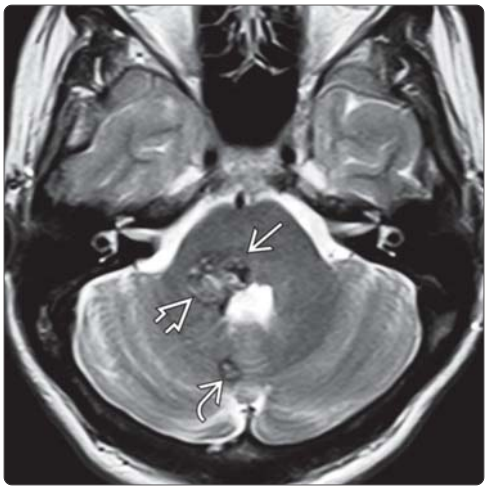

(Left) *More inferior T2WI in the same patient shows a second "popcorn ball" lesion* ➡ *posterior to the midbrain lesion, which extends inferiorly into the central pons and right cerebellar peduncle* ➡. *Faint linear hyperintensities* ➡ *can be seen lying in between the two lesions.* **(Right)** *T2* SWI shows both lesions* ⇨ *are profoundly hypointense. The linear intensities seen on the T2WI are also hypointense. The lesions represent hemorrhage, but the linear hypointensities* ⇨ *are deoxygenated blood in a DVA.*

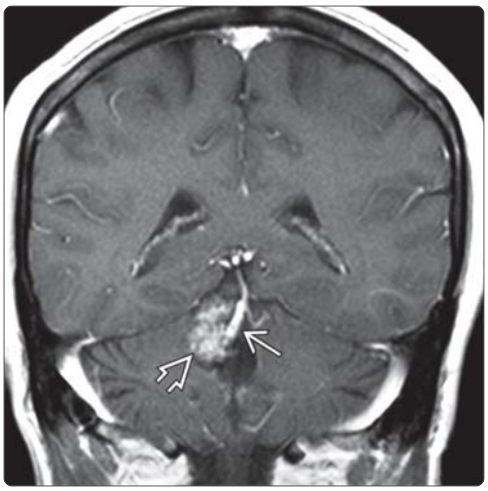

(Left) *T1 C+ FS scan shows strong foci of linear and tubular enhancement* ➡ *typical for a DVA.* **(Right)** *Coronal T1 C+ MR shows the cavernous malformation* ➡ *and the DVA* ➡. *A mixed cavernous-venous malformation is common. Surgeons need to be cognizant of the presence of a DVA to avoid ligating the collector vein and causing a venous infarct.*

https://CafePezeshki.IR

KEY FACTS

TERMINOLOGY

- Anomalous communication between intracranial dural venous sinus, extracranial venous circulation

IMAGING

- CTV, MRV delineates all vascular components of SP
  - Bone defect visualized on CT
  - 95% midline or parasagittal
    - Superior sagittal sinus most commonly involved

TOP DIFFERENTIAL DIAGNOSES

- Atretic cephalocele
  - Main DDx for SP is atretic cephalocele with herniated dural venous sinus (DVS)
- Dermoid cyst
- Hemangioma

CLINICAL ISSUES

- Child with long history of painless, reducible scalp mass
- Excellent prognosis following surgical removal
- Surgery contraindicated if sinus pericranii serves as major intracranial venous outflow or drains developmental venous anomaly (DVA)

DIAGNOSTIC CHECKLIST

- Describe contribution of sinus pericranii (SP) to IC venous drainage
- Assess for associated DVA, other congenital venous variants
- Entire DVS network must be evaluated prior to sinus pericranii removal (CTV/MRV)
- DSA may be required to delineate intracranial venous outflow, differentiate SP from atretic cephalocele with herniated DVS
  - 25% dominant (drain majority of intracranial venous outflow)
  - 75% accessory (drain only minority of outflow)

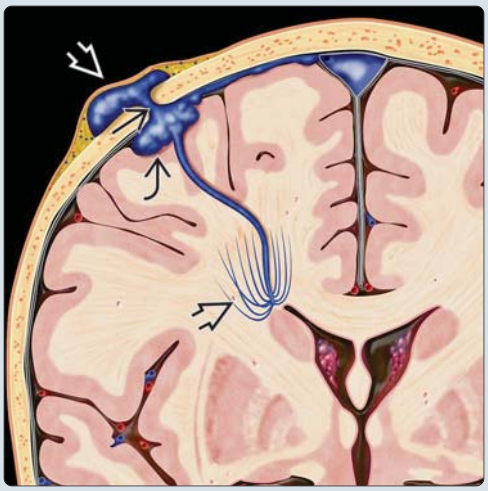

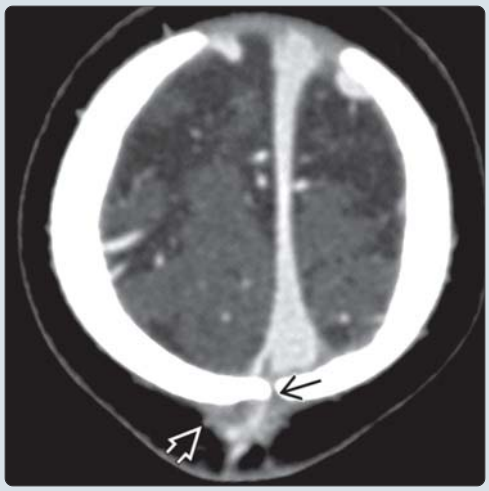

(Left) *Coronal graphic shows parasagittal sinus pericranii (SP). SP is composed of an intracranial varix ⇨, transosseous vein ⇨, and DVA ⇨, plus a scalp varix ➡. SPs are typically midline/paramedian scalp varices that communicate with the SSS via a transosseous vein &/or cortical vein.* **(Right)** *Axial CTV demonstrates a small SP, seen here as a calvarial defect ⇨ through which a scalp venous varix ➡ drains into the SSS. No associated intracranial anomalies are present.*

(Left) *Sagittal reformatted CTV from the same patient nicely shows the scalp varix ➡ communicating through a calvarial defect ⇨ with the underlying SSS.* **(Right)** *Late venous phase DSA in another patient shows a small DP with a venous varix ⇨ communicating with the SSS via a tiny transosseous vein ⇨. This is an accessory type SP.*

https://CafePezeshki.IR

TERMINOLOGY

Abbreviations

- Sinus pericranii (SP)

Definitions

- Anomalous communication between intracranial dural venous sinus (DVS), extracranial venous circulation

IMAGING

General Features

- Best diagnostic clue
  - Vascular scalp lesion communicating with underlying DVS
- Location
  - 95% midline/parasagittal
    - Frontal (40%), parietal (34%), occipital (23%), temporal (4%)
  - Superior sagittal sinus (SSS) most commonly involved
    - Transverse sinus, torcular Herophili uncommon
- Size
  - Scalp lesion: 1-13 cm; most 2-6 cm
  - Bone defect: 1-4 mm (large defect rare)
- Morphology
  - Extracranial component
    - Most common = variably sized venous varix
    - Single or multiple enlarged vein(s)
    - True scalp venous malformation (VM) or AVM rare
  - Intracranial component
    - Midline SP: Direct transosseous communication with SSS
    - Parasagittal SP: Prominent cortical/scalp vein(s) connects with DVS
    - ± associated developmental venous anomaly (DVA)

CT Findings

- NECT
  - Homogeneous soft tissue density scalp mass
    - Septations, cysts, phleboliths rare (usually with VM)
  - Bone algorithm
    - Single/multiple, well-defined bone defect(s)
    - Pressure erosion from overlying varix/VM
- CECT
  - Intense, well-delineated enhancement
    - Heterogeneous if thrombus present or VM
- CTV: Best for delineating vascular components

MR Findings

- T1WI
  - Most iso-, hypo-, or mixed iso-/hypointense
    - Hyperintense if subacute thrombus present
    - "Flow voids" if rapidly flowing varix/VM
- T2WI
  - Most hyperintense
    - Mixed signal in large varix/VM secondary to turbulent flow
    - Flow voids in rapidly flowing varix/VM
- T1WI C+
  - Intense, sharply demarcated enhancement
    - Heterogeneous if thrombus present
    - Peripheral/solid enhancement if VM
- MRV
  - Delineates all vascular components of SP

Ultrasonographic Findings

- Grayscale ultrasound
  - Hypoechoic scalp mass and transosseous feeder(s)
  - Shadowing from skull limits IC evaluation
- Color Doppler
  - Demonstrates direction of flow

Angiographic Findings

- Late venous phase delineates connection between DVS, extracranial veins

Other Modality Findings

- Percutaneous venography (PV)
  - Visualization of scalp veins
  - Visualization of transosseous vein, DVS inconstant

Imaging Recommendations

- Best imaging tool
  - CTV, T1C+ MR/MRV
    - Both suitable for delineation of SP, associated intracranial anomalies
    - Bone defect best visualized on CT
- Protocol advice
  - DSA may be required to assess intracranial venous drainage preoperatively

DIFFERENTIAL DIAGNOSIS

Atretic Encephalocele

- Small herniation of IC contents through skull defect
- No enhancement unless vessels/DVS also herniate
- May be difficult to distinguish from SP on MR alone

Dermoid Cyst

- Well-defined fluid or fat density lesion
- Anterior fontanelle/bregma location classic

Hemangioma

- Intensely enhancing mass with flow voids
- Characteristic evolution

Rhabdomyosarcoma, Langerhans Cell Histiocytosis, Neuroblastoma Metastases

- Enhancing, destructive mass
- Invasion of DVS appears as filling defect

PATHOLOGY

General Features

- Etiology
  - Majority congenital
    - Probable anomalous venous development during late embryogenesis
    - Incomplete sutural fusion over prominent/abundant diploic or emissary veins
    - In utero DVS thrombosis
  - Traumatic
    - Disruption of emissary veins at outer table
    - Laceration or DVS thrombosis

https://CafePezeshki.IR

- Spontaneous
  - Secondary to remote, "forgotten" trauma
  - Subclinical, postnatal DVS thrombosis
- Associated abnormalities
  - DVA
  - Systemic venous malformations
  - Blue rubber bleb nevus syndrome
  - Multisutural craniosynostosis
    - SP forms secondary to DVS/internal jugular vein hypoplasia/atresia or IC hypertension
  - Isolated reports of cutis aplasia congenita

Staging, Grading, & Classification

- Based on intracranial venous outflow
  - 25% dominant (drain majority of intracranial venous outflow)
  - 75% accessory (drain only minority of outflow)

Gross Pathologic & Surgical Features

- Scalp varix/VM: Bluish, blood-filled sac or network of sacs beneath > above calvarial periosteum

Microscopic Features

- Scalp varix/VM: Nonmuscular venous channel(s)
  - Endothelial lining = congenital origin
  - Fibrous lining/capsule = traumatic origin
  - ± hemosiderin-laden macrophages, thrombus

CLINICAL ISSUES

Presentation

- Most common signs/symptoms
  - Painless nonpulsatile forehead/scalp mass (10% bluish discoloration)
    - Reduces in upright position
    - Distends when prone, with Valsalva, or crying
  - Rare: Pain, headache, nausea, dizziness
- Clinical profile
  - Child with long history of painless, reducible scalp mass

Demographics

- Age
  - Range: 0-70 years
    - Usually discovered in children, young adults
- Gender
  - Slight female predominance
- Epidemiology
  - Rare
    - 11% of patients presenting for treatment of craniofacial VMs

Natural History & Prognosis

- Not clearly understood
  - Usually stable, benign; rare spontaneous regression
  - Potential lifetime risk of hemorrhage, air embolus if SP injured is unknown
- Prognosis excellent following surgical removal

Treatment

- Evaluate entire DVS network to ensure feasibility of SP removal
  - Surgery contraindicated if SP is dominant type
- Surgery
  - Ligation of transosseous emissary vein(s), removal of scalp lesion, closure of bone hole(s) with bone wax
- Endovascular therapy
  - Suitable for accessory SP
  - Transvenous or direct percutaneous embolization (coils, glue)

DIAGNOSTIC CHECKLIST

Consider

- Blue rubber bleb nevus syndrome if SP associated with multiple intracranial DVAs

Image Interpretation Pearls

- Assess for associated intracranial venous anomalies (DVA), congenital venous variants
- Entire DVS network must be evaluated prior to sinus pericranii removal
- Diagnostic imaging appearance characteristic
  - Unless thrombosed, main DDx is cephalocele with herniated DVS

Reporting Tips

- Describe contribution of SP to IC venous drainage

SELECTED REFERENCES

1. Pavanello M et al: Sinus pericranii: diagnosis and management in 21 pediatric patients. J Neurosurg Pediatr. 15(1):60-70, 2015
2. Saba R et al: Sinus pericranii in a young adult with chronic headache. BMJ Case Rep. 2013, 2013
3. Akram H et al: Sinus pericranii: an overview and literature review of a rare cranial venous anomaly (a review of the existing literature with case examples). Neurosurg Rev. 35(1):15-26; discussion 26, 2012
4. Kanavaki A et al: Sinus pericranii: a scalp mass in a 6-month-old boy. Pediatr Neurosurg. 48(2):126-8, 2012
5. Kim YJ et al: Sonographic features of sinus pericranii in 4 pediatric patients. J Ultrasound Med. 2011 Mar;30(3):411-7. Erratum in: J Ultrasound Med. 30(5):684, 2011
6. Rozen WM et al: Spontaneous involution of two sinus pericranii - a unique case and review of the literature. J Clin Neurosci. 15(7):833-5, 2008
7. Gandolfo C et al: Sinus pericranii: diagnostic and therapeutic considerations in 15 patients. Neuroradiology. 49(6):505-14, 2007
8. Nomura S et al: Association of intra- and extradural developmental venous anomalies, so-called venous angioma and sinus pericranii. Childs Nerv Syst. 22(4):428-31, 2006

https://CafePezeshki.IR

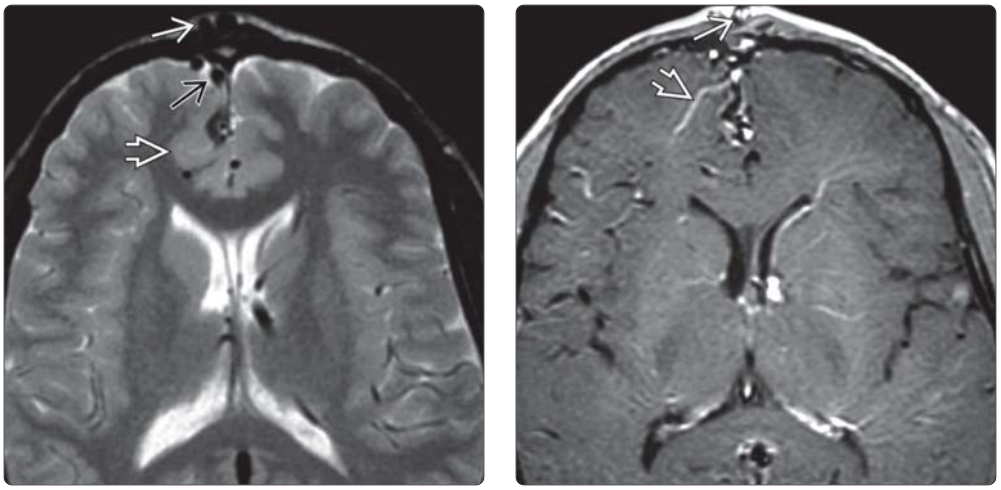

(Left) *Axial T2WI shows frontal soft tissue scalp mass ➡. Note prominent "flow voids" ⇨ associated with cortical dysplasia ➡ in the underlying brain.* **(Right)** *Axial T1 C+ MR in the same patient shows enhancing vascular channels ➡ in the scalp mass and underlying brain ➡.*

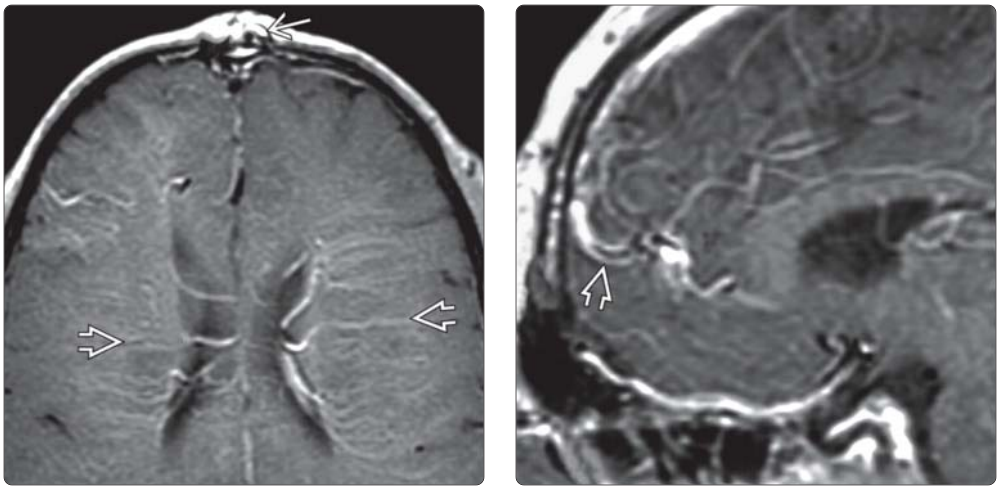

(Left) *More cephalad T1 C+ scan in the same patient shows tubular enhancing structures in the scalp mass ➡, as well as very prominent medullary veins ➡ in the white matter of both hemispheres.* **(Right)** *Sagittal T1 C+ scan in the same patient shows prominent vein ➡ draining towards the frontal scalp mass.*

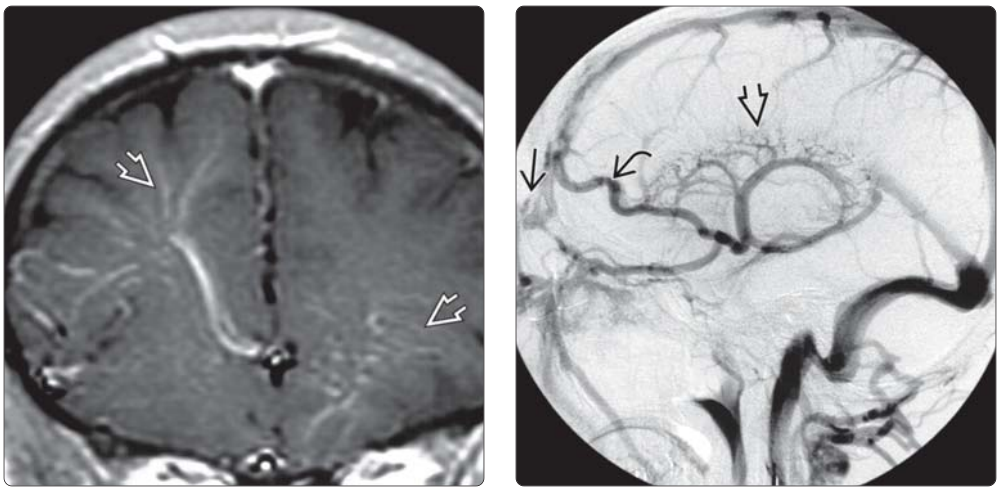

(Left) *Coronal T1 C+ scan in the same patient shows bilateral developmental venous anomalies ➡.* **(Right)** *DSA, lateral view, venous phase, shows a huge DVA ⇨ and a large draining vein ⇨ that communicates with the SP ⇨. This is a dominant type SP. (Courtesy J. Rees, MD.)*

https://CafePezeshki.IR

KEY FACTS

TERMINOLOGY

- Cavernous malformation (CM)
- Benign vascular hamartoma
  - Contains masses of closely apposed immature blood vessels ("caverns"), no neural tissue
  - Intralesional hemorrhages of different ages

IMAGING

- General: Locules of variable size with blood at different stages of evolution
  - Variable appearance depending on hemorrhage/stage
  - CMs vary from microscopic to giant (> 6 cm)
- Classic MR: "Popcorn ball" appearance with complete hypointense hemosiderin rim on T2WI MR
- DSA: Usually normal ("angiographically occult vascular malformation") unless mixed with DVA
- Zabramski classification of CMs
  - Type 1 = subacute hemorrhage (may obscure underlying CM)
  - Type 2 = mixed signal intensity on T1, T2WI (classic "popcorn ball" lesion)
  - Type 3 = chronic hemorrhage (hypo- to isointense on T1, T2WI)
  - Type 4 = punctate microhemorrhages (blooming "black spots" on T2*)

TOP DIFFERENTIAL DIAGNOSES

- Arteriovenous malformation
- Hemorrhagic neoplasm
- Calcified neoplasm
- Hypertensive microbleeds
- Amyloid angiopathy

CLINICAL ISSUES

- Variable behavior (enlarge, regress, form de novo)
- All ages (peak = 40-60 years)

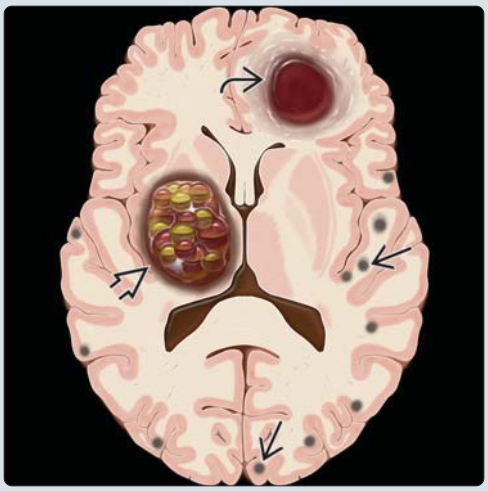

(Left) *Axial graphic depicts various stages of cavernous malformations with subacute hemorrhage ⇨ and classic "popcorn ball" ⇨ lesion with multiple blood-filled locules, surrounding hemosiderin rim. Multifocal "blooming black dots" ⇨ are also depicted.* **(Right)** *Axial NECT scan shows a mixed density right thalamic mass with edema. Note fluid-fluid level ➡ within the mass.*

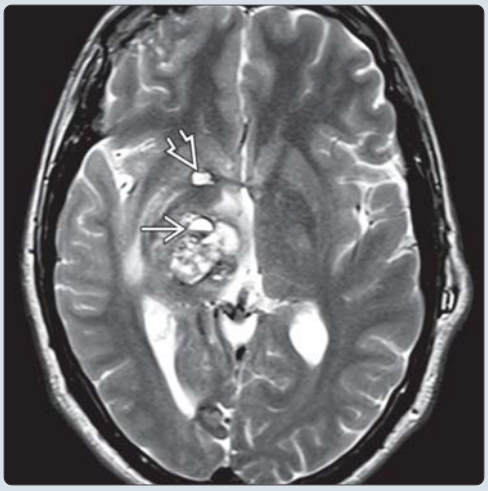

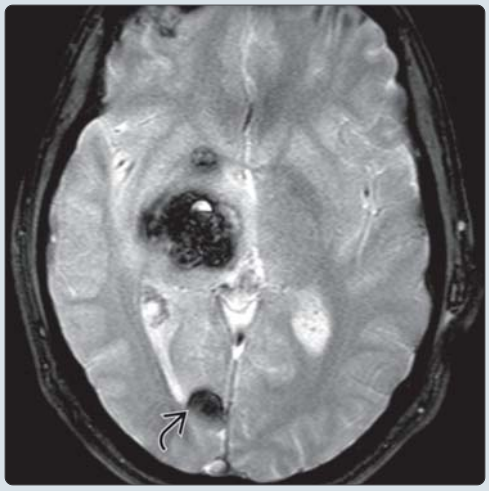

(Left) *Axial T2WI in the same case shows the classic "popcorn ball" appearance of a CM with multiple fluid-filled locules ➡. A second, separate lesion is also present ➡.* **(Right)** *T2* GRE scan in the same case shows striking "blooming" in and around the two lesions. A third lesion ⇨ in the right occipital lobe is present but was difficult to see on the standard FSE T2-weighted sequence.*

https://CafePezeshki.IR

TERMINOLOGY

Abbreviations

- Cavernous malformation (CM)

Synonyms

- Cavernoma

Definitions

- Benign vascular hamartoma with intralesional hemorrhages, no neural tissue
  - Contains masses of closely apposed immature blood vessels ("caverns")
  - Intralesional hemorrhages of different ages
- CMs exhibit range of dynamic behaviors (enlargement, regression, de novo formation)

IMAGING

General Features

- Best diagnostic clue
  - "Popcorn ball" appearance with complete hypointense hemosiderin rim on T2WI MR
- Location
  - Cavernous malformations can occur anywhere in body
  - Brain most common site
    - Hemispheres > brainstem, cerebellum
  - Spinal cord is rare (more common in patients with multiple CM syndrome)
- Size
  - CMs vary from microscopic to giant (> 6 cm)
  - Majority are 0.5-4 cm
- Morphology
  - Discrete, lobulated mass of interwoven vessels
  - Locules of variable size contain blood products at different stages of evolution

CT Findings

- NECT
  - Negative in 30-50%
  - Well-delineated round/ovoid hyperdense lesion, usually < 3 cm
    - 40-60% Ca++
    - No mass effect unless recent hemorrhage
  - Surrounding brain usually appears normal
- CECT
  - Little/no enhancement unless mixed with other lesion (e.g., developmental venous anomaly [DVA])
- CTA
  - Usually negative

MR Findings

- T1WI
  - Variable, depending on hemorrhage/stage
    - Common: "Popcorn ball" appearance of mixed hyper-, hypointense blood-containing locules
    - Less common: Acute hemorrhage (nonspecific)
  - T1 perilesional hyperintensity common
    - Helps differentiate CM from other hemorrhagic masses
- T2WI
  - Reticulated popcorn-like lesion is most typical
    - Mixed signal core, complete hypointense hemosiderin rim
    - Locules of blood with fluid-fluid levels
  - Less common: Hypointense
- FLAIR
  - May show surrounding edema in acute lesions
- T2* GRE
  - Prominent susceptibility effect (hypointense "blooming")
  - Multiple CMs: Numerous punctate hypointense foci ("black dots") on GRE scans are most common finding
    - SWI much more sensitive than GRE
- DWI
  - Susceptibility effects seen; surrounding brain is usually normal
- T1WI C+
  - Minimal or no enhancement (may show associated venous malformation)
- MRA
  - Normal (unless mixed malformation present)
  - Large acute hemorrhage may obscure more typical features of CM

Angiographic Findings

- Conventional
  - DSA
    - Usually normal ("angiographically occult vascular malformation")
    - Slow intralesional flow without AV shunting
    - Avascular mass effect if large or acute hemorrhage
    - ± other associated malformation (e.g., DVA)
    - Rare: Venous pooling, contrast "blush"

Imaging Recommendations

- Best imaging tool
  - MR
    - Standard T1, T2WI may be negative in small type 4 lesions
    - Use T2* sequence (SWI > GRE)
- Protocol advice
  - Use T2* GRE sequence with long TE (35 msec)
  - Include T1 C+ to look for associated anomalies (e.g., DVA)

DIFFERENTIAL DIAGNOSIS

"Popcorn Ball" Lesion

- Arteriovenous malformation
- Hemorrhagic neoplasm
- Calcified neoplasm

Multiple "Black Dots"

- Old trauma (diffuse axonal injury [DAI], contusions)
- Hypertensive microbleeds
- Amyloid angiopathy
- Capillary telangiectasias
- Rare: Fat emboli, thrombotic microangiopathy, pneumocephalus

PATHOLOGY

General Features

- Etiology

https://CafePezeshki.IR

- CMs are angiogenically immature lesions with endothelial proliferation, increased neoangiogenesis
- VEGF, β-FGF, TGF-α expressed

- Genetics
  - Sporadic CM
    - No *KRIT1* mutation
    - *PTEN* promoter methylation mutation common (also in familial CM syndrome)
  - Multiple (familial) CM syndrome is autosomal dominant, variable penetrance
    - 3 separate loci implicated: *KRIT1/CCM1*, *MGC4607/CCM2*, *PDCD10/CCM3* genes
      - KRIT1/CCM1 65-70%
      - MGC4607/CCM2 18%
      - PDCD10/CCM3 10-15%
- Associated abnormalities
  - Developmental venous anomaly (most common mixed vascular malformation)
  - Superficial siderosis
  - More T2/FLAIR WM hyperintensities in familial CMs

Staging, Grading, & Classification

- Zabramski classification of CMs
  - Type 1 = subacute hemorrhage (hyperintense on T1WI; hyper- or hypointense on T2WI)
  - Type 2 = mixed signal intensity on T1WI, T2WI with degrading hemorrhage of various ages (classic "popcorn ball" lesion)
  - Type 3 = chronic hemorrhage (hypo- to isointense on T1WI, T2WI)
  - Type 4 = punctate microhemorrhages ("black dots"), poorly seen except on GRE sequences

Gross Pathologic & Surgical Features

- Discrete, lobulated, bluish-purple (mulberry-like) nodule

Microscopic Features

- Angioarchitecture
  - "Bland" regions within thin-walled caverns
  - "Honeycombed" regions with notable capillary proliferation
- Thin-walled epithelial-lined spaces
  - Hemorrhage in different stages of evolution
  - Does not contain normal brain tissue

CLINICAL ISSUES

Presentation

- Most common signs/symptoms
  - Seizure (50%)
  - Neurologic deficit (25%) (may be progressive)
  - Asymptomatic (20%)

Demographics

- Age
  - Peak presentation: 40-60 years
    - May present in childhood
  - Familial CMs tend to present earlier than sporadic lesions
- Ethnicity
  - Multiple (familial) CM syndrome in Hispanic Americans of Mexican descent
    - Founder mutation in *KRIT1* (Q445X)
    - Positive family history = 90% chance of mutation resulting in CM
  - CMs may occur in any ethnic population
- Epidemiology
  - Most common angiographically "occult" vascular malformation
  - Approximate prevalence: 0.5%
    - 2/3 occur as solitary, sporadic lesion
    - 1/3 are multiple, familial

Natural History & Prognosis

- Broad range of dynamic behavior (may progress, enlarge, regress)
  - "Black spot" lesions mean bleeding rate 0.7% per lesion-year
- De novo lesions may develop
  - Therapeutic radiation may be "accelerator" of lesion formation
- Propensity for growth via repeated intralesional hemorrhages
  - Sporadic = 0.25-0.7% per year
  - Risk factor for future hemorrhage = previous hemorrhage
  - Rehemorrhage rate is initially high but decreases after 2-3 years
- Familial CMs at especially high risk for hemorrhage, forming new lesions
  - Estimated 1% per lesion per year

DIAGNOSTIC CHECKLIST

Consider

- Perform T2* scan to look for additional lesions in patients with spontaneous intracranial hemorrhage

SELECTED REFERENCES

1. Golden MJ et al: Increased Number of White Matter Lesions in Patients with Familial Cerebral Cavernous Malformations. AJNR Am J Neuroradiol. ePub, 2015
2. Golden M et al: Sensitivity of patients with familial cerebral cavernous malformations to therapeutic radiation. J Med Imaging Radiat Oncol. ePub, 2015
3. Qiao N et al: A systematic review and meta-analysis of surgeries performed for treating deep-seated cerebral cavernous malformations. Br J Neurosurg. 1-7, 2015
4. Cigoli MS et al: PDCD10 gene mutations in multiple cerebral cavernous malformations. PLoS One. 9(10):e110438, 2014
5. Meng G et al: The association between cerebral developmental venous anomaly and concomitant cavernous malformation: an observational study using magnetic resonance imaging. BMC Neurol. 14:50, 2014
6. Mikati AG et al: Dynamic permeability and quantitative susceptibility: related imaging biomarkers in cerebral cavernous malformations. Stroke. 45(2):598-601, 2014
7. Moore SA et al: Long-term natural history of incidentally discovered cavernous malformations in a single-center cohort. J Neurosurg. 120(5):1188-92, 2014
8. Nikoubashman O et al: Natural history of cerebral dot-like cavernomas. Clin Radiol. 68(8):e453-9, 2013
9. Al-Holou WN et al: Natural history and imaging prevalence of cavernous malformations in children and young adults. J Neurosurg Pediatr. 9(2):198-205, 2012

https://CafePezeshki.IR

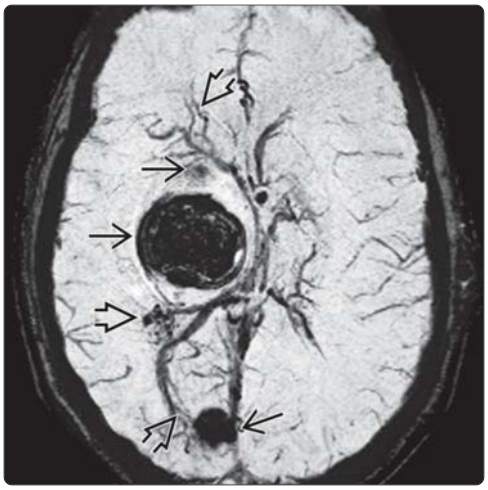

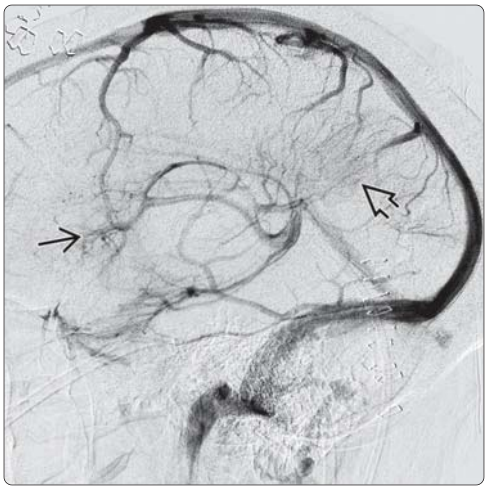

(Left) *Axial T2* SWI in the same patient shows prominent venous ⇨ channels around three CMs ⇨.* **(Right)** *Lateral DSA, venous phase, in the same case shows the hypointense structures seen on the SWI are prominent veins ⇨. Note classic "medusa head" ⇨ of developmental venous anomaly (DVA). Cavernous and venous malformations are the most common mixed vascular malformation.*

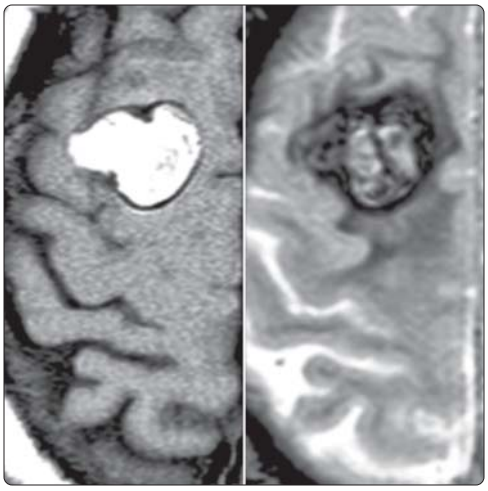

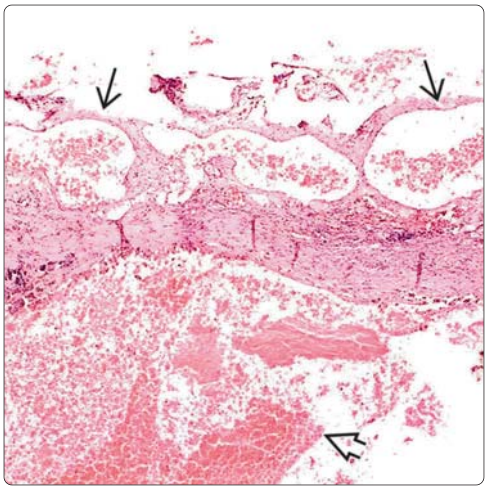

(Left) *Axial T1WI MR (left) and T2* GRE scan (right) in a 49-year-old woman with a 4-month history of convulsions shows a right frontoparietal lesion with subacute hemorrhage.* **(Right)** *Micropathology H&E from a resected surgical specimen in the same patient shows a cavity filled with clotted blood undergoing patchy organization ⇨. The wall consists of thin, endothelial-lined vascular channels ⇨. Diagnosis was classic cavernous malformation, Zabramski type 1. (Courtesy R. Hewlett, MD.)*

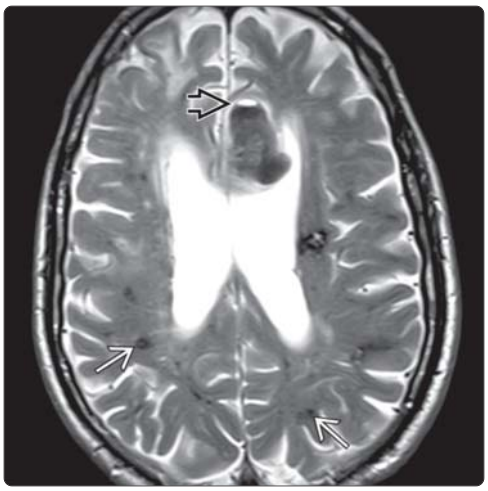

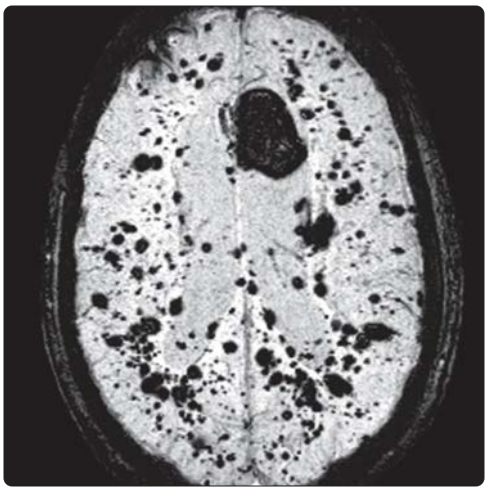

(Left) *FSEnT2WI in a patient with multiple cerebral cavernous malformations shows a large left frontal lesion with a fluid-fluid level ⇨. Multiple other hypointense lesions ➡ are present in both hemispheres.* **(Right)** *T2* SWI MIP image in the same case shows innumerable "blooming black dots" characteristic of Zabramski type 4 CM (punctate microbleeds). T2* scans are much more sensitive than FSE T2WIs in depicting field inhomogeneities with SWI more sensitive than GRE.*

https://CafePezeshki.IR

KEY FACTS

TERMINOLOGY

- Brain capillary telangiectasia (BCT)
- Cluster of enlarged, dilated capillaries interspersed with normal brain parenchyma

IMAGING

- General features
  - Common sites: Pons, cerebellum, spinal cord
  - Usually < 1 cm
- CT
  - Usually normal
- MR
  - T1WI usually normal
  - T2WI
    - 50% normal on T2WI
    - 50% show faint stippled foci of hyperintensity
  - Large BCTs may show ill-defined FLAIR hyperintensity
  - Moderately hypointense on GRE; profoundly hypointense on SWI
  - T1 C+ shows faint stippled or speckled brush-like enhancement
  - Large BCTs typically contain prominent linear draining vein(s)

TOP DIFFERENTIAL DIAGNOSES

- Developmental venous anomaly
- Metastasis
- Cavernous malformation
- Capillary hemangioma

CLINICAL ISSUES

- BCTs represent 15-20% of all intracranial vascular malformations
- Usually found incidentally at autopsy or imaging
- Rare: Headache, vertigo, tinnitus
- Clinically benign, quiescent
  - Unless histologically mixed (usually with CM)

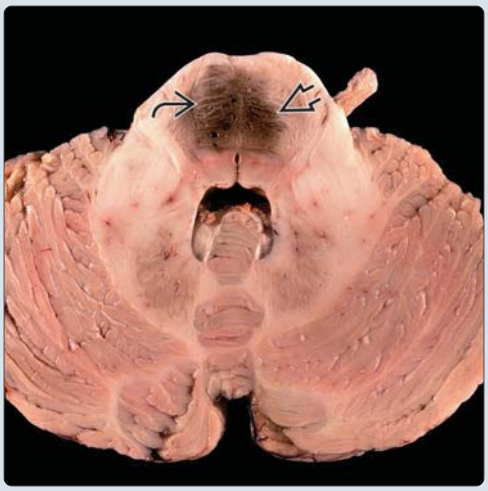

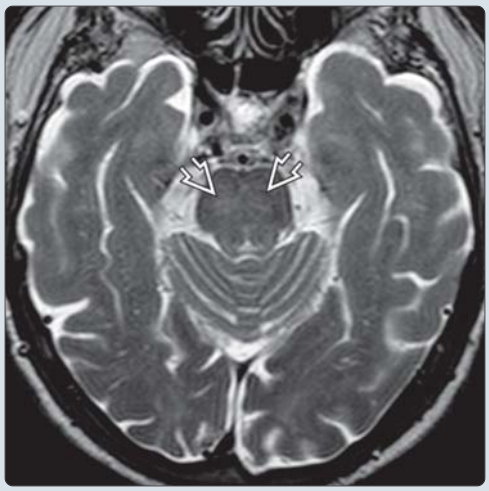

(Left) *Axial gross pathology shows a large capillary telangiectasia of the pons. The dusky color is caused by deoxygenated blood, not frank hemorrhage. Note undisturbed transverse pontine tracts crossing the telangiectasia.* **(Right)** *Axial T2WI in a neurologically normal patient with headaches shows very faint "stippled" hyperintensities in the central pons.*

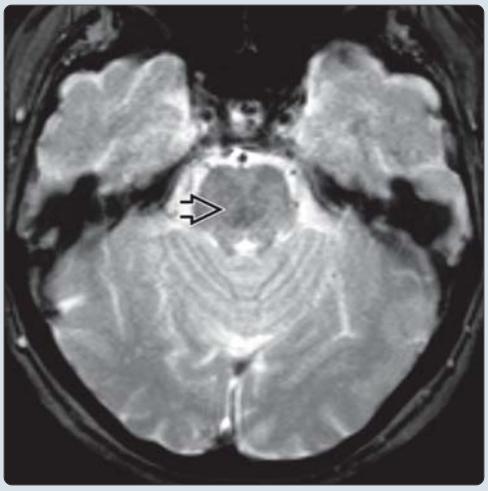

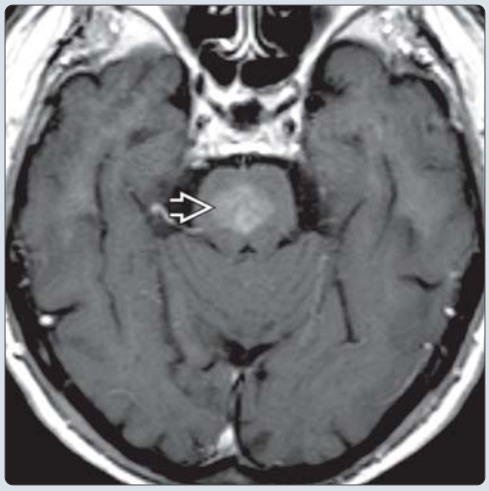

(Left) *Axial T2* GRE in the same patient shows faint hypointensity in the central pons.* **(Right)** *Axial T1 C+ MR in the same patient shows faint brush-like enhancement in the central pons, characteristic of a large capillary telangiectasia. (Courtesy P. Rodriguez, MD.)*

https://CafePezeshki.IR

TERMINOLOGY

Abbreviations

- Brain capillary telangiectasia (BCT)
- Cerebrovascular malformation (CVM)

Synonyms

- Capillary malformation
- **Not** capillary "hemangioma"
  - Hemangiomas are true benign vasoformative neoplasms
  - Usually in face, scalp, back, chest, orbit
  - Less common: Dura, venous sinuses
  - Exceptionally rare in brain parenchyma

Definitions

- Cluster of enlarged, thin-walled capillaries surrounded and separated by normal brain (usually WM)

IMAGING

General Features

- Best diagnostic clue
  - Hypointense lesion on T2* with faint brush-like enhancement
- Location
  - Can be found anywhere
  - Most common sites
    - Pons
    - Cerebellum
    - Medulla
    - Spinal cord
  - Up to 1/3 in cerebral hemispheres
    - White matter
    - Cortex
- Size
  - Usually < 1 cm
  - Occasionally "giant" (> 1 cm)
  - Solitary > > multiple
- Morphology
  - Small, poorly marginated
  - No mass effect
  - No edema

CT Findings

- NECT
  - Usually normal
  - Occasionally may show Ca++
    - Usually only if mixed histology (most commonly cavernous malformation)
- CECT
  - Usually normal

MR Findings

- T1WI
  - Usually normal
  - May be hyperintense or hypo-/hyperintense ("popcorn" appearance) if mixed with CM
- T2WI
  - 50% normal
  - 50% show faint stippled foci of hyperintensity
- FLAIR
  - Usually normal
  - If large, may show ill-defined hyperintensity
  - No mass effect, edema
- T2* GRE
  - GRE
    - Lesion moderately hypointense
      - **Not** hemorrhage (unless mixed with CM)
      - Sluggish blood flow allows oxy- → deoxyhemoglobin
    - Occasionally multifocal BCTs seen as black or gray "dots," if mixed with CMs
  - SWI
    - SWI even more sensitive than standard T2*GRE
    - Lesion may be profoundly hypointense
- DWI
  - Usually normal
- PWI
  - Shows profound drop in signal intensity with relatively rapid recovery to baseline
- T1WI C+
  - Faint stippled or mild speckled brush-like enhancement
    - May have enlarged central draining vein with prominent linear enhancement
  - Large BCTs
    - Usually contain punctate, linear/branching vessel(s)
      - Represent radicles of draining veins
      - Larger "collector" vein often present
    - Mixed BCT, developmental venous anomaly (DVA) common
- DTI
  - BCTs are interspersed with normal WM tracts
  - No alteration of FA
  - No disturbance/displacement of WM tracts

Angiographic Findings

- Conventional
  - Usually normal
  - Faint vascular "stain" ± draining vein
  - Look for associated DVA

Imaging Recommendations

- Best imaging tool
  - MR with T2*, T1 C+ sequences
- Protocol advice
  - Include SWI

DIFFERENTIAL DIAGNOSIS

Developmental Venous Anomaly (DVA)

- Often mixed with BCT

Metastasis

- Strong > > faint enhancement
- Pons/cerebellum rare locations

Cavernous Malformation

- Blood locules with fluid-fluid levels
- Complete hemosiderin rim
- Can be mixed with BCTs, cause hemorrhage

Capillary Hemangioma

- Vasoformative neoplasms, not congenital CVMs

https://CafePezeshki.IR

- Dura, venous sinuses > > brain parenchyma

PATHOLOGY

General Features

- Etiology
  - Precise etiology of sporadic BCTs unknown
  - May develop as complication of radiation
    - 20% of children after whole brain irradiation
- Genetics
  - May be related to mutated *SLPI*
    - ↑ perfusion → upregulated VEGF → ↑ capillary dysplasia
  - Capillary density increases with nonischemic venous hypertension
    - Hypoxia-inducible factor-1-α (HIF-1-α), downstream target VEGF upregulated
- Associated abnormalities
  - Often mixed with other vascular malformations (cavernous, venous)
  - Hereditary hemorrhagic telangiectasia
    - a.k.a. Osler-Weber-Rendu disease
    - Autosomal dominant disorder
    - Often complicated by vascular malformations in brain, lung, GI tract, liver
      - Brain capillary vasculary malformations most common phenotype in HHT
      - CTs also common in nasal mucosa (epistaxis, hemoptysis may be life threatening)
      - No correlation between HHT gene mutation, lesion type, or number
    - HHT-associated strokes usually secondary to pulmonary AVM/AV, brain AVM with bleed, SAH with saccular aneurysm
  - Macrocephaly capillary malformation (MCM) syndromes
    - a.k.a. macrocephaly-cutis marmorata telangiectatica congenita (M-CMTC)
      - Facial nevus flammeus, cutis marmorata
    - Rapid brain growth during infancy
      - Megalencephaly, polymicrogyria
      - Tonsillar herniation
      - Ventriculomegaly, dilated dural venous sinuses
      - Prominent perivascular spaces (PVSs)
      - Skin > > brain capillary malformations

Gross Pathologic & Surgical Features

- Most BCTs found incidentally
  - Large BCTs may appear pinkish or slightly dusky
  - No hemorrhage unless other vascular malformation (e.g., CM) present

Microscopic Features

- Cluster of dilated, but histologically normal capillaries
  - Thin-walled, endothelial-lined vascular channels
  - Largest channels may represent draining veins
- Normal brain interspersed between dilated capillaries
- Uncomplicated BCTs have no surrounding gliosis, hemorrhage, Ca++

CLINICAL ISSUES

Presentation

- Most common signs/symptoms
  - Usually found incidentally at autopsy or imaging
  - Rare: Headache, vertigo, tinnitus
- Clinical profile
  - Asymptomatic, middle-aged patient with poorly delineated, enhancing brainstem lesion

Demographics

- Age
  - Any; 30-40 years most common
  - Rarely identified in children, but does occur
- Epidemiology
  - 15-20% of all intracranial vascular malformations
  - Most common vascular malformation in HHT

Natural History & Prognosis

- Clinically benign, quiescent unless histologically mixed
- Rare reports of aggressive course

Treatment

- None

DIAGNOSTIC CHECKLIST

Image Interpretation Pearls

- Faintly enhancing pontine lesion that becomes moderately hypointense on T2* is usually BCT

SELECTED REFERENCES

1. Andrade CS et al: Giant symptomatic capillary telangiectasia of the brain. Arq Neuropsiquiatr. 73(1):66-7, 2015
2. Krings T et al: Neurovascular Manifestations in Hereditary Hemorrhagic Telangiectasia: Imaging Features and Genotype-Phenotype Correlations. AJNR Am J Neuroradiol. ePub, 2015
3. Chaudhry US et al: Susceptibility-Weighted MR Imaging: A Better Technique in the Detection of Capillary Telangiectasia Compared with T2* Gradient-Echo. AJNR Am J Neuroradiol. 35(12):2302-5, 2014
4. Gelal F et al: Capillary telangiectasia of the brain: imaging with various magnetic resonance techniques. JBR-BTR. 97(4):233-8, 2014
5. Gross BA et al: Cerebral capillary telangiectasias: a meta-analysis and review of the literature. Neurosurg Rev. 36(2):187-93; discussion 194, 2013
6. El-Koussy M et al: Susceptibility-weighted MR imaging for diagnosis of capillary telangiectasia of the brain. AJNR Am J Neuroradiol. 33(4):715-20, 2012
7. Ozcan HN et al: MRI findings in giant pontine capillary telangiectasis associated with a developmental venous anomaly. JBR-BTR. 94(5):293-4, 2011

https://CafePezeshki.IR

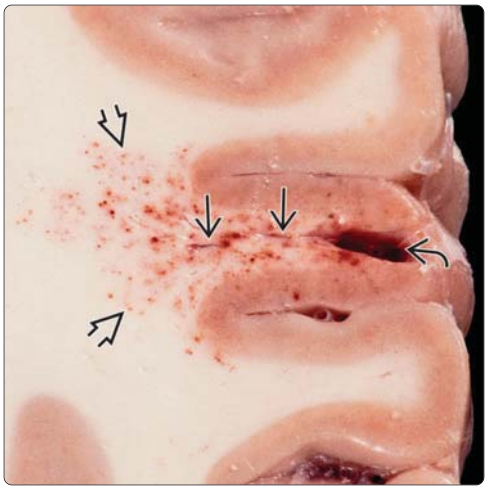

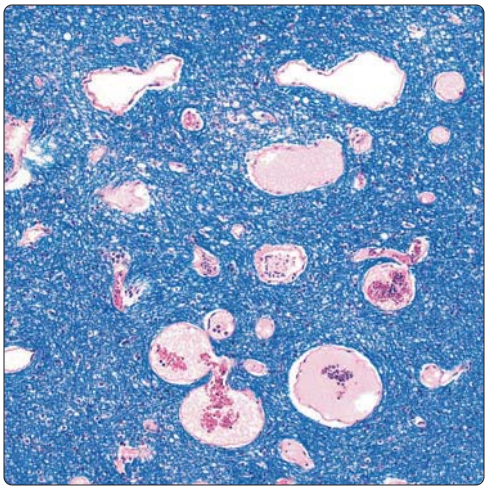

(Left) *Gross pathology shows a typical capillary hemangioma. Note normal-appearing white matter interspersed between the dilated capillaries. Many capillary telangiectasias have a prominent central vein that drains into a cortical vein.* **(Right)** *Luxol fast blue microscopic pathology in the same patient shows normal white matter (blue-stained tissue) between the dilated, but histologically normal, capillaries. (Courtesy P. Burger, MD.)*

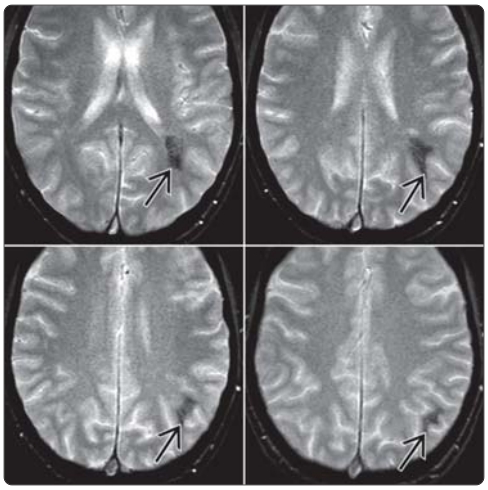

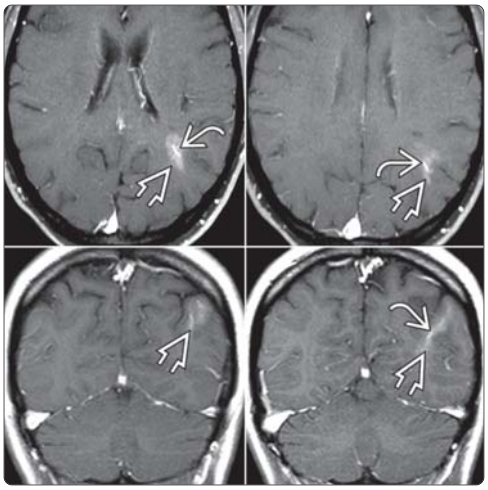

(Left) *Collage of 4 axial T2* GRE scans in an asymptomatic patient show a focal wedge-shaped subcortical hypointensity in the left parietal lobe.* **(Right)** *Collage of 2 axial (top) and 2 coronal (bottom) T1C+ images in the same patient shows faint brush-like enhancement characteristic of capillary telangiectasia. Note prominent central draining vein.*

(Left) *Axial T2* SWI MIP image shows an 8 mm rounded hypointensity in the right caudate nucleus.* **(Right)** *Axial T1 C+ MR in the same patient shows the faint brush-like enhancement characteristic of a capillary telangiectasia. This was an incidental finding in this patient with nonfocal headaches.*

https://CafePezeshki.IR

PART I
SECTION 6

Neoplasms

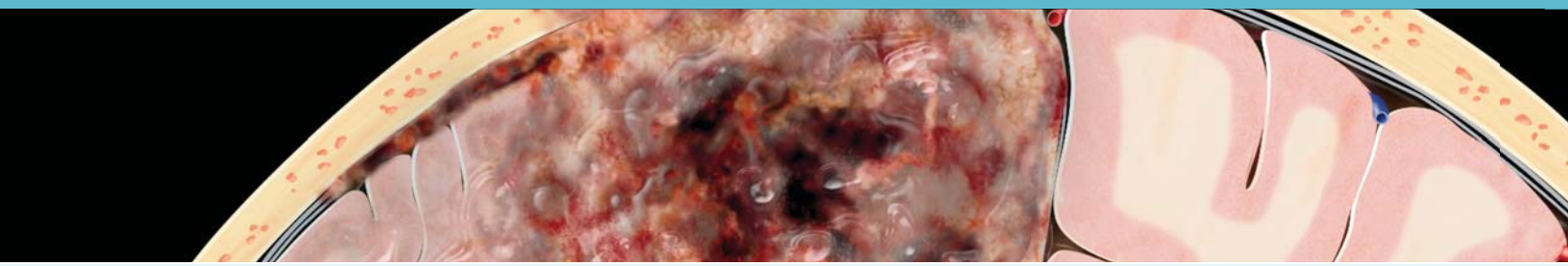

Neoplasms Overview 430

Astrocytic Tumors, Infiltrating

Low-Grade Diffuse Astrocytoma 434
Anaplastic Astrocytoma 438
Glioblastoma 442
Gliosarcoma 446
Gliomatosis Cerebri 448

Astrocytic Tumors, Localized

Pilocytic Astrocytoma 452
Pilomyxoid Astrocytoma 456
Pleomorphic Xanthoastrocytoma 460
Subependymal Giant Cell Astrocytoma 464

Oligodendroglial and Miscellaneous Tumors

Oligodendroglioma 468
Anaplastic Oligodendroglioma 472
Astroblastoma 476
Chordoid Glioma of the Third Ventricle 478
Angiocentric Glioma 480

Ependymal Tumors

Infratentorial Ependymoma 482
Supratentorial Ependymoma 486
Subependymoma 490

Choroid Plexus Tumors

Typical Choroid Plexus Papilloma 494
Choroid Plexus Carcinoma 498

Neuronal and Mixed Neuronal-Glial Tumors

Ganglioglioma 502
Desmoplastic Infantile Astrocytoma and Ganglioglioma 506
DNET 510
Central Neurocytoma 514
Extraventricular Neurocytoma 518
Cerebellar Liponeurocytoma 520

https://CafePezeshki.IR

Papillary Glioneuronal Tumor 521
Rosette-Forming Glioneuronal Tumor 522

Pineal Parenchymal Tumors

Pineocytoma 524
Pineal Parenchymal Tumor of Intermediate Differentiation 528
Pineoblastoma 530
Papillary Tumor of the Pineal Region 534

Embryonal and Neuroblastic Tumors

Medulloblastoma 536
Supratentorial PNET 540
Atypical Teratoid-Rhabdoid Tumor 544
Metastatic Neuroblastoma 548

Tumors of Cranial/Peripheral Nerves

Nonvestibular Schwannoma 552
Neurofibroma 556

Blood Vessel and Hemopoietic Tumors

Hemangioblastoma 558
Hemangiopericytoma 562
Primary CNS Lymphoma 566
Intravascular (Angiocentric) Lymphoma 570
Leukemia 574

Germ Cell Tumors

Germinoma 578
Teratoma 582
Miscellaneous Malignant Germ Cell Neoplasms 586

Metastatic Tumors and Remote Effects of Cancer

Parenchymal Metastases 590
Miscellaneous Intracranial Metastases 594
Metastatic Intracranial Lymphoma 596
Paraneoplastic Syndromes 598

https://CafePezeshki.IR

Introduction

The most widely accepted classification of brain neoplasms is sponsored by the World Health Organization (WHO). A working group of world-renowned neuropathologists periodically convenes for a consensus conference on brain tumor classification and grading. The results are then published. An update to the 2007 edition of the so-called "Blue Book" is scheduled for late 2016.

Brain tumors are both classified and graded. Although this is rapidly changing with the advent of molecular profiling, histological grading has been the primary means of predicting the biological behavior of tumors. While many different grading schemas have been proposed, the WHO classification and grading of CNS neoplasms is the most widely accepted and is utilized in this text.

Classification/Grading of CNS Neoplasms

General Considerations

CNS neoplasms are divided into primary and metastatic tumors. Primary neoplasms are divided into 6 major categories. The largest by far is tumors of neuroepithelial tissue, followed by tumors of the meninges. Tumors of cranial and spinal nerves, lymphomas and hematopoietic neoplasms, and germ cell tumors are less common but important groupings. The final category of primary neoplasms, tumors of the sellar region, is identified by geographic region rather than histologic type.

Tumors of Neuroepithelial Tissue

This category is huge, and therefore it is divided into several discrete tumor subtypes. Once thought to arise from dedifferentiation of mature neurons or glial cells (e.g., astrocytes, oligodendrocytes, ependymal cells, etc.), it is now recognized that most brain tumors arise from neural stem cells.

Astrocytomas: There are many histologic types and subtypes of astrocytomas, ranging in biological behavior from benign, relatively circumscribed tumors, such as pilocytic astrocytoma (PA) and subependymal giant cell astrocytoma (SGCA), to the highly malignant, diffusely infiltrating glioblastoma (GBM).

Two of the localized astrocytomas (PA and SGCA) are designated as WHO grade I neoplasms. Neither displays a tendency to malignant progression, although a variant of PA called pilomyxoid astrocytoma may behave more aggressively and is classified as a WHO grade II tumor.

Diffusely infiltrating astrocytomas have no distinct border between tumor and normal brain, even though the tumor may look relatively discrete on imaging. The lowest grade is simply called "diffuse astrocytoma" and is designated as WHO grade II. Anaplastic astrocytoma (AA) is WHO grade III and GBM is a grade IV neoplasm.

Patient age has a significant effect on astrocytoma type and location. For example, diffusely infiltrating astrocytomas are most common in the cerebral hemispheres of adults and the pons in children. PAs are tumors of children and young adults. They are common in the cerebellum and around the third ventricle but only rarely occur in the hemispheres.

Oligodendroglial tumors: These vary from a diffusely infiltrating, but relatively well-differentiated, WHO grade II neoplasm (oligodendroglioma) to anaplastic oligodendroglioma (WHO grade III).

Low grade gliomas (LGGs): LGGs have been distilled into 3 molecular subtypes, which yields a robust nonoverlapping, clinically relevant classification that is superior to traditional histologic methods in predicting biological behavior. LGG class is based on the FISH (fluorescence in situ hybridization) status of 3 important markers: *IDH1*, 1p19q (co-deletion of both 1p and 19q), and *ATRX* (α-thalassemia/mental retardation syndrome X-linked gene).

This molecular classification results in two diffusely infiltrating astrocytomas that are stratified primarily according to *IDH1* status. Astrocytomas with a more favorable prognosis exhibit *IDH* mutation (are *IDH1*[+]) &/or *ATRX* mutation (*ATRX*[+]). 1p19q is nondeleted. The second group is those that are *IDH1*(-) ("wild type"). Even though they may appear histologically "low grade" (WHO II), "wild type" tumors are aggressive neoplasms that behave more like GBMs. Oligodendrogliomas exhibit 1p19q codeletion are typically *IDH1*(+). *ATRX* is nonmutated.

O-6-methylguanine-DNA methyltransferase (MGMT) promoter profiling is important for glioma treatment stratification. MGMT(+) tumors are typically more chemosensitive than "wild type" neoplasms.

Gliomas in children vs. adults: Pediatric gliomas are often genetically different from their adult counterparts even though they appear identical under the microscope. Intrinsic pediatric pontine gliomas, aggressive neoplasms that are almost always fatal, exhibit histone (*H3*) and *ACVR1* mutations. In contrast to adult oligodendrogliomas, pediatric oligodendrogliomas rarely exhibit 1p19q codeletion.

Ependymal tumors: Classic histologic criteria divide ependymal neoplasms into grade I subependymomas or myxopapillary ependymomas, grade II ependymomas (further subdivided into cellular, papillary, clear cell, and tanycytic types), and grade III (anaplastic) ependymomas.

DNA methylation profiling has recently identified 9 molecular subgroups of ependymoma. This molecular classification outperforms the current histopathological grading in the risk stratification of patients for treatment.

Choroid plexus tumors: Choroid plexus tumors (CPTs) are papillary intraventricular neoplasms. Almost 80% are found in children. Classically, CPTs have been divided into choroid plexus papillomas (CPP) (WHO grade I), atypical choroid plexus papillomas (aCPP) (WHO grade III), and choroid plexus carcinomas (CPCa), designated as WHO grade III. Recent genomic analysis has shown aCPP is an immature variant of CPP with similar cytogenetic profiling and differs only by exhibiting increased proliferative activity. CPCa is a genetically distinct tumor group.

CPPs are 5-10x more common than CPCs. All choroid plexus tumors can spread diffusely through the CSF, so the entire neuraxis should be imaged prior to surgical intervention.

Other neuroepithelial tumors: These rare neoplasms include astroblastoma, chordoid glioma of the third ventricle, and angiocentric glioma.

Neuronal and mixed neuronal-glial tumors: Neuroepithelial tumors with ganglion-like cells, differentiated neurocytes, or poorly differentiated neuroblastic cells are included in this heterogeneous group. Ganglion cell neoplasms (gangliocytoma, ganglioglioma), desmoplastic infantile ganglioglioma or astrocytoma (DIG/DIA), neurocytoma

https://CafePezeshki.IR

(central as well as the newly described extraventricular variant), dysembryoplastic neuroepithelial tumor (DNET), papillary glioneuronal tumor, rosette-forming glioneuronal tumor (of the 4th ventricle), and cerebellar liponeuroblastoma are included.

Pineal region tumors: Pineal region neoplasms account for < 1% of all intracranial neoplasms and can be germ cell tumors or pineal parenchymal tumors. Pineal parenchymal tumors are less common than germ cell tumors. Because germ cell neoplasms occur in other intracranial sites as well as the pineal gland, they are considered separately.

Pineocytoma is a very slowly growing, well-delineated tumor that is usually found in adults. Pineocytomas are WHO grade I. Pineoblastoma is a highly malignant primitive embryonal tumor mostly found in children. Highly aggressive and associated with early CSF dissemination, pineoblastomas are WHO grade IV neoplasms.

Pineal parenchymal tumor of intermediate differentiation (PPTID) is intermediate in malignancy, probably WHO grade II or III. Many so-called aggressive pineocytomas would probably be reclassified as PPTIDs. A newly described neoplasm, papillary tumor of the pineal region (PTPR), is a rare neuroepithelia tumor of adults. No WHO grade has been assigned.

Embryonal tumors: This group includes medulloblastoma, CNS primitive neuroectodermal tumors (PNETs), and atypical teratoid-rhabdoid tumors (AT/RT). *SMARCB1* (*INI1/hSNF5*) mutation is diagnostic of AT/RT even in the absence of overtly rhabdoid cells.

Medulloblastoma (MB), which has 1 classic and 3 histologic variants, is now divided into 4 groups based on molecular profiling (the first step in risk stratifying MB patients for therapy). While all 4 groups are designated as WHO IV tumors, they behave quite differently and 1 specific subgroup (Wnt) is associated with an especially favorable prognosis.

Meningeal Tumors

Overview: Meningeal tumors are the second largest category of primary CNS neoplasms. They are divided into meningiomas and mesenchymal, nonmeningothelial tumors (i.e., tumors that are not meningiomas). Hemangiopericytomas, hemangioblastomas, and melanocytic lesions are also considered part of the meningeal tumor grouping.

Meningiomas: Meningiomas arise from meningothelial (arachnoid cap) cells. Most are attached to the dura but can occur in other locations (e.g., choroid plexus of the lateral ventricles). While meningiomas have many histologic subtypes (e.g., meningothelial, fibrous, psammomatous, etc.), the current WHO schema classifies them rather simply. Most meningiomas are benign and correspond to WHO grade I. Atypical meningioma, as well as the chordoid and clear cell variants, are WHO grade II tumors. Anaplastic (malignant) meningiomas correspond to WHO grade III.

Mesenchymal, nonmeningothelial tumors: Both benign and malignant mesenchymal tumors can originate in the CNS. Most correspond to tumors of soft tissue or bone. Generally, both a benign and malignant (sarcomatous) type occur. Lipomas and liposarcomas, chondromas and chondrosarcomas, osteomas and osteosarcomas are examples.

Hemangiopericytoma (HPC) is a highly cellular, vascular mesenchymal tumor that is almost always attache dura. HPCs are WHO II or III neoplasms. Hemangioblastoma (HGBL) is a WHO grade I neoplasm, consisting of stromal cells and innumerable small blood vessels. It occurs both sporadically and as a part of von Hippel-Lindau (VHL) syndrome. Primary melanocytic neoplasms of the CNS are rare. They arise from leptomeningeal melanocytes and can be diffuse or circumscribed, benign or malignant.

Tumors of Cranial (and Spinal) Nerves

Schwannoma: Schwannomas are benign, encapsulated nerve sheath tumors that consist of well-differentiated Schwann cells. They can be solitary or multiple. Multiple schwannomas are associated with neurofibromatosis type 2 and schwannomatosis, a syndrome characterized by multiple schwannomas but lacking other features of NF2. Intracranial schwannomas are almost always associated with cranial nerves (CN8 is by far the most common) but occasionally occur as a parenchymal lesion. Schwannomas do not undergo malignant degeneration and are designated as WHO grade I neoplasms.

Neurofibroma: Neurofibromas (NFs) are diffusely infiltrating, extraneural tumors that consist of Schwann cells and fibroblasts. Solitary scalp neurofibromas occur. Multiple NFs or plexiform NFs occur as part of neurofibromatosis type 1. Neurofibromas correspond histologically to WHO grade I. Plexiform neurofibromas may degenerate into malignant peripheral nerve sheath tumors (MPNSTs). MPNSTs are graded from WHO II to IV, an approach similar to sarcoma grading.

Lymphomas and Hematopoietic Tumors

Primary CNS lymphoma: As a result of HAART therapy in HIV/AIDS patients, as well as in other immunocompromised individuals, primary CNS lymphomas (PCNSL) are dramatically increasing in prevalence. PCNSL can occur as both focal parenchymal and intravascular (IVL) tumor. PCNSL can be single or multiple and is most commonly seen in the cerebral hemispheres. More than 95% of PCNSLs are diffuse large B-cell lymphomas.

Germ Cell Tumors

Intracranial germ cell tumors (GCTs) are morphologic homologues of germinal neoplasms that arise in the gonads and extragonadal sites. 80-90% occur in adolescents. Most occur in the midline (pineal region, around the third ventricle).

Sellar Region Tumors

Craniopharyngioma: Craniopharyngioma is a benign (WHO grade I), often partially cystic neoplasm that is the most common nonneuroepithelial intracranial neoplasm in children. It shows a distinct bimodal age distribution, with the cystic adamantinomatous type seen mostly in children and a second, smaller peak in middle-aged adults. The less common papillary type is usually solid and found almost exclusively in adults.

Miscellaneous sellar region tumors: Granular cell tumor of the neurohypophysis is a rare tumor of adults that usually arises from the infundibulum. Pituicytomas are glial neoplasms of adults that also usually arise within the infundibulum. Spindle cell oncocytoma of the adenohypophysis is a nonendocrine neoplasm of the adenohypophysis. These rare tumors are all WHO grade I.

https://CafePezeshki.IR

Neuroepithelial Tumors

Neoplasm	Grade	Neoplasm	Grade	Neoplasm	Grade
Astrocytic		**Choroid plexus**		**Neuronal, mixed neuronal-glial**	
Pilocytic astrocytoma	I	Choroid plexus papilloma	I	Gangliocytoma	I
Pilomyxoid astrocytoma	II	Atypical choroid plexus papilloma	II	Ganglioglioma	I
Subependymal giant cell astrocytoma	I	Choroid plexus carcinoma	III	DIG/DIA	I
Pleomorphic xanthoastrocytoma	II			DNET	I
Anaplastic astrocytoma	III	**Pineal region**		Central neurocytoma	II
Glioblastoma	IV	Pineocytoma	I	Extraventricular neurocytoma	II
Gliosarcoma	IV	PPTID	II-III	Cerebellar liponeurocytoma	II
Gliomatosis cerebri	III, II-IV	Pineoblastoma	IV	Paraganglioma (spinal cord)	I
		PTPR	II-III	Papillary glioneuronal tumor	I
Oligodendroglial				RGNT	I
Oligodendroglioma	II	**Ependymal**			
Anaplastic oligodendroglioma	III	Subependymoma	I	**Other neuroepithelial**	
Oligoastrocytoma	Variable	Myxopapillary ependymoma	I	Astroblastoma	
		Ependymoma	II	Chordoid glioma of 3rd ventricle	II
Embryonal		Anaplastic ependymoma	III	Angiocentric glioma (ANET)	I
Medulloblastoma	IV				
Primitive neuroectodermal tumor	IV				
Atypical teratoid-rhabdoid tumor	IV				

Meningeal Tumors

Neoplasm	Grade	Neoplasm	Grade	Neoplasm	Grade
Meningothelial		**Nonmeningothelial mesenchymal**		**Primary melanocytic**	
Meningioma	I	Lipoma	I	Diffuse melanocytoma	
Atypical meningioma	II	Liposarcoma		Melanocytoma	
Anaplastic/malignant meningioma	III	Chondroma	I	Malignant melanoma	
		Chondrosarcoma		Meningeal melanomatosis	
Other related		Osteoma			
Hemangioblastoma	I	Osteosarcoma			
		Osteochondroma			
		Hemangioma	I		
		Hemangiopericytoma	II-III		

Other Tumors

Neoplasm	Grade	Neoplasm	Grade	Neoplasm	Grade
Cranial and spinal nerve tumors		**Germ cell tumors**		**Sellar region tumors**	
Schwannoma	I	Germinoma		Craniopharyngioma	I
Neurofibroma	I	Embryonal carcinoma		Adamantinomatous	
MPNST	II-IV	Yolk sac tumor		Papillary	
		Mixed germ cell tumor		Granular cell tumor of neurohypophysis	I
Lymphoma/hematopoietic		Teratoma		Pituicytoma	I
Malignant lymphoma				Spindle cell oncocytoma	I

Tables modified, adapted to conform to 2007 World Health Organization Classification of Tumours of the Central Nervous System.

https://CafePezeshki.IR



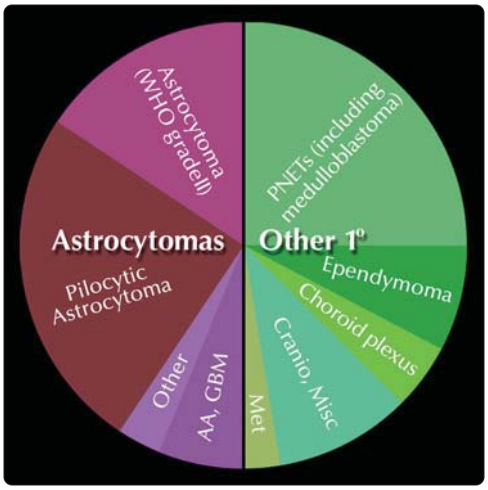

(Left) *Graphic depicts the relative prevalence of brain tumors in adults. Nearly 1/2 are metastases from systemic cancers; the other 1/2 are primary neoplasms.* **(Right)** *Graphic depicts brain tumors in children. Metastases, anaplastic astrocytoma (AA), and glioblastoma (GBM) are rare. Pilocytic astrocytoma and primitive neuroectodermal tumors (PNETs) in children are more common than in adults.*

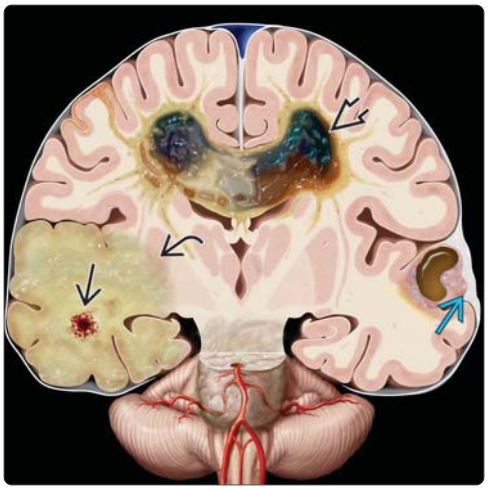

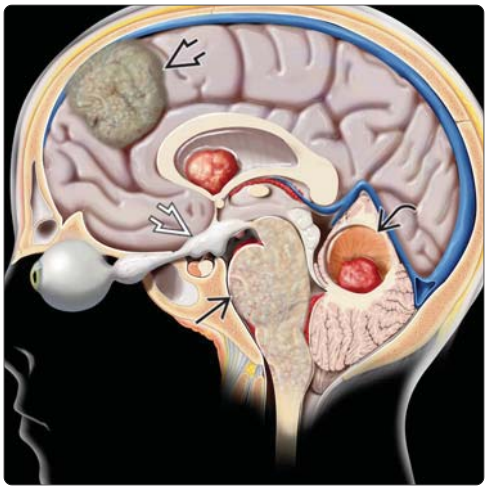

(Left) *Graphic depicts adult astrocytomas. Low-grade astrocytoma ⇨ (WHO II) has an intrinsic tendency to become anaplastic ⇨. GBM ⇨ is the most common and is shown here in the corpus callosum. PXA is a cystic tumor with nodule abutting and thickening of the meninges ⇨.* **(Right)** *Graphic depicts astrocytomas in children. Brainstem "gliomas" ⇨ and pilocytic astrocytoma (PA) ⇨ are common. Except for PAs around the 3rd ventricle ⇨, supratentorial astrocytomas ⇨ are less frequent compared to adults.*

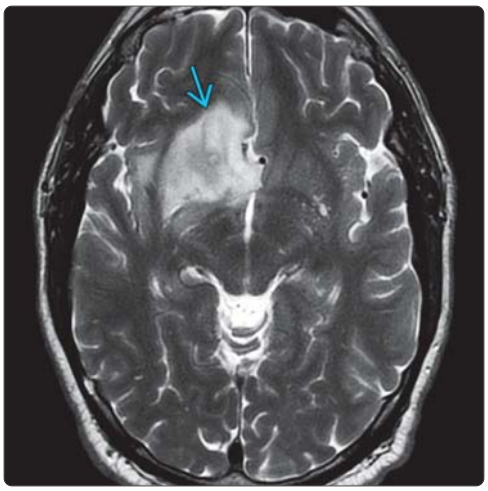

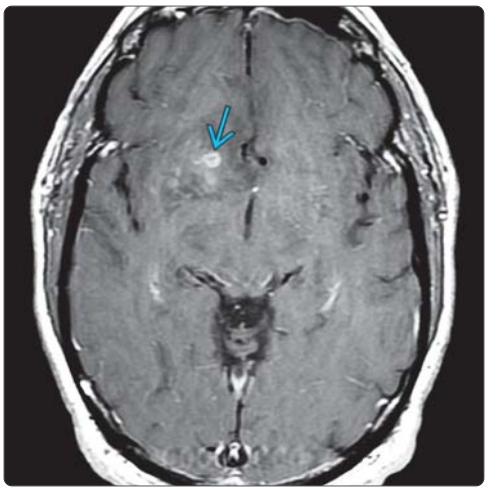

(Left) *Axial T2WI in a 58-year-old male with 2 seizures demonstrates a heterogeneously hyperintense mass ⇨ infiltrating the right basal ganglia, frontal lobe, external capsule, and posterior limb of the internal capsule.* **(Right)** *T1WI C+ MR in the same patient shows a few enhancing foci ⇨ in the center of the mass. Its location (frontal lobe) and large nonenhancing areas suggest this tumor is likely a secondary GBM. Biopsy disclosed IDH1(+), EGFR(-), MGMT(+), p53 70%(+), PTEN 25%(+), and MIB1 90%.*

https://CafePezeshki.IR

KEY FACTS

TERMINOLOGY

- Well-differentiated but infiltrating neoplasm, slow growth pattern
- Primary brain tumor of astrocytic origin with intrinsic tendency for malignant progression, degeneration into anaplastic astrocytoma (AA)

IMAGING

- Focal or diffuse nonenhancing white matter mass
- T2 homogeneously hyperintense mass
- May expand adjacent cortex
- Usually no enhancement
  - Enhancement suggests progression to higher grade
- MRS: High choline, low NAA typical but not specific
- Perfusion: Relatively lower rCBV compared to AA
- Cerebral hemispheres most common location
  - Supratentorial 2/3: Frontal and temporal lobes
- Infratentorial 1/3: Brainstem (50% of brainstem "gliomas" are low-grade astrocytoma)
- Low-grade astrocytoma may be indistinguishable from other tumors, including AA and oligodendroglioma
- May appear circumscribed on imaging, but tumor cells are often found beyond imaged signal abnormality

TOP DIFFERENTIAL DIAGNOSES

- Anaplastic astrocytoma (AA)
- Oligodendroglioma
- Ischemia
- Cerebritis

PATHOLOGY

- WHO grade II

CLINICAL ISSUES

- Seizure is most common presenting feature
- Majority occur between ages of 20-45 years, mean: 34 years
- Median survival: 6-10 years
- Increased survival: Young age, gross total resection
- More favorable prognosis: *IDH1*(+), *ARTX*(+), MGMT(+)

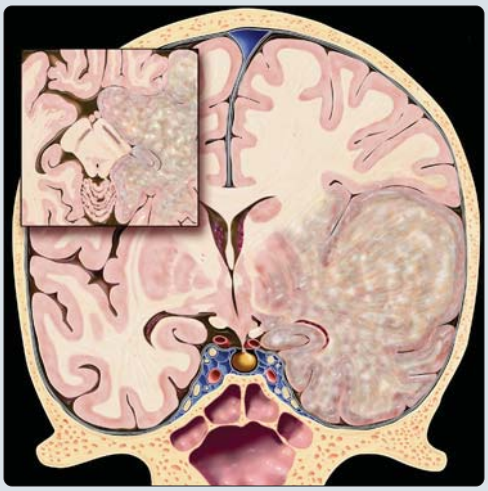

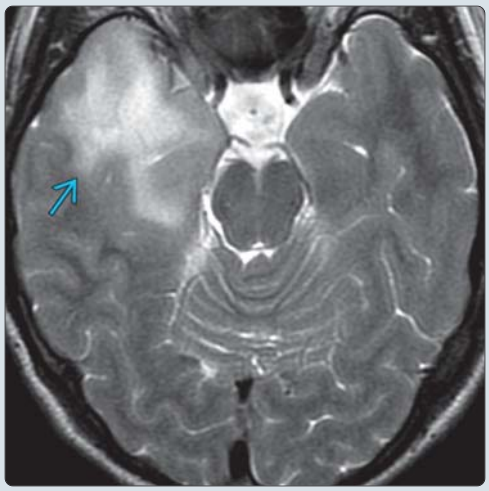

(Left) *Coronal graphic shows an infiltrative mass centered in the white matter expanding the left temporal lobe. Axial insert shows mild mass effect upon the midbrain. Low-grade astrocytomas typically affect young adults.* **(Right)** *Axial T2 MR image in a 34-year-old man with seizures shows a hyperintense infiltrative mass ⇨ centered in the right temporal lobe white matter with extension to the overlying cortex. No enhancement was present on contrast-enhanced images. WHO grade II astrocytoma was diagnosed at resection.*

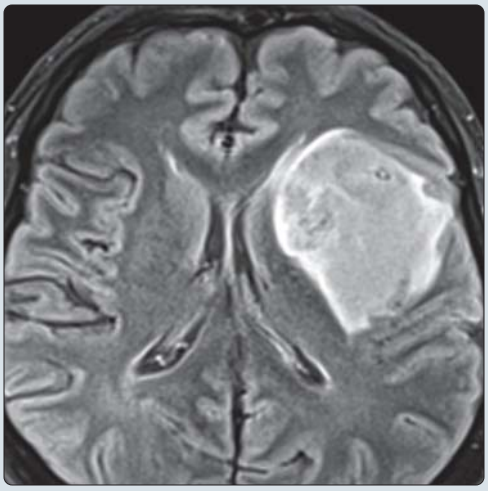

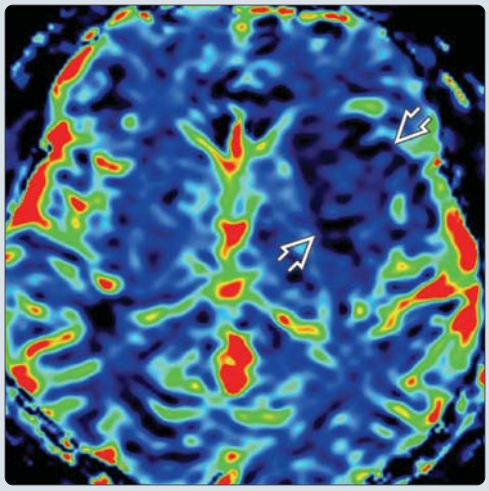

(Left) *Axial FLAIR MR shows a relatively homogeneous hyperintense mass with mild local mass effect, typical of a WHO grade II diffuse astrocytoma. These infiltrative tumors may be focal or diffuse. Fibrillary astrocytoma is the most frequent histologic variant.* **(Right)** *Axial MR perfusion in the same patient shows a low rCBV ⇨ in the frontotemporal mass, suggesting a low-grade tumor. Perfusion MR has been shown to be helpful in preoperative tumor grading, predicting survival, and guiding biopsy.*

https://CafePezeshki.IR

TERMINOLOGY

Synonyms

- Diffuse astrocytoma, grade II astrocytoma, fibrillary astrocytoma, low-grade astrocytoma (LGA)

Definitions

- Primary brain tumor of astrocytic origin with intrinsic tendency for malignant progression, degeneration into anaplastic astrocytoma (AA)
- Well-differentiated but infiltrating neoplasm, slow growth pattern

IMAGING

General Features

- Best diagnostic clue
  - Focal or diffuse nonenhancing white matter (WM) mass
- Location
  - Cerebral hemispheres, supratentorial 2/3
    - Frontal lobes 1/3, temporal lobes 1/3
    - Relative sparing of occipital lobes
    - Tumors of white matter may extend into cortex
  - Infratentorial 1/3
    - Brainstem (50% of brainstem "gliomas" are low-grade astrocytoma)
    - Occur in pons and medulla of children/adolescents
    - Cerebellum is uncommon location
  - 20% involve deep gray matter structures: Thalamus and basal ganglia
  - Less commonly occur in spinal cord
- Size
  - Variable
- Morphology
  - Homogeneous mass with enlargement and distortion of affected structures
  - May appear circumscribed on imaging, but tumor cells are often found beyond imaged signal abnormality

CT Findings

- NECT
  - Ill-defined homogeneous hypodense/isodense mass
  - 20% Ca++; cysts are rare
  - Calvarial erosion in cortical masses (rare)
- CECT
  - No enhancement or very minimal
    - Enhancement should raise suspicion of focal malignant degeneration

MR Findings

- T1WI
  - Homogeneous hypointense mass
  - May expand white matter and adjacent cortex
  - Appears circumscribed, but infiltrates adjacent brain
  - Ca++ and cysts (uncommon)
  - Hemorrhage or surrounding edema (rare)
- T2WI
  - Homogeneous hyperintense mass
  - May appear circumscribed, but often infiltrates adjacent brain
  - Ca++ and cysts less common
  - Hemorrhage or surrounding edema are rare
  - May expand adjacent cortex
- FLAIR
  - Homogeneous hyperintense mass
- DWI
  - Typically no diffusion restriction
- T1WI C+
  - Usually no enhancement
  - Enhancement suggests progression to higher grade
- MRS
  - High choline, low NAA typical but not specific
  - High mI/Cr ratio (0.82 ± 0.25)
  - May delineate tumor extent better than conventional MR
- MR perfusion
  - Relatively lower rCBV compared to AA, GBM
  - Lower permeability values than high-grade tumors
  - Increase in rCBV helps predict time to progression

Nuclear Medicine Findings

- PET
  - Low-grade astrocytomas have FDG uptake similar to normal white matter
  - FDG uptake within astrocytoma has good correlation with histologic grade of tumor
  - FDG, 18F-choline, and 11C-choline PET useful for biopsy (most hypermetabolic area)

Imaging Recommendations

- Protocol advice
  - Contrast-enhanced MR
  - MRS and perfusion imaging may be helpful

DIFFERENTIAL DIAGNOSIS

Anaplastic Astrocytoma (AA)

- Hemispheric WM lesion, usually nonenhancing
- Focal or diffuse mass
- May be indistinguishable without biopsy
- MR perfusion may show elevated CBV

Oligodendroglioma

- Cortically based mass with variable enhancement
- Ca++ common
- May be indistinguishable

Ischemia

- Vascular territory (anterior, middle, and posterior cerebral arteries), acute onset
- Diffusion restriction (acute/early subacute)
- Often wedge-shaped, involves GM and WM

Cerebritis

- Edema, patchy enhancement characteristic
- Usually shows restricted diffusion
- Typically more acute onset

Herpes Encephalitis

- Confined to limbic system, temporal lobes
- Hemorrhage and enhancement are common
- Acute onset

https://CafePezeshki.IR

Status Epilepticus

- Active seizures may cause signal abnormalities and enhancement
- Clinical history of seizures

PATHOLOGY

General Features

- Etiology
  - Arise from differentiated astrocytes or astrocytic precursor cells
  - Astrocytic neoplasm characterized by high degree of cellular differentiation, slow growth, diffuse infiltration of adjacent structures
- Genetics
  - *TP53* mutation 25-50%
  - *IDH1*(+), *ATRX* mutations common (up to 85%)
  - Overexpression of platelet-derived growth factor receptor-α (*PDGFRA*)
  - Chromosomal abnormalities: Gain of 7q; 8q amplification; LOH 10p, 22q; chromosome 6 deletions
- Associated abnormalities
  - Associated with Li-Fraumeni syndrome and inherited multiple enchondromatosis type 1 (Ollier disease)

Staging, Grading, & Classification

- WHO grade II

Gross Pathologic & Surgical Features

- Enlargement and distortion of invaded structures
- Diffusely infiltrating mass with blurring of GM/WM interface
- May appear grossly circumscribed but diffusely infiltrates adjacent brain
- Occasional cysts, Ca++

Microscopic Features

- Well-differentiated fibrillary or gemistocytic neoplastic astrocytes
- Background of loosely structured, often microcystic tumor matrix
- Moderately increased cellularity
- Occasional nuclear atypia
- Mitotic activity generally absent or very rare
- No microvascular proliferation or necrosis
- MIB-1 (proliferation index) is low (< 4%)
- Immunohistochemistry: GFAP(+)
- Histologic variants
  - Fibrillary (most frequent)
  - Gemistocytic (most likely to progress to AA, GBM)
  - Protoplasmic (rare)

CLINICAL ISSUES

Presentation

- Most common signs/symptoms
  - Seizures, increased intracranial pressure
  - Other signs/symptoms: Varies with tumor location
    - Seizure, focal neurologic deficit, behavior changes

Demographics

- Age
  - Majority occur between 20-45 years
  - Occur at all ages, mean: 34 years
- Gender
  - Slight male predominance
- Epidemiology
  - Represents 25-30% of gliomas in adults
  - 10-15% of all astrocytomas
  - 2nd most common astrocytoma of childhood (pilocytic is 1st)
  - ~ 1.4 new cases per 1,000,000/year

Natural History & Prognosis

- Patients rarely succumb to spread of low-grade tumor
- Median survival: 6-10 years
- Inherent tendency for malignant progression to AA and GBM = major cause of mortality
- Recurrent disease associated with malignant degeneration in 50-75% of cases
- Malignant progression tends to occur following mean interval of 4-5 years
- Increased survival: Young age, gross total resection
- Radiation therapy in patients with subtotal resection improves survival
- More favorable prognosis: *IDH1*(+), *ARTX*(+), MGMT(+)
- Prognosis worse for pontine, better for medullary tumors (especially dorsally exophytic)

Treatment

- Surgical resection is primary treatment
- Usually adjuvant chemotherapy and XRT at time of recurrence or progression

DIAGNOSTIC CHECKLIST

Consider

- Low-grade astrocytoma may be indistinguishable from other tumors including AA and oligodendroglioma
- Acute/subacute ischemia may mimic diffuse astrocytoma; DWI, history, and follow-up MR helpful

Image Interpretation Pearls

- Think low-grade astrocytoma if T2 hyperintense expansile mass largely confined to WM

SELECTED REFERENCES

1. Arevalo-Perez J et al: Dynamic Contrast-Enhanced Perfusion MRI and Diffusion-Weighted Imaging in Grading of Gliomas. J Neuroimaging. ePub, 2015
2. Jia ZZ et al: The assessment of immature microvascular density in brain gliomas with dynamic contrast-enhanced magnetic resonance imaging. Eur J Radiol. ePub, 2015
3. Ogura R et al: Immunohistochemical profiles of IDH1, MGMT and P53: Practical significance for prognostication of patients with diffuse gliomas. Neuropathology. 35(4):324-35, 2015
4. Reuss DE et al: ATRX and IDH1-R132H immunohistochemistry with subsequent copy number analysis and IDH sequencing as a basis for an "integrated" diagnostic approach for adult astrocytoma, oligodendroglioma and glioblastoma. Acta Neuropathol. 129(1):133-46, 2015
5. Cha S: Neuroimaging in neuro-oncology. Neurotherapeutics. 6(3):465-77, 2009
6. Louis DN et al (): WHO Classification of Tumours of the Central Nervous System: Diffuse Astrocytoma. Lyon: IARC Press. 25-9, 2007

https://CafePezeshki.IR

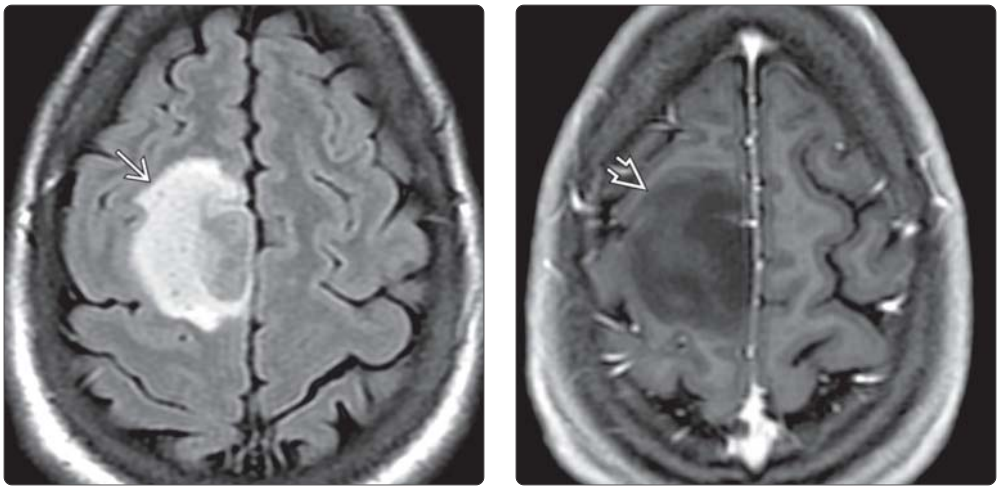

(Left) *Axial FLAIR MR in a 28-year-old woman shows a discrete-appearing posterior frontal lobe hyperintense mass ➡ centered in the white matter with extension to the overlying cortex. Increased survival is correlated with a younger age at presentation and complete surgical resection.* **(Right)** *Axial T1 C+ MR in the same patient shows no enhancement within the mass ➡, typical of a WHO grade II astrocytoma. Imaging mimics an oligodendroglioma. This tumor was IDH1(+), which also has a more favorable prognosis.*

(Left) *Sagittal T2 MR shows a dorsally exophytic medullary mass ➡ that projects into the 4th ventricle. Biopsy confirmed a low-grade astrocytoma. Most brainstem gliomas are diffuse grade II astrocytomas.* **(Right)** *Axial T1 MR shows a large isointense thalamic mass ➡ with associated severe hydrocephalus with interstitial edema (transependymal flow of CSF) ➡. Biopsy revealed a diffusely infiltrating fibrillary astrocytoma. Hydrocephalus is a rare complication of diffuse astrocytoma.*

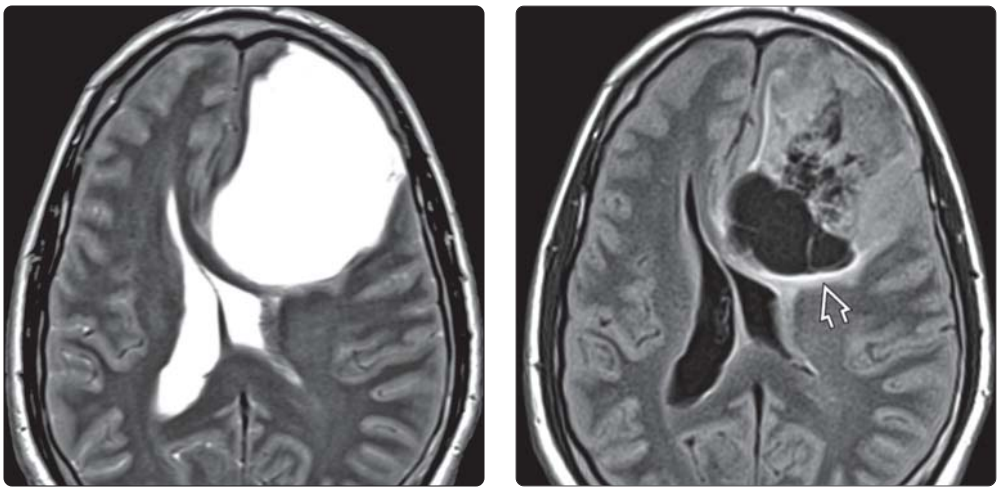

(Left) *Axial T2WI MR shows a large, hyperintense frontal lobe mass with significant mass effect in this young man with seizures. Protoplasmic astrocytoma, WHO grade II, was found at resection.* **(Right)** *Axial FLAIR MR in the same patient shows the mass to be heterogeneous with minimal surrounding vasogenic edema ➡. Protoplasmic astrocytoma is a rare variant of diffuse astrocytoma. Mucoid degeneration and microcyst formation are common. The frontotemporal region is a classic location.*

https://CafePezeshki.IR

KEY FACTS

TERMINOLOGY

- Diffusely infiltrating malignant astrocytoma with anaplasia and marked proliferative potential

IMAGING

- Infiltrating mass that predominately involves white matter with variable enhancement
- T2 heterogeneously hyperintense
- Neoplastic cells almost always found beyond areas of abnormal signal intensity
- May involve and expand overlying cortex
- Usually no enhancement
  - Focal, nodular, homogeneous, patchy enhancement less common
  - Ring enhancement is suspicious for glioblastoma (GBM)
- MRS: Increased Cho/Cr ratio, decreased NAA
- MRP: Elevated maximum rCBV
- AA have histologic and imaging characteristics along spectrum between low-grade astrocytoma and GBM

TOP DIFFERENTIAL DIAGNOSES

- Low-grade diffuse astrocytoma
- GBM
- Oligodendroglioma
- Cerebritis
- Ischemia

PATHOLOGY

- WHO grade III
- Usually evolves from low-grade (diffuse) astrocytoma (WHO grade II) (75%)

CLINICAL ISSUES

- Most common presentation: Marked clinical deterioration in patient with grade II astrocytoma
- Occurs at all ages, most common 40-50 years
- 1/3 of astrocytomas
- *IDH1*(+) and *MGMT*(+) associated with increased survival
- Median survival: 2-3 years

(Left) *Axial graphic shows an infiltrative white matter mass with extension along the corpus callosum, focal hemorrhage ➡, and local mass effect. White matter extension is typical of anaplastic astrocytoma (AA). They are most commonly located in the cerebral hemispheres.* **(Right)** *Axial T2 MR shows a heterogeneously hyperintense mass with local mass effect ⇨ in the frontal lobe. AA, WHO grade III, was diagnosed at resection. These high-grade gliomas have an intrinsic tendency to degenerate into GBM.*

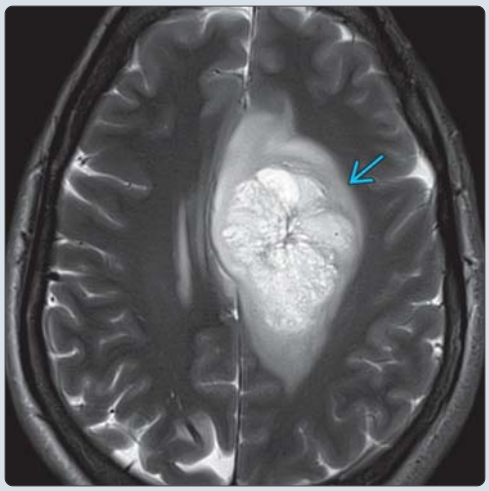

(Left) *MRS image in a patient with a tectal anaplastic astrocytoma shows a typical malignant tumor spectrum with a high choline peak ➡ and a low NAA peak ⇦.* **(Right)** *Coronal FLAIR MR image in a 47-year-old male shows a heterogeneously hyperintense mass ⇨ centered in the frontal lobe white matter. Anaplastic astrocytomas represent 1/3 of all astrocytomas. Anaplastic astrocytomas are intermediate between low-grade (diffuse) astrocytoma (WHO grade II) and GBM (WHO grade IV).*

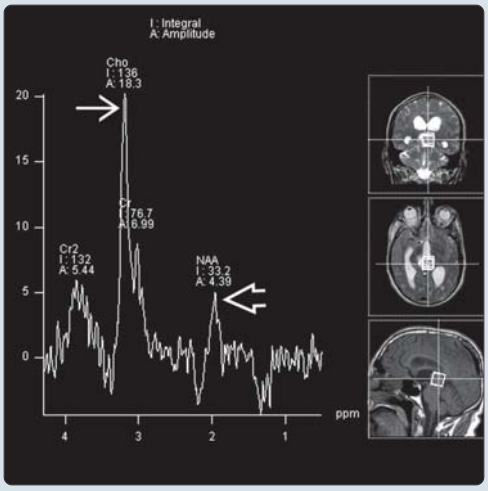

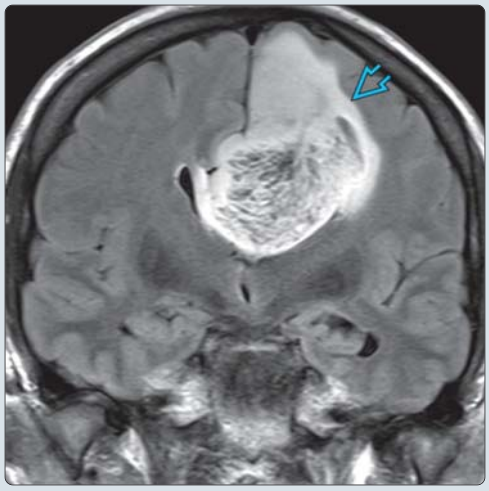

https://CafePezeshki.IR

TERMINOLOGY

Abbreviations

- Anaplastic astrocytoma (AA)

Synonyms

- Grade III astrocytoma, malignant astrocytoma, high-grade astrocytoma

Definitions

- Diffusely infiltrating malignant astrocytoma with focal or diffuse anaplasia and marked proliferative potential

IMAGING

General Features

- Best diagnostic clue
  - Infiltrating mass that predominately involves white matter (WM) with variable enhancement
- Location
  - Hemispheric WM
    - Commonly involves frontal and temporal lobes
  - May involve pons, thalamus (pons common in children)
  - Less commonly involves brainstem, spinal cord
- Size
  - Variable
- Morphology
  - Ill-defined hemispheric WM mass typical
  - May appear well circumscribed
  - Neoplastic cells almost always found beyond areas of abnormal signal intensity

CT Findings

- NECT
  - Low-density, ill-defined mass
  - Ca++ and hemorrhage rare
- CECT
  - Majority do not enhance
  - Enhancement often focal, patchy, heterogeneous
  - If ring enhancement, consider malignant progression to glioblastoma multiforme (GBM)

MR Findings

- T1WI
  - Mixed isointense to hypointense WM mass
  - May involve and expand overlying cortex
  - Ca++, hemorrhage, cysts rare
- T2WI
  - Heterogeneously hyperintense
  - May appear discrete, but infiltrates adjacent brain
  - May involve and expand overlying cortex
  - Rarely, prominent flow voids are present, suggesting progression to GBM
- FLAIR
  - Heterogeneously hyperintense
- DWI
  - No diffusion restriction is typical
- T1WI C+
  - Usually no enhancement
  - Less common: Focal, nodular, homogeneous, patchy enhancement
  - Ring enhancement is suspicious for GBM
- MRS
  - Elevated Cho/Cr ratio, decreased NAA
- Dynamic contrast-enhanced T2-weighted imaging
  - Elevated maximum rCBV compared to low-grade astrocytoma
  - Increased permeability compared to low-grade astrocytoma
- Diffusion tensor imaging (DTI) of WM tracts may help surgical planning

Nuclear Medicine Findings

- PET
  - Higher metabolism than low-grade astrocytomas
  - FDG shows high-grade gliomas have uptake similar to or exceeding normal gray matter (GM)
  - Tumor:WM ratio > 1.5 and tumor:GM ratio > 0.6 suggest high-grade tumors
  - FDG has sensitivity of 81-86%, specificity of 50-94% in differentiation of recurrent tumor from radiation brain injury

Imaging Recommendations

- Protocol advice
  - Contrast-enhanced MR
  - MRS, MR perfusion, and DTI may be helpful

DIFFERENTIAL DIAGNOSIS

Low-Grade Diffuse Astrocytoma

- Focal or diffuse WM mass
- Typically nonenhancing hemispheric mass
- May be indistinguishable without biopsy

Glioblastoma Multiforme (GBM)

- 95% necrotic core, enhancing rim
- Extensive surrounding T2/FLAIR signal
- Hemorrhage not uncommon

Cerebritis

- T2 hyperintensity and patchy enhancement
- Diffusion restriction typical

Ischemia

- Vascular territory (MCA, ACA, PCA)
- Restricted diffusion if acute/subacute
- Often wedge-shaped, involves GM and WM
- Gyriform enhancement in subacute ischemia

Oligodendroglioma

- Cortical mass with variable enhancement
- Ca++ common
- May be indistinguishable

Status Epilepticus

- Active seizures may cause signal abnormalities and enhancement
- History of seizures
- Follow-up imaging may be necessary

Herpes Encephalitis

- Confined to limbic system, temporal lobes
- Blood products and enhancement common
- Typically acute onset

https://CafePezeshki.IR

PATHOLOGY

General Features

- Etiology
  - Derived from precursor stem cells committed to astrocytic differentiation
  - Usually evolves from low-grade (diffuse) astrocytoma (WHO grade II) (~ 75%)
    - Progression from low-grade (diffuse) astrocytoma to AA is associated with multiple genetic alterations
  - Occasionally arises de novo
- Genetics
  - *TP53* mutations and LOH 17p may be seen
    - Overexpression of p53 is unfavorable
  - Abnormal cell cycle regulatory genes
  - Loss of heterozygosity: Chromosome 10q, 19q, 22q
  - Deletion of chromosome 6q (30%)
  - Majority are *IDH1*(+)
  - *MGMT* methylation common
- Biologically aggressive astrocytoma characterized by cytologic atypia and mitotic activity
  - Intrinsic tendency for progression to GBM

Staging, Grading, & Classification

- WHO grade III
- Intermediate between low-grade (diffuse) astrocytoma (WHO grade II) and GBM (grade IV)

Gross Pathologic & Surgical Features

- Infiltrating mass with poorly delineated margins
- Often expands invaded structures without frank destruction
- May appear discrete but tumor always infiltrates adjacent brain
- Cysts, hemorrhage uncommon

Microscopic Features

- Characterized by increased cellularity, marked mitotic activity, distinct nuclear atypia
- High nuclear/cytoplasmic ratio
- Nuclear/cytoplasmic pleomorphism
- No necrosis or microvascular proliferation (presence = grade IV)
- Immunohistochemistry: *GFAP*(+) common
- KI-67 (MIB-1): 5-10% (proliferation index)

CLINICAL ISSUES

Presentation

- Most common signs/symptoms
  - Acceleration in clinical deterioration in patient with low-grade (diffuse) astrocytoma (WHO grade II)
  - Varies with location
    - Seizures, focal neurologic deficit common
    - May have headache, drowsiness
    - Increased intracranial pressure
    - Personality or behavioral changes

Demographics

- Age
  - Occurs at all ages, most common 40-50 years
- Gender
  - M:F = 1.6:1
- Epidemiology
  - 1/3 of astrocytomas
  - 25% of gliomas
  - Diffusely infiltrating gliomas including WHO grades II, III, IV account for > 60% of all primary tumors

Natural History & Prognosis

- Median survival: 2-3 years
- Commonly arise as recurrence after resection of grade II tumor
  - Typically *IDH1*(+) (better prognosis)
- *IDH1*(-) (wild-type) are associated with poor prognosis (similar to GBM)
- Progression to secondary GBM very common
  - 2 years is typical time for progression
- Spreads along WM tracts commonly
  - May spread along ependyma, leptomeninges, and CSF
- Increased survival: Younger age, high Karnofsky score, gross total resection
- Other factors associated with longer survival
  - Absence of enhancement, proliferation index of 5.1% or lower, oligodendroglial component
  - *IDH1*(+), *MGMT* methylation (+)

Treatment

- Resection with adjuvant radiation therapy and chemotherapy (temozolomide)

DIAGNOSTIC CHECKLIST

Consider

- AA may mimic other tumors, particularly diffuse, low-grade astrocytomas (grade II)
- Nonneoplastic mimics, such as cerebritis, may be differentiated with help of clinical history
- AA have histologic and imaging characteristics along spectrum between low-grade astrocytoma and GBM

Image Interpretation Pearls

- AA are typically nonenhancing hemispheric masses
- If new areas of enhancement are seen, malignant degeneration is likely

SELECTED REFERENCES

1. Ogura R et al: Immunohistochemical profiles of IDH1, MGMT and P53: Practical significance for prognostication of patients with diffuse gliomas. Neuropathology. 35(4): 324-35, 2015
2. Speirs CK et al: Impact of 1p/19q codeletion and histology on outcomes of anaplastic gliomas treated with radiation therapy and temozolomide. Int J Radiat Oncol Biol Phys. 91(2):268-76, 2015
3. Gempt J et al: Multimodal imaging in cerebral gliomas and its neuropathological correlation. Eur J Radiol. 83(5):829-34, 2014
4. Minniti G et al: IDH1 mutation and MGMT methylation status predict survival in patients with anaplastic astrocytoma treated with temozolomide-based chemoradiotherapy. J Neurooncol. 118(2):377-83, 2014
5. Rusthoven CG et al: The impact of adjuvant radiation therapy for high-grade gliomas by histology in the United States population. Int J Radiat Oncol Biol Phys. 90(4):894-902, 2014
6. Hirai T et al: Prognostic value of perfusion MR imaging of high-grade astrocytomas: long-term follow-up study. AJNR Am J Neuroradiol. 29(8):1505-10, 2008
7. Iwamoto FM et al: Clinical relevance of 1p and 19q deletion for patients with WHO grade 2 and 3 gliomas. J Neurooncol. 88(3):293-8, 2008
8. Louis DN et al (eds): WHO Classification of Tumours of the Central Nervous System: Anaplastic Astrocytoma. Lyon, France: IARC Press. 30-2, 2007

https://CafePezeshki.IR

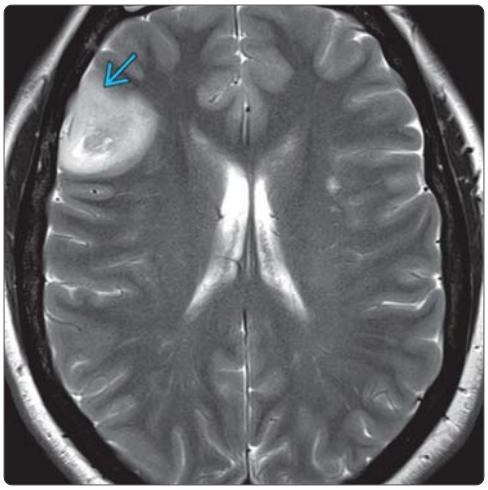

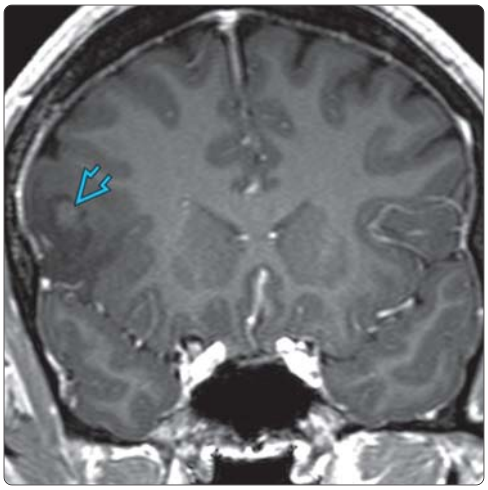

(Left) *Axial T2 MR in a 47-year-old female shows a heterogeneously hyperintense right frontal lobe mass* ⇨ *centered in the white matter with involvement of the overlying cortex. Although the mass appears discrete, tumor cells often extend beyond the signal abnormality.* **(Right)** *Coronal T1 C+ in the same patient shows focal enhancement* ⇨ *within the mass. The enhancement pattern of anaplastic astrocytoma is variable, from no enhancement to patchy or nodular enhancement. Most AAs do not enhance.*

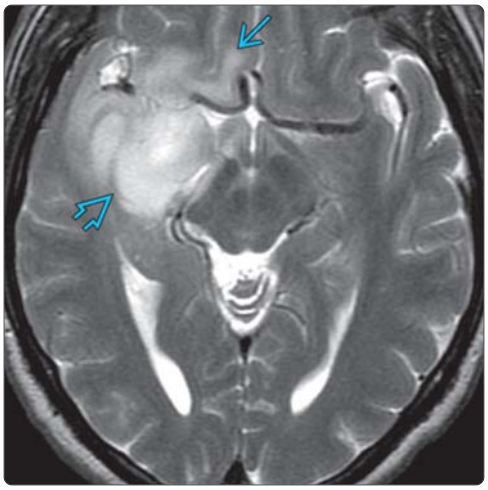

(Left) *Axial T2 MR in a 62-year-old man shows an infiltrative, hyperintense mass in the right temporal lobe* ⇨ *with extension to the inferior frontal lobe* ⇨*. No enhancement was present on the enhanced images. Anaplastic astrocytoma often resembles the more benign diffuse astrocytoma.* **(Right)** *Axial NECT shows a hemorrhagic mass in the right frontal lobe with surrounding low density and mass effect. Hemorrhage is seen in both anaplastic astrocytoma and GBM but is more common in the grade IV GBM.*

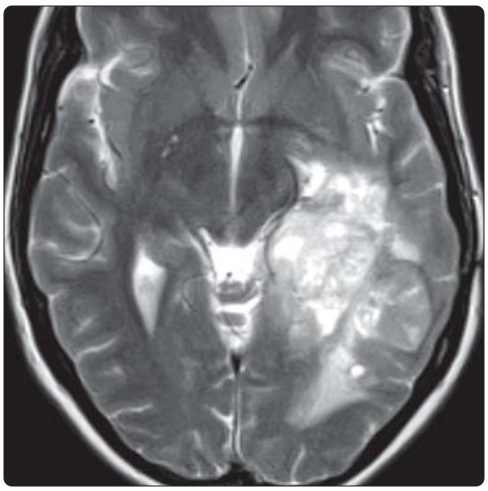

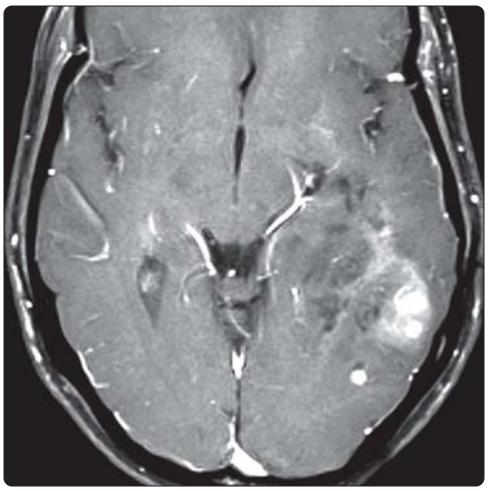

(Left) *Axial T2WI MR shows a heterogeneously hyperintense mass in the left posterior temporal and occipital lobes in a patient with a previously treated low-grade (diffuse) astrocytoma.* **(Right)** *Axial T1WI C+ MR in the same patient shows heterogeneous enhancement of the mass, a new finding in this patient with a grade II astrocytoma and clinical deterioration. Repeat biopsy disclosed a grade III astrocytoma. New enhancement in a lower grade astrocytoma is almost always malignant degeneration.*

https://CafePezeshki.IR

KEY FACTS

TERMINOLOGY

- Rapidly enlarging malignant astrocytic tumor characterized by necrosis and neovascularity
- Most common of all primary intracranial neoplasms

IMAGING

- Best imaging clue: Thick, irregularly enhancing rind of neoplastic tissue surrounding necrotic core
- Heterogeneous, hyperintense mass with adjacent tumor infiltration/vasogenic edema
- Necrosis, cysts, hemorrhage, fluid/debris levels, flow voids (neovascularity) may be seen
- Supratentorial white matter most common location
  - Cerebral hemispheres > brainstem > cerebellum
- Viable tumor extends far beyond signal changes

TOP DIFFERENTIAL DIAGNOSES

- Abscess
- Metastasis
- Primary CNS lymphoma
- Anaplastic astrocytoma
- Tumefactive demyelination
- Subacute ischemia

PATHOLOGY

- 2 types: Primary (de novo) and secondary (degeneration from lower grade astrocytoma)
- Necrosis and microvascular proliferation are hallmarks
- WHO grade IV

CLINICAL ISSUES

- Symptoms vary with location: Seizures, focal neurologic deficits common
- Peak: 45-75 years, but may occur at any age
- Represents 12-15% of all intracranial neoplasms
- 60-75% of astrocytomas
- Relentless progression, survival often < 1 year

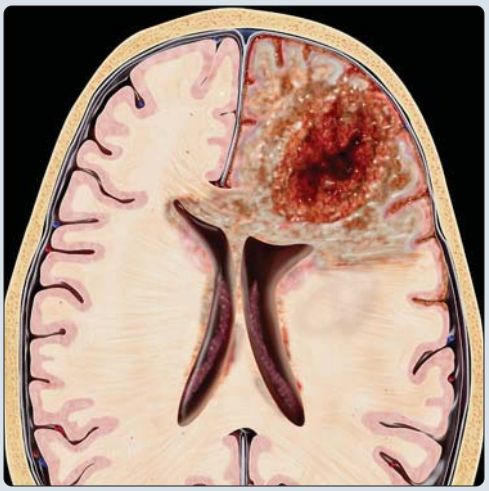

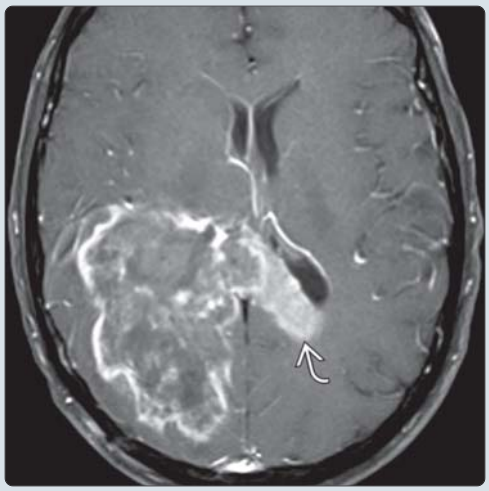

(Left) *Axial graphic shows a centrally necrotic infiltrating mass with extension across the corpus callosum; a peripheral rind of tumor is seen surrounding the necrotic core, typical of GBM.* **(Right)** *Axial T1WI C+ FS MR in a 60-year-old man with acute onset of seizures shows a heterogeneously enhancing occipital lobe mass with central necrosis and extension across the splenium of the corpus callosum, characteristic of GBM. The frontal and temporal lobes are the most common locations for GBM.*

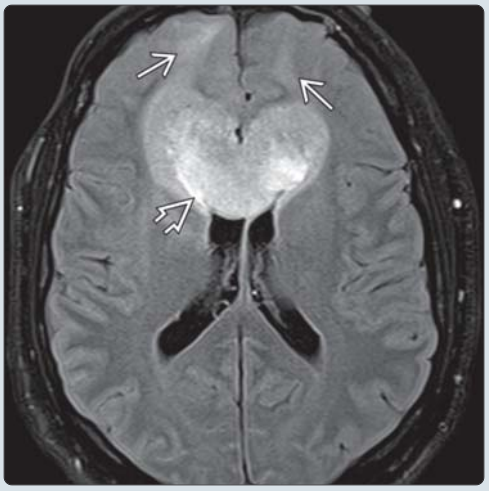

(Left) *Axial FLAIR MR shows a heterogeneously hyperintense mass crossing the corpus callosum genu with signal abnormality extending into the frontal lobe subcortical white matter. Viable tumor cells may extend beyond the area of MR signal abnormality.* **(Right)** *Axial T1 C+ FS MR in the same patient shows a thick enhancing rind of tumor that surrounds the necrotic tumor core, characteristic of GBM. Other lesions including lymphoma and demyelination may also involve the corpus callosum.*

https://CafePezeshki.IR

TERMINOLOGY

Synonyms

- Grade IV astrocytoma, malignant astrocytoma, glioblastoma multiforme (GBM)

Definitions

- Rapidly enlarging malignant astrocytic tumor characterized by necrosis and neovascularity
- Most common of all primary intracranial neoplasms

IMAGING

General Features

- Best diagnostic clue
  - Thick, irregularly enhancing rind of neoplastic tissue surrounding necrotic core
- Location
  - Supratentorial white matter (WM) most common
    - Frontal, temporal, parietal > occipital lobes
  - Cerebral hemispheres > brainstem > cerebellum
  - Basal ganglia/thalamus less common
  - Brainstem, cerebellum more common in children
- Morphology
  - Poorly marginated, diffusely infiltrating necrotic hemispheric mass
  - Tumor typically crosses WM tracts to involve contralateral hemisphere
    - Corpus callosum ("butterfly" glioma)
    - Anterior and posterior commissures
  - Rarely may invade meninges
  - Rarely may be multifocal (~5%)

CT Findings

- NECT
  - Irregular isodense or hypodense mass with central hypodensity representing necrosis
  - Marked mass effect and surrounding edema/tumor infiltration
  - Hemorrhage not uncommon
  - Ca++ rare (related to low-grade tumor degeneration)
- CECT
  - Strong, heterogeneous, irregular rim enhancement

MR Findings

- T1WI
  - Irregular isointense, hypointense WM mass
  - Necrosis, cysts, and thick irregular margin common
  - May have subacute hemorrhage
- T2WI
  - Heterogeneous, hyperintense mass with adjacent tumor infiltration/vasogenic edema
  - Necrosis, cysts, hemorrhage, fluid/debris levels, flow voids (neovascularity) may be seen
  - Viable tumor extends far beyond signal changes
- FLAIR
  - Heterogeneous, hyperintense mass with adjacent tumor infiltration/vasogenic edema
- T2* GRE
  - Susceptibility artifact related to blood products
- DWI
  - Lower measured ADC than low-grade gliomas
  - Variable diffusion restriction in solid portions of tumor
- PWI
  - Elevated maximum relative cerebral blood volume compared to low grade
  - Elevated permeability compared to low grade
- T1WI C+
  - Thick, irregular rind of enhancement surrounding central necrosis typical
  - Enhancement may be solid, ring, nodular, or patchy
- MRS
  - Decreased NAA, myoinositol
  - Elevated choline, lactate/lipid peak (1.33 ppm)
- Diffusion tensor imaging (DTI) can improve surgical planning

Nuclear Medicine Findings

- PET
  - Malignant tumors have high glucose metabolism and avidly accumulate FDG
  - Tumor:WM > 1.5 and tumor:gray matter (GM) > 0.6 suggests high-grade tumors

Imaging Recommendations

- Best imaging tool
  - Contrast-enhanced MR is most sensitive
  - Newer techniques help improve diagnosis/biopsy accuracy: MRS, perfusion, hypoxia imaging, DTI

DIFFERENTIAL DIAGNOSIS

Abscess

- Ring enhancement typically thinner than GBM
- T2 hypointense rim, diffusion restriction is typical
- MRS may show succinate, amino acids

Metastasis

- Typically multiple lesions at gray-white junctions
- Round > infiltrating lesion
- Single lesion may be indistinguishable

Primary CNS Lymphoma

- Periventricular enhancing mass
- Often crosses corpus callosum
- Typically isointense/hypointense on T2WI
- Necrosis common in AIDS-related lymphoma

Anaplastic Astrocytoma

- Often nonenhancing WM mass
- Enhancement may indicate degeneration to GBM
- May be indistinguishable

Tumefactive Demyelination

- Often incomplete, horseshoe-shaped enhancement, open towards cortex
- Lesions in typical locations; younger patients

Subacute Ischemia

- Typical vascular territory (MCA, PCA, ACA)
- May have mass effect and enhancement (gyriform)
- Follow-up imaging may be helpful to differentiate

https://CafePezeshki.IR

Status Epilepticus

- Active seizures may cause signal abnormality and enhancement
- Enhancement often diffuse, affecting GM and WM
- Clinical history of seizures

Arteriovenous Malformation (AVM)

- Multiple flow voids with minimal mass effect
- If associated with hemorrhage, may mimic GBM

PATHOLOGY

General Features

- Etiology
  - 2 types: Primary (de novo) and secondary (degeneration from lower grade astrocytoma)
    - Genetically distinct, same appearance
  - Spreads by creating "permissive environment"
  - Rare cases related to irradiation
- Genetics
  - **Primary GBM** (de novo)
    - Older patients (mean = 62 years), biologically more aggressive
    - Develops de novo (without preexisting lower grade tumor), likely from neural stem cell
    - Amplification, overexpression of *EGFR*, *MDM2*
    - *PTEN* mutation (up to 40% of cases)
    - Chromosome 10p loss of heterozygosity (LOH)
    - Represent > 90% of GBMs
  - **Secondary GBM** (degeneration from lower grade)
    - Younger patients (mean = 45 years), less aggressive than primary GBM
    - Develops from lower grade astrocytoma (usually 4-5 years of progression)
    - *TP53, IDH1* mutations
    - *PDGFR* amplification, overexpression
    - Chromosomes 10q, 17p LOH
    - Increased telomerase activity and *hTERT* expression
    - Represent < 10% of GBMs
- Associated abnormalities
  - Occurs sporadically or as part of heritable tumor syndrome
    - Neurofibromatosis type 1, Li-Fraumeni syndrome (*TP53* mutation)
    - Turcot syndrome, Ollier disease, Maffucci syndrome
  - Giant cell glioblastoma, histologic variant of GBM (5%), slightly improved prognosis

Staging, Grading, & Classification

- WHO grade IV

Gross Pathologic & Surgical Features

- Reddish-gray "rind" of tumor surrounds necrotic core
  - Necrosis is hallmark of GBM
- Most GBMs have marked vascularity, ± gross hemorrhage

Microscopic Features

- Necrosis and microvascular proliferation are hallmarks
- Pleomorphic astrocytes, marked nuclear atypia, numerous mitoses
- High MIB-1 (proliferation index): > 10%

CLINICAL ISSUES

Presentation

- Most common signs/symptoms
  - Varies with location: Seizures, focal neurologic deficits common
  - Increased intracranial pressure, mental status change
  - Typically short duration of symptoms (< 3 months)

Demographics

- Age
  - Peak 45-75 years, but may occur at any age
- Gender
  - Male predominance (M:F = 1.3:1)
- Epidemiology
  - Most common primary brain tumor
  - Represents 12-15% of all intracranial neoplasms
  - 60-75% of astrocytomas
  - 3-4:100,000 per year
  - Multifocal in up to 20% (2-5% synchronous independent tumors)

Natural History & Prognosis

- Relentless progression
- Prognosis is dismal (death typically in 9-12 months)
- Patterns of dissemination
  - Most common: Along WM tracts
  - Less common: Ependymal/subpial spread, CSF metastases, perivascular spaces
  - Uncommon: Dural/skull invasion
  - Rare: Extraneural spread (lung, liver, nodes, bone)
- Independent predictors of longer survival
  - Age (younger: < 45 years), Karnofsky performance scale (higher), extent of resection (gross total vs. subtotal); MGMT methylation status
  - Degree of necrosis, enhancement on preoperative MR

Treatment

- Biopsy/tumor debulking followed by XRT, chemotherapy (temozolomide)
- Newer antiangiogenesis agents, particularly bevacizumab (vascular endothelial growth factor blocker) for recurrent disease

DIAGNOSTIC CHECKLIST

Consider

- Corpus callosum involvement may be seen in GBM, lymphoma, demyelination, or less commonly with metastases

Image Interpretation Pearls

- Viable tumor extends far beyond signal abnormalities

SELECTED REFERENCES

1. Harris RJ et al: MRI perfusion measurements calculated using advanced deconvolution techniques predict survival in recurrent glioblastoma treated with bevacizumab. J Neurooncol. 122(3):497-505, 2015
2. Mabray MC et al: Modern brain tumor imaging. Brain Tumor Res Treat. 3(1):8-23, 2015
3. Pope WB: Genomics of brain tumor imaging. Neuroimaging Clin N Am. 25(1):105-19, 2015
4. Louis DN et al: WHO classification of tumours of the central nervous system: a. Lyon: IARC Press. 33-49, 2007

https://CafePezeshki.IR

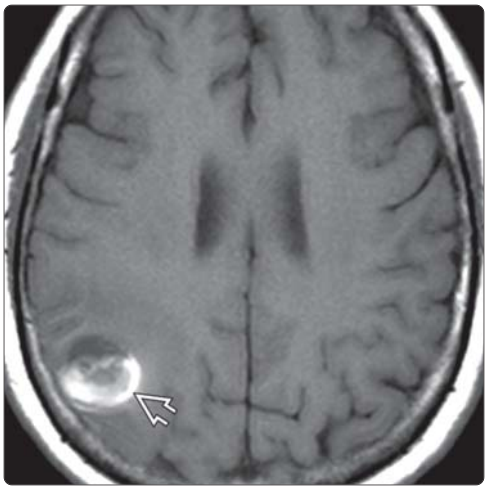

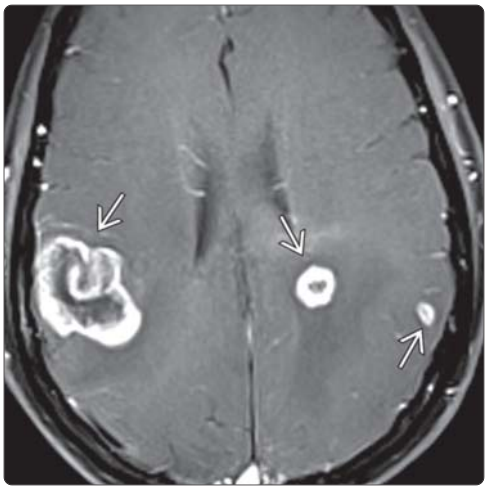

(Left) *Axial T1 MR in a 62-year-old female shows a hemorrhagic mass with areas of T1 shortening related to subacute blood products. Biopsy disclosed GBM. GBM should always be considered in an older adult with no history of hypertension and an unexplained intracranial hemorrhage.* **(Right)** *Axial T1 C+ MR in a 72-year-old male shows 3 separate areas of enhancement representing a multifocal GBM. This rare synchronous presentation of GBM occurs in up to 5% of cases.*

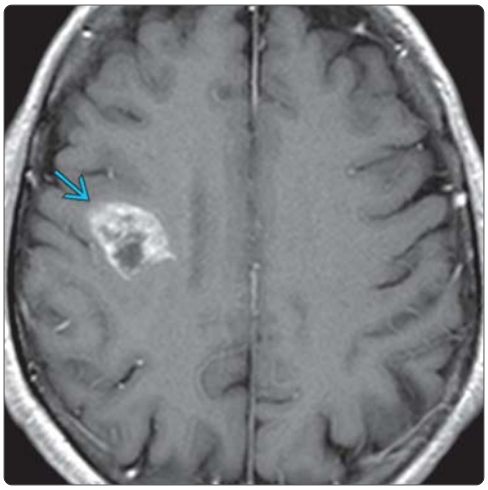

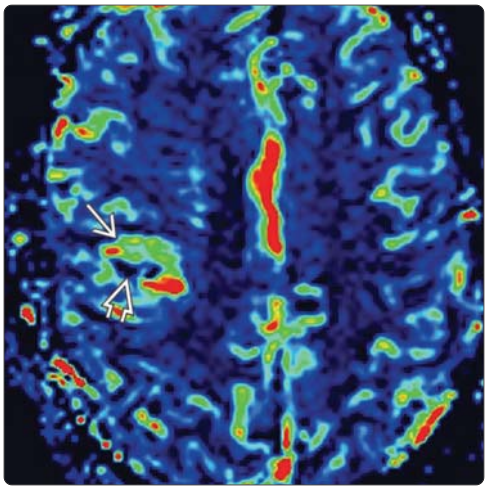

(Left) *Axial T1 C+ MR in a 42-year-old male with new onset seizure shows a peripherally enhancing mass with only mild associated mass effect.* **(Right)** *Axial MR perfusion in the same patient shows an increased rCBV in the solid parts of the tumor and a low rCBV in the necrotic center. Perfusion MR is helpful to provide an accurate preoperative diagnosis. In addition, it is often used to help guide a biopsy if the location of the tumor prevents the patient from undergoing a complete resection.*

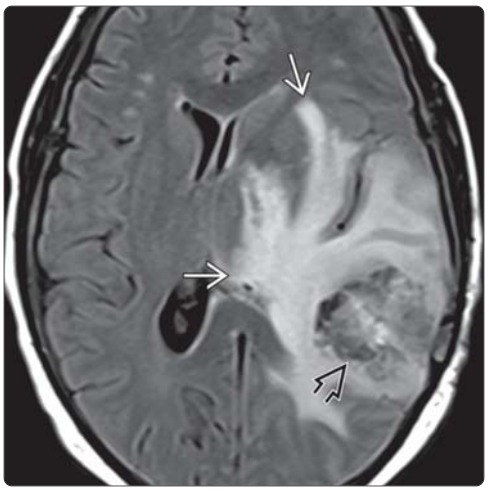

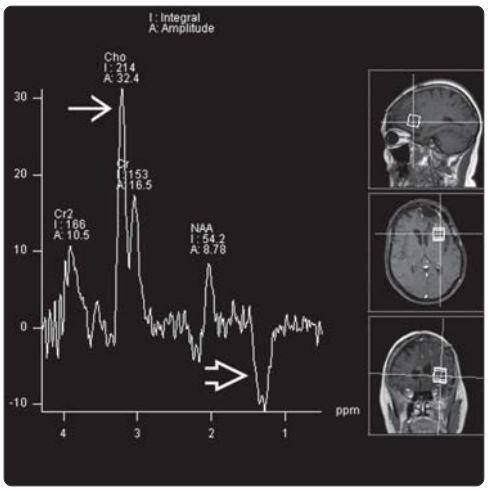

(Left) *Axial FLAIR MR in a patient with GBM shows a heterogeneous mass and the typical extensive surrounding signal abnormality that represents a combination of tumor cells and vasogenic edema. Pathologically, tumor cells are found beyond the regions of signal abnormality.* **(Right)** *MRS in a patient with recurrent GBM shows a classic malignant tumor spectrum with a markedly elevated choline (Cho), a low NAA at 2.02 ppm, and an inverted lactate peak at 1.33.*

https://CafePezeshki.IR

KEY FACTS

TERMINOLOGY

- Rare glioblastoma variant with both glial & mesenchymal elements
- May be primary or secondary (sarcomatous growth in recurrent glioblastoma [GBM])

IMAGING

- Heterogeneously enhancing mass with dural invasion, ± skull involvement
- May be indistinguishable from GBM
- Temporal > parietal > frontal > occipital lobes
- Heterogeneous mass related to hemorrhage, necrosis
- Heterogeneous, thick irregular enhancement with central necrosis

TOP DIFFERENTIAL DIAGNOSES

- Glioblastoma (GBM)
- Metastasis
- Hemangiopericytoma
- Malignant meningioma

PATHOLOGY

- Sarcomatous elements thought to arise from transformed vascular elements within GBM
- WHO grade IV

CLINICAL ISSUES

- Most common presenting symptoms: Headache, seizures, focal neurologic deficit
- Typically 5th to 6th decade
- Poor prognosis, median survival 6-12 months
- Extracranial metastases common (15-30%)
- Treatment: Surgery followed by adjuvant XRT, chemotherapy

DIAGNOSTIC CHECKLIST

- Consider gliosarcoma in event of peripheral mass with dural invasion

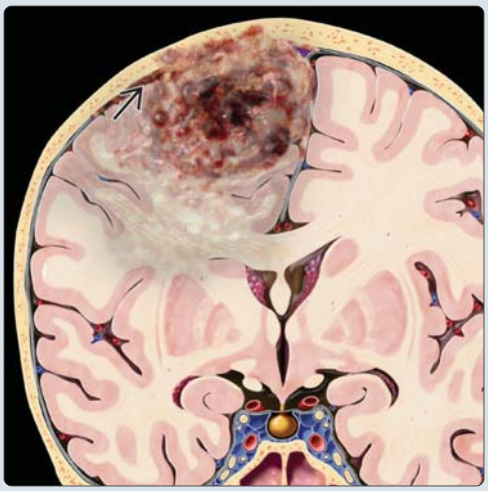

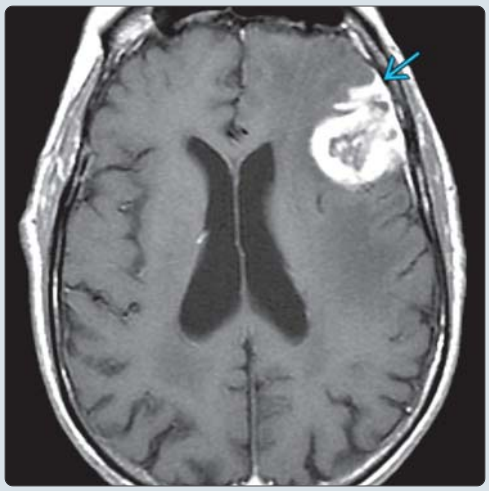

(Left) *Coronal graphic shows a peripherally located, heterogeneous necrotic mass with invasion of the dura ⇨ and the adjacent skull, findings typical of gliosarcoma. The infiltrative tumor involves the corpus callosum as well. Dural invasion with or without skull involvement helps distinguish this glioblastoma (GBM) variant from a typical GBM.* **(Right)** *Axial T1 C+ MR shows a heterogeneous frontal mass with thick enhancement and dural invasion ⇨, typical for gliosarcoma.*

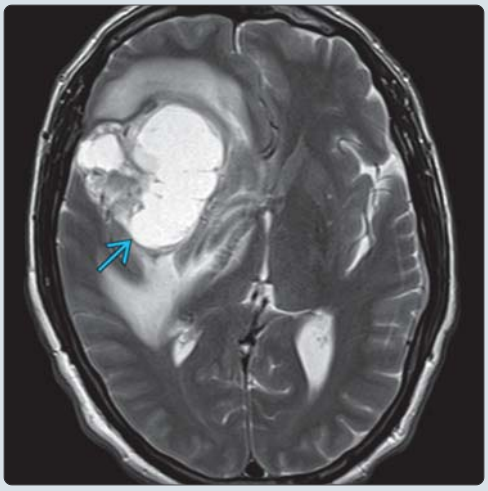

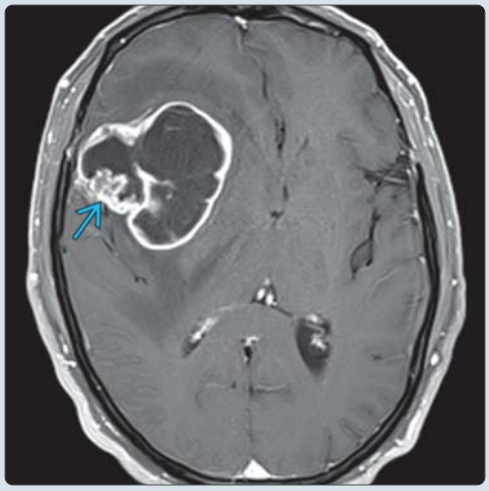

(Left) *Axial T2 MR in a 57-year-old man shows a heterogeneous right frontal lobe mass ⇨.* **(Right)** *Axial T1 C+ FS MR in the same patient shows heterogeneous rim enhancement ⇨ with central low signal related to necrosis. When there is no dural involvement, gliosarcoma is indistinguishable from a typical GBM. Both of these WHO grade IV tumors have a poor prognosis.*

https://CafePezeshki.IR

TERMINOLOGY

Definitions

- Rare glioblastoma variant with both glial and mesenchymal elements
- May be primary or secondary (sarcomatous growth in recurrent glioblastoma [GBM])

IMAGING

General Features

- Best diagnostic clue
  - Heterogeneously enhancing mass with dural invasion, ± skull involvement
  - May be indistinguishable from GBM
- Location
  - Cerebral hemispheres
    - Temporal > parietal > frontal > occipital lobes
  - Rarely posterior fossa or intraventricular
- Size
  - Variable, typically 3-8 cm
- Morphology
  - Infiltrating mass, may have discrete portion

CT Findings

- NECT
  - Heterogeneous mass with surrounding edema
  - Hemorrhage may be seen
- CECT
  - Heterogeneous, thick irregular enhancement
  - May see dural involvement ± skull involvement

MR Findings

- T1WI
  - Heterogeneous, hypointense mass
- T2WI
  - Heterogeneous mass related to hemorrhage, necrosis
  - Marked surrounding edema + infiltrative tumor
- T1WI C+
  - Heterogeneous, thick, irregular enhancement with central necrosis
  - May see dural involvement ± skull involvement

DIFFERENTIAL DIAGNOSIS

Glioblastoma

- Typically indistinguishable
- Heterogeneous mass with hemorrhage, necrosis
- No dural or skull involvement

Metastasis

- Multiple lesions common; primary often known

Hemangiopericytoma

- Extraaxial mass with dural and skull invasion

Malignant Meningioma

- Extraaxial mass with parenchymal invasion

Abscess

- Ring-enhancing lesion with central necrosis
- T2 hypointense rim and DWI+ is typical

PATHOLOGY

General Features

- Etiology
  - Sarcomatous elements thought to arise from transformed vascular elements within GBM
  - Reports suggest XRT induces sarcomatous change

Staging, Grading, & Classification

- WHO grade IV

Gross Pathologic & Surgical Features

- May mimic metastasis or meningioma at surgery
- Firm, lobular mass with central necrosis, ± meningeal invasion

Microscopic Features

- Malignant glial and mesenchymal elements

CLINICAL ISSUES

Presentation

- Most common signs/symptoms
  - Increased intracranial pressure: Headache
- Other signs/symptoms
  - Related to location: Seizure, focal neuro deficit

Demographics

- Age
  - Typically 5th to 6th decade
  - Congenital gliosarcoma has been reported (rare)
- Gender
  - M:F = 2:1
- Epidemiology
  - Rare, accounts for 2-8% of GBM

Natural History & Prognosis

- Poor prognosis, median survival 6-12 months
- Local recurrence typical
- Extracranial metastases common (15-30%)

Treatment

- Surgery followed by adjuvant XRT, ± chemotherapy

DIAGNOSTIC CHECKLIST

Image Interpretation Pearls

- Consider gliosarcoma in event of peripheral mass with dural invasion
- Gliosarcomas may mimic GBM and metastases
- Tumor cells extend beyond enhancing mass

SELECTED REFERENCES

1. McAleer MF et al: Therapeutic management of gliosarcoma in the temozolomide era. CNS Oncol. 4(3):171-8, 2015
2. Blumenthal DT et al: A Phase III study of radiation therapy (RT) and O^6-benzylguanine + BCNU versus RT and BCNU alone and methylation status in newly diagnosed glioblastoma and gliosarcoma: Southwest Oncology Group (SWOG) study S0001. Int J Clin Oncol. ePub, 2014
3. Smith AB et al: From the radiologic pathology archives: mass lesions of the dura: beyond meningioma-radiologic-pathologic correlation. Radiographics. 34(2):295-312, 2014
4. Romero-Rojas AE et al: Primary gliosarcoma of the brain: radiologic and histopathologic features. Neuroradiol J. 26(6):639-48, 2013
5. Kleihues et al: WHO Classification of Tumours of the Central Nervous ma. Lyon: IARC Press. 48-9, 2007

https://CafePezeshki.IR

KEY FACTS

TERMINOLOGY

- Diffusely infiltrating, frequently bilateral glial tumor involving at least 3 lobes
- Infiltrative extent of tumor is out of proportion to histologic and clinical features

IMAGING

- T2 hyperintense infiltrating mass with enlargement of involved structures
  - Typical cerebral hemispheres (75%)
  - Brain architecture enlarged, distorted, but preserved
- Typically no or minimal enhancement
- Enhancement may indicate malignant progression or focus of malignant glioma
- MRS: Increased choline, decreased NAA

TOP DIFFERENTIAL DIAGNOSES

- Arteriolosclerosis
- Vasculitis
- Anaplastic astrocytoma
- Viral encephalitis
- Demyelination

PATHOLOGY

- Usually WHO grade III; range grade II-IV
- Shares many features of diffusely infiltrating astrocytoma
- Rarely, oligodendroglioma is predominant cell type
- Diagnosis typically made on basis of histology and imaging

CLINICAL ISSUES

- Presenting symptoms: Mental status changes, dementia, headaches, seizures, lethargy
- Treatment: Biopsy for diagnosis, ± radiation and chemotherapy
- Peak incidence between 40-50 years, occurs at all ages
- Relentless progression
- Survival ranges from weeks to years
  - Median survival ~ 14 months

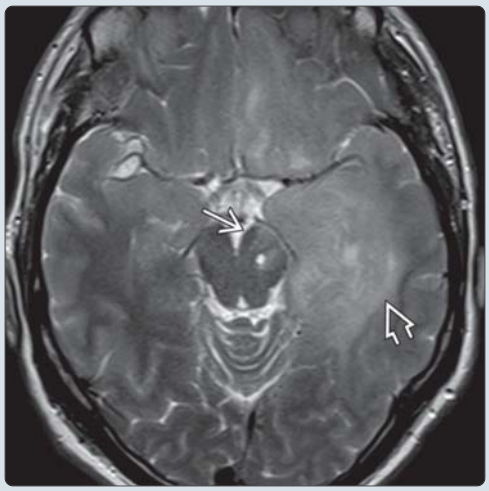

(Left) *Axial graphic shows infiltrating tumor involving the frontal lobes, insulae, and basal ganglia with preservation of the underlying cerebral architecture. Note the focal malignant degeneration.* **(Right)** *Axial T2 MR shows abnormal hyperintensity in the left cerebral peduncle, left temporal and left frontal lobes with blurring of the corticomedullary junctions. There is subtle expansion of the involved structures with relative preservation of the underlying architecture, typical of gliomatosis cerebri.*

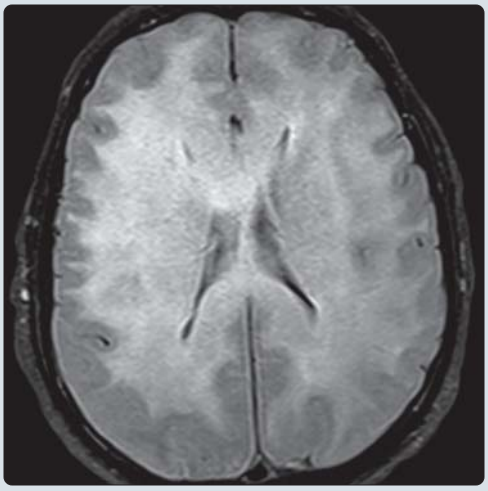

(Left) *Axial FLAIR MR in a 73-year-old male shows diffuse hyperintensity extending throughout the hemispheric supratentorial white matter. Gliomatosis cerebri may mimic a nonneoplastic white matter process, including arteriolosclerosis.* **(Right)** *Axial T1 C+ MR in the same patient shows no enhancement, typical of gliomatosis cerebri. Enhancement often correlates with focal anaplasia or disease progression. Mild sulcal effacement is present. These infiltrative tumors may be WHO grade II through IV.*

https://CafePezeshki.IR

TERMINOLOGY

Abbreviations

- Gliomatosis cerebri (GC)

Synonyms

- Gliomatosis, diffuse cerebral gliomatosis

Definitions

- Diffusely infiltrating, frequently bilateral glial tumor involving at least 3 lobes
- Infiltrative extent of tumor is out of proportion to histologic and clinical features

IMAGING

General Features

- Best diagnostic clue
  - T2 hyperintense infiltrating mass with enlargement of involved structures
- Location
  - Typically hemispheric white matter (WM) involvement (76%), may also involve cortex (19%)
  - 3 lobes, diffuse WM plus
    - Basal ganglia, thalami (75%)
    - Brainstem (52%)
    - Corpus callosum (50%)
    - Cerebellum (29%)
    - Spinal cord (9%)
  - May cross corpus callosum or massa intermedia
- Morphology
  - Infiltrates, enlarges yet preserves underlying brain architecture

CT Findings

- NECT
  - Poorly defined, asymmetric low density (often subtle)
  - Loss of gray-white differentiation with expansion and mild mass effect
- CECT
  - No enhancement typical

MR Findings

- T1WI
  - Isointense or hypointense infiltrating mass
  - Typically homogeneous
- T2WI
  - Homogeneous hyperintense infiltrating mass
  - Mass effect with mild diffuse sulcal and ventricular effacement
  - May cause hydrocephalus (rare)
- FLAIR
  - Homogeneous hyperintense infiltrating mass
- DWI
  - Usually no restriction
- T1WI C+
  - Typically no or minimal enhancement
  - Patchy enhancement rarely
  - Enhancement may indicate malignant progression or focus of malignant glioma
- MRS
  - Marked elevation of myoinositol (mI)
  - Increased choline
  - Decreased NAA
  - ± lactate, lipid peaks at 1.33 ppm (suggests decreased survival)
- Dynamic perfusion MR
  - Low rCBV: Correlates with no vascular hyperplasia
  - High rCBV: Suggests higher grade tumor
- Diffusion tensor imaging
  - Preservation of nerve fibers in GC compared to other tumors

Nuclear Medicine Findings

- FDG PET shows marked hypometabolism

Imaging Recommendations

- Protocol advice
  - Multiplanar contrast-enhanced MR
  - MRS and perfusion imaging may help further characterize

DIFFERENTIAL DIAGNOSIS

Arteriolosclerosis

- Aging brain, microvascular disease
- No mass effect; spares cortex
- Often associated volume loss
- Some cases may be indistinguishable without biopsy

Vasculitis

- Often multifocal areas of ischemia
- DWI positive acutely
- Patchy, multifocal enhancement may be seen
- May be indistinguishable without biopsy

Anaplastic Astrocytoma

- May appear discrete or infiltrating, often less diffuse
- Variable enhancement

Viral Encephalitis

- More acute presentation, history may distinguish
- ± meningeal involvement
- Herpes involves temporal lobes, limbic system

Demyelination

- Usually multiple lesions in typical locations
- Typically lack significant mass effect
- Often enhances, incomplete ring, open at cortex
- May involve WM and deep gray nuclei

Progressive Multifocal Leukoencephalopathy

- Asymmetric T2 hyperintensity in periventricular, subcortical WM
- No or minimal enhancement typical
- Often parietooccipital region, may cross corpus callosum
- Immunosuppressed patients, typically AIDS

Lymphoma

- Periventricular/deep GM enhancing mass in primary CNS lymphoma
  - Corpus callosum involvement classic
  - Isointense/hypointense on T2WI
- Intravascular lymphoma may appear diffusely infiltrating

https://CafePezeshki.IR

Inherited/Acquired Metabolic Disorder

- Metachromatic leukodystrophy (MLD): Confluent periventricular WM T2 hyperintensity
- Alexander disease: Frontal lobe WM hyperintensity and enhancement

PATHOLOGY

General Features

- Etiology
  - Controversial, classified as neoplasm of unknown histogenesis
  - Shares some, but not all, features of diffusely infiltrating astrocytoma
  - Rarely oligodendroglioma is predominant cell type
- Genetics
  - *TP53* mutation similar to diffuse astrocytoma, lower frequency
  - In oligodendroglioma subtype, chromosome 1p and 19q deletions common
  - May have IDH1 mutation

Staging, Grading, & Classification

- Usually WHO grade III (range from grades II-IV)
- Dx typically made on basis of histology and imaging

Gross Pathologic & Surgical Features

- 2 gross pathologic GC types recognized
  - Type 1: Neoplastic overgrowth, expansion of existing structures without circumscribed tumor mass
  - Type 2: Diffuse lesion + focal neoplastic mass with malignant features (may develop from type 1)
- Blurring of gray-white junction borders ± distinct tumor nodule
- Underlying brain architecture preserved
- Diffuse neoplastic overgrowth

Microscopic Features

- Extensive tumor infiltration is disproportionate to histologic features
  - Necrosis and neovascularity typically absent
- Neuroepithelial neoplasm with diffuse invasion of parenchyma with tumor cells
- Elongated glial cells with hyperchromatic nuclei, variable mitoses
- Diffuse infiltration along/between myelinated nerve fibers
- Immunohistochemistry: Often *GFAP*(+), S100(+)
- Ki-67 (proliferation index) = 1-30%

CLINICAL ISSUES

Presentation

- Most common signs/symptoms
  - Mental status changes, dementia, headaches, seizures, lethargy
- Other signs/symptoms
  - Cranial nerve signs, increased intracranial pressure, personality changes
  - Rare: Hydrocephalus

Demographics

- Age
  - Peak incidence between 40-50 years
  - Occurs at all ages, reported in neonates to 83 years
- Gender
  - No gender predominance
- Epidemiology
  - Rare
  - Represents ~ 1% of all astrocytomas

Natural History & Prognosis

- Relentless progression
- Poor prognosis
  - 50% mortality by 1 year
  - 75% by 3 years
- Survival ranges from weeks to years, median survival ~ 14 months
- Karnofsky performance scale ≥ 70 correlates with increased survival
- Ki-67 labeling index may correlate with survival time
- IDH1 mutation correlates with increased survival
- Rarely complicated by hydrocephalus or herniation
- Very rarely GC is complicated by hemorrhage

Treatment

- Stereotaxic biopsy (enhancing nodule, if present)
- Mixed response to chemotherapy, radiation therapy
  - Some reports show increased survival with treatment
- Steroids may help as initial treatment
- Surgical decompression, ventricular shunting occasionally required

DIAGNOSTIC CHECKLIST

Consider

- GC = diffusely infiltrating glial tumor that can be mistaken for nonneoplastic WM disease

Image Interpretation Pearls

- Extensive MR findings and tumor infiltration are disproportionate to histologic features
- MR often underestimates extent of disease when correlated with postmortem findings
- 3 or more contiguous lobes of multiregional involvement characterizes GC

SELECTED REFERENCES

1. Jung TY et al: Gliomatosis cerebri having a poor performance status without recurrence after radiotherapy: a single institutional experience. Clin Neurol Neurosurg. 130:1-5, 2015
2. Kandula S et al: Patterns of presentation and failure in patients with gliomatosis cerebri treated with partial-brain radiation therapy. Cancer. 120(17):2713-20, 2014
3. Chappé C et al: Primary gliomatosis cerebri involving gray matter in pediatrics: a distinct entity? A multicenter study of 14 cases. Childs Nerv Syst. 29(4):565-71, 2013
4. Chen S et al: Gliomatosis cerebri: clinical characteristics, management, and outcomes. J Neurooncol. 112(2):267-75, 2013
5. Kwon MJ et al: Mutated IDH1 is a favorable prognostic factor for type 2 gliomatosis cerebri. Brain Pathol. 22(3):307-17, 2012
6. Park S et al: Gliomatosis cerebri: clinicopathologic study of 33 cases and comparison of mass forming and diffuse types. Clin Neuropathol. 28(2):73-82, 2009
7. Fuller GN et al: WHO Classification of Tumours of the Central Nervous System: Gliomatosis cerebri. Lyon: IARC Press. 50-2, 2007
8. Taillibert S et al: Gliomatosis cerebri: a review of 296 cases from the ANOCEF database and the literature. J Neurooncol. 76(2):201-5, 2006

https://CafePezeshki.IR

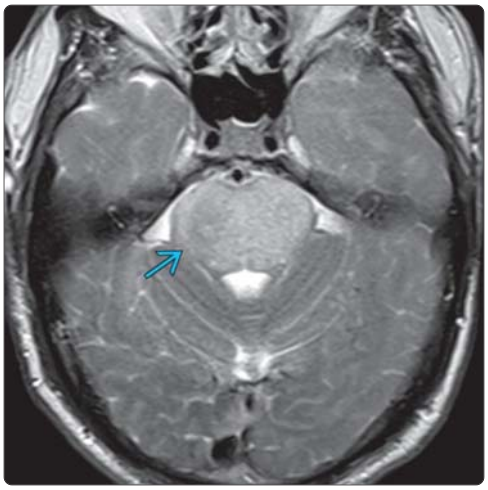

(Left) *Axial T2 MR shows abnormal hyperintensity throughout the pons ⇨ with associated enlargement. Imaging mimics a diffuse pontine glioma. Gliomatosis cerebri most commonly involves the bilateral cerebral hemispheres, though extension to the brainstem is present in approximately 50% of patients.* **(Right)** *Axial NECT shows loss of the normal gray-white interfaces and sulcal effacement ⇨. CT diagnosis of gliomatosis cerebri is difficult, as the study may appear normal.*

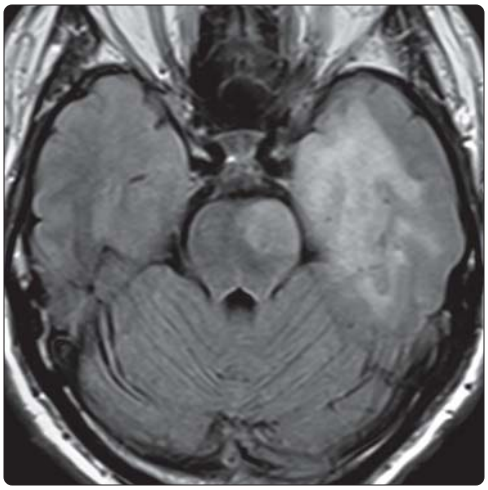

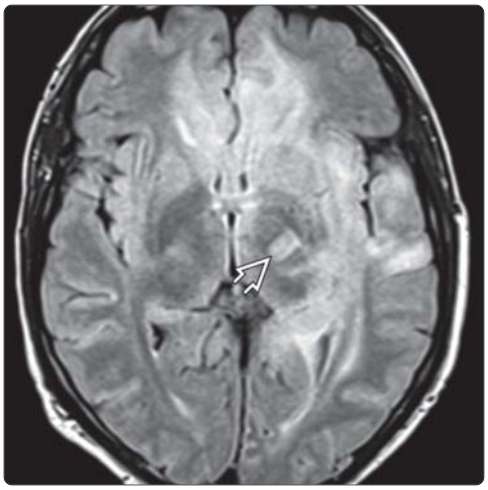

(Left) *Axial FLAIR MR shows abnormal hyperintensity in the left brainstem with extension into the temporal lobe. Note the subtle expansion of the involved structures with relative preservation of the underlying architecture, typical of gliomatosis cerebri.* **(Right)** *Axial FLAIR MR in the same patient shows hyperintensity in the left temporal and parietal lobes, corpus callosum, frontal lobes, & thalamus ⇨. Usually a WHO grade III tumor, biopsy revealed a grade IV tumor in this patient.*

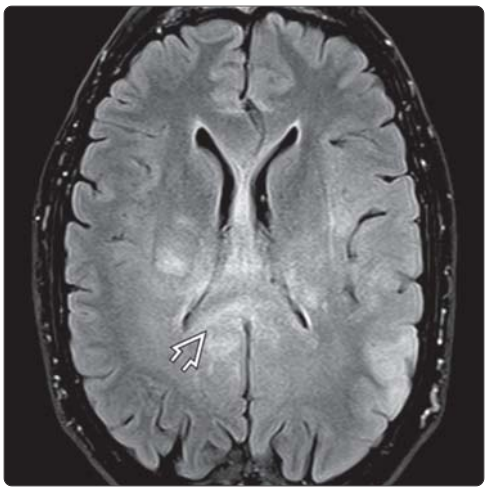

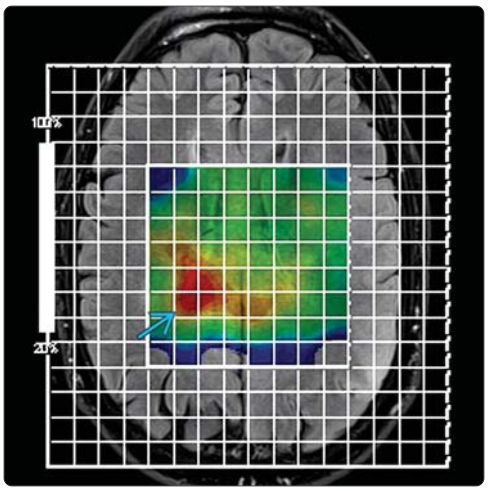

(Left) *Axial FLAIR MR in a patient with gliomatosis cerebri, WHO grade III, shows hyperintensity in the left temporal and parietal lobes, corpus callosum ⇨, and bilateral basal ganglia.* **(Right)** *Axial MRS choline color map in the same patient shows elevated choline ⇨ as the red area in the right hemisphere. A biopsy in this region would likely reveal a higher grade tumor. MRS may appear normal or show elevated choline and decreased NAA. Elevated choline and presence of lactate correlates with decreased survival.*

https://CafePezeshki.IR

KEY FACTS

TERMINOLOGY

- Pilocytic astrocytoma (PA): Well-circumscribed, slow-growing tumor, often with cyst and mural nodule

IMAGING

- Cystic cerebellar mass with enhancing mural nodule
  - Arises from cerebellar hemisphere and compresses 4th ventricle
- Enlarged optic nerve/chiasm/tract with variable enhancement
- Cerebellum (60%) > optic nerve/chiasm (25-30%) > adjacent to 3rd ventricle > brainstem
- Well circumscribed with little to no edema
- Aggressive appearance (enhancement and MRS) of tumor is misleading

TOP DIFFERENTIAL DIAGNOSES

- Medulloblastoma (PNET-MB)
- Ependymoma
- Ganglioglioma
- Hemangioblastoma
- Demyelination

PATHOLOGY

- WHO grade I
- 15% of neurofibromatosis type 1 (NF1) patients develop PAs, most commonly in optic pathway
- Up to 1/3 of patients with optic PAs have NF1
- Most common primary brain tumor in children

CLINICAL ISSUES

- Clinical presentation varies with location
  - Headache, nausea, vomiting most common
  - Visual loss (optic pathway lesions)
  - Ataxia, cerebellar signs (cerebellar lesions)
- Peak incidence: 5-15 years of age
- Slowly growing tumor with very good prognosis
- Median survival rates at 20 years > 70%

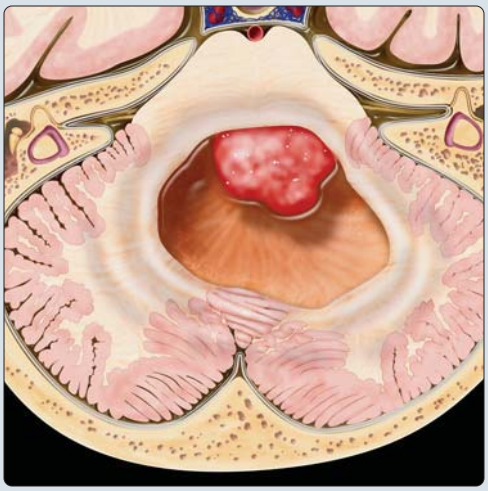

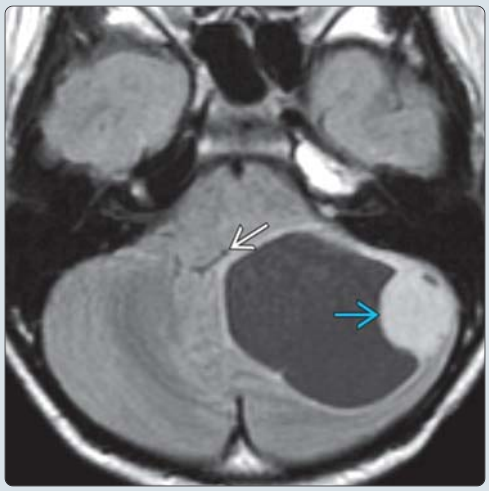

(Left) *Axial graphic shows the characteristic cyst with mural nodule appearance of a posterior fossa pilocytic astrocytoma (PA). These WHO grade I tumors most commonly arise in the cerebellar hemispheres and compress the 4th ventricle.* **(Right)** *Axial FLAIR MR shows a classic cyst with mural nodule appearance ⇨ of a cerebellar PA in a child. Note the typical lack of surrounding edema in the adjacent cerebellum. Mass effect on the 4th ventricle ➡ with associated hydrocephalus is common.*

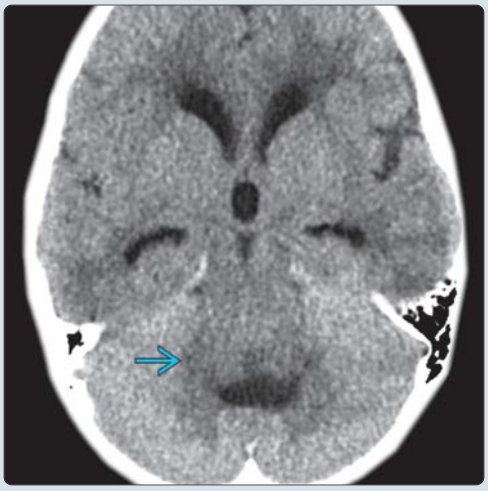

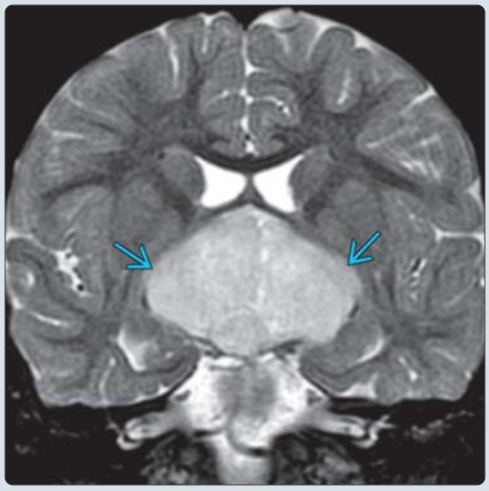

(Left) *Axial NECT shows a cystic and solid isodense posterior fossa mass ⇨ causing obstructive hydrocephalus. The lack of increased density helps to differentiate this PA from a medulloblastoma.* **(Right)** *Coronal T2WI MR shows a hyperintense hypothalamic/chiasmatic mass ⇨ with no surrounding edema. PAs in this location have variable enhancement. Optic pathway PAs are highly associated with neurofibromatosis 1 (NF1): ≤ 1/3 of patients with an optic pathway PA have NF1.*

https://CafePezeshki.IR

TERMINOLOGY

Abbreviations

- Pilocytic astrocytoma (PA), juvenile pilocytic astrocytoma (JPA)

Definitions

- Pilocytic astrocytoma: Well-circumscribed, slow-growing tumor, often with cyst and mural nodule
- Characterized by hair-like cytoplasmic (Rosenthal) fibers &/or eosinophilic granular bodies in stacked bipolar cells

IMAGING

General Features

- Best diagnostic clue
  - Cystic cerebellar mass with enhancing mural nodule
  - Enlarged optic nerve/chiasm/tract with variable enhancement
- Location
  - Cerebellum (60%) > optic nerve/chiasm (25-30%) > adjacent to 3rd ventricle > brainstem
- Size
  - Large lesions in cerebellum, often > 3 cm
  - Optic nerve lesions typically smaller
- Morphology
  - Overall morphology often determined by cystic component
  - Well circumscribed with little to no adjacent T2 prolongation
  - Optic nerve tumors elongate and widen nerve causing buckling in orbit: Dotted i appearance

CT Findings

- NECT
  - Discrete cystic-solid mass
  - May have little or no surrounding edema
  - Solid component hypo- to isodense to gray matter (GM)
  - Ca++ in 20%, hemorrhage uncommon
  - Often causes obstructive hydrocephalus, location dependent
- CECT
  - > 95% enhance (patterns vary)
    - 50% nonenhancing cyst, strongly enhancing mural nodule
    - 40% solid with necrotic center, heterogeneous enhancement
    - 10% solid, homogeneous
    - Cyst may accumulate contrast on delayed images
    - Cyst wall may have some enhancement

MR Findings

- T1WI
  - Solid portions iso-/hypointense to GM
  - Cyst contents iso- to slightly hyperintense to cerebrospinal fluid (CSF)
- T2WI
  - Solid portions hyperintense to GM
  - Cyst contents iso-/hyperintense to CSF
  - Optic pathway hyperintense to GM
- FLAIR
  - Solid portions hyperintense to GM
  - Cyst contents do not suppress: Hyperintense to CSF
  - Margins of chiasmatic/hypothalamic tumors in patients with neurofibromatosis type 1 (NF1) difficult to resolve
- DWI
  - Solid tumor has similar diffusivity to GM
- T1WI C+
  - Intense but heterogeneous enhancement of solid portion
  - Cyst wall occasionally enhances
  - Rare: Leptomeningeal metastases
  - Optic pathway: Variable enhancement
- MRS: Aggressive-appearing metabolite pattern
  - ↑ choline, ↓ NAA, ↑ lactate
  - Paradoxical finding: MRS does not accurately reflect clinical behavior of tumor

Ultrasonographic Findings

- Grayscale ultrasound
  - Solid components are hyperechoic relative to brain parenchyma
  - Cysts may contain debris

Angiographic Findings

- Conventional: Avascular mass
  - Occasional neovascularity seen in solid portion

Nuclear Medicine Findings

- PET
  - 18F-fluorodeoxyglucose (FDG) studies show increased tumor metabolism in PAs
  - Paradoxical finding: PET does not accurately reflect histologic behavior of tumor

Imaging Recommendations

- Best imaging tool
  - Contrast-enhanced MR
- Protocol advice
  - Multiplanar or 3D volume post-contrast imaging key to show structure of origin and degree of extension

DIFFERENTIAL DIAGNOSIS

Medulloblastoma (PNET-MB)

- Hyperdense enhancing midline mass fills 4th ventricle
- Solid components T2 isointense to GM; ↓ ADC
- Younger patient age (2-6 years)

Ependymoma

- "Plastic" tumor, extends out 4th ventricle foramina
- Ca++, cysts, hemorrhage common
- Heterogeneous enhancement

Ganglioglioma

- Cortically based cystic and solid enhancing mass
- Ca++ common
- Typically located in temporal or frontal lobes

Hemangioblastoma

- Large cyst with small enhancing mural nodule at periphery of cerebellum, associated with feeding vessel
- **Adult** tumor
- Associated with von Hippel-Lindau disease

https://CafePezeshki.IR

Pilomyxoid Astrocytoma

- Chiasmatic/hypothalamic tumor in infants
- Solid and enhancing
- More likely to disseminate, more aggressive

Demyelination/Inflammation

- Optic neuritis in acute multiple sclerosis, acute disseminated encephalitis, pseudotumor can mimic optic nerve glioma
- "Tumefactive" MS can mimic hemispheric PA

PATHOLOGY

General Features

- Etiology
  - Astrocytic precursor cell
- Genetics
  - Syndromic: Association with NF1
    - 15% of NF1 patients develop PAs, most commonly in optic pathway
    - Up to 1/3 of patients with optic pathway PAs have NF1
  - Sporadic: No definite loss of tumor suppressor gene
- Associated abnormalities
  - Major source of morbidity in NF1
  - Frequently causes obstructive hydrocephalus
  - Gross appearance and clinical impact varies with location

Staging, Grading, & Classification

- WHO grade I

Gross Pathologic & Surgical Features

- Well-circumscribed, soft, gray mass ± cyst

Microscopic Features

- Classic biphasic pattern of 2 astrocyte populations
  - Compacted bipolar cells with Rosenthal fibers
  - Loose-textured multipolar cells with microcysts, eosinophilic granular bodies
- Highly vascular with glomeruloid features
- May have aggressive features, but still grade I tumor
- MIB-1 proliferation index ~ 1%
- GFAP(+), IDH1(-)

CLINICAL ISSUES

Presentation

- Most common signs/symptoms
  - Headache, nausea, and vomiting (consequence of hydrocephalus and increased intracranial pressure)
  - Visual loss (optic pathway lesions)
  - Ataxia, cerebellar signs (cerebellar lesions)
  - Seizures, focal neurological deficit, mass effect (cerebral hemisphere lesion)
- Clinical profile
  - Children, 5-15 years old
  - Prolonged duration of symptoms on close inquiry: Months to years

Demographics

- Age
  - > 80% under 20 years
  - Peak incidence: 5-15 years of age
    - Older than children with medulloblastoma
- Gender
  - M = F
- Epidemiology
  - 5-10% of all gliomas
  - Most common primary brain tumor in children (up to 25% of total)
  - Represents 85% of posterior fossa astrocytomas in children

Natural History & Prognosis

- Slowly growing, mass effect accommodated
  - Rarely spontaneously involute without treatment or after partial resection or biopsy
- Tumor may spread through subarachnoid space in rare cases (but is still WHO grade I)
- 10-year survival > 90%
- Median survival rates at 20 years > 70%
- Rare reports of malignant features associated with prior radiation therapy

Treatment

- Cerebellar or hemispheric: Resection
  - Adjuvant chemotherapy or radiation only if residual progressive unresectable tumor
- Optic/chiasmatic/hypothalamic: Often none
  - Stable or slowly progressive tumors watched
  - Debulking or palliative surgery considered after vision loss
  - Radiation or chemotherapy for rapidly progressive disease

DIAGNOSTIC CHECKLIST

Consider

- Cerebellar or supratentorial cyst with enhancing nodule in child, most likely PA
- Generally not reasonable diagnostic consideration in adults
- Rarely presents with CSF metastatic disease or as hemorrhagic mass

Image Interpretation Pearls

- Differentiate cerebellar lesions from medulloblastoma
  - PA arises from hemisphere, compresses 4th ventricle, circumscribed, DWI similar to GM
- Aggressive appearance of PA is misleading
  - Enhancing intraaxial tumor with cystic change in child is most likely PA
- MRS pattern of PA is contradictory to clinical behavior

SELECTED REFERENCES

1. Alkonyi B et al: Differential imaging characteristics and dissemination potential of pilomyxoid astrocytomas versus pilocytic astrocytomas. Neuroradiology. 57(6):625-38, 2015
2. Collins VP et al: Pilocytic astrocytoma: pathology, molecular mechanisms and markers. Acta Neuropathol. 129(6):775-88, 2015
3. Nabavizadeh SA et al: High accuracy of arterial spin labeling perfusion imaging in differentiation of pilomyxoid from pilocytic astrocytoma. Neuroradiology. 57(5):527-33, 2015
4. Mazloom A et al: Outcome of patients with pilocytic astrocytoma and leptomeningeal dissemination. Int J Radiat Oncol Biol Phys. 84(2):350-4, 2012
5. Burger PC et al: Pilocytic astrocytoma. In Louis DN et al: Tumours of the vous System. Lyon: IARC Press. 14-21, 2007

https://CafePezeshki.IR

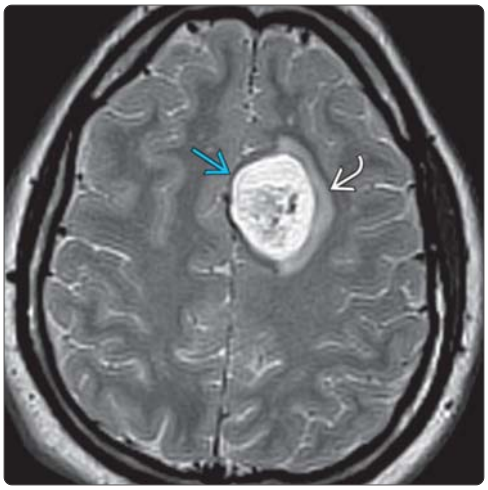

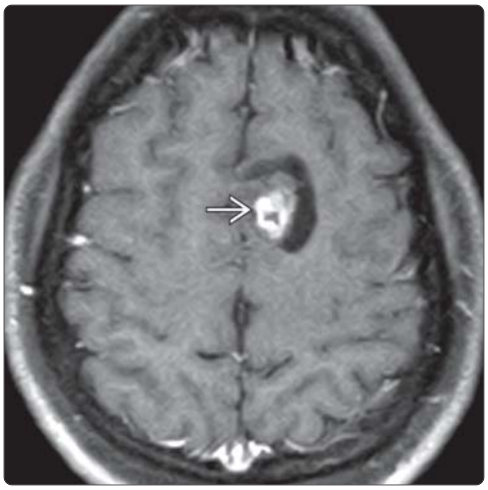

(Left) *Axial T2 MR shows a heterogeneously hyperintense frontal mass ⇨ with mild peritumoral edema ➡ in a 19-year-old female.* **(Right)** *Axial T1WI C+ MR in the same patient shows central enhancement ➡ of the tumor and a cystic portion. Pilocytic astrocytomas are most common in the posterior fossa (60%) and optic nerve/chiasm (25-30%). Within the supratentorial brain, PAs are commonly adjacent to the 3rd ventricle. Hemispheric PAs are rare. The cystic and solid appearance is typical of these WHO grade I tumors.*

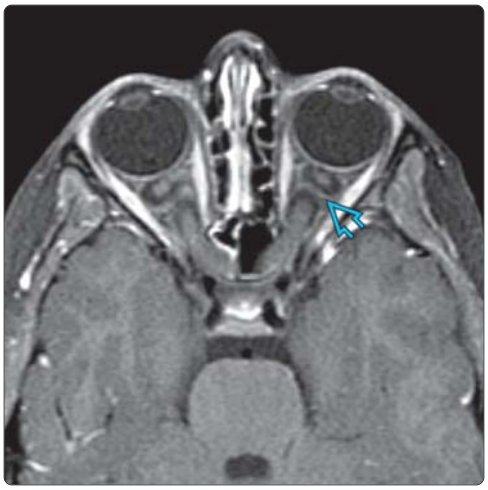

(Left) *Axial T1WI C+ MR with fat saturation in an NF1 patient with bilateral optic nerve gliomas shows the characteristic dotted i appearance of the intraorbital optic nerves ⇨ caused by buckling of the elongated nerve just proximal to the globe.* **(Right)** *Coronal T1 C+ FS MR image shows a markedly enhancing optic nerve glioma ➡. Pilocytic astrocytomas of the optic nerve have variable enhancement, from none to striking enhancement. Optic pathway PAs are highly associated with NF1.*

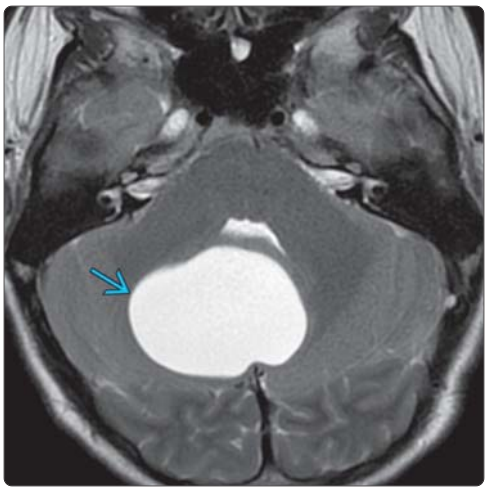

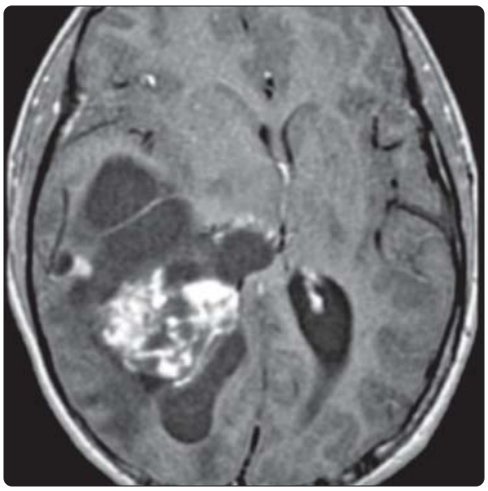

(Left) *Axial T2 MR in a teenage male with cerebellar symptoms shows a discrete T2 hyperintense posterior fossa mass ⇨. The lack of surrounding edema is typical of pilocytic astrocytoma. An enhancing mural nodule was present on post-contrast images.* **(Right)** *Axial T1WI C+ MR shows a large, cystic and solid mass in a child. Note the associated mass effect. The large size and heterogeneous enhancement might suggest a more aggressive histology. At resection, this proved to be a WHO grade I PA.*

https://CafePezeshki.IR

KEY FACTS

TERMINOLOGY

- Pilomyxoid astrocytoma (PMA): More aggressive, myxoid variant of pilocytic astrocytoma (PA)
  - High risk of local recurrence, cerebrospinal fluid (CSF) dissemination

IMAGING

- 60% suprasellar (large, bulky H-shaped mass in hypothalamus/optic chiasm, medial temporal lobes)
- 40% outside diencephalon (hemisphere, ventricles)
- Grossly well circumscribed, little/no edema
- Enhances strongly
- 20% show intratumoral hemorrhage

TOP DIFFERENTIAL DIAGNOSES

- Pilocytic astrocytoma
- Low-grade diffuse astrocytoma
- Glioblastoma multiforme

PATHOLOGY

- WHO grade II (typical PA is WHO grade I)

CLINICAL ISSUES

- Typical: Infants, young children (< 4 years)
- Less common: Older children, young adults
- 5-10% of cases initially diagnosed as PAs may actually be PMAs
  - Especially if tumor is hemorrhagic, presents in very young child, or shows CSF dissemination

DIAGNOSTIC CHECKLIST

- Consider PMA if
  - Infant or young child has large/bulky or hemorrhagic H-shaped suprasellar mass
  - Presumed PA in any patient who has atypical imaging (e.g., hemorrhage, metastases)

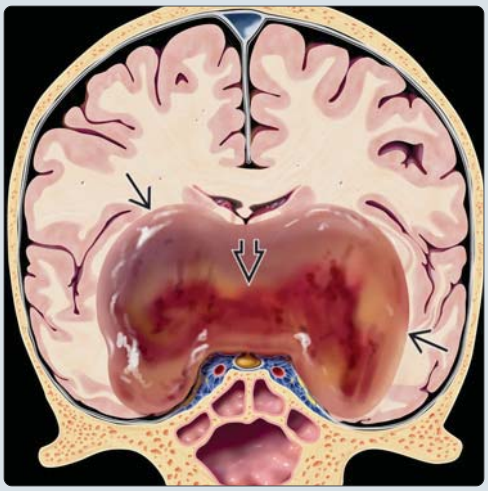

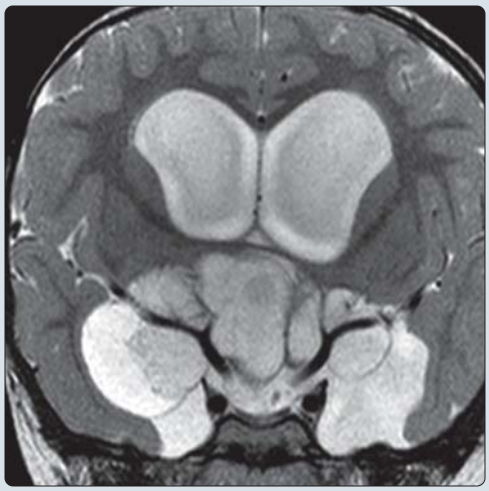

(Left) *Coronal graphic depicts pilomyxoid astrocytoma (PMA). Note the large, bulky H-shaped mass ⇨ centered on the hypothalamic/chiasmatic region & extending into both temporal lobes. The tumor is relatively well circumscribed and shows little/no edema. Glistening myxoid matrix is typical. Hemorrhage ⇨ occurs in ~ 20% of PMAs but is unusual in classic pilocytic astrocytoma (PA).* **(Right)** *Coronal T2WI in an infant with a large head shows markedly enlarged lateral ventricles and a lobulated hyperintense suprasellar mass .*

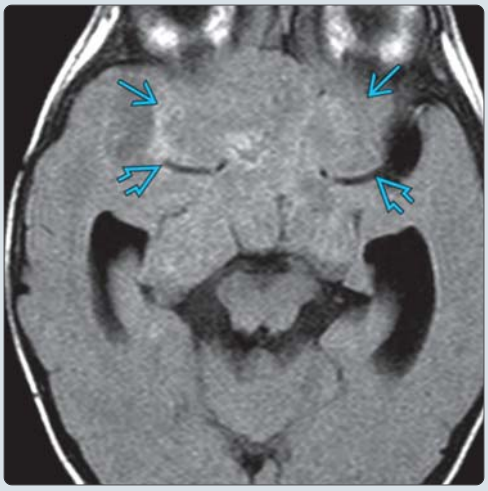

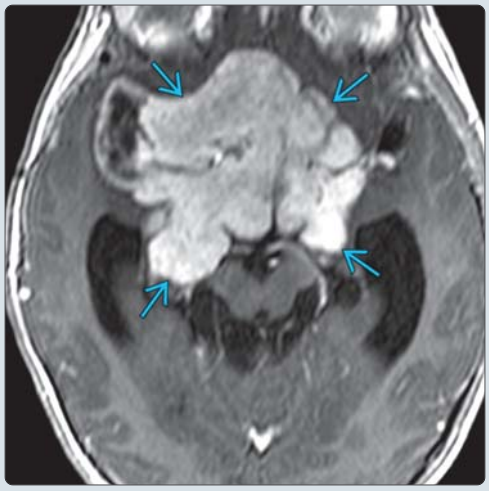

(Left) *Axial FLAIR scan in the same patient shows the large mass ⇨ completely fills the suprasellar cistern, elevating and encasing both middle cerebral arteries ⇨. The mass is mildly hyperintense relative to cortex.* **(Right)** *Axial T1C+ SPGR scan in the same patient shows the mass ⇨ enhances intensely and quite uniformly. The H-shaped configuration centered in the suprasellar cistern is classic for pilomyxoid astrocytoma, which was confirmed at surgery. (Courtesy M. Thurnher, MD.)*

https://CafePezeshki.IR

TERMINOLOGY

Abbreviations

- Pilomyxoid astrocytoma (PMA)
- Myxoid variant of pilocytic astrocytoma (PA)

Definitions

- Tumor with monomorphic piloid cells dispersed in mucopolysaccharide-rich matrix
  - More aggressive tumor than PA with high risk of local recurrence, dissemination

IMAGING

General Features

- Best diagnostic clue
  - Infant or young child with large, bulky H-shaped mass in hypothalamus/optic chiasm, medial temporal lobes
- Location
  - 60% suprasellar
    - Optic chiasm, hypothalamus
    - Extension into adjacent structures is common with larger tumors
    - Deep gray nuclei, temporal lobes, adjacent white matter often involved
  - 40% centered **outside** diencephalon
    - Cerebral hemispheres
      - 2nd most common general location
      - Temporal lobe most common
      - May be purely cortical
    - Less common sites reported
      - Midbrain
      - Cerebellum
      - 4th ventricle
      - Spinal cord
- Size
  - Variable
    - Mean: 4 cm
    - Often large, bulky (up to 12 cm)
- Morphology
  - Grossly well circumscribed

CT Findings

- NECT
  - Uniform hypodensity most common
  - 20% show intratumoral hemorrhage
    - Hyperdense
    - Mixed hypo-/hyperdense
  - Ca++ occurs but uncommon
- CECT
  - Strong but inhomogeneous enhancement
  - Irregular central nonenhancing area in 1/3

MR Findings

- T1WI
  - Typical: Uniformly hypointense (almost 2/3 of cases)
  - Less common: Mixed hypo-/hyperintensity (10-15%)
  - Uncommon: Blood-fluid level
- T2WI
  - 70% uniformly hyperintense
  - 15% inhomogeneously hyperintense
  - 10% hypointense center, hyperintense rim
- FLAIR
  - 50% uniformly hyperintense
  - 33% heterogeneously hyperintense
  - Relatively well-demarcated margins
  - Little or no peritumoral edema
- T2* GRE
  - Intratumoral hemorrhage in 20%
  - May be strikingly hypointense
- DWI
  - Typically does not restrict
- T1WI C+
  - Strong but heterogeneous enhancement
    - 50% heterogeneous (i.e., rim)
    - 40% solid, homogeneous
    - 10% no enhancement
  - Basilar/spinal meningeal enhancement is common and indicates cerebrospinal fluid (CSF) dissemination

Other Modality Findings

- MRS
  - ↑ Cho, ↓ Cr and NAA ± lactate
  - Some authors report low-metabolite pattern with ↓ Cho, Cr, NAA

Imaging Recommendations

- Best imaging tool
  - MR with T1WI C+, DWI, T2* (GRE or SWI), MRS

DIFFERENTIAL DIAGNOSIS

Pilocytic Astrocytoma

- Older children (mean age at diagnosis: 6 years)
- PMA usually more hyperintense on T2/FLAIR (mucoid matrix)
- Hemorrhage, CSF dissemination uncommon

Low-Grade Diffuse Astrocytoma

- Peak age: 20-45 years
- Cerebral hemispheres, brainstem > diencephalon
- Does not enhance

Glioblastoma Multiforme

- Hemorrhage, necrosis common
- Hypothalamus rare location
- Patients usually older
- May arise from lower grade astrocytoma

PATHOLOGY

General Features

- Genetics
  - PMA has significant differences in gene expression vs. PA
    - *H19*, *DACT2*, extracellular matrix collagens, IGF2BP3 (*IMP3*) overexpressed in PMAs
    - Variable tendencies toward maturation to PA
- Associated abnormalities
  - Few cases associated with neurofibromatosis type 1 have been reported

Staging, Grading, & Classification

- WHO grade II (PA is WHO grade I)

https://CafePezeshki.IR

- Grade III if anaplastic features
- Malignant transformation to glioblastoma multiforme (GBM) (IV) rare but does occur
- *MIB1* generally low (1-2%) but higher in anaplastic pleomorphic xanthoastrocytomas

Gross Pathologic & Surgical Features

- Large, grossly well-circumscribed mass
- Necrosis, hemorrhage may be present

Microscopic Features

- Lacks classic biphasic pattern seen in PAs
- Consists of monomorphic piloid tumor cells
  - Embedded in myxoid (mucopolysaccharide-rich) matrix
  - GFAP(+), vimentin (+)
- Conspicuous angiocentric growth pattern (perivascular rosettes)
  - Vascular proliferation may be marked
  - Infiltration of tumor cells into adjacent brain common
  - Necrosis rare

CLINICAL ISSUES

Presentation

- Most common signs/symptoms
  - Signs of ↑ intracranial pressure
    - Headache
    - Nausea, vomiting
  - Delayed development
  - Failure to thrive (so-called diencephalic syndrome)
  - Visual disturbances
  - Hypothalamic dysfunction
- Other signs/symptoms
  - Seizures
  - Focal neurologic deficit

Demographics

- Age
  - Typical: Infants, young children (< 4 years)
  - Less common: Older children, young adults
  - Rare: Middle-aged adult (up to 46 years)
- Gender
  - Slight male predominance (M:F = 4:3)
- Epidemiology
  - Rare; represent < 1% of astrocytomas
  - 5-10% of cases initially diagnosed as PAs may be PMAs, especially if hemorrhage is present or tumor presents in very young child

Natural History & Prognosis

- Higher recurrence rate than PA
- CSF dissemination common
- Bimodal pattern
  - Can mature to PA
  - May dedifferentiate into GBM

Treatment

- Partial resection with adjuvant therapy may prolong survival

DIAGNOSTIC CHECKLIST

Consider

- Pilomyxoid astrocytoma if
  - Infant or young child has large/bulky or hemorrhagic suprasellar mass
  - Imaging atypical for PA (i.e., hemorrhage)
- If "pilocytic astrocytoma" with repeated recurrences, CSF dissemination, review histopathology and consider PMA

Image Interpretation Pearls

- H-shaped suprasellar mass may be PMA

SELECTED REFERENCES

1. Alkonyi B et al: Differential imaging characteristics and dissemination potential of pilomyxoid astrocytomas versus pilocytic astrocytomas. Neuroradiology. 57(6):625-38, 2015
2. Amarasinghe SG et al: A rare case of multicystic disseminated astrocytoma with pilomyxoid characteristics in a 4-year-old child. Childs Nerv Syst. 31(4):625-9, 2015
3. El Beltagy MA et al: Surgical and clinical aspects of cerebellar pilomyxoid-spectrum astrocytomas in children. Childs Nerv Syst. 30(6):1045-53, 2014
4. Kleinschmidt-DeMasters BK et al: Pilomyxoid Astrocytoma (PMA) Shows Significant Differences in Gene Expression vs. Pilocytic Astrocytoma (PA) and Variable Tendency Toward Maturation to PA. Brain Pathol. 25(4):429-40, 2015
5. Amirjamshidi A et al: Pilomyxoid astrocytoma. J Neurosurg Pediatr. 11(5):613, 2013
6. Bhargava D et al: Occurrence and distribution of pilomyxoid astrocytoma. Br J Neurosurg. 27(4):413-8, 2013
7. Lee IH et al: Imaging characteristics of pilomyxoid astrocytomas in comparison with pilocytic astrocytomas. Eur J Radiol. 79(2):311-6, 2011
8. Johnson MW et al: Spectrum of pilomyxoid astrocytomas: intermediate pilomyxoid tumors. Am J Surg Pathol. 34(12):1783-91, 2010
9. Amatya VJ et al: Clinicopathological and immunohistochemical features of three pilomyxoid astrocytomas: comparative study with 11 pilocytic astrocytomas. Pathol Int. 59(2):80-5, 2009
10. Buccoliero AM et al: Occipital pilomyxoid astrocytoma in a 14-year-old girl–case report. Clin Neuropathol. 27(6):373-7, 2008
11. Komotar RJ et al: Magnetic resonance imaging characteristics of pilomyxoid astrocytoma. Neurol Res. 30(9):945-51, 2008
12. Linscott LL et al: Pilomyxoid astrocytoma: expanding the imaging spectrum. AJNR Am J Neuroradiol. 29(10):1861-6, 2008
13. Brat DJ et al: Newly codified glial neoplasms of the 2007 WHO Classification of Tumours of the Central Nervous System: angiocentric glioma, pilomyxoid astrocytoma and pituicytoma. Brain Pathol. 17(3):319-24, 2007
14. Ceppa EP et al: The pilomyxoid astrocytoma and its relationship to pilocytic astrocytoma: report of a case and a critical review of the entity. J Neurooncol. 81(2):191-6, 2007
15. Morales H et al: Magnetic resonance imaging and spectroscopy of pilomyxoid astrocytomas: case reports and comparison with pilocytic astrocytomas. J Comput Assist Tomogr. 31(5):682-7, 2007
16. Komotar RJ et al: Astrocytoma with pilomyxoid features presenting in an adult. Neuropathology. 26(1):89-93, 2006
17. Melendez B et al: BCR gene disruption in a pilomyxoid astrocytoma. Neuropathology. 26(5):442-6, 2006
18. Cirak B et al: Proton magnetic resonance spectroscopic imaging in pediatric pilomyxoid astrocytoma. Childs Nerv Syst. 21(5):404-9, 2005
19. Komotar RJ et al: Pilomyxoid astrocytoma of the spinal cord: report of three cases. Neurosurgery. 56(1):191, 2005
20. Chikai K et al: Clinico-pathological features of pilomyxoid astrocytoma of the optic pathway. Acta Neuropathol (Berl). 108(2):109-14, 2004
21. Darwish B et al: Juvenile pilocytic astrocytoma 'pilomyxoid variant' with spinal metastases. J Clin Neurosci. 11(6):640-2, 2004
22. Komotar RJ et al: Pilomyxoid astrocytoma: a review. MedGenMed. 6(4):42, 2004
23. Arslanoglu A et al: MR imaging characteristics of pilomyxoid astrocytomas. AJNR Am J Neuroradiol. 24(9):1906-8, 2003
24. Burger PC et al: Pathology of diencephalic astrocytomas. Pediatr Neurosurg. 32(4):214-9, 2000
25. Tihan T et al: Pediatric astrocytomas with monomorphous pilomyxoid features and a less favorable outcome. J Neuropathol Exp Neurol. 58(10):1061-8, 1999

https://CafePezeshki.IR

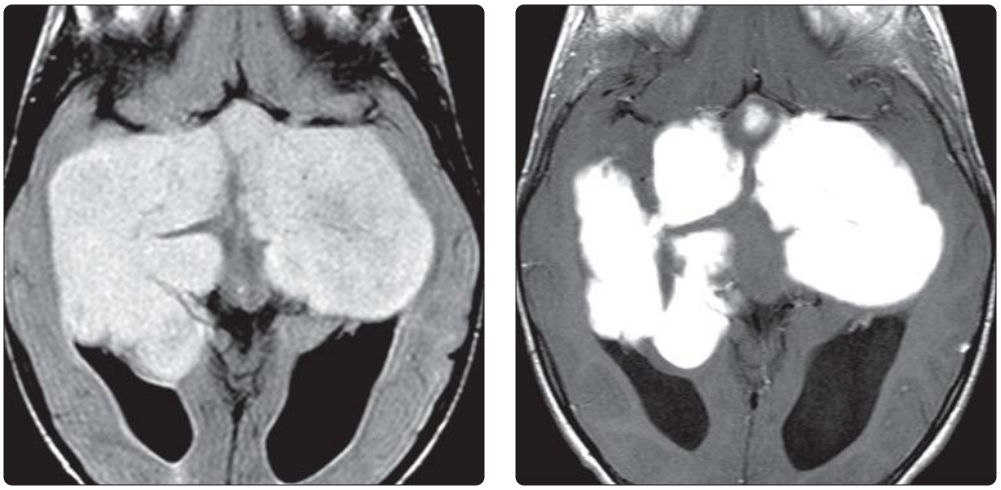

(Left) *Axial FLAIR MR in a 3 year old shows a large H-shaped suprasellar mass with extension into the basal ganglia and both medial temporal lobes. The tumor is quite well delineated despite its size and shows no evidence for surrounding edema.* **(Right)** *Axial T1WI C+ MR in the same patient shows intense, uniform enhancement.*

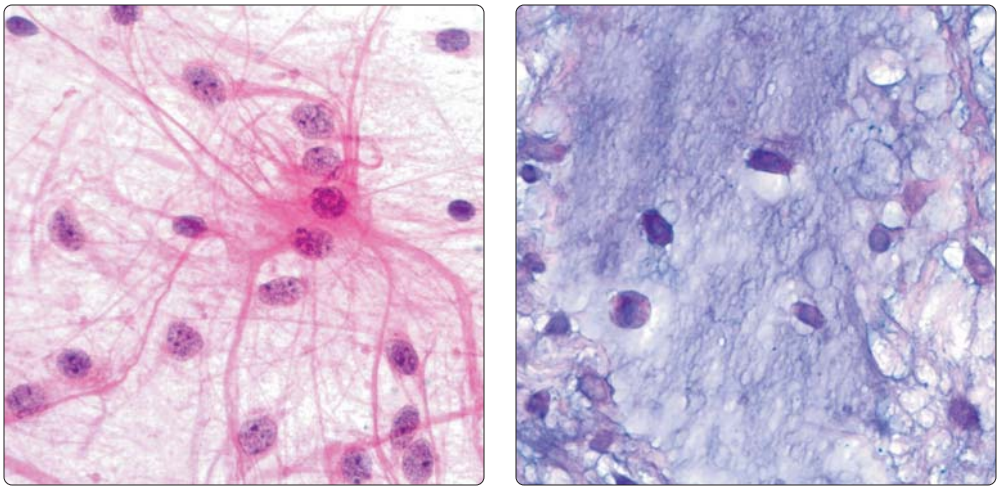

(Left) *Micropathology biopsied from the same patient shows neoplastic, bipolar, "pilocytic" cells. No Rosenthal fibers are seen.* **(Right)** *High-power micropathology with mucin stain shows the mucinous matrix (blue) with embedded glial nuclei. MIB1 was elevated. Final diagnosis was pilomyxoid astrocytoma (WHO grade II). (Courtesy R. Hewlett, MD.)*

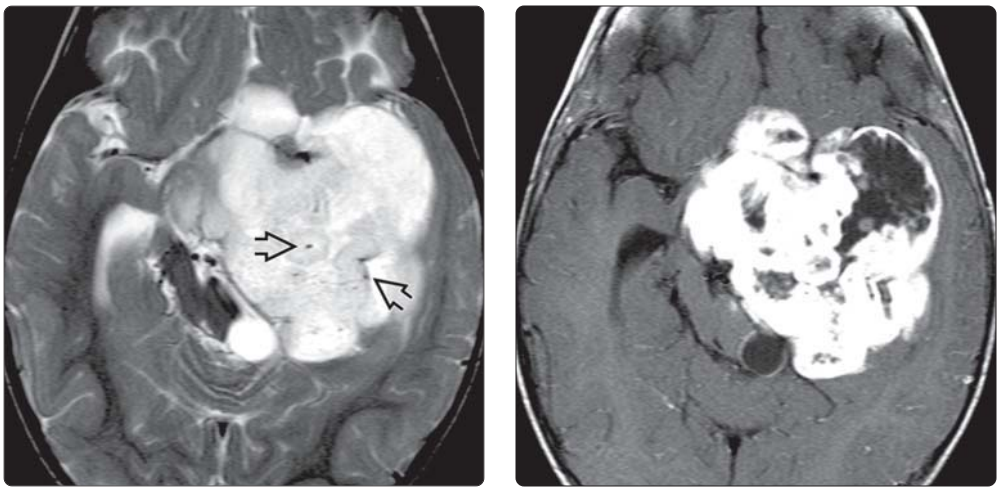

(Left) *Axial T2WI MR in a 20 month old shows a huge bulky suprasellar and medial temporal lobe mass. Scattered foci of T2 shortening within the mass ⇨ may represent hemorrhage (no T2* imaging was performed.)* **(Right)** *Axial T1WI C+ MR in the same patient shows mixed solid and rim enhancement. Biopsy disclosed elongated "piloid" cells in a mucin-rich matrix consistent with PMA. (Courtesy R. Hewlett, MD.)*

https://CafePezeshki.IR

KEY FACTS

TERMINOLOGY

- Astrocytic neoplasm with generally favorable prognosis in children and young adults

IMAGING

- Peripherally located hemispheric mass, often involves cortex and meninges
  - Temporal lobe most common
- Supratentorial cortical mass with adjacent enhancing dural "tail"
  - Cyst and enhancing mural nodule typical
  - Enhancing nodule often abuts pial surface

TOP DIFFERENTIAL DIAGNOSES

- Ganglioglioma
- Pilocytic astrocytoma
- Dysembryoplastic neuroepithelial tumor
- Oligodendroglioma
- Meningioma

PATHOLOGY

- WHO grade II
- "PXA with anaplastic features" also described

CLINICAL ISSUES

- Majority of patients have longstanding epilepsy, often partial complex seizures (temporal lobe)
  - Rare but important cause of temporal lobe epilepsy
- Tumor of children and young adults, majority < 18 years
- Represent < 1% of all astrocytomas
- Surgical resection is treatment of choice
- Survival 70% at 10 years
- Extent of resection and mitotic index are most significant predictors of outcome

DIAGNOSTIC CHECKLIST

- If cortical mass and meningeal thickening in a young adult with long seizure history, think PXA
- Ganglioglioma may mimic PXA clinically and by imaging

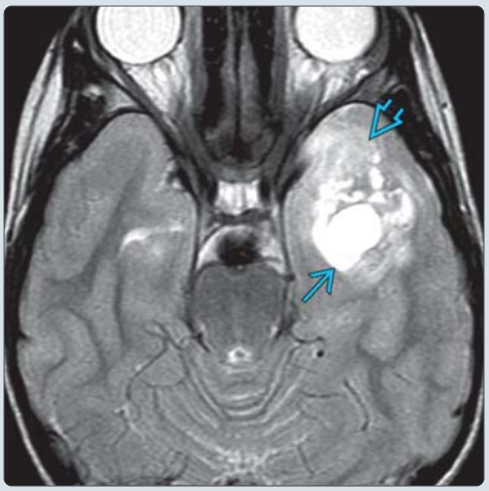

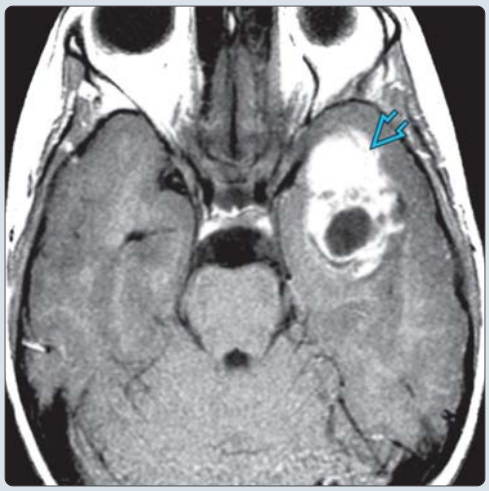

(Left) *Axial T2WI MR shows a cystic ⇨ and solid ⇨ temporal lobe mass in a 6-year-old girl with epilepsy.* **(Right)** *Axial T1WI C+ MR in the same patient shows marked enhancement ⇨ of the solid portions of the mass. Note the relative lack of surrounding edema and mass effect, characteristic of PXA. The imaging differential diagnosis includes ganglioglioma and pilocytic astrocytoma. Enhancement along the meninges when present helps make an accurate preoperative diagnosis.*

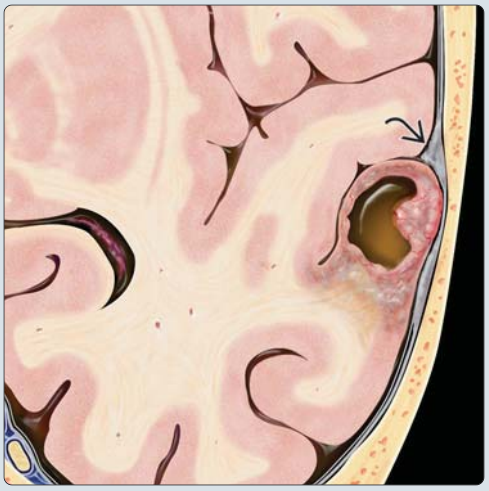

(Left) *Coronal graphic shows a cystic and solid cortical mass with thickening of the adjacent meninges ⇨, characteristic of PXA. The mural nodule often abuts the pial surface and may result in a dural "tail." Thinning of the adjacent calvaria is rare.* **(Right)** *Axial T1 C+ MR image shows a peripherally located frontal lobe mass, which abuts the dura ➡ with mild local mass effect. Solid, enhancing mural nodules ⇨ are present. PXA was diagnosed at surgical resection. These WHO grade II tumors typically occur in the temporal lobes.*

https://CafePezeshki.IR

TERMINOLOGY

Abbreviations

- Pleomorphic xanthoastrocytoma (PXA)

Definitions

- Astrocytic neoplasm with generally favorable prognosis in children and young adults
  - Superficial location in cerebral hemispheres with involvement of meninges

IMAGING

General Features

- Best diagnostic clue
  - Supratentorial cortical mass with adjacent enhancing dural "tail"
  - Cyst and enhancing mural nodule typical
- Location
  - Peripherally located hemispheric mass, often involves cortex and meninges
    - 98% supratentorial
  - Temporal lobe most common (40-50%)
    - Frontal and parietal > occipital lobes
  - Rarely found in cerebellum, sella, spinal cord, retina
- Size
  - Variable
- Morphology
  - 50-60% cyst with mural nodule that abuts meninges (may be solid)
  - Discrete, round to oval mass typical (may be ill defined)
  - Despite circumscribed appearance, tumor often infiltrates into brain and perivascular spaces

CT Findings

- NECT
  - Cystic/solid mass: Hypodense with mixed density nodule
  - Solid mass: Variable; hypodense, hyperdense, or mixed
  - Minimal or no edema is typical
  - Ca++, hemorrhage, frank skull erosion (rare)
- CECT
  - Strong, sometimes heterogeneous enhancement of tumor nodule

MR Findings

- T1WI
  - Mass is hypo- or isointense to gray matter
  - Mixed signal intensity may be seen
  - Cystic portion isointense to cerebrospinal fluid (CSF)
  - Associated cortical dysplasia may be seen (rare)
- T2WI
  - Hyperintense or mixed signal intensity mass
  - Cystic portion isointense to CSF
  - Surrounding edema (rare)
- FLAIR
  - Hyperintense or mixed signal intensity mass
  - Cystic portion isointense to CSF
- DWI
  - May show apparent diffusion coefficient (ADC) hypointensity in solid portions
  - Relatively low ADC values and ADC ratios (compared with pilocytic astrocytoma and ganglioglioma)
  - Mean ADC ratio of tumor to normal brain: 1.14 ± 0.26
- T1WI C+
  - Enhancement usually moderate/strong, well delineated
  - Enhancement of adjacent meninges, dural "tail" common (~ 70%)
    - Enhancing nodule often abuts pial surface
  - Rare: Deep tumor extension, distant metastases

Angiographic Findings

- Typically avascular
- Vascular blush may indicate necrotic or aggressive PXA

Nuclear Medicine Findings

- PET
  - FDG PET may show hypermetabolic foci even in low-grade PXA

Imaging Recommendations

- Best imaging tool
  - Multiplanar MR is most sensitive
  - CT may be helpful for calvarial changes
- Protocol advice
  - Contrast-enhanced MR including coronal images to better evaluate temporal lobes

DIFFERENTIAL DIAGNOSIS

Ganglioglioma

- Cortically based hemispheric mass, solid/cystic, or solid
- Mural nodule typical, often not adjacent to meninges
- Variable enhancement, no enhancing dural "tail"
- Ca++ is common; may remodel calvaria

Pilocytic Astrocytoma

- Supratentorial location other than hypothalamus/chiasm is rare
- Typically solid and cystic or solid mass
- Enhancement but no dural "tail"

Dysembryoplastic Neuroepithelial Tumor (DNET)

- Superficial cortical tumor, well demarcated
- Multicystic bubbly appearance
- T2 hyperintense mass with rare, mild enhancement
- May remodel calvaria

Oligodendroglioma

- Heterogeneous, Ca++ mass
- Typically larger and more diffuse than PXA
- May remodel/erode calvaria

Meningioma

- Diffusely enhancing, dural-based mass with dural "tail"
- Usually older patients

Low-Grade Astrocytoma (Grade II)

- Demarcated but infiltrative white matter mass
- No enhancement

PATHOLOGY

General Features

https://CafePezeshki.IR

- May originate from cortical (subpial) astrocytes
- May arise from multipotential neuroectodermal precursor cells common to both neurons and astrocytes or from preexisting hamartomatous lesions

- Genetics
  - No definite association with hereditary tumor syndromes
  - Rare reports of PXA in neurofibromatosis type 1 and Sturge-Weber patients
  - PXA with *TP53* mutations reported (low incidence)
  - Tumors with *BRAF* mutation associated with overall longer survival
  - Frequent loss of chromosome 9
- Associated abnormalities
  - PXA may occur with ganglioglioma and oligodendroglioma (rare)
  - PXA reported with DNET and atypical teratoid-rhabdoid tumor
  - Synchronous, multicentric PXA lesions are rare
  - May be associated with cortical dysplasia

Staging, Grading, & Classification

- WHO grade II
- PXA with anaplastic features (10-15%)
  - Significant mitoses (5 or more per 10 HPF) &/or necrosis
  - Has been associated with poorer prognosis
    - Increased recurrence and decreased survival
  - Some classify these PXA as WHO grade III

Gross Pathologic & Surgical Features

- Cystic mass with mural nodule abutting meninges
- May be completely solid
- Leptomeningeal adhesion/attachment is common
- Dural invasion is rare
- Deep margin may show infiltration of parenchyma

Microscopic Features

- Superficial, circumscribed astrocytic tumor noted for cellular pleomorphism and xanthomatous change
- Pleomorphic appearance
  - Fibrillary and giant multinucleated neoplastic astrocytes
  - Large xanthomatous (lipid-containing) cells are GFAP positive
  - Dense reticulin network
  - Lymphocytic infiltrates
- Tumor sharply delineated from cortex, but infiltration may be seen
- Some positive for synaptophysin, neurofilament proteins, S100 protein
- CD34 antigen may help differentiate PXA from other tumors
- Necrosis, mitotic figures rare/absent
  - *MIB1* index generally < 1%

CLINICAL ISSUES

Presentation

- Most common signs/symptoms
  - Majority with longstanding epilepsy, often partial complex seizures (temporal lobe)
  - Other signs/symptoms: Headache, focal neurologic deficits

Demographics

- Age
  - Tumor of children and young adults
    - Typically first 3 decades
    - 2/3 < 18 years
    - Range: 2-82 years, mean: 26 years
- Gender
  - No definite gender predominance
- Epidemiology
  - < 1% of all astrocytomas
  - Rare but important cause of temporal lobe epilepsy

Natural History & Prognosis

- Usually circumscribed, slow growing
- Recurrence of tumor is uncommon
- Hemorrhage is rare complication
- Survival 70% at 10 years
- 5-year survival 75-80%
- Malignant transformation in 10-25% of cases
- Extent of resection and mitotic index are most significant predictors of outcome
- Younger age at diagnosis portends a better overall survival
- Aggressive PXA with malignant progression, dissemination may occur

Treatment

- Surgical resection is treatment of choice
- Repeat resection for recurrent tumors
- Radiation therapy and chemotherapy show mild improvement in outcome in some cases

DIAGNOSTIC CHECKLIST

Consider

- If cortical mass and meningeal thickening in young adult with long seizure history, think PXA
- Ganglioglioma may mimic PXA clinically and by imaging

Image Interpretation Pearls

- Meningioma-like lesion in young patient should raise suspicion of PXA

SELECTED REFERENCES

1. Ho CY et al: Relative cerebral blood volume from dynamic susceptibility contrast perfusion in the grading of pediatric primary brain tumors. Neuroradiology. 57(3):299-306, 2015
2. Ida CM et al: Pleomorphic Xanthoastrocytoma: Natural History and Long-Term Follow-Up. Brain Pathol. ePub, 2014
3. Koelsche C et al: BRAF-mutated pleomorphic xanthoastrocytoma is associated with temporal location, reticulin fiber deposition and CD34 expression. Brain Pathol. 24(3):221-9, 2014
4. Moore W et al: Pleomorphic xanthoastrocytoma of childhood: MR imaging and diffusion MR imaging features. AJNR Am J Neuroradiol. 35(11):2192-6, 2014
5. Oh T et al: Pleomorphic xanthoastrocytomas: institutional experience of 18 patients. J Clin Neurosci. 21(10):1767-72, 2014
6. Borja MJ et al: Conventional and advanced MRI features of pediatric intracranial tumors: supratentorial tumors. AJR Am J Roentgenol. 200(5):W483-503, 2013
7. Neal MT et al: Pleomorphic xanthoastrocytoma in two siblings with neurofibromatosis type 1 (NF-1). Clin Neuropathol. 31(1):54-6, 2012
8. Hirose T et al: Pleomorphic xanthoastrocytoma: a comparative pathological study between conventional and anaplastic types. Histopathology. 52(2):183-93, 2008
9. Louis DN et al: WHO Classification of Tumours of the Central Nervous System: Pleomorphic xanthoastrocytoma. Lyon: IARC Press. 22-24, 2007

https://CafePezeshki.IR

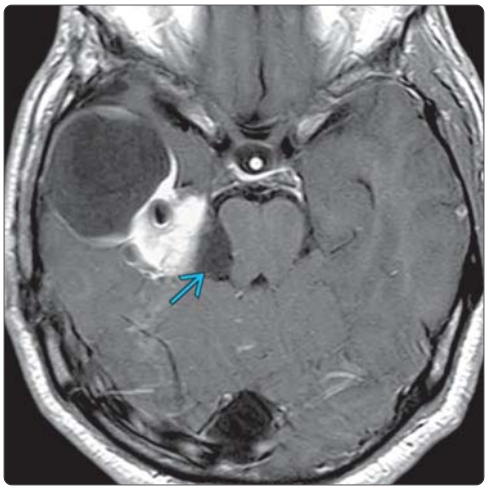

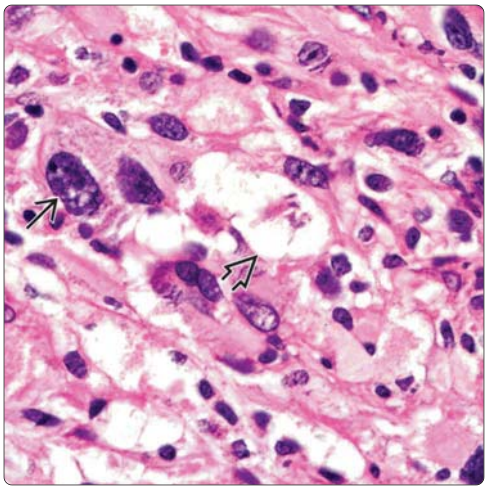

(Left) *Axial T1WI C+ MR shows a solid and cystic temporal lobe mass related to a recurrent pleomorphic xanthoastrocytoma (PXA). Note the extraaxial portion ⇨ with mass effect on the adjacent midbrain.* **(Right)** *H&E micropathology from the same patient shows conspicuous pleomorphism of the tumor with multinucleated giant cells ⇨ and vacuolation ⇨, characteristic for PXA, WHO grade II. Malignant transformation occurs in 10-25% of cases. (Courtesy R. Hewlett, MD.)*

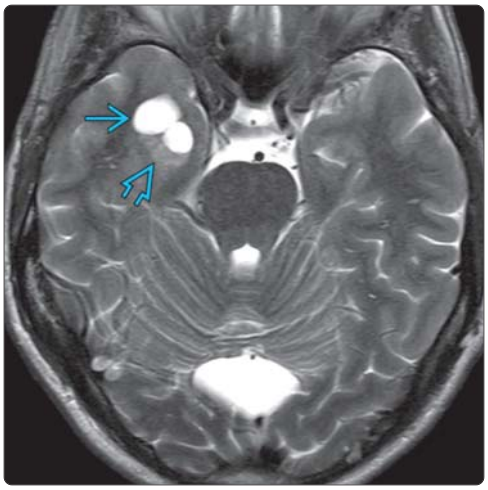

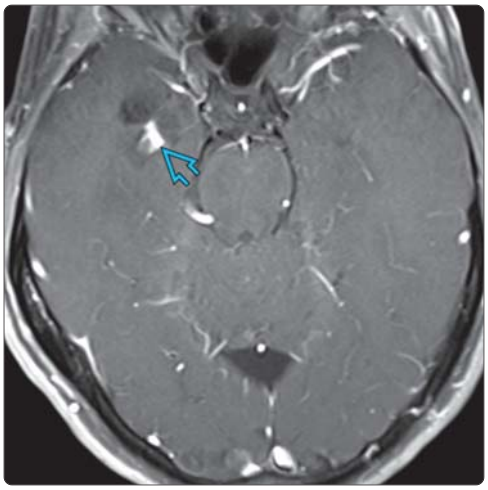

(Left) *Axial T2WI MR in an epilepsy patient shows a cystic ⇨ and solid ⇨ temporal lobe mass with no significant mass effect or surrounding edema.* **(Right)** *Axial T1 C+ FS MR in the same patient shows minimal nodular enhancement ⇨ of the mass. Imaging differential diagnosis includes ganglioglioma, pilocytic astrocytoma, PXA, and DNET. This was diagnosed as a PXA, WHO grade II, at resection. Coronal imaging is often helpful to better visualize the presence of meningeal involvement that is typical of PXA.*

(Left) *Axial T1 C+ FS MR shows a heterogeneously enhancing periventricular mass ⇨ in a 49-year-old male with local mass effect. PXA, WHO grade II, was diagnosed at resection. These tumors typically present in children or young adults.* **(Right)** *Axial CECT shows a large, mixed density, partially calcified, parietooccipital mass with patchy enhancement. This was classified as PXA with anaplastic features, WHO grade III, at resection, and the tumor had a high mitotic rate. These anaplastic tumors are uncommon and associated with a poor prognosis.*

https://CafePezeshki.IR

KEY FACTS

TERMINOLOGY

- Subependymal giant cell astrocytoma (SGCA, SEGA)
- Benign, slow-growing glioneuronal tumor in patient with tuberous sclerosis complex (TSC)
  - Arises near foramen of Monro

IMAGING

- General findings
  - Enlarging, enhancing mass near foramen of Monro in patient with TSC
  - Other findings of TS (cortical tubers, SE nodules)

TOP DIFFERENTIAL DIAGNOSES

- Choroid plexus tumors
  - Choroid plexus papilloma > atypical choroid plexus papilloma, carcinoma
- Central neurocytoma
  - Body of lateral ventricle
- Astrocytoma
  - Pilocytic astrocytoma, chordoid glioma (rare)
- Subependymoma
  - Middle-aged, older adults
- Supratentorial PNET (rare)
  - Young child without TSC

PATHOLOGY

- SGCA probably arises from SE nodule in region of germinal matrix
- Likely represents disordered neuronal migration
- WHO grade I, curable with complete resection

CLINICAL ISSUES

- Most common CNS neoplasm in TSC
  - SGCA in up to 15% of patients with TSC
  - Rarely (if ever) arises in absence of TSC
- Typically occurs during first 2 decades
- Treatment with rapamycin (Everolimus)
  - Most TS patients have 50% ↓ in SEGA within 9 months

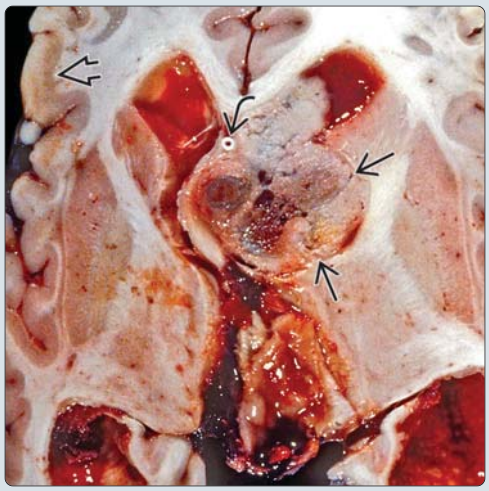

(Left) *Coronal graphic demonstrates hydrocephalus secondary to a subependymal giant cell astrocytoma (SGCA) arising near the left foramen of Monro. Note the subependymal tubers.* **(Right)** *Axial section through the ventricles in a patient with tuberous sclerosis complex (TSC) shows a large SGCA obstructing the foramen of Monro. Note the well-delineated tumor margins and cortical tuber. Despite emergent ventricular shunting, the ventricles were not decompressed successfully. (Courtesy R. Hewlett, MD.)*

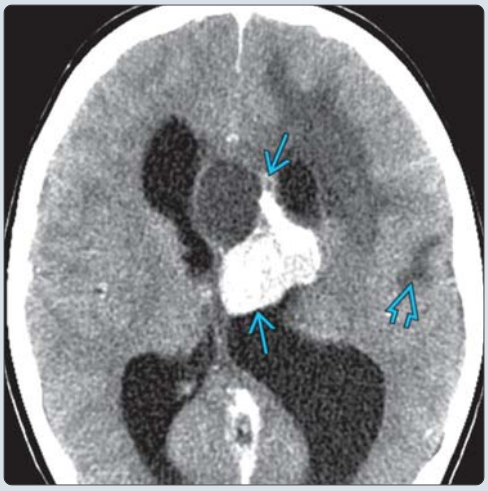

(Left) *Axial CECT in a patient with TSC shows a large, partially calcified mass that obstructs the foramen of Monro. Note the hypodense white matter lesion underlying a cortical tuber.* **(Right)** *Axial FLAIR MR in the same patient shows that the mass is heterogeneously hyperintense. Note the cortical tubers and subcortical white matter hyperintensities. SGCA was found at surgery.*

https://CafePezeshki.IR

TERMINOLOGY

Abbreviations

- Subependymal giant cell astrocytoma (SGCA, SEGA)

Definitions

- Benign, slow-growing glioneuronal tumor arising near foramen of Monro in patient with tuberous sclerosis complex (TSC)

IMAGING

General Features

- Best diagnostic clue
  - Enlarging, enhancing foramen of Monro mass in patient with TSC
    - Other imaging findings of TSC (cortical tubers, subependymal nodules)
    - Subependymal giant cell astrocytoma in absence of clinical/genetic evidence of TSC reported but very rare
- Location
  - Subependymal nodules (SENs) in > 90% of tuberous sclerosis (TS) patients
    - Lateral ventricles adjacent to caudate nuclei
  - SEGAs may arise from SENs
    - Almost always near foramen of Monro
- Size
  - SEGAs variable, slowly growing
    - Often presents when 2-3 cm; causes obstructive hydrocephalus
  - SENs typically 5-10 mm
    - Larger SENs near foramen of Monro should be followed with serial imaging
      - SEGAs usually grow slowly while SENs remain stable
- Morphology
  - Well marginated, often lobulated
  - Frond-like margins

CT Findings

- NECT
  - Hypo- to isodense; heterogeneous
  - Ca++ variable
  - Hydrocephalus
- CECT
  - Heterogeneous, strong enhancement
  - Presence of interval growth suggests SGCA
  - Initially tumor is typically > 1 cm
- CT perfusion
  - May be mildly hypervascular

MR Findings

- T1WI
  - Hypointense to isointense to gray matter (GM)
  - ± Ca++ (hyperintense to hypointense)
- T2WI
  - Heterogeneous
    - Isointense to hyperintense
  - Ca++ foci hypointense
  - Hydrocephalus
- PD/intermediate
  - Hyperintense
- FLAIR
  - Heterogeneously hyperintense
  - Periventricular interstitial edema from ventricular obstruction
- T2* GRE
  - Low signal from Ca++
- DWI
  - Apparent diffusion coefficient (ADC) values are less than parenchymal hamartomas of TS
- T1WI C+
  - Robust enhancement
    - Enhancement alone does not allow discrimination from hamartoma
  - Enlarging, enhancing foramen of Monro mass > 1.2 cm suggests SGCA
  - CSF dissemination not seen
- MRS
  - Less than expected decrease in N-acetylaspartate (NAA) due to some neuronal elements in this primarily glial neoplasm

Imaging Recommendations

- Best imaging tool
  - MR demonstrates extent of mass, delineates associated TSC features
- Protocol advice
  - FLAIR MR to detect subtle CNS features of TSC
  - Recommend brain MR with contrast every 1-2 years for SGCA follow-up

DIFFERENTIAL DIAGNOSIS

Choroid Plexus Papilloma

- Atrium of lateral ventricle; foramen of Monro rare

Astrocytoma

- Origin: Septum pellucidum fornices or medial basal ganglia
  - Common pediatric intraaxial neoplasm
  - Variable enhancement, Ca++ rare

Germinoma

- Hugs midline, often arises near 3rd ventricle
- May originate from basal ganglia, resemble SGCA
- Early CSF spread

Subependymoma

- Tumor of middle-aged, elderly adults
- Inferior 4th/frontal horn of lateral ventricle

Central Neurocytoma

- Well-defined, variably vascularized, lobulated mass
- Body of lateral ventricle > foramen of Monro or septum pellucidum
- Necrosis, cyst formation are common
- Seen in young adults

Supratentorial PNET

- May exophytically extend into ventricle
- Lack of peritumoral edema
- Highly cellular tumor, isointense → slightly hyperintense on T2WI

https://CafePezeshki.IR

PATHOLOGY

General Features

- Etiology
  - SGCA probably arises from SEN in region of germinal matrix
  - Likely represents disordered neuronal migration complex
- Genetics
  - 50% of TSC patients have positive family history
    - High rate of de novo mutations
    - Inheritance: Autosomal dominant
    - High penetrance
    - Considerable phenotypic variability
  - Molecular genetics
    - 2 distinct TSC loci (chromosome 9q on *TSC1* and 16p on *TSC2*)
    - Protein products of *TSC1* (hamartin) and *TSC2* (tuberin)
      - Suppress mammalian target of rapamycin (mTOR), a major cell growth and proliferation controller
    - Mutation results in activation of mTOR
- Associated abnormalities
  - Other CNS, extraneural manifestations of TSC

Staging, Grading, & Classification

- WHO grade I

Gross Pathologic & Surgical Features

- Well-marginated mass arising from lateral ventricular wall near foramen of Monro
  - ± cysts, Ca++, and hemorrhage
- Does not seed CSF pathways

Microscopic Features

- Tumor cells of SGCAs show wide spectrum of astroglial phenotypes
  - Giant pyramidal ganglioid astrocytes
  - Perivascular pseudopalisading
- Histology may be indistinguishable from subependymal nodules
  - Diagnosis based on size and growth
- Immunohistochemistry
  - Variable immunoreactivity for GFAP, S100
  - Glial, neuronal antigen expression variable

CLINICAL ISSUES

Presentation

- Most common signs/symptoms
  - Increased intracranial pressure secondary to tumor obstructing foramen of Monro
    - Headache, vomiting, loss of consciousness
  - Other signs/symptoms
    - Worsening epilepsy
    - Massive spontaneous hemorrhage
- Clinical profile
  - Patient with TSC develops signs and symptoms of ventricular obstruction
  - Worsening of epilepsy

Demographics

- Age
  - SGCA typically occurs during first 2 decades
    - Mean age: 11 years
    - Rarely arise after 20-25 years of age
- Epidemiology
  - 1.4% of all pediatric brain tumors
  - Most common CNS neoplasm in TSC
    - Incidence of SGCA: 10-20% of patients with TSC
    - Rarely occurs in absence of TSC
- Uncommon reports of congenital cases
- No race or gender predilection

Natural History & Prognosis

- Solitary, slow-growing, benign tumor
- Symptoms from ventricular obstruction
- Good outcome and low recurrence rate with complete resection
- Rarely, massive spontaneous hemorrhage

Treatment

- Successful treatments reported with rapamycin (Everolimus)
  - Part of mTORC1 pathway
  - Restores pathway after inhibition by *TSC1* or *TSC2* mutation
- Surgery is no longer necessary in most cases

DIAGNOSTIC CHECKLIST

Consider

- SGCA in TSC patient with worsening seizures &/or symptoms of ventricular obstruction

Image Interpretation Pearls

- Enlarging, enhancing, intraventricular mass near foramen of Monro in TSC patient
- Foramen of Monro mass and associated intraventricular hemorrhage

SELECTED REFERENCES

1. Beaumont TL et al: Subependymal giant cell astrocytoma in the absence of tuberous sclerosis complex: case report. J Neurosurg Pediatr. 1-4, 2015
2. Cardamone M et al: Mammalian target of rapamycin inhibitors for intractable epilepsy and subependymal giant cell astrocytomas in tuberous sclerosis complex. J Pediatr. 164(5):1195-200, 2014
3. Harter DH et al: A management strategy for intraventricular subependymal giant cell astrocytomas in tuberous sclerosis complex. J Neurosurg Pediatr. 13(1):21-8, 2014
4. Kotulska K et al: Surgical treatment of subependymal giant cell astrocytoma in tuberous sclerosis complex patients. Pediatr Neurol. 50(4):307-12, 2014
5. Ouyang T et al: Subependymal giant cell astrocytoma: current concepts, management, and future directions. Childs Nerv Syst. 30(4):561-70, 2014
6. Rovira À et al: Recommendations for the radiological diagnosis and follow-up of neuropathological abnormalities associated with tuberous sclerosis complex. J Neurooncol. 118(2):205-23, 2014
7. Krueger DA et al: Everolimus long-term safety and efficacy in subependymal giant cell astrocytoma. Neurology. 80(6):574-80, 2013
8. Roth J et al: Subependymal giant cell astrocytoma: diagnosis, screening, and treatment. Recommendations from the International Tuberous Sclerosis Complex Consensus Conference 2012. Pediatr Neurol. 49(6):439-44, 2013
9. Buccoliero AM et al: Subependymal giant cell astrocytoma (SEGA): Is it an astrocytoma? Morphological, immunohistochemical and ultrastructural study. Neuropathology. 29(1):25-30, 2009
10. Khayal IS et al: Characterization of low-grade gliomas using RGB color maps derived from ADC histograms. J Magn Reson Imaging. 30(1):209-13, 2009

https://CafePezeshki.IR

(Left) *Axial T1WI MR in a 13-year-old boy with TS shows 2 SENs along the right frontal horn. A bilobulated mixed signal intensity mass is present in the left frontal horn adjacent to the foramen of Monro. Note serial cortical tubers with widened gyri, indistinct gray matter-white matter interfaces.* **(Right)** *More cephalad axial T1WI MR in the same case shows additional SENs.*

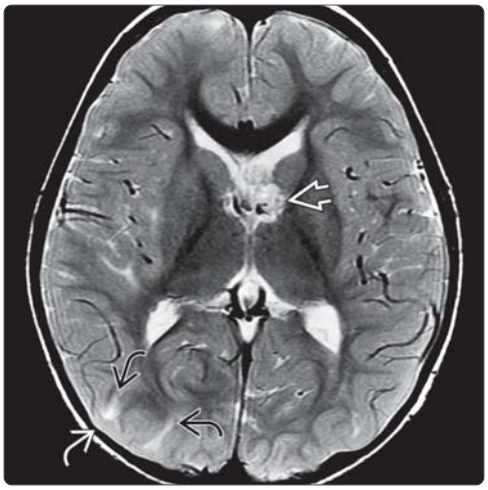

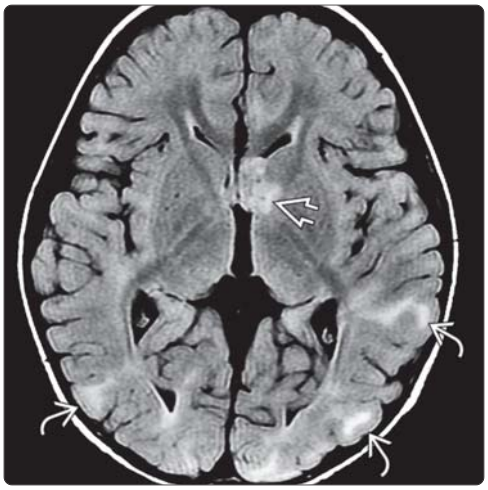

(Left) *Axial T2WI MR in the same case shows the lobulated mass in the left frontal horn is hyperintense relative to both white matter, gray matter. Several flame-shaped white matter subcortical hyperintensities under the cortical tubers are present.* **(Right)** *Axial FLAIR MR in the same case shows the lobulated mass in the left frontal horn has not obstructed the lateral ventricle. The flame-shaped white matter hyperintensities under the cortical tubers are more apparent on this sequence.*

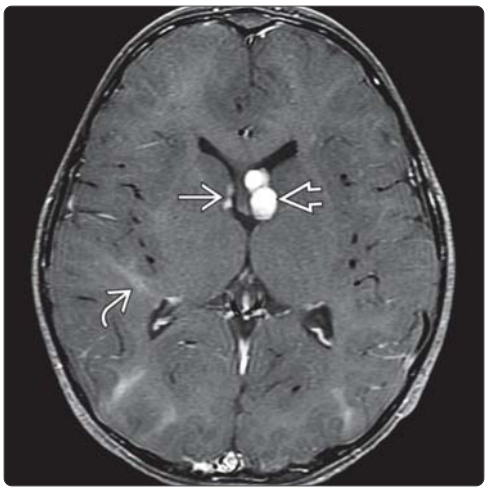

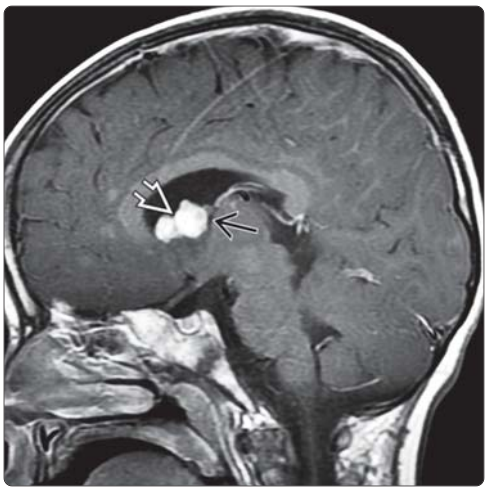

(Left) *T1 C+ FS MR in the same case shows the right frontal SENs enhance, as does the lobulated left frontal horn mass. The flame-shaped white matter hyperintensities are better seen on this image, with 1 radial band extending to the ventricular margin.* **(Right)** *Sagittal T1C+ MR in this case shows the lobulated mass in the left frontal horn is directly adjacent to the foramen of Monro but does not obstruct it. Presumed SGCA is being followed without surgery and has remained stable over several years.*

https://CafePezeshki.IR

KEY FACTS

TERMINOLOGY

- Well-differentiated, slowly growing but diffusely infiltrating cortical/subcortical tumor

IMAGING

- Most common site is frontal lobe (50-65%)
- Best diagnostic clue: Partially calcified subcortical/cortical frontal mass in middle-aged adult
  - Typically T2 heterogeneous, hyperintense mass
- ~ 50% enhance
  - Heterogeneous enhancement is typical
- New enhancement in previously nonenhancing oligodendroglioma suggests malignant progression

TOP DIFFERENTIAL DIAGNOSES

- Anaplastic oligodendroglioma (AO)
- Low-grade diffuse astrocytoma
- Ganglioglioma
- Dysembryoplastic neuroepithelial tumor (DNET)
- Pleomorphic xanthoastrocytoma (PXA)
- Cerebritis
- Cerebral ischemia

PATHOLOGY

- Loss of heterozygosity for 1p and 19q (50-70%)
- WHO grade II
- Anaplastic oligodendroglioma = WHO grade III
- Oligodendrogliomas carry better prognosis than astrocytomas of same grade

CLINICAL ISSUES

- 5-10% of primary intracranial neoplasms
- Seizures, headaches, and focal neurologic deficits are most common presentations
- Peak incidence: 4th and 5th decades
- Median survival time = 10 years
- 1p, 19q deletions and *IDH1*(+) associated with more favorable prognosis

(Left) *Axial graphic shows a heterogeneous cystic and solid mass involving the cortex and subcortical white matter, typical of oligodendroglioma. Note the deep infiltrative margin and calvarial remodeling.* **(Right)** *Axial NECT in a 20-year-old man shows a large, calcified, left frontal lobe mass, typical of oligodendroglioma. The vast majority (70-90%) of oligodendrogliomas show calcification. The calcification helps distinguish this tumor from other gliomas, particularly astrocytomas.*

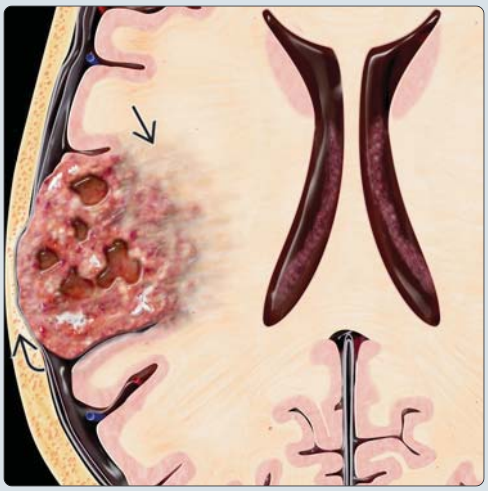

(Left) *Axial FLAIR MR in the same patient shows a heterogeneous, hyperintense infiltrative mass expanding the frontal gyri. The frontal lobe location and involvement of both cortex and subcortical white matter are typical of oligodendroglioma.* **(Right)** *Axial T1WI C+ MR in the same patient shows heterogeneous enhancement in this grade II oligodendroglioma. Differentiating a grade II from a grade III oligodendroglioma is difficult on conventional imaging. MRS and MR perfusion may help predict the tumor grade preoperatively.*

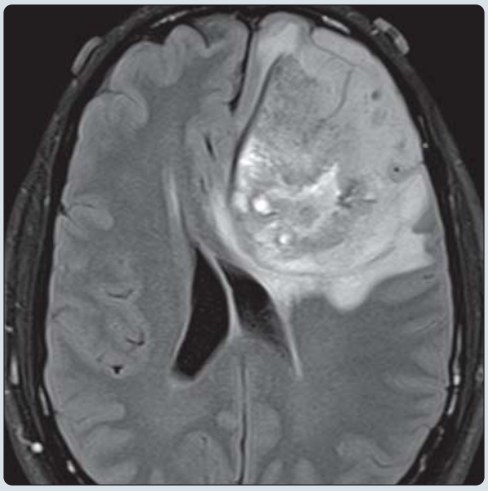

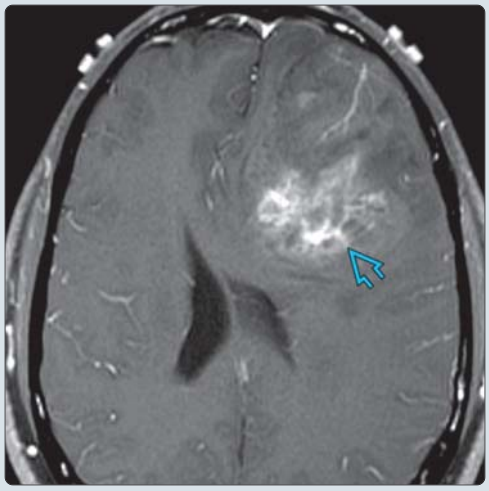

https://CafePezeshki.IR

TERMINOLOGY

Definitions

- Well-differentiated, slowly growing, but diffusely infiltrating, cortical/subcortical tumor

IMAGING

General Features

- Best diagnostic clue
  - Partially calcified subcortical/cortical mass in middle-aged adults
- Location
  - Typically involves subcortical white matter (WM) and cortex
  - Majority supratentorial (85%), hemispheric WM
    - Most common site is frontal lobe (50-65%)
    - May involve temporal, parietal, or occipital lobes
    - Rare: Posterior fossa
    - Extremely rare: Intraventricular, brainstem, spinal cord, primary leptomeningeal
- Morphology
  - Infiltrative mass that appears well demarcated

CT Findings

- NECT
  - Mixed density (hypo-/isodense) hemispheric mass that extends to cortex
  - Majority calcify, nodular or clumped Ca++ (70-90%)
  - Cystic degeneration common (20%)
  - Hemorrhage, edema are uncommon
  - May expand, remodel, erode calvaria
- CECT
  - ~ 50% enhance
  - Enhancement varies from none to striking

MR Findings

- T1WI
  - Hemispheric mass, hypo- to isointense to gray matter
  - Typically heterogeneous
  - Cortical and subcortical with cortical expansion
  - May appear well circumscribed with minimal associated edema
- T2WI
  - Typically heterogeneous, hyperintense mass
    - Heterogeneity related to Ca++, cystic change, less commonly blood products
  - May appear well circumscribed with minimal associated edema
  - Typically expands overlying cortex
  - Hemorrhage, necrosis are rare unless anaplastic
  - May expand, erode calvaria
- FLAIR
  - Typically heterogeneous, hyperintense
  - May appear well circumscribed but infiltrative
- T2* GRE
  - Ca++ seen as areas of "blooming"
- DWI
  - No diffusion restriction is typical
- T1WI C+
  - Heterogeneous enhancement is typical
  - ~ 50% enhance
  - Rarely, leptomeningeal enhancement is seen
- MRS
  - ↑ Cho, ↓ NAA
  - Absence of lipid/lactate peak helps differentiate from anaplastic oligodendroglioma
  - 2HG MRS has been found helpful to identify *IDH* status
- Perfusion MR
  - Relative cerebral blood volume (rCBV) can help differentiate grade II from grade III
  - Foci of elevated rCBV can mimic high-grade tumor

Nuclear Medicine Findings

- PET
  - FDG uptake similar to normal white matter
  - 11C-methionine studies show marked uptake differences between oligo and anaplastic oligo

Imaging Recommendations

- Best imaging tool
  - MR is most sensitive to delineate tumor
  - CT is helpful for identifying Ca++
- Protocol advice
  - Contrast-enhanced MR with T2* GRE or SWI ± MRS, perfusion

DIFFERENTIAL DIAGNOSIS

Anaplastic Oligodendroglioma (AO)

- May require biopsy to distinguish
- MRS, perfusion, or PET may be helpful

Low-Grade Diffuse Astrocytoma

- Calcification less common
- Usually involves white matter, cortex relatively spared
- May be indistinguishable

Ganglioglioma

- Usually temporal lobe, cortical
- Sharply demarcated, cyst with enhancing nodule
- Ca++ common
- Childhood, young adult tumor

Dysembryoplastic Neuroepithelial Tumor (DNET)

- Sharply demarcated cortical neoplasm
- Heterogeneous, bubbly appearance
- Variable enhancement
- Childhood, young adult tumor

Pleomorphic Xanthoastrocytoma (PXA)

- Supratentorial cortical mass, dural "tail" common
- Often cyst and mural nodule, may be solid
- Enhancing nodule abuts pial surface
- Childhood, young adult tumor

Cerebritis

- T2 hyperintensity and patchy enhancement
- Diffusion restriction typical

Cerebral Ischemia

- Typical vascular distribution (MCA, ACA, PCA)
- Diffusion restriction if acute/subacute
- Involves gray and white matter, often wedge-shaped

https://CafePezeshki.IR

- Cortical, gyriform enhancement if subacute

Arteriovenous Malformation (AVM)

- Typically multiple enlarged flow voids
- Often calcified
- If thrombosed, may be indistinguishable

Herpes Encephalitis

- Confined to limbic system, temporal lobes
- Blood products and enhancement common
- Acute onset is typical

PATHOLOGY

General Features

- Etiology
  - Arises from neoplastic transformation of mature oligodendrocytes or immature glial precursors
- Genetics
  - Loss of heterozygosity (LOH) for 1p and 19q (50-70%)
  - *IDH1* mutation (+) (80%)
  - Pediatric cases, often *IDH*(-) and *MGMT*(+)
  - *ATRX* is nonmutated
  - Familial cases have been reported
- Associated abnormalities
  - Oligoastrocytomas include neoplastic cell types of both oligodendroglioma and diffuse astrocytoma
    - Proposal to remove term oligoastrocytoma and stratify tumors based on *IDH1* status
  - Rarely occurs with other tumors, pleomorphic xanthoastrocytoma (PXA)
  - Rarely may be multifocal or multicentric
  - Oligodendroglial gliomatosis cerebri (rare)
  - Primary leptomeningeal oligodendrogliomatosis (extremely rare)

Staging, Grading, & Classification

- WHO grade II
- Anaplastic oligodendroglioma = WHO grade III
  - Mitoses, microvascular proliferation, ± necrosis
- Oligodendrogliomas carry better prognosis than astrocytomas of same grade

Gross Pathologic & Surgical Features

- Solid, infiltrative lesions of cortex/subcortical WM
- Well-defined, grayish pink, soft, unencapsulated mass
- Ca++ frequent; ± cystic degeneration, hemorrhage

Microscopic Features

- Moderately cellular tumors with occasional mitoses
- Rounded, homogeneous nuclei and clear cytoplasm
  - Fried egg and honeycomb patterns probably artifactual, perinuclear halos
- May have dense network of branching capillaries
- MIB-1 < 5% (proliferation index)

CLINICAL ISSUES

Presentation

- Most common signs/symptoms
  - Seizures, headaches, focal neurologic deficits
  - Patients have relatively longstanding history of symptoms

Demographics

- Age
  - Peak incidence: 4th and 5th decades
- Gender
  - Slight male predominance
- Epidemiology
  - 5-10% of primary intracranial neoplasms
  - 5-20% of all gliomas
  - 3rd most common glial neoplasm

Natural History & Prognosis

- More favorable outcome correlated with younger age, frontal location, lack of enhancement, complete resection, radiation therapy after partial resection
- Worse prognosis correlated with necrosis, increased cellularity, mitotic activity, nuclear atypia, cellular pleomorphism, microvascular proliferation
- Median survival time = 10 years
- 5-year survival rate in 50-75% of cases
- Local recurrence is common; CSF seeding is uncommon
- 1p, 19q deletion and *IDH1*(+) associated with more favorable prognosis, better response to chemotherapy
- Tumors without *IDH1* mutation are considered wild type and behave more aggressively with poor survival

Treatment

- Surgical resection is primary treatment
- ± adjuvant radiation therapy & chemotherapy (temozolomide)

DIAGNOSTIC CHECKLIST

Consider

- If frontal lobe calcified mass, think oligodendroglioma
- Oligos may mimic cortically based masses (i.e., DNET), although these typically occur in younger patients

Image Interpretation Pearls

- Grade II oligos cannot be reliably differentiated from grade III (AO) on conventional imaging
- Oligos are most common intracranial tumor to calcify
- New enhancement in previously nonenhancing oligodendroglioma suggests malignant progression

SELECTED REFERENCES

1. Ogura R et al: Immunohistochemical profiles of IDH1, MGMT and P53: Practical significance for prognostication of patients with diffuse gliomas. Neuropathology. ePub, 2015
2. Reuss DE et al: ATRX and IDH1-R132H immunohistochemistry with subsequent copy number analysis and IDH sequencing as a basis for an "integrated" diagnostic approach for adult astrocytoma, oligodendroglioma and glioblastoma. Acta Neuropathol. 129(1):133-46, 2015
3. Sahm F et al: Farewell to oligoastrocytoma: in situ molecular genetics favor classification as either oligodendroglioma or astrocytoma. Acta Neuropathol. 128(4):551-9, 2014

https://CafePezeshki.IR

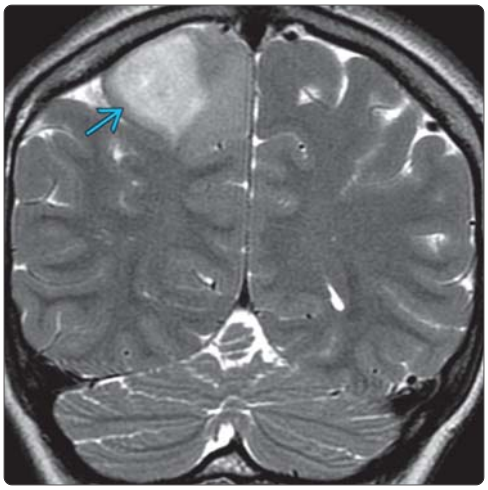

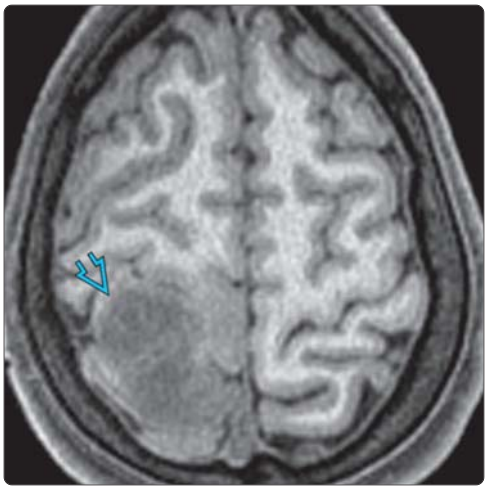

(Left) *Coronal T2 MR shows a discrete-appearing hyperintense white matter mass* ⇨ *with involvement of the overlying cortex. Grade II oligodendroglioma, 1p, 19q deletion was diagnosed at resection. 1p 19q deletions and IDH1 mutation are associated with improved survival.* **(Right)** *Axial T1 MR in the same patient shows a hypointense mass* ⇨ *involving the right frontoparietal cortex and deep white matter. No enhancement was present following contrast. About 50% of grade II oligodendrogliomas show enhancement.*

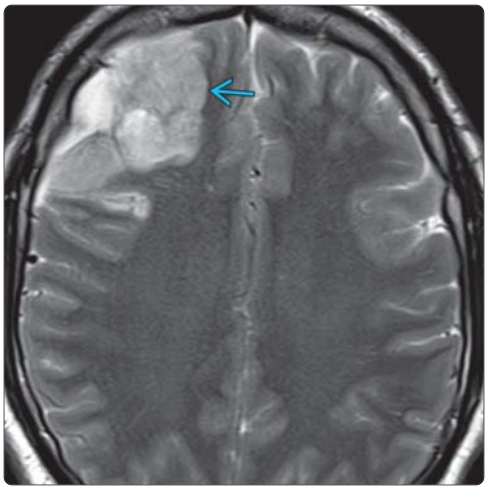

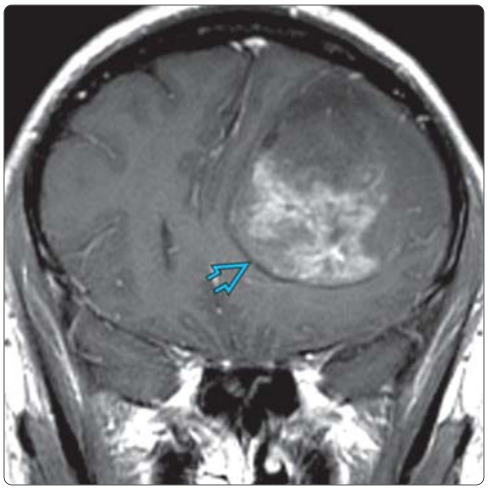

(Left) *Axial T2 MR shows a heterogeneous, hyperintense mass* ⇨ *with involvement of the cortex and subcortical white matter with mild associated mass effect. Imaging is highly suggestive of oligodendroglioma. Anaplastic oligodendroglioma was diagnosed at resection. Grade II oligodendrogliomas cannot be reliably differentiated from grade III on conventional imaging. MRS and MR perfusion may be helpful.* **(Right)** *Coronal T1 C+ MR shows a heterogeneously enhancing frontal lobe grade II oligodendroglioma* ⇨.

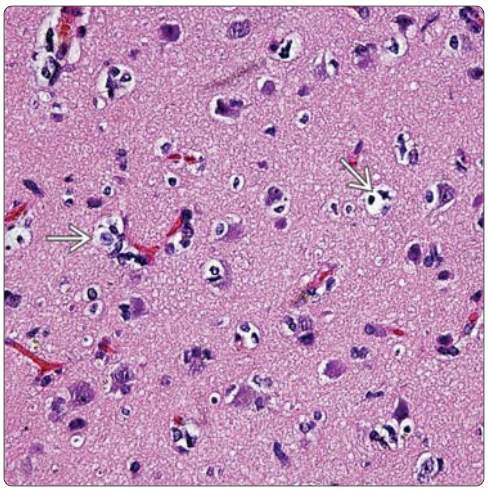

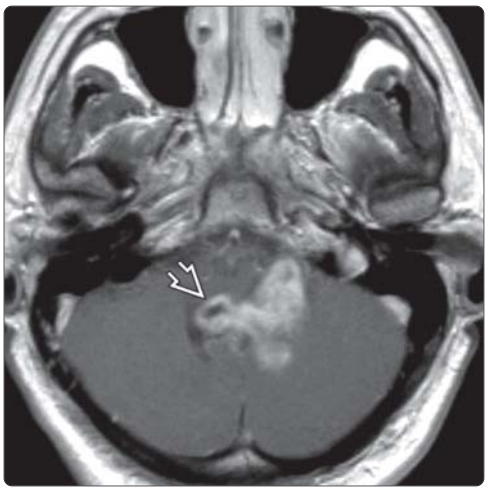

(Left) *High-power micropathology shows the classic histopathologic fried egg appearance* ➡ *related to a perinuclear halo, characteristic for oligodendroglioma. Oligodendrogliomas carry a better prognosis than astrocytomas of the same grade.* **(Right)** *Axial T1WI C+ MR shows a heterogeneously enhancing posterior fossa mass* ➡ *involving the 4th ventricle. Though imaging mimics an ependymoma, this was a grade II oligodendroglioma at resection.*

https://CafePezeshki.IR

KEY FACTS

TERMINOLOGY

- Oligodendroglioma with focal or diffuse histologic features of malignancy

IMAGING

- Best diagnostic clue: Calcified frontal lobe mass involving cortex and subcortical white matter
  - Frontal lobe is most common location, followed by temporal lobe
- Majority have nodular or clumped calcification
- May see hemorrhage or necrosis
- Variable enhancement
  - Anaplastic oligodendroglioma more likely to enhance than low-grade oligo
- Neoplastic cells almost always found beyond areas of abnormal signal intensity
- MRS and MR perfusion may help distinguish grade II from grade III oligos

TOP DIFFERENTIAL DIAGNOSES

- Oligodendroglioma
- Anaplastic astrocytoma (AA)
- Glioblastoma multiforme (GBM)
- Cerebritis
- Ischemia

PATHOLOGY

- WHO grade III
- Oligos: Better prognosis than astrocytomas of same grade

CLINICAL ISSUES

- Headache, seizures are most common presentations
- Occurs at all ages; mean is 49 years
- 20-50% of oligodendrogliomas are anaplastic
- Median survival: 4 years
- 5-year survival: 40-45%; 10-year survival: 15%
- 1p and 19q deletions associated with prolonged survival

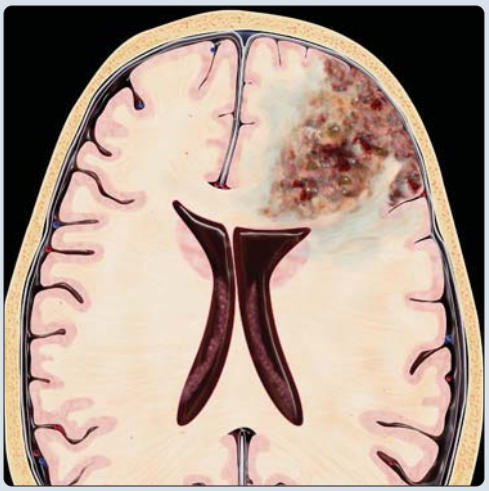

(Left) *Axial graphic shows a heterogeneous frontal cortical and subcortical mass with areas of necrosis and hemorrhage. Note the mass effect and infiltrative margins, typical of anaplastic grade III oligodendroglioma. These malignant gliomas have a poor prognosis.* **(Right)** *Axial CT image in a 43-year-old man with seizures shows a calcified, cystic, and solid frontal lobe mass. There is associated intraventricular obstructive hydrocephalus with ventricular enlargement and transependymal CSF flow (interstitial edema).*

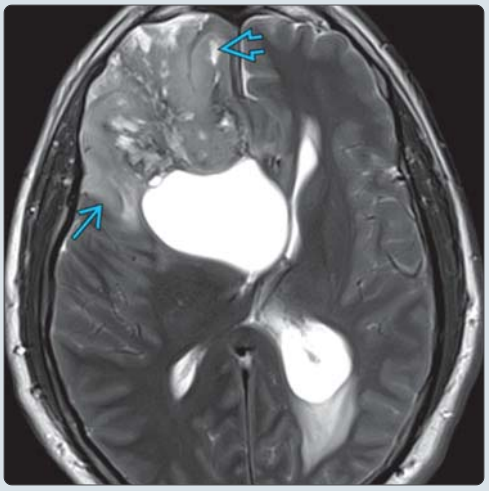

(Left) *Axial T2 MR in the same patient shows the heterogeneously hyperintense mass with significant mass effect and associated hydrocephalus. The T2 heterogeneity is related to cystic change and calcification. The calcification is better seen on CT or T2* MR.* **(Right)** *Axial T1 C+ MR in the same patient shows heterogeneous enhancement of the mass. WHO grade III anaplastic oligodendroglioma was diagnosed at resection. Enhancement is more common in grade III than in grade II oligodendrogliomas.*

https://CafePezeshki.IR

TERMINOLOGY

Abbreviations

- Anaplastic oligodendroglioma (AO), high-grade oligodendroglioma (oligo)

Definitions

- Highly cellular, diffusely infiltrating glioma
- Oligodendroglioma with focal or diffuse histologic features of malignancy

IMAGING

General Features

- Best diagnostic clue
  - Calcified frontal lobe mass involving cortex and subcortical white matter (WM)
- Location
  - Supratentorial hemispheric mass, involves cortex and subcortical WM
  - Frontal lobe most common, followed by temporal lobe
  - May involve parietal or occipital lobes
  - Often expands overlying cortex
- Morphology
  - Diffusely infiltrative mass
  - May appear discrete, but always infiltrative
  - Neoplastic cells almost always found beyond areas of abnormal signal intensity

CT Findings

- NECT
  - Mixed density (hypodense/isodense) mass
  - Majority calcify, nodular or clumped Ca++
    - May see gyriform Ca++
  - Cystic degeneration common
  - May see hemorrhage or necrosis
  - May expand, remodel, or erode calvaria

MR Findings

- T1WI
  - Heterogeneous hypointense infiltrative mass
  - May appear circumscribed
  - May see blood products, edema, necrosis
  - Cortical expansion may be seen
- T2WI
  - Heterogeneous hyperintense infiltrative mass
    - Heterogeneity related to Ca++, cystic change, blood products
  - Typically expands overlying cortex
  - May see hemorrhage, necrosis
- FLAIR
  - Heterogeneous hyperintense infiltrative mass
  - Typically expands overlying cortex
- T2* GRE
  - Ca++ &/or hemorrhage seen as areas of "blooming"
- DWI
  - No diffusion restriction is typical
- T1WI C+
  - Variable enhancement
  - New enhancement suggests malignant progression
  - 50% of all oligodendrogliomas enhance
  - AOs more likely to enhance than low-grade oligo
- MRS
  - ↑ Cho/Cr, ↓ NAA
  - Lipid/lactate peak at 1.33 ppm may be seen
- PWI
  - High relative cerebral blood volume (rCBV) common
  - Helpful to distinguish grade II from grade III
  - May help guide biopsy

Nuclear Medicine Findings

- PET
  - High glucose metabolism, accumulate FDG similar to or exceeding gray matter
  - FDG shows high-grade gliomas have uptake similar to or exceeding normal gray matter
  - Tumor/WM > 1.5 and tumor/GM > 0.6 suggest high-grade tumors
  - 11C-methionine studies show marked uptake differences between oligo, AO

Imaging Recommendations

- Best imaging tool
  - MR to delineate tumor; CT for Ca++
- Protocol advice
  - MR with contrast, GRE ± MRS and PWI

DIFFERENTIAL DIAGNOSIS

Oligodendroglioma

- Calcified mass involving gray and white matter
- May appear more circumscribed
- May be indistinguishable without biopsy
- MRS and perfusion may help preoperative diagnosis

Anaplastic Astrocytoma (AA)

- Infiltrative mass, predominantly involves white matter
- Often nonenhancing, Ca++ rare
- May be indistinguishable

Glioblastoma Multiforme (GBM)

- 95% necrotic core, enhancing rim
- Extensive surrounding T2/FLAIR signal
- Hemorrhage common

Cerebritis

- T2 hyperintensity and patchy enhancement
- Diffusion restriction is typical
- May appear mass-like
- Acute onset common

Ischemia

- Typical vascular distribution (MCA, ACA, PCA)
- Diffusion restriction if acute/subacute
- Involves GM and WM, often wedge-shaped
- Cortical, gyriform enhancement if subacute

Herpes Encephalitis

- Confined to limbic system, temporal lobes
- Blood products and enhancement common
- Acute onset is typical

Meningioma

- Enhancing extraaxial dural-based mass

https://CafePezeshki.IR

- Often calcified with broad dural base, dural "tail"
- Hyperostosis and Ca++ is characteristic
- Older patients

PATHOLOGY

General Features

- Etiology
  - May arise de novo or from malignant progression of preexisting grade II oligo
  - Arises from neoplastic transformation of mature oligodendrocytes or immature glial precursors
- Genetics
  - Loss of heterozygosity for 1p and 19q (30-40%)
  - Average number of chromosomes involved is higher in grade III than grade II oligo
- Associated abnormalities
  - Oligoastrocytoma (mixed tumor with 2 distinct neoplastic cell types) is common
    - Recent proposal to remove term oligoastrocytoma and stratify based on *IDH1* status
    - WHO grade II (oligoastrocytoma)
    - WHO grade III (anaplastic oligoastrocytoma)
    - Decreased survival compared with pure oligodendroglioma

Staging, Grading, & Classification

- WHO grade III
- May rarely be multifocal or multicentric
- Oligodendroglial gliomatosis cerebri rare

Gross Pathologic & Surgical Features

- Well-defined, grayish pink, soft unencapsulated mass
- Located in cortex and subcortical WM
- Ca++ is extremely common
- Cystic degeneration and hemorrhage common
- Necrosis may be present
- Rarely infiltrates overlying leptomeninges

Microscopic Features

- Rounded, homogeneous nuclei and clear cytoplasm
  - Perinuclear halos, fried egg and honeycomb patterns related to fixation artifact
- Microcalcifications, mucoid/cystic degeneration
- Dense network of branching capillaries
  - Chicken-wire pattern
- Increased cellularity, marked atypia
- High mitotic activity
- Microvascular proliferation and necrosis

CLINICAL ISSUES

Presentation

- Most common signs/symptoms
  - Headache, seizures most common
  - Focal neurologic deficits
  - Duration of symptoms shorter than in grade II oligo

Demographics

- Age
  - Peak incidence: 4th through 6th decades
  - Occurs at all ages; mean is 49 years
  - Older on average than WHO grade II patients
- Gender
  - Slight male predominance
- Epidemiology
  - 20-50% of oligodendrogliomas are anaplastic
  - Oligos represent 5-25% of all gliomas

Natural History & Prognosis

- Poor prognosis, survival is months to years
- Median survival: 4 years
- 5-year survival: 40-45%; 10-year survival: 15%
- Local tumor recurrence common
- CSF metastasis uncommon
- Systemic metastasis rare
- Leptomeningeal oligodendrogliomatosis, spinal cord metastasis extremely rare
- Positive prognostic factors
  - Age: < 50 years
  - Karnofsky performance status (KPS): 90-100
  - Tumors ≤ 4 cm
  - Complete tumor resection
- *CDKN2A* tumor suppressor gene deletions associated with shorter survival
- 1p and 19q loss of heterozygosity associated with prolonged survival
- Oligos have better prognosis than astrocytomas of same grade

Treatment

- Surgical resection + adjuvant chemo and radiation therapy

DIAGNOSTIC CHECKLIST

Consider

- Many gliomas may mimic AO
- Presence of Ca++, cortical expansion may help distinguish AOs from other gliomas

Image Interpretation Pearls

- AOs cannot be reliably differentiated from grade II oligos on conventional MR
- Neoplastic cells are almost always found beyond areas of abnormal signal intensity
- New enhancement in previously nonenhancing oligo suggests malignant progression

SELECTED REFERENCES

1. Ahluwalia MS et al: Efficacy and patient-reported outcomes with dose-intense temozolomide in patients with newly diagnosed pure and mixed anaplastic oligodendroglioma: a phase II multicenter study. J Neurooncol. 122(1):111-9, 2015
2. Kobayashi K et al: Prognostic value of volume-based measurements on (11)C-methionine PET in glioma patients. Eur J Nucl Med Mol Imaging. 42(7):1071-80, 2015
3. Speirs CK et al: Impact of 1p/19q codeletion and histology on outcomes of anaplastic gliomas treated with radiation therapy and temozolomide. Int J Radiat Oncol Biol Phys. 91(2):268-76, 2015
4. Fudaba H et al: Comparison of multiple parameters obtained on 3T pulsed arterial spin-labeling, diffusion tensor imaging, and MRS and the Ki-67 labeling index in evaluating glioma grading. AJNR Am J Neuroradiol. 35(11):2091-8, 2014
5. Chawla S et al: Differentiation between oligodendroglioma genotypes using dynamic susceptibility contrast perfusion-weighted imaging and proton MR spectroscopy. AJNR Am J Neuroradiol. 34(8):1542-9, 2013
6. Louis DN et al: WHO Classification of Tumours of the Central Nervous System: Anaplastic Oligodendroglioma. Lyon, France: IARC Press. 60-2, 2007

https://CafePezeshki.IR

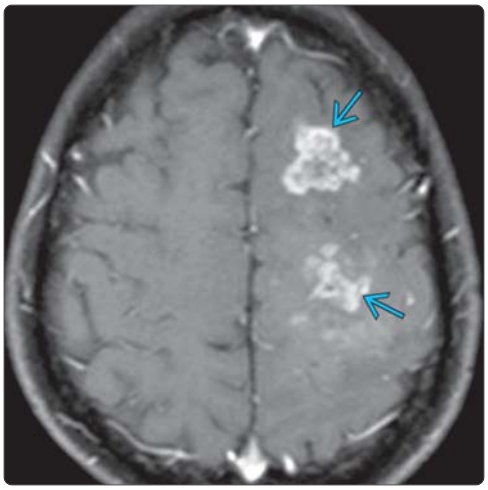

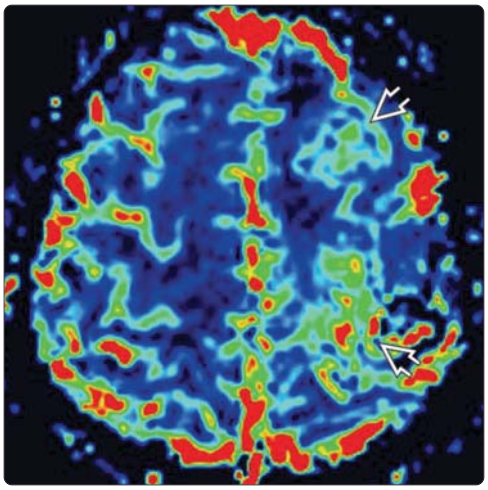

(Left) *Axial T1 C+ MR in a patient who was treated with surgery, radiation therapy, and temozolomide for her anaplastic oligodendroglioma shows new enhancement in the left frontal lobe. New enhancement in a previously nonenhancing mass is highly concerning for disease progression.* **(Right)** *Axial rCBV color map from a DSC MR perfusion study shows elevated relative cerebral blood volume in the regions of new enhancement related to progressive tumor.*

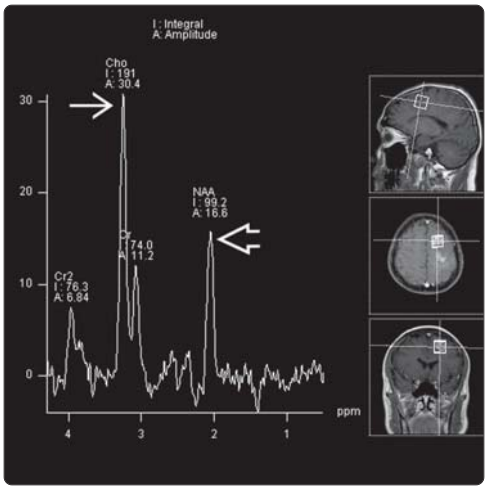

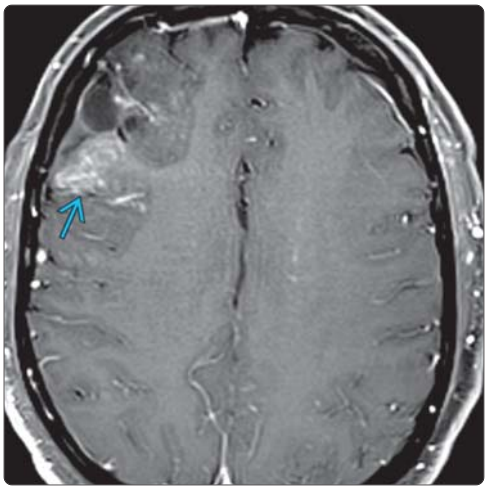

(Left) *MRS in the same patient shows a typical malignant tumor spectrum with marked elevation of choline and decreased NAA. MR perfusion and MRS may be helpful in the preoperative diagnosis as well as the post-treatment evaluation of patients with glial neoplasms.* **(Right)** *Axial T1WI C+ FS MR shows a heterogeneously enhancing frontal mass. Grade III oligodendrogliomas was found at resection. Oligodendrogliomas have a better prognosis than pure astrocytomas of the same grade.*

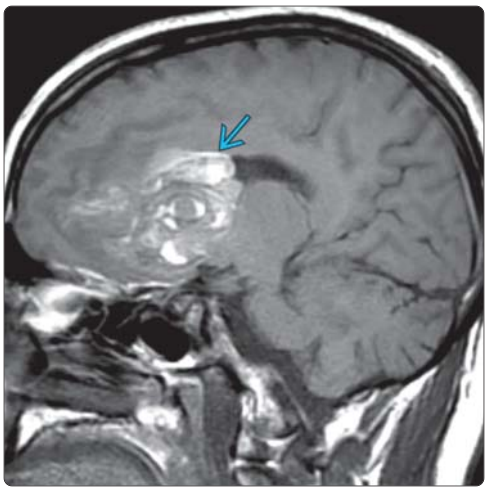

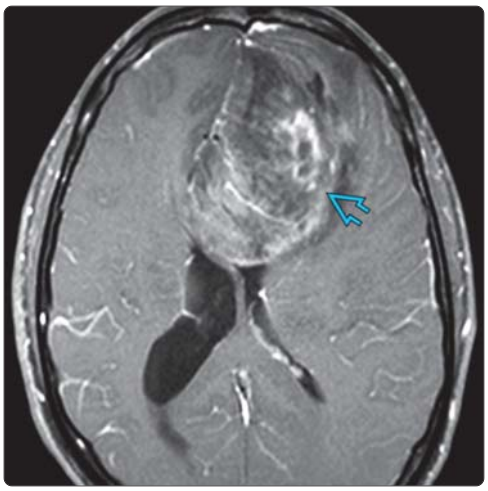

(Left) *Sagittal T1 MR shows a heterogeneous mass with areas of hyperintensity related to blood products and calcifications in this anaplastic oligodendroglioma.* **(Right)** *Axial T1WI C+ FS MR in a different patient with anaplastic oligodendroglioma shows heterogeneous enhancement of a large mass. Approximately 50% of all oligodendrogliomas enhance. Enhancement does not reliably differentiate between grade II and grade III oligodendrogliomas.*

https://CafePezeshki.IR

KEY FACTS

TERMINOLOGY

- Rare glial neoplasm with perivascular pseudorosettes and variable biological behavior

IMAGING

- Well-delineated, mixed solid and cystic hemispheric mass with bubbly appearance
- Almost always supratentorial, usually within cerebral hemisphere
- Majority (up to 80%) have calcification
- T2WI: Solid and cystic mass with heterogeneous bubbly appearance of solid portion
- GRE/SWI: Hypointensity related to Ca++ or blood products
- Heterogeneous enhancement is typical (75%)
  - Mixed solid, rim-enhancing pattern
- MRS may show ↓ NAA, ↑ choline

TOP DIFFERENTIAL DIAGNOSES

- Ependymoma
- Primitive neuroectodermal tumor
- Atypical teratoid-rhabdoid tumor
- Oligodendroglioma
- Pleomorphic xanthoastrocytoma

PATHOLOGY

- No WHO grade officially established
  - Low- and high-grade histologic features

CLINICAL ISSUES

- Most common presentation: Headache, seizures, focal neurologic deficit
- Occurs at all ages; median is 11 years (peak: 10-30 years)
- Rare: 0.5-3% of primary gliomas
- Low-grade astroblastomas often have good long-term survival
- Surgical resection is treatment of choice
- Adjuvant radiation therapy and chemotherapy for high-grade (anaplastic) lesions

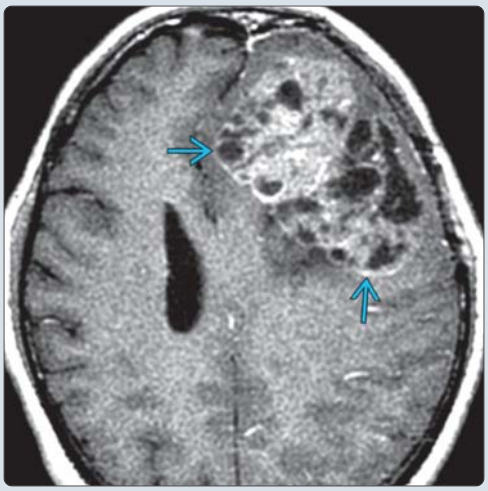

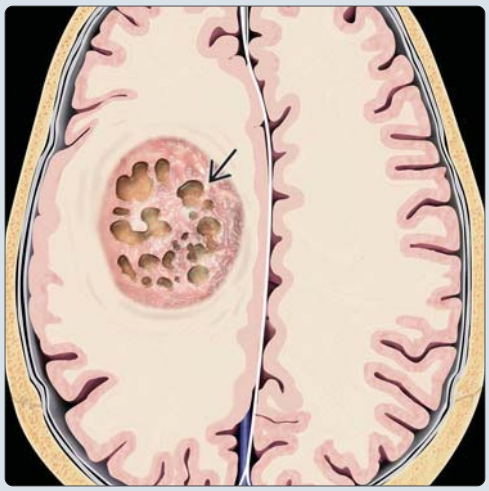

(Left) *Axial T1WI C+ MR shows a large frontal lobe mass with strong, heterogeneous enhancement. Note the multiple cysts surrounded by rims and solid masses of enhancing tissue. Note the relative lack of surrounding edema and mass effect for the size of the lesion, typical of astroblastoma.* **(Right)** *Axial graphic shows a well-delineated mixed solid and cystic hemispheric mass with calcification and a bubbly appearance characteristic of astroblastoma.*

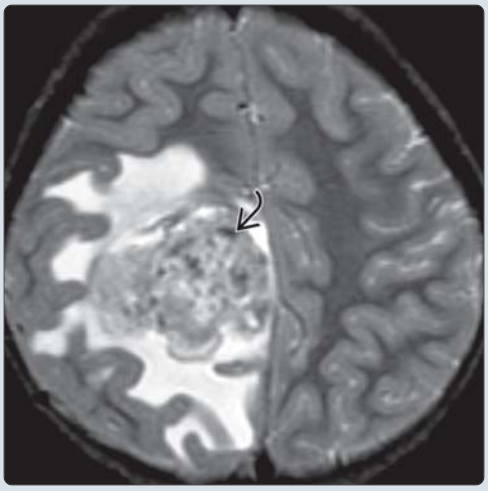

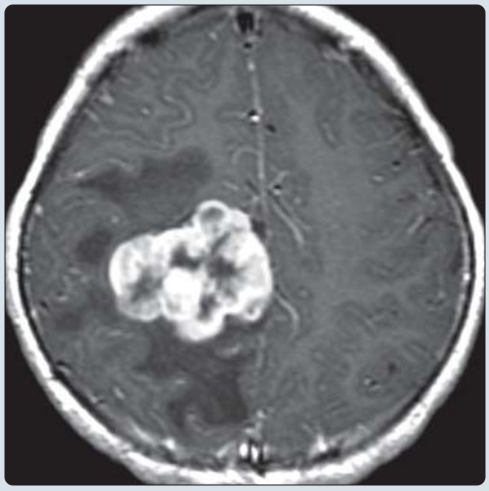

(Left) *Axial T2WI MR shows a large heterogeneous mass in this 5 year old with seizures. The areas of low signal intensity are related to calcifications. These rare tumors typically occur in children and young adults.* **(Right)** *Axial T1WI C+ MR in the same patient shows strong, heterogeneous enhancement of the mass. Histology revealed a well-differentiated astroblastoma. Surgical resection is the primary treatment with adjuvant radiation and chemotherapy reserved for anaplastic tumors.*

https://CafePezeshki.IR

TERMINOLOGY

Definitions

- Rare glial neoplasm with perivascular pseudorosettes and variable biological behavior

IMAGING

General Features

- Best diagnostic clue
  - Well-delineated mixed solid and cystic hemispheric mass with bubbly appearance in child or young adult
- Location
  - Almost always supratentorial, usually within cerebral hemisphere
    - Parietal > frontal lobe
- Size
  - Range: 1-10 cm; mean: 4 cm
- Morphology
  - Circumscribed, lobular, solid and cystic mass with dominant solid component

CT Findings

- NECT
  - Mixed areas of hyperdensity, hypodensity, isodensity typical
  - Majority (up to 80%) have calcification (Ca++)

MR Findings

- T1WI
  - Solid and cystic mass with heterogeneous signal
- T2WI
  - Solid and cystic mass with heterogeneous bubbly appearance of solid portion
  - Hyperintense to white matter (80%)
  - 50% lack peritumoral hyperintensity
- T1WI C+
  - Heterogeneous enhancement (70-75%)
  - < 10% show no enhancement

Imaging Recommendations

- Best imaging tool
  - NECT best to identify calcification
  - Multiplanar contrast-enhanced MR best for tumor evaluation

DIFFERENTIAL DIAGNOSIS

Ependymoma

- Supratentorial (1/3): Heterogeneous parenchymal/periventricular enhancing mass
- Hemorrhage, necrosis, Ca++, and edema common

Primitive Neuroectodermal Tumor (PNET)

- Peripheral, heterogeneous parenchymal mass
- Hemorrhage, cysts, and Ca++ common

Atypical Teratoid-Rhabdoid Tumor (AT/RT)

- Heterogeneous solid mass with hemorrhage, necrosis, Ca++, cyst formation

Oligodendroglioma

- Peripheral, cortically based mass ± enhancement
- Ca++ common; minimal surrounding edema

Pleomorphic Xanthoastrocytoma

- Cyst with mural nodule in temporal lobe typical
- Enhancing nodule abuts dura with dural "tail"

Pilocytic Astrocytoma

- Enhancing solid component + cyst common

PATHOLOGY

Staging, Grading, & Classification

- No WHO grade officially established
- Some pathologists designate well differentiated (low grade) or anaplastic (high grade) based on histologic features

Gross Pathologic & Surgical Features

- Circumscribed, well-demarcated mass, cysts common
- Necrosis may be seen in low-grade or high-grade lesions

Microscopic Features

- Perivascular pseudorosettes
- Oval to elongated hyperchromatic nuclei; ± Ca++

CLINICAL ISSUES

Presentation

- Most common signs/symptoms
  - Headache, seizures, focal neurologic deficit

Demographics

- Age
  - Most common in children and young adults
    - Median: 11 years
- Gender
  - Female predominance
- Epidemiology
  - Rare (0.5-3% of primary gliomas)

Natural History & Prognosis

- Gross total resection is associated with favorable outcome
- Low-grade astroblastomas often have good long-term survival
- Anaplastic histology is associated with tumor recurrence and progression

DIAGNOSTIC CHECKLIST

Consider

- "Bubbly" hemispheric mass in child or young adult may be astroblastoma

Image Interpretation Pearls

- Astroblastoma often shows lack of significant mass effect for size of lesion

SELECTED REFERENCES

1. Asha U et al: Lack of IDH1 mutation in astroblastomas suggests putative origin from ependymoglial cells? Neuropathology. ePub, 2015
2. de la Garma VH et al: High-grade astroblastoma in a child: Report of one case and review of literature. Surg Neurol Int. 5:111, 2014
3. Janz C et al: Astroblastoma: report of two cases with unexpected clinical behavior and review of the literature. Clin Neurol Neurosurg. 125:114-24, 2014

https://CafePezeshki.IR

KEY FACTS

TERMINOLOGY

- Rare glioma arising from anterior wall/roof of 3rd ventricle

IMAGING

- Adult with well-delineated, homogeneously enhancing 3rd ventricular mass
- CT: Moderately hyperdense anterior 3rd ventricular mass
- Ca++ may be present
- Hydrocephalus in 10-15% of cases

TOP DIFFERENTIAL DIAGNOSES

- Craniopharyngioma
- Pilocytic astrocytoma
- Germinoma
- Choroid plexus papilloma
- Colloid cyst

PATHOLOGY

- WHO grade II
- Cords/clusters of oval/polygonal epithelioid cells within mucinous stroma
- Likely ependymal origin
  - From ependymal cells in/near lamina terminalis
  - May arise from subcommissural organ

CLINICAL ISSUES

- Headache, nausea due to hydrocephalus most common symptom
  - Endocrine disturbances (hypothyroidism, diabetes insipidus, amenorrhea)
  - Dysautonomias
  - Visual disturbances
- Surgical excision is primary therapy

DIAGNOSTIC CHECKLIST

- Consider chordoid glioma of 3rd ventricle if adult with T2 hyperintense, enhancing, anterior 3rd ventricular mass

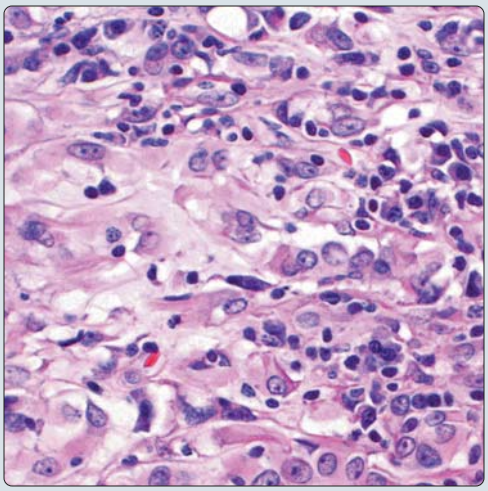

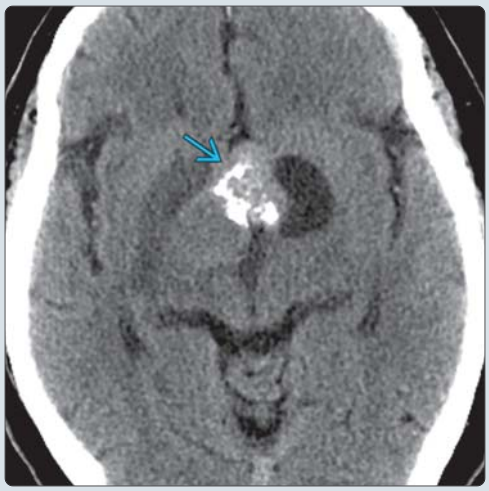

(Left) *High-power H&E stain of a classic chordoid glioma shows a neoplasm with clusters and cords of epithelioid cells with abundant eosinophilic cytoplasm in a mucinous stroma. GFAP (not shown) was strongly positive.* **(Right)** *Axial CT in a 48-year-old man with visual changes shows a calcified cystic and solid suprasellar/anterior 3rd ventricular region mass ⇨. Imaging mimics the more common craniopharyngioma. Chordoid glioma was diagnosed at resection. (Courtesy L. Shah, MD.)*

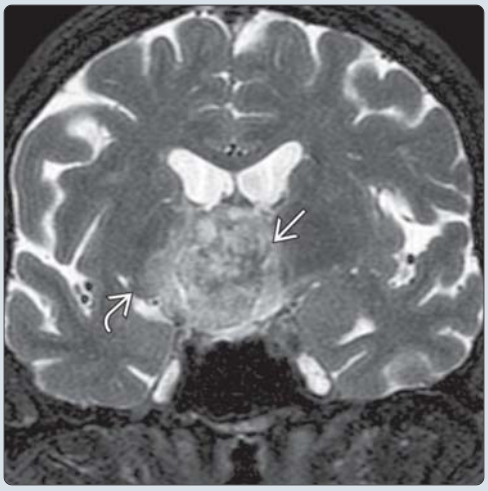

(Left) *Coronal T2 FS MR image in a 65-year-old woman with a 3-year history of weight gain and personality changes shows a lobulated heterogeneously hyperintense mass ⇨ mostly contained within the 3rd ventricle. The optic tract ⇨ is displaced laterally.* **(Right)** *Sagittal T1 C+ MR image in the same patient shows strong, uniform enhancement of the slightly lobulated 3rd ventricular mass ⇨. Chordoid glioma was diagnosed at histopathology. (Courtesy C. Glastonbury, MBBS.)*

https://CafePezeshki.IR

TERMINOLOGY

Abbreviations

- Chordoid glioma of third ventricle (CGOTV)

Definitions

- Rare glioma arising from anterior wall/roof of 3rd ventricle

IMAGING

General Features

- Best diagnostic clue
  - Well-delineated, homogeneously enhancing anterior 3rd ventricular mass
- Location
  - Suspended from roof/anterior wall of 3rd ventricle
- Size
  - 1.5-7 cm
- Morphology
  - Rounded or ovoid, well circumscribed

MR Findings

- T1WI
  - 3rd ventricular mass isointense to brain
  - Hydrocephalus in 10-15% of cases
- T2WI
  - Iso-/hyperintense 3rd ventricular mass
- T1WI C+
  - Strong uniform enhancement

Imaging Recommendations

- Protocol advice
  - Thin section imaging through sella region
    - Thin sagittal, coronal T1WI, T2WI
    - T1WI C+ FS sagittal, coronal

DIFFERENTIAL DIAGNOSIS

Craniopharyngioma

- Heterogeneous, 90% cystic, 90% Ca++
- Suprasellar location most common
- Children > adults

Pilocytic Astrocytoma

- Optic tract, hypothalamus, 3rd ventricular floor
- Children, young adults, ± neurofibromatosis type 1

Germinoma

- Diabetes insipidus common
- Usually involves stalk, suprasellar or pineal region
- Hyperdense on CT, homogeneously enhancing
- Children, young adults

Choroid Plexus Papilloma

- Lobulated, enhancing lateral ventricular mass in child
- Rare in 3rd ventricle
- Typically child < 5 years

Colloid Cyst

- Wedged between fornices at foramen of Monro
- Round, nonenhancing

Ependymoma

- Enhancing 4th ventricular mass typical
- Uncommon in 3rd ventricle

PATHOLOGY

General Features

- Etiology
  - Likely ependymal origin
    - From ependymal cells in or around lamina terminalis
    - May arise from subcommissural organ

Staging, Grading, & Classification

- WHO grade II

Gross Pathologic & Surgical Features

- Grossly well circumscribed
- Occasional extension into adjacent hypothalamic tissue
- Variable calcifications, cystic regions; hemorrhage rare

Microscopic Features

- Cords/clusters of oval/polygonal epithelioid cells within mucinous stroma
  - Strongly GFAP(+); vimentin (+)
  - Mitotic figures uncommon

CLINICAL ISSUES

Presentation

- Most common signs/symptoms
  - Headache ± nausea due to hydrocephalus
- Other signs/symptoms
  - Visual field defect
  - Endocrine disturbances (10-15%)
    - Hypothyroidism, diabetes insipidus, amenorrhea
  - Dysautonomias (hyperhidrosis)

Demographics

- Age: Adults (35-60 years)
- Gender: Female predominance (M:F = 1:2)
- Epidemiology: Rare, represent < 1% of all gliomas

Natural History & Prognosis

- Slow enlargement

Treatment

- Surgical excision is primary therapy

DIAGNOSTIC CHECKLIST

Image Interpretation Pearls

- Bulky, well-circumscribed 3rd ventricular mass in adult

SELECTED REFERENCES

1. Hewer E et al: Suprasellar chordoid neoplasm with expression of thyroid transcription factor 1: evidence that chordoid glioma of the third ventricle and pituicytoma may form part of a spectrum of lineage-related tumors of the basal forebrain. Hum Pathol. ePub, 2015
2. Morais BA et al: Chordoid glioma: Case report and review of the literature. Int J Surg Case Rep. 7C:168-71, 2015
3. Smith AB et al: From the radiologic pathology archives: intraventricular neoplasms: radiologic-pathologic correlation. Radiographics. 33(1):21-43, 2013
4. Glastonbury CM et al: Masses and malformations of the third ventricle: normal anatomic relationships and differential diagnoses. Radiographics. 31(7):1889-905, 2011

https://CafePezeshki.IR

KEY FACTS

TERMINOLOGY

- Angiocentric glioma (AG) is also known as
  - Angiocentric neuroepithelial tumor (ANET)
  - Monomorphous angiocentric glioma
- Epilepsy-associated, slowly-growing, low-grade cortical neoplasm mainly affecting children and young adults

IMAGING

- Frontal, temporal lobes most common sites
- Nonenhancing, ill-defined cortical mass
  - Most commonly solid
  - Rarely mixed solid, cystic
  - Rim-like hyperintensity on T1WI
- Hyperintense on T2WI, FLAIR
  - Stalk-like extension toward ventricle common

TOP DIFFERENTIAL DIAGNOSES

- Dysembryoplastic neuroepithelial tumor (DNET)
- Ganglioglioma
- Oligodendroglioma

PATHOLOGY

- WHO grade I
  - Angiocentric growth pattern
  - MIB-1 proliferation low (1-5%)
  - No malignant degeneration

CLINICAL ISSUES

- Longstanding drug-resistant focal epilepsy
  - Typically starting in childhood
- Complete surgical resection curative

DIAGNOSTIC CHECKLIST

- Cortical neoplasm in child/young adult with refractory epilepsy
- Nonenhancing cortical mass with rim-like hyperintensity on T1 MR

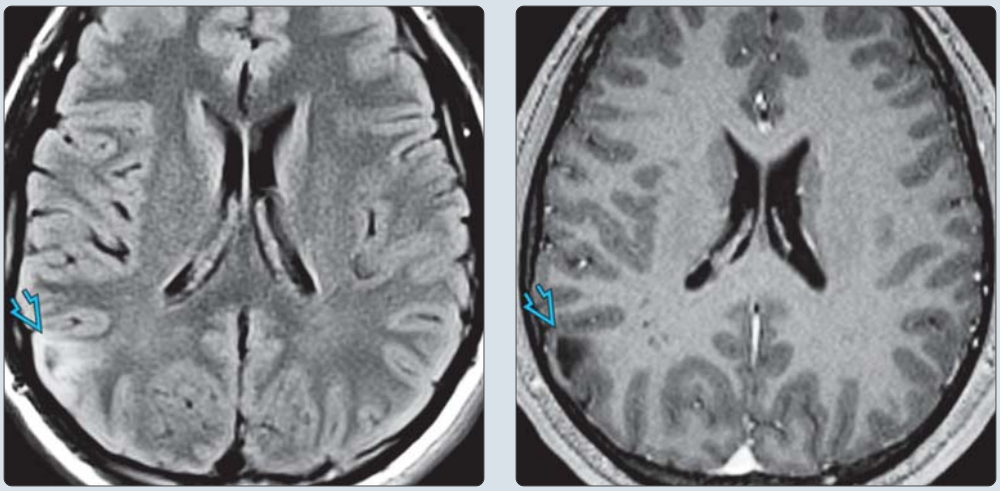

(Left) *Axial FLAIR MR in a young adult with longstanding seizures shows a wedge-shaped hyperintense cortical and subcortical mass in the right parietal lobe. Note the lack of surrounding edema.* **(Right)** *Axial T1 C+ MR in the same patient shows no enhancement within the mass, a typical finding in angiocentric glioma. Focal cortical dysplasia is often present adjacent to the tumor and must be resected to prevent recurrent seizures. (Courtesy M Castillo, MD.)*

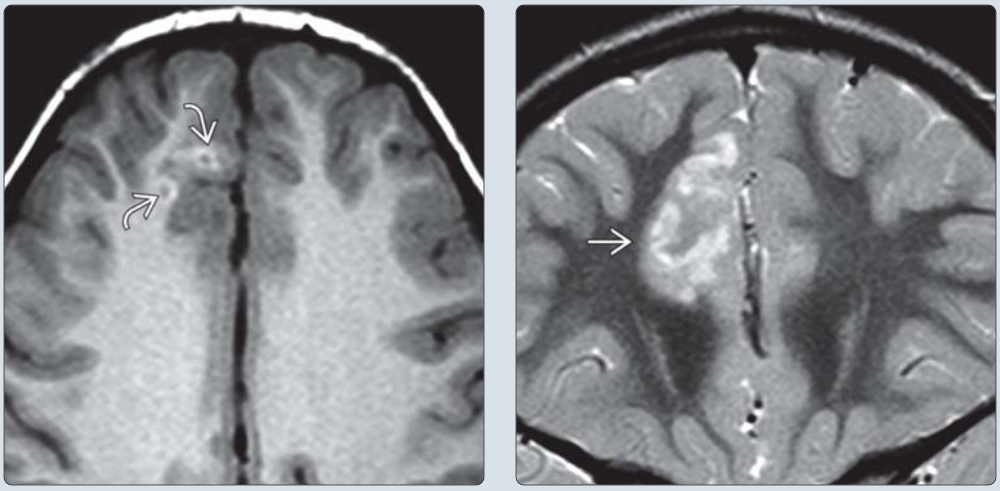

(Left) *Axial T1WI MR in 6-year-old child with refractory epilepsy shows an ill-defined, cortical and subcortical mass. Note the hyperintense ring-like areas, findings typical for an angiocentric glioma.* **(Right)** *Coronal T2 MR in the same patient shows high signal intensity of the cortical and subcortical right frontal lobe lesion. Angiocentric glioma was diagnosed at surgical resection. Imaging may mimic the more common DNET. (Courtesy A. Rossi, MD.)*

https://CafePezeshki.IR

TERMINOLOGY

Abbreviations

- Angiocentric glioma (AG)

Synonyms

- Angiocentric neuroepithelial tumor (ANET)
- Monomorphous angiocentric glioma

Definitions

- Epilepsy-associated, slowly-growing, low-grade cortical neoplasm mainly affecting children and young adults

IMAGING

General Features

- Best diagnostic clue
  - Nonenhancing, ill-defined cortical/subcortical mass in child/young adult with seizures
- Location
  - Cortex or subcortical white matter
  - Frontal > temporal lobes most common sites
- Size
  - 3-4 cm (up to 10 cm)

Imaging Recommendations

- Best imaging tool
  - MR

CT Findings

- Solid, cortically-based tumor
- No calcification, hemorrhage, or necrosis

MR Findings

- T1WI
  - Ill-defined cortical/subcortical mass
  - Most commonly solid
    - Rarely mixed solid, cystic
  - Can be hypo-, iso-, or hyperintense
  - Rim-like hyperintensity may be seen
- T2WI
  - Hyperintense expansile cortical/subcortical mass
  - Stalk-like extension toward ventricle common
- FLAIR
  - Hyperintense
  - Stalk-like extension toward ventricle
- T1WI C+
  - Usually no enhancement

DIFFERENTIAL DIAGNOSIS

Dysembryoplastic Neuroepithelial Tumor (DNET)

- Cortical/subcortical cystic or "bubbly" T2 hyperintense mass
- May be wedge-shaped and point towards ventricle
- Enhancement uncommon

Ganglioglioma

- Cortical mass with cyst and mural nodule is common
- May be predominantly solid mass
- May see Ca++ (30-50%) and enhancement (50%)

Oligodendroglioma

- Round or ovoid T2 hyperintense cortical/subcortical mass
- Ca++ in ~ 80%, variable enhancement

PATHOLOGY

General Features

- Etiology
  - Uncertain origin: Astrocytic and ependymal lineages have been suggested
  - Dysembryoplastic theory
    - Radial glia suggested cell of origin
- Associated abnormalities
  - Adjacent focal cortical dysplasia is common

Staging, Grading, & Classification

- WHO grade I

Microscopic Features

- Small polygonal/spindle-shaped tumor cells with ependymal features
- Angiocentric growth pattern
- MIB-1 proliferation low (1-5%)

CLINICAL ISSUES

Presentation

- Most common signs/symptoms
  - Drug-resistant focal epilepsy starting in childhood

Demographics

- Age
  - Children, young adults
- Epidemiology
  - AG represents up to 8% of tumors found at epilepsy surgery

Natural History & Prognosis

- Benign course
- No malignant degeneration

Treatment

- Complete surgical resection curative

DIAGNOSTIC CHECKLIST

Consider

- Cortical neoplasm in child/young adult with longstanding seizures

Image Interpretation Pearls

- Ill-defined nonenhancing cortical mass with rim-like hyperintensity on T1 MR

SELECTED REFERENCES

1. Ni HC et al: Angiocentric glioma: a report of nine new cases, including four with atypical histological features. Neuropathol Appl Neurobiol. 41(3):333-46, 2015
2. Grajkowska W et al: Angiocentric glioma: a rare intractable epilepsy-related tumour in children. Folia Neuropathol. 52(3):253-9, 2014
3. Buccoliero AM et al: Angiocentric glioma: clinical, morphological, immunohistochemical and molecular features in three pediatric cases. Clin Neuropathol. 32(2):107-13, 2013
4. Liu CQ et al: Refractory temporal lobe epilepsy caused by angiocentric glioma complicated with focal cortical dysplasia: a surgical case series. J Neurooncol. 110(3):375-80, 2012
5. Lellouch-Tubiana A et al: Angiocentric neuroepithelial tumor (ANET): a new epilepsy-related clinicopathological entity with distinctive MRI. Brain Pathol. 15(4):281-6, 2005

https://CafePezeshki.IR

KEY FACTS

TERMINOLOGY

- Posterior fossa ependymoma (PF-EPN)

IMAGING

- Ependymoma can occur anywhere in neuraxis
- Most common site: Posterior fossa (2/3 of cases)
  - Lobulated mass in body/inferior 4th ventricle
    - Soft or "plastic" tumor
      - Accommodates to shape of ventricle
      - Squeezes through foramen of Magendie into cisterna magna
      - ± extension through foramina of Luschka into CPA cisterns
- NECT
  - Ca++ common (50%)
  - ± cysts, hemorrhage
  - Obstructive hydrocephalus common
- MR
  - Variable enhancement
  - Usually does not restrict on DWI

PATHOLOGY

- 3 posterior fossa ependymoma molecular subtypes
  - Posterior fossa ependymoma subtype A (PF-EPN-A)
    - Most common (50%)
    - Predominately infants
    - Poor prognosis
  - Posterior fossa ependymoma subtype B (PF-EPN-B)
    - 10% of PF-EPNs
    - Older children, adults
    - Better prognosis
  - Subependymoma (PF-SE; discussed in separate chapter)

CLINICAL ISSUES

- Signs of increased intracranial pressure
- 3-17% CSF dissemination

DIAGNOSTIC CHECKLIST

- Much less common than PNET-MB or pilocytic astrocytoma

(Left) *Sagittal graphic shows a posterior fossa ependymoma extending through the 4th ventricle outlet foramina into the cisterna magna ⇨ and CPA cistern ⇨. This "plastic" pattern of growth is typical of ependymoma in this location and increases the difficulty of surgical resection.* **(Right)** *Sagittal T1 C+ MR shows classic PF-EPN as a lobulated mixed cystic/solid enhancing mass displacing the brainstem anteriorly, expanding the 4th ventricle. Tumor extrudes posteroinferiorly through the foramen of Magendie ⇨ into the cisterna magna ⇨.*

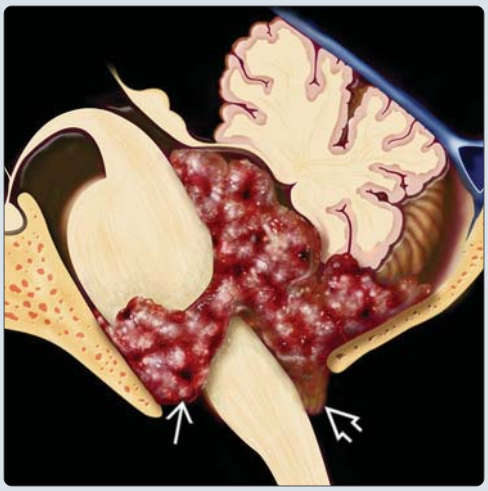

(Left) *Axial T1 C+ FS MR scan in the same case shows the enhancing mixed cystic ⇨ and solid ⇨ tumor expanding, filling the 4th ventricle ⇨.* **(Right)** *Coronal T1 C+ MR scan in the same case again shows the mixed cystic/solid enhancing mass conforming to the shape of the expanded 4th ventricle ⇨. The tumor extrudes inferiorly through the enlarged foramen of Magendie ⇨ and extends into the upper cervical spinal canal ⇨. WHO II cellular ependymoma was found at surgery.*

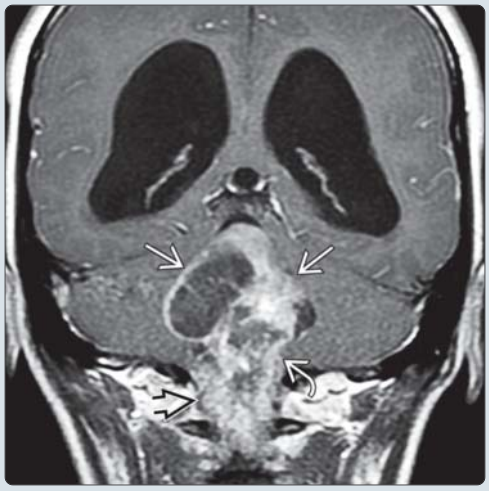

https://CafePezeshki.IR

TERMINOLOGY

Definitions

- Posterior fossa ependymoma (PF-EPN)
  - Slow-growing tumor of ependymal cells
  - Subtypes: Cellular, papillary, clear cell, tanycytic

IMAGING

General Features

- Best diagnostic clue
  - Soft "plastic" tumor squeezes out through 4th ventricle foramina into cisterns
  - Heterogeneous density, signal intensity
  - ± indistinct interface with floor of 4th ventricle
- Location
  - May arise along entire neuraxis (hemispheres, hindbrain, spinal cord)
  - 2/3 posterior fossa (most in 4th ventricle)
    - Usually from inferior 1/2 of 4th ventricle
    - Extends anterolaterally through foramina of Luschka
  - 1/3 supratentorial
    - Majority outside ventricles, in periventricular white matter (WM)
- Size
  - 2-4 cm
- Morphology
  - Accommodates to shape of ventricle
  - Typical = lobulated inferior 4th ventricle mass
    - Anterolateral extension through recess(es) into CPA cistern
    - Posteroinferior extension through foramen of Magendie into cisterna magna

CT Findings

- NECT
  - 4th ventricle mass
  - Ca++ common (50%); ± cysts, hemorrhage
  - Hydrocephalus common
- CECT
  - Variable heterogeneous enhancement

MR Findings

- T1WI
  - Heterogeneous, usually iso- to hypointense
  - Cystic foci slightly hyperintense to CSF
  - Hyperintense foci (Ca++, blood products) common
- T2WI
  - Heterogeneous, usually iso- to hyperintense
  - Hyperintense cystic foci
  - Hypointense foci (Ca++, blood products)
- FLAIR
  - Can show sharp interface between tumor, CSF
  - Tumor cysts very hyperintense to CSF
- T2* GRE
  - "Blooming" of Ca++, hemorrhage
- DWI
  - No restriction (relatively low cellularity)
  - Intratumoral hemorrhage may complicate appearance
- T1WI C+
  - Enhancement
    - Varies from none to mild/moderate
    - Typically heterogeneous
- MRS
  - ↓ NAA, ↑ Cho
    - NAA:Cho ratio higher than in primitive neuroectodermal tumor-medulloblastoma (PNET-MB)
  - ↑ lactate
  - MR spectroscopy alone does not reliably differentiate ependymoma from astrocytoma or PNET-MB

Imaging Recommendations

- Best imaging tool
  - NECT + MR with contrast, MRS
- Protocol advice
  - Image entire neuraxis before surgery
  - Need combination of imaging, clinical findings to distinguish from PNET-MB
  - High-quality sagittal imaging can distinguish point of origin as floor vs. roof of 4th ventricle

DIFFERENTIAL DIAGNOSIS

Medulloblastoma (PNET-MB)

- Hyperdense on NECT
- Homogeneous mass
- Arises from roof of 4th ventricle
- More distinct interface with floor
- Low ADC, high cellularity

Cerebellar Pilocytic Astrocytoma (PA)

- Heterogeneous tumor of cerebellar hemisphere
- Cyst with mural nodule
- Solid portion enhances vigorously

Brainstem Glioma

- Infiltrating mass expanding brainstem
- Homogeneous signal on MR
- May project dorsally into 4th ventricle

Atypical Teratoid/Rhabdoid Tumor (AT/RT)

- Large mass with cyst or necrosis
- Variable enhancement pattern

Choroid Plexus Papilloma

- Vigorously enhancing intraventricular tumor
- 4th ventricle location more common in adults

Oligodendroglioma

- Heterogeneous supratentorial mass in young adults
- Frontal lobe lesion with Ca++

Glioblastoma

- Older adults; rare in posterior fossa
- Heterogeneous malignant supratentorial mass
- Necrosis, hemorrhage common

PATHOLOGY

General Features

- Etiology
  - Thought to arise from regionally distinct radial glial cells
    - Differences between these cell populations carried forward in neoplasm

https://CafePezeshki.IR

- May account for part of observed heterogeneity
- Genetics
  - Gene amplifications almost totally absent
    - Gains or losses of whole chromosomes characteristic
    - Epigenetic abnormalities most important
  - DNA methylation profiling identifies 9 molecular ependymoma subgroups
  - 3 posterior fossa ependymoma subgroups
    - Subependymoma (PF-SE)
    - Posterior fossa ependymoma subtype A (PF-EPN-A)
      - Largest ependymoma subgroup (~ 50% of all cases)
      - Predominately infants
      - Stable genome ("genetically bland")
      - Epigenetically deregulated (CpG island methylator phenotype-positive [CIMP(+)])
      - Highly malignant with poor response to surgery, radiation therapy
      - **But** CIMP+ ("methylated") tumors may be responsive to drugs targeting DNA or H3K27 methylation
    - Posterior fossa ependymoma subtype B (PF-EPN-B)
      - Older children, adults
      - 10% of all cases
      - Most unstable genome of all ependymomas
      - Large-scale copy number alterations (often whole chromosome gains/losses)
      - Better prognosis
      - CIMP(-)
  - Molecular subgroups remain stable at relapse
  - Risk stratification by molecular subgrouping superior to histological grading

Staging, Grading, & Classification

- WHO grade II (low grade, well differentiated)
- WHO grade III (high grade, anaplastic)

Gross Pathologic & Surgical Features

- Well demarcated
- Soft, lobulated, grayish red mass
- ± cysts, necrosis, hemorrhage
- Extrudes through 4th ventricle outlet foramina into "plastic development"
- Typically displaces rather than invades adjacent brain parenchyma

Microscopic Features

- Despite being histologically identical, ependymomas from different anatomic regions are biologically and clinically distinct

CLINICAL ISSUES

Presentation

- Most common signs/symptoms
  - ↑ intracranial pressure: Headache, nausea, vomiting
- Clinical profile
  - Age 1-5 years; headache, vomiting
- Other
  - Ataxia, hemiparesis, visual disturbances, neck pain, torticollis, dizziness
  - Infants: Irritability, lethargy, developmental delay, vomiting, macrocephaly

Demographics

- Age
  - PF-EPN-A
    - 1-5 years (mean: 3 years)
  - PF-EPN-B
    - Mean age at diagnosis: 30 years
- Gender
  - Slight male predominance
- Epidemiology
  - 3-5% of all intracranial tumors
  - 15% of posterior fossa tumors in children
    - 3rd most common posterior fossa tumor in children
      - Most common are PA and PNET-MB

Natural History & Prognosis

- Prognosis highly variable
  - PF-EPN-A 5-year overall survival: 50-60%
  - PF-EPN-B: 90-95% 5-year survival
- 3-17% CSF dissemination
- 5-year survival after recurrence: 15%

Treatment

- Maximal safe surgical resection, then XRT
  - Surgical resection often difficult due to adherence and infiltrating nature of tumor
  - Gross total resection + XRT correlates with improved survival
- Chemotherapy does not improve survival

DIAGNOSTIC CHECKLIST

Consider

- Much less common than PNET-MB or PA
- Gross total resection has greater impact on survival than in PNET-MB or PA
- Surveillance imaging to detect asymptomatic recurrence can increase survival

Image Interpretation Pearls

- Indistinct interface
  - With **floor** of 4th ventricle = ependymoma
  - With **roof** of 4th ventricle = PNET-MB

SELECTED REFERENCES

1. Archer TC et al: Defining the molecular landscape of ependymomas. Cancer Cell. 27(5):613-5, 2015
2. Huse JT et al: The emerging molecular foundations of pediatric brain tumors. J Child Neurol. ePub, 2015
3. Mohankumar KM et al: An in vivo screen identifies ependymoma oncogenes and tumor-suppressor genes. Nat Genet. ePub, 2015
4. Nowak J et al: Systematic comparison of MRI findings in pediatric ependymoblastoma with ependymoma and CNS primitive neuroectodermal tumor not otherwise specified. Neuro Oncol. ePub, 2015
5. Mack SC et al: Epigenomic alterations define lethal CIMP-positive ependymomas of infancy. Nature. 506(7489):445-50, 2014
6. Nobusawa S et al: Molecular genetics of ependymomas and pediatric diffuse gliomas: a short review. Brain Tumor Pathol. 31(4):229-33, 2014
7. Yuh EL et al: Imaging of ependymomas: MRI and CT. Childs Nerv Syst. 25(10):1203-13, 2009
8. Schneider JF et al: Multiparametric differentiation of posterior fossa tumors in children using diffusion-weighted imaging and short echo-time 1H-MR spectroscopy. J Magn Reson Imaging. 26(6):1390-8, 2007
9. Good CD et al: Surveillance neuroimaging in childhood intracranial ependymoma: how effective, how often, and for how long? J Neurosurg. 94(1):27-32, 2001

https://CafePezeshki.IR

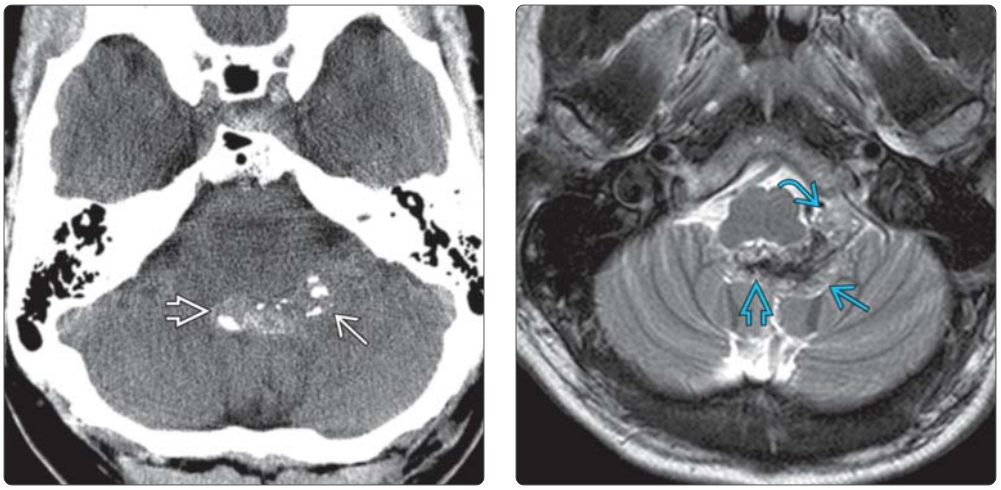

(Left) *Axial NECT scan shows a partially calcified hyperdense mass in the inferior 4th ventricle. Note extension toward the right cerebellopontine angle cistern.* **(Right)** *Axial T2 MR in the same case shows that the mass is well-demarcated and extends from the midline of the inferior 4th ventricle through the left lateral recess and projects into the cerebellopontine angle cistern.*

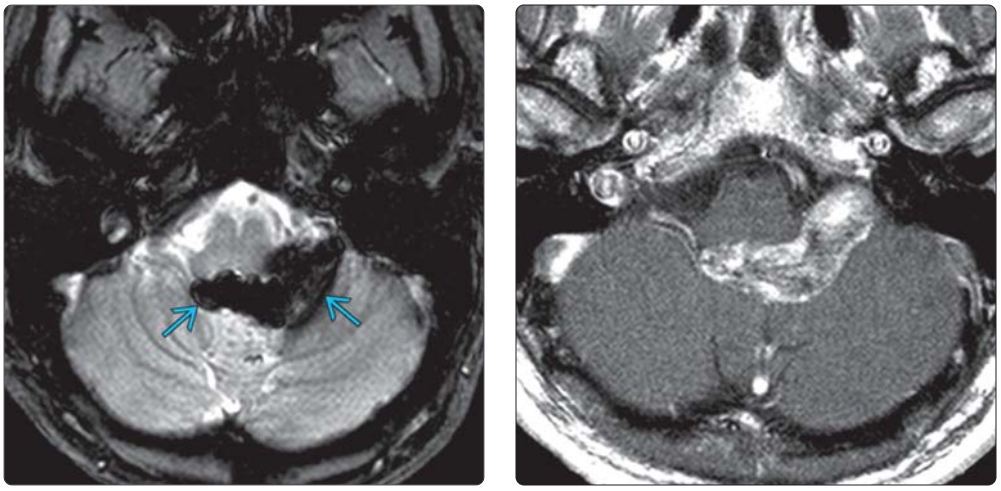

(Left) *T2* GRE MR scan in the same case shows extensive "blooming", probably from both tumoral calcification and hemorrhage.* **(Right)** *Axial T1 C+ MR in the same case shows that the mass enhances moderately but heterogeneously. The lobulated, "plastic" appearance of the tumor "squeezing" out through the foramen of Luschka is characteristic of ependymoma.*

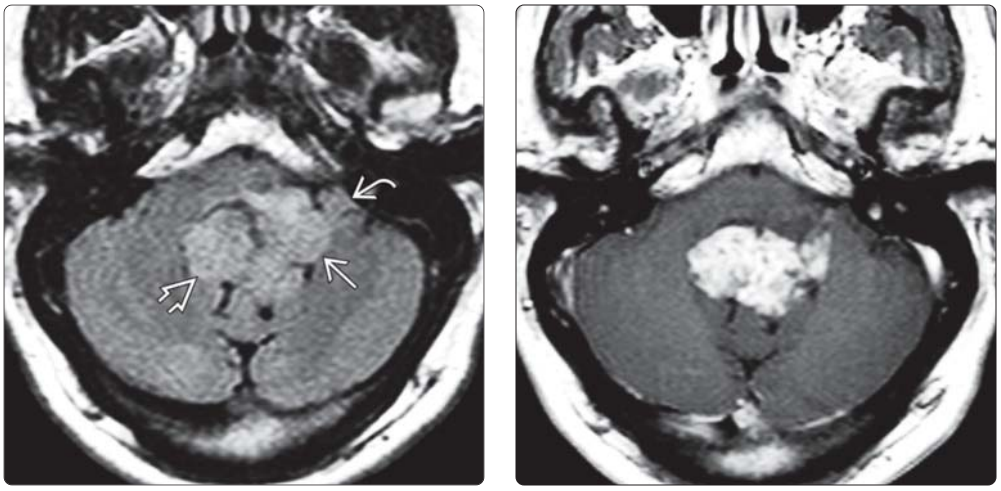

(Left) *Axial FLAIR MR in a 49-year-old man with suboccipital headaches shows a lobulated, slightly hyperintense mass in the 4th ventricle. Note anterolateral extension through the left foramen of Luschka into the left cerebellopontine angle cistern.* **(Right)** *Axial T1 C+ MR in the same case shows that the mass enhances strongly but somewhat heterogeneously. WHO grade II tanycytic ependymoma was found at surgery.*

https://CafePezeshki.IR

KEY FACTS

IMAGING

- General location of ependymomas
  - 2/3 infratentorial, 1/3 supratentorial
  - 45-65% of supratentorial ependymomas (STEs) are **extraventricular**
  - Common locations of STEs: Cerebral hemisphere > 3rd ventricle > lateral ventricle
- General features
  - Large, complex-appearing mixed solid/cystic hemispheric mass
  - Calcification, intratumoral hemorrhage common
  - Moderate but inhomogeneous enhancement

TOP DIFFERENTIAL DIAGNOSES

- Glioblastoma
- Ganglioglioma
- Astroblastoma
- Oligodendroglioma/anaplastic oligodendroglioma
- Pleomorphic xanthoastrocytoma
- Supratentorial PNET
- Atypical teratoid-rhabdoid tumor

PATHOLOGY

- Majority of adult STEs are WHO grade III tumors

CLINICAL ISSUES

- Older children, adults
  - Seizures
- Most important prognostic factor: Location
- Children < 3 years have poor outcome

DIAGNOSTIC CHECKLIST

- If large, mixed solid-cystic, calcified hemispheric/cortical mass in older children or adult, think STE

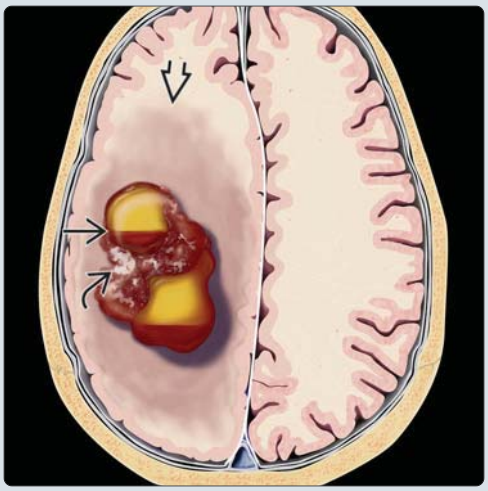

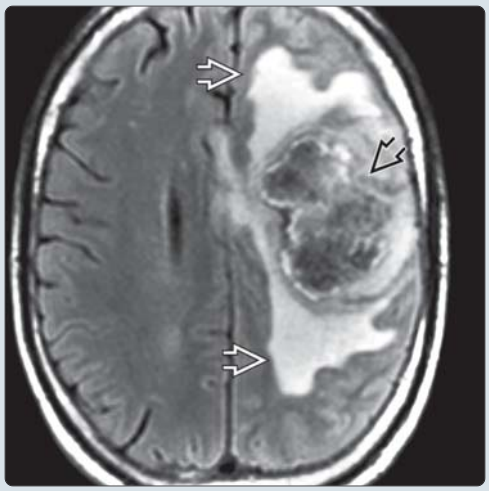

(Left) *Graphic depicts supratentorial ependymoma (STE) as a large, hemorrhagic hemispheric mass with multiple cysts, fluid-fluid levels ⇨, calcifications ⇨, significant mass effect, and peritumoral edema ⇨.* **(Right)** *Axial FLAIR MR in a 47-year-old man with anaplastic (grade III) hemispheric STE shows an inhomogeneous extraventricular mass in the left frontal lobe ⇨ with perifocal edema ⇨.*

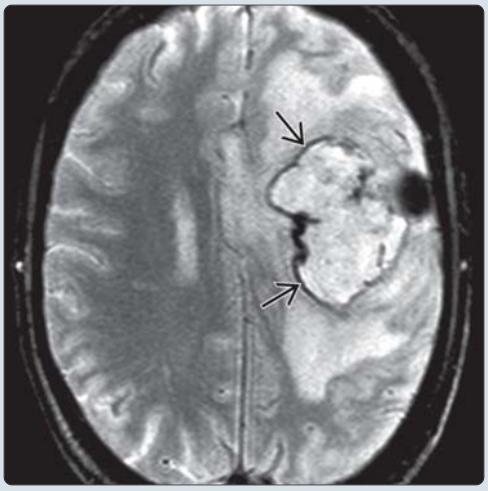

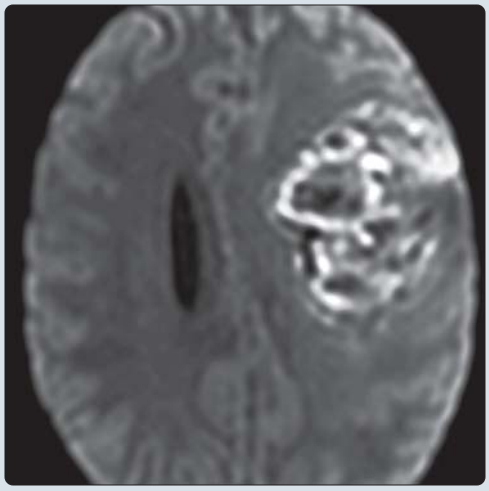

(Left) *Axial T2* GRE MR in the same patient demonstrates a rim of peripheral low signal intensity ⇨ indicating hemorrhage. STEs commonly demonstrate intratumoral hemorrhage.* **(Right)** *Axial DWI MR in the same patient reveals inhomogeneous high signal of the tumor, representing areas of elevated diffusion (dark) and areas of restricted diffusion due to hemorrhage (hyperintense).*

https://CafePezeshki.IR

TERMINOLOGY

Abbreviations

- Supratentorial ependymoma (STE)

Synonyms

- Hemispheric STE (a.k.a. brain surface ependymoma)
- Supratentorial ectopic cortical ependymoma
- Cortical ependymoma

Definitions

- Ependymoma in supratentorial location

IMAGING

General Features

- Best diagnostic clue
  - Large, complex-appearing mixed solid/cystic hemispheric mass
- Location
  - General location of ependymomas
    - 2/3 infratentorial (ITE)
    - 1/3 supratentorial (STE)
  - 45-65% of STEs are **extraventricular**
    - Hemispheric white matter or cortex
      - Frontal lobe most common location of cortical STEs
      - In cortex or infiltrating cortex from white matter
    - Rare: Suprasellar region
  - Less common location = intraventricular
    - 3rd ventricle > lateral ventricle
- Size
  - STEs often larger size at presentation than ITEs
    - 95% > 4 cm

CT Findings

- NECT
  - Mixed iso-/hypodense
    - Hyperdense = solid portion
    - Hypodense = cystic component
    - Calcifications (44%)
      - Can be small scattered foci or very extensive
  - May show bone destruction (tumor invades meninges, dura, and bone)

MR Findings

- T1WI
  - Iso-/hypointense
  - Cysts follow CSF
- T2WI
  - Variable morphological features
    - Cystic with mural nodule
    - Solid mass
    - Huge, partially necrotic mass
  - Variable signal
    - Hyper-/hypointense (high cellularity, calcifications)
    - Cysts hyperintense (CSF)
- T2* GRE
  - Low signal indicates hemorrhage or calcifications
- DWI
  - High signal with low ADC in hypercellular solid portions
- T1WI C+
  - Moderately intense enhancing tumor (solid parts) with necrotic foci
  - Rarely nonenhancing
  - Pattern
    - Cystic + mural nodule appearance (often in hemispheric location)
      - Mural nodule moderate or intensely enhancing
      - Nonenhancing or rim-enhancing cysts
  - Continuity with ventricle may be present
  - Continuity with surface present in cortical STE

Imaging Recommendations

- Best imaging tool
  - MR ± contrast
  - T2* (hemorrhage, calcification)

DIFFERENTIAL DIAGNOSIS

Glioblastoma

- If STE presents as huge partially necrotic mass
- Less common: Low-grade anaplastic astrocytoma

Astrocytoma (Other)

- Anaplastic astrocytoma, anaplastic pleomorphic xanthoastrocytoma can be very complex, heterogeneous-appearing

Oligodendroglioma, Anaplastic Oligodendroglioma

- Cerebral hemispheres
- Cortical and subcortical locations
- Calcifications
- Scalloping of inner table of skull

Astroblastoma

- Older children and young adults
- Solid cystic mass
- Supratentorial location
- Calcifications

Supratentorial PNET

- Children < 5 years of age
- Clearly separated from ventricle

Atypical Teratoid-Rhabdoid Tumor

- Very young children

Ganglioglioma

- Most common in temporal lobe
- Not as complex-appearing (usually cyst + nodule)

Angiocentric Glioma

- Children, young adults
- Nonenhancing cortical mass
- Rim-like hyperintensity on T1WI
- Epilepsy since childhood

Papillary Glioneuronal Tumor

- Cortical mass, often with connection to ventricle
- Calcifications
- May be cystic or have nodule-cystic appearance

https://CafePezeshki.IR

PATHOLOGY

General Features

- Etiology
  - General: Ependymoma is glial-based neoplasm arising from ependymal lining of ventricular system
  - Extraventricular STEs arise either from
    - Fetal rests of ependymal cells located at angle of ventricles
    - Random distribution of fetal ependymal rests located periventricularly
- Genetics
  - Gains of 1q (associated with aggressive clinical behavior), 12q, 7q, 8, 9
  - Perinuclear LRIG3 proteins more highly expressed in STE than ITE
  - Complete and partial losses of chromosomes 22, 22q, 10q, 3, 6q, 9q
    - 9q contains P16 *INK4A* gene often seen in STE
  - Upregulation of components of EphB-ephrin and Notch signaling pathways in STE
  - New entity: **Trisomy 19 ependymoma**
    - WHO grade III
    - Occurs in 9% of ependymomas

Staging, Grading, & Classification

- WHO grade I includes subependymoma and myxopapillary ependymoma
- WHO grade II ependymoma
  - 4 variants: Cellular, papillary, clear cell, and tanycytic
- WHO grade III anaplastic ependymoma
  - Majority of adult STEs are WHO grade III tumors
  - Defined by presence of any 2 of 4 + factors
    - 4 mitoses per 10 high-power fields (brisk mitotic activity)
    - Hypercellularity
    - Endothelial proliferation
    - Necrosis (pseudopalisading necrosis)

Gross Pathologic & Surgical Features

- Well-delineated tumors
- Lobulated mass, grayish-red surface, hemorrhagic and calcified parts

Microscopic Features

- Histological hallmarks
  - Perivascular rosettes
  - Ependymal rosettes
  - GFAP(+)
- Nonrosetting angiocentric growth pattern
- Variable amount of solid tumor growth
- Low proliferative index
- Infiltrating brain parenchyma
  - Infiltration along axonal tracts, perineuronal satellitosis, subpial mounding

CLINICAL ISSUES

Presentation

- Most common signs/symptoms
  - Seizures most common symptom
  - Focal motor or sensory deficit, headache

Demographics

- Age
  - Bimodal
    - Most in children 1-5 years, smaller peak 20-30 years
- Gender
  - M > F
- Epidemiology
  - Ependymomas = 1.2-7.8% of all intracranial tumors
  - 3rd most common intracranial neoplasm in children

Natural History & Prognosis

- 5-year survival for supratentorial ependymomas (72%), significantly better than for infratentorial
- Higher recurrence rate for 3rd ventricular tumors (compared to hemispheric tumors)
- Most important prognostic factor: Location
- Children < 3 years have poor outcome

Treatment

- Gross total resection with adjuvant radiotherapy

DIAGNOSTIC CHECKLIST

Consider

- Large, solid-cystic, calcified mass in ventricular or cortical location in older children or adults

SELECTED REFERENCES

1. de Andrade FG et al: Immunohistochemical expression of cyclin D1 is higher in supratentorial ependymomas and predicts relapses in gross total resection cases. Neuropathology. ePub, 2015
2. Mohaghegh MR et al: Supratentorial cortical ependymoma: An unusual presentation of a rare tumor. Adv Biomed Res. 4:72, 2015
3. Khilji MF et al: Supratentorial extraventricular anaplastic ependymoma in a child. BMJ Case Rep. 2014, 2014
4. Purdy E et al: Ependymoma in children under the age of 3 years: a report from the Canadian Pediatric Brain Tumour Consortium. J Neurooncol. 117(2):359-64, 2014
5. Alexiou GA et al: Supratentorial ependymomas in children: Analysis of nine cases. J Pediatr Neurosci. 8(1):15-8, 2013
6. Cage TA et al: A systematic review of treatment outcomes in pediatric patients with intracranial ependymomas. J Neurosurg Pediatr. 11(6):673-81, 2013
7. Li JY et al: Giant cell ependymoma-report of three cases and review of the literature. Int J Clin Exp Pathol. 5(5):458-62, 2012
8. Reis F et al: Supratentorial tanycytic ependymoma: an uncommon fibrillary ependymoma variant. Arq Neuropsiquiatr. 69(4):723, 2011
9. Niazi TN et al: WHO Grade II and III supratentorial hemispheric ependymomas in adults: case series and review of treatment options. J Neurooncol. 91(3):323-8, 2009
10. Yi W et al: Expression of leucine-rich repeats and immunoglobulin-like domains (LRIG) proteins in human ependymoma relates to tumor location, WHO grade, and patient age. Clin Neuropathol. 28(1):21-7, 2009
11. Lehman NL: Central nervous system tumors with ependymal features: a broadened spectrum of primarily ependymal differentiation? J Neuropathol Exp Neurol. 67(3):177-88, 2008
12. Lehman NL: Patterns of brain infiltration and secondary structure formation in supratentorial ependymal tumors. J Neuropathol Exp Neurol. 67(9):900-10, 2008
13. Miyazawa T et al: Supratentorial ectopic cortical ependymoma occurring with intratumoral hemorrhage. Brain Tumor Pathol. 24(1):35-40, 2007
14. Rousseau E et al: Trisomy 19 ependymoma, a newly recognized genetico-histological association, including clear cell ependymoma. Mol Cancer. 6:47, 2007
15. Vinchon M et al: Supratentorial ependymoma in children. Pediatr Neurosurg. 34(2):77-87, 2001

https://CafePezeshki.IR

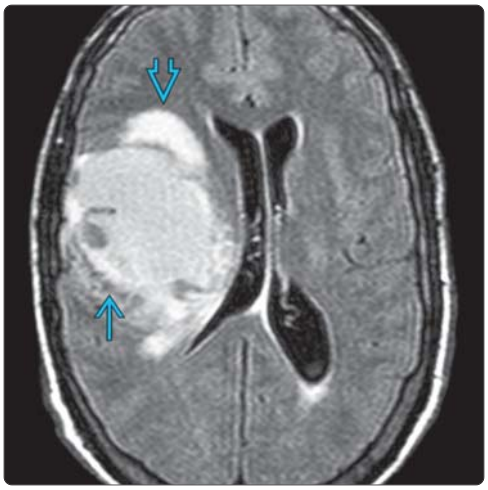

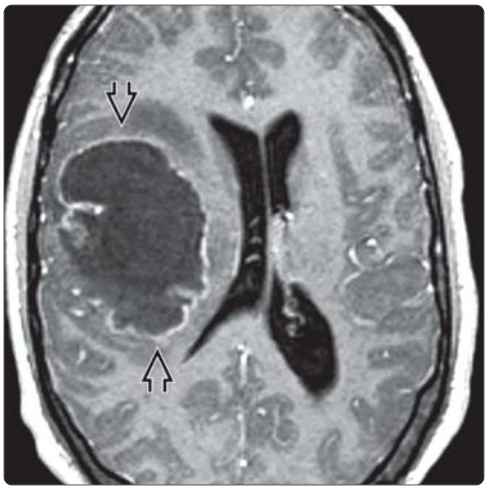

(Left) *Axial FLAIR MR shows a large, cystic mass in the right hemisphere with perifocal edema and compression of the right ventricle with minimal midline shift.* **(Right)** *Axial T1WI C+ MR in the same patient shows peripheral enhancement around a nonenhancing cystic component. STE was found at surgery. This STE does not show any contiguity with the ventricular system.*

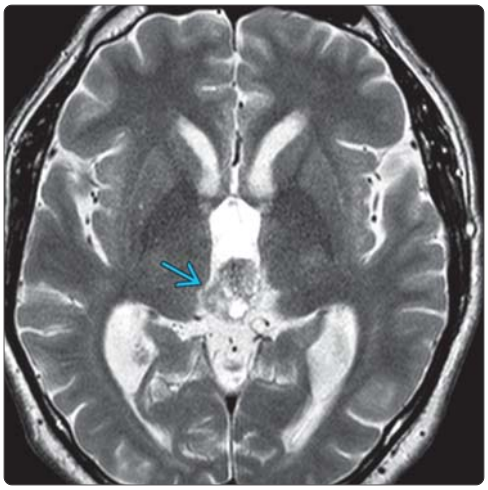

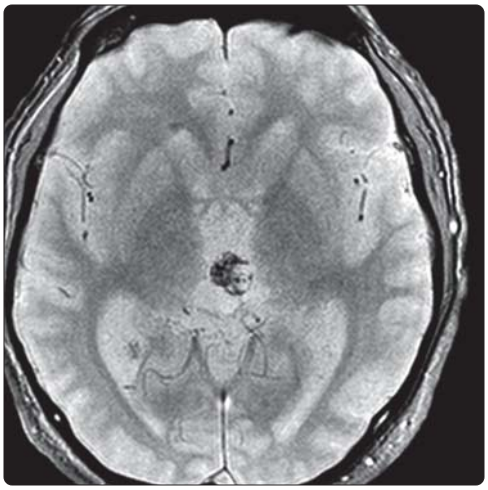

(Left) *Axial T2WI MR in a patient with STE shows an inhomogeneous mass in the 3rd ventricle. Note the relatively low signal, small intratumoral cysts.* **(Right)** *Axial T2* GRE MR in the same case shows blooming, hypointense foci indicating calcification or hemorrhage.*

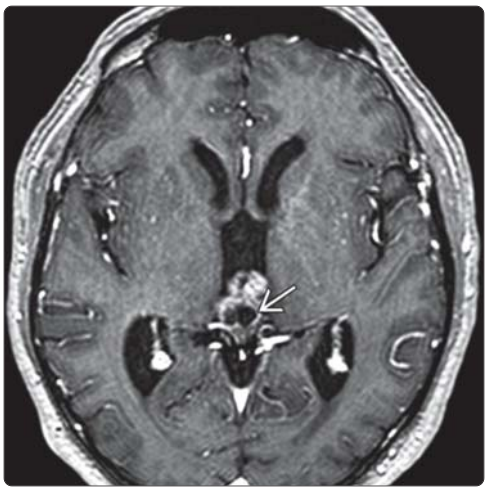

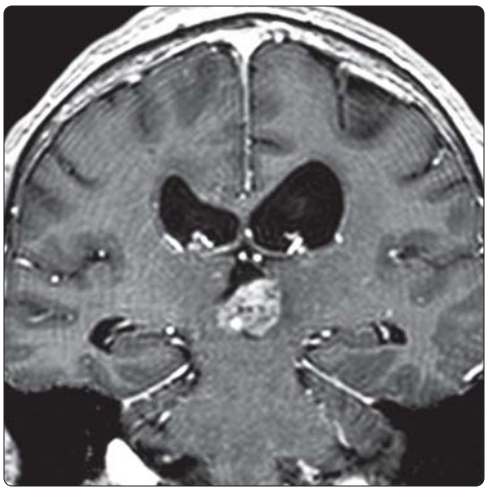

(Left) *Axial T1WI C+ MR in the same patient demonstrates marked but inhomogeneous enhancement. Note the solid portions, intratumoral cysts of various sizes, and a larger cyst with rim enhancement.* **(Right)** *Coronal T1WI C+ MR in the same patient demonstrates an inhomogeneously enhancing nodular mass within the 3rd ventricle.*

https://CafePezeshki.IR

KEY FACTS

TERMINOLOGY

- Rare, benign, well-differentiated, intraventricular ependymal tumor, typically attached to ventricular wall

IMAGING

- Intraventricular, inferior 4th ventricle typical (60%)
- Other locations: Lateral > 3rd ventricle > spinal cord
- T2/FLAIR hyperintense intraventricular mass
  - Heterogeneity related to cystic changes; blood products or Ca++ may be seen in larger lesions
- Variable enhancement, typically none to mild
- T2WI and FLAIR are often most sensitive sequences

TOP DIFFERENTIAL DIAGNOSES

- Ependymoma
- Central neurocytoma
- Subependymal giant cell astrocytoma
- Choroid plexus papilloma (CPP)
- Hemangioblastoma
- Metastases

PATHOLOGY

- WHO grade I

CLINICAL ISSUES

- 40% become symptomatic, often supratentorial
  - Related to increased intracranial pressure, hydrocephalus
- Present in middle-aged/elderly adults (typically 5th-6th decades)
- Treatment: Conservative management with serial imaging if asymptomatic patient
- Surgical resection is curative in most cases
- Excellent prognosis for supratentorial lesions
  - Recurrence is extremely rare

DIAGNOSTIC CHECKLIST

- If 4th or lateral ventricular hyperintense mass in elderly man, think subependymoma

(Left) *Sagittal graphic shows a solid, well-circumscribed mass arising from the floor of the 4th ventricle with mild mass effect. Note the lack of hydrocephalus, typical of subependymoma.* **(Right)** *Sagittal FLAIR MR shows a solid, hyperintense mass along the inferior 4th ventricle in a 64-year-old man with headaches. Subependymoma was found at resection. These 4th ventricular tumors are often asymptomatic. T2 and FLAIR are typically the most sensitive sequences to identify this WHO grade I tumor.*

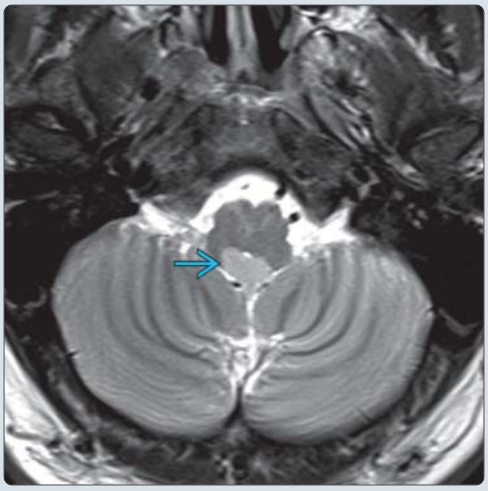

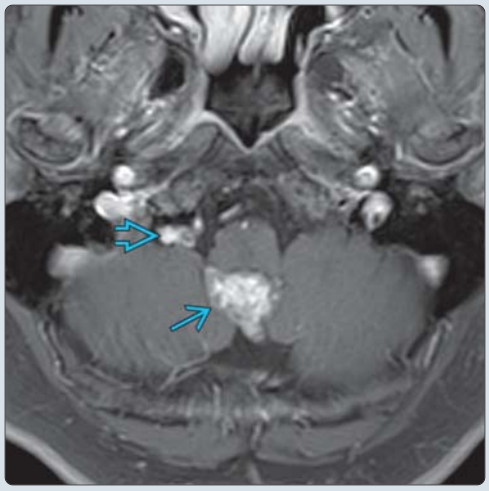

(Left) *Axial T2WI MR shows a hyperintense mass along the inferior 4th ventricle at the level of the medulla (classic imaging of a subependymoma).* **(Right)** *Axial T1 C+ MR shows an enhancing mass in the 4th ventricular outflow tract. The moderate enhancement is uncommon. Subependymomas classically have no or minimal enhancement. They can protrude through the foramen of Magendie. In this case, tumor is also present anterior to the cerebellar hemisphere through the foramen of Luschka.*

https://CafePezeshki.IR

TERMINOLOGY

Synonyms

- Older literature: Subependymal glomerulate astrocytoma, subependymal astrocytoma, subependymal mixed glioma

Definitions

- Rare, benign, well-differentiated, intraventricular ependymal tumor, often attached to ventricular wall

IMAGING

General Features

- Best diagnostic clue
  - T2-hyperintense, lobular, nonenhancing, intraventricular mass
- Location
  - Typical: Intraventricular, inferior 4th ventricle (60%)
    - Often protrudes through foramen of Magendie
  - Other locations: Lateral > 3rd ventricle > spinal cord (cervical or cervicothoracic)
    - Lateral ventricle: Attached to septum pellucidum or lateral wall
  - Rare: Periventricular
- Size
  - Typically small, 1-2 cm
  - May become large, > 5 cm
    - More commonly symptomatic when large
- Morphology
  - Well-defined, solid, lobular mass
  - When large, may see cysts, hemorrhage, Ca++

CT Findings

- NECT
  - Iso- to hypodense intraventricular mass
  - Cysts or Ca++ may be seen in larger lesions
  - Rarely hemorrhage
- CECT
  - No or mild enhancement typical
  - Heterogeneous enhancement may be seen

MR Findings

- T1WI
  - Intraventricular mass, hypo- or isointense to white matter
  - Typically homogeneous solid mass
  - Heterogeneity may be seen in larger lesions
- T2WI
  - Hyperintense intraventricular mass
  - Heterogeneity related to cystic changes; blood products or Ca++ may be seen in larger lesions
  - No edema seen in adjacent brain parenchyma
- FLAIR
  - Hyperintense intraventricular mass
  - No edema seen in adjacent brain parenchyma
- T2* GRE
  - May see Ca++ "bloom" in larger lesions and 4th ventricle location
- T1WI C+
  - Variable enhancement, typically none to mild
  - Marked enhancement may be seen: More common in 4th than lateral ventricular subependymomas

Nuclear Medicine Findings

- PET
  - Rare reports show exceedingly low rates of glucose metabolism and kinetic constants
    - Hypometabolism indicates low cellular density and slow growth

Imaging Recommendations

- Best imaging tool
  - MR is most sensitive
  - CT may be useful for calcification
- Protocol advice
  - Multiplanar contrast-enhanced MR including T2WI, FLAIR

DIFFERENTIAL DIAGNOSIS

Ependymoma

- Younger patients
- Heterogeneous, enhancing mass with edema
- Typically 4th ventricular mass with hydrocephalus
- Often parenchymal when supratentorial

Central Neurocytoma

- Typical bubbly appearance, Ca++ common
- Lateral ventricle, attached to septum pellucidum
- Moderate to strong enhancement

Subependymal Giant Cell Astrocytoma

- Enhancing mass at foramen of Monro
- Ca++ common
- Tuberous sclerosis patients: Subependymal nodules, cortical tubers, white matter lesions

Choroid Plexus Papilloma (CPP)

- Typically pediatric tumors, lateral ventricle
- In adults, 4th ventricle
- Enhancing papillary mass, hydrocephalus common

Hemangioblastoma

- Cystic mass with enhancing mural nodule
- Typically cerebellar hemispheres, often at pial surface
- Rarely intraventricular

Metastases

- Primary tumor often known
- Often multiple lesions at gray-white junctions
- Typically involve choroid plexus if intraventricular

Cavernous Malformation

- Rarely intraventricular, 2.5-11% of cases
- Ca++ and T2 hypointense hemosiderin rim common
- Enhancement variable

PATHOLOGY

General Features

- Etiology
  - Proposed cells of origin: Subependymal glia, astrocytes of subependymal plate, ependymal cells
    - Development from subependymal glial precursors appears likely

https://CafePezeshki.IR

- Genetics
  - Most are sporadic
  - Rare familial cases have been reported
- Associated abnormalities
  - Contains both astrocytes and ependymal elements
  - Occasionally coexists with cellular ependymomas
  - Rare: Multiple lesions

Staging, Grading, & Classification

- WHO grade I

Gross Pathologic & Surgical Features

- Solid, well-delineated, white to grayish, avascular mass
- Firmly attached to site of origin
  - 4th ventricle: Floor typical
  - Lateral ventricle: Septum pellucidum or lateral wall
- Larger lesions are lobulated, more often Ca++; hemorrhage, cyst formation common
- 4th ventricular lesions often protrude out of foramen of Magendie

Microscopic Features

- Highly fibrillar, low cellularity with nuclei clustering
- Microcystic change common in tumors near foramen of Monro
- Ca++ is commonly seen in 4th ventricle tumors
- Mitoses are rare or absent, MIB < 1%
- Hemorrhage is rare
- Immunohistochemistry: Strongly GFAP(+)
- Electron microscopy: Closely packed cell processes filled with glial intermediate filaments

CLINICAL ISSUES

Presentation

- Most common signs/symptoms
  - Most asymptomatic
  - 40% become symptomatic, often supratentorial
    - Related to increased intracranial pressure, hydrocephalus
      - Headache, gait ataxia, visual disturbance, cranial neuropathy, nystagmus, vertigo, nausea, vomiting

Demographics

- Age
  - Middle-aged/elderly adult (typically 5th-6th decades)
    - Asymptomatic patients: Mean age = 60 years
    - Symptomatic patients: Mean age = 40 years
  - Rare in children
- Gender
  - Male predominance
- Epidemiology
  - Reported in 0.5-1% of autopsies
  - Account for 0.7% of intracranial neoplasms
  - Represent ~ 8% of ependymal tumors

Natural History & Prognosis

- Excellent prognosis for supratentorial lesions
- Recurrence is extremely rare
- Complications include hydrocephalus and rarely hemorrhage
- Rare, benign, slow-growing tumors often found incidentally at imaging or autopsy

Treatment

- Surgical resection is curative in most cases
  - Lateral ventricle lesions: Complete resection
  - 4th ventricle lesions: Subtotal resection more common
- Perioperative mortality low but increased by attachment of tumor to adjacent structures
- If hydrocephalus, CSF diversion may be required
- Adjuvant radiation therapy is controversial
- Conservative management with serial imaging if asymptomatic

DIAGNOSTIC CHECKLIST

Consider

- Other intraventricular tumors tend to enhance more prominently
- May be indistinguishable from ependymoma or central neurocytoma
- Differential diagnosis varies with age
  - Adults: Central neurocytoma, choroid plexus papilloma, metastases, hemangioblastoma
  - Children: Ependymoma, choroid plexus papilloma, subependymal giant cell astrocytoma

Image Interpretation Pearls

- If 4th or lateral ventricular hyperintense mass in an elderly man, think subependymoma
- T2WI and FLAIR are often most sensitive

SELECTED REFERENCES

1. Bi Z et al: Clinical, radiological, and pathological features in 43 cases of intracranial subependymoma. J Neurosurg. 122(1):49-60, 2015
2. Arvanitis LD et al: A 40-year-old male with an intraventricular tumor. Combined tanycytic ependymoma and subependymoma. Brain Pathol. 23(3):359-60, 2013
3. Hou Z et al: Clinical features and management of intracranial subependymomas in children. J Clin Neurosci. 20(1):84-8, 2013
4. Iwasaki M et al: Thoracolumbar intramedullary subependymoma with multiple cystic formation: a case report and review. Eur Spine J. 22 Suppl 3:S317-20, 2013
5. Smith AB et al: From the radiologic pathology archives: intraventricular neoplasms: radiologic-pathologic correlation. Radiographics. 33(1):21-43, 2013
6. Cunha AM et al: Cerebellopontine angle subependymoma without fourth ventricle extension: an uncommon tumor in a rare location. Neuropathology. 32(2):164-70, 2012
7. Jain A et al: Subependymoma: clinical features and surgical outcomes. Neurol Res. 34(7):677-84, 2012
8. Koral K et al: Subependymoma of the cerebellopontine angle and prepontine cistern in a 15-year-old adolescent boy. AJNR Am J Neuroradiol. 29(1):190-1, 2008
9. Louis DN et al: WHO Classification of Tumours of the Central Nervous System: Subependymoma. Lyon: IARC Press. 70-71, 2007
10. Rushing EJ et al: Subependymoma revisited: clinicopathological evaluation of 83 cases. J Neurooncol. 85(3):297-305, 2007
11. Ragel BT et al: Subependymomas: an analysis of clinical and imaging features. Neurosurgery. 58(5):881-90; discussion 881-90, 2006
12. Rath TJ et al: Massive symptomatic subependymoma of the lateral ventricles: case report and review of the literature. Neuroradiology. 47(3):183-8, 2005
13. Im SH et al: Clinicopathological study of seven cases of symptomatic supratentorial subependymoma. J Neurooncol. 61(1):57-67, 2003
14. Burger PC et al: Surgical pathology of the nervous system and its coverings: The Brain: Tumors. 4th ed. Philadelphia: Churchill Livingstone. 250-4, 2002

https://CafePezeshki.IR

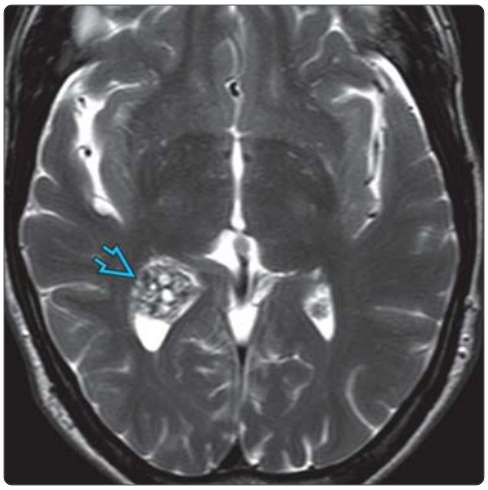

(Left) *Axial T2 MR shows a heterogeneous right lateral ventricle mass in a 58-year-old man. Subependymoma was found at resection. Imaging mimics a cavernous malformation.* **(Right)** *Sagittal T1WI C+ MR shows a mildly enhancing mass. Subependymomas are most commonly found in the inferior 4th ventricle (50-60%). The lateral ventricle is the next most common location (30-40%). These tumors are primarily treated conservatively or with surgical resection, which is typically curative.*

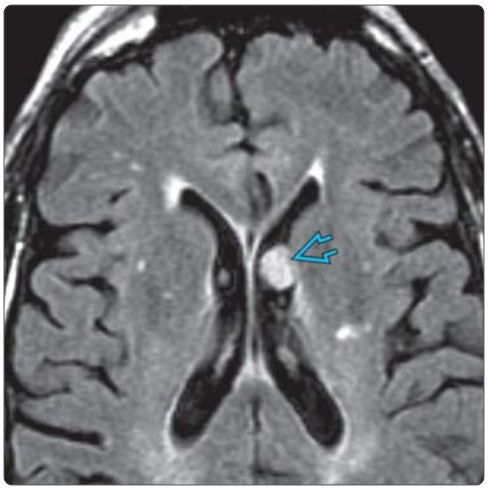

(Left) *Coronal graphic shows a solid, well-circumscribed, intraventricular mass attached to the septum pellucidum with neither mass effect nor hydrocephalus. Subependymomas are typically asymptomatic, but they may cause hydrocephalus and increased intracranial pressure.* **(Right)** *Axial FLAIR MR shows a hyperintense lateral ventricle mass at the level of the septum pellucidum. When in the lateral ventricle, subependymomas are typically attached to the septum pellucidum or lateral wall.*

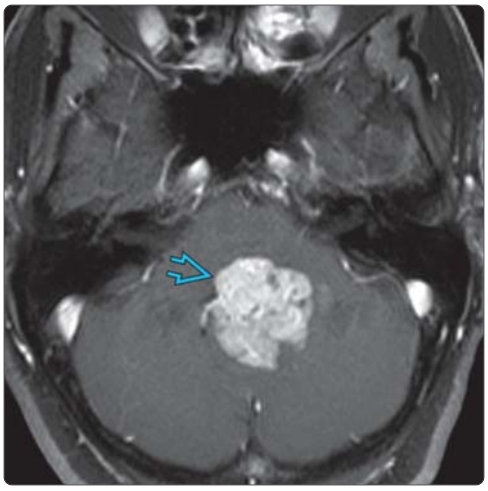

(Left) *Axial T1 C+ MR shows a markedly enhancing 4th ventricular mass. Differential considerations include ependymoma and choroid plexus papilloma. Subependymoma was diagnosed at resection.* **(Right)** *Sagittal T2WI MR shows a heterogeneous mass filling the 4th ventricle with inferior extension. Enhancement was present on contrast images of this WHO grade I subependymoma. Cysts, blood, and calcification may be seen in larger lesions. Imaging mimics ependymoma and hemangioblastoma.*

https://CafePezeshki.IR

Typical Choroid Plexus Papilloma

KEY FACTS

TERMINOLOGY

- Choroid plexus tumor (CPT)
  - 3 types of CPTs
    - Choroid plexus papilloma (CPP)(WHO grade I)
    - Atypical choroid plexus papilloma (aCPP)(grade II)
    - Choroid plexus carcinoma (CPCa)(grade III)

IMAGING

- Classic: Child with enhancing lobulated (cauliflower-like) mass in atrium of lateral ventricle
- CPPs occur in proportion to amount of choroid plexus
  - 50% in lateral ventricle (usually atrium)
  - 40% in 4th ventricle &/or foramina of Luschka
  - 5% in 3rd ventricle (roof)
- Hydrocephalus (overproduction, obstructive)

TOP DIFFERENTIAL DIAGNOSES

- Atypical choroid plexus papilloma
- Choroid plexus carcinoma
- Physiologic choroid plexus enlargement
- Choroid plexus xanthogranuloma
- Meningioma
- Intraventricular metastasis
- Medulloblastoma
- Ependymoma

CLINICAL ISSUES

- Most common brain tumor in children < 1 year old
  - 13.1% of all brain tumors in 1st year of life
  - 7.9% of fetal brain tumors diagnosed by ultrasound
- Benign, slowly growing
  - ± CSF spread (does not distinguish CPP from CPCa)
  - Malignant progression rare

DIAGNOSTIC CHECKLIST

- Consider CPP if intraventricular mass in child < 2 years old
- Imaging cannot reliably distinguish CPP from aCPP, CPCa

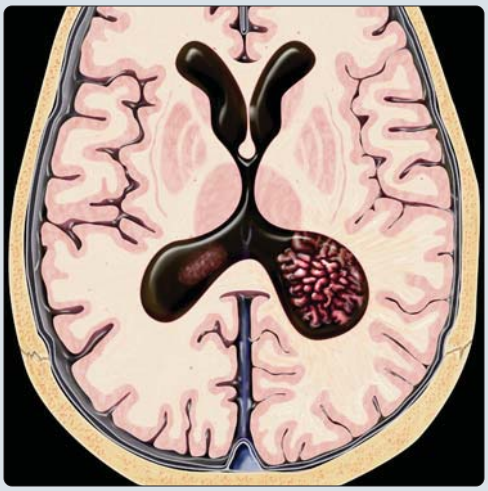

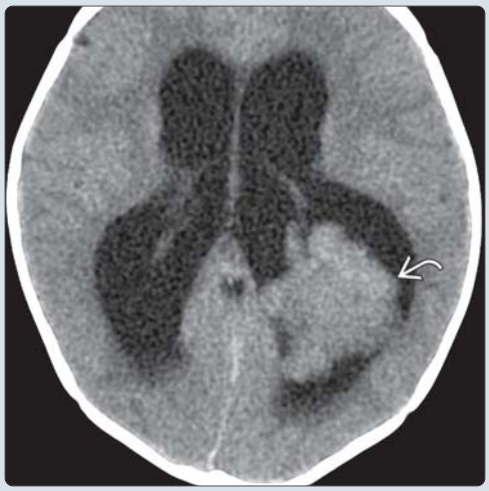

(Left) *Axial graphic shows a choroid plexus papilloma (CPP) arising from the glomus of the left lateral ventricular trigone. Note the characteristic frond-like surface projections. CPPs are most common in the lateral ventricles of a child.* **(Right)** *Axial NECT in a child with macrocephaly shows hydrocephalus with a lobulated mass ⇄ in the atrium of the left lateral ventricle.*

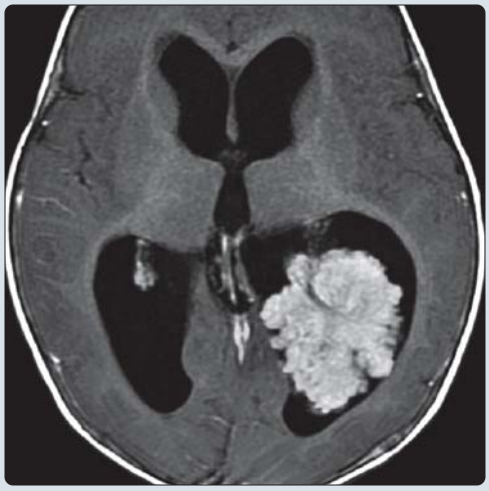

(Left) *Axial T2WI MR in the same patient shows a heterogeneously hyperintense lateral ventricle mass with scattered hypointense flow voids ⇨ indicating high vascularity. The lobulated nature of the mass is striking.* **(Right)** *Axial T1WI C+ MR shows marked enhancement of the lobular mass with frond-like projections, characteristic of CPP. CPP cannot be reliably differentiated from atypical choroid plexus papilloma (aCPP) by conventional imaging alone.*

https://CafePezeshki.IR

TERMINOLOGY

Abbreviations

- Choroid plexus tumor (CPT)
  - 3 recognized subtypes of CPTs
    - Choroid plexus papilloma (CPP)
    - Atypical choroid plexus papilloma (aCPP)
    - Choroid plexus carcinoma (CPCa)

Definitions

- Benign (WHO grade I) papillary neoplasm derived from choroid plexus epithelium

IMAGING

General Features

- Best diagnostic clue
  - Child with strongly enhancing lobulated (cauliflower-like) intraventricular mass
- Location
  - CPPs occur in proportion to amount of normally present choroid plexus
    - 50% → atrium of lateral ventricle, left > right
    - 40% → 4th ventricle (posterior medullary velum) and foramina of Luschka
    - 5% → 3rd ventricle (roof)
    - 5% → multiple sites (synchronous lesions at diagnosis)
    - Rare: Cerebellopontine angle, suprasellar, intraparenchymal
- Size
  - Varies from tiny to huge
- Morphology
  - Cauliflower-like mass

CT Findings

- NECT
  - Intraventricular lobular mass
  - 75% iso- or hyperattenuating
  - Ca++ in 25%
  - Hydrocephalus
    - Overproduction of CSF → obstruction
    - Can be as much as 800-1,500 mL/day
- CECT
  - Intense, homogeneous enhancement
    - Heterogeneous enhancement suggests choroid plexus carcinoma
  - No or minimal parenchymal invasion

MR Findings

- T1WI
  - Well-delineated iso- to hypointense lobular mass
- T2WI
  - Iso- to hyperintense mass
  - ± internal linear and branching vascular flow voids
  - Large CPP may bury itself within brain parenchyma
    - Extensive invasion suggests CPCa
  - Hydrocephalus common
- FLAIR
  - Bright periventricular signal
    - Periventricular interstitial edema due to ventricular obstruction common
    - Asymmetric ipsilateral T2 hyperintensity may suggest invasion and CPCa
- T2* GRE
  - ± foci of diminished signal if Ca++ &/or blood products are present
- T1WI C+
  - Robust homogeneous enhancement
  - Occasional cysts and small foci of necrosis
  - Look for CSF dissemination
- MRA
  - Flow-related signal within mass
  - Enlarged choroidal artery (trigonal mass)
- MRS
  - NAA absent, mild ↑ choline, lactate if necrotic
  - Myoinositol (mI) elevation in CPP may help to distinguish from CPCa

Ultrasonographic Findings

- Grayscale ultrasound
  - Hyperechoic mass with frond-like projections
  - Mass echogenicity similar to normal choroid plexus
  - Hydrocephalus

Angiographic Findings

- Conventional
  - Enlarged choroidal arteries
  - Prolonged vascular stain
  - Arteriovenous shunting

Imaging Recommendations

- Best imaging tool
  - MR with contrast
- Protocol advice
  - Perform contrast-enhanced MR of entire neuraxis before surgery

DIFFERENTIAL DIAGNOSIS

Atypical Choroid Plexus Papilloma

- Neuropathologic diagnosis
  - WHO grade II based on ↑ proliferation, cellular atypia
    - > 2 mitoses/10 high-power fields
  - Indistinguishable from CPP on imaging alone
    - CPP:aCPCa = 10:1
  - Cytogenetic profiles similar to CPP

Choroid Plexus Carcinoma

- Difficult to distinguish from CPP by imaging
- CPP:CPCa = 2:1
- More heterogeneous, more likely to invade brain

Physiologic Choroid Plexus Enlargement

- Collateral venous drainage (Sturge-Weber)
- Enlargement of choroid following hemispherectomy

Villous Hypertrophy (VH)

- Rare (many presumed VH cases may be bilateral CPPs)
- Proliferation index (MIB-1) is useful to distinguish

Meningioma

- Older adults
- Enhancing, circumscribed, intraventricular mass
- Consider neurofibromatosis type 2

https://CafePezeshki.IR

Intraventricular Metastasis
- Rare in children
- Known history of primary tumor

Medulloblastoma
- Hyperdense 4th ventricular mass in child
- More spherical than CPP

Ependymoma
- More common in 4th ventricle in children
- Heterogeneous enhancing mass

Subependymoma
- Nonenhancing intraventricular mass

Choroid Plexus Xanthogranuloma
- Multiloculated cysts in enhancing choroid plexus of atrium
- Middle-aged, older adults
- Benign, incidental finding
- Usually bilateral

PATHOLOGY

General Features
- Genetics
  - Genetic changes common (> 90% of CPPs)
    - Hyperdiploidy, focal chromosomal gains common
    - High expression of *TWIST1* (transcription factor that inhibits p53)
    - Association with Aicardi, Li-Fraumeni syndromes
- Associated abnormalities
  - Diffuse hydrocephalus from
    - CSF overproduction
    - Mechanical obstruction
    - Impaired CSF resorption (due to hemorrhage)

Staging, Grading, & Classification
- WHO grade I

Gross Pathologic & Surgical Features
- Well-circumscribed, lobulated, intraventricular mass
  - ± cysts, necrosis, and hemorrhage

Microscopic Features
- Fibrovascular connective tissue fronds
  - Covered by cuboidal or columnar epithelium
- Mitotic activity, necrosis, and brain invasion typically absent
- Resembles nonneoplastic choroid plexus (CP)
- Immunohistochemistry
  - Transthyretin may help distinguish from normal CP
  - GFAP reactivity can distinguish from normal CP
  - Kir7.1 and stanniocalcin-1 reactivity differentiates normal CP and CPT from other cell origins

CLINICAL ISSUES

Presentation
- Most common signs/symptoms
  - Macrocrania, bulging fontanelle, vomiting, headache, ataxia, seizure
- Clinical profile
  - Child < 2 years with signs and symptoms of elevated intracranial pressure

Demographics
- Age
  - Lateral ventricular CPPs: 80% < 20 years
  - 4th ventricular CPPs: More common in adults
- Gender
  - Lateral ventricle: M:F = 1:1
  - 4th ventricle: M:F = 3:2
- Epidemiology
  - < 1% of all adult brain tumors
  - 2-4% of all pediatric brain tumors
  - 1 of most common brain tumors in children < 1 year
    - 50% manifest in 1st decade
    - 86% present by 5 years
    - 13.1% of all brain tumors in 1st year of life
    - 7.9% of fetal brain tumors diagnosed by ultrasound

Natural History & Prognosis
- Benign, slowly growing
  - Malignant progression rare
- 5-year survival ~ 100%

Treatment
- Total surgical resection (recurrence rare)

DIAGNOSTIC CHECKLIST

Consider
- CPP if intraventricular mass in child under 2 years

Image Interpretation Pearls
- Imaging alone cannot reliably distinguish CPP from aCPP or CPCa
  - Final diagnosis is histologic
- Lobulated intraventricular mass with intense enhancement in young child most likely represents CPT

SELECTED REFERENCES

1. Cannon DM et al: Choroid plexus tumor epidemiology and outcomes: implications for surgical and radiotherapeutic management. J Neurooncol. 121(1):151-7, 2015
2. Japp AS et al: High-resolution genomic analysis does not qualify atypical plexus papilloma as a separate entity among choroid plexus tumors. J Neuropathol Exp Neurol. 74(2):110-20, 2015
3. Thomas C et al: Pediatric atypical choroid plexus papilloma reconsidered: increased mitotic activity is prognostic only in older children. Acta Neuropathol. ePub, 2015
4. Anderson M et al: Unique presentation of cerebellopontine angle choroid plexus papillomas: case report and review of the literature. J Neurol Surg Rep. 75(1):e27-32, 2014
5. Turkoglu E et al: Clinical outcome of adult choroid plexus tumors: retrospective analysis of a single institute. Acta Neurochir (Wien). 156(8):1461-8; discussion 1467-8, 2014
6. Gupta P et al: Choroid plexus papilloma of the third ventricle: A rare infantile brain tumor. J Pediatr Neurosci. 8(3):247-9, 2013
7. Safaee M et al: Surgical outcomes in choroid plexus papillomas: an institutional experience. J Neurooncol. 113(1):117-25, 2013
8. Lysyy O et al: Choroid plexus papilloma in an infant: ultrasound diagnosis. Eur J Pediatr. 171(11):1717-8, 2012
9. Ogiwara H et al: Choroid plexus tumors in pediatric patients. Br J Neurosurg. 26(1):32-7, 2012
10. Hasselblatt M et al: TWIST-1 is overexpressed in neoplastic choroid plexus epithelial cells and promotes proliferation and invasion. Cancer Res. 69(6):2219-23, 2009
11. Naeini RM et al: Spectrum of choroid plexus lesions in children. AJR Am J Roentgenol. 192(1):32-40, 2009

https://CafePezeshki.IR

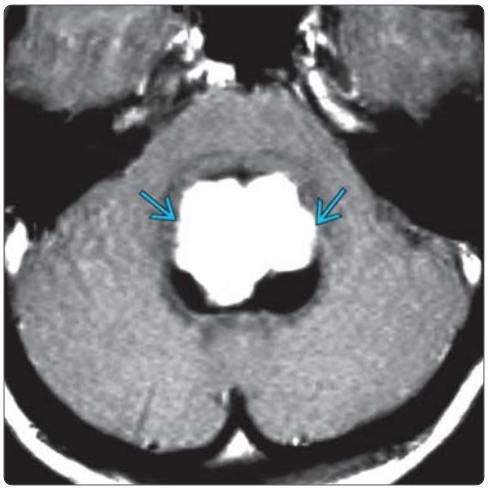

(Left) *Sagittal T1 C+ MR in an adult with headaches demonstrates the 4th ventricular presentation of CPP. Note the lobulated, cauliflower-like morphology of the mass ⇨. Choroid plexus tumors in adults are more likely to involve the choroid plexus within the 4th ventricle. These tumors may be centered in the 4th ventricle or at the lateral recess.* **(Right)** *Axial T1 C+ MR in the same patient shows the robust enhancement of the mass ⇨.*

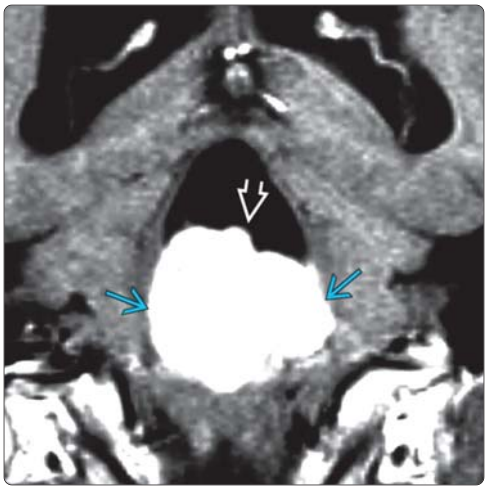

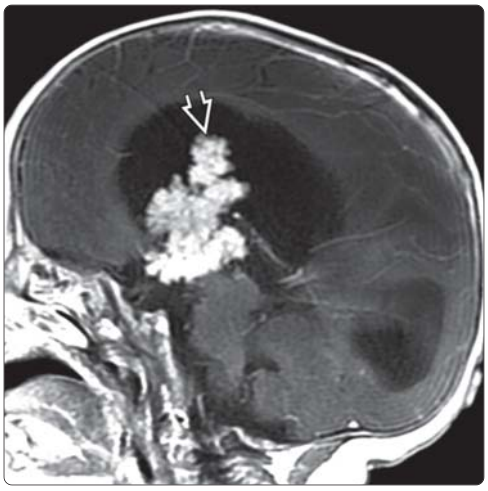

(Left) *Coronal T1 C+ MR in the same patient shows the lobulated, well-demarcated character of the mass ⇨ and the intense, uniform enhancement ⇨.* **(Right)** *Sagittal T1WI C+ MR in a child with a large head and papilledema shows a lobular, markedly enhancing 3rd ventricle mass with distinct frond-like projections ⇨. The 3rd ventricle is an uncommon location for choroid plexus tumors. Note the cephalad extension through the foramen of Monro and the associated hydrocephalus.*

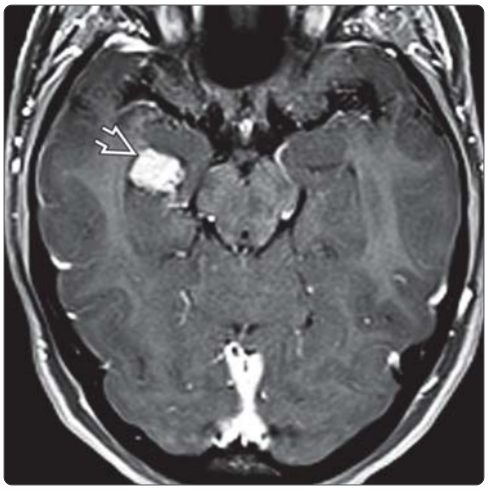

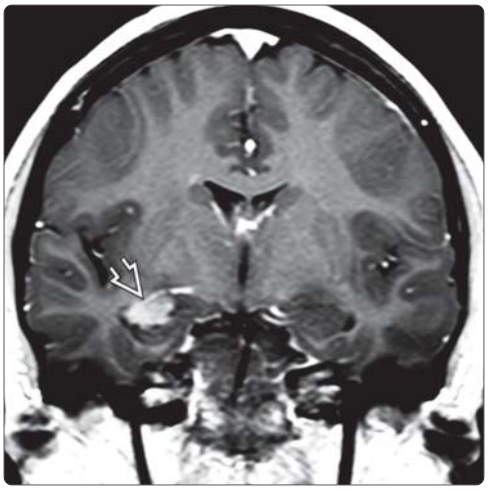

(Left) *Axial T1 C+ FS MR in a 19-year-old woman with headaches, nausea, and vomiting shows a strongly enhancing mass in the temporal horn of the right lateral ventricle ⇨.* **(Right)** *Coronal T1 C+ scan in the same patient shows the intraventricular mass ⇨ is lobulated and well delineated. Preoperative diagnosis was meningioma. Pathology disclosed a typical CPP. The temporal horn is an unusual location for a CPP, but the appearance, in this case, is consistent with the diagnosis.*

https://CafePezeshki.IR

KEY FACTS

TERMINOLOGY

- Malignant tumor originating from epithelium of choroid plexus (WHO grade III)

IMAGING

- Best imaging clue: Child < 5 years with enhancing intraventricular mass and ependymal invasion, ± prominent flow voids
  - Asymmetric periventricular white matter edema suggests invasion
- MR may not distinguish papilloma from carcinoma
  - Heterogeneity, brain invasion, CSF spread favors CPCa
- Important to image spine prior to surgery

TOP DIFFERENTIAL DIAGNOSES

- Choroid plexus papilloma (CPP)
- Ependymoma
- Subependymal giant cell astrocytoma

PATHOLOGY

- WHO grade III
- Microscopic features: Hypercellularity, pleomorphism, increased mitotic activity
  - Cysts, necrosis, hemorrhage, microcalcifications
  - Brain invasion common
- Increased incidence in Li-Fraumeni and Aicardi syndromes

CLINICAL ISSUES

- Occurs in infants and young children
  - 70% occur before 2 years of age
- Nausea, vomiting, headache, obtundation most common presenting features
- CPCa represent 20-40% of all choroid plexus tumors
- Grows rapidly
- 30-50% 5-year survival
- Poor outcome with brain invasion or CSF seeding

(Left) *Axial graphic demonstrates a lobular mass centered in the atria of the left lateral ventricle. Note the invasion and expansion of the surrounding parenchyma, more characteristic of a choroid plexus carcinoma. There is associated midline shift and entrapment of the right lateral ventricle.* **(Right)** *Axial NECT in a 2-year-old female with a large head and papilledema shows a predominately hyperdense mass in the left cerebral hemisphere.*

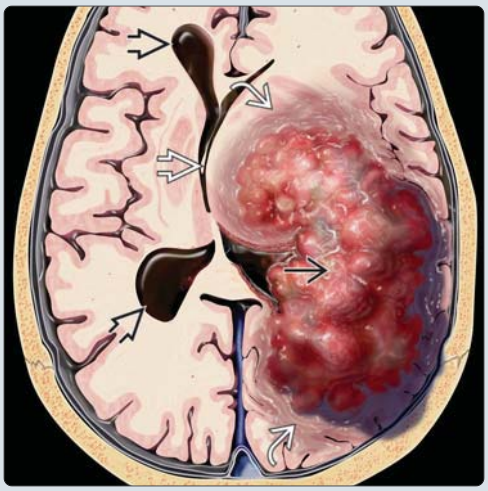

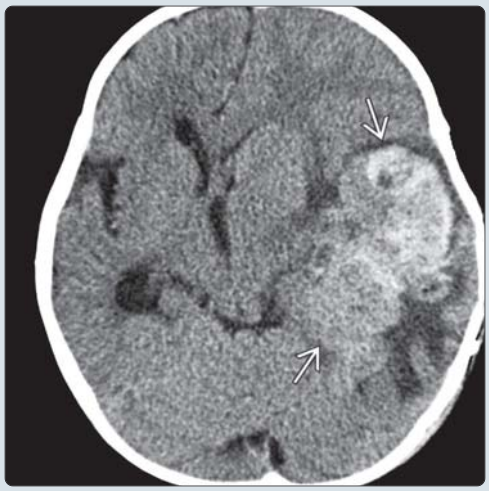

(Left) *Axial T2WI in the same case shows the lobulated mass is extremely heterogeneous in signal intensity. The lesion appears to arise within the atrium of the left lateral ventricle and invades the adjacent brain extensively.* **(Right)** *Axial post-contrast T1WI shows the mass enhances strongly but heterogeneously. Choroid plexus carcinoma (WHO grade III) was found at surgery.*

https://CafePezeshki.IR

TERMINOLOGY

Abbreviations

- Choroid plexus carcinoma (CPCa)
- Choroid plexus tumor (CPT)

Definitions

- Malignant tumor originating from epithelium of choroid plexus

IMAGING

General Features

- Best diagnostic clue
  - Child (< 5 years) with enhancing intraventricular mass and ependymal invasion
  - Differentiation from choroid plexus papilloma (CPP) is histologic, not radiologic
- Location
  - Almost always arise in lateral ventricle
- Size
  - Variable
- Morphology
  - Cauliflower-like mass
  - Necrosis, cysts, and hemorrhage common

CT Findings

- NECT
  - Iso- to hyperattenuating mass with irregular contours
  - Necrosis, cysts, and hemorrhage common
  - Hydrocephalus common
  - Calcification (Ca++) in 20-25%
- CECT
  - Heterogeneous, strong enhancement
  - Peritumoral edema
  - ± CSF tumor seeding

MR Findings

- T1WI
  - Iso- to hypointense intraventricular mass
  - Lobulated or irregularly marginated, papillary appearance
  - Heterogeneous (necrosis, cysts, hemorrhage)
- T2WI
  - Mixed signal mass, hypo-/iso-/hyperintense
  - Heterogeneous related to necrosis, cysts, hemorrhage, Ca++
  - ± prominent flow voids
  - Many invade brain and cause edema
- PD/intermediate
  - Heterogeneous mass with vascular flow voids
- FLAIR
  - Heterogeneous intraventricular mass
  - Periventricular white matter edema suggests invasion
  - Transependymal CSF flow from hydrocephalus
- T2* GRE
  - Low signal from hemorrhage or calcification
- DWI
  - Low ADC values in solid portions of tumor
- T1WI C+
  - Heterogeneous enhancement, ± CSF seeding
- MRS
  - NAA absent; ↑ choline ± ↑ lactate

Angiographic Findings

- Conventional
  - Enlarged choroidal artery and vascular stain

Nuclear Medicine Findings

- PET
  - 11C-methionine → ↑ tumor: Normal brain ratios
- Tc-99m sestamibi → ↑ in CPTs

Imaging Recommendations

- Best imaging tool
  - Contrast-enhanced MR of brain and spine
- Protocol advice
  - Enhanced MR of entire neuraxis prior to surgery

DIFFERENTIAL DIAGNOSIS

Choroid Plexus Papilloma (CPP)

- MR may not distinguish CPCa from typical or atypical CPP
- Aggressive CPP may seed through CSF pathways
- CPP rarely shows minimal brain invasion

Ependymoma

- Heterogeneous 4th ventricular mass
- Classically squeezes out 4th ventricular foramina into cisterns
- Supratentorial ependymoma often extraventricular

Subependymal Giant Cell Astrocytoma

- Associated CNS findings of tuberous sclerosis
- Characteristic location near foramen of Monro
- Rarely cause edema

Astrocytic Tumors

- May arise from periventricular tissues (septum pellucidum, thalamus)
- Smooth or lobular masses, no papillary margins
- High-grade tumor may cause periventricular edema

Medulloblastoma

- Hyperdense, round 4th ventricular mass
- Arises from roof of 4th ventricle (superior medullary velum)

Central Neurocytoma

- "Bubbly" intraventricular mass in adult
- Often attached to septum pellucidum

Meningioma

- Delineated, oval enhancing mass
- Uncommon in children, associated with neurofibromatosis type 2

Primitive Neuroectodermal Tumor (PNET)

- Heterogeneous tumor can be lobulated within lateral ventricle
- May arise deep in hemisphere
- Peritumoral edema often minimal

Atypical Teratoid/Rhabdoid Tumor (AT/RT)

- Heterogeneous tumor with cysts or hemorrhage

https://CafePezeshki.IR

- Common in posterior fossa, may occur in lateral ventricle, often intraaxial
- Typically present in patients < 2 years of age
- INI1 protein negative on immunohistochemistry
  - Most CPCa positive

Vascular Lesions

- Arteriovenous malformation
- Cavernous malformation

Metastases

- History of previous tumor often known
- Multiple lesions common
- Rare in children

PATHOLOGY

General Features

- Etiology
  - SV40 virus DNA sequences in 50% of CPTs
- Genetics
  - Increased incidence in Li-Fraumeni and Aicardi syndromes
    - Li-Fraumeni *TP53* mutation/deletion
      - Autosomal dominant tumor predisposition syndrome
  - Overlap with rhabdoid tumors and *SNF5(INI1)* mutation
- Associated abnormalities
  - Diffuse hydrocephalus → mechanical obstruction, increased CSF production, decreased resorption

Staging, Grading, & Classification

- WHO grade III

Gross Pathologic & Surgical Features

- Well-circumscribed lobulated intraventricular mass
- Ependymal invasion

Microscopic Features

- Hypercellular, pleomorphic, increased mitotic activity
- Cysts, necrosis, hemorrhage, microcalcifications
- Brain invasion common
- May have CSF seeding
- Ki-67 (MIB-1) proliferation indices high (~ 14-20%)

Immunochemistry

- Kir7.1 and Stanniocalcin-1 may distinguish choroid plexus origin from other tumors
- CPC express cytokeratins
- Transthyretin, S100(+) (less than CPP)

Genetic Alterations

- Recurrent copy number losses and gains of multiple chromosomes, varying with age

CLINICAL ISSUES

Presentation

- Most common signs/symptoms
  - Nausea, vomiting, headache, obtundation
  - Focal neurologic signs and symptoms
- Clinical profile
  - Infant or child with elevated ICP and focal neuro deficits

Demographics

- Age
  - Infants and young children (typically < 5 years)
  - Median: 26-32 months
- Gender
  - M = F
- Epidemiology
  - 80% arise in children
  - 70% before 2 years of age
  - 20-40% of all CPTs
  - ~ 5% of supratentorial tumors in children
  - < 1% of all pediatric intracranial tumors

Natural History & Prognosis

- Small percentage may be malignant progression from WHO grade I and II papillomas
- Grows rapidly
- 30-50% 5-year survival
- Poor outcome with brain invasion, CSF seeding

Treatment

- "Head Start" (HS) irradiation-avoiding strategy has improved survival, minimized neurocognitive sequelae
  - Maximal surgical resection 1st
  - High dose consolidation myeloablative chemotherapy next
    - With autologous hematopoietic stem cell rescue
  - ± post-chemo irradiation (based on patient age, evidence of residual disease)

DIAGNOSTIC CHECKLIST

Consider

- CPCa in child with invasive intraventricular mass and focal neurologic signs

Image Interpretation Pearls

- MR may not distinguish papilloma from carcinoma
- Heterogeneity, brain invasion, CSF spread favors CPCa
- Image spine prior to surgery

SELECTED REFERENCES

1. Cannon DM et al: Choroid plexus tumor epidemiology and outcomes: implications for surgical and radiotherapeutic management. J Neurooncol. 121(1):151-7, 2015
2. Zaky W et al: Choroid plexus carcinoma in children: The Head Start experience. Pediatr Blood Cancer. 62(5):784-9, 2015
3. Ruland V et al: Choroid plexus carcinomas are characterized by complex chromosomal alterations related to patient age and prognosis. Genes Chromosomes Cancer. 53(5):373-80, 2014
4. Korchi AM et al: Pseudoprogression after proton beam irradiation for a choroid plexus carcinoma in pediatric patient: MRI and PET imaging patterns. Childs Nerv Syst. 29(3):509-12, 2013
5. Gonzalez KD et al: Beyond Li Fraumeni syndrome: clinical characteristics of families with p53 germline mutations. J Clin Oncol. 27(8):1250-6, 2009
6. Gopal P et al: Choroid plexus carcinoma. Arch Pathol Lab Med. 132(8):1350-4, 2008
7. Wrede B et al: Chemotherapy improves the survival of patients with choroid plexus carcinoma: a meta-analysis of individual cases with choroid plexus tumors. J Neurooncol. 85(3):345-51, 2007
8. Levy ML et al: Choroid plexus tumors in children: significance of stromal invasion. Neurosurgery. 48(2):303-9, 2001
9. Malkin D et al: Tissue-specific expression of SV40 in tumors associated with the Li-Fraumeni syndrome. Oncogene. 20(33):4441-9, 2001

https://CafePezeshki.IR

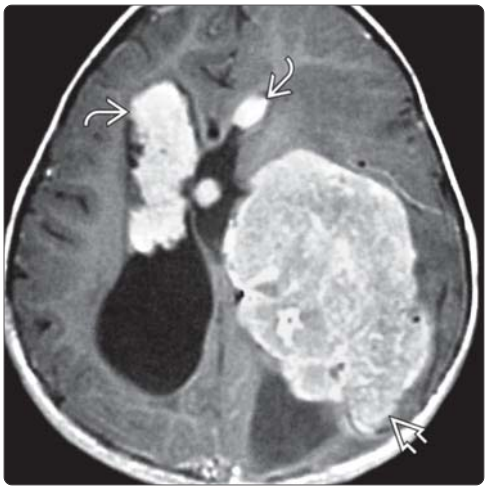

(Left) *Axial T2WI MR shows a massive left lateral ventricle choroid plexus carcinoma* ⇨ *with multiple nodules of metastatic CSF spread* ⇨. *Note the asymmetric periventricular T2 hyperintensity* ⇨ *related to brain invasion.* **(Right)** *Axial T1WI C+ MR in the same patient shows marked enhancement of the lateral ventricle choroid plexus carcinoma with ependymal invasion* ⇨ *and multiple nodules of metastatic CSF spread* ⇨. *CSF spread and brain invasion is associated with a poor prognosis.*

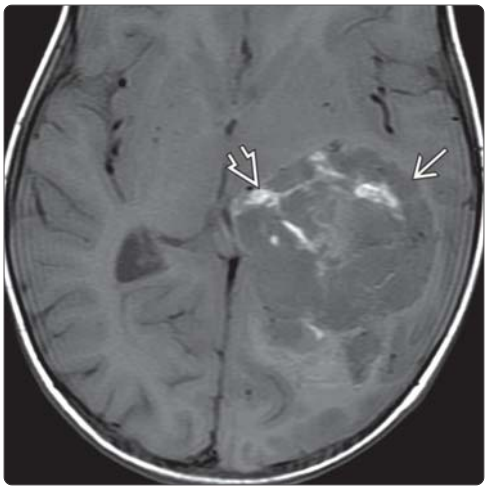

(Left) *Axial NECT in a 2 year old with altered mental status shows a hyperdense mass with areas of necrosis* ⇨ *in the atrium of the left lateral ventricle.* **(Right)** *Axial T1 MR in the same case shows a heterogenous mass expanding the atria of the left lateral ventricle* ⇨. *Areas of T1 hyperintensity* ⇨ *consistent with hemorrhage.*

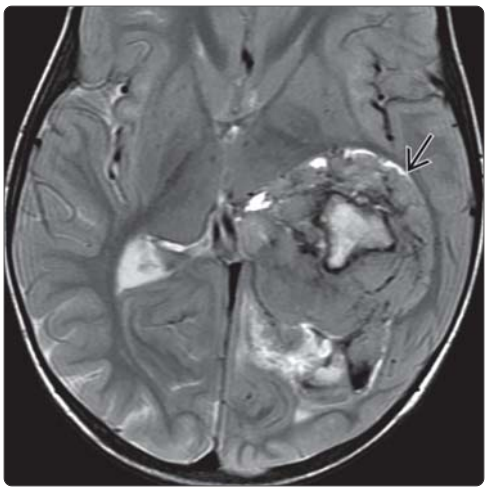

(Left) *Axial T2WI MR shows a large inhomogeneous mass* ⇨ *filling the left atrium and temporal horn.* **(Right)** *Axial T1WI C+ MR in the same patient shows intense enhancement of the intraventricular mass with central necrosis* ⇨. *Note the enhancement of the adjacent occipital lobe, confirming tumor invasion* ⇨. *CPCa was found at resection.*

https://CafePezeshki.IR

Ganglioglioma

KEY FACTS

TERMINOLOGY

- Well-differentiated, slowly growing neuroepithelial tumor composed of neoplastic ganglion cells and neoplastic glial cells
- Most common neoplastic cause of temporal lobe epilepsy (TLE)

IMAGING

- Best diagnostic clue: Partially cystic, enhancing, cortically based mass in child/young adult with TLE
- Can occur anywhere, but most commonly superficial hemispheres, temporal lobe (> 75%)
- Circumscribed cyst with mural nodule most common
- May be solid and appear well circumscribed
- Calcification is common (up to 50%)
- Superficial lesions may expand cortex, remodel bone
- ~ 50% enhance
- Protocol advice: Contrast-enhanced MR to include coronal T2 images for better evaluation of temporal lobes

TOP DIFFERENTIAL DIAGNOSES

- Pleomorphic xanthoastrocytoma (PXA)
- Dysembryoplastic neuroepithelial tumor (DNET)
- Astrocytoma
- Oligodendroglioma
- Neurocysticercosis

PATHOLOGY

- WHO grade I or II (80% grade I)
- Uncommon: Anaplastic ganglioglioma (WHO III)
- Rare: Malignant with glioblastoma multiforme (GBM)-like glial component (WHO IV)

CLINICAL ISSUES

- Occurs at all ages (peak: 10-20 years)
- Most common mixed neuronal-glial tumor
- Cortical dysplasia is commonly associated with GG
- Excellent prognosis if surgical resection complete

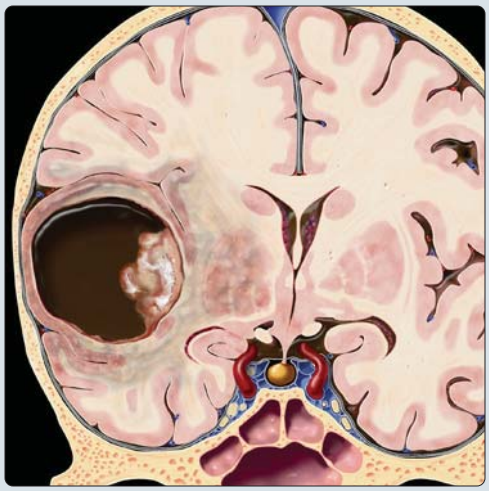

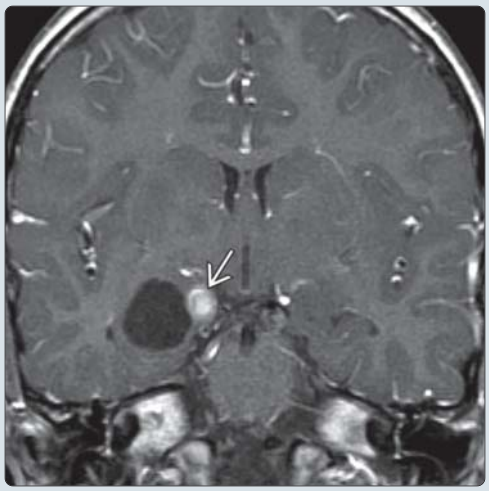

(Left) *Coronal graphic shows a discrete cystic and solid temporal lobe mass expanding the overlying cortex. Calvarial remodeling is seen, typical of a superficially located ganglioglioma. Gangliogliomas are the most common tumors to cause temporal lobe epilepsy.* **(Right)** *Coronal T1WI C+ MR in a young adult with temporal lobe epilepsy shows a circumscribed, cystic, and solid temporal lobe mass with intense enhancement of the mural nodule. This is the classic enhancement pattern of a ganglioglioma.*

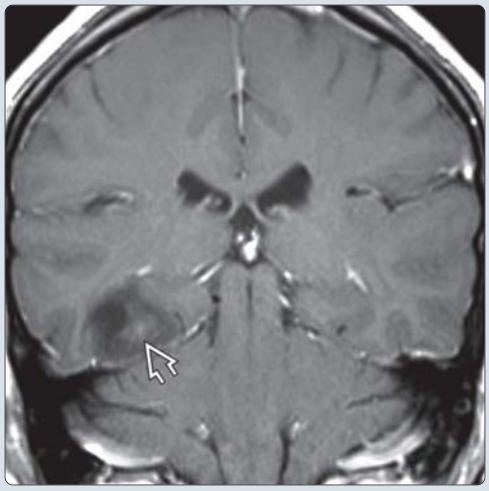

(Left) *Axial CT image shows a partially calcified frontal lobe mass in a 25 year old with headaches and seizures. The lack of surrounding edema is typical for ganglioglioma. Imaging mimics an oligodendroglioma. Calcification is seen in 30-50% of gangliogliomas.* **(Right)** *Coronal T1WI C+ MR shows subtle enhancement within a right temporal lobe ganglioglioma in a female patient with seizures. The differential diagnosis for this lesion includes DNET, astrocytoma, PXA, and oligodendroglioma.*

https://CafePezeshki.IR

TERMINOLOGY

Abbreviations

- Ganglioglioma (GG)

Definitions

- Well-differentiated, slowly growing neuroepithelial tumor composed of neoplastic ganglion cells and neoplastic glial cells
- Most common neoplasm to cause temporal lobe epilepsy (TLE)

IMAGING

General Features

- Best diagnostic clue
  - Partially cystic, enhancing, cortically based mass in child/young adult with TLE
- Location
  - Can occur anywhere, but most commonly superficial hemispheres, temporal lobe (> 75%)
    - Frontal and parietal lobes next most common
  - Rare locations: Brainstem, cerebellum, pineal region, optic nerve/chiasm, intraventricular, pituitary axis, spinal cord, cranial nerves
- Size
  - Variable in adults, typically 2-3 cm
  - Larger in children, typically > 4 cm
  - Up to 6 cm reported
- Morphology
  - 3 patterns
    - Most common: Circumscribed cyst with mural nodule
    - Solid tumor (often thickens, expands gyri)
    - Uncommon: Infiltrating, poorly delineated mass
  - Calcification is common (up to 50%)
  - In younger patients (< 10 years), gangliogliomas are larger and more cystic

CT Findings

- NECT
  - Variable density
    - 40% hypodense
    - 30% mixed hypodense (cyst), isodense (nodule)
    - 15% isodense or hyperdense
  - Ca++ common (35-50%)
  - Superficial lesions may expand cortex, remodel bone
  - Hemorrhage is rare
- CECT
  - ~ 50% enhance
    - Variable; moderate and uniform to heterogeneous
    - Can be solid, rim, or nodular
    - Often shows cyst with enhancing nodule

MR Findings

- T1WI
  - Mass is hypointense to isointense to gray matter
    - Rarely hyperintense
  - Ca++ has variable signal intensity
  - May see associated cortical dysplasia
- T2WI
  - Hyperintense mass typical
  - May be heterogeneous
  - No surrounding edema
- T2* GRE
  - May show Ca++ as areas of "blooming"
- T1WI C+
  - Variable enhancement, usually moderate but heterogeneous
    - May be minimal, ring like, homogeneous
    - Some GG do not enhance
  - Meningeal enhancement rarely seen
- MRS
  - Elevated Cho has been described

Nuclear Medicine Findings

- PET
  - Typically decreased activity with FDG PET indicating tumor hypometabolism
  - May have some hypermetabolic foci
- Th-201 SPECT: Increased activity in high-grade gangliogliomas (grade III, IV)
  - Typical gangliogliomas have decreased or normal SPECT activity

Imaging Recommendations

- Best imaging tool
  - Multiplanar MR
- Protocol advice
  - Contrast-enhanced MR to include coronal T2 images for better evaluation of temporal lobes

DIFFERENTIAL DIAGNOSIS

Pleomorphic Xanthoastrocytoma (PXA)

- Supratentorial cortical mass, dural "tail" common
- Often cyst and mural nodule, may be solid
- Enhancing nodule abuts pial surface
- Temporal lobe most common location

Dysembryoplastic Neuroepithelial Tumor (DNET)

- Superficial cortical tumor, well demarcated
- Multicystic bubbly appearance
- T2-hyperintense mass with rare, mild enhancement
- May remodel calvaria

Pilocytic Astrocytoma

- Supratentorial location other than hypothalamus/chiasm rare
- Typically solid and cystic or solid mass
- Enhancement typical

Low-Grade Astrocytoma (Grade II)

- Circumscribed but infiltrative white matter mass
- No enhancement

Oligodendroglioma

- Calcified, heterogeneous mass
- Typically more diffuse than ganglioglioma
- May remodel/erode calvaria

Neurocysticercosis

- Cyst with "dot" inside
- Often calcified
- Multiple lesions common

https://CafePezeshki.IR

- Imaging varies with pathologic stage, host response

PATHOLOGY

General Features

- Etiology
  - 2 theories
    - Origin from dysplastic, malformative glioneuronal precursor lesion with glial element neoplastic transformation
    - Neoplastic transformation of glial hamartoma or subpial granule cells
- Genetics
  - Gain of chromosome 7 and 12 reported
  - Deletions of 22q in neoplastic glial cells
  - Sporadic
    - *TP53* mutations found in malignant degeneration
  - Syndromic
    - Ganglioglioma has been reported in Turcot syndrome, NF1, and NF2
- Associated abnormalities
  - Gangliogliomas have been found in association with oligodendroglioma, DNET, tanycytic ependymoma
  - Malignant transformation into GBM, neuroblastoma has been reported
  - Cortical dysplasia is commonly associated
    - Possibly related to mutations affecting mTORC1 pathway

Staging, Grading, & Classification

- Common: WHO grade I 80% or II
- Uncommon: Anaplastic ganglioglioma (WHO grade III)
- Rare: Malignant with GBM-like glial component (WHO grade IV)

Gross Pathologic & Surgical Features

- Solid or cystic mass with mural nodule
- Firm, well-circumscribed mass, often expands cortex
- Ca++ is common

Microscopic Features

- Mix of mature but neoplastic ganglion cells and neoplastic glial cells (usually astrocytes)
- Dysmorphic, occasionally binucleate neurons
  - Immunohistochemistry of neuronal cells
    - Synaptophysin and neurofilament protein are positive
    - Majority exhibit CD34 immunoreactivity (70-80% of gangliogliomas)
- Electron microscopy shows dense core granules, variable synapses
- Neoplastic glial cells are GFAP(+)
- Mitoses rare (75% have Ki-67 < 1%, low MIB [1-3%])

CLINICAL ISSUES

Presentation

- Most common signs/symptoms
  - Chronic temporal lobe epilepsy (~ 90%)
    - Often partial complex seizures
  - Other signs/symptoms: Headache and signs of increased intracranial pressure

Demographics

- Age
  - Tumor of children, young adults
  - 80% of patients < 30 years
  - Occurs at all ages
  - Peak: 10-20 years
- Gender
  - Slight male predominance
- Epidemiology
  - 1% of primary intracranial neoplasms
  - Most common mixed neuronal-glial tumor
  - Represents ~ 5% of pediatric CNS neoplasms
  - Most common tumor to cause TLE (> 45%)
    - Ganglioglioma (40%) > DNET (20%) > pilocytic astrocytoma > low-grade astrocytoma > oligodendroglioma > PXA

Natural History & Prognosis

- Excellent prognosis if surgical resection complete
- 94% have 7.5-year recurrence-free survival
- Vast majority of patients seizure-free after surgery (80%)
- Well-differentiated tumor with slow growth pattern
- Malignant degeneration is rare (~ 5-10% glial component)

Treatment

- Surgical resection is treatment of choice
- Radiation therapy &/or chemotherapy for aggressive or unresectable tumors

DIAGNOSTIC CHECKLIST

Consider

- Ganglioglioma in young patient with history of TLE
- In children < 10 years old, gangliogliomas are larger and more cystic

Image Interpretation Pearls

- Cyst with enhancing mural nodule is classic, but not specific for ganglioglioma

SELECTED REFERENCES

1. Dudley RW et al: Pediatric low-grade ganglioglioma: epidemiology, treatments, and outcome analysis on 348 children from the surveillance, epidemiology, and end results database. Neurosurgery. 76(3):313-9; discussion 319; quiz 319-20, 2015
2. Lucas JT Jr et al: Anaplastic ganglioglioma: a report of three cases and review of the literature. J Neurooncol. 123(1):171-7, 2015
3. Deling L et al: Intraventricular ganglioglioma prognosis and hydrocephalus: the largest case series and systematic literature review. Acta Neurochir (Wien). 155(7):1253-60, 2013
4. Gopalakrishnan CV et al: Brainstem ganglioglioma in an infant: Case report and review of literature. J Pediatr Neurosci. 8(1):41-5, 2013
5. Allende DS et al: The expanding family of glioneuronal tumors. Adv Anat Pathol. 16(1):33-9, 2009
6. Karremann M et al: Anaplastic ganglioglioma in children. J Neurooncol. 92(2):157-63, 2009
7. Westwood DA et al: Pontomedullary ganglioglioma: a rare tumour in an unusual location. J Clin Neurosci. 16(1):108-10, 2009
8. Adachi Y et al: Gangliogliomas: Characteristic imaging findings and role in the temporal lobe epilepsy. Neuroradiology. 50(10):829-34, 2008
9. Brat DJ et al: Surgical neuropathology update: a review of changes introduced by the WHO classification of tumours of the central nervous system, 4th edition. Arch Pathol Lab Med. 132(6):993-1007, 2008
10. Park YS et al: Factors contributing to resectability and seizure outcomes in 44 patients with ganglioglioma. Clin Neurol Neurosurg. 110(7):667-73, 2008

https://CafePezeshki.IR

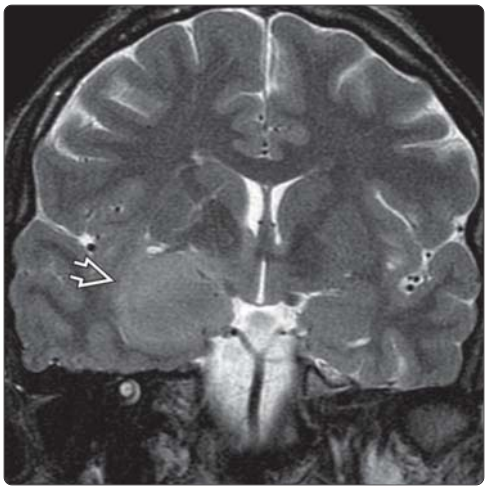

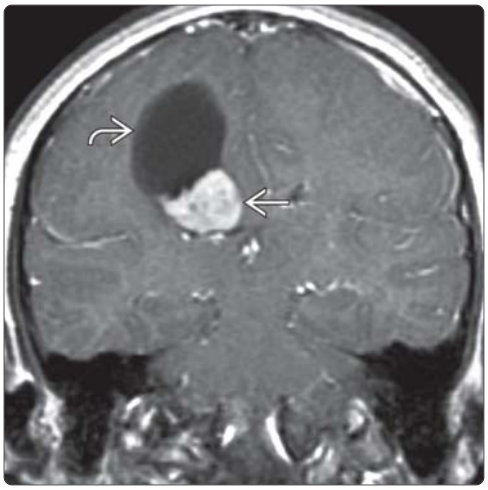

(Left) *Coronal T2WI MR shows a discrete, hyperintense mass ➡ in this 25-year-old temporal lobe epilepsy patient. Thin-section T2 imaging is very helpful for evaluation of patients with temporal lobe epilepsy. This nonenhancing mass proved to be ganglioglioma at resection.* **(Right)** *Coronal T1WI C+ MR shows a well-circumscribed frontal lobe mass with a sharply demarcated cystic portion ➡ and an enhancing deep soft tissue nodule ➡ that indents the ventricle. This deep white matter location is atypical of ganglioglioma.*

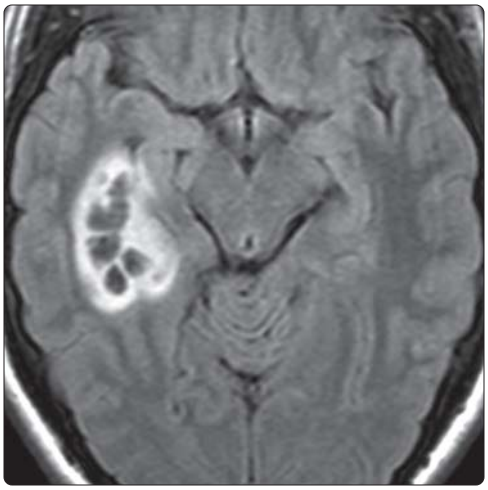

(Left) *Axial FLAIR MR shows a discrete, multiseptated temporal lobe mass. The lack of surrounding edema and lack of significant mass effect is typical of ganglioglioma. This WHO grade I tumor has a very good prognosis with resection.* **(Right)** *Axial T2WI MR shows a hyperintense, cystic parietal lobe mass ➡ with remodeling of the overlying calvaria. This mass showed a cyst with an enhancing mural nodule, classic for ganglioglioma. Superficial tumors often have associated bone remodeling.*

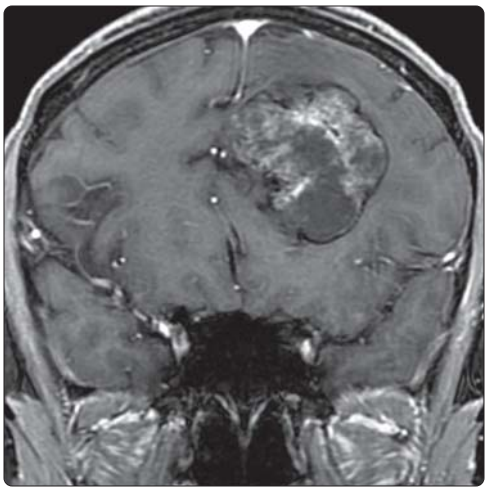

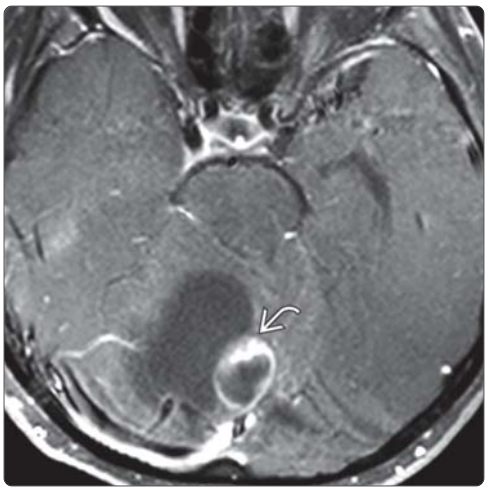

(Left) *Coronal T1WI C+ MR in a young adult with seizures shows a heterogeneously enhancing frontal lobe mass. Ganglioglioma was diagnosed at resection. The frontal lobe is the 2nd most common location for a ganglioglioma.* **(Right)** *Axial T1WI C+ FS MR shows an enhancing cyst and mural nodule along the medial border of a large cystic mass ➡. The posterior fossa is an uncommon location for a ganglioglioma. Differential considerations would include hemangioblastoma and pilocytic astrocytoma in this young adult.*

https://CafePezeshki.IR

KEY FACTS

TERMINOLOGY

- Large cystic tumors of infants involving superficial cerebral cortex and leptomeninges
- Desmoplastic infantile ganglioglioma (DIG/DIGG)
  - Prominent desmoplastic stroma + neoplastic astrocytes, variable neuronal component
- Desmoplastic infantile astrocytoma (DIA)
  - Desmoplastic stroma + neoplastic astrocytes

IMAGING

- Best diagnostic clue: Peripheral supratentorial tumor with cyst and nodule in infant < 2 years
  - Large cyst + cortical-based tumor nodule
  - Enhancement of adjacent meninges
  - T2 hypointense solid portion
- Frontal and parietal > temporal > occipital
- Cysts may be very large, cause macrocephaly and bulging fontanelles in infants

TOP DIFFERENTIAL DIAGNOSES

- Primitive neuroectodermal tumor (PNET)
- Supratentorial ependymoma
- Pleomorphic xanthoastrocytoma (PXA)
- Hemangioblastoma
- Ganglioglioma
- Pilocytic astrocytoma

PATHOLOGY

- WHO grade 1
- Areas of cellular proliferation, mitoses, and necrosis may cause misdiagnosis as higher grade tumor

CLINICAL ISSUES

- Most are found at 1-24 months (peak: 3-6 months)
- 16% of intracranial tumors in 1st year of life
- Median survival rate is > 75% at 15 years
- Surgical resection typically curative

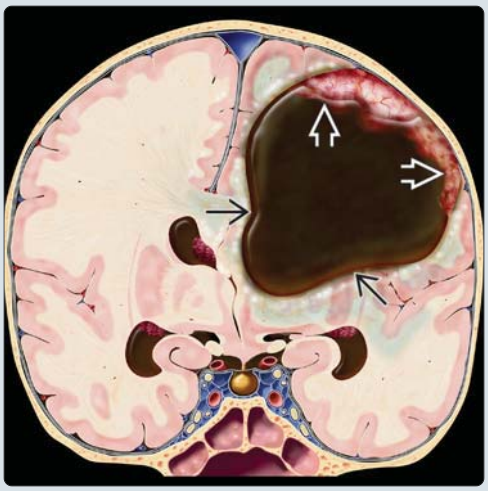

(Left) *Coronal graphic shows an infant with an enlarged head caused by desmoplastic infantile ganglioglioma and astrocytoma (DIG/DIA). Note the dominant cystic component ⇨ with a dural-based plaque of desmoplastic stroma ⇨. Mild surrounding edema and hydrocephalus is present.* **(Right)** *Coronal T2WI MR shows a large cystic and solid mass with a T2 hypointense, peripheral plaque-like solid component ⇨, characteristic of DIG/DIA. Note the significant associated mass effect and hydrocephalus ⇨.*

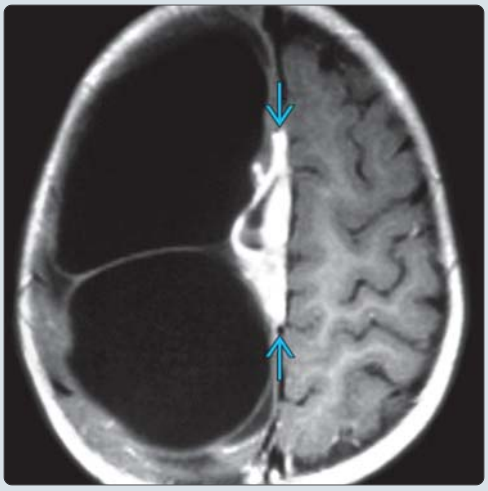

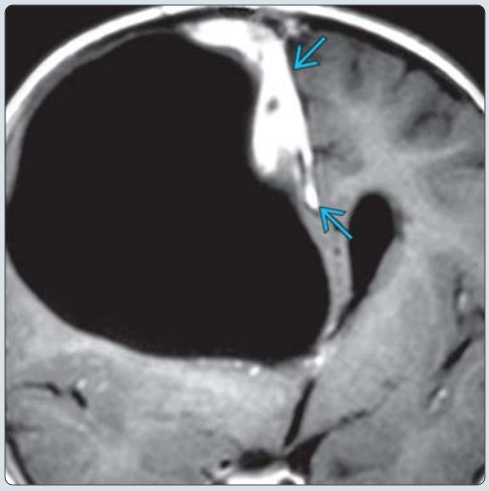

(Left) *Axial T1WI C+ MR shows a large cystic and solid mass with a markedly enhancing solid component along the falx ⇨.* **(Right)** *Coronal T1WI C+ MR in the same patient shows the large cystic and solid mass with a dural-based enhancing solid portion ⇨, characteristic of DIG/DIA. Involvement of the adjacent dura is typical. DIG/DIA should be considered in supratentorial tumors demonstrating cysts and peripheral nodules in the 1st year of life. (Courtesy M. Sage, MD.)*

https://CafePezeshki.IR

TERMINOLOGY

Abbreviations

- Desmoplastic infantile ganglioglioma (DIG/DIGG)
- Desmoplastic infantile astrocytoma (DIA)

Synonyms

- Desmoplastic supratentorial neuroepithelial tumors of infancy
- Superficial cerebral astrocytoma ± neuronal elements attached to dura

Definitions

- Large cystic tumors of infants involving superficial cerebral cortex and leptomeninges, often attached to dura
- DIG: Prominent desmoplastic stroma + neoplastic astrocytes, variable neuronal component
- DIA: Desmoplastic stroma + neoplastic astrocytes

IMAGING

General Features

- Best diagnostic clue
  - Large cyst + cortical-based enhancing tumor nodule/plaque in infant < 2 years
  - Enhancement of adjacent pia plus reactive dural thickening
  - T2 hypointense solid portion
- Location
  - Supratentorial: Frontal/parietal > temporal > occipital
- Size
  - Cysts may be very large, cause macrocephaly and bulging fontanelles in infants
- Morphology
  - Solid and cystic mass usually with dural attachment

CT Findings

- NECT
  - Large heterogeneous solid and cystic mass
  - Well-demarcated hypodense cyst (isodense to CSF)
  - Solid tumor nodule(s) isodense/slightly hyperdense to GM
  - Calcification extremely rare
- CECT
  - Cyst → no enhancement
  - Nodule → marked enhancement
- CTA
  - Hypovascular; supply from intra- and extraparenchymal vessels
  - Vessels markedly stretched around large cyst

MR Findings

- T1WI
  - Cyst: Hypointense, often multilobulated
    - May contain septa
  - Solid portion: Nodule or plaque-like areas → heterogeneous
- T2WI
  - Cyst is hyperintense
  - Lobular, solid tumor nodule is hypointense
  - Degree of surrounding edema dependent upon local ventricular obstruction
- FLAIR
  - Cysts are isointense to CSF
  - Solid portions usually isointense to GM
- T2* GRE
  - No hemorrhage or calcification
- DWI
  - Usually no restriction
- T1WI C+
  - Solid tumor nodule(s) enhance markedly, homogeneously
  - Enhancement of leptomeninges, dura adjacent to solid tumor is typical
  - Cyst typically more central than enhancing solid nodule, ± wall enhancement
- MRS
  - ↓ NAA, ↑ choline

Ultrasonographic Findings

- Grayscale ultrasound
  - Large, multicystic mass
  - Hypoechoic tumor nodule, if identified

Imaging Recommendations

- Best imaging tool
  - Multiplanar contrast-enhanced MR

DIFFERENTIAL DIAGNOSIS

Primitive Neuroectodermal Tumor (PNET)

- Solid tumor is hyperdense on CT, isointense to GM on T2, contains cysts, Ca++, edema
- Large heterogeneously enhancing hemispheric mass
- Large cyst less common than in DIG/DIA

Supratentorial Ependymoma

- Nonspecific imaging findings but commonly contains Ca++
- Solid portion usually less peripherally located than DIG/DIA
- Cysts are often less complex than DIG/DIA

Pleomorphic Xanthoastrocytoma (PXA)

- May appear identical to DIG
- Occurs in older patients, children, and young adults
- Temporal lobe most common location

Hemangioblastoma

- Cyst with mural nodule appearance in posterior fossa
- Solid nodule is vascular, flow void may be seen
- Older patients
- Imaging features similar to DIG but rare above tentorium

Ganglioglioma

- Similar appearance to DIG but generally smaller in size
- Ca++ is common
- Older patients, children, and young adults
- Temporal lobe most common location

Pilocytic Astrocytoma

- Rare in infancy
- Uncommon in cerebral hemispheres
- Cyst is usually smaller; nodule hyperintense on T1WI

https://CafePezeshki.IR

PATHOLOGY

General Features

- Etiology
  - Possibly related to progenitor cells in subcortical zone along with mature subpial astrocytes
- Genetics
  - DIA, DIG represent histologic spectrum of same tumor rather than 2 separate entities
  - Large chromosomal alterations rare, inconsistent
  - BRAF V600E mutation rare; affects subset of DIA/DIGs

Staging, Grading, & Classification

- WHO grade I

Gross Pathologic & Surgical Features

- 2 distinct components
  - Cortical-based solid tumor nodule with adjacent dural thickening
  - Large associated cyst compresses adjacent ventricular system
- Large cyst(s) containing xanthochromic fluid
- Firm attachment to dura and brain parenchyma
- No necrosis within solid component of tumor, no hemorrhage

Microscopic Features

- DIA: Astrocytes are sole tumor cell
- DIG: Astrocytes + neoplastic neurons
  - Intense desmoplasia with mixture of astroglial and neuronal cells
  - Immature neuronal component and neoplastic astrocytes
- Spindle cells in collagenous stroma forming whorled patterns
- Ki-67 (MIB-1) proliferation indices < 2-5%
  - Rare: ↑ Ki-67, malignant histologic features, behaves in aggressive clinical manner

Immunohistochemistry

- GFAP and vimentin positive
- Synaptophysin (+) if neuronal elements (DIG)

CLINICAL ISSUES

Presentation

- Most common signs/symptoms
  - ↑ head size, bulging fontanelles, paresis, and seizures
  - Older children: Seizures and focal neurologic signs/symptoms
- Clinical profile
  - Infant with rapidly progressive macrocephaly

Demographics

- Age
  - Most are found at 1-24 months (peak: 3-6 months)
  - Children, < 24 months, usually ≤ 12 months; occasionally older patients (5-17 years)
- Gender
  - Slightly more common in males (M:F = 2:1)
- Epidemiology
  - 1.25% of intracranial tumors in childhood
  - 16% of intracranial tumors in 1st year of life

Natural History & Prognosis

- Median survival rate is > 75% at 15 years after diagnosis
- Spontaneous disappearance rare
- Anaplasia is very rare
- Leptomeningeal metastasis rare

Treatment

- Surgical resection curative, no recurrence with complete resection
- Chemotherapy if brain invasion or recurrence

DIAGNOSTIC CHECKLIST

Consider

- Large cystic mass in infant with plaque-like or nodular component along meninges, think DIG/DIA
- Important to mention DIG/DIA in report as pathologists may initially misinterpret as highly malignant tumor

Image Interpretation Pearls

- Solid portion is peripheral involving cortex, often invades adjacent meninges
- Solid portion is T2 hypointense

SELECTED REFERENCES

1. Bader A et al: Radiological features of infantile glioblastoma and desmoplastic infantile tumors: British Columbia's Children's Hospital experience. J Neurosurg Pediatr. 1-7, 2015
2. Koelsche C et al: BRAF V600E expression and distribution in desmoplastic infantile astrocytoma/ganglioglioma. Neuropathol Appl Neurobiol. 40(3):337-44, 2014
3. Gessi M et al: Genome-wide DNA copy number analysis of desmoplastic infantile astrocytomas and desmoplastic infantile gangliogliomas. J Neuropathol Exp Neurol. 72(9):807-15, 2013
4. Romero-Rojas AE et al: Desmoplastic infantile ganglioglioma with late presentation. A clinical, radiological and histopathological analysis. Neuroradiol J. 26(6):649-54, 2013
5. Chandrashekhar TN et al: Pathological spectrum of neuronal/glioneuronal tumors from a tertiary referral neurological Institute. Neuropathology. 32(1):1-12, 2012
6. Schindler G et al: Analysis of BRAF V600E mutation in 1,320 nervous system tumors reveals high mutation frequencies in pleomorphic xanthoastrocytoma, ganglioglioma and extra-cerebellar pilocytic astrocytoma. Acta Neuropathol. 121(3):397-405, 2011
7. Balaji R et al: Imaging of desmoplastic infantile ganglioglioma: a spectroscopic viewpoint. Childs Nerv Syst. 25(4):497-501, 2009
8. Hoving EW et al: Desmoplastic infantile ganglioglioma with a malignant course. J Neurosurg Pediatr. 1(1):95-8, 2008
9. Brat DJ et al: Desmoplastic infantile astrocytoma and ganglioglioma. In Louis DN et al: Tumours of the Central Nervous System. Lyon: IARC Press. 96-8, 2007
10. Darwish B et al: Desmoplastic infantile ganglioglioma/astrocytoma with cerebrospinal metastasis. J Clin Neurosci. 14(5):498-501, 2007
11. Lönnrot K et al: Desmoplastic infantile ganglioglioma: novel aspects in clinical presentation and genetics. Surg Neurol. 68(3):304-8; discussion 308, 2007
12. Bhardwaj M et al: Desmoplastic infantile ganglioglioma with calcification. Neuropathology. 26(4):318-22, 2006
13. Cerdá-Nicolás M et al: Desmoplastic infantile ganglioglioma. Morphological, immunohistochemical and genetic features. Histopathology. 48(5):617-21, 2006
14. Bächli H et al: Therapeutic strategies and management of desmoplastic infantile ganglioglioma: two case reports and literature overview. Childs Nerv Syst. 19(5-6):359-66, 2003
15. Tamburrini G et al: Desmoplastic infantile ganglioglioma. Childs Nerv Syst. 19(5-6):292-7, 2003
16. Shin JH et al: Neuronal tumors of the central nervous system: radiologic findings and pathologic correlation. Radiographics. 22(5):1177-89, 2002

https://CafePezeshki.IR

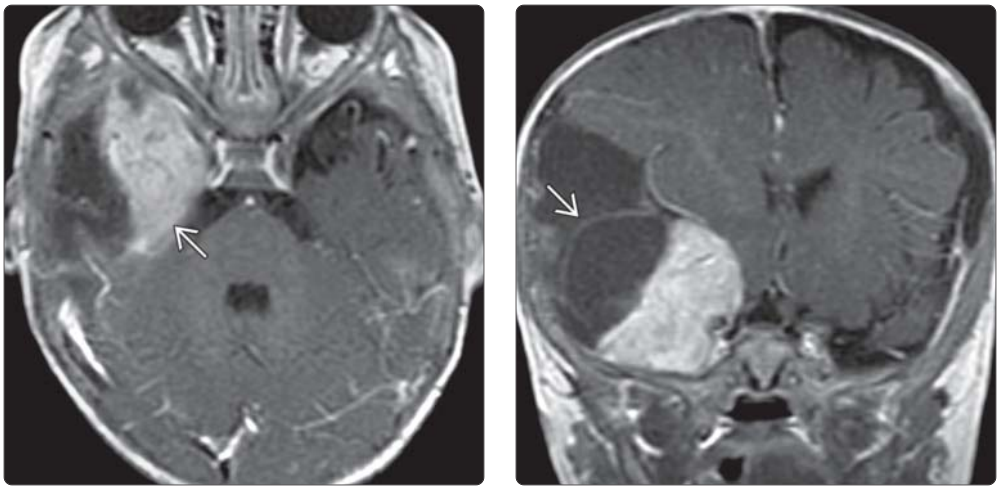

(Left) *Axial T1WI C+ MR shows a cystic and solid mass in the temporal lobe with intense enhancement of the solid portion* ⇨. **(Right)** *Coronal T1WI C+ MR in the same patient shows the cystic and solid mass with internal septations* ⇨ *present in the cystic portion of the tumor. There is mild associated mass effect. DIAs and DIGs are often very large at presentation. Enhancement of the cortically based solid portion with involvement of the adjacent pia and dura is characteristic of these rare tumors.*

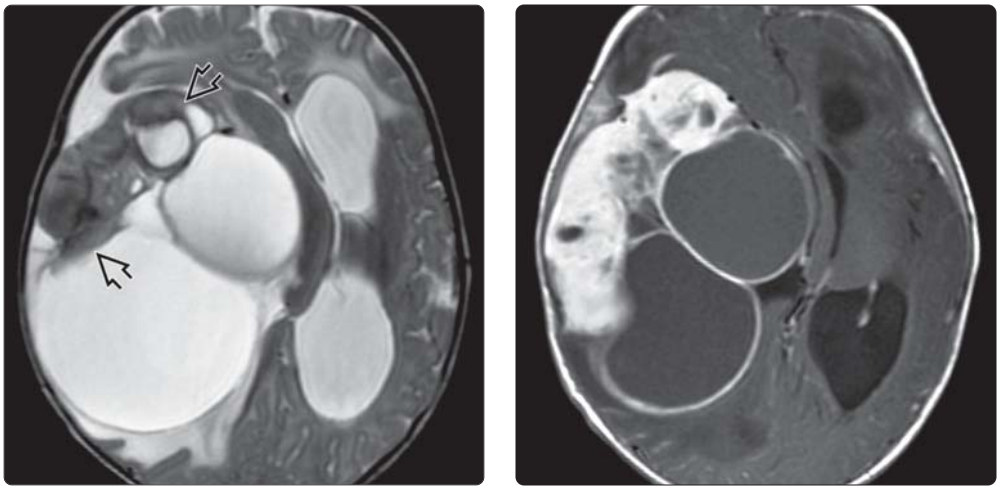

(Left) *Axial T2WI MR shows a large multicystic and solid mass of the right hemisphere. The cortically based T2 hypointense solid portion* ⇨ *is typical of DIG/DIA.* **(Right)** *Axial T1WI C+ MR in the same patient shows marked enhancement of the solid elements with mild cyst wall enhancement. DIA and DIG presents in infants as large tumors, often approaching 13 cm. Macrocephaly with seizures are the most common presenting features.*

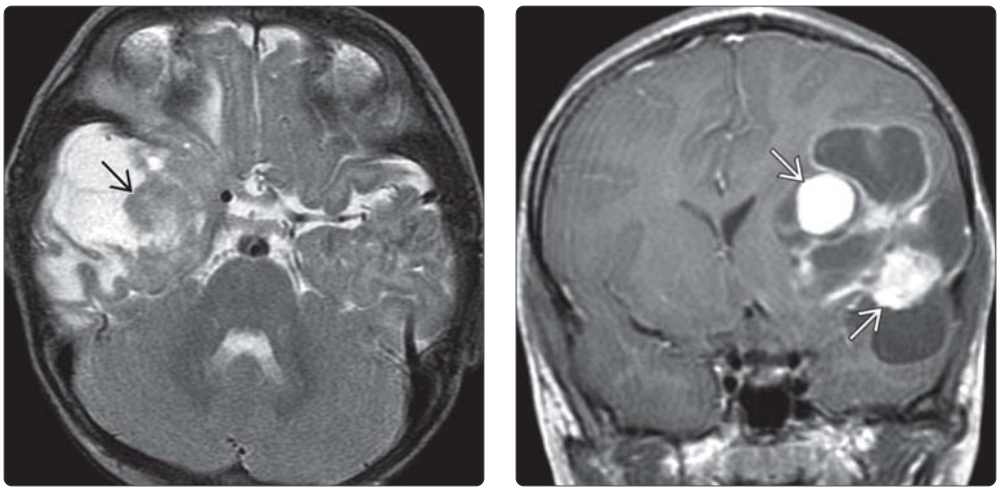

(Left) *Axial T2WI MR shows a heterogeneous cystic and solid mass with a hypointense cortically based* ⇨ *medial solid portion. Diagnosis was DIA/DIG.* **(Right)** *Coronal T1WI C+ MR shows a heterogeneous cystic and solid frontal mass with marked enhancement of the multiple solid nodules* ⇨. *Typically, the solid portion is peripheral and dural-based in DIA/DIG. These WHO grade I tumors are important to recognize, as the initial pathology may suggest a more malignant tumor.*

https://CafePezeshki.IR

KEY FACTS

TERMINOLOGY

- Dysembryoplastic neuroepithelial tumor (DNET)
  - Benign mixed glial-neuronal neoplasm
  - Frequently associated with cortical dysplasia

IMAGING

- May occur in any region of supratentorial cortex
  - Temporal lobe most common, followed by frontal lobe
  - Mass frequently "points" toward ventricle
- Sharply demarcated, wedge shaped
  - Cystic ("bubbly") intracortical mass
  - Minimal/no mass effect
  - No surrounding edema
- Slow growth over years
- Usually does not enhance
- Faint focal punctate or ring enhancement in 20-30%
  - Higher rate of recurrence if enhancement

TOP DIFFERENTIAL DIAGNOSES

- Focal cortical dysplasia type II (Taylor type)
- Neuroepithelial cyst
- Ganglioglioma
- Pleomorphic xanthoastrocytoma (PXA)
- Angiocentric glioma (a.k.a. ANET)

PATHOLOGY

- WHO grade I
- Hallmark = specific glioneuronal element (SGNE)

CLINICAL ISSUES

- Longstanding drug-resistant partial complex seizures in child/young adult
- Surgical resection usually curative
- Histology usually remains benign even if tumor recurs, enhances

(Left) *Coronal oblique graphic shows the typical appearance of a cystic cortical DNET. The gyrus is expanded by the multicystic-appearing tumor. DNETs typically present in children or young adults with seizures.* **(Right)** *Sagittal T1 MR image in a young adult with seizures shows the characteristic "bubbly" appearance of a DNET. Note the low T1 signal within the wedge-shaped cortical mass ➡. These WHO grade I neoplasms have an excellent prognosis with surgical resection.*

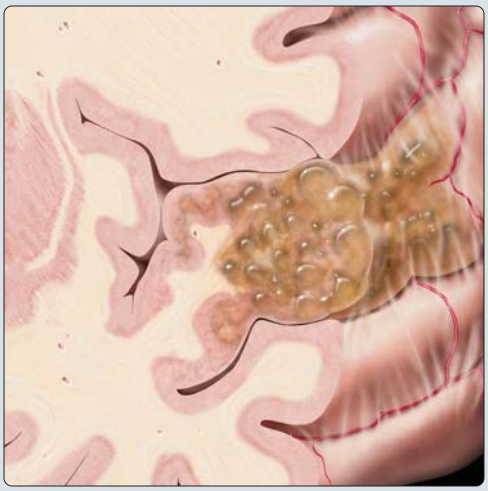

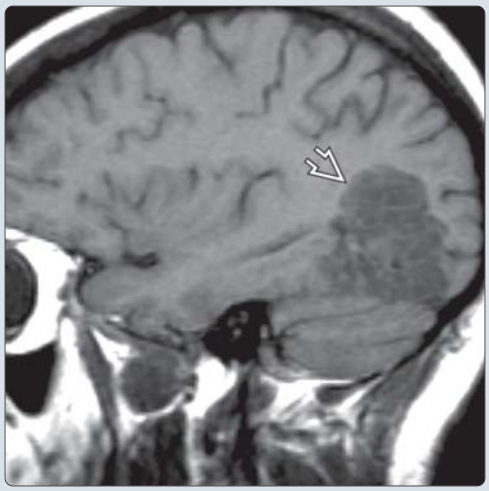

(Left) *Axial T2WI MR shows a multilobular, wedge-shaped cystic cortically based mass ➡ in the right posterior frontal lobe. Note the lack of edema and mass effect, given the size of the tumor, which is typical of a DNET.* **(Right)** *Axial FLAIR MR image in the same patient shows the characteristic appearance of a DNET. Note the cortically based, sharply demarcated, wedge-shaped mass with a hyperintense rim ➡. The tumor points toward the ventricle, and there is no surrounding edema.*

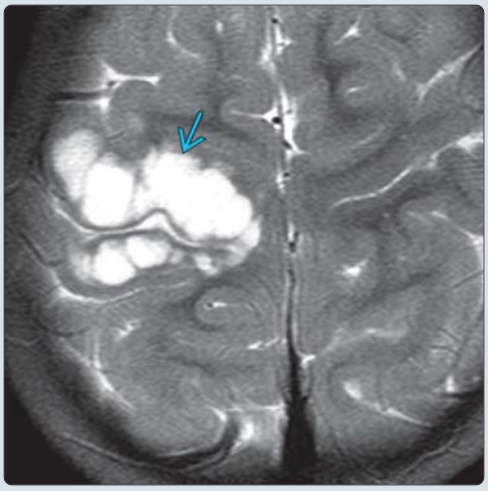

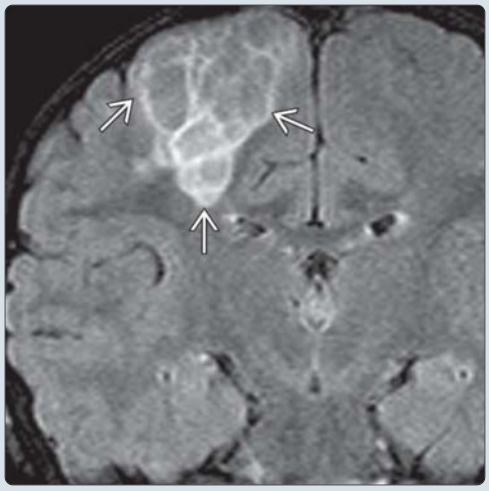

https://CafePezeshki.IR

TERMINOLOGY

Abbreviations

- Dysembryoplastic neuroepithelial tumor (DNET)

Synonyms

- Mixed glial-neuronal neoplasm

Definitions

- Benign, highly epileptogenic tumor frequently associated with cortical dysplasia

IMAGING

General Features

- Best diagnostic clue
  - Demarcated, wedge-shaped/ovoid, cystic/multicystic cortical mass in young patients with longstanding partial complex seizures
- Location
  - May occur in any region of supratentorial cortex
    - Temporal lobe is most common (45-68%)
      - Often amygdala/hippocampus
    - Frontal lobe is also common (1/3 of cases)
    - Basal ganglia, septum pellucidum are less frequent sites
  - Cortical mass frequently "points" toward ventricle
- Size
  - Variable: Small (involving part of gyrus)
  - Large (several cm) lesions involving large portion of lobe have been reported
- Morphology
  - Circumscribed, wedge shaped, cystic
  - Minimal or no mass effect relative to size of lesion
  - No associated surrounding edema
  - Slow growth over many years
    - May remodel overlying bone

CT Findings

- NECT
  - Wedge shaped/ovoid
    - Cortical/subcortical
    - Scalloped inner table in 44-60%
  - Low density
    - May resemble stroke on initial CT
      - **But** no temporal evolution to atrophy
  - Calcification in 20-36%
- CECT
  - Usually nonenhancing
  - Faint nodular or patchy enhancement in 20%
    - Higher incidence of recurrence if enhancement
- CTA
  - Avascular CTA, MRA, conventional angiography

MR Findings

- T1WI
  - Multilobular, hypointense "bubbly" mass
    - Cortex; may extend into subcortical WM and (rarely) basal ganglia
- T2WI
  - Multilobular or septated appearance
  - Very hyperintense on T2
  - "Pseudocystic" or multicystic appearance
    - True cysts uncommon
- PD/intermediate
  - Hyperintense rim
- FLAIR
  - Variable
    - Mixed hypo-/isointense signal
    - Well-defined, complete or incomplete, hyperintense ring(s) surrounding mass
  - No peritumoral edema
- T2* GRE
  - Bleeding into DNET is uncommon but does occur
    - Possibly in association with microvascular abnormalities
    - May simulate cavernoma
- DWI
  - High diffusivity
- T1WI C+
  - Usually does not enhance
  - Focal punctate or ring enhancement in up to 30%
- MRS
  - Nonspecific, but lactate present in some
  - Often spectroscopy is normal

Nuclear Medicine Findings

- PET
  - FDG-18 PET demonstrates glucose hypometabolism
  - Lower 11C-methionine (MET) uptake in DNET than in ganglioglioma or gliomas
- Tc-99m-HMPAO SPECT
  - Ictal may show hyperperfusion
  - Interictal hypoperfusion typical

Imaging Recommendations

- Best imaging tool
  - MR with T1WI C+, FLAIR ± MRS

DIFFERENTIAL DIAGNOSIS

Focal Cortical Dysplasia Type II

- Single tuberous sclerosis-like cortical lesion
- Expands single gyrus
- Looks like tuber, nonenhancing

Neuroepithelial Cyst

- Nonenhancing single or complex cystic structure
- No bright rim on FLAIR

Ganglioglioma

- Ca++ common
- Frequently solid and cystic components
- Solid components avidly enhance

Pleomorphic Xanthoastrocytoma (PXA)

- Enhancing nodule abuts pia
- May have pial enhancement
- Look for dural "tail"

Angiocentric Glioma

- a.k.a. angiocentric neuroepithelial tumor (ANET)
- Rare superficial cortical lesion, usually frontoparietal
- Child/young adult with longstanding epilepsy

https://CafePezeshki.IR

PATHOLOGY

General Features

- Etiology
  - Embryology: Likely dysplastic cells in germinal matrix
  - Extend along migratory path of neurons toward cortex
  - Associated with cortical dysplasia
  - Contain gelatinous cysts
- Genetics
  - Sporadic
  - Nonneoplastic focal cortical dysplasias may be syndrome related
  - Reported cases with NF1; most are sporadic

Staging, Grading, & Classification

- WHO grade I

Gross Pathologic & Surgical Features

- Neocortical lesion
- Thick gyrus
- Glioneuronal component of tumor is viscous in consistency
- Firm nodules represent more stromal components

Microscopic Features

- Hallmark = specific glioneuronal element (SGNE)
  - Characterized by columns of bundled axons oriented perpendicular to cortex
  - Columns lined by oligodendroglia-like cells
  - Other cells show astrocytic, neuronal differentiation
- Several histological types
  - Complex form
    - Multinodular architecture
    - Mixed cellular composition
    - Foci of cortical disorganization
    - SGNE
  - Simple form with SGNE only
  - 3rd nonspecific form has no SGNE
    - But has same neuroimaging characteristics as complex form
- Microcystic degeneration
  - Neurons "float" in pale, eosinophilic mucoid matrix
- Calcification and leptomeningeal involvement are common
- Adjacent cortical dysplasia is common
- Low proliferative potential with variable MIB-1 index

CLINICAL ISSUES

Presentation

- Most common signs/symptoms
  - Partial complex seizures
- Clinical profile
  - Longstanding frequently drug-resistant partial complex seizures in child or young adult

Demographics

- Age
  - Children and young adults
    - 2nd-3rd decades
    - Majority present by 20 years
- Gender
  - Slight male predominance
- Ethnicity
  - None established
- Epidemiology
  - < 1% of all primary brain tumors
  - ~ 1% of primary neuroepithelial brain tumors in patients < 20 years
  - Represents 0.2% of neuroepithelial tumors in patients > 20 years
  - Reported in 5-80% of epilepsy specimens

Natural History & Prognosis

- Benign lesions
  - Rare malignant transformation or spinal drop metastases
- No to very slow increase in size over time
- Rare recurrence
  - Beware of atypical features (enhancement) on preoperative imaging
  - Malignant transformation described but extremely rare
    - Imaging may look alarming (e.g., new ring-enhancing mass)
    - Histology usually remains benign

Treatment

- Seizures may become intractable
  - Glutamate receptors shown within tumor and margins may explain typical, difficult-to-control seizures
- Surgical resection of epileptogenic foci (may include cortical dysplasia)
- Surgical resection usually curative

DIAGNOSTIC CHECKLIST

Consider

- DNET if T2 hyperintense, "bubbly" cortical mass in child/young adult with longstanding partial complex epilepsy

Image Interpretation Pearls

- Beware of enhancing lesions; they may represent more ominous lesion than DNET

SELECTED REFERENCES

1. Alexander H et al: Progressive dysembryoplastic neuroepithelial tumour. J Clin Neurosci. 22(1):221-4, 2015
2. Ranger A et al: Seizures in children with dysembryoplastic neuroepithelial tumors of the brain-A review of surgical outcomes across several studies. Childs Nerv Syst. ePub, 2015
3. Kim AH et al: Recurrence after gross-total resection of low-grade pediatric brain tumors: the frequency and timing of postoperative imaging. J Neurosurg Pediatr. 14(4):356-64, 2014
4. Yang AI et al: Multifocal dysembryoplastic neuroepithelial tumours associated with refractory epilepsy. Epileptic Disord. 16(3):328-32, 2014
5. Chuang NA et al: Glioblastoma multiforme arising from dysembryoplastic neuroepithelial tumor in a child in the absence of therapy. J Pediatr Hematol Oncol. Epub ahead of print, 2013
6. Daghistani R et al: Atypical characteristics and behavior of dysembryoplastic neuroepithelial tumors. Neuroradiology. 55(2):217-24, 2013
7. Englot DJ et al: Factors associated with seizure freedom in the surgical resection of glioneuronal tumors. Epilepsia. 53(1):51-7, 2012
8. Bird-Lieberman G et al: Diffuse hemispheric dysembryoplastic neuroepithelial tumor: a new radiological variant associated with early-onset severe epilepsy. J Neurosurg Pediatr. 7(4):416-20, 2011
9. Bilginer B et al: Surgery for epilepsy in children with dysembryoplastic neuroepithelial tumor: clinical spectrum, seizure outcome, neuroradiology, and pathology. Childs Nerv Syst. 25(4):485-91, 2009

https://CafePezeshki.IR

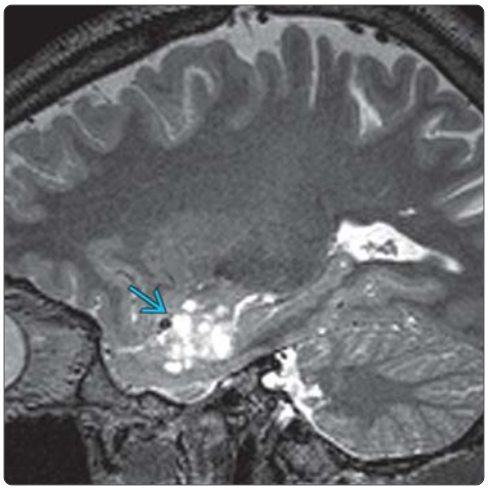

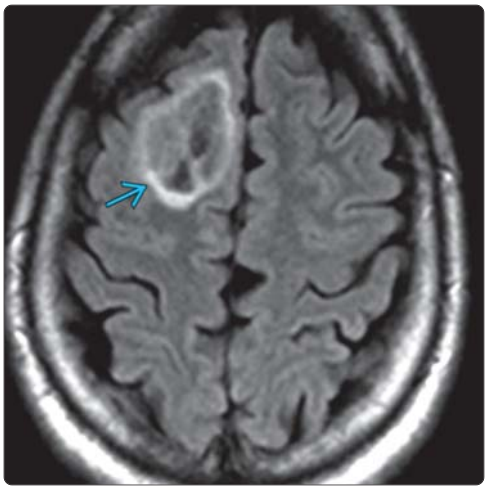

(Left) *Sagittal T2 MR image in a young patient with temporal lobe epilepsy shows the bubbly cortical and subcortical mass ⇨ with no surrounding edema, typical of DNET. Surgical resection is curative in the vast majority of patients.* **(Right)** *Axial FLAIR MR in an older adult shows the classic hyperintense rim ⇨ surrounding the cortically based frontal lobe DNET. This FLAIR hyperintense rim is present in ~ 75% of DNET cases. Lack of peritumoral edema is also characteristic of these WHO I tumors.*

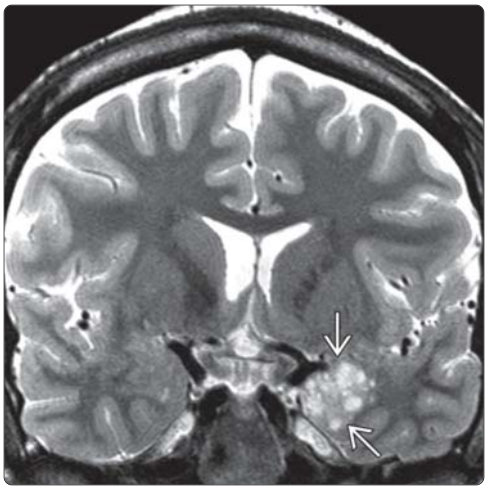

(Left) *Coronal T2WI MR shows a demarcated, "bubbly" mass ⇨ in the medial left temporal lobe. The tumor is heterogeneous with both cystic and more solid areas. There is no associated surrounding edema.* **(Right)** *Coronal T1WI C+ MR in the same patient shows the cortically based mass with cystic areas ⇨. There is no enhancement of the solid portion of the tumor. Enhancement is uncommon in these tumors and is generally nodular or punctate.*

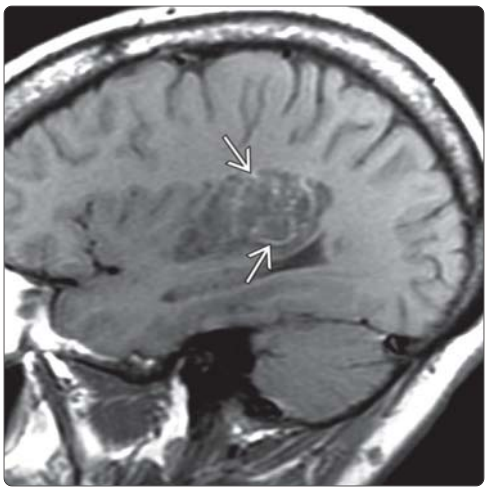

(Left) *Sagittal T1WI MR in a patient with DNET and multiple resections shows a "bubbly," cortically based temporal lobe mass, mostly hypointense and with a few scattered areas of T1 shortening ⇨.* **(Right)** *Sagittal T1WI C+ MR in the same patient shows foci of heterogeneous enhancement ⇨ mostly around the cystic-appearing components. DNETs with atypical features may behave more aggressively. This tumor continued to show benign histology despite multiple recurrences.*

https://CafePezeshki.IR

KEY FACTS

TERMINOLOGY

- Intraventricular neuroepithelial tumor with neuronal differentiation, typically in young adult

IMAGING

- Best diagnostic clue: "Bubbly" mass in frontal horn or body of lateral ventricle
  - May involve 3rd ventricle
- CT: Usually mixed solid and cystic mass with calcification
  - Hydrocephalus common
  - Rarely complicated by hemorrhage
- MR: Heterogeneous, T2 hyperintense, "bubbly" appearance
  - May be a predominantly solid mass
  - Moderate to strong heterogeneous enhancement
- MRS: ↑ Cho, ↓ NAA
  - Glycine peak at 3.55 ppm
- Consider central neurocytoma if "bubbly," "feathery," or solid intraventricular mass near foramen of Monro in young adult

TOP DIFFERENTIAL DIAGNOSES

- Subependymoma
- Subependymal giant cell astrocytoma
- Intraventricular metastasis
- Ependymoma
- Choroid plexus papilloma

CLINICAL ISSUES

- Young adults, commonly 20-40 years of age
- Usually benign, local recurrence is uncommon
  - Surgical resection is typically curative
  - If incomplete resection, radiation therapy, chemotherapy, &/or radiosurgery may be helpful
- 5-year survival rate: 90%
- MIB-1 > 2-3% associated with poorer prognosis
- Headache, increased intracranial pressure, mental status changes, seizure are most common presenting features
  - Hydrocephalus secondary to foramen of Monro obstruction

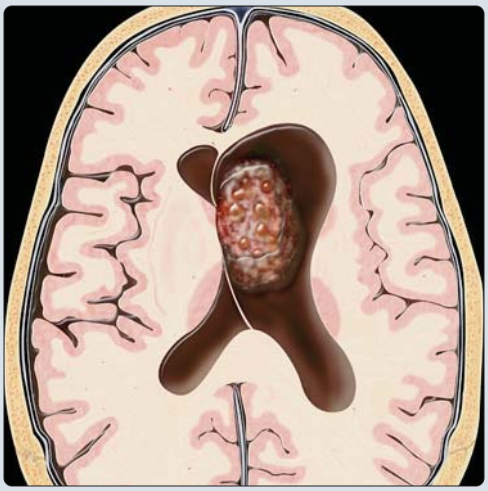

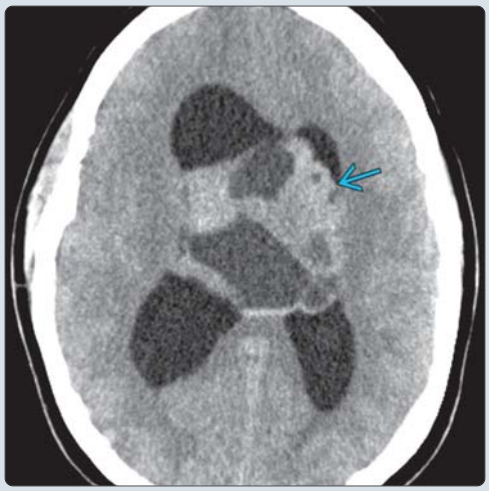

(Left) *Axial graphic shows a circumscribed, lobular, "bubbly" mass attached to the septum pellucidum. Ventricular dilatation is related to foramen of Monro obstruction. This is the classic appearance of a central neurocytoma. Complete surgical resection is often curative for these WHO grade II tumors.* **(Right)** *Axial NECT shows a heterogeneous, cystic, and solid mass in the lateral ventricles attached to the septum pellucidum. There is associated hydrocephalus, typical for central neurocytoma.*

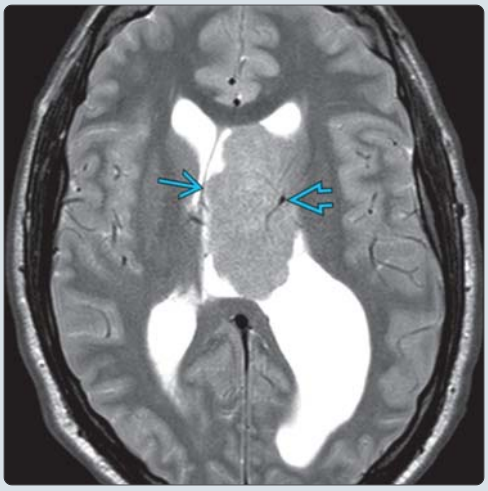

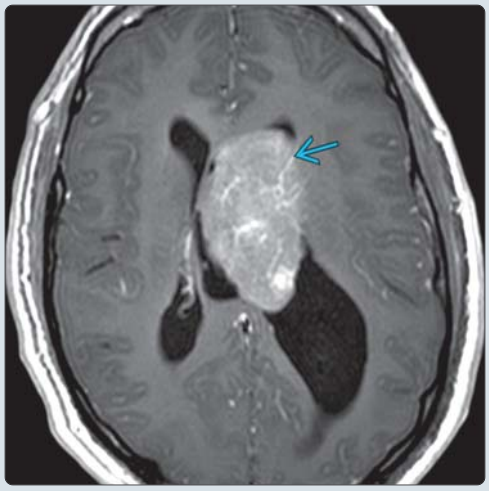

(Left) *Axial T2WI MR in a 20 year old with headaches shows a predominantly solid ventricular mass in the body of the lateral ventricle attached to the septum pellucidum with prominent flow voids.* **(Right)** *Axial T1WI C+ MR in the same patient shows diffuse enhancement. Central neurocytoma was diagnosed at resection. Imaging differential considerations include subependymal giant cell astrocytoma, subependymoma, and meningioma. (Courtesy S. van der Westhuizen, MD.)*

https://CafePezeshki.IR

TERMINOLOGY

Abbreviations

- Central neurocytoma (CN)

Synonyms

- Neurocytoma

Definitions

- Intraventricular neuroepithelial tumor with neuronal differentiation
- Well-demarcated, intraventricular, neurocytic neoplasm located in foramen of Monro region

IMAGING

General Features

- Best diagnostic clue
  - "Bubbly" mass in frontal horn or body of lateral ventricle
- Location
  - Typically supratentorial, intraventricular
  - Intraventricular mass attached to septum pellucidum
    - > 50% in frontal horn/body of lateral ventricle, near foramen of Monro
    - 15% extend into 3rd ventricle
  - Both lateral ventricles: 13%
  - 3rd ventricle only: ~ 5%
  - 4th ventricle: Extremely rare
  - Rare extraventricular tumors with neurocytoma features (extraventricular neurocytoma)
    - Brain parenchyma, cerebellum, brainstem, spinal cord
- Morphology
  - Circumscribed, lobulated mass with intratumoral "cysts"
  - Characteristic bubbly appearance on imaging studies
  - May be predominantly solid

CT Findings

- NECT
  - Usually mixed solid and cystic (iso-/hyperdense)
  - Ca++ common (50-70%)
  - Hydrocephalus common
  - Rarely complicated by hemorrhage
- CECT
  - Moderate heterogeneous enhancement

MR Findings

- T1WI
  - Heterogeneous, mostly isointense to gray matter
  - Cysts are hypointense
  - Prominent flow voids may be seen
  - Hemorrhage is rare
- T2WI
  - Heterogeneous, hyperintense bubbly appearance
  - Associated hydrocephalus is common
  - Ca++ often hypointense
  - Prominent flow voids may be seen
- FLAIR
  - Heterogeneous, predominantly hyperintense mass
- T2* GRE
  - Ca++ seen as areas of "blooming"
- T1WI C+
  - Moderate to strong heterogeneous enhancement
- MRS
  - Elevated Cho peak, decreased NAA typical
  - Glycine peak at 3.55 ppm typical
  - Alanine peak may be seen

Angiographic Findings

- DSA: Variable appearance
  - Avascular mass to marked vascularity

Nuclear Medicine Findings

- PET
  - Typically characterized by decreased metabolism on FDG PET
  - Hypermetabolic activity has been described in atypical central neurocytoma

Imaging Recommendations

- Protocol advice
  - Multiplanar contrast-enhanced MR, + coronal T2

DIFFERENTIAL DIAGNOSIS

Subependymoma

- May be indistinguishable
- Older patients
- Usually faint or no enhancement
- 4th > lateral ventricle

Subependymal Giant Cell Astrocytoma

- Mass at foramen of Monro, Ca++ common
- Look for stigmata of tuberous sclerosis
  - Subependymal nodules, cortical tubers, white matter lesions

Intraventricular Metastasis

- Uncommon, usually older patients
- Primary tumor often known

Ependymoma

- Supratentorial ependymomas rarely intraventricular
- Heterogeneous enhancing mass with edema
- Aggressive features

Choroid Plexus Papilloma

- Typically younger patients, lateral ventricle
- In adults, 4th ventricle
- Intensely enhancing papillary mass, hydrocephalus common

Meningioma

- Circumscribed, intensely enhancing mass
- Typically at trigone of lateral ventricle
- Older patients

Cavernous Malformation

- Rarely intraventricular (up to 11%)
- Ca++, T2-hypointense hemosiderin rim common

Oligodendroglioma

- Typically cortical mass with variable enhancement
- Main histologic differential

https://CafePezeshki.IR

PATHOLOGY

General Features

- Etiology
  - Likely arise from neuroglial or bipotential progenitor cells
- Genetics
  - Chromosomal abnormalities on 7, 2p, 10q, 18q, 13q reported
- Associated abnormalities
  - "Central neurocytoma" describes typical intraventricular tumors
    - Parenchymal invasion is rare, found in more aggressive tumors
  - Central neurocytoma rarely found in association with medulloblastoma

Staging, Grading, & Classification

- WHO grade II
- "Atypical central neurocytoma" (aggressive variant)
  - MIB-1 index > 2%
  - Vascular proliferation

Gross Pathologic & Surgical Features

- Grayish, friable, circumscribed, intraventricular mass
- Moderately vascular, may calcify, hemorrhage rare
- Typically attached to septum pellucidum or lateral ventricular wall

Microscopic Features

- Resembles oligodendroglioma
  - Many central neurocytomas misdiagnosed in past
- Uniform round cells with neuronal differentiation
  - Stippled nuclei, perinuclear halos
- Various architectural patterns (can resemble other neoplasms)
  - Monotonous sheets of cells
  - Perivascular pseudorosettes (ependymoma)
  - Honeycomb appearance (oligodendroglioma)
  - Large fibrillary areas (pineocytoma)
- Benign (low proliferation rate, mitoses rare)
  - MIB-1 usually low (< 2%)
- Anaplasia, necrosis rare
  - May have brisk mitotic activity, MIB-1 > 2-3%
  - Microvascular proliferation
- Synaptophysin and neuron-specific enolase positive; rarely GFAP positive
- Electron microscopy: Finely speckled chromatin, small distinct nucleolus, cell processes with neuritic features (microtubules)

CLINICAL ISSUES

Presentation

- Most common signs/symptoms
  - Headache, increased intracranial pressure, mental status changes, seizure
- Other signs/symptoms
  - Hydrocephalus secondary to foramen of Monro obstruction
  - Tumors of septum, 3rd ventricle, hypothalamus may have visual disturbances, hormonal dysfunction
  - Acute ventricular obstruction and death reported
  - Rarely asymptomatic

Demographics

- Age
  - Young adults, commonly 20-40 years (70%)
  - Range: 1-67 years; mean: 29 years
- Gender
  - No gender predominance
- Epidemiology
  - < 1% of all primary intracranial neoplasms
  - ~ 10% of intraventricular neoplasms
  - Represents 50% of intraventricular tumors in patients 20-40 years

Natural History & Prognosis

- Usually benign, local recurrence is uncommon
  - Surgical resection is typically curative
- Rarely complicated by hemorrhage
- 5-year survival rate: 90%
- MIB-1 > 2-3% associated with poorer prognosis
- Craniospinal dissemination extremely rare
- Tumors with extraventricular extension have poorer clinical outcome

Treatment

- Complete surgical resection is treatment of choice
- If incomplete resection, radiation therapy, chemotherapy, &/or radiosurgery may be helpful
- Radiosurgery may improve local control rates and increase survival

DIAGNOSTIC CHECKLIST

Consider

- Subependymoma and giant cell astrocytoma mimic central neurocytoma, clinical information may help
- May mimic other tumors pathologically, so imaging correlation is important

Image Interpretation Pearls

- Think central neurocytoma if "bubbly," "feathery," intraventricular mass near foramen of Monro in young adult
- Central neurocytoma is typically attached to septum pellucidum

SELECTED REFERENCES

1. Bonney PA et al: Histology and molecular aspects of central neurocytoma. Neurosurg Clin N Am. 26(1):21-9, 2015
2. Choudhri O et al: Atypical and rare variants of central neurocytomas. Neurosurg Clin N Am. 26(1):91-8, 2015
3. Donoho D et al: Imaging of central neurocytomas. Neurosurg Clin N Am. 26(1):11-9, 2015
4. Chen YD et al: Long-term outcomes of adjuvant radiotherapy after surgical resection of central neurocytoma. Radiat Oncol. 9:242, 2014
5. Tlili-Graiess K et al: Diffusion weighted MR imaging and proton MR spectroscopy findings of central neurocytoma with pathological correlation. J Neuroradiol. 41(4):243-50, 2014
6. Kim JW et al: Radiosurgery for central neurocytoma: long-term outcome and failure pattern. J Neurooncol. 115(3):505-11, 2013
7. Patel DM et al: Update on the diagnosis, pathogenesis, and treatment strategies for central neurocytoma. J Clin Neurosci. 20(9):1193-9, 2013

https://CafePezeshki.IR

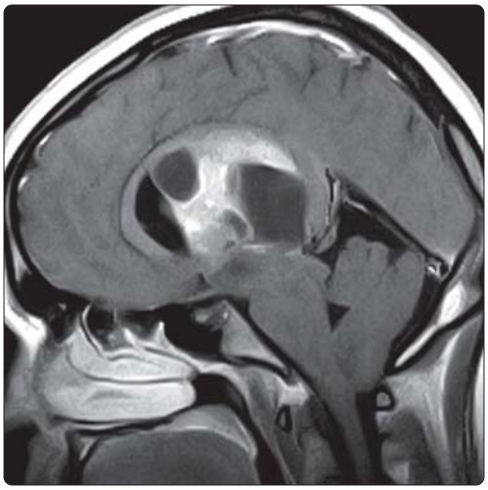

(Left) *Sagittal T1 C+ MR in a 36-year-old woman shows a heterogeneously enhancing cystic and solid intraventricular mass. WHO grade II central neurocytoma was diagnosed at resection. Surgical resection is typically curative of these tumors.* **(Right)** *Axial FLAIR MR shows a heterogeneously hyperintense mass ⇨ in the lateral ventricles. There is associated hydrocephalus, typical for central neurocytoma. (Courtesy M. Michel, MD.)*

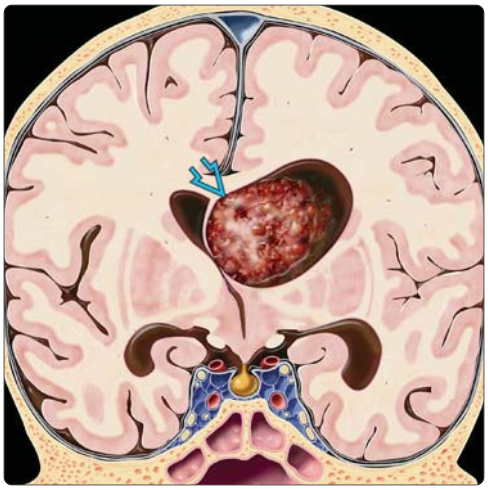

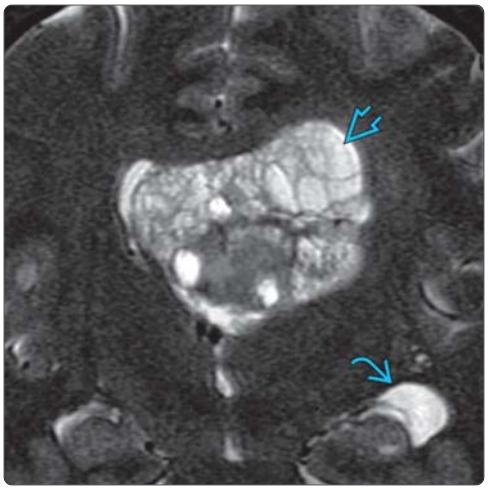

(Left) *Coronal graphic shows a "bubbly," lobular, intraventricular central neurocytoma ⇨ with bowing of the septum pellucidum and associated ventricular dilatation.* **(Right)** *Coronal T2WI MR shows the characteristic bubbly appearance of this lateral ventricle central neurocytoma ⇨ with septum pellucidum bowing and temporal horn dilatation ⇨. Strong heterogeneous enhancement is typical. These tumors typically present in young adults between 20 and 40 years old.*

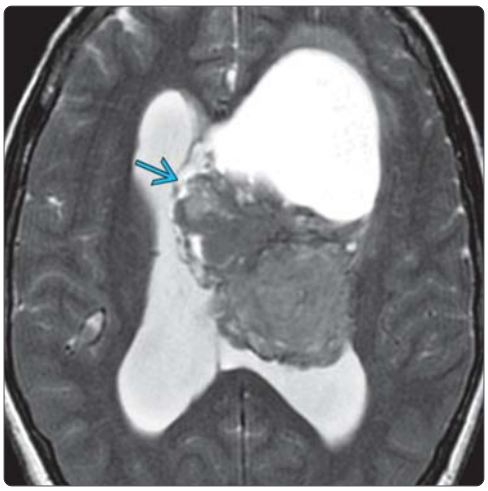

(Left) *Axial T2WI MR shows a heterogeneous, "bubbly" lateral ventricular mass with attachment to the septum pellucidum ⇨ and hydrocephalus, typical for central neurocytoma.* **(Right)** *Axial T1WI C+ MR in the same patient shows marked enhancement of the lobular mass with a large cyst filling the frontal horn. The imaging features of subependymoma and subependymal giant cell astrocytoma may mimic a central neurocytoma. Clinical features can help differentiate.*

https://CafePezeshki.IR

KEY FACTS

TERMINOLOGY

- Neuroepithelial tumor located outside ventricular system, commonly in brain parenchyma

IMAGING

- Best diagnostic clue: Well-circumscribed, enhancing, cystic and solid parenchymal mass in young adult
- Majority are supratentorial involving cerebral hemispheres
  - Frontal and parietal lobes most common
  - Deep gray nuclei less common
- Ca++ in 10-15%
- T2 MR: Heterogeneously hyperintense mass
- T2* GRE: May show "blooming" related to blood products or Ca++
- T1WI C+: Variable enhancement of solid portions
  - May have cyst with mural nodule appearance

TOP DIFFERENTIAL DIAGNOSES

- Oligodendroglioma
- Pilocytic astrocytoma
- Ganglioglioma
- DNET
- Glioblastoma

PATHOLOGY

- WHO grade II
- May be identical to central neurocytoma
  - Often contain ganglion cells or ganglioid cells

CLINICAL ISSUES

- Seizures, headaches, hemiparesis are most common presenting features
- Occur in children and young adults (median: 34 years)
- Rare: < 0.5% of primary CNS tumors
- Surgical resection is typically curative
- Subtotal resection, atypical histologic features, and high cell proliferation rates correlate with recurrence

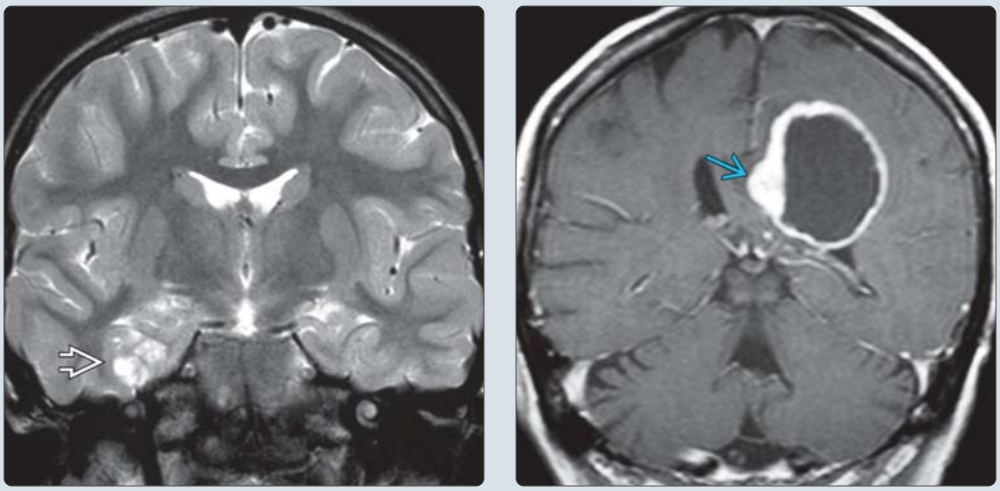

(Left) *Coronal T2WI MR shows a heterogeneously hyperintense superficial temporal lobe mass. The bubbly appearance mimics a DNET, but this proved to be an extraventricular neurocytoma. (Courtesy A. Rossi, MD.)* **(Right)** *Coronal T1WI C+ MR in a 61-year-old woman with weakness shows a peripherally nodular enhancing parietal lobe mass. Extraventricular neurocytoma was diagnosed at histopathology. (Courtesy J. Boxerman, MD.)*

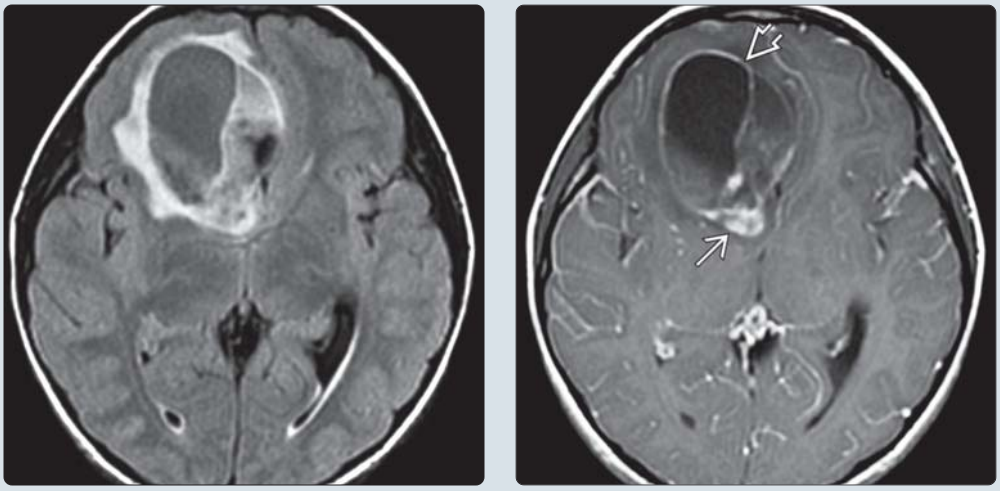

(Left) *Axial FLAIR MR shows a cystic and solid mass in the frontal lobe with mild surrounding vasogenic edema. (Courtesy N. Fischbein, MD.)* **(Right)** *Axial T1WI C+ MR in the same patient shows heterogeneous enhancement of the solid portion and rim enhancement of the cystic portion. The lack of significant vasogenic edema is typical for extraventricular neurocytoma. Imaging differential considerations include oligodendroglioma, astrocytoma, and ganglioglioma. (Courtesy N. Fischbein, MD.)*

https://CafePezeshki.IR

TERMINOLOGY

Abbreviations

- Extraventricular neurocytoma (EVN)

Definitions

- Neuroepithelial tumor located outside of ventricular system, commonly in brain parenchyma

IMAGING

General Features

- Best diagnostic clue
  - Well-circumscribed, enhancing, cystic and solid parenchymal mass in young adult
- Location
  - Majority are supratentorial involving cerebral hemispheres
    - Frontal and parietal lobes most common
    - Deep gray nuclei less common
  - Cerebellum and brainstem rare
  - Sella, pineal region, spinal cord reported
- Morphology
  - Cystic and solid masses
  - May have cyst with mural nodule appearance

Imaging Recommendations

- Protocol advice
  - Contrast-enhanced MR with GRE, ± MRS

CT Findings

- NECT
  - Circumscribed, complex, cystic and solid mass
  - Ca++ in 10-15%
  - Vasogenic edema variable

MR Findings

- T1WI: Cystic, heterogeneously solid mass
  - Usually involve deep white matter (WM), may involve cortex
- T2WI: Heterogeneously hyperintense mass
  - Mild vasogenic edema typical
- T2* GRE: May show "blooming" related to blood products or Ca++
- T1WI C+: Variable enhancement of solid portions
  - May see cyst and mural nodule
- MRS: ↓ NAA and ↑ choline (Cho)

DIFFERENTIAL DIAGNOSIS

Oligodendroglioma

- Calcified, heterogeneous mass
- Variable enhancement

Pilocytic Astrocytoma

- Solid-cystic or solid enhancing mass
- Typically posterior fossa or chiasmatic/hypothalamic

Ganglioglioma

- Enhancing cystic and solid, cortically based mass in child or young adult
- Temporal lobe commonly > parietal, frontal

DNET

- Cortical "bubbly" mass in young adult

Glioblastoma

- Heterogeneous mass with central necrosis
- Typically older patients

PATHOLOGY

General Features

- Etiology
  - May arise from neuroglial precursor cells
- Associated abnormalities
  - Single case reported in patient with neurofibromatosis type 1

Staging, Grading, & Classification

- WHO grade II

Gross Pathologic & Surgical Features

- Cysts, necrosis, Ca++ may be seen
- Hemorrhage rare

Microscopic Features

- May be identical to central neurocytoma
  - Densely cellular, cytologically monomorphous
- Often contain ganglion cells or ganglioid cells
- Hyalinized vessels and dense Ca++ common
- Synaptophysin positive, often GFAP positive

CLINICAL ISSUES

Presentation

- Most common signs: Seizures, headaches, hemiparesis

Demographics

- Age
  - Typically children, young adults (median: 34 years)
- Gender
  - No gender predominance
- Epidemiology
  - Rare: < 0.5% of primary CNS tumors

Natural History & Prognosis

- Surgical resection is typically curative
- Subtotal resection, atypical histologic features, and high cell proliferation rates correlate with recurrence

Treatment

- Surgical resection ± adjuvant therapy
- Radiation therapy in recurrent tumors

SELECTED REFERENCES

1. Sweiss FB et al: Extraventricular neurocytomas. Neurosurg Clin N Am. 26(1):99-104, 2015
2. Kawaji H et al: Extraventricular neurocytoma of the sellar region with spinal dissemination. Brain Tumor Pathol. 31(1):51-6, 2014
3. Nabavizadeh SA et al: Extraventricular neurocytoma and ganglioneurocytoma: advanced MR imaging, histopathological, and chromosomal findings. J Neuroimaging. 24(6):613-6, 2014
4. Huang WY et al: Computed tomography and magnetic resonance features of extraventricular neurocytoma: a study of eight cases. Clin Radiol. 68(4):e206-12, 2013
5. Liu K et al: MR imaging of cerebral extraventricular neurocytoma: a report of 9 cases. AJNR Am J Neuroradiol. 34(3):541-6, 2013

https://CafePezeshki.IR

KEY FACTS

TERMINOLOGY

- Cerebellar liponeurocytoma (CLN)
- Rare cerebellar parenchymal neoplasm of adults
  - Consistent neuronal, variable astrocytic and lipomatous elements

IMAGING

- CT
  - Hypodense (fat density)
- MR
  - Hyperintense on T1WI
  - Inhomogeneously hyperintense on T2WI
  - Lipomatous component suppresses with fat saturation
  - Heterogeneous enhancement

TOP DIFFERENTIAL DIAGNOSES

- Medulloblastoma with lipidized cells
- Teratoma
- Anaplastic oligodendroglioma
- Ependymoma

PATHOLOGY

- *TP53* missense mutations
- WHO grade II
- Moderate to low mitotic index
  - MIB-1 mean: 2.5%

CLINICAL ISSUES

- Headache is most common presenting symptom
  - More focal cerebellar symptoms depending on location
- Age range: 24-77 years; mean: 50 years
- M = F
- ~ 2/3 recur after resection within 1-12 years
  - 5-year survival: 48%
- Consider cerebellar liponeurocytoma in fat-containing cerebellar mass in adult

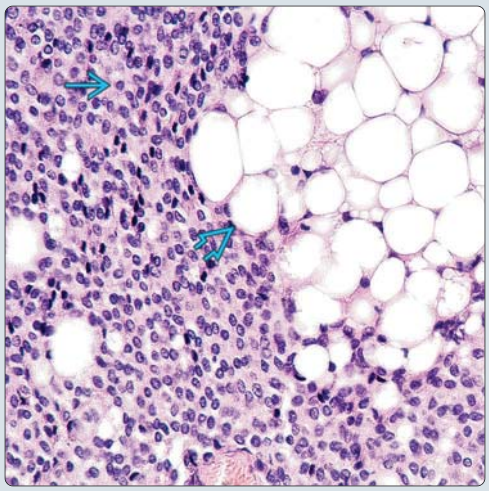

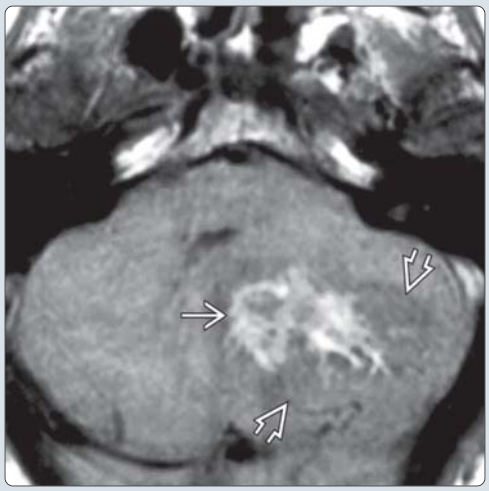

(Left) *The principal components of a cerebellar liponeurocytoma include classic neurocytes ⇨ and distinctive, variably lipidized cells ⇨ resembling adipose tissue. (From DP: Neuro.)* **(Right)** *Precontrast axial T1 MR image shows irregular areas of high signal intensity ➡ within a left cerebellar mass due to areas of fatty tissue that cause T1 shortening. The majority of the mass is isointense with poorly defined borders ➡. (Courtesy AFIP.)*

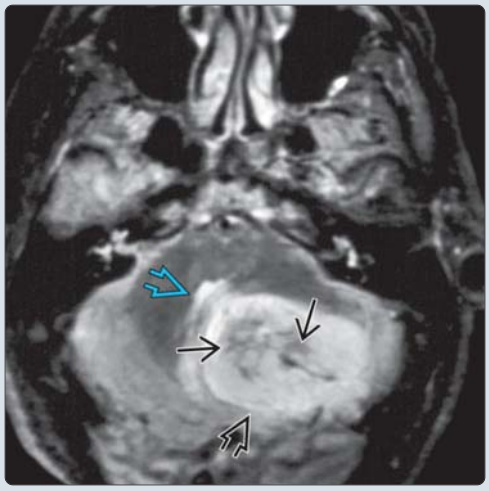

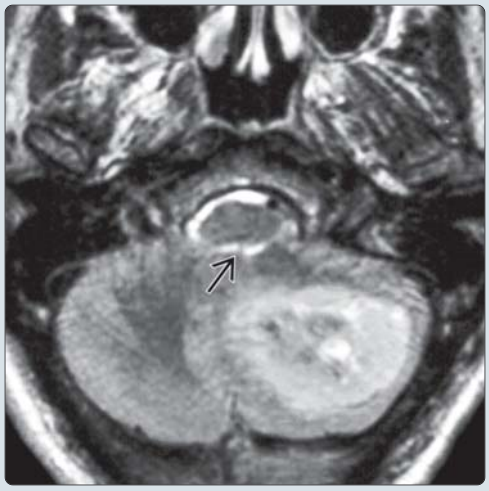

(Left) *Axial T2 MR image in the same patient shows the left cerebellar mass as a discrete lesion with the fatty component ⇨ slightly hypointense compared to the larger, more cellular, nonfatty, hyperintense portion of the tumor ⇨. Note the significant mass effect upon the 4th ventricle ⇨. (Courtesy AFIP.)* **(Right)** *Axial T2 MR image shows the mass effect from the tumor significantly effacing the inferior 4th ventricle ⇨ resulting in the supratentorial hydrocephalus. (Courtesy AFIP.)*

https://CafePezeshki.IR

KEY FACTS

TERMINOLOGY

- Indolent glioneuronal tumor
  - Previously considered ganglioglioma subtype
  - Also described as pseudopapillary neurocytoma with glial differentiation

IMAGING

- General features
  - Cerebral hemispheres most common site
    - Temporal lobe predilection
  - Parenchymal mass with solid, cystic, or cyst/mural nodule architecture
- CT
  - Partially calcified mass ± cystic regions
- MR
  - Isointense ± hypointense cysts on T1WI
  - Inhomogeneously hyperintense on T2WI
  - Inhomogeneously hyperintense nodule on FLAIR (cyst may suppress)
  - Strong, heterogeneous enhancement on T1WI C+
- Imaging may be indistinguishable from ganglioglioma

TOP DIFFERENTIAL DIAGNOSES

- Ganglioglioma
- Oligodendroglioma
- Neurocysticercosis
- Ependymoma

PATHOLOGY

- "Biphasic" neurocytic, glial components
- WHO grade I with low MIB-1 index (1-2%)

CLINICAL ISSUES

- Seizures, headache most common symptoms
- Affects children, young adults (range: 4-75 years)
- Potentially curable with complete resection
- Generally indolent course although aggressive papillary glioneuronal tumors reported

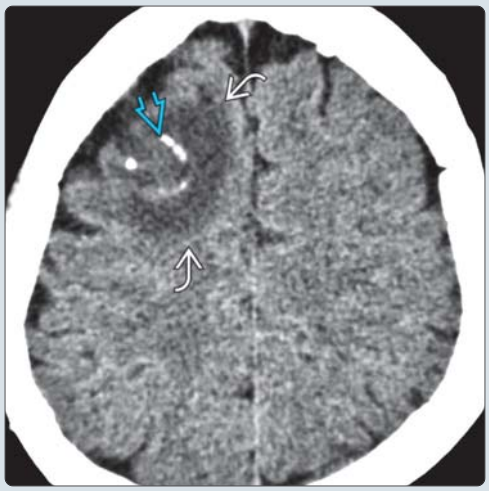

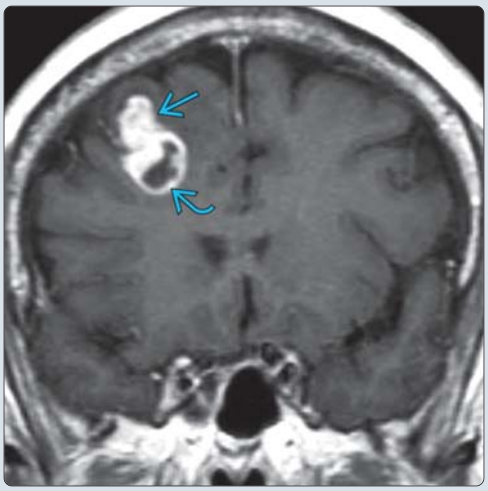

(Left) *Axial NECT in a recently arrived immigrant with seizures shows a right frontal mass with incomplete ring calcification and moderate perilesional edema. The imaging differential diagnosis includes both neoplasm and parasitic infection.* **(Right)** *Coronal T1WI C+ MR in the same patient shows an intensely, but heterogeneously, enhancing mass with a larger cystic area with rim enhancement. Stereotaxic biopsy disclosed a papillary glioneuronal tumor.*

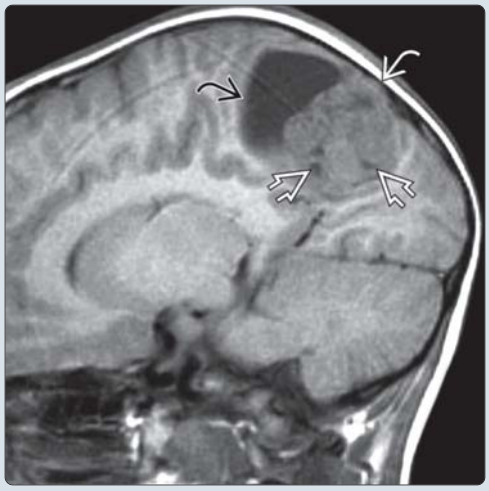

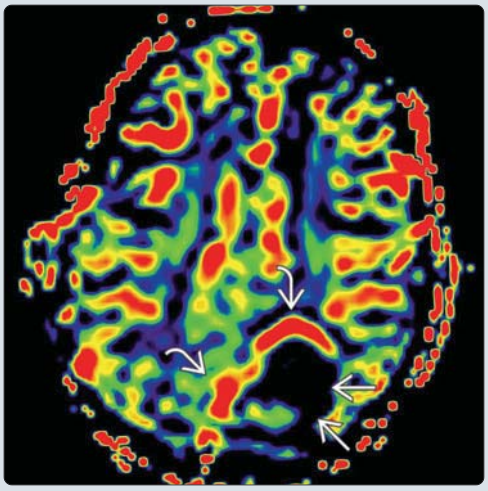

(Left) *Sagittal T1WI MR in an 8-year-old boy with seizures shows a solid and cystic parietal lobe mass. The solid component shows lobulations with some intratumoral cystic-appearing spaces. PGNT are most common in the temporal lobes. (Courtesy M. Castillo, MD.)* **(Right)** *Axial perfusion MR in the same patient shows a parietal lobe mass with relatively decreased perfusion surrounded by a rim of relatively increased perfusion. Papillary glioneuronal tumor was found at surgery. (Courtesy M. Castillo, MD.)*

https://CafePezeshki.IR

KEY FACTS

TERMINOLOGY

- Rosette-forming glioneuronal tumor (RGNT)
- Rare, slowly growing benign tumor of young adults
  - 4th ventricle most common site > cerebellum
  - Rarely in pineal region, cerebellopontine angle, brain hemispheres

IMAGING

- Midline cerebellar neoplasm
  - Mixed solid-cystic appearance
  - Variable Ca++, hemorrhage
  - Hyperintense on T2WI
- Variable enhancement

TOP DIFFERENTIAL DIAGNOSES

- Ependymoma
- Medulloblastoma (PNET-MB)
- Pilocytic astrocytoma
- Metastases

PATHOLOGY

- WHO grade I
- 2 components
  - Neurocytic: Neurocytes forming neurocytic/perivascular pseudorosette
  - Astrocytic: Resembles pilocytic astrocytoma

CLINICAL ISSUES

- Young/middle-aged adults
- Headache (60% associated hydrocephalus) and ataxia are common presenting symptoms
- Benign, no malignant transformation
  - CSF dissemination into ventricular system has been reported

DIAGNOSTIC CHECKLIST

- Suspect RGNT when young adult presents with well-circumscribed 4th ventricle mass with combined cystic-nodule appearance, no edema

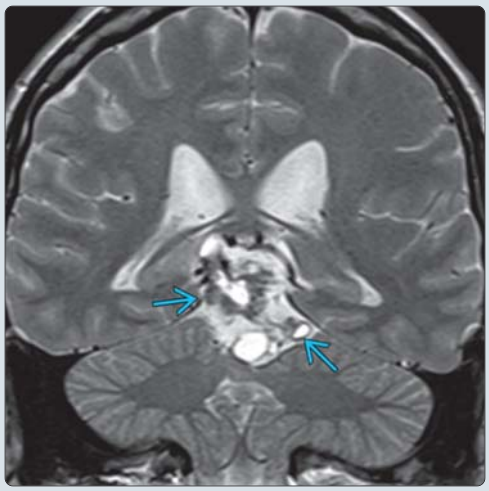

(Left) *Sagittal T1WI MR in a young adult with headaches shows a mixed signal intensity mass filling the 4th ventricle. Foci of T1 shortening represent hemorrhage. No enhancement was seen on T1WI C+ scans. Pathology showed a RGNT.* **(Right)** *Coronal T2 MR in a 31-year-old man with headaches shows a heterogeneous pineal region mass with mass effect but no surrounding edema. RGNT was diagnosed at resection. These tumors are most commonly in the posterior fossa, within the 4th ventricle or cerebellar vermis.*

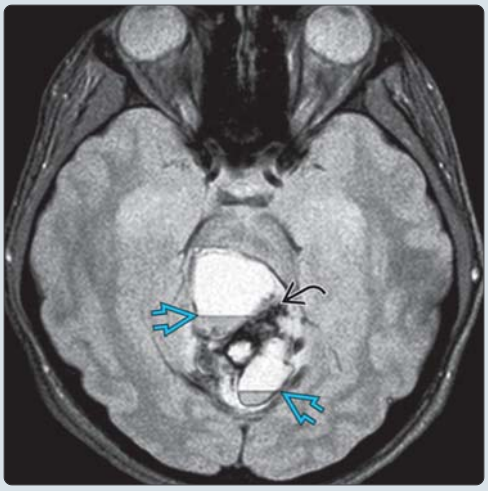

(Left) *Axial T2* GRE MR in a patient with headaches and papilledema on physical examination demonstrates a large, multicystic midline mass in the posterior fossa. Note the fluid-fluid levels and regions of low signal intensities representing calcifications.* **(Right)** *Axial T1WI C+ in the same patient shows mild heterogeneous enhancement of the 4th ventricle mass. Note the dilated optic nerve sheaths and elevated optic discs from papilledema. A RGNT was found at surgery.*

https://CafePezeshki.IR

TERMINOLOGY

Abbreviations

- Rosette-forming glioneuronal tumor (RGNT)

Synonyms

- 1st described as dysembryoplastic neuroepithelial tumor (DNT) of cerebellum
- Also formerly called cerebellar DNT

Definitions

- Rare, slowly growing benign tumor
  - 4th ventricle most common (sometimes called RGNT of 4th ventricle)

IMAGING

General Features

- Best diagnostic clue
  - Midline cerebellar mass with solid-cystic appearance without edema in young/middle-aged adult
- Location
  - Majority in cerebellar midline around 4th ventricle (posterior fossa)
  - Rarely in pineal region, cerebellopontine angle, brain hemispheres
- Size
  - Varies between 1.5 and 10 cm

Imaging Recommendations

- Best imaging tool
  - MR with T1WI C+, T2* (hemorrhage, Ca++)

CT Findings

- NECT
  - Midline posterior fossa cystic/solid mass
  - Variable Ca++, hemorrhage

MR Findings

- T1WI
  - Iso-/hypointense mass
- T2WI
  - Hyperintense, heterogeneous
- T2* GRE
  - Hemorrhage common
- T1WI C+
  - Variable enhancement (none to heterogeneous)

DIFFERENTIAL DIAGNOSIS

Ependymoma

- Usually tumor of childhood
- "Squeezes" out through lateral recesses
- Strong but heterogeneous enhancement

Medulloblastoma (PNET-MB)

- Children > adults
- Typically strong enhancement
- Gross hemorrhage, cyst formation less common

Pilocytic Astrocytoma (PA)

- Children > adults
- Cyst with nodule appearance
  - Nodule enhances strongly
  - If cyst wall enhances, may resemble RGNT

Metastases

- Older adult > young adult
- Primary tumor often known

PATHOLOGY

General Features

- Etiology
  - Derives from pluripotential cells of subependymal plate

Staging, Grading, & Classification

- WHO grade I

Gross Pathologic & Surgical Features

- Cystic/nodular appearance

Microscopic Features

- 2 components
  - Neurocytic: Neurocytes forming neurocytic/perivascular pseudorosette
  - Astrocytic: Resembles pilocytic astrocytoma

CLINICAL ISSUES

Presentation

- Most common signs/symptoms
  - Headache, ataxia
- Other signs/symptoms
  - Nausea, vertigo
  - 60% of patients present with obstructive hydrocephalus

Demographics

- Age
  - Young/middle-aged adults
    - Mean: ~ 30 years old
- Gender
  - M:F = 1:2

Natural History & Prognosis

- Benign; no malignant transformation

Treatment

- Surgical removal, ± adjuvant therapy

DIAGNOSTIC CHECKLIST

Consider

- Suspect RGNT when young adult presents with well-circumscribed 4th ventricle mass with combined cystic-nodule appearance, no edema

SELECTED REFERENCES

1. Allinson KS et al: Rosette-forming glioneuronal tumor with dissemination throughout the ventricular system: a case report. Clin Neuropathol. 34(2):64-9, 2015
2. Smith AB et al: From the radiologic pathology archives: intraventricular neoplasms: radiologic-pathologic correlation. Radiographics. 33(1):21-43, 2013
3. Zhang J et al: A comprehensive analysis of 41 patients with rosette-forming glioneuronal tumors of the fourth ventricle. J Clin Neurosci. 20(3):335-41, 2013

https://CafePezeshki.IR

Pineocytoma

KEY FACTS

TERMINOLOGY

- Pineocytoma (PC), pineal parenchymal tumor (PPT)
- PCs are composed of small, uniform, mature cells
  - Cells resemble pineocytes

IMAGING

- General features: Circumscribed, enhancing pineal mass
  - May mimic benign pineal cyst or pineal parenchymal tumor of intermediate differentiation (PPTID)
  - Typically < 3 cm
  - May compress adjacent structures
  - Rarely extends into 3rd ventricle, rarely invasive
  - Can compress aqueduct → hydrocephalus
- CT
  - Circumscribed iso-/hypodense pineal region mass
  - Peripheral ("exploded") Ca++ common
  - CECT: Enhances (solid, ring, nodular)
- MR (most sensitive)
  - Cystic change may be present
  - Enhancement may be solid or peripheral

TOP DIFFERENTIAL DIAGNOSES

- Nonneoplastic pineal cyst
- PPTID
- Pineoblastoma
- Germinoma, other germ cell tumors

CLINICAL ISSUES

- Headache, Parinaud syndrome (paralysis of upward gaze) are most common features
- Increased intracranial pressure, ataxia, hydrocephalus, mental status changes may occur
- Most common in adults, mean 40 years
- Stable- or slow-growing tumor
- Germ cell markers (α-fetoprotein, hCG) absent
- Surgical excision or stereotactic biopsy is primary treatment
  - Complete surgical resection generally curative

(Left) *Sagittal graphic shows a cystic pineal gland mass with a fluid-fluid level and nodular tumor along the periphery of the mass, typical of pineocytoma. No significant mass effect is present. Pituicytomas may be found incidentally or present with hydrocephalus.* **(Right)** *Axial NECT shows a classic example of a pineocytoma. Note the "exploded" peripheral calcification in this small mass that arises from the pineal region. The tumor is just over 1 cm in size. There is no hydrocephalus.*

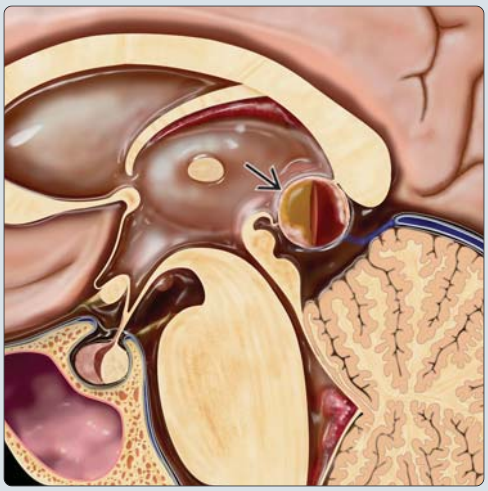

(Left) *Sagittal T1 MR image of a 50-year-old woman with headache shows a cystic pineal region mass with associated ventriculomegaly and local mass effect on the tectum. Mass effect on the superior tectum often results in Parinaud syndrome, paralysis of upward gaze.* **(Right)** *Axial FLAIR MR in the same patient shows the hyperintense, lobular pineal region mass with associated ventriculomegaly. Pineocytoma was diagnosed at resection. These WHO grade I tumors are often stable for years.*

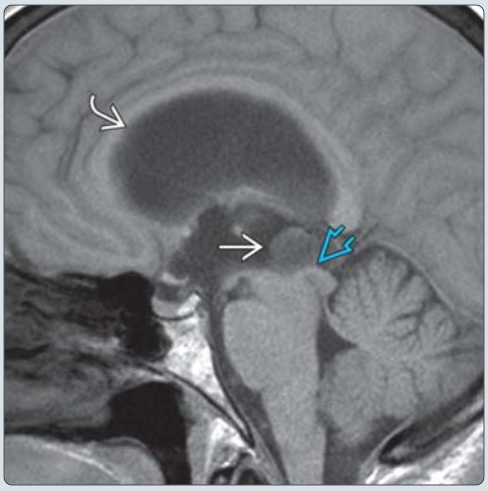

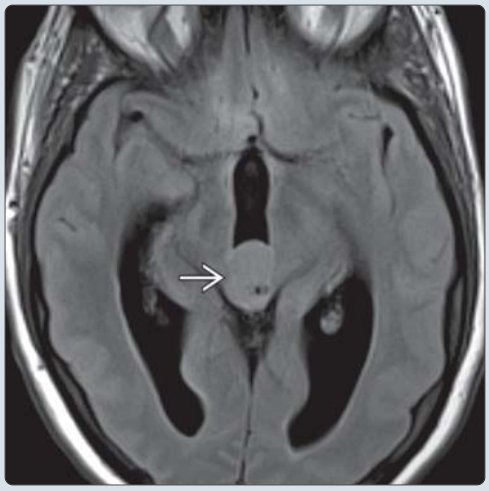

https://CafePezeshki.IR

TERMINOLOGY

Abbreviations

- Pineocytoma (PC)

Definitions

- Slow-growing pineal parenchymal tumor (PPT) of young adults
  - Composed of small, uniform, mature cells resembling pineocytes

IMAGING

General Features

- Best diagnostic clue
  - Circumscribed pineal mass that "explodes" pineal calcification peripherally
  - May mimic pineal cyst, pineal parenchymal tumor of intermediate differentiation (PPTID)
- Location
  - Pineal region
  - Rarely extends into 3rd ventricle
  - Rarely invasive
  - May compress adjacent structures
    - Rarely, associated hydrocephalus if aqueduct compression
- Size
  - Typically < 3 cm
- Morphology
  - Demarcated round or lobular mass

CT Findings

- NECT
  - Iso-/hypodense mass
  - Peripheral ("exploded") Ca++
  - Cystic change may be present
- CECT
  - Enhancement present, often heterogeneous

MR Findings

- T1WI
  - Iso- to hypointense round or lobular mass
- T2WI
  - Hyperintense round or lobular mass
- FLAIR
  - Hyperintense round or lobular pineal mass
- T2* GRE
  - May see Ca++
    - Areas of "blooming" at periphery/within mass
  - May hemorrhage (less common)
- T1WI C+
  - Avid enhancement is typical
  - Enhancement may be solid or peripheral

Imaging Recommendations

- Best imaging tool
  - MR imaging most sensitive
  - CT helpful to confirm Ca++
- Protocol advice
  - MR: Include post-contrast coronal and sagittal images

DIFFERENTIAL DIAGNOSIS

Nonneoplastic Pineal Cyst

- Round, smooth, cystic mass
- Typically < 1 cm, may be up to 2 cm
- Variable calcification and cyst fluid
- No/minimal rim enhancement
  - Compressed enhancing gland often seen posteriorly
- May be indistinguishable from PC on imaging

Pineal Parenchymal Tumor of Intermediate Differentiation (PPTID)

- Often middle-aged, older patients
- PPTIDs have more aggressive appearance than PC
  - Intermediate between PC, pineoblastoma
  - WHO grade II or III

Pineoblastoma

- Younger patients
- Large, lobulated, heterogeneous
- Mass effect, parenchymal invasion, CSF spread
- May be seen in patients with retinoblastoma ("trilateral retinoblastoma")

Germinoma

- "Engulfs" calcified pineal gland
- Intensely enhancing, often homogeneous
- CSF spread often present at diagnosis
- Hyperdense on CT
- Typically young male patients

Papillary Tumor of Pineal Region (PTPR)

- Rare
- Enhancing pineal region mass
- May be indistinguishable from PC, PPTID on imaging

Astrocytoma

- Infiltrative, T2 hyperintense mass
- Significant mass effect
- Variable enhancement

Other Germ Cell Tumors (GCT)

- Teratoma
- Choriocarcinoma, endodermal sinus (yolk sac) tumor, embryonal carcinoma, mixed GCT
- May have fat, hemorrhage, cystic change
- Lab studies may help (i.e., α-fetoprotein, hCG)

Meningioma

- Avidly enhancing, homogeneous mass with dural tail
- Middle-aged, older female patients

PATHOLOGY

General Features

- Etiology
  - Derived from pineal parenchymal cells (pineocytes) or their embryonic precursors
  - Pineocytes have photosensory and neuroendocrine function
- Genetics
  - No *TP53* mutations
  - Inconsistent reports of chromosomal gains/deletions

https://CafePezeshki.IR

Staging, Grading, & Classification

- WHO grade I
- Grading system for PPTs
  - Based on mitoses, neurofilament (NF) protein staining
    - Grade 1: Classic PC with no mitoses, NF(+)
    - Grade 2: < 6 mitoses/10 high-power fields, NF(+) (PPTID)
    - Grade 3: < 6 mitoses, NF(-) or ≥ 6 mitoses, NF(+) (PPTID)
    - Grade 4: Variable mitoses ± NF (pineoblastoma)

Gross Pathologic & Surgical Features

- Well-circumscribed, gray-tan mass
  - Homogeneous or granular cut surface
- Cysts, small hemorrhagic foci may be present
- Compresses, does not invade adjacent structures
- Rarely extends into 3rd ventricle

Microscopic Features

- Well-differentiated tumor
  - Small, uniform, mature cells
    - Resemble pineocytes
  - Sheets/lobules of tumor
  - Separated by mesenchymal septa
  - Variable neuronal, ganglionic, astrocytic differentiation
- Large fibrillary "pineocytomatous rosettes" characteristic
  - Large rosettes surround a fine network of processes
- Mitoses, necrosis absent
- Immunohistochemistry
  - Synaptophysin strongly positive
  - Neuron-specific enolase (NSE) strongly positive
- Electron microscopy
  - Microtubules
  - Clear-core or dense-core vesicles
  - Synapses
- Pleomorphic subset (probably PPTID)
  - Mixed/intermediate differentiation, mitoses
  - Occasional areas of necrosis, endothelial hyperplasia

CLINICAL ISSUES

Presentation

- Most common signs/symptoms
  - Headache
  - Parinaud syndrome (paralysis of upward gaze)
- Other signs/symptoms
  - ↑ intracranial pressure, hydrocephalus
  - Ataxia
  - Mental status changes
- Clinical profile
  - Germ cell markers
    - α-fetoprotein, hCG absent

Demographics

- Age
  - May occur at any age, including children
  - Mean: 35-40 years
- Gender
  - M = F
- Epidemiology
  - < 1% of primary brain tumors
  - Pineal region tumors ~ 3-8% of pediatric tumors
  - Pineal parenchymal tumors (PPT) account for ~ 15-30% of pineal gland tumors
    - PPT: Pineocytoma, pineal parenchymal tumor of intermediate differentiation (PPTID), pineoblastoma
  - Germ cell neoplasms account for ~ 40% of pineal gland tumors
    - Germinoma > > PPTs
  - Pineocytomas: ~ 45% of PPTs

Natural History & Prognosis

- Stable or slow-growing tumor
- Overall 5-year survival ~ 85-100%
  - 90% (grade II) to 100% (grade I) 5-year survival
- Rarely complicated by hemorrhage

Treatment

- Surgical excision or stereotactic biopsy is primary treatment
- Complete surgical resection generally curative
  - CSF diversion may be necessary
- Postoperative radiation therapy is controversial
- Some reports suggest stereotactic radiosurgery may be used as primary therapy or adjuvant therapy

DIAGNOSTIC CHECKLIST

Consider

- Pineocytoma may be cystic, mimic pineal cyst
- May appear aggressive, mimic pineoblastoma or PPTID
- Clinical information often helpful to differentiate pineal region masses
- GCTs often have positive serum markers

Image Interpretation Pearls

- Pineocytomas have peripheral Ca++
  - Germinomas "engulf" gland Ca++
- Enhancement often solid, may be peripheral

SELECTED REFERENCES

1. Balossier A et al: Role of radiosurgery in the management of pineal region tumours: indications, method, outcome. Neurochirurgie. 61(2-3):216-22, 2015
2. Awa R et al: Neuroimaging diagnosis of pineal region tumors-quest for pathognomonic finding of germinoma. Neuroradiology. 56(7):525-34, 2014
3. Farnia B et al: Clinical Outcomes and Patterns of Failure in Pineoblastoma: A 30-Year, Single-Institution Retrospective Review. World Neurosurg. 82(6):1232-1241, 2014
4. Jouvet A et al: Pineal parenchymal tumours and pineal cysts. Neurochirurgie. ePub, 2014
5. Dumrongpisutikul N et al: Distinguishing between germinomas and pineal cell tumors on MR imaging. AJNR Am J Neuroradiol. 33(3):550-5, 2012
6. Tong T et al: MRI and 1H-MRS on diagnosis of pineal region tumors. Clin Imaging. 36(6):702-9, 2012
7. Villà S et al: Primary pineal tumors: outcome and prognostic factors--a study from the Rare Cancer Network (RCN). Clin Transl Oncol. 14(11):827-34, 2012
8. Wilson DA et al: Long-term radiosurgical control of subtotally resected adult pineocytomas. J Neurosurg. 117(2):212-7, 2012
9. Kano H et al: Role of stereotactic radiosurgery in the management of pineal parenchymal tumors. Prog Neurol Surg. 23:44-58, 2009
10. Boco T et al: Papillary tumor of the pineal region. Neuropathology. 28(1):87-92, 2008
11. Fakhran S et al: Pineocytoma mimicking a pineal cyst on imaging: true diagnostic dilemma or a case of incomplete imaging? AJNR Am J Neuroradiol. 29(1):159-63, 2008
12. Lekovic GP et al: Role of Gamma Knife surgery in the management of pineal region tumors. Neurosurg Focus. 23(6):E12, 2007
13. Smirniotopoulos JG et al: Pineal region masses: differential diagnosis. Radiographics. 12(3):577-96, 1992

https://CafePezeshki.IR

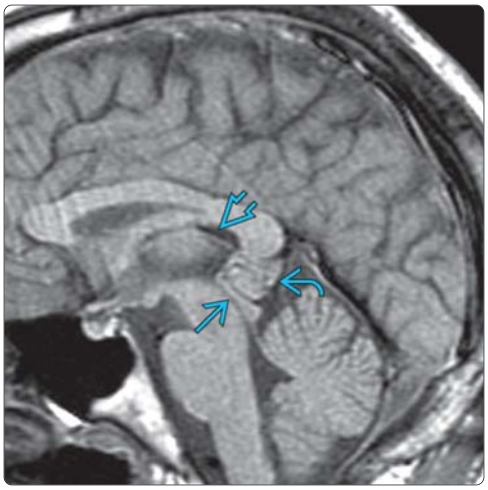

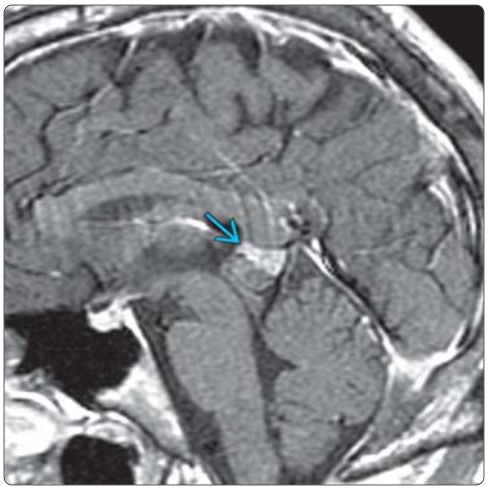

(Left) *Sagittal T1WI MR shows a demarcated mass of the pineal gland, isointense to the brain parenchyma. It exerts mild mass effect on the tectum, but the aqueduct is patent and there is no hydrocephalus. The pineal tumor sits underneath the internal cerebral veins and splenium of the corpus callosum.* **(Right)** *Sagittal T1WI C+ MR in the same patient shows the heterogeneously enhancing nature of the pineocytoma, with avid enhancement of the superior nodular component.*

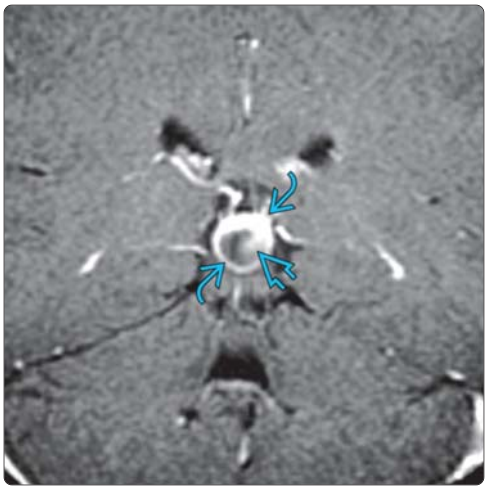

(Left) *Axial T1 C+ MR image of a pineocytoma shows a lobular, partially enhancing, partially cystic pineal region mass. Pineocytoma is the most common pineal parenchymal tumor. When cystic, these tumors may mimic a benign pineal cyst. (Courtesy C. Glastonbury MBBS.)* **(Right)** *Coronal T1WI C+ MR in a patient with pineocytoma shows both peripheral and more solid enhancement of a cystic pineal mass. A small central "target" of enhancement is also present.*

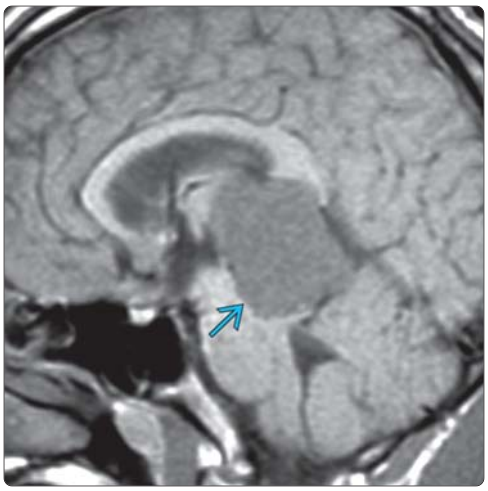

(Left) *Sagittal T1WI MR shows a variant appearance of a pineocytoma. There is a large, lobular, circumscribed tumor that causes obstructive hydrocephalus due to compression of the cerebral aqueduct. The tumor is slightly hyperintense relative to CSF and mildly hypointense relative to brain.* **(Right)** *Coronal T1WI C+ MR shows avid enhancement of the tumor with mild heterogeneity. "Variant" cases of presumed pineocytoma must be distinguished from PPTID, a more aggressive tumor.*

https://CafePezeshki.IR

KEY FACTS

TERMINOLOGY

- Primary parenchymal neoplasm of pineal gland
  - Intermediate in malignancy between pineoblastoma and pineocytoma

IMAGING

- General features
  - Aggressive-looking pineal mass in adult
  - Extension into adjacent structures (ventricles, thalami) is common
  - Lobulated, moderately vascular
  - Size varies from small (< 1 cm) to large (~ 6 cm)
- CT
  - Hyperdense mass centered in pineal region
  - Engulfs pineal gland Ca++
  - Hydrocephalus
- MR
  - T1: Mixed iso-/hypointense mass
  - T2: Isointense with gray matter, + small hyperintense foci
  - FLAIR: Hyperintense
  - Strong, heterogeneous enhancement
  - MRS: Elevated Cho, decreased NAA
- If aggressive-looking pineal region tumor in middle-aged, older adult, consider PPTID

TOP DIFFERENTIAL DIAGNOSES

- Germinoma
- Pineocytoma
- Pineoblastoma
- Papillary tumor of pineal region (PTPR)

PATHOLOGY

- Neuroepithelial neoplasm
  - Arises from pineocytes or their precursors
- WHO grade II or III

CLINICAL ISSUES

- Presenting features: Diplopia, Parinaud syndrome, headache

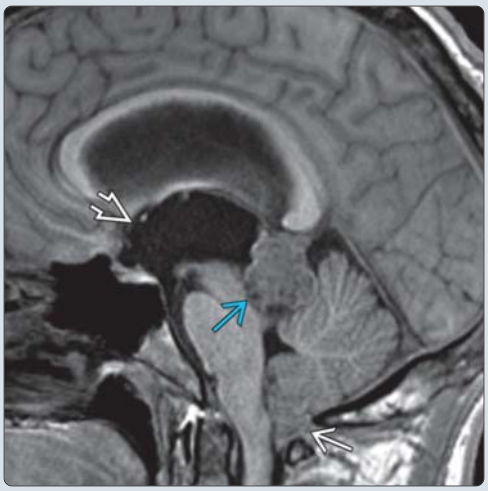

(Left) *Sagittal T1WI MR in a 21-year-old man with headache shows a pineal region mass ⇨ with obstructive hydrocephalus, enlargement of the 3rd ventricle ⇨, and cerebellar tonsillar descent ⇨. Imaging differential considerations include PPTID, pineoblastoma, and germinoma.* **(Right)** *Axial T2WI MR shows a very large PPTID ⇨ with extension into the ventricular system. Note the heterogeneous T2 appearance of the mass with multiple cystic regions ⇨, typical of PPTID. (Courtesy L. Loevner, MD.)*

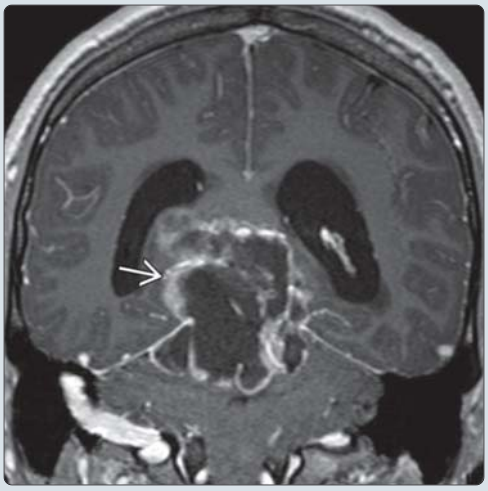

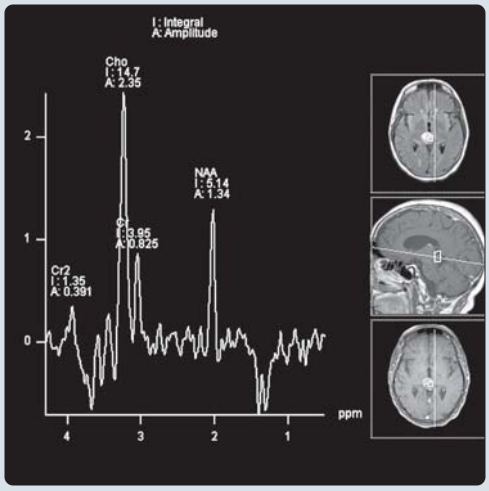

(Left) *Coronal T1WI C+ MR shows a large, peripherally enhancing pineal mass ⇨ in a 24-year-old male. PPTID was diagnosed at resection.* **(Right)** *MRs in a 48-year-old woman patient shows elevated choline, decreased NAA, and a lactate doublet. Imaging is too aggressive for a pineocytoma. Germinomas are rare in middle-aged females. Imaging is most suggestive of a PPTID, although a papillary tumor of the pineal region would be a possible diagnosis. PPTID was confirmed at histologic examination.*

https://CafePezeshki.IR

TERMINOLOGY

Abbreviations

- Pineal parenchymal tumor of intermediate differentiation (PPTID)

Definitions

- Primary parenchymal neoplasm of pineal gland
  - Intermediate in malignancy between pineocytoma and pineoblastoma
    - Pineocytoma: Slow-growing neoplasm with small mature cells that resemble pineocytes
    - Pineoblastoma: Highly malignant primitive embryonal tumor of pineal gland

IMAGING

General Features

- Best diagnostic clue
  - Aggressive-looking pineal mass in adult
- Location
  - Pineal gland mass
  - Extension into adjacent structures common: Ventricles, tectum, thalamus
  - CSF dissemination (rare)
- Size
  - Varies from small (< 1 cm) to ~ 6 cm

CT Findings

- NECT
  - Hyperdense mass centered in pineal region, ± hydrocephalus
  - Engulfs pineal gland Ca++

MR Findings

- T1WI
  - Mixed iso-/hypointense lobulated mass
- T2WI
  - Isointense with gray matter
  - Small, intratumor, hyperintense, cystic-appearing foci common
- T2* GRE
  - May show foci of "blooming"
- T1WI C+
  - Strong, heterogeneous enhancement

Imaging Recommendations

- Protocol advice
  - Pre-, post-contrast sagittal/axial/coronal T1WI
    - T2WI, FLAIR, T2* (GRE, SWI), DWI
  - Perform complete imaging of entire neuraxis prior to surgery to look for CSF dissemination

DIFFERENTIAL DIAGNOSIS

Germinoma

- Most common pineal neoplasm
- M > > F; mostly children, young adults < 25 years
- Engulfs pineal gland Ca++
- Intraventricular, distant CSF spread is common

Pineocytoma

- Most common pineal parenchymal neoplasm
- Generally tumor of adults (mean: 35-40 years)
- "Explodes" pineal gland Ca++
- Solid or solid and cystic, enhancement of solid portion

Pineoblastoma

- Most common in children but can occur at any age; M = F
- May require biopsy to distinguish from large PPTID
- CSF spread common, early

Papillary Tumor of Pineal Region (PTPR)

- Rare neuroepithelial tumor with papillary architecture
- Indistinguishable on imaging, gross pathology from PPTID, pineocytoma

PATHOLOGY

General Features

- Etiology
  - Neuroepithelial neoplasm
- Historical background
  - PPTID not generally recognized as distinct entity until 2007
  - Neoplasms diagnosed as "pineocytoma vs. pineoblastoma" or "atypical pineocytoma" prior to 2007 may be PPTIDs

Staging, Grading, & Classification

- WHO grade II or III

Gross Pathologic & Surgical Features

- Circumscribed, soft tumor without gross hemorrhage or necrosis

Microscopic Features

- Diffuse sheets of relatively uniform small cells
- Moderate to high cellularity; mild to moderate nuclear atypia

CLINICAL ISSUES

Presentation

- Most common signs/symptoms
  - Diplopia, Parinaud syndrome, headache
- Other signs/symptoms
  - Signs of elevated intracranial pressure, ataxia

Demographics

- Pineal region tumors uncommon as a group
  - 1% of all intracranial neoplasms
  - Germinomas > > pineal parenchymal neoplasms
  - PPTIDs probably represent ~ 20% of pineal parenchymal tumors

Treatment

- Stereotaxic biopsy, surgical resection common treatment

SELECTED REFERENCES

1. Yu T et al: Twenty-seven cases of pineal parenchymal tumours of intermediate differentiation: mitotic count, Ki-67 labelling index and extent of resection predict prognosis. J Neurol Neurosurg Psychiatry. ePub, 2015
2. Ito T et al: Clinicopathologic study of pineal parenchymal tumors of intermediate differentiation. World Neurosurg. 81(5-6):783-9, 2014
3. Nakazato Y et al: Pineal parenchymal tumour of intermediate differentiation. In DN Louis et al: WHO Classification of Tumours of the Central Nervous System. Lyon: IARC Press. 124-5, 2007

https://CafePezeshki.IR

Pineoblastoma

KEY FACTS

TERMINOLOGY
- Pineoblastoma (PB)
  - Neoplasm of pineal parenchyma (not germ cells)
  - Highly malignant, primitive embryonal tumor (PNET)

IMAGING
- General features
  - Large, heterogeneous pineal mass
  - Lobulated with poorly delineated margins
- Invasion into adjacent brain common
  - Corpus callosum, thalamus, midbrain, vermis
- Solid portion
  - NECT
    - Hyperdense with peripheral Ca++
  - MR
    - Iso- to hypointense on T2WI
    - Often shows restricted diffusion
    - Variable heterogeneous enhancement

TOP DIFFERENTIAL DIAGNOSES
- Germ cell tumors
- Other pineal parenchymal tumors

PATHOLOGY
- WHO grade IV
  - Embryonic precursors of pineal parenchymal cells (pinealocytes)
- Common phylogenetic origin of retina and pineal gland as light-sensing organs
- Germline mutations in retinoblastoma gene *RB1* → "trilateral" retinoblastomas
- Germline LOE mutations in *DICER1* → distinctive autosomal dominant tumor/dysplasia predisposition syndrome (DICER1 syndrome) that includes PB

DIAGNOSTIC CHECKLIST
- Image **entire neuraxis** preoperatively
  - Up to 45% CSF dissemination on MR or in CSF

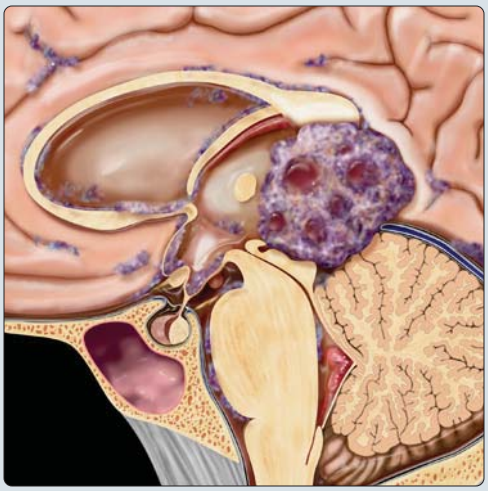

(Left) *Sagittal graphic shows a large, heterogeneous pineal mass with areas of hemorrhage and necrosis. Note the compression of adjacent structures, hydrocephalus, and diffuse CSF seeding, which is typical of pineoblastoma.* **(Right)** *Axial NECT shows a large, hyperdense, pineal region mass with peripheral calcification; it proved to be a pineoblastoma. Germinomas have a similar appearance, but calcification, when identified, is usually central (engulfed).*

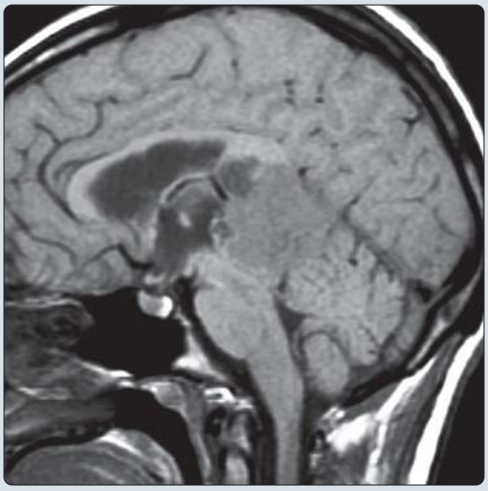

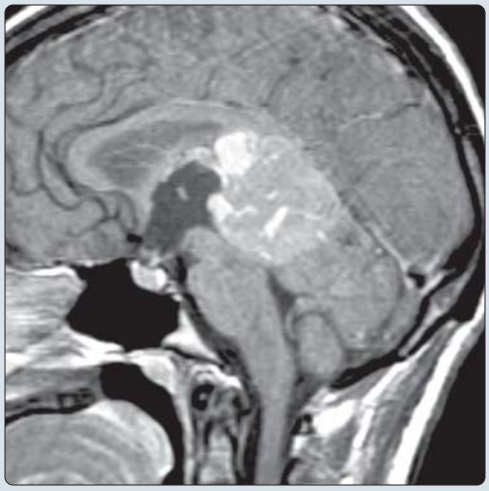

(Left) *Sagittal T1WI MR shows a mildly heterogeneous pineal region tumor with invasion of the midbrain tectum and posterior corpus callosum, typical of pineoblastoma.* **(Right)** *Sagittal T1WI C+ MR in the same patient shows moderate heterogeneous enhancement of the pineal region tumor and demonstrates the typical enhancement pattern of pineoblastoma.*

https://CafePezeshki.IR

TERMINOLOGY

Abbreviations

- Pineoblastoma (PB)

Synonyms

- Primitive neuroectodermal tumor (PNET) of pineal gland

Definitions

- Highly malignant primitive embryonal tumor of pineal gland

IMAGING

General Features

- Best diagnostic clue
  - Child with large, heterogeneous hyperdense pineal mass with peripheral Ca++
- Location
  - Pineal gland
    - Pineal masses lie below corpus callosum splenium
    - Elevate internal cerebral veins
    - Flatten/compress tectal plate
  - Frequent invasion of adjacent brain common
    - Corpus callosum, thalami, midbrain, vermis
- Size
  - Large (most ≥ 3 cm)
- Morphology
  - Irregular, lobulated mass with poorly delineated margins

CT Findings

- NECT
  - Mixed density; solid portion frequently hyperdense
  - Peripheral Ca++ common
  - Nearly 100% have obstructive hydrocephalus
- CECT
  - Weak to avid but heterogeneous enhancement

MR Findings

- T1WI
  - Heterogeneous; solid portion iso-/hypointense
- T2WI
  - Heterogeneous
    - Solid portion iso-/hypointense more common than minimally hyperintense to cortex
    - Frequent necrosis/hemorrhage, cysts
  - Mild peritumoral edema characteristic
- T2* GRE
  - Ca++ and hemorrhage may "bloom"
- DWI
  - Solid portion frequently restricts
  - ADC values lower than germ cell tumors (GCTs)
- T1WI C+
  - Heterogeneous enhancement
- MRS
  - ↑ Cho, ↓ NAA
  - Prominent glutamate and taurine peak (~ 3.4 ppm) described at TE 20 msec

Other Modality Findings

- No elevation of serum tumor markers

Imaging Recommendations

- Best imaging tool
  - MR with T1WI C+, DWI
- Protocol advice
  - Image entire neuraxis preoperatively
    - 15-45% present with **CSF dissemination**
  - Sagittal images ideal for pineal region anatomy

DIFFERENTIAL DIAGNOSIS

Germ Cell Tumors (GCTs)

- Germinoma: Cannot be differentiated from PB by imaging
- Mature teratoma
  - 2nd most common GCT and pineal region tumor
  - Heterogeneous, multicystic mass with foci of Ca++ and fat
- Choriocarcinoma, endodermal sinus tumor, embryonal cell carcinoma
  - Uncommon, highly malignant
  - Characteristic elevation of serum tumor markers
    - Choriocarcinoma: β-hCG
    - Endodermal sinus tumor: α-fetoprotein (AFP)
    - Embryonal cell carcinoma: β-hCG and AFP
- 10% of GCTs are mixed histology (mixed GCT)

Other Pineal Parenchymal Tumors (PTTs)

- Pineocytoma (WHO grade I), pineal parenchymal tumor of intermediate differentiation (PPTID; WHO II-III)
- Arise from pineal gland parenchymal cells
- Well-defined mass "explodes" pineal Ca++
- Older age group compared to pineoblastomas
- Cone-rod homeobox gene (*CRX*) expressed in pineal parenchymal tumors, retinoblastomas as well as some medulloblastomas and PNETs

Papillary Tumor of Pineal Region

- Rare; usually older

Trilateral Retinoblastoma

- Some authors consider primitive round cell pineal tumor associated with retinoblastoma to be P
- Look for ocular lesions

Astrocytoma

- Rarely arise from pineal gland
- More commonly from thalamus or midbrain tectum
- Pilocytic astrocytoma (WHO grade I) most common
- Tectal astrocytoma
  - Nonenhancing, well-defined, expansile tectal mass
- Thalamic astrocytoma
  - T2-hyperintense, paramedian mass or cyst with enhancing mural nodule

Meningioma

- Females (5th-7th decades)
- Well-defined, round, dural-based mass isointense to cortex on all sequences with intense, homogeneous enhancement
- Pineal region meningiomas arise from tentorium cerebelli, falx
- Dural "tail" (35-80%)

https://CafePezeshki.IR

Metastases

- Pineal gland metastases uncommon
- Adenocarcinoma reported

PATHOLOGY

General Features

- Etiology
  - Derived from embryonic precursors of pineal parenchymal cells (pinealocytes)
  - Pinealocytes have photosensory and neuroendocrine function
  - Common phylogenetic origin of retina and pineal gland as light-sensing organs
- Genetics
  - Germline LOE mutations in *DICER1* → distinctive autosomal dominant tumor/dysplasia predisposition syndrome (DICER1 syndrome)
    - *DICER1* is important susceptibility gene for PB, ciliary body medulloepithelioma
  - Some reports of chromosome 11 deletions
  - Germline mutations in retinoblastoma gene *RB1* → "trilateral" retinoblastomas
    - Bilateral retinoblastomas + PNET-like PB
    - Incidence of PB 10x in bilateral vs. unilateral retinoblastomas

Staging, Grading, & Classification

- WHO grade IV
- New prognostic grading system for PPTs
  - Grade 1 = pineocytoma
  - Grade 2 and 3 = PPTs with intermediate differentiation
    - Grade 2 if < 6 mitoses and immunolabeling positive for neurofilaments
    - Grade 3 if ≥ 6 mitoses or if < 6 mitoses but immunolabeling negative for neurofilaments
  - Grade 4 = PB

Gross Pathologic & Surgical Features

- Soft, friable, poorly marginated, infiltrative
- Compresses/invades cerebral aqueduct, leading to hydrocephalus
- CSF dissemination at autopsy frequent

Microscopic Features

- Highly cellular tumor
  - Mitoses common, MIB-1 elevated

CLINICAL ISSUES

Presentation

- Most common signs/symptoms
  - ↑ intracranial pressure (hydrocephalus)
    - Headache, nausea, vomiting, lethargy
    - Papilledema, abducens nerve palsy
- Other signs/symptoms
  - Parinaud syndrome, ataxia
- Clinical profile
  - Toddler with Parinaud syndrome, signs/symptoms of ↑ intracranial pressure

Demographics

- Age
  - Children > young adults (rare tumors up to 5th decade)
  - Mean age at diagnosis in children = 3 years
- Gender
  - M:F = 1:2
- Epidemiology
  - PPTs comprise 0.5-1% of primary brain tumors and 15% of pineal region neoplasms
  - PBs comprise 30-45% of PPTs

Natural History & Prognosis

- CSF seeding common
  - Up to 45% of patients present with spinal dissemination on MR &/or CSF analysis
- Rare reports of hematogenous metastases to bone
- Dismal; median survival 16-25 months from presentation

DIAGNOSTIC CHECKLIST

Consider

- Could pineal region mass be GCT (more common than PPTs)
  - Does patient have elevated serum tumor markers
  - Is patient male
  - Is there a coexistent suprasellar mass (germinoma)

Image Interpretation Pearls

- Both PBs and germinomas frequently hyperdense on CT (hypointense on T2WI) and prone to CSF dissemination
- Peripheral "exploded" Ca++ in PB and central "engulfed" Ca++ in classic germinoma

Clinical Pearl

- Pineal region astrocytomas typically do not present with Parinaud syndrome

SELECTED REFERENCES

1. Choudhri AF et al: Diffusion characteristics of pediatric pineal tumors. Neuroradiol J. ePub, 2015
2. Alkhotani A et al: A 49 year-old woman with a pineal mass. Brain Pathol. 24(2):191-2, 2014
3. de Kock L et al: Germ-line and somatic DICER1 mutations in pineoblastoma. Acta Neuropathol. 128(4):583-95, 2014
4. Farnia B et al: Clinical outcomes and patterns of failure in pineoblastoma: a 30-year, single-institution retrospective review. World Neurosurg. 82(6):1232-1241, 2014
5. Jouvet A et al: Pineal parenchymal tumours and pineal cysts. Neurochirurgie. ePub, 2014
6. Kakigi T et al: Quantitative imaging values of CT, MR, and FDG-PET to differentiate pineal parenchymal tumors and germinomas: are they useful? Neuroradiology. 56(4):297-303, 2014
7. Manila A et al: Is CRX protein a useful marker in differential diagnosis of tumors of the pineal region? Pediatr Dev Pathol. 17(2):85-8, 2014
8. Ramasubramanian A et al: Incidence of pineal gland cyst and pineoblastoma in children with retinoblastoma during the chemoreduction era. Am J Ophthalmol. 156(4):825-9, 2013
9. Dumrongpisutikul N et al: Distinguishing between germinomas and pineal cell tumors on MR imaging. AJNR Am J Neuroradiol. 33(3):550-5, 2012
10. Villà S et al: Primary pineal tumors: outcome and prognostic factors--a study from the Rare Cancer Network (RCN). Clin Transl Oncol. 14(11):827-34, 2012
11. Cuccia V et al: Pinealoblastomas in children. Childs Nerv Syst. 22(6):577-85, 2006

https://CafePezeshki.IR

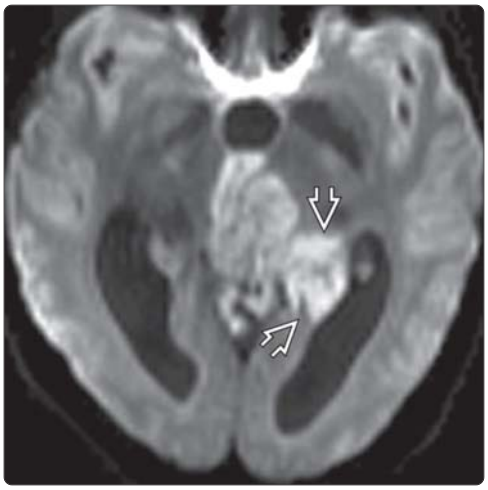

(Left) *Axial NECT shows a poorly demarcated, infiltrative, mildly hyperdense mass centered in the pineal region. Note the peripheral calcifications. On close evaluation there is invasion of the adjacent brain parenchyma. There is compression of the aqueduct of Sylvius and resultant hydrocephalus.* **(Right)** *Axial DWI MR shows restricted diffusion in the solid mass and better delineates the neoplasm and the invasion of the adjacent brain parenchyma.*

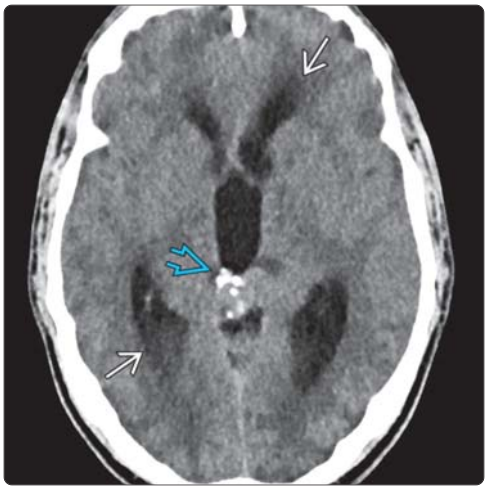

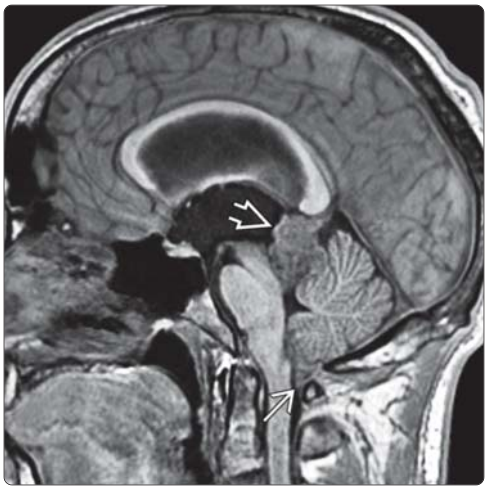

(Left) *Axial NECT scan in a 23-year-old man in the ER who presented with several weeks of headache and recent onset of blurred vision shows a calcified mass in the pineal region. Moderate obstructive hydrocephalus is present with "blurred" margins around the enlarged lateral ventricles.* **(Right)** *Sagittal T1-weighted MPRAGE scan in the same patient shows a lobulated mass in the pineal region. The 3rd/lateral ventricles are moderately enlarged and there is downward displacement of the cerebellar tonsils.*

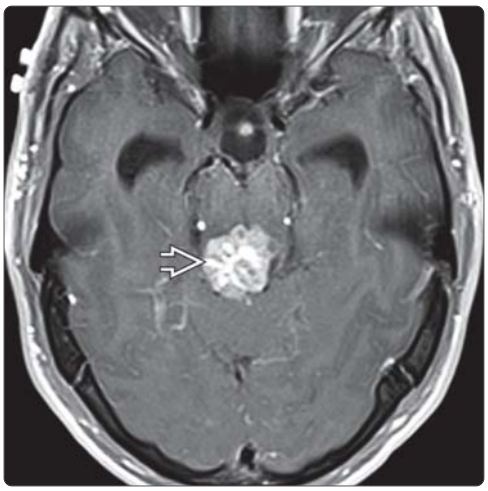

(Left) *T2WI in the same patient shows the mass is heterogeneously hyperintense with numerous intratumoral cysts. Papilledema is present with intraoptic protrusion of the optic nerve head and dilated optic nerve sheaths.* **(Right)** *T1 C+ FS MR in the same patient shows the mass enhances strongly but heterogeneously. Preoperative diagnosis was pineal parenchymal tumor of intermediate differentiation vs. papillary tumor of the pineal region. Final diagnosis was pineoblastoma, WHO grade IV.*

https://CafePezeshki.IR

KEY FACTS

TERMINOLOGY

- Papillary tumor of pineal region (PTPR)

IMAGING

- Enhancing, often well-circumscribed pineal mass
- T1: May be heterogeneously hyperintense
- T2: Cystic regions common
- Moderate heterogeneous enhancement
- Imaging often mimics other pineal parenchymal neoplasms

TOP DIFFERENTIAL DIAGNOSES

- Germinoma
- Pineocytoma
- Pineoblastoma
- Pineal parenchymal tumor of intermediate differentiation (PPTID)
- Teratoma

PATHOLOGY

- May derive from specialized ependymocytes of subcommissural organ
- WHO grade II-III
- Epithelial tumor
  - Papillary regions with large cuboidal/columnar cells
  - Cytokeratin (+), EMA(-)

CLINICAL ISSUES

- Most common symptoms related to increased intracranial pressure, headache
- Primarily tumor of adults, typically 30-50 years
- > 5 mitoses per 10 high-power fields correlates with decreased survival and increased likelihood of recurrence
- Frequent local recurrence
- CSF dissemination common
- Treatment: Surgical resection ± adjuvant radiation therapy
- Complete resection affords highest chance of cure

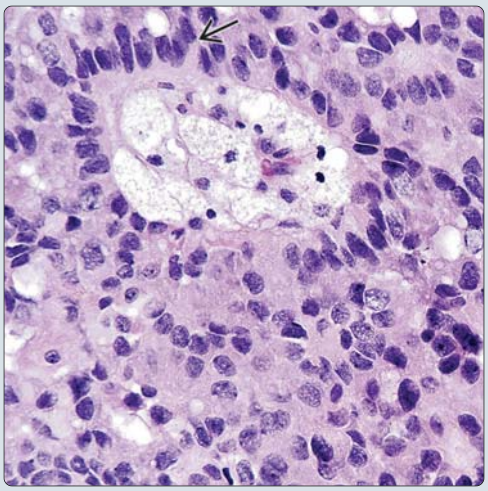

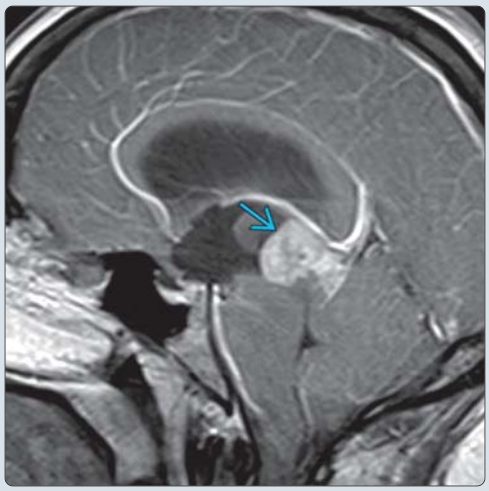

(Left) *H&E micrograph shows the typical epithelial features ⇨ of a papillary tumor of the pineal region. (From DP: Neuropathology.)* **(Right)** *Sagittal T1 C+ MR image shows a heterogeneously enhancing pineal region mass ⇨. The mass obstructs the aqueduct of Sylvius causing hydrocephalus. Imaging differential considerations include pineal parenchymal tumors and germ cell tumors. Papillary tumor of the pineal region was diagnosed at surgical resection. (Courtesy P. Burger, MD.)*

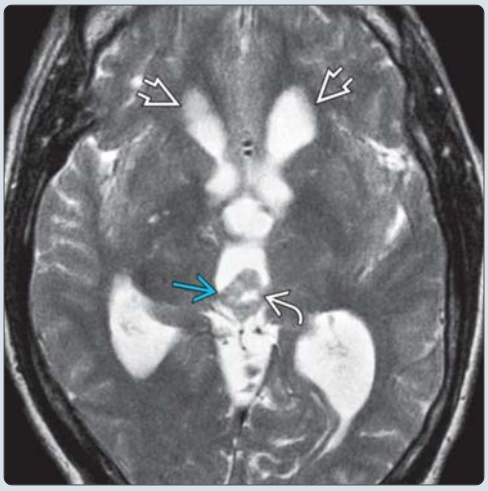

(Left) *Axial T2WI in a 66-year-old man with headaches shows a small heterogeneous mass in the pineal region ⇨. The mass is primarily isointense with the brain but contains a small, more focal, cystic-like area ⇨. Note the hydrocephalus with transependymal CSF flow (interstitial edema) seen here as "blurred" ventricular margins ⇨. (Courtesy J. Rees, MD.)* **(Right)** *Axial T1WI C+ MR in the same patient shows the pineal region mass ⇨ enhances diffusely but somewhat heterogeneously. (Courtesy J. Rees, MD.)*

https://CafePezeshki.IR

TERMINOLOGY

Abbreviations

- Papillary tumor of pineal region (PTPR)

IMAGING

General Features

- Best diagnostic clue
  - Enhancing pineal mass in adult
- Size
  - Variable, ~ 1-6 cm
- Morphology
  - Well circumscribed, ± cystic regions

Imaging Recommendations

- Best imaging tool
  - MR ± gadolinium
- Protocol advice
  - Pre-/post-contrast thin section sagittal T1WIs

MR Findings

- T1WI
  - Variable but can be heterogeneously hyperintense
- T2WI
  - Heterogeneously iso-/hyperintense
- FLAIR
  - Hyperintense
- T1WI C+
  - Moderate heterogeneous enhancement

DIFFERENTIAL DIAGNOSIS

Germinoma

- Most common pineal neoplasm
- Adolescent males > middle-aged adults
- Engulfs pineal gland Ca++
- Intraventricular, distant CSF spread is common

Pineocytoma

- Most common pineal parenchymal neoplasm
- Arises from pineal gland; "explodes" pineal gland Ca++
- Solid or solid and cystic, enhancement of solid portion

Pineoblastoma

- Most common in children but can occur at any age; M = F
- Enhancing pineal mass
- CSF spread common, early

Pineal Parenchymal Tumor of Intermediate Differentiation (PPTID)

- Enhancing, aggressive pineal mass in adult
- Can be indistinguishable from PTPR
- Histologic diagnosis

Teratoma

- Heterogeneous pineal mass with fat density/signal intensity
- Suppresses with FS sequences

PATHOLOGY

General Features

- Etiology
  - May derive from specialized ependymocytes of subcommissural organ, in posterior wall of 3rd ventricle
  - May be related to ependymal cells in pineal recess
- Genetics
  - Most show losses on chromosomes 10 and 22q
  - Gains on chromosomes 4, 8, 9, and 12
- Associated abnormalities
  - No other anomalies or syndromal associations

Staging, Grading, & Classification

- WHO grade II-III

Gross Pathologic & Surgical Features

- Moderate to large well-circumscribed mass

Microscopic Features

- Epithelial tumor with characteristic papillary regions with large cuboidal or columnar cells or, less commonly, smaller cells
- Some ependymal-type rosettes and tubular regions as well as perivascular pseudorosettes
- Immunohistochemistry
  - Strongly positive for cytokeratin, S100, NSE, vimentin
  - Weak or nonreactive to GFAP
- Occasional areas of necrosis, variable mitotic figures

CLINICAL ISSUES

Presentation

- Most common signs/symptoms
  - Nonspecific CNS symptoms, headache

Demographics

- Age
  - Reported in ages 5-66 but primarily tumor of adults, mean 32 years

Natural History & Prognosis

- Variable: 5-year survival (73%); progression free (27%)
- > 5 mitoses per 10 high-power fields correlates with decreased survival and increased likelihood of recurrence
- Frequent local recurrence
- CSF dissemination common

Treatment

- Complete resection affords highest chance of cure
- Adjuvant radiotherapy for subtotal resection of tumor
- Role of chemotherapy unclear

SELECTED REFERENCES

1. Edson MA et al: Outcomes after surgery and radiotherapy for papillary tumor of the pineal region. World Neurosurg. ePub, 2015
2. Heim S et al: Increased mitotic and proliferative activity are associated with worse prognosis in papillary tumors of the pineal region. Am J Surg Pathol. 38(1):106-10, 2014
3. Cohen AL et al: Bevacizumab is effective for recurrent papillary tumor of the pineal region: first report. Case Rep Oncol. 6(2):434-40, 2013
4. Fauchon F et al: Role of surgery, radiotherapy and chemotherapy in papillary tumors of the pineal region: a multicenter study. J Neurooncol. 112(2):223-31, 2013
5. Chang AH et al: MR imaging of papillary tumor of the pineal region. AJNR Am J Neuroradiol. 29(1):187-9, 2008
6. Roncaroli F et al: Papillary tumor of the pineal region and spindle cell oncocytoma of the pituitary: new tumor entities in the 2007 WHO Classification. Brain Pathol. 17(3):314-8, 2007

https://CafePezeshki.IR

KEY FACTS

TERMINOLOGY

- Medulloblastoma (MB)
  - Malignant, invasive, highly cellular embryonal tumor
- Four distinct MB molecular subgroups
  - WNT (wingless)
  - SHH (sonic hedgehog)
  - Group 3
  - Group 4

IMAGING

- MB subgroups arise in different locations
  - Midline (4th ventricle)
    - Predominately (but not exclusively) groups 3 and 4
  - Cerebellar peduncle/CPA cistern: WNT
  - Cerebellar hemispheres (lateral): SHH
- NECT: 90% hyperdense (Ca++ uncommon, hemorrhage rare)
- MR: > 90% enhance (group 4 minimal/no enhancement)
  - Restricted diffusion, low ADC
  - T1C+ essential to detect CSF dissemination

TOP DIFFERENTIAL DIAGNOSES

- Atypical teratoid/rhabdoid tumor (AT/RT)
- Ependymoma
- Cerebellar pilocytic astrocytoma (PA)

PATHOLOGY

- WHO grade IV (overstates risk of WNT MB)
- Histologic subtypes
  - Classic
  - Desmoplastic
  - MB with extensive nodularity (MBEN)
  - Large cell/anaplastic (LC/A)

CLINICAL ISSUES

- Most common malignant pediatric brain tumor
- Prognosis varies with subgroup, mutations
  - WNT best, group 3 worst

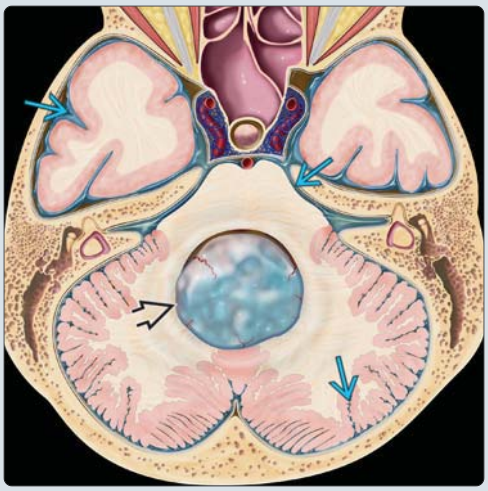

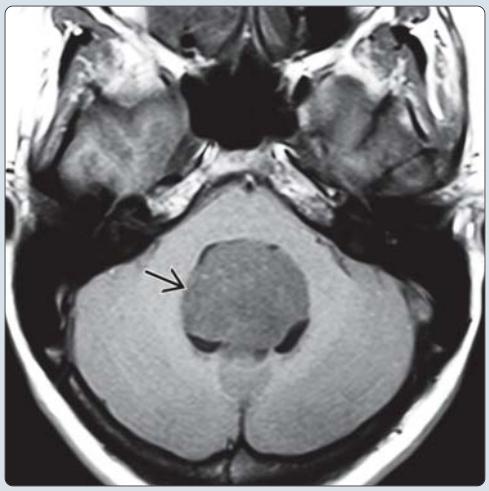

(Left) *Axial graphic shows a spherical tumor centered in the 4th ventricle ⇨, typical of classic medulloblastoma. CSF dissemination ("sugar icing") is common at initial diagnosis and is shown in blue ⇨.* **(Right)** *Axial T1WI shows imaging findings of classic medulloblastoma, with a rounded, slightly hypointense mass ⇨ in the 4th ventricle.*

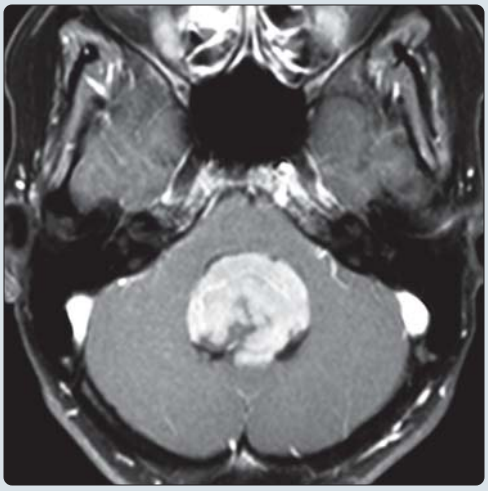

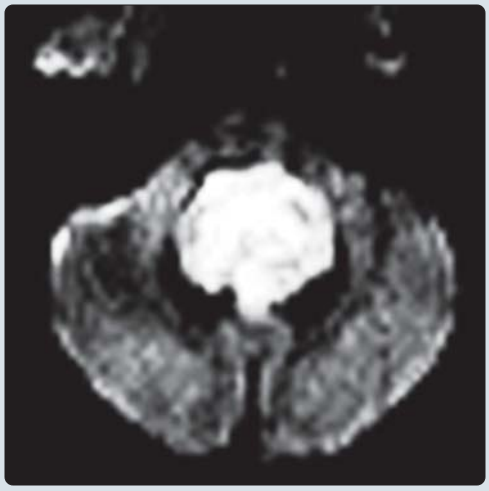

(Left) *Axial T1 C+ FS in the same patient shows strong, slightly heterogeneous enhancement in the mass. No definite CSF spread is identified.* **(Right)** *DWI in the same patient shows strongly restricted diffusivity. Surgery disclosed medulloblastoma, desmoplastic subtype. The midline 4th ventricle is the 2nd most common location for desmoplastic medulloblastomas (MBs) and the most common site for classic MBs. Histopathology disclosed desmoplastic medulloblastoma, SHH subtype.*

https://CafePezeshki.IR

TERMINOLOGY

Abbreviations

- Medulloblastoma (MB)

Synonyms

- PNET-MB

Definitions

- Malignant, invasive, highly cellular embryonal tumor
  - Not single-disease entity
  - 4 distinct molecular subgroups
    - Each has distinct cells of origin
    - Each has distinct molecular and clinical features
    - Each has different therapeutic approach
    - Subgroup maintained in relapse/recurrence
  - MB subgroups
    - WNT (wingless)
    - SHH (sonic hedgehog)
    - Group 3
    - Group 4

IMAGING

General Features

- Best diagnostic clue
  - Most common: Round, dense 4th ventricle mass
- Location
  - MB subgroups arise in distinct regions of cerebellum, associated with subgroup-specific genetic aberrations and cells of origin
    - Midline (4th ventricle)
      - Predominately (but not exclusively) groups 3 and 4
    - Cerebellar peduncle/cerebellopontine angle cistern
      - WNT most common
    - Cerebellar hemispheres (lateral)
      - SHH (slightly > 50%, remainder mostly midline)

CT Findings

- NECT
  - Solid mass in 4th ventricle
    - 90% hyperdense
    - Ca++ (up to 20%), hemorrhage rare
    - Small intratumoral cysts/necrosis in 40-50%
  - Hydrocephalus common (95%)
- CECT
  - > 90% enhance
    - Relatively homogeneous
    - Occasionally patchy (may fill in slowly)

MR Findings

- T1WI
  - Hypointense to gray matter (GM)
- T2WI
  - Near GM intensity, or slightly hyperintense to GM
- FLAIR
  - Hyperintense to brain
  - Good differentiation of tumor from CSF in 4th ventricle
- DWI
  - Restricted diffusion, low ADC
- T1WI C+
  - > 90% enhance (group 4 minimal/no enhancement)
  - Often heterogeneous
  - Contrast essential to detect CSF dissemination
    - Linear icing-like enhancement over brain surface: "Zuckerguss"
    - Extensive grape-like tumor nodules common in desmoplastic or medulloblastoma with extensive nodularity (MBEN)
    - May have dural tail and resemble meningioma (cerebellar hemispheres)
  - Contrast-enhanced MR of spine (entire neuraxis)
    - Up to 1/3 have subarachnoid metastatic disease at presentation
    - Image preoperatively to avoid postoperative false-positive: Blood in spinal canal may mimic or mask metastases
- MRS
  - ↓ ↓ NAA
  - ↑ ↑ choline
  - Lactate usually present
  - Elevation in Tau (short TE)
  - Cr/Cho < 0.75 and mI/NAA < 2.1 indicative for MB (resembles ependymoma)

Imaging Recommendations

- Best imaging tool
  - Contrast-enhanced MR

DIFFERENTIAL DIAGNOSIS

Atypical Teratoid/Rhabdoid Tumor (AT/RT)

- Top differential diagnosis (indistinguishable by imaging)

Pilocytic Astrocytoma (PA)

- Cerebellar hemisphere > 4th ventricle
- Cyst with enhancing nodule

Ependymoma

- Extrudes through 4th ventricle foramina/foramen magnum
- Heterogeneous (Ca++, hemorrhage more common)
- Higher ADC values (less cellular)

Choroid Plexus Papilloma (CPP)

- 4th ventricle less common, mostly adults

PATHOLOGY

General Features

- Etiology
  - WNT, SHH
    - WNT, SHH signaling regulate neural stem cell self-renewal, differentiation
  - Group 3
    - Cerebellar granule neuron precursors at weeks 10-15
      - Abnormal neuronal differentiation
      - Resemble rod precursor cells at week 15
  - Group 4
    - Cerebellar glutamatergic granule neuron precursors (GNPs) at weeks 20-30
      - Deregulation of synaptic pruning apoptosis
      - Dopamine, semaphorin signaling, and cell cycle deregulation
- Genetics

https://CafePezeshki.IR

- WNT
  - *DKK1*, *DKK2*, *DKK3*; *WNT16*, etc.
- SHH
  - *PTCH1*, *PTCH2*, and *SUFU* (infants)
  - *TP53*, *GLI2*, and *MYCN* amplifications (children)
  - *SMO* (adults)
- Group 3
  - Transient rod precursor gene *NRL*
  - *CRX* (normally regresses to pineal gland at week 15) and over expressed *SAG*
  - Group 3 MB, pineoblastoma often histologically indistinguishable
- Group 4
  - Late granule neuron markers, reelin pathway expressed
  - *SNCAIP* overexpressed exclusively in group 4
    - GNP proliferation promoted, protected from apoptosis
- Associated abnormalities
  - Some familial cancer syndromes (e.g., Gorlin)

Staging, Grading, & Classification

- WHO grade IV (overstates risk of WNT MB)

Microscopic Features

- Histologic subtypes
  - Classic
  - Desmoplastic
  - MBEN
  - Large cell/anaplastic (LC/A)
- MB diagnosis based on molecular subtype + histology, immunohistochemistry
  - WNT: Classic (90%)
  - SHH: All 4 histologic subtypes represented
    - Most all desmoplastic MBs are SHH
    - Subgroups
  - Group 3: Most are classic or LC/A (desmoplastic rare)
    - Further stratification into subgroups based on *MYC* amplification, chr 8
  - Group 4: All types except desmoplastic
    - Recurs with metastases

CLINICAL ISSUES

Presentation

- Most common signs/symptoms
  - Ataxia, signs of increased intracranial pressure
  - Macrocephaly in infants with open sutures
- Clinical profile
  - Relatively short (average 2 months) of symptoms
  - Symptoms reflect local mass effect &/or ↑ ICP
    - Nausea and vomiting, ataxia
    - Cranial nerve palsies (less common than in brainstem astrocytomas)
  - Gastrointestinal work-up for nausea, vomiting may precede diagnostic neuroimaging

Demographics

- Age
  - 75% < 10 years
  - Most diagnosed by 5 years
- Gender
  - M:F = 2-4:1
- Epidemiology
  - Most common malignant pediatric brain tumor
    - 15-20% of all pediatric brain tumors
    - 30-40% of posterior fossa tumors in children
    - Leading cause of childhood cancer-related mortality
  - Rare in adults

Natural History & Prognosis

- Varies with subgroup, mutations
  - WNT best (only MB categorized as low risk)
  - Group 3 worst
    - Higher risk if *MYC* amplified or iso17q or M(+)
  - SHH intermediate
    - Adults do better than children/infants
    - Low risk if M0, *GLI2* not amplified, no 14q loss
  - Group 4 intermediate
    - High risk if M(+), low risk with chr11 loss or 17 gain
- Risk also varies with histology
  - Generally desmoplastic > classic > LC/A

Treatment

- Surgical excision, adjuvant chemotherapy
- Craniospinal irradiation if > 3 years
- Low risk MB (WNT) may warrant reduced therapeutic intensity

DIAGNOSTIC CHECKLIST

Consider

- AT/RT in patients under 3 years
- Preoperative evaluation of entire neuraxis and postoperative evaluation of surgical bed are key to prognosis

Image Interpretation Pearls

- 4th ventricle tumor arising from roof = PNET-MB
- 4th ventricle tumor arising from floor = ependymoma
- If thinking of MB in childhood posterior fossa tumor, include AT/RT

SELECTED REFERENCES

1. Brandes AA et al: New perspectives in the treatment of adult medulloblastoma in the era of molecular oncology. Crit Rev Oncol Hematol. 94(3):348-359, 2015
2. Wang X et al: Medulloblastoma subgroups remain stable across primary and metastatic compartments. Acta Neuropathol. 129(3):449-57, 2015
3. Gerber NU et al: Recent developments and current concepts in medulloblastoma. Cancer Treat Rev. 40(3):356-65, 2014
4. Hooper CM et al: Gene expression analyses of the spatio-temporal relationships of human medulloblastoma subgroups during early human neurogenesis. PLoS One. 9(11):e112909, 2014
5. Perreault S et al: MRI surrogates for molecular subgroups of medulloblastoma. AJNR Am J Neuroradiol. 35(7):1263-9, 2014
6. Shih DJ et al: Cytogenetic prognostication within medulloblastoma subgroups. J Clin Oncol. 32(9):886-96, 2014
7. Rodriguez Gutierrez D et al: Metrics and textural features of MRI diffusion to improve classification of pediatric posterior fossa tumors. AJNR Am J Neuroradiol. 35(5):1009-15, 2014
8. Pitsika M et al: Cerebellar mutism. J Neurosurg Pediatr. 12(6):604-14, 2013
9. Spina A et al: Review of cerebellopontine angle medulloblastoma. Br J Neurosurg. 27(3):316-20, 2013
10. Yeom KW et al: Distinctive MRI features of pediatric medulloblastoma subtypes. AJR Am J Roentgenol. 200(4):895-903, 2013

https://CafePezeshki.IR

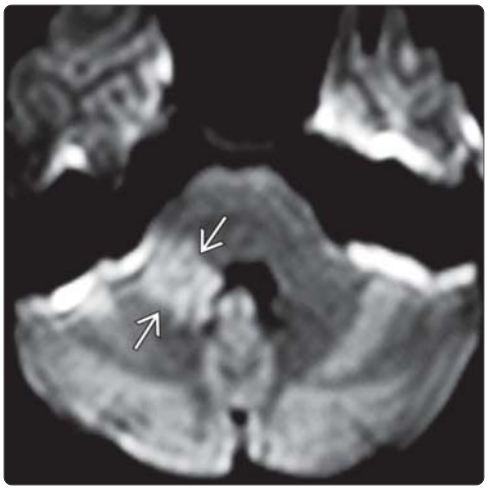

(Left) *Axial FLAIR MR in an 11-year-old woman with hearing loss, facial droop, and loss of balance shows a hyperintense right cerebellopontine mass ➡ predominately centered within the brachium pontis.* **(Right)** *DWI in the same case shows the mass ➡ exhibits strong, uniform restricted diffusion.*

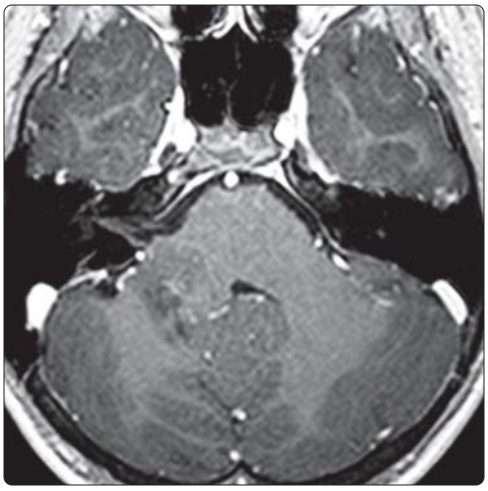

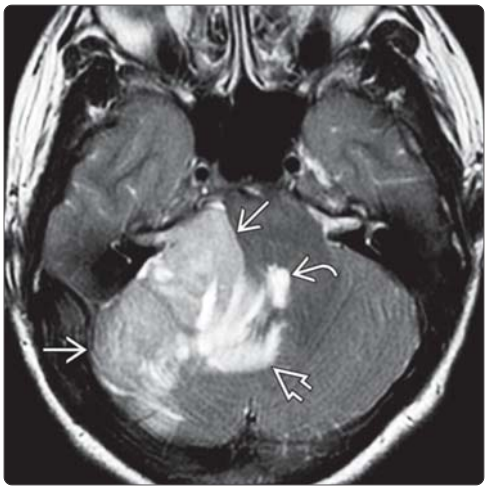

(Left) *Axial T1 C+ SPGR MR shows the mass has minimal enhancement. The preoperative diagnosis of medulloblastoma was documented at surgery. Molecular profiling disclosed WNT subtype. (Courtesy S. Blaser, MD.)* **(Right)** *Axial T2WI in a 27-year-old woman with headaches shows a hyperintense mass ➡ in the lateral aspect of the right cerebellar hemisphere. Moderate edema ➡ is present adjacent to the mass. The lesion compresses and displaces the 4th ventricle ➡.*

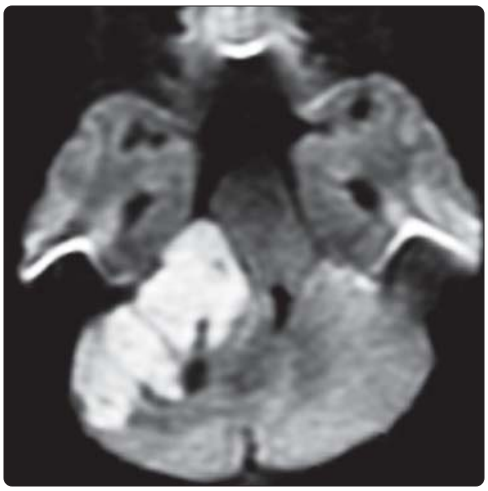

(Left) *T1 C+ FS MR in the same patient shows moderately intense, uniform enhancement. No CSF spread is apparent.* **(Right)** *DWI in the same patient shows the mass exhibits restricted diffusion (and was also hypointense on ADC, not shown). SHH-type desmoplastic MB was confirmed at surgery and subsequent molecular profiling.*

https://CafePezeshki.IR

KEY FACTS

TERMINOLOGY

- CNS supratentorial primitive neuroectodermal tumor (S-PNET)
  - Embryonal tumor composed of undifferentiated neuroepithelial cells

IMAGING

- Large, complex-appearing hemispheric mass in infant/young child
- Variable size, based on location
  - Hemispheric PNETs larger (mean diameter: 5 cm)
  - Suprasellar, pineal PNETs smaller
- Sharply delineated to diffusely infiltrative
  - Minimal peritumoral edema
- Calcification common (50-70%)
- Heterogeneous density/signal intensity, enhancement
  - Restricted diffusion common

TOP DIFFERENTIAL DIAGNOSES

- Atypical teratoid/rhabdoid tumor (AT/RT)
- Astrocytoma
- Ependymoma

PATHOLOGY

- WHO grade IV
- Some histologic subtypes now combined into single common diagnostic entity
  - Characterized by *C19MC* amplified/LIN28(+)
  - Enriched for primitive neural features
  - 75% in cerebral hemispheres

DIAGNOSTIC CHECKLIST

- If large bulky hemispheric mass with sparse edema in infant, think PNET or AT/RT
- Perform enhanced MR of entire neuraxis before surgery
  - Enhanced FLAIR detects subarachnoid seeding

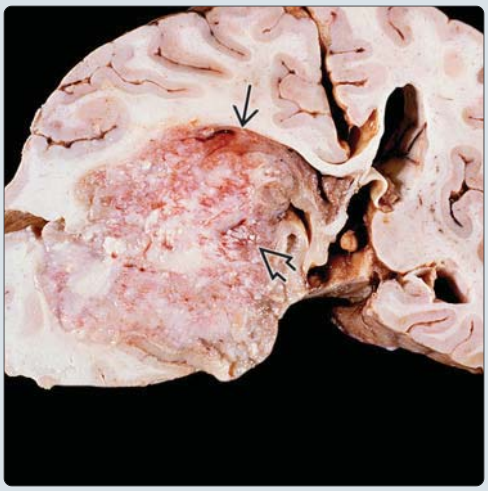

(Left) *Coronal gross pathology shows a cerebral PNET as a large, bulky hemispheric mass. Note the heterogeneous appearance, foci of hemorrhage, and necrosis. (Courtesy Rubinstein Collection, AFIP.)* **(Right)** *Axial T1WI MR shows a typical, very large, solid, intraaxial mass with distinctive lack of peritumoral edema. The mass is overall mildly hypointense relative to gray matter, though regions of hemorrhage are hyperintense. Ventricular obstruction with dilatation results from subfalcine herniation.*

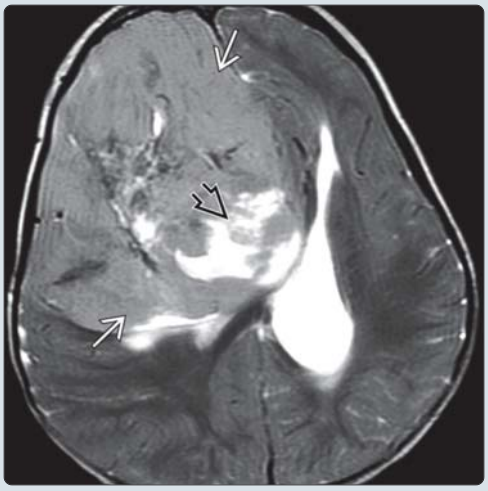

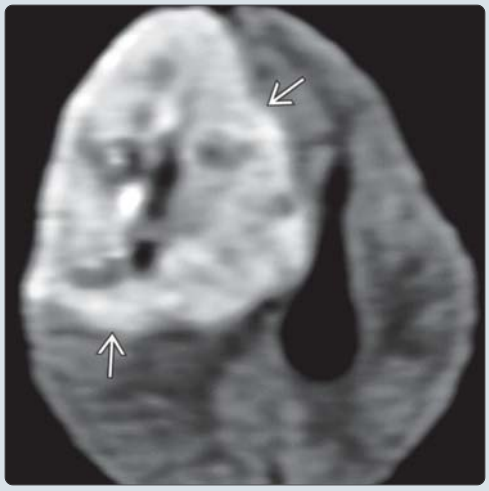

(Left) *Axial T2WI MR shows a large, mildly hyperintense, right frontal lobe mass. Note that the signal intensity is just slightly greater than gray matter. Also note the lack of peritumoral edema. Central and medial tumoral heterogeneity and hyperintensity represent necrosis.* **(Right)** *Axial DWI MR shows restricted diffusion within this highly cellular mass. Restricted diffusion was confirmed on corresponding ADC maps (not shown).*

https://CafePezeshki.IR

TERMINOLOGY

Abbreviations

- CNS supratentorial primitive neuroectodermal tumor (S-PNET)

Definitions

- CNS PNET: Generic designation comprising histologically diverse group of tumors
  - Composed of undifferentiated neuroepithelial cells
  - Broad capacity for divergent differentiation
    - Astrocytic, ependymal, neuronal, muscular, melanotic elements

IMAGING

General Features

- Best diagnostic clue
  - Large, complex-appearing hemispheric mass with minimal peritumoral edema in infant/young child
- Location
  - Cerebral hemisphere
    - Cortical/subcortical
    - Thalamic
  - Suprasellar
  - Pineal
- Size
  - Variable, based on location
    - Cerebral hemispheric PNETs are larger at diagnosis (mean diameter: ~ 5 cm)
      - Hemispheric lesions in infants often huge
    - Suprasellar PNETs tend to be smaller
      - Earlier symptoms (e.g., neuroendocrine and visual disturbances) due to mass effect on adjacent structures
    - Pineal PNETs cause hydrocephalus and gaze/convergence difficulties
- Morphology
  - Sharply delineated to diffusely infiltrative

Radiographic Findings

- Radiography
  - Macrocephaly and widened sutures (neonate and infant)

CT Findings

- NECT
  - Iso- to hyperattenuating
  - Calcification (50-70%)
  - Hemorrhage and necrosis common
- CECT
  - Heterogeneous enhancement
  - Prone to subarachnoid tumor seeding

MR Findings

- T1WI
  - Hypo- to isointense to gray matter
  - Homogeneous to heterogeneous
- T2WI
  - Solid elements isointense to slightly hyperintense to gray matter
  - No or minimal peritumoral edema; margins may appear sharp
  - Ca++ → hypointense foci
  - Blood products → mixed signal intensity
- PD/intermediate
  - Slightly hyperintense
- FLAIR
  - Solid components hyperintense
  - Little peritumoral edema
  - Post-contrast enhancement FLAIR detects leptomeningeal metastases
- T2* GRE
  - Dephasing from blood products
- DWI
  - Restricted diffusion common
- T1WI C+
  - Heterogeneous enhancement
  - Subarachnoid seeding common
  - Subtraction imaging helpful with hemorrhagic masses
- MRS
  - ↓ NAA, ↓ creatine, ↑ choline, + lipid and lactate

Ultrasonographic Findings

- Congenital S-PNET (antenatal sonography)
  - Large hyperechoic hemispheric mass
  - Hydrocephalus

Imaging Recommendations

- Best imaging tool
  - MR with T1WI C+, FLAIR, DWI, MRS
- Protocol advice
  - Perform T1WI C+ MR of entire neuraxis before surgery
  - Adding post-contrast enhancement FLAIR aids in detecting leptomeningeal metastases

DIFFERENTIAL DIAGNOSIS

Atypical Teratoid/Rhabdoid Tumor

- Posterior fossa > 50%, supratentorial 39%
- Necrosis, cysts, and vasogenic edema common
- Subarachnoid seeding common

Astrocytoma (AA, GBM)

- Extensive vasogenic edema
- Ca++

Ependymoma

- When supratentorial (30%), usually intraaxial
  - Only 15-25% arise within 3rd or lateral ventricle
- Necrosis and hemorrhage not uncommon

Choroid Plexus Carcinoma

- Parenchymal invasion can be dramatic
- Extensive vasogenic edema
- Avid enhancement

Cavernous Malformation

- Can be huge (almost holohemispheric) in newborn, infant
- Mimics hemorrhagic tumor

PATHOLOGY

General Features

- Etiology
  - Tumor suppressor gene aberrations may play role

https://CafePezeshki.IR

- Deregulation of epigenetic processes contributes to heterogeneity in tumor phenotypes, drivers of cancer initiation/progression
- C19MC amplified/LIN28(+)
- Genetics
  - Unlike medulloblastoma (PNET-MB), chromosome 17 aberrations (rare)
  - Somatic mutations in tumor suppressor genes
    - *ASCL1*
    - *SMARCB1* on chromosome 22
  - Other chromosome anomalies in S-PNETs
    - TTYH1-C19MC gene fusion
    - Aberrations of short arm of chromosome 11
    - Trisomies of chromosomes 9,13,1q, and 18p telomere maintenance
- Associated abnormalities
  - Hereditary syndromes
    - Gorlin syndrome
    - Turcot syndrome
    - Hereditary retinoblastoma and risk for secondary malignancies
    - Rubinstein-Taybi syndrome

Staging, Grading, & Classification

- All PNETs are WHO grade IV
- 2007 WHO classification
  - CNS PNET and embryonal tumors not otherwise specified (CNS PNET, NOS)
  - CNS PNET histologic subtypes
    - Neuroblastoma
    - Ganglioneuroblastoma
    - Ependymoblastoma (EPB)
    - Embryonal tumor with abundant neuropil and true rosettes (ETANTR)
    - Medulloepithelioma (MEP)
- EPB, ETANTR, MEP now combined into single common diagnostic entity (as yet unnamed)
  - These histologic subclasses are closely related molecular entities
    - Characterized by *C19MC* amplified/LIN28(+)
      - LIN23(+) (but not *C19MC*) also seen in other malignant pediatric brain tumors (e.g., rhabdoid brain tumors, some malignant gliomas)
    - Enriched for primitive neural features
    - Occur in children < 4 years
    - 75% in cerebrum
- New: "Group 1 CNS-PNETs"
- "CNS-PNET" now uncommon diagnosis of molecular exclusion

Gross Pathologic & Surgical Features

- Variable consistency
  - Solid and homogeneous → cystic, necrotic, hemorrhagic, and partially calcified
  - Solid portions and soft pink-red coloration, unless prominent desmoplasia
  - Demarcation between tumor and brain may range from indistinct to sharp

Microscopic Features

- Similar to medulloblastoma (PNET-MB)

CLINICAL ISSUES

Presentation

- Most common signs/symptoms
  - Vary with site of origin and size of tumor
    - Hemispheric → seizures, altered mental status, motor deficit, elevated intracranial pressure
    - Suprasellar → visual disturbance, endocrine dysfunction
    - Pineal → hydrocephalus, Parinaud syndrome
- Other signs/symptoms
  - Cranial neuropathies due to herniation or diffuse CSF metastases
- Clinical profile
  - Infant presenting with macrocephaly, seizures, large hemispheric mass

Demographics

- Age
  - Most common in younger children
    - Median age at diagnosis: 30-35 months
- Gender
  - M:F = 2:1
- Ethnicity
  - No ethnic predilection
- Epidemiology
  - S-PNETs constitute 1% of pediatric brain tumors
  - Of all CNS PNETs, 5-6% are supratentorial

Natural History & Prognosis

- Compared to posterior fossa PNET (PNET-MB), S-PNETs have poorer survival
  - S-PNET: 5-year survival: 30-35%
  - PNET-MB: 5-year survival: 80-85%
- Heavily calcified S-PNETs have slightly better prognosis

Treatment

- Aggressive surgical resection, chemotherapy, craniospinal radiation
- mTOR inhibitors may be helpful in LIN28(+) tumors

DIAGNOSTIC CHECKLIST

Consider

- S-PNET in newborn, infant, or young child with
  - Hemispheric tumor lacking edema
  - Suprasellar or pineal mass

Image Interpretation Pearls

- Large hemispheric mass with sparse peritumoral edema

SELECTED REFERENCES

1. Nowak J et al: Systematic comparison of MRI findings in pediatric ependymoblastoma with ependymoma and CNS primitive neuroectodermal tumor not otherwise specified. Neuro Oncol. ePub, 2015
2. Korshunov A et al: Embryonal tumor with abundant neuropil and true rosettes (ETANTR), ependymoblastoma, and medulloepithelioma share molecular similarity and comprise a single clinicopathological entity. Acta Neuropathol. 128(2):279-89, 2014
3. Nowak J et al: MRI characteristics of ependymoblastoma: results from 22 centrally reviewed cases. AJNR Am J Neuroradiol. 35(10):1996-2001, 2014
4. Spence T et al: CNS-PNETs with C19MC amplification and/or LIN28 expression comprise a distinct histogenetic diagnostic and therapeutic entity. Acta Neuropathol. 128(2):291-303, 2014

https://CafePezeshki.IR

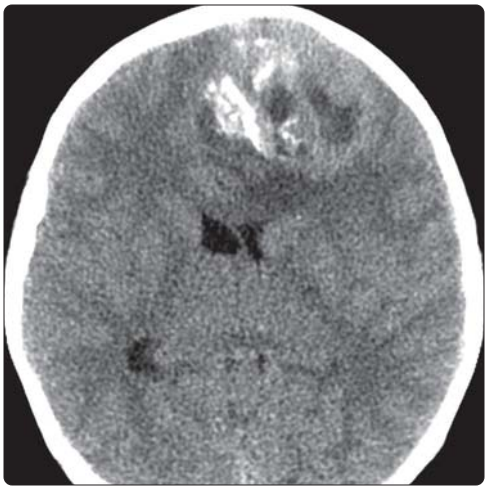

(Left) *Axial NECT shows a typical, intraaxial, frontal lobe cerebral PNET with heterogeneity, features of high cellularity and little or no peritumoral edema. The tumor is largely hyperattenuating with scattered calcifications.* **(Right)** *Axial T2WI in a 7-year-old boy with seizures shows a large heterogeneous mixed iso- and hyperintense mass ➡ in the right parietal lobe. Note the absence of peritumoral edema.*

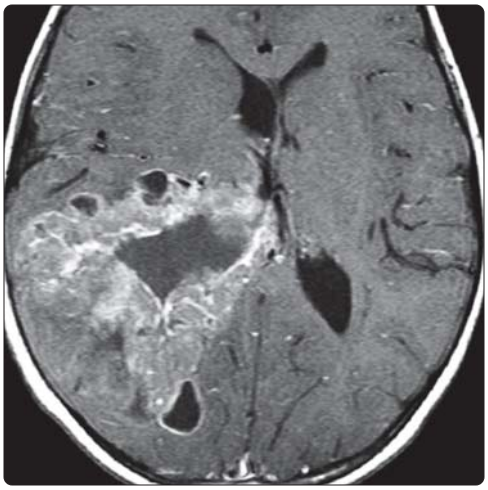

(Left) *FLAIR scan in the same patient shows a hyperintense area of central necrosis ⇨, solid portions of the tumor ➡, and several intratumoral cysts ➡ that do not suppress completely.* **(Right)** *T1 C+ MR in the same patient shows heterogeneous enhancement in the solid portions of the mass and around the intratumoral cysts. The central necrotic area does not enhance. PNET was found at surgery.*

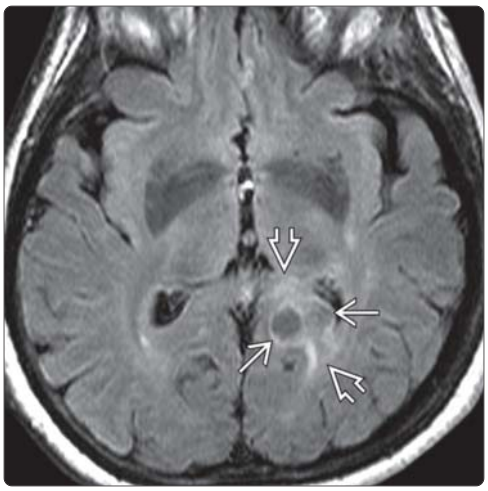

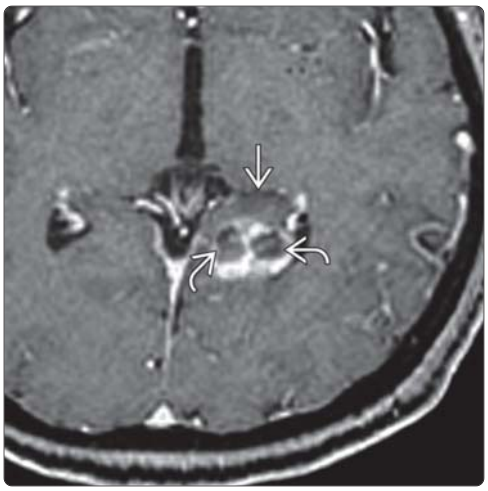

(Left) *Axial FLAIR MR shows a lobular, heterogeneous mass ➡ medial to the trigone of the left lateral ventricle at the parietooccipital junction. More subtle areas of hyperintensity in the surrounding white matter ➡ proved to be an infiltrating tumor.* **(Right)** *Axial T1WI C+ MR in the same patient shows heterogeneous enhancement of the lobular portion with regions of central necrosis ➡. The infiltrating portions do not enhance ➡. Final diagnosis was a supratentorial PNET.*

https://CafePezeshki.IR

KEY FACTS

TERMINOLOGY

- Lethal (usually childhood) cancer with *SMARCB1/hSNF5* mutations
- Loss of INI1 protein expression hallmark of CNS AT/RT

IMAGING

- Heterogeneous intracranial mass in infant
- Hyperattenuating mass on CT
- Commonly contains cysts or hemorrhage
- Relatively little edema for size of tumor
- Heterogeneous enhancement
- Leptomeningeal spread common
- Solid portions have reduced diffusivity on DWI, show decreased ADC
  - Cystic/necrotic regions show increased diffusivity, increased ADC

TOP DIFFERENTIAL DIAGNOSES

- Medulloblastoma, other PNETs

PATHOLOGY

- WHO grade IV
- Extreme morphological, immunophenotypic heterogeneity
- Divergent differentiation along mesenchymal, neuronal, glial, or epithelial lines
  - Accounts for "teratoid" label
  - Rhabdoid cells common but not invariably present
  - Often contains primitive neuroectodermal cells that resemble PNET
- Lack of immunostaining for INI1 protein correlates with *hSNF5/INI1* mutation
  - Required for definitive diagnosis of AT/RT

DIAGNOSTIC CHECKLIST

- Always consider AT/RT when large tumor found in child younger than 3 years
- Include AT/RT whenever medulloblastoma (PNET-MB) is diagnostic consideration

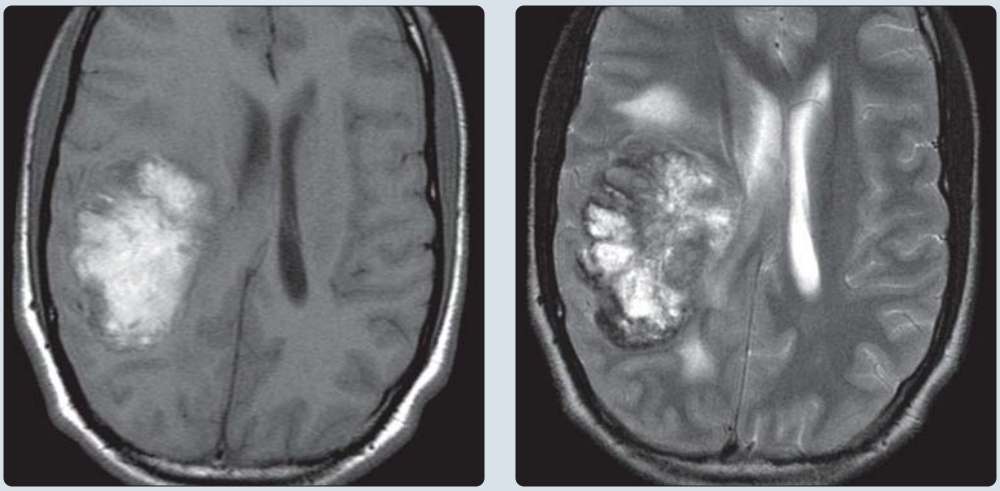

(Left) *Axial T1WI shows a large right parietal mass with predominately high signal intensity, suggesting hemorrhage.* **(Right)** *Axial T2WI in the same case shows a very heterogeneous lesion with mixed hyper-, hypo-, and isointense regions. Peripheral edema is relatively minimal in this case.*

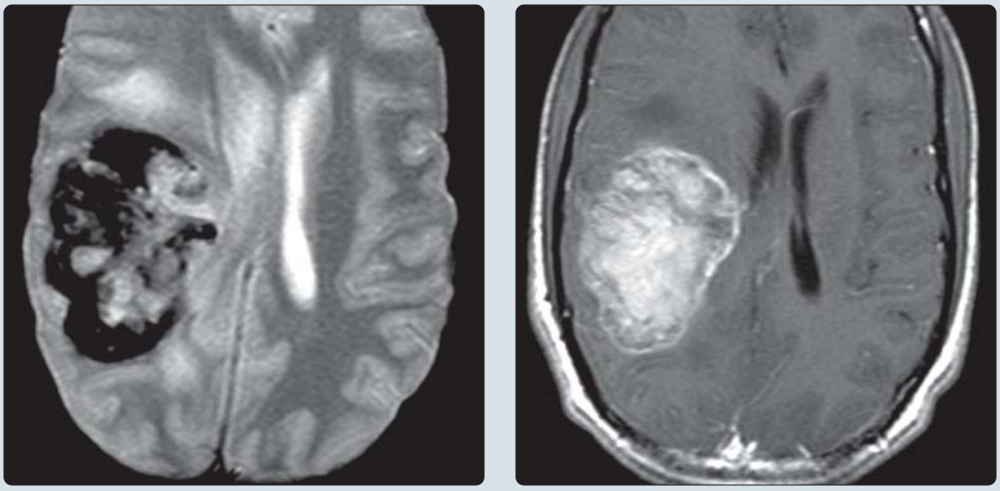

(Left) *Axial T2*GRE shows markedly hypointense "blooming" in the mass, consistent with hemorrhage.* **(Right)** *Axial T1C+ MR in the same case shows some enhancement around the periphery of the mass. AT/RT was found at surgery. (Courtesy R. Hewlett, MD.)*

https://CafePezeshki.IR

TERMINOLOGY

Abbreviations

- Atypical teratoid/rhabdoid tumor (AT/RT)

Synonyms

- Malignant rhabdoid tumor of brain
- Rhabdoid brain tumor

Definitions

- Lethal (usually childhood) cancer with *SMARCB1/hSNF5* mutations
  - Loss of INI1 protein expression hallmark of CNS AT/RT

IMAGING

General Features

- Best diagnostic clue
  - Heterogeneous mass in infant/young child
  - Moderately large, bulky tumor with mixed solid cystic components
- Location
  - Infratentorial (47%)
    - Most off midline
    - Cerebellopontine angle (CPA)
    - Cerebellum &/or brainstem
  - Supratentorial (41%)
    - Hemispheric or suprasellar
  - Both infra- and supratentorial (12%)
  - 15-20% present with disseminated tumor at time of initial diagnosis
- Size
  - Most 1-3 cm at presentation (can be very large)
- Morphology
  - Roughly spherical, irregular/lobulated

CT Findings

- NECT
  - Hyperattenuating mass
  - Commonly contains cysts &/or hemorrhage
  - May contain Ca++
  - Obstructive hydrocephalus common
- CECT
  - Strong but heterogeneous enhancement typical

MR Findings

- T1WI
  - Heterogeneous
    - Isointense to brain
    - ± hyperintense hemorrhagic foci
    - Cysts slightly hyperintense to CSF
- T2WI
  - Heterogeneous
    - Hypointense foci (hemorrhage)
    - Hyperintense foci (cysts)
- FLAIR
  - Solid tumor isointense to hyperintense
  - Cysts hyperintense to CSF
  - Transependymal edema from hydrocephalus
  - Relatively little edema for size of tumor
- T2* GRE
  - Hypointense "blooming" of hemorrhagic foci
- DWI
  - May restrict because of cellularity
  - Decreased apparent diffusion coefficient (ADC)
- T1WI C+
  - Heterogeneous enhancement
  - Leptomeningeal spread common (15-20%)
    - Diffuse linear
    - Multiple nodular
  - "Brain-to-brain" parenchymal metastases
- MRA
  - May show narrowing of encased vessels
- MRS
  - Aggressive metabolite pattern
    - Elevated choline
    - Low or absent N-acetylaspartate (NAA), creatine
    - Lipid/lactate peak common

Imaging Recommendations

- Best imaging tool
  - MR with contrast
- Protocol advice
  - Entire CNS must be imaged at presentation to identify subarachnoid spread of tumor

DIFFERENTIAL DIAGNOSIS

Medulloblastoma (PNET-MB)

- Posterior fossa tumor
- AT/RT more likely to have cysts than PNET-MB
- Heterogeneous CPA tumors statistically more likely to be PNET-MB but more typical of AT/RT

Ependymoma

- "Plastic" tumor, extends out 4th ventricle foramina
- Ca++, cysts, hemorrhage common
- Strong, heterogeneous enhancement

Choroid Plexus Papilloma

- Intraventricular mass
- Homogeneous enhancement

Glioblastoma/Sarcoma

- High-grade glioma
- Exophytic from brainstem

Teratoma

- More often pineal or parasellar in location
- Heterogeneous on imaging due to Ca++, hemorrhage

PATHOLOGY

General Features

- Genetics
  - *SMARCB1* mutation with INI1 loss of expression/mutation diagnostic of AT/RT
    - Core member of SWI/SNF chromatin remodeling complex
  - 2 AT/RT molecular subgroups, each with distinct clinicopathological and survival features
    - Group 1: *ASCL1* (regulator of NOTCH signaling, marker of primitive neural lineage) upregulated
      - 60% supratentorial, 40% infratentorial

https://CafePezeshki.IR

- Neural differentiation = 5-year survival
  - *ASCL1* negative tumor (infratentorial, poor survival)
    - Mesenchymal differentiation, BMP/MAPK signaling pathways enriched
    - 70% infratentorial, 30% supratentorial
    - Infratentorial location, BMP signaling = worse outcome
- Familial cases occur in rhabdoid tumor predisposition syndrome (RTPS)
  - When mutation in *SMARCB1* gene, called RTPS1
  - *SMARCB4* gene mutation → RTPS2

Staging, Grading, & Classification

- WHO grade IV
  - Without molecular information, diagnosis is "embryonal tumor with rhabdoid features"

Gross Pathologic & Surgical Features

- Frequently unresectable at presentation
- Poorly defined tumor margins
- Infiltration into parenchyma

Microscopic Features

- Extreme morphological, immunophenotypic heterogeneity
- Divergent differentiation along mesenchymal, neuronal, glial, or epithelial lines
  - Accounts for "teratoid" label
  - Rhabdoid cells common but not invariably present
    - Large, pale, bland cells with moderate eosinophilic cytoplasm
  - Often contains primitive neuroectodermal cells that resemble PNET
- Lack of immunostaining for INI1 protein correlates with *hSNF5/INI1* mutation
  - Required for definitive diagnosis of AT/RT

CLINICAL ISSUES

Presentation

- Most common signs/symptoms
  - Signs of increased intracranial pressure
    - Lethargy
    - Vomiting
    - Increased head circumference
  - Other signs/symptoms
    - Torticollis
    - Seizure
    - Regression of skills
    - Acute facial nerve palsy in infant

Demographics

- Age
  - < 3 years; smaller peak in adults
    - Adult tumors often in atypical locations (e.g., pineal, suprasellar, spine)
- Gender
  - M = F
- Epidemiology
  - Rare > 3 years
  - Up to 20% of primitive CNS tumors in children < 3 years of age

Natural History & Prognosis

- Median survival = 16 months with leptomeningeal disease, 149 months without
- Death rate = 64%

Treatment

- Aggressive resection and chemoradiation have increased survival times but still remains poor
- Radiation has shown to increased survival time, especially in older children
  - Controversial in younger children due to damage to developing brain
- Chemotherapy regimens designed for PNET-MB largely ineffectual

DIAGNOSTIC CHECKLIST

Consider

- Always consider AT/RT when large tumor found in child < 3 years of age
- Include AT/RT whenever medulloblastoma (PNET-MB) is diagnostic consideration

Image Interpretation Pearls

- Imaging appearance is nonspecific
- More likely to be heterogeneous or supratentorial than PNET-MB

SELECTED REFERENCES

1. Sredni ST et al: Rhabdoid tumor predisposition syndrome. Pediatr Dev Pathol. 18(1):49-58, 2015
2. Torchia J et al: Molecular subgroups of atypical teratoid rhabdoid tumours in children: an integrated genomic and clinicopathological analysis. Lancet Oncol. 16(5):569-82, 2015
3. Agaimy A: The expanding family of SMARCB1(INI1)-deficient neoplasia: implications of phenotypic, biological, and molecular heterogeneity. Adv Anat Pathol. 21(6):394-410, 2014
4. Kubicky CD et al: Rare primary central nervous system tumors. Rare Tumors. 6(3):5449, 2014
5. Louis DN et al: International Society Of Neuropathology--Haarlem consensus guidelines for nervous system tumor classification and grading. Brain Pathol. 24(5):429-35, 2014
6. Margol AS et al: Pathology and diagnosis of SMARCB1-deficient tumors. Cancer Genet. 207(9):358-64, 2014
7. Siu A et al: Association of cerebellopontine angle atypical teratoid/rhabdoid tumors with acute facial nerve palsy in infants. J Neurosurg Pediatr. 13(1):29-32, 2014
8. Souki C et al: Atypical teratoid rhabdoid tumor in adulthood. Clin Neuropathol. 33(3):245-50, 2014
9. Xin X et al: A primary spinal extradural atypical teratoid/rhabdoid tumor of the cervical spine with bony involvement. J Child Neurol. 29(5):670-3, 2014
10. Au Yong KJ et al: How specific is the MRI appearance of supratentorial atypical teratoid rhabdoid tumors? Pediatr Radiol. 43(3):347-54, 2013
11. Bruggers CS et al: Magnetic resonance imaging spectroscopy in pediatric atypical teratoid rhabdoid tumors of the brain. J Pediatr Hematol Oncol. Epub ahead of print, 2013
12. Koral K et al: Diffusion MRI improves the accuracy of preoperative diagnosis of common pediatric cerebellar tumors among reviewers with different experience levels. AJNR Am J Neuroradiol. 34(12):2360-5, 2013
13. Birks DK et al: Claudin 6 is a positive marker for atypical teratoid/rhabdoid tumors. Brain Pathol. 20(1):140-50, 2010
14. Koral K et al: Imaging characteristics of atypical teratoid-rhabdoid tumor in children compared with medulloblastoma. AJR Am J Roentgenol. 190(3):809-14, 2008
15. Warmuth-Metz M et al: CT and MR imaging in atypical teratoid/rhabdoid tumors of the central nervous system. Neuroradiology. 50(5):447-52, 2008
16. Squire SE et al: Atypical teratoid/rhabdoid tumor: the controversy behind radiation therapy. J Neurooncol. 81(1):97-111, 2007
17. Meyers SP et al: Primary intracranial atypical teratoid/rhabdoid tumors of infancy and childhood: MRI features and patient outcomes. AJNR Am J Neuroradiol. 27(5):962-71, 2006

https://CafePezeshki.IR

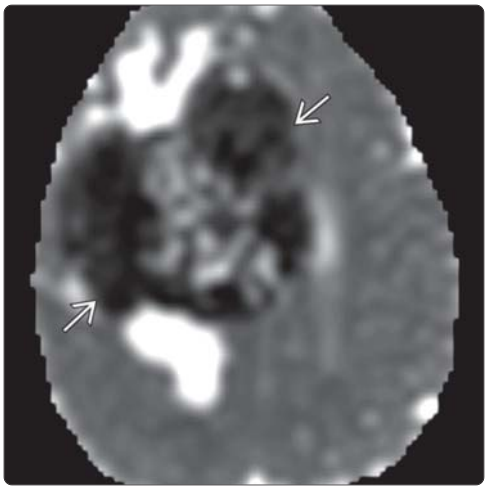

(Left) *Axial T2WI MR shows a large, bulky, supratentorial, heterogeneous tumor ⇨ with central hemorrhage and mass effect. Although some edema is present ⇨, it is less than expected given the size of the tumor.* **(Right)** *Axial ADC in the same case shows decreased apparent diffusion coefficient ⇨ compatible with the hypercellular nature of the tumor.*

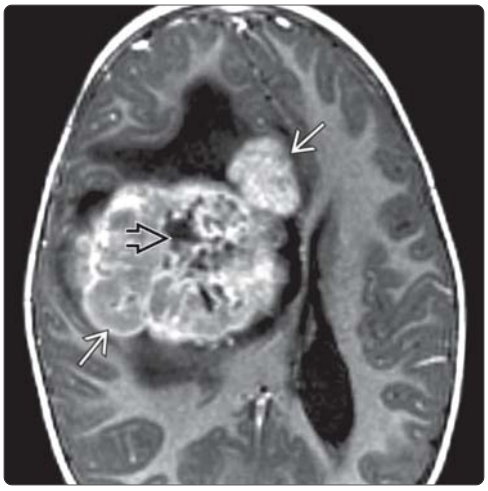

(Left) *Axial T1WI C+ MR in the same patient shows strong but rather heterogeneous enhancement ⇨. Some central areas of necrosis ⇨ can be seen within the generally solid mass.* **(Right)** *Sagittal T1WI C+ MR demonstrates "drop" metastases ⇨. Preoperative contrast-enhanced scans of the entire neuraxis should be obtained in all cases of posterior fossa neoplasms in children to rule out subarachnoid metastases, as in this example.*

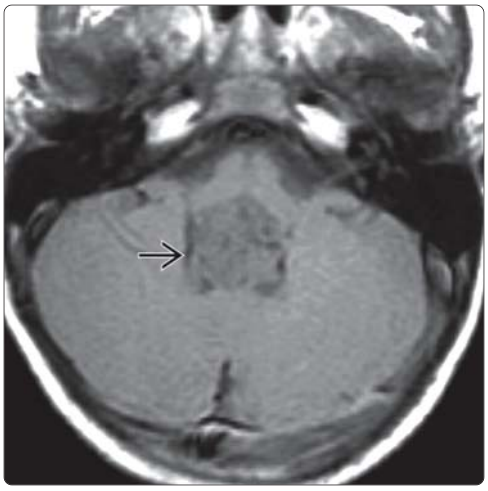

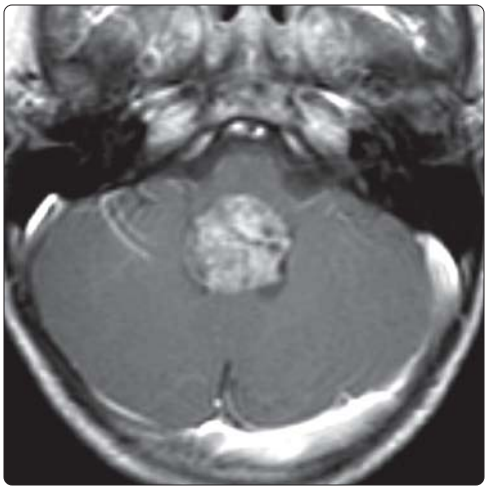

(Left) *Axial T1WI MR in a 3-year-old male with history of morning emesis for 4-6 weeks shows a mass in the fourth ventricle ⇨.* **(Right)** *Axial T1 C+ MR in the same case shows the mass enhances moderately but heterogeneously. The preoperative diagnosis was medulloblastoma. The final pathological diagnosis was AT/RT.*

https://CafePezeshki.IR

KEY FACTS

TERMINOLOGY

- Malignant tumor of sympathetic nervous system arising from embryonal neural crest cell derivatives

IMAGING

- Classic imaging appearance:
  - "Hair on end" spiculated periostitis of orbits and skull ± bone destruction
- Cranial metastases
  - Nearly always extradural, calvarial-based mass
- Brain metastases rare
  - ↑ prevalence with improved treatment protocols, stage IV metastatic disease
  - Most parenchymal NB mets supratentorial, hemorrhagic

TOP DIFFERENTIAL DIAGNOSES

- Leukemia
- Langerhans cell histiocytosis (LCH)
- Extraaxial hematoma
- Ewing sarcoma

PATHOLOGY

- Calvarial metastases indicate stage IV disease
  - 60-75% < 1-year survival
  - 15% > 1-year survival despite aggressive treatment

CLINICAL ISSUES

- Most common solid extracranial tumor in children < 5 years of age
  - 8-10% of all childhood cancers
- Most common tumor in neonates/infants < 1 month of age (congenital)
  - Median age at diagnosis = 22 months
  - Ophthalmic manifestation in 20-55%
    - Proptosis and "raccoon eyes"
- Metastasis to bone most common, 2/3 of patients at diagnosis
  - Stage IV disease

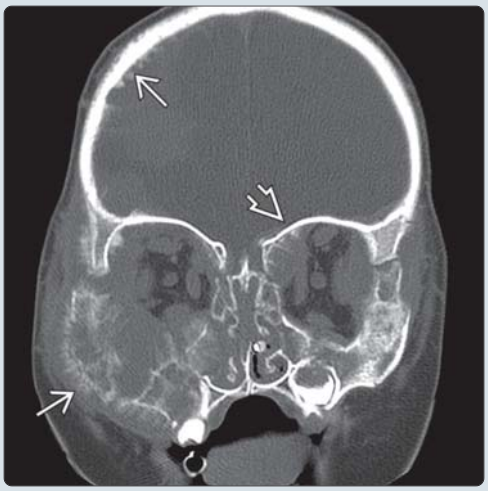

(Left) *Coronal NECT of a child with an abdominal mass reveals orbital, facial bone, and calvarial spiculated periostitis giving rise to a "hair on end" appearance ➡ with associated large soft tissue masses. Note bilateral disease ➡. Metastatic stage IV neuroblastoma typically involves the skull and bony orbits.* **(Right)** *Axial NECT in the same patient shows the "hair on end" appearance. Involvement of the orbits often gives rise to proptosis and ecchymosis "raccoon eyes," which may be mistaken for abuse.*

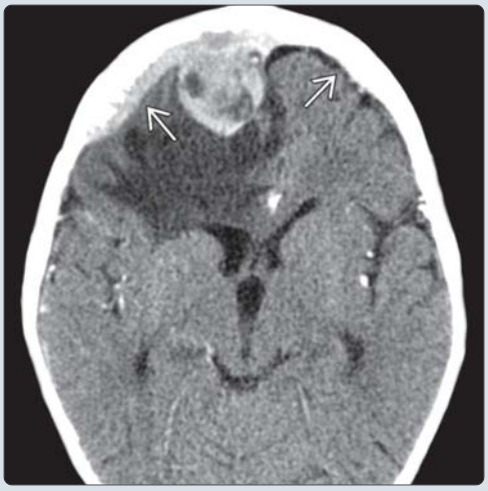

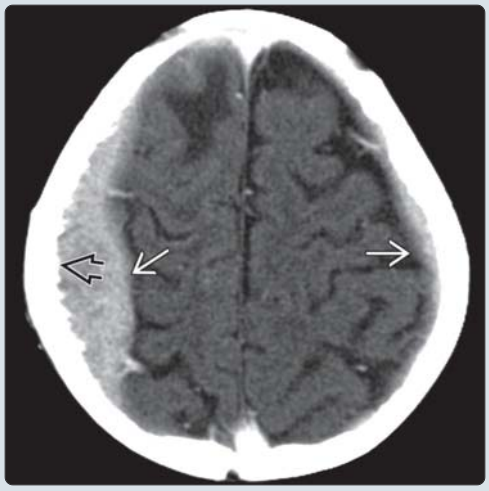

(Left) *Axial CECT in a 2-year-old male with neuroblastoma shows strong, heterogeneously enhancing epidural masses ➡ with mass effect and edema in frontal lobe.* **(Right)** *Cephalad CECT scan in the same case shows strongly enhancing epidural masses ➡. Irregularity of overlying skull ⇨ indicates calvarial involvement. Intracranial involvement in neuroblastoma is typically from adjacent calvarial metastases with dural invasion. Brain parenchymal metastases are rare.*

https://CafePezeshki.IR

TERMINOLOGY

Abbreviations

- Neuroblastoma (NB), neuroblastic tumors (NBT)

Definitions

- Malignant tumor of sympathetic nervous system arising from embryonal neural crest cell derivatives

IMAGING

General Features

- Best diagnostic clue
  - Spiculated periorbital bone mass causing proptosis in child with "raccoon eyes"
- Location
  - Cranial metastases nearly always extradural calvarial-based masses
    - Calvaria, orbit, skull base
  - Brain metastases rare but ↑ with improved treatment protocols, stage IV metastatic disease
    - CNS NB is sole site of disease recurrence in 64% of high-risk patients
    - CNS may represent "sanctuary site" for NB
    - Most parenchymal NB mets supratentorial, hemorrhagic
    - Leptomeningeal, intraventricular lesions also occur
- Morphology
  - Crescentic or lenticular, following contour of bone
  - Typically poorly defined
- Classic imaging appearance: "Hair on end" spiculated periostitis of orbits and skull, ± bony destruction

Radiographic Findings

- Coronal suture widening and periosteal new bone

CT Findings

- NECT
  - Best for showing fine spicules of periosteal bone projecting off skull or sphenoid wings
  - Soft tissue mass typically iso- to hyperdense to brain
    - May mimic epidural or subdural hematoma
  - Mass projects into orbit (extraconal), with extension to surrounding spaces, not preseptal space
  - May project through inner and outer tables of skull
  - May be bilateral
- CECT
  - Enhancing dural metastasis if intracranial
  - Rare ring-enhancing brain parenchymal metastasis

MR Findings

- T1WI
  - Slightly heterogeneous
  - Hypointense to muscle
- T2WI
  - Heterogeneous
  - Hypointense to brain
  - Slightly hyperintense to muscle
- FLAIR: Heterogeneous; hyperintense to muscle
- T2* GRE: Hypointense
- T1WI C+: Vigorously enhances, may be heterogeneous
- MRV: May narrow or invade adjacent dural sinuses

Nuclear Medicine Findings

- Bone scan
  - MIBG (meta-iodobenzylguanidine)
    - Catecholamine analog
    - Labeled with iodine-131 or iodine-123
    - Avid uptake by neural crest tumors
      - NB, ganglioneuroblastoma, ganglioneuroma, carcinoid, medullary thyroid carcinoma
    - 99% specific for NBT
    - Caveat: Up to 30% of NB not MIBG positive
      - Misses 50% of recurrent tumors
    - Cannot distinguish marrow disease from bone disease
  - Tc-99m-MDP (methylene diphosphonate)
    - Increased uptake from calcium metabolism of tumor not specific to neural crest tissue
    - 74% sensitivity for bony metastases
    - May distinguish marrow from bone disease
    - Bone scan essential for differentiating stage IV disease from stage IV-S in children < 1 year
  - In111 pentetreotide
    - Somatostatin analog
    - Not specific to NBT; not superior to MIBG
- PET
  - FDG PET has shown high sensitivity and specificity for recurrent tumor in small numbers of cases
  - FDG PET may identify recurrence when MIBG negative due to dedifferentiation

Imaging Recommendations

- Best imaging tool
  - CT/MR to evaluate primary tumor
  - Nuclear medicine MIBG & Tc-99m-MDP bone scan
  - Brain/orbit CT if scintigraphy indicates metastases
- Protocol advice
  - MR C+ and FS complementary to CT

DIFFERENTIAL DIAGNOSIS

Leukemia

- Dural- or calvarial-based masses
- More frequent parenchymal masses
- Less heterogeneous on MR

Langerhans Cell Histiocytosis (LCH)

- Lytic bone lesions without periosteal new bone
- Often associated with diabetes insipidus

Extraaxial Hematoma

- Subdural or epidural hematoma
- Bleeding disorder or child abuse to be considered

Ewing Sarcoma

- < 1% of cases involve skull
- Aggressive bone destruction
- Spiculated periosteal reaction

Osteosarcoma

- Rarely primary in calvaria

Rhabdomyosarcoma

- Most common soft tissue malignancy of pediatric orbit
- Less likely bilateral; may invade preseptal space

https://CafePezeshki.IR

Beta Thalassemia Major

- Classic "hair on end" calvarial expansion
- Not focal or destructive like neuroblastoma

PATHOLOGY

General Features

- Etiology
  - Arises from pathologically maturing neural crest progenitor cells
  - Primary tumors arise at sites of sympathetic ganglia
  - No known causative factor
- Genetics
  - Multiple gene loci associated with NB 1p, 4p, 2p, 12p, 16p, 17q
    - *Myc-N* oncogene (chromosome 2) important marker
    - 35% have chromosome 1 short arm deletion
  - 1-2% of cases inherited
- Associated abnormalities
  - Rarely associated with Beckwith-Wiedemann syndrome, neurofibromatosis type 1
  - Some association with neurocristopathy syndromes
    - Hirschsprung disease, congenital central hypoventilation, DiGeorge syndrome

Staging, Grading, & Classification

- Calvarial metastases indicate stage IV disease
- International Neuroblastoma Staging System
  - Stage I: Confined to primary organ
  - Stage IIA: Unilateral tumor, no positive lymph nodes (LN)
  - Stage IIB: Unilateral tumor, unilateral positive LN
  - Stage III: Contralateral involvement
  - Stage IV: Distal metastases
  - Stage IV-S: < 1 year at diagnosis, stage I or II + metastatic disease confined to skin, liver, or bone marrow

Gross Pathologic & Surgical Features

- Grayish-tan soft nodules
- Infiltrating or circumscribed without capsule
- Necrosis, hemorrhage, and calcifications variable

Microscopic Features

- Undifferentiated round blue cells with scant cytoplasm, hyperchromatic nuclei
- May form Homer Wright rosettes
- Ganglioneuroblastoma has interspersed mature ganglion cells
  - Different regions of same tumor may have ganglioneuroblastoma or NB

CLINICAL ISSUES

Presentation

- Most common signs/symptoms
  - "Raccoon eyes" (periorbital ecchymosis)
  - Palpable calvarial masses
- Other signs/symptoms
  - Palpable abdominal or paraspinal mass
  - Cranial metastatic disease rarely occurs in isolation
- Clinical profile
  - Ophthalmic manifestation in 20-55% at presentation
    - Proptosis and "raccoon eyes," 50% bilateral
    - Horner syndrome
    - Opsoclonus, myoclonus, and ataxia
      - Myoclonic encephalopathy of infancy
      - Paraneoplastic syndrome (not metastatic)
      - Up to 2-4% of NB patients; more favorable prognosis
  - Elevated vasoactive intestinal peptides (VIP)
    - Up to 7% of NBT patients
    - Diarrhea, hypokalemia, achlorhydria
  - Elevated homovanillic acid and vanillylmandelic acid in urine (> 90%)

Demographics

- Age
  - Median at diagnosis: 22 months
  - 40% diagnosed by 1 year
  - 35% between 1-2 years
  - 25% > 2 years
  - 89% by 5 years
- Gender
  - M:F = 1.2:1
- Epidemiology
  - Most common solid extracranial tumor in patients < 5 years
  - 8-10% of all childhood cancers
  - Most common tumor in patients < 1 month (congenital)
  - Bony metastasis most common, 2/3 of patients at diagnosis
  - 1-2% spontaneously regress in 6-12 months, mostly stage IV-S
  - NB is most common and aggressive of NBT

Natural History & Prognosis

- Stage I, II, and IV-S have 3-year event-free survival (EFS) of 75-90%
- Stage III: < 1 year old (80-90%) 1-year EFS; > 1 year old (50%) 3-year EFS
- Stage IV: < 1 year old (60-75%) 1-year EFS; > 1 year old (15%) 3-year EFS
- Poor prognostic indicators: Deletion of 1p, translocation of 17q, *Myc-N* amplification
- Good prognostic indicators: Localized disease, stage IV-S, decreased *Myc-N* amplification

Treatment

- Surgical resection + chemotherapy, radiation
- Bone marrow transplant
- Stage IV-S may spontaneously regress

DIAGNOSTIC CHECKLIST

Consider

- Abdominal imaging to identify primary tumor site

Image Interpretation Pearls

- CT without contrast can help identify bone spicules, eliminating LCH from differential

SELECTED REFERENCES

1. Nabavizadeh SA et al: Imaging findings of patients with metastatic neuroblastoma to the brain. Acad Radiol. 21(3):329-37, 2014
2. Wiens AL et al: The pathological spectrum of solid CNS metastases in the pediatric population. J Neurosurg Pediatr. 14(2):129-35, 2014

https://CafePezeshki.IR

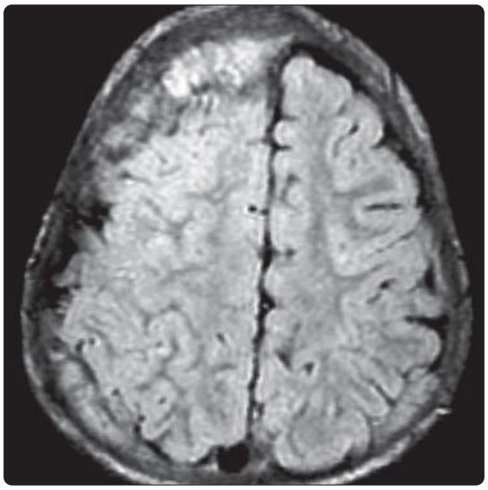

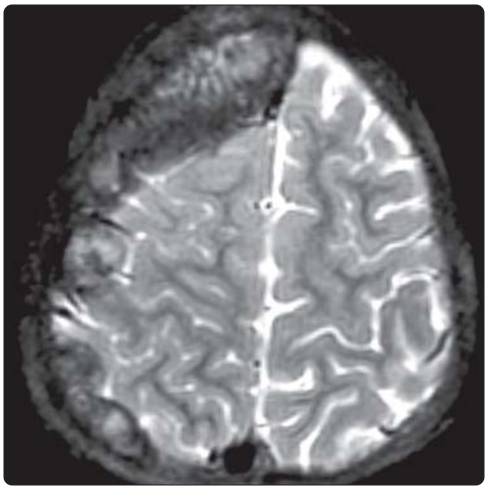

(Left) *Axial FLAIR MR shows heterogeneous signal in a patient with extradural metastatic neuroblastoma. Little reactive change is seen in the underlying brain parenchyma despite significant mass effect.* **(Right)** *Axial T2WI MR in the same case shows heterogeneous and hypointense signal in this metastatic neuroblastoma. T2 hypointensity is characteristic of densely cellular masses with high nuclear to cytoplasmic ratio.*

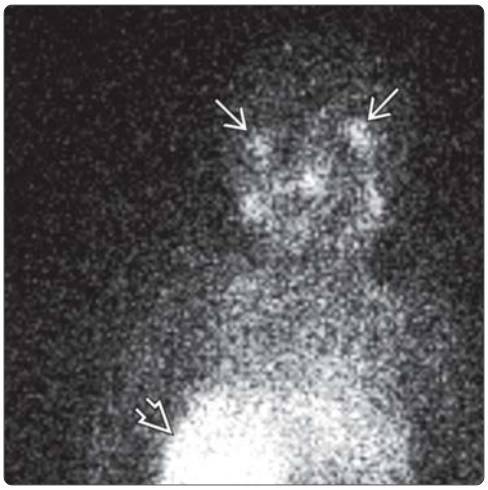

(Left) *Coronal I-123-labeled MIBG scan shows areas of increased uptake in the orbits related to neuroblastoma metastases. Note the large area of uptake in the right abdomen from the primary tumor. Although MIBG scanning is highly specific for neuroblastic tumors, up to 30% of primary and 50% of recurrent neuroblastomas do not take up MIBG.* **(Right)** *Coronal T1WI C+ MR shows an enhancing convexity mass centered at the diploic space with subperiosteal and epidural components in a child with neuroblastoma.*

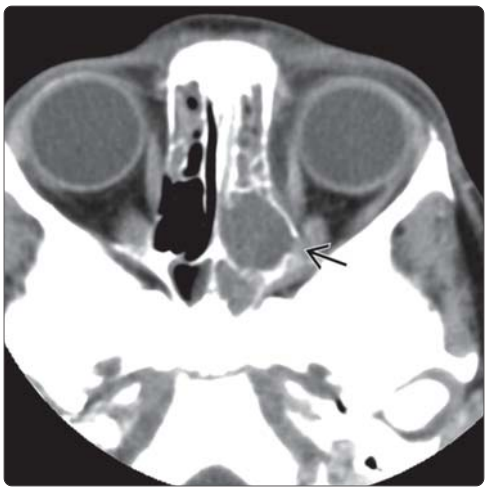

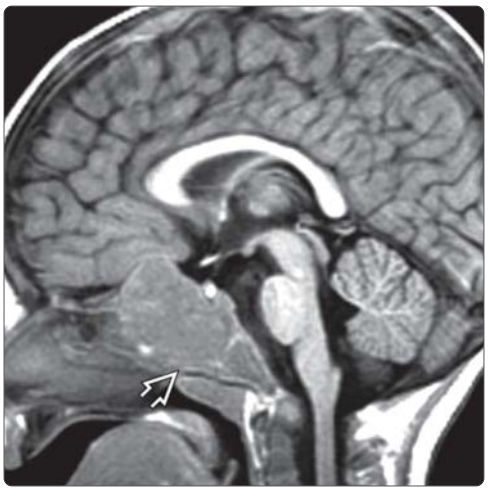

(Left) *Axial NECT in a child with neuroblastoma shows an ethmoid mass. There is a small focus of bony erosion suggesting the correct diagnosis of neuroblastoma metastasis.* **(Right)** *Sagittal T1WI MR shows a mildly heterogeneous, large, central skull base mass with marked expansion of the clivus in this 2 year old with stage IV neuroblastoma. Imaging mimics other malignancies. Neuroblastoma metastases most commonly involve the calvaria or orbital region.*

https://CafePezeshki.IR

KEY FACTS

TERMINOLOGY

- Benign encapsulated nerve sheath tumor composed of differentiated neoplastic Schwann cells
  - 99% of all schwannomas associated with cranial nerves
  - 95% involve CN8
  - < 1% of all intracranial schwannomas are intraparenchymal

IMAGING

- CT
  - Iso- to slightly hyperdense compared to brain
  - Adjacent bone, foramina may show smooth, scalloped enlargement
  - Avid, sometimes heterogeneous enhancement
- MR
  - Heterogeneously hyperintense on T2WI, FLAIR
  - 100% enhance (avid, heterogeneously)

TOP DIFFERENTIAL DIAGNOSES

- CN schwannoma (enlarged, enhancing cranial nerve[s])
  - Metastases
  - Lymphoma
  - Multiple sclerosis
  - Neurofibromatosis type 2
  - Schwannomatosis
- Parenchymal schwannoma (rare)
  - Ganglioglioma
  - Pleomorphic xanthoastrocytoma
  - Pilocytic astrocytoma

PATHOLOGY

- Spindle-shaped neoplastic Schwann cells
- Single cell type with 2 basic histologic patterns
  - High cellularity (Antoni A pattern)
  - Low cellularity ± lipidization ± cystic degeneration (Antoni B pattern)

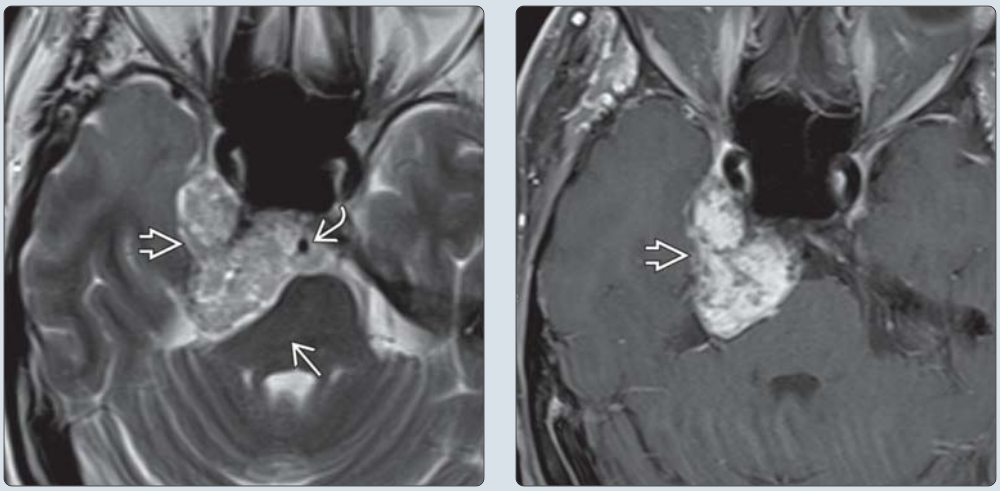

(Left) *Right trigeminal nerve schwannoma in a 58-year-old man. Axial T2WI shows a heterogeneously hyperintense mass ⇨ extending from the cisternal segment through trigeminal cave, effacing the pons ⇨ and contacting the basilar artery ⇨.* **(Right)** *Heterogeneous, but avid enhancement is seen in solid portions of the tumor ⇨.*

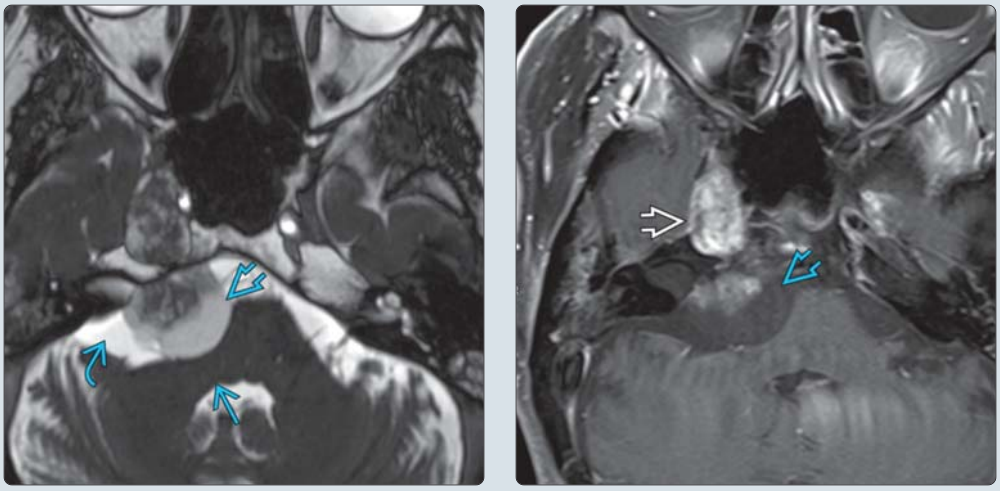

(Left) *Axial CISS MR imaging in the same patient demonstrates a tumor-associated cyst ⇨, which is hyperintense to brain, but hypointense relative to CSF ⇨. This contributes to mass ⇨ effect upon the pons and brachium pontis.* **(Right)** *The tumor-associated cyst is non-enhancing ⇨, in contradistinction to the solid portions of the schwannoma ⇨.*

https://CafePezeshki.IR

TERMINOLOGY

Abbreviations

- Nonvestibular schwannoma (nVS)

Synonyms

- Neurilemmoma, neurinoma

Definitions

- Benign encapsulated nerve sheath tumor composed of differentiated neoplastic Schwann cells

IMAGING

General Features

- Best diagnostic clue
  - T2 hyperintense, avid but heterogeneously enhancing cranial nerve mass
- Location
  - Extraaxial
    - 99% of all intracranial schwannomas are extraaxial
      - Arise from a cranial nerve
    - 95% associated with CN8 (vestibular schwannoma [VS])
      - VS = 2nd most common extraaxial tumor in adults (meningioma is most common)
      - VS accounts for ~ 90% of all CPA-IAC masses
    - Between 1-5% of intracranial schwannomas are nonvestibular schwannomas
    - Relative incidence of nVSs
      - Trigeminal nerve (CN5) 2nd most common schwannoma
      - Schwannomas of all other CNs are uncommon
      - CN9 > 10 > 7 > 11 > 12
      - Nonvestibular schwannomas of CN3, 4, 6 rare in absence of neurofibromatosis type 2
      - Multiple nVSs should raise suspicion for Schwannomatosis
  - Intraparenchymal
    - < 1% of all intracranial schwannomas
  - Schwannomas can be solitary or multiple
    - Solitary (sporadic) schwannoma
    - Multiple schwannomas
      - Neurofibromatosis type 2
      - Schwannomatosis
- Size
  - Varies from tiny to enormous
    - Small schwannomas along oculomotor CNs (3, 4, 6)
    - Largest along CN8, 5
- Morphology
  - Smooth, well-demarcated, often lobulated

CT Findings

- NECT
  - Iso- to slightly hyperdense compared to brain
  - Look for effect on adjacent bone, foramina
    - **Smooth enlargement**
    - Thin, sclerotic but well-demarcated margins
    - CN5 schwannoma often extends into (or originates from) trigeminal cave
    - Extracranial extension of nVS (e.g., CN5, 9) more common than with VS
  - Nonneoplastic tumor-associated cyst between tumor, brain in ~ 5%
  - Ca++, gross hemorrhage uncommon
- CECT
  - Strong, sometimes heterogeneous enhancement

MR Findings

- T1WI
  - Isointense to brain
  - Tumor-associated cyst hypointense
- T2WI
  - Inhomogeneously hyperintense
  - Tumor-associated cyst very hyperintense
- FLAIR
  - Both nodule, tumor-associated cyst may be hyperintense
- T2* GRE
  - May show small "blooming" hemorrhagic foci
- DWI
  - No restriction (iso- to hyperintense to brain parenchyma on ADC)
  - May help differentiate from high cellularity malignant neoplasm (low ADC relative to brain parenchyma)
- T1WI C+
  - 100% enhance
    - Avid, usually heterogeneous
    - 10-15% have intramural cysts (nonenhancing)
    - Nonneoplastic tumor-associated cysts do not enhance

Imaging Recommendations

- Best imaging tool
  - Precontrast T1-, T2WIs; whole brain FLAIR with axial, coronal T1WI C+ FS
- Protocol advice
  - For suspected cranial nerve schwannoma
    - Add thin-section high-resolution T2WI, CISS, or 3D T2 turbo spin echo with variable flip angles (SPACE or CUBE)

DIFFERENTIAL DIAGNOSIS

CN Schwannoma

- Enlarged, enhancing cranial nerve(s)
  - Metastases
  - Lymphoma
  - Multiple sclerosis
  - Neurofibromatosis type 2
  - Neurosarcoid
  - Chronic inflammatory demyelinating polyneuropathy (CIDP)

Parenchymal Schwannoma (Rare)

- Ganglioglioma
- Pleomorphic xanthoastrocytoma
- Pilocytic astrocytoma
- Hemangioblastoma

PATHOLOGY

General Features

- Etiology

https://CafePezeshki.IR

- Benign cranial nerve tumor
  - Arises from glial-Schwann cell junction
  - Distance from brain to glial-Schwann cell junction varies according to CN
- Parenchymal schwannoma may arise from dedifferentiated neural crest cells
- Genetics
  - Inactivating **somatic** mutations of *NF2* tumor suppressor gene in 60% of sporadic schwannomas
    - Loss of remaining wild-type allele on chromosome 22q
    - Encodes Merlin (schwannomin) protein
  - Germline mutation of *SMARCB1* tumor suppressor/chromatin remodeling gene in Schwannomatosis
    - AKA *INI1*, *hSNF5*, and *BA547*
    - Located on chromosome 22, centromeric to *NF2* gene
    - Complex, multi-hit mutation interplay between SMARCB1 and NF2 in affected somatic tissues of schwannomatosis patients

Staging, Grading, & Classification

- WHO grade I

Gross Pathologic & Surgical Features

- Yellowish tan, rubbery
  - Round/ovoid
  - Encapsulated by epineurium, well delineated
- Arises eccentrically from cranial nerve
  - Nerve often appears "splayed" over schwannoma
- 15-20% have associated fluid-filled cysts
  - Most are small, intratumoral
  - Occasionally large, nonneoplastic, fluid-containing collections form between tumor and brain
- Hemorrhage
  - Small hemorrhagic foci occur but are uncommon
  - Gross hemorrhage rare (< 1%)

Microscopic Features

- Spindle-shaped neoplastic Schwann cells
- Single cell type with 2 basic histologic patterns
  - High cellularity and spindle-shaped nuclei (*Antoni A pattern*)
    - Frequent "Verocay bodies" = foci of prominent nuclear palisades separated by nuclear free zones
  - Low cellularity, disorganized matrix with common cystic degeneration (*Antoni B pattern*)
    - May represent spectrum of degenerated Antoni A
- Immunohistochemistry
  - S100 protein strongly expressed
  - Vimentin variably expressed
  - Usually GFAP negative
- Rare variant = melanotic schwannoma

CLINICAL ISSUES

Presentation

- Most common signs/symptoms
  - Cranial nerve schwannoma
    - Vestibular schwannoma
      - Unilateral sensorineural hearing loss
      - Small VS: Tinnitus, disequilibrium common
      - Large VS: Trigeminal ± facial neuropathy
    - Symptoms of nVS vary depending on which nerve is affected
  - Parenchymal schwannoma
    - Much less common
    - Seizure
    - Headache
    - Focal neurologic deficit uncommon

Demographics

- Age
  - Adult (unless neurofibromatosis type 2)
    - Age range = 30-70 years
    - Peak = 40-60 years
- Epidemiology
  - Schwannomas account for 8% of all intracranial tumors
  - Vestibular schwannoma accounts for 90% of all CPA masses
  - 90% of schwannomas are solitary
  - 5% associated with neurofibromatosis type 2
  - 5% associated with Schwannomatosis

Natural History & Prognosis

- Benign, slowly growing
- Malignant change extremely rare

Treatment

- Vestibular schwannoma
  - Resection
  - Fractionated/stereotaxic neurosurgery
- Other (nonvestibular schwannoma)
  - Varies with location

DIAGNOSTIC CHECKLIST

Consider

- Patient may have NF2 if
  - nVS in unusual location
  - > 1 schwannoma
  - Coexisting meningioma identified
- Patient may have Schwannomatosis if
  - > 1 schwannoma
  - No VS
  - Age > 35

SELECTED REFERENCES

1. Sanmillán JL et al: Supratentorial brain schwannomas: an uncommon location for a common tumour. Br J Neurosurg. 28(1):25-8, 2014
2. Bondi S et al: Non-vestibular head and neck schwannomas: a 10-year experience. Eur Arch Otorhinolaryngol. 270(8):2365-9, 2013
3. Luo W et al: Intracranial intraparenchymal and intraventricular schwannomas: report of 18 cases. Clin Neurol Neurosurg. 115(7):1052-7, 2013
4. Rousseau G et al: SMARCB1/INI1 germline mutations contribute to 10% of sporadic schwannomatosis. BMC Neurol. 11:9, 2011
5. Sughrue ME et al: The natural history of untreated sporadic vestibular schwannomas: a comprehensive review of hearing outcomes. J Neurosurg. 112(1):163-7, 2010
6. Ambekar S et al: Frontal intraparenchymal Schwannoma–case report and review of literature. Br J Neurosurg. 23(1):86-9, 2009
7. Asthagiri AR et al: Neurofibromatosis type 2. Lancet. 373(9679):1974-86, 2009
8. Azarpira N et al: Cytologic findings in pigmented melanotic schwannoma: a case report. Acta Cytol. 53(1):113-5, 2009
9. Godefroy WP et al: Surgery for large vestibular schwannoma: residual tumor and outcome. Otol Neurotol. 30(5):629-34, 2009

https://CafePezeshki.IR

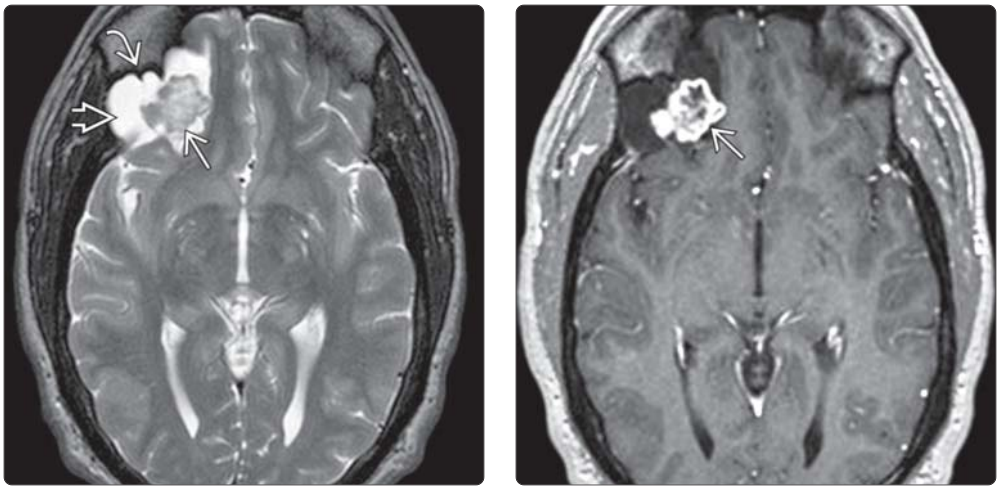

(Left) *Axial T2WI MR demonstrates a cystic mass ⇨ with a mural nodule ⇨ in the right inferior frontal lobe. Note the benign remodeling (scalloping) ⇨ of the adjacent calvaria, characterizing this as a slow-growing mass.* **(Right)** *Axial T1WI C+ MR shows avid enhancement of the mural nodule ⇨. Most intracranial schwannomas are extraaxial, associated with cranial nerves. Parenchymal schwannomas are rare (< 1% of schwannomas), commonly seen as a cyst with a mural nodule.*

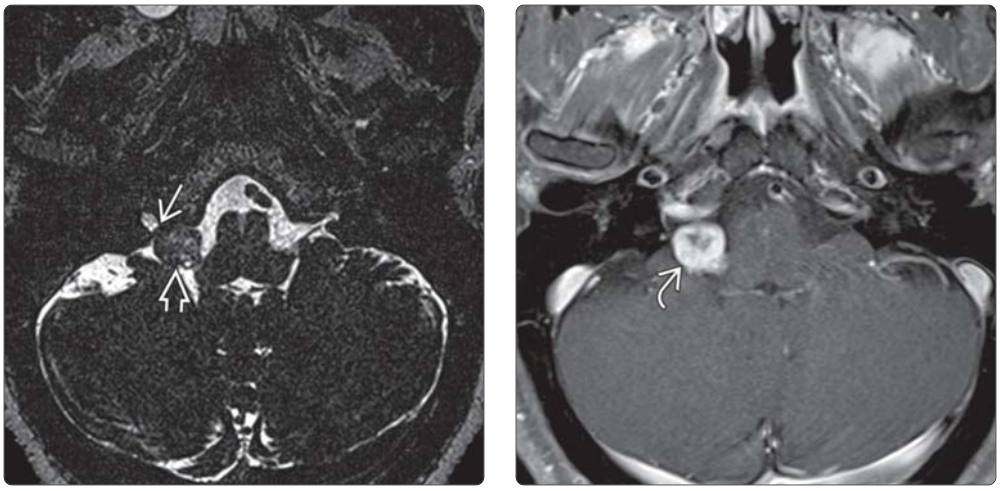

(Left) *Axial T2 SPACE of a 57-year-old man with schwannoma demonstrates a heterogeneously hypointense mass ⇨ in the right cerebellopontine angle, extending just to the jugular foramen ⇨.* **(Right)** *There is avid, targetoid enhancement ⇨, consistent with schwannoma. Given location and extension, this may be of CN 9, 10, or 11 origin. Central non-enhancement corresponds to an area of T2 hyperintensity (not shown), often seen in Antoni B regions of hypocellularity and myxoid stroma.*

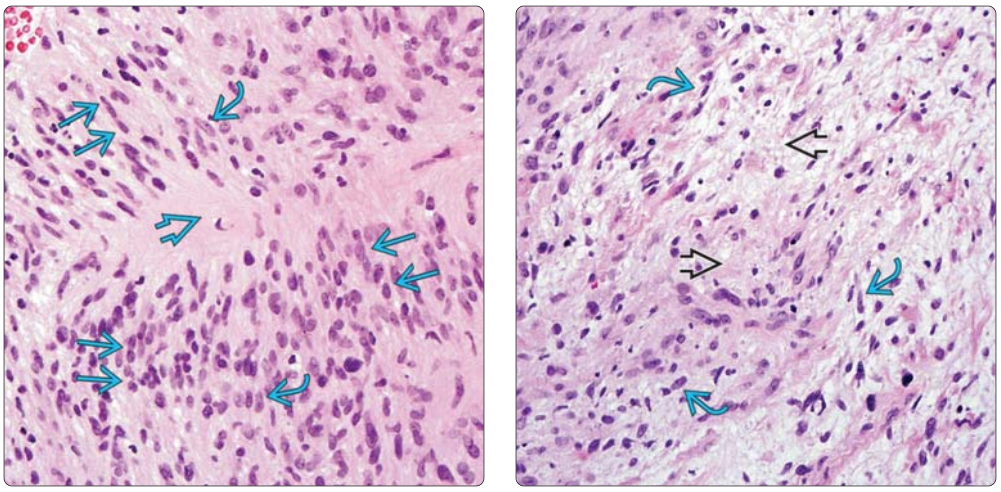

(Left) *Photomicrograph (H&E, 400x) demonstrates typical features of a high cellularity (Antoni A) region within a schwannoma. Spindle-shaped nuclei ⇨ are arranged in palisades ⇨ surrounding a nuclear-free zone ⇨, a so-called Verocay body that is characteristic of an Antoni A region.* **(Right)** *In contrast, Antoni B pattern is a low-cellularity region characterized by a spindle-shaped nuclei ⇨ in a background of myxoid stroma ⇨, often manifesting higher T2 signal on MR imaging.*

https://CafePezeshki.IR

KEY FACTS

TERMINOLOGY

- PNF: Infiltrative extraneural tumor
  - Occurs exclusively in neurofibromatosis type 1 (NF1)
- SNF: Round/ovoid subcutaneous mass
  - Usually solitary, not associated with NF1

IMAGING

- General features
  - PNF: NF1 patient with poorly delineated, infiltrating, worm-like, soft tissue mass
  - PNF: Orbit (CNV1), scalp, parotid gland
  - SNF: Well-circumscribed, round/oval scalp mass
  - SNF: Skin, spinal, or peripheral nerve roots (rarely, if ever, involves cranial nerves [CN])
- CT
  - PNF infiltrates CNV1
  - May enlarge superior orbital fissure
  - May extend intracranially into cavernous sinus
  - Almost never extends beyond Meckel (trigeminal) cave
  - Moderate to avid enhancement
- MR
  - Isointense, infiltrating on T1WI
  - Hyperintense on T2WI
  - Avid, somewhat heterogeneous enhancement

TOP DIFFERENTIAL DIAGNOSES

- Schwannoma
- Metastasis
- Malignant peripheral nerve sheath tumor (MPNST)
- Sarcoma

CLINICAL ISSUES

- 2-12% of PNFs degenerate into MPNST

DIAGNOSTIC CHECKLIST

- Look for other imaging stigmata of NF1 (optic nerve/pathway glioma, skeletal and vascular dysplasias, WM lesions, spinal dural ectasia, lateral spinal meningocele, etc.)

(Left) *Axial graphic shows extensive plexiform neurofibroma of the right face and orbit, resulting in proptosis.* **(Right)** *Axial T2WI FS MR shows a large, multilobulated, right cavernous sinus mass ⇨ with extension through markedly enlarged superior orbital fissure into the retrobulbar space ⇨. Note the right temporal scalp involvement ⇨. Plexiform neurofibromas in and around the orbit and scalp rarely have this degree of intracranial involvement.*

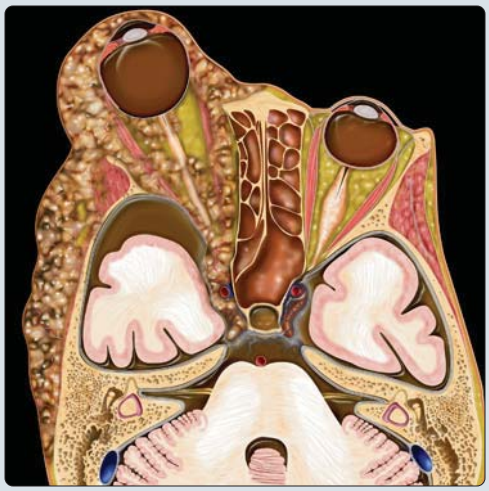

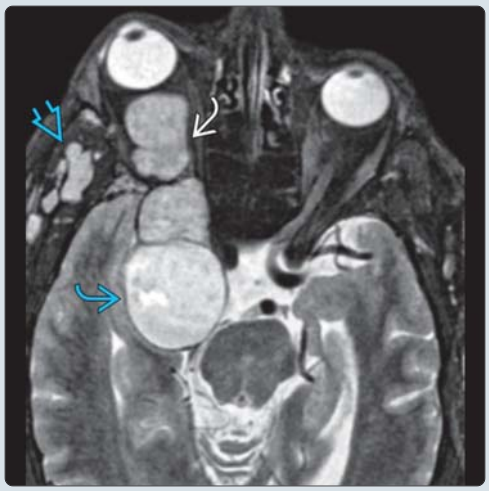

(Left) *A 4-year-old boy with progressive left facial weakness is shown. Sagittal oblique reconstruction of T1 C+ SPGR MR demonstrates abnormal enhancement along the tympanic ⇨ and descending mastoid ⇨ segments of the left facial nerve.* **(Right)** *Intraoperative photograph of subsequent resection of a symptomatic left facial nerve neurofibroma is shown. The patient has undergone left middle cranial fossa approach mastoidectomy & the enlarged facial nerve ⇨ is identified prior to en bloc resection.*

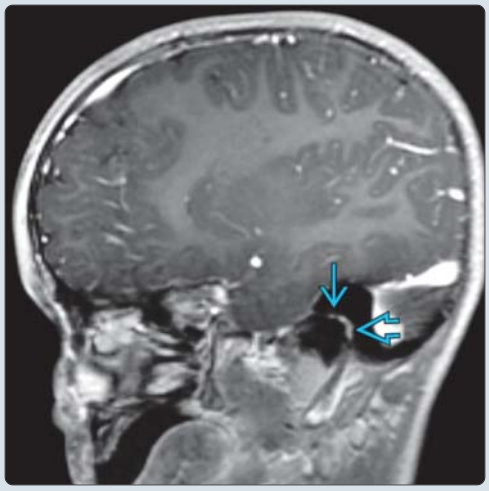

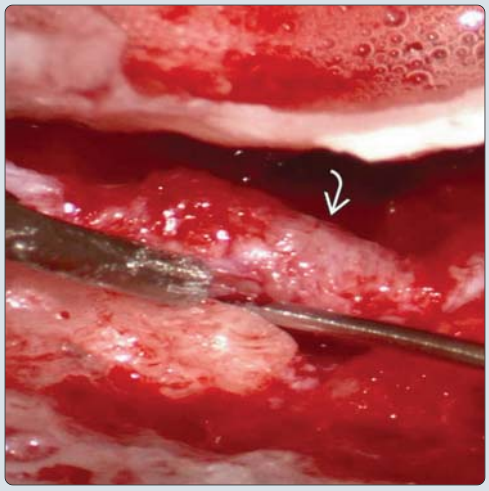

https://CafePezeshki.IR

TERMINOLOGY

Abbreviations

- Neurofibroma (NF)

Definitions

- Plexiform neurofibroma (PNF): Infiltrative extraneural tumor
  - Occurs exclusively in patients with NF1
- Solitary neurofibroma (SNF): Round/ovoid subcutaneous mass
  - Not associated with NF1

IMAGING

General Features

- Best diagnostic clue
  - PNF: NF1 patient with poorly delineated, worm-like, soft tissue mass infiltrating scalp, orbit, or parotid gland
  - SNF: Well-circumscribed, round/oval scalp mass
- Location
  - PNF: Orbit (CNV1) most common head/neck site
    - Scalp, parotid gland (CN7)
    - Spinal, peripheral nerve roots
  - SNF: Skin, spinal, or peripheral nerve roots
    - Rarely (if ever) involves cranial nerves
- Morphology
  - Can be small or large; well demarcated (SNF) or diffusely infiltrating (PNF)

CT Findings

- NECT
  - Plexiform NF
    - Mass infiltrates CNV1
    - PNFs may enlarge orbital fissure, extend into cavernous sinus (almost never posterior to trigeminal cave)
    - Other sites: Scalp, skull base (e.g., parotid gland, pterygopalatine fossa)
- CECT
  - Moderate/strong enhancement

MR Findings

- T1WI
  - Plexiform NF = isointense infiltrating mass
- T2WI
  - Hyperintense
- T1WI C+
  - Enhances strongly, sometimes heterogeneously

Imaging Recommendations

- Best imaging tool
  - MR ± contrast
- Protocol advice
  - PNF: Scan entire neuraxis to detect other manifestations of NF1

DIFFERENTIAL DIAGNOSIS

Schwannoma

- Usually solitary, well circumscribed
- May involve CN, spinal nerve roots (rare in scalp)

Metastasis

- Scalp lesions rare without underlying bone/dura involvement

Malignant Peripheral Nerve Sheath Tumor

- Infiltrative, invasive

Sarcoma of Skull/Scalp

- Kaposi sarcoma (usually in AIDS patients)
- Ewing sarcoma (metastatic)

Lymphoma

- Skull, dura often involved

Vascular Malformation of Scalp

- Can be seen in patients with NF1

PATHOLOGY

General Features

- Genetics
  - Neurofibromatosis type 1 = Germline *NF1* mutation (neurofibromin tumor suppressor) with loss of remaining wild-type allele
    - Autosomal dominant, 50% new mutations
- Associated abnormalities
  - PNFs = other stigmata of NF1

Staging, Grading, & Classification

- NF = WHO grade I

Gross Pathologic & Surgical Features

- Plexiform NF may look like infiltrating bag of worms
- Solitary NF is ovoid/fusiform circumscribed nodule

Microscopic Features

- Neoplastic Schwann cells with all other cellular substrates of the nerve (fibroblasts, axons, perineurium, and mast cells)
- Matrix of collagen fibers, mucoid substances

CLINICAL ISSUES

Presentation

- Most common signs/symptoms
  - Painless scalp or skin mass

Natural History & Prognosis

- Slow growth
- 2-12% of PNFs and NFs of major nerves degenerate into malignant peripheral nerve sheath tumor

Treatment

- ± surgical resection (PNFs have high recurrence rate)

DIAGNOSTIC CHECKLIST

Consider

- Look for other imaging stigmata of NF1

SELECTED REFERENCES

1. Riccardi VM: Ketotifen suppression of NF1 neurofibroma growth over 30 years. Am J Med Genet A. ePub, 2015
2. Hirbe AC et al: Neurofibromatosis type 1: a multidisciplinary approach to care. Lancet Neurol. 13(8):834-43, 2014

https://CafePezeshki.IR

KEY FACTS

TERMINOLOGY

- Hemangioblastoma (HGBL): Highly vascular tumor of adults most commonly found in cerebellum, brainstem, spinal cord
  - 25-40% of HGBLs occur in patients with VHL

IMAGING

- Best diagnostic clue: Adult with a cerebellar mass with cyst and enhancing mural nodule
- General features
  - Adult with intraaxial posterior fossa mass
  - 50-60% cyst + "mural" nodule; 40% solid enhancing mass
  - 90-95% in posterior fossa
  - 5-10% supratentorial (around optic pathways, hemispheres; usually in VHL)

TOP DIFFERENTIAL DIAGNOSES

- Metastasis (adult)
- Pilocytic astrocytoma (child)
- Cavernous malformation (CM)
- Hereditary hemorrhagic telangiectasia (HHT)

PATHOLOGY

- WHO grade I
- Red or yellowish, well-circumscribed, unencapsulated, highly vascular mass that abuts leptomeninges
- Histology shows stromal cells, innumerable small vessels

CLINICAL ISSUES

- Headache is most common presenting symptom
- Primary therapy = surgical resection
- Begin MR screening of patients from VHL families after 10 years of age

DIAGNOSTIC CHECKLIST

- Most common posterior fossa intraaxial mass in middle-aged/older adult is metastasis, not HGBL
- Most common posterior fossa primary tumor in middle-aged/older adult is HGBL

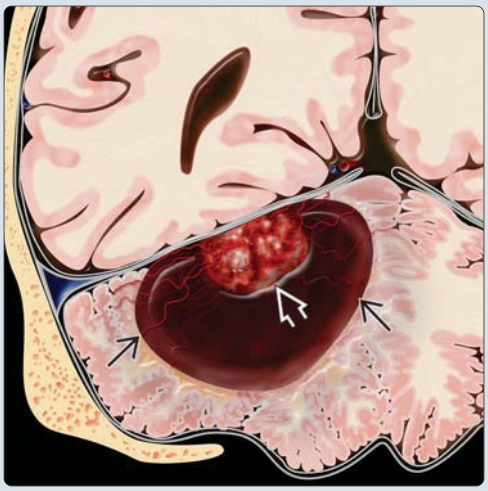

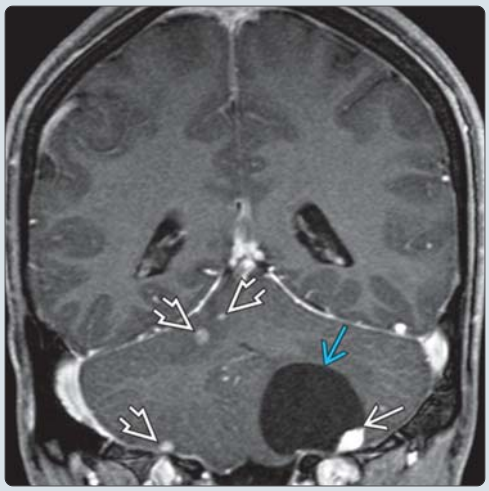

(Left) *Coronal graphic shows a classic cerebellar hemangioblastoma as largely cystic mass ⇨ with a vascular tumor nodule ➡ that abuts the pial surface. These low-grade tumors are the most common primary posterior fossa tumor in adults.* **(Right)** *Coronal T1 C+ MR shows a large cyst and mural nodule ➡ in a VHL patient with multiple hemangioblastomas. Note the lack of enhancement ⇨ of the cyst wall, which consists of compressed but normal cerebellum. The other hemangioblastomas ➡ have a solid enhancing appearance.*

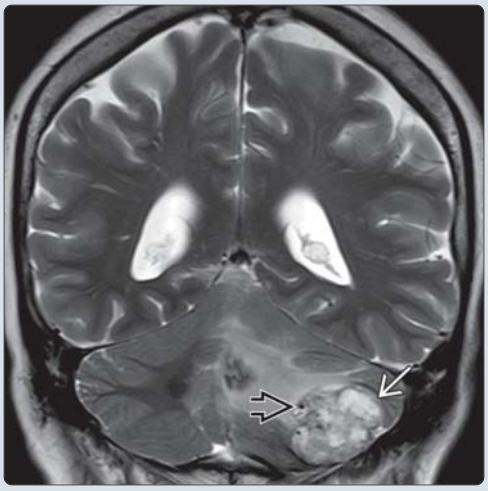

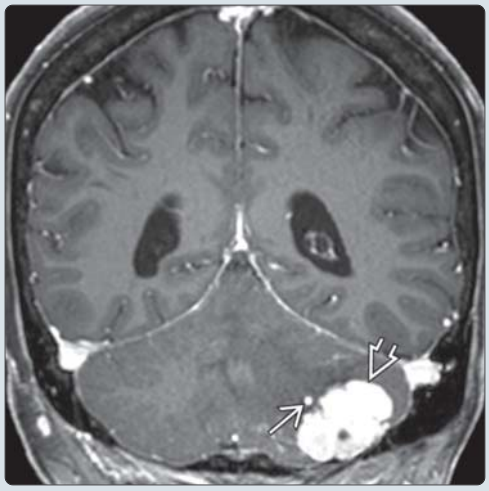

(Left) *Coronal T2 MR image in a 60-year-old woman with headaches shows a heterogeneous cerebellar mass ➡ with prominent flow voids ⇨ and surrounding edema.* **(Right)** *Coronal T1 C+ MR image in the same patient shows marked enhancement of the mass ➡ and a prominent adjacent vessel ➡. Hemangioblastoma was found at surgical resection. The main imaging differential diagnosis in this adult was metastatic disease. These WHO grade I tumors have an excellent prognosis in sporadic cases.*

https://CafePezeshki.IR

TERMINOLOGY

Abbreviations

- Hemangioblastoma (HGBL)

Synonyms

- Capillary hemangioma

Definitions

- Slow-growing, highly vascular tumor of adults most commonly found in cerebellum, brainstem, spinal cord

IMAGING

General Features

- Best diagnostic clue
  - Adult with a cerebellar mass with cyst and enhancing mural nodule abutting pia
- Location
  - Posterior fossa (90-95%)
    - Cerebellar hemispheres (80%)
    - Vermis (15%), other, e.g., medulla, 4th ventricle (5%)
  - Supratentorial (5-10%) (around optic pathways, hemispheres; usually in von Hippel-Lindau)
  - Spinal cord, typically dorsal surface
  - Rarely extraaxial dural-based mass
    - May also rarely be extramedullary in spine
- Size
  - Size varies from tiny to several cms
- Morphology
  - 50-60% cyst + "mural" nodule; 40% solid

CT Findings

- NECT
  - Low-density cyst + isodense to hyperdense nodule
  - No calcification
  - Hemorrhage is rare
- CECT
  - Nodule enhances intensely, relatively uniformly
  - Cyst wall usually does not enhance
- CTA
  - May demonstrate arterial feeders

MR Findings

- T1WI
  - Nodule isointense with brain ± flow voids
  - Cyst slightly/moderately hyperintense compared to CSF
- T2WI
  - Both nodule, cyst are hyperintense to brain
  - Prominent flow voids in some cases
- FLAIR
  - Both cyst and nodule hyperintense
- T2* GRE
  - May "bloom" if blood products present
- DWI
  - Cyst slightly or markedly low signal
- T1WI C+
  - Common: Nodule enhances strongly, intensely
  - Less common: Solid tumor enhancement
  - Rare: Ring-enhancing mass

Angiographic Findings

- Rarely performed as diagnosis is established by MR, preoperative embolization uncommon
  - Large avascular mass (cyst)
  - Highly vascular nodule
    - Prolonged blush
    - ± arteriovenous shunting (early draining vein)

Imaging Recommendations

- Best imaging tool
  - Contrast-enhanced MR (sensitivity > > CT for small HGBLs)
- Protocol advice
  - Begin MR screening of patients from von Hippel-Lindau families after 10 years of age
  - Screen complete spine, as cord lesions are common

DIFFERENTIAL DIAGNOSIS

Pilocytic Astrocytoma

- Cyst and mural nodule
- Imaging mimics HGBL
- Child or young adult

Metastasis

- Solitary posterior fossa metastasis uncommon
  - **But** most common parenchymal posterior fossa mass in > 40 year old is metastasis
- May be very vascular
- Solid > cystic
- Multiple > single
- Vascular mets (renal cell carcinoma) do not express inhibin A or GLUT1; HGBL does

Cavernous Malformation (CM)

- Heterogeneous mass with blood products
- Hemosiderin rim common
- Enhancement uncommon
- May acutely hemorrhage
- Complete hemosiderin rim typical in CMs

Glioblastoma

- Adults with irregular ring-enhancing mass
- Posterior fossa uncommon location

Vascular Neurocutaneous Syndromes

- Hereditary hemorrhagic telangiectasia (HHT)
- Wyburn-Mason
- Multiple intracranial AVMs may mimic HGBLs

PATHOLOGY

General Features

- Etiology
  - Precise histogenesis unknown
  - Presence of 2 cell types suggests undifferentiated precursor cell with angiogenic and stromal potential
  - Alternative theory: Stromal cells are neoplastic and vascular cells are nonneoplastic response to stromal VEGF
- Genetics
  - Familial HGBL (von Hippel-Lindau disease)

https://CafePezeshki.IR

  - Autosomal dominant
  - Chromosome 3p mutation
  - Suppressor gene product (VHL protein) causes neoplastic transformation
  - VEGF highly expressed in stromal cells
  - Other *VHL* gene mutations common
  - Sporadic HGBL
    - Upregulation of erythropoietin common in both sporadic, VHL-related HGBL
- Associated abnormalities
  - Secondary polycythemia (may elaborate erythropoietin)
  - 25-40% of patients with HGBL have VHL
  - Multiple HGBLs are rule in VHL
  - Other VHL markers (visceral cysts, renal clear cell carcinoma), + family history

Staging, Grading, & Classification

- WHO grade I
- Low MIB-1 index, typically < 1
- No difference between sporadic, VHL-associated HGBLs

Gross Pathologic & Surgical Features

- Red or yellowish, well-circumscribed, unencapsulated, highly vascular mass that abuts leptomeninges
  - ± cyst with yellow-brown fluid

Microscopic Features

- Nodule
  - Large vacuolated stromal cells
    - Neoplastic component
    - Lipid-containing vacuoles ("clear cell" morphology)
  - Immunohistochemistry
    - Negative for cytokeratin, EMA
    - Positive for inhibin A, GLUT1
    - Overexpress VEGF protein
  - Rich capillary network
- Cyst wall
  - Usually compressed brain (not neoplasm)
  - Variable intratumoral hemorrhage

CLINICAL ISSUES

Presentation

- Most common signs/symptoms
  - Sporadic HGBL
    - Headache (85%), dysequilibrium, dizziness
  - Familial
    - Retinal HGBL: Ocular hemorrhage often 1st manifestation of VHL
    - Other: Symptoms due to renal cell carcinoma, polycythemia, endolymphatic sac tumor

Demographics

- Age
  - Sporadic HGBL
    - Peak 40-60 years
    - Rare in children
  - Familial
    - VHL-associated HGBLs occur at younger age (rare < 15 years)
    - Retinal HGBL: Mean onset 25 years
- Gender
  - Slight male predominance
- Epidemiology
  - VHL seen in 1:36-40,000
  - < 1/2 (25-40%) HGBLs associated with VHL
  - 1-2% of primary intracranial tumors
    - 7-10% of posterior fossa tumors in adults
  - 2nd most common posterior fossa tumor in adults (after metastases)
  - 3-13% of spinal cord tumors

Natural History & Prognosis

- Usually benign tumor with slow growth pattern
  - Symptoms usually associated with cyst expansion (may occur rapidly)
  - Rare: Leptomeningeal tumor dissemination, leptomeningeal hemangioblastomatosis
- 2/3 with a single VHL-associated HGBL develop additional lesions
  - Average: 1 new lesion every 2 years
  - Require periodic screening, lifelong follow-up
  - Periods of intermixed growth, relative quiescence common with VHL-associated HGBL
  - Median life expectancy in patients with VHL: 49 years

Treatment

- En bloc surgical resection (piecemeal may result in catastrophic hemorrhage)
  - 10-year survival rate: 85%
  - Recurrence rate: 15-20%
- Preoperative embolization: Limited efficacy and usage
- Expectant management without surgery may occasionally be considered if lesion is stable and nonsymptomatic
- Some reports show good results with radiosurgery
- Evolving medical and gene target therapies

DIAGNOSTIC CHECKLIST

Consider

- Screen entire neuraxis for other HGBLs in a VHL patient

Image Interpretation Pearls

- Most common posterior fossa intraaxial mass in middle-aged/older adult is metastasis, not HGBL
- Most common posterior fossa primary tumor in middle-aged/older adult is HGBL

Reporting Tips

- Degree of mass effect
- Presence of hemorrhage
- Extent of additional screening needed

SELECTED REFERENCES

1. Kano H et al: Stereotactic radiosurgery for intracranial hemangioblastomas: a retrospective international outcome study. J Neurosurg. 1-10, 2015
2. Gorovoy IR et al: Retinal hemangioblastoma. JAMA Ophthalmol. 132(3):325, 2014
3. Liao CC et al: Clinical features and surgical outcomes of sporadic cerebellar hemangioblastomas. Clin Neurol Neurosurg. 125:160-5, 2014
4. Shin GW et al: Preoperative embolization of cerebellar hemangioblastoma with onyx: report of three cases. Neurointervention. 9(1):45-9, 2014
5. Courcoutsakis NA et al: Aggressive leptomeningeal hemangioblastomatosis of the central nervous system in a patient with von Hippel-Lindau disease. AJNR Am J Neuroradiol. 30(4):758-60, 2009

https://CafePezeshki.IR

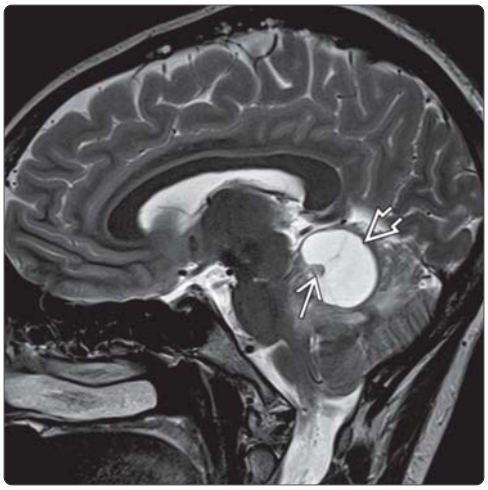

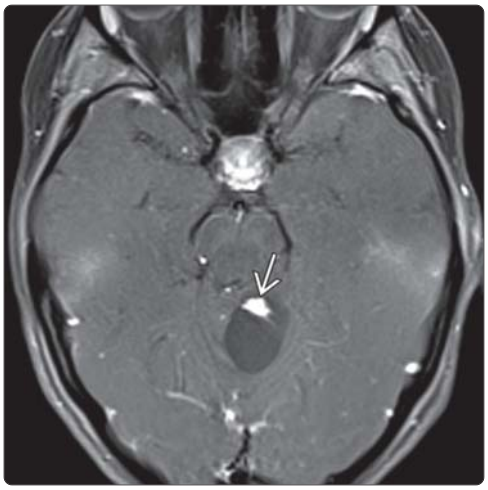

(Left) *Sagittal T2 MR in a 29-year-old woman shows a cystic ⇨ and solid ⇨ posterior fossa mass with surrounding edema.* **(Right)** *Axial T1 C+ FS MR in the same patient shows the classic cyst and mural nodule ⇨ appearance of this hemangioblastoma. In a child or young adult, the main imaging differential consideration would be a pilocytic astrocytoma.*

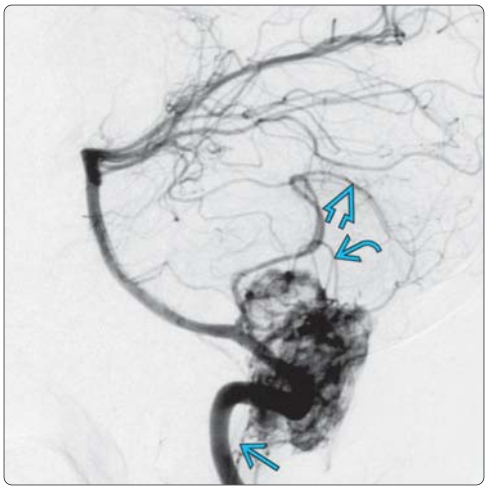

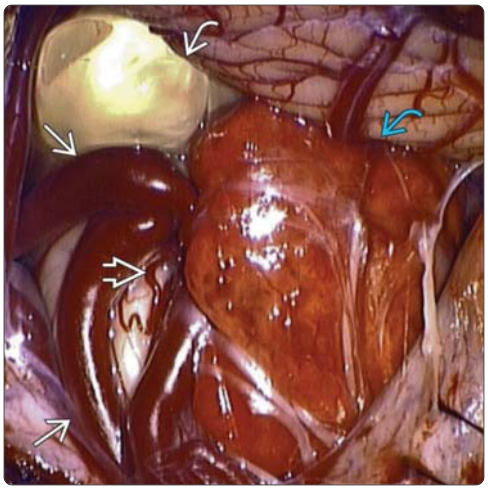

(Left) *Lateral DSA shows a highly vascular tumor nodule supplied by PICA ⇨ and branches of the vertebral and anterior spinal arteries ⇨. Avascular mass effect caused by the large associated cyst displaces the hemispheric branches superiorly ⇨.* **(Right)** *Intraoperative photograph of the same lesion shows the solid, highly vascular tumor nodule ⇨, the cystic component with yellowish fluid ⇨, and a markedly enlarged PICA ⇨ with prominent dilated feeding vessels ⇨.*

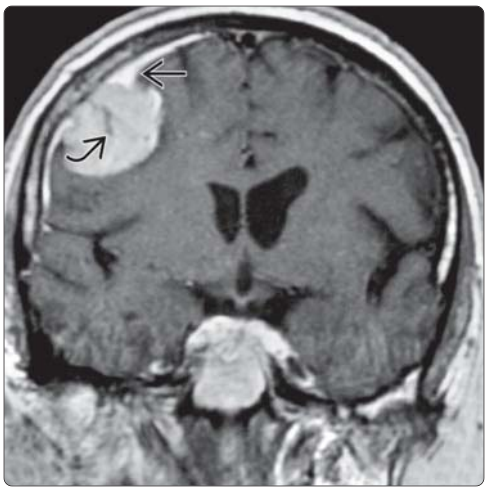

(Left) *Axial T1 C+ MR in a 35-year-old man shows a cystic and solid enhancing posterior fossa hemangioblastoma ⇨.* **(Right)** *Rare extraaxial dural-based hemangioblastoma shows diffuse enhancement with a visible central flow void ⇨. A slight enhancing dural tail is present ⇨. Imaging findings in this variant case mimic meningioma. Most supratentorial hemangioblastomas cluster around the optic nerves and chiasm. (Courtesy J. Rees, MD.)*

https://CafePezeshki.IR

KEY FACTS

TERMINOLOGY

- Highly cellular and vascularized mesenchymal tumor, nearly always attached to dura

IMAGING

- Lobular enhancing extra-axial mass with dural attachment, ± skull erosion
  - Mimics meningioma, but no Ca++ or hyperostosis
- Typically supratentorial heterogeneous, extraaxial mass; occipital region most common
- Commonly involve falx, tentorium, or dural sinuses
- Marked enhancement, often heterogeneous
- Dural "tail" seen in ~ 50%

TOP DIFFERENTIAL DIAGNOSES

- Meningioma
- Dural metastases
- Lymphoma
- Gliosarcoma

PATHOLOGY

- WHO grade II and WHO grade III (anaplastic)
- Hemangiopericytoma (HPC): Distinctive mesenchymal neoplasm unrelated to meningioma
  - Arises from primitive mesenchymal cells throughout body

CLINICAL ISSUES

- Headache is most common presenting feature
- Commonly occur in 4th-6th decades, mean: 43 years
- Represents < 1% of primary CNS tumors
- Surgical resection with radiation therapy or radiosurgery is treatment of choice
- Local recurrence common (50-90%)

DIAGNOSTIC CHECKLIST

- Consider HPC when "meningioma" has atypical features (frank bone erosion, multiple flow voids)

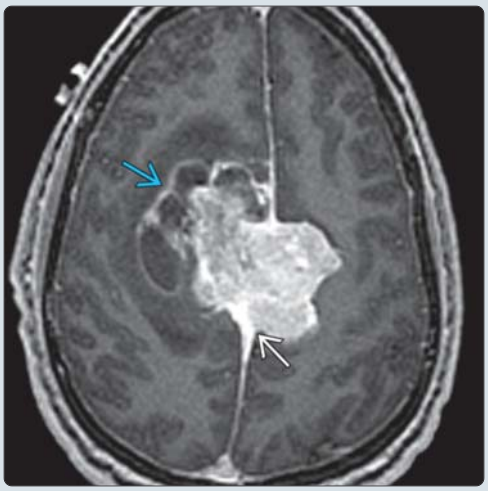

(Left) *Axial T1 C+ MR image shows a large heterogeneous, enhancing mass ⇨ attached to the falx ➡. Imaging mimics the much more common atypical meningioma. Hemangiopericytoma was diagnosed at surgical resection.* **(Right)** *Axial T1WI C+ MR shows a lobular, heterogeneously enhancing mass with central low signal ⇨, likely related to necrosis. Extension through the calvaria ⇨ is common in hemangiopericytomas. These rare tumors are typically attached to the falx, tentorium, or dural sinuses.*

(Left) *Axial T1WI C+ FS MR shows an enhancing extraaxial mass along the greater sphenoid wing that extends into the orbit. Although this mimics a meningioma, the associated bone erosion ➡, not hyperostosis, helps with the diagnosis of the more aggressive hemangiopericytoma.* **(Right)** *Gross pathology cut section shows a lobulated, circumscribed vascular mass with multiple enlarged vascular channels characteristic of hemangiopericytoma. (Courtesy R. Hewlett, MD.)*

https://CafePezeshki.IR

TERMINOLOGY

Abbreviations

- Hemangiopericytoma (HPC), meningeal hemangiopericytoma

Synonyms

- In older literature called "angioblastic meningioma," hemangiopericytic type
- New literature supports the term solitary fibrous tumor (SFT), hemangiocytoma type, cellular SFT or malignant SFT

Definitions

- Highly cellular and vascularized mesenchymal tumor, nearly always attached to dura
- Sarcoma related to neoplastic transformation of pericytes, contractile cells about capillaries
  - Occur in any region of body where capillaries are found

IMAGING

General Features

- Best diagnostic clue
  - Lobular enhancing extraaxial mass with dural attachment, ± skull erosion
  - May mimic meningioma, but without Ca++ or hyperostosis
- Location
  - Supratentorial: Occipital region most common
  - Typically involve falx, tentorium, or dural sinuses
  - Rare reports of intraparenchymal, skull base, cranial nerve, intraventricular involvement
- Size
  - Variable; 2-9 cm, often > 4 cm
- Morphology
  - Lobular dural-based extraaxial mass
    - Dural attachment may be narrow pedicle or broad based
  - Dural "tail" commonly seen, ~ 50%
  - Rarely may appear intraaxial

CT Findings

- NECT
  - Hyperdense extraaxial mass with surrounding edema
    - Low-density cystic or necrotic areas are common
  - Calvarial erosion may be seen
  - No Ca++ or hyperostosis
- CECT
  - Strong, heterogeneous enhancement

MR Findings

- T1WI
  - Heterogeneous mass, isointense to gray matter
  - Flow voids may be seen
- T2WI
  - Heterogeneous isointense mass
  - Prominent flow voids are common
  - Surrounding edema, mass effect typical
  - Hydrocephalus may be seen
- T1WI C+
  - Marked enhancement, often heterogeneous
  - Dural "tail" seen in ~ 50%
  - Central necrosis may be seen
- MRV
  - May show occlusion of dural sinuses

Angiographic Findings

- Hypervascular mass with irregular tumor vessels and prolonged, dense tumor stain
- Extensive arteriovenous shunting
- Mixed dural-pial vascular supply typical
- Preoperative embolization has been shown helpful

Nuclear Medicine Findings

- Bone scan
  - Helpful to detect extracranial metastases
- PET
  - Early FDG studies show lower metabolic rate in HPC than gray matter

Imaging Recommendations

- Best imaging tool
  - CT helpful to evaluate bone erosion
  - Multiplanar MR is most sensitive
- Protocol advice
  - Multiplanar contrast-enhanced MR, ± MRS
  - Bone scan useful in patient follow-up as extracranial metastases are common

DIFFERENTIAL DIAGNOSIS

Meningioma

- May be indistinguishable
- Enhancing extraaxial dural based mass
- Often calcified with broad dural base, dural "tail"
- Hyperostosis and Ca++ is characteristic

Dural Metastases

- Dural metastases with calvarial invasion may be indistinguishable
- Typically multiple lesions
- Primary tumor often known
  - Breast and prostate cancer most common

Gliosarcoma

- Rare glial tumor often with dural involvement
- Heterogeneously enhancing parenchymal mass

Lymphoma

- Dural involvement by lymphoma may mimic HPC
  - Diffusely enhancing dural mass, often multifocal
  - T2 low signal related to hypercellularity
- Calvarial involvement uncommon
- Flow voids usually absent

Neurosarcoidosis

- Dural-based masses can occur, often multifocal
- No calvarial involvement
- Typically leptomeningeal enhancement

Solitary Fibrous Tumor

- Circumscribed enhancing dural-based mass
- May have associated hyperostosis
- Extremely rare, < 20 reported cases

https://CafePezeshki.IR

PATHOLOGY

General Features

- Etiology
  - Distinctive mesenchymal neoplasm unrelated to meningioma
    - Considered a fibroblastic sarcoma
  - Uncertain histogenesis
    - Considered as morphological continuum with SFT
  - Arises from primitive mesenchymal cells throughout body
    - Most commonly involves soft tissues of lower extremities, pelvis, and retroperitoneum
    - ~ 15% occur in head and neck region (scalp, face, neck, sinonasal)
    - Less favorable prognosis in CNS
- Genetics
  - No consistent chromosomal losses or gains
  - Reports of abnormalities of chromosomes 12 and 3

Staging, Grading, & Classification

- WHO grade II
  - IIa: High cellularity, no necrosis, ≤ 5 mitoses/10 HPF
  - IIb: High cellularity, no necrosis, > 5 mitoses/10 HPF
- WHO grade III (anaplastic)
  - High cellularity, necrosis, and > 5 mitoses/10 HPF

Gross Pathologic & Surgical Features

- Extremely vascular with tendency to bleed at surgery
- Well-circumscribed, encapsulated firm mass with dural attachment
- Cut surface is gray to red-brown with visible vascular spaces

Microscopic Features

- Highly cellular, monotonous tumor with randomly oriented plump cells in dense reticulin network
- "Staghorn" vascular pattern characteristic
  - Lobules of tumor cells surrounding wide, branching capillaries
- Immunohistochemistry: Antibodies to factor XIIIa, Leu-7, and CD34 may help differentiate from other tumors
  - Vimentin positive
  - Epithelial membrane antigen (EMA) negative, S100 negative
- Prominent mitotic activity, median Ki-67 index (MIB-1) of 5-10%

CLINICAL ISSUES

Presentation

- Most common signs/symptoms
  - Headache
- Other signs/symptoms
  - Related to tumor location: Focal neurologic deficit, seizure

Demographics

- Age
  - Most common 4th to 6th decade, mean = 43 years
  - Occur at all ages, uncommon in children
- Gender
  - Slight male predominance
- Epidemiology
  - Represents < 1% of primary CNS tumors, ~ 0.4%
  - Represents 2-4% of all meningeal tumors
  - HPC to meningioma ratio = 1:50

Natural History & Prognosis

- Local recurrence common (50-90%)
  - Recurrence usually within 40-70 months
  - 65% recurrence at 5 years, 90% at 12 years
- Extracranial metastases common (up to 30%)
  - Commonly liver, lungs, lymph nodes, bones
  - Mean survival after metastases: 2 years
- Complications
  - Invasion of dural sinuses, bone, and cranial nerves
  - Hemorrhage (rare)
- May cause oncogenic osteomalacia
  - Rare paraneoplastic syndrome associated with mesenchymal tumors
- 5-year survival rate has improved (up to 93%)
- Complete resection and adjuvant radiation therapy improves overall survival

Treatment

- Preoperative embolization may be helpful, tumors are highly vascular
- Surgical resection with radiation therapy or radiosurgery is treatment of choice
  - Reduces risk of local recurrence
- Radiosurgery may be effective alternative to repeated surgical resection in recurrent tumors
- Chemotherapy shows some improved survival in recurrent tumors in recent reports
- Careful long-term follow-up is mandatory
  - Potential for local recurrence and metastases many years after initial diagnosis

DIAGNOSTIC CHECKLIST

Consider

- Bone erosion is most commonly seen in metastatic disease, but can suggest HPC
- Dural "tail" is nonspecific and is much more common in meningioma

Image Interpretation Pearls

- Consider HPC when "meningioma" has atypical features (frank bone erosion, multiple flow voids)

SELECTED REFERENCES

1. Damodaran O et al: Primary intracranial haemangiopericytoma: comparison of survival outcomes and metastatic potential in WHO grade II and III variants. J Clin Neurosci. 21(8):1310-4, 2014
2. Liu L et al: Comparison of ADC values of intracranial hemangiopericytomas and angiomatous and anaplastic meningiomas. J Neuroradiol. 41(3):188-94, 2014
3. Smith AB et al: From the radiologic pathology archives: mass lesions of the dura: beyond meningioma-radiologic-pathologic correlation. Radiographics. 34(2):295-312, 2014
4. Scheithauer BW et al: The 2007 WHO classification of tumors of the nervous system: controversies in surgical neuropathology. Brain Pathol. 2008 Jul;18(3):307-16. Erratum in: Brain Pathol. 18(4):640, 2008
5. Louis DN et al: WHO Classification of Tumours of the CNS: Haemangiopericytoma. Lyon: IARC Press. 178-80, 2007

https://CafePezeshki.IR

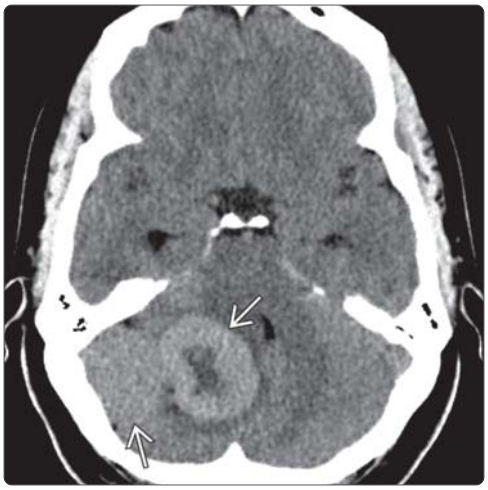

(Left) *Axial NECT shows a hyperdense posterior fossa mass* ⇨ *with local mass effect. Anaplastic hemangiopericytoma, WHO grade III was diagnosed at resection.* **(Right)** *Axial CECT shows a heterogeneously enhancing mass* ⇨ *in the occipital region with extensive bone erosion. Note the surrounding edema and mass effect. Location and appearance are typical of hemangiopericytoma. These rare tumors have a high rate of recurrence and often metastasize outside the CNS.*

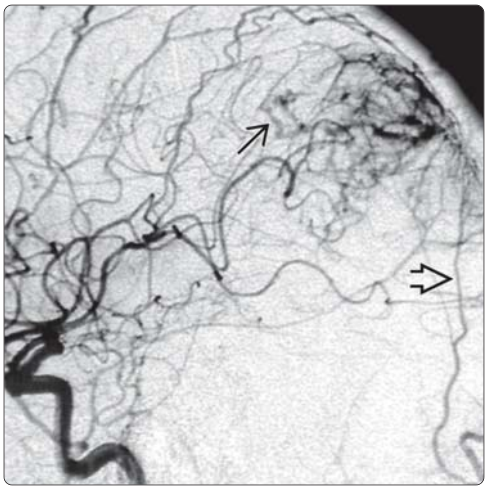

(Left) *Coronal T2 FS MR image shows a large, heterogeneous mass* ⇨ *centered in the right cerebellopontine angle, attached to the dura. Hemangiopericytoma was diagnosed at resection.* **(Right)** *Lateral ICA injection DSA shows arteriovenous shunting with early draining veins* ⇨*. An additional dural feeding vessel, a branch of the occipital artery* ⇨*, is also seen. A mixed dural-pial vascular supply is typical of hemangiopericytoma. Preoperative embolization is often helpful prior to surgical resection.*

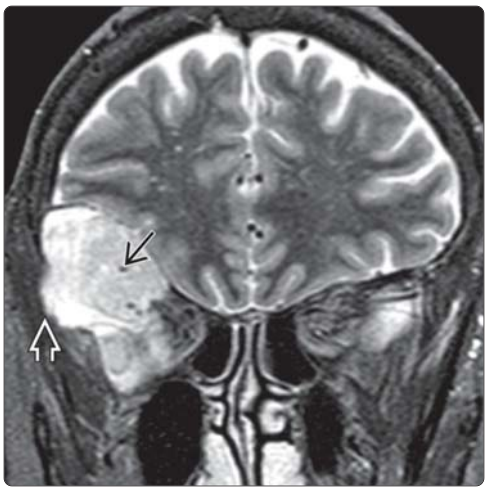

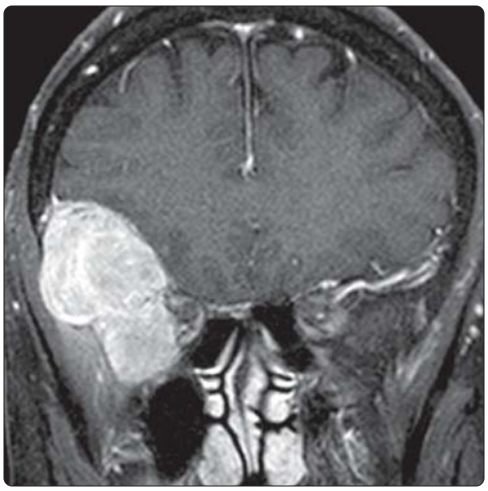

(Left) *Coronal T2WI FS MR shows a heterogeneous hyperintense mass in the inferior frontal region with central flow voids* ⇨ *and bone erosion* ⇨*, characteristic of hemangiopericytoma.* **(Right)** *Coronal T1WI C+ FS MR in the same patient shows diffuse enhancement of the lobular mass. Imaging mimics a meningioma. CT can be helpful to further define bone erosion. Other imaging differential considerations would include a dural metastasis and lymphoma.*

https://CafePezeshki.IR

KEY FACTS

TERMINOLOGY

- Malignant primary CNS neoplasm primarily composed of B lymphocytes

IMAGING

- Best diagnostic clue: Enhancing lesion(s) within basal ganglia &/or periventricular white matter
- 60-80% supratentorial
  - Often involve, cross corpus callosum
  - Frequently contact, extend along ependymal surfaces
- Classically hyperdense on CT (helpful for diagnosis)
- Diffusely enhancing periventricular mass in immunocompetent
- May see hemorrhage or necrosis in immunocompromised
- DWI: Low ADC values
- PWI: Low rCBV ratios
- Periventricular location and subependymal involvement is characteristic of PCNSL
- Corpus callosum involvement may be seen with PCNSL, glioblastoma (GBM), and rarely metastases or demyelination

TOP DIFFERENTIAL DIAGNOSES

- Acquired toxoplasmosis
- Glioblastoma (GBM)
- Abscess
- Progressive multifocal leukoencephalopathy (PML)

PATHOLOGY

- 98% diffuse large B-cell, non-Hodgkin lymphoma

CLINICAL ISSUES

- Imaging and prognosis varies with immune status
- 6.6% of primary brain tumors, incidence rising
- Poor prognosis
- Stereotactic biopsy, followed by XRT and chemotherapy is treatment of choice
- Stereotactic biopsy, followed by chemotherapy, ± XRT

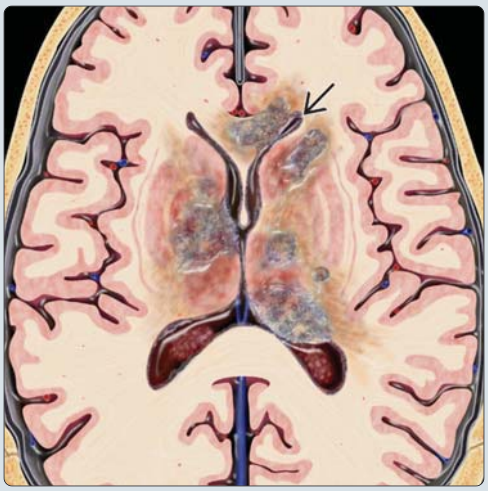

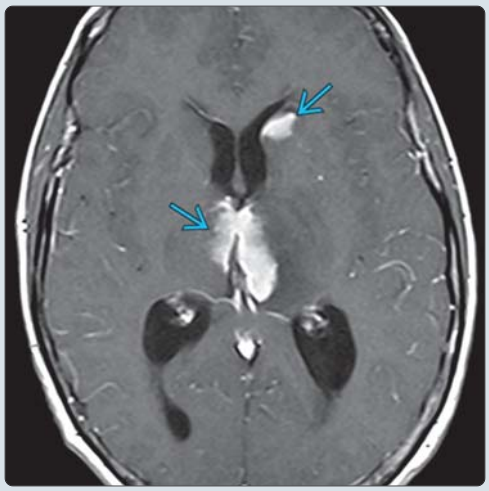

(Left) *Axial graphic shows multiple periventricular lesions with involvement of the basal ganglia, thalamus, and corpus callosum, typical of primary CNS lymphoma (PCNSL). Note the extensive subependymal spread of the disease. PCNSL typically extends along ependymal surfaces.* **(Right)** *Axial T1 C+ MR image in a 63 year old shows the classic appearance of PCNSL. Note the multiple homogeneously enhancing masses in the basal ganglia along the ependymal lining of the ventricular system.*

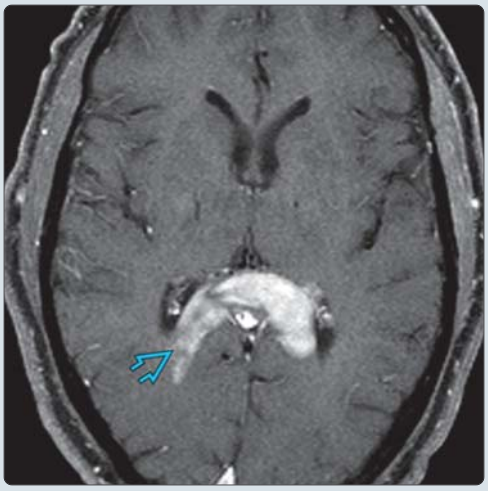

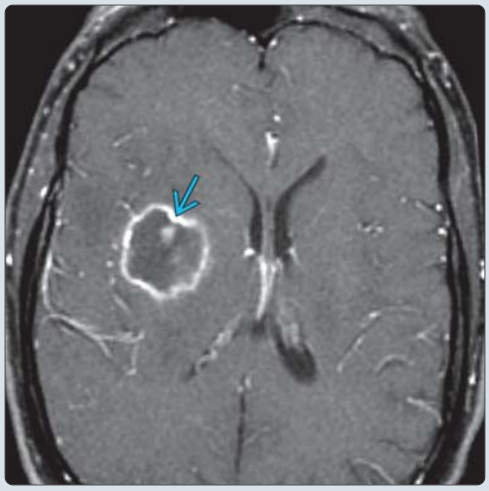

(Left) *Axial T1 C+ MR shows a homogeneously enhancing mass crossing the corpus callosum splenium typical of PCNSL in this 76-year-old man with a headache. The main differential consideration would be a glioblastoma, which typically has a more heterogeneous appearance.* **(Right)** *Axial T1WI C+ MR in an AIDS patient shows a ring-enhancing mass with a "target" sign, suggestive of toxoplasmosis. Hemorrhage, necrosis, and ring-enhancing lesions are typical of PCNSL in AIDS patients.*

https://CafePezeshki.IR

TERMINOLOGY

Abbreviations

- Primary central nervous system lymphoma (PCNSL)

Definitions

- Extranodal malignant lymphoma arising in CNS in absence of systemic lymphoma

IMAGING

General Features

- Best diagnostic clue
  - Enhancing lesion(s) within basal ganglia, periventricular white matter (WM)
- Location
  - 60-80% supratentorial
    - Frontal, temporal, and parietal lobes most common
  - Deep gray nuclei commonly affected (10%)
  - Lesions cluster around ventricles, gray-white matter junction
  - Often involve, cross corpus callosum (5-10%)
  - Frequently abut, extend along ependymal surfaces
  - Posterior fossa, sella, pineal region uncommon
  - Spine involvement rare (1%)
  - May involve leptomeninges or dura (more common in secondary lymphoma)
- Morphology
  - Solitary mass or multiple lesions
  - May be circumscribed or infiltrative

CT Findings

- NECT
  - Classically hyperdense; may be isodense
  - ± hemorrhage, necrosis (immunocompromised)
- CECT
  - Common: Moderate, uniform (immunocompetent)
  - Less common: Ring (immunocompromised)
  - Rare: Nonenhancing (infiltrative)

MR Findings

- T1WI
  - Immunocompetent: Homogeneously iso-/hypointense to cortex
  - Immunocompromised: Iso-/hypointense
    - May be heterogeneous from hemorrhage, necrosis
- T2WI
  - Immunocompetent: Homogeneously iso-/hypointense to cortex
    - Hypointensity related to high nuclear to cytoplasmic ratio
  - Immunocompromised: Iso-/hypointense
    - May be heterogeneous from hemorrhage, necrosis
    - Ca++ may rarely be seen, usually after therapy
  - Mild surrounding edema is typical
- FLAIR
  - Homogeneously iso-/hypointense
  - Immunocompromised: Iso-/hypointense
  - May be hyperintense
- T2* GRE
  - May see blood products or calcium as areas of "blooming" (immunocompromised)
- DWI
  - May show restricted diffusion
  - Low ADC values compared to malignant glioma
    - Minimal ADC lower than glioblastoma
- PWI
  - Relative CBV ratios are lower than malignant glioma
    - Relative CBV much lower than glioblastoma
- T1WI C+
  - Immunocompetent: Strong homogeneous enhancement
  - Immunocompromised: Peripheral enhancement with central necrosis or homogeneous enhancement
  - Nonenhancement extremely rare
- MRS
  - NAA ↓, Cho ↑
  - Lipid and lactate peaks reported
- Diffusion tensor imaging (DTI)
  - Low fractional anisotropy (FA) and ADC
    - FA and ADC of PCNSL significantly lower than glioblastoma (GBM)

Nuclear Medicine Findings

- FDG PET and Tl-201 SPECT: Hypermetabolic

Imaging Recommendations

- Protocol advice
  - Contrast-enhanced MR ± DWI, PWI, DTI
  - PET or Tl-201 SPECT may be helpful when toxoplasmosis is considered

DIFFERENTIAL DIAGNOSIS

Acquired Toxoplasmosis

- Involves basal ganglia, corticomedullary junction
- Enhancing lesions, "eccentric target" sign
- No ependymal spread
- Often indistinguishable on standard MR
  - DWI, DTI, perfusion may be helpful
  - SPECT, PET helpful (iso-/hypometabolic)

Glioblastoma (GBM)

- "Butterfly glioma" involving corpus callosum
- Hemorrhage common
- Enhancement typically heterogeneous
- Necrosis with ring enhancement in 95%

Abscess

- T2 hypointense rim, diffusion restriction typical
- Peripheral enhancement with central necrosis
- Enhancement often thinner on ventricular side
- MRS: Elevated amino acids in cystic cavity (low TE)

Progressive Multifocal Leukoencephalopathy

- White matter T2 hyperintensity, nonenhancing
- Involves subcortical U-fibers and corpus callosum

Demyelination

- May involve corpus callosum
- Often incomplete, horseshoe-shaped enhancement, open toward cortex

https://CafePezeshki.IR

- Other lesions in characteristic locations
- Younger patients

Metastases

- Multiple lesions common
- Significant associated vasogenic edema

Neurosarcoidosis

- "Lacy" leptomeningeal enhancement typical
- Dural, leptomeningeal > > parenchymal disease
- Most patients have systemic disease

Secondary CNS Lymphoma

- Lymphomatous meningitis or dural disease common
- Can have single/multiple deep, periventricular lesions

PATHOLOGY

General Features

- Etiology
  - Site of origin controversial as CNS does not have lymphoid tissue or lymphatic circulation
  - Inherited or acquired immunodeficiency predisposes
- Genetics
  - Clonal abnormalities in chromosomes 1, 6, 7, and 14
  - Translocations reported in (1;14), (6;14), (13;18), and (14;21)
- Associated abnormalities
  - Epstein-Barr virus (EBV) plays major role in immunocompromised (95%)
  - 8% of PCNSL patients have had prior malignancy, commonly leukemia or adenocarcinoma
  - Rarely PCNSL is preceded by demyelinating lesions

Staging, Grading, & Classification

- Majority are diffuse large B-cell, non-Hodgkin lymphoma

Gross Pathologic & Surgical Features

- Single or multiple mass(es) in cerebral hemispheres
- Well-circumscribed > infiltrative mass
- Central necrosis, hemorrhage in HIV-positive patients

Microscopic Features

- Cells surround, infiltrate vessels and perivascular spaces
- High nuclear:cytoplasmic ratio (high electron density)
- MIB-1, proliferation index, usually high (50-70%)

CLINICAL ISSUES

Presentation

- Most common signs/symptoms
  - Altered mental status, focal neurologic deficits
- Other signs/symptoms
  - Cognitive, neuropsychiatric disturbance
  - Headache, increased intracranial pressure, seizure
- Clinical profile
  - Cytology positive in 5-30% of PCNSL

Demographics

- Age
  - Immunocompetent: 6th-7th decades, mean 60 years
  - Immunocompromised
    - AIDS: Mean age 39 years
    - Transplant recipients: Mean age 37 years
    - Inherited immunodeficiency: Mean age 10 years
- Gender: Male predominance
- Epidemiology
  - 6.6% of primary brain tumors
  - Represents ~ 1% of lymphomas
  - PCNSL is present in 0.4% of AIDS patients
    - PCNSL is AIDS-defining condition
    - Highly effective antiviral therapy (HAART) has reduced occurrence of all NHL in AIDS patients
  - In post-transplant lymphoma, CNS involvement occurs in 22%

Natural History & Prognosis

- Poor prognosis
- Median survival
  - 50 months in immunocompetent
  - 36 months in AIDS patients
    - Marked improvement with HAART and XRT
- Favorable prognostic factors
  - Single lesion
  - Absence of meningeal or periventricular disease
  - Immunocompetent patient
  - Age < 60 years
    - Patients < 61 years: 5-year survival 75%
- Dramatic but short-lived response to steroids and XRT
- Rarely, PCNSL is complicated by systemic disease

Treatment

- Stereotactic biopsy, followed by chemotherapy, ± XRT
- Treatment with enhanced chemotherapy delivery with blood-brain barrier disruption may be helpful

DIAGNOSTIC CHECKLIST

Consider

- Corpus callosum involvement may be seen with PCNSL, GBM and rarely metastases, demyelination
- Steroids may dramatically ↓ mass, enhancement; mask biopsy results
- Occult systemic disease present in up to 8% of PCNSL, systemic staging helpful

Image Interpretation Pearls

- Imaging and prognosis varies with immune status
- PCNSL is characteristically hyperdense on NECT
- Periventricular location and subependymal involvement is characteristic of PCNSL

SELECTED REFERENCES

1. Lu SS et al: Histogram analysis of apparent diffusion coefficient maps for differentiating primary CNS lymphomas from tumefactive demyelinating lesions. AJR Am J Roentgenol. 204(4):827-34, 2015
2. Matinella A et al: Neurological complications of HIV infection in pre-HAART and HAART era: a retrospective study. J Neurol. 262(5):1317-27, 2015
3. Yamasaki F et al: Magnetic resonance spectroscopy detection of high lipid levels in intraaxial tumors without central necrosis: a characteristic of malignant lymphoma. J Neurosurg. 122(6):1370-9, 2015
4. Kickingereder P et al: Evaluation of microvascular permeability with dynamic contrast-enhanced MRI for the differentiation of primary CNS lymphoma and glioblastoma: radiologic-pathologic correlation. AJNR Am J Neuroradiol. 35(8):1503-8, 2014
5. Louis DN et al: WHO Classification of Tumours of the Central Nervous System: Malignant lymphomas. Lyon: IARC Press. 188-92, 2007

https://CafePezeshki.IR

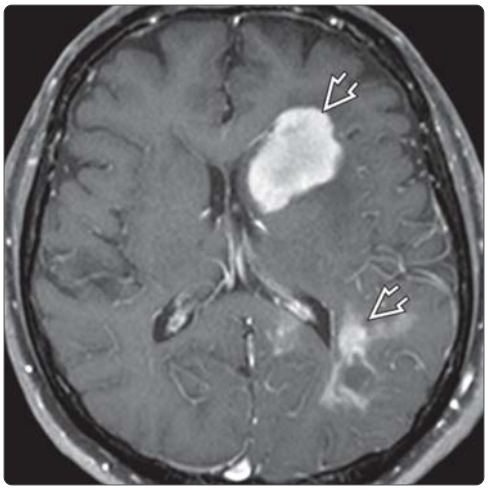

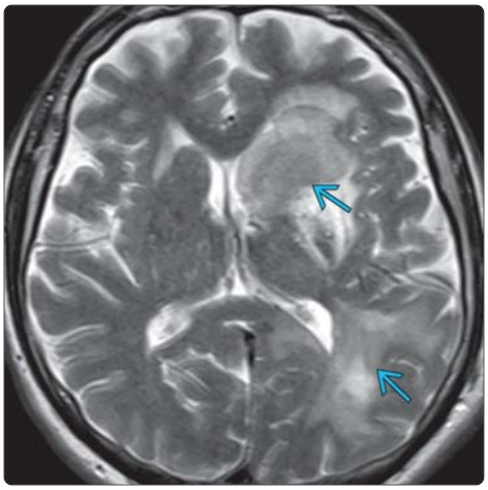

(Left) *Axial T1 C+ MR shows several enhancing masses in the periventricular white matter ➡ typical of PCNSL. It is important to recognize PCNSL as the preoperative diagnosis, as a biopsy rather than a resection is the initial treatment of choice.* **(Right)** *Axial T2 MR in the same patient shows hypointensity ⇨ within the lesions related to the high nuclear to cytoplasmic ratio within the tumor, a common finding in primary CNS lymphoma. The vast majority of primary CNS lymphoma are diffuse large, B-cell, non-Hodgkin lymphoma.*

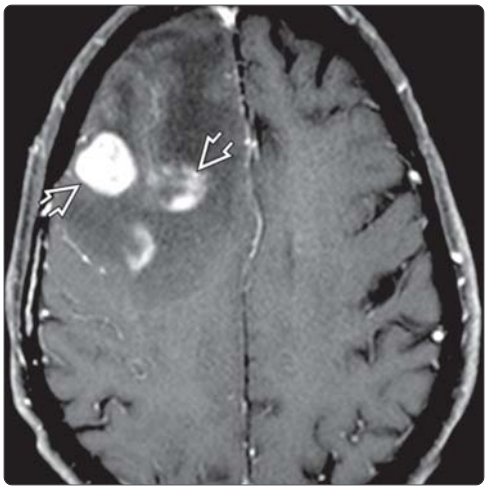

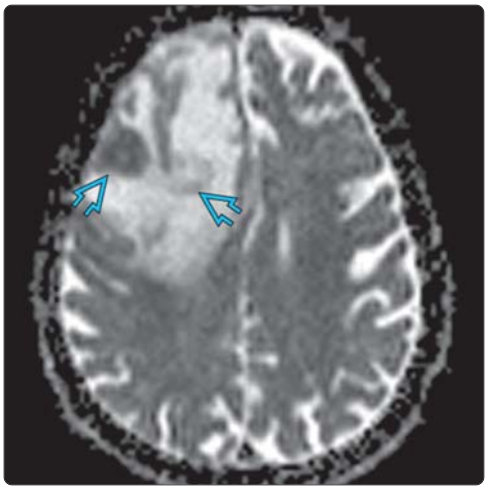

(Left) *Axial T1 C+ MR shows several enhancing masses in the right frontal lobe with smooth homogeneous enhancement ➡ typical of PCNSL. PCNSL is increasing in prevalence related to the increased number of immunocompromised patients.* **(Right)** *Axial DWI ADC map in the same patient shows the characteristic diffusion restriction within these tumors as a low ADC value ⇨. DWI has been shown to be helpful in differentiating PCNSL from other tumors and demyelinating lesions.*

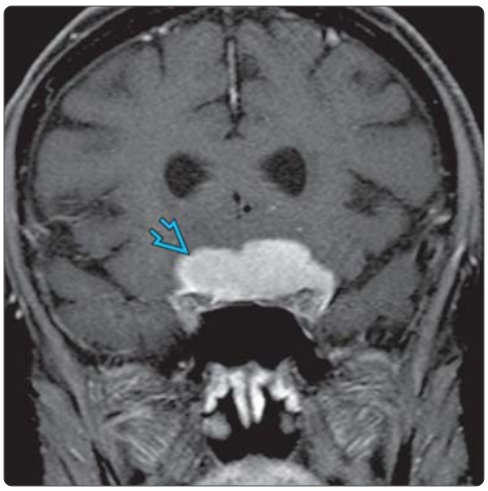

(Left) *Axial NECT shows a hyperdense mass ➡ with surrounding vasogenic edema. CT hyperdensity is characteristic of PCNSL and is helpful for an accurate preoperative diagnosis.* **(Right)** *Coronal T1 C+ FS MR shows a dural-based mass ⇨ along the anterior cranial fossa in a female patient with optic neuropathy. Imaging mimics a meningioma, but PCNSL was found at biopsy. Dural involvement is more common in secondary CNS lymphoma.*

https://CafePezeshki.IR

KEY FACTS

TERMINOLOGY

- Rare malignancy characterized by intravascular proliferation of lymphoid cells with predilection for CNS and skin

IMAGING

- T2/FLAIR multifocal hyperintensities in deep white matter, cortex, and basal ganglia
  - May mimic infarct
- Diffusion restriction common
- GRE/SWI: Multifocal hemorrhage often seen
- Linear and punctate enhancement typical
  - May see meningeal &/or dural enhancement
- Often mimics vasculitis

TOP DIFFERENTIAL DIAGNOSES

- Vasculitis
- Multi-infarct dementia
- Primary CNS lymphoma (PCNSL)
- Neurosarcoid

PATHOLOGY

- Malignant lymphoid cells occlude and distend small arteries, veins, and capillaries

CLINICAL ISSUES

- Dementia is most common presenting feature
- May present with multiple stroke-like episodes
- Presents in 5th-7th decades; mean: 60-65 years
- Diagnosis may be made by skin or brain biopsy
- Rapidly progressive disease with high mortality rate
  - Mean survival: 7-13 months
- Rare, but underdiagnosed
  - CNS involved in up to 75% of cases

DIAGNOSTIC CHECKLIST

- Imaging of intravascular lymphoma (IVL) is nonspecific, but IVL should be considered in patients with dementia, multifocal lesions, and enhancement

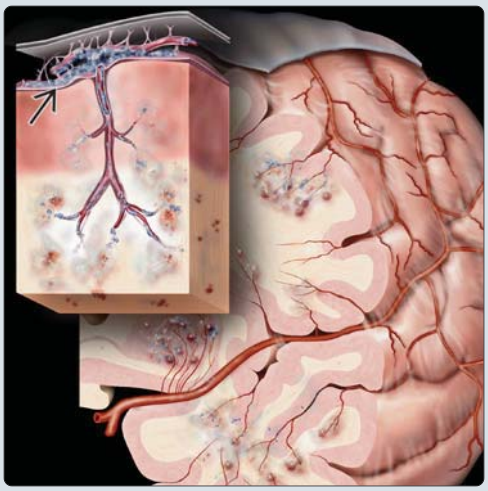

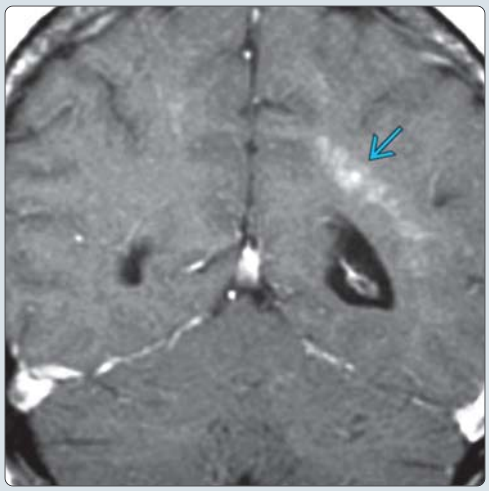

(Left) *Graphic shows malignant lymphoid cells occluding and distending small arteries, veins, and capillaries, resulting in ischemic regions. Note also the meningeal involvement ⇨ typical of intravascular lymphoma (IVL).* **(Right)** *Coronal T1WI C+ MR shows a classic multifocal linear and patchy enhancement pattern in the deep white matter ⇨ related to IVL in this patient with dementia. The enhancement occurs in regions of T2/FLAIR hyperintensity and is often the key to a correct preoperative diagnosis.*

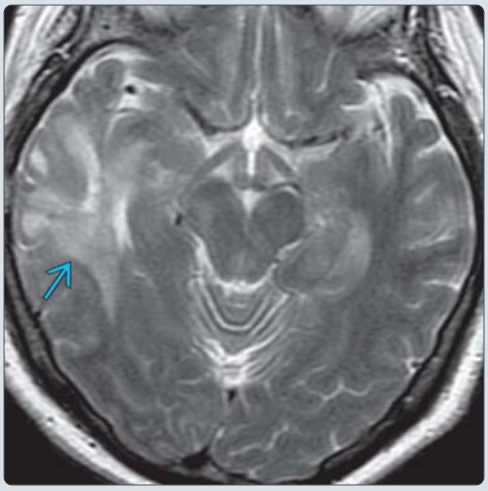

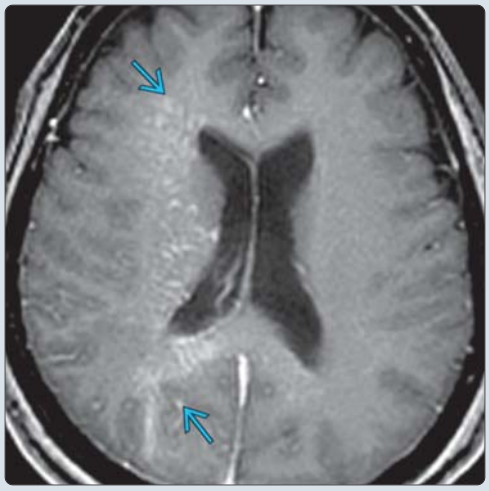

(Left) *Axial T2 MR shows confluent areas of hyperintensity in the right temporal periventricular and subcortical white matter ⇨ in this elderly patient. The T2 hyperintensities seen in IVL are nonspecific and mimic other disease processes, including chronic small vessel ischemia and vasculitis. Cortical lesions are also commonly seen.* **(Right)** *Axial T1 C+ MR in the same patient shows multifocal linear and nodular enhancement ⇨ in the periventricular and subcortical white matter, typical of IVL.*

https://CafePezeshki.IR

TERMINOLOGY

Abbreviations

- Intravascular (angiocentric) lymphoma (IVL)

Synonyms

- Intravascular malignant lymphomatosis
- Angioendotheliotropic lymphoma
- Malignant angioendotheliomatosis
- Angiotropic large cell lymphoma
- Intravascular B-cell lymphoma

Definitions

- Rare malignancy characterized by intravascular proliferation of lymphoid cells with predilection for CNS and skin
- Form of non-Hodgkin lymphoma (NHL) characterized by angiotropic growth

IMAGING

General Features

- Best diagnostic clue
  - Multifocal abnormal T2 hyperintensities in deep white matter (WM), cortex, or basal ganglia with enhancement
  - Linear and nodular enhancement commonly
  - No pathognomonic criteria for IVL
- Location
  - Supratentorial
    - Periventricular/deep WM, gray-white junction
  - May involve basal ganglia, brainstem, cerebellum
  - Spinal cord involvement reported

CT Findings

- NECT
  - Often normal or nonspecific
  - Focal, bilateral, asymmetric, low-density lesions in WM, cortex, or basal ganglia
- CECT
  - Variable enhancement
    - None to moderate

MR Findings

- T1WI
  - Multifocal hypointense lesions
  - May see blood products
- T2WI
  - Majority show hyperintensities in deep WM
    - e.g., edema, gliosis
  - May see cortex hyperintensity, infarct-like lesions (1/3 of cases)
  - Hyperintense basal ganglia lesions common
  - May see hemorrhagic transformation
- T2* GRE
  - May see blood products "blooming"
- DWI
  - Diffusion restriction common
  - Often mimics acute stroke or vasculitis
- T1WI C+
  - Variable enhancement
    - Linear, punctate, patchy, nodular, ring like, gyriform, homogeneous
  - Meningeal &/or dural enhancement
- SWI
  - Multifocal blood products related to microhemorrhage

Angiographic Findings

- Often mimics vasculitis
  - Alternating stenoses and dilatation, "beading," primarily involving 2nd and 3rd order branches

Imaging Recommendations

- Best imaging tool
  - Multiplanar MR
- Protocol advice
  - Contrast-enhanced MR with DWI

Nuclear Medicine Findings

- PET
  - FDG PET helpful in diagnosing IVL in bone marrow and kidneys

DIFFERENTIAL DIAGNOSIS

Vasculitis

- Multifocal subcortical ischemia, ± enhancement
- DWI positive in acute setting
- DSA suggests diagnosis (IVL may mimic)
- Enhancement pattern may mimic IVL (particularly granulomatous angiitis)
- Imaging and clinical features may mimic IVL

Multi-Infarct Dementia

- Large and small infarcts, WM disease
- Deep gray nuclei typically involved
- Clinical diagnosis can mimic IVL

Primary CNS Lymphoma (PCNSL)

- Enhancing lesions in basal ganglia, periventricular WM
- Corpus callosum often involved
- Ependymal involvement characteristic

Neurosarcoid

- Dural or leptomeningeal enhancement
- Brain parenchyma typically spared
- Patients often have systemic disease

Viral Encephalitis

- T2/FLAIR hyperintense lesion
- Often DWI hyperintensity, ± enhancement
- May mimic IVL on pathologic specimen

PATHOLOGY

General Features

- Etiology
  - Aggressive, malignant B-cell non-Hodgkin lymphoma, angiotropic
    - May arise from T cells or rarely NK cells
  - IVL typically affects CNS and skin
    - May affect any organ
      - Reported in kidneys, bone marrow, breast, uterus, testes, lungs, larynx, adrenal gland
- Associated abnormalities
  - Possible association with Epstein-Barr virus (EBV)
    - NK-IVL is typically EBV positive

https://CafePezeshki.IR

Gross Pathologic & Surgical Features

- Small infarcts of varying ages throughout cortex and subcortical WM
  - May be hemorrhagic, petechial > confluent macroscopic bleeds
- May appear macroscopically normal
- May cause cerebral masses (rare)

Microscopic Features

- Accumulations of large B cells typical
- Malignant lymphoid cells occlude and distend small arteries, veins, and capillaries
- Minimal perivascular extension into adjacent brain parenchyma
- CD20(+), CD19(+), CD22(+), CD79a(+)
- Ki-67 high proliferative activity

CLINICAL ISSUES

Presentation

- Most common signs/symptoms
  - Dementia, confusion, memory loss
  - Multiple stroke-like episodes
  - Patients in Asia often present with hemophagocytic syndrome (Asian variant)
- Other signs/symptoms
  - Cognitive failure, focal deficits, seizure, fever
  - Myelopathy reported with spinal cord involvement
- Clinical profile
  - Skin changes
    - Raised plaques or nodules over abdomen and thighs (50%)
  - CSF studies may show elevated protein
  - No malignant cells in peripheral blood smear or bone marrow
  - Laboratory studies often inconclusive
  - Absence of lymphadenopathy is typical

Demographics

- Age
  - 5th-7th decades; mean: 60-65 years
- Gender
  - Slight male predominance
- Epidemiology
  - Rare, but underdiagnosed
  - CNS involved in up to 75% of IVL cases

Natural History & Prognosis

- Rapidly progressive disease with high mortality rate
- Mean survival: 7-13 months
  - Mildly improved survival in recent reports
- Mortality rate: > 80%
- Rarely, spontaneous regression of symptoms occurs
- Diagnosis often made postmortem
- Risk of recurrence at 1 year: 25%
- Duration of diagnosis to CNS recurrence short

Treatment

- Diagnosis may be made by skin or brain biopsy
- Treatment primarily includes steroids and chemotherapy (rituximab, methotrexate)
- Variable results with radiation therapy

DIAGNOSTIC CHECKLIST

Consider

- In evaluation of patients with dementia, contrast-enhanced MR may be helpful
- IVL often mimics vasculitis and vascular dementia clinically and by imaging
- Stereotactic biopsy often required for definitive diagnosis

Image Interpretation Pearls

- Imaging of IVL is nonspecific, but IVL should be considered in patients with dementia, multifocal lesions, and enhancement
- Linear enhancement along perivascular spaces suggests diagnosis of IVL
- Ischemic foci are most common imaging finding in IVL, often acute foci of ischemia present

SELECTED REFERENCES

1. Colavolpe C et al: FDG-PET/CT is a pivotal imaging modality to diagnose rare intravascular large B-cell lymphoma: case report and review of literature. Hematol Oncol. 33(2):99-109, 2015
2. Nguyen GH et al: Unusual variants of intravascular malignant hematopoietic neoplasms: a report of 4 cases and review of the literature. Am J Dermatopathol. 37(5):360-7, 2015
3. Wang L et al: Intravascular NK/T-cell lymphoma: a report of five cases with cutaneous manifestation from China. J Cutan Pathol. ePub, 2015
4. Sekiguchi Y et al: Intravascular large B-cell lymphoma with pontine involvement successfully treated with R-CHOP therapy and intrathecal administration: a case report and review of literature. Int J Clin Exp Pathol. 7(6):3363-9, 2014
5. Roohi F: Diagnosis of intravascular lymphoma. JAMA Neurol. 70(7):941, 2013
6. Shimada K et al: Central nervous system involvement in intravascular large B-cell lymphoma: a retrospective analysis of 109 patients. Cancer Sci. 101(6):1480-6, 2010
7. Liu H et al: Spinal cord infarct as the initial clinical presentation of intravascular malignant lymphomatosis. J Clin Neurosci. 16(4):570-3, 2009
8. Pusch G et al: Intravascular lymphoma presenting with neurological signs but diagnosed by prostate biopsy: suspicion as a key to early diagnosis. Eur J Neurol. 16(3):e39-41, 2009
9. Sumer M et al: Intravascular lymphoma masquerading as multiembolic stroke developing after coronary artery by-pass surgery. Neurologist. 15(2):98-101, 2009
10. Yago K et al: Usefulness of FDG-PET/CT for the diagnosis of intravascular large B-cell lymphoma presenting with fever of unknown origin and renal dysfunction. Rinsho Ketsueki. 50(6):499-502, 2009
11. Anda T et al: Ruptured distal middle cerebral artery aneurysm filled with tumor cells in a patient with intravascular large B-cell lymphoma. J Neurosurg. 109(3):492-6, 2008
12. Balkema C et al: Usefulness of FDG-PET to diagnose intravascular lymphoma with encephalopathy and renal involvement. Acta Clin Belg. 63(3):185-9, 2008
13. Cerroni L et al: Intravascular large T-cell or NK-cell lymphoma: a rare variant of intravascular large cell lymphoma with frequent cytotoxic phenotype and association with Epstein-Barr virus infection. Am J Surg Pathol. 32(6):891-8, 2008
14. Grove CS et al: Intravascular lymphoma presenting as progressive paraparesis. J Clin Neurosci. 15(9):1056-8, 2008
15. Im SH et al: Headache as the only presentation of intravascular lymphoma. Headache. 48(4):627-9, 2008
16. Louis DN et al: Malignant lymphomas. In Louis DN et al: WHO Classification of Tumours of the Central Nervous System. Lyon: IARC Press. 188-192, 2007

https://CafePezeshki.IR

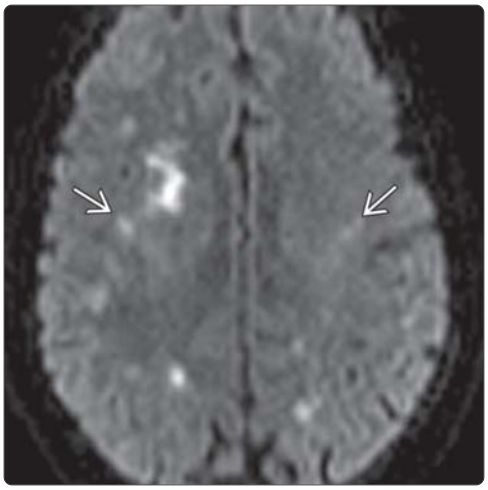

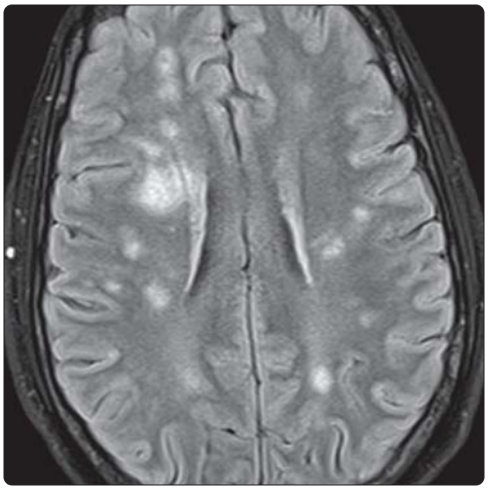

(Left) *Axial DWI shows multiple foci of diffusion restriction of varying ages* ⇨ *in the cerebral hemispheres in a 60 year old with increasing confusion.* **(Right)** *Axial FLAIR MR in the same patient shows multiple nonspecific foci of hyperintensity in the periventricular and subcortical white matter. Without contrast, the imaging is nonspecific, and this patient may have been diagnosed with thromboembolic disease, chronic small vessel ischemia, or vasculitis. IVL often mimics vasculitis clinically and on imaging.*

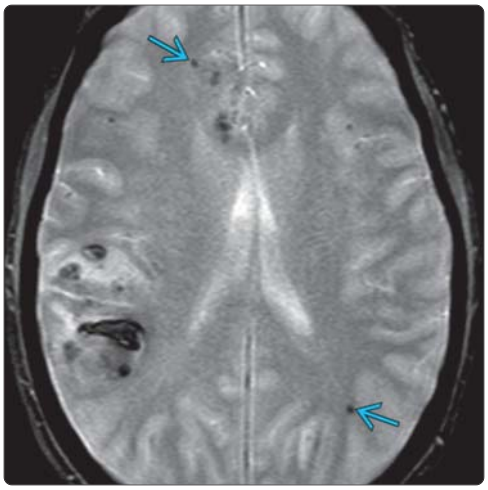

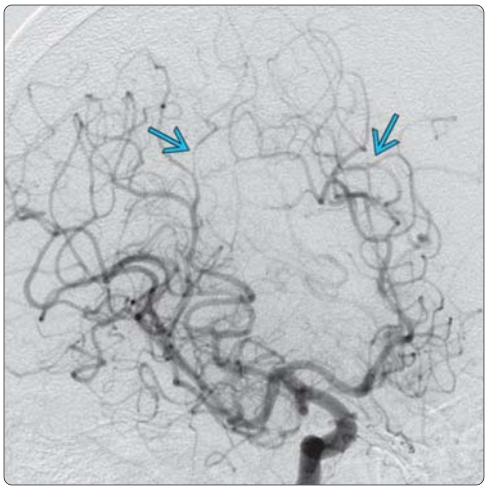

(Left) *Axial GRE in the same patient shows multiple foci of susceptibility artifact* ⇨ *or "blooming" related to multiple hemorrhages throughout the hemispheres. IVL was diagnosed at autopsy. GRE and SWI MR are helpful to identify the microhemorrhages often seen in IVL.* **(Right)** *AP view of a right internal carotid artery injection DSA in the same patient shows multifocal narrowing in small- and medium-sized vessels* ⇨*. This pattern may be seen in both vasculitis and IVL. Biopsy is typically required for definitive diagnosis.*

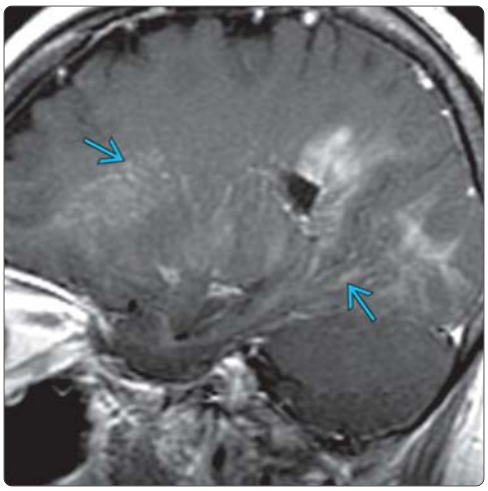

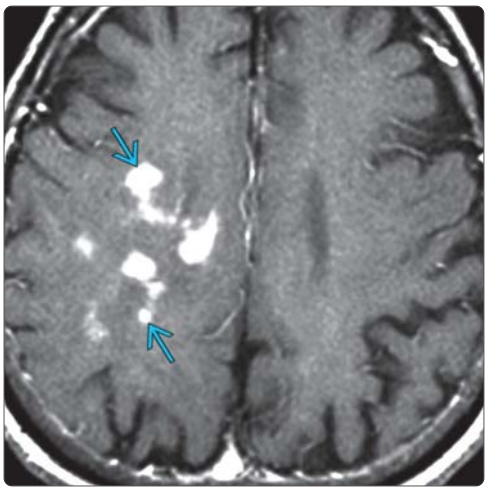

(Left) *Sagittal T1 C+ MR image in a patient with IVL shows the classic linear and punctate enhancement* ⇨ *often seen in IVL. When enhancement is oriented along perivascular spaces, IVL can be suggested.* **(Right)** *Axial T1WI C+ MR shows multifocal areas of enhancement in the hemispheric white matter* ⇨ *in this IVL patient. Enhancement patterns of IVL are variable and may be linear, punctate, patchy, nodular, ring-like, gyriform, or homogeneous. Meningeal &/or dural enhancement has also been described.*

https://CafePezeshki.IR

KEY FACTS

TERMINOLOGY

- Extramedullary leukemic tumors (EML)
- Synonyms: Granulocytic sarcoma, chloroma

IMAGING

- Best diagnostic clue: Homogeneous enhancing tumor(s) in patients with known or suspected myeloproliferative disorder
- Meningeal (dural-based or pial) > intraparenchymal lesions
- NECT: Hyperdense
- CECT: Moderate uniform enhancement
- MR
  - T2/FLAIR iso- to hypointense
  - Restricted diffusion on DWI

TOP DIFFERENTIAL DIAGNOSES

- Metastatic neuroblastoma (NBT)
- Meningioma
- Extraaxial hematoma
- Extramedullary hematopoiesis
- Langerhans cell histiocytosis (LCH)

PATHOLOGY

- CNS leukemia presents in 3 forms
  - Meningeal disease (usually with ALL)
  - Intravascular aggregates (leukostasis): Can rupture, hemorrhage with markedly ↑ leukocyte counts
  - Tumor masses (chloroma)
- Multiple other intracranial manifestations, complications of leukemia/treatment
  - Posterior reversible encephalopathy syndrome (PRES)
  - Post-transplant lymphoproliferative disease (PTLD) after bone marrow transplantation
  - Invasive fungal infection
  - Venous thrombosis associated with chemotherapy
  - Late development of cavernous angiomas after radiation therapy

(Left) *Coronal graphic shows multiple foci of leukemic infiltrates in the skull base/paranasal sinuses ➡, hypothalamus/infundibulum ⇨, basal ganglia ⇨, and dura ➡. Green color observed at pathology results in the name "chloroma." The accepted term is "granulocytic sarcoma."* **(Right)** *Axial NECT scan in a child with acute myelogenous leukemia (AML) and a palpable scalp mass shows a hyperdense intra- ➡ and extracranial mass ➡ that centers on the calvaria.*

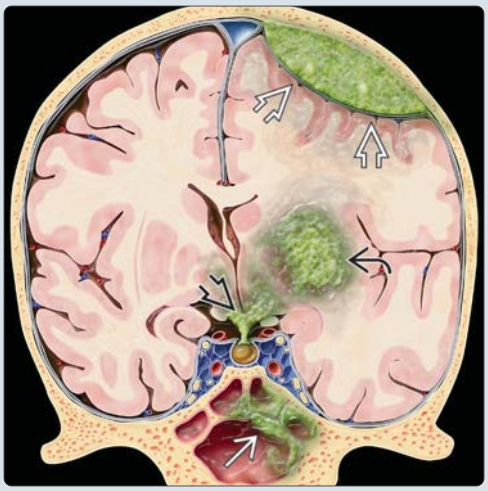

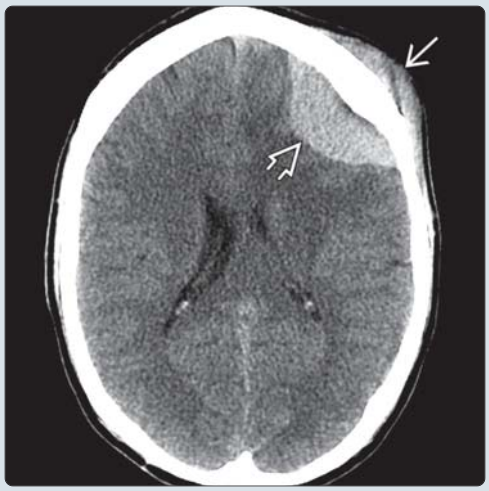

(Left) *Axial T2WI in a child with AML demonstrates a hypointense parietal mass ➡ surrounded by a collar of edema ⇨. AML with parenchymal metastasis (cerebral granulocytic sarcoma) is rare.* **(Right)** *NECT scan in a 5-year-old girl with AML shows chloroma infiltrating both trigeminal nerves, enlarging the cisternal ⇨ and Meckel cave segments ⇨. (Courtesy N. Aggarwal, MD.)*

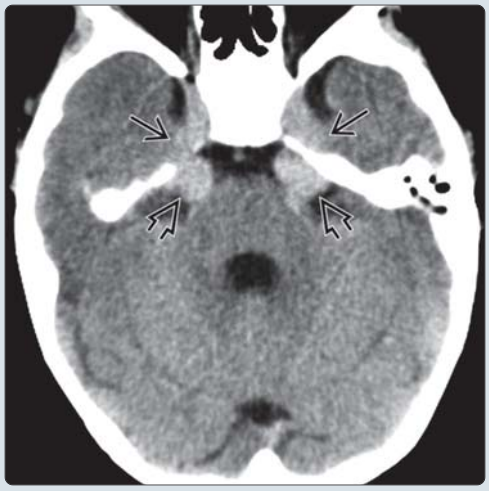

https://CafePezeshki.IR

TERMINOLOGY

Abbreviations

- Extramedullary leukemic tumors (EML)
- Extramedullary myeloblastoma, extramedullary myeloid cell tumors (EmMCT)

Synonyms

- Granulocytic sarcoma, chloroma

Definitions

- Solid tumor of myeloblasts/myelocytes/promyelocytes
  - In patients with myeloproliferative disorder
- Multiple other intracranial manifestations of leukemia/treatment complications
  - Posterior reversible encephalopathy syndrome (PRES)
  - Invasive fungal infection
  - Late development of cavernous angiomas after radiation therapy
  - Post-transplantation lymphoproliferative disease (PTLD) after bone marrow transplantation
  - Venous thrombosis associated with chemotherapy (L-asparaginase)
  - Vasculitis
    - Primary manifestation of leukemia
    - Secondary to treatment (trans retinoic acid)
    - Secondary to infection (e.g., *Aspergillus*)

IMAGING

General Features

- Best diagnostic clue
  - Homogeneous enhancing tumor(s) in patients with known or suspected myeloproliferative disorder
  - Most often complication of acute myelogenous leukemia (AML)
- Location
  - Meningeal (dural-based or pial) > intraparenchymal lesions

CT Findings

- NECT
  - Iso-/hyperdense to brain
    - May rapidly become hypodense (necrosis, liquefaction)
  - May present with (or mimic) hematoma
  - Look for skull base/paranasal sinus involvement
- CECT
  - Homogeneous enhancement
    - Hyperdensity or presence of hemorrhage may mask enhancement
  - May have rim enhancement, mimic abscess

MR Findings

- T1WI
  - Hypo-/isointense to brain
  - Can distinguish between acute hematoma, nonhemorrhagic mass
- T2WI
  - Variable; may be hypointense
  - Pial disease may extend into perivascular spaces, appear as patchy WM hyperintensities
- FLAIR
  - More sensitive than T2WI for leptomeningeal disease
- T2* GRE
  - Helpful for identifying cavernous angiomas as very late complication of leukemia treatment
- DWI
  - May restrict (hyperintense on DWI, hypointense on ADC)
  - Helps distinguish ischemic complications from PRES
- T1WI C+
  - Homogeneous enhancement
    - May become heterogeneous with necrosis/liquefaction
  - Leptomeningeal or perivascular space enhancement
  - Fat-saturation technique essential for assessment of skull base disease
- MRA
  - May show vasospasm in cases of PRES
  - May identify medium-vessel vasculitis
- MRV
  - Essential in evaluation of hemorrhagic lesions
  - Identify presence or extent of venous thrombosis

Nuclear Medicine Findings

- Bone scan
  - Tc-99m MDP commonly used for bone disease in leukemia
  - Soft tissue uptake typically reflects hypercalcemia, not chloroma
- PET
  - Avid uptake on FDG PET exams

Imaging Recommendations

- Best imaging tool
  - MR with contrast
- Protocol advice
  - Use T1WI C+ FS

DIFFERENTIAL DIAGNOSIS

Metastatic Neuroblastoma (NBT)

- Rarely occurs without extracranial disease
- Characteristic "raccoon eyes" clinical presentation
- Spiculated periostitis

Meningioma

- May be very difficult to distinguish
- Dural "tail" may be more common in meningioma

Extraaxial Hematoma

- Extracranial soft tissue swelling or skull fracture
- If no appropriate history, consider possibility of child abuse

Extramedullary Hematopoiesis

- Markedly hypointense on T2WI
- Same at-risk patient population

Langerhans Cell Histiocytosis (LCH)

- Destruction of adjacent bone without periosteal reaction
- Diabetes insipidus

Ewing Sarcoma

- Aggressive pattern of growth
- Destruction of adjacent bone

https://CafePezeshki.IR

Neurosarcoidosis

- Mimic of leptomeningeal disease
- Less commonly presents as dural-based masses

PATHOLOGY

General Features

- Etiology
  - Some association with exposures
    - Ionizing radiation, hydrocarbons, benzene, alkylating agents
- Genetics
  - CNS involvement have higher incidence of 11q23 abnormalities compared to those without CNS disease
  - Chromosomal t(8;21) translocations reported in cases of AML with chloroma
  - AML has higher incidence in some genetic syndromes
    - Down, Bloom, Fanconi syndromes
- Associated abnormalities
  - Less common in non-AML myeloproliferative disorders
    - Myeloid metaplasia
    - Hypereosinophilic syndrome
    - Polycythemia vera
- CNS leukemia presents in 3 forms
  - Meningeal disease
    - Usually with acute lymphoblastic leukemia (ALL)
  - Intravascular aggregates (leukostasis)
    - May rupture, hemorrhage (with markedly high leukocyte counts)
  - Focal tumor masses (chloroma)
- Chloroma
  - Leukemic masses first described in 1811
  - "Chloroma" coined in 1853
  - Renamed granulocytic sarcoma in 1966

Gross Pathologic & Surgical Features

- Called chloroma because of green color in 70% of cases
  - Caused by high levels of myeloperoxidase

Microscopic Features

- Moderate to large cells
- Pleomorphic nuclei
- Multiple mitoses give "starry sky" appearance

CLINICAL ISSUES

Presentation

- Most common signs/symptoms
  - May precede marrow diagnosis of leukemia
  - 50% of cases diagnosed only at autopsy
  - CNS lesions more likely symptomatic
  - Focal signs from local mass effect
  - Headache from hemorrhage
- Clinical profile
  - Child with AML develops new neurological signs or symptoms

Demographics

- Age
  - 60% of patients < 15 years
- Gender
  - M:F = 1.38:1
- Ethnicity
  - Hispanic children < 19 years have highest rates of leukemia
  - Incidence in Americans of European descent > African descent
- Epidemiology
  - 5-10% of patients with AML; 1-2% with CML
  - Risk factors for CNS disease = age < 45 years, WBC counts > 50,000/μL, 11q23 translocations

Natural History & Prognosis

- Overall survival rates for AML (40-50%)
- Chloroma in setting of other myeloproliferative syndrome
  - Implies blastic transformation
  - Poor prognostic sign

Treatment

- Chemotherapy for induction
  - Cytarabine (Ara-C)
  - Anthracycline
- Bone marrow transplant for consolidation
- Note: Methotrexate treatment can cause stroke-like symptoms
  - MR → round WM lesions with reduced diffusion

DIAGNOSTIC CHECKLIST

Consider

- Extramedullary hematopoiesis can present in same patient population with similar appearance
- Hemorrhagic lesions in children with AML can be manifestation of chloroma or complication of therapy

Image Interpretation Pearls

- Multiple lesions at multiple sites suggestive of diagnosis
- Chloromas with enhancing rim (rare) can mimic abscess

SELECTED REFERENCES

1. Bar M et al: Central nervous system involvement in acute myeloid leukemia patients undergoing hematopoietic cell transplantation. Biol Blood Marrow Transplant. 21(3):546-51, 2015
2. Cheng CL et al: Risk factors and clinical outcomes of acute myeloid leukaemia with central nervous system involvement in adults. BMC Cancer. 15(1):344, 2015
3. Bhojwani D et al: Methotrexate-induced neurotoxicity and leukoencephalopathy in childhood acute lymphoblastic leukemia. J Clin Oncol. 32(9):949-59, 2014
4. Rozovski U et al: Incidence of and risk factors for involvement of the central nervous system in acute myeloid leukemia. Leuk Lymphoma. 1-6, 2014
5. Morioka S et al: Effects of chemotherapy on the brain in childhood: diffusion tensor imaging of subtle white matter damage. Neuroradiology. 55(10):1251-7, 2013
6. Spataro R et al: Neurological picture. Petechial brain haemorrhages in acute lymphoblastic leukaemia. J Neurol Neurosurg Psychiatry. 84(8):908, 2013
7. Faraci M et al: Magnetic resonance imaging in childhood leukemia survivors treated with cranial radiotherapy: a cross sectional, single center study. Pediatr Blood Cancer. 57(2):240-6, 2011
8. Dicuonzo F et al: Posterior reversible encephalopathy syndrome associated with methotrexate neurotoxicity: conventional magnetic resonance and diffusion-weighted imaging findings. J Child Neurol. 24(8):1013-8, 2009
9. Koenig MK et al: Central nervous system complications of blastic hyperleukocytosis in childhood acute lymphoblastic leukemia: diagnostic and prognostic implications. J Child Neurol. 23(11):1347-52, 2008
10. Hakyemez B et al: Parlak M. Intracranial myeloid sarcoma: conventional and advanced MRI findings. Br J Radiol. 80(954):e109-12, 2007

https://CafePezeshki.IR

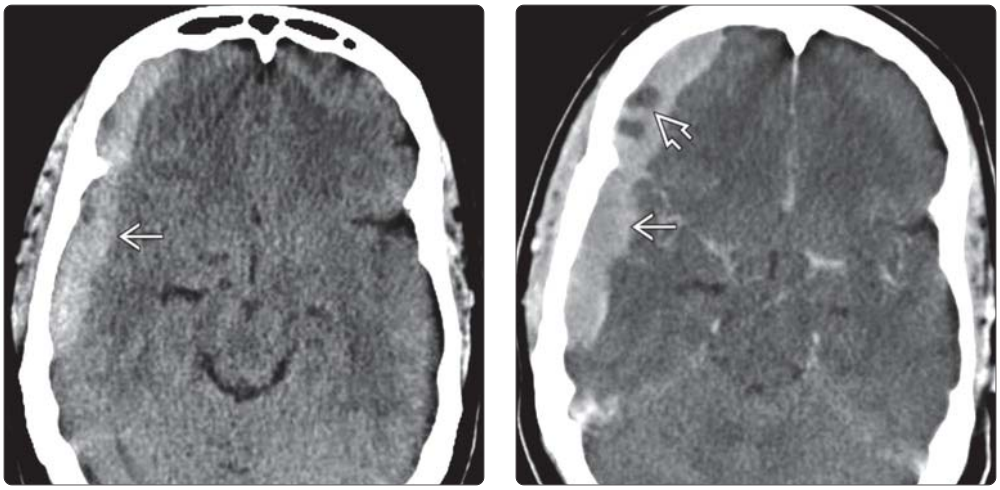

(Left) *Axial NECT demonstrates a hyperdense dural-based mass mimicking a subdural hematoma in a patient with acute myelocytic leukemia* ➡. **(Right)** *Axial CECT shows homogeneous enhancement in the dural-based mass* ➡, *thus excluding simple hemorrhage. Small areas of nonenhancement* ➡ *are due to necrosis/liquefaction rather than rapid bleeding. These are typical findings in dural-based leukemic infiltrates in patients with AML.*

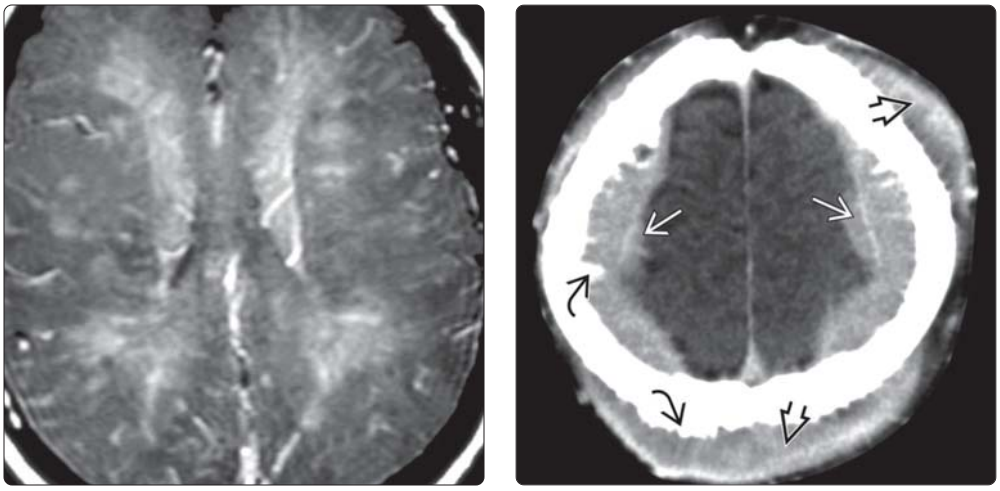

(Left) *Axial T1WI C+ MR in a patient with leukemia and progressive encephalopathy shows multiple, enhancing intra- and perivascular infiltrates. Carcinomatous encephalitis is a rare complication of leukemia.* **(Right)** *Axial CECT in a patient with leukemic disease and skull involvement shows large, bilateral, convexity epidural leukemic masses* ➡. *Note the subperiosteal accumulations of tumor* ⇨. *The spiculated appearance of the outer and inner calvaria* ⇨ *speaks to the extensive marrow involvement.*

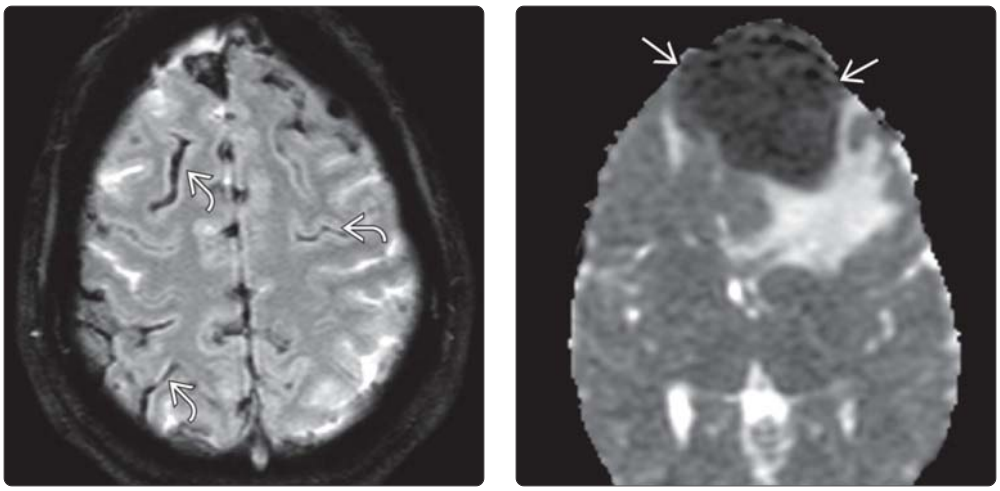

(Left) *Axial T2* GRE MR shows leptomeningeal low signal* ➡ *in a patient with AML and blast crisis. CSF analysis showed hemorrhage and leukemic cell infiltrates.* **(Right)** *Axial ADC in a 13-year-old girl with sinusitis and scalp swelling shows a restricting, profoundly hypointense mass* ➡ *that was hyperdense on CT and hyperintense and strongly enhancing on DWI (not shown). Biopsy and blood studies showed high-risk ALL.*

https://CafePezeshki.IR

KEY FACTS

TERMINOLOGY

- Intracranial germ cell tumor (iGCT)
- iGCTs are intracranial homologue of gonadal germinomas (ovarian dysgerminoma, testicular seminoma)

IMAGING

- Most common: In/near midline (80-90%)
  - Pineal region ~ 50-65%
  - Suprasellar ~ 25-35%
- Less common: Basal ganglia/thalami ~ 5-10%
- 20% multiple
  - Most common = pineal with suprasellar
- NECT (pineal germinoma)
  - Hyperdense pineal region mass engulfs pineal Ca++
- MR (suprasellar germinoma)
  - Absent posterior pituitary "bright spot"
  - "Fat" stalk/pituitary gland
  - Strong, relatively uniform enhancement
  - May have cysts, hemorrhage (rare)

TOP DIFFERENTIAL DIAGNOSES

- Pineal germinoma
  - Pineocytoma
  - Other pineal GCTs
- Suprasellar germinoma ("fat" infundibulum)
  - Adult
    - Neurosarcoid
    - Metastases
  - Child
    - Langerhans cell histiocytosis (LCH)

CLINICAL ISSUES

- 90% of patients < 20 years old
- Pineal region germinoma: M:F ~ 10:1

DIAGNOSTIC CHECKLIST

- If young patient presents with diabetes insipidus, think germinoma or LCH

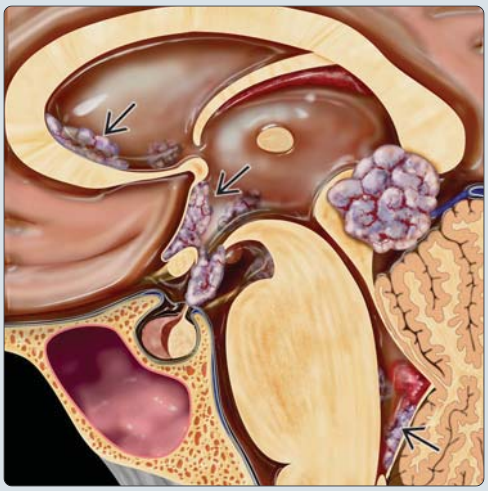

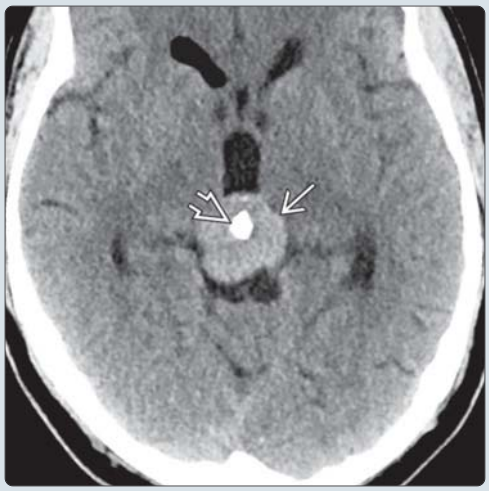

(Left) *Sagittal graphic shows synchronous germinomas in the suprasellar and pineal regions. Note the CSF spread of tumor in the lateral, 3rd, and 4th ventricles.* **(Right)** *Axial NECT scan shows typical findings of pineal germinoma with a well-demarcated slightly hyperdense mass engulfing the calcified pineal gland.*

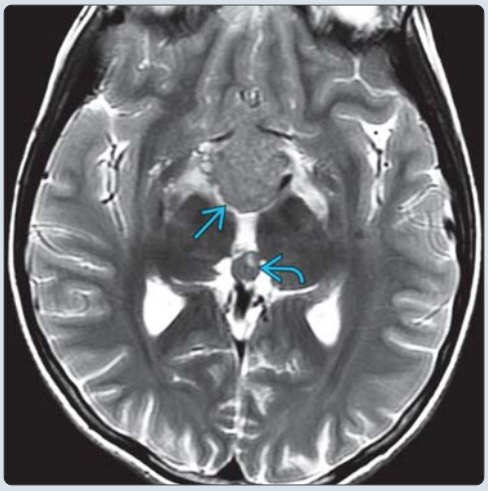

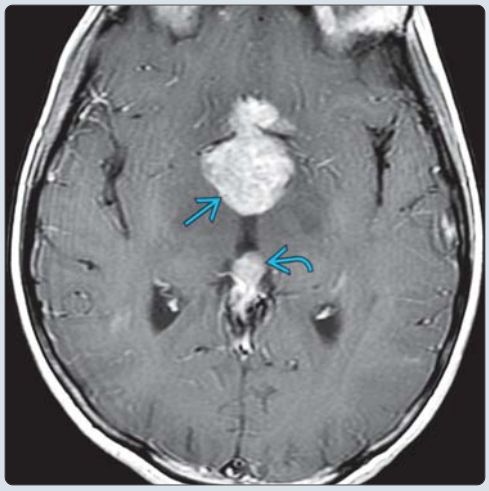

(Left) *Axial T2WI in a 14-year-old boy with visual symptoms shows a suprasellar mass that is slightly hypointense relative to gray matter. A 2nd, smaller mass is present in the pineal gland.* **(Right)** *T1 C+ MR in the same patient shows the lobulated suprasellar mass enhances strongly. The pineal mass also enhances uniformly. The combination of suprasellar and pineal mass (sometimes called "double midline" germinoma) occurs in ~ 20% of cases.*

https://CafePezeshki.IR

TERMINOLOGY

Abbreviations

- Intracranial germ cell tumor (iGCT)

Synonyms

- Dysgerminoma, extragonadal seminoma

Definitions

- iGCTs are intracranial homologue of gonadal germinomas (ovarian dysgerminoma, testicular seminoma)

IMAGING

General Features

- Best diagnostic clue
  - Hyperdense pineal region mass that engulfs pineal Ca++
  - Suprasellar mass with diabetes insipidus (DI)
  - BG mass with ipsilateral hemiatrophy
- Location
  - Most common: In/near midline (80-90%)
    - Pineal region ~ 50-65%
    - Suprasellar ~ 25-35%
  - Less common: Basal ganglia/thalami ~ 5-10%
  - Other sites: Intraventricular (3rd), intrasellar, bulbar, intramedullary, midbrain, hemispheric
- Size
  - Varies with location
    - Pineal: Can be large if no hydrocephalus, midbrain compression ± invasion
    - Infundibular stalk: Early presentation with DI common
      - Mass can initially be tiny/imperceptible
- Number
  - 20% multiple; most common = pineal with suprasellar

CT Findings

- NECT
  - Lobulated hyperdense mass
    - Pineal: Mass drapes around posterior 3rd ventricle or engulfs Ca++ pineal gland
    - Suprasellar: "Fat" infundibulum
    - Basal ganglia: Often no abnormality in early stage, later iso-/hyperdense lesions without mass effect
      - Single calcified spot may be seen on NECT in early stage
  - ± cysts
  - ± hemorrhage (especially in basal ganglia germinomas)
  - ± hydrocephalus
- CECT
  - Strong uniform enhancement, ± CSF seeding
    - Pineal region: Look for posterior 3rd ventricle, midbrain/thalami infiltration
    - Suprasellar: Look for thick stalk, infiltration of 3rd ventricular floor, lateral walls, and anterior columns of fornices

MR Findings

- T1WI
  - Iso-/hyperintense to GM
  - "Fat" stalk/pituitary gland
    - Absent posterior pituitary "bright spot"
      - Pituitary "bright spot" present in 99.7% of normal patients
  - Basal ganglia/thalami: 20-33% associated ipsilateral hemiatrophy
- T2WI
  - Iso- to hyperintense to GM (high nuclear to cytoplasmic ratio)
    - Cystic/necrotic foci (high T2 signal)
      - Multiple cysts common in germinoma and all GCTs (up to 44%)
    - Less common: Hypointense foci (hemorrhage)
- FLAIR
  - Slightly hyperintense to GM
- T2* GRE
  - Calcification, hemorrhage "bloom"
- DWI
  - Reduced diffusion due to high cellularity
- T1WI C+
  - Strong, homogeneous enhancement, ± CSF seeding, ± brain invasion
  - BG and thalami: Ill-defined enhancement
    - Later cystic changes (due to previous hemorrhage and tumor progression)
- MRS
  - ↑ choline, ↓ NAA, ± lactate

Imaging Recommendations

- Best imaging tool
  - Enhanced MR of brain and spine
- Protocol advice
  - MR evaluation of entire neuraxis before surgery

DIFFERENTIAL DIAGNOSIS

Other Pineal GCTs

- Malignant mixed germ cell, yolk sac, choriocarcinoma, embryonal carcinoma
- Immature teratoma, mature teratoma, mixed mature/immature

Pineoblastoma

- Large, heterogeneous pineal mass; peripheral Ca++
- Obstructive hydrocephalus

Pineocytoma

- Mass "explodes" rather than engulfs pineal Ca++

Pineal Parenchymal Tumor of Intermediate Differentiation

- Pineal mass with histology between pineocytoma and pineoblastoma

Pineal Cyst (Atypical)

- Often > 15 mm, rim enhancing, variable signal of cyst contents, ± tectal compression

Other Pineal Region Masses

- Astrocytoma
- Metastasis
- Meningioma
- Retinoblastoma
  - Trilateral → evaluate orbits and suprasellar regions
- Papillary tumor of pineal region

https://CafePezeshki.IR

"Fat" Infundibulum

- Child
  - Langerhans cell histiocytosis (LCH)
  - Tuber cinereum hamartoma (isointense with GM, nonenhancing)
- Adult
  - Neurosarcoid
  - Metastases

PATHOLOGY

General Features

- Etiology
  - Genetics
    - Frequent aberrations of *CCND2* (12p13)
    - *KIT* alterations also common in pure germinomas
- Associated abnormalities
  - Klinefelter syndrome (47XXY)
  - Down syndrome
  - Neurofibromatosis type 1
  - Laboratory derangements
    - Elevated placental alkaline phosphatase (PLAP)
    - Most germinomas have elevated serum, CSF β-HCG irrespective of histology

Staging, Grading, & Classification

- Multiple site involvement (pineal, suprasellar, BG, thalamus) considered metastatic in USA, synchronous in Canada and Europe
- Pure germinoma: WHO grade II
- Germinoma with syncytiotrophoblastic giant cells (STGCs): WHO grade II-III

Gross Pathologic & Surgical Features

- Soft and friable, tan-white mass, ± necrosis

Microscopic Features

- Sheets of large polygonal primitive germ cells
- Lymphocytic infiltrates along fibrovascular septa
- IHC shows PLAP, c-kit, OCT3/4 highly expressed

CLINICAL ISSUES

Presentation

- Most common signs/symptoms
  - Pineal region germinoma
    - Parinaud syndrome (upward gaze paralysis and altered convergence)
    - Headache due to tectal compression or invasion (hydrocephalus)
  - Suprasellar germinoma
    - Diabetes insipidus (DI)
    - Visual loss
    - Hypothalamic-pituitary dysfunction (↓ growth, precocious puberty)
  - Off-midline germinoma
    - Slow, progressive hemiparesis (due to involvement of internal capsule and subsequent Wallerian degeneration)
    - Progressive mental deterioration, personality change, fever of unknown origin
    - Precocity, diabetes insipidus, hemianopsia, speech disturbance
    - Choreoathetoid movements

Demographics

- Age
  - CNS GCTs primarily in young patients
    - 90% < 20 years
    - Peak: 10-12 years
- Gender
  - Pineal region germinoma: M:F ~ 10:1
  - Suprasellar germinoma: More common in women
  - For all CNS germinomas: M:F = 1.5-2:1
- Ethnicity
  - CNS GCTs far more prevalent in Asia (9-15%)
- Epidemiology
  - Germinomas → 1-2% of all CNS tumors
    - 2/3 of all iGCTs
    - 50% of pineal region tumors
    - 2-4% of pediatric CNS tumors (9-15% of CNS tumors in Japanese children)

Natural History & Prognosis

- Pure germinoma has favorable prognosis
  - Moderate elevation of β-HCG → favorable
- CSF dissemination and invasion of adjacent brain common

Treatment

- Biopsy to confirm histology, "pure" germinomas have best outcome
- Reduced dose and volume of XRT ± adjuvant chemotherapy

SELECTED REFERENCES

1. Takami H et al: Human chorionic gonadotropin is expressed virtually in all intracranial germ cell tumors. J Neurooncol. 124(1):23-32, 2015
2. Vasiljevic A et al: Histopathology of pineal germ cell tumors. Neurochirurgie. 61(2-3):130-7, 2015
3. Côté M et al: Normal dimensions of the posterior pituitary bright spot on magnetic resonance imaging. J Neurosurg. 120(2):357-62, 2014
4. Fukushima S et al: Mutually exclusive mutations of KIT and RAS are associated with KIT mRNA expression and chromosomal instability in primary intracranial pure germinomas. Acta Neuropathol. 127(6):911-25, 2014
5. Terashima K et al: Genome-wide analysis of DNA copy number alterations and loss of heterozygosity in intracranial germ cell tumors. Pediatr Blood Cancer. 61(4):593-600, 2014
6. Jinguji S et al: Factors affecting functional outcomes in long-term survivors of intracranial germinomas: a 20-year experience in a single institution. J Neurosurg Pediatr. 11(4):454-63, 2013
7. Khan AA et al: An unusual anatomic and geographic location of primary germinoma of the fourth ventricle. J Clin Neurosci. 20(11):1620-2, 2013
8. Sethi RV et al: Delayed diagnosis in children with intracranial germ cell tumors. J Pediatr. 163(5):1448-53, 2013
9. Park DeWitt J et al: Primary intracranial germ cell tumor originating from septum pellucidum that mimics central neurocytoma. J Clin Oncol. 30(27):e274-7, 2012
10. Lee J et al: Atypical basal ganglia germinoma presenting as cerebral hemiatrophy: diagnosis and follow-up with 11C-methionine positron emission tomography. Childs Nerv Syst. 25(1):29-37, 2009
11. Guerrero-Vázquez S et al: [Simultaneous suprasellar and pineal germinoma: a case report] Rev Neurol. 46(7):411-5, 2008
12. Rossi A et al: Bilateral germinoma of the basal ganglia. Pediatr Blood Cancer. 50(1):177-9, 2008
13. Sartori S et al: Germinoma with synchronous involvement of midline and off-midline structures associated with progressive hemiparesis and hemiatrophy in a young adult. Childs Nerv Syst. 23(11):1341-5, 2007
14. Ueno T et al: Spectrum of germ cell tumors: from head to toe. Radiographics. 24(2):387-404, 2004

https://CafePezeshki.IR

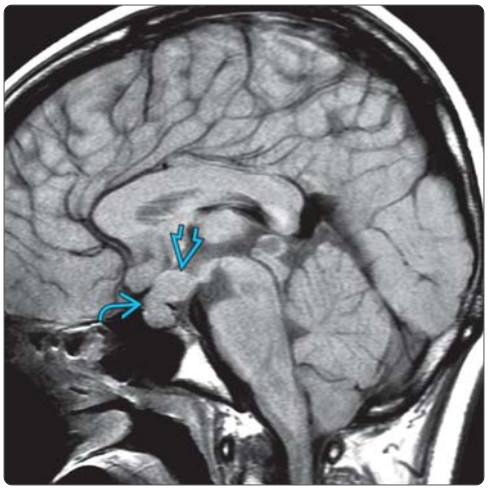

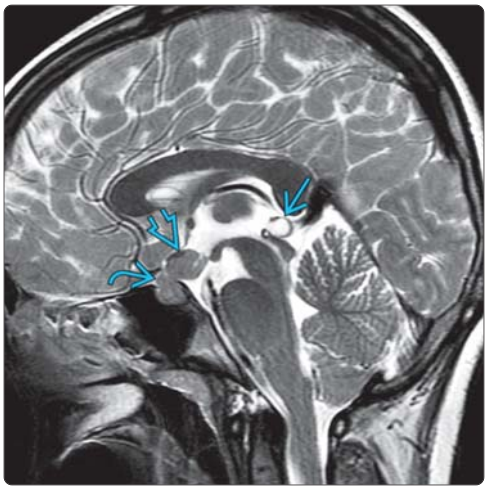

(Left) *Sagittal T1WI in a 14-year-old girl with diabetes insipidus shows absence of the posterior pituitary "bright spot." A lobulated mass that is isointense with the cortex thickens the infundibular stalk ⇨ and extends superiorly into the hypothalamus and 3rd ventricle ⇨.* **(Right)** *Sagittal T2WI in the same patient shows the mass in the pituitary stalk ⇨ and hypothalamus/inferior 3rd ventricle ⇨ remains isointense with gray matter. Note the benign-appearing pineal cyst ⇨.*

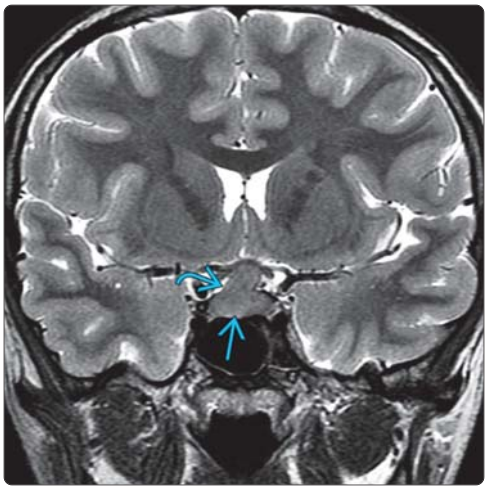

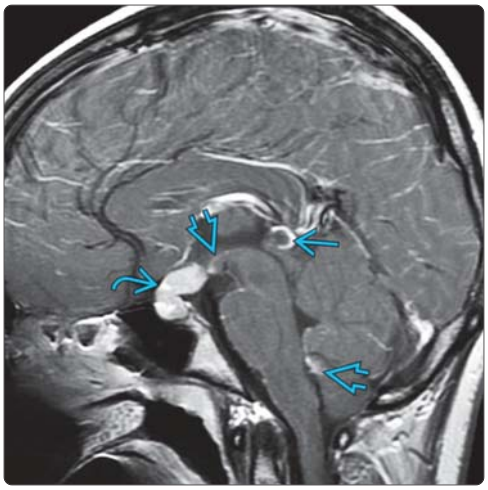

(Left) *Coronal T2WI in the same patient shows the mass ⇨ seems to be infiltrating both the infundibular stalk and pituitary gland ⇨.* **(Right)** *Sagittal T1 C+ in the same patient shows the mass ⇨ enhances strongly and uniformly. Note the enhancing rim around the benign pineal cyst ⇨. Subtle CSF spread is present ⇨ and was documented by lumbar puncture. Biopsy showed germinoma.*

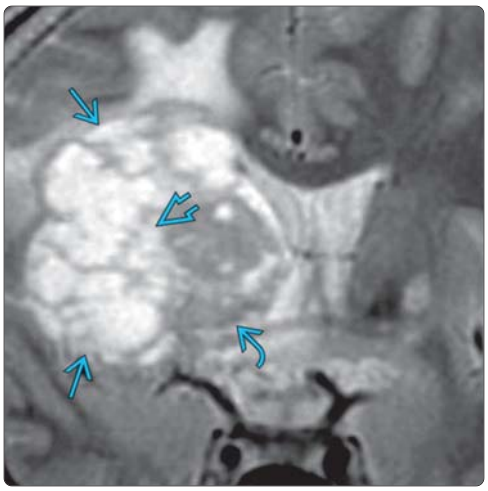

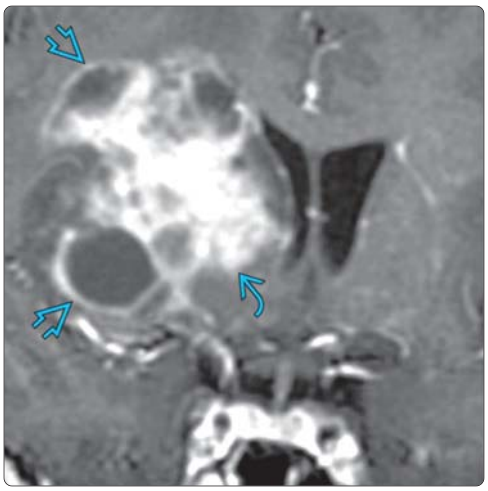

(Left) *Coronal T2WI shows a mixed signal intensity mass in the right basal ganglia ⇨. Note the numerous intratumoral cysts ⇨. The solid portion of the tumor ⇨ is isointense with gray matter.* **(Right)** *Coronal T1 C+ shows enhancement in the cyst walls ⇨ & the solid portion of the mass ⇨. Biopsy disclosed germinoma. Primary germinomas in the basal ganglia & thalami are uncommon. They are often atypical in appearance. Intratumoral hemorrhage and cysts are common. (Courtesy R. Babbel, MD).*

https://CafePezeshki.IR

KEY FACTS

TERMINOLOGY

- Teratoma: Nongerminomatous germ cell tumor
  - Arises from multipotential germ cells
  - Tridermic (contains tissues derived from all 3 germ cell layers)
- Types
  - Mature teratoma (most common; well differentiated)
  - Immature teratoma (some incompletely differentiated tissue)
  - Teratoma with malignant transformation

IMAGING

- NECT
  - Midline mass containing Ca++, soft tissue, cysts, and fat
- T1WI
  - Fat → ↑ signal, Ca++ → variable signal
  - Soft tissue components iso- to hyperintense, enhancing
- T2WI: ↓ signal from Ca++
- DWI: Restriction in solid (high cellular) parts
- Anatomic location indeterminate in 50%
  - Huge holocranial mass in newborns or fetus
  - Anatomic landmarks effaced
- Fetal US: Macrocephaly
  - Rapidly ↑ mass, mixed hyper-, hypoechoic features

TOP DIFFERENTIAL DIAGNOSES

- Germinoma
- Other nongerminomatous germ cell tumor
- PNET, AT/RT
- Dermoid
- Craniopharyngioma

CLINICAL ISSUES

- Often detected in utero or as neonate
- M:F = 4:1

DIAGNOSTIC CHECKLIST

- If newborn with holocranial tumor, think teratoma

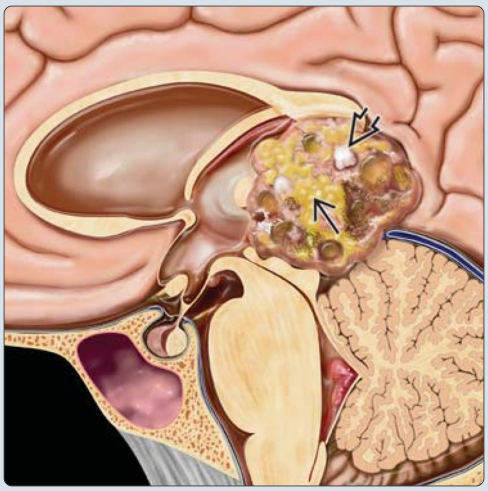

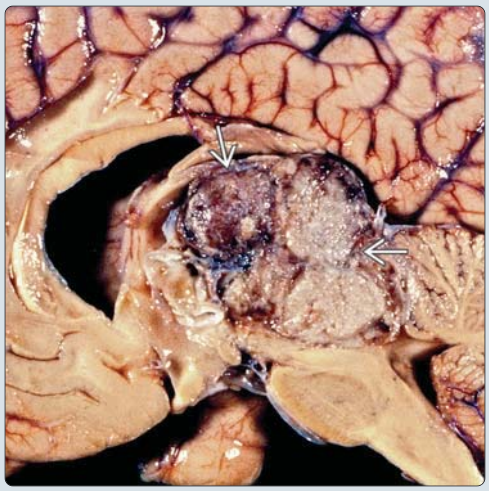

(Left) *Sagittal graphic shows a heterogeneous pineal teratoma with a solid, calcific ⇨, and fatty ⇨ composition.* **(Right)** *Sagittal gross pathology section shows a pineal teratoma ⇨ with obstructive hydrocephalus. (Courtesy B. Alvord, MD.)*

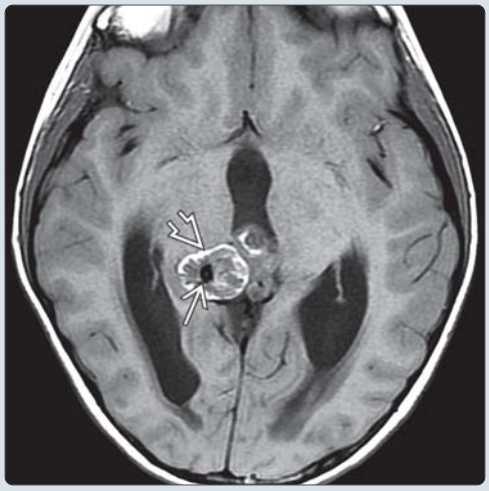

(Left) *Axial NECT scan in an 8-year-old boy who presented with headaches, morning nausea, and vomiting shows a mixed density mass in the pineal region. Note the fat-like ⇨ tissue calcifications, including one that resembles a tooth ⇨. The lateral ventricles are moderately enlarged, consistent with obstructive hydrocephalus.* **(Right)** *T1WI in the same patient shows mixed hyper- ⇨, isointense lobulated soft tissue mass with a central hypointense focus ⇨ from the tooth-like structure.*

https://CafePezeshki.IR

TERMINOLOGY

Definitions

- Teratoma: Nongerminomatous germ cell tumor
  - Arises from multipotential germ cells
  - Tridermic (contains tissues derived from all 3 germ cell layers)
- Types
  - Mature teratoma (most common; well differentiated)
  - Immature teratoma (some incompletely differentiated tissue)
  - Teratoma with malignant transformation

IMAGING

General Features

- Best diagnostic clue
  - Midline mass containing Ca++, soft tissue, cysts, fat
  - Huge holocranial mass in newborn or fetus
- Location
  - Midline
    - Pineal gland
      - Tectum, mesencephalon commonly involved
    - Sellar/suprasellar
      - Hypothalamus, optic chiasm
      - Less common: Parasellar (cavernous sinuses or mesial middle cranial fossa)
    - Basal ganglia, thalami
    - Spine (thoracolumbar junction)
  - Rare locations
    - Brain hemispheres
    - Ventricles
    - ~ 50% so large that anatomic origin indeterminate
- Size
  - Variable; infantile teratomas often huge ("holocranial")

CT Findings

- NECT
  - Fat, soft tissue, Ca++
  - Cystic components common
  - Often large (may fill entire cranium)
- CECT
  - Soft tissue components enhance
- Bone CT
  - Look for tooth-like configuration of Ca++

MR Findings

- T1WI
  - Increased signal from fat
  - Variable signal from Ca++
- T2WI
  - Soft tissue components iso- to hyperintense
  - Perifocal edema
    - Usually minimal or absent (mature teratoma)
    - Common in immature (malignant) teratoma
- FLAIR
  - ↓ signal from cysts, ↑ signal from solid tissue
- T2* GRE
  - Decreased signal from Ca++
- DWI
  - Restricted diffusion in solid (high cellular) parts
  - Useful in differentiating high- vs. low-grade neoplasms for large bulky supratentorial tumors in 1st year of life
    - ADC values negatively correlated with tumor grade
- T1WI C+
  - Soft tissue enhancement
- Fetal MR
  - Extremely heterogeneous mass containing fat, fluid, bone, and soft tissue
  - Usually midline, may fill and expand cranium
  - When small, often midline
    - Suprasellar vs. pineal region vs. 4th ventricle

Ultrasonographic Findings

- Neonates: Heterogeneous mass with internal shadowing (Ca++)
- In utero ultrasound
  - Intracranial mass (often huge)
  - Hydrocephalus, polyhydramnios

Imaging Recommendations

- Best imaging tool
  - CT to demonstrate soft tissue, fat, Ca++
  - MR best characterizes relationship of teratoma to midline structures
- Protocol advice
  - MR with and without fat suppression

DIFFERENTIAL DIAGNOSIS

Germinoma

- Homogeneous appearance

Other Nongerminomatous Germ Cell Tumor

- Includes embryonal carcinoma, yolk sac tumor, choriocarcinoma, mixed germ cell tumor
- Heterogeneous suprasellar or pineal mass

Craniopharyngioma

- Cystic and solid, calcifications

Dermoid

- Minimal/no enhancement
- Calcifications common
- Look for rupture with fat "droplets"

Pineoblastoma

- Large pineal mass with "exploded" Ca++
- Hydrocephalus present in 100%

Supratentorial PNET

- Ca++, hemorrhage, necrosis common
- Does not contain fat

Atypical Teratoid/Rhabdoid Tumor (AT/RT)

- Large, bulky AT/RT in newborn difficult to distinguish

Astrocytoma

- Newborn GBM can be large, bulky, very heterogeneous

Lipoma

- Contains fat, calcifications but no soft tissue component
- Uncommon in suprasellar location

https://CafePezeshki.IR

PATHOLOGY

General Features

- Etiology
  - Originates during 3rd or 4th week of fetal development
  - Anomalous development of primitive streak or its derivatives
- Genetics
  - Gains of hypomethylated, active X chromosomes occur in all intracranial germ cell tumors (ICGCTs)
- Associated abnormalities
  - Increased serum carcinoembryonic antigen (CEA)
  - Increased α-fetoprotein if tumor contains enteric glandular elements (yolk sac cells)

Staging, Grading, & Classification

- WHO classification
  - Mature teratoma (WHO grade I)
  - Immature teratoma
  - Teratoma with malignant transformation (TMT)
    - Usually arises from immature teratoma
    - Contains somatic-type cancers (e.g., rhabdomyosarcoma)

Gross Pathologic & Surgical Features

- Mature teratomas → fully differentiated tissue
  - Cystic component frequent in mature teratoma
- Immature or malignant teratoma → resembles fetal tissues
- Teratomas may be part of mixed tumors, with germinomas or nongerminomatous ICGCT

Microscopic Features

- Contain elements representing 3 germinal layers
  - Ectoderm
  - Mesoderm
  - Endoderm

CLINICAL ISSUES

Presentation

- Most common signs/symptoms
  - Macrocephaly → congenital teratoma
  - Parinaud syndrome → pineal lesions
- Other signs/symptoms
  - Increased serum carcinoembryonic antigen (CEA)
- Clinical profile
  - In utero demonstration of hydrocephalus, macrocephaly, and heterogeneous mass
  - Congenital teratomas
    - Diffuse intracranial form: Large tumors replacing intracranial content
    - Small tumors causing hydrocephalus
    - Massive form: Extension in orbits, pharynx, neck

Demographics

- Age
  - Average age at diagnosis = 15 years
  - Range: Newborn-6th decade
  - Often detected in utero or as neonate
- Gender
  - M > F
- Ethnicity
  - More common among Asians
- Epidemiology
  - 2-4% of intracranial tumors in children
  - Leading perinatal brain tumor (42%)

Natural History & Prognosis

- 5-year survival for malignant teratomas: 18%
- Congenital teratoma
  - May be seen on fetal ultrasound or MR
  - Majority stillborn or die within 1st week of life
- Lowest survival rate of all fetal brain tumors
- Pineal mature teratomas have good prognosis
- CSF metastases common in malignant (immature) teratoma

Treatment

- Surgical removal
  - Operative mortality in 1st year: 20%

DIAGNOSTIC CHECKLIST

Consider

- Think teratoma in newborn with holocranial tumor
- Heterogeneous midline mass, young age, male predominance, pineal preferential location

Image Interpretation Pearls

- Midline tumor predominantly in sellar and pineal region containing fat, soft tissue, and Ca++

SELECTED REFERENCES

1. Zygourakis CC et al: Management of central nervous system teratoma. J Clin Neurosci. 22(1):98-104, 2015
2. Kralik SF et al: Diffusion imaging for tumor grading of supratentorial brain tumors in the first year of life. AJNR Am J Neuroradiol. 35(4):815-23, 2014
3. Bohara M et al: Mature posterior fossa teratoma mimicking dermoid cyst. Brain Tumor Pathol. 30(4):262-5, 2013
4. Ghosal N et al: Posterior third ventricular mature teratoma with a hemangiomatous component. Clin Neuropathol. 32(6):532-5, 2013
5. Goyal N et al: Intracranial teratomas in children: a clinicopathological study. Childs Nerv Syst. 29(11):2035-42, 2013
6. Liu Z et al: Imaging characteristics of primary intracranial teratoma. Acta Radiol. Epub ahead of print, 2013
7. Sanyal P et al: A case of mature cystic teratoma arising from the fourth ventricle. Case Rep Pathol. 2013:702424, 2013
8. Sweiss RB et al: Suprasellar mature cystic teratoma: an unusual location for an uncommon tumor. Case Rep Neurol Med. 2013:180497, 2013
9. Taniguchi M et al: A rapidly expanding immature teratoma originating from a neurohypophyseal germinoma. Neuropathol Appl Neurobiol. 39(4):445-8, 2013
10. Goyal N et al: Mature teratoma in association with neural tube defect (occipital encephalocele): series of four cases and review of the literature. Pediatr Neurosurg. 48(2):67-72, 2012
11. Isaacs H: Fetal brain tumors: a review of 154 cases. Am J Perinatol. 26(6):453-66, 2009
12. Sato K et al: Pathology of intracranial germ cell tumors. Prog Neurol Surg. 23:59-75, 2009
13. Berhouma M et al: Transcortical approach to a huge pineal mature teratoma. Pediatr Neurosurg. 44(1):52-4, 2008
14. Köken G et al: Prenatal diagnosis of a fetal intracranial immature teratoma. Fetal Diagn Ther. 24(4):368-71, 2008
15. Noudel R et al: Intracranial teratomas in children: the role and timing of surgical removal. J Neurosurg Pediatr. 2(5):331-8, 2008
16. Arslan E et al: Massive congenital intracranial immature teratoma of the lateral ventricle with retro-orbital extension: a case report and review of the literature. Pediatr Neurosurg. 43(4):338-42, 2007
17. Erman T et al: Congenital intracranial immature teratoma of the lateral ventricle: a case report and review of the literature. Neurol Res. 27(1):53-6, 2005
18. Cavalheiro S et al: Fetal brain tumors. Childs Nerv Syst. 19(7-8):529-36, 2003
19. Jaing TH et al: Intracranial germ cell tumors: a retrospective study of 44 children. Pediatr Neurol. 26(5):369-73, 2002

https://CafePezeshki.IR

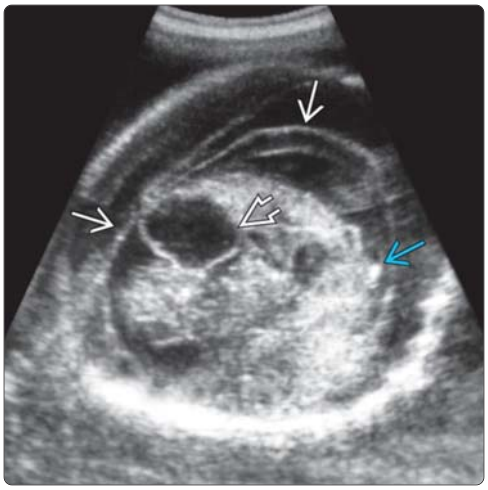

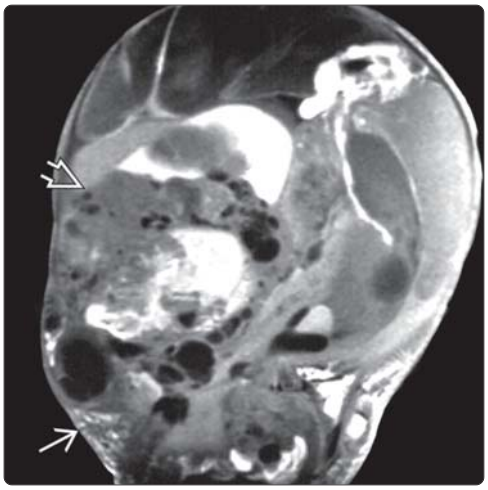

(Left) *Fetal ultrasound shows a fetus with a large head* ➔ *that is almost completely filled with mixed hyper-* ➔ *and hypoechoic* ➔ *tissue. No normal anatomic structures are recognizable. Stillborn fetus with immature teratoma was found.* **(Right)** *Postmortem T1WI of a stillborn infant shows replacement of all brain tissue by a complex mixed signal intensity mass* ➔ *that also extends into the face* ➔*. Immature teratoma with primitive neural ectodermal tissue was identified at autopsy.*

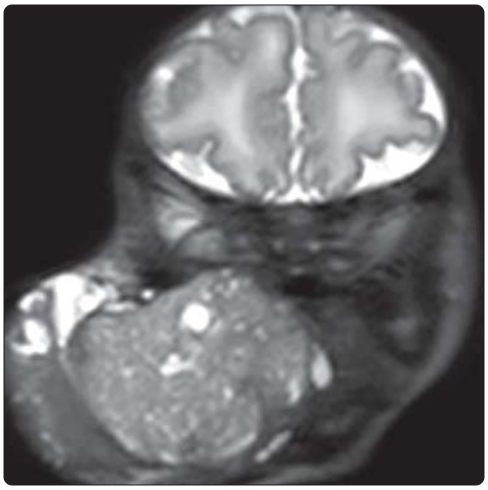

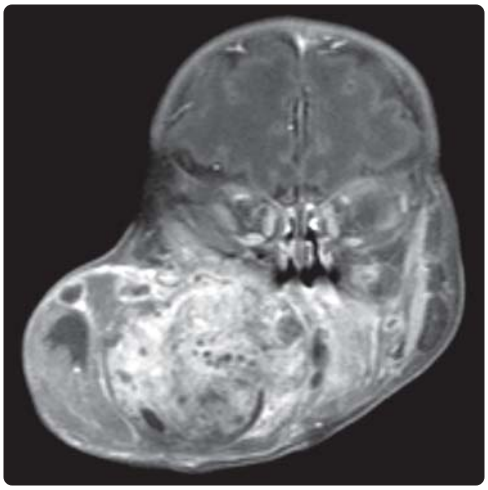

(Left) *Coronal T2WI MR in a newborn infant shows a huge neck mass with relatively low signal intensity (indicating high cellularity) without extension into the brain.* **(Right)** *Coronal T1WI C+ FS MR in the same patient shows the huge mass enhances heterogeneously. Immature teratoma with foci of malignant transformation was found at surgery.*

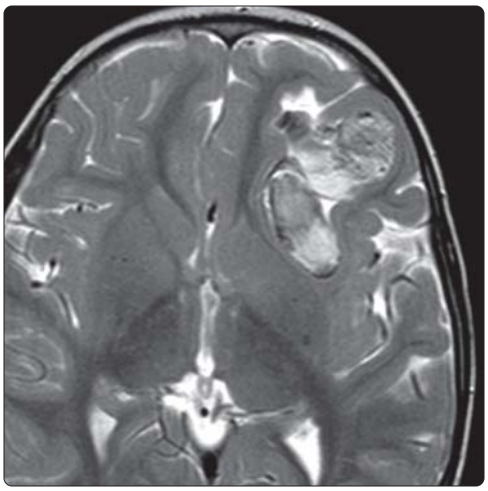

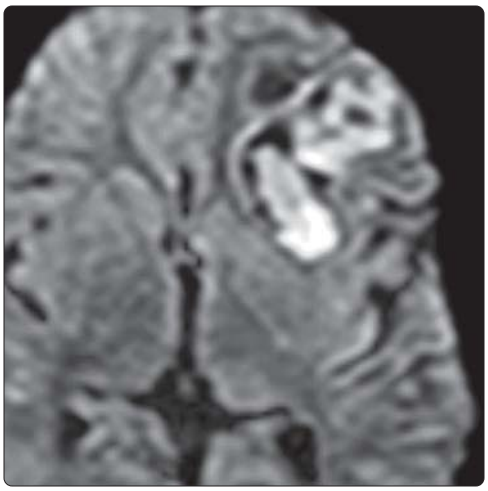

(Left) *Axial T2WI MR shows a significant interval increase in the size of the lesion.* **(Right)** *On axial DWI MR, the left frontal mass appears hyperintense, indicating high cellularity. At surgery, mature teratoma was found.*

https://CafePezeshki.IR

KEY FACTS

TERMINOLOGY

- 2 major types of germ cell tumor (GCTs)
  - Most common = germinoma (50-70%)
  - Nongerminomatous GCTs
- Nongerminomatous malignant GCTs
  - Teratoma with malignant transformation
  - Embryonal carcinoma
  - Yolk sac tumor (endodermal sinus tumor)
  - Choriocarcinoma

IMAGING

- Location
  - Pineal region most common location
  - May occur in suprasellar location
  - Propensity to hug midline
- MR features
  - Hypo-/isointense to gray matter
  - T1 shortening common (protein, blood, or fat)
  - Heterogeneous enhancement ± CSF spread

TOP DIFFERENTIAL DIAGNOSES

- Germinoma
- Pineoblastoma
- Pineal parenchymal tumor of intermediate differentiation (PPTID)
- Pineocytoma
- Astrocytoma

CLINICAL ISSUES

- Peak incidence 10-15 years
- Peripubertal patients (rare < 4 years)
- M:F = 14:1 (purely pineal tumors)
- Visual/endocrine symptoms, Parinaud syndrome
- Signs of hypothalamic/pituitary dysfunction (suprasellar)

DIAGNOSTIC CHECKLIST

- Difficult to differentiate from germinoma on imaging alone

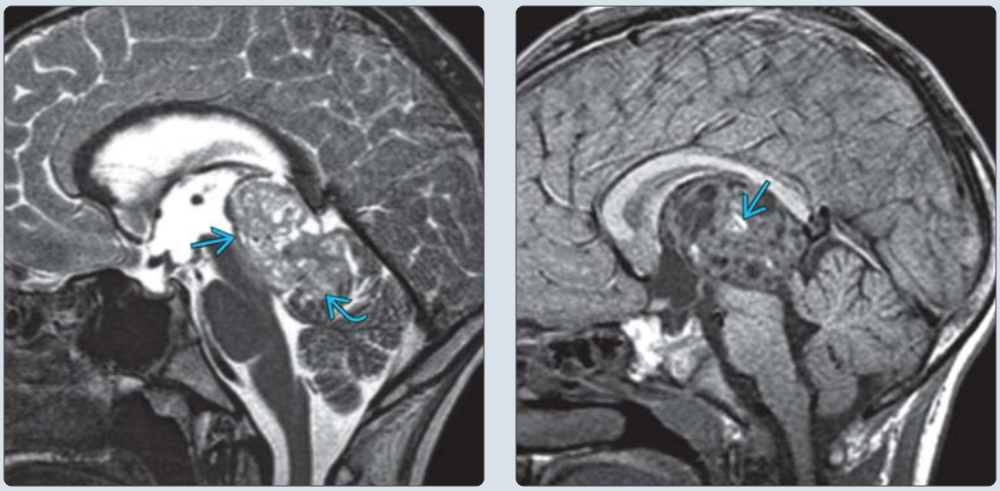

(Left) *Sagittal T2WI FS MR in a 13-year-old boy shows a mixed germ cell tumor (GCT) presenting as a lobulated mixed solid-cystic pineal region mass ⇨ with focal invasion of the vermis ⇨.* **(Right)** *Sagittal T1WI MR in an 8-year-old boy with Parinaud syndrome and embryonal carcinoma shows a heterogeneous mass with foci of T1 shortening that represent hemorrhage ⇨. This tumor, like other intracranial GCTs, tends to hug the midline and may occur as a component of a histologically mixed GCT.*

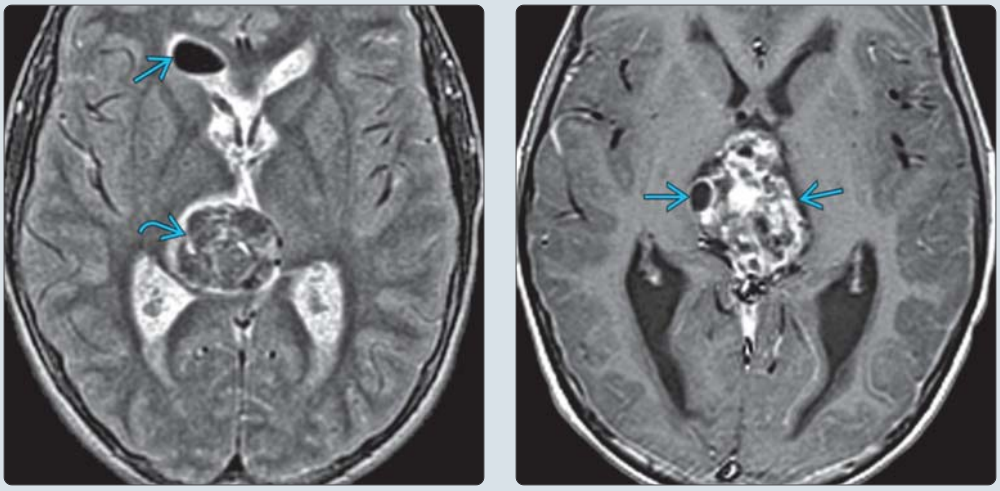

(Left) *Axial T2 MR of a patient with embryonal carcinoma shows a heterogeneous, hypointense, pineal region mass ⇨. Relatively low signal intensity is due to the high nuclear:cytoplasmic ratio in the cells of this highly malignant neoplasm. Also note the air within the frontal horn following ventricular catheter placement ⇨.* **(Right)** *Axial T1WI C+ MR shows heterogeneous enhancement within a pineal embryonal carcinoma ⇨. Embryonal cell carcinomas often have a worse prognosis than a mixed GCT.*

https://CafePezeshki.IR

TERMINOLOGY

Abbreviations

- Germ cell tumor (GCT)

Synonyms

- Malignant GCT
- Primary GCT (PGCT)
- Intracranial GCT

Definitions

- Malignant tumor composed of undifferentiated epithelial cells
- Morphological, immunophenotypic homologues of gonadal/extraneuraxial GCTs but in CNS
- 2 major types of GCTs
  - Germinoma (50-70%)
  - Nongerminomatous GCTs (NGGCTs)
    - Embryonal carcinoma
    - Yolk sac tumor (YST)
    - Choriocarcinoma
    - Teratoma
    - Mixed GCT

IMAGING

General Features

- Best diagnostic clue
  - Heterogeneous pineal or suprasellar mass in adolescent
- Location
  - Hugs midline as do other CNS GCTs
  - Brainstem GCT (rare)
- Size
  - Suprasellar, pineal region GCTs usually smaller than hemispheric tumors
- Morphology
  - Typically lobulated, well circumscribed

CT Findings

- NECT
  - Heterogeneous (mixed iso- to hyperdense)
  - ± hydrocephalus
- CECT
  - Enhancing, ± cysts, hemorrhage

MR Findings

- T1WI
  - Hypo- to isointense to gray matter
  - Short T1 due to protein, blood, or fat
- T2WI
  - Iso- to slightly hyperintense to gray matter
- FLAIR
  - Hyperintense solid elements
- T2* GRE
  - Susceptibility artifact (dephasing) from hemorrhagic foci
- DWI
  - ± restriction within solid components
- T1WI C+
  - Heterogeneous enhancement
  - Variable CSF spread
- MRS
  - ↑ choline, lipid, and lactate
  - ↓ NAA

Angiographic Findings

- Variable (can be very vascular)

Imaging Recommendations

- Best imaging tool
  - C+ MR ± MRS
  - Contrast helpful for majority of tumors
- Protocol advice
  - Preoperative MR of **entire** neuraxis

DIFFERENTIAL DIAGNOSIS

Germinoma

- Typically at midline: Pineal, suprasellar, basal ganglia
- Pineal region mass engulfs pineal gland
- Hyperdense on CT
- Strongly enhancing

Pineoblastoma

- Large, lobulated enhancing pineal mass
- Mass effect, parenchymal invasion, CSF spread
- All ages, but commonly in child or adolescent

Pineal Parenchymal Tumor of Intermediate Differentiation (PPTID)

- Often middle-aged, older patients
- Heterogeneous pineal mass
- WHO grade II or III

Pineocytoma

- Enhancing pineal mass in young adult
- Typically < 3 cm
- May be cystic, solid, or mixed
- May mimic pineal cyst or PPTID

Astrocytoma

- May occur in tectum, splenium of corpus callosum
- T2/FLAIR hyperintense
- Variable enhancement, depending on grade

Supratentorial PNET

- Minimal peritumoral edema
- Heterogeneous, enhancing parenchymal mass

PATHOLOGY

General Features

- Etiology
  - Aberrations in
    - Histogenesis
    - Germ cell migration
    - Stem cells
  - 2 possible theories
    - "Germ cell" theory
      - GCTs arise from primordial germ cells that have migrated aberrantly during embryonic development with subsequent malignant transformation
    - "Embryonic cell" theory

https://CafePezeshki.IR

- Mismigrational pluripotent embryonic cells give rise to GCTs
- Genetics
  - Reports of near triploid complex karyotypes
  - *p14* and *KIT* gene alterations in germinomas
  - Homozygous deletion or frameshift mutation of CDKN2A (71% of ICGCTs)
  - Overexpression of CDKN2A
    - Associated with poor prognosis in intracranial GCTs
- Associated abnormalities
  - Klinefelter syndrome (47XXY)
  - Down syndrome

Staging, Grading, & Classification

- Several types of nongerminomatous GCTs
  - Teratoma (mature, immature, malignant transformation)
  - Yolk sac tumor (endodermal sinus)
  - Embryonal carcinoma
  - Choriocarcinoma
- Malignant GCTs often histologically mixed
  - May exist with both germinomatous, other nongerminomatous GCTs
  - Prognosis correlated with most malignant component
    - Choriocarcinoma, yolk sac tumor, embryonal carcinoma elements have worst prognosis

Gross Pathologic & Surgical Features

- Soft, often friable mass

Microscopic Features

- Undifferentiated epithelial cells
- YST: Delicate fibrovascular projections forming distinct papillae (Schiller-Duval bodies)
- Embryonal carcinoma: Large anaplastic cells with epithelial features and abundant mitoses
- Choriocarcinoma: Extraembryonic differentiation
- Other GCTs usually mixed

Special Immunohistochemical Markers

- Human chorionic gonadotropin (hCG): Choriocarcinoma
- α-fetoprotein (AFP): Teratoma, yolk sac tumor
- Human placental alkaline phosphatase (PLAP): Germinoma, embryonal carcinoma, ± YST, choriocarcinoma
- Cytokeratin: May be seen in all GCTs
- C-Kit (CD117): Germinoma, ± teratoma
- OCT4 (POU5F1): Germinoma, embryonal carcinoma

CLINICAL ISSUES

Presentation

- Most common signs/symptoms
  - Signs of hypothalamic/pituitary dysfunction
  - ↑ intracranial pressure from suprasellar or pineal region mass
  - Other signs/symptoms
    - Visual, endocrine symptoms
    - Parinaud syndrome (paralysis of upward gaze)
  - Brainstem GCT: Pulmonary complaints, cranial neuropathies
- Other signs/symptoms
  - Choriocarcinoma: High serum and CSF hCG
- Clinical profile
  - Adolescent with obstructing midline mass in vicinity of 3rd ventricle, ± focal neuro deficits

Demographics

- Age
  - Strong predilection for peripubertal patients
    - Peak incidence 10-15 years
    - Rare < 4 years
- Gender
  - Males show slight increased incidence for pineal region
    - When purely pineal tumors, M:F = 14:1
  - Female predominance in suprasellar cases
- Ethnicity
  - More common in Asians
    - In Japan 1.8-3% of all primary brain tumors are GCT (in patients < 15 years, 15%)
- Epidemiology
  - Rare (0.3-3.4% of all CNS tumors)
  - Teratoma is leading perinatal brain tumor
    - Accounts for 42% of fetal brain tumors

Natural History & Prognosis

- Locally invasive with metastatic potential
- Follow-up: PLAP, cytokeratin markers
- Yolk sac tumor
  - Median survival: < 2 years
  - 5-year survival rate: < 25%
- Choriocarcinoma is most malignant intracranial GCT
  - High risk of hemorrhage
  - Extraneural/CSF dissemination

Treatment

- Surgical resection → chemotherapy → neuraxis radiation
- Combination of pre- and postirradiation chemotherapy: Improved survival

DIAGNOSTIC CHECKLIST

Consider

- Embryonal carcinoma if heterogeneous pineal region or suprasellar mass in adolescent
- Metastasis of embryonal carcinoma from testicular source
- Metastasis of choriocarcinoma from other source in patients with cerebral hemorrhage and multiple pseudoaneurysms

Image Interpretation Pearls

- Difficult to differentiate from other CNS GCTs on imaging alone

SELECTED REFERENCES

1. Ben Nsir A et al: Primary pure and nonsecreting embryonal carcinoma of the anterior third ventricle: a case report. Pediatr Neurosurg. 50(2):76-9, 2015
2. Lai IC et al: Treatment results and prognostic factors for intracranial nongerminomatous germ cell tumors: single institute experience. Childs Nerv Syst. 31(5):683-91, 2015
3. Ogiwara H et al: Second-look surgery for intracranial germ cell tumors. Neurosurgery. 76(6):658-62, 2015
4. Ogiwara H et al: Apparent diffusion coefficient of intracranial germ cell tumors. J Neurooncol. 121(3):565-71, 2015
5. Takami H et al: Human chorionic gonadotropin is expressed virtually in all intracranial germ cell tumors. J Neurooncol. ePub, 2015
6. Wang L et al: Novel somatic and germline mutations in intracranial germ cell tumours. Nature. 511(7508):241-5, 2014

https://CafePezeshki.IR

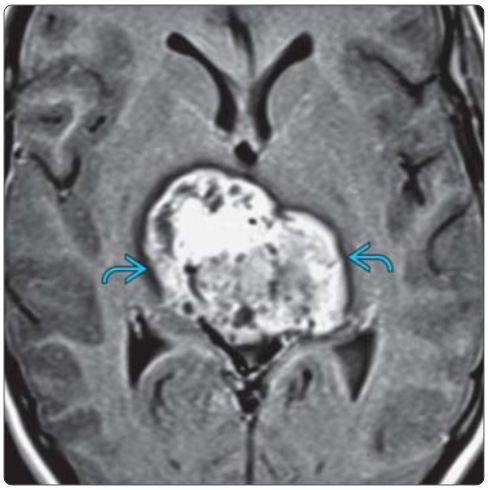

(Left) *Sagittal T1WI MR in a 5-year-old boy shows a well-circumscribed, lobulated, low signal intensity, midline, pineal region mass with a small cystic component. (Courtesy A. Rossi, MD.)* **(Right)** *Axial T1WI C+ MR in the same patient shows intense, but heterogeneous enhancement of the mass. No evidence of CSF dissemination was identified on preoperative evaluation of the entire neuraxis. Histopathology revealed a yolk sac tumor. (Courtesy A. Rossi, MD.)*

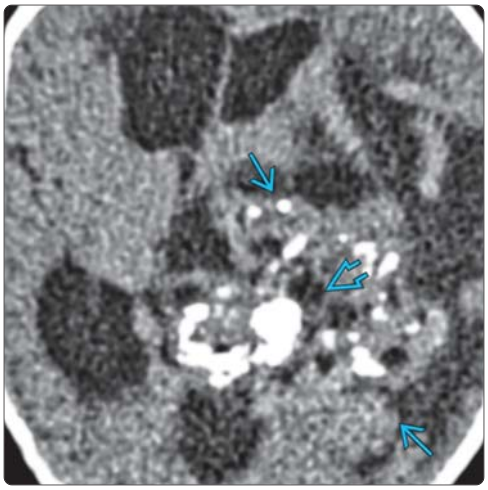

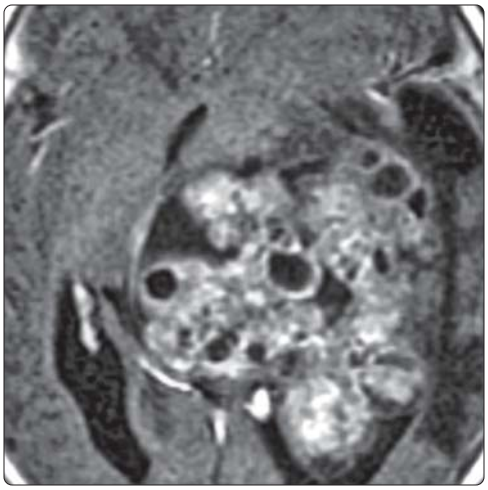

(Left) *Axial NECT shows a lobulated heterogeneous mass centered in the left hypothalamus and causing obstructive hydrocephalus. Note the multiple calcifications, intratumoral cysts and surrounding edema.* **(Right)** *Axial T1WI MR in the same patient demonstrates the very heterogeneous nature of the mass. Foci of enhancing solid tumor intermixed with cysts characterize this neoplasm. An immature teratoma was found at histopathological examination.*

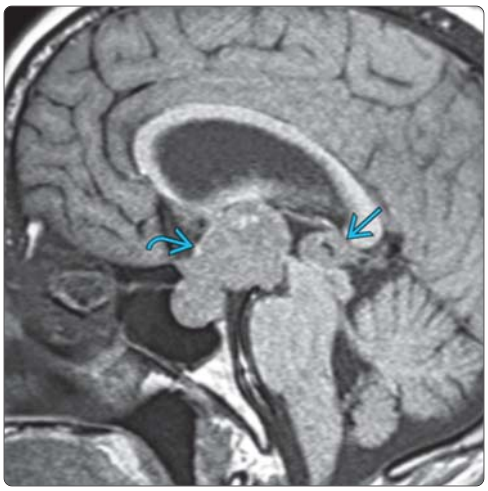

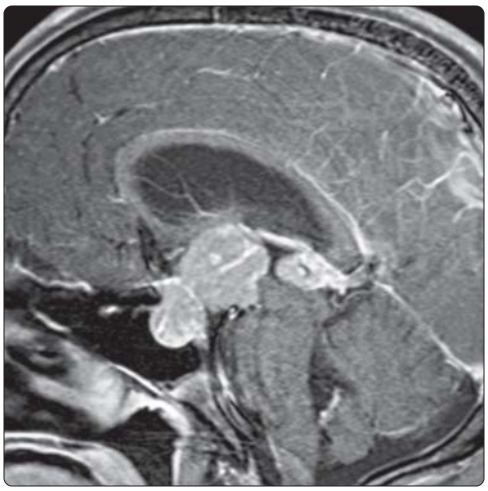

(Left) *Sagittal T1WI MR in a 22-year-old man with headaches, diabetes insipidus, and a hyperdense suprasellar mass on NECT (not shown) reveals a "double midline" mass with a small pineal lesion and a larger sellar and suprasellar mass.* **(Right)** *Sagittal T1WI C+ FS MR in the same patient shows intense but heterogeneous enhancement. Preoperative diagnosis was germinoma. Biopsy disclosed embryonal carcinoma, a highly malignant neoplasm.*

https://CafePezeshki.IR

KEY FACTS

TERMINOLOGY

- Secondary brain tumors (metastases) arise from
  - Tumors outside CNS spreading to CNS (usually via hematogenous dissemination)
  - Primary CNS neoplasms spreading from one site to another (usually geographic extension, e.g., along WM tracts)

IMAGING

- General features
  - Round enhancing lesion(s) at gray-white interface (arterial border zones)
  - Most metastases are circumscribed/discrete > > infiltrating, spherical > > linear
  - 50% are solitary; 20% have 2 metastases
  - 30% of patients have 3 or more
- MR signal intensity varies with
  - Cellularity, nuclear:cytoplasmic ratio
  - Presence/absence of hemorrhage
- Usually no restriction on DWI
  - Exception: Densely cellular metastases may restrict

TOP DIFFERENTIAL DIAGNOSES

- Abscess (solitary or multiple)
- Glioblastoma multiforme
- Cerebral infarction (multiple embolic)
- Demyelinating disease (e.g., tumefactive MS)

PATHOLOGY

- Metastases represent at least 50% of all brain tumors
- In 10% of cases, brain is only site

CLINICAL ISSUES

- Progressive increase in size and numbers is typical
- Median survival with whole brain XRT = 3-6 months
- Stereotactic radiosurgery alone > whole brain XRT
- Survival advantage if 1-4 metastases, avoids deleterious effects of whole brain XRT on quality of life, cognition
- Resection of solitary metastasis may improve survival

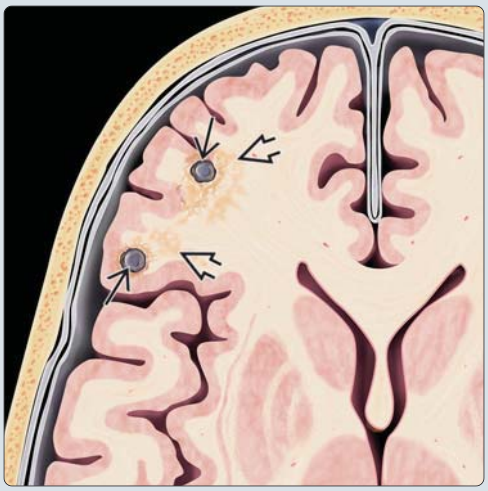

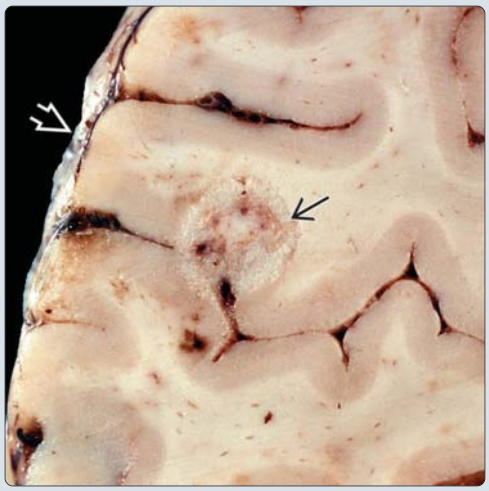

(Left) *Axial graphic shows parenchymal metastases ⇨ with surrounding edema ⇨. The gray-white matter junction is the most common location. Most metastases are round, not diffusely infiltrating.* **(Right)** *Close-up view of an axial section through an autopsied brain shows a classic metastasis ⇨ in the classic location, the gray-white matter junction. Note the round shape, central necrosis, and relative lack of edema. Diffuse leptomeningeal metastatic spread ⇨ is also present.*

(Left) *Axial T2WI MR in a 52-year-old man with a seizure, history of melanoma, shows multiple lesions ⇨ at the gray-white matter interfaces. Moderate edema surrounds the lesions. One of the lesions has a hypointense nodule ⇨ suggesting at least one is a hemorrhagic metastasis.* **(Right)** *Axial T1 C+ FS MR in the same patient shows the parenchymal lesions enhance ⇨. Note small metastasis ⇨ in the choroid plexus of the right lateral ventricle that was not appreciated on T2WI.*

https://CafePezeshki.IR

TERMINOLOGY

Abbreviations

- Parenchymal metastases (mets)

Definitions

- Secondary brain tumors (metastases) arise from
  - Tumors outside CNS that spread to CNS (usually via hematogenous dissemination)
  - Primary CNS neoplasms that spread from one site to another (usually geographic spread, e.g., along white matter [WM] tracts)

IMAGING

General Features

- Best diagnostic clue
  - Discrete enhancing lesion(s) at gray-white interface
- Location
  - Common: At arterial border zones/gray-white matter (GM-WM) junctions
    - 80% hemispheres
    - 15% cerebellum
    - 3% basal ganglia
    - < 1% midbrain, pons, medulla
  - Uncommon
    - Only 5% deep white matter
  - Rare
    - Diffusely infiltrating tumors ("carcinomatous encephalitis")
      - Perivascular (e.g., intravascular lymphoma)
      - Perineural (e.g., adenocystic carcinoma along CN5 to pons)
- Morphology
  - Most mets are circumscribed/discrete > > infiltrating, spherical > > linear
  - 50% of metastases are solitary
  - 20% 2 metastases
  - 30% 3 or more

CT Findings

- NECT
  - Iso-/hypodense mass(es) at GM-WM interface
  - Variable peritumoral edema (none to striking)
  - Variable intracranial hemorrhage (ICH)
    - Mets may cause "spontaneous" ICH in elderly
- CECT
  - Intense, punctate, nodular, or ring enhancement
  - Conspicuity, number, volume of tumors may increase on delayed scans

MR Findings

- T1WI
  - Most common: Iso-/hypointense
  - Less common: Hyperintense
    - Some nonhemorrhagic mets (e.g., melanoma) have intrinsically short T1
    - Hemorrhagic metastases
      - Disordered/bizarre appearance, evolution (compared to nonneoplastic ICH)
- T2WI
  - Signal varies depending on
    - Cellularity, nuclear:cytoplasmic ratio
    - Presence/absence of hemorrhage
  - Multifocal hyperintense mets mimic vascular WM disease
- FLAIR
  - Usually moderately hyperintense with strikingly hyperintense adjacent edema
- T2* GRE
  - "Blooms" if hemorrhage present
- DWI
  - Usually no restriction on DWI
    - Exception: Densely cellular mets may restrict
- T1WI C+
  - Almost all mets enhance
    - Enhancement usually strong
    - Patterns variable
      - Solid, uniform
      - Nodular
      - Ring-like
  - Dynamic susceptibility contrast-enhanced MR
    - May show elevated rCBV
    - Can be difficult to distinguish metastasis from high-grade glioma on standard imaging
      - rCBV in adjacent brain higher for glioma than metastasis
- MRS
  - Elevated Cho
  - Lipid or lipid/lac peak often present
  - 80-85% lack Cr peak
- DTI
  - Fractional anisotropy helpful in distinguishing met from glioblastoma multiforme (GBM)
  - Tractography may help detect WM tract invasion

Nuclear Medicine Findings

- PET
  - PET/CT helpful for systemic mets
    - Not as sensitive as MR for brain parenchymal lesions
  - PET/MR
    - May be superior for melanoma staging

Imaging Recommendations

- Best imaging tool
  - MR with DWI, T2*, T1WI C+
- Protocol advice
  - T1WI C+ with FS enhances lesion conspicuity
  - 3D MP-RAGE sequence may improve detection
  - T2 C+ FLAIR may show more small (< 3 mm) lesions
  - Delayed sequences at 20-30 minutes often show additional lesions
  - Double- or triple-contrast dose increases sensitivity but of questionable value on routine basis

DIFFERENTIAL DIAGNOSIS

Abscess

- Usually restricts on DWI
- MRS: Elevated amino acids, lactate in cystic component; no Cho elevation

https://CafePezeshki.IR

Glioblastoma Multiforme

- Tends to be infiltrating, deep location (rather than discrete gray-white junction masses)
- Solitary > multifocal
  - Solitary met can mimic GBM

Multiple Embolic Cerebral Infarction

- Arterial border-zone location common
- Ring-enhancing pattern uncommon
- Multiple acute embolic strokes usually show restricted diffusion
- Chronic-appearing hyperintensities
  - If they do not enhance, they are not metastases

Multiple Sclerosis

- Periventricular > gray-white junction
- Incomplete ring, horseshoe-shaped enhancement
- Younger patients

PATHOLOGY

General Features

- Etiology
  - Hematogenous spread from systemic primary neoplasm
    - Lung, breast, melanoma most common primary malignancies
    - 10% unknown source
- Genetics
  - Metastasis formation is complex, often genetically mediated event
    - Inactivation of tumor suppressor genes
    - Activation of protooncogenes
- Associated abnormalities
  - Other organs often involved
  - In 10% of cases, brain is only site
  - Limbic encephalitis
    - Paraneoplastic syndrome (remote effect of cancer)
    - Resembles herpes encephalitis (subacute clinical presentation)

Gross Pathologic & Surgical Features

- Round/confluent, relatively discrete, tan or grayish-white mass
- Edema, mass effect varies from little to striking
- Hemorrhage common with some mets (melanoma, choriocarcinoma, lung/renal cell carcinomas)

Microscopic Features

- Usually similar to primary neoplasm
- Metastases usually displace rather than infiltrate tissue
- Necrosis, neovascularity common
- Marked mitoses; labeling index may be greater than primary

CLINICAL ISSUES

Presentation

- Most common signs/symptoms
  - Seizure, focal neurologic deficit
- Clinical profile
  - Middle-aged/elderly patient with known systemic cancer, new onset of neurological symptoms

Demographics

- Age
  - Incidence increases with age
    - Rare in children (skull/dura more common site than parenchyma)
    - Peak prevalence over 65 years
- Gender
  - Slight male predominance
- Epidemiology
  - With better treatment, patients with systemic cancers are surviving longer
    - Mets now most common CNS tumors in adults
  - Result
    - Prevalence of metastases vs. primary CNS neoplasms increasing
    - Now account for up to 50% of all brain tumors
    - Brain involvement is found in 25% of systemic cancer patients at autopsy

Natural History & Prognosis

- Progressive increase in size and numbers is typical
- Median survival with whole brain XRT = 3-6 months
  - Younger age, high Karnofsky performance status associated with longer survival

Treatment

- Stereotactic radiosurgery alone > whole brain XRT
  - Survival advantage if 1-4 mets, avoids deleterious effects of whole brain XRT on quality of life, cognition
- Resection of solitary metastasis may improve survival

DIAGNOSTIC CHECKLIST

Consider

- Spontaneous ICH or new onset seizures in elderly patient may be caused by metastasis

Image Interpretation Pearls

- White matter disease (UBOs) in elderly patient can be caused by multifocal metastases
- Consider T1WI C+ in patients with WM disease, unexplained mental decline

SELECTED REFERENCES

1. Kwak HS et al: Detection of small brain metastases at 3 T: comparing the diagnostic performances of contrast-enhanced T1-weighted SPACE, MPRAGE, and 2D FLASH imaging. Clin Imaging. ePub, 2015
2. Pfannenberg C et al: [Whole-body staging of malignant melanoma: advantages, limitations and current importance of PET-CT, whole-body MRI and PET-MRI.] Radiologe. 55(2):120-6, 2015
3. Puhalla S et al: Unsanctifying the sanctuary: challenges and opportunities with brain metastases. Neuro Oncol. 17(5):639-651, 2015
4. Rodriguez A et al: Neurosurgical management of brain metastases. Curr Probl Cancer. ePub, 2015
5. Seidel C et al: Analysis of frequency of deep white matter metastasis on cerebral MRI. J Neurooncol. ePub, 2015
6. Sneed PK et al: Adverse radiation effect after stereotactic radiosurgery for brain metastases: incidence, time course, and risk factors. J Neurosurg. 1-14, 2015
7. Nensa F et al: Clinical applications of PET/MRI: current status and future perspectives. Diagn Interv Radiol. 20(5):438-47, 2014

https://CafePezeshki.IR

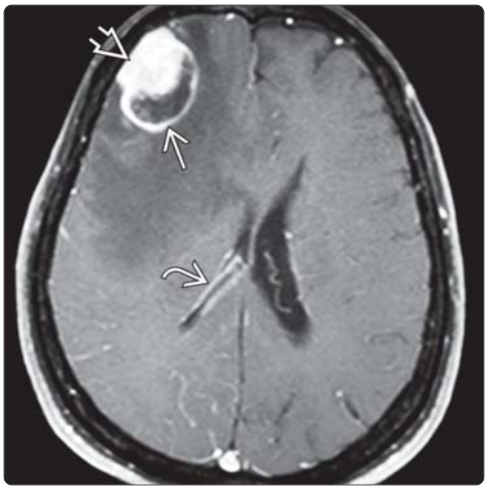

(Left) *Axial T2WI MR shows a solitary metastasis from lung carcinoma in the right frontal lobe ⇨. A large amount of edema surrounds the lesion and there is significant subfalcine herniation of the lateral ventricle secondary to the mass effect.* **(Right)** *Axial T1 C+ FS in the same patient shows the solitary parenchymal metastasis has a cyst ➡ + nodule ➡ configuration. Close inspection of the image shows ependymal enhancement along the wall of the right lateral ventricle ➡.*

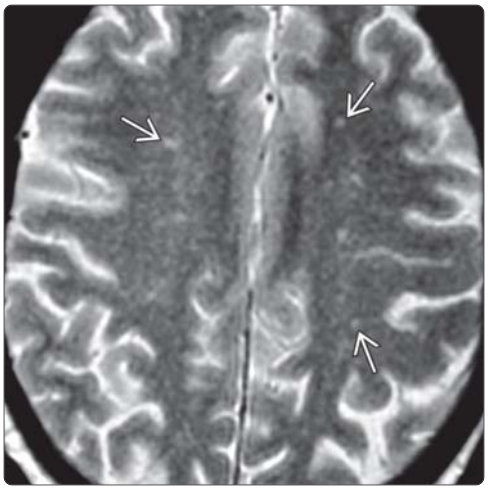

(Left) *Axial T2WI MR in a middle-aged patient with unexplained mental decline and normal neurologic examination shows multifocal white matter hyperintensities (WMHs) ➡. These are indistinguishable from the usual WMHs of small vessel disease, most commonly arteriolosclerosis.* **(Right)** *Axial T1WI C+ MR in the same patient demonstrates that several of the WMHs enhance ➡. Other images (not shown) revealed several subependymal enhancing foci. Further evaluation revealed breast carcinoma.*

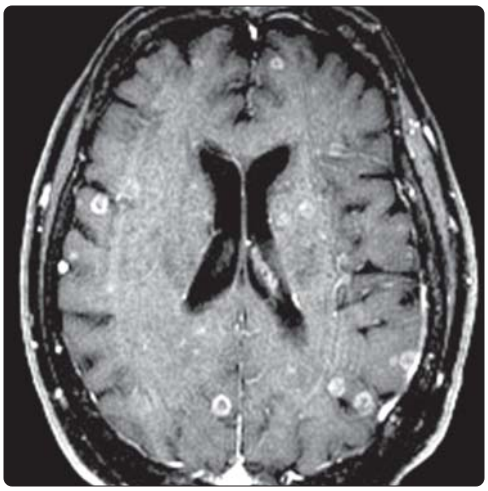

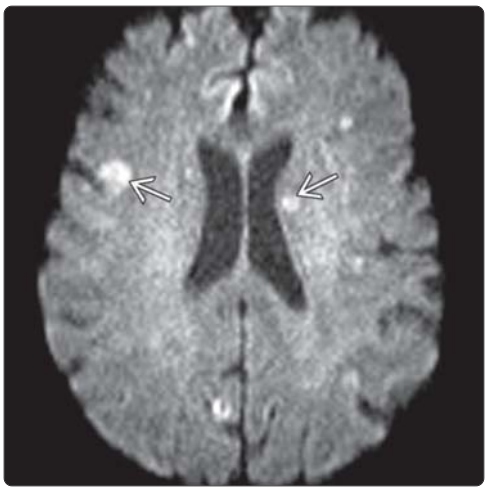

(Left) *Axial T1WI C+ FS MR in a 70-year-old woman with breast cancer shows multiple punctate and ring-enhancing lesions.* **(Right)** *Axial DWI MR in the same patient shows several foci of restricted diffusion ➡ that were hypointense on ADC (not shown). Most neoplasms do not restrict, but metastases often have a high nuclear to cytoplasm ratio and sometimes show restricted diffusion.*

https://CafePezeshki.IR

KEY FACTS

TERMINOLOGY

- Brain metastases in locations other than skull/meninges or parenchyma

IMAGING

- General features
  - > 95% of brain metastases parenchymal
  - Only 1-2% in ventricles, pituitary gland, etc.
  - Sites generally very vascular
  - Extraventricular metastases more diffuse, infiltrative than parenchymal mets (usually round)
- Location
  - Choroid plexus ± ventricular ependyma
  - Pituitary gland infundibulum
  - Eye (choroid)
  - Cranial nerves
  - Pineal gland
  - Preexisting neoplasm ("collision tumor")
- Best imaging tool: MR with T1WI C+ FS
  - Metastases almost always enhance

TOP DIFFERENTIAL DIAGNOSES

- Varies with location
- Choroid plexus, ventricle = meningioma
- Pituitary gland, infundibular stalk
  - Pituitary macroadenoma
  - Lymphocytic hypophysitis
  - Lymphoma
- Cranial nerves = NF2, lymphoma
- Eye (globe)
  - Ocular melanoma
  - Retinal or choroidal detachment
  - Choroidal hemangioma

DIAGNOSTIC CHECKLIST

- Look for "secret sites" outside parenchyma when imaging brain for possible metastatic disease

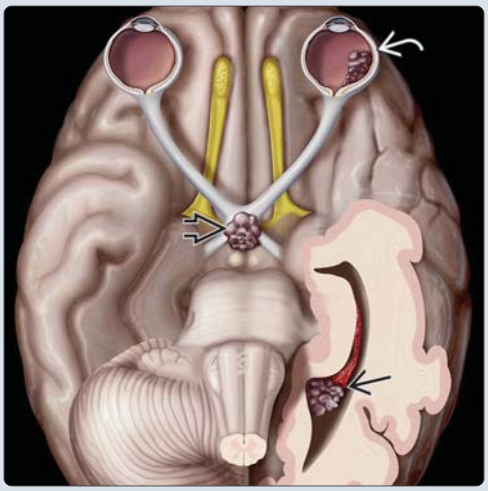

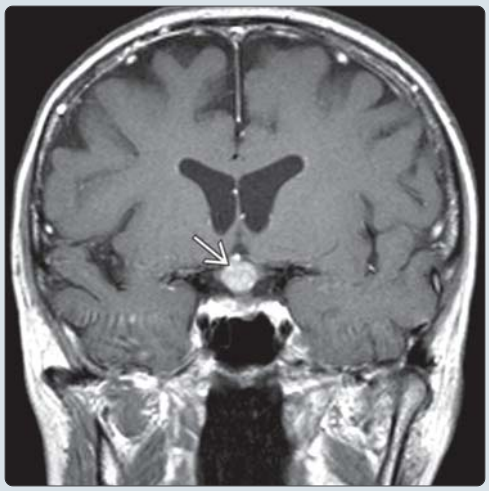

(Left) *Submentovertex graphic shows the typical sites for miscellaneous nonparenchymal CNS metastases. These include the choroid plexus and ventricles ⇨, pituitary gland, infundibular stalk ⇨, and eye (choroid of the retina) ⇨.* **(Right)** *Coronal T1WI C+ MR in an elderly woman with known breast carcinoma shows a thickened, enhancing infundibular stalk ⇨. This was the only intracranial metastasis identified in this patient.*

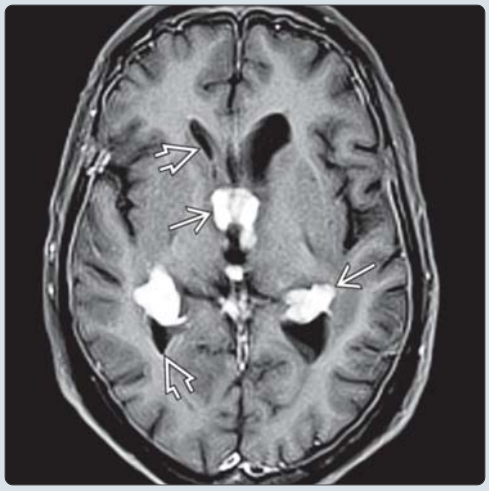

(Left) *Axial T1 C+ FS in a patient with diplopia and known esophageal cancer shows an enhancing nodule on the left 3rd cranial nerve ⇨, as well as on the left optic nerve/sheath ⇨. Cranial nerve metastases from extracranial tumors are less common than from hematopoietic neoplasms (e.g., lymphoma).* **(Right)** *Axial T1 C+ FS in a patient with systemic B-cell lymphoma shows multiple metastases to the choroid plexus ⇨. Subtle ependymal metastases ⇨ are present along with diffuse dura-arachnoid thickening.*

https://CafePezeshki.IR

TERMINOLOGY

Definitions

- Brain metastases in locations other than skull/meninges, parenchyma

IMAGING

General Features

- Best diagnostic clue
  - "Unusual" mass in patient with known systemic primary neoplasm
- Location
  - In general, sites very vascular
  - Choroid plexus ± ventricular ependyma
  - Pituitary gland, infundibulum
  - Cranial nerves
  - Eye (uvea)
    - Usually late stage, disseminated disease, poor prognosis
  - Pineal gland
  - Preexisting neoplasm ("collision tumor")
    - 2 unique tumor types within single lesion
    - Metastasis to meningioma most common
- Morphology
  - Often more diffuse, infiltrative than round parenchymal metastases

Imaging Recommendations

- Best imaging tool
  - MR with T1WI C+ FS

DIFFERENTIAL DIAGNOSIS

Choroid Plexus, Ventricle

- Meningioma
- Choroid plexus cyst (xanthogranuloma)
- Ventriculitis/choroid plexitis

Pituitary Gland, Infundibular Stalk

- Pituitary macroadenoma
- Lymphocytic hypophysitis
- Lymphoma

Cranial Nerves (Multiple Enhancing)

- Lymphoma
  - May be indistinguishable from other metastases
  - CNs, brain surface often coated
- Neurofibromatosis type 2
- Lyme disease
- Chronic inflammatory demyelinating polyneuropathy

Eye (Globe)

- Ocular melanoma
  - Most ocular melanomas are choroidal
  - Ciliary body, iris lesions less common
- Retinal or choroidal detachment
  - Retina is V-shaped
  - Choroid is ovoid, parallel to choroidal plane
- Choroidal hemangioma
  - Middle-aged/elderly patients
  - Lenticular mass in juxtapapillary or macular region
  - Can be solitary or diffuse
  - Avid enhancement (> metastasis, melanoma)

PATHOLOGY

General Features

- Etiology
  - Extracranial primary sources
    - Breast carcinoma most common
    - Others include lung, kidney, colon
  - Intracranial sources of "brain-to-brain" metastases
    - Glioblastoma multiforme, anaplastic astrocytoma most common
      - White matter > extraparenchymal sites
- Associated abnormalities
  - Other CNS metastases (often multifocal)
    - Parenchyma
    - Pia-subarachnoid space
    - Skull, meninges
  - Systemic metastases
    - Often multiorgan
    - In 10% of cases, brain is only metastatic site

CLINICAL ISSUES

Presentation

- Most common signs/symptoms
  - Varies with location

Demographics

- Age
  - Middle-aged, older patients
- Epidemiology
  - > 95% of brain metastases parenchymal
  - Only 1-2% found in ventricles, pituitary gland, etc.

DIAGNOSTIC CHECKLIST

Consider

- Metastasis in middle-aged or older patient with intraventricular or intraocular mass

Image Interpretation Pearls

- Look for "secret sites" outside parenchyma when imaging brain for possible metastatic disease

SELECTED REFERENCES

1. Arepalli S et al: Choroidal metastases: Origin, features, and therapy. Indian J Ophthalmol. 63(2):122-7, 2015
2. Shields CL et al: Iris metastasis from systemic cancer in 104 patients: the 2014 Jerry A. Shields Lecture. Cornea. 34(1):42-8, 2015
3. Shah SU et al: Uveal metastasis from lung cancer: clinical features, treatment, and outcome in 194 patients. Ophthalmology. 121(1):352-7, 2014
4. Shapira Y et al: The ventricular system and choroid plexus as a primary site for renal cell carcinoma metastasis. Acta Neurochir (Wien). 156(8):1469-74, 2014

https://CafePezeshki.IR

KEY FACTS

TERMINOLOGY

- Secondary involvement of CNS in patients with systemic lymphoma

IMAGING

- Secondary CNS lymphoma: Skull, dura, leptomeninges >> parenchymal mass
- Best diagnostic clue: Diffusely enhancing dural mass ± bone involvement
  - May see leptomeningeal enhancement or nonsupression of CSF on FLAIR; CT hyperdensity
- Lower rCBV than other tumors

TOP DIFFERENTIAL DIAGNOSES

- Meningioma
- Meningeal metastases
- Primary CNS lymphoma
- Leptomeningeal disease
- Hemangiopericytoma

CLINICAL ISSUES

- Prognostic markers suggestive of CNS relapse
  - Elevated serum lactate dehydrogenase (LDH) levels
  - Presence of B symptoms
  - Extranodal involvement at more than 1 site
  - Advanced stage
- Aggressive histologic features increase risk for SCNSL
- Involvement of liver, bladder, testis, or adrenals increases risk of CNS spread
- CNS involvement of lymphoma almost always fatal
- Prophylactic CNS chemotherapy recommended for patients considered at high risk of CNS recurrence

DIAGNOSTIC CHECKLIST

- Occult lymphoma found in 8% of patients presenting with CNS lymphoma
- SCNSL commonly mimics meningioma or other metastatic disease

(Left) *Axial CECT shows extensive dural enhancement related to metastatic intracranial lymphoma. Secondary lymphoma has a propensity for the meninges. About 1/3 of systemic lymphoma patients develop CNS disease.* **(Right)** *Axial T1 C+ MR shows an enhancing central skull base mass with associated dural and leptomeningeal enhancement within the internal auditory canals. The clivus is often involved by metastatic disease, particularly breast cancer and lymphoma.*

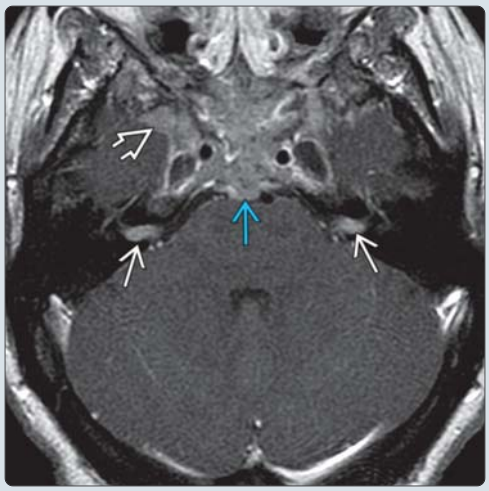

(Left) *Axial T1 C+ MR in a 54-year-old man with systemic lymphoma shows multiple enhancing masses. Some lesions involve the dura, while others are parenchymal. Metastatic intracranial lymphoma often involves the dura and may mimic a meningioma.* **(Right)** *Axial T1WI C+ FS MR shows enhancement along the maxillary division (V2) of CN5, extending from the cavernous sinus into the pterygopalatine fossa, in this patient with systemic lymphoma and new facial paresthesias.*

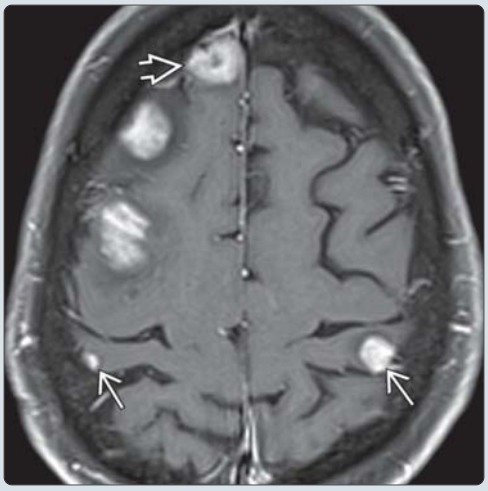

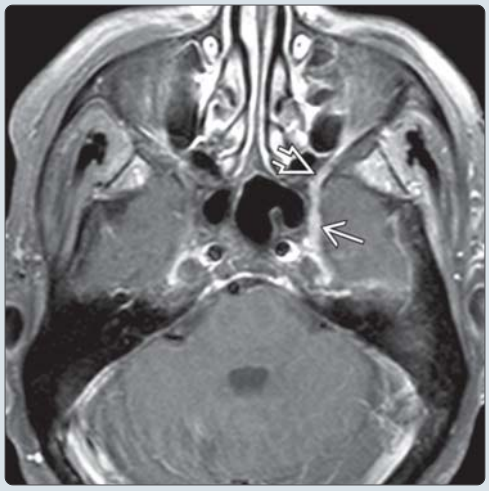

https://CafePezeshki.IR

TERMINOLOGY

Synonyms

- Secondary CNS lymphoma (SCNSL)

Definitions

- Secondary involvement of CNS in patients with systemic lymphoma

IMAGING

General Features

- Best diagnostic clue
  - Enhancing dural mass ± bone involvement
- Location
  - Typically involves dura or leptomeninges
  - Parenchymal lesions may occur
  - Peripheral nerve = neurolymphomatosis
  - Spine involvement: ~ 3-5%
- Morphology
  - Solitary mass or multiple lesions
  - May be circumscribed or infiltrative

Imaging Recommendations

- Protocol advice
  - Contrast-enhanced MR

MR Findings

- T1WI
  - Single or multiple iso- or hypointense mass(es)
- T2WI
  - Homogeneously iso- or hypointense to cortex
- FLAIR
  - Leptomeningeal: Nonsuppression of CSF in sulci
- PWI
  - Lower rCBV than other tumors
- T1WI C+
  - Diffusely enhancing dural mass ± bone changes
  - May see leptomeningeal enhancement

DIFFERENTIAL DIAGNOSIS

Meningioma

- Enhancing mass with dural tail in older women
- Often solitary
- May be indistinguishable

Meningeal Metastases

- Prostate and breast primaries may cause dural metastases
- Calvarial erosion may be seen

Primary CNS Lymphoma

- Periventricular or basal ganglia-enhancing mass
- Typically DWI+
- May rarely present as dural mass

Leptomeningeal Disease

- Infectious meningitis usually diagnosed clinically
- Carcinomatous meningitis indistinguishable

Hemangiopericytoma

- Lobular extraaxial mass ± skull erosion
- Heterogeneous enhancement typical

PATHOLOGY

General Features

- Etiology
  - Secondary involvement of CNS in patients with systemic lymphoma (typically systemic B-cell lymphomas 80%)
  - CNS involvement occurs in 22% of post-transplantation lymphomas

Staging, Grading, & Classification

- Highly aggressive lymphomas (i.e., lymphoblastic and Burkitt) carry high risk of CNS relapse
- Intermediately aggressive subtypes (i.e., diffuse large B-cell lymphoma) carry lower risk of CNS relapse
- Hodgkin disease uncommon

Gross Pathologic & Surgical Features

- Typically firm dural mass
- Parenchymal mass less common

CLINICAL ISSUES

Presentation

- Most common signs/symptoms
  - Headache, altered mental status
- Clinical profile
  - Polymerase chain reaction (PCR) and flow cytometry assays of CSF useful for correct diagnosis

Demographics

- Age
  - Typically 6th-7th decade

Natural History & Prognosis

- Prognostic markers suggestive of CNS relapse of lymphoma
  - Elevated serum lactate dehydrogenase (LDH) levels
  - Presence of B symptoms
    - Fever, night sweats, weight loss
  - Extranodal involvement at more than 1 site
  - Advanced stage
- Aggressive histologic features increase risk for SCNSL
- Involvement of liver, bladder, testis, or adrenals increases risk of CNS spread
- CNS involvement is almost always fatal

Treatment

- Prophylactic CNS chemotherapy for patients considered at high risk of CNS recurrence

DIAGNOSTIC CHECKLIST

Consider

- Occult systemic lymphoma found in 8% of patients presenting with CNS lymphoma

SELECTED REFERENCES

1. Oh DH et al: Treatment of patients with secondary central nervous system lymphoma with high-dose busulfan/thiotepa-based conditioning and autologous stem cell transplant. Leuk Lymphoma. 1-6, 2015
2. Baraniskin A et al: Modern cerebrospinal fluid analyses for the diagnosis of diffuse large B-cell lymphoma of the CNS. CNS Oncol. 3(1):77-85, 2014
3. Ferreri AJ: Risk of CNS dissemination in extranodal lymphomas. Lancet Oncol. 15(4):e159-69, 2014
4. Louis DN et al: WHO classification of tumours of the central nervous system: Malignant lymphomas. Lyon: IARC Press. 188-92, 2007

https://CafePezeshki.IR

KEY FACTS

TERMINOLOGY

- Remote neurological effects of cancer, associated with extra-CNS tumors
  - Most common tumor: Small cell lung carcinoma
- Limbic encephalitis (LE) is most common clinical paraneoplastic syndrome

IMAGING

- Limbic encephalitis: Hyperintensity in mesial temporal lobes, limbic system
  - Mimics herpes encephalitis but subacute/chronic
- Paraneoplastic cerebellar degeneration (PCD): Cerebellar atrophy
- Brainstem encephalitis: T2 hyperintensity in midbrain, pons, cerebellar peduncles, basal ganglia
- Most paraneoplastic syndromes do not have associated imaging findings

TOP DIFFERENTIAL DIAGNOSES

- Herpes encephalitis
- Low-grade (grade II) diffuse astrocytoma
- Status epilepticus
- Gliomatosis cerebri

CLINICAL ISSUES

- < 1% of patients with systemic cancers develop paraneoplastic syndrome
- Immune-mediated by autoantibodies or cytotoxic T cell-related mechanisms
  - 60% have circulating serum autoantibodies
- LE: Memory loss, cognitive dysfunction, dementia, psychological features, seizures
- PCD: Ataxia, incoordination, dysarthria, nystagmus
- Brainstem encephalitis: Brainstem dysfunction including cranial nerve palsies, visual changes
- Treatment of primary tumor may improve symptoms

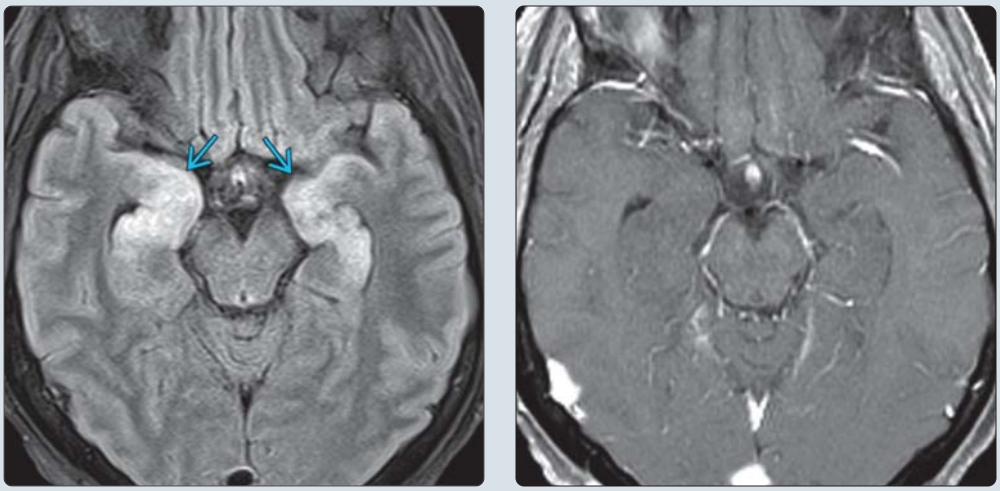

(Left) *Axial FLAIR MR shows abnormal hyperintensity in the bilateral medial temporal lobes, characteristic of limbic encephalitis, the most common paraneoplastic syndrome. Bilateral involvement is typical of limbic encephalitis.* **(Right)** *Axial T1WI C+ MR in the same patient shows no significant enhancement in the medial temporal lobes. Enhancement is often present in limbic encephalitis. The patient's symptoms often improve after treatment of the primary tumor.*

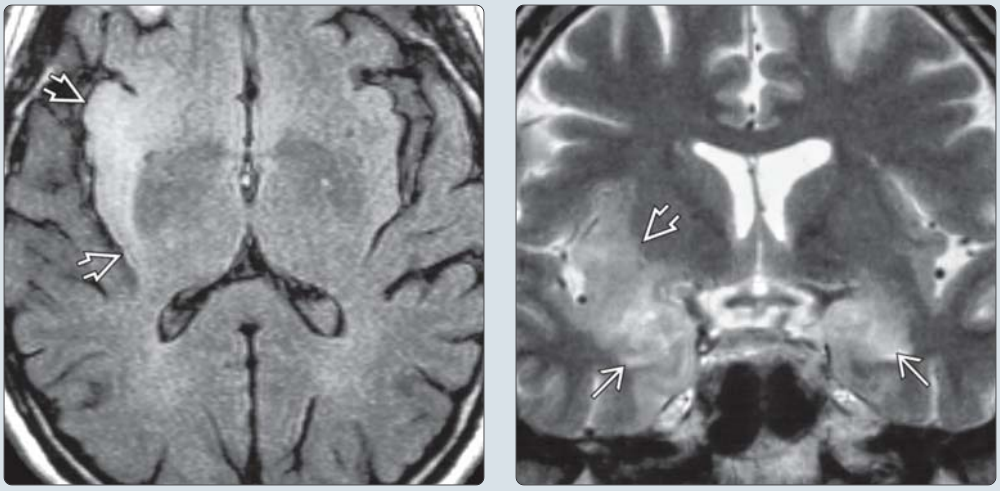

(Left) *Axial FLAIR MR in an older adult with small cell lung cancer and subacute dementia shows striking hyperintensity in the right insula.* **(Right)** *Coronal T2WI in the same patient shows abnormal hyperintensity in both medial temporal lobes and right insular cortex. Imaging of limbic encephalitis mimics that of herpes encephalitis; however, patients with limbic encephalitis have a subacute presentation. Hemorrhage suggests herpes rather than limbic encephalitis.*

https://CafePezeshki.IR

TERMINOLOGY

Synonyms

- Paraneoplastic syndromes (PS), paraneoplastic disease

Definitions

- Remote neurological effects of cancer, associated with extra-CNS tumors
  - Most common tumor: Small cell lung carcinoma
- Limbic encephalitis (LE) is most common clinical paraneoplastic syndrome
  - Only PS with clearly defined imaging features

IMAGING

General Features

- Best diagnostic clue
  - Limbic encephalitis: Hyperintensity in mesial temporal lobes, limbic system
    - Looks like herpes encephalitis but different clinical course (subacute vs. chronic)
  - Initial study normal in 20-40%
- Location of LE: Hippocampus, amygdala, cingulate gyrus, pyriform cortex, subfrontal cortex, insula

CT Findings

- NECT: Initial CT scan normal in > 95%
  - Rare: Low density within mesial temporal lobes
- CECT: Usually no visible enhancement

MR Findings

- T1WI
  - Hypointensity in mesial temporal lobes (hippocampus, amygdala), insula, cingulate gyrus, subfrontal cortex, inferior frontal white matter (WM)
  - May see minimal mass effect
  - May see atrophy in chronic cases
  - No hemorrhage
- DWI
  - Diffusion restriction rare
- T2WI: Hyperintensity in mesial temporal lobes (hippocampus, amygdala), insula, cingulate gyrus, subfrontal cortex, inferior frontal WM
  - May see minimal mass effect
- FLAIR: Hyperintensity in temporal lobes, insula, cingulate gyrus, subfrontal cortex, inferior frontal WM
- T2* GRE: No hemorrhage
  - If blood products seen, consider herpes encephalitis
- T1WI C+: Patchy enhancement common
- Brainstem encephalitis: T2 hyperintensity in midbrain, pons, cerebellar peduncles, basal ganglia
- Paraneoplastic cerebellar degeneration (PCD): Cerebellar atrophy

Nuclear Medicine Findings

- FDG PET: Increased glucose metabolism in medial temporal lobes in LE patients

Imaging Recommendations

- Protocol advice
  - Contrast-enhanced MR with coronal T2 or FLAIR
  - Consider repeat MR if initial scan normal with high clinical suspicion

DIFFERENTIAL DIAGNOSIS

Herpes Encephalitis

- T2 hyperintensity in temporal lobes, limbic system
- Mass effect common; restricted DWI common
- Rapid onset, febrile illness
- HSV titers (CSF, serum) may be negative early
- Late acute/subacute may hemorrhage
- May be indistinguishable from limbic encephalitis

Low-Grade (Grade II) Diffuse Astrocytoma

- Unilateral T2 hyperintense mass
- May involve medial temporal lobe
- No enhancement typical

Status Epilepticus

- Seizures may cause abnormal T2/FLAIR of mesial temporal lobes
- Cortical enhancement with DWI is typical
- Clinical history of seizures

Gliomatosis Cerebri

- Diffuse process, no predilection for limbic system
- T2 hyperintensity in multiple contiguous lobes
- Enlarges affected area

Parenchymal Metastases

- Typically multifocal enhancing lesions
- Primary tumor often known

PATHOLOGY

General Features

- Etiology
  - Immune-mediated by **autoantibodies** or cytotoxic T cell-related mechanisms
  - 60% of patients have circulating serum **autoantibodies**
    - **Anti-Hu** (lung cancer): Limbic encephalitis
    - **Anti-Ta** (testicular germ cell tumors): Limbic encephalitis, brainstem encephalitis
    - **Anti-Yo** (breast and ovarian): Paraneoplastic cerebellar degeneration
    - **Anti-Tr** (Hodgkin disease): Paraneoplastic cerebellar degeneration
    - **Anti-Ri** (lung, breast, ovarian): Opsoclonus myoclonus
  - Reversible extralimbic paraneoplastic encephalopathy
    - Associated with breast cancer and lung cancer
    - Reversible when primary tumors controlled
  - New **cell surface antigens** reported: Voltage-gated potassium channels (**VGKC**) and N-methyl-D-aspartate receptor (**NMDAR**)
    - Associated with other tumors (thymoma, teratoma, Hodgkin lymphoma)
    - Appear to be antibody-mediated and respond better to immunotherapy (90%)
    - Patients may present with limbic encephalitis; more frequently manifest severe psychiatric symptoms, seizures, dyskinesias, autonomic instability, or hypoventilation
  - New antibody to α-amino-3-hydroxy-5-methyl-4-isoxazolepropionic acid receptor (**AMPAR**)
    - Associated with limbic encephalitis

https://CafePezeshki.IR

- – May occur with other antibodies

Staging, Grading, & Classification

- PSs divided into disorders of CNS, peripheral NS, CNS/PNS, neuromuscular junction
  - CNS: Paraneoplastic cerebellar degeneration (PCD), opsoclonus myoclonus, retinopathy
  - Peripheral NS: Sensory-motor neuropathy, autonomic neuropathy
  - Both CNS/PNS: Encephalomyelitis (limbic encephalitis, brainstem encephalitis, myelitis, motor neuron disease)
  - Neuromuscular junction: Lambert-Eaton myasthenic syndrome
- Limbic encephalitis most common PS
  - Nonparaneoplastic limbic encephalitis reported
- PCD is 2nd most common PS
- Multiple PSs may occur in same patient

Gross Pathologic & Surgical Features

- LE: Ill-defined softening, discoloration of gray matter (GM)
  - Hippocampus, cingulate gyrus, pyriform cortex, frontal orbital surface of temporal lobe, insula, amygdala; typically bilateral
- PCD: Cerebellar atrophy, gyral thinning
- Brainstem encephalitis: Brainstem softening

Microscopic Features

- Limbic encephalitis
  - Neuronal loss, reactive gliosis, perivascular infiltration of lymphocytes, microglial nodules
  - No neoplasm and no viral inclusions
- PCD: Purkinje cell loss, microglial proliferation, Bergmann glia hyperplasia, decrease in granule cells
- Brainstem encephalitis: Perivascular inflammatory infiltrates, glial nodules, neuronophagia

CLINICAL ISSUES

Presentation

- Most common signs/symptoms
  - LE: Memory loss, cognitive dysfunction, dementia, psychological features (anxiety, depression, hallucinations), seizures; subacute presentation
  - PCD: Ataxia, incoordination, dysarthria, nystagmus
    - In patients > 50 years, cerebellar degeneration is paraneoplastic in 50% of cases, often precedes remote malignancy
  - Brainstem encephalitis: Brainstem dysfunction including cranial nerve palsies, visual changes
  - In patients with known primary tumor, must exclude other complications
    - Metastases, infection, metabolic disorder, chemotherapy effects
- Clinical profile
  - Up to 60% have no known primary tumor at presentation, many have no tumor found at work-up
  - Identification of antineuronal antibodies in serum or CSF facilitates diagnosis of PS and primary cancer
  - Primary neoplasms
    - Limbic encephalitis
      - Most common: Small cell lung carcinoma
      - Other = GI, GU (ovary > renal > uterus), lymphoma, breast, testicular, thymus, neuroblastoma (pediatric)
      - 90% have positive CSF (pleocytosis, ↑ protein, oligoclonal bands)
      - EEG reveals involvement of temporal lobes
    - Paraneoplastic cerebellar degeneration
      - GU (ovary), breast, lung, lymphoma
    - Opsoclonus myoclonus
      - Neuroblastoma, lung cancer
    - Lambert-Eaton myasthenic syndrome
      - Small cell lung cancer

Demographics

- Age: Occurs at all ages, most commonly adults
- Epidemiology: < 1% of patients with systemic cancers develop paraneoplastic syndrome

Natural History & Prognosis

- Relates to primary neoplasm
- Some reports suggest patients with PSs have more indolent primary tumor growth than those without
- Relates to type of paraneoplastic syndrome
  - Slow long-term cognitive decline (LE)
  - Progressive ataxia, weakness (PCD, spinal cord degeneration)

Treatment

- Treatment of primary malignancy may improve neurologic symptoms of PSs (25-45%)
- Primary neoplasm resected, ± chemoradiation
- Treatment of paraneoplastic syndromes is variable
  - Treatment of primary tumor is best therapy
  - ± steroids, immunoglobulins, plasmapheresis

DIAGNOSTIC CHECKLIST

Consider

- LE is only PS with defined imaging features
- Paraneoplastic syndromes are often clinically evident before diagnosis of primary tumor
- Repeat MR if initial scan normal and high clinical suspicion, as initial MR often normal in LE

Image Interpretation Pearls

- Herpes encephalitis mimics LE on imaging but has acute presentation
  - Patients often initially treated with antiviral therapy until HSV titers final
- Hemorrhage suggests herpes rather than LE

SELECTED REFERENCES

1. Höftberger R et al: Encephalitis and AMPA receptor antibodies: Novel findings in a case series of 22 patients. Neurology. 84(24):2403-12, 2015
2. Thomas AC et al: Autoimmune limbic encephalitis detected on FDG brain scan performed for the evaluation of dementia. Clin Nucl Med. 40(4):358-9, 2015
3. Kotsenas AL et al: MRI findings in autoimmune voltage-gated potassium channel complex encephalitis with seizures: one potential etiology for mesial temporal sclerosis. AJNR Am J Neuroradiol. 35(1):84-9, 2014
4. Baumgartner A et al: Cerebral FDG-PET and MRI findings in autoimmune limbic encephalitis: correlation with autoantibody types. J Neurol. 260(11):2744-53, 2013
5. Scaravilli F et al: The neuropathology of paraneoplastic syndromes. Brain Pathol. 9(2):251-60, 1999

https://CafePezeshki.IR

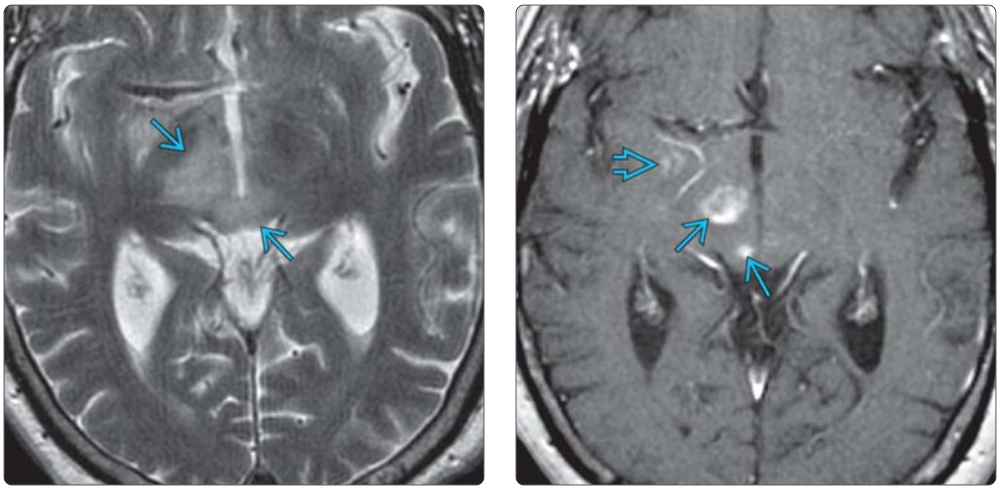

(Left) *Axial T2WI MR shows midbrain hyperintensity related to brainstem encephalitis, which is characterized by hyperintensity in the midbrain, pons, cerebellar peduncle, and basal ganglia.* **(Right)** *Axial T1WI C+ MR in the same patient shows patchy enhancement of the midbrain lesions and of the medial temporal lobe. This patient was diagnosed with limbic encephalitis with new brainstem symptoms. Multiple paraneoplastic syndromes may occur in the same patient.*

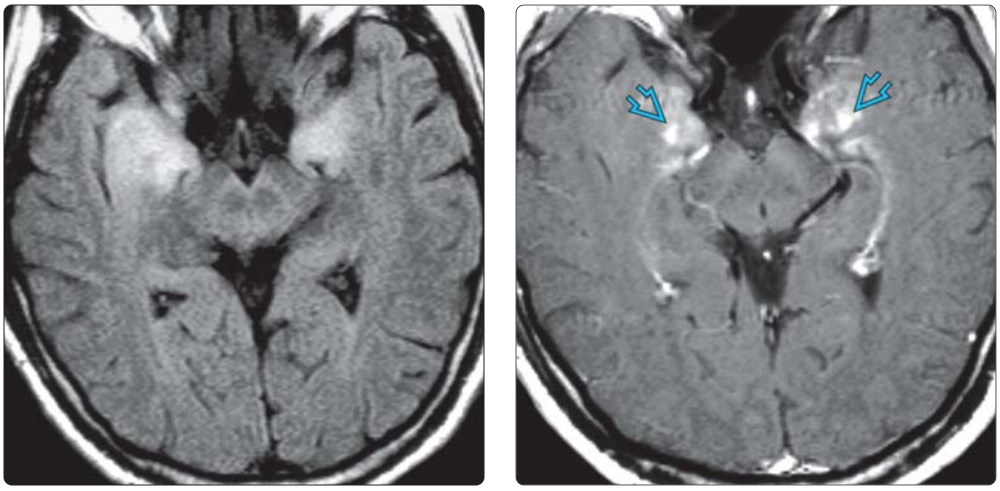

(Left) *Axial FLAIR MR shows abnormal hyperintensity in the medial temporal lobes bilaterally, related to limbic encephalitis. As imaging mimics herpes encephalitis, most patients are initially treated with antiviral therapy until HSV titers are found to be negative. Less than 1% of cancer patients develop a paraneoplastic syndrome.* **(Right)** *Axial T1WI C+ MR in the same patient shows patchy enhancement of the medial temporal lobes. Limbic encephalitis is the only paraneoplastic syndrome with defined imaging features.*

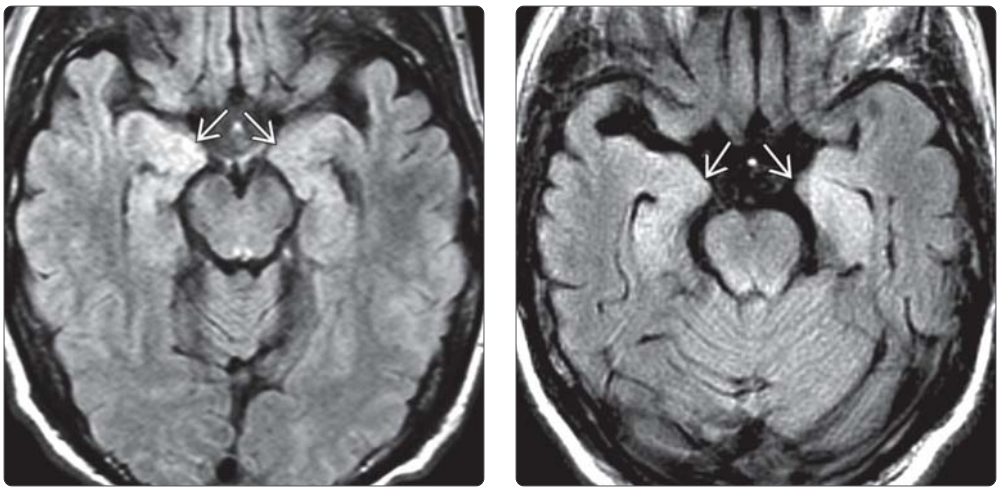

(Left) *Axial FLAIR MR shows subtle asymmetric hyperintensity of the hippocampi in this young patient with melanoma and subacute dementia.* **(Right)** *Axial FLAIR MR shows hyperintensity in both medial temporal lobes in this patient with subacute dementia and voltage-gated potassium channel (VGKC) autoimmunity. VGKC may occur without a primary neoplasm or may present as a paraneoplastic syndrome and mimic limbic encephalitis. VGKC responds well to immunotherapy.*

https://CafePezeshki.IR

This page intentionally left blank

https://CafePezeshki.IR

PART I
SECTION 7

Primary Nonneoplastic Cysts

Primary Nonneoplastic Cysts Overview	604
Arachnoid Cyst	608
Colloid Cyst	612
Dermoid Cyst	616
Epidermoid Cyst	620
Neuroglial Cyst	624
Periventricular Cyst	626
Choroid Fissure Cyst	630
Hippocampal Sulcus Remnant Cysts	631
Enlarged Perivascular Spaces	632
Pineal Cyst	636
Choroid Plexus Cyst	640
Ependymal Cyst	644
Porencephalic Cyst	646
Neurenteric Cyst	650
Nonneoplastic Tumor-Associated Cysts	652

https://CafePezeshki.IR

General Approach to Brain Cysts

General Considerations

Overview: Cysts are common findings on MR and CT brain scans. There are many types of intracranial cysts, some significant, some incidental. In this section, we exclude cystic neoplasms (such as pilocytic astrocytoma and hemangioblastoma), solid neoplasms that commonly have intratumoral cysts (such as ependymoma), and tumors that often display central necrosis (e.g., glioblastoma).

We also exclude parasitic cysts (neurocysticercosis, hydatid disease) and cystic brain malformations (Dandy-Walker spectrum) from the discussion. Thus, the focus of this particular section is primary nonneoplastic cysts.

Because the etiology, pathology, and clinical importance of nonneoplastic cysts is so varied, classifying them presents a real challenge. Some neuropathologists typically classify cysts according to the histology of the cyst wall. Others group them according to putative origin or pathogenesis.

In a schema based on pathogenesis, cysts may occur as normal anatomic variants (e.g., enlarged perivascular [Virchow-Robin] spaces), congenital inclusion cysts (e.g., dermoid and epidermoid cysts), or lesions derived from embryonic ecto-/endoderm (colloid and neurenteric cysts). Of course, there is a group of miscellaneous cysts (such as choroid plexus cysts and nonneoplastic tumor-associated cysts [TACs]) that does not fit nicely into any category.

Neuroimagers face a very real dilemma: A cystic-appearing lesion is identified on MR or CT. What is it? What else could it be? Histopathology of the cyst wall isn't a practical consideration. What **is** readily apparent is (1) the anatomic location of the cyst; (2) its imaging characteristics (density/signal intensity, presence or absence of calcification, enhancement, etc.); and (3) the patient's age. The recommended initial approach to analyzing brain cysts is anatomy-based.

Anatomy-Based Approach to Brain Cysts

General Considerations

Key features: Four features help the diagnostic approach to cystic-appearing intracranial lesions. The 1st step is to determine if the cyst is intra- or extraaxial. If it is extraaxial, is the cyst supra- or infratentorial? Is it midline or off midline? If a cyst is intraaxial, is it supra- or infratentorial? Is it parenchymal or intraventricular? While many intracranial cysts certainly may occur in more than 1 location, some sites are "preferred" by certain cysts.

Extraaxial Cysts

Supratentorial extraaxial cysts: Nonneoplastic, noninfectious extraaxial cysts can occur in the midline or off midline. Pineal and Rathke cleft cysts occur only in the midline. While dermoid cysts seem to prefer a midline location like the suprasellar cistern, they also occur off midline. Look for rupture with fatty "droplets" in the subarachnoid cisterns.

Arachnoid cysts (AC) are usually off midline. In the supratentorial compartment, midline ACs are relatively rare. The most frequent midline locations are the suprasellar cistern, followed by the quadrigeminal cistern and velum interpositum. Large suprasellar ACs usually present in children and may cause obstructive hydrocephalus.

The most common off midline extraaxial supratentorial cyst is an arachnoid cyst. While these can occur virtually anywhere, the middle cranial fossa is the location of at least 50% of all ACs. Occasionally ACs occur over the cerebral convexities, most commonly over the parietal lobe. ACs follow CSF on all sequences and are differentiated from epidermoid cysts using FLAIR and DWI. ACs suppress completely on FLAIR and do not show diffusion restriction.

Extraaxial tumors, such as meningioma, schwannoma, pituitary macroadenoma, and craniopharyngioma, may be associated with prominent extratumoral cysts. These nonneoplastic TACs occur in both the supra- and infratentorial compartments.

TACs are benign collections of fluid that vary from clear and CSF-like to proteinaceous. TACs are typically positioned between at the tumor-brain interface, between the mass and adjacent cortex. Whether TACs are true arachnoid cysts, obstructed PVSs, or fluid collections mostly lined by gliotic brain is debatable.

Scalp and skull cysts are less common than intracranial cysts. Sebaceous cysts (more accurately termed trichilemmal cysts [TCs]) are a common scalp mass in middle-aged and older patients. Most are identified incidentally on MR and CT scans. TCs can be solitary or multiple, are well-delineated, and vary in size from a few millimeters to several centimeters. The classic finding is a subepidermal scalp tumor in a female over the age of 60 years.

Leptomeningeal cysts, also known as "growing fractures," are a rare but important extraaxial cyst that is most commonly found in the parietal bone. An enlarging calvarial fracture adjacent to post-traumatic encephalomalacia is typical. The vast majority of patients are under 3 years of age. They present with an enlarging, palpable soft tissue mass. Fluid and encephalomalacic brain extrude through torn dura and arachnoid and then through the enlarging linear calvarial fracture. Leptomeningeal cysts are seen as linear lucent skull lesions with rounded, scalloped margins.

Infratentorial extraaxial cysts: Most nonneoplastic cysts in the posterior fossa occur off midline. The 2 major cyst types found in this location are epidermoid and arachnoid cysts.

The cerebellopontine angle (CPA) is by far the most common posterior fossa sublocation of an epidermoid cyst (EC). Occasionally, an EC occurs in the 4th ventricle. A 4th ventricular EC can mimic a trapped, dilated 4th ventricle, but ECs do not suppress on FLAIR and usually exhibit some degree of restricted diffusion.

The next most common posterior fossa cyst is AC. While ACs can also occur in the midline cisterna magna, the cerebellopontine angle is the most common site. TACs sometimes occur in the CPA cistern. Most are associated with vestibular schwannoma, but a CPA meningioma may also cause formation of a TAC.

Neurenteric cysts (NE) are congenital endodermal cysts that are much more commonly found in the spinal canal. Intracranial NE cysts occur in the cerebromedullary cistern and are usually midline or slightly off midline, lying just anterior to the pontomedullary junction. Sometimes NE cysts occur off midline, in the lower CPA (cerebromedullary) cistern. Bony skull defects can occur but are rare.

An anatomic variant that can be confused with a posterior fossa NE cyst is retroclival ecchordosis physaliphora (EP), found in about 2% of autopsies. EP is a gelatinous notochordal remnant that can occur anywhere from the dorsum sellae to

https://CafePezeshki.IR

the sacrococcygeal region. Intracranial EPs typically occur in the prepontine cistern and are attached to a defect in the dorsal clivus by a thin, stalk-like pedicle. NE cysts and EPs are both hyperintense on T2WI. Chordomas are the malignant counterparts of ecchordosis.

Intraaxial Cysts

Supratentorial intraaxial cysts: Here, anatomic sublocation is key to the differential diagnosis. Parenchymal cysts represent a completely different group than intraventricular cysts. The most common parenchymal cysts in the brain are enlarged perivascular (Virchow-Robin) spaces (PVSs). PVSs have a distinct predilection for the basal ganglia, where they tend to cluster around the anterior commissure. The midbrain is another common site. When they occur here, enlarged PVSs may cause obstructive hydrocephalus. Prominent PVSs also occur in the subcortical and deep white matter. They are pial-lined, interstitial fluid-containing structures that tend to occur in clusters of variably sized cysts. Most PVSs suppress completely; 75% are surrounded by normal-appearing brain, which helps distinguish them from porencephalic cysts.

Hippocampal sulcus remnant cysts are common normal variants, seen as a "string" of small CSF-like cysts lying in the hippocampus just medial to the temporal horn of the lateral ventricle. They are caused by defective or incomplete fusion of the embryonic cornu ammonis and dentate gyrus and are of no clinical significance.

Porencephalic cysts are the 3rd most common supratentorial parenchymal cysts. They may communicate with the ventricles and are typically lined by gliotic white matter, not ependyma, and are caused by brain destruction (e.g., peri- or antenatal insult). The brain surrounding a porencephalic cyst is typically hyperintense on T2WI and FLAIR.

Periventricular cysts of newborns encompasses a wide, overlapping variety of periventricular cystic lesions that ranges from cystic periventricular leukomalacia to connatal and germinolytic cysts.

Neuroglial cysts, sometimes called neuroepithelial cysts, are benign glial-lined cavities buried within the cerebral white matter. While they can occur anywhere, the frontal lobe is the most common site. They tend to be solitary, whereas PVSs are usually collections of multiple cysts of different sizes. A choroid fissure cyst is a neuroglial cyst that occurs anywhere along the infolded choroid fissure. Most are found medial to the temporal horn of the lateral ventricle. Hippocampal sulcus remnant cysts (HSRCs) occur when there is incomplete fusion of the cornu ammonis and the dentate gyrus. HSRCs are often multiple, appearing like a string of small CSF-containing cysts along the lateral margin of the hippocampus.

Supratentorial intraventricular cysts are most often found in the atria of the lateral ventricles and foramen of Monro. Choroid plexus cysts (CPCs) are the most common of all intracranial neuroepithelial cysts, occurring in up to 50% of autopsies. Most CPCs are actually xanthogranulomas. Lipid accumulates in the choroid plexus from degenerating &/or desquamating choroid epithelium. CPCs are common incidental imaging findings in middle-aged and older adults. They are usually bilateral and are often multicystic. Most CPCs are small, measuring 2-8 mm in diameter. They typically do not suppress completely on FLAIR and may show moderately high signal intensity on DWI.

Ependymal cysts (EC) are rare, benign, ependymal-lined cysts of the lateral ventricles. Most ECs, even large ones, are asymptomatic and incidental. EC patients presenting with headache, seizure, &/or obstructive hydrocephalus have been reported in the literature. They contain clear serous CSF-like fluid secreted from ependymal cells. ECs typically follow CSF on all sequences and suppress completely on FLAIR.

Colloid cysts (CCs) occur almost exclusively in the foramen of Monro, attached to the anterosuperior portion of the 3rd ventricular roof. They are wedged into the foramen and are typically straddled by the fornices. CCs are endodermal in origin and contain viscous gelatinous material consisting of mostly mucin. CCs may also contain blood degradation products, foamy cells, and cholesterol crystals. Even relatively small CCs may suddenly obstruct the foramen of Monro, causing acute hydrocephalus. Occasionally brain herniation with rapid clinical deterioration ensues. The imaging appearance of a well-delineated, hyperdense mass at the foramen of Monro on NECT is virtually pathognomonic of a CC.

Infratentorial intraaxial cysts: Parenchymal infratentorial cysts are rare; most are PVSs. The only common site is in and around the dentate nuclei. Most are asymptomatic. Occasionally, large PVSs occur in the pons and can be a rare cause of cranial neuropathy.

Nonneoplastic, nonparasitic cysts in the 4th ventricle are uncommon. The most common cause is not a true cyst but an enlarged, "encysted" 4th ventricle. Infection or aneurysmal subarachnoid hemorrhage may cause outlet foraminal obstruction. When combined with superior obstruction near the aqueduct, the 4th ventricle can become completely encysted. Choroid plexus continues to produce CSF. With egress blocked, the 4th ventricle enlarges. Epidermoid cysts can arise in the 4th ventricle, a much less common posterior fossa location than the CPA. Some ECs are so similar to CSF that only FLAIR and DWI permit distinction of an EC from CSF in an enlarged but otherwise normal-appearing 4th ventricle.

Selected References

1. Aboud E et al: Giant intracranial epidermoids: is total removal feasible? J Neurosurg. 1-14, 2015
2. Ali M et al: Exploring predictors of surgery and comparing operative treatment approaches for pediatric intracranial arachnoid cysts: a case series of 83 patients. J Neurosurg Pediatr. 1-8, 2015
3. Kalani MY et al: Pineal cyst resection in the absence of ventriculomegaly or Parinaud's syndrome: clinical outcomes and implications for patient selection. J Neurosurg. 1-5, 2015
4. Ahmad M et al: Giant perivascular spaces: utility of MR in differentiation from other cystic lesions of the brain. JBR-BTR. 97(6):364-5, 2014
5. Demir MK et al: Rare and challenging extra-axial brain lesions: CT and MRI findings with clinico-radiological differential diagnosis and pathological correlation. Diagn Interv Radiol. 20(5):448-52, 2014
6. Fanous AA et al: Analysis of the growth pattern of a dermoid cyst. J Neurosurg Pediatr. 14(6):621-5, 2014
7. Bender B et al: MR imaging findings in colloid cysts of the sellar region: comparison with colloid cysts of the third ventricle and Rathke's cleft cysts. Acad Radiol. 20(11):1457-65, 2013
8. Hingwala DR et al: Neuroenteric cysts of the brain-comprehensive magnetic resonance imaging. Indian J Radiol Imaging. 23(2):155-63, 2013
9. Osborn AG et al: Intracranial cysts: radiologic-pathologic correlation and imaging approach. Radiology. 239(3):650-64, 2006

https://CafePezeshki.IR

Intracranial Cystic-Appearing Lesions

Extraaxial	Intraaxial
Supratentorial	Supratentorial
Midline	Parenchymal
Pineal cyst	Enlarged perivascular spaces (PVSs)
Dermoid cyst	Neuroglial cyst
Rathke cleft cyst	Porencephalic cyst
Arachnoid cyst (suprasellar)	Connatal, germinolytic cysts
	Hippocampal sulcus remnants
Off midline	Intraventricular
Arachnoid cyst (middle cranial fossa, convexity)	Choroid plexus cysts
Epidermoid cyst	Ependymal cyst
TACs (macroadenoma, meningioma)	Colloid cyst
Sebaceous cyst (scalp)	
Leptomeningeal cyst ("growing fracture")	
Infratentorial	Infratentorial
Midline	Parenchymal
Neurenteric cyst	Enlarged PVSs (dentate nuclei)
Arachnoid cyst	
Off midline	Intraventricular
Epidermoid (CPA)	Epidermoid (4th ventricle, cisterna magna)
Arachnoid cyst (CPA)	Cystic ("trapped") 4th ventricle
TACs (schwannoma, meningioma)	

Nonneoplastic, noninfectious cystic brain lesions are classified by common anatomic locations. The 1st division is extra- vs. intraaxial, then supra- vs. infratentorial. Extraaxial cysts are further subdivided into midline and off midline lesions. Intraaxial cysts are subdivided into parenchymal and intraventricular. CPA = cerebellopontine angle; PVSs = perivascular (Virchow-Robin) spaces; TACs = tumor-associated cysts.

Intracranial Cysts by Type, Most Common Location(s)

Cyst Type	Common Location(s)
Arachnoid cyst	Middle cranial fossa; cerebellopontine angle (CPA); suprasellar cistern
Choroid fissure cyst	Choroid fissure, between temporal horn and suprasellar cistern
Choroid plexus cyst	Choroid plexus glomus
Colloid cyst	Interventricular foramen/anterosuperior 3rd ventricle
Connatal cyst(s)	Peri- or intraventricular, adjacent to frontal horn, body of lateral ventricle
Dermoid cyst	Suprasellar, frontonasal (anteroinferior interhemispheric fissure)
Enlarged perivascular spaces (PVSs)	Basal ganglia, midbrain, cerebral white matter, dentate nuclei
Epidermoid cyst	Cerebellopontine angle (CPA)
Ependymal cyst	Lateral ventricle (atrium most common)
Germinolytic pseudocyst(s)	Periventricular, subependymal along caudothalamic groove
Hippocampal sulcus remnants	Hippocampus, just medial to lateral ventricle
Leptomeningeal cyst ("growing fracture")	Parietal bone
Neurenteric cyst	Prepontine at pontomedullary junction
Neuroglial cyst	Frontal/temporal subcortical WM, choroid fissure
Pineal cyst	Pineal gland
Porencephalic cyst	Cerebral hemispheres, adjacent to lateral ventricles
Rathke cleft cyst	Suprasellar, intrasellar
Sebaceous (trichilemmal) cyst	Scalp (dermis or subcutaneous tissues)
Tumor-associated cyst	Between schwannoma, meningioma, macroadenoma, and brain

https://CafePezeshki.IR

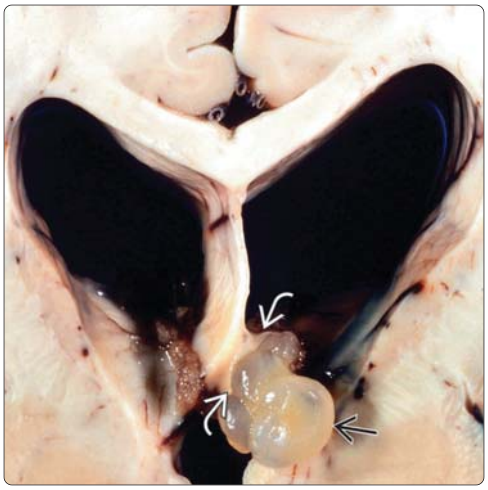

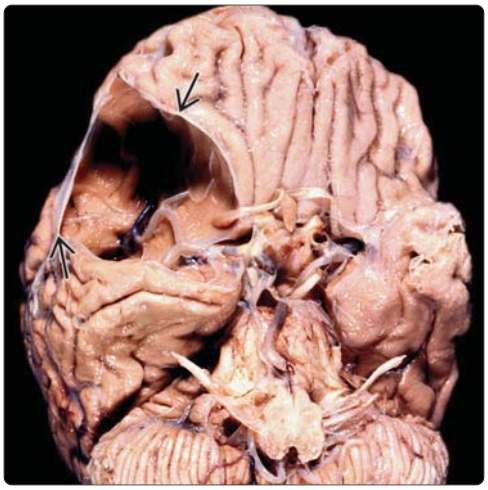

(Left) *Gross pathology shows an autopsied case of a colloid cyst, sectioned in the coronal plane through the foramen of Monro. Note the gelatinous-appearing lobulated cyst ⇨ with the fornices ➡ straddling the cyst. This patient died of sudden obstructive hydrocephalus. (Courtesy J. Townsend, MD.)* **(Right)** *Gross pathology of an autopsied brain, seen from below, shows a large arachnoid cyst of the middle cranial fossa. The cyst contained CSF within split layers of arachnoid ⇨. (Courtesy J. Townsend, MD.)*

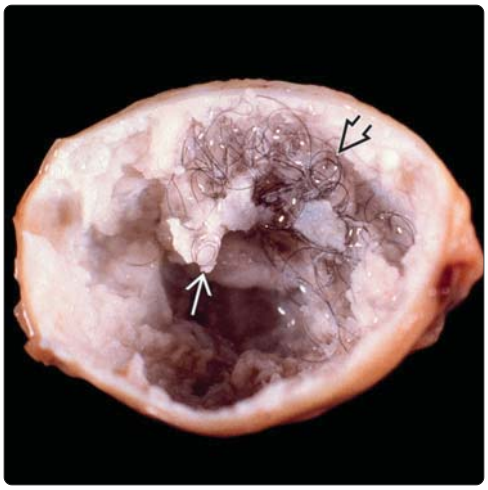

(Left) *Gross surgical specimen of a sectioned dermoid cyst shows the characteristic lining of stratified squamous epithelium plus intracystic keratin debris ➡. Matted, tangled hairs ⇨ are present within the cyst, which contained thick, greasy sebaceous material when sectioned. (Courtesy R. Hewlett, MD.)* **(Right)** *Microscopy of a typical dermoid cyst shows squamous epithelium ⇨ and sebaceous glands ⇨ lining a cavity that contains desquamated keratinaceous debris.*

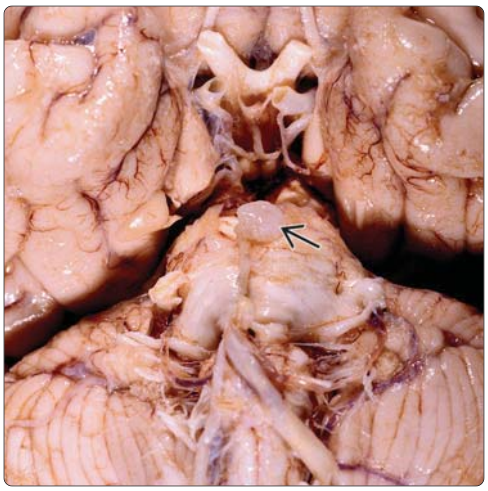

(Left) *Close-up view of an epidermoid cyst shows the cauliflower-like cyst surface that is composed of nodular masses of squamous epithelium and pearly white keratin.* **(Right)** *Autopsy specimen shows a small, gelatinous-appearing nodule ⇨ just anterior to the pons. Ecchordosis physaliphora, a notochordal remnant, grossly appears similar to neurenteric cyst. (Courtesy R. Hewlett, MD.)*

https://CafePezeshki.IR

KEY FACTS

TERMINOLOGY

- Intraarachnoid CSF-filled sac that does not communicate with ventricular system

IMAGING

- General findings
  - Sharply demarcated round/ovoid extraaxial cyst
  - Isodense/isointense with CSF
- Location
  - Middle cranial fossa (50-60%)
  - Cerebellopontine angle (10%)
  - Suprasellar (10%)
  - Miscellaneous (10%) (convexity, quadrigeminal)
- MR
  - Isointense with CSF on all sequences
  - Suppresses completely with FLAIR
  - No restriction on DWI
  - CISS, FIESTA: Use to delineate cyst wall, adjacent structures
  - 2D cine PC: Use to detect communication between AC, adjacent subarachnoid space

TOP DIFFERENTIAL DIAGNOSES

- Epidermoid cyst
- Other nonneoplastic cysts (e.g., porencephalic)
- Chronic subdural hematoma
- Subdural Hygroma

CLINICAL ISSUES

- Most common congenital intracranial cystic abnormality
- 1% of all intracranial masses
- Can be found at any age (75% in children)
- Usually an incidental finding

DIAGNOSTIC CHECKLIST

- FLAIR, DWI best for AC vs. epidermoid

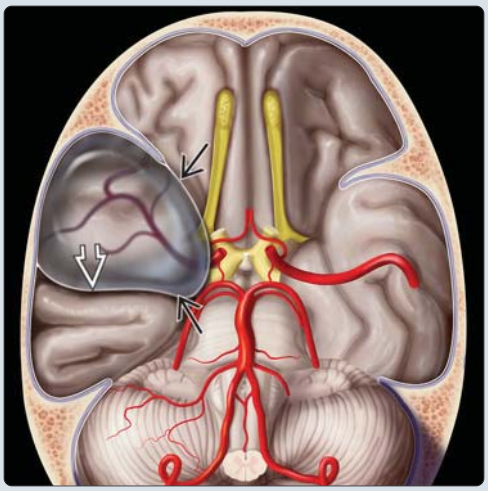

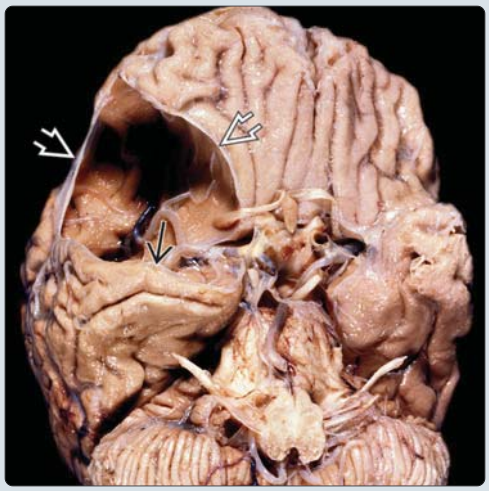

(Left) *Graphic depicts the middle cranial fossa AC. Note the arachnoid ⇨ splits and encloses CSF. The middle fossa is expanded, and the overlying bone is thinned. Note that the temporal lobe ⇨ is displaced posteriorly.* **(Right)** *Submentovertex view shows autopsied brain with incidental finding of middle cranial fossa AC. Note "splitting" of arachnoid ⇨ containing a large CSF collection (drained during removal). The temporal lobe is displaced posteriorly ⇨, and the middle fossa is expanded. (Courtesy J. Townsend, MD.)*

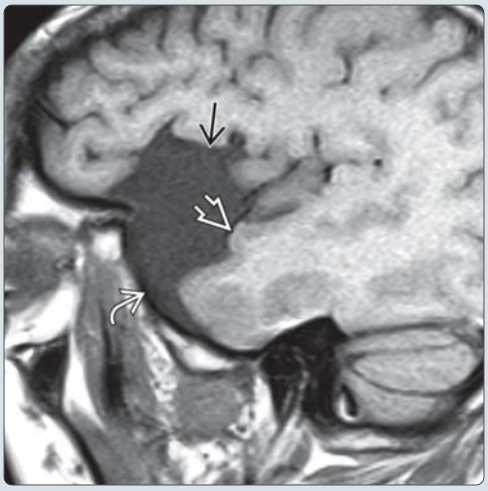

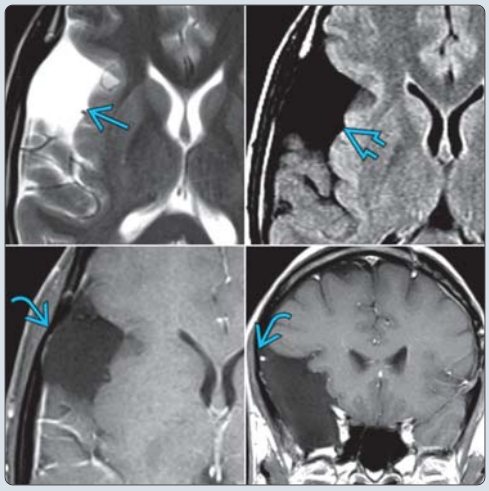

(Left) *Sagittal T1WI MR shows a classic middle fossa arachnoid cyst ⇨. Note the expansion of the greater sphenoid wing ⇨ and posteriorly displaced temporal lobe ⇨.* **(Right)** *Composite of axial T2, FLAIR, post-contrast T1WI, and coronal T1C+ images show the scalloped margins characteristic of ACs. ACs are CSF-like on T2WI ⇨, suppress completely on FLAIR ⇨, remodel the adjacent calvaria ⇨, and do not enhance.*

https://CafePezeshki.IR

TERMINOLOGY

Abbreviations

- Arachnoid cyst (AC)

Synonyms

- Meningeal cyst

Definitions

- Intraarachnoid CSF-containing sac that does not communicate with ventricular system

IMAGING

General Features

- Best diagnostic clue
  - Sharply demarcated round/ovoid extraaxial cyst that follows CSF attenuation/signal
- Location
  - Middle cranial fossa (MCF) (50-60%)
  - Cerebellopontine angle (CPA) (10%)
  - Suprasellar arachnoid cyst (SSAC), variable types (10%)
    - Noncommunicating = cyst of membrane of Liliequist
    - Communicating = cystic dilation of interpeduncular cistern
  - 10% miscellaneous
    - Cerebral convexity
    - Quadrigeminal plate
    - Retrocerebellar
- Size
  - Varies from few mm to 5 cm or more
- Morphology
  - Sharply delineated translucent cyst
  - Displays features of extraaxial mass
    - Displaces cortex
    - "Buckles" gray-white interface

CT Findings

- NECT
  - Usually CSF density
    - Hyperdense if intracyst hemorrhage present (rare)
  - May expand, thin/remodel bone
- CECT
  - Does not enhance
- CTA
  - Posterior displacement of middle cerebral artery (MCA) in MCF ACs
- Cisternography may demonstrate communication with subarachnoid space

MR Findings

- T1WI
  - Sharply marginated extraaxial fluid collection isointense with CSF
- T2WI
  - Isointense with CSF
- PD/intermediate
  - Isointense with CSF
- FLAIR
  - Suppresses completely
- T2* GRE
  - No "blooming" unless hemorrhage present (rare)
- DWI
  - No restriction; nearly identical to ventricles
- T1WI C+
  - Does not enhance
- MRA
  - Cortical vessels displaced away from calvaria
- MRV
  - Can demonstrate anomalies of venous drainage
- MRS
  - Can predict pathology in > 90% of similar-appearing intracranial cystic lesions

Ultrasonographic Findings

- Grayscale ultrasound
  - Useful for demonstrating sonolucent ACs in infants < 1 year

Angiographic Findings

- MCA, sylvian triangle displaced posteriorly in MCF ACs

Nuclear Medicine Findings

- SPECT
  - May show hypoperfusion in brain adjacent to cyst

Imaging Recommendations

- Best imaging tool
  - MR with FLAIR, DWI
- Protocol advice
  - Consider adding
    - Magnetic resonance cisternography
      - CISS, FIESTA (high-resolution sequences to delineate cyst wall, adjacent anatomic structures); particularly in suprasellar cyst
      - Can help distinguish AC from enlarged subarachnoid space
    - MR CSF flow imaging, quantification
      - 2D cine PC (to look for communication between AC, adjacent subarachnoid space)

DIFFERENTIAL DIAGNOSIS

Epidermoid Cyst

- Scalloped margins
- Insinuating growth pattern
  - Creeps along into CSF cisterns
  - Surrounds, engulfs vessels/nerves
    - ACs displace, but usually do not engulf vessels, cranial nerves
- Does not suppress on FLAIR
- Restricted diffusion (bright) on DWI

Chronic Subdural Hematoma

- Signal not identical to CSF
- Often bilateral, lentiform-shaped
- ± enhancing membrane
- Look for foci of "blooming" on T2*
  - < 5% of ACs hemorrhage

Subdural Hygroma

- Often bilateral
- Crescentic or flat configuration

https://CafePezeshki.IR

Other Nonneoplastic Cysts

- Porencephalic cyst
  - Surrounded by gliotic brain, not compressed cortex
  - History of trauma, stroke common
- Neurenteric cyst
  - Rare; spine, posterior fossa = most common locations
  - Often proteinaceous fluid
- Neuroglial (glioependymal) cyst
  - Rare
  - Usually intraaxial

PATHOLOGY

General Features

- Etiology
  - Old concept = "splitting" or diverticulum of developing arachnoid
  - New concept (middle fossa ACs)
    - Frontal, temporal embryonic meninges (endomeninx) fail to merge as Sylvian fissure forms
    - Remain separate, forming "duplicated" arachnoid
  - Possible mechanisms
    - Active fluid secretion by cyst wall
    - Slow distention by CSF pulsations
    - CSF accumulates by 1-way (ball-valve) flow
  - Rare: ACs may form as shunt complication
- Genetics
  - Usually sporadic, nonsyndromic, rarely familial
  - Inherited disorders of metabolism
    - "Sticky" leptomeninges: Mucopolysaccharidoses
- Associated abnormalities
  - Temporal lobe may appear (or be) hypoplastic (MCF ACs)
  - Subdural hematoma
    - 5% in middle fossa ACs
  - Syndromic ACs
    - Acrocallosal (cysts in 1/3), Aicardi, Pallister-Hall syndromes
  - Periventricular giant ACs may cause hydrocephalus, may be associated with
    - Foramen of Monro stenosis
    - Aqueductal stenosis/occlusion

Staging, Grading, & Classification

- Galassi classification for middle fossa ACs: Increases with ↑ size/mass effect and ↓ communication with basal cisterns
  - Type 1: Small, spindle-shaped; limited to anterior MCF
  - Type 2: Superior extent along Sylvian fissure; temporal lobe displaced
  - Type 3: Huge, fills entire MCF; frontal/temporal/parietal displacement

Gross Pathologic & Surgical Features

- Fluid-containing cyst with translucent membrane
- Arachnoid layers bulge around, contain CSF collection

Microscopic Features

- Wall has variable histology; may explain why some grow
  - 50% have arachnoid-like tissue
  - 17% have thicker wall with mostly fibrous connective tissue
  - 33% have ciliated cells
- No inflammation, neoplastic change

CLINICAL ISSUES

Presentation

- Most common signs/symptoms
  - Often asymptomatic, found incidentally
  - Symptoms vary with size and location of cyst
    - Headache, dizziness, sensorineural hearing loss, hemifacial spasm/tic
    - SSACs may cause obstructive hydrocephalus
- Other signs/symptoms
  - Rarely, ruptured MCF ACs cause increased intracranial pressure requiring shunting

Demographics

- Age
  - ACs can be found at any age
  - 75% in children (symptom onset, if any, may be delayed)
- Gender
  - M:F = 3-5:1; especially middle cranial fossa
- Ethnicity
  - None reported
- Epidemiology
  - Most common congenital intracranial cystic abnormality
  - 1% of all intracranial masses
  - 2% incidental finding on imaging for seizure

Natural History & Prognosis

- May (but usually do not) slowly enlarge
- Occasionally decompress spontaneously

Treatment

- Usually none
  - Majority of ACs are found incidentally
- Resection (may be endoscopic)
- Fenestration/marsupialization
- Shunt (cystoperitoneal is common option)

DIAGNOSTIC CHECKLIST

Image Interpretation Pearls

- FLAIR, DWI best sequences for distinguishing etiology of cystic-appearing intracranial masses

SELECTED REFERENCES

1. De Keersmaecker B et al: Outcome of 12 antenatally diagnosed fetal arachnoid cysts: Case series and review of the literature. Eur J Paediatr Neurol. 19(2):114-121, 2015
2. Adrien J et al: Petrous and sphenoid arachnoid cysts: Diagnosis and management. Head Neck. Epub ahead of print, 2014
3. Balak N: The Sylvian fissure, cistern and arachnoid membrane. Br J Neurosurg. 28(1):98-106, 2014
4. Liu Z et al: Arachnoid cysts with subdural hematoma or intracystic hemorrhage in children. Pediatr Emerg Care. 30(5):345-51, 2014
5. Rabiei K et al: Diverse arachnoid cyst morphology indicates different pathophysiological origins. Fluids Barriers CNS. 11(1):5, 2014
6. Adeeb N et al: The intracranial arachnoid mater : a comprehensive review of its history, anatomy, imaging, and pathology. Childs Nerv Syst. 29(1):17-33, 2013

https://CafePezeshki.IR

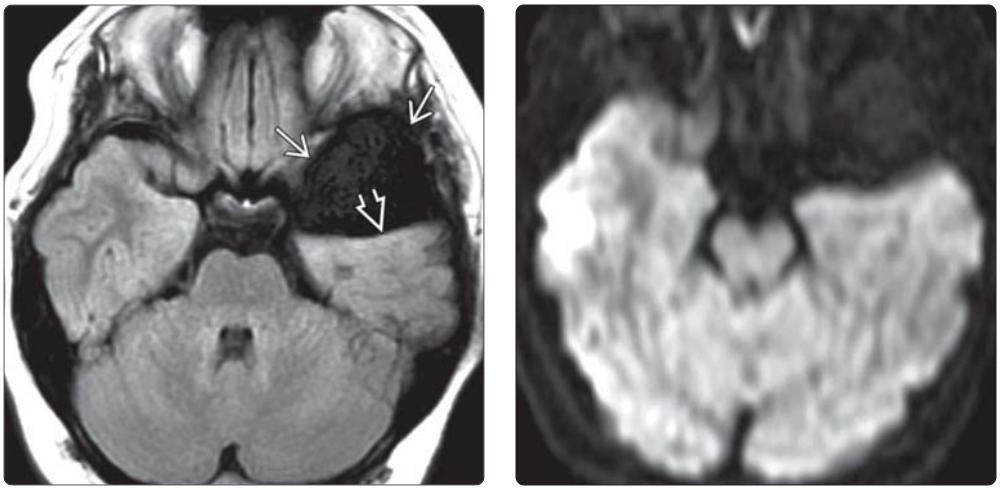

(Left) *Axial FLAIR MR in a 9 year old with seizures shows a large CSF-like mass* ➡ *that slightly expands the middle cranial fossa and displaces the temporal lobe posteriorly* ➡. **(Right)** *Axial DWI MR in the same patient shows that the cystic mass does not restrict. Typical ACs follow CSF on all sequences, suppress completely on FLAIR, and show no restriction on DWI.*

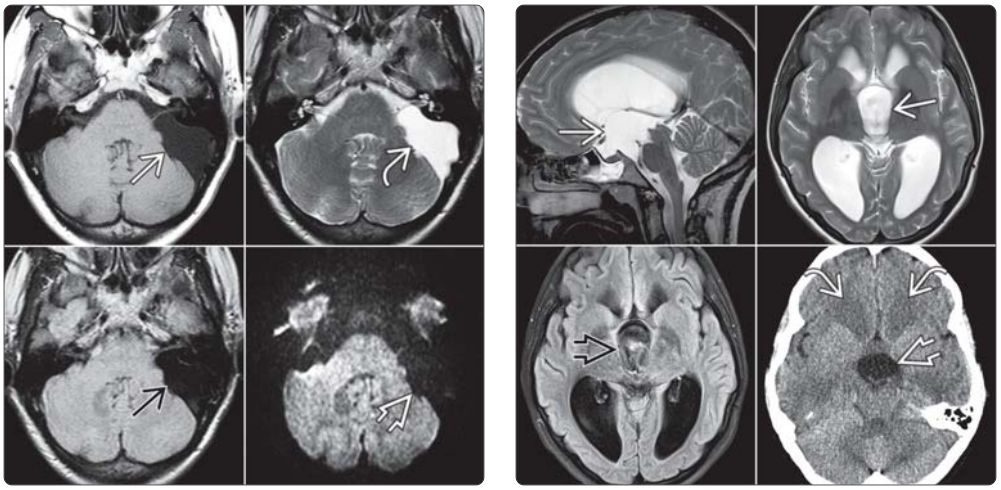

(Left) *Composite images of classic posterior fossa AC show isointensity with CSF on T1* ➡ *and T2WI* ➡. *The cyst suppresses completely on FLAIR* ➡ *and does not restrict on DWI* ➡. **(Right)** *Suprasellar AC is isointense with CSF on T2WIs* ➡. *CSF pulsations in the cyst do not suppress completely on FLAIR* ➡. *CT cisternogram shows dilute contrast in the enlarged lateral ventricles* ➡ *while the noncommunicating AC* ➡ *remains unopacified.*

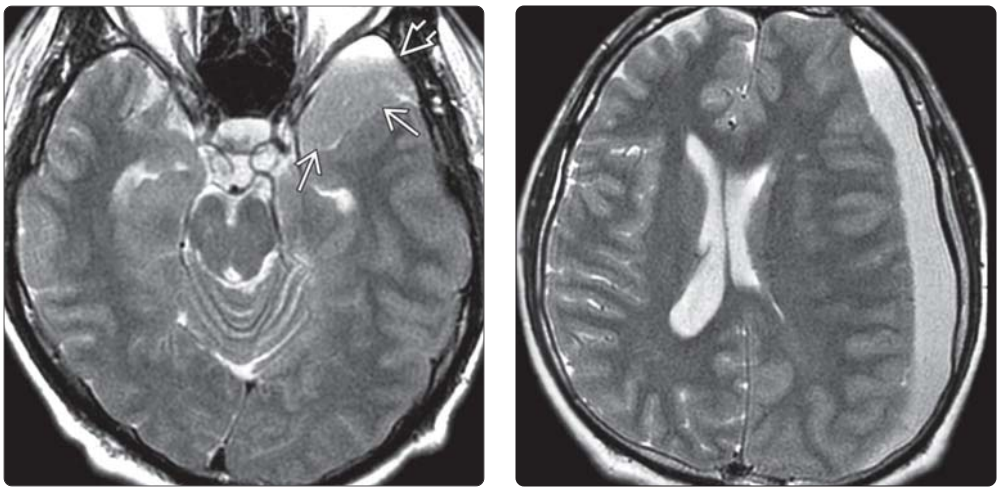

(Left) *A patient with head trauma had a middle fossa arachnoid cyst on initial imaging (not shown). Repeat MR obtained a few days later, after the patient became drowsy and developed progressive right-sided weakness, shows hemorrhage into the cyst* ➡. *Note fluid-fluid level* ➡ *between acute blood and the CSF in the AC.* **(Right)** *Axial T2WI cephalad MR in the same patient shows a subdural hematoma that had developed. Patients with ACs are at increased risk for developing SDHs. Intracyst hemorrhage is uncommon.*

https://CafePezeshki.IR

KEY FACTS

TERMINOLOGY

- Unilocular mucin-containing 3rd ventricular cyst

IMAGING

- > 99% are wedged into foramen of Monro
  - Pillars of fornix straddle, drape around cyst
  - Majority are hyperdense on NECT
  - Density correlates inversely with hydration state
- MR signal more variable
  - Generally reflects water content
  - Majority isointense to brain on T2WI (small cysts may be difficult to see)
  - 25% mixed hypo/hyper ("black hole" effect)
  - May show mild rim enhancement (rare)

TOP DIFFERENTIAL DIAGNOSES

- Neurocysticercosis
- CSF flow artifact (MR "pseudocyst")
- Vertebrobasilar dolichoectasia (VBD)/aneurysm
- Subependymoma
- Craniopharyngioma

PATHOLOGY

- From embryonic endoderm, not neuroectoderm
- Similar to other foregut-derived cysts (neurenteric, Rathke)

CLINICAL ISSUES

- 40-50% asymptomatic, discovered incidentally
- Headache (50-60%)
  - Acute foramen of Monro obstruction may lead to rapid onset hydrocephalus, herniation, death
- Peak age = 3rd to 4th decade (rare in children)
- 90% stable or stop enlarging
- 10% enlarge

DIAGNOSTIC CHECKLIST

- Beware of flow artifact in 3rd ventricle mimicking CC

(Left) *Axial graphic shows a classic CC at the foramen of Monro causing mild/moderate obstructive hydrocephalus. Note that the fornices and choroid plexus are elevated and stretched over the cyst* ⇨. **(Right)** *Axial gross pathology in a patient who suddenly and inexplicably died shows a large colloid cyst* ⇨ *causing moderate obstructive hydrocephalus. A small cavum septi pellucidi is present. Fornices* ⇨ *are draped over the cyst. (Courtesy R. Hewlett, MD.)*

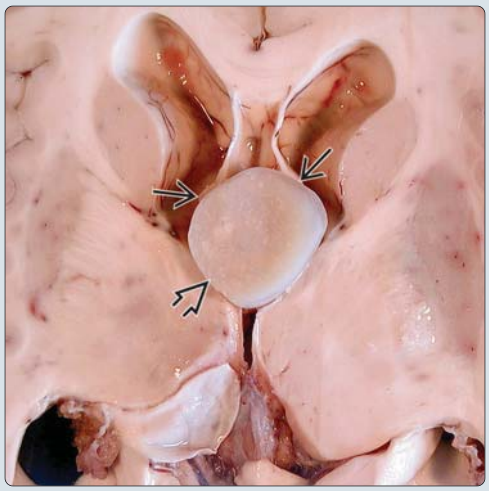

(Left) *Axial NECT in a 65-year-old man with "thunderclap" headache, obtained to look for a subarachnoid hemorrhage, shows a classic colloid cyst, seen here as a hyperdense mass* ➡ *wedged into the foramen of Monro and upper 3rd ventricle.* **(Right)** *Sagittal T2WI MR in the same patient shows the mass* ⇨ *to be very hypointense, indicating inspissated proteinaceous contents. Note the markedly enlarged lateral ventricle with a normal-sized 3rd ventricle. The colloid cyst was removed emergently.*

https://CafePezeshki.IR

TERMINOLOGY

Abbreviations

- Colloid cyst (CC)

Synonyms

- Paraphyseal cyst, endodermal cyst

Definitions

- Unilocular, mucin-containing 3rd ventricular cyst

IMAGING

General Features

- Best diagnostic clue
  - Hyperdense foramen of Monro mass on NECT
- Location
  - > 99% are wedged into foramen of Monro
    - Attached to anterosuperior 3rd ventricular roof
    - Pillars of fornix straddle, drape around cyst
    - Posterior part of frontal horns splayed laterally around cyst
  - < 1% found at other sites
    - Lateral, 4th ventricles
    - Extraventricular CCs (very rare)
      - Parenchyma (cerebellum)
      - Extraaxial (prepontine, meninges, olfactory groove)
- Size
  - Variable (few mm to 3 cm)
  - Mean: 15 mm
- Morphology
  - Well-demarcated round > ovoid/lobulated mass

CT Findings

- NECT
  - Density correlates inversely with hydration state
    - 2/3 hyperdense
    - 1/3 iso-/hypodense
  - ± hydrocephalus
  - Rare
    - Hypodense
    - Change in density/size
    - Hemorrhage (cyst "apoplexy"), Ca++ rare
- CECT
  - Usually does not enhance
  - Rim enhancement (rare)

MR Findings

- T1WI
  - Signal correlates with cholesterol concentration
    - 2/3 hyperintense on T1WI
    - 1/3 isointense
      - Small CCs may be difficult to see
  - May have associated ventriculomegaly
- T2WI
  - Signal more variable
    - Generally reflects water content
    - Majority isointense to brain on T2WI
      - Small CCs may be difficult to see
  - Less common findings
    - 25% mixed hypo/hyper ("black hole" effect)
    - Fluid-fluid level
- FLAIR
  - Does not suppress
- DWI
  - Does not restrict
- T1WI C+
  - Usually no enhancement
  - Rare: May show peripheral (rim) enhancement
- MRS
  - Normal brain metabolites absent

Imaging Recommendations

- Protocol advice
  - NECT + contrast-enhanced MR
  - ± serial imaging for asymptomatic cysts < 1 cm, no hydrocephalus

DIFFERENTIAL DIAGNOSIS

Neurocysticercosis

- Multiple lesions within parenchyma and cisterns
- Associated ependymitis or basilar meningitis common
- Ca++ common
- Look for scolex

CSF Flow Artifact (MR "Pseudocyst")

- Multiplanar technique confirms artifact
- Look for phase artifact

Vertebrobasilar Dolichoectasia (VBD)/Aneurysm

- Extreme VBD can cause hyperdense foramen of Monro mass
- Look for flow void, phase artifact on MR

Neoplasm

- Subependymoma
  - Frontal horn of lateral ventricle
  - Attached to septum pellucidum
  - Patchy/solid enhancement
- Craniopharyngioma
  - 3rd ventricle rare location
  - Usually not wedged into foramen of Monro, fornix
  - Ca++, rim/nodular enhancement common
- Pituitary adenoma
  - Rare in 3rd ventricle
  - Enhances (usually strongly, uniformly)

Choroid Plexus Mass

- Choroid plexus papilloma
  - Rare in 3rd ventricle
  - Tumor of early childhood
- Xanthogranuloma
  - Rare in 3rd ventricle
  - Ovoid > round
  - Can be hyper- or hypodense ± Ca++
  - Can obstruct foramen of Monro
  - Can be indistinguishable on imaging studies
- Choroid plexus cyst
  - Usually found in infants
  - Anechoic at ultrasound

https://CafePezeshki.IR

PATHOLOGY

General Features

- Etiology
  - From embryonic endoderm, not neuroectoderm
    - Similar to other foregut-derived cysts (neurenteric, Rathke)
    - Ectopic endodermal elements migrate into embryonic diencephalic roof
  - Contents accumulate from mucinous secretions, desquamated epithelial cells
- Genetics
  - None known
- Associated abnormalities
  - Variable hydrocephalus

Gross Pathologic & Surgical Features

- Smooth, spherical/ovoid well-delineated cyst
  - Thick gelatinous center, variable viscosity (mucinous or desiccated)
  - Rare = evidence for recent/remote hemorrhage
- Gross appearance, location virtually pathognomonic

Microscopic Features

- Outer wall = thin fibrous capsule
- Inner lining
  - Simple or pseudostratified epithelium
  - Interspersed goblet cells, scattered ciliated cells
  - Rests on thin connective tissue layer
- Cyst contents
  - PAS + gelatinous ("colloid") material
  - Variable viscosity
  - ± necrotic leukocytes, cholesterol clefts
- Immunohistochemistry
  - ± epithelial antigen reactivity (cytokeratins, EMA)
  - Neuroepithelial markers negative
- Electron microscopy
  - Resembles mature respiratory epithelium
  - Nonciliated or tall columnar cells
  - Basal cells contain dense core vesicles

CLINICAL ISSUES

Presentation

- Most common signs/symptoms
  - Headache (50-60%)
  - Less common = nausea, vomiting, memory loss, altered personality, gait disturbance, visual changes
  - Acute foramen of Monro obstruction may lead to rapid onset hydrocephalus, herniation, death
  - 40-50% asymptomatic, discovered incidentally
    - 3-, 5-, and 10-year incidence of developing cyst-related symptoms = 0, 0, and 8%, respectively
- Clinical profile
  - Adult with headache

Demographics

- Age
  - 3rd to 4th decade
    - Peak: 40
    - Rare in children (only 8% < 15 at diagnosis)
- Gender
  - M = F
- Epidemiology
  - 0.5-1.0% primary brain tumors
  - 15-20% intraventricular masses
  - Few familial cases reported

Natural History & Prognosis

- Varies with presence/rate of growth, development of CSF obstruction
- 90% stable or stop enlarging
  - Older age
  - Small cyst
  - No hydrocephalus
  - Hyperdense on NECT, hypointense on T2-weighted MR
- 10% enlarge
  - Younger patients
  - Larger cyst, hydrocephalus
  - Iso-/hypodense on NECT, often hyperintense on T2WI
  - May enlarge rapidly, cause coma/death
- Prognosis excellent when CCs diagnosed early and excised

Treatment

- Most common = complete surgical resection
  - Neuronavigation-guided endoscopic approach increasingly common
  - 50% experience short-term memory disturbance (usually resolves)
  - Recurrence rare if resection complete
- Options
  - Precoronal, paramedian minicraniotomy
  - Stereotactic aspiration (difficult with extremely viscous/solid cysts)
  - Imaging features that may predict difficulty with percutaneous therapy
    - Hyperdensity on CT/hypointensity on T2WI suggest high viscosity
  - Ventricular shunting
  - Observation (rare; not recommended as sudden obstruction can occur with even small CCs)

DIAGNOSTIC CHECKLIST

Consider

- Consider CT or MR in patient with longstanding history of intermittent headaches
- Notify referring MD immediately if CC identified (especially if hydrocephalus is present)

Image Interpretation Pearls

- Beware of flow artifact in 3rd ventricle mimicking CC

SELECTED REFERENCES

1. Margetis K et al: Endoscopic resection of incidental colloid cysts. J Neurosurg. 120(6):1259-67, 2014
2. Diyora B et al: Hemorrhagic colloid cyst: Case report and review of the literature. Asian J Neurosurg. 8(3):162, 2013

https://CafePezeshki.IR

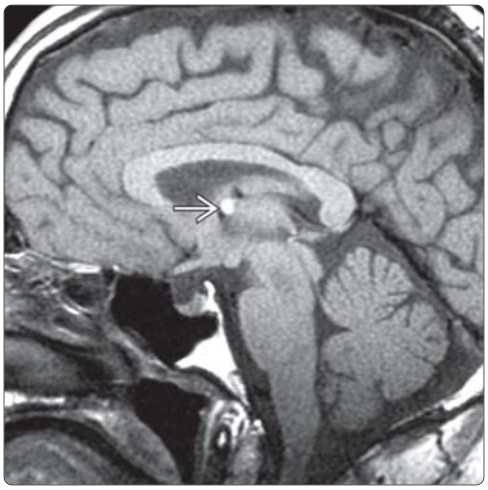

(Left) *Sagittal T1WI MR shows a tiny colloid cyst* ➡ *discovered incidentally in this asymptomatic patient.* **(Right)** *Axial T2WI MR in a patient with a large colloid cyst shows the "black hole" effect* ⇨, *a focus of profound hypointensity within the larger lesion* ⇨ *caused by inspissated, dessicated proteinaceous contents. These cysts are difficult to aspirate and generally must be surgically removed.*

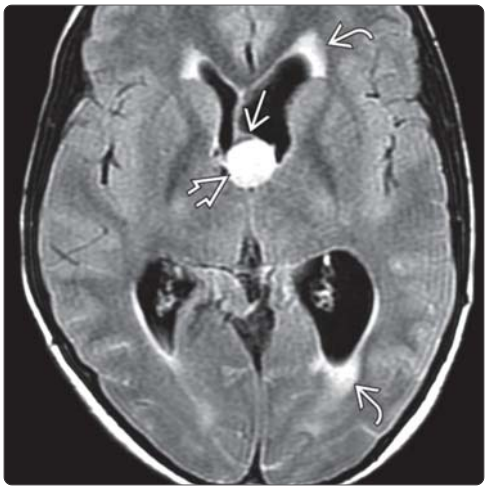

(Left) *Axial NECT in a 16-year-old boy, who presented in the ER with severe headaches and papilledema, shows severe obstructive hydrocephalus with dilated lateral ventricles and complete effacement of all superficial sulci. An isodense mass* ➡ *is present at the foramen of Monro.* **(Right)** *Axial FLAIR MR in the same patient shows the lesion* ➡ *to be very hyperintense and straddled by the fornix* ➡. *Ventricles are dilated and transependymal CSF flow* ➡ *is present. The colloid cyst was removed at surgery.*

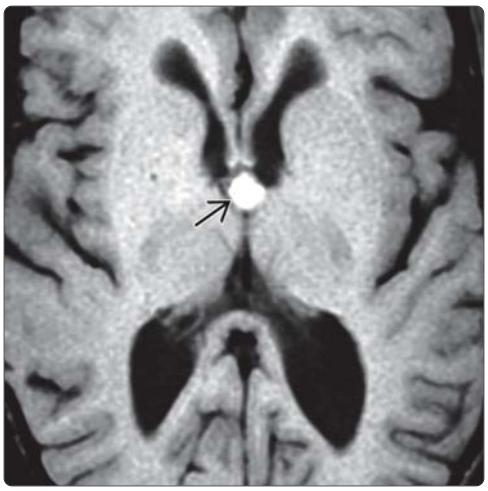

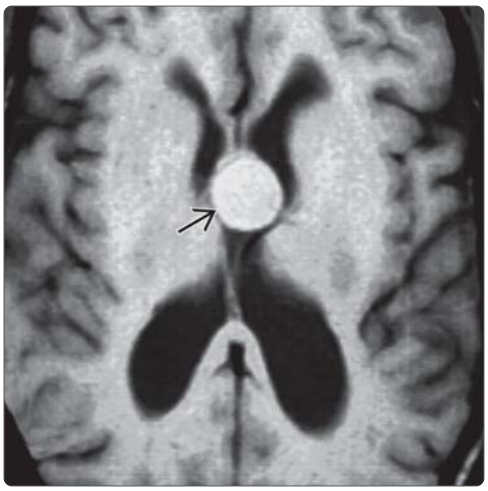

(Left) *Axial T1WI MR in this patient with only mild headaches shows a small CC* ⇨ *at the foramen of Monro. The patient declined surgery. Occasionally colloid cysts may increase in size over a relatively short period of time.* **(Right)** *Axial T1WI MR in the same patient performed after the patient developed sudden, dramatic increase in headaches a few months later. The cyst* ⇨ *enlarged and is now causing moderate obstructive hydrocephalus. A classic colloid cyst without evidence for hemorrhage was found.*

https://CafePezeshki.IR

Dermoid Cyst

KEY FACTS

TERMINOLOGY

- Benign, ectopic, squamous epithelial cyst containing dermal elements, including hair follicles and sebaceous and sweat glands

IMAGING

- Midline unilocular cystic lesion with fat
  - Subarachnoid fatty droplets if ruptured
- Suprasellar or posterior fossa most common intracranial sites
- Extracranial sites = spine, orbit
  - May have fistulous connections to skin (dermal sinus tract)
- CT hypodensity and negative Hounsfield units (fat)
  - 20% capsular Ca++
- MR: T1 hyperintense
  - Fat-suppression sequence confirms lipid elements
  - Fat-fluid level in cyst and in ventricles (if ruptured)
- With rupture: Extensive leptomeningeal enhancement possible from chemical meningitis

TOP DIFFERENTIAL DIAGNOSES

- Epidermoid cyst
- Craniopharyngioma
- Teratoma
- Lipoma

CLINICAL ISSUES

- Rare: < 0.5% of primary intracranial tumors
- Intradural dermoid cysts 4-9x less common than epidermoid cysts
- Rupture can cause significant morbidity/mortality
- Dermoid + dermal sinus may cause meningitis, hydrocephalus
- Treatment: Complete surgical excision ± shunt for hydrocephalus

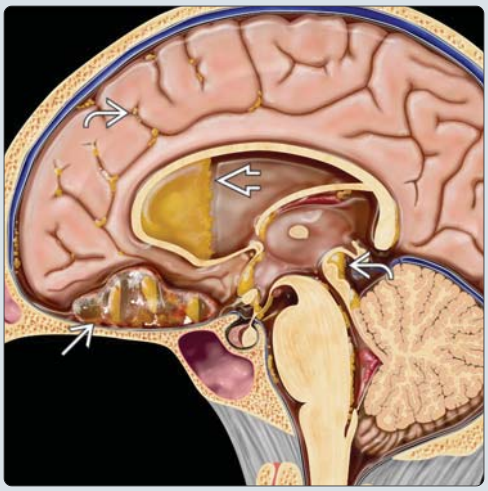

(Left) *Sagittal graphic of an inferior frontal dermoid shows a discrete, heterogeneous fat-containing mass with squamous epithelium and dermal appendages. There is a ventricular fat-fluid level and fat within the subarachnoid spaces related to the rupture.* **(Right)** *Axial NECT shows a hypodense midline fatty mass with focal calcification charateristic for ruptured dermoid cyst. Note fatty hypodense droplets in the sylvian fissures and subarachnoid spaces.*

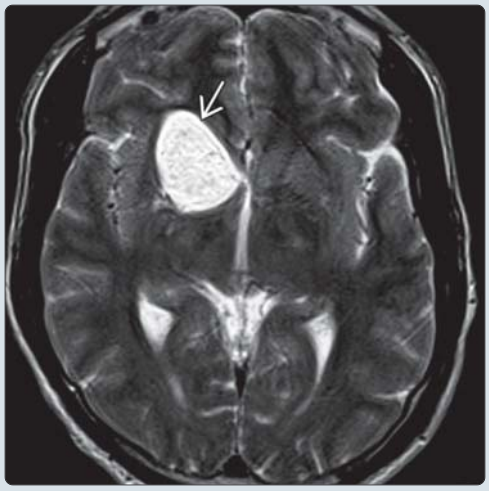

(Left) *T1WI shows classic dermoid cyst is hyperintense. Note fatty droplets in adjacent sylvian fissure typical for ruptured dermoid.* **(Right)** *Axial FSE T2WI in the same patient shows the mass is hyperintense, but internally heterogeneous. Ruptured dermoid cyst was confirmed at surgery.*

https://CafePezeshki.IR

TERMINOLOGY

Synonyms

- Dermoid inclusion cyst, ectodermal inclusion cyst

Definitions

- Benign, ectopic, squamous epithelial cyst containing dermal elements, including hair follicles and sebaceous and sweat glands

IMAGING

General Features

- Best diagnostic clue
  - Midline nonenhancing unilocular cystic lesion with fat
    - Subarachnoid fatty droplets if ruptured
- Location
  - Suprasellar, parasellar
  - Less common in posterior fossa: Cisterna magna, 4th ventricle, and basal cisterns
  - Extracranial sites = spine, orbit
    - May have fistulous connections to skin (dermal sinus tract)
    - Orbit: Dermolipoma at zygomatico-frontal suture
  - Ruptured: Subarachnoid/intraventricular spread of contents
- Size
  - Variable
- Morphology
  - Well-circumscribed, lipid-containing mass

CT Findings

- NECT
  - Round/lobulated, well-delineated, unilocular cystic mass
  - Hypodensity and negative Hounsfield units from fat
  - Capsular Ca++ (20%)
  - With rupture, droplets of fat disseminate in cisterns, may cause fat-fluid level within ventricles
  - Skull/scalp dermoid expands diploë
  - Frontonasal dermoid sinus tract: Bifid crista galli, large foramen cecum + sinus tract
  - Rare dense dermoid: Hyperattenuating
- CECT
  - Generally no enhancement in absence of infection

MR Findings

- T1WI
  - Unruptured: Hyperintense
  - Ruptured: Droplets very hyperintense
    - Fat-suppression sequence confirms lipid elements
    - Fat-fluid level in cyst; if ruptured, in ventricles as well
  - Rare dense dermoid: Very hyperintense
- T2WI
  - Unruptured: Heterogeneous, hypo- to hyperintense
    - Chemical shift artifact in frequency encoding direction with long TR
  - Ruptured: Typically hyperintense droplets
  - Rare dense dermoid: Very hypointense
  - With hair: Fine curvilinear hypointense elements
- T1WI C+
  - ± mild enhancement of capsule without central enhancement
  - With rupture: Extensive leptomeningeal enhancement possible from chemical meningitis
  - With infection: May see rim enhancement
- MRS
  - Elevated lipid peak from 0.9-1.3 ppm

Angiographic Findings

- Vasospasm with chemical meningitis from rupture
  - May relieve vasospasm with angioplasty
- Dermoid-encased vessels may have ↑ rupture risk

Imaging Recommendations

- Best imaging tool
  - MR with fat saturation
- Protocol advice
  - Use fat-suppression sequence to confirm diagnosis
  - Chemical shift-selective sequence useful to detect tiny droplets

DIFFERENTIAL DIAGNOSIS

Epidermoid Cyst

- Most epidermoid cysts resemble cerebrospinal fluid (CSF), no fat
- Restricted diffusion on DWI is classic
- Cyst lined with squamous epithelium without dermal elements
- 4-9x more common than dermoid
- Off midline > midline: In CPA (40-50%), parasellar/middle fossa (10-15%), diploic (10%)

Craniopharyngioma

- Also suprasellar/midline, often with intrasellar component
- CT: Multilocular with solid enhancing tissue (> 90%), nodular Ca++ in majority
- MR: Commonly T1 hypointense, T2 hyperintense, enhances strongly
- More common than dermoid (3-5% of primary intracranial tumors)

Teratoma

- Location similar, but usually pineal region
- 90% have all 3 embryologic layers: Ectoderm, mesoderm, endoderm
- Often multicystic/multiloculated
- Heterogeneous appearance containing calcification, CSF, lipid, and soft tissue components
- Does not have fat-fluid level

Lipoma

- Homogeneous midline fat
- Dermoids more likely heterogeneous
- Ca++ less frequent than in dermoid

PATHOLOGY

General Features

- Etiology
  - Embryology (2 theories)

https://CafePezeshki.IR

  - Sequestration of surface ectoderm at lines of epithelial fusion/along course of normal embryonic invaginations
  - Inclusion of cutaneous ectoderm at time of neural tube closure; 3rd to 5th week of embryogenesis
  - Can also arise at any age from traumatic implantation (i.e., lumbar puncture)
  - Similar etiology with epidermoid, which is thought to be later in development and off midline
- Genetics
  - Usually sporadic
  - Association with Goldenhar syndrome
  - Possible association with Klippel-Feil syndrome
- Associated abnormalities
  - Occipital/nasofrontal dermal sinus may be present; 89% of dermal sinuses associated with inclusion cysts
  - Goldenhar syndrome (a.k.a. oculoauriculovertebral dysplasia); congenital condition includes
    - Cranial lipomas and dermoids
    - Ocular dermoids
    - Anomalies of 1st and 2nd branchial arch derivatives
    - Cardiovascular, facial, oral, auricular, visceral, and spinal defects

Gross Pathologic & Surgical Features

- Unilocular cyst with thick wall
- Contents = lipid and cholesterol elements from sebaceous secretions floating on proteinaceous material

Microscopic Features

- Outer wall of squamous epithelium
- Inner lining contains dermal elements of hair follicles, sebaceous and apocrine glands
- Rare squamous cell carcinoma (SCCa) degeneration
  - Squamous cell predominance with some glandular differentiation
  - Suggestive of poorly differentiated squamous cell carcinoma with adenomatous component

CLINICAL ISSUES

Presentation

- Most common signs/symptoms
  - Uncomplicated dermoid: Headache (32%), seizure (30%) are most common symptoms
    - Large cyst can cause obstructive hydrocephalus
    - Less commonly hypopituitarism, diabetes insipidus, or cranial nerve (CN) defects
    - Suprasellar may present with visual symptoms
  - Cyst rupture causes chemical meningitis (6.9%)
- Other signs/symptoms
  - Recurrent meningitis when associated with sinus tract

Demographics

- Age
  - 2nd-3rd decade
- Gender
  - Slight male predilection
- Epidemiology
  - Rare: < 0.5% of primary intracranial tumors
  - Intradural dermoid cysts 4-9x less common than epidermoid cysts

Natural History & Prognosis

- Benign, slow growing
- Larger lesions associated with higher rupture rate
- Rupture can cause significant morbidity/mortality
  - Relatively rare and typically spontaneous
  - Seizure, coma, vasospasm, infarction, death
- Dermoid + dermal sinus may cause meningitis, hydrocephalus
- Rare malignant transformation into SCCa
  - Postulated prolonged or reparative process from foreign material leads to cellular atypia and neoplasia
  - May occur years after surgical resection

Treatment

- Complete surgical excision
  - Residual capsule may lead to recurrence
  - Rare SCCa degeneration within surgical remnants
- Subarachnoid dissemination of contents may occur during operative/postoperative course
  - Cause aseptic meningitis or other complications (hydrocephalus, seizures, CN deficits)
    - May require shunt placement for hydrocephalus
  - Alternatively, disseminated fat particles can remain silent without radiological/neurological change
    - Justifies "wait and see" approach
    - Regular MR and clinical exams are necessary to avoid complications

DIAGNOSTIC CHECKLIST

Consider

- When possible dermoid is seen near glabella or crista galli, look for sinus tract

Image Interpretation Pearls

- Follows fat characteristics on NECT and T1WI fat-suppressed MR

SELECTED REFERENCES

1. Fanous AA et al: Analysis of the growth pattern of a dermoid cyst. J Neurosurg Pediatr. 14(6):621-5, 2014
2. Wang YM et al: Spontaneous rupture of intracranial dermoid cyst with chemical meningitis. J Emerg Med. 44(2):e275-6, 2013
3. Ren X et al: Clinical, radiological, and pathological features of 24 atypical intracranial epidermoid cysts. J Neurosurg. 116(3):611-21, 2012
4. Li ZJ et al: Unusual CT hyperattenuating dermoid cyst of cerebellum: a new case report and literature review. Cerebellum. 10(3):536-9, 2011
5. Turgut M: Klippel-Feil syndrome in association with posterior fossa dermoid tumour. Acta Neurochir (Wien). 151(3):269-76, 2009
6. Liu JK et al: Ruptured intracranial dermoid cysts: clinical, radiographic, and surgical features. Neurosurgery. 62(2):377-84; discussion 384, 2008
7. Orakcioglu B et al: Intracranial dermoid cysts: variations of radiological and clinical features. Acta Neurochir (Wien). 150(12):1227-34; discussion 1234, 2008

https://CafePezeshki.IR

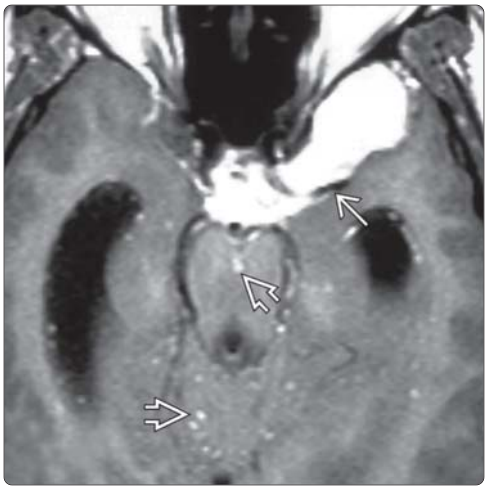

(Left) *Axial NECT shows a large, heterogeneous fatty mass in the left parasellar region. Note the typical fat-fluid level ⇨ within the dermoid cyst and minimal calcification ⇨.* **(Right)** *Axial T1WI MR in the same patient shows a hyperintense mass ⇨ with scattered foci of hyperintensity throughout the subarachnoid space ⇨. Chemical meningitis from a ruptured dermoid, while uncommon, can cause significant morbidity from seizures, vasospasm, infarction, and even death.*

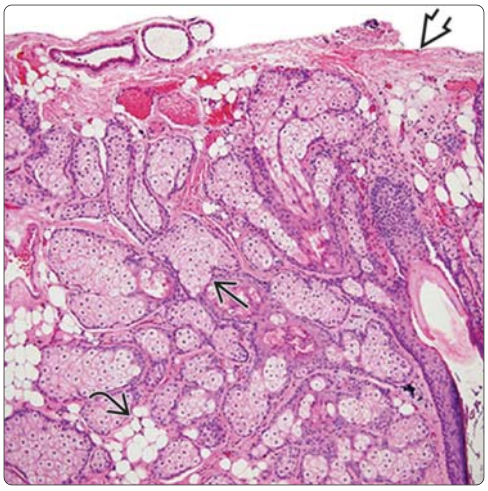

(Left) *Axial T1WI C+ FS MR in the same patient shows complete suppression of the fatty mass with minimal capsular enhancement ⇨. The severe communicating hydrocephalus is caused by a chemical meningitis ⇨. Patients with a ruptured dermoid are typically treated with resection of the cyst and ventricular decompression.* **(Right)** *High-power micropathology shows typical dermoid cyst features with keratin lining ⇨, multiple sebaceous glands ⇨, and fat ⇨.*

(Left) *Axial NECT shows a large, mixed fatty and calcified, suprasellar and subfrontal mass. Low-density fat droplets ⇨ are seen in the adjacent sylvian fissure, related to dermoid rupture. Headaches and seizures are the most common presenting features of these cysts. Rupture may cause a chemical meningitis.* **(Right)** *Axial CECT shows a fat-containing orbital mass in a young adult. Dermoids of the orbit are most commonly "dermolipomas" and are associated with the zygomatico-frontal suture.*

https://CafePezeshki.IR

KEY FACTS

TERMINOLOGY

- Intracranial epidermoids: Congenital inclusion cysts

IMAGING

- CSF-like mass that insinuates cisterns and encases neurovascular structures
- Morphology: Lobulated, irregular, cauliflower-like mass with "fronds"
- FLAIR: Usually does not completely null
- DWI: Diffusion hyperintensity definitively distinguishes from arachnoid cyst

TOP DIFFERENTIAL DIAGNOSES

- Arachnoid cyst
- Inflammatory cyst (i.e., neurocysticercosis)
- Cystic neoplasm
- Dermoid cyst

PATHOLOGY

- Arise from ectodermal inclusions during neural tube closure, 3rd to 5th week embryogenesis

CLINICAL ISSUES

- Symptoms depend on location and effect on adjacent neurovascular structures
  - Most common symptom: Headache
  - Cranial nerve 5, 7, 8 neuropathy common
- 0.2-1.8% of all primary intracranial tumors
- Rare malignant degeneration into squamous cell carcinoma
- Treatment: Microsurgical resection
  - Recurrence common if incompletely removed

DIAGNOSTIC CHECKLIST

- Insinuates and surrounds rather than displaces
- Incomplete nulling on FLAIR; DWI hyperintense

(Left) *Sagittal graphic illustrates a multilobulated epidermoid primarily within the prepontine cistern. Significant mass effect displaces the pons, cervicomedullary junction, and upper cervical spine.* **(Right)** *Sagittal T1WI C+ MR shows a nonenhancing epidermoid ➡ arising from the prepontine cistern with extensive mass effect upon the pons, midbrain, and hypothalamus. Its intensity is slightly greater than normal CSF ⇨, and it has insinuated itself around the pons into the ambient cistern ⇨.*

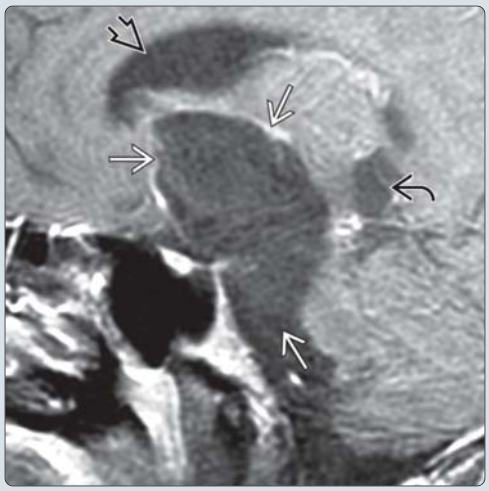

(Left) *Gross pathology shows an epidermoid cyst extending anterosuperiorly from the CPA cistern, insinuating within the prepontine cistern and encasing the basilar artery ⇨. Note its typical pearly appearance. (Courtesy E. Hedley-Whyte, MD.)* **(Right)** *Collage of images illustrates cerebellopontine angle epidermoid cyst that resembles CSF on T1- and T2WI ➡ but typically does not suppress on FLAIR ⇨ and demonstrates moderate restricted diffusion ➡.*

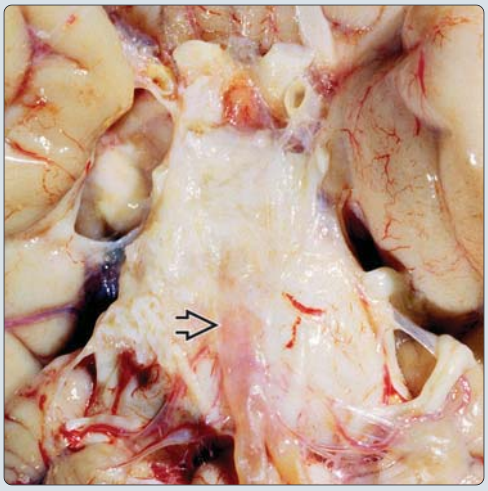

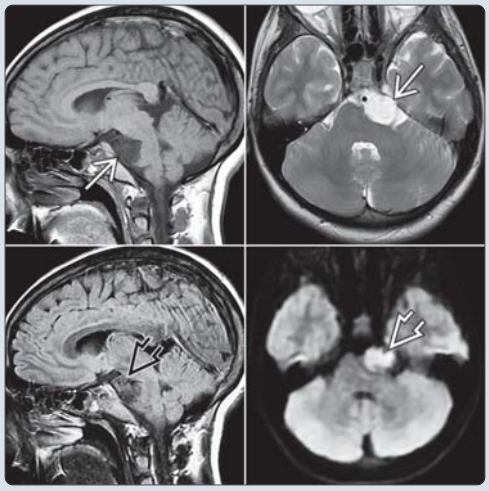

https://CafePezeshki.IR

TERMINOLOGY

Synonyms

- Ectodermal inclusion cyst

Definitions

- Intracranial epidermoids: Congenital inclusion cysts

IMAGING

General Features

- Best diagnostic clue
  - CSF-like mass that insinuates cisterns and encases neurovascular structures
- Location
  - Intradural (90%), primarily in basal cisterns
    - Cerebellopontine angle (CPA) (40-50%)
    - 4th ventricle (17%)
    - Parasellar/middle cranial fossa (10-15%)
    - Cerebral hemispheres (rare) (1.5%)
    - Brainstem location exceedingly rare
    - Intraventricular within tela choroidea of temporal horn, 3rd or 4th ventricles
  - Extradural (10%): Skull (intradiploic within frontal, parietal, occipital, sphenoid skull) as well as spine
- Morphology
  - Lobulated, irregular, cauliflower-like mass with "fronds"
  - Insinuates without mass effect unless large

Radiographic Findings

- Radiography
  - Diploic space epidermoids
    - May alter scalp, outer/inner skull tables, and epidural space appearance
    - Typically round or lobulated
    - Well delineated with sclerotic rim

CT Findings

- NECT
  - Round/lobulated mass
  - > 95% hypodense, resembling CSF
  - 10-25% contain calcifications
  - Rare variant = "dense" epidermoid
    - 3% of intracranial epidermoids
    - Secondary to hemorrhage, high protein, saponification of cyst debris to calcium soaps or iron-containing pigment
- CECT
  - Usually none, though margin of cyst may show minimal enhancement
- Bone CT
  - May have bony erosion; sharply corticated margins when intradiploic

MR Findings

- T1WI
  - Often (~ 75%) slightly hyperintense to CSF
  - Lobulated periphery may be slightly more hyperintense than center
  - Uncommonly hyperintense to brain ("white epidermoid") due to high triglycerides and unsaturated fatty acids
  - Uncommonly hypointense to CSF ("black epidermoid")
    - Presence of solid crystal cholesterol and keratin
    - Lack of triglycerides and unsaturated fatty acids
- T2WI
  - Often isointense (65%) to slightly hyperintense (35%) to CSF
  - Very rarely hypointense due to calcification, ↓ hydration, viscous secretions, and iron pigments
- FLAIR
  - Usually does not completely null
- DWI
  - Characteristic hyperintensity
    - High fractional anisotropy due to diffusion along 2D geometric plane
      - Attributed to microstructure of parallel-layered keratin filaments and flakes
    - In comparison to white matter, which also shows high fractional anisotropy, due to diffusion along single direction
  - ADC = brain parenchyma
- T1WI C+
  - Usually none, though margin of cyst may show minimal enhancement (25%)
  - Enhancing tumor is sign of malignant degeneration
- MRS
  - Resonances from lactate
  - No NAA, choline, or lipid

Angiographic Findings

- Conventional
  - Depending on location and size, may show avascular mass effect

Nonvascular Interventions

- Myelography
  - Cisternography contrast delineates irregular lobulated tumor borders, extends into interstices

Imaging Recommendations

- Best imaging tool
  - MR
- Protocol advice
  - FLAIR will often distinguish whereas conventional sequences may not
  - Diffusion hyperintensity definitively distinguishes from arachnoid cyst

DIFFERENTIAL DIAGNOSIS

Arachnoid Cyst

- Usually isointense to CSF on all standard sequences
  - Completely nulls on FLAIR
  - Hypointense diffusion: Contains highly mobile CSF, ADC = stationary water
- Rather than insinuate and engulf local structures, arachnoid cysts displace them
- Smooth surface, unlike lobulations of epidermoids

Inflammatory Cyst

- i.e., neurocysticercosis
- Often enhances
- Density/signal intensity usually not precisely like CSF
- Adjacent edema, gliosis common

https://CafePezeshki.IR

Cystic Neoplasm

- Attenuation/signal intensity not that of CSF
- Often enhances

Dermoid Cyst

- Usually at or near midline
- Resembles fat, not CSF, and contains dermal appendages; often ruptured

PATHOLOGY

General Features

- Etiology
  - Congenital: Embryology
    - Arise from ectodermal inclusions during neural tube closure, 3rd to 5th week embryogenesis
    - Congenital intradural CPA epidermoids derived from cells of 1st branchial groove
  - Acquired: Develop as result of trauma
    - Uncommon etiology for intracranial tumors
    - More common as spine etiology following LP
- Genetics
  - Sporadic
- Associated abnormalities
  - May have occipital/nasofrontal dermal sinus tract

Gross Pathologic & Surgical Features

- Outer surface often has shiny, glistening mother of pearl appearance ("beautiful tumor")
- Soft and pliable
  - Conforms to shape of adjacent local structures/spaces
- Lobulated excrescences
  - May invaginate into brain
- Insinuating growth pattern, extends through cisterns, surrounds and encases vessels/nerves
- Cyst filled with soft, waxy, creamy, or flaky material

Microscopic Features

- Cyst wall = internal layer of simple stratified cuboidal squamous epithelium covered by fibrous capsule
- Cyst contents = solid crystalline cholesterol, keratinaceous debris; no dermal appendages
- Grows by progressive desquamation with conversion to keratin/cholesterol crystals, forming concentric lamellae

CLINICAL ISSUES

Presentation

- Most common signs/symptoms
  - Symptoms depend on location and effect on adjacent neurovascular structures
    - Most common symptom: Headache
    - Cranial nerve 5, 7, 8 neuropathy common
    - 4th ventricular cerebellar signs common, yet increased intracranial pressure rare
    - Less commonly hypopituitarism, diabetes insipidus
    - Seizures if in sylvian fissure/temporal lobe
  - May remain clinically silent for many years

Demographics

- Age
  - Presents between 20-60 years with peak at 40 years
  - Presentation is uncommon in childhood
- Gender
  - M = F
    - CT hyperdense variant lesions have female predominance (M:F = 1:2.5)
- Epidemiology
  - Epidermoids make up 0.2-1.8% of all primary intracranial tumors
  - Much more common than dermoid cyst (4-9x higher incidence)
  - Most common congenital intracranial tumor
  - 3rd most common CPA/IAC mass, after vestibular schwannoma and meningioma

Natural History & Prognosis

- Grows slowly: Epithelial component growth rate commensurate to that of normal epithelium
- Chemical meningitis possible from content leakage
- Rare malignant degeneration into squamous cell carcinoma (SCCa) reported
  - Postulated prolonged or reparative process from foreign material leads to cellular atypia and neoplasia
  - Often predated by frequent recurrences
  - May occur years after surgical resection
  - Mean age at presentation: 52 years with male preponderance

Treatment

- Microsurgical resection
  - Complicated by investment of local structures
  - Recurrence common if incompletely removed
  - Subarachnoid dissemination of contents may occur during operative/postoperative course
    - May cause chemical meningitis
    - CSF seeding and implantation reported
- Rare malignant degeneration of resection bed into SCCa reported

DIAGNOSTIC CHECKLIST

Consider

- Epidermoid if insinuates and surrounds rather than displaces

Image Interpretation Pearls

- Resembles CSF on imaging studies, except usually incomplete nulling on FLAIR
- DWI hyperintensity is diagnostic

SELECTED REFERENCES

1. Aboud E et al: Giant intracranial epidermoids: is total removal feasible? J Neurosurg. 1-14, 2015
2. Law EK et al: Atypical intracranial epidermoid cysts: rare anomalies with unique radiological features. Case Rep Radiol. 2015:528632, 2015
3. Vellutini EA et al: Malignant transformation of intracranial epidermoid cyst. Br J Neurosurg. 28(4):507-9, 2014
4. Ren X et al: Clinical, radiological, and pathological features of 24 atypical intracranial epidermoid cysts. J Neurosurg. 116(3):611-21, 2012

https://CafePezeshki.IR

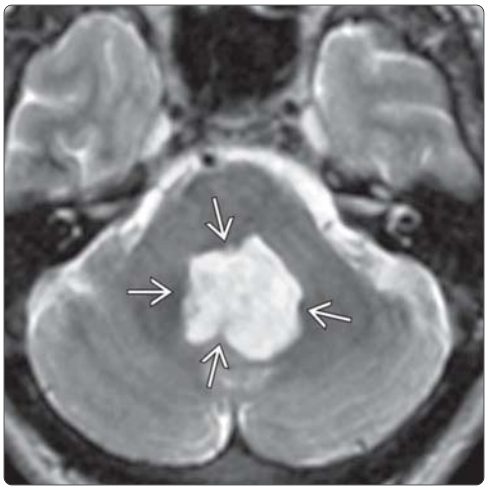

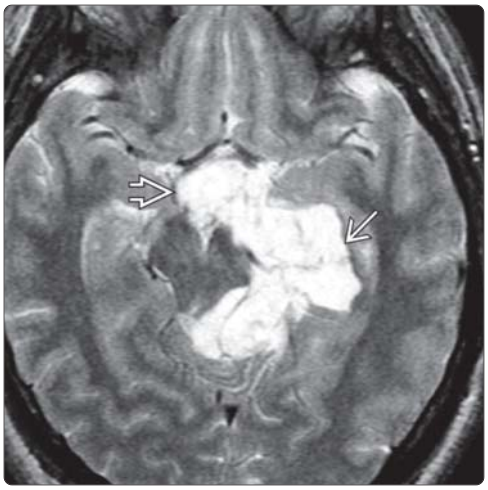

(Left) *Axial T2WI MR demonstrates "scalloped" expansion of an epidermoid within the 4th ventricle ➡. This is the 2nd most common location for epidermoids yet is statistically uncommon at only 17%.* **(Right)** *Axial T2WI MR shows a hyperintense, lobulated mass in the ambient cistern ➡. Most epidermoid cysts are laterally located, but this one is unusually extensive and has a large suprasellar component as well ➡.*

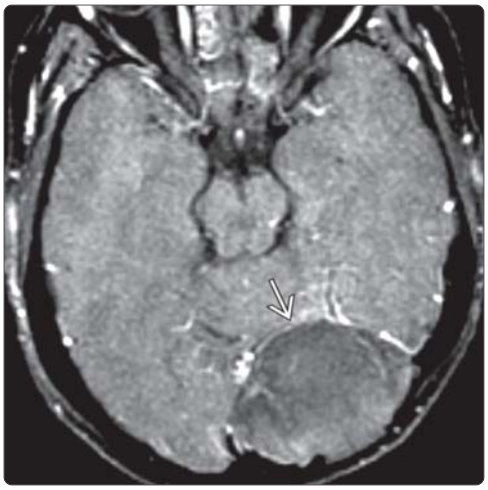

(Left) *Axial T2WI MR shows an extraaxial left occipital mass that scallops the skull ➡ and displaces the dura inwardly ➡.* **(Right)** *Axial T1WI C+ FS MR in the same patient shows the mass does not enhance ➡. DWI (not shown) clinched the diagnosis as an epidermoid cyst. This is an atypical location for epidermoid.*

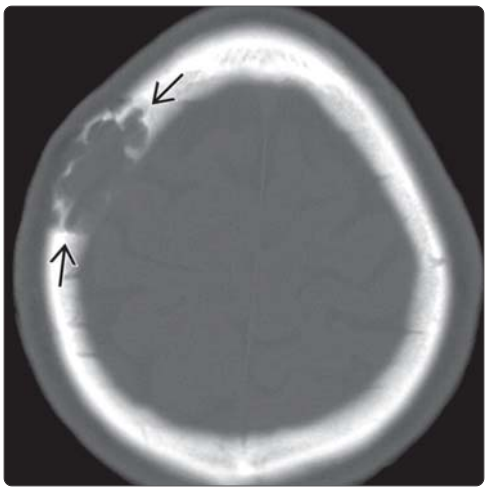

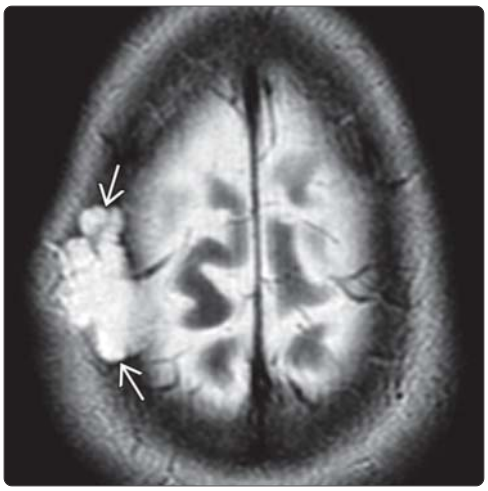

(Left) *Axial bone CT demonstrates the typical appearance of an intradiploic epidermoid as an expansile lesion with sharply corticated margins ⇨.* **(Right)** *Axial T2WI MR in the same patient shows lobulated hyperintense mass scallops the skull ➡. Intradiploic epidermoid cyst was removed at surgery.*

https://CafePezeshki.IR

Neuroglial Cyst

KEY FACTS

TERMINOLOGY

- Neuroglial cyst (NGC), a.k.a. glioependymal cyst
- Benign, glial-lined, fluid-containing cavity buried within cerebral white matter
  - May occur anywhere throughout neuraxis
  - Frontal lobe most common site
  - Size varies from few mm up to several cm

IMAGING

- CT
  - Well-delineated, low-density, unilocular parenchymal cyst
  - No Ca++ or enhancement
- MR
  - T1 hypo-/T2 hyperintense (resembles CSF)
  - Usually suppresses on FLAIR
  - Does not restrict on DWI
  - No enhancement
  - Minimal/no surrounding signal abnormality

TOP DIFFERENTIAL DIAGNOSES

- Porencephalic cyst
- Enlarged perivascular spaces (PVSs)
- Arachnoid cyst
- Ependymal cyst
- Epidermoid cyst
- Infectious cyst (e.g., neurocysticercosis, echinococcosis)

DIAGNOSTIC CHECKLIST

- Parenchymal cysts that do not communicate with ventricular system and have minimal/no surrounding gliosis may be NGC
- Use FLAIR, DWI to help distinguish between different types of intracranial cysts

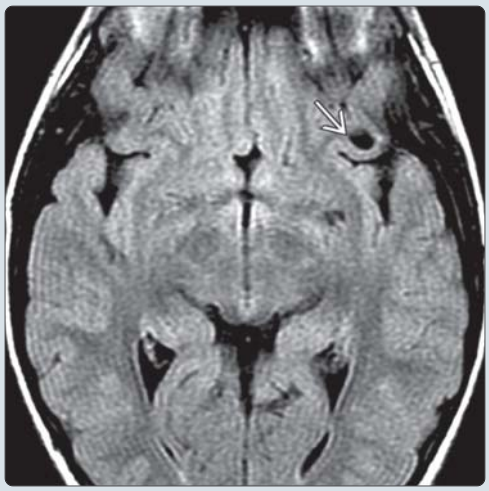

(Left) *Axial graphic shows a classic neuroglial cyst. This well-delineated, unilocular lesion does not communicate with the ventricles and contains clear fluid. The surrounding brain is normal. Neuroglial cysts are lined with glial cells, astrocytes, and rarely ependymal cells.* **(Right)** *Axial FLAIR MR in a child shows incidental finding of a benign-appearing cyst in the left frontal subcortical white matter ➡. The cyst followed CSF on all sequences and did not enhance.*

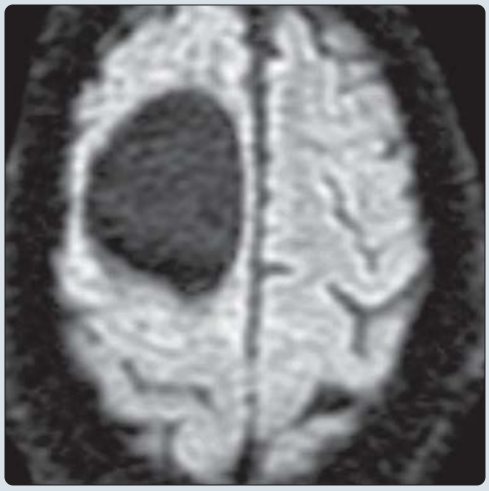

(Left) *Axial FLAIR MR in a young adult with headaches shows a large right frontal CSF-like cyst ➡.* **(Right)** *Axial DWI MR in the same patient shows no restriction. The cyst was biopsied and drained. Histological examination showed the cyst lining was glial tissue with no evidence for epithelial elements.*

https://CafePezeshki.IR

TERMINOLOGY

Abbreviations

- Neuroglial cyst (NGC)

Synonyms

- Glioependymal cyst

Definitions

- Benign, glial-lined, fluid-containing cavity buried within cerebral white matter

IMAGING

General Features

- Best diagnostic clue
  - Nonenhancing CSF-like parenchymal cyst with minimal/no surrounding signal abnormality
- Location
  - May occur anywhere throughout neuraxis
    - Frontal lobe most common site
    - Intraparenchymal > extraparenchymal
- Size
  - Varies from few mm up to several cm
- Morphology
  - Smooth, rounded, unilocular, benign-appearing cyst

CT Findings

- NECT
  - Well-delineated, low-density cyst
    - Unilocular; no Ca++
- CECT
  - Wall does not enhance

MR Findings

- T1WI
  - Usually hypointense, resembles CSF
- T2WI
  - Hyperintense
- PD/intermediate
  - May be slightly hyperintense to CSF
- FLAIR
  - Usually suppresses
- DWI
  - Typically no diffusion restriction
- T1WI C+
  - No enhancement

Imaging Recommendations

- Best imaging tool
  - MR with T1WI C+, FLAIR, DWI

DIFFERENTIAL DIAGNOSIS

Porencephalic Cyst

- Communicates with ventricles
- Adjacent brain usually shows gliosis, spongiosis

Enlarged Perivascular Spaces (PVSs)

- Clusters of variable-sized cysts > single, unilocular cyst

Arachnoid Cyst

- Extraaxial

Ependymal Cyst

- Intraventricular

Epidermoid Cyst

- Does not suppress on FLAIR, restricts on DWI

Infectious Cyst

- e.g., neurocysticercosis, echinococcosis

PATHOLOGY

Gross Pathologic & Surgical Features

- Rounded, smooth, unilocular cyst usually containing clear fluid resembling CSF

Microscopic Features

- Varies from columnar (ependymal type) epithelium to low cuboidal cells resembling choroid plexus
  - Variable expression of GFAP
  - Cytokeratin, EMA expression absent

CLINICAL ISSUES

Presentation

- Most common signs/symptoms
  - Headache
- Other signs/symptoms
  - Seizures
  - Neurologic deficit (depends on cyst size, location)

Demographics

- Age
  - Any age; adults > children
- Gender
  - M = F
- Epidemiology
  - Uncommon (< 1% of intracranial cysts)

Natural History & Prognosis

- Varies with cyst size, location
- May be stable over many years

Treatment

- Observation vs. fenestration/drainage of cyst

DIAGNOSTIC CHECKLIST

Image Interpretation Pearls

- Use FLAIR, DWI to help distinguish between different types of intracranial cysts

SELECTED REFERENCES

1. El-Ghandour NM: Endoscopic treatment of intraparenchymal arachnoid cysts in children. J Neurosurg Pediatr. 14(5):501-7, 2014
2. Fiorindi A et al: Neuroendoscopic options in the treatment of mesencephalic expanding cysts: report of four cases and review of the literature. Clin Neurol Neurosurg. 115(11):2370-6, 2013
3. Eyselbergs M et al: Epileptic seizure due to neuroglial cyst. JBR-BTR. 95(3):142-3, 2012
4. Osborn AG et al: Intracranial cysts: radiologic-pathologic correlation and imaging approach. Radiology. 239(3):650-64, 2006

https://CafePezeshki.IR

KEY FACTS

TERMINOLOGY

- Periventricular cysts (PCs) of newborn
  - Encompasses wide variety of periventricular cystic lesions

IMAGING

- Anterior choroid plexus cysts (ACPC)
  - Posterior to caudothalamic groove, within choroid plexus or protruding into lateral ventricle
- Subependymal pseudocysts (SEPC)
  - Nonhemorrhagic: Anterior to caudothalamic groove
  - Posthemorrhagic: Commonly in caudothalamic notch
- Connatal cyst (CS)
  - At or just below superolateral angles of frontal horns &/or body of lateral ventricles
- Cystic periventricular leukomalacia (cPVL)
  - At or above superolateral angle of frontal horn
  - Along margins of lateral ventricles

CLINICAL ISSUES

- Bilateral ACPC or SEPC → look for systemic disease
  - Inborn error of metabolism, TORCH, cocaine, etc.
- cPVL: More common in association with cytokine damage
  - Neonatal enterovirus
  - Maternal chorioamnionitis
  - Sepsis
- SEPC &/or ACPC detected in up to 5% of neonates
  - Frequently involute over time

DIAGNOSTIC CHECKLIST

- Isolated SEPCs detected at prenatal US should prompt further investigation in following conditions
  - Cysts ≥ 9 mm diameter
  - SEPC located posterior to caudothalamic notch
  - SEPC with atypical morphology
  - SEPC facing temporal horns

(Left) *Coronal ultrasound in a newborn with intrauterine growth retardation demonstrates a round cyst in the anterior horn of the left lateral ventricle.* **(Right)** *Longitudinal ultrasound in the same infant shows the cyst behind the caudothalamic groove. The cyst may "bounce" on ultrasound.*

(Left) *Axial FLAIR MR in newborn with mitochondrial depletion syndrome and lactic acidosis demonstrates multiple periventricular cysts (PCs). Large paraventricular cysts adjacent to the frontal horns were noted in utero. Additionally, a subependymal cyst is anterior to the caudothalamic groove.* **(Right)** *Sagittal T2WI MR in a newborn with Zellweger syndrome reveals ventriculomegaly, focal cortical dysplasia, and a large subependymal cyst anterior to the caudothalamic groove.*

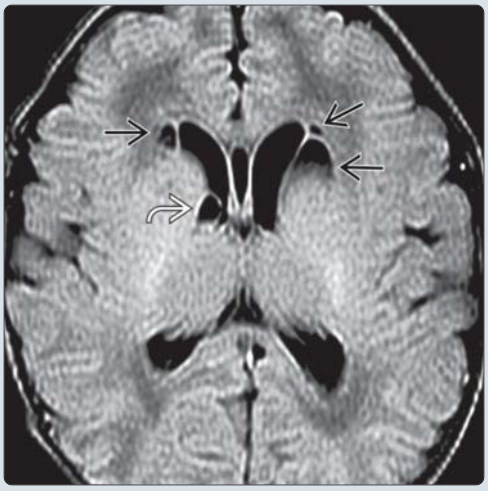

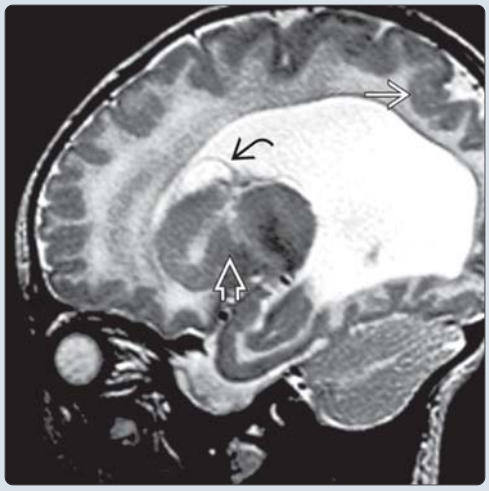

https://CafePezeshki.IR

TERMINOLOGY

Abbreviations

- Neonatal periventricular cysts (PCs)

Definitions

- Periventricular cysts of newborn: Encompasses wide variety of periventricular cystic lesions
  - Anterior choroid plexus cyst (ACPC)
    - Cyst of anterior portion of choroid plexus in body of lateral ventricles
  - Subependymal pseudocyst (SEPC)
    - Subependymal cyst in region of caudate nucleus; may be congenital (germinolytic) or acquired (posthemorrhagic)
  - Connatal cyst (CS), a.k.a. coarctation of anterior horns
    - Controversial, some authors consider CS to be germinolytic cysts (GC)
  - Cystic periventricular leukomalacia (cPVL), previously known as paraventricular cysts
- Considerable overlap and confusion in literature

IMAGING

General Features

- Best diagnostic clue
  - ACPC
    - Spherical, thick or double walled
    - On US, look for "bouncing" of ACPC with pulsation to confirm location within choroid plexus
  - SEPC
    - Teardrop-shaped, thin walled
    - Nonhemorrhagic
      - Anterior to caudothalamic groove
    - Hemorrhagic
      - In caudothalamic groove, blood products identifiable during acute phase
  - cPVL
    - Local loss of brain volume
- Location
  - ACPC
    - Posterior to caudothalamic groove
    - Within choroid plexus or protruding into lateral ventricle
  - SEPC
    - Nonhemorrhagic
      - Anterior to caudothalamic groove
    - Posthemorrhagic
      - Commonly in caudothalamic notch
    - Slightly more common on left side
  - CS
    - At or just below superolateral angles of frontal horns &/or body of lateral ventricles
    - Anterior to foramina of Monro
  - cPVL
    - At or above superolateral angle of frontal horn
    - Along margins of lateral ventricles, anterior to posterior
    - Cysts may communicate with ventricles (porencephaly) or be separated from ventricles by ependyma
- Size
  - SEPC: 2-11 mm
  - Cysts in cystic periventricular leukomalacia are most variable in size, may be several centimeters in diameter
- Morphology
  - ACPC: Spherical, may exhibit double wall, nonseptate
  - SEPC: Teardrop-shaped, thin walled

CT Findings

- NECT: Hemorrhage within cysts may give clue to etiology

Ultrasonographic Findings

- ACPC: Double wall, may "bounce" with pulsation

Imaging Recommendations

- Best imaging tool
  - High-resolution sonography/linear array
- Protocol advice
  - Include gradient sequences with MR to exclude or confirm hemorrhagic etiology

DIFFERENTIAL DIAGNOSIS

Arachnoid Cyst

- Giant arachnoid cysts of foramen of Monro
- Distinguished by location
  - Not along caudothalamic groove
  - Not at superolateral frontal horn
  - Not along ventricular margins

Choroid Plexus Papilloma

- Rarely, choroid plexus papillomas can be purely cystic
- Intra- rather than periventricular

Hippocampal Sulcus Remnant Cysts

- Cornu ammonis, dentate gyrus normally fuse
- Defects leave remnant cysts within primitive hippocampal fissure
- Seen medial to temporal horn of lateral ventricle
- CSF-like "string of pearls" along hippocampus

Leukoencephalopathy With Calcifications and Cysts

- Distinguished genetically from Coats plus by absence of *CTC1* mutations
- Dense Ca++ in basal ganglia, thalami, dentate, brainstem, deep WM, pericystic distribution
- Diffuse leukoencephalopathy, usually symmetrical and periventricular
- Cysts in basal ganglia, thalami, deep WM, cerebellum, brainstem

PATHOLOGY

General Features

- Etiology
  - SEPC: Subependymal germinal matrix of neuronal and glial proliferation
    - Metabolically active and richly vascular
    - Insult (infection, hemorrhage, genetic) → lysis of cells

Gross Pathologic & Surgical Features

- Subependymal cyst
  - Cystic cavity bounded by pseudocapsule

https://CafePezeshki.IR

- Pseudocapsule consists of aggregates of germinal cells and glial tissue, not epithelium
- ± hemorrhage or reactive astrocytes, cystic necrosis
- CS: Ependymal lined
- cPVL: Cavitary white matter necrosis

CLINICAL ISSUES

Presentation

- Most common signs/symptoms
  - SEPC vs. ACPC
    - SEPC somewhat more likely than ACPC to be associated with anomalies or systemic disease
    - Unilateral ACPC or SEPC
      - Low likelihood of associated anomalies
    - Bilateral ACPC or SEPC
      - Look for systemic disease
- Other signs/symptoms
  - ACPC very occasionally causes obstruction at foramina of Monro

Natural History & Prognosis

- SEPC &/or ACPC detected in up to 5% of neonates, frequently involute over time
  - Neurodevelopment of newborns with SEPC normal when no underlying disease present (exclude CMV infection)
  - Postnatal acquired SEPC (hemorrhagic) in very low-birth-weight infants = risk factor for impaired motor development
- cPVL prognosis generally poor, dependent upon amount of destroyed tissue that becomes incorporated into ventricle over time

Treatment

- None unless obstruction of lateral ventricles occurs

DIAGNOSTIC CHECKLIST

Consider

- Bilateral SEPCs are markers for systemic disease
  - Aneuploidy and multiple congenital anomaly syndromes
  - Growth disorders: Intrauterine growth restriction, large for gestational dates, Soto syndrome
  - TORCH: CMV, rubella
  - Intrauterine exposure to cocaine
  - Inborn error of metabolism
    - Peroxisomal biogenesis disorders (Zellweger)
    - Congenital lactic acidoses, PDH deficiency
    - Holocarboxylase synthetase deficiency
    - D-2OH and L-2OH glutaric aciduria
- Isolated SEPCs detected at prenatal US should prompt further investigation in following conditions
  - Cysts ≥ 9 mm diameter
  - SEPC facing temporal horns
  - SEPC located posterior to caudothalamic notch
  - SEPC with atypical morphology

Image Interpretation Pearls

- CT or gradient sequences may aid in differentiation

Reporting Tips

- May be extremely difficult or even impossible to differentiate SEPC and ACPC

SELECTED REFERENCES

1. Drenckhahn A et al: Leukodystrophy with multiple beaded periventricular cysts: unusual cranial MRI results in Canavan disease. J Inherit Metab Dis. ePub, 2015
2. Esteban H et al: Prenatal features of isolated subependymal pseudocysts associated with adverse pregnancy outcome. Ultrasound Obstet Gynecol. ePub, 2015
3. Livingston JH et al: Leukoencephalopathy with calcifications and cysts: a purely neurological disorder distinct from coats plus. Neuropediatrics. 45(3):175-82, 2014
4. Cevey-Macherel M et al: Neurodevelopment outcome of newborns with cerebral subependymal pseudocysts at 18 and 46 months: a prospective study. Arch Dis Child. 98(7):497-502, 2013
5. Tan ZY et al: Case of the month. Ultrasound and MRI features of connatal cysts: clinicoradiological differentiation from other supratentorial periventricular cystic lesions. Br J Radiol. 83(986):180-3, 2010
6. Fernandez Alvarez JR et al: Diagnostic value of subependymal pseudocysts and choroid plexus cysts on neonatal cerebral ultrasound: a meta-analysis. Arch Dis Child Fetal Neonatal Ed. 94(6):F443-6, 2009
7. Leijser LM et al: Brain imaging findings in very preterm infants throughout the neonatal period: part I. Incidences and evolution of lesions, comparison between ultrasound and MRI. Early Hum Dev. 85(2):101-9, 2009
8. van Baalen A et al: From fossil to fetus: nonhemorrhagic germinal matrix echodensity caused by mineralizing vasculitis--hypothesis of fossilizing germinolysis and gliosis. J Child Neurol. 24(1):36-44, 2009
9. Soares-Fernandes JP et al: Neonatal pyruvate dehydrogenase deficiency due to a R302H mutation in the PDHA1 gene: MRI findings. Pediatr Radiol. 38(5):559-62, 2008
10. van Baalen A et al: Anterior choroid plexus cysts: distinction from germinolysis by high-resolution sonography. Pediatr Int. 50(1):57-61, 2008
11. Chuang YC et al: Neurodevelopment in very low birth weight premature infants with postnatal subependymal cysts. J Child Neurol. 22(4):402-5, 2007
12. van Baalen A et al: [Non-haemorrhagic subependymal pseudocysts: ultrasonographic, histological and pathogenetic variability.] Ultraschall Med. 28(3):296-300, 2007
13. Epelman M et al: Differential diagnosis of intracranial cystic lesions at head US: correlation with CT and MR imaging. Radiographics. 26(1):173-96, 2006
14. Finsterer J et al: Adult unilateral periventricular pseudocysts with ipsilateral headache. Clin Neurol Neurosurg. 108(1):73-6, 2005
15. Cuillier F et al: [Subependymal pseudocysts in the fetal brain revealing Zellweger syndrome.] J Gynecol Obstet Biol Reprod (Paris). 33(4):325-9, 2004
16. Qian JH et al: [Prospective study on prognosis of infants with neonatal subependymal cysts.] Zhonghua Er Ke Za Zhi. 42(12):913-6, 2004
17. Herini E et al: Clinical features of infants with subependymal germinolysis and choroid plexus cysts. Pediatr Int. 45(6):692-6, 2003
18. Pal BR et al: Frontal horn thin walled cysts in preterm neonates are benign. Arch Dis Child Fetal Neonatal Ed. 85(3):F187-93, 2001
19. Rosenfeld DL et al: Coarctation of the lateral ventricles: an alternative explanation for subependymal pseudocysts. Pediatr Radiol. 27(12):895-7, 1997
20. Shackelford GD et al: Cysts of the subependymal germinal matrix: sonographic demonstration with pathologic correlation. Radiology. 149(1):117-21, 1983
21. Takashima S et al: Old subependymal necrosis and hemorrhage in the prematurely born infants. Brain Dev. 1(4):299-304, 1979

https://CafePezeshki.IR

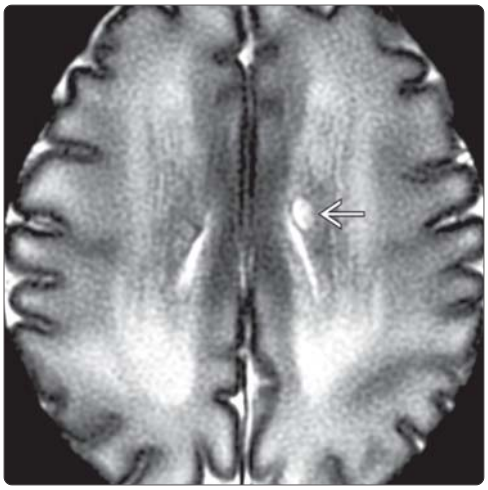

(Left) *Coronal ultrasound 1 day after birth in a 31-week gestational infant demonstrates a cyst ⇨ adjacent to the lateral corner of the anterior horn. It is formed by a web-like adhesion ⇨ or coaptation of the anterior horn, representing a connatal cyst (CS).* **(Right)** *Axial T2WI MR in the same infant shows the CS ⇨. As is typical, the cyst was not present on follow-up ultrasound or MR.*

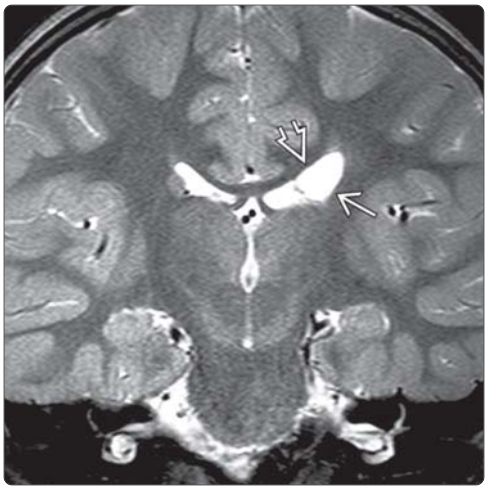

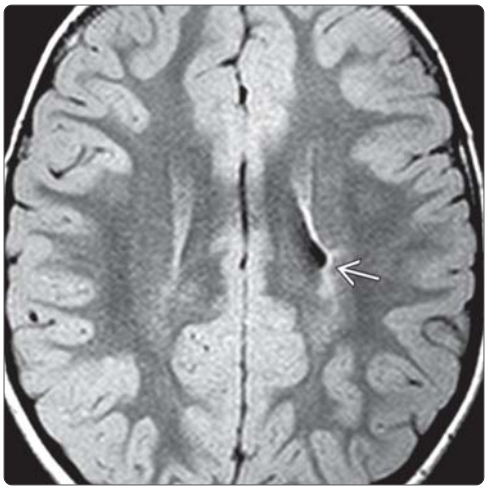

(Left) *Coronal T2WI MR in a toddler with a history of congenital hemiparesis demonstrates an apparent cyst of the anterior horn ⇨. However, note the loss of the body of the caudate nucleus ⇨ in this child with a paraventricular volume loss following neonatal ischemia.* **(Right)** *Axial FLAIR MR in the same child reveals focal atrophy in the body of the caudate nucleus and surrounding white matter gliosis ⇨.*

(Left) *Coronal T2WI MR in a preterm infant with a history of maternal chorioamnionitis reveals large paraventricular cysts ⇨. This pattern is more commonly called extensive cystic periventricular leukomalacia (cPVL).* **(Right)** *Sagittal T2WI MR reveals extensive cystic white matter damage ⇨. Lesions do not communicate with the ventricles, an appearance reported in term and pre-term infants who present with neonatal enterovirus or who have had exposure to maternal chorioamnionitis.*

https://CafePezeshki.IR

Choroid Fissure Cyst

KEY FACTS

TERMINOLOGY

- Extraaxial neuroepithelial cyst arising in or near choroid fissure

IMAGING

- Best imaging clue
  - Cystic lesion of medial temporal lobe, choroid fissure
  - Well-circumscribed round or ovoid on axial, "spindle-shaped" on sagittal MR
- NECT
  - CSF-like along medial temporal lobe, posteromedial to temporal horn
- MR
  - Follows CSF on all sequences
    - FLAIR: Complete suppression
    - DWI: No restricted diffusion
    - T1 C+: No enhancement
  - Sagittal MR shows typical "spindle" shape
  - Coronal T2 shows relationship to choroid fissure

TOP DIFFERENTIAL DIAGNOSES

- Arachnoid cyst
- Epidermoid cyst
- Dermoid cyst
- Cystic tumor

PATHOLOGY

- Likely etiology = maldevelopment of embryonic tela choroidea
- Choroid fissure anatomy
  - Choroid fissure is CSF space between fimbria of hippocampus, diencephalon
  - Shallow fissure that curves posterosuperiorly from anterior temporal lobe to atrium of lateral ventricle

CLINICAL ISSUES

- Incidental benign finding
- Most commonly asymptomatic

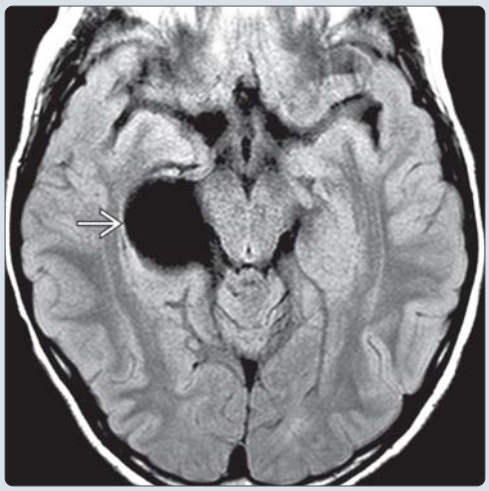

(Left) *Sagittal T1WI MR shows a large choroidal fissure cyst ➡ with mass effect on the adjacent hippocampus. While these are most commonly incidental, there are case reports suggesting an association with complex partial seizures.* **(Right)** *Axial FLAIR MR in the same patient shows the isointense choroid fissure cyst ➡ just posterior to the uncus. The cyst displaces the temporal horn and distorts the normal hippocampus. Choroid fissure cysts follow CSF on all sequences.*

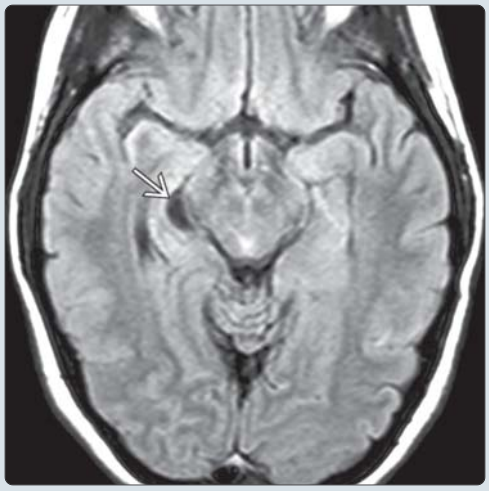

(Left) *Coronal T2WI MR shows a choroid fissure cyst displacing the temporal horn and causing hippocampal and parahippocampal gyrus flattening and distortion ➡.* **(Right)** *Axial FLAIR MR shows an incidental choroid fissure cyst ➡, medial to the temporal horn, in a young adult with headaches. These benign cysts follow CSF signal intensity on all sequences, including DWI, and do not enhance. These cysts usually require no treatment unless associated with medically refractory epilepsy.*

https://CafePezeshki.IR

KEY FACTS

TERMINOLOGY

- Synonyms: Hippocampal remnant cyst, hippocampal sulcal cavities
- Cyst or string of cysts along residual cavity of primitive hippocampal sulcus

IMAGING

- String of cysts along lateral margin of hippocampus
- Cysts follow CSF signal on all MR sequences
  - T2: Hyperintense
  - FLAIR: Complete suppression
  - T1WI C+: No enhancement

TOP DIFFERENTIAL DIAGNOSES

- Mesial temporal sclerosis
- Choroid fissure cyst
- Arachnoid cyst
- DNET

PATHOLOGY

- Represent partially unfused hippocampal sulcus
- Embryology
  - Primitive hippocampal fissure is formed as cornu ammonis and dentate gyrus fold on each other to form cleft
  - Cornu ammonis and dentate gyrus then fuse, leaving shallow hippocampal sulcus
  - Defects in this fusion cause remnant cysts within primitive sulcus

CLINICAL ISSUES

- Incidental finding, not associated with pathology
- Often observed on high-resolution imaging for evaluation of seizure patients (10-15%)
- Have been noted to enlarge with temporal lobe atrophy in Alzheimer disease

(Left) *Axial graphic of the normal temporal lobe shows a string of cysts within the lateral hippocampus, along the residual cavity of the primitive hippocampal sulcus ⇨, representing hippocampal sulcus remnant cysts. These incidental findings have a characteristic appearance.* **(Right)** *Axial T2WI in an asymptomatic patient shows prominent hippocampal sulcus remnants ⇨ in both medial temporal lobes.*

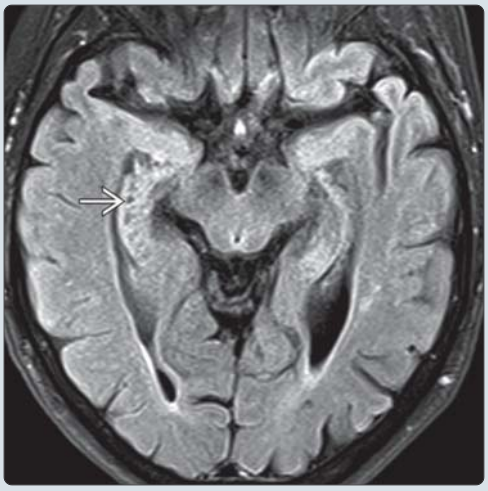

(Left) *Axial T2WI MR shows small hyperintense cysts in the hippocampus ⇨. These unfused remnants of the embryonic hippocampal sulcus present as CSF-like cysts, appearing as a "string of beads" coursing through the hippocampus.* **(Right)** *Axial FLAIR MR in the same patient shows complete suppression of the hippocampal sulcus remnant cysts ⇨. The "string of beads" appearance is typical of these common normal variants. They have been found to enlarge in patients with temporal lobe atrophy.*

https://CafePezeshki.IR

KEY FACTS

TERMINOLOGY

- Pial-lined interstitial fluid (ISF) -filled structures
  - Accompany penetrating arteries
  - Do not communicate with subarachnoid space

IMAGING

- Clusters of variable-sized, well-delineated nonenhancing cysts
- PVSs occur in all locations, at all ages; easily seen in most patients on 3T imaging
- Most common site for normal PVSs = basal ganglia (clustered around anterior commissure)
  - Midbrain, thalami
  - Deep white matter (including corpus callosum, subinsular cortex, extreme capsule)
  - Almost never involve cortex (PVSs expand within subcortical white matter)
- PVSs usually 5 mm or less
  - Occasionally expand, attain large size
  - Most common location for expanded ("giant" or "tumefactive") PVSs = midbrain
  - May cause mass effect, obstructive hydrocephalus
- Isodense/isointense with CSF

TOP DIFFERENTIAL DIAGNOSES

- Lacunar infarcts
- Cystic neoplasm (e.g., DNET, cystic astrocytoma)
- Infectious/inflammatory cysts

CLINICAL ISSUES

- Should not be mistaken for serious disease
- Usually remain stable in size over years

DIAGNOSTIC CHECKLIST

- Prominent, but normal, PVSs are identified in nearly all patients, in virtually every location at 3T imaging

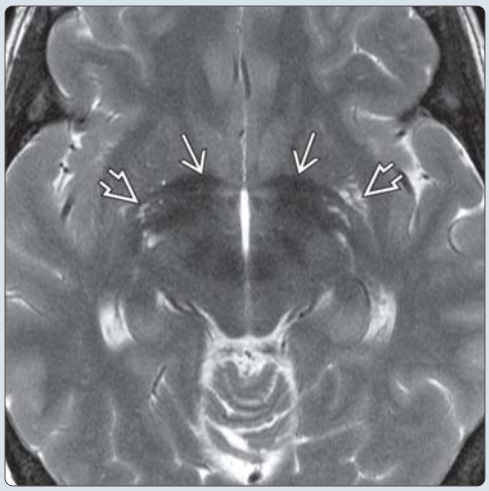

(Left) *Coronal graphic shows normal perivascular spaces (PVSs) as they accompany penetrating arteries into the basal ganglia and subcortical white matter. Normal PVSs cluster around the anterior commissure but occur in all areas.* **(Right)** *Axial T2WI 3T MR with thin sections shows multiple small perivascular spaces ➔ clustered around the anterior commissure ➔ in the inferior 1/3 of the basal ganglia. These are normal findings.*

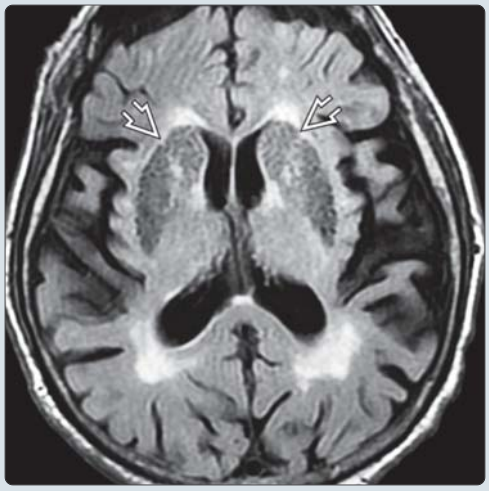

(Left) *Axial T2WI in an 88-year-old female with mild cognitive decline shows innumerable tiny CSF-like cysts in both basal ganglia ➔.* **(Right)** *Axial FLAIR in the same patient shows almost all the basal ganglia cysts ➔ suppress, indicating they are filled with fluid similar to CSF. The symmetry of the cysts and absence of FLAIR hyperintensity indicate these are enlarged perivascular spaces, sometimes called "état criblé" (cribriform state), and not lacunar infarcts.*

https://CafePezeshki.IR

TERMINOLOGY

Abbreviations

- Perivascular spaces (PVSs)

Synonyms

- Virchow-Robin spaces

Definitions

- Pial-lined interstitial fluid (ISF) -filled structures that accompany penetrating arteries but do not communicate directly with subarachnoid space

IMAGING

General Features

- Best diagnostic clue
  - Clusters of variable-sized fluid-filled spaces resembling CSF
    - Surround/accompany penetrating arteries
    - Found in virtually all locations, in patients of all ages
- Location
  - Most common site for normal PVSs = basal ganglia (clustered around anterior commissure)
  - Other common locations
    - Midbrain/thalami
    - Deep white matter
    - Subinsular cortex, extreme capsule
  - Less common sites
    - Dentate nuclei
    - Corpus callosum, cingulate gyrus
  - Most common location for expanded ("giant" or "tumefactive") PVSs = midbrain
    - Can be found almost anywhere
    - Almost never involve cortex (PVSs expand within subcortical white matter)
- Size
  - PVSs usually 5 mm or less
    - Occasionally expand, attain large size (up to several cm)
    - May cause focal mass effect, hydrocephalus
    - Widespread dilatation of PVSs may look very bizarre
- Morphology
  - Clusters of well-demarcated, variable-sized parenchymal cysts
  - Multiple > solitary cysts

CT Findings

- NECT
  - Clusters of round/ovoid/linear/punctate cyst-like lesions
    - Low density (attenuation = CSF)
    - No Ca++
- CECT
  - Do not enhance

MR Findings

- T1WI
  - Multiple well-delineated cysts isointense with CSF
  - Focal mass effect common
    - Expand overlying gyri
    - Thalamomesencephalic enlarged PVSs may compress aqueduct/3rd ventricle, cause hydrocephalus
- T2WI
  - Appear isointense with CSF
    - Signal intensity within PVSs actually measures slightly < CSF
  - No edema in adjacent brain; may have ↑ SI
- PD/intermediate
  - Isointense with CSF
- FLAIR
  - Suppress completely
  - 25% have minimal increased signal in brain surrounding enlarged PVSs
- T2* GRE
  - No "blooming"
- DWI
  - No restricted diffusion
- T1WI C+
  - No enhancement
  - ± visualization of penetrating arteries with contrast
- MRS
  - Spectra in adjacent brain typically normal

Imaging Recommendations

- Best imaging tool
  - Routine MR + FLAIR, DWI
- Protocol advice
  - Contrast optional

DIFFERENTIAL DIAGNOSIS

Lacunar Infarcts

- Older patients
- Common in basal ganglia, white matter
- Adjacent parenchymal hyperintensity

Cystic Neoplasm

- Usually in pons, cerebellum, thalamus/hypothalamus
- Single > multiple cysts
- Signal not quite like CSF
- Parenchymal signal abnormalities common
- May enhance

Infectious/Inflammatory Cysts

- Neurocysticercosis
  - Cysts often have scolex
  - Most are < 1 cm
  - Can be multiple but do not typically occur in clusters
  - Cyst walls often enhance
  - Surrounding edema often present
- Other parasites
  - Hydatid cysts often unilocular, almost all in children
  - Multilocular parasitic cysts typically enhance, mimic neoplasm more than PVSs

PATHOLOGY

General Features

- Etiology
  - Theory: ISF accumulates between penetrating vessel, pia
  - Egress of ISF blocked, causing cystic enlargement of PVS
    - Enlarged cystic-appearing spaces
    - Actually contain interstitial fluid, not CSF
- Genetics

https://CafePezeshki.IR

- Usually normal unless PVSs expanded by undegraded mucopolysaccharides (Hurler, Hunter disease)
- PVSs expand in some congenital muscular dystrophies
- Associated abnormalities
  - Hydrocephalus (midbrain expanding PVSs can obstruct aqueduct)
  - "Cysts" caused by enlarged/obstructed PVSs reported with pituitary adenomas, large aneurysms
  - PVSs provide entry site into CNS in inflammatory, neoplastic disorders
    - Transmigration across capillaries, venules into PVSs
    - Progress across glia limitans into parenchyma
  - May be associated with increased risk of microvascular disease

Gross Pathologic & Surgical Features

- Smoothly demarcated, fluid-filled cyst(s)

Microscopic Features

- Single or double layer of invaginated pia
- Pia becomes fenestrated, disappears at capillary level
- PVSs usually very small in cortex, often enlarge in subcortical white matter
- Surrounding brain usually lacks gliosis, amyloid deposition

CLINICAL ISSUES

Presentation

- Most common signs/symptoms
  - Usually normal, discovered incidentally at imaging/autopsy
  - Nonspecific symptoms (e.g., headache)
  - Reported association with increased risk of hypertensive hemorrhages, cerebral small vessel disease
- Clinical profile
  - Patient with nonspecific, nonlocalizing symptoms and bizarre, alarming multicystic-appearing brain mass initially diagnosed as "cystic neoplasm"

Demographics

- Age
  - Occur in all locations, at all ages
    - Easily seen on 3T imaging
  - Present in 25-30% of children (benign normal variant)
  - Enlarged PVSs
    - Mean age = mid 40s
    - May occur in children
- Gender
  - Giant PVSs: M:F = 1.8:1
- Epidemiology
  - Common nonneoplastic brain "cyst"
  - Common cause of multifocal hyperintensities on T2WI

Natural History & Prognosis

- Usually remain stable in size over many years
- Rarely continue to expand
- Rare spontaneous regression of "tumefactive" PVS reported

Treatment

- "Leave me alone" lesion that should not be mistaken for serious disease
- Shunt ventricles if midbrain lesions cause obstructive hydrocephalus
  - Cystoventriculoperitoneal shunt has been reported as alleviating symptoms

DIAGNOSTIC CHECKLIST

Consider

- Could multicystic, nonenhancing mass on MR or CT be cluster of enlarged PVSs

Image Interpretation Pearls

- Prominent, but normal, PVSs are identified in nearly all patients, in virtually every location at 3T imaging

SELECTED REFERENCES

1. Branch BC et al: Posterior fossa giant tumefactive perivascular spaces: 8-year follow-up in an adolescent. Surg Neurol Int. 6:2, 2015
2. Kilsdonk I et al: Perivascular spaces in MS patients at 7 Tesla MRI: A marker of neurodegeneration? Mult Scler. 21(2):155-62, 2015
3. Lochhead JJ et al: Rapid transport within cerebral perivascular spaces underlies widespread tracer distribution in the brain after intranasal administration. J Cereb Blood Flow Metab. 35(3):371-81, 2015
4. Ramirez J et al: Visible Virchow-Robin spaces on magnetic resonance imaging of Alzheimer's disease patients and normal elderly from the Sunnybrook Dementia Study. J Alzheimers Dis. 43(2):415-24, 2015
5. Bouvy WH et al: Visualization of perivascular spaces and perforating arteries with 7 T magnetic resonance imaging. Invest Radiol. 49(5):307-13, 2014
6. Eluvathingal Muttikkal TJ et al: Spontaneous regression and recurrence of a tumefactive perivascular space. Neuroradiol J. 27(2):195-202, 2014
7. Hawkes CA et al: Failure of perivascular drainage of β-amyloid in cerebral amyloid angiopathy. Brain Pathol. 24(4):396-403, 2014
8. Hladky SB et al: Mechanisms of fluid movement into, through and out of the brain: evaluation of the evidence. Fluids Barriers CNS. 11(1):26, 2014
9. Roelz R et al: Giant perivascular spaces causing hemiparesis successfully treated by cystoventriculoperitoneal shunt. Br J Neurosurg. 1-3, 2014
10. Saylisoy S et al: Is there a connection between perivascular space and subarachnoid space? J Comput Assist Tomogr. 38(1):33-5, 2014
11. Yakushiji Y et al: Topography and associations of perivascular spaces in healthy adults: the Kashima scan study. Neurology. 83(23):2116-23, 2014
12. Martinez-Ramirez S et al: Topography of dilated perivascular spaces in subjects from a memory clinic cohort. Neurology. 80(17):1551-6, 2013
13. Stephens T et al: Giant tumefactive perivascular spaces. J Neurol Sci. 266(1-2):171-3, 2008
14. Salzman KL et al: Giant tumefactive perivascular spaces. AJNR Am J Neuroradiol. 26(2):298-305, 2005

https://CafePezeshki.IR

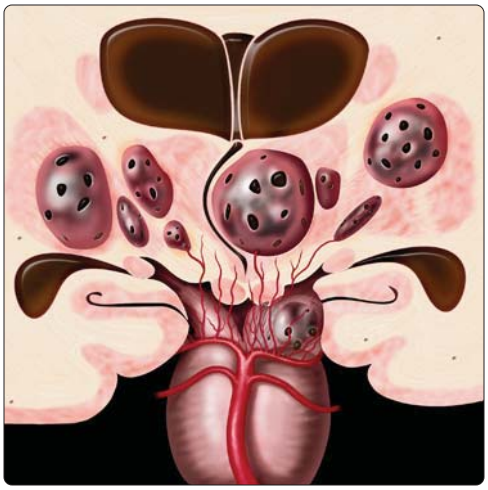

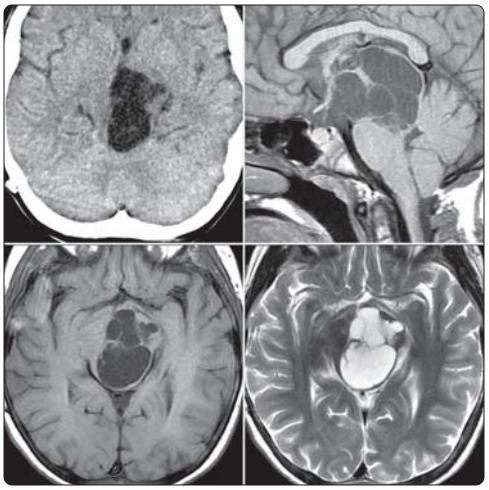

(Left) *Coronal graphic shows enlarged perivascular spaces in the midbrain and thalami causing mass effect on the 3rd ventricle and aqueduct with resulting hydrocephalus.* **(Right)** *Composite imaging in a 15-year-old boy with longstanding shunted hydrocephalus caused by "cystic brain mass." These are multiple enlarged PVSs that expand the midbrain, causing hydrocephalus. The PVSs are of variable size and follow CSF on all sequences.*

(Left) *Axial T2WI in a 69-year-old male with moderate dementia and no focal neurologic findings shows multiple bilateral cystic lesions in the white matter of both cerebral hemispheres.* **(Right)** *More cephalad scan in the same patient shows the gyri are markedly expanded by the cysts. The overlying cortex is spared. The findings are most consistent with giant "tumefactive" perivascular spaces. (Courtesy M. Warmuth-Metz, MD.)*

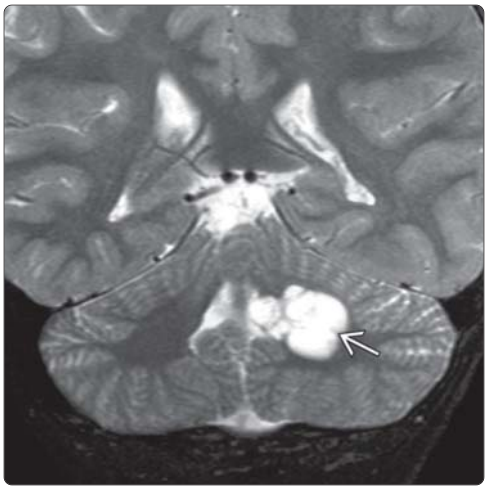

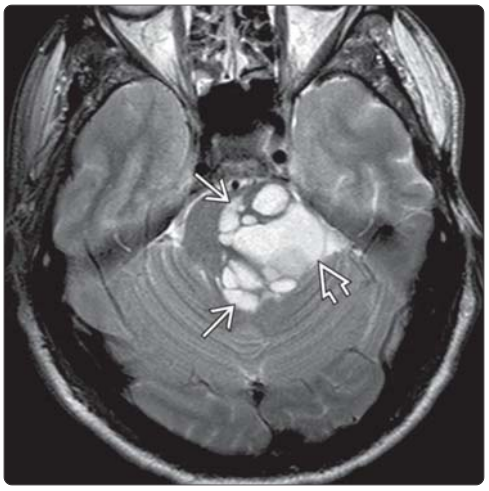

(Left) *This coronal T2WI MR of a child with headaches who was referred for overread with a diagnosis of "cystic brain tumor" shows dilated PVSs in the left dentate nucleus ➔.* **(Right)** *Axial T2WI MR in a 27 year old with left-sided facial numbness and sensorineural hearing loss shows variable-sized cysts ➔ with a large cyst ➔ expanding into the CPA and probably compressing the 7th and 8th cranial nerves. No enhancement was seen on T1WI C+ MR.*

https://CafePezeshki.IR

KEY FACTS

TERMINOLOGY

- Nonneoplastic intrapineal glial-lined cyst

IMAGING

- CT
  - Sharply demarcated, smooth cyst behind 3rd ventricle
  - 80% < 10 mm (can be large; reported up to 4.5 cm)
  - Fluid iso-/slightly hyperdense to CSF
  - 25% Ca++ in cyst wall
- MR
  - Slightly hyperintense to CSF (55-60%) on most sequences
  - Isointense (40%)
  - 1-2% hemorrhage (heterogeneous signal intensity)
  - Does not suppress on FLAIR

TOP DIFFERENTIAL DIAGNOSES

- Normal pineal gland
- Pineocytoma
- Epidermoid cyst
- Arachnoid cyst
- Pineal parenchymal tumor of intermediate differentiation

CLINICAL ISSUES

- Vast majority clinically silent, discovered incidentally
  - Occur at all ages
  - Found in 1-5% of normal MRs
  - May spontaneously resolve in children
- Headache (less common)
- "Pineal apoplexy" with intracystic hemorrhage (rare)
  - ± acute hydrocephalus, sudden death (very rare)

DIAGNOSTIC CHECKLIST

- Cannot distinguish benign PC from neoplasm (pineocytoma) on basis of imaging studies alone
  - Both may remain stable for many years
- Heterogeneous, nodular, or ring-like enhancing pineal mass may be benign cyst, not neoplasm

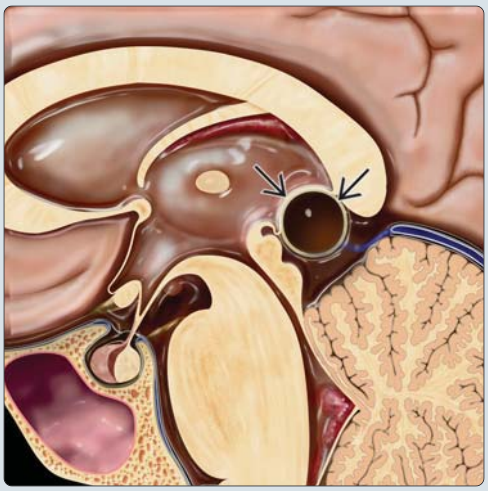

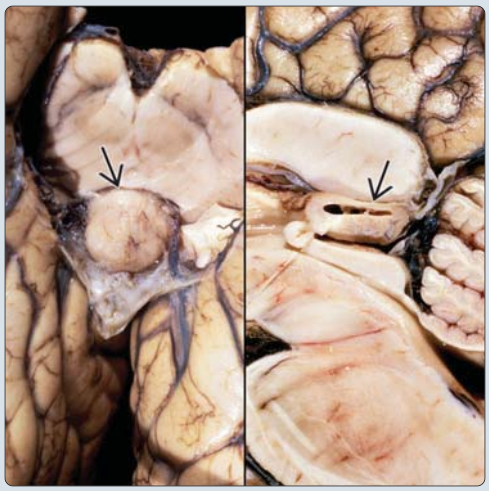

(Left) *Sagittal graphic shows a small cystic lesion within the pineal gland. Small benign pineal cysts (PCs) are often found incidentally at autopsy or imaging.* **(Right)** *Submentovertex (left) and sagittal midline section (right) show a benign, nonneoplastic pineal gland cyst found incidentally at autopsy. The cyst is very well delineated and has a moderately thick wall surrounding the cystic cavity. (Courtesy E. Tessa Hedley-Whyte, MD.)*

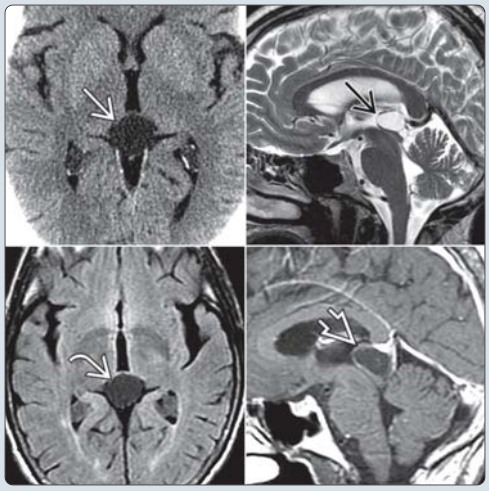

(Left) *Axial NECT scan in a patient with chronic nonspecific headaches and normal neurologic examination shows a 16 mm cystic pineal gland with rim calcifications. The lesion is stable over several years and is a presumed nonneoplastic pineal cyst.* **(Right)** *Collage of images shows a 20 mm pineal cyst on NECT that is slightly hyperdense to CSF in the adjacent 3rd ventricle. The lesion is hyperintense on T2WI and FLAIR. A thin enhancing rim is present on T1C+. This is a surgically proven pineal cyst.*

https://CafePezeshki.IR

TERMINOLOGY

Abbreviations

- Pineal cyst (PC)

Synonyms

- Glial cyst of pineal gland

Definitions

- Nonneoplastic intrapineal glial-lined cyst

IMAGING

General Features

- Best diagnostic clue
  - Fluid-filled pineal region mass
- Location
  - Above, clearly distinct from tectum
  - Below velum interpositum, internal cerebral veins (ICVs)
- Size
  - Most are small (< 1 cm)
  - Occasionally up to 2 cm or more
- Morphology
  - Round/ovoid, relatively thin-walled cyst
    - 95% minimal/no compression of tectum, aqueduct
      - May be multilocular
    - 5% flatten tectum, occasionally compress aqueduct
    - Variable hydrocephalus (with large cysts or cyst apoplexy)
      - Enlarged 3rd, lateral ventricles
      - Normal 4th ventricle

CT Findings

- NECT
  - Sharply demarcated, smooth cyst behind 3rd ventricle
    - Fluid iso-/slightly hyperdense to CSF
    - Ca++ in cyst wall (25%)
    - Rare: Hyperdense cyst
      - Acute hemorrhage ("pineal apoplexy")
- CECT
  - Rim or nodular enhancement

MR Findings

- T1WI
  - Slightly hyperintense to CSF (55-60%)
  - Isointense (40%)
  - Hemorrhagic (heterogeneous signal intensity) (1-2%)
- T2WI
  - Iso-/slightly hyperintense to CSF
  - Multicystic/septated (20-25%)
- PD/intermediate
  - Hyperintense to CSF (85-90%)
- FLAIR
  - Does not suppress
  - Moderately hyperintense
- T2* GRE
  - Usually normal
  - Uncommon: Blooming (old or recent hemorrhage)
- DWI
  - Typically shows no restriction
- T1WI C+
  - Pineal gland always enhances (no blood-brain barrier)
    - Most common: Thin rim (≤ 2 mm)
      - Can be partial, eccentric, incomplete
    - Less common: Nodular, irregular enhancement
    - Cystic areas will always fill in on delayed scans, can resemble solid tumor
      - Differentiate from tumor by doing sagittal MR immediately after contrast administration
- MRV
  - ICVs may be elevated by large lesions
- MRS
  - Neuronal markers absent

Angiographic Findings

- Arterial phase almost always normal
- Venous phase
  - May show elevation, displacement of ICVs if large PC present
  - Thalamostriate veins splayed, bowed if hydrocephalus present

Imaging Recommendations

- Best imaging tool
  - MR ± contrast
    - DWI, T2*, MRS may be helpful
- Protocol advice
  - Use thin sections (≤ 3 mm) for detecting and defining lesions in this anatomically complex region

DIFFERENTIAL DIAGNOSIS

Normal Pineal Gland

- Can be cystic
- 3 anatomic appearances on contrast-enhanced imaging
  - Nodule (52%)
  - Crescent (26%)
  - Ring-like (22%)

Pineocytoma

- Usually solid or partially solid/cystic
- Purely cystic pineocytoma much less common
  - May be indistinguishable on imaging studies
  - Require histology for definitive diagnosis
- Both pineal cyst and pineocytoma may remain stable for many years without significant change on serial imaging

Epidermoid Cyst

- Quadrigeminal cistern relatively rare location
- "Cauliflower" configuration
- Mild/moderate restriction on DWI

Arachnoid Cyst

- Displaces normal gland; no Ca++, enhancement
- Follows CSF attenuation, signal intensity

Pineal Parenchymal Tumor of Intermediate Differentiation

- 20% of pineal parenchymal tumors
- Usually larger, more heterogeneous than pineal cyst or pineocytoma
  - Extension into adjacent structures common
  - CSF dissemination not uncommon

https://CafePezeshki.IR

PATHOLOGY

General Features

- Etiology
  - Etiology/pathogenesis: 3 major theories
    - Enlargement of embryonic pineal cavity
    - Ischemic glial degeneration ± hemorrhagic expansion
    - Small preexisting cysts enlarge with hormonal influences
- Genetics
  - None known
- Associated abnormalities
  - Hydrocephalus (uncommon)
  - Embryology
    - Primitive pineal diverticulum divides into pineal recess, cavum pineal
    - Cavum pineal usually obliterated by glial fibers
    - Incomplete obliteration may leave residual cavity

Gross Pathologic & Surgical Features

- Smooth, soft, tan to yellow cyst wall
  - Cavity can be uni- or multilocular
  - Fluid contents vary
    - Clear yellow (most common) to hemorrhagic
- 80% < 10 mm
- Can be large (reported up to 4.5 cm)

Microscopic Features

- Delicate (usually incomplete) outer leptomeningeal layer
- Middle layer of attenuated pineal parenchyma
  - ± Ca++
- Inner layer of dense fibrillar glial tissue with
  - Variable granular bodies
  - ± hemosiderin-laden macrophages
- Compare with pineocytoma
  - Pseudolobular arrangement of small, round cells with pleomorphic nuclei
  - "Pinocytic" rosettes
  - Neuronal differentiation
    - Neuron-specific enolase, synaptophysin positive cells

CLINICAL ISSUES

Presentation

- Most common signs/symptoms
  - Vast majority clinically silent
    - Discovered incidentally at imaging/autopsy
  - Large cysts (> 1 cm) rarely become symptomatic
    - 50% headache (aqueduct compression, hydrocephalus)
    - 10% Parinaud syndrome (tectal compression)
    - Sx usually associated with hemorrhage
  - Rare: "Pineal apoplexy"
    - Severe headache (can be "thunderclap," mimic aneurysmal subarachnoid hemorrhage)
    - Intracystic hemorrhage, acute hydrocephalus, sudden death
- Clinical profile
  - Young female with nonfocal headache

Demographics

- Age
  - Can occur at **any** age
    - Older adults > children
  - Incidence among women between 21-30 years significantly higher than any other group
    - Incidence in women decreases with age
    - No change in males
- Gender
  - F:M = 3:1
- Ethnicity
  - None known
- Epidemiology
  - 1-5% of normal MRs
    - 2% in children, young adults
  - 25-40% of microscopic cysts within pineal gland found at autopsy

Natural History & Prognosis

- Size generally remains unchanged in males
- Cystic expansion of pineal in some females begins in adolescence, decreases with aging
- Rare: Sudden expansion, hemorrhage ("pineal apoplexy")

Treatment

- Usually none
- Atypical/symptomatic lesions may require stereotactic aspiration or biopsy/resection
  - Preferred approach = infratentorial supracerebellar

DIAGNOSTIC CHECKLIST

Consider

- PCs often asymptomatic, incidental MR finding
- MR appearance of PCs varies
  - Uncomplicated cystic mass
  - Mass with hemorrhage, enhancement, or hydrocephalus
- Heterogeneous, nodular, or ring-like enhancing pineal mass **may be benign cyst, not neoplasm**

Image Interpretation Pearls

- Cannot distinguish benign PC from neoplasm (pineocytoma) on basis of imaging studies alone
- Histopathology required for definitive diagnosis
  - May be complicated by tissue fragmentation, cyst collapse, reactive changes in adjacent tissue

SELECTED REFERENCES

1. Kalani MY et al: Pineal cyst resection in the absence of ventriculomegaly or Parinaud's syndrome: clinical outcomes and implications for patient selection. J Neurosurg. 1-5, 2015
2. Westphal M et al: Pineal lesions: a multidisciplinary challenge. Adv Tech Stand Neurosurg. 42:79-102, 2015
3. Berhouma M et al: Update on the management of pineal cysts: Case series and a review of the literature. Neurochirurgie. ePub, 2014
4. Jouvet A et al: Pineal parenchymal tumours and pineal cysts. Neurochirurgie. ePub, 2014
5. Kahilogullari G et al: Pineal cysts in children: case-based update. Childs Nerv Syst. 29(5):753-60, 2013
6. Choy W et al: Pineal cyst: a review of clinical and radiological features. Neurosurg Clin N Am. 22(3):341-51, vii, 2011

https://CafePezeshki.IR

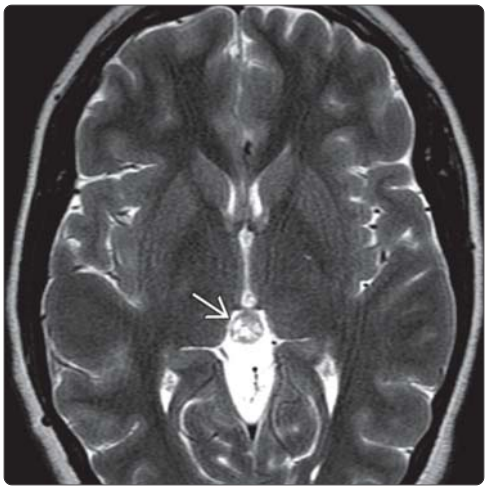

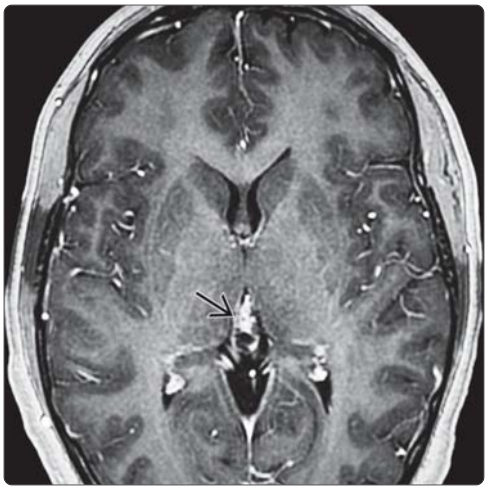

(Left) *Axial T2WI in a 52-year-old female with dizziness and double vision, but normal neurologic examination, shows a normal-sized, but multicystic-appearing, pineal gland* ➡. **(Right)** *T1C+FS in the same patient shows rim stippled enhancement of the pineal gland* ⇨. *Multicystic pineal glands are a normal variant.*

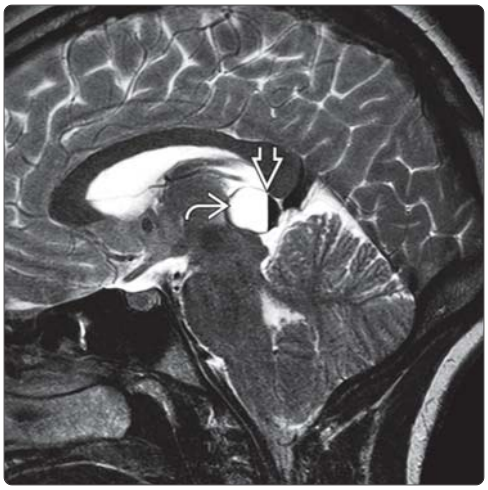

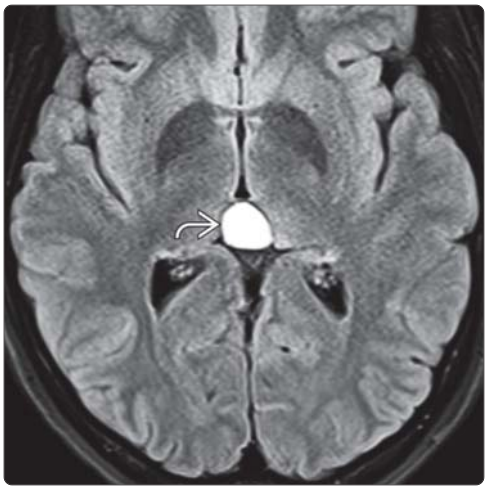

(Left) *Sagittal T2FS MR in a 17-year-old female with sudden onset of severe headache shows a cystic pineal gland* ⇨ *with a blood-fluid level* ➡. **(Right)** *Axial FLAIR in the same patient shows the fluid-filled pineal cyst* ⇨ *does not suppress. There is no evidence for obstructive hydrocephalus.*

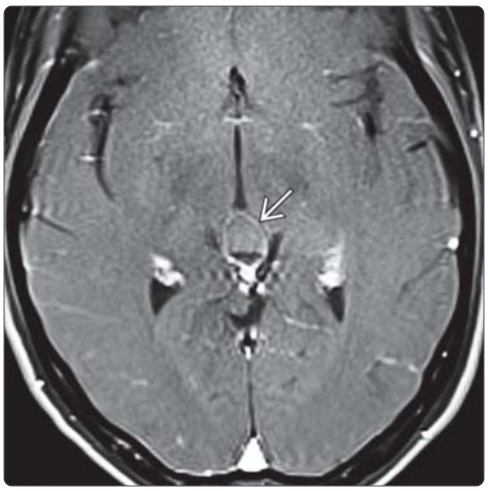

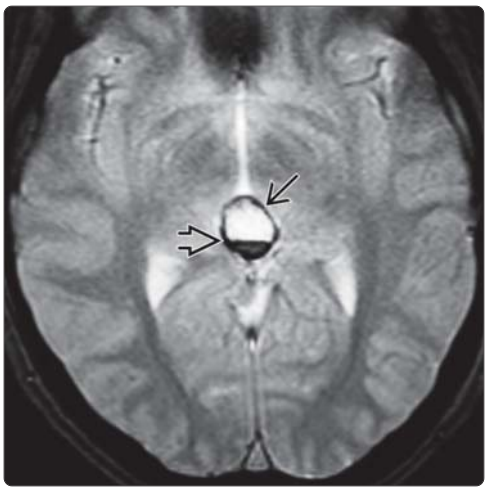

(Left) *T1C+FS in the same patient shows a thin rim of enhancement in the cyst wall* ➡. **(Right)** *Axial T2* GRE scan shows blooming hemorrhage in the cyst wall* ⇨ *and a dependent blood-fluid level* ⇨ *in the cyst. Pineal cyst apoplexy is rare but can cause acute neurologic symptoms.*

https://CafePezeshki.IR

KEY FACTS

TERMINOLOGY

- Nonneoplastic, noninflammatory cysts
  - Contained within choroid plexus
  - Lined by compressed connective tissue

IMAGING

- General
  - Typically in atria of lateral ventricle
  - Usually small (2-8 mm)
  - Rare: Large cysts (> 2 cm)
  - Usually multiple, often bilateral
- CT
  - Isodense or slightly hyperdense to CSF
  - Irregular, peripheral Ca++ common in adults
- MR
  - Isointense or slightly hyperintense compared to CSF on T1WI
  - 2/3 isointense, 1/3 hypointense on FLAIR
  - 60-80% "bright" on DWI
  - Enhancement (ring, nodular, solid) varies from none to strong

TOP DIFFERENTIAL DIAGNOSES

- Ependymal cyst
- Neurocysticercosis
- Epidermoid cyst
- Choroid plexus papilloma (CPP)
  - Purely cystic CPP very rare

CLINICAL ISSUES

- Found at both ends of age spectrum
  - Common in fetus, infants, older adults
  - Less common in children, young adults
- Clinically silent, discovered incidentally
- Associations: Aicardi syndrome, trisomy 18

DIAGNOSTIC CHECKLIST

- Most common choroid plexus mass in adults = CPC

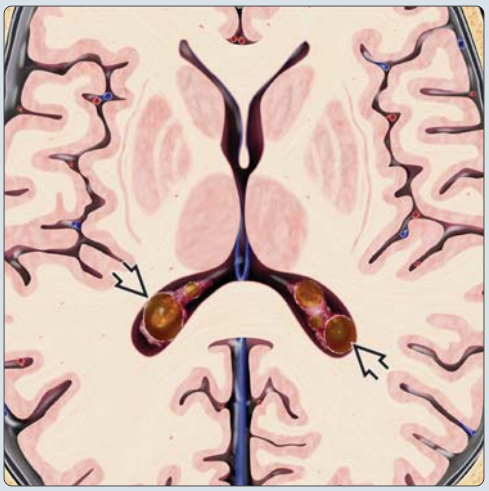

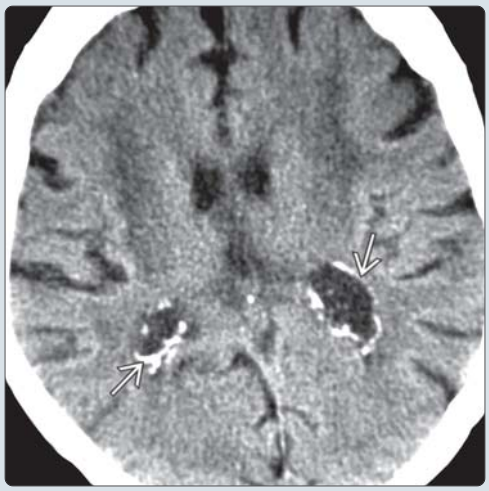

(Left) *Axial graphic shows multiple cystic masses in the choroid plexus glomi ⇨, often seen incidentally on scans of middle-aged and older adults. Most are degenerative xanthogranulomas.* **(Right)** *Axial NECT obtained in an elderly adult with minor head trauma and a normal neurological examination shows dense peripheral calcifications ➡ around cystic masses in the atria of both lateral ventricles. This was an incidental finding with no clinical significance.*

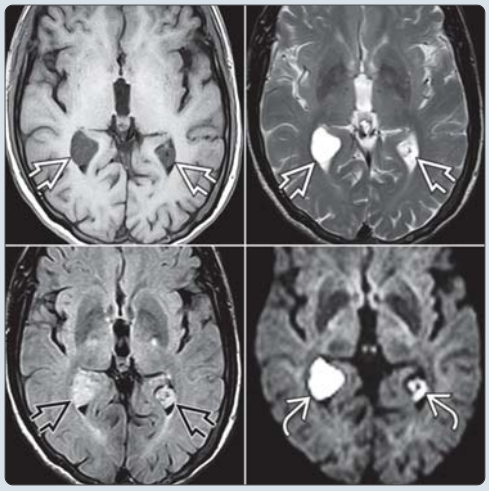

(Left) *Axial T1WI C+ FS MR in a 52-year-old man with headaches and no neurological abnormalities shows multiple mixed solid and ring-enhancing cysts in the atria of both lateral ventricles ➡.* **(Right)** *Series of axial MR scans show incidental finding of bilateral choroid plexus cysts in an older patient. Cysts are slightly hyperintense to CSF on T1- and T2WIs ➡, typically do not suppress on FLAIR ⇨ and frequently appear very bright on DWI ➡.*

https://CafePezeshki.IR

TERMINOLOGY

Abbreviations

- Choroid plexus cyst (CPC)
- Choroid plexus xanthogranuloma (CPX)

Definitions

- Nonneoplastic, noninflammatory cysts of choroid plexus
  - Lined by compressed connective tissue
  - Adult: CPC is common incidental finding on imaging studies in older patients (~ 40% prevalence)
  - Fetus: CPCs seen in 1% of 2nd trimester pregnancies

IMAGING

General Features

- Best diagnostic clue
  - Older patient with "bright" cysts in choroid plexuses on T2WI
  - Fetus or newborn with large (> 2 mm) choroid plexus cyst(s) on US
- Location
  - Most common: Atria of lateral ventricles
    - Attached to or within choroid plexus
    - > 2/3 bilateral
  - Less common: 3rd and 4th ventricles
- Size
  - Variable
    - Usually small (2-8 mm)
    - Often multiple
    - Rare: Large cysts (> 2 cm)
- Morphology
  - Cystic or nodular/partially cystic mass(es) in choroid plexus glomi

CT Findings

- NECT
  - Iso-/slightly hyperdense (due to presence of increased protein) to CSF
  - Irregular, peripheral Ca++ in majority of adult cases
- CECT
  - Varies from none to rim of solid enhancement

MR Findings

- T1WI
  - Isointense or slightly hyperintense (due to presence of increased protein) compared to CSF
- T2WI
  - Hyperintense compared to CSF
- PD/intermediate
  - Hyperintense
- FLAIR
  - 2/3 isointense, 1/3 hypointense
- T2* GRE
  - Foci of "blooming" common
    - Ca++ (intracystic hemorrhage rare)
- DWI
  - 60-80% show high signal on DWI
- T1WI C+
  - Enhancement varies from none to strong
  - Variable pattern (solid, ring, nodular)
  - Delayed scans may show filling in of contrast within cysts

Ultrasonographic Findings

- Grayscale ultrasound
  - Prenatal US
    - Cyst > 2 mm surrounded by echogenic choroid
    - In absence of other abnormalities, low risk for chromosomal abnormalities

Imaging Recommendations

- Best imaging tool
  - Adults: MR ± contrast
  - Fetus, newborn
    - Antenatal: Maternal US or MR
    - Postnatal: US of infant with anterior, posterior, mastoid fontanelles as acoustic windows
- Protocol advice
  - MR with contrast, FLAIR, DWI
  - US transverse view of lateral ventricle at atrial level

DIFFERENTIAL DIAGNOSIS

Ependymal Cyst

- Does not enhance
- Usually unilateral
- Attenuation, signal more like CSF
- Immunohistochemistry differentiates

Neurocysticercosis (NCC)

- Multiple cysts common (subarachnoid space, parenchyma ventricles)
- Not associated with choroid plexus
- Look for scolex, other signs of NCC (e.g., parenchymal Ca++)
- May be migratory

Epidermoid Cyst

- Intraventricular location rare (4th > > lateral ventricle)
- "Cauliflower," insinuating pattern

Choroid Plexus Papilloma (CPP)

- Children < 5 years
- Strong, relatively uniform enhancement
- Purely cystic CPP very rare

Villous Hyperplasia of Choroid Plexus

- Very rare
- Often overproduces CSF
- Causes hydrocephalus

Ultrasound Pseudolesion

- Tiny anechoic areas in fetal choroid are normal, not CPC
- Normal, fluid-filled atria can be confused with CPC on transverse view
- "Split" or "truncated" choroid can mimic CPC

Neoplasm

- Meningioma (usually solid)
- Metastasis (rarely cystic)
- Cystic astrocytoma (rare in older patients)

Sturge-Weber Syndrome

- Enlarged, angiomatous, choroid plexus ipsilateral to malformation

https://CafePezeshki.IR

Choroid Plexus Infarct

- Usually seen in choroid artery infarct
- May cause ↑ intraventricular signal on DWI

Choroid Plexus Cavernoma

- Rare mass most common in adults
- Mention when MR shows marked susceptibility

PATHOLOGY

General Features

- Etiology
  - CPCs
    - Lipid from desquamating, degenerating choroid epithelium accumulates in choroid plexus
    - Lipid provokes xanthomatous response
- Genetics
  - Large, fetal choroid plexus cysts associated with trisomy 21 or 18 in only 6% of cases
  - Presence of additional malformations increases risk factors for aneuploidy
- Associated abnormalities
  - Fetal CPC
    - Trisomy 18 (mildly increased risk < 2x baseline risk)
    - Trisomy 21 (only if other markers present)
  - Adult CPC: May cause obstructive hydrocephalus (rare)
  - Aicardi syndrome
    - Patients diagnosed by presence of retinal lacunae, severe corpus callosum hypo-/agenesis, polymicrogyria, heterotopia
    - Usually associated with choroid plexus papillomas, but may occur with choroid plexus cysts

Gross Pathologic & Surgical Features

- CPC commonly found at autopsy in middle-aged, older adults
  - Nodular, partly cystic, yellowish-gray masses in choroid plexus glomus
  - Contents often gelatinous, highly proteinaceous
  - Rare: Hemorrhage

Microscopic Features

- Neuroepithelial microcysts
- Trapped choroid plexus epithelium often associated
- Cysts contain nests of foamy, lipid-laden histiocytes
- Foreign body giant cells
- Chronic inflammatory infiltrates (lymphocytes, plasma cells)
- Cholesterol clefts, hemosiderin
- Peripheral psammomatous Ca++ common
- Immunohistochemistry positive for prealbumin, cytokeratins, GFAP, EMA, S100

CLINICAL ISSUES

Presentation

- Most common signs/symptoms
  - Adult CPC
    - Typical: Clinically silent, discovered incidentally at autopsy/imaging
    - Rare: Headache

Demographics

- Age
  - Found at both ends of age spectrum
    - Adult CPC: Prevalence increases with age
    - Fetal CPC: Prevalence decreases with age
- Gender
  - No known prevalence
- Ethnicity
  - No known prevalence
- Epidemiology
  - Most common type of neuroepithelial cyst
    - 1% of all pregnancies on routine US
    - 50% of fetuses with T18
    - Small, asymptomatic CPCs found incidentally in more than 1/3 of all autopsied adults

Natural History & Prognosis

- Fetal CPCs
  - Transient finding; typically resolve in 3rd trimester regardless of whether isolated or with associated anomalies
  - CPC + minor markers = 20% risk for chromosome abnormality
  - CPC + major markers = 50% risk for chromosome abnormality
- Adult CPCs
  - Usually remain asymptomatic, nonprogressive

Treatment

- Adult CPC: Usually none
  - Rare: Shunt for obstructive hydrocephalus
- Fetal CPC
  - In absence of other markers, none
  - With other markers, amniocentesis warranted

DIAGNOSTIC CHECKLIST

Consider

- Amniocentesis with karyotyping if CPCs + other anomalies (e.g., cardiac anomaly, clenched hands with overlapping fingers, clubfeet) present on fetal US

Image Interpretation Pearls

- Benign degenerative cyst (xanthogranuloma): Most common cause of choroid plexus mass in adults

SELECTED REFERENCES

1. de Lara D et al: Endoscopic treatment of a third ventricle choroid plexus cyst. Neurosurg Focus. 34(1 Suppl):Video 9, 2013
2. Moreau E et al: Incidental bilateral xanthogranuloma of the lateral ventricles at autopsy–a case report. J Forensic Leg Med. 20(6):647-9, 2013
3. Norton KI et al: Prevalence of choroid plexus cysts in term and near-term infants with congenital heart disease. AJR Am J Roentgenol. 196(3):W326-9, 2011
4. Peltier J et al: [Rare tumors of the lateral ventricle. Review of the literature.] Neurochirurgie. 57(4-6):225-9, 2011
5. Naeini RM et al: Spectrum of choroid plexus lesions in children. AJR Am J Roentgenol. 192(1):32-40, 2009
6. Kinoshita T et al: Clinically silent choroid plexus cyst: evaluation by diffusion-weighted MRI. Neuroradiology. 47(4):251-5, 2005

https://CafePezeshki.IR

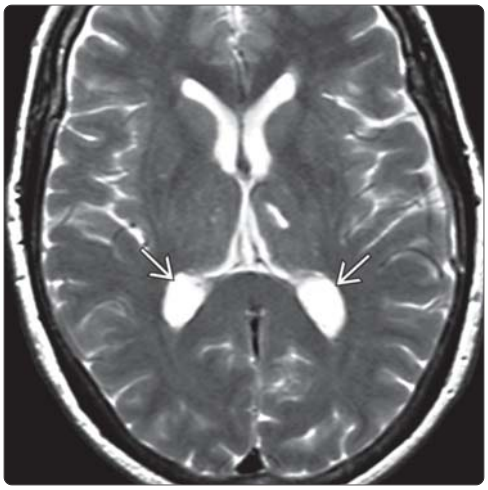

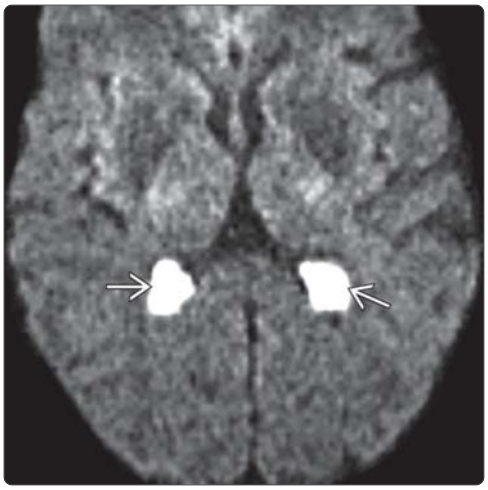

(Left) *Axial T2WI MR in an asymptomatic patient with an old left thalamic infarct shows hyperintense lesions in the atria of both lateral ventricles* ➡ *that are difficult to see because they are isointense with CSF.* **(Right)** *Axial DWI MR shows restriction in the choroid plexus lesions* ➡. *Choroid plexus cysts (CPC) often restrict on diffusion-weighted imaging.*

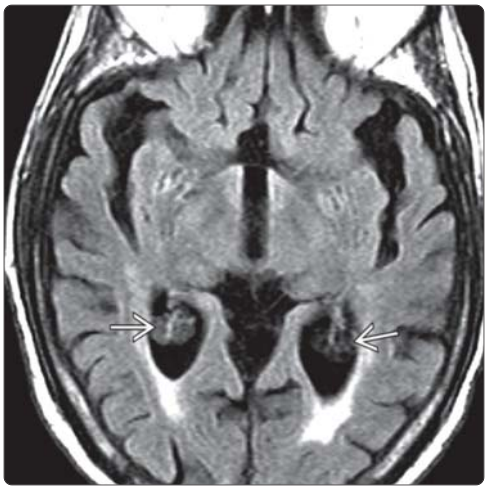

(Left) *Axial FLAIR MR in an elderly, hypertensive patient scanned for memory problems shows diffuse atrophy, especially in the temporal lobes. Periventricular hyperintensity is seen around both atria and occipital horns. Note the intraventricular cysts that seem to be "dangling" from the choroid plexus glomi* ➡. **(Right)** *Coronal T1WI C+ MR in the same patient shows enhancement around the cyst margins* ⇨, *findings typical for choroid plexus cysts.*

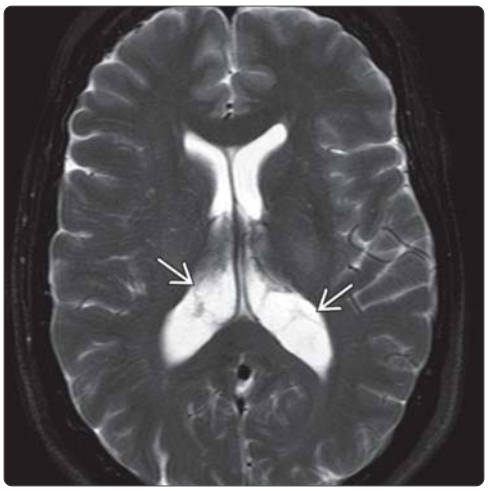

(Left) *Axial T2FS scan in a normal patient shows multiple bilateral choroid plexus cysts* ➡. **(Right)** *Axial T1C+FS scan in the same patient shows the choroid plexus cysts exhibit mixed rim* ➡ *and solid* ➡ *enhancement. Incidental choroid plexus cysts (xanthogranulomas).*

https://CafePezeshki.IR

Ependymal Cyst

KEY FACTS

TERMINOLOGY
- Congenital, benign, ependymal-lined cyst of brain

IMAGING
- Nonenhancing thin-walled cyst
  - CSF density/intensity
- Most common location = intraventricular (lateral; 3rd rare)
  - Less common: Parenchyma, subarachnoid space

TOP DIFFERENTIAL DIAGNOSES
- Asymmetric lateral ventricles (normal variant)
- Choroid plexus cyst
- Arachnoid cyst
- Epidermoid cyst
- Neurenteric cyst
- Porencephalic cyst
- Neurocysticercosis

PATHOLOGY
- Thin-walled cyst filled with clear serous liquid
- Fluid-filled space lined by columnar or cuboidal cells

CLINICAL ISSUES
- Typically asymptomatic
- Headache, seizure, gait disturbance, dementia
- Symptoms related to CSF obstruction/↑ ICP
- Young adults (typically < 40 years old)
- Interval follow-up typically shows no clinical or imaging changes in asymptomatic lesions
- Symptomatic intraventricular cysts treated via neuronavigation-assisted fenestration

DIAGNOSTIC CHECKLIST
- Ependymal cysts may be indistinguishable from other benign intracranial cysts
- Ependymal cysts follow CSF on all MR sequences, including DWI; no enhancement

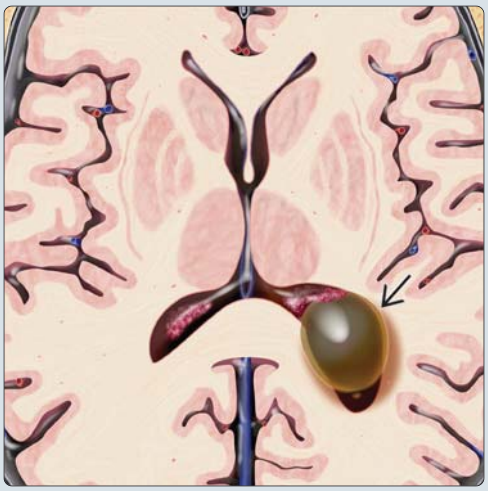

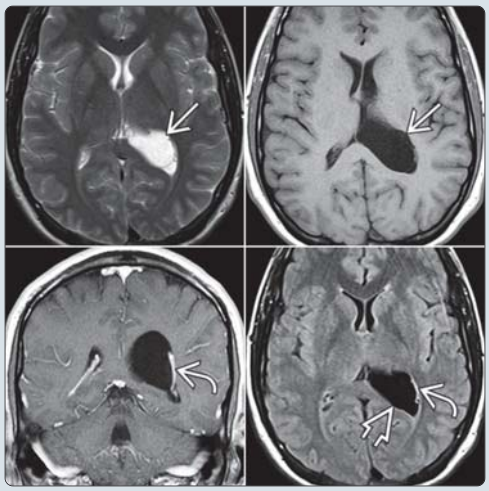

(Left) *Axial graphic depicts a typical ependymal cyst of the lateral ventricle ⇨, seen here as a CSF-containing simple cyst that displaces the choroid plexus around it. Ependymal cysts typically follow CSF signal on all sequences.* **(Right)** *MR scans demonstrate the typical appearance of an ependymal cyst in the atrium of the left lateral ventricle. The cyst ⇨ behaves exactly like CSF on all sequences, suppressing completely on FLAIR ⇨. Note the choroid plexus ⇨ displaced around the cyst. Incidental finding in this asymptomatic patient.*

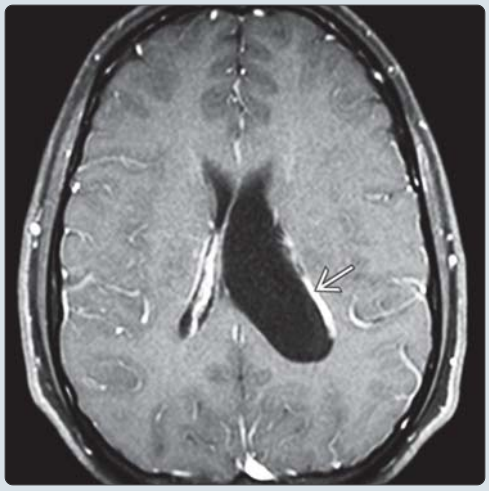

(Left) *NECT in a 22 year old with headaches shows a CSF-like mass in the body of the left lateral ventricle ⇨. The large intraventricular cyst displaces the septum pellucidum across the midline ⇨ and displaces the calcified choroid plexus laterally ⇨.* **(Right)** *T1C+FS in the same patient shows the cyst does not enhance. The enhancing choroid plexus ⇨ is displaced laterally around the cyst. Neuronavigation-assisted endoscopic fenestration of the ependymal cyst was performed.*

https://CafePezeshki.IR

TERMINOLOGY

Abbreviations

- Ependymal cyst (EC)

Synonyms

- Neuroepithelial cyst, glioependymal cyst

Definitions

- Congenital, benign, ependymal-lined cyst of brain

IMAGING

General Features

- Best diagnostic clue
  - Nonenhancing, thin-walled, CSF density/intensity
- Location
  - Most common: Intraventricular (lateral > 3rd, 4th)
  - Less common: Cerebral parenchyma
- Size
  - Typically small (2-3 mm) but up to 8-9 cm reported
- Morphology
  - Smooth, thin-walled cyst

CT Findings

- NECT
  - Cyst is isodense to CSF; Ca++ extremely rare
- CECT
  - No enhancement

MR Findings

- T1WI
  - Isointense to CSF, cyst wall may be seen
- T2WI
  - Isointense to hyperintense to CSF (protein content)
- FLAIR
  - Isointense to CSF (suppresses)
- DWI
  - Isointense to CSF
- T1WI C+
  - No enhancement unless infected

Imaging Recommendations

- Best imaging tool
  - Multiplanar MR with T1WI C+, DWI

DIFFERENTIAL DIAGNOSIS

Asymmetric Ventricles

- Lateral ventricle asymmetry, normal variant

Choroid Plexus Cyst

- Typically bilateral, arises in choroid plexus glomus

Neurocysticercosis

- Scolex present; does not suppress on FLAIR

Arachnoid Cyst

- May be indistinguishable; CSF intensity

Epidermoid Cyst

- Subarachnoid space > ventricles (4th most common)
- Heterogeneous on FLAIR, DWI hyperintensity

Neurenteric Cyst

- Extraaxial (typically posterior fossa) > parenchyma

PATHOLOGY

Gross Pathologic & Surgical Features

- Thin-walled cyst
- Filled with clear, serous liquid

Microscopic Features

- Fluid-filled space
  - May be lined by columnar or cuboidal cells

CLINICAL ISSUES

Presentation

- Most common signs/symptoms
  - Typically asymptomatic
- Other signs/symptoms
  - Rarely headache, seizure, gait disturbance, dementia
  - Symptoms related to CSF obstruction/↑ ICP

Demographics

- Age
  - Young adults (typically < 40 years old)
- Gender
  - Male predominance
- Epidemiology
  - Uncommon (< 25 symptomatic cases reported)

Natural History & Prognosis

- Uncommon so natural history unknown
- Follow-up typically shows no clinical or imaging changes in asymptomatic lesions
  - Imaging follow-up best with MR

Treatment

- If asymptomatic, conservative management
- Symptomatic intraventricular cysts treated via neuronavigation-assisted fenestration

DIAGNOSTIC CHECKLIST

Consider

- Ependymal cysts may be indistinguishable from other benign intracranial cysts

Image Interpretation Pearls

- Ependymal cysts follow CSF on all MR sequences, including DWI; no enhancement

SELECTED REFERENCES

1. Yang T et al: Clinical characteristics and surgical outcomes of spinal intramedullary ependymal cysts. Acta Neurochir (Wien). 156(2):269-75, 2014
2. Prieto R et al: Ependymal cyst of the midbrain. Clin Neuropathol. 32(3):183-8, 2013
3. Savas Erdeve S et al: The endocrine spectrum of intracranial cysts in childhood and review of the literature. J Pediatr Endocrinol Metab. 24(11-12):867-75, 2011
4. 1: Osborn AG, Preece MT. Intracranial cysts: radiologic-pathologic correlation and imaging approach. Radiology. 2006 Jun;239(3):650-64. Review. PubMed PMID: 16714456. and imaging approach. Radiology. 2006 Jun;239(3):650-64. Review. PubMed PMID: 16714456.

https://CafePezeshki.IR

KEY FACTS

TERMINOLOGY

- CSF-filled parenchymal cavity
  - Deep, unilateral/bilateral cavity/excavation
  - Usually communicates with ventricle &/or subarachnoid space
  - Lined by reactive gliosis/astrocytic proliferation
- Congenital (perinatal brain destruction) or acquired (trauma, infection, etc)

IMAGING

- Best diagnostic clue: CSF-filled cavities with enlarged adjacent ventricle
- MR: Smooth-walled cavity; CSF isointense; lined by gliotic white matter

TOP DIFFERENTIAL DIAGNOSES

- Consider arachnoid, ependymal, neoplastic, or inflammatory cyst
- Agenesis of corpus callosum
- Encephalomalacia
- Schizencephaly
- Dandy-Walker malformation
- Hydranencephaly

PATHOLOGY

- Congenital: In utero destructive process caused by cerebral vascular events or infectious injury (CMV)
- Acquired: Injury later in life, following head trauma, surgery, vascular occlusion, or infection
- Genetics: Rare, autosomal dominant familial porencephaly → procollagen defect

CLINICAL ISSUES

- Spastic hemiplegia most common symptom
- Indications for therapy: Mass effect, localized/generalized refractory symptoms

(Left) *Coronal graphic illustrates an intraparenchymal CSF-filled cavity that communicates with the left lateral ventricle and subarachnoid space. Note the classic porencephalic cyst is lined with gliotic white matter ⇨.* **(Right)** *Lateral view of autopsied brain with a porencephalic cyst in the temporal lobe shows a CSF-filled cavity that extends from the brain surface ⇨ to the ventricular ependyma of the temporal horn ⇨. The cyst is lined with gliotic white matter. (Courtesy J. Townsend, MD.)*

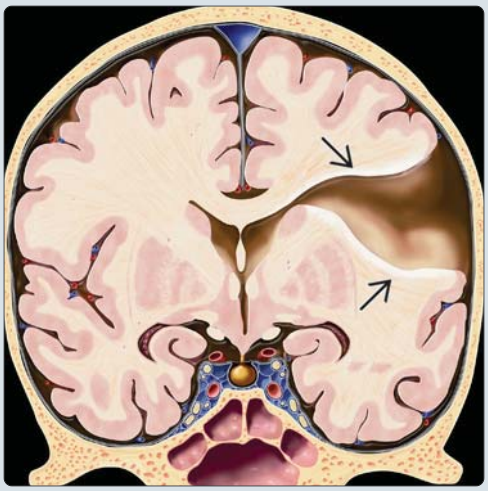

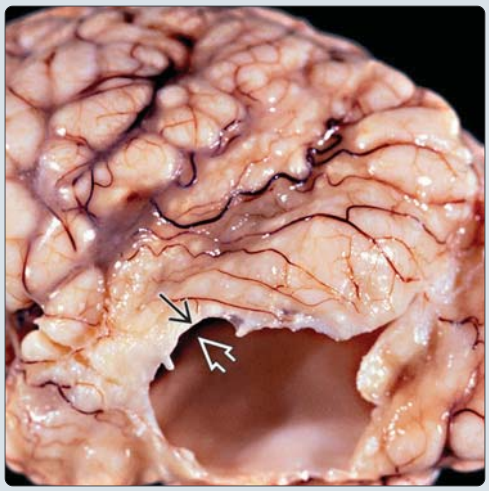

(Left) *Axial FLAIR of a porencephalic cyst reveals a CSF intensity parenchymal defect, which was isointense to CSF on all sequences, including FLAIR nulling ⇨. Also note the small amount of associated white matter gliosis ⇨. Susceptibility artifact is secondary to a ventriculostomy shunt ⇨.* **(Right)** *Coronal T1 C+ MR in the same patient shows a CSF-density parenchymal defect ⇨, which communicates with the atrium of the left lateral ventricle with dilatation of the occipital horn ⇨. Classic porencephalic cyst is also seen.*

https://CafePezeshki.IR

TERMINOLOGY

Synonyms

- Porencephaly

Definitions

- Various definitions of porencephaly
  - Congenital/acquired CSF-filled cavity that usually communicates with ventricular system
    - Deep, unilateral/bilateral cavities or excavations
    - Lined by reactive gliosis/astrocytic proliferation
  - Presence of cysts/cavities in brain parenchyma
    - Communicating by "pore" with arachnoid space
  - Cavities arising in fetal life or early infancy
    - Brain destruction during perinatal period
    - Frequently communicate with subarachnoid space &/or lateral ventricles

IMAGING

General Features

- Best diagnostic clue
  - CSF-filled cavities; enlarged adjacent ventricle
- Location
  - Often corresponds to territories supplied by cerebral arteries (ischemic injury in midgestation)
  - Cortical/subcortical cavity, unilateral/bilateral
  - Usually connected with a lateral ventricle
- Size
  - Varies from small to enormous

CT Findings

- NECT
  - Intraparenchymal smooth-walled cavity
    - Isodense with CSF
  - Directly communicates with ventricle
  - May see thin membrane separating cavity from ventricle
- CECT
  - No contrast enhancement of fluid-filled cavity
- Bone CT
  - Skull remodeling from chronic CSF pulsation
- CTA
  - Absence of vessels at site of porencephaly

MR Findings

- T1WI
  - Smooth-walled cavity; CSF isointense; lined by WM
- T2WI
  - Brain atrophy, gliosis common; CSF isointense; lined by white matter
- FLAIR
  - Accurately depicts CSF content of cyst and gliosis
- T1WI C+
  - Nonenhancing cyst

Ultrasonographic Findings

- Prenatal ultrasound for congenital porencephaly
  - Solitary or multiple echo-spared lesions(s)
  - Some cortical tissue may be preserved

Nonvascular Interventions

- Myelography
  - Contrast material injected into lumbar region may fill cystic space

Nuclear Medicine Findings

- PET
  - Area of absent glucose metabolism

Imaging Recommendations

- Best imaging tool
  - MR
- Protocol advice
  - FLAIR

DIFFERENTIAL DIAGNOSIS

Arachnoid Cyst

- CSF-isointense extraaxial cyst that exerts variable degrees of mass effect
- Unlike porencephalic cyst, extraaxial and displaces brain tissue away from adjacent skull

Ependymal Cyst

- Intraventricular; brain usually normal

Neoplastic Cyst

- Any cystic appearance of neoplastic processes

Inflammatory Cyst

- Mass effect, contrast enhancement if neoplastic

Agenesis of Corpus Callosum

- CSF-filled space extending cephalad from 3rd ventricle
- Parallel appearance of lateral ventricles
- Colpocephaly: Dilatation of occipital horns and posterior portions of temporal horns

Encephalomalacia

- Late gestational, perinatal, or postnatal injuries (thrombotic/embolic infarction, asphyxia, infection)
- May be slightly hyperdense/hyperintense to CSF (T1, T2, FLAIR)
- Cavity typically does not communicate with ventricle
  - Often contains septations and is lined by astrocytic proliferation

Schizencephaly

- Intraparenchymal cavity lined by gray matter, extending from ventricular surface to brain surface

Dandy-Walker Malformation

- Large median posterior fossa cyst widely communicating with 4th ventricle
- Rotated, raised, and small cerebellar vermis in contact with tentorium
- Upward displacement of tentorium and lateral sinuses

Hydranencephaly

- Early destructive process of developing brain caused by toxoplasmosis, CMV, or arterial occlusion
- Cortex and white matter destroyed and replaced by thin-walled CSF-filled sacs of leptomeninges

https://CafePezeshki.IR

PATHOLOGY

General Features

- Etiology
  - Congenital: In utero destructive process caused by cerebral vascular events or infectious injury (CMV)
    - May be induced by antenatal trauma, even when mild or not directed at uterine wall
  - Acquired: Injury later in life, following head trauma, surgery, vascular occlusion, or infection
- Genetics
  - Most cases are sporadic
  - Inherited cases often result from bleeding
    - Rare, autosomal dominant familial porencephaly
      - Chromosome 13qter → mutation of gene encoding procollagen type IV α1
      - Encodes basement membrane protein expressed in all tissues
      - ↑ intracerebral hemorrhage risk for life
    - Inherited thrombophilia, most often heterozygosity for factor V Leiden mutation (gene *F5*)
- Associated abnormalities
  - Amygdala-hippocampal atrophy often coexists with congenital porencephaly (95% in some reports)
    - May be bilateral despite unilateral cysts
  - Syndromes: Septo-optic dysplasia, oro-facio-digital syndrome type I, encephalocraniocutaneous lipomatosis, Proteus syndrome, Delleman syndrome, DK-focomelia
  - Alloimmune thrombocytopenia
  - Coagulopathies (e.g., von Willebrand disease), factor V or X deficiency, maternal warfarin use
  - Multiple gestation associated with vascular disruption defects: Large intestinal atresia, transverse limb deficiency, porencephaly, and renal agenesis

Gross Pathologic & Surgical Features

- CSF-filled cavity with smooth walls
  - Lined by gliotic or spongiotic white matter
- Overlying skull
  - May be remodeled due to long-term transmission of CSF pulsations
  - May be thickened when intervening brain tissue precludes transmission of CSF pulsations

Microscopic Features

- Congenital porencephalic cyst
  - Gray and white matter necrosis
  - Fluid-filled, focal cavity with smooth walls and minimal surrounding glial reaction
- Acquired porencephalic cyst
  - Mature brain reacts to injury by significant astrocytic proliferation
  - Resulting cavity often has septations and irregular wall composed primarily of reactive astrocytes

CLINICAL ISSUES

Presentation

- Most common signs/symptoms
  - Spastic hemiplegia most common feature
  - May be associated with severe neurological deficits
    - Mental retardation, medically intractable epilepsy
- Clinical profile
  - Cerebellar symptoms; ophthalmological signs
  - Various forms of cerebral paralysis
  - Seizures, psychomotor retardation

Demographics

- Age
  - Pediatric age most common; also occurs in adults
- Gender
  - Male > female infants, especially with mothers < 20 years
- Epidemiology
  - 2.5% incidence of porencephalic cysts among 1,000 congenital and acquired brain lesions
  - 0.035% prevalence per 10,000 live births

Natural History & Prognosis

- Narrow communication with ventricular system may ↑ pressure in cyst → mass effect
- Children with neonatal intraparenchymal echodensities and porencephaly have much worse long-term neurodevelopmental outcome

Treatment

- Usually no treatment required
- Indications for therapy: Mass effect, localized/generalized refractory symptoms
  - Cystoperitoneal shunt (preferred)
  - If no communication with ventricular system: Fenestration or partial resection of cyst wall
  - Children with intractable seizures benefit from uncapping and cyst fenestration to lateral ventricle
- Congenital porencephaly should prompt collagen *4A1* genetic screening

DIAGNOSTIC CHECKLIST

Consider

- Arachnoid cyst simulating porencephalic cyst

Image Interpretation Pearls

- Assess hippocampus in setting of seizures

SELECTED REFERENCES

1. Williams T et al: Antenatal diagnosis of intracranial haemorrhage and porencephalic cyst. BMJ Case Rep. 2015, 2015
2. Bennett-Back O et al: Magnetoencephalography helps delineate the extent of the epileptogenic zone for surgical planning in children with intractable epilepsy due to porencephalic cyst/encephalomalacia. J Neurosurg Pediatr. 14(3):271-8, 2014
3. Ryzenman JM et al: Porencephalic cyst: a review of the literature and management of a rare cause of cerebrospinal fluid otorrhea. Otol Neurotol. 28(3):381-6, 2007

https://CafePezeshki.IR

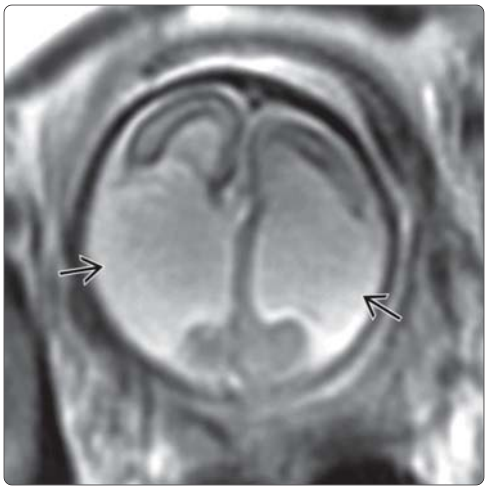

(Left) *Axial T2WI fetal MR technique demonstrates bilateral supratentorial porencephalic cysts ⇨ as CSF isointense lesions communicating with dilated lateral ventricles.* **(Right)** *Coronal T2WI fetal MR in the same patient nicely shows bilateral supratentorial porencephalic cysts ⇨ with normal posterior fossa contents. Congenital porencephalic cysts are the result of an in utero destructive process, usually cerebral vascular events or infectious injury.*

(Left) *Axial NECT reveals porencephalic dilatation of the right lateral ventricle ➡ as a smooth-walled extension from the lateral ventricular wall which appears CSF-isodense.* **(Right)** *Axial NECT in the same fetal patient shows how the lesion extends into the parenchyma and appears as a deep, smooth-walled, unilateral cavity ➡. Note that the overlying brain has a normal morphology.*

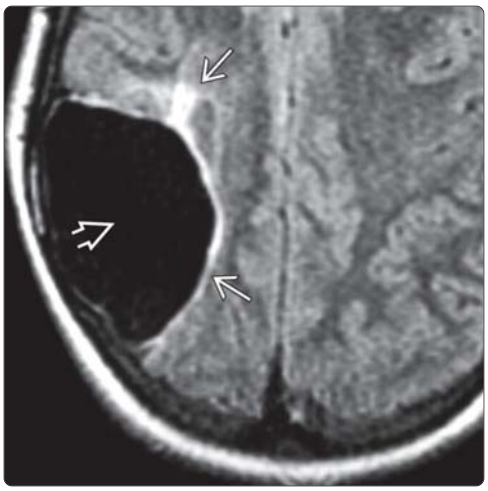

(Left) *A low-density outpouching extends posteriorly and laterally from the occipital horn. While a very thin rim of cortex seems to contain the cystic enlargement of the lateral ventricle, the cyst nearly reaches the brain surface and can be considered either porencephalic dilatation or a porencephalic cyst of the lateral ventricle.* **(Right)** *Axial FLAIR MR shows fluid within a right parietal lesion suppressing completely ➡. This classic porencephalic cyst is lined by hyperintense gliotic white matter ➡.*

https://CafePezeshki.IR

KEY FACTS

TERMINOLOGY

- Congenital endodermal cyst
  - Like Rathke cleft, colloid cysts

IMAGING

- General
  - Oblong nonenhancing, slightly hyperintense (to CSF) mass in front of medulla
- Location
  - More common in spine than brain (3:1)
  - 70-75% of intracranial NECs infratentorial, extraaxial
  - Anterior/lateral to pontomedullary junction
  - 25-30% supratentorial (suprasellar, cerebral hemispheres)
- CT
  - Hypo-/iso-/hyperdense, no Ca++
  - Bony anomalies usually absent
- MR
  - Almost always iso-/hyperintense to CSF on T1WI
  - 90% hyperintense to CSF, 10% hypointense on T2WI
  - Usually does not restrict on DWI
  - Usually no enhancement (mild rim in some)

TOP DIFFERENTIAL DIAGNOSES

- Most common
  - Epidermoid
  - Arachnoid cyst
- Less common
  - Schwannoma (cystic)
- Rare
  - Ecchordosis physaliphora

DIAGNOSTIC CHECKLIST

- Mass in front of brainstem, hyperdense/hyperintense to CSF may be neurenteric cyst

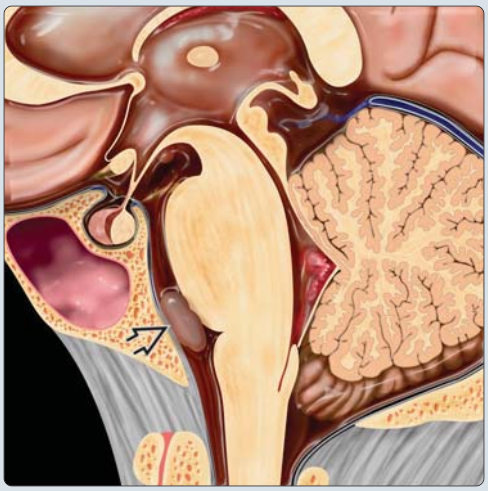

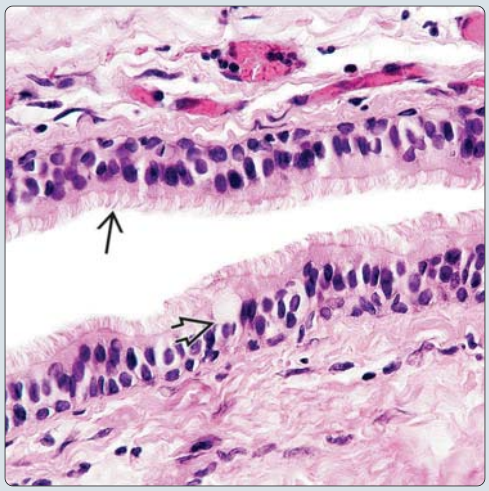

(Left) *Sagittal graphic shows a classic neurenteric (NE) cyst ⇨. Intracranial NE cysts are most often found near the midline, anterior to the brainstem.* **(Right)** *Neurenteric (endodermal) cysts are mostly lined with pseudostratified columnar epithelium with heavily ciliated cells ⇨. Variable numbers of mucin-secreting goblet cells ⇨ are present. (Courtesy P. Burger, MD.)*

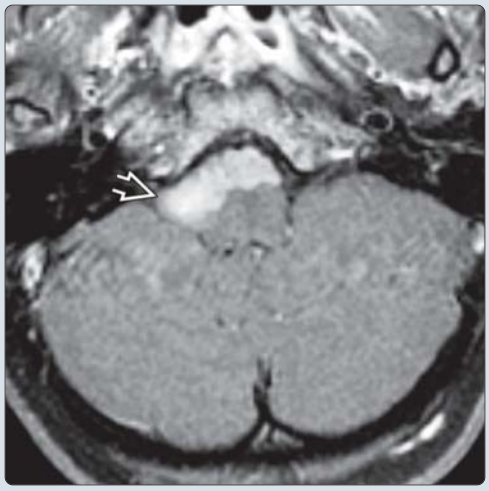

(Left) *Sagittal T1WI shows typical neurenteric cyst as a well-delineated hyperintense ovoid paramedian mass ⇨ anterior to the pontomedullary junction.* **(Right)** *Axial T1C+FS MR in the same patient shows that the mass ⇨ extends inferolaterally in front of the lower medulla. The center of the mass is slightly off midline, a typical location for a posterior fossa neurenteric cyst.*

https://CafePezeshki.IR

TERMINOLOGY

Abbreviations

- Neurenteric cyst (NEC)

Synonyms

- Neuroepithelial cyst. enterogenous cyst, enteric cyst

Definitions

- Rare benign malformative endodermal CNS cyst

IMAGING

General Features

- Best diagnostic clue
  - Oblong, nonenhancing, slightly T1/T2 hyperintense mass in front of medulla
- Location
  - More common in spine than brain (3:1)
  - 70-75% of intracranial NECs found in posterior fossa
    - > 95% extraaxial
    - Anterior/lateral to pontomedullary junction
    - 70% extend to midline
  - 25-30% supratentorial
    - Suprasellar, quadrigeminal cisterns
    - Cerebral hemispheres (frontal most common)
- Size
  - Posterior fossa usually < 2 cm; supratentorial often large
- Morphology
  - Smooth, lobulated, well demarcated

CT Findings

- NECT
  - Hypo-/iso-/hyperdense mass, no Ca++ or hemorrhage
  - Bony anomalies usually absent
- CECT
  - No enhancement

MR Findings

- T1WI
  - Almost always iso-/hyperintense to CSF
- T2WI
  - 90% hyperintense to CSF, 10% hypointense
- FLAIR
  - Hyperintense to CSF
- DWI
  - Usually none, but may show mild restriction
- T1WI C+
  - Usually none; occasionally mild rim

Imaging Recommendations

- Best imaging tool
  - MR with T1 C+, FLAIR, DWI

DIFFERENTIAL DIAGNOSIS

Epidermoid Cyst

- "White" epidermoid (rare) is hyperintense on T1WI
- Usually restricts on DWI

Dermoid Cyst

- Like fat; often Ca++

Arachnoid Cyst

- Like CSF on all sequences

Schwannoma

- Enhances strongly; usually not midline

Other Endodermal Cysts

- Rathke cleft, colloid cysts
- Excluded by location

Ecchordosis Physaliphora

- Notochordal remnant
- Often involves clivus

PATHOLOGY

General Features

- Etiology
  - Congenital endodermal cyst
  - Probably arises from persistent neurenteric canal

Gross Pathologic & Surgical Features

- Transparent, thin-walled, smooth, round/lobulated cyst
- Contents vary from clear, colorless fluid (like CSF) to thicker, more viscous/mucoid

CLINICAL ISSUES

Presentation

- Most common signs/symptoms
  - Brain = asymptomatic or headache

Demographics

- Age
  - Any age; peak 34 years
- Gender
  - M:F = 1:3
- Epidemiology
  - Rare (only 75 intracranial cases reported)

Natural History & Prognosis

- May be stable for years or grow very slowly

Treatment

- Observation vs. total surgical excision

DIAGNOSTIC CHECKLIST

Consider

- Mass in front of brainstem, hyperdense/hyperintense to CSF may be neurenteric cyst

SELECTED REFERENCES

1. Medhi G et al: T1 Hyperintense Prepontine Mass with Restricted Diffusion-A White Epidermoid or a Neuroenteric Cyst? J Neuroimaging. ePub, 2015
2. Mathon B et al: Intracranial neurenteric cyst mimicking prepontine subarachnoid hemorrhage. Rev Neurol (Paris). 170(4):301-2, 2014
3. Roder C et al: Neurenteric cysts of the cerebellopontine angle. J Neurol Surg A Cent Eur Neurosurg. 74 Suppl 1:e36-40, 2013
4. Gauden AJ et al: Intracranial neuroenteric cysts: a concise review including an illustrative patient. J Clin Neurosci. 19(3):352-9, 2012
5. Little MW et al: Neurenteric cyst of the anterior cranial fossa: case report and literature review. Acta Neurochir (Wien). 153(7):1519-25, 2011
6. Preece MT et al: Intracranial neurenteric cysts: imaging and pathology spectrum. AJNR Am J Neuroradiol. 27(6):1211-6, 2006

https://CafePezeshki.IR

KEY FACTS

TERMINOLOGY

- Nonneoplastic tumor-associated cysts (TACs)
- Benign fluid-containing cyst
  - Directly adjacent to, but not within neoplasm

IMAGING

- General features of TAC
  - Smooth, well demarcated
  - Can be single, multiple, multiloculated
  - Abuts tumor directly
  - Usually lies between tumor, brain
  - Extraaxial > > intraaxial TACs
  - Size varies from small to very large
  - Neoplasms that cause TACs are typically large
- CT
  - Hypodense fluid collection adjacent to mass
  - No Ca++, hemorrhage
  - No enhancement
- MR
  - Variable signal (depending on protein content)
  - Often hyperintense to CSF
  - May suppress on FLAIR
  - Usually no restriction on DWI
  - Enhancement absent/minimal

TOP DIFFERENTIAL DIAGNOSES

- Arachnoid cyst
- Enlarged perivascular spaces
- Cystic neoplasms

PATHOLOGY

- Considered tumor "epiphenomenon"
- Most likely represent trapped, encysted pools of CSF adjacent to large extraaxial neoplasm
- As tumor grows, traps CSF between itself and adjacent brain

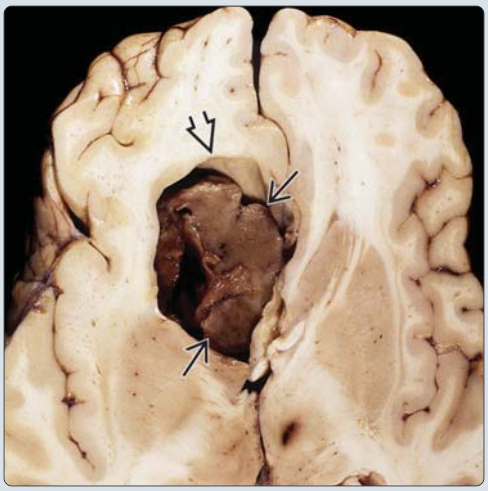

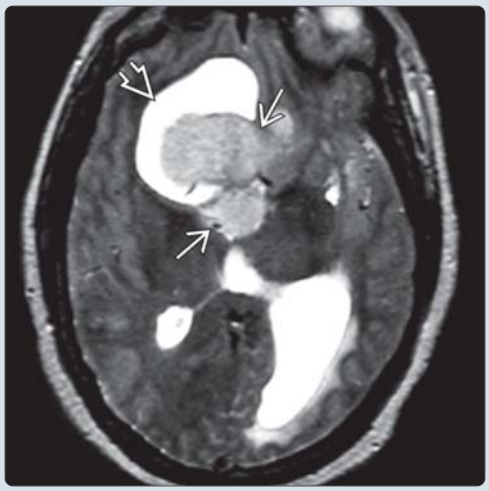

(Left) *Axial autopsy study shows giant pituitary macroadenoma ⇨ with a large, benign, nonneoplastic peritumoral cyst ⇨. (Courtesy R. Hewlett, MD.)* **(Right)** *Axial T2WI in a 58-year-old male with a giant pituitary macroadenoma and lobulated suprasellar extension ⇨ shows an associated benign, nonneoplastic peritumoral cyst ⇨. The cyst collapsed when the tumor was removed and did not recur.*

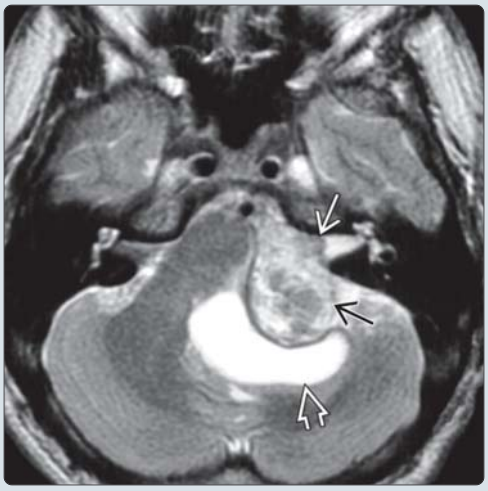

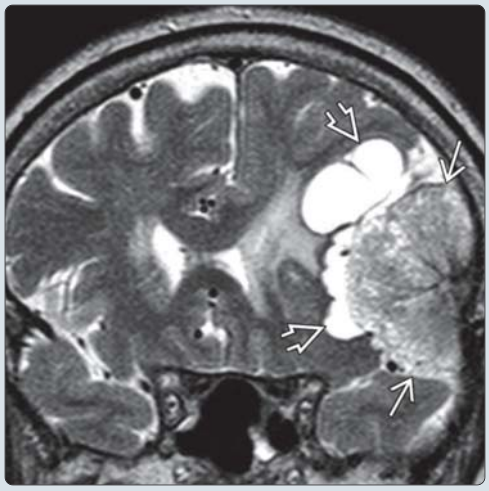

(Left) *Axial T2WI MR in a 33-year-old man with gradually increasing left-sided hearing loss shows a large, mixed signal intensity, CPA mass ⇨ that extends into the proximal IAC ⇨. Note the large nonneoplastic peritumoral cyst ⇨, hyperintense to CSF, associated with this vestibular schwannoma.* **(Right)** *Coronal T2WI MR shows a classic meningioma ⇨ with several large tumor-associated cysts ⇨. The neoplasm enhanced strongly, but heterogeneously, after contrast administration; the cysts showed no enhancement.*

https://CafePezeshki.IR

TERMINOLOGY

Abbreviations

- Nonneoplastic tumor-associated cysts (TACs)

Synonyms

- Peritumoral cyst
- "Herald" cyst (at surgery, may "herald" immediately adjacent mass)
- Tumor-associated arachnoid cyst (AC)
- Tumor-associated enlarged perivascular spaces (PVSs)

Definitions

- Benign fluid-containing cyst adjacent to, but not within, neoplasm

IMAGING

General Features

- Best diagnostic clue
  - Nonenhancing cyst immediately adjacent to neoplasm
- Location
  - Adjacent to tumor
    - Extraaxial TACs much more common than intraaxial
    - TACs generally between tumor, brain
- Size
  - TACs vary from small to very large
  - Neoplasms that cause TACs are typically large
- Morphology
  - Smooth, well demarcated
  - Can be single, multiple, multiloculated

Imaging Recommendations

- Best imaging tool
  - Contrast-enhanced MR
- Protocol advice
  - Include FLAIR, DWI

CT Findings

- NECT
  - Hypodense
  - No Ca++, hemorrhage
- CECT
  - No enhancement

MR Findings

- T1WI
  - Variable depending on protein content
    - Hypointense to brain
    - Iso- to hyperintense to CSF
- T2WI
  - Hyperintense
- FLAIR
  - May suppress
- DWI
  - Usually no restriction
  - May show mildly increased diffusivity
- T1WI C+
  - Usually none
  - Minimal/mild peripheral enhancement may occur
    - Secondary to reactive inflammatory changes, not neoplastic cells in cyst wall

DIFFERENTIAL DIAGNOSIS

Arachnoid Cyst

- Non-tumor-associated arachnoid cysts more common than TACs
- Typically behave **exactly** like CSF
  - Suppress on FLAIR
  - Does not restrict/show increased diffusivity on DWI

Enlarged Perivascular Spaces

- Intraparenchymal, not extraaxial
- Clustered variably-sized cysts > > solitary lesion
- Contain interstitial fluid but behave like CSF

Cystic Neoplasms

- Pilocytic astrocytoma
- Hemangioblastoma
- Schwannoma

PATHOLOGY

General Features

- Etiology
  - Precise etiology unknown
  - Considered tumor "epiphenomenon"
  - Most likely represent trapped, encysted pools of CSF adjacent to large extraaxial neoplasm
    - As tumor grows, traps CSF between itself and adjacent brain
  - Trapped PVSs less likely etiology
  - Some TACs may be true arachnoid cysts

Gross Pathologic & Surgical Features

- Thin cyst wall
- Fluid varies from clear to turbid, proteinaceous

Microscopic Features

- TAC cyst wall is generally gliotic brain ± reactive astrocytes, lymphocytes
- No tumor cells

SELECTED REFERENCES

1. Herde RF, et al: Peritumoral cysts associated with pituitary macroadenoma. J Neurosurg 2015 in press.
2. Güzel A et al: Pituitary adenoma coexisting with a suprasellar arachnoid cyst. Turk Neurosurg. 17(2):138-41, 2007
3. Jung S et al: Increased expression of intracystic matrix metalloproteinases in brain tumors: relationship to the pathogenesis of brain tumor-associated cysts and peritumoral edema. J Clin Neurosci. 14(12):1192-8, 2007
4. Arai M et al: Enhancing gliotic cyst wall with microvascular proliferation adjacent to a meningioma. J Clin Neurosci. 13(1):136-9, 2006
5. Osborn AG et al: Intracranial cysts: radiologic-pathologic correlation and imaging approach. Radiology. 239(3):650-64, 2006
6. Lonser RR et al: Edema is a precursor to central nervous system peritumoral cyst formation. Ann Neurol. 58(3):392-9, 2005

https://CafePezeshki.IR

PART I
SECTION 8

Infectious, Inflammatory, and Demyelinating Disease

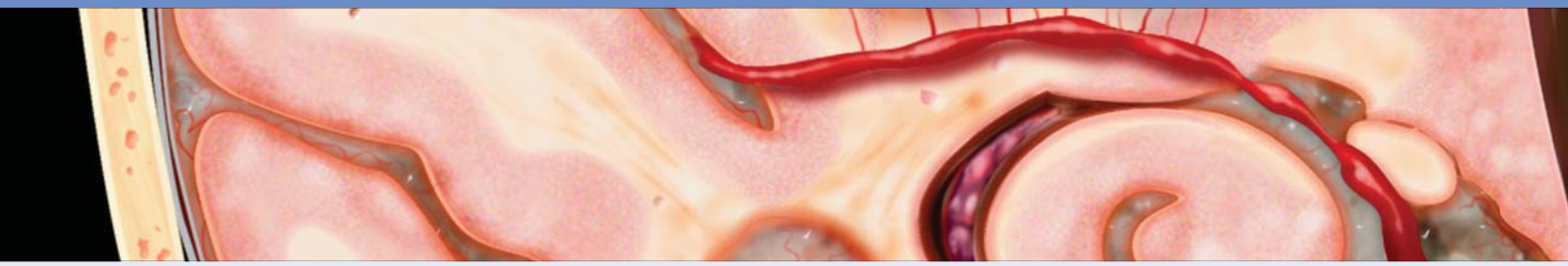

CNS Infectious Disease Overview 656

Congenital/Neonatal Infections

TORCH Infections, Overview 658
Congenital CMV 662
Congenital HIV 666
Neonatal Herpes Encephalitis 668

Acquired Infections

Group B Streptococcal Meningitis 670
Citrobacter Meningitis 674
Meningitis 678
Abscess 682
Ventriculitis 686
Empyema 688
Herpes Encephalitis 692
Miscellaneous Encephalitis 696
West Nile Virus Encephalitis 700
HHV-6 Encephalitis 702
Cerebellitis 704
Rasmussen Encephalitis 706
Subacute Sclerosing Panencephalitis 710
Tuberculosis 712
Neurocysticercosis 716
Hydatid Disease 720
Amebic Disease 722
Cerebral Malaria 724
Miscellaneous Parasites 726
Fungal Diseases 730
Rickettsial Diseases 734
Lyme Disease 736
Acquired HIV Encephalitis 738

https://CafePezeshki.IR

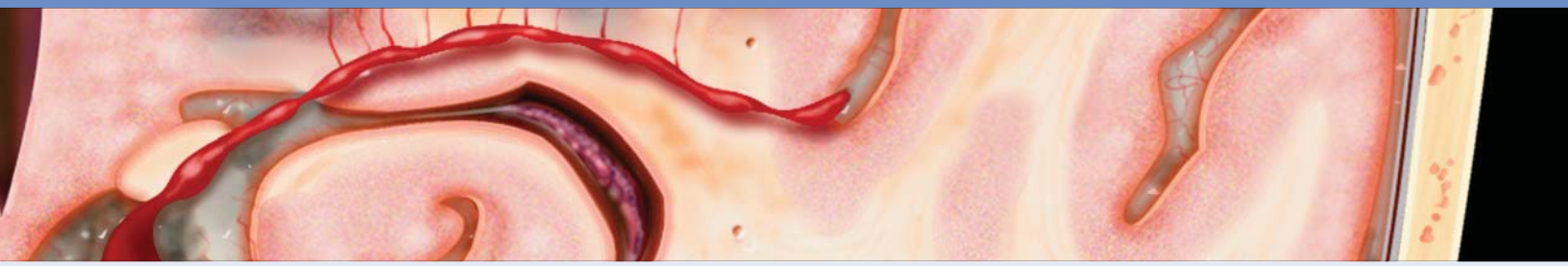

Acquired Toxoplasmosis **742**
Acquired CMV **744**
Cryptococcosis **746**
Progressive Multifocal Leukoencephalopathy (PML) **748**
Immune Reconstitution Inflammatory Syndrome (IRIS) **750**
HIV/AIDS, Miscellaneous Manifestations **752**

Inflammatory and Demyelinating Disease

Multiple Sclerosis **756**
Neuromyelitis Optica **760**
ADEM **764**
AHLE **768**
CLIPPERS **770**

https://CafePezeshki.IR

Overview of CNS Infections

General Considerations

Classification: Infectious diseases can be classified into congenital/neonatal and acquired infections. They can be further subdivided by etiology, i.e., bacterial, viral, fungal, parasitic, and rickettsial diseases.

Infectious diseases can have different manifestations depending on disease acuity. Some diseases like herpes encephalitis are typically acute and fulminant. Others are subacute or chronic (e.g., subacute sclerosing panencephalitis (SSPE) and Rasmussen encephalitis).

Congenital/Neonatal Infections

General Considerations

Terminology: Congenital brain infections are often grouped together and simply called TORCH infections (for **to**xoplasmosis, rubella, **C**ytomegalovirus, and **h**erpes). If congenital syphilis is included, the grouping is called TORCH(S) or (S)TORCH.

Other congenital infections include human immunodeficiency virus (HIV) and lymphocytic choriomeningitis (LCM). Approximately 40% of HIV-positive mothers pass on their infection to the fetus which has shown to be dramatically reduced with HAART treatment of mothers and delivery by cesarean section.

Etiology: Most congenital infections are transmitted to the fetus through the transplacental route, except for herpes, which is acquired during parturition. With 2 exceptions, toxoplasmosis and syphilis, most are viral. All are relatively rare with the possible exceptions of cytomegalovirus (CMV) and herpes encephalitis.

Pathology: Transplacental transmission of various pathogens results in a spectrum of findings depending on both the agent and timing of infection. When infections occur early in fetal development (e.g., the 1st trimester), they tend to result in miscarriage or birth defects. Malformations, such as migrational defects and schizencephaly, are seen in surviving neonates. When infections occur later, encephaloclastic manifestations predominate. Microcephaly with frank brain destruction and widespread encephalomalacia occur. Dystrophic parenchymal calcifications are characteristic of CMV, toxoplasmosis, HIV, and congenital rubella infections.

Acquired Infectious/Inflammatory Diseases

Bacterial Infections

Bacterial pathogens that commonly cause meningitis include *Streptococcus pneumoniae*, *Neisseria meningitidis*, *Haemophilus influenzae*, *Listeria monocytogenes*, Group B *Streptococcus* and *E. coli*.

Meningitis: Purulent exudates, predominately in the basal cisterns, are the common pathologic feature of meningitis, regardless of the specific infectious agent. Exudates may fill the cisterns and subarachnoid spaces. Pia-subarachnoid enhancement is the most common imaging finding. Complications, such as hydrocephalus, empyema, and vasculitis, with or without cerebral infarction, are common.

Abscess: Abscesses develop in 4 general stages: Early and late cerebritis and early and late capsule. In early cerebritis, infection is focal but not yet localized. An unencapsulated mass of inflammatory cells, edema, necrotic foci, and petechial hemorrhage forms. In late cerebritis, the infection coalesces. Central necrosis with a poorly delineated rim of inflammatory cells, granulation tissue, and fibroblasts is seen. The early capsule stage follows late cerebritis. A well-defined collagenous capsule with a liquified necrotic core forms 2-4 weeks after the initial infection. Eventually the abscess cavity shrinks and collapses. This "late capsule" stage can last for months, with imaging findings still present long after symptoms resolve.

Ventriculitis: An abscess rim is thinnest on the paraventricular side. If the abscess ruptures into the ventricle, it causes ventriculitis ("pyocephalus") and choroid plexitis. Intraventricular abscess rupture is often fatal.

Viral Infections

Acute viral infections: Herpes simplex encephalitis (HSE) is the most common nonepidemic viral encephalitis. Over 95% are caused by HSV-1 (oral herpes virus). Currently the most common epidemic viral encephalitis is the West Nile virus.

Subacute and chronic viral infections: Many viruses have a slow incubation period and are characterized by symptoms that progress over months or even years. Subacute sclerosing panencephalitis (SSPE) is an example. Progressive multifocal leukoencephalopathy (PML), caused by JC virus (a ubiquitous polyomavirus), is another.

Miscellaneous Infections

Tuberculosis: With 8-10 million new cases each year and rising prevalence in developing countries, TB is a special public health concern. The emergence of multi-drug resistant TB (MDR TB) and extremely drug-resistant TB (XDR TB) make early recognition and urgent treatment of TB even more important. The "deadly intersection" between HIV and TB, with each disease amplifying the lethality of the other, is of special concern.

Parasites: Neurocysticercosis (NCC) has become the most common CNS parasitic infection in the world and the most common worldwide cause of epilepsy. Although most parasites rarely infect the brain, CNS lesions eventually develop in most patients infected with NCC.

Fungal diseases: Fungi are ubiquitous organisms and endemic in many areas of the world. Most, such as *Aspergillus*, infect humans infrequently, usually through inhalation or puncture wounds. When fungal infections occur in immunocompetent patients, lung disease is more common than brain infection.

CNS and disseminated systemic fungal infections typically occur in immunocompromised patients. HIV/AIDS and immunosuppressive drugs are factors that increasingly predispose patients to opportunistic infections.

Rickettsial diseases: Rickettsial diseases, such as Rocky Mountain and Mediterranean spotted fever, usually have associated skin rashes. CNS infection is uncommon. When it occurs, Rickettsiae have a distinct predilection for the perivascular spaces and cause infarct-like lesions in the basal ganglia.

Spirochetes: Spirochetes are a phylum of gram-negative bacteria. Syphilis and Lyme disease which are caused by *Treponema pallidum* and *Borrelia burgdorferi*, respectively are them most common encountered diseases in this pathogen group. Lyme disease is the most common vector (tick) borne disease in the US. Lyme neuroborreliosis is neurologic involvement secondary to systemic infection by the spirochete *Borrelia burgdorferi*.

https://CafePezeshki.IR

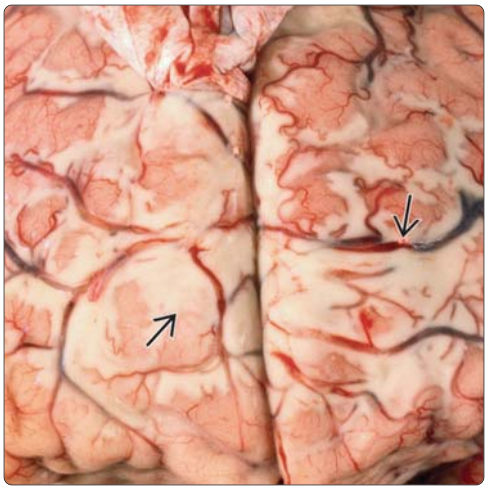

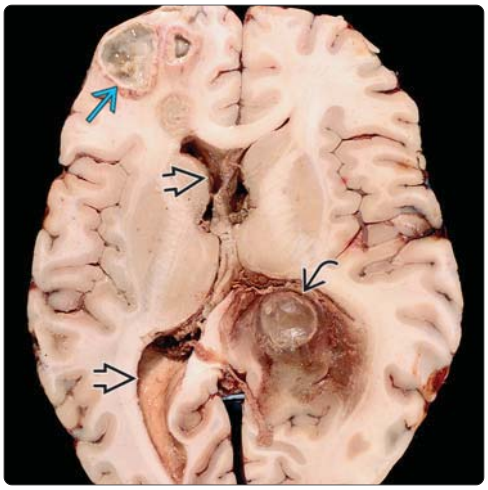

(Left) *Close-up view of the autopsied brain in a patient who died from acute bacterial meningitis. Note thick purulent exudate filling the sulci. The underlying gyri are edematous and diffusely swollen. The pia is inflamed and congested, with prominent cortical vessels. (Courtesy R. Hewlett, MD.)* **(Right)** *Autopsy case shows multiple pyogenic abscesses. A large abscess in the deep white matter has ruptured into the ventricles, causing ventriculitis. (Courtesy R. Hewlett, MD.)*

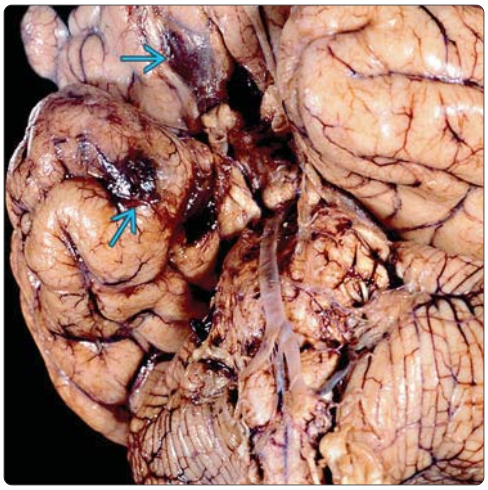

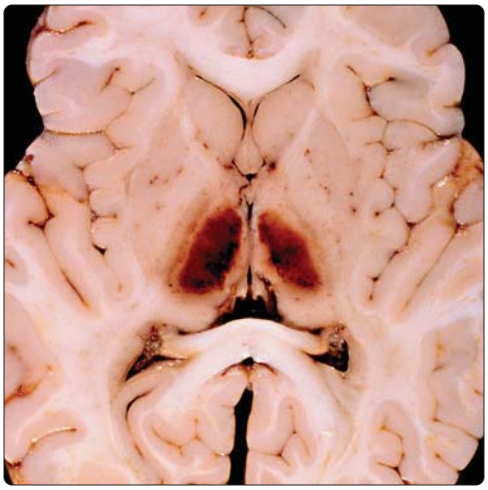

(Left) *Autopsied brain shows classic findings of acute herpes encephalitis. Note the predilection for the limbic system, seen here as hemorrhagic necrosis in the temporal lobe and subfrontal cortex. (Courtesy R. Hewlett, MD.)* **(Right)** *Autopsy case of acute hemorrhagic, necrotizing encephalitis, probably viral. Many nonepidemic viral encephalitides have a predilection for the basal ganglia, thalami, midbrain, and pons. (Courtesy R. Hewlett, MD.)*

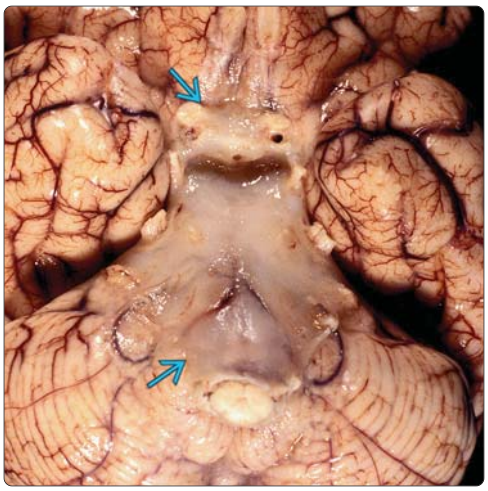

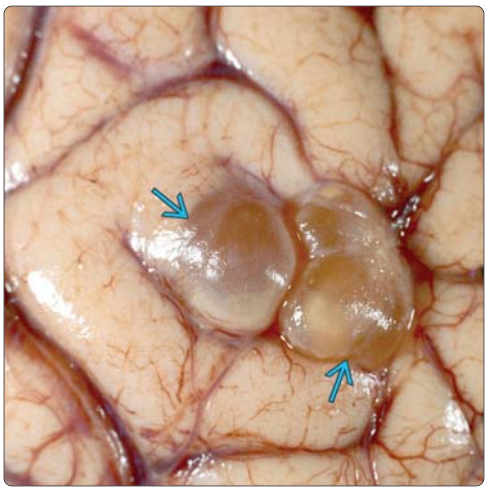

(Left) *Autopsy case demonstrates tuberculous meningitis (TBM). TBM typically causes thick, purulent-appearing exudates with a predilection for the basal cisterns. The imaging and pathologic appearance of meningitis is generally similar, regardless of the etiology. (Courtesy R. Hewlett, MD.)* **(Right)** *Autopsy case shows 2 neurocysticercosis (NCC) cysts lodged within the superficial sulci. The subarachnoid spaces are the most common location for NCC cysts in the brain. (Courtesy R. Hewlett, MD.)*

https://CafePezeshki.IR

KEY FACTS

TERMINOLOGY

- Acronym for congenital infections caused by transplacental transmission of pathogens
- TORCH(S), (S)TORCH, congenital infections, intrauterine infection

IMAGING

- CMV, toxo, lymphocytic choriomeningitis, HIV, and rubella all have parenchymal calcifications (Ca++)
- CMV → periventricular Ca++ ± cysts, cortical clefts, cortical dysplasia, WM abnormalities, and cerebellar hypoplasia
- Sonography for neonatal screening, MR for comprehensive evaluation, NECT to detect or confirm Ca++
- Rubella and HSV cause lobar destruction/encephalomalacia

TOP DIFFERENTIAL DIAGNOSES

- Pseudo-TORCH syndromes → basal ganglia Ca++, progressive demyelination
- Congenital lymphocytic choriomeningitis → micro- or macrocephaly; Ca++ precise mimic of CMV

PATHOLOGY

- CMV most common cause of intrauterine infection; DNA herpesvirus

CLINICAL ISSUES

- CMV most common TORCH infection
- CMV can present at birth (10%) with microcephaly, hepatosplenomegaly, petechial rash
- Congenital toxoplasmosis is usually inapparent at birth, presenting at 2-3 months
- HSV acquired during delivery typically presents at 3-15 days with seizures, lethargy

DIAGNOSTIC CHECKLIST

- CMV → microcephaly, cortical dysplasia, periventricular Ca++ and ± cysts, WM disease, and cerebellar hypoplasia

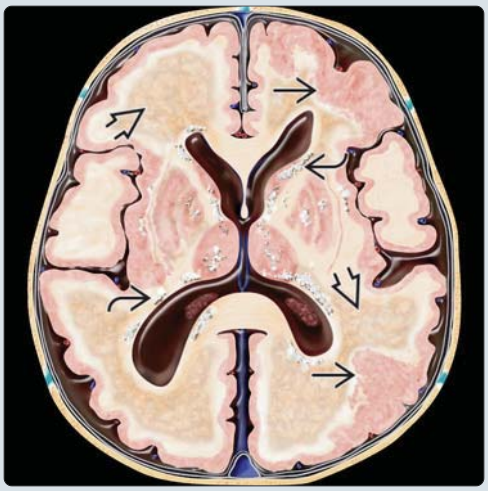

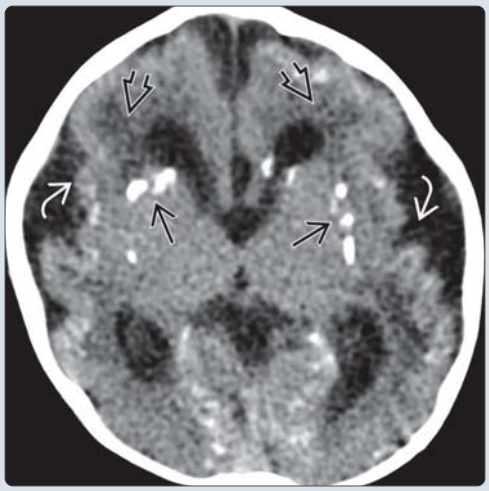

(Left) *Axial graphic shows periventricular parenchymal calcifications, damaged white matter, and dysplastic cortex, all characteristic of an in utero cytomegalovirus infection.* **(Right)** *Axial NECT in a microcephalic infant with cytomegalovirus shows extensive parenchymal Ca++. Note the open sylvian cisterns. MR (not shown) confirmed bilateral perisylvian polymicrogyria. Bilateral frontal white matter hypodensity corresponded to regions of demyelination.*

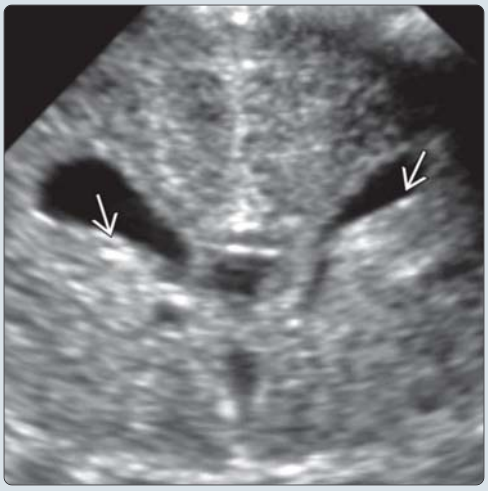

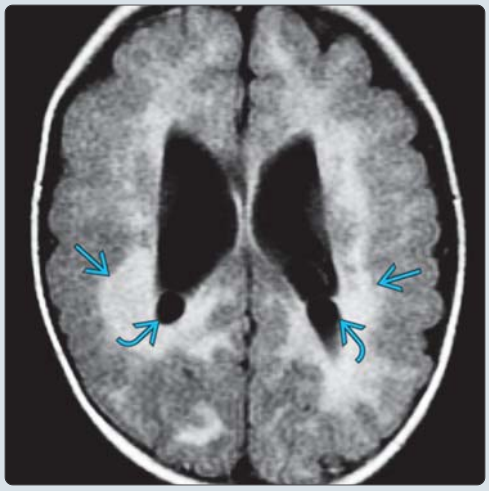

(Left) *Periventricular foci of hyperechogenicity correspond to Ca++ on a NECT in this patient with congenital CMV. Ultrasound may also detect cysts, clefts, and schizencephaly, all associated with congenital CMV.* **(Right)** *Axial FLAIR MR in congenital CMV infection shows periventricular germinolytic cysts and extensive white matter hyperintensities due to gliosis.*

https://CafePezeshki.IR

TERMINOLOGY

Synonyms

- TORCH(S), (S)TORCH, congenital infections, intrauterine infection

Definitions

- Congenital infections caused by transplacental transmission of pathogens
  - Toxoplasmosis (toxo): *Toxoplasma gondii*
  - Rubella: Rubella virus
  - Cytomegalovirus (CMV): Most common TORCH infection
  - Herpes: Herpes simplex virus 2 (HSV-2)
  - Other: Human immunodeficiency virus (HIV), lymphocytic choriomeningitis (LCM), syphilis

IMAGING

General Features

- Best diagnostic clue
  - Toxo, CMV, HIV, and rubella all cause parenchymal calcifications (Ca++)
  - CMV causes periventricular cysts, clefts, schizencephaly, and migrational defects
  - HSV in neonates is diffuse and multifocal unlike adults (localize in frontal and temporal lobes)
  - Rubella and HSV cause lobar destruction/encephalomalacia
  - Syphilis causes basilar meningitis

CT Findings

- NECT
  - Cytomegalovirus
    - ~ 50% of patients have parenchymal &/or periventricular Ca++
    - Focal regions of white matter (WM) low attenuation, ± cysts
    - Migrational defects, cortical clefts, schizencephaly
    - Ventricular dilatation, cerebral volume loss, cerebellar hypoplasia
  - Toxoplasmosis
    - Parenchymal and periventricular Ca++ usually less extensive than CMV, scattered
  - Herpes simplex virus
    - Large regions of decreased attenuation, ± high attenuation foci of hemorrhage
  - HIV
    - Combination of volume loss, basal ganglia, and subcortical Ca++
- CECT
  - Lesions with meningeal inflammatory components (syphilis, HSV) may show enhancement

MR Findings

- T1WI
  - Cytomegalovirus
    - Periventricular subependymal foci of T1 shortening due to Ca++, hypointensity WM
  - Herpes simplex virus
    - Hemorrhagic regions may be hyperintense
- T2WI
  - Cytomegalovirus
    - Cortical abnormalities (polymicrogyria, schizencephaly), hippocampal dysplasia (vertical orientation)
  - Herpes simplex virus
    - Obliterated normal "dark cortex" on T2WI, diffusion restriction, ± hemorrhagic foci
- FLAIR
  - Cytomegalovirus
    - Focal, patchy, or confluent regions of increased signal due to gliosis and demyelination
- T2* GRE
  - Hypointense signal due to Ca++ in CMV, toxo, and HIV
  - Blooming blood in HSV and rubella
- T1WI C+
  - Thickened and enhancing basal meninges in syphilis
  - Patchy mild parenchymal enhancement in HSV
- MRS
  - Active lesions: ↑ myoinositol and excitatory amino acids
  - Chronic disease: ↓ N-acetylaspartate (NAA)

Ultrasonographic Findings

- Grayscale ultrasound
  - Echogenic periventricular foci (Ca++) in CMV, toxo
  - Branching basal ganglia and thalamic echoes: "Mineralizing vasculopathy"
    - Associated with CMV, toxo, syphilis, rubella, and trisomies
  - Periventricular pseudocysts and ventricular adhesions

Imaging Recommendations

- Best imaging tool
  - Cranial sonography for neonatal screening
  - MR brain to completely characterize abnormalities
- Protocol advice
  - T2* GRE &/or NECT to detect periventricular Ca++ or hemorrhage

DIFFERENTIAL DIAGNOSIS

Tuberous Sclerosis

- Subependymal Ca++ characteristic
- Peripheral tubers will mimic migrational abnormalities
- WM lesions can mimic gliosis in TORCH infections

Congenital Lymphocytic Choriomeningitis

- Produces necrotizing ependymitis → aqueductal obstruction; macrocephaly (43%), microcephaly (13%)
- NECT may perfectly mimic CMV

Pseudo-TORCH Syndromes

- Baraitser-Reardon, Aicardi-Goutières (cerebrospinal fluid [CSF] pleocytosis, ↑ CSF α interferon)
  - Progressive cerebral and cerebellar demyelination
  - Basal ganglia Ca++, ± periventricular Ca++

PATHOLOGY

General Features

- Etiology
  - Cytomegalovirus
    - Ubiquitous DNA virus of Herpesviridae family
    - Most common cause of intrauterine infection

https://CafePezeshki.IR

  - Mother has primary or reactivation infection during pregnancy
- Herpes encephalitis
  - HSV2
  - Active genital infection during delivery; transplacental infection less common
- Rubella
  - Togaviridae family of viruses; very rare in USA
  - High risk of miscarriage and birth defects with 1st trimester maternal infection
- Toxoplasmosis
  - Cats are definitive hosts for protozoan parasite
  - 50% of toxoplasmosis infections in USA are from contaminated meat
  - Active infection in pregnancy → 20-50% congenital infection
- HIV
  - Transmitted by transcervical route
  - 30% of pregnancies in HIV(+) women will result in transmission unless preventative measures taken
- Syphilis
  - Caused by spirochetal bacterium *Treponema pallidum*

Gross Pathologic & Surgical Features

- Microcephaly, schizencephaly, polymicrogyria in CMV
- Inflammation/destruction in toxo, rubella, HSV

Microscopic Features

- May find encysted parasites in toxo
- Ischemic necrosis in rubella
- Microglial nodules and cytomegalic cells in CMV

CLINICAL ISSUES

Presentation

- Most common signs/symptoms
  - CMV can present at birth (10%) with microcephaly, hepatosplenomegaly, petechial rash
    - 55% with systemic disease have central nervous system (CNS) involvement
  - Congenital toxoplasmosis is usually inapparent at birth, presenting at 2-3 months
    - Leukokoria (chorioretinitis)
  - HSV acquired during delivery typically presents at 3-15 days with seizures, lethargy
    - HSV acquired in utero (5%) typically presents at birth with hydranencephaly and growth retardation
  - HIV typically diagnosed at 6-12 months with developmental delay
  - Rubella presents with petechial rash, low birth weight, and leukokoria (cataracts)
  - Syphilis → failure to thrive and irritability in newborn, bone pain in infant

Demographics

- Epidemiology
  - CMV most common TORCH infection
    - Incidence 30,000-40,000 per year in USA
  - In utero infection with *T. gondii* reported 1-6/1,000 births
  - HSV 2nd most common TORCH infection
    - Incidence 1/5,000 births
  - Congenital rubella very rare in US due to rubella vaccination program
  - Congenital syphilis varies with geographic region; highest reported incidences in South Africa

Natural History & Prognosis

- Timing of infection during pregnancy in toxo, CMV correlates with severity of disease
  - Infections in early gestation have worse prognosis
- Up to 95% of newborns with neurological symptoms from CMV have major neurodevelopmental sequelae

Treatment

- Ganciclovir may benefit CMV-infected infants
- No treatment for rubella
- Antiretroviral treatment in 2nd and 3rd trimesters and during labor can prevent transmission of HIV
- Pyrimethamine and sulfadiazine are used to treat neonatal toxo → improved outcomes compared to untreated infants
- HSV is treated with acyclovir
- All forms of syphilis are treated with penicillin

DIAGNOSTIC CHECKLIST

Consider

- TORCH infection in newborn and infant with microcephaly, ocular abnormalities, and intrauterine growth restriction

Image Interpretation Pearls

- Congenital CMV encephalitis should be considered when imaging shows
  - Microcephaly, polymicrogyria, periventricular Ca++ and cysts, cortical clefts, WM disease, and cerebellar hypoplasia

SELECTED REFERENCES

1. Bajaj M et al: Clinical and neuroimaging findings in neonatal herpes simplex virus infection. J Pediatr. 165(2):404-407.e1, 2014
2. Bale JF Jr: Congenital cytomegalovirus infection. Handb Clin Neurol. 123:319-26, 2014
3. Wilson MR et al: Diseases of the central nervous system caused by lymphocytic choriomeningitis virus and other arenaviruses. Handb Clin Neurol. 123:671-81, 2014
4. Anderson JL et al: Congenital Lymphocytic Choriomeningitis Virus: When to Consider the Diagnosis. J Child Neurol. 29(6):837-842, 2013
5. Nickerson JP et al: Neuroimaging of pediatric intracranial infection--part 2: TORCH, viral, fungal, and parasitic infections. J Neuroimaging. 22(2):e52-63, 2012
6. Parmar H et al: Pediatric intracranial infections. Neuroimaging Clin N Am. 22(4):707-25, 2012
7. Kulkarni AM et al: Fetal intracranial calcification: pseudo-TORCH phenotype and discussion of related phenotypes. Am J Med Genet A. 152A(4):930-7, 2010
8. Briggs TA et al: Band-like intracranial calcification with simplified gyration and polymicrogyria: a distinct "pseudo-TORCH" phenotype. Am J Med Genet A. 146A(24):3173-80, 2008
9. Sanchis A et al: Genetic syndromes mimic congenital infections. J Pediatr. 146(5):701-5, 2005
10. de Vries LS et al: The spectrum of cranial ultrasound and magnetic resonance imaging abnormalities in congenital cytomegalovirus infection. Neuropediatrics. 35(2):113-9, 2004
11. Jones J et al: Congenital toxoplasmosis. Am Fam Physician. 67(10):2131-8, 2003

https://CafePezeshki.IR

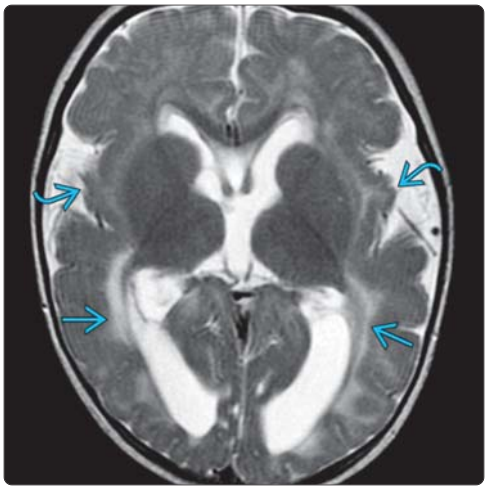

(Left) *Axial T2WI FSE MR in an infant with congenital CMV shows broad, sylvian cisterns due to perisylvian polymicrogyria. Confluent regions of periventricular white matter increased signal due to gliosis and demyelination* **(Right)** *Axial NECT in a patient with toxoplasmosis shows multiple scattered cerebral calcifications. Note the ventricular dilation and cerebral hemispheric volume loss. The infection is caused by the protozoan Toxoplasma gondii.*

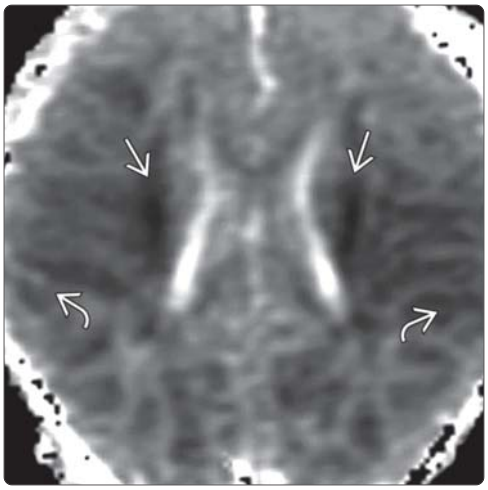

(Left) *Axial ADC of an acutely infected, seizing neonate with herpes simplex virus type 2 sepsis shows widespread low diffusivity (hypointensity) within the periventricular white matter, cortex, and subcortical white matter.* **(Right)** *Axial NECT in an infant with congenital rubella and cataracts shows atrophy of the cerebral hemispheres. There is overlap of the cranial sutures, secondary to volume loss. Note the central basal ganglia calcification.*

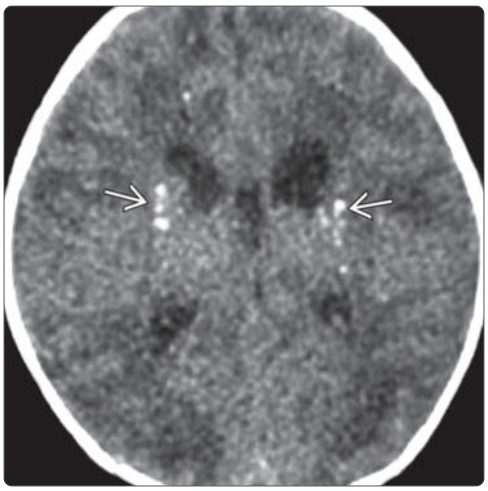

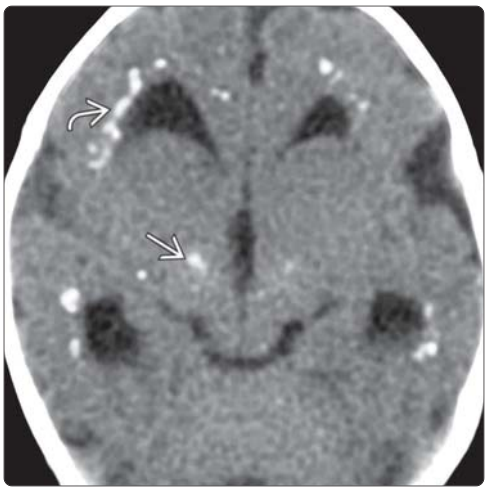

(Left) *Axial NECT in a microcephalic infant with a lymphocytic choriomeningitis virus infection shows scattered basal ganglia calcifications. The clinical and imaging features of this disorder may precisely mimic congenital cytomegalovirus infection.* **(Right)** *Axial NECT in pseudo-TORCH shows basal ganglia calcification and periventricular calcification. Pseudo-TORCH states are autosomal recessive disorders showing mineralization and progressive demyelination.*

https://CafePezeshki.IR

KEY FACTS

TERMINOLOGY

- Congenital cytomegalovirus (CMV)
  - Most common source of intrauterine infection in USA

IMAGING

- Microcephaly: Spectrum and severity of brain injury depends on timing of fetal infection
- Cranial sonography
  - Periventricular hyperechoic foci
  - Branching basal ganglia hyperechogenicities (lenticulostriate vasculopathy)
  - Ring-like regions of periventricular lucency may precede subependymal Ca++
- NECT when CMV is clinically suspected &/or to complement brain MR
  - Intracranial Ca++ (40-70%): Periventricular (subependymal) (germinolytic zones)
- MR brain to completely characterize abnormalities
  - Agyria ↔ pachygyria ↔ diffuse polymicrogyria ↔ focal cortical dysplasia ↔ schizencephalic clefting
  - WM abnormalities: Periventricular germinolytic cysts, demyelination, gliosis
  - Cerebellar hypoplasia

TOP DIFFERENTIAL DIAGNOSES

- Congenital lymphocytic choriomeningitis (LCM)
- Toxoplasmosis
- Pseudo-TORCH syndromes

PATHOLOGY

- Ubiquitous DNA virus of herpes virus family
- Hematogenously seeds choroid plexus, replicates in ependyma, germinal matrix, and capillary endothelia

CLINICAL ISSUES

- Most infected newborns appear normal
- 55% with systemic disease have CNS involvement

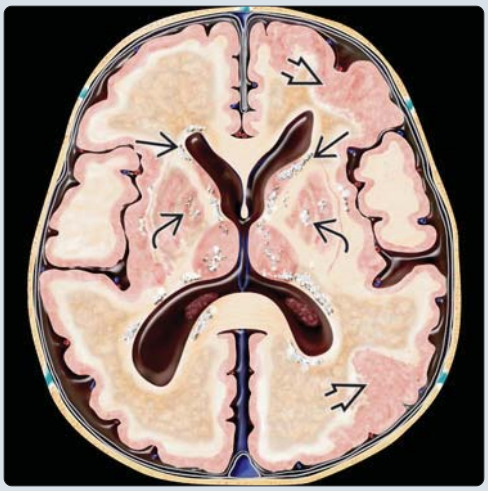

(Left) *Axial graphic shows numerous periventricular and basal ganglia calcifications. Note regions of cortical dysplasia (polymicrogyria). Ventricular dilation reflects adjacent white matter (WM) volume loss. The yellowish WM abnormalities reflect regions of edema, demyelination, &/or gliosis.* **(Right)** *Axial NECT shows extensive periventricular and parenchymal calcification. Note the open sylvian fissures and simplified perisylvian cortex. MR confirmed polymicrogyria.*

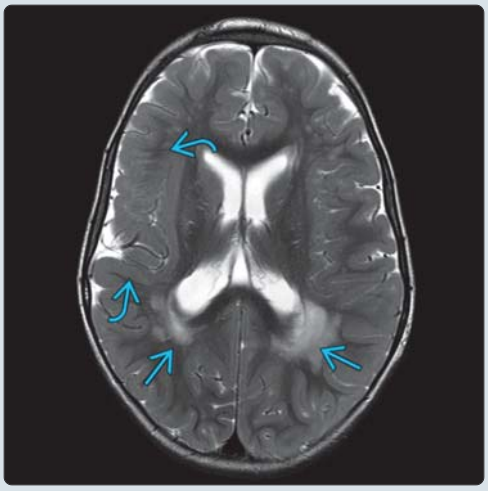

(Left) *Axial T2WI MR in a child with congenital CMV shows right perisylvian dysplastic cortex (likely polymicrogyria) and regions of abnormal WM signal predominantly in the parietal lobes, likely due to gliosis &/or demyelination. Ventricular dilation is secondary to WM volume loss.* **(Right)** *Axial SWI image in the same patient shows foci of low signal in the frontal periventricular region due to calcifications*

https://CafePezeshki.IR

TERMINOLOGY

Abbreviations

- Congenital cytomegalovirus (CMV)

Definitions

- Congenital infection caused by transplacental transmission of CMV, a member of herpes virus family
  - Most common source of intrauterine infection in USA

IMAGING

General Features

- Best diagnostic clue
  - Microcephaly, spectrum of brain injury depending on timing of fetal infection
  - Intracranial calcifications (40-70%); periventricular (subependymal germinal matrix zones)
  - Migration abnormalities : Lissencephaly ↔ pachygyria ↔ polymicrogyria ↔ schizencephalic clefting
  - White matter (WM) abnormality: Delayed myelination, dysmyelination
  - Cerebral, cerebellar atrophy
  - Periventricular cysts, ventriculomegaly, ventricular adhesions, lenticulostriate vasculopathy
- Gestational age at time of infection determines pattern of CNS injury
  - Prior to 18 weeks → reduction in neurons and glia, lissencephaly, small cerebellum, ventriculomegaly
  - 18-24 weeks → migration anomalies, cerebellar hypoplasia, schizencephaly
  - 3rd trimester → Delayed myelination, dysmyelination, periventricular cysts
  - Perinatal infection → delay in myelin maturation, focal WM injury (astrogliosis)

CT Findings

- NECT
  - Intracranial Ca++ (40-70%): Periventricular (subependymal) (germinolytic zones)
  - WM volume loss , WM low attenuation, ± periventricular cysts, ventriculomegaly
  - Cortical gyral abnormalities
  - Cerebellar hypoplasia

MR Findings

- T1WI
  - Periventricular subependymal foci of T1 shortening secondary to Ca++
  - Ventricular dilatation and periventricular WM volume loss ± periventricular cysts
  - Cerebellar hypoplasia
- T2WI
  - Migration abnormalities : Lissencephaly, pachygyria, diffuse or focal polymicrogyria, schizencephaly
  - Myelination delay or destruction ± periventricular cysts (often at temporal tip)
  - Focal WM lesions with ↑ T2 intensity (gliosis/demyelination) predominantly in parietal deep WM
  - Hippocampal dysplasia (vertical orientation)
- FLAIR
  - Focal, patchy, or confluent regions of increased signal due to gliosis ± periventricular hypointense cysts
- T2* GRE
  - Periventricular ↓ signal due to Ca++
- MRS
  - ↓ NAA:Cr ratio due to loss of neuronal elements, ↑ myoinositol (gliosis)

Ultrasonographic Findings

- Grayscale ultrasound
  - Ring-like regions of periventricular lucency may precede subependymal Ca++
  - Branching basal ganglia and thalamic echoes (lenticulostriate vasculopathy)
  - Periventricular cysts and ventricular adhesions
  - Cerebellar hypoplasia

Imaging Recommendations

- Best imaging tool
  - Sonography for prenatal or neonatal screening
  - NECT rarely necessary
  - Brain MR to completely characterize abnormalities
- Protocol advice
  - High-resolution neonatal neurosonography
  - NECT or T2* GRE to detect subtle calcification or hemorrhage

DIFFERENTIAL DIAGNOSIS

Congenital Lymphocytic Choriomeningitis

- Rodent-borne arenavirus: Carried by feral house mouse and hamster
- Necrotizing ependymitis leading to aqueductal obstruction (macrocephaly in 43%, microcephaly in 13%)
- Appearance on NECT may perfectly mimic CMV

Toxoplasmosis

- Protozoan parasite
  - Maternal risk factors include
    - Exposure to cat excreta during pregnancy
    - Eating raw or undercooked meat
- 1/10 as common as CMV, macrocrania > microcrania, cortical dysplasia less common, random cerebral Ca++

Pseudo-TORCH Syndromes

- Baraister-Reardon, Aicardi-Goutières (CSF pleocytosis, ↑ CSF α-interferon)
  - Autosomal recessive, progressive cerebral and cerebellar demyelination and degeneration
  - Basal ganglia and brainstem Ca++, periventricular Ca++ less common
- Mutations of *OCLN* gene encoding occludin
  - Autosomal recessive microcephaly
  - Polymicrogyria with band of subcortical calcification

PATHOLOGY

General Features

- Etiology
  - CMV is ubiquitous DNA virus of herpesvirus family
  - Neurotropic virus that replicates in ependyma, germinal matrix, capillary endothelium

https://CafePezeshki.IR

- Chronic ischemia from placentitis leading to secondary perfusion insufficiency
- Most common cause of intrauterine infection
- Mechanisms of infection
  - Fetal infection
    - Mother with primary infection during pregnancy vs. mother with reactivation of latent infection
  - Neonatal infection
    - Mother infected at delivery, transmission of virus in breast milk, or by blood transfusion

Staging, Grading, & Classification

- Timing of gestational infection determines insult
  - Neuronal formation between 8-20 weeks
  - Neuron migration until 24-26 weeks
  - Astrocyte generation begins near end of neuronal production
  - Maximal size of germinal zones at 26 weeks
  - Oligodendrocytes produced during 1st half of 3rd trimester

Gross Pathologic & Surgical Features

- Microcephaly
- Early gestational infection
  - Germinal zone necrosis, diminished number of glia and neurons, WM volume loss

Microscopic Features

- Hallmark of CMV infection: Cytomegaly with viral nuclear and cytoplasmic inclusions
- Patchy and focal cellular necrosis (particularly germinal matrix cells)
- Vascular inflammation and thrombosis, vascular and subependymal dystrophic Ca++

CLINICAL ISSUES

Presentation

- Most common signs/symptoms
  - Most infected newborns appear normal
  - 10% have systemic signs of disease
    - Hepatosplenomegaly, petechiae, chorioretinitis, jaundice, intrauterine growth retardation
  - 55% with systemic disease have CNS involvement
    - Microcephaly, seizures, hypotonia or hypertonia, sensorineural hearing loss (SNHL)
- Clinical profile
  - Seronegative women are at greatest risk for vertical transmission
- Methods of diagnosis
  - Shell-vial assay for CMV (urine)
  - Late diagnosis with PCR for CMV-DNA from neonatal Guthrie card
  - Elevated CSF β-2 microglobulin levels, microcephaly, neuroimaging findings predictive of outcome

Demographics

- Epidemiology
  - Affects ~ 1% of all newborns (10% of whom have CNS or systemic signs and symptoms)
  - 40% of mothers who acquire infection during pregnancy transmit virus to fetus

Natural History & Prognosis

- 3 prognostic groups
  - Newborns with CNS manifestations (microcephaly, periventricular Ca++)
    - Up to 95% have major neurodevelopmental sequelae
  - Newborns with only systemic manifestations (hepatosplenomegaly, petechiae, jaundice)
    - Have better prognosis but still significantly affected
  - Infected newborns with neither CNS nor systemic manifestations
    - Best prognosis, yet still at risk for developmental delays, motor deficits, and SNHL
  - Overall mortality ~ 5%

Treatment

- Ganciclovir therapy may benefit infected infants

DIAGNOSTIC CHECKLIST

Consider

- Congenital CMV in developmentally delayed, microcephalic infant with SNHL

Image Interpretation Pearls

- Congenital CMV encephalitis should be considered when MR shows
  - Microcephaly, migration anomalies, periventricular cysts, WM abnormalities, and cerebellar hypoplasia
- When NECT is classic for CMV encephalitis but work-up for (S)TORCH infection is negative, consider
  - Lymphocytic choriomeningitis (LCM) and pseudo-TORCH syndromes

SELECTED REFERENCES

1. Capretti MG et al: Role of cerebral ultrasound and magnetic resonance imaging in newborns with congenital cytomegalovirus infection. Brain Dev. 36(3):203-11, 2014
2. Alarcon A et al: Clinical, biochemical, and neuroimaging findings predict long-term neurodevelopmental outcome in symptomatic congenital cytomegalovirus infection. J Pediatr. 163(3):828-34, 2013
3. Fink KR et al: Neuroimaging of pediatric central nervous system cytomegalovirus infection. Radiographics. 30(7):1779-96, 2010
4. Lanari M et al: Neuroimaging in CMV congenital infected neonates: how and when. Early Hum Dev. 88 Suppl 2:S3-5, 2012
5. Manara R et al: Brain magnetic resonance findings in symptomatic congenital cytomegalovirus infection. Pediatr Radiol. 41(8):962-70, 2011
6. Malinger G et al: Imaging of fetal cytomegalovirus infection. Fetal Diagn Ther. 29(2):117-26, 2011
7. O'Driscoll MC et al: Recessive mutations in the gene encoding the tight junction protein occludin cause band-like calcification with simplified gyration and polymicrogyria. Am J Hum Genet. 87(3):354-64, 2010
8. Malm G et al: Congenital cytomegalovirus infections. Semin Fetal Neonatal Med. 12(3):154-9, 2007

https://CafePezeshki.IR

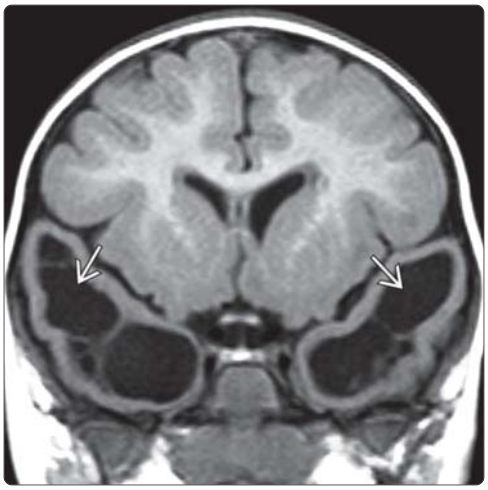

(Left) *Coronal T1WI MR in a microcephalic infant shows numerous periventricular cavitary germinolytic cysts. Detecting these cysts on US, CT, or MR imaging should prompt the consideration of possible congenital CMV infection.* **(Right)** *Coronal cranial ultrasound in congenital CMV shows periventricular foci of echogenicity consistent with calcification.*

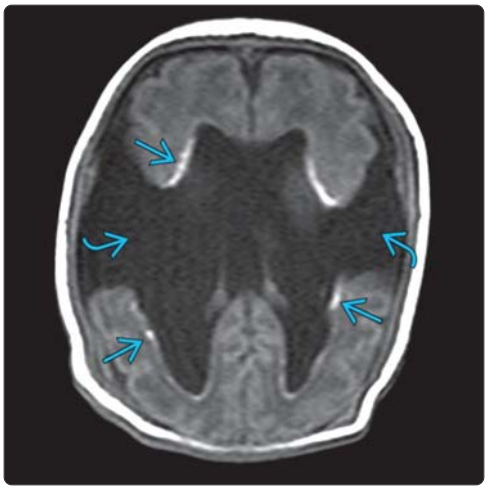

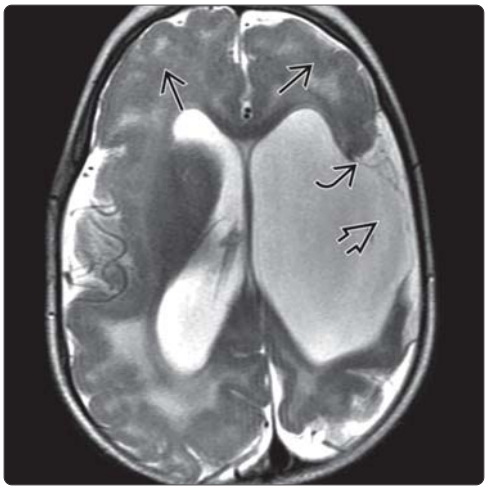

(Left) *Axial T1WI in an infant with congenital CMV demonstrates bilateral open lip schizencephaly. Note the periventricular T1 hyperintense signal due to calcifications.* **(Right)** *Axial T2WI MR shows a left hemispheric "open-lip" schizencephaly lined by polymicrogyric cortex. Note the extensive bifrontal polymicrogyria. Patchy central WM hyperintensity reflects regions of demyelination or gliosis.*

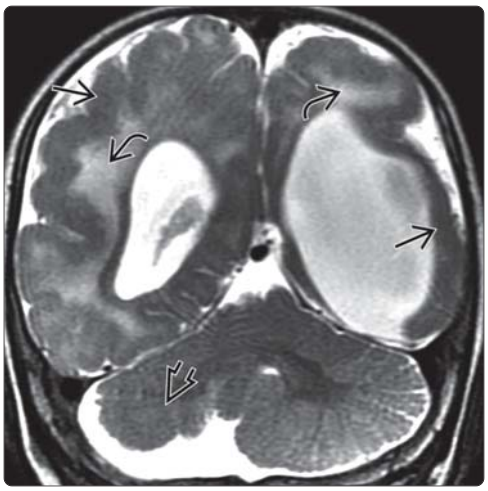

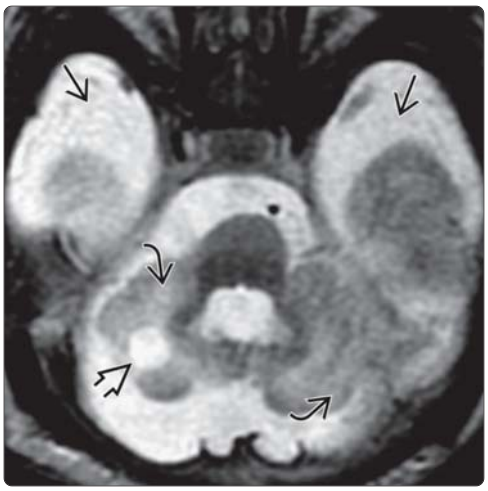

(Left) *Coronal T2WI MR shows ventriculomegaly secondary to central WM volume loss; WM hyperintensities reflecting edema, gliosis, or demyelination; and polymicrogyria. Also note the hypoplastic right cerebellar hemisphere.* **(Right)** *Axial T2WI MR in a neonate demonstrates cerebellar hypoplasia and focal cystic injury of the cerebellum. Expansion of the middle cranial fossa subarachnoid spaces is indicative of temporal lobe atrophy.*

https://CafePezeshki.IR

KEY FACTS

TERMINOLOGY

- Congenital AIDS, maternally transmitted AIDS

IMAGING

- Basal ganglia (BG) Ca++, cerebral atrophy
- Atrophy particularly frontal lobes
- Mineralizing microangiopathy: BG Ca++ (30-85%) > frontal WM > cerebellum
- Atrophy, ± T1 shortening within BG due to Ca++
- ± high signal in frontal subcortical WM, infarcts
- Fusiform vasculopathy (late)
- Include MRA with baseline NECT/MR

TOP DIFFERENTIAL DIAGNOSES

- Cytomegalovirus: Periventricular Ca++, microcephaly, cortical dysplasia
- Toxoplasmosis: Scattered Ca++, ± hydrocephalus
- Pseudo-TORCH: BG, brainstem, and parenchymal Ca++, neurodegeneration

PATHOLOGY

- HIV in microglial cells and macrophages
- Fibrosing and calcific vasculopathy, aneurysms, strokes, demyelination, ± hemorrhage

CLINICAL ISSUES

- Developmental delay, progressive encephalopathy, ↓ motor milestones, stroke
- Pediatric HIV: HIV cases in USA (2%), worldwide (5-25%); 90% are vertically transmitted (90%)
- Most acquired at birth, 3rd trimester, or via breastfeeding
- Opportunistic infections less common than in adult HIV

DIAGNOSTIC CHECKLIST

- Consider congenital HIV with bilateral symmetrical BG Ca++ in children > 2 months
- Consider congenital HIV when fusiform arteriopathy is detected

(Left) *Axial NECT in a 5-year-old girl with vertically transmitted HIV infection shows mild to moderate atrophy, most notable at the sylvian cisterns. Note the focal calcification involving the globus pallidus.* **(Right)** *Axial T2WI MR in a 12-year-old boy with a history of previous strokes and congenital HIV infection demonstrates fusiform aneurysmal dilation of the arteries of the circle of Willis. There is evidence of early atrophy involving the occipital lobes.*

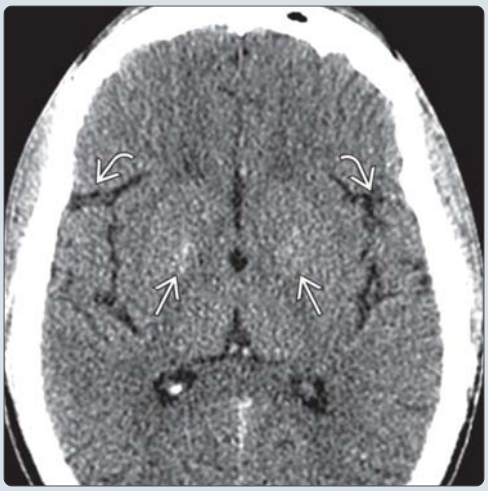

(Left) *Axial T2WI in a 10 year old with congenital HIV demonstrates encephalomalacia due to old infarcts in the right frontal and both parietal lobes. Note diffuse volume loss as well as ill-defined T2 signal change in the deep white matter.* **(Right)** *Axial T1WI MR in the same patient shows T1 shortening in the basal ganglia due to calcifications. Cystic encephalomalacia due to old infarcts are also noted.*

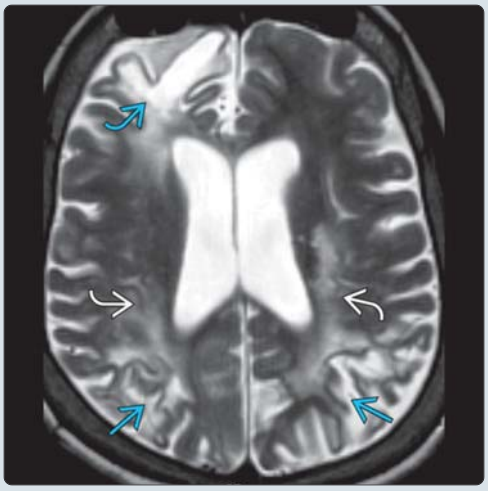

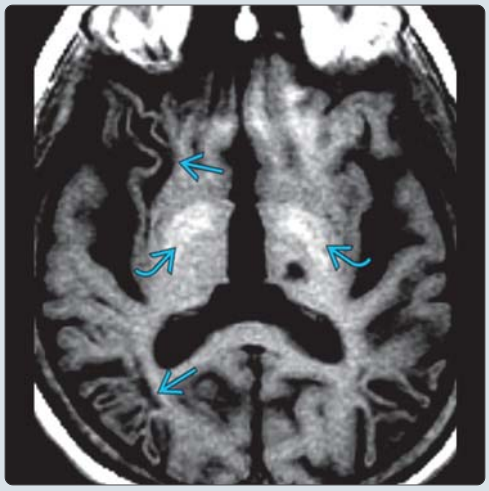

https://CafePezeshki.IR

TERMINOLOGY

Synonyms

- Congenital AIDS, pediatric human immunodeficiency virus-1 infection

Definitions

- Infection early in utero/late pregnancy, at delivery, or by breast feeding

IMAGING

General Features

- Best diagnostic clue
  - Basal ganglia (BG) Ca++
  - Cerebral atrophy

CT Findings

- NECT
  - Atrophy, particularly frontal lobes
  - Mineralizing microangiopathy: BG Ca++ (30-85%) > frontal white matter (WM) > cerebellum
- CECT
  - ± faint enhancement of BG prior to appearance of Ca++
- CTA
  - Ectasia/fusiform enlargement of intracranial arteries (3-5%)

MR Findings

- T1WI
  - Atrophy, ± T1 shortening within BG due to Ca++
- T2WI
  - ± high signal in frontal subcortical WM, infarcts
- T2* GRE
  - May accentuate Ca++
- DWI
  - ± restricted diffusion for patients presenting with stroke
- T1WI C+
  - ± faint BG enhancement initially
- MRA
  - Fusiform vasculopathy (late)
- MRS
  - ↓ NAA, ↑ Cho:Cr, presence of excitatory neurotransmitters

Imaging Recommendations

- Best imaging tool
  - NECT
- Protocol advice
  - Include MRA with baseline NECT/MR

DIFFERENTIAL DIAGNOSIS

Cytomegalovirus

- Periventricular Ca++, microcephaly, cortical dysplasia

Toxoplasmosis

- Scattered Ca++, ± hydrocephalus

PATHOLOGY

General Features

- Etiology
  - HIV in microglial cells and macrophages

Gross Pathologic & Surgical Features

- Generalized brain volume loss
- Fibrosing and calcific vasculopathy, aneurysms, strokes, demyelination, ± hemorrhage
- Cerebrovascular disease found in 25% at autopsy (3-5% on imaging)

Microscopic Features

- Microglial nodules, multinucleated giant cells, Ca++ vasculopathy, myelin loss

CLINICAL ISSUES

Presentation

- Most common signs/symptoms
  - Encephalopathy, ↓ motor milestones
  - Stroke, microcephaly
- Clinical profile
  - Children become symptomatic after 3rd month of life
    - Hepatomegaly, lymphadenopathy, pneumonitis, infections, encephalopathy
    - High prevalence of congenital CMV when mothers have prenatal antiviral prophylaxis

Demographics

- Age
  - Symptoms begin at 12 weeks of life; some asymptomatic until 10 years
- Epidemiology
  - Pediatric HIV cases in USA (2%), worldwide (5-25%); 90% are vertically transmitted
    - Most acquired at birth, 3rd trimester, or via breastfeeding

Natural History & Prognosis

- If symptomatic in 1st year of life → 20% die in infancy
- Opportunistic infections less common than in adult HIV

Treatment

- Confirm diagnosis with polymerase chain reaction, HIV blood culture, p24-antigen assay
- Retroviral therapy improves survival

DIAGNOSTIC CHECKLIST

Image Interpretation Pearls

- Consider congenital HIV with bilateral symmetrical BG Ca++ in children > 2 months
- Consider HIV when fusiform arteriopathy is detected

SELECTED REFERENCES

1. Tardieu M et al: Virus-induced lesions and the fetal brain: examples of the transmission of HIV-1 and CMV from mother to offspring. Handb Clin Neurol. 112:1103-8, 2013
2. Parmar H et al: Pediatric intracranial infections. Neuroimaging Clin N Am. 22(4):707-25, 2012

https://CafePezeshki.IR

KEY FACTS

TERMINOLOGY

- Neonatal herpes simplex encephalitis, HSV-2, neonatal HSV

IMAGING

- Early : Edema, DWI abnormality
- Late: Atrophy, cysts, ventriculomegaly, Ca++
- Variable brain involvement, early DWI abnormality
- Variable: WM, GM (cortical, BG), temporal lobe, brainstem, cerebellum, ± watershed
  - Unlike HSV encephalitis in adults & older children, infants with HSV have a diffuse, rather than temporal lobe predilection
- Early: CT normal (27%); variable distribution, low attenuation
- Early: Swelling, T1 hypointensity in affected regions
- Early: T2 hyperintensity (edema, neuronal necrosis), BG involved ~ 57%
- Hemorrhage less common than with HSV-1

TOP DIFFERENTIAL DIAGNOSES

- Peripartum &/or postnatal infection
- Stroke/ischemia, arterial or venous
- Vertically transmitted infection, TORCH
  - CMV → microcephaly, Ca++, cortical clefting or malformation
  - Toxoplasmosis → scattered Ca++, hydrocephalus

PATHOLOGY

- Transmission: Peripartum (85%), postnatal (10%), in utero (5%)

CLINICAL ISSUES

- C-section if active maternal infection, intravenous acyclovir

DIAGNOSTIC CHECKLIST

- Suspect HSV-2 in neonates with unexplained DWI abnormality

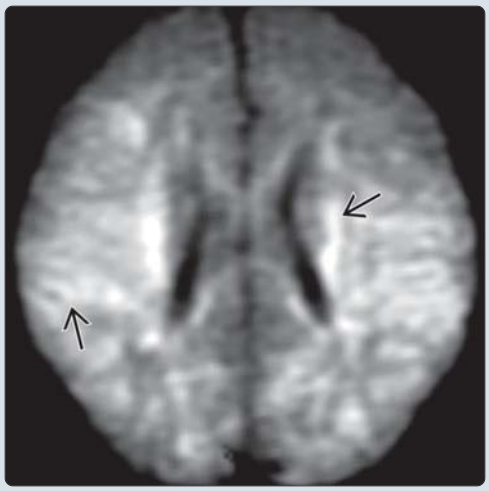

(Left) *Axial NECT in a neonate with HSV-2 encephalitis demonstrates widespread regions of gray and white matter hypoattenuation. The initial NECT will be negative in up to 27% of infected neonates.* **(Right)** *Axial DWI MR in a 2 week old with seizures & bulging fontanelle demonstrates extensive bihemispheric reduced diffusion involving gray and white matter structures in a random widespread manner. Increased IgM & positive PCR against HSV were detected. DWI is essential for early detection.*

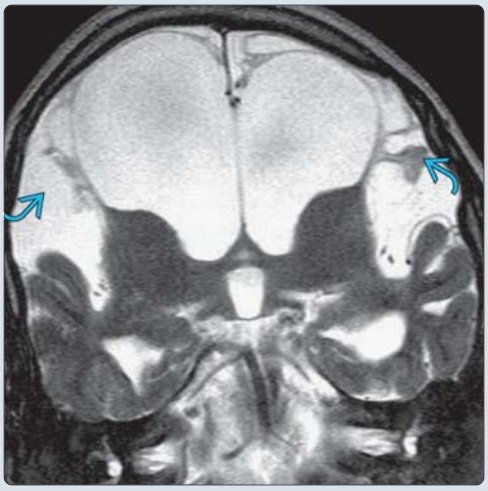

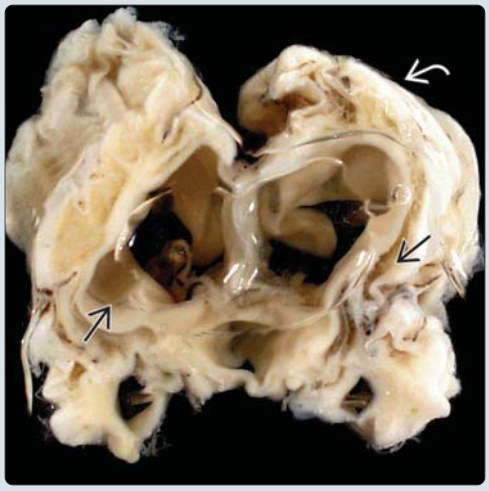

(Left) *Coronal T2 MR in an infant who had HSV-2 peripartum encephalitis demonstrates extensive bihemispheric cystic encephalomalacia with marked ex vacuo dilatation of the lateral ventricles* **(Right)** *Coronal gross pathology section shows a neonatal brain with changes of vertically transmitted HSV-2 infection, including ventricular dilation, cystic encephalomalacia, and lack of normal cortical sulcation. About 5% of neonatal HSV-2 is acquired in utero.*

https://CafePezeshki.IR

TERMINOLOGY

Abbreviations

- Neonatal HSV, HSV-2

IMAGING

General Features

- Best diagnostic clue
  - Variable brain involvement, early DWI abnormality
- Location
  - Variable: White matter (WM), gray matter (GM) (cortical, basal ganglia [BG]), temporal lobe, brainstem, cerebellum, ± watershed

CT Findings

- NECT
  - Early: Normal (27%), variable distribution, low attenuation
  - Late: Hydrocephalus, cysts, Ca++ (BG, thalami, cortex, or WM)

MR Findings

- T1WI
  - Early: Swelling, T1 hypointensity in affected regions
  - Late: Atrophy, cysts, ventriculomegaly, ± T1 shortening (Ca++)
- T2WI
  - Early: T2 hyperintensity (edema, neuronal necrosis), BG involved ~ 57%
  - Late: Cystic encephalomalacia, atrophy, WM hyperintensity
- T2* GRE
  - Hemorrhage less common than with HSV-1
- DWI
  - Restricted diffusion in affected regions
- T1WI C+
  - Patchy enhancement in affected regions, ± meningeal enhancement
- MRS
  - Acute: ↑ Cho, Glx, glutamine, ± lipid lactate, ↓ NAA
  - Chronic: All metabolites ↓

Ultrasonographic Findings

- Early: Linear echoes in BG
- Late: Multicystic encephalomalacia, ± Ca++

Imaging Recommendations

- Protocol advice
  - NECT, MR

DIFFERENTIAL DIAGNOSIS

Peripartum &/or Postnatal Infection

- Other bacterial and viral infections can mimic neonatal HSV

Stroke/Ischemia

- Arterial or venous infarction

Vertically Transmitted Infection, TORCH

- CMV → microcephaly, Ca++, cortical clefting or malformation
- Toxoplasmosis → scattered Ca++, hydrocephalus

PATHOLOGY

General Features

- Etiology
  - Transmission: Peripartum (85%), postnatal (10%), in utero (5%)

Staging, Grading, & Classification

- HSV infection acquired in the intrauterine, peripartum, or postnatal period is classified into the following types
  - Intrauterine infection
  - Disseminated disease
  - CNS disease

Gross Pathologic & Surgical Features

- Early: Meningoencephalitis, necrosis, ± hemorrhage, microglial proliferation
- Late: Atrophy, cysts, Ca++, ± hydranencephaly

CLINICAL ISSUES

Presentation

- Most common signs/symptoms
  - Postnatal: Lethargy, apnea, poor feeding, ± seizures, bulging fontanelle
  - In utero: Low birth weight, microcephaly, microphthalmia, ± mucous membrane ulceration
- Clinical profile
  - CSF: Pleocytosis (mononuclear cells), ↑ protein
  - EEG: Nonspecific

Demographics

- Age
  - Onset for peripartum infection → 2-4 weeks
- Epidemiology
  - Uncommon, estimated 1 in 3200 deliveries

Natural History & Prognosis

- Death in ~ 3 % of neonates with CNS disease and 29% with disseminated disease
- Survivors → cerebral palsy, seizures, mental retardation

Treatment

- C-section if active maternal infection, intravenous acyclovir

DIAGNOSTIC CHECKLIST

Consider

- HSV-2 in neonates with unexplained MR diffusion abnormalities

Image Interpretation Pearls

- Postnatal: Varied distribution, + DWI, ± hemorrhage
- In utero: Atrophy, scattered brain Ca++, cystic encephalomalacia, ventriculomegaly

SELECTED REFERENCES

1. Bajaj M et al: Clinical and neuroimaging findings in neonatal herpes simplex virus infection. J Pediatr. 165(2):404-407.e1, 2014
2. Pinninti SG et al: Neonatal herpes simplex virus infections. Pediatr Clin North Am. 60(2):351-65, 2013

https://CafePezeshki.IR

KEY FACTS

TERMINOLOGY

- GBS meningitis, group B β-hemolytic streptococcal meningitis
- Leading cause of newborn meningitis in developed countries

IMAGING

- Acute manifestations: Meningitis, cerebritis, vasculitis, ventriculitis, subdural effusion, empyema, arterial and venous infarction
- Arterial distributions often affected
- Variable: Dural, leptomeningeal, and parenchymal enhancement
- Ependymal enhancement and ventricular debris = ventriculitis
- Blurring/loss of gray-white matter junction → ± BG, thalamic, WM hyperintensities
- FLAIR hyperintensity in cortex, SAS, and subdural, cisternal, and ventricular spaces
- Diffusion restriction within infarcts and empyema
- Rim enhancement with subdural effusion (thinner) and empyema (thicker)
- Arterial narrowing, ± occlusions
- Dural venous sinus/cortical vein thrombosis ~ 30%
- MR with IV contrast, DWI, MRA, and MRV

TOP DIFFERENTIAL DIAGNOSES

- Enteric, gram-negative meningitis
- *Escherichia coli*: Along with GBS meningitis, major cause of newborn meningitis in developed countries
- Listeria monocytogenes: Gram-positive rod
- *Enterobacter*: Most common cause of meningitis in 1st few months of life

DIAGNOSTIC CHECKLIST

- No imaging features distinguish GBS meningitis from other neonatal meningitides

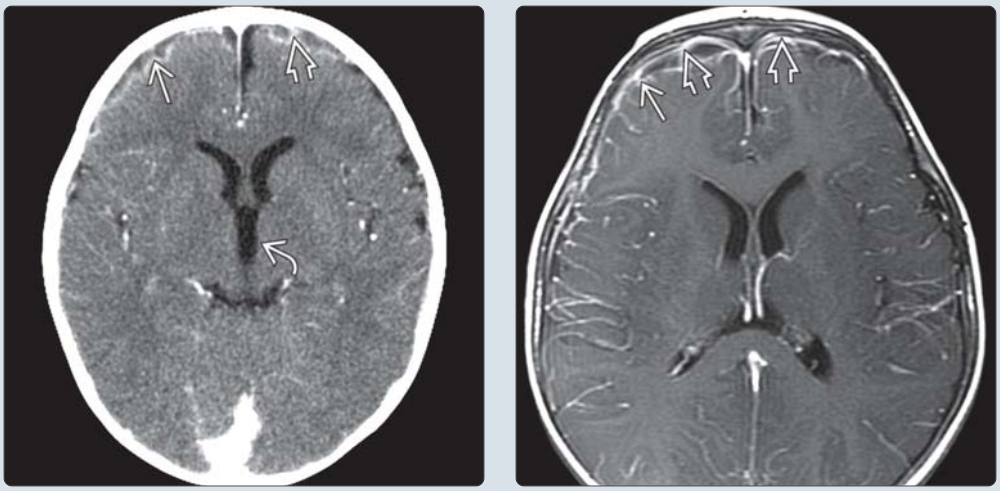

(Left) *Axial CECT in an infant with group B streptococcal meningitis shows cortical enhancement ➡ and leptomeningeal enhancement ➡. Note the dilation of the frontal horns and 3rd ventricle ➡ reflecting impeded CSF circulation.* **(Right)** *Axial T1WI C+ MR of the same patient, performed for evaluation of status epilepticus 24 hours following CECT, more clearly shows the peripheral frontal cortical ➡ and leptomeningeal enhancement ➡. CSF Gram stain showed gram-positive diplococci.*

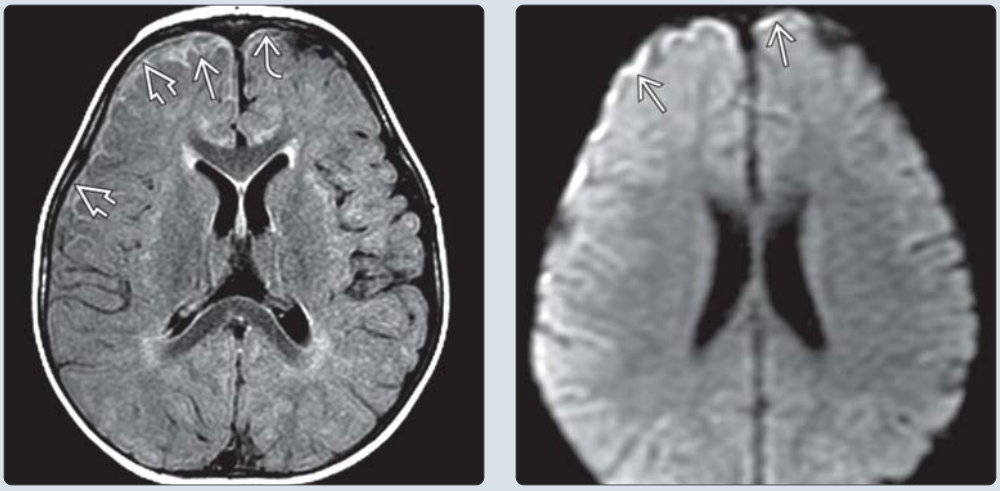

(Left) *Axial FLAIR MR is a sensitive tool to detect early complicated extraaxial fluid collections. FLAIR hyperintensity is seen in the right frontal cortex ➡ and within the right frontal temporal subarachnoid spaces ➡. Note the early involvement of the left frontal subarachnoid space ➡.* **(Right)** *Axial DWI MR in the same patient with meningitis helps to differentiate subdural effusions from subdural empyemas. These bifrontal hyperintense subdural collections ➡ showed low ADC values.*

https://CafePezeshki.IR

TERMINOLOGY

Abbreviations

- Group B streptococcal (GBS) meningitis

Synonyms

- Group B β-hemolytic streptococcal meningitis

Definitions

- Leading cause of newborn meningitis in developed countries
  - Early-onset disease (EOD): GBS sepsis presenting in 1st week of life
  - Late-onset disease (LOD): GBS sepsis presenting between 1-4 weeks of life

IMAGING

General Features

- Best diagnostic clue
  - Meningoencephalitis in newborn
- Location
  - Leptomeninges, cerebral hemispheres, and deep gray matter
- Morphology
  - Multifocal involvement
  - Arterial distributions often affected, particularly BG and thalami
- Acute manifestations: Meningitis, cerebritis, vasculitis, ventriculitis, subdural effusion, empyema, arterial and venous infarction
- Chronic sequelae: Loculated hydrocephalus, cystic encephalomalacia

CT Findings

- NECT
  - Hydrocephalus ± dependent debris in ventricles
  - Hypodensities in arterial distributions, BG, thalami, white matter (WM)
  - Occasional hyperdense foci = hemorrhagic venous infarcts, laminar necrosis
  - Hypodense subdural collections (effusion vs. empyema)
- CECT
  - Variable: Dural, leptomeningeal, and parenchymal enhancement
    - Rim enhancement around subdural effusions and empyemas
  - Ependymal enhancement/ventricular debris

MR Findings

- T1WI
  - Hypo- and hyperintense foci common
    - Multifocal hypointensities = edema, ischemia, infarction
    - Hyperintense foci cortex, BG, and WM = laminar necrosis, hemorrhagic venous infarction
- T2WI
  - Blurring/loss of gray-white matter junction, ± BG, thalamic and WM hyperintensity
- FLAIR
  - Hyperintensity in cortex and subarachnoid, subdural, cisternal, and ventricular spaces
- T2* GRE
  - Blooming of hemorrhagic foci
- DWI
  - Diffusion reduced in infarcts, pus collections
- T1WI C+
  - Variable: Dural, leptomeningeal, parenchymal, and ependymal enhancement
  - Rim enhancement with subdural effusion (thinner) and empyema (thicker)
- MRA
  - Arterial narrowing, ± occlusions
- MRV
  - Dural venous sinus/cortical vein thrombosis (in up to 30%)
- MRS
  - ↑ choline, ↓ NAA; increased lactate in areas of ischemia/infarction

Ultrasonographic Findings

- Grayscale ultrasound
  - ↑ echogenicity of sulci and parenchyma → hydrocephalus → ventricular debris

Imaging Recommendations

- Best imaging tool
  - MR with IV contrast, DWI, MRA, and MRV
- Protocol advice
  - CECT for rapid, initial assessment of hemodynamically unstable neonate

DIFFERENTIAL DIAGNOSIS

Other Neonatal Meningitides

- Enteric, gram-negative meningitis
  - Account for majority of early-onset meningitis in developing countries
  - Higher mortality than GBS meningitis
  - Specific pathogens
    - *Escherichia coli*: Major cause of newborn meningitis in developed countries (along with GBS meningitis)
    - *Enterobacter*: Most common cause of meningitis in 1st few months of life
    - *Citrobacter*: Rare; high morbidity/mortality secondary to frequent abscess formation
- Other meningitides
  - Listeria monocytogenes: Gram-positive rod

Congenital Infections (TORCH)

- CMV, toxoplasmosis, rubella: Infection occurs in utero with chronic sequelae present in neonate/infant
  - CMV: Periventricular Ca++, microcephaly, migrational abnormalities, encephalomalacia, cerebellar hypoplasia
  - Toxoplasmosis: Parenchymal Ca++, encephalomalacia, microphthalmia
- Herpes simplex virus type 2 (HSV-2): Infection acquired during vaginal birth; presents in 1st 2-4 weeks of life
  - Meningoencephalitis with extensive edema, necrosis, late cystic encephalomalacia

Hypoxic-Ischemic Encephalopathy

- Preterm: Injury to periventricular WM (mild) or thalami, basal ganglia, brainstem (severe)

https://CafePezeshki.IR

- Term: Injury to mature vascular watershed (mild) or areas of early myelination/metabolic activity (severe)

PATHOLOGY

General Features

- Etiology
  - EOD: Aspiration of infected amniotic fluid or birth canal secretions
  - LOD: As EOD or postnatal maternal contact, breast milk, nosocomial
  - Bacteremia facilitated by immature neonatal immune system
  - Development of meningitis related to magnitude/duration of bacteremia
  - Production of β-hemolysin facilitates access of GBS across blood-brain barrier
- GBS agalactiae serotype 3 responsible for majority of GBS meningitis
- GBS is potent activator of neonatal immune/inflammatory response

Gross Pathologic & Surgical Features

- Debris, exudates within subarachnoid spaces and ventricles
- Parenchymal infarction/encephalomalacia; luminal narrowing of vessels

Microscopic Features

- Inflammation of adventitia and vaso vasorum = vasculitis

CLINICAL ISSUES

Presentation

- Most common signs/symptoms
  - Lethargy, poor feeding, irritability
  - Seizures (40%) and bulging fontanelle are typically late findings
- Clinical profile
  - Newborn with sepsis
  - Typical signs/symptoms of meningitis subtle or absent in neonate
- CSF analysis: ↑ WBCs, ↑ protein, ↓ glucose
- CSF/blood Gram stain: Gram-positive diplococci
- Maternal risk factors for EOD: GBS colonization, GBS chorioamnionitis/bacteruria, membrane rupture > 18 hours, intrapartum fever ≥ 38°C, previous newborn with EOD, delivery at < 37 weeks gestation

Demographics

- Age
  - 90% of newborns with GBS EOD present within 1st 24 hours of life
  - GBS LOD presents between 1-4 weeks after birth; occasionally up to 6 months
- Gender
  - Male, preterm infants (< 37 weeks) most at risk for EOD
- Ethnicity
  - Maternal GBS colonization rates highest in African American women
- Epidemiology
  - 10-30% of pregnant women have asymptomatic GBS colonization of genital/GI tract
    - < 1% of newborns born to colonized women develop EOD
  - EOD incidence: 0.5/1,000 live births
    - Incidence decreased by > 50% as result of maternal screening and intrapartum chemoprophylaxis
    - ↓ incidence of GBS EOD accompanied by ↑ incidence of neonatal gram-negative sepsis
    - Term infants account for 50% of GBS EOD secondary to preterm intrapartum chemoprophylaxis

Natural History & Prognosis

- Prognosis
  - Mortality of early-onset disease
    - Full-term newborns (2%), 34-36 weeks gestational age (10%), < 33 weeks gestational age (30%)
  - Morbidity meningitis: Neurological sequelae (12-30%) (cortical blindness, spasticity, global mental retardation)

Treatment

- Maternal
  - GBS screen: Rectovaginal swab at 35-37 weeks gestation
  - Positive maternal GBS screen or presence of other risk factors: Intrapartum IV penicillin
  - Future strategies
    - GBS PCR assay and rapid *Streptococcus* screen at onset of labor
    - GBS vaccine: Ideal prevention strategy; would prevent development of antibiotic-resistant pathogens
- Neonatal meningitis
  - High-dose IV penicillin → ± antiepileptics → CSF diversion may be required for complicated hydrocephalus

DIAGNOSTIC CHECKLIST

Image Interpretation Pearls

- No imaging features distinguish GBS meningitis from other neonatal meningitides

SELECTED REFERENCES

1. Simonsen KA et al: Early-onset neonatal sepsis. Clin Microbiol Rev. 27(1):21-47, 2014
2. Tan YC et al: Treatment strategies for central nervous system infections: an update. Expert Opin Pharmacother. 1-17, 2014
3. Baker CJ: The spectrum of perinatal group B streptococcal disease. Vaccine. 31 Suppl 4:D3-6, 2013
4. Berardi A et al: Group B streptococcus late-onset disease: 2003-2010. Pediatrics. 131(2):e361-8, 2013
5. Hernández MI et al: Stroke patterns in neonatal group B streptococcal meningitis. Pediatr Neurol. 44(4):282-8, 2011
6. Thigpen MC et al: Bacterial meningitis in the United States, 1998-2007. N Engl J Med. 364(21):2016-25, 2011
7. Hamada S et al: Neonatal group B streptococcal disease: incidence, presentation, and mortality. J Matern Fetal Neonatal Med. 21(1):53-7, 2008
8. Yikilmaz A et al: Sonographic findings in bacterial meningitis in neonates and young infants. Pediatr Radiol. 38(2):129-37, 2008
9. Smirniotopoulos JG et al: Patterns of contrast enhancement in the brain and meninges. Radiographics. 27(2):525-51, 2007

https://CafePezeshki.IR

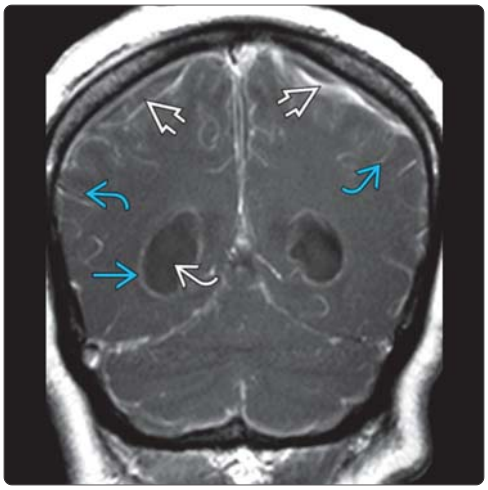

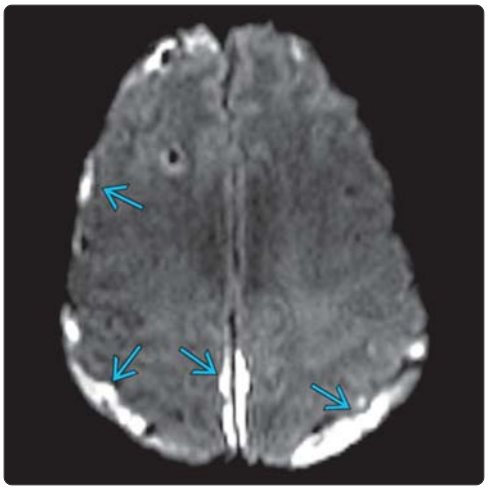

(Left) *Coronal T1 C+ MR in group B streptococcal meningitis shows extensive leptomeningeal enhancement. Ependymal enhancement with ventricular debris is due to a ventriculitis. Note extraaxial collections with rim enhancement.* **(Right)** *Axial DWI MR in the same patient shows restricted diffusion in the subdural collections consistent with empyemas. DWI helps to differentiate reactive subdural effusions from empyemas.*

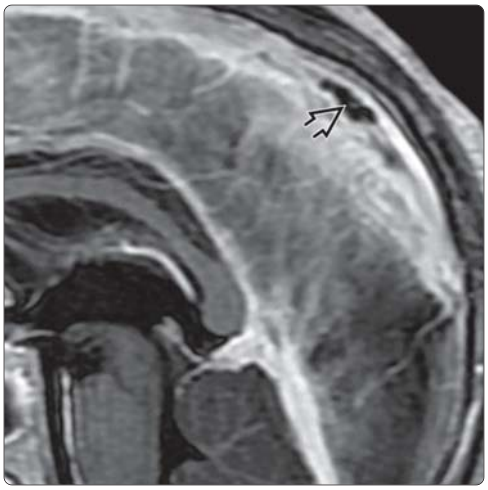

(Left) *Axial T1WI C+ MR shows extensive leptomeningeal enhancement. Note the ventricular ependymal enhancement, dependent ventricular debris (ventriculitis), and basal ganglia enhancement due to perivascular space inflammation/arteritis. Ventricular dilation reflects early hydrocephalus.* **(Right)** *Sagittal MRV with contrast shows a hypointense clot within the sagittal sinus, creating a partial occlusion. Small clots were also detected in the transverse sinuses.*

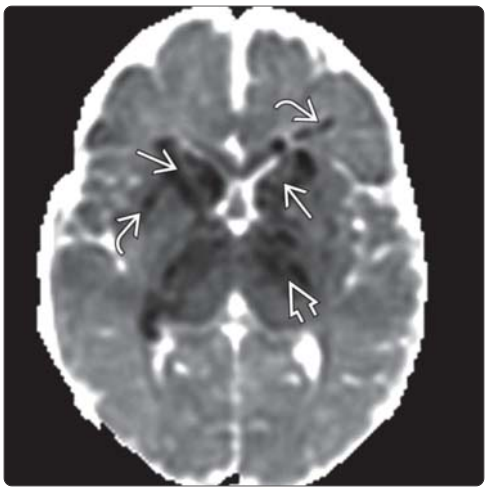

(Left) *Axial T2WI MR demonstrates focal basal ganglia, thalamic, and white matter hyperintensities, reflecting infarction secondary to perivascular space inflammatory involvement/arteritis.* **(Right)** *Axial ADC in the same patient shows multiple basal ganglia and thalamic infarctions. Note the scattered white matter infarctions. Early detection of infarction is best achieved with diffusion imaging when T2 and FLAIR images may be "normal."*

https://CafePezeshki.IR

KEY FACTS

IMAGING

- Multiple, large, cystic white matter (WM) lesions
- Predilection for lobar white matter
- ± diffuse pneumocephalus (due to gas production)
- Square morphology of abscesses
- Rim or dot-like septal enhancement
- Best imaging tool: MR with contrast

TOP DIFFERENTIAL DIAGNOSES

- Other bacterial brain infections
- Periventricular white matter injury
- Cystic encephalomalacia
- White matter lacerations in nonaccidental head injury

PATHOLOGY

- Infection acquired: Horizontally (nosocomial) or vertically (maternal)
- Colonization (skin, umbilicus stump) → bacteremia → meningitis

CLINICAL ISSUES

- Immunocompromised patients at higher risk
- Neonates & sick preterms are immunocompromised
- Preterm newborns are most susceptible
- 5% of neonatal (gram-negative) meningitis → 80% of neonatal brain abscesses
- Abscesses may only appear near completion of therapy
- 80% of neonates with *Citrobacter* meningitis develop brain abscesses

DIAGNOSTIC CHECKLIST

- Square WM abscesses with rim or dot-like septal enhancement

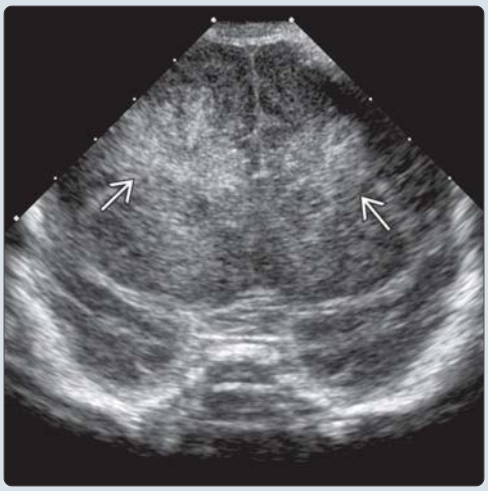

(Left) *Coronal cranial ultrasound in a newborn with Citrobacter sepsis shows bilateral frontal lobe white matter hyperechogenicity corresponding to regions of cerebritis on earlier MR (not shown). (Courtesy C. Glasier, MD.)* **(Right)** *Axial T1WI MR in a newborn with peripartum Citrobacter sepsis shows bifrontal "square" cavitary white matter abscesses. These cavitary lesions progressed from foci of cerebritis. Note the necrotic debris within the cavities. (Courtesy C. Glasier, MD.)*

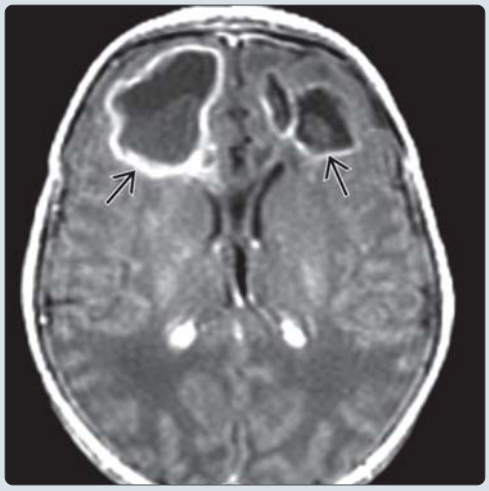

(Left) *Axial DWI MR in the same patient demonstrates reduced diffusivity (increased signal intensity) within the dependent infected debris. (Courtesy C. Glasier, MD.)* **(Right)** *Axial T1 C+ MR in the same patient shows rim enhancement of the abscesses. Dot-like septal enhancement within the abscesses is another finding that may be seen on CECT or T1WI C+ MR. (Courtesy C. Glasier, MD.)*

https://CafePezeshki.IR

TERMINOLOGY

Synonyms

- *Citrobacter* cerebritis

Definitions

- Gram-negative enteric bacterium infection

IMAGING

General Features

- Best diagnostic clue
  - Multiple, large, cystic white matter (WM) lesions
  - "Polygonal" abscesses from complete replacement of WM; border parallels cortex
    - Increasing mass effect/edema more likely to have infected contents
    - "Rounding" of edges suggests increased pressure/active infection
- Location
  - Predilection for lobar white matter
- Size
  - Multiple large WM cysts
- Morphology
  - Polygonal abscesses

CT Findings

- NECT
  - Early (cerebritis)
    - Patchy, multilobar WM lesions
    - Low attenuation compared to unmyelinated brain
    - ± diffuse pneumocephalus (due to gas production)
  - Late (abscess)
    - Lobar WM cavities with septations
    - Square morphology of abscesses
    - Dot-like focus of septal Ca++
- CECT
  - Early (cerebritis)
    - Variable, often subtle parenchymal enhancement
  - Late (abscess)
    - Rim or dot-like septal enhancement
    - Multiple large cavities (± septations), replace WM

MR Findings

- T1WI
  - Early (cerebritis)
    - Patchy multilobar areas of T1 hypointensity
  - Late (abscess)
    - Multiple large cysts
    - Square morphology
    - Septations
    - T1 WM signal abnormality diminishes
- T2WI
  - Early (cerebritis)
    - Patchy multilobar T2 hyperintensity
  - Late (abscess)
    - Multiple, often septated cavities
    - Usually bilateral
    - Extensive T2 hyperintensity within WM
    - Variable edema, mass effect
    - Eventually, cavities may contract, causing profound WM loss
- FLAIR
  - Increased signal within lobar WM
- T2* GRE
  - Dot-like Ca++ within septal walls shows diminished signal
- T1WI C+
  - Early (cerebritis)
    - Subtle patchy WM enhancement
  - Late (abscess)
    - Patchy WM enhancement
    - Rim or septal wall enhancement
    - Dot-like focus of septal enhancement
- MRS
  - Products of fermentation
    - Lactate (1.3 ppm) , acetate (1.9 ppm), and succinate (2.4 ppm)
  - Proteolysis end products released from neutrophils
    - Valine and leucine (0.9 ppm)

Ultrasonographic Findings

- Grayscale ultrasound
  - Early (meningitis/cerebritis)
    - Sulcal thickening and increased sulcal echogenicity
    - Regions of WM hyperechogenicity
    - Loss of normal WM echo architecture
  - Late (abscess)
    - Multiple, septated, WM, anechoic, or hypoechoic cavities
- Color Doppler
  - Subtle flow within abscess septal walls

Imaging Recommendations

- Best imaging tool
  - MR with contrast best depicts location and severity of involvement
- Protocol advice
  - MR with contrast
    - Shows early parenchymal enhancement of cerebritis
    - Reveals dot-like foci of septal enhancement of "squared" abscesses
    - Detects complications of brain infection (vascular, extraaxial purulent collections)

DIFFERENTIAL DIAGNOSIS

Other Bacterial Brain Infections

- Usually with greater surrounding edema and mass effect
- Search for possible sinus, mastoid, or embolic/hematogenous sources of infection

Periventricular Leukomalacia

- Perifrontal and peritrigonal locations of WM cysts
- Slower progression of cystic change
- No rim or septal "dot" enhancement

Cystic Encephalomalacia

- Cortical and deep gray matter involved
- Thalamic and basal ganglia Ca++
- Cysts replaces WM
- Passive ventricular dilatation

https://CafePezeshki.IR

White Matter Lacerations in Nonaccidental Head Injury (NAHI)

- Frontal lobe WM
- Fluid level may be seen dependently within laceration
- Associated intracranial manifestations of NAHI
  - Parafalcine/convexity subdural hematoma, subarachnoid hemorrhage

PATHOLOGY

General Features

- Etiology
  - Neurovirulence factors of *Citrobacter* species
    - Unique 32-kD outer membrane protein
    - Resistance to phagocytosis
  - *Citrobacter* invades/transcytoses microvascular endothelial cells
    - Leads to hemorrhagic necrosis and abscess
  - Intracellular replication of *Citrobacter* in microvascular endothelial cells
    - Contributes to persistence of brain infection and cavitation
- Associated abnormalities
  - Infection acquired: Horizontally (nosocomial) or vertically (maternal)
  - Colonization (skin, umbilicus stump) → bacteremia → meningitis
  - *Citrobacter* is facultative anaerobe
    - Hydrolyzes urea and ferments glucose → produces gas

Gross Pathologic & Surgical Features

- Opaque leptomeninges, purulent exudate
- Diffuse ependymitis

Microscopic Features

- No well-formed fibrotic capsule
- Organisms in walls of congested vessels
- Neutrophils plus necrotic cell debris

CLINICAL ISSUES

Presentation

- Most common signs/symptoms
  - Septic newborn or preterm infant: Bulging fontanelle, apnea, seizures
- Clinical profile
  - In very premature neonates
    - Sepsis, irritability, poor feeding, bulging fontanelle
  - Immunocompromised patients at higher risk
    - Neonates, sick preterms are immunocompromised

Demographics

- Age
  - Predilection for very young, very old patients
    - Newborns → sepsis, meningitis, and cerebral abscesses
    - Elderly → causes urinary, upper respiratory tract infections
  - Mean age of sepsis onset: 5 days
  - Preterm newborns are most susceptible
  - Citrobacter CNS infection beyond 1 month of age is rare
- Epidemiology
  - *Citrobacter* infection
    - 5% of neonatal (gram-negative) meningitis → 80% of neonatal brain abscesses
    - Abscesses may only appear near completion of therapy
  - *Citrobacter* CNS infection
    - Most cases considered sporadic ↔ neonatal ICU outbreaks do occur

Natural History & Prognosis

- 30% of neonates and infants with *Citrobacter* CNS infection die
- 80% of neonates with *Citrobacter* meningitis develop brain abscesses
- 50% of *Citrobacter* meningitis/abscess survivors have significant CNS damage

Treatment

- Antibiotics are mainstay of therapy
- Late abscesses occur, and prolonged IV therapy is rule
- Adjunctive surgical drainage of abscesses
  - For enlarging cysts on optimized IV therapy
  - Poorly responsive to initial antibiotic therapy

DIAGNOSTIC CHECKLIST

Image Interpretation Pearls

- Minimal edema surrounding abscesses
- Square abscesses with focal septal enhancement
- Not all rim-enhancing cavities are abscesses
  - Some are WM necrosis and liquefaction
- *Citrobacter* species and *Cronobacter sakazakii* have similar imaging

SELECTED REFERENCES

1. Nuñez Cuadros E et al: Medical and neurosurgical management of Citrobacter koseri, a rare cause of neonatal meningitis. J Med Microbiol. 63(Pt 1):144-7, 2014
2. Plakkal N et al: Citrobacter freundii brain abscess in a preterm infant: a case report and literature review. Pediatr Neonatol. 54(2):137-40, 2013
3. Vaz Marecos C et al: Sepsis, meningitis and cerebral abscesses caused by Citrobacter koseri. BMJ Case Rep. 2012, 2012
4. Martínez-Lage JF et al: Citrobacter koseri meningitis: a neurosurgical condition? Eur J Paediatr Neurol. 14(4):360-3, 2010
5. Samonis G et al: Citrobacter infections in a general hospital: characteristics and outcomes. Eur J Clin Microbiol Infect Dis. 28(1):61-8, 2009
6. Benca J et al: Nosocomial meningitis caused by Enterobacteriaceae: risk factors and outcome in 18 cases in 1992-2007. Neuro Endocrinol Lett. 28 Suppl 2:27-9, 2007
7. Alviedo JN et al: Diffuse pneumocephalus in neonatal Citrobacter meningitis. Pediatrics. 118(5):e1576-9, 2006
8. Agrawal D et al: Vertically acquired neonatal citrobacter brain abscess - case report and review of the literature. J Clin Neurosci. 12(2):188-90, 2005
9. Pooboni SK et al: Pneumocephalus in neonatal meningitis: diffuse, necrotizing meningo-encephalitis in Citrobacter meningitis presenting with pneumatosis oculi and pneumocephalus. Pediatr Crit Care Med. 5(4):393-5, 2004
10. Badger JL et al: Citrobacter freundii invades and replicates in human brain microvascular endothelial cells. Infect Immun. 67(8):4208-15, 1999
11. Doran TI: The role of Citrobacter in clinical disease of children: review. Clin Infect Dis. 28(2):384-94, 1999
12. Meier A et al: Neonatal citrobacter meningitis: neurosonographic observations. J Ultrasound Med. 17(6):399-401, 1998

https://CafePezeshki.IR

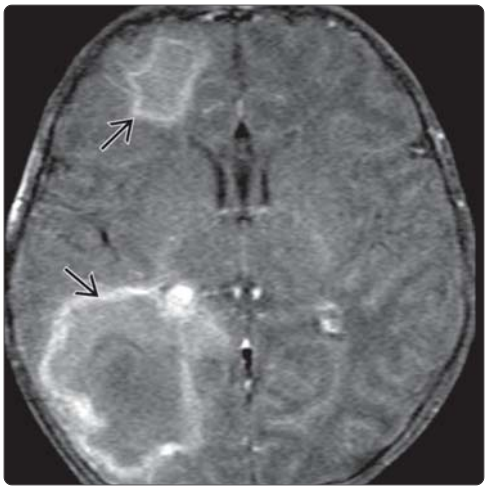

(Left) *Axial T2WI MR in a 1 month old with neonatal Citrobacter sepsis demonstrates a large cavitary right parietooccipital abscess ➡ with dependent debris ⇨. Note the developing small right frontal lobe abscess ➡, which is just starting to cavitate. (Courtesy L. Lowe, MD.)* **(Right)** *Rim enhancement ⇨ of a more mature parietooccipital and less mature frontal abscess is seen. Progression from meningitis to cerebritis to abscess is common (~ 80%). (Courtesy L. Lowe, MD.)*

(Left) *Axial T1WI C+ MR in an infant with "treated" Citrobacter meningitis demonstrates large bilateral parietooccipital rim-enhancing abscesses ➡. Note the associated ependymal thickening and enhancement reflecting ventriculitis ⇨. (Courtesy T. Booth, MD.)* **(Right)** *In this newborn with "treated" Citrobacter meningitis, bilateral frontal ➡ and right peritrigonal ⇨ rim-enhancing abscesses are seen. Long-term IV therapy is the rule in such cases. (Courtesy T. Feygin, MD.)*

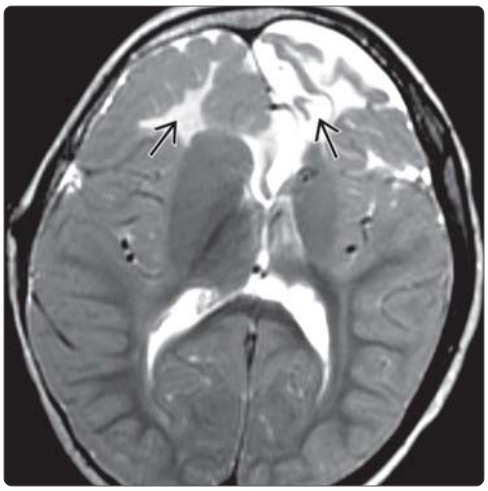

(Left) *Axial T2WI MR in a 1 year old with refractory seizures remote from long-term IV therapy for Citrobacter brain abscesses shows bilateral frontal retraction cavities, gliosis, and atrophy ⇨. (Courtesy C. Glasier, MD.)* **(Right)** *Axial NECT in an infant originally diagnosed with Citrobacter sepsis and meningitis shows that the meningitis has progressed. Note the multifocal cerebral abscesses lead to macrocystic encephalomalacia and multiple septated cavities ➡. (Courtesy S. Gorges, MD.)*

https://CafePezeshki.IR

KEY FACTS

TERMINOLOGY

- Acute or chronic inflammatory infiltration of pia, arachnoid, and CSF
- Classified as acute pyogenic (bacterial), lymphocytic (viral), chronic (tuberculosis or granulomatous)

IMAGING

- Imaging best delineates complications: Empyema, ischemia, hydrocephalus, cerebritis/abscess, ventriculitis
- FLAIR MR: Hyperintense signal in sulci, cisterns
- T1WI C+: Exudate and brain surface (pia) enhance
- Delayed C+ FLAIR most sensitive sequence for leptomeningeal disease
- DWI: Invaluable for detecting complications
- Basilar meningitis typical of pyogenic infections, TB, cryptococcosis, neurosyphilis, sarcoid, lymphoma
- Meningitis is clinical/laboratory diagnosis, not imaging diagnosis
  - Can occur in presence of normal imaging

TOP DIFFERENTIAL DIAGNOSES

- Carcinomatous meningitis
- Neurosarcoidosis
- Increased FLAIR signal in CSF (SAH, high inspired oxygen, artifact, venous congestion from stroke)

PATHOLOGY

- Hematogenous spread from remote infection (i.e., heart, teeth) is most common etiology

CLINICAL ISSUES

- Adults: Headache, fever, nuchal rigidity, ± altered mental status
- Children: Fever, irritability, nuchal rigidity
- Infants: Fever, lethargy, irritability
- Intravenous antibiotics are mainstay of therapy
- Empiric therapy based on age
- Specific therapy based on culture and sensitivity

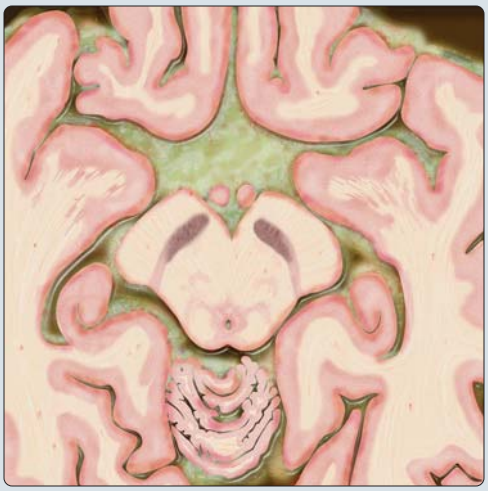

(Left) *Axial graphic shows diffuse inflammatory exudate that involves the leptomeninges and fills the basal cisterns and sulci. This typically results in increased density on CT or T1 signal intensity on MR. It is important to remember that meningitis is a clinical/laboratory diagnosis, not an imaging diagnosis.* **(Right)** *Autopsy case shows changes of severe meningitis with dense purulent exudate covering the pons and filling the basal cisterns. (Courtesy R. Hewlett, MD.)*

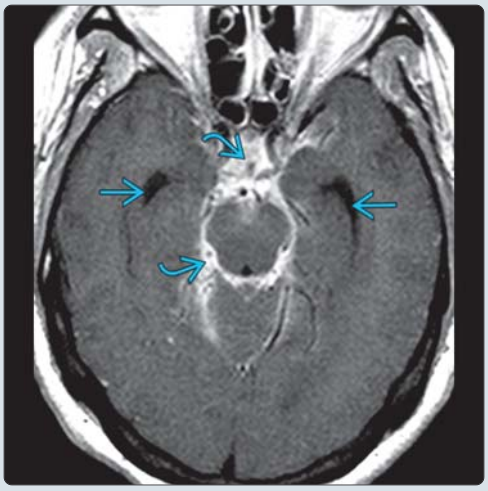

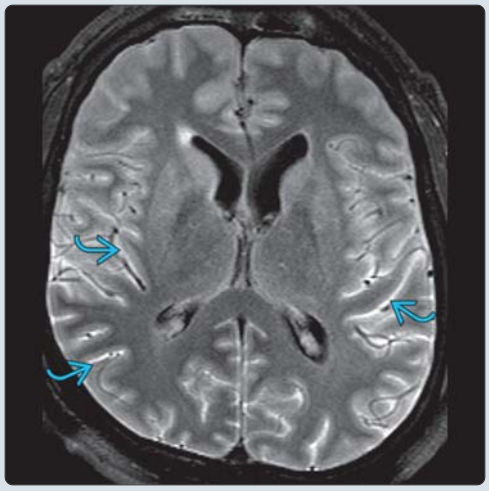

(Left) *Axial T1WI C+ MR in a patient with TB meningitis shows extensive cisternal enhancement, as well as early hydrocephalus.* **(Right)** *Axial FLAIR MR in a 24-year-old man with headache, fever, and vomiting demonstrates extensive high signal in the sulci due to a pyogenic meningitis. Axial FLAIR, T1 +C and DWI are important sequences in evaluation of a patient with suspected meningitis.*

https://CafePezeshki.IR

TERMINOLOGY

Synonyms

- Leptomeningitis; infectious meningitis

Definitions

- Acute or chronic inflammatory infiltration of pia, arachnoid, and CSF
- Classified as acute pyogenic (bacterial), lymphocytic (viral), chronic (tubercular or granulomatous)

IMAGING

General Features

- Best diagnostic clue
  - Positive CSF by lumbar puncture
- Location
  - Pia, arachnoid, and subarachnoid space of brain and spine
- Morphology
  - Typically smooth ± thick, intense sulcal-cisternal enhancement
  - Tuberculosis (TB), fungal meningitis often basilar/confluent; may be nodular
- Imaging may be normal early
- Imaging best delineates complications
  - Hydrocephalus: Mild transient communicating most common
  - Extraaxial fluid collections: Sterile (effusions) or infected/purulent (empyema)
  - Cerebritis/abscess
  - Ventriculitis
  - Arterial narrowing/occlusions, venous thrombosis & associated infarcts

CT Findings

- NECT
  - Most common = normal
  - Mild ventricular enlargement common
  - Sulci, basal cisterns may appear effaced
  - May see increased density in basilar cisterns or sylvian fissures related to inflammatory debris simulating subarachnoid hemorrhage
  - ± subdural effusion in pediatric patients
- CECT
  - Enhancing exudate in sulci, cisterns
  - Low-density areas related to ischemic complications
- CTA
  - Arterial narrowing, occlusion may be seen

MR Findings

- T1WI: Isointense exudate
- T2WI: Hyperintense exudate
- FLAIR: Hyperintense signal in sulci, cisterns (nonspecific)
  - May see hydrocephalus
- DWI: Useful to detect infarcts (2° to vascular complications), empyema, abscess, ventriculitis
- T1WI C+: Exudate and brain surface (pia) enhance
  - Characterizes complications
- MRA: May see arterial narrowing or occlusion
- MRV: May see venous thrombosis
- MRS: Helpful for evaluation of complications
  - e.g., cerebritis, abscess, infarct

Ultrasonographic Findings

- Sulcal enlargement, echogenic deposits in subarachnoid space in infants
- Ventricular dilatation and subdural collections

Imaging Recommendations

- Best imaging tool
  - Contrast-enhanced MR + DWI: Best to evaluate complications
- Protocol advice
  - MR with FLAIR, DWI, T1WI C+
  - Delayed enhanced FLAIR most sensitive sequence for leptomeningeal disease

DIFFERENTIAL DIAGNOSIS

Carcinomatous Meningitis

- Primary tumor often known (exception = lymphoma)
- Breast, lung most common extracranial sources
- Primary CNS tumors: GBM, medulloblastoma, pineal/choroid plexus tumors, PNET, ATRT, ependymoma

Neurosarcoidosis

- Lacy leptomeningeal enhancement
- May have ventricular or dural-based enhancing masses

Increased FLAIR Signal in CSF

- Nonspecific; many causes
  - Subarachnoid hemorrhage (SAH)
  - High inspired oxygen
  - Artifact
  - Acute stroke (parenchymal edema, vascular congestion)
  - Retained gadolinium in CSF: Dialysis-dependent patient with end-stage renal disease

PATHOLOGY

General Features

- Etiology
  - Hematogenous (most common)
    - Spread from remote infection (heart, teeth, etc.)
    - Some may enter CNS via choroid plexus (lacks blood-brain barrier)
  - Direct extension
    - Less common
    - Sinusitis, otitis media, orbital infection
    - Skull base fracture
  - Penetrating injury (least common)
  - Basilar meningitis typical of pyogenic infections, TB, cryptococcosis, neurosyphilis, sarcoid, lymphoma
- Associated abnormalities
  - Complications
    - Extraventricular obstructive hydrocephalus (EVOH)
    - Ventriculitis, choroid plexitis
    - Cerebritis, abscess
    - Subdural fluid collections (empyema, effusion)
  - Cerebrovascular complications
    - Venous and arterial thrombosis
    - Ischemia/infarct

https://CafePezeshki.IR

Gross Pathologic & Surgical Features

- Gross pathology generally same regardless of agent
- Cisterns, sulci filled with cloudy CSF, then purulent exudate
- Pia-arachnoid congested, may mimic SAH
- Cortex may be edematous

Microscopic Features

- Meningeal exudate: Neutrophils, fibrin, bacteria
- Vessels within exudate may show fibrinoid necrosis, thrombosis
- Infection may extend into perivascular spaces (PVSs), ventricles
  - PVSs may act as conduit for infection to reach brain parenchyma
- May spread by direct invasion of pia
- Subpial, microglial, astrocytic proliferation

CLINICAL ISSUES

Presentation

- Most common signs/symptoms
  - Adults: Headache, fever, nuchal rigidity, ± altered mental status
    - Brudzinski sign: Hips and knees flex involuntarily when neck is flexed
    - Kernig sign: Flex hips and knees, try to extend knees = pain in hamstrings, patient resistance
  - Children: Fever, headache, photophobia, vomiting, irritability, nuchal rigidity
  - Infants: Fever, lethargy, irritability
  - Seizures in 30%
  - Meningitis is clinical/laboratory diagnosis, not imaging diagnosis
- Clinical profile
  - CSF shows increased white blood cells (leukocytosis)
    - Elevated CSF protein, decreased glucose typical of infectious meningitis
  - Purpuric rash may develop in *Neisseria meningitidis* (meningococcal) meningitis, highly morbid

Demographics

- Epidemiology
  - Bacterial meningitis increase in last 30 years related to nosocomial infection
    - ~ 3/100,000 in USA
  - Meningitis is most common form of CNS infection in children
  - Incidence of bacteria based on age
    - Elderly: *Listeria monocytogenes*, *S. pneumoniae*, *N. meningitidis*, gram-negative bacilli
    - Adults: *S. pneumoniae*, *N. meningitidis*, group B *Streptococcus*
    - Children: *N. meningitidis*
    - Infants: *S. pneumoniae*, *N. meningitidis*
    - Neonates: Group B *Streptococcus*, *Escherichia coli*, *Enterobacter*
  - Vaccine has markedly decreased incidence of *H influenzae* meningitis
  - Viral meningitis: Enteroviruses most common
  - Chronic meningitis
    - TB most common
    - High morbidity, mortality despite treatment
  - Fungal meningitis: *Cryptococcus neoformans* (AIDS) and *Coccidioides immitis* most common

Natural History & Prognosis

- Effective antimicrobial agents have reduced but not eliminated mortality, morbidity
- Impaired CSF resorption may cause hydrocephalus
- Elevated intracranial pressure, cerebral perfusion alterations can be early complications
- Complications occur in 50% of adult patients
  - Infectious: Cerebritis/abscess, ventriculitis, empyema, effusion
  - Vascular: Ischemia related to arterial spasm or infectious arteritis, dural venous thrombosis
  - Labyrinthine ossificans is uncommon complication
    - Infection of labyrinth via cochlear aqueduct from subarachnoid space
    - Typically results in bilateral hearing loss
- Mortality up to 25%

Treatment

- Intravenous antibiotics
  - Empiric therapy based on age
  - Specific therapy based on culture and sensitivity
  - Most bacterial meningitides: Ceftriaxone or cefotaxime ± vancomycin is treatment of choice
  - Fungal meningitis: Amphotericin B ± fluconazole or flucytosine
  - TB meningitis requires combination therapy: Isoniazid, pyrazinamide, rifampin
  - Viral meningitis: Supportive care, except for herpes meningitis (acyclovir)
- Surgery for complications (hydrocephalus, empyema)

DIAGNOSTIC CHECKLIST

Consider

- Imaging may be normal, most useful for complications

Image Interpretation Pearls

- Meningitis is clinical/laboratory diagnosis, not imaging diagnosis
  - Can occur in presence of normal imaging
- T1WI C+, FLAIR often complementary in diagnosis
- DWI invaluable for detecting complications of meningitis

SELECTED REFERENCES

1. Oliveira CR et al: Brain magnetic resonance imaging of infants with bacterial meningitis. J Pediatr. 165(1):134-9, 2014
2. Schoeman JF et al: Tuberculous meningitis. Handb Clin Neurol. 112:1135-8, 2013
3. Bartt R: Acute bacterial and viral meningitis. Continuum (Minneap Minn). 18(6 Infectious Disease):1255-70, 2012
4. Mohan S et al: Imaging of meningitis and ventriculitis. Neuroimaging Clin N Am. 22(4):557-83, 2012
5. Smirniotopoulos JG et al: Patterns of contrast enhancement in the brain and meninges. Radiographics. 27(2):525-51, 2007

https://CafePezeshki.IR

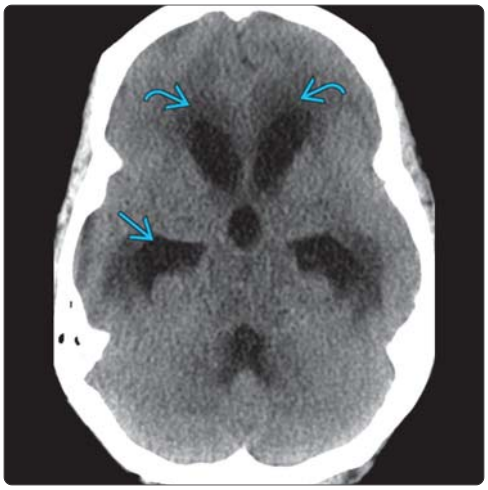

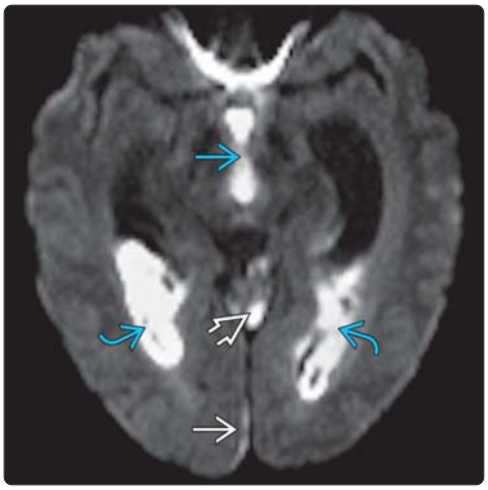

(Left) *NECT in a patient with pneumococcal meningitis shows communicating hydrocephalus* ⇨ *with periventricular low density* ⇨ *due to periventricular interstitial edema.* **(Right)** *Axial DWI MR in the same patient shows complications of meningitis. Restricted diffusion is seen in the 3rd ventricle* ⇨ *and occipital horns* ⇨ *due to ventriculitis. There is a small subdural empyema* ➡ *in the right occipital parasagittal region. Note high DWI signal due to exudates* ➡ *in the superior cerebellar cistern.*

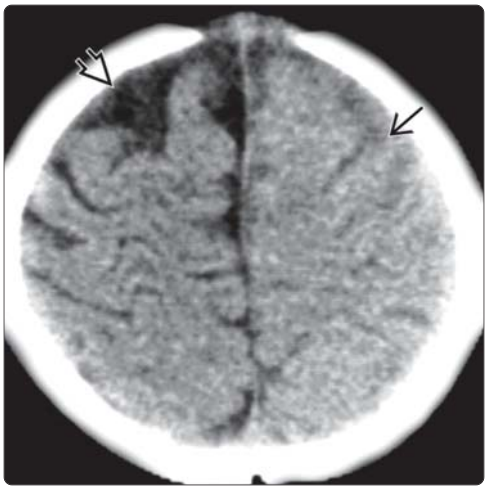

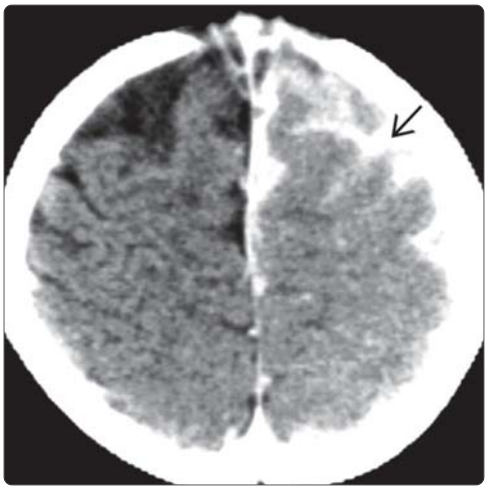

(Left) *Axial NECT in an infant shows poor visualization of the left convexity sulci related to an inflammatory exudate due to bacterial meningitis. The pus-filled sulci* ⇨ *are nearly isodense with the underlying brain, making them difficult to see unless you compare them with the normal CSF-filled sulci* ⇨ *on the right.* **(Right)** *CECT scan in the same case shows intense enhancement of the left-sided exudate that completely fills the sulci* ⇨.

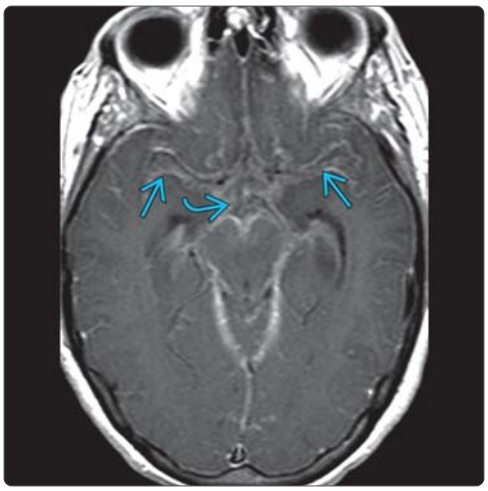

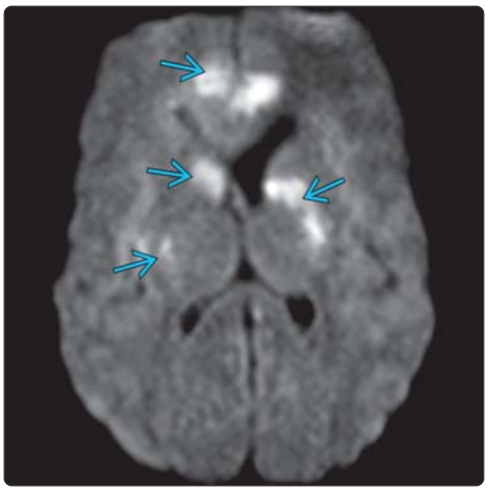

(Left) *Axial T1 +C MR in a patient with blastomycosis shows extensive leptomeningeal enhancement in the basal cisterns* ⇨ *and sylvian fissures* ⇨ *due to meningitis.* **(Right)** *Axial DWI MR in the same patient shows multiple focal areas of high signal* ⇨ *due to acute infarcts. Ischemia may be the result of arterial spasm/occlusion or true arteritis. DWI is invaluable in the evaluation of meningitis complications*

https://CafePezeshki.IR

KEY FACTS

TERMINOLOGY

- Focal pyogenic infection of brain parenchyma, typically bacterial; fungal or parasitic less common
- 4 pathologic stages: Early cerebritis, late cerebritis, early capsule, late capsule

IMAGING

- Ring-enhancing lesion with T2 hypointense rim and central diffusion restriction characteristic
- Imaging varies with stage of abscess development
  - Early cerebritis: Ill-defined T2 hyperintense mass
- Findings with contrast enhancement
  - Early cerebritis: Patchy enhancement
  - Late cerebritis: Intense, irregular rim enhancement
  - Early capsule: Well-defined, thin-walled, enhancing rim
  - Late capsule: Cavity collapses, capsule thickens
- MRS: Central necrotic area may show presence of amino acids (0.9 ppm), lactate (1.3 ppm), acetate (1.9 ppm), succinate (2.4 ppm)
- Multiplanar MR ± contrast, DWI, ± MRS, PWI
- Dual rim sign on SWI (hypointense outside, hyperintense inside) helpful in from other ring-enhancing lesions

TOP DIFFERENTIAL DIAGNOSES

- Glioblastoma
- Parenchymal metastases
- Demyelinating disease
- Resolving intracerebral hematoma
- Subacute cerebral infarction

CLINICAL ISSUES

- Headache (up to 90%); may have seizures, altered mental status, focal deficits, nausea, vomiting
- Potentially fatal but treatable lesion

DIAGNOSTIC CHECKLIST

- DWI, MRS helpful to distinguish abscess from mimics

(Left) *Axial graphic shows early cerebritis, the initial phase of abscess formation, in the frontal lobe. There is a focal unencapsulated mass of petechial hemorrhage, inflammatory cells, and edema.* **(Right)** *Axial T1W C+ in a 24-year-old male with headache, fever, and altered sensorium shows early cerebritis with patchy enhancement. Imaging varies with stage of abscess development and may mimic a neoplasm, demyelination, or subacute infarct. DWI is often helpful to distinguish cerebritis from its mimics.*

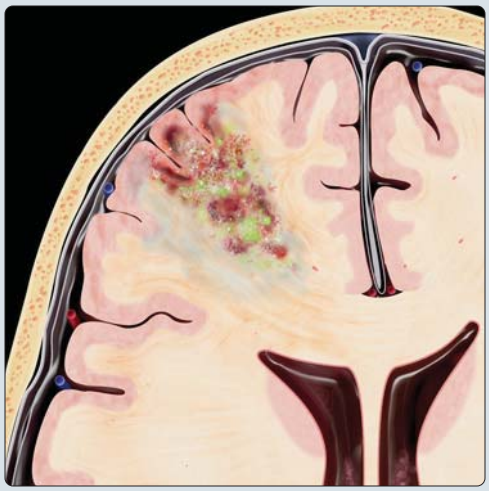

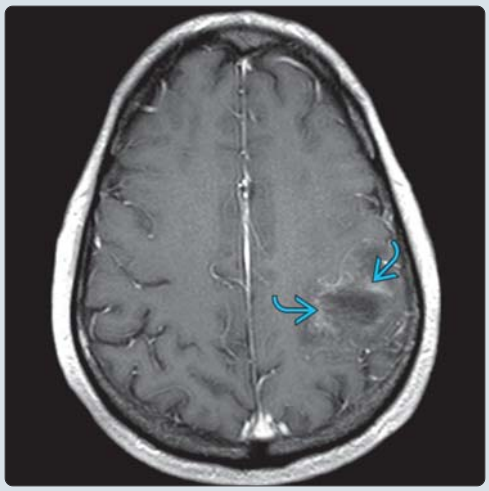

(Left) *Axial graphic shows the early capsule formation of an abscess with central liquified necrosis and inflammatory debris. Collagen and reticulin form the well-defined abscess wall. Note the surrounding edema.* **(Right)** *Axial T1W +C demonstrates a ring-enhancing abscess with a central necrotic core and surrounding edema.*

https://CafePezeshki.IR

TERMINOLOGY

Definitions

- Localized infection of brain parenchyma, typically bacterial; fungal or parasitic less common
- 4 pathologic stages: Early cerebritis, late cerebritis, early capsule, late capsule

IMAGING

General Features

- Best diagnostic clue
  - Imaging varies with stage of abscess development
  - Early capsule: Well-defined, thin-walled enhancing rim
    - Ring-enhancing lesion: DWI high signal, low ADC
    - T2 hypointense rim with surrounding edema
- Location
  - Typically supratentorial; up to 14% infratentorial
  - Frontal lobe (sinusitis, odontogenic infection), temporal lobe (otomastoiditis)
  - Usually at gray-white junction (hematogenous)
  - Multiple lesions may represent septic emboli
- Size
  - 5 mm up to several cm
- Morphology
  - Thin-walled, well-delineated, ring-enhancing, cystic-appearing mass

CT Findings

- NECT
  - Early cerebritis: Ill-defined, hypodense subcortical lesion with mass effect; CT may be normal early
  - Late cerebritis: Central low-density area; peripheral edema, increased mass effect
  - Early capsule: Hypodense mass with moderate vasogenic edema and mass effect
  - Late capsule: Edema, mass effect diminish
  - Gas-containing abscess rare
- CECT
  - Early cerebritis: ± mild patchy enhancement
  - Late cerebritis: Irregular rim enhancement
  - Early capsule: Low-density center with thin, distinct enhancing rim
    - Medial or ventricular wall of capsule thinnest; thickest near cortex
  - Late capsule: Cavity shrinks, capsule thickens
    - May have "daughter" abscesses

MR Findings

- T1WI
  - Early cerebritis: Poorly marginated, mixed hypo-/isointense mass
  - Late cerebritis: Hypointense center, iso-/mildly hyperintense rim
  - Early capsule: Rim iso-/hyperintense to white matter (WM); center hyperintense to CSF
  - Late capsule: Cavity shrinks, capsule thickens
- T2WI
  - Early cerebritis: Ill-defined hyperintense mass
  - Late cerebritis: Hyperintense center, hypointense rim; hyperintense edema
  - Early capsule: Hypointense rim (due to collagen, hemorrhage, or paramagnetic free radicals)
  - Late capsule: Edema and mass effect diminish
- T2* GRE
  - Dual rim sign on SWI (hypointense outside, hyperintense inside) helpful in distinguishing from other ring-enhancing lesions
- DWI
  - Increased signal intensity in cerebritis and abscess
  - ADC map: Markedly decreased signal (low ADC) centrally within abscess
  - Elevated fractional anisotropy (FA) within abscess cavity
- T1WI C+
  - Early cerebritis: Patchy enhancement
  - Late cerebritis: Intense, irregular rim enhancement
  - Early capsule: Well-defined, thin-walled enhancing rim
  - Late capsule: Cavity collapses, capsule thickens
    - Capsule thinnest on ventricular side
- MRS
  - Central necrotic area may show presence of amino acids (0.9 ppm), lactate (1.3 ppm), acetate (1.9 ppm), succinate (2.4 ppm)
- PWI: Abscess capsule shows lower rCBV values than rims of enhancing tumors
- Resolving abscess: T2 hypointense rim resolves, central ADC increases, enhancement resolves last
  - Small ring/punctate enhancing focus may persist for months

Nuclear Medicine Findings

- PET: FDG and carbon-11-methionine show increased uptake in brain abscess

Imaging Recommendations

- Best imaging tool
  - Contrast-enhanced MR
- Protocol advice
  - Multiplanar MR ± contrast, DWI, ± MRS, PWI

DIFFERENTIAL DIAGNOSIS

Glioblastoma

- Thick, nodular > thin wall
- Low signal on DWI (rarely high, mimics abscess)
- Hemorrhage common
- Other cystic primary neoplasms can also mimic abscess

Parenchymal Metastases

- Thick-walled, centrally necrotic mass, often multiple, marked edema
- May be solitary ring-enhancing lesion
- DWI may be positive and mimic abscess

Demyelinating Disease

- Multiple sclerosis, ADEM
- Ring enhancement often incomplete ("horseshoe")
- Characteristic lesions elsewhere in brain
- Mass effect small for size of lesion

Resolving Intracerebral Hematoma

- History of trauma or vascular lesion
- Blood products present on MR

https://CafePezeshki.IR

Subacute Cerebral Infarction

- History of stroke, vascular distribution
- Gyriform > > ring enhancement (rare)

PATHOLOGY

General Features

- Etiology
  - Hematogenous from extracranial location (pulmonary infection, endocarditis, urinary tract infections)
  - Direct extension from calvarial or meningeal infection
    - Paranasal sinus, middle ear, teeth infections (via valveless emissary veins)
  - Postoperative
  - Penetrating trauma (bone fragments > metal)
  - Right-to-left shunts (congenital cardiac malformations, pulmonary arteriovenous fistulas)
  - Neonatal: 2/3 associated with meningitis
    - "Square abscess" associated with Citrobacter meningitis
  - 20-30% have no identifiable source (cryptogenic)
    - Often polymicrobial (streptococci, staphylococci, anaerobes)

Gross Pathologic & Surgical Features

- Early cerebritis (3-5 days)
  - Infection focal but not localized
  - Unencapsulated mass of PMNs, edema, scattered foci of necrosis, petechial hemorrhage
- Late cerebritis (4-5 days to 2 weeks)
  - Necrotic foci coalesce
  - Rim of inflammatory cells, macrophages, granulation tissue, and fibroblasts surrounds central necrotic core
  - Vascular proliferation, surrounding vasogenic edema
- Early capsule (begins at about 2 weeks)
  - Well-delineated collagenous capsule
  - Liquified necrotic core, peripheral gliosis
- Late capsule (weeks to months)
  - Central cavity shrinks
  - Thick wall (collagen, granulation tissue, macrophages, gliosis)

Microscopic Features

- Early cerebritis: Hyperemic tissue with PMNs, necrotic blood vessels, microorganisms
- Late cerebritis: Progressive necrosis, inflammatory cells, fibroblasts deposit an early reticulin matrix around periphery
- Early capsule: Granulation tissue proliferation around necrotic core
- Late capsule: Multiple layers of collagen and fibroblasts

CLINICAL ISSUES

Presentation

- Most common signs/symptoms
  - Headache (up to 90%); may have seizures, altered mental status, focal deficits, nausea, vomiting
  - Fever in only 50%
- Other signs/symptoms
  - Increased ESR (75%), elevated WBC count (50%), absence of leukocytosis does not exclude diagnosis

Demographics

- Age
  - Most common in 3rd and 4th decades; 25% in patients < 15 years
- Gender
  - M:F = 2:1
- Epidemiology
  - Uncommon; ~ 2,500 cases per year in USA
  - Bacterial: *Staphylococcus*, *Streptococcus*, *Pneumococcus*
  - Diabetic: *Klebsiella pneumoniae*
  - Post-transplant: *Nocardia*, *Aspergillus*, *Candida*
  - AIDS: *Toxoplasmosis*, *Mycobacterium tuberculosis*
  - Neonates: *Citrobacter*, *Proteus*, *Pseudomonas*, *Serratia*, *Staphylococcus aureus* (meningitis related)

Natural History & Prognosis

- Potentially fatal but treatable lesion
  - Stereotactic surgery + medical therapy have greatly reduced mortality
- Complications of inadequately or untreated abscesses
  - Meningitis, "daughter" lesions, mass effect, herniation
  - Intraventricular rupture, ventriculitis
    - Ventricular debris with irregular fluid level
    - Hydrocephalus and ependymal enhancement
- Factors affecting prognosis: Size, location, virulence of infecting organism(s), and immune status
- Mortality variable: 0-30%
- Epilepsy: Common complication in pediatric patients

Treatment

- Primary therapy: Surgical drainage &/or excision
- If < 2.5 cm or early-phase cerebritis: Antibiotics only
- Steroids to treat edema and mass effect
- Lumbar puncture hazardous if findings of ↑ ICP; pathogen often cannot be determined from CSF unless related to meningitis

DIAGNOSTIC CHECKLIST

Consider

- DWI, MRS helpful to distinguish abscess from mimics
- Dual rim sign on SWI (hypointense outside, hyperintense inside) helpful in from other ring-enhancing lesions

Image Interpretation Pearls

- Search for local cause (sinusitis, otitis media, mastoiditis)
- T2 hypointense abscess rim resolves before enhancement in successfully treated patients

SELECTED REFERENCES

1. Brouwer MC et al: Brain abscess. N Engl J Med. 371(5):447-56, 2014
2. Rath TJ et al: Imaging of cerebritis, encephalitis, and brain abscess. Neuroimaging Clin N Am. 22(4):585-607, 2012

https://CafePezeshki.IR

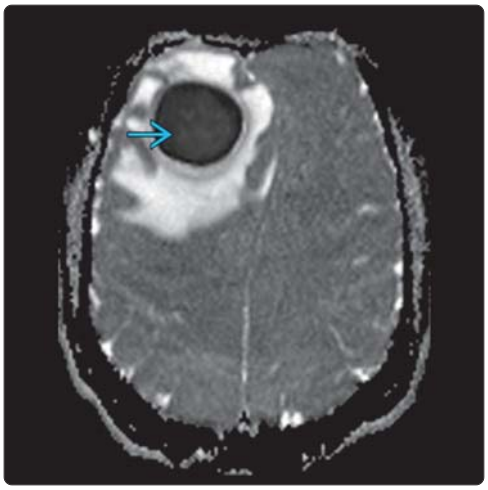

(Left) *Axial DWI MR in a 20-year-old male with an abscess shows a large, well-defined mass with restricted diffusion ⇨ in the right frontal lobe.* **(Right)** *Axial ADC map in the same patient shows very low ADC values ⇨. Restriction of water proton mobility within abscess cavity is due to necrotic debris, macromolecules, viscosity of pus. Studies suggest that persistent low ADC or recurrent low ADC in an abscess cavity following treatment indicates reactivation of infection or failed therapy.*

(Left) *Axial T2WI in the same patient as above shows a T2 hypointense rim ⇨ of abscess wall with extensive vasogenic edema ⇨. There is mass effect, subfalcine herniation to the left ⇨. T2 hypointensity of abscess capsule has been attributed to free radicals generated by phagocytic macrophages.* **(Right)** *Axial SWI MR in the same patient shows a characteristic dual rim sign. Abscess is bordered by 2 concentric rims, the outer one hypointense ⇨ and inner one hyperintense ⇨ relative to cavity content, forming the dual rim sign.*

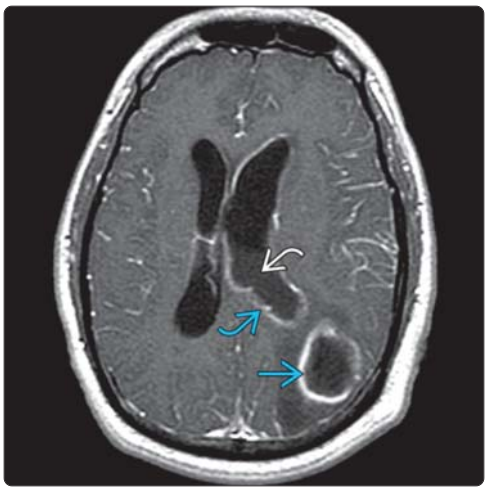

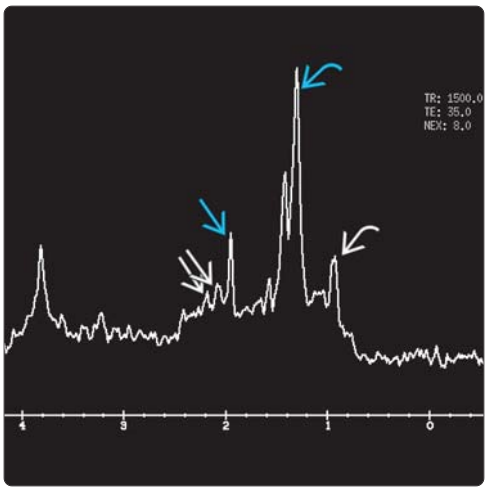

(Left) *Axial T1WI MR C+ in the patient with pyogenic abscess and ventriculitis shows a rim-enhancing lesion ⇨, dependent ventricular debris ⇨, and ependymal enhancement ⇨.* **(Right)** *MRS (TR 1500, TE 35) shows typical spectrum for a bacterial brain abscess. There is a large lactate peak at 1.3 ppm ⇨, acetate at 1.9 ppm ⇨, amino acids (valine, leucine, isoleucine) at 0.9 ppm ⇨ and succinate at 2.4 ppm ⇨.*

https://CafePezeshki.IR

KEY FACTS

TERMINOLOGY

- Ventricular ependyma infection related to meningitis, ruptured brain abscess, or ventricular catheter

IMAGING

- Best imaging clue: Ventriculomegaly with debris level, abnormal ependyma, periventricular T2/FLAIR hyperintensity
- DWI: Restriction of layering debris with low ADC is characteristic
- T1WI C+: Marked ependymal enhancement with ventriculomegaly
- Ultrasound: Ventriculomegaly with echogenic ependyma and debris in infant
  - Can play important role in detection of postinfectious hydrocephalus

TOP DIFFERENTIAL DIAGNOSES

- Primary central nervous system lymphoma
- Ependymal tumor spread (e.g., glioblastoma multiforme, medulloblastoma, pineal and choroid plexus tumors, ependymoma)
- Intraventricular hemorrhage
- Prominent ependymal veins (e.g., arteriovenous malformation, developmental venous anomaly, cavernoma, Sturge-Weber)

CLINICAL ISSUES

- Bacterial ventriculitis may occur in healthy individuals after trauma or neurosurgical procedure
- Fungal or viral ventriculitis occurs most commonly in immunosuppressed patients
- Ventriculitis occurs in 30% of meningitis patients; up to 80-90% in neonates/infants
- High mortality rate: 40-80%
- Treatment: Surgical irrigation, drainage, &/or IV antibiotics

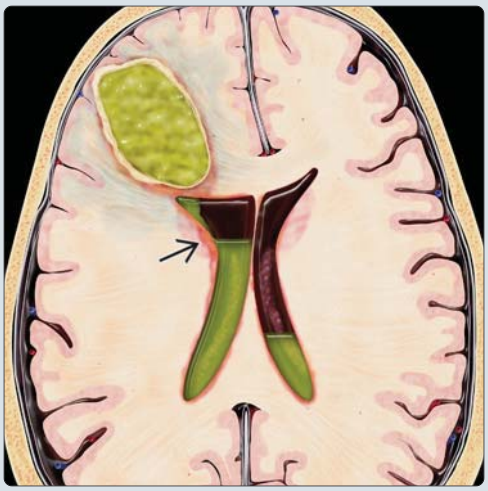

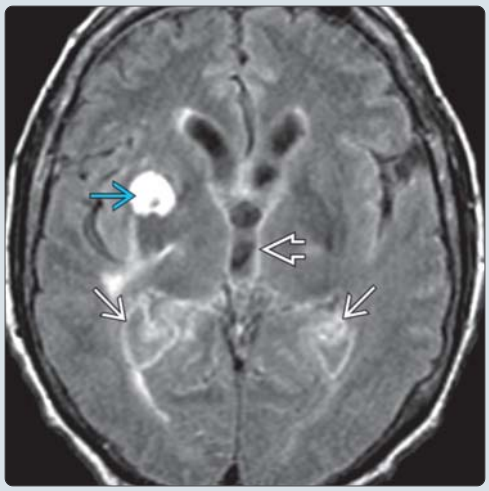

(Left) *Axial graphic shows a right frontal abscess that has ruptured into the ventricular system, resulting in ventriculitis. Note the characteristic debris level within the ventricles and the inflammation along the ventricular margins.* **(Right)** *Axial FLAIR MR shows striking hyperintensity along the ventricular ependyma with hyperintense debris filling the atria of the lateral ventricles. FLAIR and DWI are the most sensitive sequences to identify ventriculitis. Note the right basal ganglia abscess.*

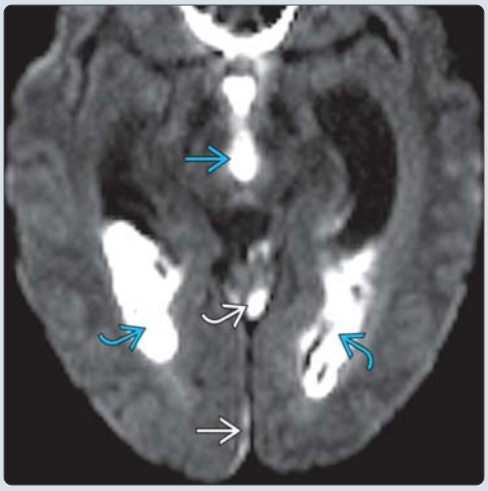

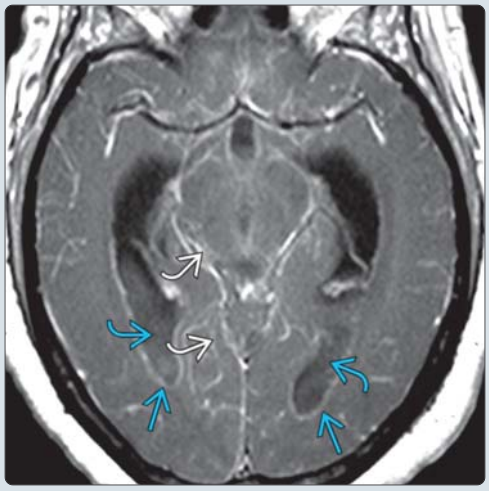

(Left) *Axial DWI MR in a patient with pneumococcal meningitis shows diffusion restriction in 3rd ventricle and lateral ventricular debris due an associated ventriculitis. Exudates in superior cerebellar cistern and a small subdural empyema. DWI is invaluable in the diagnosis of ventriculitis.* **(Right)** *Axial T1WI C+ MR in the same patient shows dependent ventricular debris, ependymal as well as leptomeningeal enhancement.*

https://CafePezeshki.IR

TERMINOLOGY

Synonyms

- Ependymitis, ventricular abscess, pyocephalus

Definitions

- Ventricular ependyma infection related to meningitis, ruptured brain abscess, or ventricular catheter

IMAGING

General Features

- Best diagnostic clue
  - Ventriculomegaly with debris level, abnormal ependymal enhancement, periventricular T2/FLAIR hyperintensity

CT Findings

- NECT
  - Ventriculomegaly with dependent debris level
  - Subtle low density along ventricular margins
- CECT
  - Enhancement of ventricular walls

MR Findings

- T1WI
  - Ventriculomegaly with hyperintense debris
  - Subtle periventricular hypointensity
- T2WI
  - Hyperintensity along ventricular margins
- FLAIR
  - Hyperintensity along ventricular margins
  - Hyperintense debris layering dependently
- DWI
  - Diffusion restriction of layering debris, low ADC
- T1WI C+
  - Marked ependymal enhancement
  - May have associated choroid plexitis with enlarged, edematous choroid
  - Inflammatory septations and loculations (chronic)

Ultrasonographic Findings

- Ventriculomegaly with echogenic debris and echogenic ependyma, increased periventricular echogenicity, poor definition of choroid plexus in infant

Imaging Recommendations

- Best imaging tool
  - MR in adults, ultrasound in infants
- Protocol advice
  - Multiplanar MR with contrast, DWI, FLAIR

DIFFERENTIAL DIAGNOSIS

Primary Central Nervous System (CNS) Lymphoma

- Ependymal enhancement, typically nodular
- Parenchymal disease usually present

Ependymal Tumor Spread

- Primary brain tumors: GBM, medulloblastoma, pineal tumors, ependymoma, choroid plexus tumors
- Metastatic tumor from extracranial primary

Intraventricular Hemorrhage

- History of trauma; other sequelae seen
- Ventricles are typically not enlarged acutely

Prominent Ependymal Veins

- Vascular malformations: Arteriovenous malformation, developmental venous anomaly, cavernoma
- Abnormal venous drainage (i.e., Sturge-Weber)

PATHOLOGY

General Features

- Etiology
  - Complication of meningitis or cerebral abscess that ruptures into ventricular system
  - Complication of neurosurgical procedure, most commonly intraventricular catheter
  - Pathogens include bacteria, fungus, virus, parasites
    - Common bacterial organisms: *Staphylococcus*, *Streptococcus*, *Enterobacter*

Gross Pathologic & Surgical Features

- Intraventricular sedimentation levels with inflammation and proteinaceous debris

Microscopic Features

- Ependymal and subependymal inflammation with macrophages, lymphocytes

CLINICAL ISSUES

Presentation

- Most common signs/symptoms
  - Dependent on etiology; often indolent
- Clinical profile
  - Cerebrospinal fluid (CSF) cytology, cultures may be normal

Demographics

- Epidemiology
  - Bacterial ventriculitis may occur in healthy individuals after trauma or neurosurgical procedure
  - Fungal or viral ventriculitis occurs most commonly in immunosuppressed patients
  - Ventriculitis occurs in 30% of meningitis patients; up to 80-90% in neonates/infants
  - Intrathecal chemotherapy, rarely associated

Natural History & Prognosis

- Mortality rate: 40-80%

Treatment

- Surgical irrigation, drainage, &/or IV antibiotics

SELECTED REFERENCES

1. Hazany S et al: Magnetic resonance imaging of infectious meningitis and ventriculitis in adults. Top Magn Reson Imaging. 23(5):315-25, 2014
2. Lummel N et al: Spectrum and Prevalence of Pathological Intracranial Magnetic Resonance Imaging Findings in Acute Bacterial Meningitis. Clin Neuroradiol. ePub, 2014
3. Mohan S et al: Imaging of meningitis and ventriculitis. Neuroimaging Clin N Am. 22(4):557-83, 2012
4. Nickerson JP et al: Neuroimaging of pediatric intracranial infection–part 1: techniques and bacterial infections. J Neuroimaging. 22(2):e42-51, 2012

https://CafePezeshki.IR

KEY FACTS

TERMINOLOGY

- Collection of pus in subdural or epidural space, or both (15%); subdural much more common
- Subdural empyema (SDE), epidural empyema (EDE)

IMAGING

- Best diagnostic clue: Extraaxial collection with enhancing rim, DWI positive
- Supratentorial typical
  - EDE: Often adjacent to frontal sinus
  - SDE: Convexity in > 50%, parafalcine in 20%
- Infratentorial (up to 10%); related to mastoiditis
- T2 MR: Inwardly displaced dura seen as hypointense line between fluid and brain
- T1 C+ MR: Prominent enhancement at margin related to granulomatous tissue and inflammation
- MR with DWI best to demonstrate presence, nature, extent, and complications

TOP DIFFERENTIAL DIAGNOSES

- Chronic subdural hematoma
- Subdural effusion, subdural hygroma

PATHOLOGY

- Infants, young children: Complication of bacterial meningitis
- Older children, adults: Related to paranasal sinus disease (> 2/3)

CLINICAL ISSUES

- Sinus or ear infection in > 75% of cases
- EDE, SDE rare, yet highly lethal
- Complications common: Cerebritis, abscess, venous thrombosis, ischemia, hydrocephalus
- Mortality: 10-15%
- Surgical drainage is primary treatment
- Sinus drainage + antibiotics: Small sinus-related EDE

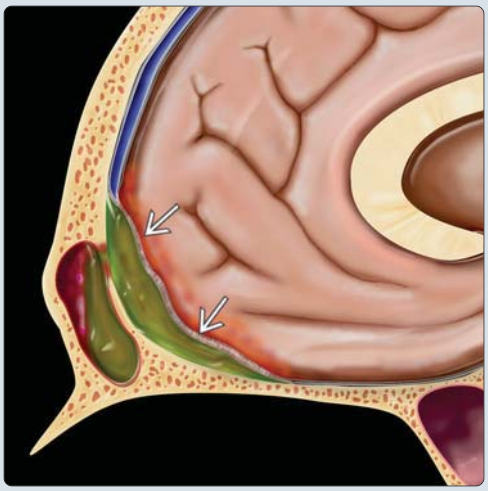

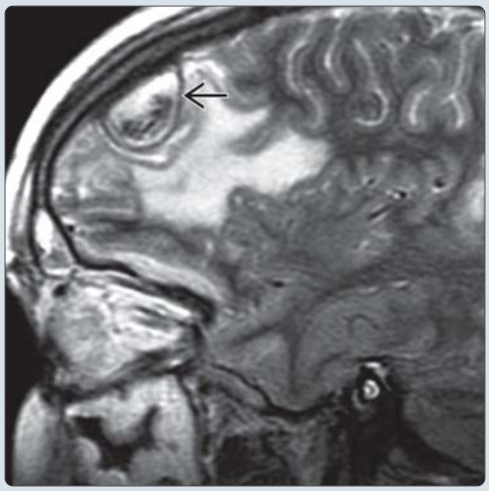

(Left) *Sagittal graphic shows frontal sinus purulence and direct extension into the epidural space, resulting in an epidural empyema (EDE). Note the displaced dura ➡ and inflammation in the adjacent frontal lobe. EDE is often located adjacent to the frontal sinus.* **(Right)** *Sagittal T2WI MR shows an EDE with abnormal signal in the adjacent brain related to cerebritis. Note the inwardly displaced dura ⇨, seen as a hypointense line between the EDE and the brain, in this child with sinusitis.*

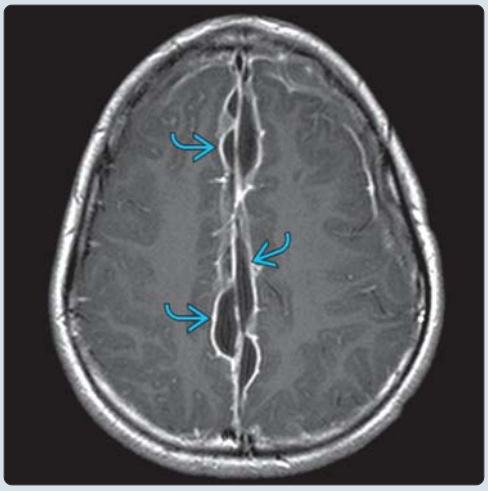

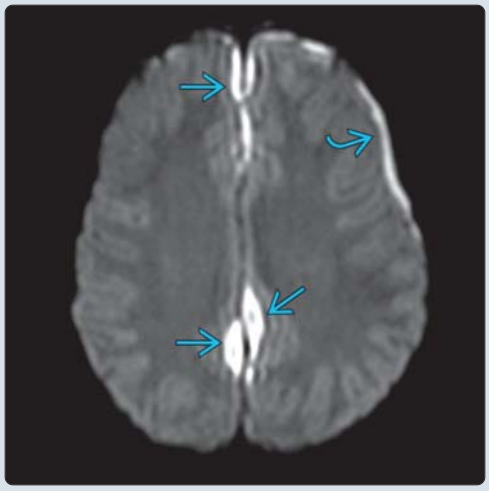

(Left) *Axial T1WI C+ FS MR in a patient presenting with headache and fever shows rim-enhancing parafalcine collections ⇨ related to subdural empyemas.* **(Right)** *Axial DWI MR in the same patient shows bright diffusion restriction in the parafalcine ⇨ and left frontal ⇨ subdural empyemas. DWI is an important sequence to demonstrate the presence, extent, and complications of a subdural or epidural empyema.*

https://CafePezeshki.IR

TERMINOLOGY

Abbreviations

- Subdural empyema (SDE), epidural empyema (EDE)

Synonyms

- Epidural empyema = epidural abscess

Definitions

- Collection of pus in subdural or epidural space or both; subdural much more common

IMAGING

General Features

- Best diagnostic clue
  - Extraaxial collection with enhancing rim
- Location
  - Supratentorial typical
    - SDE: Convexity in > 50%, parafalcine in 20%
    - EDE: Often adjacent to frontal sinus
  - Infratentorial (up to 10%)
    - Often associated with mastoiditis
    - > 90% associated with hydrocephalus
- Morphology
  - SDE: Crescentic typical; may be lens-shaped (lentiform) on coronal images
    - Can spread diffusely over hemispheres, along tentorium/falx
  - EDE: Biconvex, lentiform

CT Findings

- NECT
  - Extraaxial collection, iso- to hyperdense to CSF
  - SDE: Crescentic iso- to hyperdense collection, limited by dural reflections
    - Frequently bilateral
    - Warning: Can be small, easily overlooked
  - EDE: Biconvex low-density collection between dura, calvaria; contained by cranial sutures
    - Often continuous across midline
  - Posterior fossa EDE
    - Typically at sinodural angle
    - Tegmen tympani ± sigmoid plate eroded
    - Pus may extend into cerebellopontine angle
- CECT
  - Strong peripheral rim enhancement
  - Posterior fossa EDE: Look for venous thrombosis
- Bone CT
  - **Sinusitis** common in **supratentorial** SDE-EDE
  - **Otomastoiditis** common in **infratentorial** SDE-EDE

MR Findings

- T1WI
  - Extraaxial collection, hyperintense to CSF
  - SDE: Crescentic extraaxial collection
  - EDE: Lentiform bifrontal or convexity collection
    - May cross midline in frontal region
- T2WI
  - Iso- to hyperintense to CSF
  - SDE: Crescentic collection, underlying brain may be hyperintense
  - EDE: Lentiform bifrontal or convexity collection
    - Inwardly displaced dura seen as **hypointense line** between fluid and brain
- FLAIR
  - Hyperintense to CSF
  - SDE: Crescentic collection, underlying brain may be hyperintense
  - EDE: Lentiform bifrontal or convexity collection
  - Hyperintensity in underlying brain parenchyma may be caused by cerebritis or ischemia (venous or arterial)
- DWI
  - SDE: **Restricted diffusion** (↑ signal intensity) typical
  - EDE: Variable signal with some restricting components
- T1WI C+
  - Prominent enhancement at margin related to granulomatous tissue and inflammation
  - SDE: Encapsulating membranes enhance strongly, may be loculated with internal fibrous strands
  - EDE: Strong enhancement of collection margins
  - May see enhancement of adjacent brain parenchyma (cerebritis/abscess)
  - May see leptomeningeal enhancement due to associated meningitis
  - Frontal subgaleal phlegmon or abscess ("Pott puffy tumor")
- MRV: Venous thrombosis especially with SDE

Ultrasonographic Findings

- Useful in infants
- Heterogeneous echogenic convexity collection with mass effect
  - Hyperechoic fibrous strands
  - Thick, hyperechoic inner membrane
  - Increased echogenicity of pia-arachnoid and exudates in subarachnoid space

Imaging Recommendations

- Best imaging tool
  - **MR with DWI** best to demonstrate presence, nature, extent, and complications
- Protocol advice
  - Contrast-enhanced multiplanar MR with DWI
  - **DWI** helpful to evaluate extent and complications

DIFFERENTIAL DIAGNOSIS

Chronic Subdural Hematoma

- MR shows blood products; may be loculated
- Often enhances along edge; enhancement usually thinner than SDE
- May be indistinguishable; history may help

Subdural Effusion

- Sterile, CSF-like collection associated with meningitis
- Follows CSF on all MR sequences
- Usually nonenhancing; may enhance mildly
- Frontal and temporal regions common, often bilateral

Subdural Hygroma

- Nonenhancing CSF collection, often trauma/surgical history

https://CafePezeshki.IR

Dural Metastasis

- Primary tumor often known, typically breast, prostate
- Often diffuse, nodular enhancement
- May have associated bone metastases

PATHOLOGY

General Features

- Etiology
  - Infants, young children: Complication of **bacterial meningitis**
  - Older children, adults: Related to **paranasal sinus disease** (> 2/3)
    - Direct spread via posterior wall of frontal sinus
    - Retrograde spread through **valveless bridging emissary veins** of extra- and intracranial spaces
  - **Mastoiditis** (± cholesteatoma) in 20%
  - Complication of head trauma or neurosurgical procedure (rare)
  - Complication of meningitis in adults (very rare)
  - Causative organism: *Staphylococcus aureus*, *Staphylococcus epidermidis*, enteric gram-negative bacilli most common
  - Aerobic and microaerophilic streptococci (infection from paranasal sinuses)
- SDE much more common than EDE
- SDE more commonly complicated by abscess and venous thrombosis (> 10%)
- 15% of cases have both EDE and SDE

Gross Pathologic & Surgical Features

- Encapsulated, yellowish, purulent collection
- Spreads widely but may be loculated
- Often accompanying osteitis

Microscopic Features

- Inflammatory infiltrate & granulomatous tissue

CLINICAL ISSUES

Presentation

- Most common signs/symptoms
  - Majority have fever, headaches
  - Meningismus common, may mimic meningitis
  - Sinusitis often present
  - Cerebritis/brain abscess causes neurologic signs
- Clinical profile
  - Sinus or ear infection in > 75% of cases
  - Frontal subgaleal abscess ("Pott puffy tumor") in up to 1/3; typically adolescent males
  - Periorbital swelling may be seen
  - Confused with meningitis; delayed diagnosis
  - EDE, SDE rare, yet highly lethal

Demographics

- Age
  - Can occur at any age
- Epidemiology
  - SDE: 15-22%, EDE: 2-5% of focal intracranial infections
  - SDE: Sinusitis (67%), mastoiditis (10%)

Natural History & Prognosis

- Progresses rapidly, **neurosurgical emergency**
- Rapidly evolving, fulminant course
- EDE may occasionally have indolent course, as dura mater functions as barrier between infection and brain
  - Much better prognosis than SDE
- Can be fatal unless recognized and treated
  - **Lumbar puncture** can be **fatal**
  - CSF can be normal
- Complications common
  - Cerebritis and brain abscess: ~ 5%
  - Cortical vein, dural sinus thrombosis (venous ischemia)
  - Cerebral edema
  - Hydrocephalus (> 90% of infratentorial SDE)
- **Mortality: 10-15%**

Treatment

- Surgical drainage via wide craniotomy is gold standard
- Intravenous antibiotics
- Sinus drainage + antibiotics possible in small sinus-related EDE

DIAGNOSTIC CHECKLIST

Consider

- Chronic subdural hematoma may be difficult to differentiate from SDE; history may help
- Look for empyema in patient with sinusitis and neurologic symptoms
- If SDE or EDE discovered, look also for sinusitis, otomastoiditis, dural sinus thrombosis, brain abscess

Image Interpretation Pearls

- MR with contrast and **DWI** is most sensitive; CT may miss small collections
- DWI differentiates SDE from subdural effusions
- MR with DWI may be used to monitor treatment response

SELECTED REFERENCES

1. French H et al: Intracranial subdural empyema: a 10-year case series. Ochsner J. 14(2):188-94, 2014
2. Salomão JF et al: Neurosurgical implications of Pott's puffy tumor in children and adolescents. Childs Nerv Syst. 30(9):1527-34, 2014
3. Sharma PK et al: Orbitocranial complications of acute sinusitis in children. J Emerg Med. 47(3):282-5, 2014
4. Holland AA et al: Complicated subdural empyema in an adolescent. Arch Clin Neuropsychol. 28(1):81-91, 2013
5. Calik M et al: Masked subdural empyema secondary to frontal sinusitis. Am J Emerg Med. 30(8):1657, 2012
6. Cole TS et al: Pediatric focal intracranial suppuration: a UK single-center experience. Childs Nerv Syst. 28(12):2109-14, 2012
7. Nickerson JP et al: Neuroimaging of pediatric intracranial infection--part 1: techniques and bacterial infections. J Neuroimaging. 22(2):e42-51, 2012
8. Sarrazin JL et al: Brain infections. Diagn Interv Imaging. 93(6):473-90, 2012
9. Tsai YD et al: Intracranial suppuration: a clinical comparison of subdural empyemas and epidural abscesses. Surg Neurol. 59(3):191-6; discussion 196, 2003

https://CafePezeshki.IR

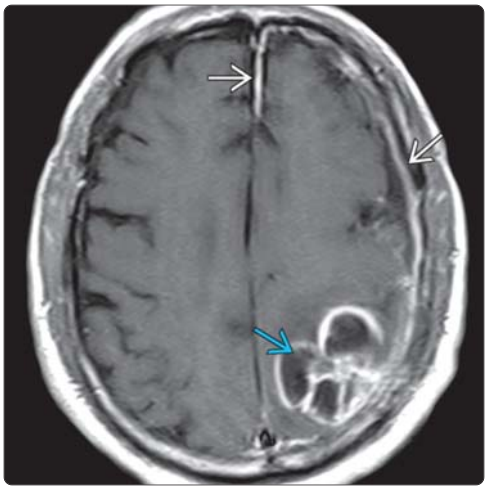

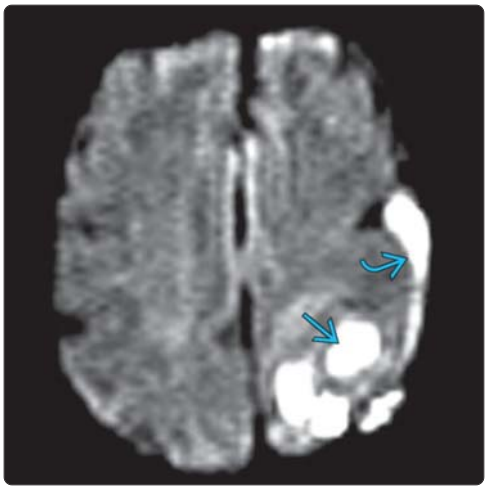

(Left) *Axial T1WI C+ MR in this 67-year-old patient with weakness shows a multiloculated, rim-enhancing parietal "mass" and thick dural enhancement over the hemisphere extending into the interhemispheric fissure.* **(Right)** *Axial DWI MR in the same patient shows diffusion restriction in the "mass" as well as in the subdural collection, confirming the diagnosis of empyema and brain abscess. (Courtesy C. Sutton, MD.)*

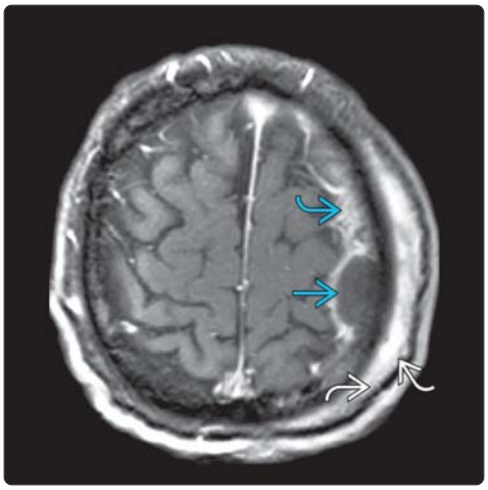

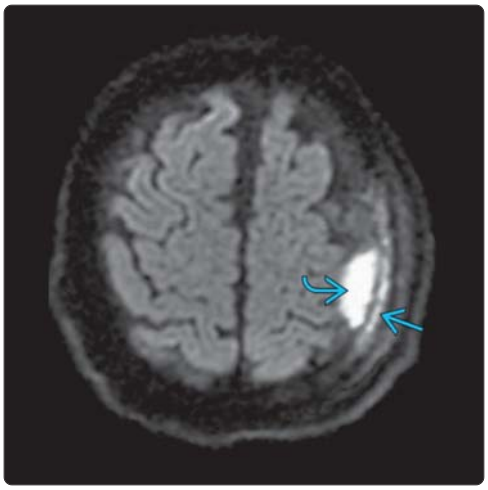

(Left) *Axial T1WI MR C+ in an elderly man presenting with fever and scalp swelling demonstrates an epidural abscess with thick enhancement of the adjacent dura. There is also enhancing subgaleal soft tissue in the fronto-parietal scalp.* **(Right)** *Axial DWI MR in the same patient shows diffusion restriction in the epidural abscess as well as in the subjacent calvaria. At surgery, this was an osteomyelitis of the calvaria with associated epidural abscess and subgaleal phlegmon.*

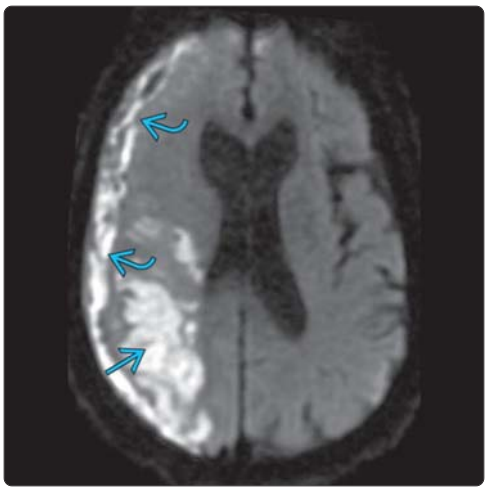

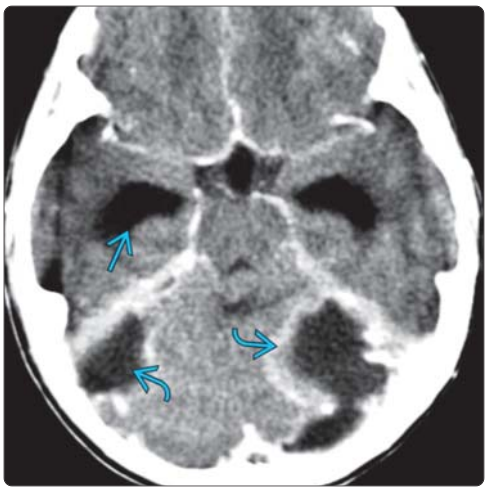

(Left) *Axial DWI MR demonstrates an SDE with restricted diffusion. There is also restricted diffusion in the adjacent brain parenchyma due to an arterial infarct (MCA distribution). Complications of SDE/EDE include meningitis, cerebritis/abscess, venous thrombosis, and ischemia (venous or arterial).* **(Right)** *Axial CECT shows bilateral posterior fossa SDEs with irregularly enhancing margins in this patient with mastoiditis further complicated by hydrocephalus and venous thrombosis.*

https://CafePezeshki.IR

KEY FACTS

TERMINOLOGY

- Brain parenchyma infection caused by herpes simplex virus type 1 (HSV1)
- Typically reactivation in immunocompetent patients

IMAGING

- Best imaging clue: T2/FLAIR hyperintensity of limbic system (medial temporal and inferior frontal cortex) with DWI restriction
  - Typically bilateral disease, but asymmetric
  - Deep gray nuclei usually spared
- CT often normal early
- MR with DWI most sensitive for early diagnosis
- T2/FLAIR: Cortical, subcortical hyperintensity with relative white matter sparing
- GRE: If hemorrhagic, hypointensity "blooms" within edematous brain
- DWI: Restricted diffusion in limbic system
- T1WI C+: May see mild, patchy enhancement early
  - Gyriform enhancement usually seen 1 week after initial symptoms

TOP DIFFERENTIAL DIAGNOSES

- Acute cerebral ischemia-infarction
- Status epilepticus
- Limbic encephalitis
- Infiltrating neoplasm

CLINICAL ISSUES

- Common presentation: Fever, headache, seizures, ± viral prodrome
- Children often present with nonspecific symptoms
- Polymerase chain reaction (PCR) of CSF most accurate diagnosis
- HSV1 causes 95% of all herpetic encephalitis
- Start IV acyclovir immediately if HSE suspected

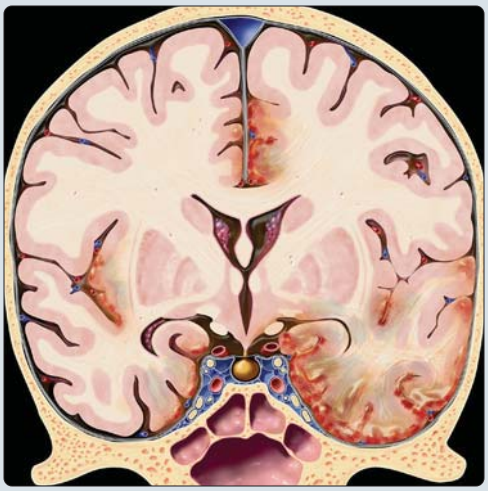

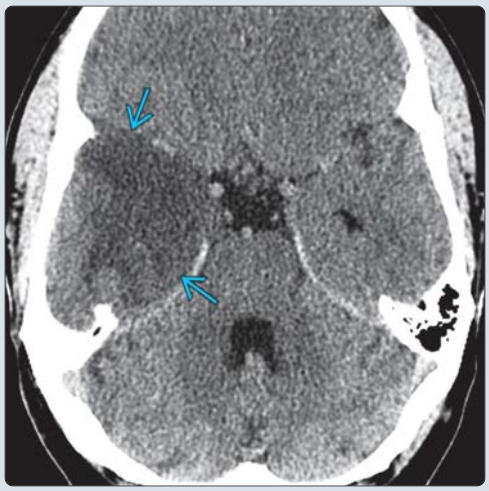

(Left) *Coronal graphic shows the classic features of herpes encephalitis with bilateral but asymmetric involvement of the limbic system. There is inflammation involving the temporal lobes, cingulate gyri, and insular cortices.* **(Right)** *NECT in a 52-year-old man with herpes simplex encephalitis shows hypodensity ⇨ and mild mass effect in the right anteromedial temporal lobe. Hemorrhage and contrast enhancement appear 2-3 days later in the disease course.*

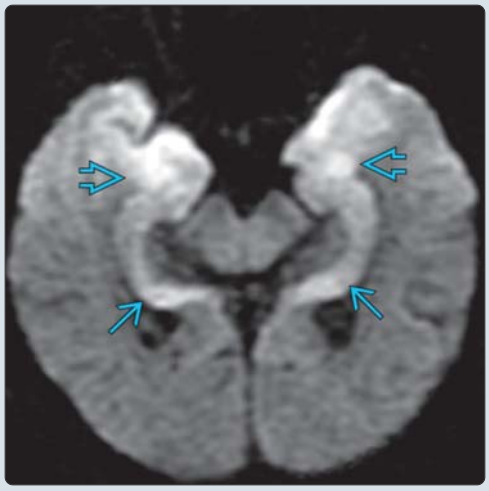

(Left) *Axial FLAIR MR shows classic bilateral but asymmetric abnormal hyperintense signal in the medial temporal lobes of this patient with herpes encephalitis. Note involvement of the hippocampi ⇨.* **(Right)** *Axial DWI MR in the same patient shows diffusion restriction as a bright signal in the medial temporal lobes ⇨ and hippocampi ⇨. DWI and FLAIR are the most sensitive sequences for detection of encephalitis. CT is often normal early in the course of herpes encephalitis.*

https://CafePezeshki.IR

TERMINOLOGY

Abbreviations

- Herpes simplex encephalitis (HSE)

Definitions

- Brain parenchyma infection caused by herpes simplex virus type 1 (HSV1)
- Typically reactivation in immunocompetent patients

IMAGING

General Features

- Best diagnostic clue
  - Abnormal signal in medial temporal and inferior frontal cortex with DWI restriction
  - Involvement of cingulate gyrus and contralateral temporal lobe highly suggestive
- Location
  - Limbic system: Temporal lobes, insula, subfrontal area, cingulate gyri typical
  - Cerebral convexity, posterior occipital cortex may become involved
  - Typically bilateral disease, but asymmetric
  - Basal ganglia usually spared
  - Atypical patterns seen in infants and children (may be caused by HSV1 or HSV2)
    - May primarily affect cerebral hemispheres
  - Rarely affects midbrain and pons (mesenrhombencephalitis)

CT Findings

- NECT
  - CT often normal early
    - Low attenuation, mild mass effect in medial temporal lobes, insula
    - Hemorrhage typically late feature
  - Predilection for limbic system; basal ganglia spared
  - Earliest CT findings at 3 days after symptom onset
- CECT
  - Patchy or gyriform enhancement of temporal lobes (late acute/subacute feature)

MR Findings

- T1WI
  - Cortical swelling with loss of gray-white junction, mass effect
  - May see subacute hemorrhage as increased signal within edematous brain
  - Atrophy, encephalomalacia in late subacute/chronic cases
- T2WI
  - Cortical and subcortical hyperintensity with relative white matter sparing
  - May see subacute hemorrhage as increased signal within edematous brain
- FLAIR
  - Cortical and subcortical hyperintensity with relative white matter sparing
  - Often see changes earlier than on T2WI
- T2* GRE
  - If hemorrhagic, hypointensity "blooms" within edematous brain
- DWI
  - Restricted diffusion in limbic system
  - Look for bilateral disease
  - DWI findings may precede T2/FLAIR changes
- T1WI C+
  - May see mild, patchy enhancement early
  - Gyriform enhancement usually seen 1 week after initial symptoms
  - Meningeal enhancement occasionally seen
  - Enhancement seen in temporal lobes, insular cortex, subfrontal area, cingulate gyrus
- MRS
  - ↓ NAA, prominent lipid-lactate peak

Imaging Recommendations

- Best imaging tool
  - MR (positive 24-48 hours earlier than CT)
- Protocol advice
  - Multiplanar MR with coronal T2 &/or FLAIR, DWI, T2* GRE, contrast

DIFFERENTIAL DIAGNOSIS

Acute Cerebral Ischemia-Infarction

- Typical vascular distribution (MCA, ACA, PCA)
- Hyperacute symptoms vs. 2-3 day history of flu-like illness
- Reduced diffusivity in acute infarct
- ACA distribution ischemia may mimic HSE

Status Epilepticus

- Active seizures may disrupt blood-brain barrier, cause signal abnormalities and enhancement
- Temporal lobe epilepsy hyperperfusion may mimic HSE
- No hemorrhage in status epilepticus

Limbic Encephalitis

- Rare paraneoplastic syndrome associated with primary tumor, often lung
- Predilection for limbic system, often bilateral
- Nonhemorrhagic
- Imaging may be indistinguishable
- Symptom onset weeks to months (vs. acute in HSE)

Infiltrating Neoplasm

- Low-grade gliomas may involve medial temporal lobe and cause epilepsy
- Gliomatosis cerebri may involve frontal and temporal lobes, may be bilateral
- Onset usually indolent

Other Encephalitides

- Limbic system not typically involved
- Neurosyphilis can affect medial temporal lobes and mimic HSE
  - May involve meninges, blood vessels (obliterative endarteritis)
- West Nile can mimic HSE clinically, but typically involves basal ganglia &/or thalami

https://CafePezeshki.IR

PATHOLOGY

General Features

- Etiology
  - Initial HSV1 infection usually occurs in oronasopharynx via contact with infected secretions
    - Invades along cranial nerves (via lingual nerve, division of trigeminal nerve) to ganglia
    - Remains dormant in trigeminal ganglion
    - Reactivation may occur spontaneously or be precipitated by various factors
      - Local trauma, immunosuppression, hormonal fluctuations, emotional stress

Staging, Grading, & Classification

- Herpes viruses include HSV1, HSV2, Epstein-Barr virus (EBV), cytomegalovirus (CMV), varicella-zoster virus (VZV), B virus, HSV6, HSV7
- HSV1 in adults, children
- HSV2 is more common in neonates
- HSV1 and HSV2 are DNA viruses
- Viruses are obligate intracellular pathogens

Gross Pathologic & Surgical Features

- Hemorrhagic, necrotizing encephalitis
  - Severe edema, massive tissue necrosis with hemorrhage typical
  - Involvement of temporal lobes, insular cortex, orbital surface of frontal lobes
  - Less frequent involvement of cingulate gyrus and occipital cortex

Microscopic Features

- Intense perivascular cuffing, interstitial lymphocytic inflammation
- Intranuclear inclusion bodies in infected cells (neurons, glia, endothelial cells)
  - Typically eosinophilic Cowdry A nuclear inclusions
- Immunohistochemistry shows viral antigens, antibodies to HSV1
- Chronic cases: Microglial nodules

CLINICAL ISSUES

Presentation

- Most common signs/symptoms
  - Fever, headache, seizures, ± viral prodrome
  - Children often present with nonspecific symptoms
    - Behavioral changes, fever, headaches, seizures
  - Patients typically immunocompetent
    - HSV1 uncommon in AIDS patients
- Other signs/symptoms
  - Altered mental status
  - Focal or diffuse neurologic deficit (< 30%)
- Clinical profile
  - CSF studies show lymphocytic pleocytosis, ↑ protein
  - Polymerase chain reaction (PCR) of CSF most accurate diagnosis
    - Sensitivity/specificity nearly 95-100%
    - False-negative PCR possible if CSF obtained < 72 hours after clinical onset
  - EEG: Temporal high voltage discharges in background of generalized slowing
  - Brain biopsy may be required for diagnosis

Demographics

- Age
  - May occur at any age
  - Highest incidence in adolescents and young adults
  - ~ 1/3 of all patients < 20 years old
- Gender
  - M = F
- Epidemiology
  - HSV1 causes 95% of all HSE
  - Most common cause of fatal sporadic encephalitis
  - Most common nonepidemic cause of viral meningoencephalitis
  - In adults, typically related to viral reactivation
  - In neonates, related to maternal infection
  - Incidence: 1-3/1 million

Natural History & Prognosis

- May progress to coma and death
  - 50-70% mortality rate
  - Rapid diagnosis, early treatment with antiviral agents can decrease mortality, may improve outcome
- Nearly 2/3 of survivors have significant neurological deficits, despite acyclovir therapy
- Survival complicated by memory difficulties, hearing loss, intractable epilepsy, personality changes

Treatment

- Antiviral therapy with intravenous acyclovir

DIAGNOSTIC CHECKLIST

Consider

- Start IV acyclovir immediately if HSE suspected
- Unilateral disease may mimic stroke or tumor; history often helpful
- Limbic encephalitis if all clinical HSE tests negative and subacute onset of symptoms
- Acute onset of HSE helps differentiate from other etiologies

Image Interpretation Pearls

- CT often normal early, MR with FLAIR/DWI most sensitive for early diagnosis
- Imaging often key in diagnosis

SELECTED REFERENCES

1. Hatanpaa KJ et al: Neuropathology of viral infections. Handb Clin Neurol. 123:193-214, 2014
2. Mahan M et al: Neuroimaging of viral infections of the central nervous system. Handb Clin Neurol. 123:149-73, 2014
3. Steiner I et al: Update on herpes virus infections of the nervous system. Curr Neurol Neurosci Rep. 13(12):414, 2013
4. Sureka J et al: Clinico-radiological spectrum of bilateral temporal lobe hyperintensity: a retrospective review. Br J Radiol. 85(1017):e782-92, 2012
5. Akyldz BN et al: Diffusion-weighted magnetic resonance is better than polymerase chain reaction for early diagnosis of herpes simplex encephalitis: a case report. Pediatr Emerg Care. 24(6):377-9, 2008
6. Bulakbasi N et al: Central nervous system infections of herpesvirus family. Neuroimaging Clin N Am. 18(1):53-84; viii, 2008

https://CafePezeshki.IR

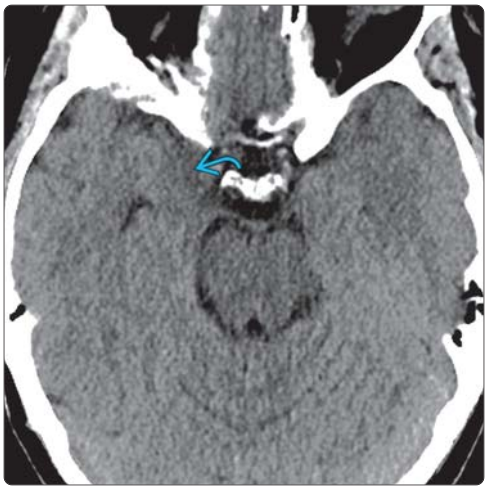

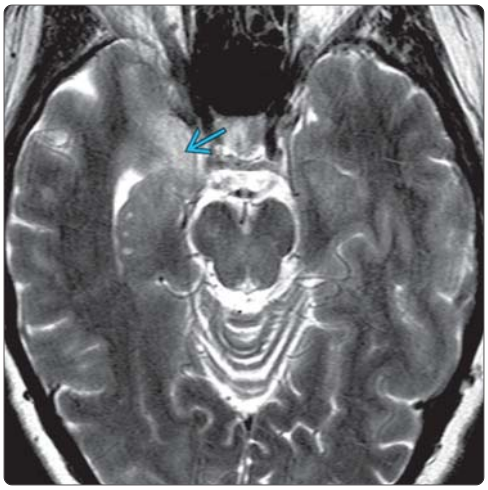

(Left) *Axial NECT in a 45 year old with fever and altered mental status shows questionable subtle low density changes in the right medical temporal lobe.* **(Right)** *Axial T2 WI MR in the same patient shows signal abnormality in right medical temporal lobe. CSF polymerase chain reaction (PCR) was positive for HSV-1. CT study may be normal in early stages of herpes encephalitis.*

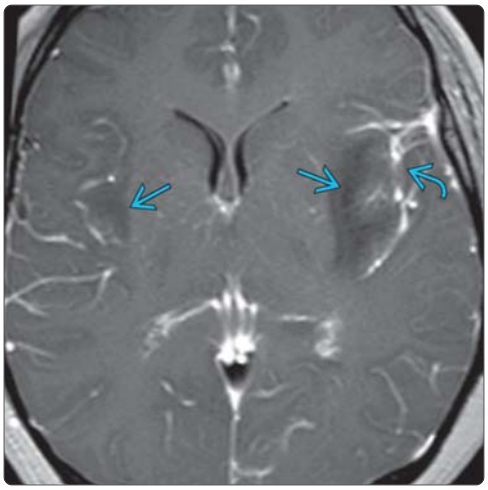

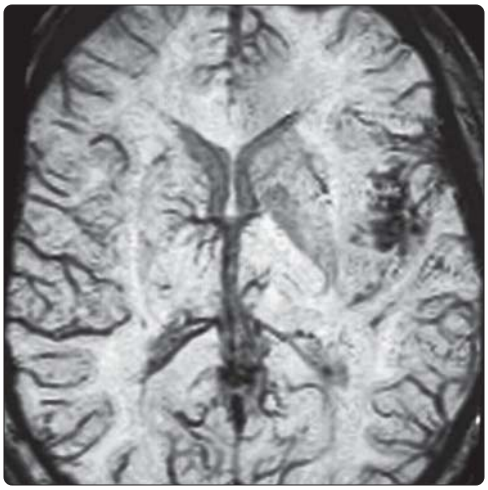

(Left) *Axial T1C+ MR in subacute stage of herpes encephalitis shows bilateral but asymmetric hypointensities in the insular regions. There is associated pial enhancement in the left insular region. Pial, leptomeningeal, diffuse, ring-like enhancement patterns have been reported in herpes encephalitis.* **(Right)** *Axial SWI MR in the same patient shows patchy hemorrhage in the left insular region. Following the acute stage (> 1 week), MR is superior to CT in detecting hemorrhage.*

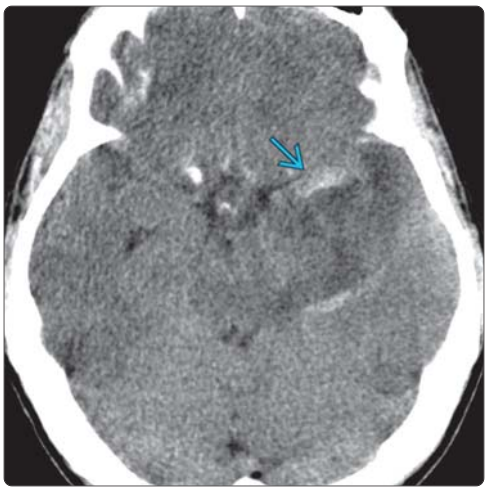

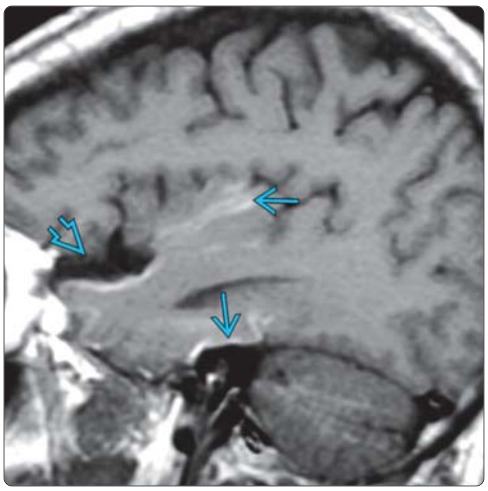

(Left) *Axial NECT shows edema and hemorrhage in the left temporal lobe in this young adult with altered mental status. Despite early acyclovir therapy, the patient succumbed to his disease. Mortality ranges from 50-70% in HSE patients.* **(Right)** *Sagittal T1WI in a patient 2 weeks after the initial presentation of herpes encephalitis shows volume loss in the temporal lobe and linear gyriform T1 shortening within the temporal lobe cortex, characteristic of subacute cortical hemorrhage.*

https://CafePezeshki.IR

KEY FACTS

TERMINOLOGY

- Diffuse brain parenchymal inflammation caused by variety of pathogens, most commonly viruses
- Location dependent on etiology

IMAGING

- Abnormal T2 hyperintensity of gray matter ± white matter or deep gray nuclei
- Large, poorly delineated areas of involvement common, ± patchy hemorrhage
- Imaging is often nonspecific, mimics other etiologies

TOP DIFFERENTIAL DIAGNOSES

- Acute ischemia
- Autoimmune encephalitis
- Herpes encephalitis
- Status epilepticus
- Toxic/metabolic lesions

PATHOLOGY

- Most (but not all) are caused by viruses
- Spread of virus to CNS is hematogenous or neural

CLINICAL ISSUES

- Herpes: Most common cause of sporadic (nonepidemic) viral encephalitis
- Japanese encephalitis: Most common endemic encephalitis in Asia
- Many encephalitides have high morbidity, mortality
- Rapid diagnosis and early treatment with antiviral or antibacterial agents can decrease mortality, may improve outcome

DIAGNOSTIC CHECKLIST

- Clinical history often helpful for accurate diagnosis
- DWI may detect lesions earlier than conventional MR

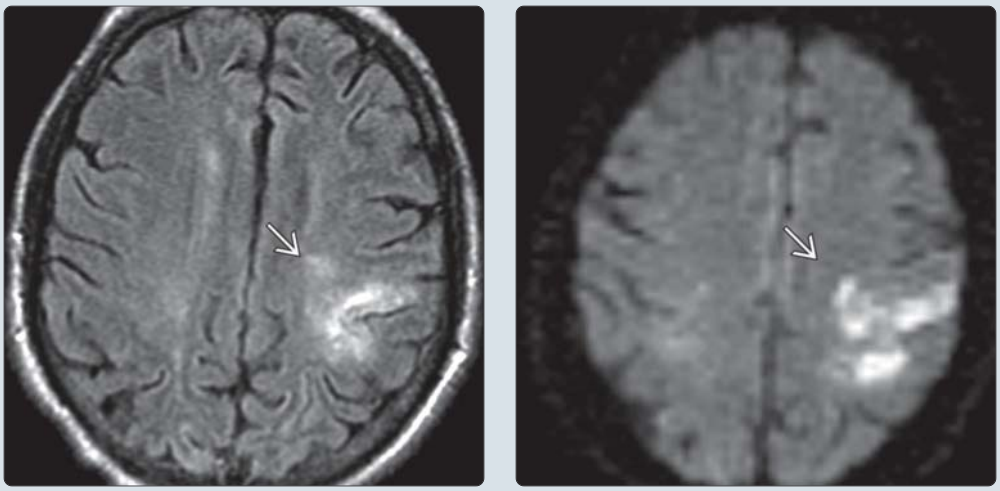

(Left) *Axial FLAIR MR shows hyperintense signal primarily in the left posterior frontal lobe ⇨ in an immunosuppressed patient with CMV meningoencephalitis. CMV typically involves the periventricular white matter.* **(Right)** *Axial DWI MR in the same patient shows restricted diffusion in the left posterior frontal lobe ⇨ with involvement of the gray and white matter. DWI is often positive in encephalitis and may be the most sensitive MR sequence.*

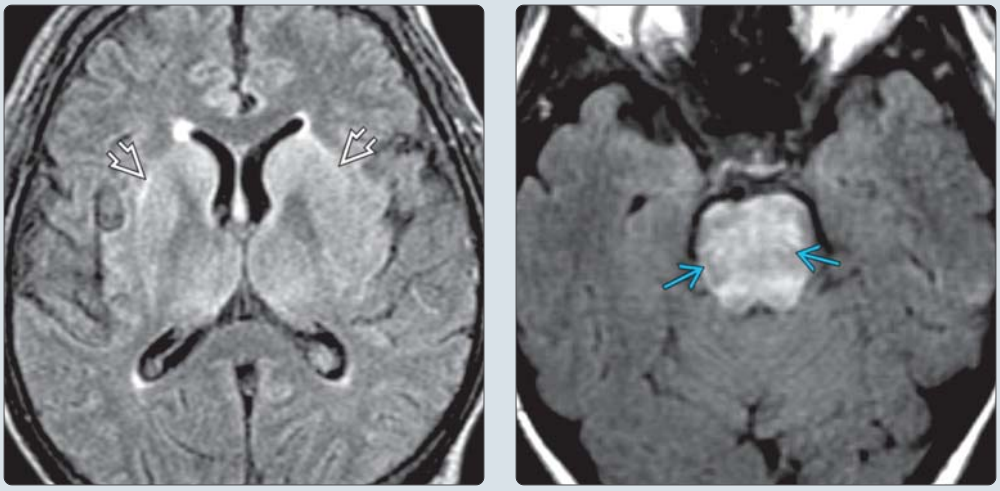

(Left) *Axial FLAIR MR shows symmetric abnormal hyperintensity in the basal ganglia ⇨ and thalami in this patient with West Nile virus encephalitis. Symmetric appearance of deep gray nuclei involvement mimics toxic and metabolic etiologies.* **(Right)** *Axial FLAIR MR in a patient with ataxia shows diffuse hyperintensity and enlargement of brainstem ⇨. Rhombencephalitis is often caused by viruses; other pathogens include Listeria monocytogenes, Legionnaire, Mycoplasma, Lyme disease.*

https://CafePezeshki.IR

TERMINOLOGY

Definitions

- Diffuse brain parenchymal inflammation caused by variety of pathogens, most commonly viruses
- Location dependent on etiology

IMAGING

General Features

- Best diagnostic clue
  - Abnormal T2 hyperintensity of gray matter (GM) ± white matter (WM) or deep gray nuclei
  - Large, poorly delineated areas of involvement common, ± patchy hemorrhage
  - Imaging is often nonspecific
- Location
  - Herpes simplex virus type 1 (**HSV1**): Limbic system
  - Cytomegalovirus (**CMV**): Deep periventricular WM
  - Epstein-Barr virus (**EBV**)
    - Multifocal, diffuse involvement of brain and spinal cord
    - Splenium of corpus callosum
  - Varicella-zoster virus (**VZV**)
    - Varicella: May affect multifocal areas of cortex
    - Zoster: Brainstem/cortical GM, cranial nerves
  - **Cerebellitis**: Bilateral cerebellar hemispheres
  - Eastern equine encephalitis (**EEE**): BG and thalami
  - **Enteroviral** encephalomyelitis
    - **Enterovirus (EV) 71**: Posterior medulla, pons, midbrain, dentate nuclei, spinal cord
    - **Polio, Coxsackie**: Midbrain, anterior spinal cord
  - **Hantavirus**: Pituitary gland hemorrhage
  - **HIV-1**: Cerebral WM, brainstem, thalamus, BG
  - **Japanese encephalitis**: Bilateral thalami, brainstem, cerebellum, spinal cord, cerebral cortex
  - Murray Valley encephalitis (**MVE**): Bilateral thalami; may affect midbrain, cervical spinal cord
  - **Nipah viral encephalitis**: Multifocal WM
  - **Rabies encephalitis**: Brainstem, hippocampi, hypothalamus, WM, GM
  - **Rhombencephalitis**: Brainstem and cerebellum
  - **St. Louis encephalitis**: Substantia nigra
  - West Nile virus (**WNV**): BG &/or thalami; may affect brainstem, cerebral WM, substantia nigra, cerebellum, spinal cord

CT Findings

- NECT: Initial CT negative in vast majority of patients
  - Japanese encephalitis: May see thalamic hemorrhage

MR Findings

- T1WI
  - **Japanese encephalitis**: Low signal foci in WM, brainstem, BG, thalami bilaterally
  - **Rabies encephalitis**: Hyperintense bilateral BG (rare)
- T2WI
  - **CMV**: Deep periventricular WM patchy increased signal
  - **EBV**: Hyperintensity in BG, thalamus, cortex
  - **Varicella**: Multifocal increased cortical signal
  - **Zoster**: Increased signal in brainstem, cortex
  - **Cerebellitis**: Hyperintense cerebellar signal
  - **EEE**: Increased signal in BG and thalami; may involve brainstem, cortex, periventricular WM
  - Enteroviral encephalomyelitis (**EV71**): Hyperintense lesions in posterior medulla, pons, midbrain, dentate nuclei of cerebellum
    - Less common: Cervical cord, thalamus, putamen
  - **Japanese encephalitis**: High signal foci in WM, brainstem, BG, thalami bilaterally
  - **MVE**: Hyperintensity in bilateral thalami; may involve midbrain, cerebral peduncles
  - **Nipah viral encephalitis**: Multifocal WM hyperintensities; may affect GM
  - **Rabies encephalitis**: Ill-defined mild hyperintensity in brainstem, hippocampi, thalami, WM, BG
    - Paralytic rabies: Medulla and spinal cord hyperintensity
  - **Rhombencephalitis**: Patchy hyperintensity in pons, medulla, midbrain
  - **St. Louis encephalitis**: May see hyperintensity of substantia nigra, often normal
  - **WNV**: Hyperintensity in deep gray nuclei ± cerebral WM
- FLAIR
  - **Nipah encephalitis**: Discrete high-signal lesions in subcortical, deep WM ± GM
    - Confluent cortical involvement in relapsed and late-onset encephalitis
- T2* GRE
  - Japanese encephalitis: Thalamic hemorrhage
- DWI: Diffusion restriction is commonly seen
- T1 C+: Variable enhancement, none to intense
  - Meningeal enhancement can be seen
  - Herpes zoster oticus (Ramsay Hunt syndrome): Enhancing CN7, CN8, membranous labyrinth
- MRS: May help distinguish encephalitis from infarct

Imaging Recommendations

- Protocol advice
  - Multiplanar MR with FLAIR, DWI, and contrast

DIFFERENTIAL DIAGNOSIS

Acute Ischemia

- Typical vascular distribution, DWI positive

Autoimmune Encephalitis

- Often mediated by anti-NMDA receptors antibodies; subcortical white matter

Herpes Encephalitis

- Limbic system and temporal lobe involvement

Status Epilepticus

- Active seizures with cerebral hyperperfusion, BBB disruption causes abnormal signal and enhancement

Toxic/Metabolic Lesions

- Symmetric BG or thalamic involvement common

PATHOLOGY

General Features

- Etiology

https://CafePezeshki.IR

- Most (but not all) are caused by viruses
  - Viruses are obligate intracellular parasites
  - Replicate in skin or mucous membranes of respiratory, GI tracts
  - Spread of virus to CNS is hematogenous or neural
  - Some invade along CNS (i.e., HSV1 via lingual nerve to trigeminal ganglia)
  - Latent infections may reactivate, spread along meningeal branches
- **Herpes viruses** include HSV1, HSV2, CMV, EBV, VZV, B virus, HSV6, HSV7
  - HSV2: Neonatal encephalitis
- **Varicella:** Meningoencephalitis, cerebellar ataxia, and aseptic meningitis (< 1% of patients)
- **Zoster infection:** Encephalitis, neuritis, myelitis, or herpes ophthalmicus
  - Latent virus in ganglia of CN (often CN5 and CN7) can reactivate, spread to brainstem
  - Immunocompetent patients: Cranial and peripheral nerve palsies
  - Immunosuppressed patients: Diffuse encephalitis
  - Herpes zoster ophthalmicus can cause internal carotid artery necrotizing angiitis
- **EBV:** Agent in infectious mononucleosis
  - Diffuse encephalitis seen in < 1% of patients
  - Associated with meningoencephalitis, Guillain-Barré syndrome, transverse myelitis
- **Enteroviruses** include Coxsackie viruses A and B, poliovirus, echoviruses, enteroviruses 68 to 71
- **Arboviruses** (arthropod-borne viruses) include Eastern, Western, and Venezuelan equine encephalitis, St. Louis encephalitis, Japanese B encephalitis, California encephalitis, tick-borne encephalitis
- **Nipah encephalitis**: Paramyxovirus related to close contact with infected pigs
  - Nipah encephalitis: Inflammation of small blood vessels with thrombosis and microinfarction
- **Rhombencephalitis:** Viruses (most commonly) , Listeria monocytogenes, Legionnaire disease, Mycoplasma, Lyme disease

Gross Pathologic & Surgical Features

- Vascular congestion, generalized or local edema, ± hemorrhage, necrosis

Microscopic Features

- Infiltration by polymorphonuclear cells (PMNs), lymphocytes, plasma cells, and mononuclear cells
- Perivascular cuffing characteristic
- May see inclusion bodies (i.e., Negri bodies in rabies)

CLINICAL ISSUES

Presentation

- Most common signs/symptoms
  - Varies widely: Slight meningeal to severe encephalitic symptoms, ± fever, prodrome
  - Varicella and herpes zoster: Different clinical manifestations of infection by same virus (VZV)
    - **Varicella encephalitis**: Fever, headache, vomiting, seizures, altered mental status days to weeks after onset of (chicken pox) rash
    - **Zoster**: Immunocompetent, CN and peripheral nerve palsies in dermatomes involved by skin lesions
      - CN5, ophthalmic branch most affected (herpes zoster ophthalmicus)
  - **Zoster**: Immunosuppressed patient with fever, meningismus, altered mental status
  - **Cerebellitis**: Sudden onset of limb &/or gait ataxia after infectious prodrome
  - Enterovirus encephalitis (**EV 71**)
    - Hand, foot, and mouth disease (HFMD): Fever, vesicles on hands, feet, elbows, knees, lips
    - Cranial neuropathies, ocular disturbance, dyspnea, tachycardia if brainstem involved
  - **Nipah virus**: Fever, headache, dizziness, vomiting; segmental myoclonus, areflexia, hypotonia, hypertension
  - **MVE**: Fever, headache, confusion, tremors; may progress to paralysis, coma, respiratory failure
  - **Rabies** (encephalitic): Fever, malaise, altered mental status, limbic dysfunction, autonomic stimulation
    - Paralytic: Weakness of all extremities
  - **Rhombencephalitis**: Areflexia, ataxia, ophthalmoplegia
  - **St. Louis encephalitis**: Tremors, fevers

Demographics

- Epidemiology
  - Herpes: Most common cause of sporadic (nonepidemic) viral encephalitis
  - Japanese encephalitis: Most common endemic encephalitis in Asia
  - CNS involvement in EBV is uncommon (< 10% of cases)
  - VZV: < 1% have CNS involvement
  - Marked seasonal variation in USA

Natural History & Prognosis

- Many encephalitides have high morbidity, mortality
- Rapid diagnosis, early treatment with antiviral or antibacterial agents can decrease mortality, may improve outcome

DIAGNOSTIC CHECKLIST

Consider

- Imaging often nonspecific, mimics other etiologies
- Clinical and travel history often helpful

Image Interpretation Pearls

- DWI may detect lesions earlier than conventional MR

SELECTED REFERENCES

1. Griffiths MJ et al: Japanese encephalitis virus infection. Handb Clin Neurol. 123:561-76, 2014
2. Mahan M et al: Neuroimaging of viral infections of the central nervous system. Handb Clin Neurol. 123:149-73, 2014
3. Speers DJ et al: Clinical and radiological predictors of outcome for Murray Valley encephalitis. Am J Trop Med Hyg. 88(3):481-9, 2013
4. Handique SK: Viral infections of the central nervous system. Neuroimaging Clin N Am. 21(4):777-94, vii, 2011

https://CafePezeshki.IR

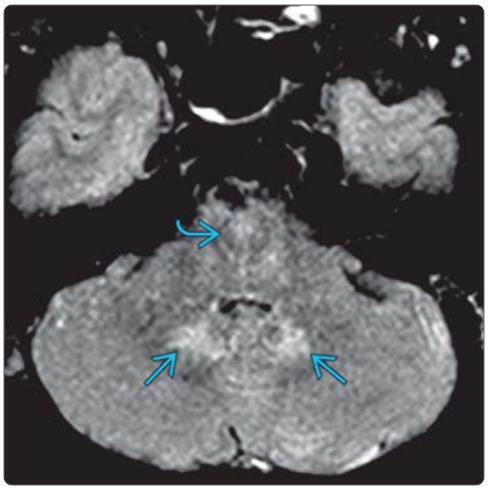

(Left) *Sagittal STIR MR in a patient with acute enterovirus encephalitis shows extensive T2 hyperintensity involving the medulla and cervical cord.* **(Right)** *Axial FLAIR MR in the same patient shows hyperintense signal in the medulla and dentate nuclei. Enterovirus encephalitis can involve the pons, medulla, midbrain, dentate nuclei, thalami, basal ganglia, and cervical spinal cord. Enteroviruses include Coxsackie viruses, poliovirus, echovirus, and enteroviruses 68-71.*

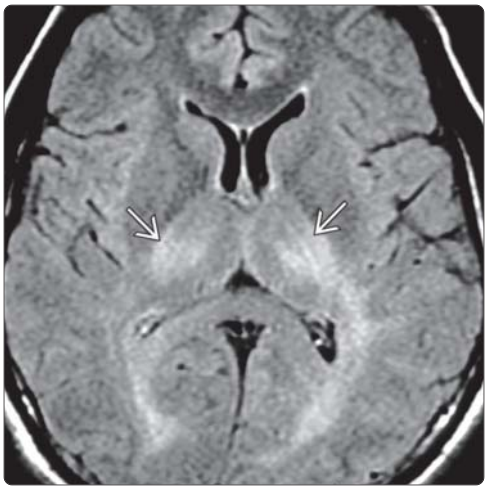

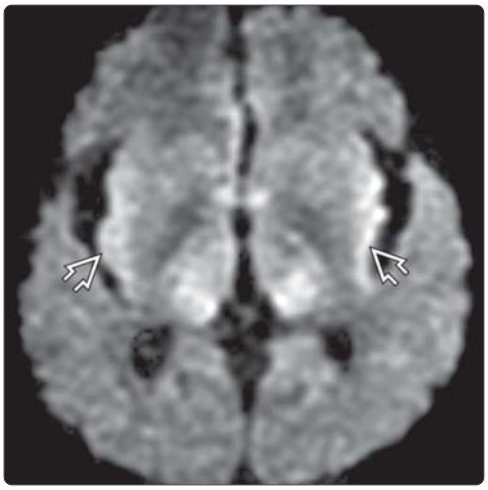

(Left) *Axial FLAIR MR shows symmetric hyperintense signal in the thalami in this patient with a history of infectious mononucleosis. EBV commonly involves the basal ganglia, thalami, cortex, &/or brainstem.* **(Right)** *Axial DWI MR shows symmetric diffusion restriction in the thalami and insular cortex in this patient with West Nile virus encephalitis. Basal ganglia and thalamic involvement is classic for West Nile virus encephalitis. DWI may help detect lesions earlier than conventional MR imaging.*

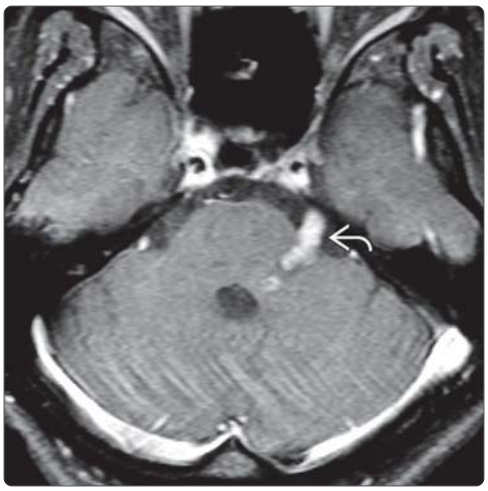

(Left) *Axial T1WI C+ MR shows enhancement of CN5, cisternal segment, root entry zone, and brachium pontis in this patient with trigeminal neuralgia. The ophthalmic branch (V1) is most affected in herpes zoster. Zoster commonly affects cranial nerves in immunocompetent patients. VZV encephalitis is rare.* **(Right)** *Sagittal T2WI MR shows diffuse enlargement and hyperintensity of the cervical spinal cord in this paralytic rabies patient. Paralytic rabies often affects the medulla and spinal cord.*

https://CafePezeshki.IR

KEY FACTS

TERMINOLOGY

- West Nile virus (WNV), West Nile fever (WNF), West Nile neuroinvasive disease (WNND)
- Mosquito-transmitted acute meningoencephalitis

IMAGING

- Head CT usually normal
- MR with DWI, T1 C+
  - Classic: Bilateral basal ganglia, thalamic hyperintensity
  - Patchy, poorly demarcated hyperintense foci in cerebral WM on T2WI/FLAIR
  - Enhancement usually absent (has been reported)
  - DWI may show restricted diffusion
- Other sites of involvement
  - Brainstem
  - Corpus callosum splenium
  - Mesial temporal lobes
  - Cerebellum
  - Spinal cord, cauda equina

PATHOLOGY

- WNV: Flavivirus (like Japanese encephalitis)
- Arthropod-transmitted (mosquito)

CLINICAL ISSUES

- Approximately 1/140 patients infected with WNV develop CNS symptoms
  - Incubation period: 3-14 days
- ~ 80% of infected individuals asymptomatic
  - Mild febrile syndrome (West Nile fever) in 20%
  - Meningoencephalitis in < 1%
  - Rare: Anterior myelitis
- CNS symptoms more common in diabetics, immunocompromised
- Treatment is supportive; hydration, antipyretics, airway and seizure management as indicated
- No human vaccine
  - Best way to prevent infection? Fight the bite
- Mortality rate is approximately 10%

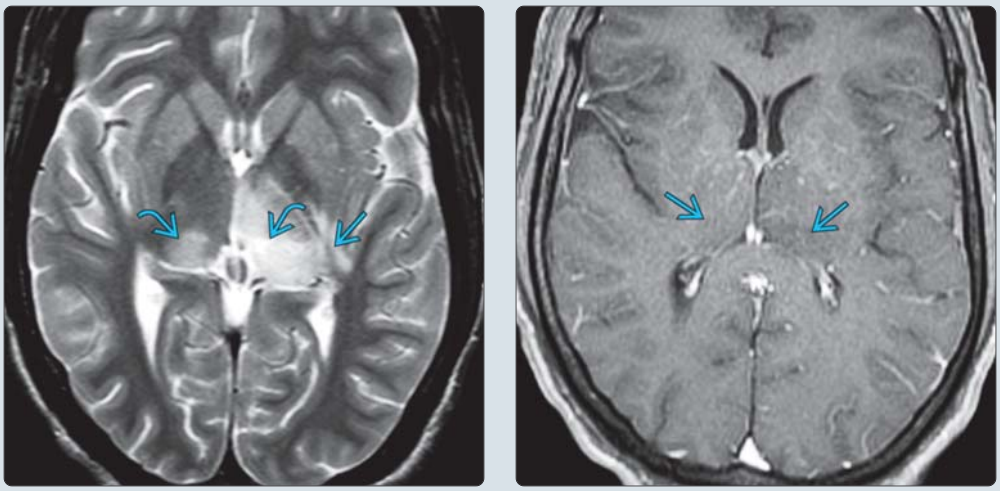

(Left) *Axial T2WI MR in a 24-year-old man with West Nile encephalitis demonstrates asymmetric T2 hyperintensity in the thalami. Posterior limb of left internal capsule is also involved.* **(Right)** *Axial T1 C+ MR in the same patient shows low signal in the thalami, more pronounced on the left with no abnormal enhancement. Anatomic areas commonly affected in West Nile encephalitis are basal ganglia, thalami, brainstem, mesial temporal structures, and cerebellum.*

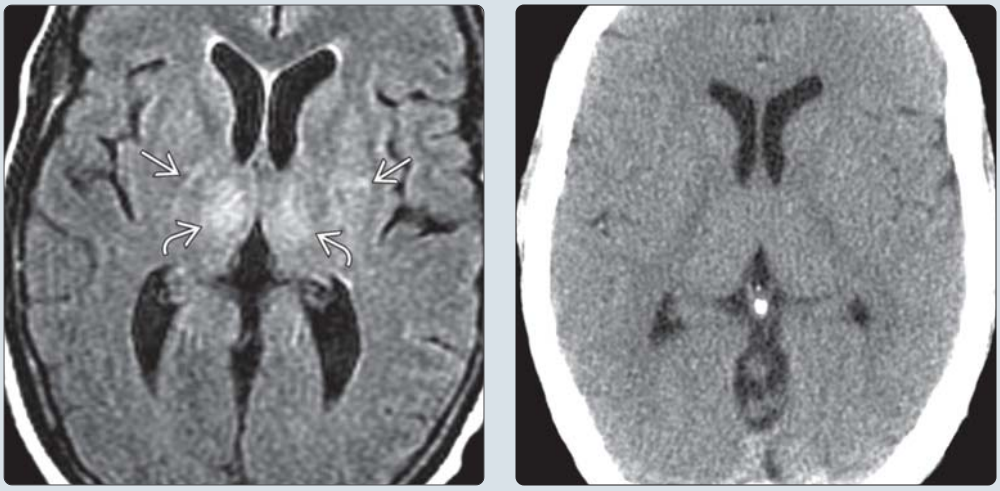

(Left) *Axial FLAIR MR in a patient with West Nile virus meningoencephalitis shows bilaterally symmetric high signal intensity in the thalami. There is subtle hyperintensity in the basal ganglia and right internal capsule.* **(Right)** *Axial NECT in the same patient performed 6 hours prior to the MR exam is normal. No edema is seen in the thalami or white matter. Indeed, early in the disease course, CT scans are frequently unremarkable.*

https://CafePezeshki.IR

TERMINOLOGY

Abbreviations

- West Nile virus (WNV), West Nile fever (WNF), West Nile neuroinvasive disease (WNND)

Definitions

- Mosquito-transmitted acute meningoencephalitis caused by West Nile arbovirus

IMAGING

General Features

- Best diagnostic clue
  - Bilateral basal ganglia &/or thalamic lesions
- Location
  - Classic: Bilateral basal ganglia, thalami
  - Cerebral white matter
  - Other
    - Brainstem
    - Corpus callosum splenium
    - Mesial temporal lobes
    - Cerebellum
    - Spinal cord, cauda equina

Imaging Recommendations

- Best imaging tool
  - Standard MR; include T1 C+, DWI

CT Findings

- Frequently normal

MR Findings

- Bilateral, frequently symmetric T2-hyperintense signal in basal ganglia, thalami, and brainstem
- Patchy, poorly demarcated foci of T2 signal in cerebral white matter on T2 and FLAIR sequences
- DWI may show restricted diffusion
- Enhancement usually absent (though has been reported)

DIFFERENTIAL DIAGNOSIS

Encephalitis (Other Infectious Etiologies)

- Herpes usually affects mesial temporal lobe(s)

Demyelinating Diseases

- e.g., ADEM, multiple sclerosis, Susac
- ADEM often (but not always) spares deep gray matter

PATHOLOGY

General Features

- Etiology
  - WNV: Flavivirus (like Japanese encephalitis)
    - Arthropod-transmitted (mosquito)
      - *Culex pipiens* is vector in eastern USA
      - *Culex quinquefasciatus* species in southeastern USA
      - *Culex tarsalis* species in western, midwestern USA
    - Mosquitos infect birds ("amplifying hosts")
      - Birds transmit infection to other biting mosquitos
      - Uncommonly infects humans/other mammals
    - Human-to-human transmission rare but reported
      - Blood transfusions, transplant recipients
      - Intrauterine exposure, conjunctival exposure
      - Breastfeeding, occupational exposure
- Genetics
  - Increased susceptibility to WNV disease in carriers with 2 mutated copies of gene *CCR5*

CLINICAL ISSUES

Presentation

- Most common signs/symptoms
  - ~ 80% of infected individuals asymptomatic
  - Mild febrile syndrome (WNF) in 20%
    - Fever, headache, fatigue, lymphadenopathy, arthralgia typical
    - May develop GI symptoms including nausea, vomiting, and diarrhea
    - Occasional truncal maculopapular rash
    - Incubation period: 3-14 days
  - Meningoencephalitis (WNND) in < 1%
    - Symptoms of mild febrile syndrome plus
      - Seizures, altered mental status, coma
      - Extrapyramidal signs (brisk followed by ↓ DTRs)
- Other signs/symptoms
  - Rare associations
    - Anterior myelitis ± encephalitis
      - Guillain-Barré syndrome
    - Multifocal chorioretinitis
    - Nephritis, hepatitis, myocarditis

Demographics

- Age
  - WNND more common in elderly
- Epidemiology
  - Approximately 1/140 patients infected with WNV develop CNS symptoms
  - CNS symptoms more common in diabetics, immunocompromised

Natural History & Prognosis

- Prolonged convalescent period with fatigue common
- Mortality rate is approximately 10%

Treatment

- No human vaccine
- Best way to prevent infection? Fight the bite
  - Wear light clothing that covers extremities
  - Use insect repellents
- Treatment is supportive
  - Hydration, antipyretics, airway and seizure management as indicated

SELECTED REFERENCES

1. Daep CA et al: Flaviviruses, an expanding threat in public health: focus on dengue, West Nile, and Japanese encephalitis virus. J Neurovirol. ePub, 2014
2. Racsa L et al: Clinical features of West Nile virus epidemic in Dallas, Texas, 2012. Diagn Microbiol Infect Dis. 78(2):132-6, 2014
3. Handique SK: Viral infections of the central nervous system. Neuroimaging Clin N Am. 21(4):777-94, vii, 2011
4. Kramer LD et al: West Nile virus. Lancet Neurol. 6(2):171-81, 2007
5. Ali M et al: West Nile virus infection: MR imaging findings in the nervous system. AJNR Am J Neuroradiol. 26(2):289-97, 2005

https://CafePezeshki.IR

HHV-6 Encephalitis

KEY FACTS

TERMINOLOGY
- Encephalitis caused by human herpes virus 6 (HHV-6)

IMAGING
- Immunocompromised patient with abnormal signal medial temporal lobe(s)
  - Limbic system: Hippocampus, amygdala, parahippocampal gyrus
  - Insular region, inferior frontal lobe involvement less common than herpes simplex encephalitis
- Atypical pattern in infants/children (basal ganglia, thalami, cerebellum, brainstem)
- Best imaging: MR (coronal T2/FLAIR, DWI, T1 C+)

TOP DIFFERENTIAL DIAGNOSES
- Herpes simplex virus (HSV) encephalitis
- Paraneoplastic limbic encephalitis
- Status epilepticus

PATHOLOGY
- HHV-6: DNA virus belongs to herpes virus family
- 2 variants: HHV-6A and HHV-6B
- Reactivation in immunocompromised patients

CLINICAL ISSUES
- Mental status changes, short-term memory loss, fever, seizure, headache
- Febrile seizures in infants
- Post hemopoietic stem cell transplant, lung/liver transplant
- Antiviral drugs: Ganciclovir and foscarnet
- Mortality of HHV-6 encephalitis > 50%

DIAGNOSTIC CHECKLIST
- Consider HHV-6 encephalitis in immunocompromised patients with CNS symptoms + unilateral/bilateral medial temporal lobe signal changes

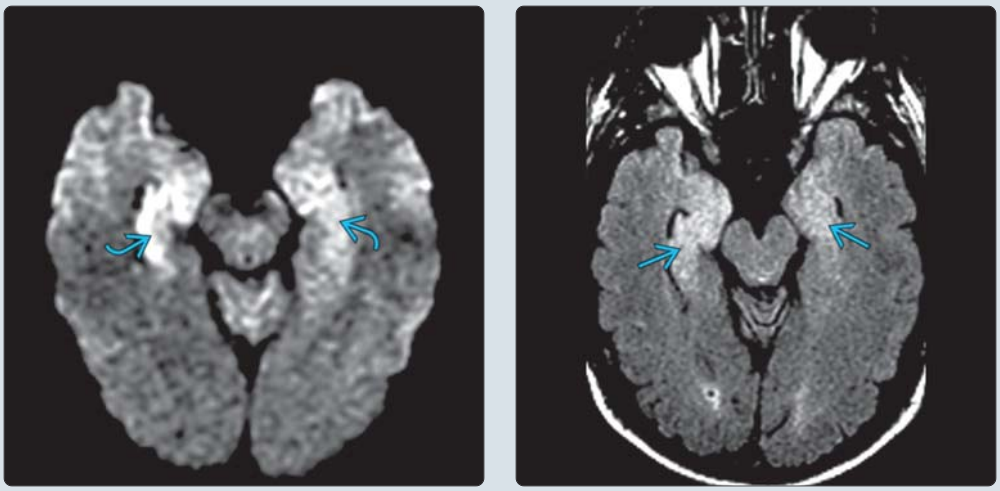

(Left) *Axial DWI MR in a 42-year-old patient post stem cell transplant who presented with altered sensorium demonstrates restricted diffusion in the hippocampi bilaterally, more pronounced on the right.* **(Right)** *Axial FLAIR MR in the same patient shows corresponding high signal in the hippocampi bilaterally, again more pronounced on the right. In this patient with immunosuppression, imaging findings are very typical for HHV-6 encephalitis*

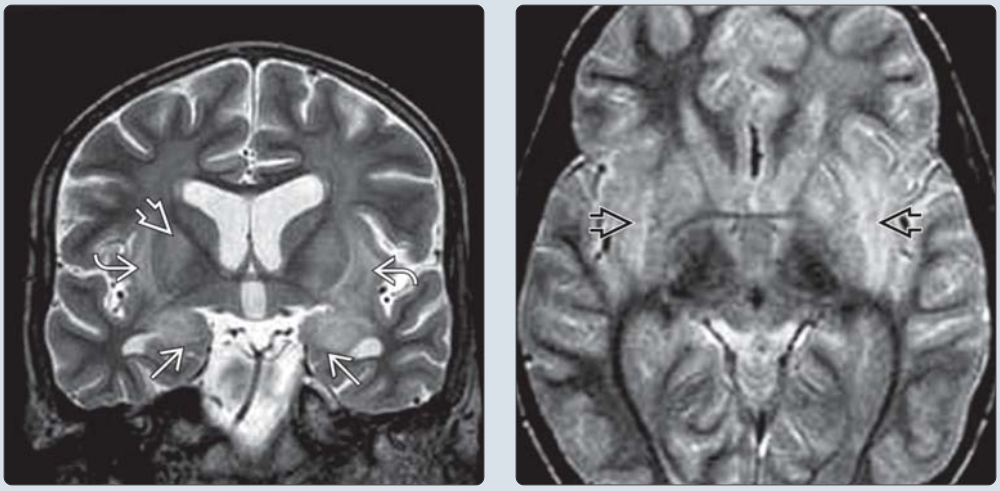

(Left) *Coronal T2WI MR in a 37-year-old man with immunosuppression, fever, and seizures shows hyperintense signal in the medial temporal lobes, basal ganglia, and subinsular white matter.* **(Right)** *Axial T2WI MR in the same patient shows asymmetric hyperintense signal in the subinsular white matter. Extrahippocampal involvement in HHV-6 encephalitis is less common than Herpes simplex encephalitis.*

https://CafePezeshki.IR

TERMINOLOGY

Abbreviations

- Human herpes virus 6 (HHV-6) encephalitis

Definitions

- Encephalitis caused by HHV-6

IMAGING

General Features

- Best diagnostic clue
  - Immunocompromised patient with abnormal signal in medial temporal lobe(s)
- Location
  - Limbic system: Hippocampus, amygdala
  - Insular region, inferior frontal lobe involvement less common than herpes simplex encephalitis
  - Atypical patterns seen in infants and children
    - Basal ganglia, thalami, cerebellum, brainstem

CT Findings

- NECT
  - CT often negative
- CECT
  - No abnormal enhancement

MR Findings

- T1WI
  - Decreased signal in medial temporal lobes
- T2WI
  - ↑ signal hippocampus, amygdala, typically bilateral but asymmetric
    - Insular region, inferior frontal lobe involvement less common
  - Early volume loss in hippocampus
- FLAIR
  - Hyperintense cortex/subcortical white matter
- DWI
  - May show restricted diffusion
- T1WI C+
  - Usually no enhancement

Imaging Recommendations

- Best imaging tool
  - MR (coronal T2/FLAIR, DWI, T1 C+)

DIFFERENTIAL DIAGNOSIS

Herpes Simplex Virus (HSV) Encephalitis

- Similar anatomic distribution
- Enhancement, DWI restriction more common

Paraneoplastic Limbic Encephalitis

- Paraneoplastic syndrome associated with primary tumor
- Symptom onset insidious

Status Epilepticus

- Medial temporal signal abnormalities with enhancement

PATHOLOGY

General Features

- Etiology
  - HHV-6: DNA virus belongs to herpes virus family
  - 2 variants: HHV-6A and HHV-6B
    - 90% general population seropositive for HHV-6 by 2 years of age
  - Primary infection < age 2, febrile exanthem (Roseola infantum/6th disease) or asymptomatic
  - Virus enters body through salivary gland, remains latent; salivary glands, WBC cells, and brain
  - Reactivation in immunocompromised patients

Gross Pathologic & Surgical Features

- Small necrotic changes in limbic structures

Microscopic Features

- Severe neuronal loss, reactive astrocytosis, detection of HHV-6 P41/P101 protein in astrocytes & neurons

CLINICAL ISSUES

Presentation

- Most common signs/symptoms
  - Mental status changes, short-term memory loss, fever, seizure, headache
  - Febrile seizures in infants
- Clinical profile
  - CSF: Lymphocytic pleocytosis and ↑ protein
  - PCR detection HHV-6 DNA in CSF: High specificity

Demographics

- Epidemiology
  - Most children primary infection < 2 years old
  - Reactivation in immunocompromised
    - Post hemopoietic stem cell transplant, lung/liver transplant

Natural History & Prognosis

- Mortality of HHV-6 encephalitis > 50%

Treatment

- Antiviral drugs: Ganciclovir and foscarnet
- Acyclovir (treatment for HSV encephalitis) ineffective

DIAGNOSTIC CHECKLIST

Consider

- HHV-6 encephalitis in immunocompromised patients with CNS symptoms + unilateral/bilateral medial temporal lobe signal changes

Image Interpretation Pearls

- MR (FLAIR, T2 most sensitive)

SELECTED REFERENCES

1. Ward KN: Child and adult forms of human herpesvirus 6 encephalitis: looking back, looking forward. Curr Opin Neurol. 27(3):349-55, 2014
2. Bhanushali MJ et al: Human herpes 6 virus encephalitis complicating allogeneic hematopoietic stem cell transplantation. Neurology. 80(16):1494-500, 2013
3. Nath A et al: Novel approaches and challenges to treatment of central nervous system viral infections. Ann Neurol. 74(3):412-22, 2013

https://CafePezeshki.IR

KEY FACTS

TERMINOLOGY

- Acute cerebellitis

IMAGING

- Bilateral cerebellar hemispheric gray and white matter low attenuation (NECT), T2/FLAIR hyperintensity (MR); unilateral involvement less common
- Confluent regions of T2 prolongation, affecting gray and white matter
- ± pial or subtle parenchymal enhancement
- DWI/ADC → affected regions typically show increased diffusivity

TOP DIFFERENTIAL DIAGNOSES

- Acute disseminated encephalomyelitis
- Infiltrating cerebellar neoplasm
- Cerebellar infarct

PATHOLOGY

- Reported in association with varicella, Epstein-Barr, enterovirus, rotavirus, HHV-7, mumps, measles, influenza & mycoplasma pneumoniae
- In most cases, definite etiology remains unknown
- Moderate to severe cerebellar swelling → vascular compression, upward transtentorial herniation, tonsillar herniation, brainstem compression, obstructive hydrocephalus

CLINICAL ISSUES

- Truncal ataxia, dysmetria, & headache
- Symptoms of ↑ ICP: Irritability, occipital headache and vomiting may overshadow manifestations of cerebellar dysfunction
- Most symptoms and signs resolve completely over weeks to months
- Surgery rarely necessary to decompress herniating cerebellum, ventricular drain for hydrocephalus

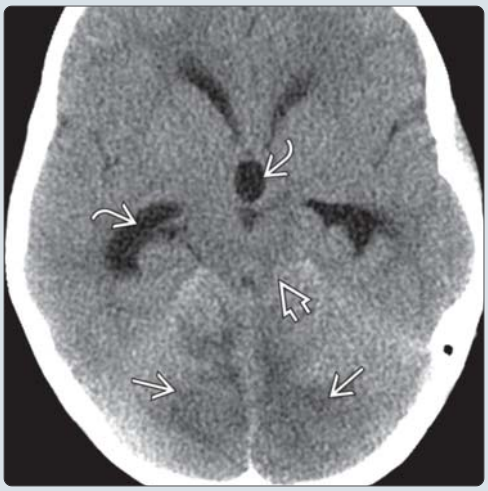

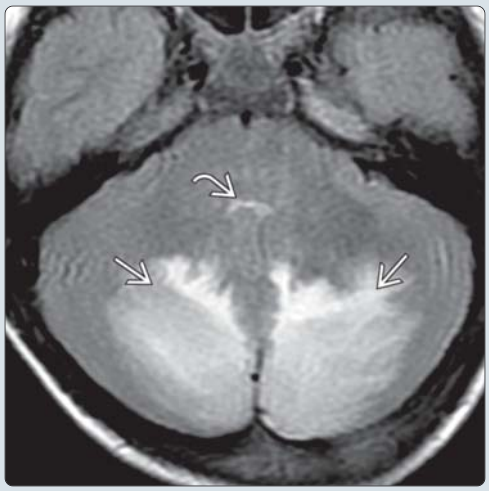

(Left) *Axial NECT in a 4-year-old girl with proven influenza A infection shows cerebellar hemispheric edema (low attenuation) involving both gray and white matter. The edema causes upward cerebellar herniation and effacement of the quadrigeminal plate cistern. The resultant aqueductal compression causes hydrocephalus.* **(Right)** *Axial T2WI MR demonstrates cerebellar edema (T2 hyperintensity) involving both gray and white matter. Note the compressed 4th ventricle.*

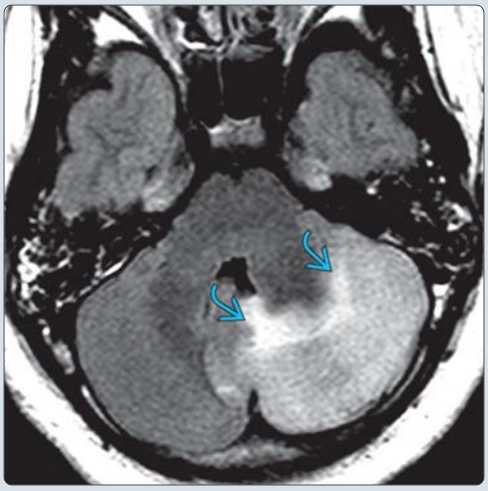

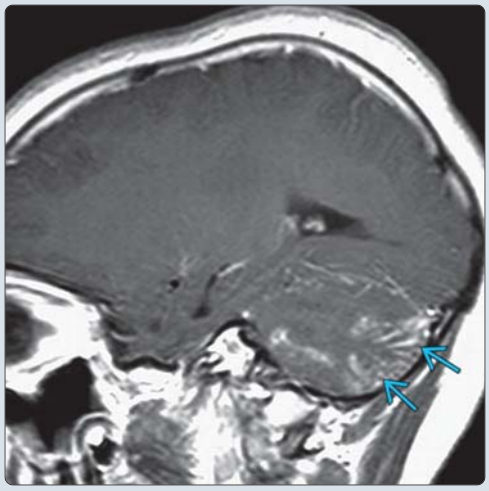

(Left) *Axial FLAIR MR in a 12 year old with acute onset of cerebellar ataxia demonstrates high signal in the left cerebellar hemisphere. Note mild mass effect on the 4th ventricle.* **(Right)** *Sagittal T1+C MR in the same patient shows patchy areas of pial enhancement along the left cerebellar hemisphere. In acute cerebellitis, unilateral involvement is far less common than bilateral.*

https://CafePezeshki.IR

TERMINOLOGY

Synonyms

- Acute cerebellitis

Definitions

- Parainfectious, postinfectious, or postvaccination cerebellar inflammation

IMAGING

General Features

- Best diagnostic clue
  - Bilateral cerebellar hemispheric gray and white matter low attenuation (NECT), T2/FLAIR hyperintensity (MR); unilateral involvement less common
- Location
  - Cerebellar gray and white matter, typically bilateral

Imaging Recommendations

- Best imaging tool
  - MR, including C+, DWI, MRS

CT Findings

- NECT
  - Bilateral or less commonly unilateral low attenuation involving gray and white matter of cerebellar hemispheres

MR Findings

- T1WI
  - Regions of T1 hypointensity in cerebellum
- T2WI
  - T2 hyperintensity affecting gray and white matter of cerebellum
- DWI
  - Typically shows increased diffusivity
- T1WI C+
  - ± pial or subtle parenchymal enhancement
- MRS
  - Acutely: ↑ excitatory neurotransmitters, ↑ choline, ± lactate and lipid, NL to ↓ NAA

DIFFERENTIAL DIAGNOSIS

Acute Disseminated Encephalomyelitis (ADEM)

- Look for supratentorial peripheral white matter, basal ganglia (BG), and brainstem lesions

Cerebellar Neoplasm (Infiltrating)

- Typical bilateral involvement of gray and white matter in cases of cerebellitis is helpful
- Use MRS as adjunct when tumor is considered (↓ NAA, ± ↓ creatine, ↑ choline, myoinositol, ± lactate and lipid)

Cerebellar Infarct

- Typical vascular distribution, DWI positive

PATHOLOGY

General Features

- Etiology
  - Reported in association with varicella, Epstein-Barr, enterovirus, rotavirus, HHV-7, mumps, measles, influenza & mycoplasma pneumoniae
  - Post varicella vaccine
  - In most cases, definite etiology remains unknown
- Associated abnormalities
  - Moderate to severe cerebellar swelling → vascular compression, upward transtentorial herniation, tonsillar herniation, brainstem compression, obstructive hydrocephalus

Gross Pathologic & Surgical Features

- Acutely, cerebellar edema, nonhemorrhagic involving gray and white matter

Microscopic Features

- Acute: Edema with lymphocytic & eosinophilic infiltrates
- Chronic: ± cerebellar atrophy

CLINICAL ISSUES

Presentation

- Most common signs/symptoms
  - Truncal ataxia, dysmetria & headache
  - Symptoms of ↑ ICP: Irritability, occipital headache, and vomiting may overshadow manifestations of cerebellar dysfunction

Demographics

- Age
  - Usually in younger children
- Epidemiology
  - Typically follows viral infection
    - Delayed presentation may occur after varicella zoster infection (chicken pox or herpes zoster ophthalmicus)

Natural History & Prognosis

- Most symptoms and signs resolve completely over weeks to months
- Severe cases with herniation & hydrocephalus: Variable outcome from full recovery to death

Treatment

- Typically supportive, ± steroids, ± antivirals if specific diagnosis is confirmed
- Surgery rarely necessary to decompress herniating cerebellum, ventricular drain for hydrocephalus

DIAGNOSTIC CHECKLIST

Consider

- Acute cerebellitis when bihemispheric GM and WM cerebellar involvement

Image Interpretation Pearls

- Bilateral cerebellar hemispheric gray and white matter edema; unilateral involvement less common

SELECTED REFERENCES

1. Desai J et al: Acute cerebellar ataxia, acute cerebellitis, and opsoclonus-myoclonus syndrome. J Child Neurol. 27(11):1482-8, 2012
2. De Bruecker Y et al: MRI findings in acute cerebellitis. Eur Radiol. 14(8):1478-83, 2004

https://CafePezeshki.IR

KEY FACTS

TERMINOLOGY

- Chronic focal (localized) encephalitis
- Chronic, progressive, unilateral brain inflammation of uncertain etiology
- Characterized by drug-resistant focal epilepsy, progressive hemiplegia, cognitive decline

IMAGING

- Unilateral progressive cortical atrophy
- CT/MR: Normal → cortical swelling → atrophy
- Usually unilateral, predominantly frontoinsular
- Best imaging tools: MR with contrast, ± PET (FDG)

TOP DIFFERENTIAL DIAGNOSES

- Sturge-Weber syndrome
- Other autoimmune encephalitides (often bilateral)
- Hemispheric infarction (Dyke-Davidoff-Masson)

PATHOLOGY

- Hemispheric cortical atrophy
- Cortical inflammation, neuronal loss, gliosis

CLINICAL ISSUES

- Intractable partial epilepsy, clonic movements
  - Other: Hemiparesis, visual and sensory deficits, dysarthria, dysphasia, personality changes
- Partial complex seizures that increase in frequency → 20% present in status epilepticus
- Surgery only definitive treatment of seizures in RE

DIAGNOSTIC CHECKLIST

- Consider Rasmussen encephalitis when/if
  - ↑ frequency of partial complex seizures, postictal deficit in patients (1-15 years) with initial "normal" imaging
  - Intractable epilepsy with progressive atrophy of 1 hemisphere showing high T2 signal

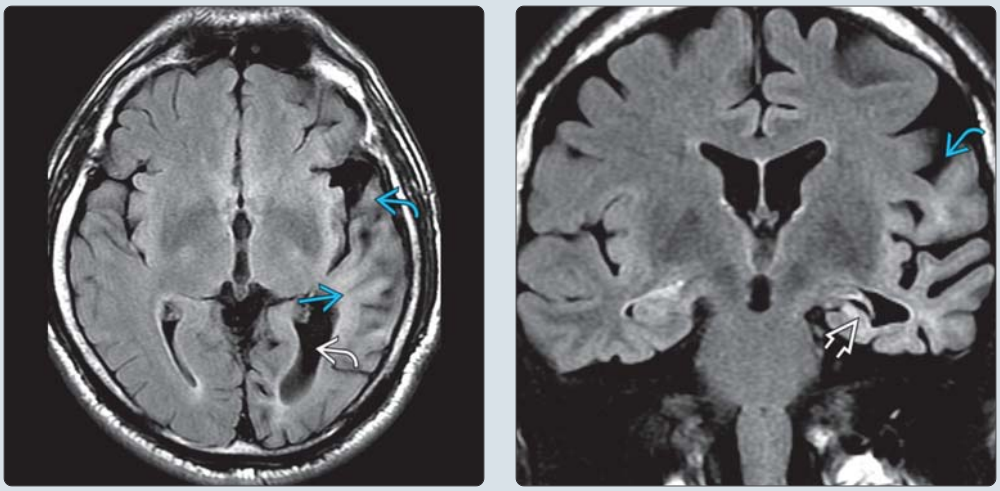

(Left) *Axial FLAIR MR in a patient with Rasmussen encephalitis demonstrates left perisylvian and posterior temporal volume loss with subcortical gliosis. Note ex vacuo dilatation of the posterior horn of the left lateral ventricle.* **(Right)** *Coronal FLAIR MR in the same patient demonstrates left perisylvian and temporal volume loss. Note the profound left hippocampal volume loss.*

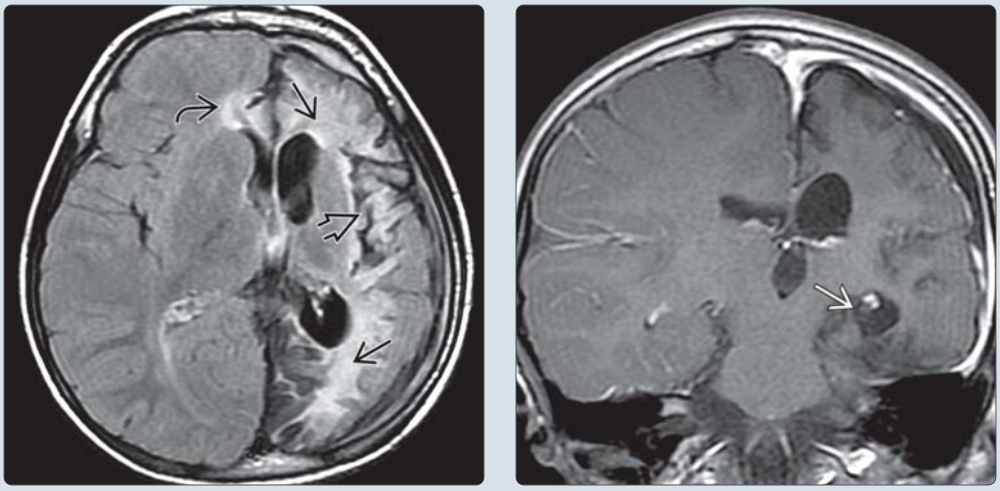

(Left) *Axial FLAIR MR shows atrophy of the left hemisphere. Gliosis is manifested as FLAIR hyperintensity. Note the insular cortical and subcortical atrophy and the involvement of the right frontal cortex.* **(Right)** *Coronal T1WI C+ MR shows extensive atrophy of the left hemisphere. Note the profound left hippocampal volume loss. Rasmussen encephalitis is distinguished on T1WI C+ MR from Sturge-Weber syndrome by the lack of enhancing leptomeningeal angiomatosis.*

https://CafePezeshki.IR

TERMINOLOGY

Abbreviations

- Rasmussen encephalitis (RE)

Synonyms

- Chronic focal (localized) encephalitis

Definitions

- Chronic, progressive, unilateral brain inflammation of uncertain etiology
- Characterized by hemispheric volume loss and difficulty controlling focal seizure activity

IMAGING

General Features

- Best diagnostic clue
  - Unilateral progressive cerebral atrophy
  - CT/MR often normal initially
    - Early cortical swelling, then cortical/subcortical T2/FLAIR hyperintensity with atrophy ensues
    - Most cerebral damage occurs in first 8-12 months after clinical onset of disease
- Location
  - Cerebral hemisphere
  - Usually unilateral, predominantly frontal/insular and parietal
    - Precentral, inferior frontal atrophy
      - Contralateral cerebellar volume loss (crossed cerebellar diaschisis)
- Size
  - Variable, usually lobar, occasionally entire hemisphere affected
- Morphology
  - Focal abnormality, "spreads across hemisphere"
  - Becomes progressively more diffuse

CT Findings

- NECT
  - Initially normal, → atrophy
- CECT
  - Usually no enhancement
  - **Rare** transient pial &/or cortical enhancement

MR Findings

- T1WI
  - Sulcal effacement due to early swelling
- T2WI
  - Early focal swelling of gyri
    - Gray-white matter (GM-WM) "blurring" and T2 prolongation
    - ± basal ganglia, hippocampi involvement
  - Late: Atrophy of involved cerebral hemisphere or lobe
- FLAIR
  - Cortical and subcortical areas of hyperintensity that progressively increase over time
  - Late: Atrophy, encephalomalacia/gliosis
- T2* GRE
  - Typically normal
  - Nonhemorrhagic
- DWI
  - Subtle high signal on trace images; ↑ diffusivity
- T1WI C+
  - Usually does not enhance
    - Occasionally, subtle pial &/or cortical enhancement
- MRS
  - ↓ N-acetyl-aspartate (NAA) and choline; ↑ myoinositol, ↑ glutamine/glutamate

Nuclear Medicine Findings

- Tc-99m HMPAO scintigraphy: ↓ perfusion even if normal MR
- PET/SPECT
  - ↓ diffuse hemispheric metabolism/perfusion
  - Crossed cerebellar diaschisis
  - Transient hypermetabolism may be related to recent seizures (rare)
    - C-11-methionine shows increased multifocal uptake

Imaging Recommendations

- Best imaging tool
  - MR + clinical signs/symptoms + appropriate EEG findings
- Protocol advice
  - MR with contrast, ± PET (FDG)

DIFFERENTIAL DIAGNOSIS

Sturge-Weber Syndrome

- Port wine facial nevus and enhancement of pial angioma
- Progressive hemispheric atrophy
- Cortical Ca++

MELAS (Mitochondrial Encephalopathy, Lactic Acidosis, and Stroke-Like Episodes)

- Acute: May cause cortical hyperintensity (parietooccipital most common), + DWI
- Chronic: Cortical atrophy, lacunes (basal ganglia, thalami)

Dyke-Davidoff-Masson (Prenatal/Neonatal Hemispheric Infarction)

- Unilateral brain atrophy
- Compensatory calvarial thickening
- Elevation of petrous ridge and hyperaeration of paranasal sinuses
- Following in utero or perinatal infarct

Focal Cortical Dysplasia

- May cause hemispheric status epilepticus, resulting in unilateral volume loss

Other Autoimmune Inflammatory Disorders

- Unilateral cerebral vasculitis, paraneoplastic syndromes, onconeural antibodies

PATHOLOGY

General Features

- Etiology
  - Etiology & pathogenesis of RE remains unkown
  - Evidence for immunopathological basis is growing
    - Antibody-mediated, T-cell cytotoxicity & microglial-induced degeneration
- Genetics

https://CafePezeshki.IR

- Possibly viral trigger of genetic predisposition to immunodysfunction
- Associated abnormalities
  - 3 potentially overlapping factors may initiate or perpetuate events leading to injury
    - Viral infection
    - Autoimmune antibodies
    - Autoimmune cytotoxic T lymphocytes

Staging, Grading, & Classification

- 3 disease stages of RE
  - Prodromal stage: Nonspecific, low seizure frequency, & mild hemiplegia
  - Acute stage: Frequent seizures, often epilepsia partialis continua, progressive hemiparesis, cognitive deterioration
  - Residual stage: Permanent and stable neurological deficits & continuing seizures
- Classification and staging: MR (T2WI)
  - Stage 1: Swelling/hyperintense signal
  - Stage 2: Normal volume/hyperintense signal
  - Stage 3: Atrophy/hyperintense signal
  - Stage 4: Progressive atrophy and normal signal

Gross Pathologic & Surgical Features

- Hemispheric cortical atrophy
- Area of damage often surrounded by normal cortex or mild inflammation
  - Biopsy can be misleading

Microscopic Features

- Robitaille classification describes cortical inflammation, neuronal loss, and gliosis confined to 1 hemisphere
  - Group 1 (pathologically active): Ongoing inflammatory process
    - Microglial nodules, ± neuronophagia, perivascular round cells
  - Group 2 (active and remote disease): Acute on chronic
    - Above plus ≥ 1 gyral segment of complete necrosis and cavitation including full thickness cortex
  - Group 3 (less active "remote" disease)
    - Neuronal loss/gliosis and fewer microglial nodules
  - Group 4 (burnt out)
    - Nonspecific scarring with little active inflammation

CLINICAL ISSUES

Presentation

- Most common signs/symptoms
  - Intractable epilepsy, clonic movements
  - Progresses to epilepsia partialis continua
  - Other: Hemiparesis, visual and sensory deficits, dysarthria, dysphasia, personality changes
- Clinical profile
  - Young child with progressive partial epilepsy unresponsive to medical therapy
- Clinical course
  - Partial complex seizures that increase in frequency
  - 20% present in status epilepticus
  - Followed by worsening seizures, progressive hemiparesis, cognitive deterioration, death
- EEG: Initial normal to persistent unilateral slowing ± epileptiform activity
- CSF: ± oligoclonal bands

Demographics

- Age
  - Usually begins in childhood (6-8 years)
  - 10% present as adolescent or adult
- Gender
  - M = F
- Ethnicity
  - No predilection
- Epidemiology
  - Preceded by inflammatory episode (50%)
    - Tonsillitis, upper respiratory infection, otitis media

Natural History & Prognosis

- Hemiplegia and cognitive deterioration in most cases
- Older patients have longer prodromal stage and protracted course
- Prognosis is poor
- Hemiplegia is inevitable ± treatment

Treatment

- Refractory to antiepileptic medications
- ± transient improvement with plasma exchange, IVIG therapy, steroids, B-cell & T-cell directed agents
- Surgery only definitive treatment of seizures in RE
  - Functional hemispherectomy/central disconnection
  - Hemispherotomy

DIAGNOSTIC CHECKLIST

Image Interpretation Pearls

- Consider Rasmussen encephalitis
  - ↑ frequency of partial complex seizures + postictal deficit in patients (1-15 years) with initial "normal" imaging
  - Intractable epilepsy with progressive atrophy of 1 hemisphere showing high T2 signal

SELECTED REFERENCES

1. Leypoldt F et al: Autoimmune encephalopathies. Ann N Y Acad Sci. ePub, 2014
2. Press C et al: The Janus-faced nature of Rasmussen's encephalitis. Semin Pediatr Neurol. 21(2):129-36, 2014
3. Varadkar S et al: Rasmussen's encephalitis: clinical features, pathobiology, and treatment advances. Lancet Neurol. 13(2):195-205, 2014
4. Nabbout R: Autoimmune and inflammatory epilepsies. Epilepsia. 53 Suppl 4:58-62, 2012
5. Takei H et al: Dual pathology in Rasmussen's encephalitis: a study of seven cases and review of the literature. Neuropathology. 30(4):381-91, 2010
6. Cauley KA et al: Diffusion tensor imaging and tractography of Rasmussen encephalitis. Pediatr Radiol. 39(7):727-30, 2009
7. Faingold R et al: MRI appearance of Rasmussen encephalitis. Pediatr Radiol. 39(7):756, 2009
8. Tessonnier L et al: Perfusion SPECT findings in a suspected case of Rasmussen encephalitis. J Neuroimaging. 19(4):378-80, 2009
9. Bien CG et al: Diagnosis and staging of Rasmussen's encephalitis by serial MRI and histopathology. Neurology. 58(2):250-7, 2002

https://CafePezeshki.IR

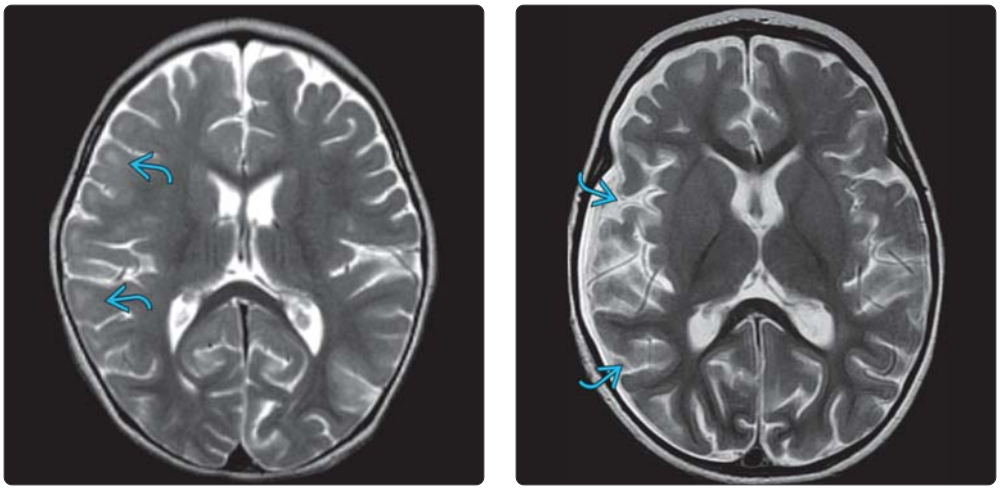

(Left) *Axial T2WI MR in a 1 year old with drug-resistant focal seizures and progressive left hemiparesis demonstrates subtle T2 hyperintensity in the right hemisphere subcortical white matter.* **(Right)** *Axial T2WI MR in the same patient after 1 month shows marked right hemisphere volume loss with prominence of the sulci. Serial MR in Rasmussen encephalitis shows progression of atrophy and cortical/subcortical signal change.*

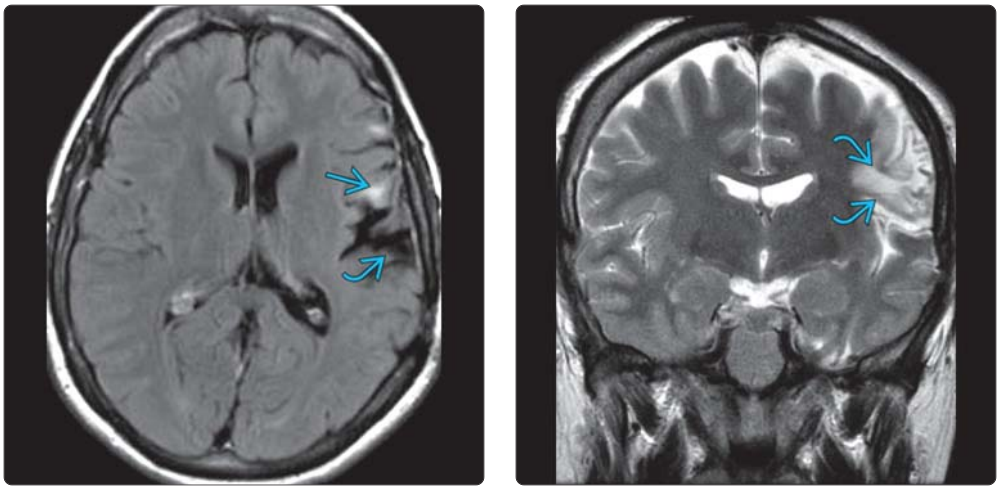

(Left) *Axial FLAIR MR in a patient with Rasmussen encephalitis (biopsy proven) shows prominence of the left perisylvian fissure due to volume loss.There is associated subcortical gliosis in the frontal operculum.* **(Right)** *Coronal T2WI MR in the same patient demonstrates left frontal opercular volume loss and gliosis.*

(Left) *Axial T1WI MR in a 4-year-old girl with chronic localized Rasmussen encephalitis demonstrates marked atrophy of the frontal lobe. Note the ex vacuo dilation of the left frontal horn and the enlargement of the circular sulcus reflecting insular volume loss.* **(Right)** *Axial FLAIR MR in the same patient shows atrophy of the superior frontal and middle frontal gyrus. Atrophy and subcortical gliosis extends into the left inferior frontal gyrus.*

https://CafePezeshki.IR

KEY FACTS

TERMINOLOGY

- Definition: Rare, progressive, measles virus-mediated encephalitis

IMAGING

- CT: Imaging often initially normal; cortical swelling, cortical/subcortical hypoattenuation
- MR: Ill-defined T2 hyperintensities in periventricular or subcortical white matter
  - Frontal > parietal > occipital; no mass effect
- MRS: Increased choline and myoinositol; decreased NAA (may precede MR abnormalities)

TOP DIFFERENTIAL DIAGNOSES

- Acute disseminated encephalomyelitis
- Tumefactive multiple sclerosis
- Human immunodeficiency virus
- Progressive multifocal leukoencephalopathy

PATHOLOGY

- Postinfectious progressive encephalitis years after measles infection

CLINICAL ISSUES

- Behavioral changes, mental deterioration, ataxia, myoclonus & visual disturbances
- Begins insidiously; subacute course; death (1-3 years after symptom onset)
- Positive CSF, plasma complement fixation test for measles; CSF plus oligoclonal bands

DIAGNOSTIC CHECKLIST

- Consider subacute sclerosing panencephalitis in immigrant child with behavioral changes and multifocal white matter disease

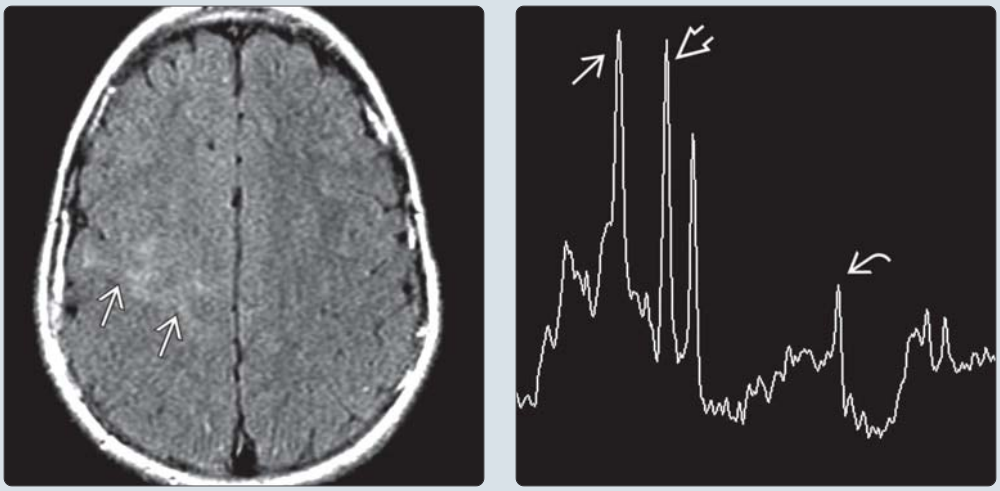

(Left) *Axial FLAIR MR in a 7-year-old boy with worsening gait disturbance and myoclonic jerks shows subtle right posterior frontal lobe cortical and subcortical white matter FLAIR hyperintensity* ⇨. **(Right)** *Single voxel proton MRS (TE = 35 ms) from the right parietal subcortical white matter in the same patient shows increased choline* ⇨ *and myoinositol* ⇨ *and a marked decrease in NAA* ⇨. *These metabolic changes were present with only subtle FLAIR and T2 signal abnormality.*

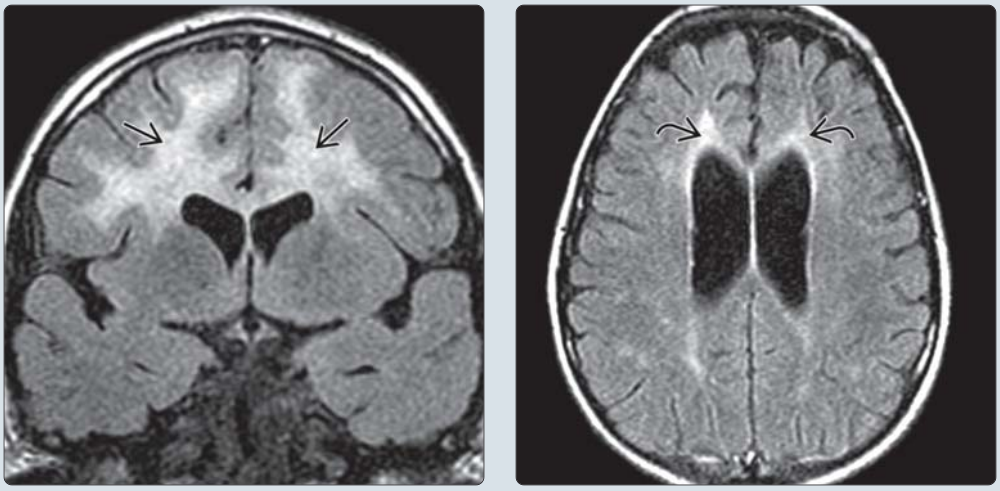

(Left) *Coronal FLAIR MR in a 7-year-old boy 6 months after initial presentation (following confirmatory CSF complement fixation test for measles) demonstrates progressive frontal lobe white matter FLAIR hyperintensity* ⇨. **(Right)** *Axial FLAIR MR in the same patient (10 months after initial clinical presentation with progressive cognitive deterioration and worsening myoclonus) shows bilateral frontal lobe white matter volume loss and FLAIR hyperintensity* ⇨ *(demyelination and gliosis).*

https://CafePezeshki.IR

TERMINOLOGY

Abbreviations

- Subacute sclerosing panencephalitis (SSPE)

Synonyms

- Dawson encephalitis

Definitions

- Progressive measles virus-mediated encephalitis

IMAGING

General Features

- Best diagnostic clue
  - T2 hyperintensities in periventricular, deep, or subcortical white matter (WM)
- Location
  - Frontal > parietal > occipital lobes

CT Findings

- NECT
  - Imaging often initially normal; cortical swelling, cortical/subcortical hypoattenuation

MR Findings

- T1WI
  - Areas of ↓ signal in WM, corpus callosum
- T2WI
  - ↑ signal in WM, frontal > parietal > occipital, generally symmetric and eventually leading to diffuse atrophy
- T1WI C+
  - No enhancement
- MRS
  - ↑ choline and myoinositol; ↓ NAA (may precede MR abnormalities)

Imaging Recommendations

- Best imaging tool
  - MR
- Protocol advice
  - MR + IV contrast + MRS

DIFFERENTIAL DIAGNOSIS

Acute Disseminated Encephalomyelitis

- Prior viral illness, peripheral areas of ↑ T2 signal

Tumefactive Multiple Sclerosis

- Mass-like lesions in periventricular WM, perimeter enhancement

Human Immunodeficiency Virus

- Atrophy, ill-defined areas of ↑ T2 signal in WM
- ↑ attenuation of basal ganglia (NECT)

Progressive Multifocal Leukoencephalopathy

- Areas of ↑ T2 signal, immunocompromised (AIDS, cancer) patients

PATHOLOGY

General Features

- Etiology
  - Postinfectious progressive encephalitis years after measles infection

Gross Pathologic & Surgical Features

- Early diffuse cerebral swelling; subcortical & periventricular white matter, basal ganglia
- Rapidly progressive diffuse cortical atrophy

Microscopic Features

- Leptomeningeal, parenchymal, and perivascular inflammation
- Reactive gliosis with white matter demyelination, intranuclear inclusions in neurons & oligodendroglia

CLINICAL ISSUES

Presentation

- Most common signs/symptoms
  - Behavioral changes, mental deterioration, ataxia, myoclonus, & visual disturbances
- Clinical profile
  - Positive CSF, plasma complement fixation test for measles; CSF plus oligoclonal bands
  - EEG: Periodic complexes with generalized polyspike, high-voltage slow waves

Demographics

- Age
  - Childhood, early adolescence; rare in adults
- Epidemiology
  - History of measles before age 2 in most patients → 16x risk of developing SSPE

Natural History & Prognosis

- Minor behavioral changes; motor dysfunction (myoclonic jerks); death (1-3 years after symptom onset)

Treatment

- No treatment, but there are some benefits from intraventricular α-interferon and Isoprinosine

DIAGNOSTIC CHECKLIST

Consider

- SSPE in immigrant child with behavioral changes and multifocal WM disease

Image Interpretation Pearls

- MR findings correlate poorly with clinical stage

SELECTED REFERENCES

1. Fisher DL et al: Measles-induced encephalitis. QJM. Epub ahead of print, 2014
2. Hatanpaa KJ et al: Neuropathology of viral infections. Handb Clin Neurol. 123:193-214, 2014
3. Anlar B: Subacute sclerosing panencephalitis and chronic viral encephalitis. Handb Clin Neurol. 112:1183-9, 2013
4. Buchanan R et al: Measles virus and associated central nervous system sequelae. Semin Pediatr Neurol. 19(3):107-14, 2012

https://CafePezeshki.IR

KEY FACTS

TERMINOLOGY

- Typically causes tuberculous meningitis (TBM) &/or localized CNS infection, tuberculoma

IMAGING

- Basilar meningitis + extracerebral TB (pulmonary)
- Meningitis + parenchymal lesions highly suggestive
- Tuberculomas
  - Supratentorial parenchyma most common
  - Usually T2 hypointense
  - Enhances strongly (solid or ring enhancing)
- Tuberculous abscess: Multiloculated ring enhancement
- MR with FLAIR, DWI, T1 C+, ± MRA, MRS
- TB abscess has prominent lipid, lactate but no amino acid resonances

TOP DIFFERENTIAL DIAGNOSES

- Meningitis
- Neurosarcoidosis
- Abscess
- Neoplasm

PATHOLOGY

- CNS TB almost always secondary (often pulmonary source)
- Meningitis = most frequent manifestation of CNS TB
  - More common in children

CLINICAL ISSUES

- Varies from mild meningitis with no neurologic deficit to coma
- Long-term morbidity in up to 80%: Mental retardation, paralysis, seizures, rigidity, speech or visual deficits
- Mortality in 25-30% of patients; higher in AIDS patients
- Reemerging disease (immigration from endemic areas, AIDS, drug-resistant strains)

DIAGNOSTIC CHECKLIST

- TB often mimics other diseases, such as neoplasm

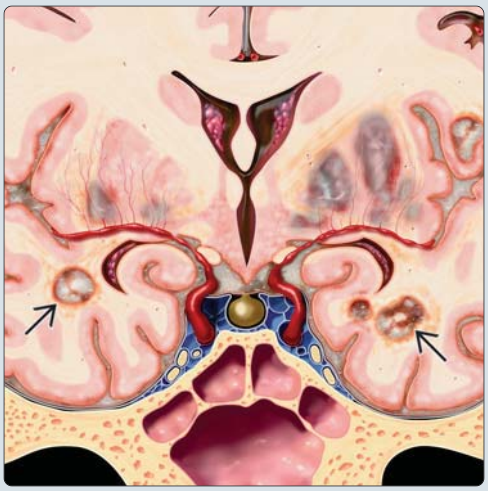

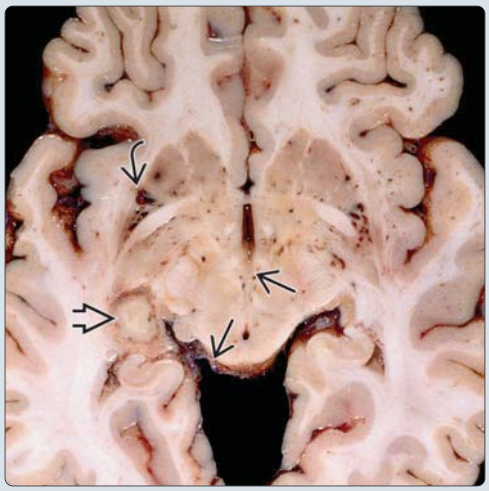

(Left) *Coronal graphic shows basilar TB meningitis and tuberculomas, which often coexist. Note the vessel irregularity and early basal ganglia ischemia related to arteritis.* **(Right)** *Axial gross pathology section shows numerous features of CNS TB. Exudates with meningitis in the basilar cisterns, tuberculoma, and vasculitic changes are all present in this autopsy specimen. (Courtesy R. Hewlett, MD.)*

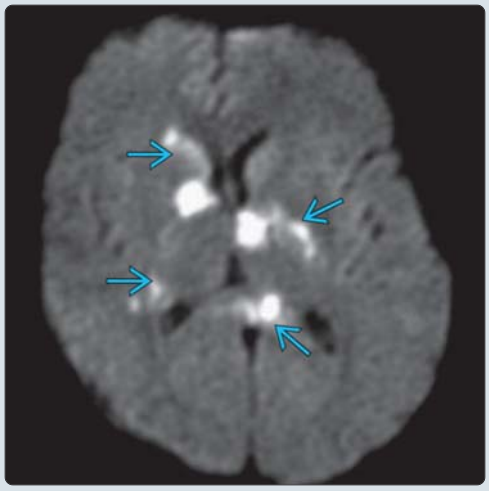

(Left) *Axial T1WI C+ MR in a child with documented tuberculous meningitis shows thick, linear enhancement along the midbrain and temporal lobes. Note the enlarged lateral ventricles and cerebral aqueduct.* **(Right)** *Axial DWI MR in a patient with tuberculous meningitis shows multiple acute infarcts in the basal ganglia, thalami, internal capsules, and splenium of the corpus callosum. Vasculitis is a common complication of TBM involving small and medium-sized vessels and causing cerebral infarction.*

https://CafePezeshki.IR

TERMINOLOGY

Abbreviations

- Tuberculosis (TB)

Definitions

- Infection by acid-fast bacillus *Mycobacterium tuberculosis*
- CNS TB almost always secondary to hematogenous spread (often pulmonary)
  - Manifestations include tuberculous meningitis (TBM)
  - Localized parenchymal infection: Tuberculoma (common), TB abscess (rare)

IMAGING

General Features

- Best diagnostic clue
  - Basilar meningitis + extracerebral TB (pulmonary)
  - Meningitis + parenchymal lesions highly suggestive
- Location
  - Meningitis (basal cisterns > superficial sulci)
  - Tuberculomas
    - Typically parenchymal: Supratentorial most common
    - Dural tuberculomas may occur
- Size
  - Tuberculomas range from 1 mm to 6 cm
  - Tuberculous abscess: Usually > 3 cm
- Morphology
  - TBM: Thick basilar exudate
  - Tuberculoma: Round or oval mass
    - Solitary or multiple (more common)
  - Tuberculous abscess: Large, solitary frequently multiloculated
- Associated findings
  - Spine is most frequent osseous site: TB spondylitis (Potts disease)
  - Less common sites: Calvaria (± dura), otomastoid
  - TB cervical adenitis
    - Conglomerate nodal neck mass

CT Findings

- NECT
  - TBM: May be normal early (10-15%)
    - Isodense to hyperdense exudate effaces CSF spaces, fills basal cisterns, sulci
  - Tuberculoma
    - Hypodense to hyperdense round or lobulated nodule/mass with moderate to marked edema
    - Ca++ uncommon (approximately 20%)
- CECT
  - TBM: Intense basilar meningeal enhancement
  - Tuberculoma: Solid or ring enhancing
    - Target sign: Central focus of enhancement + ring of peripheral enhancement
  - Tuberculous abscess: Solitary often multiloculated ring-enhancing

MR Findings

- T1WI
  - TBM: Exudate isointense or hyperintense to CSF
  - Tuberculoma
    - Noncaseating granuloma: Hypointense to brain
    - Caseating granuloma
      - Solid center: Hypointense or isointense
      - Necrotic center: Central hypointensity
      - May have hyperintense rim (paramagnetic material)
- T2WI
  - TBM: Exudate is isointense or hyperintense to CSF; may see low-signal nodules (rare)
  - Tuberculoma
    - Noncaseating granuloma: Hyperintense to brain
    - Caseating granuloma: Hypointense rim
      - Solid center: Usually hypointense
      - Necrotic center: Hyperintense
    - Surrounding edema common
  - Tuberculous abscess: Hyperintense lesion with hypointense rim & marked vasogenic edema
- FLAIR
  - TBM: Increased intensity in basal cisterns, sulci
  - Tuberculoma & tuberculous abscess: Similar to T2 characteristics
- DWI
  - May show hyperintense center of tuberculoma
  - Restricted diffusion in tuberculous abscess
  - Helpful for detecting complications (stroke, cerebritis)
- T1WI C+
  - TBM: Marked meningeal enhancement, basilar prominence; may be nodular
    - Punctate/linear basal ganglia enhancement = vasculitis
    - Rare: Ventriculitis, choroid plexitis
    - Rare: Pachymeningitis with dural thickening, enhancement (may mimic meningioma)
  - Tuberculomas
    - Noncaseating granuloma: Nodular, homogeneous enhancement
    - Caseating granuloma: Peripheral rim enhancement
      - Necrotic center will show low signal
  - Tuberculous abscess: Multiloculated ring enhancement
- MRA
  - May see vessel narrowing, irregularity, occlusion
- MRS
  - TB abscess has prominent lipid, lactate but no amino acid resonances
    - Lipids at 0.9 ppm, 1.3 ppm, 2.0 ppm, 2.8 ppm
- **Complications**: Hydrocephalus, ischemia
- **Chronic changes**: Atrophy, Ca++, chronic ischemia

Imaging Recommendations

- Best imaging tool
  - MR with FLAIR, DWI, T1 C+, ± MRA, MRS

DIFFERENTIAL DIAGNOSIS

Meningitis

- Infectious meningitis (bacterial, fungal, viral, parasitic)
  - Coccidioidomycosis, cryptococcosis often basilar
- Carcinomatous meningitis (CNS or systemic primary) or lymphoma

Neurosarcoidosis

- Typically leptomeningeal &/or dural enhancement

https://CafePezeshki.IR

- Rarely causes parenchymal nodules

Abscess

- Other granuloma, parasite (neurocysticercosis), bacteria
- Pyogenic abscess often more edema, MRS helpful

Neoplasm

- Primary or metastatic tumors may be indistinguishable
- Thick, nodular enhancing wall, variable diffusivity

PATHOLOGY

General Features

- Etiology
  - CNS TB almost always secondary to hematogenous spread (often pulmonary; rarely GI or GU tract)
    - Hyperemia, inflammation extend to meninges
    - May involve perivascular spaces, cause vasculitis
  - TBM pathophysiology
    - Penetration of meningeal vessel walls by hematogenous spread
    - Rupture of subependymal or subpial granulomata into CSF
  - Tuberculoma pathophysiology
    - Hematogenous spread (gray-white matter junction lesions)
    - Extension of meningitis into parenchyma via cortical veins or small penetrating arteries
  - Arteries directly involved by basilar exudate or indirectly by reactive arteritis (up to 40% of patients)
    - Infection causes arterial spasm resulting in thrombosis and infarct
    - Lenticulostriate arteries, MCA, thalamoperforators most often affected
    - Infarcts most common in basal ganglia, cerebral cortex, pons, cerebellum

Gross Pathologic & Surgical Features

- TBM: Thick, gelatinous, cisternal exudate
- Tuberculoma: Noncaseating, caseating with solid center, or caseating with necrotic center
  - Rarely progresses to TB abscess
    - Lobulated mass with thick rim, occurs in parenchyma, subarachnoid space, dura
- Tuberculous abscess: Encapsulated collection of pus with abundant viable tubercle bacilli

Microscopic Features

- TBM: Inflammatory cells, fragile neocapillaries
  - Caseous necrosis, chronic granulomas, endarteritis, perivascular inflammatory changes
- Tuberculoma
  - Early capsule: Peripheral fibroblasts, epithelioid cells, Langerhans giant cells, lymphocytes
  - Late capsule: Thick collagen layer, central liquefied caseating material in mature tuberculoma

CLINICAL ISSUES

Presentation

- Most common signs/symptoms
  - Varies from mild meningitis with no neurologic deficit to coma
  - TBM: Fevers, confusion, headache, lethargy, meningismus
  - Tuberculoma: Seizures, increased intracranial pressure, papilledema
- Clinical profile
  - LP: Increased protein, pleocytosis (lymphocytes), low glucose, negative for organisms
    - CSF positive on initial LP in < 40%
    - Mycobacteria grow slowly, culture 6-8 weeks
    - PCR for TB may help confirm diagnosis earlier
  - TB skin test may be negative, particularly early
  - Elevated erythrocyte sedimentation rate common

Demographics

- Age
  - Occurs at all ages, but more often in 1st 3 decades
- Epidemiology
  - Worldwide: 8-10 million cases annually
  - Reemerging disease (immigration from endemic areas, AIDS, drug-resistant strains)
  - CNS tuberculosis: 1% of all TB, 10-15% of all extrapulmonary TB

Natural History & Prognosis

- Long-term morbidity in up to 80%: Mental retardation, paralysis, seizures, rigidity, speech or visual deficits
- Mortality in 25-30% of patients; higher in AIDS patients
- Complications: Hydrocephalus (70%), stroke (up to 40%), cranial neuropathies (CN3, CN4, CN6 common), syrinx
- Tuberculomas may take months to years to resolve

Treatment

- Untreated TBM can be fatal in 4-8 weeks
- Multidrug therapy required: Isoniazid, rifampin, pyrazinamide, ± ethambutol or streptomycin
- Despite therapy, lesions may develop or increase
- Hydrocephalus typically requires CSF diversion

DIAGNOSTIC CHECKLIST

Consider

- TB often mimics other diseases, such as neoplasm

Image Interpretation Pearls

- Combination of meningitis and parenchymal lesions suggests TB

SELECTED REFERENCES

1. Garcia-Monco JC: Tuberculosis. Handb Clin Neurol. 121:1485-99, 2014
2. Torres C et al: Central nervous system tuberculosis. Top Magn Reson Imaging. 23(3):173-89, 2014
3. Thwaites GE et al: Tuberculous meningitis: more questions, still too few answers. Lancet Neurol. 12(10):999-1010, 2013
4. Patkar D et al: Central nervous system tuberculosis: pathophysiology and imaging findings. Neuroimaging Clin N Am. 22(4):677-705, 2012

https://CafePezeshki.IR

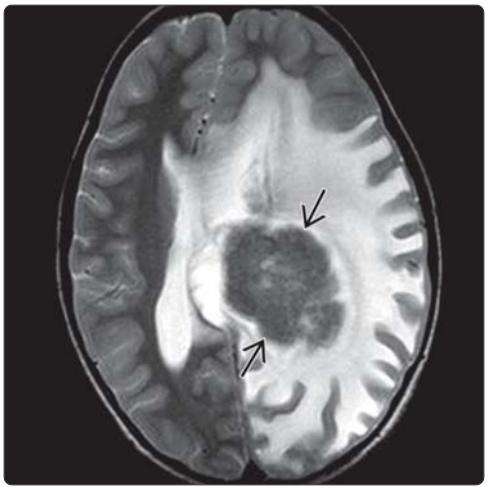

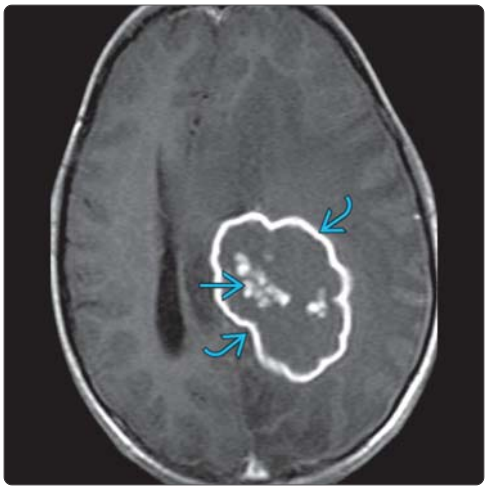

(Left) *Axial T2WI MR in a patient with tuberculoma shows a large, mostly hypointense left parietal lesion ⇨ with edema affecting almost the entire hemisphere. Note the extension into the subcortical U-fibers with sparing of the overlying cortex.* **(Right)** *Axial T1WI C+ MR in the same patient shows ring enhancement ⇨ with some central punctate enhancing foci ⇨. Giant tuberculomas can mimic CNS neoplasms on standard MR imaging.*

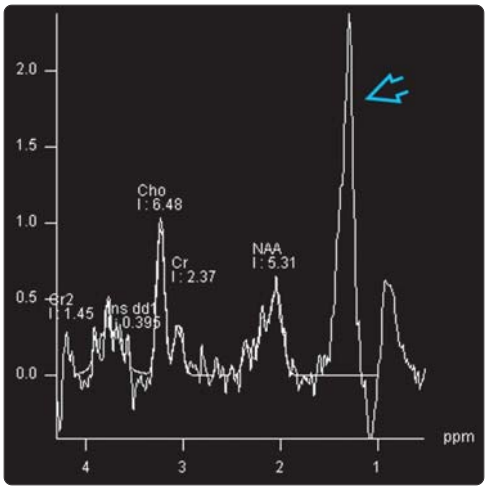

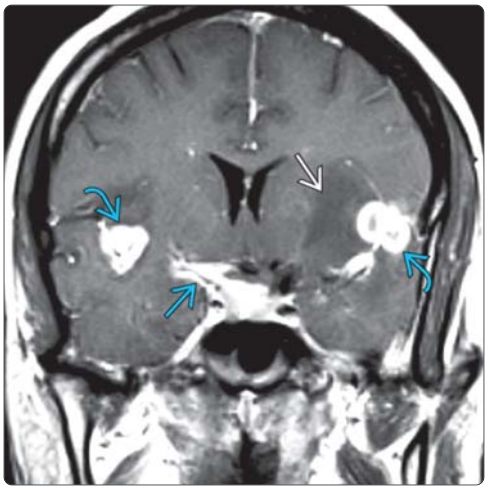

(Left) *MRS (PRESS, intermediate echo) in the same patient shows diminished NAA and a large lipid peak ⇨ (1.3 ppm), a common finding in tuberculosis.* **(Right)** *Coronal T1WI C+ MR in tuberculous meningitis shows basilar meningitis ⇨ surrounding the MCA and enhancing tuberculomas ⇨ adjacent to the sylvian fissures. Note subtle low signal ➡ in left basal ganglia related to arteritis/ischemia.*

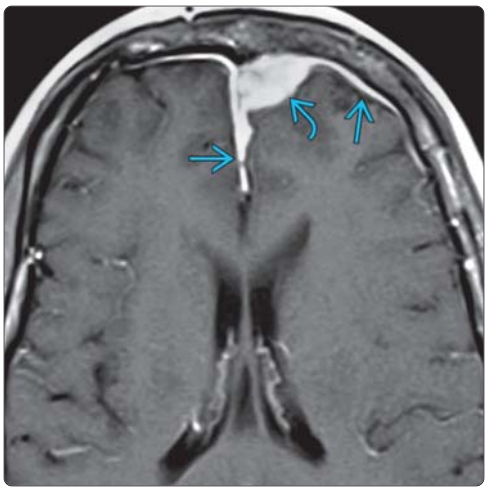

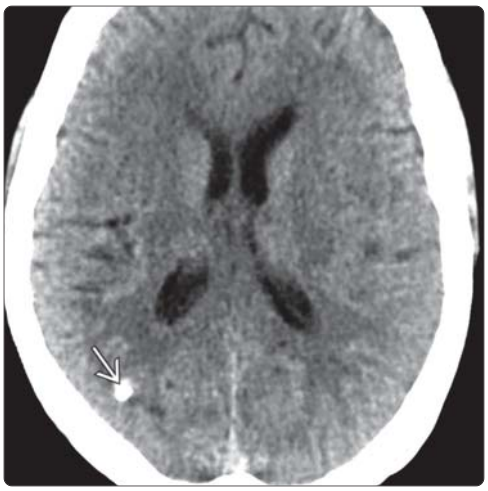

(Left) *Axial T1WI C+ MR demonstrates an enhancing dural-based mass ⇨ with adjacent dural tails ⇨. After surgical resection the final diagnosis was a dural tuberculoma. CNS TB may involve the dura causing a pachymeningitis which may be focal or diffuse. MR imaging is nonspecific in TB pachymeningitis and may mimic a large number of inflammatory and noninflammatory conditions.* **(Right)** *Axial NECT shows a calcified, healed tuberculous granuloma ➡.*

https://CafePezeshki.IR

KEY FACTS

TERMINOLOGY

- Intracranial parasitic infection caused by pork tapeworm *Taenia solium*
  - 4 pathologic stages: Vesicular, colloidal vesicular, granular nodular, and nodular calcified

IMAGING

- Best diagnostic clue: Cyst with "dot" inside
- Convexity subarachnoid spaces most common location
  - Inflammatory response around cyst may seal sulcus, making lesions appear intraaxial
- May involve cisterns > parenchyma > ventricles
- Intraventricular cysts are often isolated
- Basal cistern cysts may be racemose (grape-like)
- Imaging varies with development stage and host response
- Lesions may be at different stages in same patient
- FLAIR and T1 MR helpful to identify scolex and intraventricular lesions
- GRE/SWI helpful in young adults presenting with seizures

TOP DIFFERENTIAL DIAGNOSES

- Abscess
- Tuberculosis
- Neoplasm
- Arachnoid cyst
- Enlarged perivascular spaces

CLINICAL ISSUES

- Seizure, headaches, hydrocephalus common
  - NCC asymptomatic until larvae degenerate
- Cysticercosis is most common parasitic infection worldwide
  - CNS involved in 60-90% of cysticercosis cases
- Most common cause of epilepsy in endemic areas
- Increased travel, immigration have spread disease
- Diagnosis confirmed by ELISA of serum or CSF
- Oral albendazole (reduces parasitic burden, seizures)
- Steroids often required to decrease edema
- Consider excision or drainage of parenchymal lesions

(Left) *Coronal graphic shows subarachnoid and ventricular cysts. The convexity cysts have a scolex and surrounding inflammation. Note that the inflammation around the largest cyst "seals" the sulcus ⇨ and makes it appear parenchymal. Racemose cysts ⇨ are multilocular, nonviable, seen in the basal cisterns and typically lack a scolex.* **(Right)** *Axial CECT in a young male with first episode of seizure demonstrates a ring enhancing lesion ⇨ with an eccentric hyperdense "dot" ⇨ typical for NCC. Note surrounding edema ⇨.*

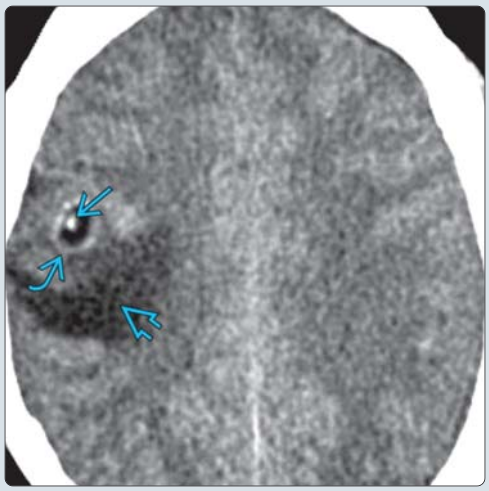

(Left) *Axial FLAIR MR shows a well-defined cyst in left parietal lobe ⇨, which follows CSF signal. There is no edema surrounding this cyst.* **(Right)** *Axial T1+C MR in the same patient shows minimal rim enhancement ⇨ of the cyst. Findings are typical for vesicular stage of NCC. Note nodular enhancing lesions ⇨ in the frontal lobes due to granular nodular stage of NCC. It is important to remember that NCC lesions may be at different stages in same patient.*

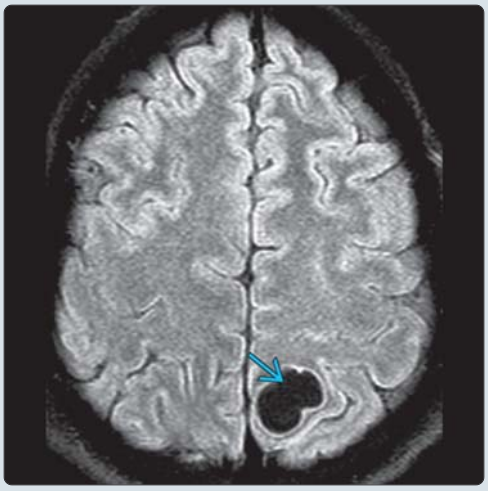

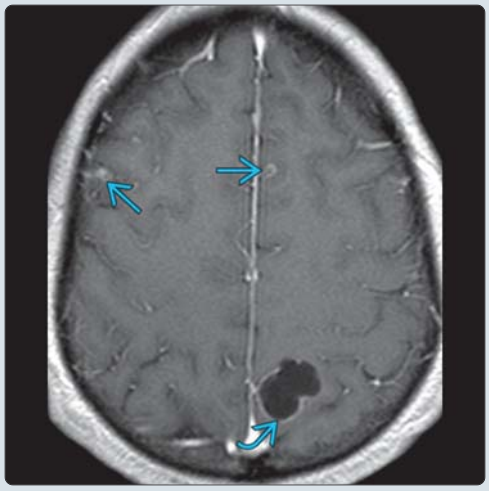

https://CafePezeshki.IR

TERMINOLOGY

Abbreviations

- Neurocysticercosis (NCC)

Synonyms

- Cysticercosis

Definitions

- Intracranial parasitic infection caused by pork tapeworm *Taenia solium*
  - 4 pathologic stages: Vesicular, colloidal vesicular, granular nodular, and nodular calcified

IMAGING

General Features

- Best diagnostic clue
  - Cyst with "dot" inside
- Location
  - Convexity subarachnoid spaces most common
  - May involve cisterns > parenchyma > ventricles
  - Parenchymal cysts often hemispheric, at gray-white junction
  - Intraventricular cysts are often isolated
    - 4th ventricle is most common
  - Basal cistern cysts may be racemose (grape-like)
- Size
  - Cysts variable, typically 1 cm, range from 5-20 mm; contain scolex (1-4 mm)
  - Parenchymal cysts ≤ 1 cm
  - Subarachnoid cysts may be larger
- Morphology
  - Round or ovoid cyst, solitary in 20-50%
  - Disseminated form (a.k.a. miliary NCC): Rare
- Imaging varies with development stage and host response
- Lesions may be at different stages in same patient
- Inflammatory response around cyst may seal sulcus, making lesions appear intraaxial

CT Findings

- NECT
  - **Vesicular** stage (viable larva): Smooth, thin-walled cyst, isodense to CSF, no edema
    - Hyperdense "dot" within cyst = protoscolex
  - **Colloidal vesicular** stage (degenerating larva): Hyperdense cyst fluid with surrounding edema
  - **Granular nodular** stage (healing): Mild edema
  - **Nodular calcified** stage (healed): Small, calcified nodule
- CECT
  - **Vesicular** stage: No (or mild) wall enhancement
  - **Colloidal vesicular** stage: Thicker, ring-enhancing fibrous capsule
  - **Granular nodular** stage: Involuting, enhancing nodule
  - **Nodular calcified** stage: Shrunken, Ca++ nodule
- Subarachnoid lesions: Multiple isodense cysts without scolex; may cause meningitis, vasculitis, or hydrocephalus
- Intraventricular cysts not well seen on CT, may see hydrocephalus

MR Findings

- T1WI
  - **Vesicular** stage: Cystic lesion isointense to CSF
    - May see discrete, eccentric scolex (hyperintense)
  - **Colloidal vesicular** stage: Cyst is mildly hyperintense to CSF
  - **Granular nodular** stage: Thickened, retracted cyst wall; edema decreases
  - **Nodular calcified** stage: Shrunken, Ca++ lesion
  - Useful to detect intraventricular cysts
- T2WI
  - **Vesicular** stage: Cystic lesion isointense to CSF
    - May see discrete, eccentric scolex
    - No surrounding edema
  - **Colloidal vesicular** stage: Cyst is hyperintense
    - Surrounding edema, mild to marked
  - **Granular nodular** stage: Thickened, retracted cyst wall; edema decreases
  - **Nodular calcified** stage: Shrunken, Ca++ lesion
- FLAIR
  - **Vesicular** stage: Cystic lesion isointense to CSF
    - May see discrete, eccentric scolex (hyperintense to CSF); no edema
  - **Colloidal vesicular** stage: Cyst is hyperintense
    - Surrounding edema, mild to marked
  - Useful to detect intraventricular cysts (hyperintense)
  - 100% inspired oxygen increases conspicuity
- T2* GRE
  - Useful to demonstrate calcified scolex
  - May show "multiple black dot" appearance
- DWI
  - Cystic lesion typically isointense to CSF
  - Scolex detectable as a hyperintense nodule
- T1WI C+
  - **Vesicular** stage: No enhancement typical, may see mild enhancement
    - May see discrete, eccentric scolex enhancement
  - **Colloidal vesicular** stage: Thick cyst wall enhances
    - Enhancing marginal nodule (scolex)
  - **Granular nodular** stage: Thickened, retracted cyst wall; may have nodular or ring-like enhancement
  - **Nodular calcified** stage: Small calcified lesion, rare minimal enhancement
- MRS
  - ↑ lactate, alanine, succinate, choline; ↓ NAA and Cr
- In children, may see "encephalitic cysticercosis" with multiple small enhancing lesions and diffuse edema
- Steady state sequences (CISS) for intraventricular cysts
- **Cisternal** NCC may appear **racemose** (multilobulated, grape-like), typically lacks scolex

Imaging Recommendations

- Best imaging tool
  - MR is most sensitive
  - Calcified lesions may be better seen on CT
- Protocol advice
  - MR with T1, T2, FLAIR, GRE/SWI, contrast

DIFFERENTIAL DIAGNOSIS

Abscess

- Typically T2-hypointense rim and DWI positive
- Multiple lesions may occur related to septic emboli

https://CafePezeshki.IR

Tuberculosis
- Tuberculomas often occur with meningitis
- Typically not cystic

Neoplasm
- Primary or metastatic (primary often known)
- Thick, irregular margin enhancement typical
- May have cyst and mural nodule (e.g., pilocytic astrocytoma, hemangioblastoma)

Arachnoid Cyst
- Solitary lesion with CSF density/intensity
- No enhancement

Enlarged Perivascular Spaces
- Follow CSF on all MR sequences, no enhancement

Other Parasitic Infection
- May be cystic, but no scolex seen

PATHOLOGY

General Features
- Etiology
  - Caused by larval form of pork tapeworm *Taenia solium*
  - Man is intermediate host in life cycle of tapeworm
    - Fecal-oral most common route of infection
    - Ingestion of eggs from contaminated water, food
    - From GI tract, primary larvae (oncospheres) disseminate into CNS and skeletal muscle
    - Once intracranial, primary develop into secondary larvae, cysticerci
  - Man may also be definitive host (infected with tapeworm)
    - Typically from uncooked pork
    - Viable larvae ingested, attach in GI tract

Staging, Grading, & Classification
- 4 pathologic stages
  - Vesicular, colloidal vesicular, granular nodular, and nodular calcified
- **Vesicular** stage: Larva is small marginal nodule projecting into small cyst with clear fluid
  - Viable parasite with little or no inflammation
  - May remain in this stage for years or degenerate
- **Colloidal vesicular** stage: Larva begins to degenerate
  - Scolex shows hyaline degeneration, slowly shrinks
  - Cyst fluid becomes turbid, and capsule thickens
  - Surrounding edema and inflammation
- **Granular nodular** stage: Cyst wall thickens and scolex is mineralized granule; surrounding edema regresses
- **Nodular calcified** stage: Lesion is completely mineralized and small; no edema

Gross Pathologic & Surgical Features
- Usually small translucent cyst with invaginated scolex

Microscopic Features
- Cyst wall has 3 distinct layers: Outer (cuticular) layer, middle cellular (pseudoepithelial) layer, inner reticular (fibrillary) layer
- Scolex has rostellum with hooklets, muscular suckers

CLINICAL ISSUES

Presentation
- Most common signs/symptoms
  - Seizure, headaches, hydrocephalus
  - NCC asymptomatic until larvae degenerate
  - Other signs/symptoms: Syncope, dementia, visual changes, focal neurologic deficits, stroke
- Clinical profile
  - Diagnosis confirmed by ELISA of serum or CSF

Demographics
- Epidemiology
  - Cysticercosis is most common parasitic infection
  - CNS infection in 60-90% of cysticercosis cases
  - Endemic in many countries (Latin America, parts of Asia, India, Africa, eastern Europe)
    - USA: Incidence rising in CA, AZ, NM, TX
  - Increased travel, immigration have spread disease
- Age: Any; commonly young, middle-aged adults
- Ethnicity: In USA, Latin American patients common

Natural History & Prognosis
- Most common cause of epilepsy in endemic areas
- Variable time from initial infection until symptoms: 6 months to 30 years; typically 2-5 years
- Variable time to progress through pathologic stages: 1-9 years; mean: 5 years
- Subarachnoid disease may be complicated by meningitis, vasculitis, and hydrocephalus
- Intraventricular NCC has increased morbidity and mortality (↑ morbidity related to acute hydrocephalus)

Treatment
- Oral albendazole (reduces parasitic burden, seizures)
  - Steroids often required to decrease edema
- Consider excision or drainage of parenchymal lesions
- Consider endoscopic resection of ventricular lesions
- CSF diversion often required to treat hydrocephalus

DIAGNOSTIC CHECKLIST

Consider
- Complex parasitic cysts may mimic brain tumor

Image Interpretation Pearls
- FLAIR and T1WI helpful to identify scolex and intraventricular lesions
- GRE/SWI helpful in young adults presenting with seizures

SELECTED REFERENCES

1. Del Brutto OH: Neurocysticercosis. Handb Clin Neurol. 121:1445-59, 2014
2. Hernández RD et al: Magnetic resonance imaging in neurocysticercosis. Top Magn Reson Imaging. 23(3):191-8, 2014
3. Carpio A et al: Neurocysticercosis: Five new things. Neurol Clin Pract. 3(2):118-125, 2013

https://CafePezeshki.IR

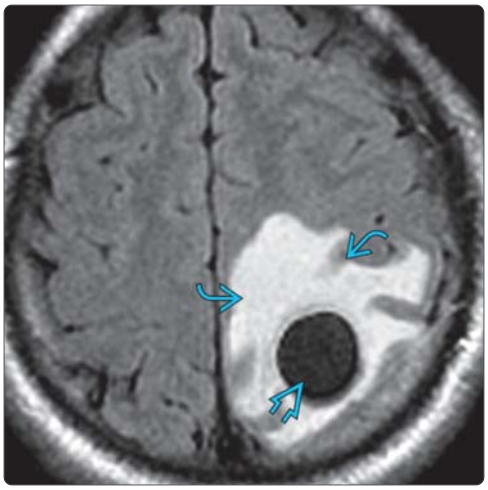

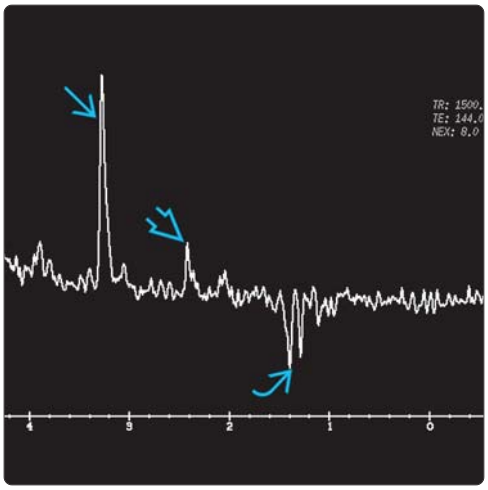

(Left) *Axial FLAIR MR in a patient with NCC shows a large CSF signal intensity cyst ⇨ with extensive surrounding vasogenic edema ⇨. In the colloidal vesicular stage of NCC the larvae begin to degenerate, which incites a striking inflammatory response and leads to prominent perilesional edema.* **(Right)** *MRS at TR 1500 TE 144 within the cyst cavity shows peaks of Cho ⇨ (3.2 ppm), succinate ⇨ (2.4 ppm), and lactate ⇨ (1.3 ppm).*

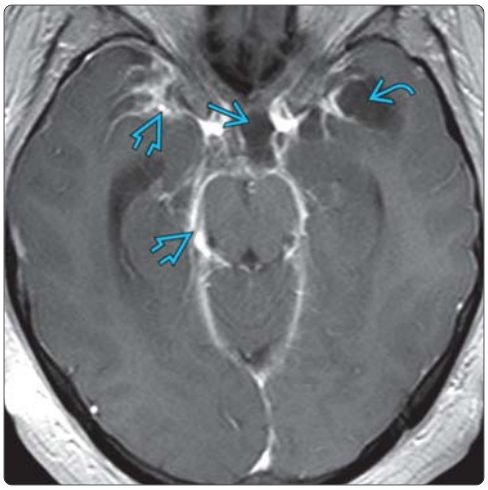

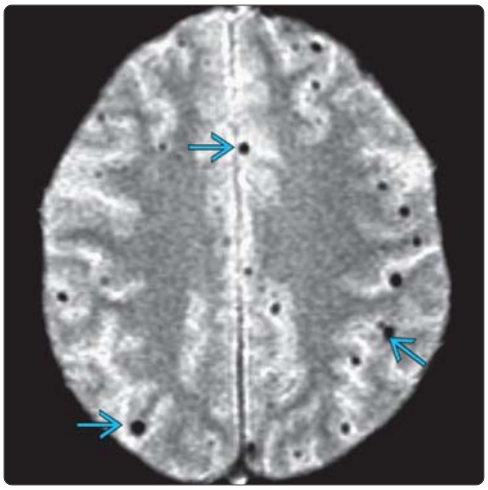

(Left) *Axial T1+ C MR demonstrates multiple cysts within the suprasellar cistern ⇨ and left sylvian fissure ⇨. There is extensive leptomeningeal enhancement ⇨ in the basal cisterns and sylvian fissures. Cisternal NCC also termed "racemose" (grape-like) may cause meningeal inflammation, communicating hydrocephalus,vasculitis, and infarcts.* **(Right)** *Axial T2* GRE MR in a patient with seizures shows multifocal "black dots" ⇨ in the sulci and parenchyma related to the nodular calcified stage of NCC.*

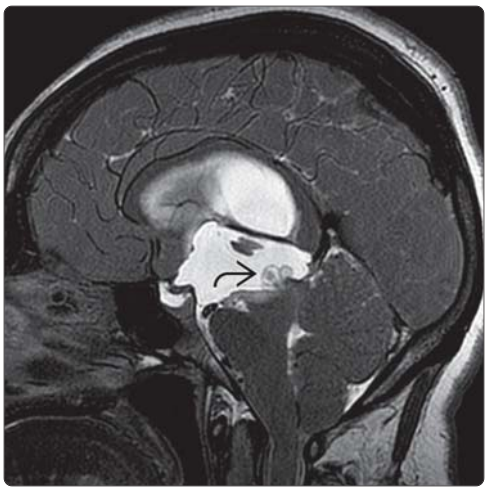

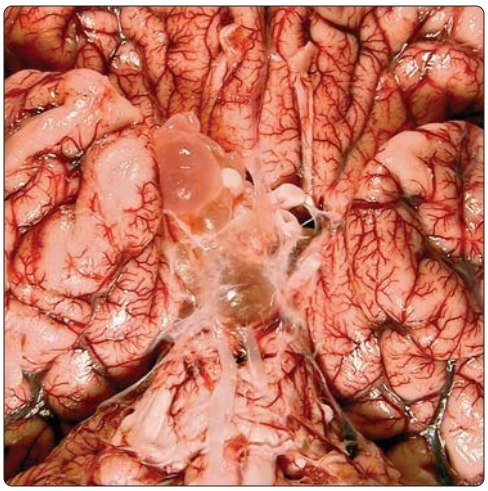

(Left) *Sagittal FIESTA MR scan shows hydrocephalus due to intraventricular cysticercosis. Note the presence of cysts ⇨ blocking the flow of CSF from the 3rd ventricle to the aqueduct. Steady-state free precession sequences are useful to show intraventricular cysts.* **(Right)** *Inferior view of the brain at autopsy shows multiple racemose NCC cysts. Basal cistern cysts are commonly complicated by meningitis, hydrocephalus, and vasculitis. (Courtesy R. Hewlett, MD.)*

https://CafePezeshki.IR

KEY FACTS

TERMINOLOGY

- Hydatid disease (HD), hydatid cyst (HC)
- *Echinococcus granulosus* (EG)
- *Echinococcus multilocularis/alveolaris* (EM/EA)

IMAGING

- General: Child/young adult with large, supratentorial, unilocular, thin-walled cyst
  - No Ca++ or surrounding edema
  - CSF density/intensity
- MR
  - EG: Well-defined, T2-hypointense rim; no enhancement
  - EM/EA: Small irregular cysts with nodular/ring enhancement, edema
  - Lactate, alanine, acetate, pyruvate (at 2.4 ppm)

TOP DIFFERENTIAL DIAGNOSES

- Arachnoid cyst
- Epidermoid cyst
- Neuroglial cyst
- Porencephalic cyst

PATHOLOGY

- Parasitic infection by *Echinococcus* tapeworms
  - Definitive host = dog (or other carnivore)
  - Intermediate host = sheep (most commonly)
  - Humans may become intermediate hosts
- CNS involvement: 1-2% in EG, 3-5% EM/EA
- HC has 3 layers: Outer (pericyst), middle laminated membrane (ectocyst), and inner germinal (endocyst)

CLINICAL ISSUES

- Surgical excision = treatment of choice
- Caution: Avoid cyst rupture
- Spillage of cyst contents can lead to anaphylactic reaction or recurrence

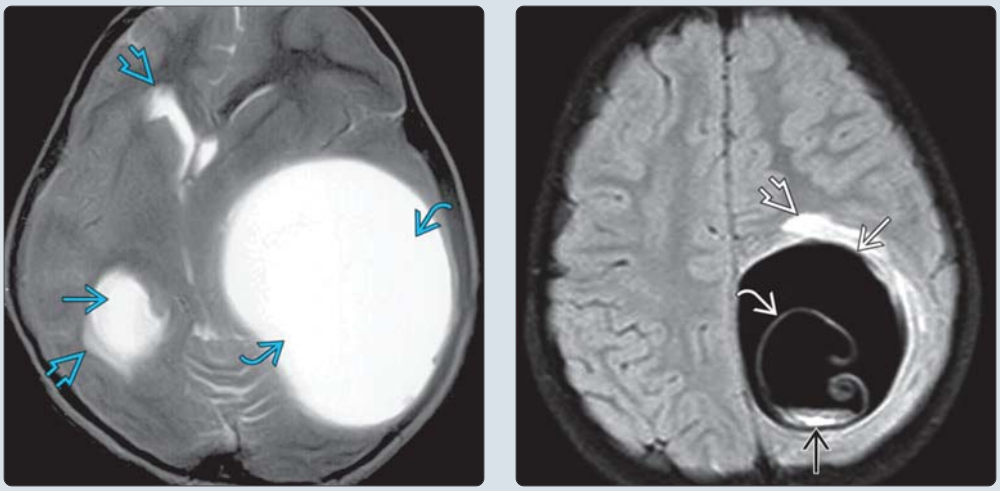

(Left) *Axial T2 MR demonstrates a huge, unilocular, CSF signal intensity hydatid cyst in the left hemisphere.There is no edema surrounding the cyst. There is mass effect with obstruction of the right lateral ventricle and periventricular interstitial edema.* **(Right)** *Axial FLAIR MR demonstrates a large left parietal hydatid cyst with an internal membrane representing detached germinal membrane and dependent hyperintense "hydatid sand". There is very mild surrounding edema.*

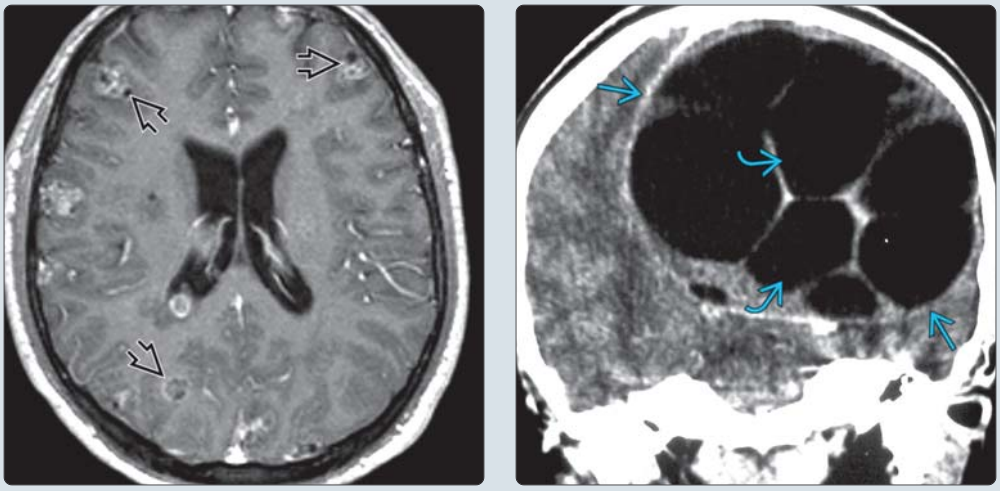

(Left) *Axial T1WI C+ MR demonstrates clusters of small cysts with peripheral ring enhancement. Alveolar echinococcosis (AE) with CNS involvement was finally diagnosed. AE is composed of numerous irregular cysts (between 1 and 20 mm in diameter), not sharply demarcated. Necrosis with liquefaction causes the cystic central areas.* **(Right)** *Coronal CECT shows a variant manifestation of hydatid disease. Multiple "daughter" cysts are present within a very large cyst. (Courtesy S. Nagi, MD.)*

https://CafePezeshki.IR

TERMINOLOGY

Abbreviations

- Hydatid disease (HD), hydatid cyst (HC)
- *Echinococcus granulosus* (EG)
- *Echinococcus multilocularis/alveolaris* (EM/EA)

Synonyms

- Echinococcosis, hydatid cyst

IMAGING

General Features

- Best diagnostic clue
  - Large, unilocular, thin-walled cyst
    - No Ca++ or surrounding edema
    - CSF density/intensity
- Location
  - Majority of HCs occur in liver, lungs
  - CNS involvement: 1-2% of EG, 3-5% of EM/EA
    - Most commonly supratentorial (MCA territory)
      - Parietal lobe most frequently involved
- Size
  - EG: Large cysts
  - EM/EA: Smaller, partially solid/cystic (1-20 mm)
- Morphology
  - EG: Generally solitary; may be multiple if ruptured
  - Multivesicular cysts uncommon in brain

CT Findings

- NECT
  - EG: Unilocular cyst isodense to CSF
    - Ca++ < 1% (more common with EM/EA)
- CECT
  - Normally no enhancement

MR Findings

- T1WI
  - EG: Unilocular cyst, isointense to CSF
- T2WI
  - EG: Cyst with well-defined hypointense rim
  - EM/EA: Small irregular cysts with edema
- T1WI C+
  - EG: None (rim only if superinfected)
  - EM/EA: Nodular/ring-like enhancement
- MRS
  - Lactate (1.3 ppm), alanine (1.48 ppm), acetate (1.92 ppm), succinate (2.4 ppm)

DIFFERENTIAL DIAGNOSIS

Arachnoid Cyst

- Extraaxial cysts follow CSF signal/attenuation

Epidermoid Cyst

- Does not suppress on FLAIR, ↑ DWI

Neuroglial Cyst

- Difficult to differentiate (travel history helps for EG)

Porencephalic Cyst

- Cystic space with adjacent enlarged ventricle

PATHOLOGY

General Features

- Etiology
  - Parasitic infection by *Echinococcus* tapeworm
    - Usually caused by EG, less frequently EM/EA
  - Life cycle
    - Definitive host = dog (or other carnivore)
    - Intermediate host = sheep (most commonly)
  - Humans may become intermediate hosts via
    - Contact with definitive host
    - Ingestion of contaminated water/vegetables

Gross Pathologic & Surgical Features

- Vesicles resemble "bunch of grapes"

Microscopic Features

- HC has 3 layers
  - Outer layer (pericyst): Modified host cells form dense, fibrous protective zone
  - Middle laminated membrane (ectocyst): Acellular and permits passage of nutrients
  - Inner germinal layer (endocyst): Produces daughter vesicles
    - Scolices (larval stage of parasite) are seen within daughter vesicles

CLINICAL ISSUES

Presentation

- Most common signs/symptoms
  - Headache, seizures, focal deficits, nausea, vomiting, papilledema (↑ ICP)

Demographics

- Age
  - Usually child, young adult
- Epidemiology
  - EG: Endemic in Australia, New Zealand, Middle East, Mediterranean, South America
  - EM/EA: Endemic in North America, central Europe, Russia, China, Turkey

Natural History & Prognosis

- Rupture, infection: Important complications of HC

Treatment

- Surgical excision = treatment of choice
  - Caution: Avoid cyst rupture
  - Spillage of cyst contents can lead to anaphylactic reaction or recurrence
- Antihelmintic therapy (praziquantel, albendazole)

DIAGNOSTIC CHECKLIST

Consider

- HC if large, unilocular, noncalcified parietal cyst without edema, enhancement
  - Residence in or travel to endemic regions

SELECTED REFERENCES

1. Teke M et al: Imaging features of cerebral and spinal cystic echinococcosis. Radiol Med. ePub, 2014

https://CafePezeshki.IR

KEY FACTS

TERMINOLOGY

- Parasitic infection caused by free-living amebae
  - *Entamoeba histolytica* (EH), *Naegleria fowleri* (NF), *Acanthamoeba* (Ac)
  - Primary amebic meningoencephalitis (PAM)
  - Granulomatous amebic encephalitis (GAE)

IMAGING

- EH: Ring-enhancing lesion(s)
- NF: (PAM) enhancing leptomeninges, cisterns (most prominent around olfactory bulbs)
- Ac: (GAE) Ring, linear & superficial gyriform enhancement
- Deep gray matter infarcts in PAM

TOP DIFFERENTIAL DIAGNOSES

- Pyogenic abscess
- Other encephalitides

PATHOLOGY

- *E. histolytica*, *N. fowleri*, *Acanthamoeba* frequent
  - *N. fowleri* causes PAM
  - *Acanthamoeba* causes GAE

CLINICAL ISSUES

- Endemic to southern USA, South America, Latin America, Southeast Asia, Africa
  - GAE: Patients often debilitated, immunocompromised
  - Ac: Insidious (headache, low-grade fever, seizures)
- Symptoms: Headache, nausea, vomiting, lethargy, seizures

DIAGNOSTIC CHECKLIST

- "Odd-looking" lesion(s); can mimic neoplasm
- Consider amebic infection in setting of meningoencephalitis with travel to endemic areas

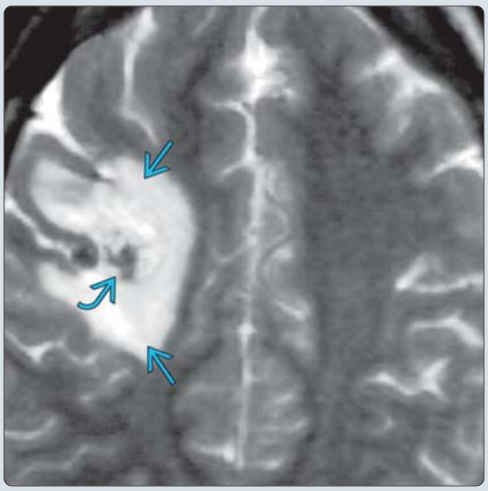

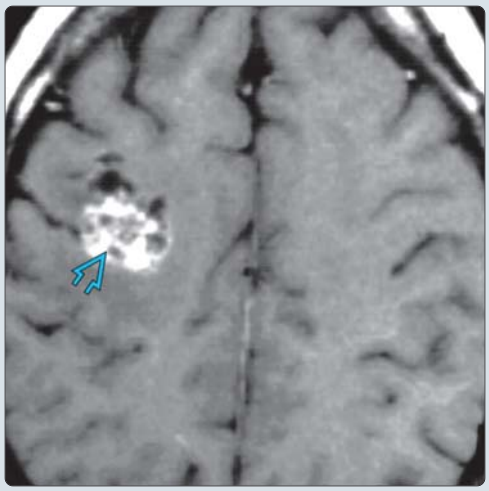

(Left) *Axial T2 FS MR in a patient with recent travel to Africa demonstrates a mixed signal intensity mass with significant surrounding edema.* **(Right)** *Axial T1 C+ MR in the same patient shows a lobulated enhancing lesion. Biopsy in this case showed granulomatous amebic encephalitis. This case demonstrates the useful dictum that if a patient comes from an endemic area where parasitic infestations are common, the possibility should be considered when an "odd-looking" intracranial mass is identified on imaging.*

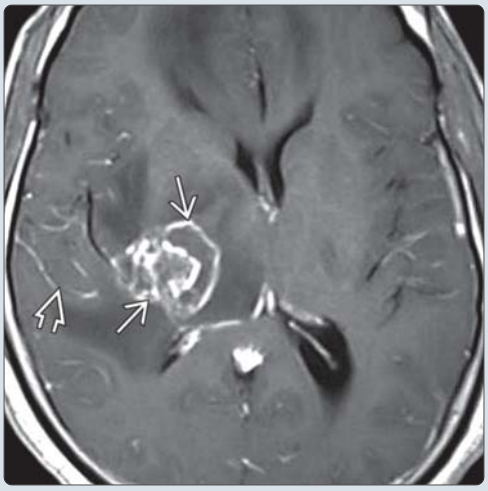

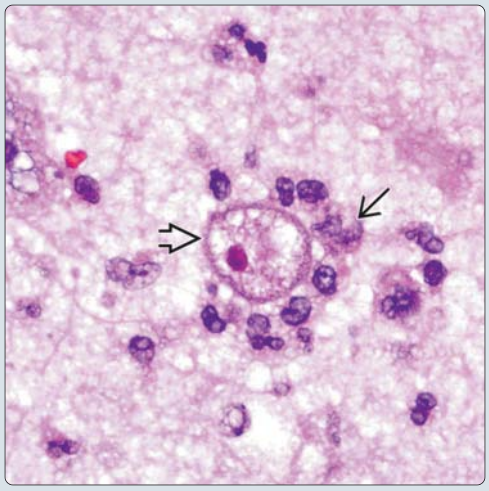

(Left) *Axial T1WI C+ MR shows inhomogeneous ring-like enhancement in a right thalamic mass. Note the leptomeningeal enhancement, consistent with meningoencephalitis.* **(Right)** *Hematoxylin & eosin micropathology obtained from biopsy in this case shows an ameba surrounded by inflammatory cells. Note the complex nucleolus with an eosinophilic rim, pyknotic core. This proves necrotizing amebic meningoencephalitis is caused by free-living forms of Acanthamoeba. (Courtesy R. Hewlett, MD.)*

https://CafePezeshki.IR

TERMINOLOGY

Abbreviations

- *Entamoeba histolytica* (EH), *Naegleria fowleri* (NF), *Acanthamoeba* (Ac)
- Primary amebic meningoencephalitis (PAM)
- Granulomatous amebic encephalitis (GAE)

Synonyms

- Central nervous system amebiasis

Definitions

- Parasitic infection caused by free-living amebic organisms

IMAGING

General Features

- Best diagnostic clue
  - Meningoencephalitis, ring-enhancing lesion(s) in patients who traveled to endemic areas
- Location
  - EH: Meninges, cortical/deep gray matter
  - NF: (PAM) meninges in region of olfactory bulb, cerebral cortex at base of brain
  - Ac: (GAE) meninges, thalamus, brainstem, cerebral hemispheres

CT Findings

- NECT
  - Hypodense lesion(s) with surrounding edema
    - Cortical, deep gray matter
- CECT
  - Single/multiple ring-enhancing lesions
  - Gyriform, leptomeningeal enhancement (PAM)

MR Findings

- T1WI
  - Hypointense edema, focal lesions
- T2WI
  - EH: Hyperintense lesions with edema
  - PAM: Ill-defined areas of ↑ T2 signal, mass effect
- FLAIR
  - Meningitis may cause ↑ signal in CSF
- T2* GRE
  - Lesions may show ↓ signal due to hemorrhage
- DWI
  - Deep gray matter infarcts in PAM
- T1WI C+
  - EH: Ring-enhancing lesion(s)
  - NF: (PAM) enhancing leptomeninges, cisterns (most prominent around olfactory bulbs)
  - Ac: (GAE) ring, linear & superficial gyriform enhancement

DIFFERENTIAL DIAGNOSIS

Pyogenic Abscess

- High signal on DWI, low ADC

Other Encephalitides

- Difficult to differentiate

PATHOLOGY

General Features

- Etiology
  - Caused by free-living amebae
  - *E. histolytica*, *N. fowleri*, and *Acanthamoeba* frequent
    - *N. fowleri* causes PAM
    - *Acanthamoeba* causes GAE
- Most are transmitted by fecal-oral contamination
  - EH & Ac by hematogenous dissemination
- NF: Organisms in stagnant freshwater
  - Nasal mucosa → olfactory neuroepithelium → CNS

Gross Pathologic & Surgical Features

- EH: Single/multiple, 2-60 mm in size, central necrosis
- NF: Purulent exudate, hyperemic meninges (region of olfactory bulbs), necrosis frontal/temporal lobes
- Ac: Multifocal hemorrhagic necrosis, edema, abscess

CLINICAL ISSUES

Presentation

- Most common signs/symptoms
  - Headache, nausea, vomiting, lethargy, seizures
  - Ac: Insidious, headache, low-grade fever, seizures

Demographics

- Age
  - EH: 20-40 years; NF in children
- Gender
  - M > F
- Epidemiology
  - Endemic to southern USA, South America, Latin America, southeast Asia, Africa
  - GAE in debilitated/immunocompromised patients

Natural History & Prognosis

- PAM: Rapid progression (fatal if untreated)
- GAE: More insidious, prolonged duration

Treatment

- Surgical intervention, drugs (miconazole, metronidazole, amphotericin B, clotrimazole)

DIAGNOSTIC CHECKLIST

Consider

- Amebic infection in clinical setting of meningoencephalitis with travel to endemic areas

Image Interpretation Pearls

- "Odd-looking" lesion(s); can mimic neoplasm

SELECTED REFERENCES

1. Visvesvara GS: Infections with free-living amebae. Handb Clin Neurol. 114:153-68, 2013
2. Akgoz A et al: Imaging of rickettsial, spirochetal, and parasitic infections. Neuroimaging Clin N Am. 22(4):633-57, 2012
3. Abdel Razek AA et al: Parasitic diseases of the central nervous system. Neuroimaging Clin N Am. 21(4):815-41, viii, 2011
4. Fukuma T: [Amebic meningoencephalitis.] Brain Nerve. 61(2):115-21, 2009

https://CafePezeshki.IR

KEY FACTS

TERMINOLOGY

- Cerebral malaria (CM)
- *Plasmodium*-infected RBCs sequester in cerebral microvasculature → multiple infarcts
  - Only 2% of infected patients develop CM
  - **But** CM most common cause of death from parasitic infection

IMAGING

- Multiple cortical, thalamic infarcts ± hemorrhages
  - Cortex, deep WM, basal ganglia, thalami > cerebellum
  - May show restriction on DWI
  - Diffuse petechial hemorrhages on T2* (GRE/SWI)

TOP DIFFERENTIAL DIAGNOSES

- Multiple cerebral emboli/infarction
- Acute infantile bilateral striatal necrosis

PATHOLOGY

- Malaria caused by 4 species of *Plasmodium*
  - > 95% *P. falciparum, P. vivax*
  - Carrier is *Anopheles* mosquito
- Infected erythrocytes sequestered in microvasculature
  - Vascular occlusions → infarcts ± hemorrhages
- Petechial hemorrhages in cortex, subcortical WM, basal ganglia
- Parasitized RBCs may become ghost-like, contain malaria parasites

CLINICAL ISSUES

- Usually young children/adults visiting endemic areas
- Incubation period 1-3 weeks
  - Fever, headache
  - Altered sensorium, seizures
- 25-50% mortality despite appropriate therapy
- Sickle cell trait confers some protection

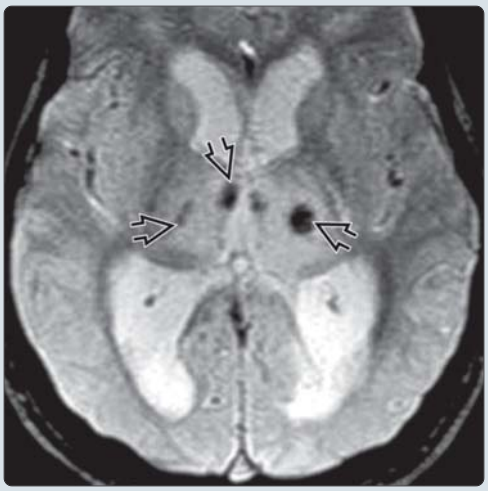

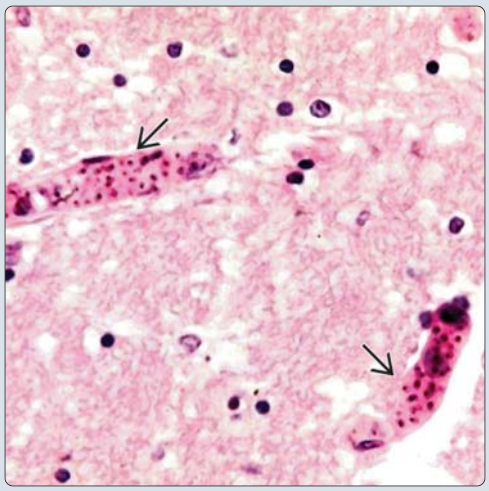

(Left) *Axial T2* GRE MR in a child with known malaria who had altered sensorium, then lapsed into coma, shows hyperintensity in both thalami with numerous hemorrhagic foci. DWI and ADC (not shown) disclosed multiple areas of restriction consistent with infarcts. Autopsy showed bithalamic infarcts. (Courtesy R. Ramakantan, MD.)* **(Right)** *Hematoxylin & eosin in the same patient shows pale-staining ischemic parenchyma and capillary plugging from RBCs containing innumerable parasites. (Courtesy R. Ramakantan, MD.)*

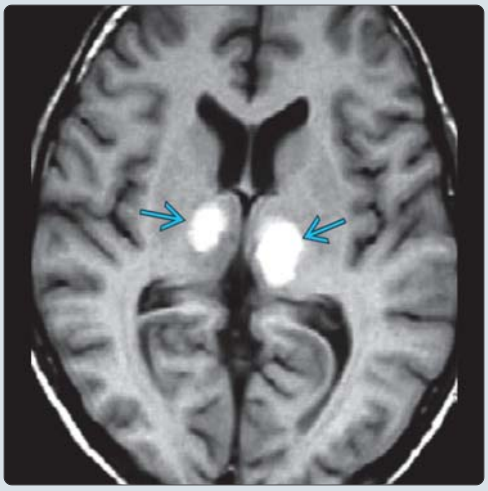

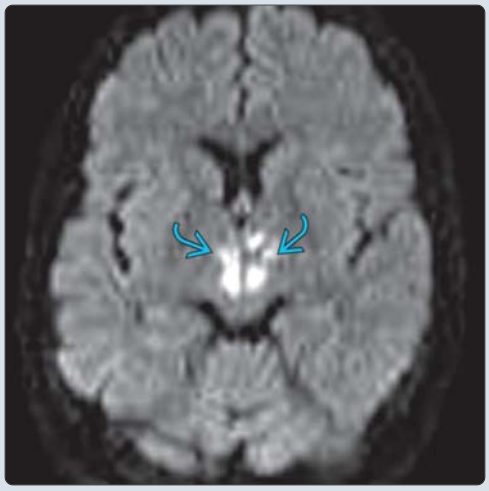

(Left) *Axial T1 MR in a 12 year old with high-grade fever and altered sensorium shows symmetric T1 hyperintensity in the thalami due to hemorrhagic infarcts. Sequestration of infected RBCs in capillaries may cause infarction often with hemorrhagic foci. (Courtesy Anagha K, MD.)* **(Right)** *Axial DWI MR in a patient with cerebral malaria and altered sensorium shows bilateral foci of diffusion restriction indicating acute thalamic infarcts. (Courtesy R. Ramakantan, MD.)*

https://CafePezeshki.IR

TERMINOLOGY

Abbreviations

- Cerebral malaria (CM)

Definitions

- Parasitic infection caused by different species of genus *Plasmodium*

IMAGING

General Features

- Best diagnostic clue
  - Multiple cortical, thalamic infarcts ± hemorrhages in patient with known *Plasmodium* infection
- Location
  - Cortex, deep white matter, basal ganglia, thalami

CT Findings

- NECT
  - Findings vary from normal to striking
    - Diffuse edema
    - Focal infarcts, often multiple
      - Cortex, thalami, basal ganglia
      - White matter, cerebellum

MR Findings

- T1WI
  - Variable hypointensity
- T2WI
  - Focal hyperintensities
    - Bilateral thalami
    - Periventricular WM including corpus callosum splenium
- FLAIR
  - Multifocal hyperintensities in WM, thalami
- T2* GRE
  - Diffuse petechial hemorrhages
- DWI
  - Variable; may show restriction
- T1WI C+
  - Generally none

Imaging Recommendations

- Best imaging tool
  - MR with FLAIR, T2* (GRE/SWI), DWI

DIFFERENTIAL DIAGNOSIS

Multiple Cerebral Emboli/Infarction

- Peripheral (gray-white junction) > > basal ganglia

Acute Infantile Bilateral Striatal Necrosis

- Usually follows respiratory illness, influenza
- Also associated with HHV-6, rotavirus gastroenteritis

PATHOLOGY

General Features

- Etiology
  - Malaria caused by 4 species of *Plasmodium*
    - > 95% *P. falciparum, P. vivax*
    - Less common: *P. malariae, P. ovale*
  - Carrier is *Anopheles* mosquito
    - Inoculates malaria sporozoites
    - Carried via blood stream to liver
    - Penetrate hepatocytes, become merozoites
    - Hepatocytes rupture → merozoites enter blood stream
    - Invade RBCs, become trophozoites then schizonts
  - Infected erythrocytes sequestered in microvasculature
    - Vascular occlusions → infarcts ± hemorrhages

Gross Pathologic & Surgical Features

- Grossly swollen brain
  - Cortex may appear dusky pink (marked congestion) or slate gray (malarial pigment related to hematin)
  - Petechial hemorrhages in cortex, subcortical WM, basal ganglia

Microscopic Features

- Parasitized RBCs may become ghost-like, contain malaria parasites

CLINICAL ISSUES

Presentation

- Most common signs/symptoms
  - Incubation period 1-3 weeks
    - Fever, headache
    - Altered sensorium, seizures
    - Decreased consciousness, coma
- Other signs/symptoms
  - Backache
  - Photophobia, nausea, vomiting

Demographics

- Age
  - Young children, adult visitors to endemic areas
- Ethnicity
  - Sickle cell trait confers some protection
- Epidemiology
  - Only 2% of patients infected by *Plasmodium falciparum* develop CM
  - CM most common cause of death from parasitic infection

Natural History & Prognosis

- 25-50% mortality despite appropriate therapy

DIAGNOSTIC CHECKLIST

Consider

- Malaria in adult with travel to endemic area

SELECTED REFERENCES

1. Potchen MJ et al: Acute brain MRI findings in 120 Malawian children with cerebral malaria: new insights into an ancient disease. AJNR Am J Neuroradiol. 33(9):1740-6, 2012
2. Potchen MJ et al: Neuroimaging findings in children with retinopathy-confirmed cerebral malaria. Eur J Radiol. 74(1):262-8, 2010
3. Nickerson JP et al: Imaging cerebral malaria with a susceptibility-weighted MR sequence. AJNR Am J Neuroradiol. 30(6):e85-6, 2009
4. Yadav P et al: Magnetic resonance features of cerebral malaria. Acta Radiol. 49(5):566-9, 2008

https://CafePezeshki.IR

KEY FACTS

IMAGING

- Enhancing supratentorial mass, may be multiloculated
- Majority of parasitic infections are supratentorial
- **Paragonimiasis**: Acutely may cause hemorrhage or infarct followed by granuloma formation
  - Conglomerated, multiple ring-enhancing lesions
- **Schistosomiasis**: Granulomatous encephalitis, hyperintense mass, enhancing dots
  - Central linear enhancement surrounded by multiple punctate nodules "arborize" appearance
- **Sparganosis**: Conglomerate, multicystic hemispheric mass with surrounding edema
  - May cause "tunnel" sign (worm migration)
  - Conglomerate ring enhancement
- **Trichinosis**: Eosinophilic meningoencephalitis, vascular thrombi, infarcts
- **Trypanosomiasis**: Meningoencephalitis, organisms in PVS → edema, congestion, petechial hemorrhages

TOP DIFFERENTIAL DIAGNOSES

- Neoplasms (glioblastoma multiforme, metastases)
- Abscess
- Neurocysticercosis
- Neurosarcoid

PATHOLOGY

- **Paragonimiasis**: Ingestion of undercooked fresh water crabs or crayfish contaminated with *Paragonimus westermani* flukes (lung fluke)
- **Schistosomiasis**: Infestation from trematode worms
- **Sparganosis**: Ingestion of contaminated water or food (snake, frogs)
- **Trichinosis**: Ingestion of uncooked meat containing infective encysted larvae
- **Trypanosomiasis**: African (tsetse fly) and American (Chagas disease, reduviid bugs)

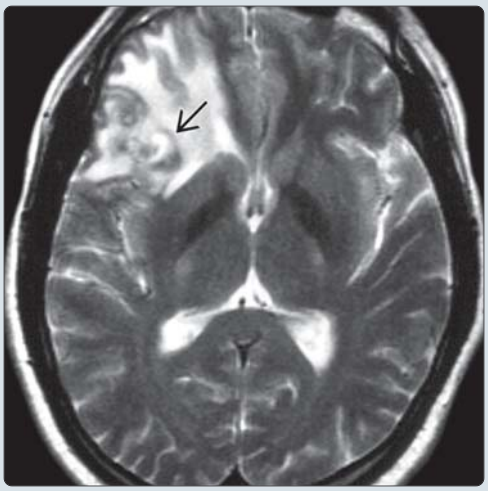

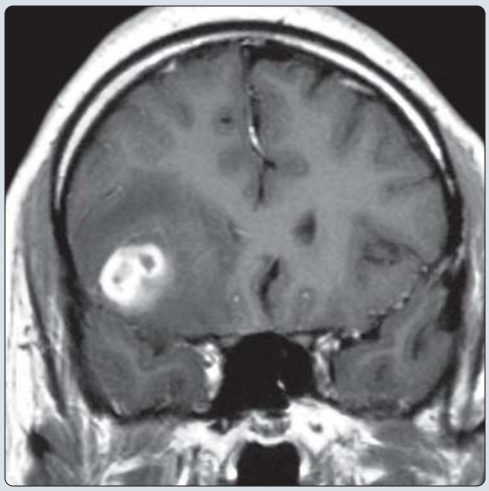

(Left) *Axial T2WI MR shows a heterogeneous lesion in the right frontal lobe with mass effect and surrounding edema in this patient from east Asia. Note the hypointense rim ⇨, typical of paragonimiasis.* **(Right)** *Coronal T1WI C+ MR in the same patient shows conglomerated, ring-enhancing lesions with marked surrounding edema. Paragonimiasis may acutely cause hemorrhage or infarct followed by granuloma formation. Imaging mimics a neoplasm. Chronically, calcifications and atrophy will develop.*

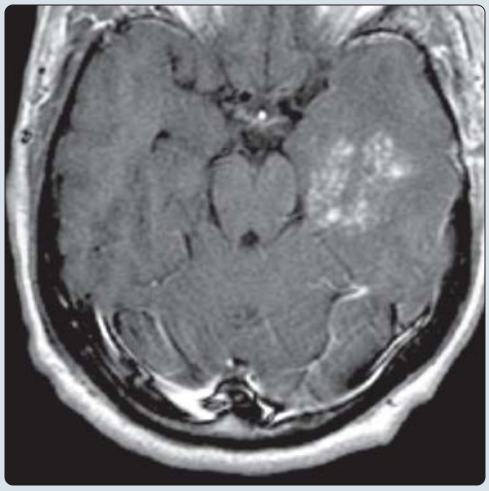

(Left) *Axial CECT shows diffuse brain atrophy with ventriculomegaly and basal ganglia hyperdensity ⇨ in this patient with a remote history of paragonimiasis. Acutely, these parasites may cause brain infarction.* **(Right)** *Axial T1WI C+ MR shows patchy, nodular enhancement in the left temporal lobe. The enhancement has a mildly arborized appearance, characteristic of schistosomiasis. This parasite often causes a granulomatous encephalitis and presents as encephalopathy or seizures.*

https://CafePezeshki.IR

TERMINOLOGY

Definitions

- Rare parasitic infection affecting CNS
- Includes paragonimiasis, schistosomiasis, sparganosis, trichinosis, trypanosomiasis

IMAGING

General Features

- Best diagnostic clue
  - Enhancing supratentorial mass, may be multiloculated
- Location
  - Majority of parasitic infections are supratentorial
  - **Paragonimiasis**: Hemispheric, commonly posterior
  - **Schistosomiasis**: Cerebrum, cerebellum, brainstem, choroid plexus
  - **Sparganosis**: Cerebral white matter, basal ganglia, insula, and cerebellum
  - **Trichinosis:** Cerebral cortex and white matter (WM)
  - **Trypanosomiasis:** Periventricular white matter, corpus callosum, cerebral peduncles, cerebellum
- Morphology
  - **Paragonimiasis**: Acutely may cause hemorrhage or infarct followed by granuloma formation
    - In chronic stage, round and ovoid Ca++ in mass
  - **Schistosomiasis**: Granulomatous encephalitis, hyperintense mass, enhancing dots
  - **Sparganosis**: Conglomerate, multicystic mass with surrounding edema
    - May cause "tunnel" sign related to worm migration
  - **Trichinosis**: Eosinophilic meningoencephalitis, vascular thrombi, infarcts
  - **Trypanosomiasis**: Meningoencephalitis, organisms in perivascular spaces (PVS) cause brain edema, congestion, petechial hemorrhages

CT Findings

- NECT
  - **Paragonimiasis**: Multiple conglomerated granulomas, ± hemorrhage
    - Multiple round or oval calcifications, surrounding low density, cortical atrophy, ventriculomegaly
  - **Schistosomiasis**: Single or multiple hyperdense lesion(s) with edema, mass effect
  - **Sparganosis**: Conglomerate, multicystic mass with surrounding edema
    - Typically unilateral, hemispheric
    - Atrophy, calcification,ventricular dilatation in chronic cases
  - **Trichinosis**: Hypodense white matter lesions, cortical infarcts
  - **Trypanosomiasis**: Edema with scattered petechial hemorrhage
- CECT
  - **Paragonimiasis**: Ring enhancement
  - **Trichinosis**: Multiple microinfarcts with ring enhancement

MR Findings

- T2WI
  - **Paragonimiasis**: Heterogeneous mass with surrounding edema, ± hemorrhage
    - May have isointense or hypointense rim
  - **Schistosomiasis**: Hyperintense mass with surrounding edema
  - **Sparganosis**: Conglomerate, multicystic mass with surrounding edema, ± hemorrhage
    - May see mixed-signal lesion, central low signal and peripheral high signal
    - Unilateral white matter degeneration, cortical atrophy in chronic cases
  - **Trichinosis**: Multiple hyperintense microinfarcts
    - Border zones of major vascular territories, periventricular white matter and corpus callosum
  - **Trypanosomiasis**: Multiple hyperintense lesions
    - Corpus callosum, periventricular white matter, subcortical regions, deep gray matter
- T1WI C+
  - **Paragonimiasis**: Conglomerated multiple ring-enhancing lesions
    - "Grape cluster" or "soap bubble" forms of enhancement
    - Chronic: Atrophy and calcification
  - **Schistosomiasis**: Central linear enhancement surrounded by multiple punctate nodules "**arborized**" appearance
  - **Sparganosis**: Variable; pattern may change on follow-up related to worm migration
    - **"Tunnel" sign**: Peripherally enhancing hollow tube
    - Conglomerate ring or bead-shaped enhancement
  - **Trichinosis**: Multiple microinfarcts with ring enhancement
  - **Trypanosomiasis**: Nodular or annular enhancement seen in American trypanosomiasis

Imaging Recommendations

- Best imaging tool
  - Contrast MR is most sensitive for detection
  - CT may be helpful to identify associated Ca++
- Protocol advice
  - Contrast-enhanced MR

DIFFERENTIAL DIAGNOSIS

Glioblastoma Multiforme

- Thick, irregular margin enhancement with central necrosis typical
- Often involves corpus callosum
- Typically in older adult

Parenchymal Metastases

- Enhancing mass at corticomedullary junctions
- Multiple lesions common
- Primary tumor often known

Abscess

- T2-hypointense rim and DWI(+) typical
- Ring enhancement, thinner on ventricular margin

Neurocysticercosis

- Cyst with marginal scolex
- Multiple lesions common

https://CafePezeshki.IR

Neurosarcoid

- Enhancing lesions involving dura, leptomeninges, and subarachnoid space
- Rarely affects brain parenchyma
  - Hypothalamus > brainstem > cerebral hemispheres > cerebellar hemispheres

Arachnoid Cyst

- Nonenhancing solitary lesion with CSF density/intensity
- Anterior middle cranial fossa most commonly

PATHOLOGY

General Features

- Etiology
  - **Paragonimiasis**: Ingestion of undercooked fresh water crabs or crayfish contaminated with *Paragonimus westermani* flukes (lung fluke)
    - Worms penetrate skull base foramina and meninges and directly invade brain parenchyma
    - Elicits granulomatous inflammatory reaction
  - **Schistosomiasis**: Infestation from trematode (fluke) worms
    - Host is freshwater snail
    - Releases *Schistosoma* larvae (cercariae) into water
    - Humans affected through skin
    - Migrate to lungs and liver, reach venous system
  - **Sparganosis**: Ingestion of contaminated water or food (snake, fish, frogs)
    - Larvae migrate through skull base foramina to reach brain
  - **Trichinosis**: Ingestion of uncooked meat containing infective encysted larvae
  - **Trypanosomiasis**: African (sleeping sickness) and American (Chagas disease)
    - African: Transmitted to humans by tsetse fly; invade meninges, subarachnoid, PVS
    - American: Transmitted by reduviid bugs

Gross Pathologic & Surgical Features

- **Paragonimiasis**: Cystic lesions elaborate toxins that result in infarction,hemorrhage, meningitis, adhesions
- **Schistosomiasis**: Granulomatous encephalitis, eggs seen at microscopy
- **Sparganosis**: Live worm or degenerated worm with surrounding granuloma found at surgery
- **Trichinosis**: Eosinophilic meningoencephalitis, ischemic lesions, petechial hemorrhage, necrosis
- **Trypanosomiasis**: Edema, congestion, hemorrhage

CLINICAL ISSUES

Presentation

- Most common signs/symptoms
  - **Paragonimiasis**: Headache, focal neurologic deficit
  - **Schistosomiasis**: Encephalopathy, seizures, paresis, headache, visual changes
  - **Sparganosis**: Headache, seizure, neurologic signs
  - **Trichinosis**: Fever, headache, delirium, seizures, focal neurologic deficits
  - **African trypanosomiasis**: Behavior change, indifference, daytime somnolence
  - **American trypanosomiasis**: Acute (fever, swollen face, conjunctivitis), chronic (neurologic)
- Clinical profile
  - Varies with organism, development stage, host immune response
  - ELISA studies can be helpful in some diseases

Demographics

- Age
  - Most parasitic infections occur at all ages, but commonly affect children and young adults
- Gender
  - Most parasitic infections have male predominance
- Epidemiology
  - Neurocysticercosis most common parasitic infection worldwide
  - Increased travel, immigration have spread diseases
  - **Paragonimiasis**: Brain involvement in 2-27% of cases
    - Endemic to East and Southeast Asia including Korea, China, and Japan
  - **Schistosomiasis**: 2% of cases have CNS complications
    - Endemic to tropical Africa, northeastern South America, and Caribbean islands
  - **Sparganosis**: Extremely rare
    - High incidence in Southeast Asia, Japan, China, and Korea
  - **Trichinosis**: CNS involvement in 10-24% of cases

Natural History & Prognosis

- Some parasitic infections (e.g., echinococcosis) develop slowly over many years
- **Schistosomiasis**: Anthelmintic treatment improves patient condition within 6 weeks with complete resolution within 6 months
- **Trichinosis**: Mortality in 5-10% of affected individuals
- **American trypanosomiasis**: Mortality in 2-10% of meningoencephalitis patients

Treatment

- Variable, ranges from oral therapy to lesion resection

DIAGNOSTIC CHECKLIST

Consider

- Complex conglomerated parasitic cysts of any etiology may mimic brain tumor
- Patient travel history is often key to diagnosis

SELECTED REFERENCES

1. Chu S et al: Magnetic resonance imaging features of pathologically proven cerebral sparganosis. J Int Med Res. 41(3):867-77, 2013
2. Coyle CM: Schistosomiasis of the nervous system. Handb Clin Neurol. 114:271-81, 2013
3. Li YX et al: Migration: a notable feature of cerebral sparganosis on follow-up MR imaging. AJNR Am J Neuroradiol. 34(2):327-33, 2013
4. MacLean L et al: Imaging African trypanosomes. Parasite Immunol. 35(9-10):283-94, 2013
5. Pittella JE: Pathology of CNS parasitic infections. Handb Clin Neurol. 114:65-88, 2013
6. Ross AG et al: Neuroschistosomiasis. J Neurol. 259(1):22-32, 2012
7. Abdel Razek AA et al: Parasitic diseases of the central nervous system. Neuroimaging Clin N Am. 21(4):815-41, viii, 2011

https://CafePezeshki.IR

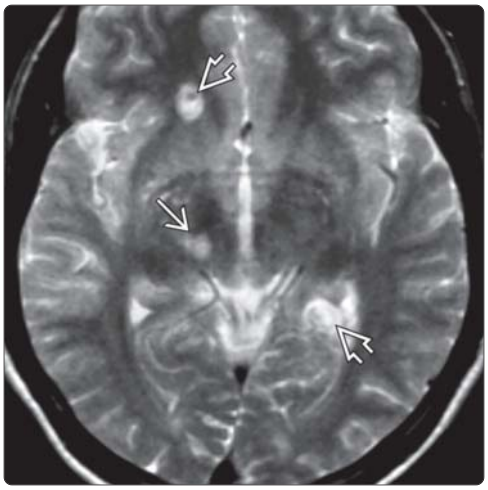

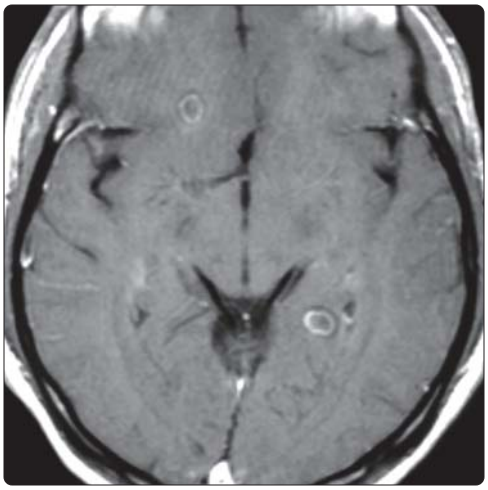

(Left) *Axial T2WI MR shows multiple round hyperintense lesions scattered in the hemispheres and right brainstem ➡. Some of the lesions have mixed signal with hypointense foci or a hypointense rim ➡.* **(Right)** *Axial T1WI C+ MR in the same patient with sparganosis shows ring enhancement of the lesions. Imaging mimics other parasites, including the much more common neurocysticercosis. Sparganosis is extremely rare and is related to ingestion of contaminated water or food. (Courtesy M. Castillo, MD.)*

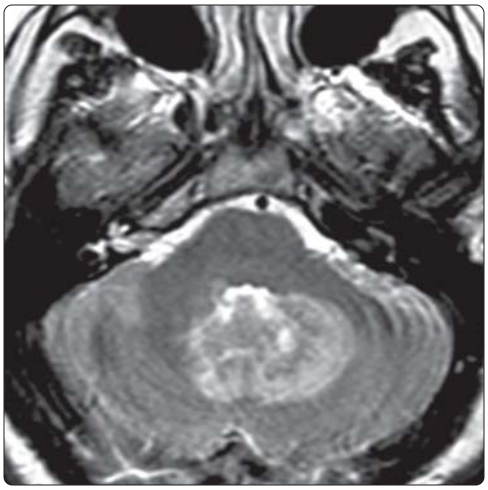

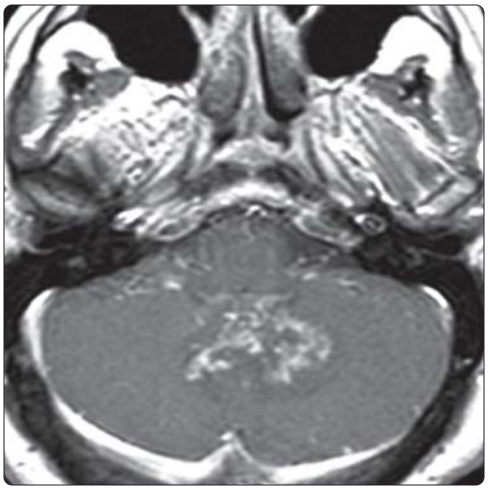

(Left) *Axial T2WI MR shows hyperintensity in the cerebellum related to edema in this young adult male with schistosomiasis.* **(Right)** *Axial T1WI C+ MR in the same patient shows patchy, mildly nodular enhancement in the cerebellum with surrounding edema. Imaging mimics granulomatous disease or neoplasm. Schistosomiasis often has central linear enhancement surrounded by multiple punctate nodules, causing an arborized appearance.*

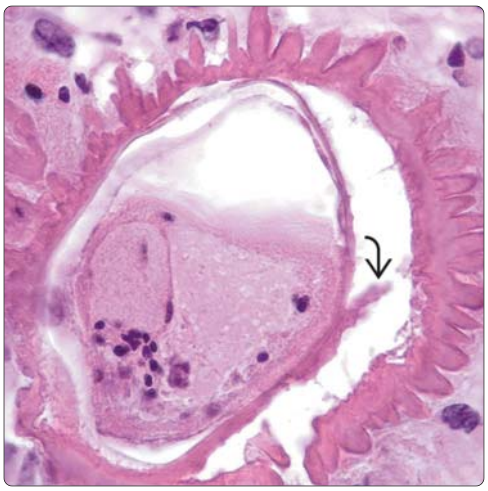

(Left) *Coronal T1WI C+ MR shows irregular punctate and nodular enhancement in the posterior fossa related to schistosomiasis. Schistosomiasis most commonly affects the cerebral hemispheres or the cerebellum.* **(Right)** *Microscopic pathology in the same patient shows a Schistosomiasis mansoni egg with a characteristic lateral spine ➡. Schistosomiasis infection is related to infestation from a trematode (fluke) worm and is very uncommon. (Courtesy D. Kremens MD., S. Galetta, MD.)*

https://CafePezeshki.IR

KEY FACTS

TERMINOLOGY

- Coccidioidomycosis, histoplasmosis (common)
- Invasive fungal infection (immunocompromised)
  - Candidiasis (common)
  - Aspergillus, mucormycosis are angioinvasive

IMAGING

- General features
  - Meningeal enhancement
  - Ring-enhancing brain lesions
  - Infarctions (both lacunar, territorial)
  - Diffuse brain edema, herniation, hydrocephalus
  - Hemorrhage(s)
  - Vasculitis, occlusions, mycotic aneurysms

TOP DIFFERENTIAL DIAGNOSES

- Invasive skull base neoplasm (e.g., SCCa)
  - Fungus often angioinvasive → ICA occlusion
  - Vessel occlusion rare in SCCa
- Ring-enhancing lesions (immunocompetent)
  - Metastases, pyogenic abscesses, septic emboli
- Ring-enhancing lesions (immunocompromised)
  - TB, toxoplasmosis, lymphoma

PATHOLOGY

- General
  - Congested meninges, swollen brain
  - Focal granulomas, abscesses
- Angioinvasive fungi
  - Vasculitis, infarcts
  - Hemorrhages, mycotic aneurysm

DIAGNOSTIC CHECKLIST

- Consider fungus in immunocompromised when
  - Acute neurologic deficit
  - Multiple brain lesions
  - Stroke, vascular occlusion

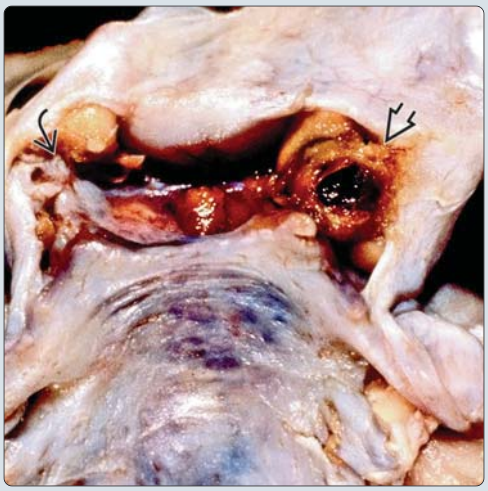

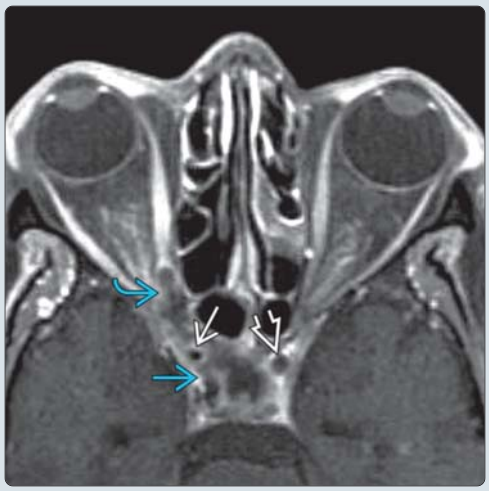

(Left) *Autopsy specimen shows aspergillosis invading the paranasal sinuses and skull base. One internal carotid artery is encased by fungus ⇨ while the other has been occluded ⇨. (Courtesy R. Hewlett, MD.)* **(Right)** *Axial T1+ C MR in a diabetic patient with invasive mucormycosis demonstrates necrotic soft tissue in the superior orbital fissure ⇨ with extension to cavernous sinus ⇨. Note narrowing of the right internal carotid artery ➡ with normal left internal carotid artery ➡.*

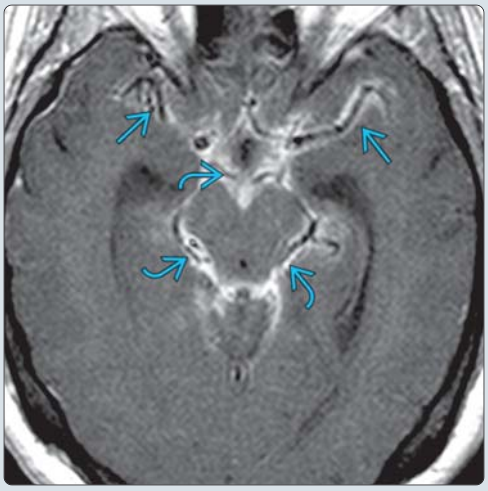

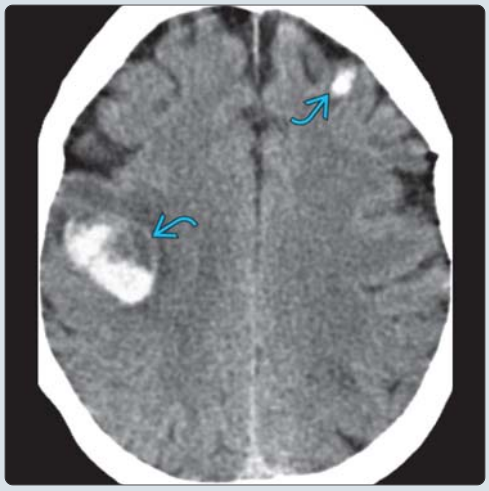

(Left) *Axial T1 C+ MR in a patient with coccidioidomycosis meningitis demonstrates extensive leptomeningeal enhancement in the basal cisterns ⇨ and sylvian fissures ⇨. Meningitis is the most common presentation of coccidioidomycosis.* **(Right)** *Axial NECT in an immunosuppressed patient shows multifocal parenchymal hemorrhages ⇨ at the gray-white matter interface. Hemorrhagic mycetomas from angioinvasive aspergillosis were documented at surgery.*

https://CafePezeshki.IR

TERMINOLOGY

Definitions

- Coccidioidomycosis
  - Sporadic, relatively common
- Histoplasmosis
  - Common
- Blastomycosis
  - Rare, sporadic, generally affects lungs/skin
- Invasive CNS fungal infections
  - Patients usually immunocompromised
  - Agents
    - Hyphae: Aspergillosis, mucormycosis
    - Pseudo-hyphae/yeast: Candidiasis

IMAGING

General Features

- Best diagnostic clue
  - Meningeal enhancement, enhancing lesions in brain in immunosuppressed patient
  - Coccidioidomycosis: Meningitis
  - Blastomycosis and histoplasmosis: Rare infections with parenchymal abscesses or meningitis
  - Angioinvasive aspergillosis: Multifocal hemorrhagic lesions with reduced diffusion
  - Mucormycosis: Frontal lobe lesions with markedly reduced diffusion
  - Candidiasis: Numerous microabscesses < 3 mm at corticomedullary junction, basal ganglia, or cerebellum
- Location
  - Meninges, brain, spinal cord
- Size
  - Variable (mm to cm)
- Morphology
  - Many lesions are ring-like

CT Findings

- NECT
  - Areas of low density = infection, lacunar infarctions, territorial infarcts
  - Diffuse brain edema, herniation, hydrocephalus
  - Hemorrhages
- CECT
  - Foci of enhancement, some ring-like

MR Findings

- T1WI
  - Ill-defined areas of low signal intensity
- T2WI
  - Focal or diffuse areas of high signal intensity
  - May have peripheral hypointense rim
  - Fungal abscess characteristic feature: Intracavitary projections
- T2* GRE
  - Blooming due to blood products
- DWI
  - May have restricted diffusion
  - Fungal abscess: Wall and intracavitary projections show restricted diffusion with ↓ ADC, cavity of abscess may show ↑ ADC
- T1WI C+
  - Thick meningeal enhancement
  - Cerebral enhancement may be ring-like, solitary to miliary
  - Fungal abscess: Intracavitary projections do not enhance
- MRA
  - Vasculitis, occlusions, mycotic aneurysms
- MRS
  - Mildly ↑ Cho, ↓ NAA, ↑ lactate
  - Fungal abscess: ↑ amino acids (valine, leucine, isoleucine), ↑ lactate as well as multiple peaks between 3.6 and 4.0 ppm

Angiographic Findings

- Vasculitis, mycotic aneurysms

Nuclear Medicine Findings

- PET
  - ↓ metabolism and ↓ blood flow to lesions

Imaging Recommendations

- Best imaging tool
  - MR
- Protocol advice
  - Contrast-enhanced MR essential
  - MRS (infection vs. neoplasm)

DIFFERENTIAL DIAGNOSIS

Locally Invasive Skull Base Neoplasm

- e.g., SCCa
- Look for soft tissue mass in nasopharynx
- Fungal infection often angioinvasive with ICA occlusion (extremely rare in SCCa)

Multiple Ring-Enhancing Brain Lesions

- Immunocompetent patients
  - Metastases
  - Pyogenic abscesses
  - Parasites (e.g., neurocysticercosis)
  - Septic emboli
- Immunocompromised patients
  - Tuberculosis
  - Toxoplasmosis
  - Primary CNS lymphoma

PATHOLOGY

General Features

- Etiology
  - Blastomycosis: *B. dermatitidis*
    - Inhalation, may be acquired by pet bites
  - Coccidioidomycosis: *C. immitis*
    - Inhalation, then hematogenous spread
  - Histoplasmosis: *H. capsulatum*
    - Inhalation, then hematogenous spread
  - Candidiasis: *C. albicans*
    - Initially involves gastrointestinal &/or respiratory systems
    - Then spreads hematogenously
  - Aspergillosis: *A. fumigatus*
    - Inhalation of spores, hypersensitivity reaction

https://CafePezeshki.IR

  - Hematogenous dissemination in immunosuppressed
  - Angioinvasive
  - Mucormycosis: Phycomycetes (*Mucor*, *Rhizopus*)
    - Enter via nasopharynx
    - Can be inhaled into lungs
    - Can have rhinocerebral extension
    - Angioinvasive
- Associated abnormalities
  - Histoplasmosis
    - Calcified/cavitating lung lesions
    - Mediastinal nodes
  - Coccidioidomycosis
    - Generally affects lungs

Gross Pathologic & Surgical Features

- All: Congested meninges, swollen brain, focal granulomas, abscesses
- Coccidioidomycosis
  - Involvement of CNS in 30%
  - Meningitis most common
  - Vasculitis (40%), infarcts, hemorrhages
- Candidiasis
  - Hemorrhagic infarcts
  - Abscess, granulomas (may be miliary)

Microscopic Features

- Granulomas or small abscesses
  - Caseous necrosis, giant cells, neutrophils, lymphocytes
- Identification of specific organism needed for diagnosis
- Fibropurulent meningitis → meningeal fibrosis

CLINICAL ISSUES

Presentation

- Most common signs/symptoms
  - Initially for all
    - Weight loss, fever, malaise, fatigue
  - Meningitis
    - Acute focal neurological deficits from stroke/hemorrhage
- Clinical profile
  - Many fungal infections have associated lung lesions (granulomas, airspace disease) in immunocompetent patients
  - CSF usually shows pleocytosis, ↓ glucose, ↑ protein

Demographics

- Age
  - More common in young and older individuals
  - Seen at any age if immunocompromised
- Gender
  - M > F (more outdoor activities)
- Ethnicity
  - No predilection
- Epidemiology
  - Blastomycosis
    - Fungus lives in damp places, rotting wood
    - Endemic in Africa, USA (Mississippi, Arkansas, Kentucky, Tennessee, Wisconsin)
  - Coccidioidomycosis
    - Fungus lives in damp places, rotting wood
    - Southwestern USA, northern Mexico, South America
    - 60,000-80,000 new cases/year in USA
  - Histoplasmosis
    - Fungus in chicken, pigeon, bat feces
    - Worldwide distribution
    - ~ 25% of USA population infected
    - Disseminated disease usually seen in infancy/childhood, immunosuppression
  - Candidiasis
    - Worldwide distribution
    - Most common nosocomial fungal infection
    - Higher incidence in diabetics, immunocompromised
    - Occasionally seen in immunocompetent individuals
  - Mucormycosis
    - Ubiquitous; found in organic matter, soil
    - Mostly affects immunocompromised
  - Aspergillosis
    - Ubiquitous; found in damp places
    - Mostly affects immunocompromised
    - Occasionally becomes invasive in immunocompetent

Natural History & Prognosis

- Delay in diagnosis and treatment → poor prognosis

Treatment

- Options, risks, complications
  - Survival depends on early diagnosis, prompt initiation of antifungal therapy
    - Amphotericin B in immunocompromised, life-threatening cases
  - Survival depends on management of underlying disease process

DIAGNOSTIC CHECKLIST

Consider

- Consider fungal infection when acute neurologic deficit in immunocompromised patient

Image Interpretation Pearls

- Consider fungal infection with multiple brain lesions in immunocompromised patient
- Consider fungal infection with associated stroke, vascular occlusion

SELECTED REFERENCES

1. Murthy JM et al: Fungal infections of the central nervous system. Handb Clin Neurol. 121:1383-401, 2014
2. Saini J et al: Intracranial infections: key neuroimaging findings. Semin Roentgenol. 49(1):86-98, 2014
3. Starkey J et al: MRI of CNS fungal infections: review of aspergillosis to histoplasmosis and everything in between. Clin Neuroradiol. 24(3):217-30, 2014
4. Lammering JC et al: Imaging spectrum of CNS coccidioidomycosis: prevalence and significance of concurrent brain and spinal disease. AJR Am J Roentgenol. 200(6):1334-46, 2013

https://CafePezeshki.IR

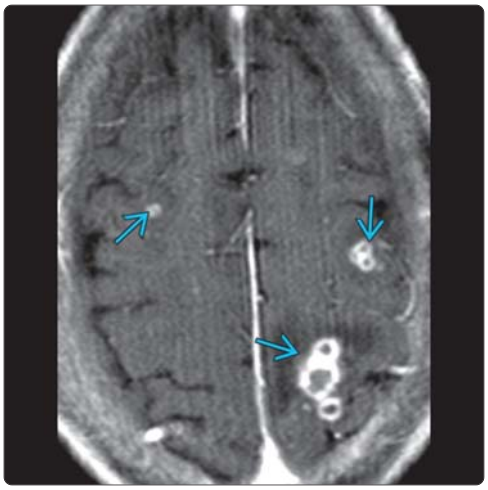

(Left) *Axial CECT in an immunosuppressed patient shows a large, low-density mass in the right frontal lobe and deep basal ganglia with irregular rim enhancement* ⇨ *and surrounding edema* ➡ *with local mass effect. Aspergilloma abscess was found at surgery.* **(Right)** *Axial T1+C MR in a patient with disseminated candidiasis demonstrates multiple small ring enhancing lesions* ⇨*. Candidiasis usually manifests by numerous microabscesses occurring at the corticomedullary junction, basal ganglia, or cerebellum.*

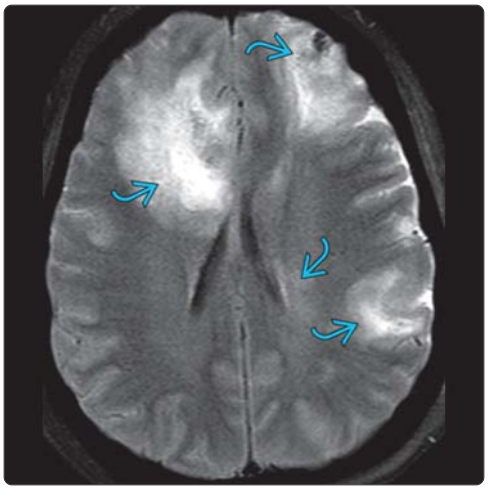

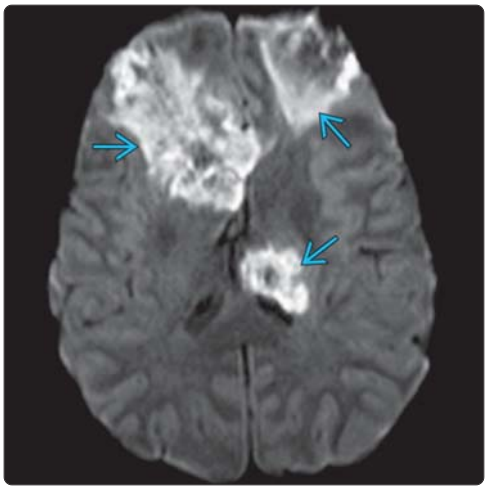

(Left) *Axial FLAIR MR in a patient with ALL status post stem cell transplant demonstrates large hyperintense areas* ⇨ *involving the cortex, subcortical white matter, and basal ganglia. There is mass effect on the lateral ventricles greater on the right.* **(Right)** *Axial DWI in the same patient shows corresponding large areas of restricted diffusion* ⇨ *due to infarction.*

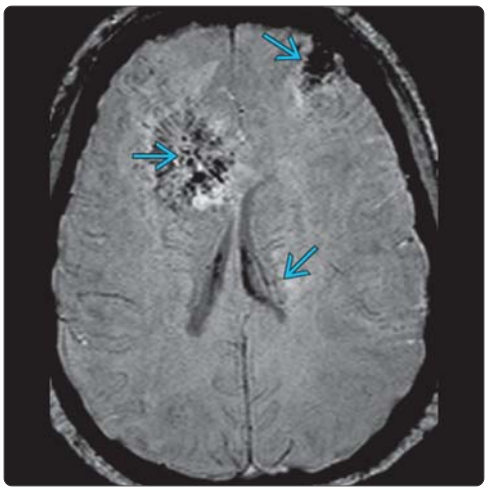

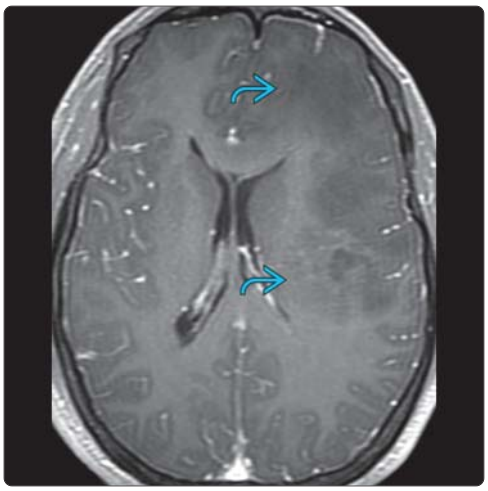

(Left) *Axial SWI MR in the same patient shows multiple punctate "blooming" foci* ⇨ *within the areas of FLAIR signal abnormality consistent with petechial hemorrhages.* **(Right)** *Axial T1+C MR in the same patient does not show any significant enhancement* ⇨*. Angioinvasive mucormycosis was found at surgery. Angioinvasive fungi (Mucor, Aspergillus) produce enzyme elastase which compromises blood vessel wall leading to inflammatory reaction, vasculitis, thrombosis, and eventual infarction.*

https://CafePezeshki.IR

KEY FACTS

TERMINOLOGY

- Rocky Mountain spotted fever (RMS), Q fever, epidemic typhus (ET)
- Zoonotic infections of squirrels and other animals → ticks carrying *Rickettsia* → humans
  - Exception is *Coxiella burnetii* (causes Q fever) transmitted by inhalation

IMAGING

- ~ 20% of patients with RMS have abnormal imaging
  - End artery infarct-like lesions (especially BG)
  - Ill-defined hypodensities on CT
  - T2 hyperintensities in perivascular spaces, deep gray nuclei
  - ± diffuse brain swelling
  - Perivascular lesions, meninges may enhance
- Cauda equina, low spinal cord may be abnormal

PATHOLOGY

- RMS caused by *Rickettsia rickettsii*
  - Dog or wood tick bite
- ET caused by *Rickettsia prowazekii*
  - Transmitted to humans via the louse
- Q fever caused by *Coxiella burnetii*
  - Transmission from inhalation of dust contaminated with *Coxiella burnetii*

CLINICAL ISSUES

- RMS: Most frequently reported life-threatening tick-borne infection
- RMS: Sudden onset fever, myalgias, headache
  - Petechial rash then develops (palms, soles, then spreads to trunk in 90%)
- RMS can be difficult to diagnose in early stages
- RMS: Mortality 2-10% even under adequate therapy
- Normal MR is favorable prognostic sign

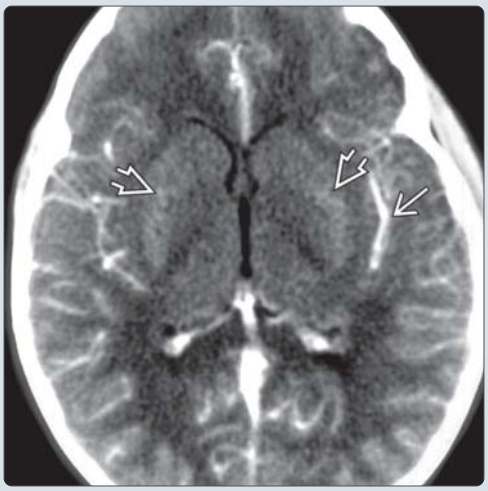

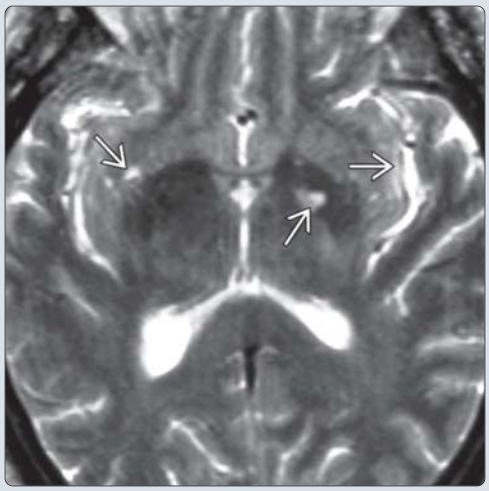

(Left) *Axial CECT in a patient with Rocky Mountain spotted fever shows pial enhancement, especially striking along the left insula. Some faint enhancement in the basal ganglia is present.* **(Right)** *Axial T2WI MR in the same patient shows punctate areas of increased signal intensity in the basal ganglia and subinsular white matter. RMS is caused by Rickettsia rickettsii and transmitted by dog or wood tick bite. Vasculitis is a characteristic appearance on pathology.*

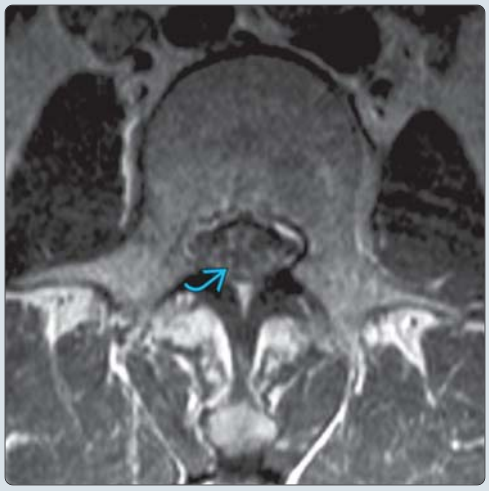

(Left) *Sagittal T1 C+ MR shows enhancement of ventral and dorsal nerve roots in the distal spinal cord and conus medullaris regions.* **(Right)** *Axial T1 C+ MR in the same patient shows the nerve roots enhancing. Rocky Mountain spotted fever (RMS) can involve the brain, spinal cord, and cauda equina. RMS is still the most frequently reported life-threatening tick-borne infection. Mortality ranges from 2-10% even under adequate antibiotic therapy.*

https://CafePezeshki.IR

TERMINOLOGY

Abbreviations

- Rocky Mountain spotted fever (RMS), Q fever, epidemic typhus (ET)

Definitions

- Zoonotic infections of squirrels and other animals → ticks carrying *Rickettsia* → humans
  - Exception is Q fever (caused by *Coxiella burnetii*) transmitted by inhalation

IMAGING

General Features

- Best diagnostic clue
  - Ill-defined areas of low density on CT, high signal on T2WI along perivascular spaces and deep gray matter
  - Associated skin rash
- Location
  - RMS: Perivascular spaces, meninges, cauda equina, lower spinal cord
  - Q fever: Meninges, cerebellum, spinal cord
- Morphology
  - End artery infarct-like lesions

CT Findings

- NECT
  - Small, ill-defined WM low-density foci
  - Infarct-like lesions in deep gray matter
  - Lesions may have small focal hemorrhages

MR Findings

- T2WI
  - Hyperintense lesions in distribution of perivascular spaces, deep gray nuclei, pons
  - Diffuse brain swelling
- DWI
  - Some lesions show restricted diffusion
- T1WI C+
  - Some lesions and meninges enhance
  - Enhancement in cauda equina nerve roots and lower thoracic spinal cord

Imaging Recommendations

- Best imaging tool
  - MR (only 20% of patients have abnormal MR)
- Protocol advice
  - Brain MR with DWI, T1 C+

DIFFERENTIAL DIAGNOSIS

Cryptococcosis and Lyme Disease

- No associated rash

Vasculitis

- Segmental arterial narrowing on DSA
- Multiple infarcts of different ages on DWI

Sarcoidosis

- Suprasellar region, orbit also frequently involved

PATHOLOGY

General Features

- Etiology
  - RMS caused by *Rickettsia rickettsii*
    - Dog or wood tick bite
    - Spreads via blood stream, proliferates, injures endothelial & vascular smooth muscle cells
  - ET caused by *Rickettsia prowazekii*
    - Transmitted to humans via louse
  - Q fever caused by *Coxiella burnetii*
    - Transmission from inhalation of dust contaminated with *Coxiella burnetii*

Microscopic Features

- RMS: Vasculitis, typhus nodules, perivascular infiltrates
- Confirmation of RMS by histologic examination of skin biopsy

CLINICAL ISSUES

Presentation

- Most common signs/symptoms
  - RMS: Sudden onset fever, myalgias, headache
    - Petechial rash (90% in palms, soles) develops later
  - Can be difficult to diagnose in early stages
- Clinical profile
  - RMS: Anemia, thrombocytopenia, coagulopathy, abnormal liver function tests, ↑ BUN

Demographics

- Epidemiology
  - RMS: Most frequently reported life-threatening tick-borne infection
  - RMS: 25% of cases in North Carolina, > 50% cases reported in South Atlantic region of USA
  - ET: Typically seen in overcrowded populations living in poor & unsanitary conditions
  - Q fever: Seen around world; occurs mainly in people in contact with goats, sheep, and dairy cattle

Natural History & Prognosis

- RMS: Early antibiotics → effective
  - If not treated → rapidly progressive
- RMS: Mortality 2-10% even under adequate therapy

Treatment

- RMS: Tetracyclines, chloramphenicol

DIAGNOSTIC CHECKLIST

Consider

- Normal MR does not exclude diagnosis but is favorable prognostic sign

SELECTED REFERENCES

1. Delord M et al: Rickettsioses and Q fever in travelers (2004-2013). Travel Med Infect Dis. 12(5):443-58, 2014
2. Hart BL et al: Armies of Pestilence: CNS Infections as Potential Weapons of Mass Destruction. AJNR Am J Neuroradiol. ePub, 2014
3. Parola P et al: Update on tick-borne rickettsioses around the world: a geographic approach. Clin Microbiol Rev. 26(4):657-702, 2013

https://CafePezeshki.IR

KEY FACTS

TERMINOLOGY

- Lyme disease (LD), Lyme neuroborreliosis (LNB)
- Multisystem inflammatory disease
  - Caused by spirochete *Borrelia burgdorferi* (USA)
  - Transmitted by *Ixodes* tick bite
  - Reservoirs = white tail deer/field mouse

IMAGING

- MS-like WM lesions (may enhance)
  - 2-8 mm (large "tumefactive" lesions rare)
- ± multiple enhancing cranial nerves
- ± cauda equina, meningeal enhancement

TOP DIFFERENTIAL DIAGNOSES

- Demyelinating disease
- Vasculitis
- Sarcoidosis
- Chronic fatigue syndrome

CLINICAL ISSUES

- Most common vector-borne disease in USA
  - Round, bull's-eye skin rash
  - ± flu-like symptoms
  - Meningopolyneuritis, radiculitis common
- Confirm with ELISA, PCR
- Peak incidence: May through July
- Incubation period varies from days to weeks
- Progressive debilitating disorder if not treated early
- 10-15% of untreated patients develop neurologic manifestations

DIAGNOSTIC CHECKLIST

- Consider geography, recreational/travel history, season
- Consider LNB if MS-like lesions in patient with erythema migrans
  - ± enhancing CNs, cauda equina

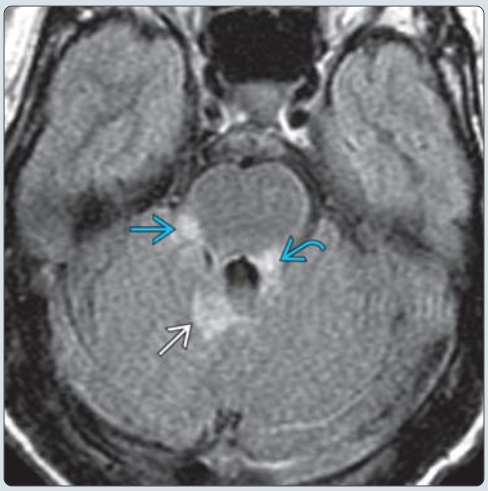

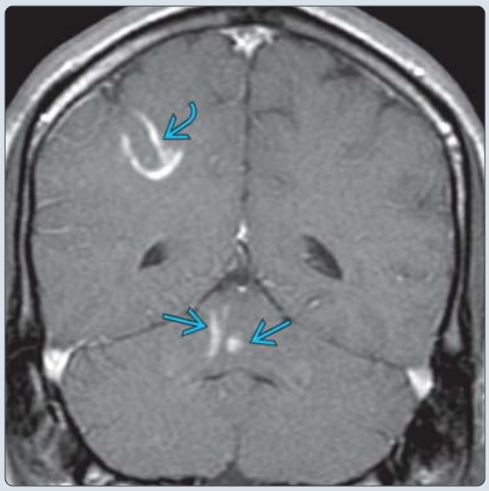

(Left) *Axial FLAIR MR in a patient with serologically documented Lyme disease shows multiple hyperintense foci in the left superior cerebellar peduncle, right lateral pons, and cerebellum.* **(Right)** *Coronal T1WI C+ MR in the same patient shows enhancement of a right cerebral white matter lesion, as well as posterior fossa lesions. Lyme disease generally manifests as foci of T2 hyperintensities, nerve root, or meningeal enhancement.*

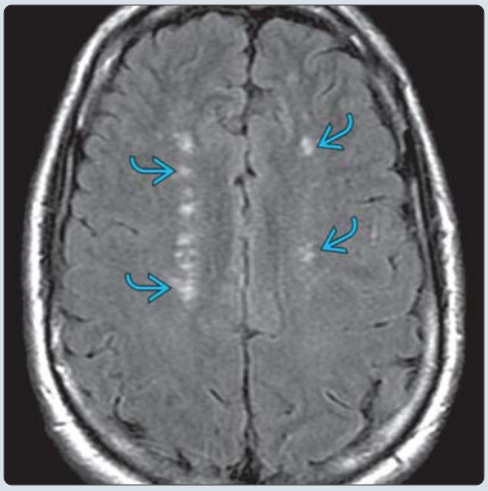

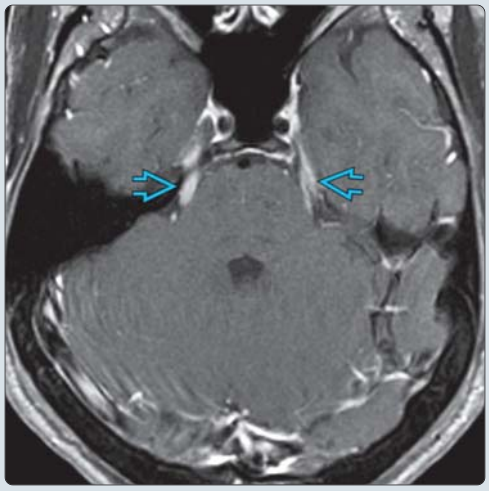

(Left) *Axial FLAIR in a patient with history of tick bite and erythema migrans demonstrates multiple white matter hyperintensities in the deep white matter. WM lesions in Lyme may resemble multiple sclerosis plaques although involvement of callososeptal interface is less common.* **(Right)** *Axial T1 C+ MR in a 24-year-old man with recent history of camping shows enhancement of the cisternal segment of both trigeminal nerves. Third, 5th, and 7th cranial nerve enhancement can be seen in Lyme neuroborreliosis.*

https://CafePezeshki.IR

TERMINOLOGY

Abbreviations

- Lyme disease (LD), Lyme neuroborreliosis (LNB)

Definitions

- Multisystem inflammatory disease
  - Caused by spirochete *Borrelia burgdorferi* (different subspecies in Europe)
  - Transmitted by hard-bodied tick bite

IMAGING

General Features

- Best diagnostic clue
  - Multiple sclerosis-like lesions + cranial neuritis
  - Meningoradiculoneuritis (Bannwarth syndrome) in Europe
- Location
  - Periventricular white matter (WM)
  - Cranial nerves (CN7 > CN3 and CN5)
  - Cauda equina, leptomeninges
- Size
  - 2-8 mm (large "tumefactive" lesions rare)

CT Findings

- NECT
  - Usually normal

MR Findings

- T2WI
  - Hyperintensities in periventricular WM, spinal cord
- DWI
  - Some lesions may show restriction
- T1WI C+
  - Variable enhancement
    - WM lesions/meninges/cauda equina
    - ± cranial nerve enhancement (including CN7 root exit zone, fundal tuft)

Imaging Recommendations

- Protocol advice
  - Brain MR (include T1 C+, DWI)

DIFFERENTIAL DIAGNOSIS

Demyelinating Disease

- WM lesions; lesions in optic nerve, spinal cord, callosal-septal interface more common in MS

Vasculitis

- T2 lesions ± arterial narrowing (DSA)

Sarcoidosis

- Meningeal, perivascular spaces, infundibulum

PATHOLOGY

General Features

- Etiology
  - Spirochete *Borrelia burgdorferi* (USA)
  - Transmitted by hard-bodied ticks of genus *Ixodid*

Microscopic Features

- Perivascular lymphocyte/plasma cell infiltrates
  - Endo-/peri-/epineurial blood vessels
  - Causes endarteritis obliterans
- Axonal degeneration
- Lymphocytes, plasma cells accumulate in autonomic ganglia

CLINICAL ISSUES

Presentation

- Most common signs/symptoms
  - Early local: Round, outwardly expanding rash ("bull's-eye")
    - ± flu-like symptoms, lymphadenopathy
  - Early disseminated: Erythema migrans (may develop at sites different from tick bite)
    - Neurologic symptoms: Facial nerve palsy, meningitis, mild encephalitis, memory loss
  - Late disseminated: Brain, nerves, eyes, joints, heart
    - Knee most common joint involved
  - CNS symptoms in about 15-20% of patients with characteristic skin rash
- Clinical profile
  - Confirmation of diagnosis: ELISA, PCR

Demographics

- Epidemiology
  - Most common vector-borne disease in USA
    - US incidence 9.7 cases per 100,000
    - Coastal Northeast states, Midwest & the West
    - Peak incidence: May through July
  - White tail deer/white-footed mouse most important reservoirs

Natural History & Prognosis

- Progressive debilitating disorder if not treated early
- 10-15% of untreated patients develop neurologic manifestations
- Most recover with minimal or no residual deficits

Treatment

- Adults: Doxycycline, tetracycline, chloramphenicol
- Children: Amoxicillin
- Ketolides (new, experimental)

DIAGNOSTIC CHECKLIST

Consider

- Lyme neuroborreliosis if MS-like lesions in patient with erythema migrans
  - ± enhancing CNs, cauda equina
- Geography, recreational/travel history, season of year

SELECTED REFERENCES

1. Hansen K et al: Lyme neuroborreliosis. Handb Clin Neurol. 115:559-75, 2013
2. Akgoz A et al: Imaging of rickettsial, spirochetal, and parasitic infections. Neuroimaging Clin N Am. 22(4):633-57, 2012
3. Hildenbrand P et al: Lyme neuroborreliosis: manifestations of a rapidly emerging zoonosis. AJNR Am J Neuroradiol. 30(6):1079-87, 2009

https://CafePezeshki.IR

KEY FACTS

TERMINOLOGY

- HIV-1 encephalitis/HIV-1 encephalopathy (HIVE)
- HIV-associated neurocognitive disorders (HAND)
- Moderate cognitive impairment common despite good virologic response to therapy
- Direct HIV infection of brain
  - Opportunistic infections absent
  - Cognitive, behavioral, motor abnormalities in 25-70%
  - Most frequent neurological manifestation of HIV infection

IMAGING

- CT
  - Atrophy
  - Bilateral periventricular/diffuse WM hypointensities
  - Basal ganglia, cerebellum, brainstem hypodensity
- MR
  - Diffuse "hazy" hyperintense WM on T2/FLAIR
  - Nonenhancing (if enhancement present, consider opportunistic infections, IRIS)
- MRS
  - AIDS dementia complex: ↑ myo-inositol, ↑ choline, ↓ N-acetyl aspartate
  - Asymptomatic patients with normal cognition: Mild ↑ myo-inositol

PATHOLOGY

- HIV has ability to cause neurologic disease
  - Does not replicate within neural/glial cells
  - Microglial nodules with multinucleated giant cells
- WM pallor early, neocortical infection/atrophy late

DIAGNOSTIC CHECKLIST

- Evidence of "cerebral atrophy" by CT/MR does not indicate AIDS dementia complex in HIV positive patient
- Consider reversible causes 1st (dehydration, malnutrition, protein depletion, alcoholism)

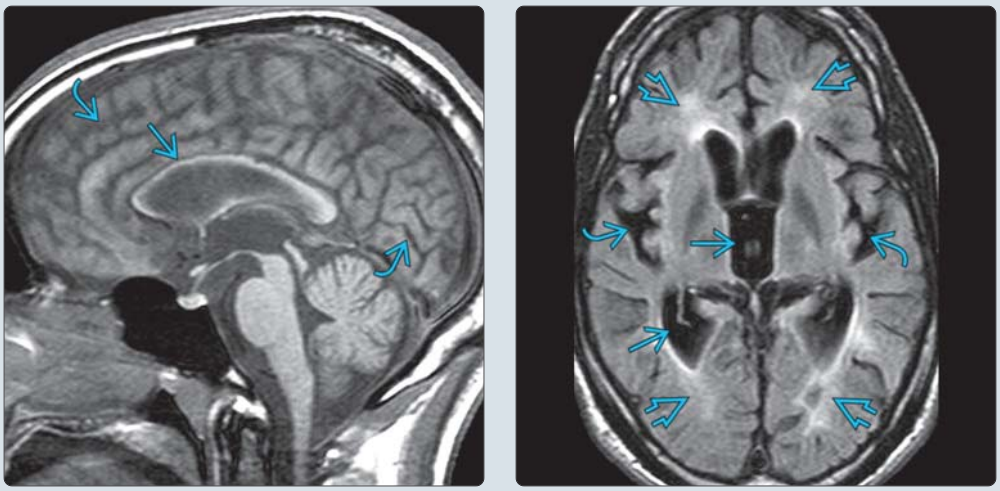

(Left) *Sagittal T1WI MR in a 35-year-old man with HIV shows generalized atrophy, enlarged sulci, and severe atrophy of the corpus callosum.* **(Right)** *Axial FLAIR MR in the same patient shows enlarged ventricles and sylvian fissures due to diffuse atrophy. There are hazy periventricular white matter hyperintensities. These imaging findings are characteristic of HIV encephalitis.*

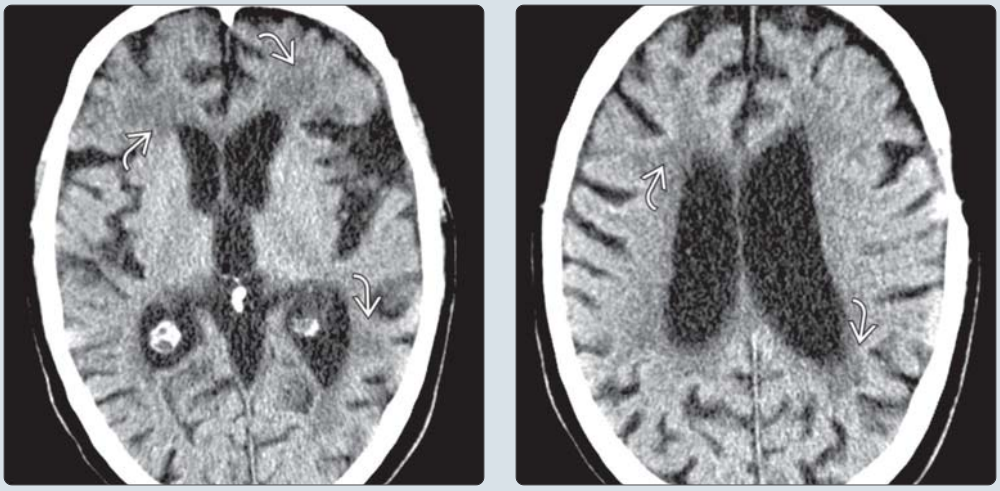

(Left) *Axial NECT in a 38-year-old man with longstanding HIV/AIDS, who was receiving HAART, was obtained for decreasing cognitive function. Note the gross atrophy and low density within the subcortical white matter.* **(Right)** *Axial NECT in the same patient shows characteristic low density in the periventricular white matter along with diffusely enlarged sulci and lateral ventricles.*

https://CafePezeshki.IR

TERMINOLOGY

Definitions

- HIV-1 encephalitis/encephalopathy (HIVE)
- Direct HIV infection of brain
  - Opportunistic infections absent
  - Cognitive, behavioral, motor abnormalities in 25-70%
  - HIV-associated neurocognitive disorders (HAND) = most frequent neurological manifestations of HIV infection
- Moderate cognitive impairment common despite good virologic response to therapy

IMAGING

General Features

- Best diagnostic clue
  - Atrophy + bilateral diffuse white matter (WM) abnormalities
    - Pathology/imaging varies with patient age, acuity of onset
- Location
  - Bilateral periventricular/centrum semiovale WM, basal ganglia, cerebellum, brainstem
- Size
  - Variable, often diffuse
- Morphology
  - Extends to gray-white matter junction

CT Findings

- NECT
  - Children: Atrophy and diffuse WM hypodensity
    - In utero HIV infection: Characteristic bilateral and symmetrical calcifications in basal ganglia and frontal WM with eventual contrast enhancement
  - Adults: Normal or mild atrophy, WM hypodensity
  - No mass effect
- CECT
  - Usually no contrast enhancement

MR Findings

- T1WI
  - WM abnormality may not be evident
- T2WI
  - 2 imaging patterns
    - Focal abnormalities of high signal intensity
    - Diffuse moderate-high signal WM changes
  - Distribution and extent of WM lesions does not always correlate with clinical picture
- FLAIR
  - Same imaging patterns as T2WI
  - Allows early detection of small lesions in cortical/subcortical and deep WM locations
  - Greater overall lesion conspicuity (when compared to T2)
- T1WI C+
  - No enhancement in involved regions
- MRS
  - AIDS dementia complex
    - ↑ myo-inositol, ↑ choline in white matter and basal ganglia
    - ↓ N-acetyl aspartate (NAA) in white matter
  - Asymptomatic patients with normal cognition
    - Mild ↑ myo-inositol in white matter
- 2 major consequences of brain tissue HIV infection
  - Atrophy of brain parenchyma due to neuronal death
  - Alterations of deep WM (usually periventricular regions) → high signal intensity on T2WI
- **Magnetization transfer ratio (MTR)**
  - MTR allows differentiation of HIVE from progressive multifocal leukoencephalopathy (PML)
    - Dramatic ↓ in MTR for PML lesions (as compared to HIVE lesions) likely due to demyelination
- **Diffusion tensor imaging**
  - May show early ↓ fractional anisotropy in HIV-associated cognitive impairment

Imaging Recommendations

- Best imaging tool
  - MR better than CT for WM lesion detection
  - MRS may detect changes in WM even during asymptomatic stage
- Protocol advice
  - CT scan should be performed when
    - New seizure, new onset of headache, depressed, or altered orientation
  - MR scan should be performed when
    - CT shows focal mass

DIFFERENTIAL DIAGNOSIS

Progressive Multifocal Leukoencephalopathy (PML)

- Patchy WM lesions
  - May be unilateral but more often bilateral, asymmetric
  - Parietooccipital locations most common
  - Subcortical U-fibers affected (unlike HIV or CMV)
- No enhancement; if present, consider immune reconstitution inflammatory syndrome (IRIS)

CMV-Associated CNS Disease

- Encephalitis (diffuse WM hyperintensities)
- Ventriculitis (ependymal enhancement)

Herpes Virus Encephalitis

- Herpes simplex virus (HSV), human herpes virus 6 (HHV-6): Initially hippocampal and medial temporal lesions

Toxoplasmosis

- Ring-enhancing mass(es)
- Hyperintense lesions on T2WI/FLAIR, DWI

Primary CNS Lymphoma

- Solitary/multifocal lesions, deep > subcortical lesions
- Marked predilection for basal ganglia, cerebellar hemispheres, thalamus, brainstem, corpus callosum, and subependymal region
- CECT: Usually rim enhancement in HIV positive patients
- Positive thallium-201 SPECT

Cryptococcosis

- "Gelatinous" pseudocysts within perivascular spaces
- Meningoencephalitis ± vasculitis, infarction

https://CafePezeshki.IR

PATHOLOGY

General Features

- Etiology
  - During primary infection, HIV is transported into brain by monocyte/macrophage system
  - HIV has ability to cause neurologic disease but does not replicate within neural/glial cells
  - Myelin destruction is not typical; T2WI WM hyperintensities may be due to ↑ water content
  - Inflammatory (T-cell) reaction with vasculitis, leptomeningitis
- Genetics
  - HIV genomic → more neurovirulent strains
  - Dementia affects only some patients depending on whether critical mutations occur in HIV strain
- Associated abnormalities
  - HIVE can occur in conjunction with other AIDS-related abnormalities (e.g., other infections)
  - Progressive encephalopathy in children is frequently associated with myelopathy
- Hallmark of HIVE: Microglial nodules with multinucleated giant cells (MGCs)
- Reactive gliosis, focal necrosis, and demyelination
- Mild neuronal loss; minor inflammatory changes
- Viral entry into brain occurs very early after systemic infection

Staging, Grading, & Classification

- 3 types of neuropathological findings
  - Finding 1: HIV encephalitis
    - Multiple disseminated foci of microglia, macrophages, and MGCs; if no MGCs found, HIV antigen/nucleic acids required
  - Finding 2: HIV leukoencephalopathy
    - Diffuse and symmetric WM damage (myelin loss, reactive astrogliosis, macrophages, and MGCs); if no MGCs found, HIV antigen/nucleic acids required
  - Finding 3: HIV giant cells
    - PAS(+) mono- or multinuclear macrophages
- Mild HIVE: Finding 1 without MGCs
- Moderate HIVE: Finding 1, 2, or 3
- Severe HIVE: Cerebral atrophy with finding 1 or 2

Gross Pathologic & Surgical Features

- Early: WM pallor
- Late: Neocortical infection, atrophy

Microscopic Features

- HIVE
  - Infected cells: Mostly macrophages and microglia; few astroglia; rarely oligodendrocytes
  - Neurons undergo secondary damage
  - Minor inflammatory changes: Perivascular macrophage infiltrates and microglial nodules
- Progressive encephalopathy in pediatric AIDS population
  - Inflammatory infiltrates with MGCs
  - Extensive calcific vasculopathy primarily in small vessels of basal ganglia, also cerebral WM and pons
  - Atrophy from impaired development of myelin or myelin loss

CLINICAL ISSUES

Presentation

- Most common signs/symptoms
  - Subcortical dementia with cognitive, motor, and behavioral deficits
- Clinical profile
  - HIV cognitive syndrome: Minor or major (dementia)
  - Deficits of central motor function
  - Behavioral: Pseudodementia (depression), delirium, and confusion
  - Pediatric: Microcephaly, cognitive defects, weakness, pyramidal signs, ataxia, and seizures

Demographics

- Age
  - Both pediatric and adult HIV positive patients
- Gender
  - No preference; gender distribution of HIVE reflects that of HIV infection
- Epidemiology
  - 33-67% of adult AIDS patients and 30-50% of pediatric AIDS patients are affected by HIVE
  - HIVE occurs before opportunistic infections and neoplasms; prevalence unrelated to disease stage

Natural History & Prognosis

- Cognitive decline occurs once patients become immunocompromised
- Slowly progressive impairment of fine motor control, verbal fluency, and short-term memory
- After few months: Severe deterioration and subcortical dementia with near vegetative state as final stage

Treatment

- Highly active antiretroviral therapy (HAART) cannot prevent occurrence of HIVE but ↓ HIVE severity
  - HAART era: ↓ frequency of severe HIVE, but ↑ frequency of mild-moderate HIVE

DIAGNOSTIC CHECKLIST

Consider

- Evidence of "cerebral atrophy" by CT/MR does not indicate AIDS dementia complex in HIV positive patient
  - Consider reversible causes 1st (dehydration, malnutrition, protein depletion, alcoholism)

Image Interpretation Pearls

- Characteristic parenchymal changes often missed by CT, but detected by MR (T2, FLAIR)

SELECTED REFERENCES

1. Bilgrami M et al: Neurologic diseases in HIV-infected patients. Handb Clin Neurol. 121:1321-44, 2014
2. Clifford DB et al: HIV-associated neurocognitive disorder. Lancet Infect Dis. 13(11):976-86, 2013
3. Risacher SL et al: Neuroimaging biomarkers of neurodegenerative diseases and dementia. Semin Neurol. 33(4):386-416, 2013

https://CafePezeshki.IR

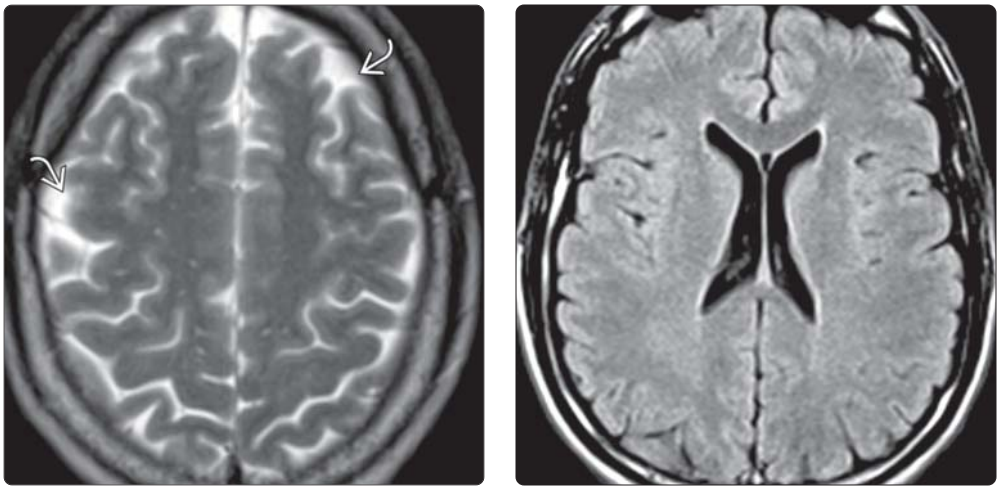

(Left) *Axial T2WI MR in an HIV-positive patient with early signs of subcortical dementia shows a variant appearance. Atrophy is obvious near the vertex with an increase in the CSF spaces around the brain ⇨. HIV encephalitis most commonly presents on imaging as diffuse "hazy" white matter abnormality in association with atrophy. However, occasionally atrophy may be the dominant feature, as in this case.* **(Right)** *FLAIR MR in the same patient reveals mild atrophy without significant white matter disease.*

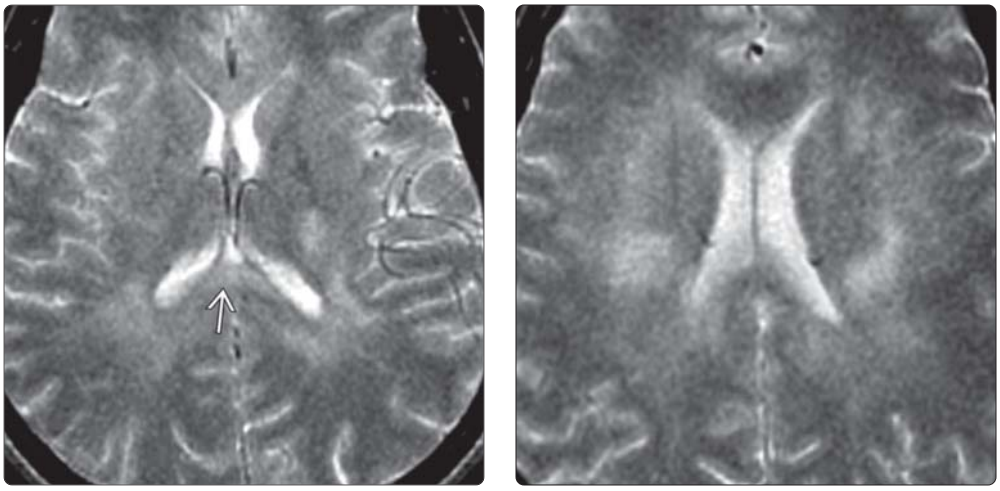

(Left) *White matter changes may appear in the brains of HIV/AIDS patients before atrophy and dementia ensue, as happened in this 34-year-old HIV-positive man with headaches. The ventricles appear normal, but bilateral "hazy" white matter hyperintensity is present, including abnormality in the corpus callosum ⇨.* **(Right)** *Axial T2WI MR in the same patient shows ill-defined, multifocal, bilateral, asymmetric, "hazy," hyperintense white matter signal intensity.*

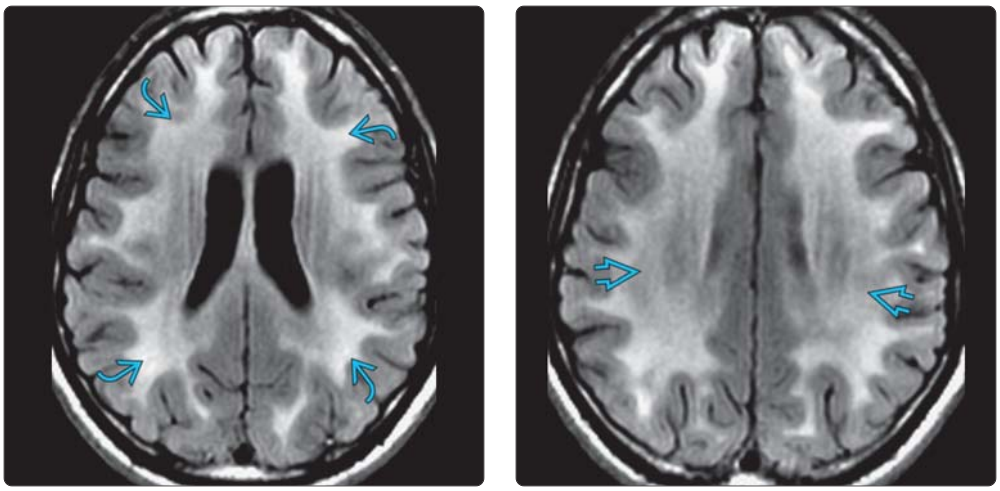

(Left) *Axial FLAIR MR in a 25-year-old HIV-positive man who presented with cognitive and behavioral abnormalities demonstrates extensive confluent relatively symmetric white matter hyperintensities ⇨ and mild atrophy.* **(Right)** *Axial FLAIR MR in the same patient shows similar diffuse white matter hyperintensities ⇨. Findings are typical for HIV encephalitis, which does not result in mass effect or enhancement. If either if these findings are present, another diagnosis must be considered.*

https://CafePezeshki.IR

KEY FACTS

TERMINOLOGY

- Opportunistic infection
  - Caused by parasite *Toxoplasma gondii*
  - Most common opportunistic CNS infection in AIDS patients

IMAGING

- CT
  - Ill-defined, hypodense lesions + edema
  - Basal ganglia, corticomedullary junction, thalamus, cerebellum
  - Rim, nodular, target enhancement
- MR
  - T2 hypointense
  - T1 C+ target sign highly suggestive
- Thallium-201 SPECT and 18F-FDG PET: Toxoplasmosis lesions are hypometabolic

TOP DIFFERENTIAL DIAGNOSES

- Lymphoma
  - Solitary mass in patient with HIV/AIDS?
    - Lymphoma > toxoplasmosis
- Other opportunistic infections
  - Cryptococcosis, PML (usually does not enhance)

PATHOLOGY

- 20-70% of USA population seropositive for *T. gondii*
  - Usually reactivation of latent infection

CLINICAL ISSUES

- Fever, malaise, headache

DIAGNOSTIC CHECKLIST

- Multiple target lesions on T1WI C+ that are dark on T2WI?
  - Consider TE
- TE lesions usually resolve in 2-4 weeks

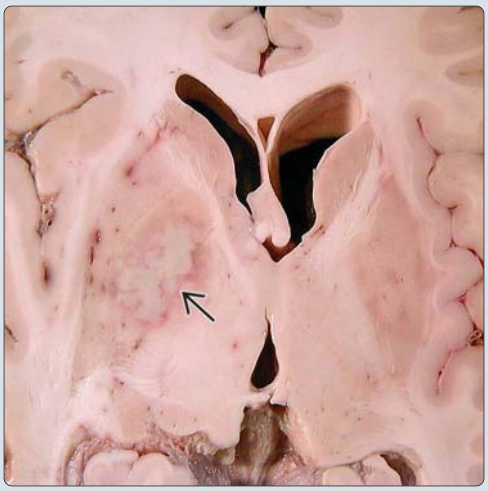

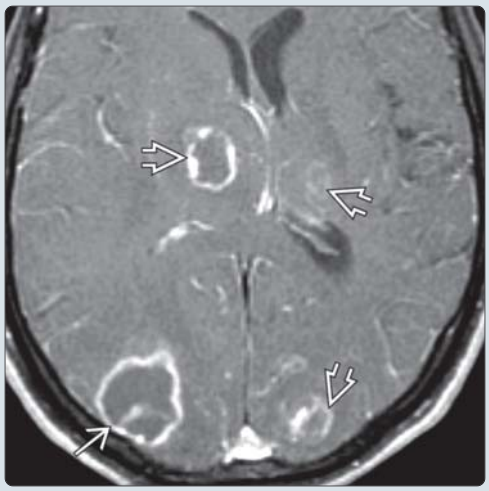

(Left) *Axial gross pathology specimen sectioned through the ventricles in a patient with HIV/AIDS shows a toxoplasmosis abscess in the right lentiform nucleus. The lesion is necrotic and poorly demarcated. (Courtesy R. Hewlett, MD.)* **(Right)** *Axial T1WI C+ MR shows several ring-enhancing lesions in the thalami and left occipital lobe. Note the large lesion showing a classic target appearance. These lesions were hypointense on T2WI.*

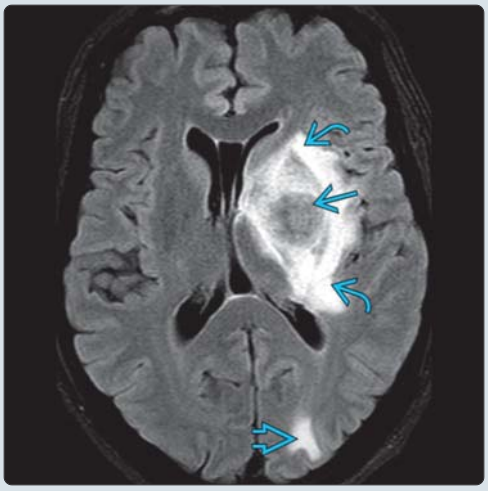

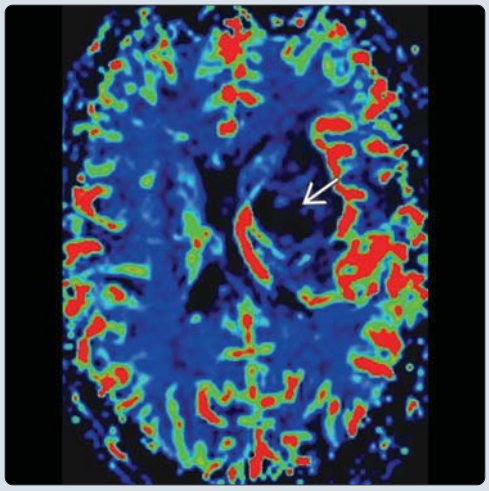

(Left) *Axial FLAIR MR in patient with HIV demonstrates a large, hypointense lesion in the left basal ganglia with extensive surrounding edema. Another smaller lesion is seen in the left occipital region. The left basal ganglia lesion showed rim and "target" enhancement on T1WI C+ MR. The most important differential consideration is toxoplasmosis vs. lymphoma.* **(Right)** *Axial CBV map from MR perfusion demonstrates low rCBV suggesting an infection (toxoplasmosis) rather than lymphoma.*

https://CafePezeshki.IR

TERMINOLOGY

Abbreviations

- Toxoplasmosis encephalitis (TE)

Definitions

- Opportunistic parasitic infection caused by *Toxoplasma gondii*
  - Most common opportunistic CNS infection in patients with AIDS

IMAGING

General Features

- Best diagnostic clue
  - T2-hypointense lesion with peripheral nodular enhancement
- Location
  - Basal ganglia, corticomedullary junction, thalamus, cerebellum most common sites
- Size
  - Variable but generally 2-3 cm in diameter
- Morphology
  - Round or oval

Imaging Recommendations

- Best imaging tool
  - MR for sensitivity; thallium-201-SPECT for specificity
- Protocol advice
  - MR with T2WI, FLAIR, T1 C+ plus DWI, MRS

CT Findings

- NECT
  - Ill-defined, hypodense lesions with edema
- CECT
  - Multiple rim-/nodular-enhancing masses

MR Findings

- T1WI
  - Ill-defined, hypointense lesions
  - Occasionally lesions are hyperintense
    - Not due to hemorrhage or calcification
    - May be coagulative necrosis/proteins
- T2WI
  - Hypointense + hyperintense peripheral edema
  - Edema is often disproportionately larger relative to lesion size
- FLAIR
  - May see target sign
- DWI
  - Increased diffusivity in necrotic centers
- PWI
  - Extremely hypovascular
- T1WI C+
  - Rim, nodular, punctate enhancement
  - Target sign highly suggestive of TE
    - Enhancing nodule within enhancing rim
- MRS
  - Prominent lipid & lactate peaks

Nuclear Medicine Findings

- Thallium-201 SPECT and 18F-FDG PET: Toxoplasmosis lesions are hypometabolic

DIFFERENTIAL DIAGNOSIS

Lymphoma

- Solitary mass in patient with HIV/AIDS?
  - Lymphoma > toxoplasmosis

Other Opportunistic Infections

- Cryptococcosis, PML (usually does not enhance)

PATHOLOGY

General Features

- Etiology
  - 20-70% of USA population seropositive for *T. gondii*
    - Usually reactivation of latent infection
  - Definitive host = cat
    - Any mammal can be carrier (intermediate host)
      - Transmitted to humans primarily by ingestion of cysts

Microscopic Features

- 3 distinct zones in parenchymal toxoplasma lesions
  - Central avascular zone reflecting coagulative necrosis
  - Intermediate zone engorged with blood vessels containing tachyzoites (corresponds to enhancing ring)
  - Peripheral zone with more encysted bradyzoites (corresponds to edema on imaging)

CLINICAL ISSUES

Presentation

- Most common signs/symptoms
  - Fever, malaise, headache

Demographics

- Epidemiology
  - CNS TE occurs in 3-10% of AIDS patients in USA
    - 35-50% of AIDS patients in Europe and Africa
  - More common when CD4(+) counts are < 200 cells/μL

Treatment

- Pyrimethamine plus sulfadiazine; trimethoprim sulfamethoxazole is acceptable alternative
- TE lesions usually resolve in 2-4 weeks; lack of resolution suggests another etiology

DIAGNOSTIC CHECKLIST

Image Interpretation Pearls

- Multiple target lesions on T1WI C+; dark on T2WI

Reporting Tips

- Know whether therapy has been administered; if poor response, suggest alternative diagnosis

SELECTED REFERENCES

1. Ho EL et al: Central nervous system diseases due to opportunistic and coinfections. Semin Neurol. 34(1):61-9, 2014

https://CafePezeshki.IR

KEY FACTS

TERMINOLOGY

- Acquired CNS cytomegalovirus infections: Meningitis, encephalitis, ventriculitis, transverse myelitis, radiculomyelitis, chorioretinitis
- Immunocompromised (AIDS, organ transplant) patients are at risk → reactivation of previously silent infection

IMAGING

- Best diagnostic clue: Ventriculitis with fluid-debris level and ependymal enhancement in an immunocompromised patient
- Encephalitis: Ill-defined T2-hyperintense area, variable enhancement
- May mimic HIV encephalitis with patchy nonspecific T2-hyperintense lesions
- Contrast should be used for imaging of all immunocompromised patients

TOP DIFFERENTIAL DIAGNOSES

- HIV encephalitis
- PML
- Toxoplasmosis
- ADEM

CLINICAL ISSUES

- Primary CMV infection is generally asymptomatic
- Infection may occur 2° to reactivation of latent viral infection or newly acquired via organ or bone marrow transplant from seropositive donor
  - CMV disseminates to CNS in late stages of HIV infection, low CD4(+) count
  - Clinically may mimic HIV encephalitis
- Disease manifestations vary in severity depending on degree of host immunosuppression
- HAART: Markedly ↓ incidence of CMV disease in AIDS; ↑ immunocompetence against CMV

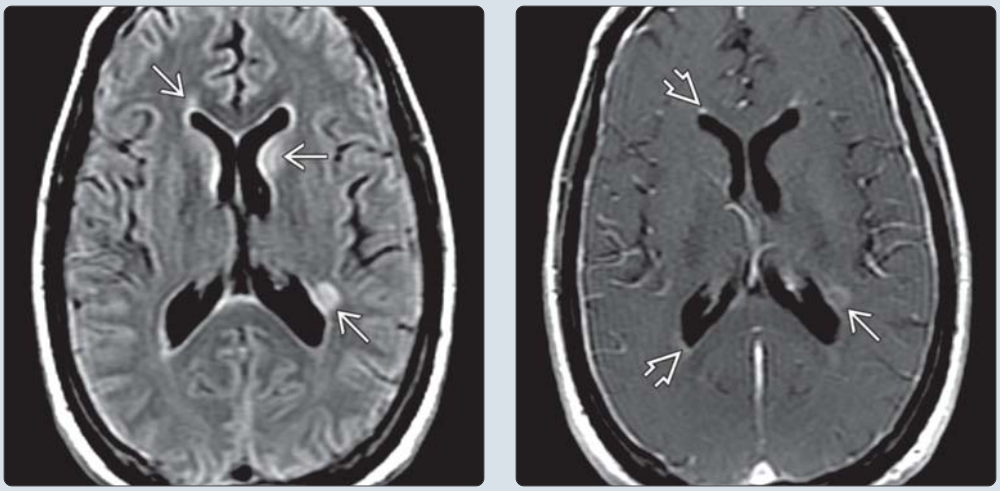

(Left) *Axial FLAIR MR shows mild ventriculomegaly and periventricular hyperintensities related to ventriculo-encephalitis.* **(Right)** *Axial T1WI C+ MR in the same patient shows ependymal and periventricular enhancement. This patient was immunocompromised, with ventriculitis and associated encephalitis. CMV encephalitis is commonly a ventriculo-encephalitis, involving the periventricular white matter. However, CMV may also cause hemorrhagic or necrotic lesions.*

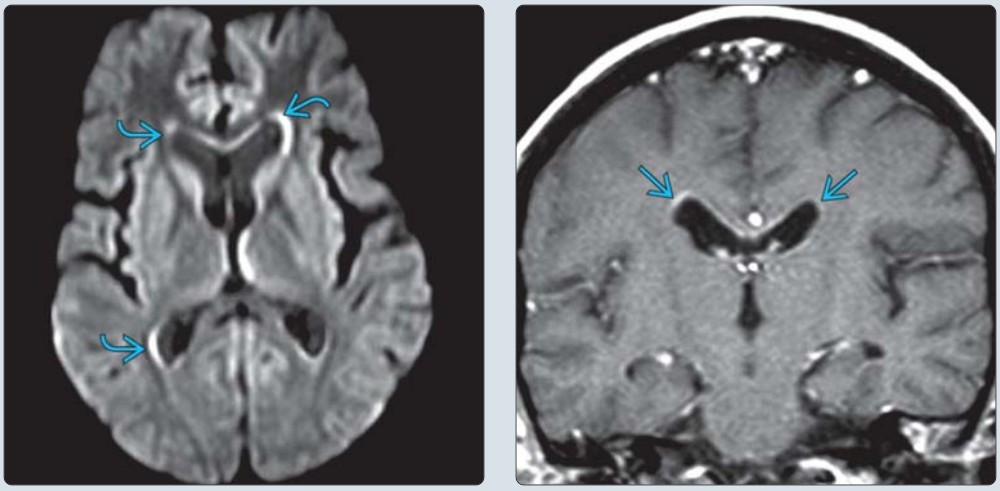

(Left) *Axial DWI MR in a 35-year-old HIV-positive patient with very low CD4(+) cell count demonstrates thin hyperintense rim along the ventricular margins. There is mild enlargement of the ventricles and mild cortical atrophy.* **(Right)** *Coronal T1WI C+ MR in the same patient shows subtle ependymal enhancement along the frontal horns. Imaging findings are characteristic of CMV ventriculitis.*

https://CafePezeshki.IR

TERMINOLOGY

Abbreviations

- Cytomegalovirus (CMV) infection

Definitions

- Acquired CNS infections: Meningitis, encephalitis, ventriculitis, retinitis, polyradiculopathy, myelitis
- Primary CMV infection: Generally asymptomatic in healthy adults
- Immunocompromised (AIDS, organ transplant) patients at risk → reactivation of previously silent infection

IMAGING

General Features

- Best diagnostic clue
  - Ventriculitis in immunocompromised patient
    - Enlarged ventricles with ependymal enhancement
  - Absent periventricular Ca++ (seen in congenital CMV)
  - Encephalitis may occur, commonly deep periventricular white matter
- Location
  - Ventricles (ependymal and subependymal)
  - Periventricular white matter (WM)
- Morphology: Encephalitis may cause "mass" lesion

Imaging Recommendations

- Best imaging tool: MR with contrast

MR Findings

- T1WI
  - Encephalitis: Ill-defined hypointense area
  - Ventriculitis: Enlarged ventricles with debris level
- T2WI
  - Encephalitis: Ill-defined periventricular hyperintensity
  - Ventriculitis: Enlarged ventricles with surrounding hyperintensity
- FLAIR
  - Encephalitis: Ill-defined periventricular hyperintensity
  - Ventriculitis: Enlarged ventricles with surrounding hyperintensity
  - May cause nonspecific, multifocal, periventricular WM hyperintensity
- T1WI C+
  - Encephalitis: Typically no significant enhancement
    - May become necrotizing with enhancement
  - Ventriculitis: Ependymal and periventricular enhancement
- MRS: Necrotizing encephalitis may show ↑ Cho, ↑ Lac , ↓ NAA
- PWI: Lower rCBV than tumor

DIFFERENTIAL DIAGNOSIS

HIV Encephalitis

- Periventricular patchy WM T2 hyperintensity with atrophy; no enhancement

PML

- T2-hyperintense WM lesions involving subcortical U-fibers; often frontal/parietooccipital
- Subcortical U-fibers > periventricular WM > gray matter

Toxoplasmosis

- Multiple ring-enhancing lesions
- Deep gray nuclei and cerebral hemispheres

ADEM

- Patchy periventricular WM T2 hyperintensities with enhancement; 10-14 days after infection/vaccination

PATHOLOGY

General Features

- Etiology
  - Vast majority of adults are infected with CMV
  - Transmission of CMV chiefly via contact with infected secretions
  - CNS disease primarily in immunosuppressed host
    - Reaches brain hematogenously
- Associated abnormalities
  - HHV-6 reactivation associated with CMV infection in patients post liver transplant
  - JC virus may be transactivated by CMV

Microscopic Features

- Cytomegalic inclusion cell: Enlarged cells with intranuclear inclusions, histologic "owl's eyes"

CLINICAL ISSUES

Presentation

- Most common signs/symptoms
  - CMV encephalitis: Confusion, gait disturbance, cranial neuropathies, hyperreflexia

Demographics

- Epidemiology
  - Most children acquire CMV infection early in life, with adult seroprevalence approaching 100%
  - CMV disseminates to CNS in late stages of HIV infection, low CD4(+) count
  - Prior to advent of highly active antiretroviral therapy (HAART) for HIV, CMV retinitis was most common cause of blindness in AIDS (> 90%)

Natural History & Prognosis

- Primary infection is generally asymptomatic; acute febrile illness rare, termed CMV mononucleosis
- Infection may occur 2° to reactivation of latent viral infection or be newly acquired via organ or bone marrow transplant (BMT) from seropositive donor

Treatment

- Ganciclovir and other antiviral drugs for severe disease
- HAART: ↓ incidence of CMV disease in AIDS

SELECTED REFERENCES

1. Bilgrami M et al: Neurologic diseases in HIV-infected patients. Handb Clin Neurol. 121:1321-44, 2014

https://CafePezeshki.IR

KEY FACTS

TERMINOLOGY

- *Cryptococcus neoformans* infection
- Opportunistic fungal infection that typically affects HIV and other immunosuppressed patients
- Cryptococci spread along PVS to deep brain: Basal ganglia (BG), thalamus, brainstem, cerebellum, dentate nucleus, periventricular white matter (WM)

IMAGING

- Dilated perivascular spaces in deep gray nuclei of AIDS patient, often no enhancement
  - Degree of enhancement depends on cell-mediated immunity of host
- May see miliary or leptomeningeal enhancing nodules + gelatinous pseudocysts
- Cryptococcoma: Ring-like or solid enhancement
- Dilated PVS in AIDS patients → consider Cryptococcus infection
- 4 imaging patterns: Miliary enhancing parenchymal nodules, leptomeningeal-cisternal nodules, cryptococcoma, gelatinous pseudocysts

TOP DIFFERENTIAL DIAGNOSES

- Acquired toxoplasmosis
- Tuberculosis
- Primary CNS lymphoma

CLINICAL ISSUES

- CNS infection related to hematogenous dissemination from lungs
- Headache most common symptom
- Most common fungal infection in AIDS patients
- 3rd most common infection seen in AIDS patients (HIV > toxoplasmosis > crypto)
- Indian ink test: Highly specific
  - Antigen titers correspond to severity of illness

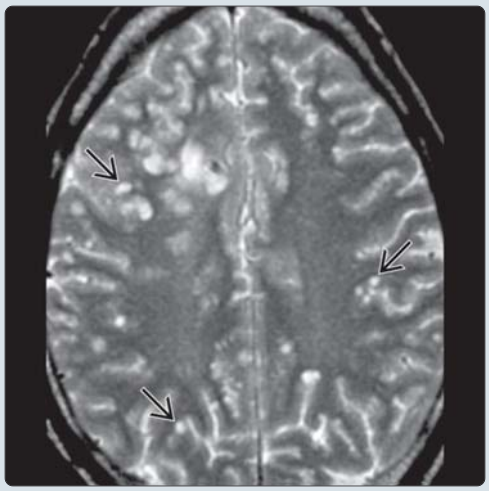

(Left) *Coronal graphic shows multiple dilated perivascular (Virchow-Robin) spaces ⇨, filled with fungi and mucoid material, resulting in gelatinous pseudocysts which are characteristic of cryptococcal infection in AIDS.* **(Right)** *Axial T2WI MR shows multiple dilated perivascular spaces ⇨ in this immunocompromised patient with cryptococcal meningitis. Gelatinous pseudocysts are most commonly located in the basal ganglia and thalami but may be seen in the brainstem, cerebellum, and cerebral hemispheres.*

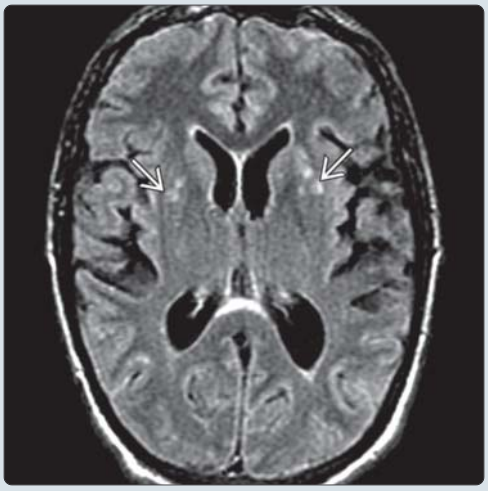

(Left) *Axial FLAIR MR shows bilateral dilated perivascular spaces ⇨ with hyperintense rims in this AIDS patient with Cryptococcus meningitis. Hydrocephalus is a common complication of this infection.* **(Right)** *Axial T1WI C+ MR in the same patient shows subependymal enhancement ⇨ along the frontal horns of the lateral ventricles as well as nodular leptomeningeal enhancement ⇨. Enhancement in Cryptococcus infection is dependent on the cell-mediated immunity of the host.*

https://CafePezeshki.IR

TERMINOLOGY

Definitions

- *Cryptococcus neoformans* infection
- Opportunistic fungal infection that typically affects HIV and other immunocompromised patients
- Pulmonary infection with subsequent transfer of circulating *Cryptococci* into subarachnoid spaces, perivascular spaces = leptomeningitis

IMAGING

General Features

- Best diagnostic clue
  - Dilated perivascular spaces in deep gray nuclei of AIDS patient, no enhancement
  - Degree of enhancement depends on cell-mediated immunity of host
    - Immunocompromised: Typically no enhancement
  - May see leptomeningeal, miliary enhancing nodules or cryptococcomas
- Location
  - Perivascular spaces (PVS)
  - Cryptococci spread along PVS to deep brain: Basal ganglia (BG), thalamus, brainstem, cerebellum, dentate nucleus, white matter (WM)
- Size: 2-3 mm nodules, up to 3-4 cm
- Morphology: Small round or oval-shaped lesions
  - May become confluent and form gelatinous pseudocysts or "soap bubbles"

Imaging Recommendations

- Best imaging tool: Contrast-enhanced MR

CT Findings

- CECT: Often normal
  - Subtle meningeal or miliary enhancement rare

MR Findings

- T2WI: PVS filled with fungi, isointense to CSF
- FLAIR: Multiple bilateral, small, cystic lesions
  - Follow CSF, may see small hyperintense rim
  - May form gelatinous pseudocysts
    - BG, thalamus, brainstem, cerebellum, periventricular and subcortical WM
  - Cryptococcoma: Hyperintense lesion
- T1 C+: Enhancement depends on host immune status
  - No enhancement is typical
  - May see leptomeningeal enhancement
  - Cryptococcoma: Ring-like or solid enhancement
  - Rare: Miliary or leptomeningeal enhancing nodules

DIFFERENTIAL DIAGNOSIS

Acquired Toxoplasmosis

- Multiple ring-enhancing masses + surrounding edema
- Typically BG and cerebral hemispheres

Tuberculosis

- Basal meningitis + parenchymal lesions (tuberculoma)
- Tuberculomas may be T2 hypointense

Primary CNS Lymphoma

- Enhancing lesion(s), often along ependymal surface
- T2-hypointense tumor

Neurosarcoid

- Leptomeningeal enhancement ± dural lesions

Enlarged Perivascular Spaces

- Typical locations, near anterior commissure
- Follow CSF on all MR sequences
- May be indistinguishable

PATHOLOGY

General Features

- Etiology
  - *Cryptococcus* is found in mammal and bird feces
  - In AIDS, CNS infection related to hematogenous dissemination from lungs

Gross Pathologic & Surgical Features

- Gelatinous mucoid material (pseudocysts) in or near prominent PVS in BG, midbrain, WM

Microscopic Features

- Large polysaccharide capsules stain with Indian ink

CLINICAL ISSUES

Presentation

- Most common signs/symptoms
  - Headache most common
- Other signs/symptoms
  - Seizure, blurred vision, focal neuro deficits (rare)
- Clinical profile
  - Lumbar puncture: ↑ CSF pressure, ↓ glucose, ↑ protein, mild to moderate leucocytosis
  - Indian ink test: Highly specific

Demographics

- Epidemiology
  - 3rd most common infection seen in AIDS patients (HIV > toxoplasmosis > crypto)
    - 10% of AIDS patients have Cryptococcus infection
    - Usually occurs when CD4 counts < 50-100 cells/μL
  - Cryptococcus meningitis > > > cryptococcoma

Treatment

- Antifungal treatment (i.e., amphotericin B)

DIAGNOSTIC CHECKLIST

Consider

- In AIDS patients with dilated PVS

SELECTED REFERENCES

1. Gottumukkala RV et al: Imaging of the brain in patients with human immunodeficiency virus infection. Top Magn Reson Imaging. 23(5):275-91, 2014
2. Starkey J et al: MRI of CNS fungal infections: review of aspergillosis to histoplasmosis and everything in between. Clin Neuroradiol. 24(3):217-30, 2014
3. Corti M et al: Magnetic resonance imaging findings in AIDS patients with central nervous system cryptococcosis. Rev Iberoam Micol. 25(4):211-4, 2008

https://CafePezeshki.IR

KEY FACTS

TERMINOLOGY

- Progressive multifocal leukoencephalopathy (PML)
- Subacute opportunistic infection caused by DNA virus JC polyomavirus (JCV)
- JC polyomavirus infects oligodendrocytes, causes demyelination in immunocompromised patients
- Associated with immunosuppression, often AIDS
  - Organ transplant, cancer, chemotherapy, myeloproliferative disease, and steroid treatment
  - Reported in treatment for multiple sclerosis (MS) and in rheumatic diseases

IMAGING

- Multifocal T2-hyperintense demyelinating plaques involve subcortical white matter (WM), extend to deep WM; gray matter often spared until late stage
- Characteristic involvement of **subcortical U-fibers**
- Generally no contrast enhancement or mass effect
- Late: Confluent WM disease, cystic changes
- Propensity for frontal and parietooccipital region, thalamus
  - May involve brainstem and cerebellum
- May be solitary, multifocal, or widespread confluent

TOP DIFFERENTIAL DIAGNOSES

- HIV encephalitis
- ADEM
- Acquired CMV
- Immune reconstitution inflammatory syndrome

CLINICAL ISSUES

- Without treatment poor prognosis, death in 2.5-4 months
- Highly active antiretrovirus therapy (HAART) reported to improve survival

DIAGNOSTIC CHECKLIST

- If multifocal subcortical white matter lesions without mass effect or enhancement in AIDS patients, consider PML over HIV encephalopathy

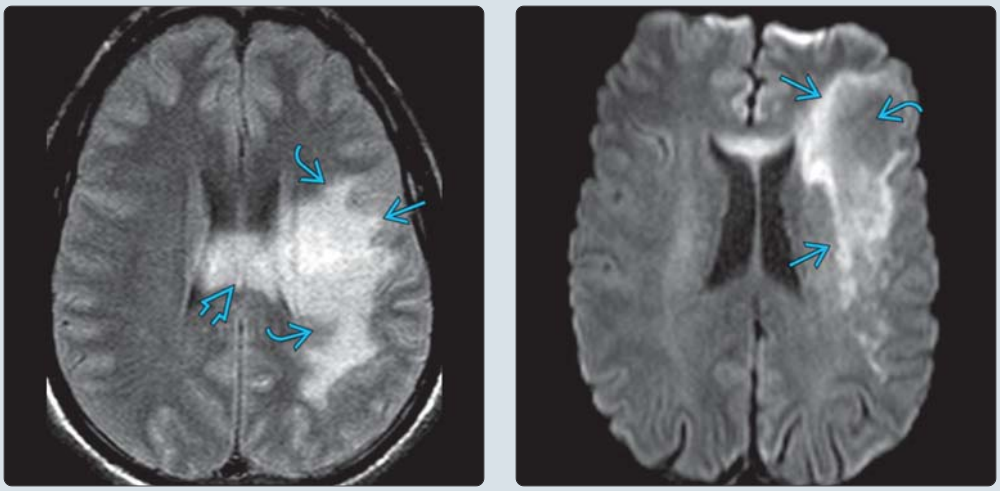

(Left) *Axial FLAIR MR in an AIDS patient who was somnolent at presentation shows scalloped hyperintensity in the left frontoparietal white matter. There is involvement of the subcortical U-fibers, characteristic of PML. Note involvement of the corpus callosum, but lack of mass effect.* **(Right)** *Axial DWI in an HIV patient with very low CD4(+) counts and PML demonstrates central core of low signal surrounded by rim of higher signal. Appearance of PML on DWI varies with disease stage.*

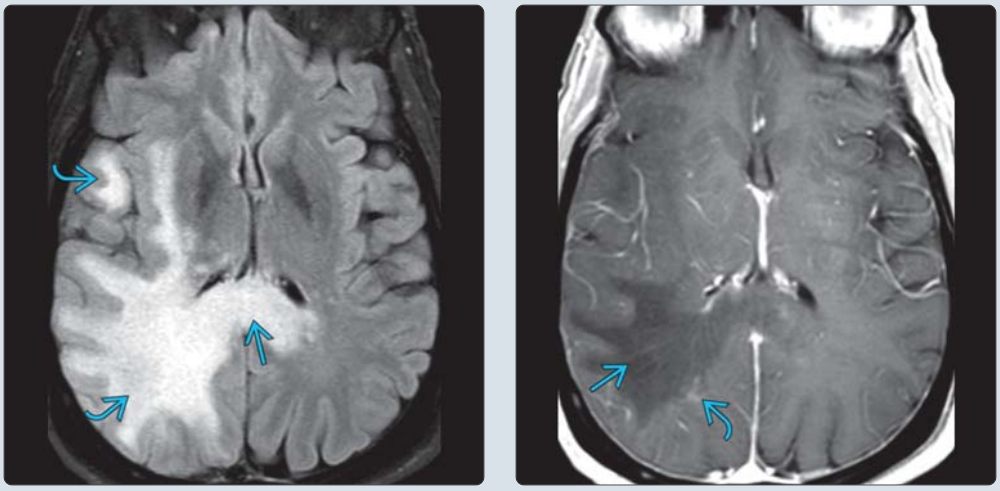

(Left) *Axial FLAIR MR in a patient with multiple sclerosis on natalizumab and developed PML demonstrates infiltrating hyperintensity involving the right temporal, parietal, and occipital white matter as well as the splenium.* **(Right)** *Axial T1C+ MR in the same patient shows white matter hypointensity with very faint enhancement at the margins. Monoclonal antibody therapy (like natalizumab) used in a wide spectrum of immunologic diseases may depress the immune system and predispose the patient to PML.*

https://CafePezeshki.IR

TERMINOLOGY

Abbreviations

- Progressive multifocal leukoencephalopathy (PML)

Definitions

- Subacute opportunistic infection caused by DNA virus JC polyomavirus (JCV)

IMAGING

General Features

- Best diagnostic clue
  - T2-hyperintense, multifocal, demyelinating plaques involve subcortical white matter (WM), extend to deep WM; gray matter often spared until late stage
  - Typically bilateral, but asymmetric; no mass effect or contrast enhancement
  - Late stage: Confluent WM lesions with cavitary changes
- Location
  - Propensity for parietooccipital region, thalamus
  - Cerebellum & brainstem may be involved
- Size
  - Variable, small subcortical lesions to confluent hemispheric lesions
- Morphology
  - May be solitary, multifocal, or widespread hemispheric WM lesions

Imaging Recommendations

- Best imaging tool
  - MR with contrast

MR Findings

- T1WI: Hypointense lesions → aggressive forms and burnt out PML lesions
- T2WI: Hyperintensity predominantly in subcortical and periventricular WM
  - Involves **subcortical U-fibers** → **scalloped** appearance
- FLAIR: Hyperintensity in subcortical and periventricular WM
- DWI: Newer lesion has slightly restricted diffusion along its margins; older lesion is unrestricted
- T1WI C+: Typically no enhancement
  - Faint peripheral enhancement may rarely be seen, typically in patients with long-term survival
  - Increasing enhancement, mass effect & edema attributable to immune reconstitution
- MRS: ↓ NAA; ↑ lactate, Cho, lipids
- Magnetization transfer: ↓ ratio compared to HIV encephalitis

DIFFERENTIAL DIAGNOSIS

HIV Encephalitis

- Atrophy and symmetric periventricular or diffuse WM disease; affects subinsular and peritrigonal WM

Acquired CMV

- May see ventriculitis, encephalitis, retinitis, or polyradiculopathy

Immune Reconstitution Inflammatory Syndrome (IRIS)

- Most often associated with PML (JC virus)

ADEM

- Post-infection/vaccination immune-mediated inflammatory demyelination

PATHOLOGY

General Features

- Etiology
  - By age 65 years, 50-70% of individuals have antibodies to JCV
  - Hematogenous spread of virus from periphery or reactivation of latent brain lesion
  - PML destroys oligodendrocytes

Gross Pathologic & Surgical Features

- Multiple confluent foci of grayish discoloration in white matter or gray-white junction

Microscopic Features

- Demyelination, oligodendroglia with large basophilic inclusion
- Bizarre reactive astrocytes with hyperchromatic nuclei resembling neoplastic cells

CLINICAL ISSUES

Presentation

- Most common signs/symptoms
  - Altered mental status, progressive neurological symptoms, headache, lethargy

Demographics

- Epidemiology
  - AIDS, organ transplantation, cancer patients undergoing chemotherapy
  - Reported in multiple sclerosis patients treated with α-integrin inhibitor (natalizumab) and in patients with rheumatic diseases

Natural History & Prognosis

- Without treatment poor prognosis, death in 2.5-4 months

Treatment

- Highly active antiretrovirus therapy (HAART) reported to improve survival

DIAGNOSTIC CHECKLIST

Image Interpretation Pearls

- If multifocal subcortical WM lesions without mass effect or enhancement in AIDS patients, consider PML over HIV encephalitis

SELECTED REFERENCES

1. Berger JR: Progressive multifocal leukoencephalopathy. Handb Clin Neurol. 123:357-76, 2014
2. Wattjes MP et al: MRI pattern in asymptomatic natalizumab-associated PML. J Neurol Neurosurg Psychiatry. ePub, 2014

https://CafePezeshki.IR

KEY FACTS

TERMINOLOGY

- Immune reconstitution inflammatory syndrome (IRIS)
  - Atypical/worsening opportunistic infection
  - HIV/AIDS patients following commencement of HAART
  - Patients with MS, immunomodulatory therapy

IMAGING

- PML-IRIS
  - WM hypodensities with ↑ mass
  - Patchy atypical enhancement
- TB-IRIS
  - ↑ leptomeningeal enhancement
  - ↑ size of ring-/nodular-enhancing tuberculomas
- Crypto-IRIS
  - ↑ nodular meningeal/subependymal enhancement
  - ↑ in size of "gelatinous" pseudocysts

TOP DIFFERENTIAL DIAGNOSES

- Diffuse/patchy WM abnormalities in AIDS
  - HIV encephalitis, PML, CMV infection
- Focal/multifocal brain lesions in AIDS
  - Lymphoma, toxo, tuberculoma, cryptococcosis

PATHOLOGY

- Reconstitution of immunity → abnormal immune response to infectious/noninfectious antigens
- IRIS is **not** caused by relapse/recurrence of preexisting disease

CLINICAL ISSUES

- 1/4 to 1/3 HIV-infected patients develop IRIS
- PML, TB common IRIS-associated pathogens

DIAGNOSTIC CHECKLIST

- IRIS if worsening/enhancing lesions in
  - HIV patient who recently started HAART
  - MS patient on immunomodulatory therapy

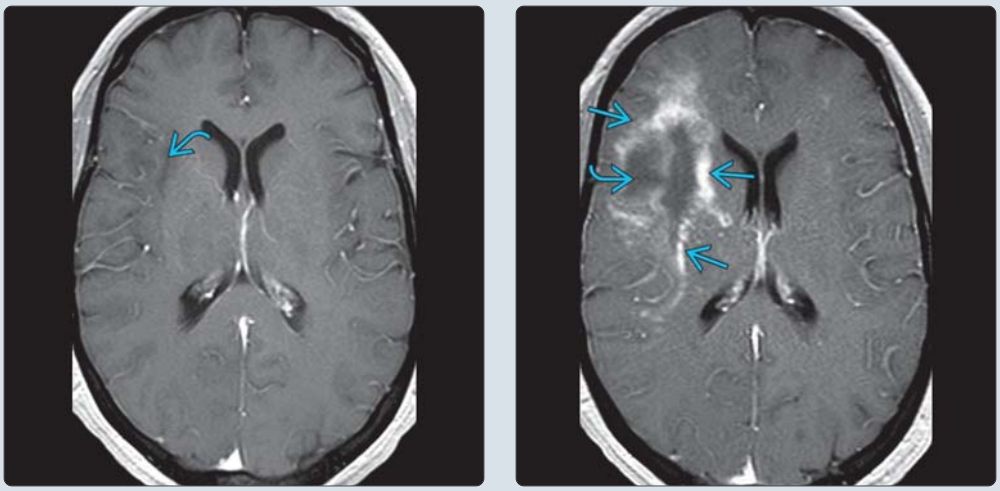

(Left) *Axial T1WI C+ MR in a patient with HIV and PML shows subtle hypodensity in the right insular region without any abnormal enhancement. FLAIR images (not shown) demonstrated multifocal confluent white matter hyperintensities.* **(Right)** *Axial T1 C+ MR in the same patient after initiation of HAART therapy and significant clinical deterioration shows patchy nodular and linear foci of enhancement as well as worsening of the underlying hypodensity. Finding are typical for PML with IRIS.*

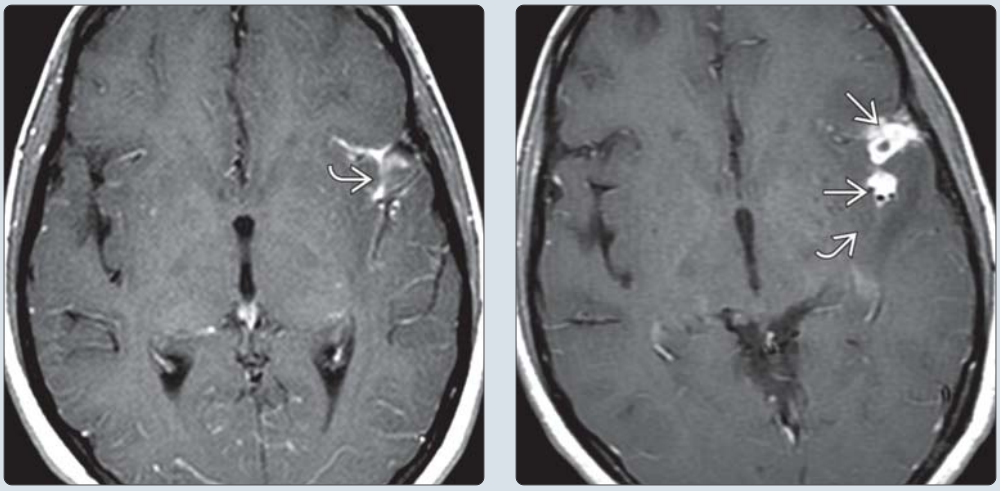

(Left) *Axial T1WI C+ MR demonstrates meningeal enhancement in the left sylvian fissure in an HIV-positive patient with tuberculous meningitis.* **(Right)** *Axial T1WI C+ MR shows worsening of imaging appearance after placement on HAART. There is an increase in enhancement, which appears more nodular, and there is development of surrounding edema. This worsening of disease could be due to drug resistance; however, the time course after starting HAART makes IRIS most likely.*

https://CafePezeshki.IR

TERMINOLOGY

Abbreviations

- Immune reconstitution inflammatory syndrome (IRIS)

Synonyms

- Immune restoration disease (IRD)
- Immune restitution syndrome (IRS)

Definitions

- Paradoxical worsening of opportunistic infection
  - After starting highly active antiretroviral therapy (HAART)
  - Patients with MS, immunomodulatory therapy

IMAGING

General Features

- Best diagnostic clue
  - Atypical/worsening imaging appearance of infection in HIV/AIDS following commencement of HAART
  - Other: Patient on immunomodulation therapy
    - MS with monoclonal antibody therapy
- Location
  - PML: Frontal/parietooccipital lobes most common
    - Less common: Posterior fossa
  - TB: Meninges, brain parenchyma
  - Cryptococcosis: Virchow-Robin spaces (VRSs), meninges

CT Findings

- NECT
  - PML-IRIS: White matter (WM) hypodensities with ↑ mass effect
- CECT
  - PML-IRIS: Atypical heterogeneous enhancement
  - TB-IRIS: Increased size of tuberculomas

MR Findings

- T1WI
  - PML-IRIS: Hypointense lesions become confluent
- T2WI
  - PML-IRIS: Hyperintense WM lesions ↑
    - Enlarge, become confluent, exert mass effect
  - TB-IRIS: ↑ edema around tuberculomas
- T1WI C+
  - PML-IRIS: Patchy atypical enhancement
  - TB-IRIS: ↑ pial enhancement
    - ↑ size of ring-/nodular-enhancing tuberculomas
  - Crypto-IRIS: ↑ nodular meningeal/subependymal enhancement, ↑ in size of "gelatinous" pseudocysts

Imaging Recommendations

- Best imaging tool
  - MR with T1 C+, T2WI, FLAIR

DIFFERENTIAL DIAGNOSIS

Diffuse/Patchy WM Abnormalities in AIDS

- HIV encephalitis, PML, CMV infection

Focal/Multifocal Brain Lesions in AIDS

- Lymphoma, toxo, TB, cryptococcosis

PATHOLOGY

General Features

- Etiology
  - Reconstitution of immunity → heightened but dysregulated immune response to infectious/noninfectious antigens
  - IRIS is **not** caused by relapse/recurrence of preexisting disease
  - Paradoxical clinical deterioration as CD4 counts ↑, viral load ↓
  - Typical in 1st 2-12 weeks after starting HAART
  - Unmasking of preexisting disease can occur
  - Pathogens: TB, CMV, crypto, JC virus (PML), and others
  - Can occur in non-HIV immunocompromised
    - MS patient on monoclonal antibody therapy

Gross Pathologic & Surgical Features

- PML-IRIS: Multifocal discoloration of WM
- TB-IRIS: Granulomas, basal exudates

Microscopic Features

- ↑ CD8(+) T cells: Parenchymal, leptomeningeal and perivascular lymphocytic inflammatory infiltrates

CLINICAL ISSUES

Presentation

- Most common signs/symptoms
  - PML-IRIS: Headache, visual disturbance, dementia
  - TB-IRIS: Fever, lymphadenopathy, seizures

Demographics

- Epidemiology
  - IRIS risk factor at HAART initiation
    - Lower CD4 cell count/cell %, ↓ CD4:CD8 ratio
    - Higher HIV RNA
  - TB common reported copathogen associated with IRIS

Natural History & Prognosis

- May progress to death in severe cases

Treatment

- Continue primary therapy for opportunistic infection
- Continue HAART + anti-inflammatory agents

DIAGNOSTIC CHECKLIST

Consider

- HIV patient who recently started HAART + worsening/unmasking of preexisting opportunist infection

SELECTED REFERENCES

1. Post MJ et al: CNS-immune reconstitution inflammatory syndrome in the setting of HIV infection, part 1: Overview and discussion of progressive multifocal leukoencephalopathy-immune reconstitution inflammatory syndrome and cryptococcal-immune reconstitution inflammatory syndrome. AJNR Am J Neuroradiol. Epub ahead of print, 2012
2. Post MJ et al: CNS-immune reconstitution inflammatory syndrome in the setting of HIV infection, part 2: Discussion of neuro-immune reconstitution inflammatory syndrome with and without other pathogens. AJNR Am J Neuroradiol. Epub ahead of print, 2012
3. Kranick SM et al: Neurologic complications of HIV-1 infection and its treatment in the era of antiretroviral therapy. Continuum (Minneap Minn). 18(6 Infectious Disease):1319-37, 2012

https://CafePezeshki.IR

KEY FACTS

TERMINOLOGY

- HIV/AIDS-related opportunistic infections and neoplasms

IMAGING

- Findings
  - Primary CNS lymphoma (PCNSL): Enhancing lesions, often hemorrhagic/necrotic within basal ganglia, periventricular WM
  - Kaposi sarcoma (KS): Intense enhancing soft tissue mass in scalp
  - Bacterial abscesses (BA): Ring-enhancing lesion with ↑ signal on DWI
  - Aspergillosis (As): Multiple ring-enhancing lesions
  - Neurosyphilis (NS): Cortical/subcortical infarcts, granulomas, leptomeningeal enhancement
  - Benign lymphoepithelial lesions of HIV (BLL-HIV): Multiple cystic masses enlarging both parotid glands
- MR is most sensitive
- PET or thallium-201 SPECT helpful to differentiate from toxoplasmosis
- Immune reconstitution inflammatory syndrome (IRIS): "Wild" looking enhancing lesion(s)

TOP DIFFERENTIAL DIAGNOSES

- Toxoplasmosis
- Metastases
- Tuberculosis

DIAGNOSTIC CHECKLIST

- Consider using DWI, MRS, PET/SPECT to differentiate opportunistic infections from malignant lesions
- Bacterial abscess, aspergillosis, neurosyphilis may need surgical biopsy for diagnosis

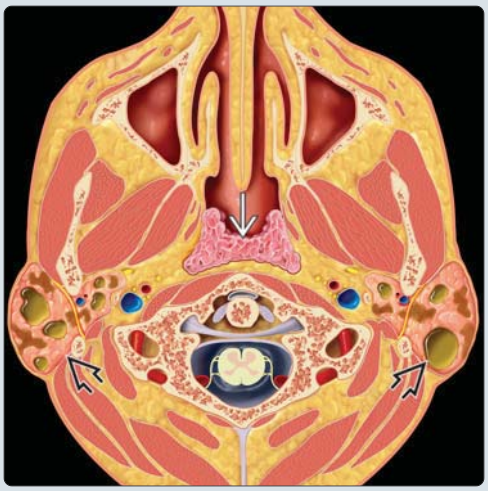

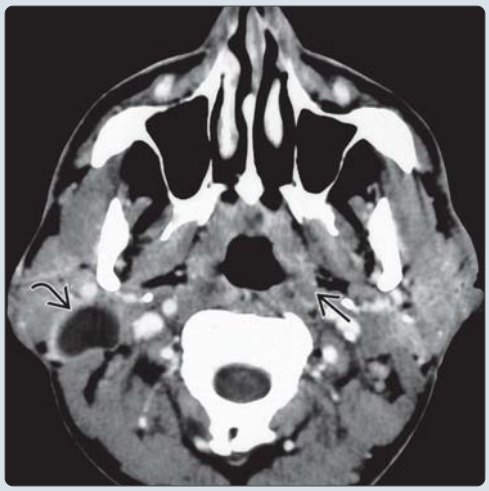

(Left) *Axial graphic shows typical lymphoid and lymphoepithelial lesions of HIV/AIDS. Note hyperplastic tonsils ➡ and multiple cysts in both parotid glands ⇨.* **(Right)** *Axial CECT scan in a 33-year-old man with HIV/AIDS shows a large right parotid cyst with enhancing rim ⇨ and enlarged Waldeyer ring ⇨.*

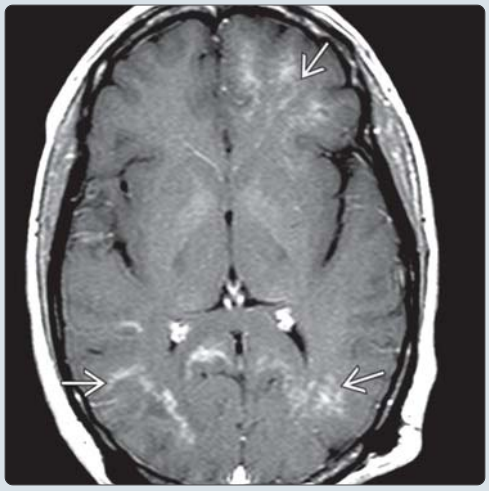

(Left) *T1 C+ scan in an HIV(+) man obtained prior to beginning HAART shows some nonenhancing periventricular hypointensities ➡.* **(Right)** *The patient deteriorated 3 weeks following institution of HAART. T1 C+ scan now shows extensive patchy enhancing lesions ➡. CSF was positive for JC virus in this case of PML-IRIS. (Courtesy T. Hutchins, MD.)*

https://CafePezeshki.IR

TERMINOLOGY

Definitions

- HIV/AIDS-related opportunistic infections, neoplasms

IMAGING

General Features

- Best diagnostic clue
  - Primary CNS lymphoma (PCNSL): Enhancing lesions, often hemorrhagic/necrotic within basal ganglia, periventricular white matter (WM)
  - Kaposi sarcoma (KS): Intense enhancing, soft tissue mass in scalp
  - Bacterial abscesses (BA): Ring-enhancing lesion with ↑ signal on DWI
  - Aspergillosis (As): Multiple ring-enhancing lesions
  - Neurosyphilis (NS): Cortical/subcortical infarcts, granulomas, leptomeningeal enhancement
  - Benign lymphoepithelial lesions of HIV (BLL-HIV): Multiple cystic masses enlarging both parotid glands
- Location
  - PCNSL: 90% supratentorial; deep gray nuclei, periventricular white matter commonly affected
  - KS: Face, scalp, and skin of neck
  - BA: Typically supratentorial, frontal, and parietal
  - As: Distribution of MCA, cortical/subcortical, basal ganglia/thalami perforating arteries
  - NS: Cortical/subcortical, meninges
  - BLL-HIV: Parotid glands
- Morphology
  - PCNSL: Solitary mass or multiple lesions
  - KS: Infiltrating soft tissue mass
  - BA: Smooth, ring-enhancing lesion
  - As: Multiple lesions, often in distribution of MCA

CT Findings

- NECT
  - PCNSL: Hypodense or hyperdense, ± hemorrhage, necrosis
  - KS: Soft tissue thickening in scalp, face
  - BA: Hypodense mass with edema and mass effect
  - As: Multiple cortical/subcortical, low-attenuation lesions; may be associated with hemorrhage
  - NS: Peripherally located lesions isointense to cortex
  - BLL-HIV: Multiple bilateral, well-circumscribed, cystic masses within enlarged parotid glands
- CECT
  - PCNSL: Ring enhancement in HIV patients
  - KS: Marked enhancing scalp soft tissue mass
  - BA: Thin ring enhancement
  - As: Multiple ring-enhancing lesions
    - Enhancement may be subtle or well defined related to immune status
  - NS: Enhancing cortical lesions ± dural thickening
  - BLL-HIV: Thin rim enhancement of cystic lesions

MR Findings

- T1WI
  - PCNSL: Iso-/hypointense to cortex
  - KS: Localized thickening scalp isointense to muscle
  - BA: Early poorly marginated hypo-/isointense mass, late hypointense center
  - As: Hypointense masses
    - Hemorrhage ↑ T1 signal
- T2WI
  - PCNSL: Iso-/hypointense to cortex, mild surrounding edema
    - May be heterogeneous due to hemorrhage, necrosis
  - KS: Scalp mass hyperintense to muscle
  - BA: Capsule with characteristic T2 hypointense rim
  - As: Heterogeneous if hemorrhage present
  - NS: Hyperintense cortical/subcortical lesions, infarcts
- DWI
  - PCNSL: Variable restricted diffusion
  - BA: ↑ signal DWI, low ADC
  - As: Restricted diffusion in wall of abscess
- T1WI C+
  - PCNSL: Peripheral enhancement with central necrosis more common in HIV patients than homogeneous enhancement
  - KS: Intensely enhancing soft tissue mass in scalp
  - BA: Early patchy enhancement, late capsule with well-defined, thin rim enhancement
  - As: Multiple ring-enhancing lesions
  - NS: Lesions enhance; overlying leptomeningeal/dural enhancement also seen
  - BLL-HIV: Well-defined, rim-enhancing, cystic lesions in parotid glands
  - Immune reconstitution inflammatory syndrome (IRIS): "Wild" looking enhancing lesion(s)
- MRS
  - PCNSL: ↓ NAA, ↑ choline
  - BA: Central necrotic area may show acetate, lactate, alanine, succinate, and amino acids

Imaging Recommendations

- Best imaging tool
  - MR is most sensitive
- Protocol advice
  - PCNSL: Contrast-enhanced MR
    - PET or Tl-201 SPECT helpful to differentiate from toxoplasmosis
  - BA: MR C+, DWI, MRS

Nuclear Medicine Findings

- PCNSL: FDG PET/Tl-201 SPECT hypermetabolic

DIFFERENTIAL DIAGNOSIS

Toxoplasmosis

- Enhancing lesions, "eccentric target" sign
- PET, SPECT helpful to differentiate from PCNSL

Metastases

- Multiple lesions common, significant vasogenic edema, primary tumor often known

Tuberculosis

- Ring/nodular enhancing lesions in cortex, gray-white junction; Ca++ in chronic cases

https://CafePezeshki.IR

PATHOLOGY

General Features

- Etiology
  - PCNSL: Typically diffuse, large B-cell non-Hodgkin lymphoma
    - Associated with CD4(+) counts < 100 cells/mm³
    - EBV plays major role in immunosuppressed
  - KS: Caused by herpesvirus HHV-8
    - Classified as AIDS-defining cancers (ADCs)
  - BA: *Staphylococcus* and *Streptococcus* most common causative organisms
  - As: *Aspergillus* species = hyaline septate molds
    - *Aspergillus fumigatus* most common agent
    - Hematogenous spread from pulmonary focus or direct extension via sinus
    - Infectious vasculopathy: Acute infarction, hemorrhage, infectious cerebritis/abscess
  - NS: Sexually transmitted disease results from infection with spirochete *Treponema pallidum*
  - IRIS: Restored immunity (a few weeks after HAART) → exaggerated immune response
    - JC virus most common pathogen (PML-IRIS)

Gross Pathologic & Surgical Features

- PCNSL: Single multiple masses in cerebral hemispheres, central necrosis/hemorrhage in HIV
- BA: Depends on stage; necrotic foci, rim of inflammatory cells, granulation tissue, surrounding vasogenic edema
- As: Hemorrhagic infarcts with variable inflammation
- NS: Syphilitic gummas; well-circumscribed necrotic masses of granulation tissue (avascular)

Microscopic Features

- PCNSL: Small, noncleaved, and large immunoblastic type
  - High nuclear to cytoplasmic ratio
  - Angiocentric: Surrounds, infiltrates vessels and perivascular spaces
- KS: Diffuse positivity for vimentin; pedunculated, ulcerated, or both
- BA: Granulation tissue about necrotic core
- As: Septate hyphae branch at acute angles
  - Invade blood vessels, spread along internal elastica and lamina
- NS: Leptomeningitis, multifocal arteritis
  - Cerebral gummas; infiltration of meninges and brain by lymphocytes and plasma cells

CLINICAL ISSUES

Presentation

- Most common signs/symptoms
  - PCNSL: Lethargy, confusion, headache, seizures, focal weakness
  - KS: Usually asymptomatic; symptoms may appear when lesions ulcerate or produce local mass effect
  - BA: Headache most common symptom
    - Seizures, focal neurologic deficits
  - As: Seizures, altered mental status, focal deficits
  - NS: Often asymptomatic
    - Headaches, seizures, personality changes, confusion
  - BLL-HIV: Bilateral parotid space masses
- Clinical profile
  - PCNSL: CD4(+) < 100 cells/mm³
    - CSF: Pleocytosis, ↑ proteins, cytology (+) for monoclonal, malignant-appearing lymphocytes
    - PCR amplification of EBV DNA in CSF
  - KS: Low CD4 count (i.e., < 150–200 cells/mm³)
  - NS: CSF ↑ WBC count, reactive CSF VDRL &/or positive CSF *T. pallidum* antibody index

Demographics

- Epidemiology
  - PCNSL: 2nd most common mass lesion after toxoplasmosis in patients with AIDS
    - 2-6% of AIDS patients
  - KS: Prevalence of AIDS-related KS has ↓, presumably due to use of HAART
  - BA: Relatively uncommon in AIDS patients
  - NS: Affects approximately 1.5% of AIDS population
  - BLL-HIV: 5% of HIV(+) patients
  - IRIS: 25-35% of HIV(+) patients beginning HAART

Treatment

- PCNSL: Definitive diagnosis requires stereotactic brain biopsy
  - HAART with radiation
- KS: Radiotherapy is primary therapy
- BA: Surgical drainage, antibiotics
- As: Surgery, antifungals
- NS: Penicillin ± steroids
- BLL-HIV: HAART therapy tends to completely or partially treat

DIAGNOSTIC CHECKLIST

Consider

- Consider using DWI, MRS, PET/SPECT to differentiate opportunistic infections from malignant lesions

Image Interpretation Pearls

- In HIV patients, difficult to differentiate between PCNSL and toxoplasmosis
  - PET/SPECT studies may be helpful
- Bacterial abscess, aspergillosis, neurosyphilis may need surgical biopsy for diagnosis

SELECTED REFERENCES

1. Bilgrami M et al: Neurologic diseases in HIV-infected patients. Handb Clin Neurol. 121:1321-44, 2014
2. Gobert A et al: [HIV-related malignancies: state of art.] Bull Cancer. 101(11):1020-9, 2014
3. Rios A: HIV-related hematological malignancies: a concise review. Clin Lymphoma Myeloma Leuk. 14 Suppl:S96-103, 2014

https://CafePezeshki.IR

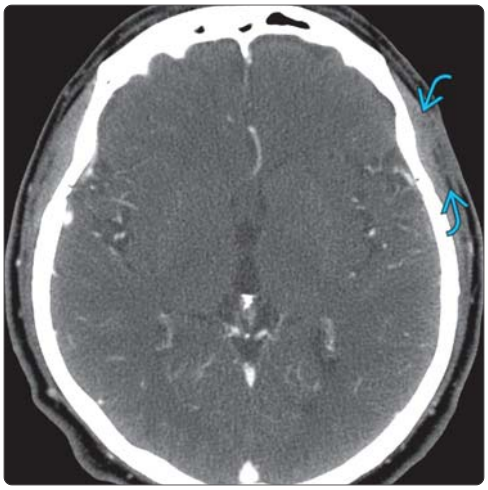

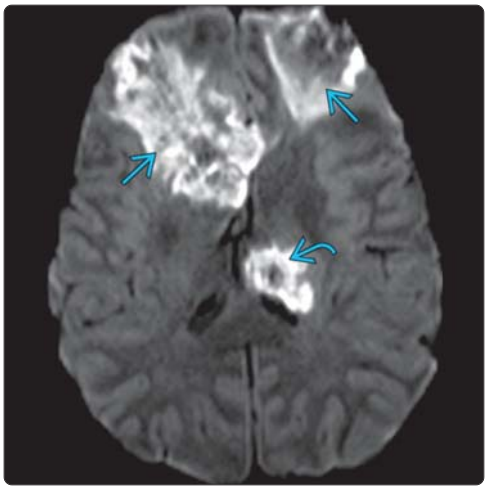

(Left) *Axial CECT in an HIV positive patient with scalp swelling shows an infiltrating soft tissue mass with adjacent skin thickening in the left frontal scalp. On biopsy this was a Kaposi sarcoma. Kaposi sarcoma is classified as AIDS-defining cancers (ADCs).* **(Right)** *Axial DWI MR in an HIV-positive patient who presented with altered sensorium and seizures demonstrates large areas of restricted diffusion in the frontal lobes and left thalamus.*

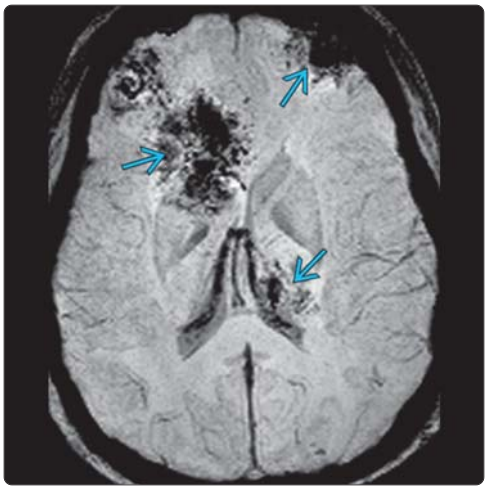

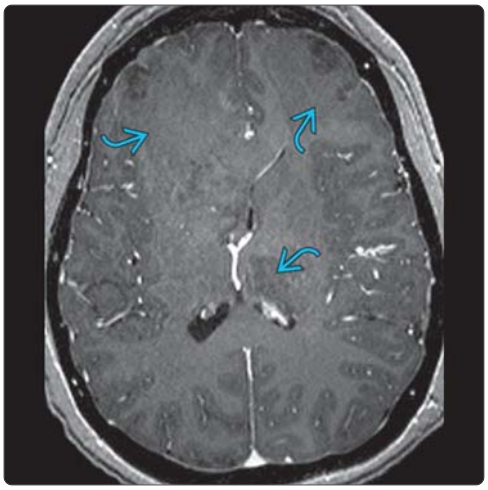

(Left) *Axial SWI image in the same patient shows areas of hemorrhage in the regions of diffusion abnormality.* **(Right)** *Axial T1+C MR in the same patient does not demonstrates any abnormal enhancement in the frontal lobes or left thalamus. Biopsy of the right frontal lobe lesion revealed invasive aspergillosis. Aspergillus infections leads to an infectious vasculopathy resulting in acute infarction, hemorrhage, and cerebritis/abscess.*

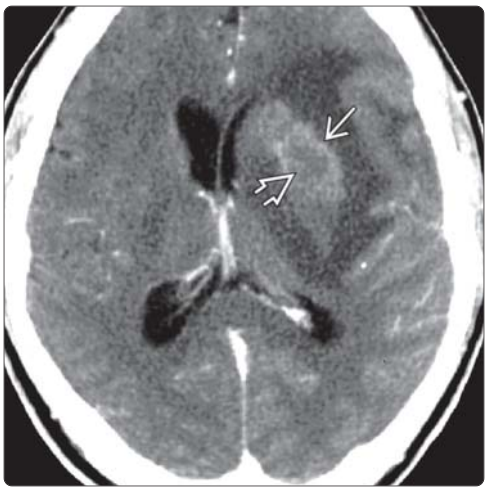

(Left) *CECT in an HIV(+) patient with a solitary basal ganglia mass shows some poorly defined enhancement around a necrotic center.* **(Right)** *Axial T1WI in the same patient shows the hyperintensity of subacute hemorrhage around a necrotic core. CNS lymphoma rarely hemorrhages or undergoes necrosis except in immunocompromised patients.*

https://CafePezeshki.IR

KEY FACTS

IMAGING

- Multiple perpendicular callososeptal T2 hyperintensities characteristic of multiple sclerosis (MS)
  - Perivenular extension: "Dawson fingers"
- Bilateral, asymmetric linear/ovoid FLAIR hyperintensities
  - > 85% periventricular/perivenular
  - 50-90% callososeptal interface
  - May also commonly involve subcortical U-fibers, brachium pontis, brainstem, spinal cord common
- Transient enhancement during active demyelination
  - > 90% disappear within 6 months
- Rare: Large tumefactive enhancing rings
- T1: Hypointense lesions suggest worse prognosis
  - Correlate with disability, atrophy, progressive disease
- Advanced imaging techniques show disease in normal-appearing white matter

TOP DIFFERENTIAL DIAGNOSES

- Acute disseminated encephalomyelitis (ADEM)
- Neuromyelitis optica
- Autoimmune-mediated vasculitis
- CADASIL
- Lyme disease
- Susac syndrome

CLINICAL ISSUES

- Estimated 2.5 million people in world have MS
- Most common disabling CNS disease of young adults; 1:1,000 in Western world
- Age: 20-40 years
  - Peak onset = 30; 3-5% < 15, 9% > 50
- Adults: M:F = 1:2; adolescents: M:F = 1:3-5

DIAGNOSTIC CHECKLIST

- Requires dissemination in time and space in central nervous system for diagnosis
- McDonald criteria: Consensus statement for diagnostic criteria, last revised in 2010

(Left) *Sagittal graphic illustrates multiple sclerosis (MS) plaques involving the corpus callosum, pons, and spinal cord. Note the characteristic perpendicular orientation of the lesions ⇨ at the callososeptal interface along penetrating venules.* **(Right)** *Axial T1WI C+ MR shows numerous enhancing MS plaques that were present throughout the infratentorial and supratentorial brain. Lesions may show homogeneous enhancement, but may also exhibit ring or an incomplete ring pattern of enhancement.*

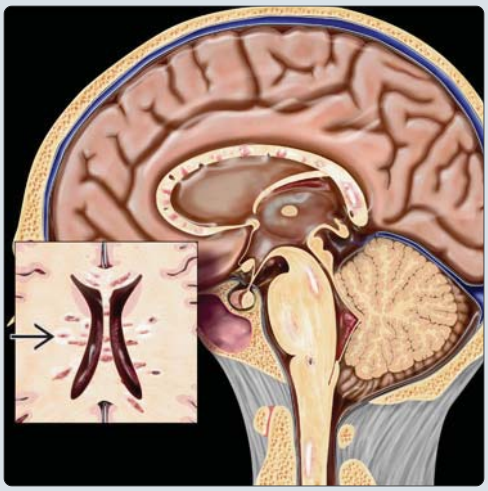

(Left) *Sagittal FLAIR shows callososeptal hyperintensities ⇨ radiating from the lateral ventricles with a typical perpendicular orientation, characteristic of multiple sclerosis.* **(Right)** *Axial FLAIR in a 35-year-old female with multiple sclerosis shows extensive confluent periventricular hyperintense lesions ⇨ typical of advanced, longstanding MS with loss of discrete, linear, periventricular lesions. Note prominence of the ventricles and cortical sulci due to diffuse atrophy.*

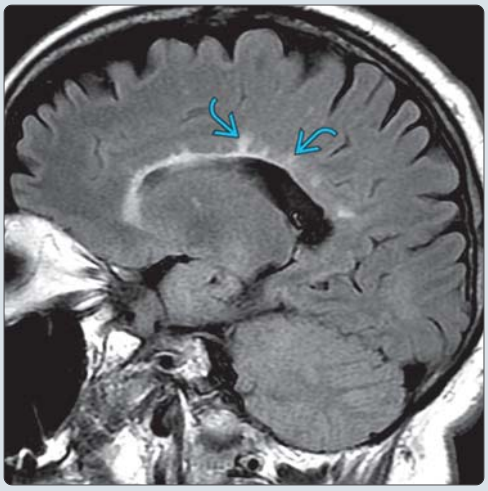

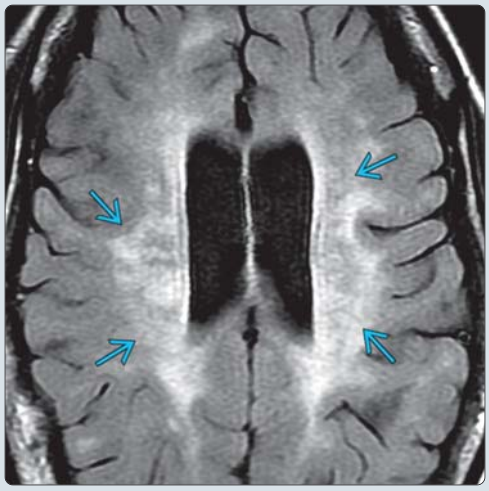

https://CafePezeshki.IR

TERMINOLOGY

Abbreviations

- Multiple sclerosis (MS)

Definitions

- Probable autoimmune-mediated demyelination in which environmental factors act upon genetically susceptible individuals

IMAGING

General Features

- Best diagnostic clue
  - Multiple perpendicular callososeptal T2 hyperintensities
- Location
  - > 85% periventricular/perivenular
  - 50-90% callososeptal interface
  - Subcortical U-fibers, brachium pontis, brainstem, spinal cord
  - Infratentorial (< 10% in adults, more common in children)
- Size
  - Small 5-10 mm, tumefactive lesions several cm
- Morphology
  - Linear, round, or ovoid; beveled, target, lesion-in-a-lesion appearance

CT Findings

- CECT
  - Iso-/hypodense ± mild/moderate enhancement
  - Both solid and ring enhancement patterns

MR Findings

- T1WI
  - Typically hypo- or isointense
  - Hypointensity correlates with axonal destruction ("black holes")
  - T1 hypointense lesions suggest worse prognosis
    - Correlated with disability, atrophy, progressive disease
  - Hyperintense dentate nuclei seen in secondary progressive form
- T2WI
  - Hyperintense, linear foci radiating from ventricles
  - Also prevalent in subcortical U-fibers, brachium pontis, brainstem, and spinal cord
  - High cortical disease burden can be predictor of primary progressive MS
  - Hypointense basal ganglia 10-20% of chronic MS
- FLAIR
  - Earliest finding: Alternating linear hyperintensity along ependyma on sagittal FLAIR
    - Ependymal "dot-dash" sign
  - Bilateral, asymmetric, linear/ovoid hyperintensities
  - Perivenular extension; "Dawson fingers"
    - Along path of deep medullary veins
  - Hyperintensities become confluent with severity
- DWI
  - Majority of acute plaques: Normal or ↑ diffusivity
  - Few acute MS plaques may show restricted diffusion
    - Often at the margins of acute plaque
  - Subacute/chronic plaques show ↑ diffusivity
  - DTI: Reduced longitudinal diffusivity in areas of axonal injury
- T1WI C+
  - Transient enhancement during active demyelination (> 90% disappear within 6 months)
    - Nodular (68%) or ring (23%)
    - Semilunar, incomplete, horseshoe-shaped (9%)
    - Rare: Large tumefactive enhancing rings
- MRS
  - ↓ NAA (NAA/Cr), ↑ choline (Cho/Cr), ↑ myoinositol
  - MRS abnormalities found in normal-appearing white matter (NAWM)
  - Only secondary progressive MS shows ↓ NAA in normal-appearing gray matter (NAGM)
    - May allow early distinction between relapsing-remitting and secondary-progressive
- Perfusion MR (contrast-enhanced T2*): Low rCBV
  - Can separate tumefactive MS from neoplasm
- Magnetization transfer (MT)
  - ↓ MT ratio (MTR) in lesions/NAWM
- Functional connectivity MR (fcMR)
  - ↓ functional connectivity between right/left hemisphere primary visual and motor cortices
- 3.0 T vs. 1.5 T: 21% ↑ number of contrast-enhancing lesions, 30% ↑ enhancing lesion volume, 10% ↑ total lesion volume

Imaging Recommendations

- Protocol advice
  - Contrast-enhanced MR with sagittal FLAIR
  - Fat saturation to assess for optic neuritis

DIFFERENTIAL DIAGNOSIS

Acute Disseminated Encephalomyelitis (ADEM)

- Viral prodrome, monophasic illness, more common in children
- Can mimic MS; gray matter often involved
- ADEM lesions tend to be larger, more edematous, and often symmetric

Neuromyelitis Optica

- Optic neuritis and spinal cord lesions
- Brain lesions look atypical for MS, tend to border midline CSF spaces

Autoimmune-Mediated Vasculitis

- Enhancing lesions spare callososeptal interface
- "Beaded" angiogram appearance

CADASIL

- Premature dementia and recurrent strokes with *NOTCH3* mutations
- Tends to spare corpus callosum, subcortical U-fibers

Lyme Disease

- Can be identical to MS (skin rash common)

Susac Syndrome

- Classic triad: Encephalopathy, branch retinal artery occlusions, hearing loss

https://CafePezeshki.IR

McDonald Criteria (2010 Revisions) for Diagnosis of MS

Dissemination in Space by MR	Dissemination in Time by MR
≥ 1 T2 hyperintense lesion(s)	**Either** new T2 or Gd-enhancing lesion(s) on follow-up MR
In at least 2 of the following 4 areas	**Or** simultaneous presence of
Periventricular	Asymptomatic Gd-enhancing **and**
Juxtacortical	Nonenhancing lesions at any time
Infratentorial	
Spinal cord	

PATHOLOGY

General Features

- Etiology
  - Unknown; probably virus &/or autoimmune-mediated in genetically susceptible individuals
  - Activated T cells attack myelinated axons
  - Cox-2, iNOS may cause excitotoxic death of oligodendrocytes
- Genetics
  - Multifactorial; ↑ incidence in 1st-order relatives

Staging, Grading, & Classification

- Major clinical subtypes
  - **Relapsing-remitting** (RR) 85% initial presentation
  - **Secondary-progressive** (SP), a.k.a. relapsing progressive
    - By 10 years 50%, and by 25 years 90% of RR patients enter SP phase
  - **Primary-progressive** (PP), a.k.a. chronic progressive
    - 5-10% of MS population progressive from start
  - **Progressive-relapsing** (PR)
    - Rare; defined as progressive disease with clear acute relapses ± full recovery
    - Periods between relapses characterized by continuing disease progression
  - **Radiologically isolated syndrome** (RIS)
    - MR findings suggestive of MS without typical MS symptoms and normal neurological exam
- MS variants/subtypes
  - **Malignant/Marburg disease**: Younger patients, febrile prodrome, clinically fulminant, death in months
  - **Schilder** type ("diffuse sclerosis"): Extensive, confluent, asymmetric demyelination in bilateral supra-/infratentorial parenchyma
  - **Baló** type ("concentric sclerosis"): Large lesions with alternating zones of demyelinated/myelinated WM

Gross Pathologic & Surgical Features

- Acute: Poorly delineated, yellowish-white, periventricular plaques
- Chronic: Gray, granular, well-demarcated plaques ± generalized volume loss

Microscopic Features

- Perivenous demyelination, oligodendrocyte loss
  - Active: Foamy macrophages with myelin fragments, lipids; reactive astrocytes + perivascular inflammation; atypical reactive astrocytes, mitoses (mimic tumor)
  - Chronic: Marked loss of myelin, oligodendrocytes; dense astrogliosis; minimal/no perivascular inflammation
- Axonal transection
- CSF positive for oligoclonal bands

CLINICAL ISSUES

Presentation

- Most common signs/symptoms
  - Variable; initially impaired/double vision of acute optic neuritis (50% with positive MR develop MS)
  - Weakness, numbness, tingling, gait disturbances
  - ↓ sphincter control, blindness, paralysis, dementia
  - Cranial nerve palsy; usually multiple, 1-5% isolated (CN5, 6 most common)
  - Spinal cord symptoms in 80%

Demographics

- Age
  - 20-40; peak onset is 30; 3-5% < 15, 9% > 50
- Gender
  - Adults: M:F = 1:2
  - Adolescents: M:F = 1:3-5
- Ethnicity
  - All groups, but white most common
  - Most often occurs in temperate zones
- Epidemiology
  - Estimated 2.5 million people in world have MS
  - Most common disabling CNS disease of young adults; 1:1,000 in Western world

Natural History & Prognosis

- 1/3 patients have initial episode followed by normal or near-normal function
- > 80% with "probable" MS, positive MR progress to clinically definite MS
- Majority: Protracted course with progression of deficits
- Late: Severe disability, cognitive impairment

Treatment

- Immunomodulators &/or immunosuppressants

DIAGNOSTIC CHECKLIST

Image Interpretation Pearls

- 95% with clinically definite MS have positive MR

SELECTED REFERENCES

1. Roosendaal SD et al: Imaging phenotypes in multiple sclerosis. Neuroimaging Clin N Am. 25(1):83-96, 2015

https://CafePezeshki.IR

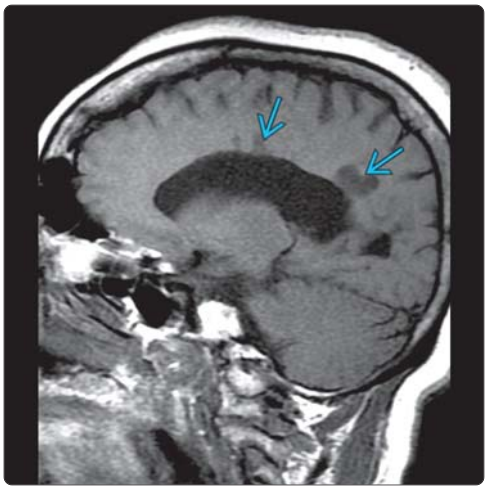

(Left) *Axial SWI image demonstrates characteristic perivenular location of a demyelinating plaque* ⇨ *with the medullary vein* ⇨ *coursing through it.* **(Right)** *Sagittal T1WI MR shows multiple hypointense lesions ("black holes") in the periventricular white matter* ⇨ *related to axonal destruction. Note the associated moderate ventricular and sulcal enlargement. T1 "back holes" are correlated with greater tissue damage and increased axonal destruction on histopathology.*

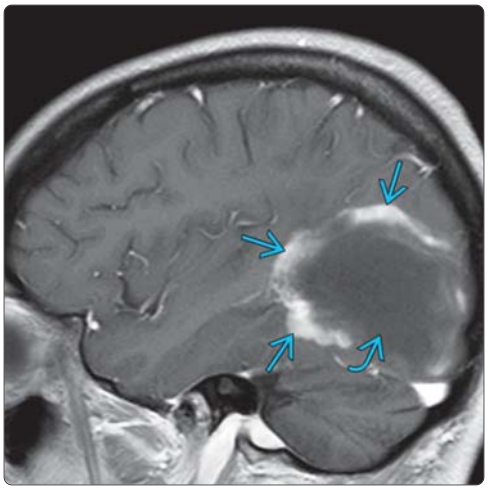

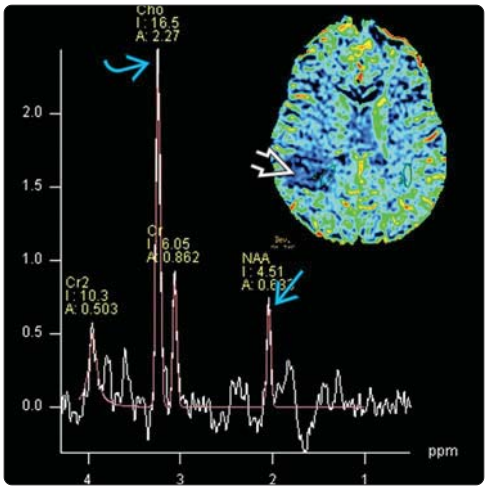

(Left) *Sag T1WI C+ MR shows a large hypointense mass* ⇨ *with a peripheral crescent of incomplete or "open ring" enhancement* ⇨*. This enhancement pattern is classic for a tumefactive demyelinating disease, most commonly MS.* **(Right)** *MRS at 144 TE in the same patient demonstrates a large choline peak* ⇨ *with ↓ in NAA* ⇨*. MRS in a tumefactive demyelinating lesion is not specific and can mimic a tumor profile. MR DSC perfusion (insert) shows marked ↓ rCBV* ⇨*, which goes more in favor of a demyelinating lesion.*

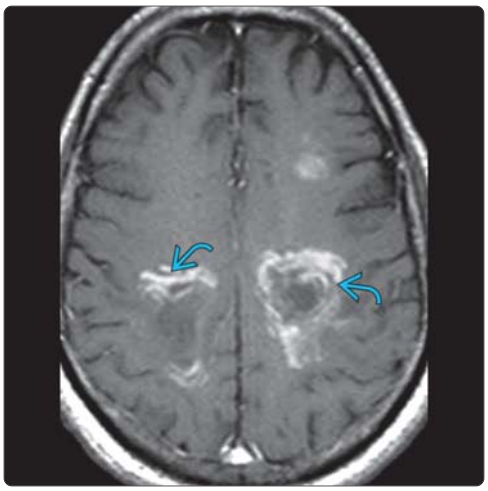

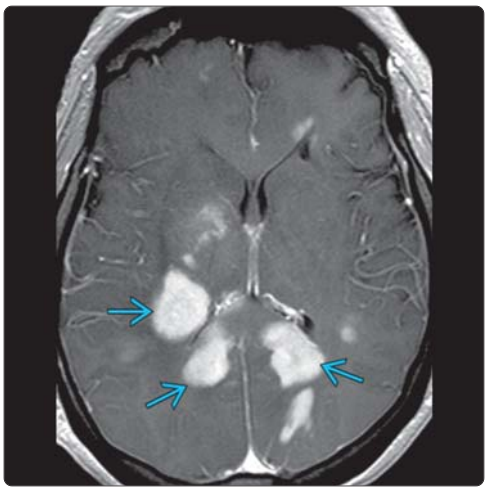

(Left) *Axial T1+C MR demonstrates concentric laminated "onion bulb" enhancement* ⇨ *characteristic of acute Baló concentric sclerosis. Baló concentric sclerosis is a rare aggressive MS variant characterized by acute onset and rapid deterioration.* **(Right)** *Axial T1+ MR in a young male with rapid onset of visual disturbance demonstrates large enhancing demyelinating lesions* ⇨ *in the deep and periventricular white matter. Marburg disease is an acute fulminant MS variant.*

https://CafePezeshki.IR

KEY FACTS

TERMINOLOGY

- Neuromyelitis optica (NMO)
- Neuromyelitis optica spectrum disorders (NMOSD)
- Idiopathic inflammatory demyelinating disorder of CNS characterized by severe attacks of optic neuritis and myelitis

IMAGING

- Hyperintense, mildly enlarged optic nerves
- Expansile, hyperintense cord signal, ≥ 3 segments
- Brain lesions in NMO or NMOSD are quite characteristic and distinct from lesions in multiple sclerosis (MS)
- Long segment optic nerve enhancement
- Acute cord lesions show patchy enhancement
- Patchy enhancement with blurred margins ("cloud-like" enhancement) in cerebral lesions
- "Pencil-thin" ependymal enhancement

TOP DIFFERENTIAL DIAGNOSES

- Multiple sclerosis
- Optic neuritis
- Transverse myelitis
- Syringomyelia
- Spinal cord neoplasm

PATHOLOGY

- Serum marker: **NMO-IgG**, targets water channel aquaporin-4 (AQP4)
- Seen in 70% of NMO patients, **99% specificity**

CLINICAL ISSUES

- Impaired or double vision, myelopathy
- 20% present with brainstem symptoms at disease onset
- Relapsing course in 90% of patients
- Anti-AQP4 antibody positivity established prognostic marker
- Acute exacerbation: IV corticosteroid treatment

(Left) *Axial T1WI C+ FS MR shows a markedly enhancing prechiasmatic right optic nerve and chiasm, consistent with acute optic neuritis.* **(Right)** *Sagittal T2 DP FSE MR in the same patient shows a long segment of cord enlargement with hyperintensity. Ill-defined enhancement was also present in the cervical cord in this patient with myelopathy and vision loss. Patients with neuromyelitis optica (NMO) have a worse prognosis with more severe disability than multiple sclerosis, despite lack of brain involvement.*

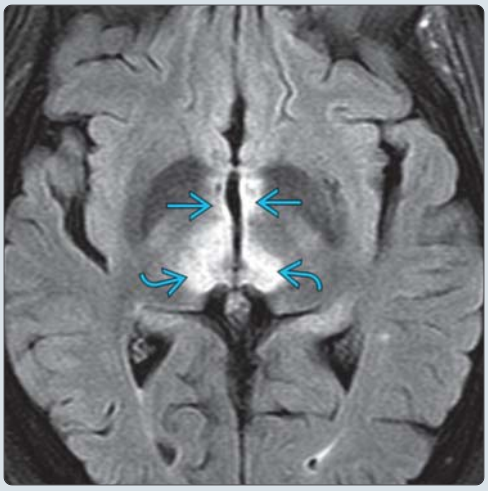

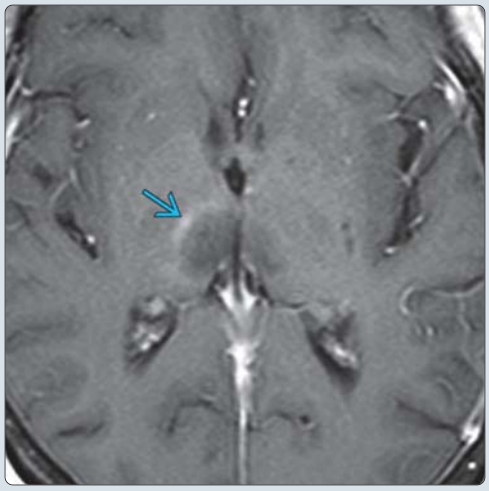

(Left) *Axial FLAIR MR in a patient with neuromyelitis optica spectrum disorder (NMOSD) shows characteristic periependymal lesions surrounding the 3rd ventricle, involving the thalamus and hypothalamus.* **(Right)** *Axial T1+C MR in the same patient shows subtle rim enhancement in the lesion in the right thalamus. Brain lesions in NMO/NMOSD are typically localized in the periependymal regions where aquaporin-4 (AQP4) is highly expressed.*

https://CafePezeshki.IR

TERMINOLOGY

Abbreviations

- Neuromyelitis optica (NMO)
- Neuromyelitis optica spectrum disorders (NMOSD)

Synonyms

- Devic syndrome

Definitions

- Idiopathic inflammatory demyelinating disorder of CNS characterized by severe attacks of optic neuritis and myelitis

IMAGING

General Features

- Best diagnostic clue
  - Optic neuritis and myelitis
  - Spectrum of brain lesions atypical for multiple sclerosis (MS)
- Location
  - Most common in cervical spinal cord, optic nerves
    - More posterior involvement of optic nerve including chiasm and simultaneous bilateral disease
  - Brain lesions: Deep white matter, periependymal regions, corpus callosum, corticospinal tracts, brainstem, and cerebellum
- Size
  - Spinal lesions typically expansile, multisegment
  - Brain lesions punctate or small (< 3 mm) to large confluent in cerebral white matter

MR Findings

- T2WI
  - Hyperintense, mildly enlarged optic nerves
    - More posterior involvement of optic nerve including chiasm and simultaneous bilateral disease
  - Expansile, hyperintense cord signal, ≥ 3 segments
    - May have heterogeneous areas of brighter (fluid) T2 signal
    - Predominantly involves central gray matter of spinal cord
  - Brain lesions with morphology and location not typical for MS
- STIR
  - Hyperintense optic nerve
  - Hyperintense cord signal ≥ 3 segments
    - Predominantly involves central gray matter of spinal cord
- FLAIR
  - Brain lesions in NMO or NMOSD are quite characteristic and distinct from lesions in MS
  - Distribution of NMO-characteristic brain lesions correspond to sites of high aquaporin-4 (AQP4) expression
    - Adjacent to ventricular system at any level
  - **Periependymal hyperintense lesions surrounding 3rd ventricle and cerebral aqueduct**
    - Thalamus, hypothalamus, ventral midbrain
  - **Dorsal brainstem hyperintense lesions adjacent to 4th ventricle**
    - Including area postrema and nucleus tracts solitarius
  - **Periventricular hyperintense lesions surrounding lateral ventricles**
    - NMO lesions follow ependymal lining in disseminated pattern
    - Often edematous and heterogeneous, creating "marbled" pattern unlike MS
    - Sometimes involving complete thickness of splenium in unique "arch bridge" pattern
    - Chronic phase lesions tend to reduce in size and intensity; may even disappear
      - Cystic changes and atrophy of corpus callosum
  - **Hyperintense lesions involving corticospinal tracts**
    - Unilateral or bilateral, posterior limb internal capsule, cerebral peduncle
    - Contiguous, often longitudinally extensive, following pyramidal tracts
    - Corticospinal tract lesions in 23% to 44% in NMOSD
  - **Extensive hemispheric hyperintense lesions**
    - Tumefactive (> 3 cm), long spindle-like, or radial shaped
    - Occasionally mimicking posterior reversible encephalopathy syndrome (PRES)
  - **Nonspecific lesions: Not unique, but most common**
    - Nonspecific punctate or small (< 3 mm) dots or patches of hyperintensities in subcortical or deep white matter
- DWI
  - Higher diffusivity, lower fractional anisotropy than MS patients or controls
  - Patient with NMO and normal brain MR
    - DTI shows increased mean diffusivity in corticospinal tract and optic radiation, but not in cingulum or corpus callosum
- T1WI C+
  - Long segment optic nerve enhancement unilateral or bilateral, often extending posterior to optic chiasm
  - Acute lesions in cord show patchy enhancement
  - Most NMO brain lesions do not show enhancement
  - Patchy enhancement with blurred margins ("cloud-like" enhancement) in cerebral lesions
    - Relatively specific for NMO
  - "Pencil-thin" ependymal enhancement
  - Rarely, well-marginated nodular enhancement or meningeal enhancement
- MRS
  - In NMO metabolites are normal in normal-appearing white matter (NAWM) and normal-appearing gray matter (NAGM) compared to patients with MS
  - In MS, NAA ↓ and choline ↑ in NAWM

Imaging Recommendations

- Best imaging tool
  - Contrast-enhanced MR of brain, spine, and orbits
- Protocol advice
  - Orbits: Axial or coronal STIR or T2 FS and T1 C+ FS
  - Spine: Sagittal STIR or T2, T1WI C+
  - Brain: Axial and Sagittal FLAIR, T1WI C+

https://CafePezeshki.IR

DIFFERENTIAL DIAGNOSIS

Multiple Sclerosis

- Radially oriented, well-demarcated perivenular lesions (Dawson fingers)
- Optic neuritis and spinal involvement may be seen
- Multisegment, expansile cord lesion more common in neuromyelitis optica

Optic Neuritis

- 1 component of NMO
- Consider NMO-IgG in case of 1st optic neuritis, but otherwise normal brain MR

Transverse Myelitis

- 1 component of NMO
- Idiopathic inflammatory or postinfectious myelitis
- Differentiation of spinal NMO and other immune-mediated myelitis like Sjögren disease or SLE difficult

Syringomyelia

- Enlargement and T2 hyperintensity of spinal cord
- May appear similar to NMO

Spinal Cord Neoplasm

- Astrocytoma or ependymoma can show similar multisegment cord T2 hyperintensity and enhancement

PATHOLOGY

Staging, Grading, & Classification

- **Diagnostic criteria for diagnosis of NMO**
  - Optic neuritis
  - Transverse myelitis
  - At least 2 of following 3 supportive criteria
    - Contiguous spinal cord MR lesion extending over at least 3 vertebral segments
    - Onset brain MR not meeting diagnostic criteria for MS
    - NMO-IgG seropositive status

Gross Pathologic & Surgical Features

- Cavitation of spinal cord

Microscopic Features

- Serum marker: **NMO-IgG**, targets water channel AQP4
  - Seen in 70% of NMO patients, **99% specificity**
  - AQP4 is most abundant cell membrane water channel in CNS
  - Expressed in foot processes of astrocytes in contact with blood vessels throughout brain, spinal cord, and optic nerves
  - Periventricular area, hypothalamus, and brainstem also sites of high expression of AQP4
- Evolving lesions show fragmentation and loss of astrocytes that precede demyelination
- Granulocyte infiltration with perivascular immunoglobulin and complement deposition

CLINICAL ISSUES

Presentation

- Most common signs/symptoms
  - Optic neuritis: Impaired or double vision
  - Myelitis: Myelopathy
  - 20% present with brainstem symptoms at disease onset
    - Nystagmus, dysarthria, dysphagia, ataxia, or ophthalmoplegia
  - Symptomatic narcolepsy or acute diencephalic syndrome
  - Aphasia, seizures, disturbance of consciousness, cognitive symptoms
- Clinical profile
  - CSF: Neutrophilic pleocytosis, negative oligoclonal bands

Natural History & Prognosis

- Relapsing course in 90% of patients
- Worse prognosis with more severe disability than MS
- Anti-AQP4 antibody positivity established prognostic marker
  - Indicates high risk of further relapses of optic neuritis and myelitis
- Early and aggressive immunosuppression required to prevent or reduce severe disability
- Routine imaging surveillance necessary to monitor complications of immunosuppression

Treatment

- Acute exacerbation: IV methylprednisone treatment followed by oral prednisone and then gradual tapering over 6-12 months
  - Plasma exchange in relapses not responding to steroids
- Prevention of relapses: Low dose corticosteroids, azathioprine, rituximab, methotrexate
- Symptom management and rehabilitation

DIAGNOSTIC CHECKLIST

Consider

- NMO in patient with optic neuritis and myelitis
- NMOSD in patient with characteristic brain lesions involving periependymal regions, corpus callosum, corticospinal tracts, brainstem

SELECTED REFERENCES

1. Kim HJ et al: MRI characteristics of neuromyelitis optica spectrum disorder: An international update. Neurology. ePub, 2015
2. Barnett Y et al: Conventional and advanced imaging in neuromyelitis optica. AJNR Am J Neuroradiol. 35(8):1458-66, 2014
3. Kawachi I et al: [Characteristic features of radiological findings in multiple sclerosis and neuromyelitis optica.] Nihon Rinsho. 72(11):1976-82, 2014
4. Uzawa A et al: Neuromyelitis optica: concept, immunology and treatment. J Clin Neurosci. 21(1):12-21, 2014
5. Jacob A et al: Current concept of neuromyelitis optica (NMO) and NMO spectrum disorders. J Neurol Neurosurg Psychiatry. 84(8):922-30, 2013
6. Sato DK et al: Clinical spectrum and treatment of neuromyelitis optica spectrum disorders: evolution and current status. Brain Pathol. 23(6):647-60, 2013
7. Kim W et al: Brain abnormalities in neuromyelitis optica spectrum disorder. Mult Scler Int. 2012:735486, 2012
8. Lana-Peixoto MA et al: The expanded spectrum of neuromyelitis optica: evidences for a new definition. Arq Neuropsiquiatr. 70(10):807-13, 2012
9. Benavente E et al: Neuromyelitis Optica-AQP4: an update. Curr Rheumatol Rep. 13(6):496-505, 2011

https://CafePezeshki.IR

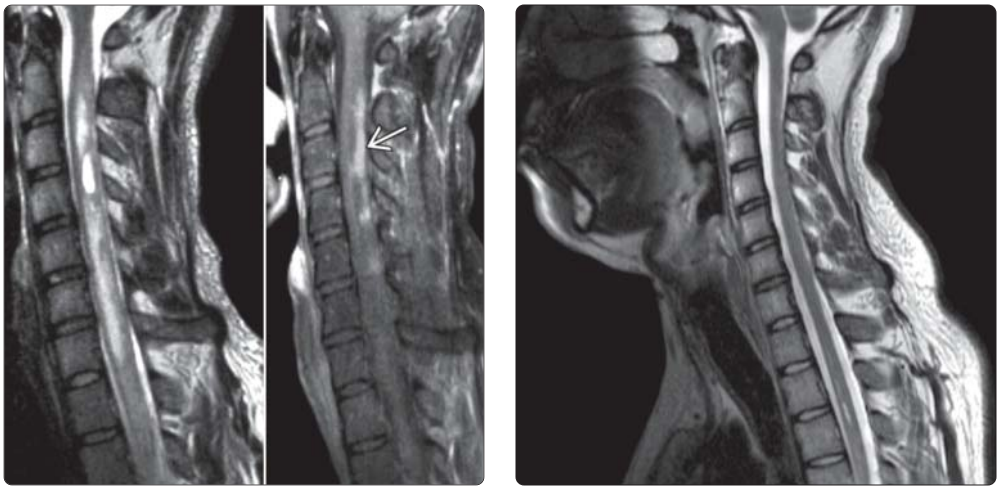

(Left) *Sagittal T2 (left) and T1WI C+ FS (right) images show multilevel T2 hyperintensity with irregular posterior enhancement* ➡ *in the cervical cord in a patient with a previous history of optic neuritis.* **(Right)** *Sagittal T2WI MR in the same patient 1 year after treatment shows near complete resolution of the T2 signal abnormality. Enhancement was no longer seen in the cervical cord. The cord lesions seen in NMO typically extend over 3 or more segments.*

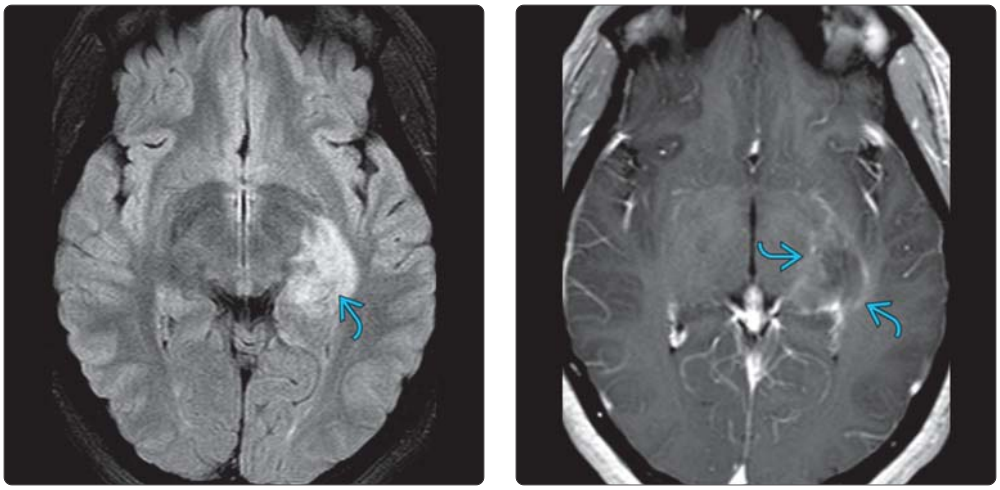

(Left) *Axial FLAIR MR in a patient who presented with altered sensorium demonstrates a large hyperintense lesion in the left medial temporal lobe* ⇨*.* **(Right)** *Axial T1+ C MR in the same patient shows patchy enhancement* ⇨ *with blurred margins ("cloud-like" enhancement). NMO-immunoglobulin G antibody in serum was positive in this patient. This pattern of enhancement has been reported as relatively specific for NMO.*

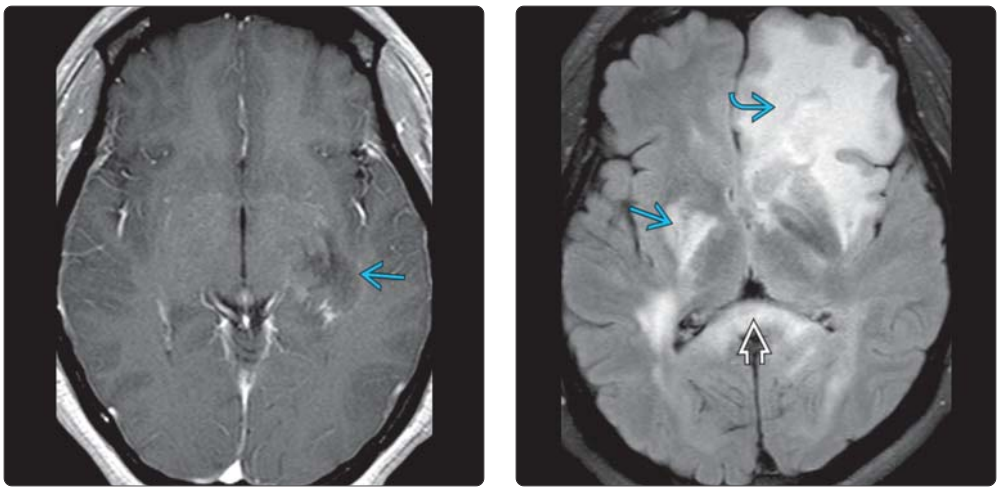

(Left) *Axial T1+C MR in the same patient 4 days after IV steroid therapy shows almost complete resolution of the enhancement* ⇨*.* **(Right)** *Axial FLAIR MR in a patient with NMO shows multiple characteristic brain lesions. A large tumefactive lesion with ill-defined borders is seen in the left frontal lobe* ⇨*. An ill-defined hyperintense lesion is seen involving the posterior limb of right internal capsule* ⇨ *and there involvement of the splenium of corpus callosum* ➡ *in a unique "arch bridge" pattern.*

https://CafePezeshki.IR

KEY FACTS

TERMINOLOGY

- Autoimmune-mediated white matter (WM) demyelination of brain &/or spinal cord, usually with remyelination

IMAGING

- Best diagnostic clue: Multifocal WM and deep gray lesions days to weeks following infection/vaccination
- May involve both brain and spinal cord; white matter > gray matter, but usually both affected
- Deep/juxtacortical WM > periventricular WM
- Both supratentorial and infratentorial lesions
- Multifocal punctate to large flocculent FLAIR hyperintensities
- Do not usually involve callososeptal interface
- Most lesions show increased signal on DWI (T2 shine through)
- Punctate, ring, incomplete ring, peripheral enhancement
- Absence of enhancement does not exclude diagnosis
- MRS: ↓ NAA within lesions; may see ↑ Cho, ↑ lactate

TOP DIFFERENTIAL DIAGNOSES

- Multiple sclerosis (MS)
- Autoimmune-mediated vasculitis
- Acute hypertensive encephalopathy, PRES
- Fabry disease
- Behçet disease

PATHOLOGY

- Over 30 different infectious agents and immunizations reported

CLINICAL ISSUES

- Mean age is 5-8 years, but can occur at any age
- Male predominance (M:F = 1:0.6-0.8), unlike MS
- Usually monophasic, self-limited
- Complete recovery within 1 month: 50-60%
- Mortality: 10-30%

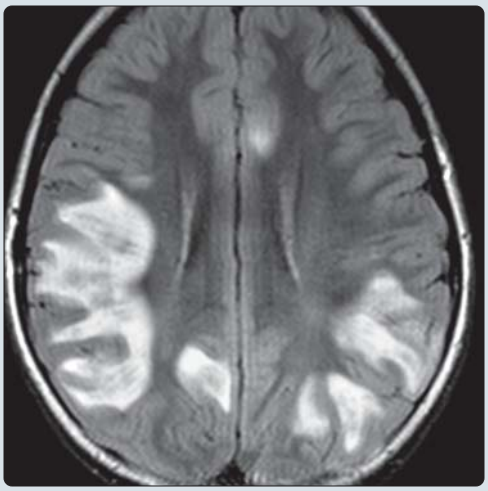

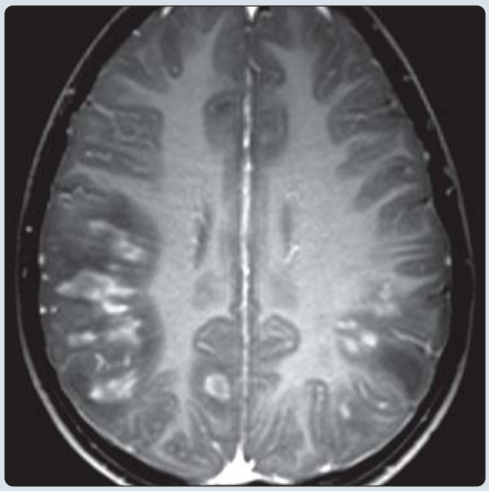

(Left) *Axial FLAIR MR shows peripheral, confluent areas of hyperintensity predominantly involving the subcortical white matter in this child with ADEM. The bilateral but asymmetric pattern is typical of ADEM.* **(Right)** *Axial T1WI C+ MR in the same patient shows marked, irregular enhancement of nearly all of the lesions. As ADEM is a monophasic illness, enhancement of the majority of lesions is typical, as the lesions all have a similar time course. Enhancement of MS lesions is more variable.*

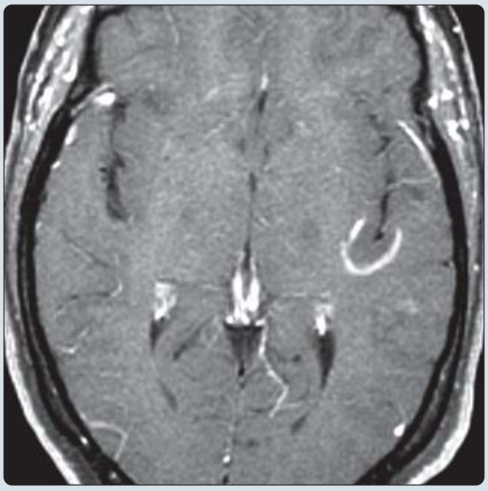

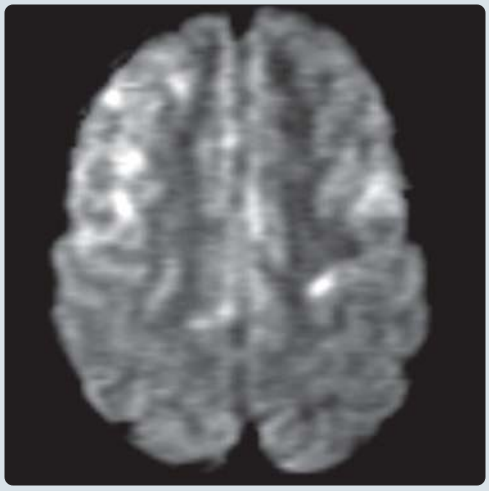

(Left) *Axial T1WI C+ MR shows an incomplete ring of peripheral enhancement, typical of a demyelinating process. Other contrast enhancement patterns include ovoid or punctate homogeneous enhancement.* **(Right)** *Axial DWI MR shows increased signal in areas of FLAIR hyperintensity. The foci were hypointense on ADC images, indicating diffusion restriction. Both white and gray matter involvement is present. Diffusion restriction is an uncommon imaging finding and is associated with a worse prognosis.*

https://CafePezeshki.IR

TERMINOLOGY

Abbreviations

- Acute disseminated encephalomyelitis (ADEM)

Definitions

- Autoimmune-mediated white matter (WM) demyelination of brain &/or spinal cord, usually with remyelination

IMAGING

General Features

- Best diagnostic clue
  - Multifocal WM/basal ganglia lesions days to weeks following infection/vaccination
    - 93% within 3 weeks of infection, 5% within 1 month of vaccination
- Location
  - May involve both brain and spinal cord; white matter > gray matter, but usually both affected
  - Deep/juxtacortical WM > periventricular WM
  - Both supratentorial and infratentorial lesions
- Size
  - Tumefactive lesions may be large, but with less mass effect than expected from tumor size
- Morphology
  - Punctate to "flocculent"
  - Tumefactive, mass-like lesions possible

CT Findings

- NECT
  - Initial CT normal in 40%
- CECT
  - Multifocal punctate or ring-enhancing lesions

MR Findings

- T2WI
  - Hyperintensities may be better visualized in brainstem and posterior fossa on T2
- FLAIR
  - Multifocal punctate to large flocculent FLAIR hyperintensities
    - Bilateral but asymmetric
  - Involve peripheral white-gray matter junction subcortical WM
  - Thalami & basal ganglia frequently involved, typically symmetric
  - Can involve brainstem and posterior fossa
  - Do not usually involve callososeptal interface
- DWI
  - Variably hyperintense lesions on DWI (trace) images
  - Apparent diffusion coefficient (ADC) may be increased or decreased
    - Most lesions show increased signal (T2 shine through)
    - Diffusion restriction uncommon, suggests worse prognosis
    - Diffusivity normal within normal-appearing white matter (NAWM), unlike MS
- T1WI C+
  - Punctate, ring, incomplete ring, peripheral enhancement
  - Cranial nerve(s) may enhance
  - Absence does not exclude diagnosis
- MRS
  - NAA low within lesions, lactate may be elevated
  - Choline often elevated in acute lesions
  - NAA normalizes with resolution of symptoms/MR abnormalities
- Magnetization transfer ratio (MTR)
  - ADEM MTR normal within NAWM, unlike MS

Imaging Recommendations

- Best imaging tool
  - Contrast-enhanced MR
    - Initial imaging often normal but more sensitive than CT
    - May appear identical to MS; repeat MR necessary to distinguish with certainty
- Protocol advice
  - Limited rapid interval follow-up may be provided by FLAIR alone

DIFFERENTIAL DIAGNOSIS

Multiple Sclerosis (MS)

- Predilection for periventricular WM (callososeptal interface), involves subcortical U-fibers, commonly in posterior fossa
- Lesions often more symmetric than ADEM
- Relapsing-remitting course common

Autoimmune-Mediated Vasculitis

- Multifocal GM-WM lesions
  - Bilateral, usually cortical/subcortical, basal ganglia/thalami
  - Ring-enhancing lesions may mimic infection

Acute Hypertensive Encephalopathy, PRES

- Typically posterior circulation in cortex/subcortical WM
- May affect deep gray nuclei

Aging Brain With Hyperintense WM Lesions

- Atherosclerotic brain changes in 50% patients > 50 years old
- Found in normotensive patients; more common in hypertensives
- Present in 10-30% of cognitively normal elderly patients
- MR: Scattered, asymmetric WM lesions, without enhancement
  - Often periatrial; posterior fossa uncommon
  - Spares callososeptal interface, subcortical U-fibers

Fabry Disease

- Deficiency α-galactosidase A; overaccumulation of glycosphingolipids within lysosomes
- MR: Scattered, asymmetric WM lesions, without enhancement
  - May involve brainstem and posterior fossa
  - Spares callososeptal interface and subcortical U-fibers
  - Cranial MR sensitive to identify neurologic involvement in asymptomatic patients
- Present with renal failure/heart disease

Behçet Disease

- MR: Scattered, asymmetric, subcortical WM lesions without cortical involvement

https://CafePezeshki.IR

- Nodular enhancement in acute phase
- Predilection for midbrain
- ADC ↑, similar to ADEM
- Classic triad: Oral & genital ulcerations with uveitis

PATHOLOGY

General Features

- Etiology
  - Autoimmune-mediated severe acute demyelination
  - Following nonspecific upper respiratory tract infection, often viral
    - Over 30 different infectious agents and immunizations reported
  - After specific viral illness: Epstein-Barr, influenza A, mumps, coronavirus
  - Especially after exanthematous diseases of childhood (chickenpox, measles)
  - After vaccination: Diphtheria, influenza, rabies, smallpox, tetanus, typhoid
  - Spontaneously (no known cause)
- Genetics
  - ADEM associated with DRB1*01 and DRB1*017(03) in Russian population
- Associated abnormalities
  - Acute hemorrhagic leukoencephalopathy variant associated with ulcerative colitis and asthma

Gross Pathologic & Surgical Features

- None, unless hemorrhage (rare) or tumefactive edema

Microscopic Features

- Acute myelin breakdown
- Perivenous inflammation; lymphocytic infiltrates
- Relative axonal preservation; atypical astrogliosis
- Virus generally not found, unlike viral encephalitides
- Similar to experimental allergic encephalomyelitis, supporting autoimmune-related etiology

CLINICAL ISSUES

Presentation

- Most common signs/symptoms
  - Usually preceded by prodromal phase: Fever, malaise, myalgia
  - Multifocal neurological symptoms, 2 days to 4 weeks after viral illness/immunization
    - Initial symptoms: Headache, fever, drowsiness
    - Cranial nerve palsies, seizures, hemiparesis
    - Decreased consciousness (from lethargy to coma)
    - Behavioral changes
- Other signs/symptoms
  - Seizures in 10-35%
- Clinical profile
  - CSF normal in 60 %
  - If abnormal (lymphocyte pleocytosis, elevated protein)
    - Usually lacks CSF oligoclonal bands

Demographics

- Age
  - Children > adults
  - Mean age is 5-8 years but can occur at any age
- Gender
  - Male predominance (M:F = 1.0:0.6-0.8), unlike MS
- Epidemiology
  - Rare, yet most common para-/post-infectious disorder
  - Most common in winter and spring
  - Exact epidemiology unknown, but increasingly reported

Natural History & Prognosis

- Usually monophasic, self-limited
- Variable prognosis
  - Complete recovery within 1 month (50-60%)
  - Neurologic sequelae (most commonly seizures) (20-30%)
  - Mortality (10-30%)
  - Relapses are rare
    - "Relapsing disseminated encephalomyelitis"
    - May not be separate entity from relapsing-remitting MS
- Typically delay between symptom onset and imaging findings
- Varicella and rubella ADEM have preferential patterns
  - Varicella ADEM characterized by cerebellar ataxia and mild pyramidal dysfunction
  - Rubella ADEM characterized by acute explosive onset, seizures, coma, and moderate pyramidal signs
- Rare manifestations of ADEM
  - Acute hemorrhagic leukoencephalopathy (2%)
    - Young patients with abrupt symptom onset
    - Fulminant, often ending in death
  - Bilateral striatal necrosis (usually in infants, may be reversible)

Treatment

- Immunosuppressive/immunomodulatory therapy
  - MR may show prompt improvement after therapy
- Plasma exchange therapy
  - 40% of patients failing steroid treatment may show marked improvement

DIAGNOSTIC CHECKLIST

Image Interpretation Pearls

- Imaging findings often lag behind symptom onset, resolution

SELECTED REFERENCES

1. Bester M et al: Neuroimaging of multiple sclerosis, acute disseminated encephalomyelitis, and other demyelinating diseases. Semin Roentgenol. 49(1):76-85, 2014
2. Kanekar S et al: A pattern approach to focal white matter hyperintensities on magnetic resonance imaging. Radiol Clin North Am. 52(2):241-61, 2014
3. Karussis D: The diagnosis of multiple sclerosis and the various related demyelinating syndromes: a critical review. J Autoimmun. 48-49:134-42, 2014
4. Tenembaum SN: Acute disseminated encephalomyelitis. Handb Clin Neurol. 112:1253-62, 2013
5. Wingerchuk DM et al: Acute disseminated encephalomyelitis, transverse myelitis, and neuromyelitis optica. Continuum (Minneap Minn). 19(4 Multiple Sclerosis):944-67, 2013
6. Rossi A: Imaging of acute disseminated encephalomyelitis. Neuroimaging Clin N Am. 18(1):149-61; ix, 2008

https://CafePezeshki.IR

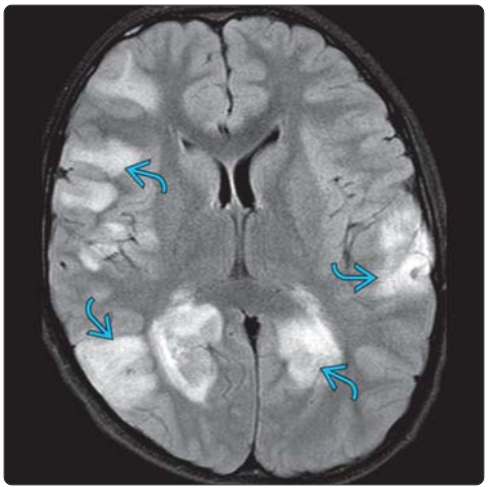

(Left) *Axial T2WI MR shows hyperintense lesions in the brachium pontis bilaterally, typical for demyelination. The right-sided lesion shows a targetoid ➡ appearance. Enhancement of several of the lesions was present on post-contrast T1 images (not shown).* **(Right)** *Axial FLAIR shows large confluent regions of hyperintense signal ⇨ in the periventricular and subcortical white matter in a 14 year old who presented with neck stiffness, fatigue, and seizures.*

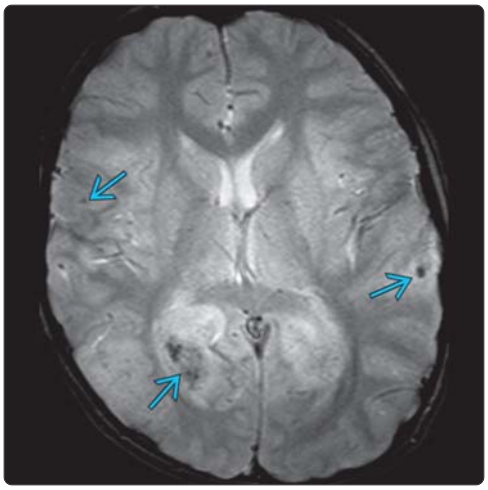

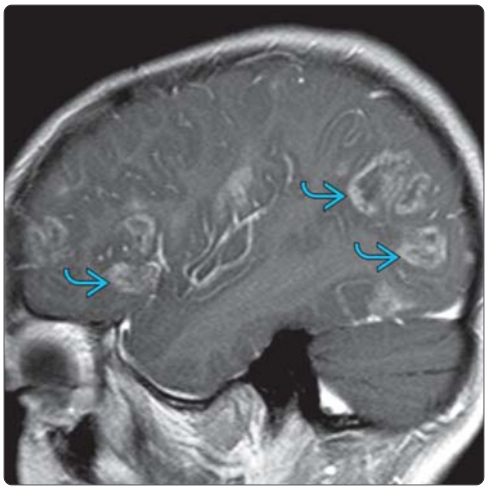

(Left) *Axial SWI in the same patient shows petechial hemorrhages ⇨ in regions of FLAIR signal abnormality.* **(Right)** *Sagittal T1+C in the same patient shows extensive irregular ring enhancement ⇨ involving the multiple subcortical white matter lesions. Acute hemorrhagic leukoencephalopathy (AHL) is a rare manifestation of ADEM occurring in 2% of cases. AHL is associated with a very poor prognosis. Aggressive therapeutic management is a prerequisite to avoid usual disease course with fatal outcome.*

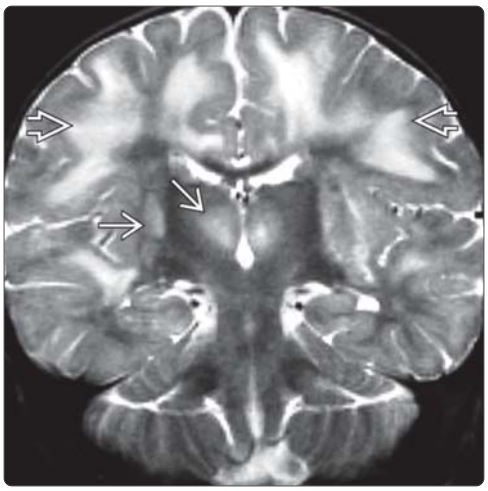

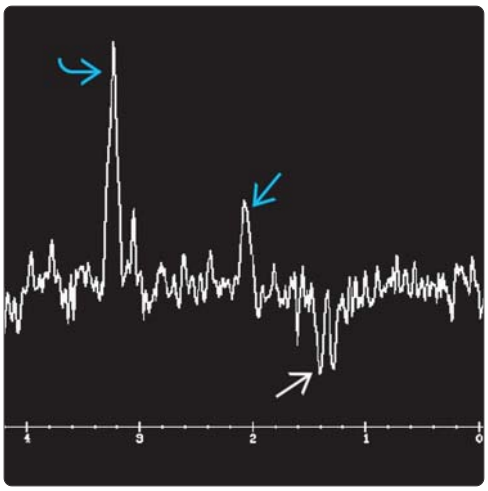

(Left) *Coronal T2WI MR shows large confluent regions of hyperintense signal in the white matter ➡ and deep gray nuclei ➡ of a child with ADEM. Although ADEM predominantly involves white matter, gray matter is often affected.* **(Right)** *MRS at long TE in a patient with acute lesions in ADEM demonstrates an ↑ choline ⇨, ↓ NAA ⇨, and the presence of a lactate doublet ➡. Increase in choline with corresponding reductions in NAA normalize as the clinical and conventional neuroimaging abnormalities resolve.*

https://CafePezeshki.IR

KEY FACTS

TERMINOLOGY

- Hyperacute, fulminant hemorrhagic perivascular demyelinating disorder
- Usually viral or immunization related

IMAGING

- Best imaging: MR with T2*GRE, SWI
- CT: May be normal if only microbleeds present
- MR
  - Multifocal scattered or confluent white matter (WM) hyperintensities on T2/FLAIR
  - T2* shows multifocal "blooming" microbleeds in WM (often striking sparing of cortex)
    - Most striking in corpus callosum
    - Less common: Large lobar confluent hemorrhages
  - SWI significantly more sensitive than GRE

TOP DIFFERENTIAL DIAGNOSES

- Acute disseminated encephalomyelitis (ADEM)
- Multiple sclerosis
- Acute necrotizing encephalopathy
- Other brain "microbleeds"
  - Trauma (DAI), fat emboli, HUS/TTP
  - Sepsis, vasculitis, hemorrhagic viral fevers
  - High altitude cerebral edema

CLINICAL ISSUES

- Demographics
  - AHLE represents ~ 2% of ADEM cases
  - All ages but children, young adults most common
- Presentation and course
  - Fever, then rapid neurological deterioration
  - 60-80% mortality without treatment

DIAGNOSTIC CHECKLIST

- Do T2* (GRE or SWI) in all febrile CNS illnesses with rapid clinical deterioration

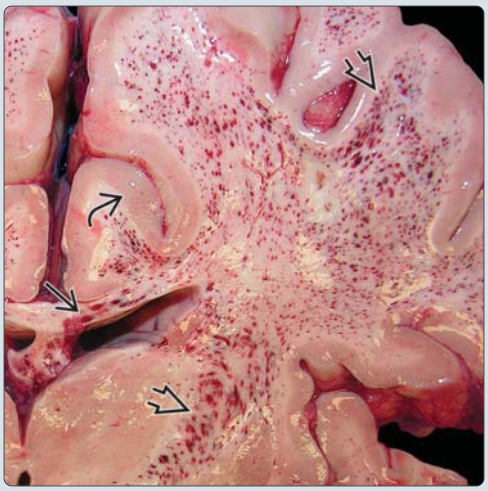

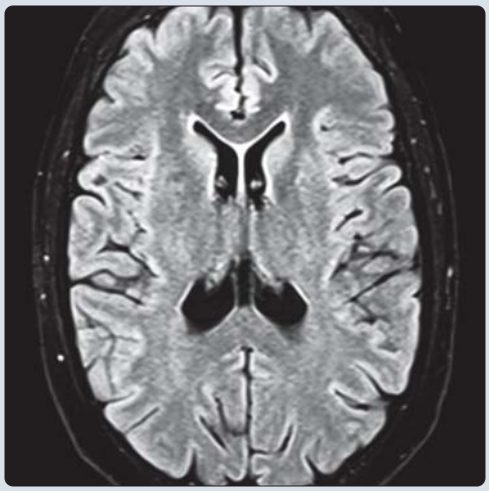

(Left) *Close-up view of autopsied brain in a patient with acute hemorrhagic leukoencephalitis (AHLE) shows innumerable tiny microbleeds in the subcortical and deep white matter (WM) ⇨, corpus callosum ⇨. Note the overlying cortex is almost completely spared ⇨. (Courtesy E. Rushing, MD.)* **(Right)** *Axial FLAIR MR in a 25-year-old man with fever and rapidly decreasing mental status shows no definite abnormalities.*

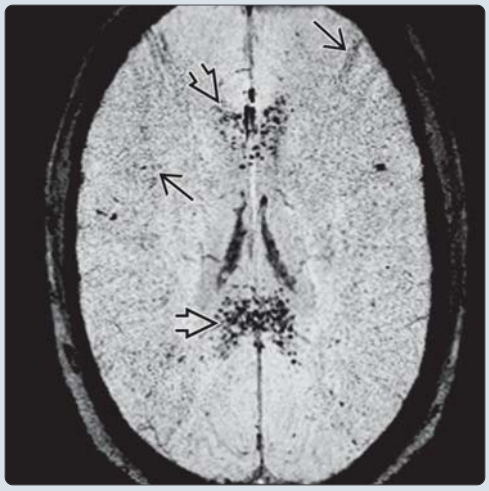

(Left) *T2* GRE in the same patient shows a few punctate "blooming" foci in the corpus callosum genu ⇨ and splenium ⇨. The remainder of the WM appears normal.* **(Right)** *Axial SWI in the same patient shows innumerable tiny "blooming" microbleeds in the corpus callosum ⇨, as well as the subcortical and deep WM ⇨. The cortex is largely spared. These imaging findings are characteristic of AHLE.*

https://CafePezeshki.IR

TERMINOLOGY

Abbreviations

- Acute hemorrhagic leukoencephalitis (AHLE)

Synonyms

- Acute hemorrhagic encephalomyelitis (AHEM)
- Weston Hurst disease

Definitions

- Hyperacute, fulminant hemorrhagic perivascular demyelinating disorder
  - Usually viral or immunization related
- May be exceptionally severe form of acute disseminated encephalomyelopathy (ADEM)

IMAGING

General Features

- Best diagnostic clue
  - T2* shows multifocal petechial white matter (WM) microhemorrhages with striking sparing of cortex
  - Less common: Large, lobar confluent hemorrhages
- Location
  - White matter
    - Corpus callosum, subcortical WM (U-fibers)
  - Less common: Basal ganglia, midbrain, pons, cerebellum
- Size
  - Punctate microbleeds > large lobar hemorrhages

CT Findings

- NECT
  - May be normal if only microbleeds present
  - ± WM edema with hypodensity

MR Findings

- T1WI
  - Often normal
- T2WI
  - Multifocal scattered or confluent WM hyperintensities
    - Most striking in corpus callosum
- T2* GRE
  - Multifocal "blooming" microbleeds
  - SWI significantly more sensitive than GRE

Imaging Recommendations

- Best imaging tool
  - MR with T2*GRE, SWI

DIFFERENTIAL DIAGNOSIS

Acute Disseminated Encephalomyelitis (ADEM)

- AHLE may be most severe form of ADEM
- ADEM usually less fulminant
- ADEM lacks lobar or perivascular hemorrhages of AHLE

Multiple Sclerosis (MS)

- Acute fulminant MS (Marburg type)
  - Lacks hemorrhage, high fever, marked leukocytosis

Acute Necrotizing Encephalopathy

- Rare complication of acute viral infection, such as influenza A
- Children < 4 years most common
- Bilateral, symmetric lesions in thalami typical
- WM predominance rare

Other Etiologies of Brain "Microbleeds"

- Diffuse traumatic vascular injury
- Fat emboli
- HUS/TTP
- Sepsis, vasculitis
- Hemorrhagic infections (viral fevers, malaria, rickettsial diseases)
- High altitude cerebral edema

PATHOLOGY

Gross Pathologic & Surgical Features

- Predominately involves WM of brain ± spinal cord
- May affect basal ganglia but usually spares cortical GM
- Focal confluent &/or multifocal petechial WM hemorrhages

Microscopic Features

- Fibrinoid necrosis of vessel walls
- Perivascular demyelination, hemorrhages

CLINICAL ISSUES

Presentation

- Most common signs/symptoms
  - Fever, then rapid neurological deterioration
  - Somnolence, impaired consciousness
- Other signs/symptoms
  - Long-tract signs

Demographics

- AHLE represents ~ 2% of ADEM cases
- All ages but children, young adults most common

Natural History & Prognosis

- Rapid clinical deterioration; death within days typical course
- Mortality: 60-80%

Treatment

- Aggressive IV steroids, immunoglobulin, plasmapheresis

DIAGNOSTIC CHECKLIST

Consider

- Do T2* (GRE or SWI) in all febrile CNS illnesses with rapid clinical deterioration

Image Interpretation Pearls

- Corpus callosum, subcortical WM microbleeds with striking sparing of overlying cortex typical for AHLE

SELECTED REFERENCES

1. Goenka A et al: Neurological manifestations of influenza infection in children and adults: results of a National British Surveillance Study. Clin Infect Dis. 58(6):775-84, 2014
2. Jeganathan N et al: Acute hemorrhagic leukoencephalopathy associated with influenza A (H1N1) virus. Neurocrit Care. 19(2):218-21, 2013
3. Gallucci M et al: Pediatric Inflammatory Diseases. Part II: Acute Post-Infectious Immune Disorders. Neuroradiol J. 25(6):702-14, 2012

https://CafePezeshki.IR

KEY FACTS

TERMINOLOGY

- Chronic lymphocytic inflammation with pontine perivascular enhancement responsive to steroids
  - Predominantly involving brainstem, adjacent rhombencephalic structures
  - Shows clinical, imaging response to glucocorticosteroids

IMAGING

- Location: Predominately pons
  - May extend laterally into cerebellar peduncles or hemispheres
  - Caudally into medulla, spinal cord
  - Rostrally into midbrain
- MR
  - Classic: Enhancing punctate/curvilinear lesions "peppering" the pons
    - May exhibit subtle radiating pattern
  - ± faint, patchy or "speckled" punctate hyperintensities on T2/FLAIR
  - Beware: May begin as isolated, enhancing mass in pons/cerebellar peduncle before exhibiting typical pattern of multifocal punctate pontine lesions

TOP DIFFERENTIAL DIAGNOSES

- Angiocentric (intravascular) lymphoma
- Neurosarcoidosis
- Demyelinating disease (MS, NMO spectrum)
- Vasculitis (primary, secondary, Behçet)
- Lymphomatoid granulomatosis
- CNS histiocytosis (LCH, Erdheim-Chester, hemophagocytic)

CLINICAL ISSUES

- Brainstem symptoms, gait ataxia, diplopia
  - Often relapsing-remitting course (without treatment)
  - Mean age at onset 40-50 years (reported range 13-86 years)
- Keep in mind: CLIPPERS is diagnosis of exclusion

(Left) *Sagittal FLAIR MR in a 56-year-old female with weight loss and 3-week history of diplopia and disequilibrium shows confluent and punctate hyperintensities in the pons ⇨ and medulla ⇨.* **(Right)** *Axial T1C+ scan in the same patient shows multiple punctate and curvilinear enhancing foci "peppering" the pons ⇨. Additional lesions are present in both cerebellar peduncles, vermis, and the left cerebellar hemisphere.*

(Left) *More cephalad T1C+ scan in the same patient shows the punctate ⇨ and curvilinear ⇨ lesions involving the upper pons.* **(Right)** *Coronal T1C+FS scan in the same patient shows the lesions "peppering" the pons. Note cephalad extension into the cerebral peduncles ⇨ and inferior extension into the medulla ⇨ and upper cervical cord ⇨. DSA (not shown) was negative. The lesions resolved with corticosteroids, so this is a presumed case of CLIPPERS.*

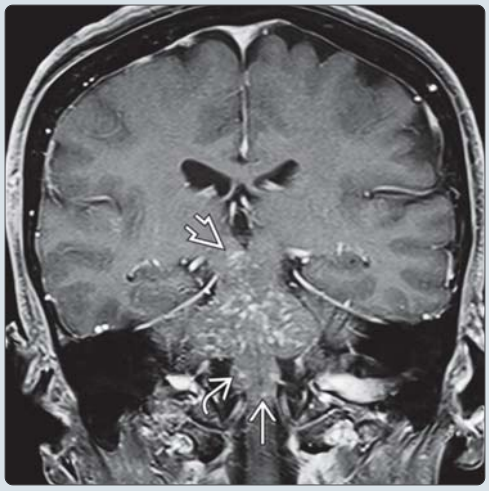

https://CafePezeshki.IR

TERMINOLOGY

Abbreviations

- Chronic lymphocytic inflammation with pontine perivascular enhancement responsive to steroids (CLIPPERS)

Definitions

- Recently described inflammatory CNS disorder
- Predominantly involving brainstem, adjacent rhombencephalic structures
- Clinical, imaging response to glucocorticosteroids

IMAGING

General Features

- Best diagnostic clue
  - Enhancing punctate/curvilinear lesions "peppering" the pons
    - May exhibit subtle radiating pattern
- Location
  - Predominately pons
  - May extend laterally into cerebellar peduncles or hemispheres
  - Caudally into medulla, spinal cord
  - Rostrally into midbrain
  - Sometimes involves basal ganglia, cerebral WM
  - May begin as isolated, enhancing mass in pons/cerebellar peduncle before exhibiting typical pattern of multifocal punctate pontine lesions
- Morphology
  - Typically small, punctate or curvilinear

CT Findings

- Usually normal

MR Findings

- T1WI
  - Usually normal
  - Pontocerebellar/cerebellar, cord, cerebral atrophy may be late changes
- T2WI
  - ± faint, patchy or "speckled" punctate hyperintensities on T2/FLAIR
  - Minimal or no mass effect, vasogenic edema
- T2* GRE
  - May show blooming foci
- T1WI C+
  - Punctate &/or curvilinear enhancing foci ("peppering the pons")

Angiographic Findings

- DSA normal without evidence for vasculitis

Imaging Recommendations

- Best imaging tool
  - MR ± contrast (include coronal T1C+), DWI, T2*

DIFFERENTIAL DIAGNOSIS

Lymphoma, Angiocentric (Intravascular)

- Hemorrhage, foci of restricted diffusion common

Neurosarcoidosis

- Dura, leptomeningeal lesions common

Demyelinating Disease

- MS, ADEM

Vasculitis

- PACNS; ANCA, polyarteritis nodosa, Churg-Strauss
- Systemic vasculitides (SLE, RA)

Glioblastoma

- Primary brainstem GBM rare in adults

Lymphomatoid Granulomatosis

- Brain often more diffusely involved

Paraneoplastic Syndromes

Neuromyelitis Optica/NMO Spectrum Disorders

- Brain less commonly involved; AqP4(+) common

CNS Histiocytosis

- Langerhans cell, Erdheim-Chester, hemophagocytic lymphohistiocytosis

PATHOLOGY

General Features

- Etiology
  - Immune-mediated inflammation (precise etiology unknown)

Microscopic Features

- Perivascular tropism with adjacent parenchymal inflammatory infiltrate

CLINICAL ISSUES

Presentation

- Most common signs/symptoms
  - Brainstem symptoms, gait ataxia, diplopia
  - Systemic symptoms common

Demographics

- Age
  - Mean age at onset 40-50 years (reported range 13-86 years)
- Gender
  - Both; slight male preponderance

Natural History & Prognosis

- Generally subacute presentation
  - Often relapsing-remitting course (without treatment)
- Diagnosis of exclusion
  - Requires careful exclusion of alternative diagnoses

Treatment

- Corticosteroids (clinical, imaging response key to diagnosis)

SELECTED REFERENCES

1. Gul M et al: Atypical Presentation of CLIPPERS Syndrome: A New Entity in the Differential Diagnosis of Central Nervous System Rheumatologic Diseases. J Clin Rheumatol. 21(3):144-8, 2015

https://CafePezeshki.IR

This page intentionally left blank

https://CafePezeshki.IR

PART I
SECTION 9

Inherited Metabolic/Degenerative Disorders

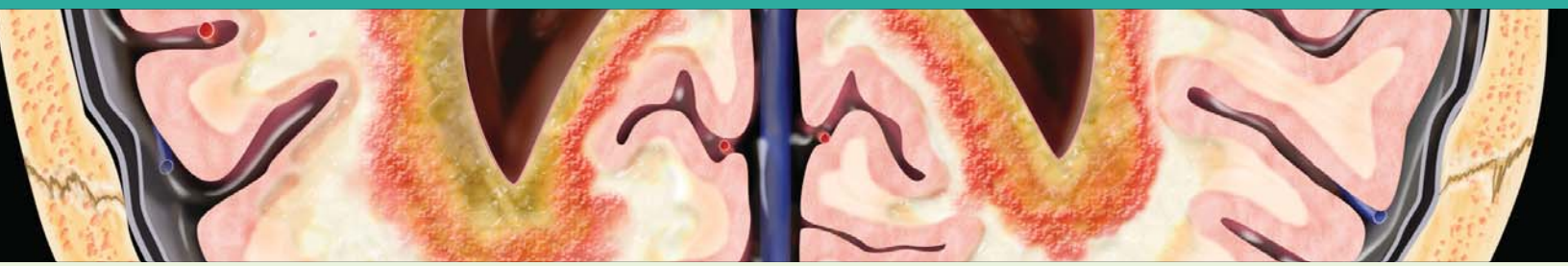

Inherited Metabolic Disorders Overview 774

Normal Variants

Hypomyelination 778

Mitochondrial Disorders

Leigh Syndrome 782
MELAS 786
Kearns-Sayre Syndrome 790

Lysosomal Disorders

Mucopolysaccharidoses 792
Gangliosidosis (GM2) 796
Metachromatic Leukodystrophy (MLD) 800
Krabbe 804
Fabry Disease 808

Peroxisomal Disorders

Zellweger Syndrome Spectrum 810
X-Linked Adrenoleukodystrophy 812
Other Peroxisomal Disorders 816

Organic and Aminoacidopathies

Maple Syrup Urine Disease 820
Urea Cycle Disorders 824
Glutaric Aciduria Type 1 826
Canavan Disease 830
Alexander Disease 832
Miscellaneous Organic/Aminoacidopathies 836

Miscellaneous

Megalencephaly With Leukoencephalopathy and Cysts (MLC) 838
Neurodegeneration With Brain Iron Accumulation (NBIA) 842
PKAN 844
Huntington Disease 848
Wilson Disease 852

https://CafePezeshki.IR

Overview

Inherited metabolic disorders (IMD) are very difficult to diagnose. Affected patients can present at any age; symptoms vary depending upon age of onset and severity of the biochemical defect. Completely different parts of the brain may be involved in less severely affected patients as compared to more severely affected patients. The same enzyme may perform different functions, in different parts of the brain, as the person matures from infancy to childhood to adulthood. Clearly, patients will have different symptoms if different parts of the brain are involved.

Adding to the confusion, IMDs have been **classified** in many different ways: Biochemical characteristics, the biochemical pathway that is affected, the cellular organelle in which the affected protein or affected biochemical pathway is located, characteristics of clinical presentation, and the gene that is affected. None of these classifications have been very successful, and it is likely that classification by the biochemical pathways affected will, ultimately, be the most useful.

The imaging features of inherited metabolic disorders can be equally confusing, particularly if not approached methodically. The imaging appearances of many disorders overlap and often vary with the stage and the variant of the disease. Imaging is most helpful early in the course of the disease, when it can help to narrow the differential diagnosis and reduce the amount of testing needed. From a neuroimaging perspective, it is most useful to classify disorders based on the **pattern of brain involvement on MR early in the course of the disease**. This pattern can be supplemented by the use of metabolic data (obtained from proton MR spectroscopy), diffusion data (obtained from diffusion-weighted imaging), and, occasionally, magnetization transfer.

First Analysis: White vs. Gray Matter

The first important determination is whether the disease involves primarily gray matter, primarily white matter, or both gray and white matter.

If the gray matter is primarily involved, scrutinize both the cortex and deep nuclei to determine whether involvement is primarily cortical, primarily deep nuclear, or both. Sometimes disorders that primarily affect cortical gray matter will show cortical swelling with effaced sulci early in the course of the disease; more commonly, diagnosis is made later and cortical thinning is found, with prominent cortical sulci, In later stages, cortical thinning is the rule in all such disorders. The cerebral white matter will often have an abnormal appearance in patients with primary cortical disorders, as Wallerian degeneration of axons causes diminished white matter volume and sometimes mild hyperintensity on FLAIR and T2-weighted images. This appearance can be differentiated from that of primary white matter disorders if the study is performed early in the course of the disease; primarily affected white matter will typically be edematous and, therefore, brighter and more voluminous (causing compressed, smaller sulci) than the white matter that has undergone secondary degeneration. In the acute phase, disorders primarily affecting deep gray matter will typically show edema (FLAIR hyperintensity and prolonged T1 and T2 relaxation times) in the involved structures. In the chronic phase, volume loss with gliosis (resulting in T2 hyperintensity) is more typical.

Disorders primarily affecting white matter cause marked signal abnormality before any volume loss is apparent. Some white matter disorders cause spongiform changes, result in intramyelinic edema, or have an inflammatory component in the early stages. These conditions cause edema with accompanying mass effect upon adjacent structures. Diffusion-weighted images can add specificity as spongiform changes typically cause increased diffusivity, while intramyelinic edema and inflammation cause reduced diffusivity. Alternatively, many white matter disorders, such as X-linked adrenoleukodystrophy and fibrinoid leukodystrophy (Alexander disease), start locally and expand to involve adjacent areas. Neither of these appearances are seen in the white matter of gray matter disorders. White matter diseases can result in necrosis and cavitation of the affected regions and subsequent ex vacuo dilation of the ventricles, whereas the abnormal white matter in gray matter disorders appears less severely damaged.

Gray Matter Disorders

Gray matter disorders need to be further analyzed to determine whether the disorder primarily involves the cerebral cortex or the deep gray matter nuclei. If the pattern of the imaging study indicates that the metabolic disorder is **primarily one of cortical involvement** (cortical thinning with enlarged cortical sulci), consideration should be given to disorders such as the neuronal ceroid lipofuscinoses, the mucolipidoses, glycogen storage diseases, or GM1 gangliosidosis.

When **only deep gray matter is involved**, it is important to identify the specific structures that are affected and their signal intensities. Involvement of the striatum (caudate and putamen) is typically seen in mitochondrial disorders (primarily Leigh syndrome, mitochondrial encephalopathy with lactic acidosis and stroke-like symptoms [MELAS], and the glutaric acidurias), propionic acidemia, Wilson disease, juvenile Huntington disease, molybdenum cofactor deficiency, asphyxia, and childhood or adult hypoglycemia.

Associated white matter or cortical injury may be present in many disorders. If globi pallidi show isolated T2 prolongation, succinate semialdehyde dehydrogenase deficiency, methylmalonic academia (cavitation of globi pallidi), guanidinoacetate methyltransferase deficiency (a creatine synthesis disorder), isovaleric acidemia, pyruvate dehydrogenase deficiency (due to mutation of the dihydrolipoamide acetyltransferase [E2] component), carbon monoxide poisoning, or the chronic phase of kernicterus should be considered. If T2 or FLAIR hyperintensity of the globi pallidi is associated with subcortical white matter demyelination, sparing of the periventricular white matter, and involvement of the cerebellar dentate nuclei, L-2-hydroxyglutaricaciduria and Kearns-Sayre syndrome should be considered. When the MR shows atrophy of the dorsal brainstem, cerebellar nuclei, and subthalamic nuclei, one should consider Leigh syndrome secondary to *SURF1* mutation. If T1 hyperintensity of the globi pallidi is associated with normal T2 signal, and the patient is not receiving hyperalimentation, consider chronic hepatic disease. If both T1 and T2 hyperintensity are seen in a neonate or young infant, consider acute hyperbilirubinemia of infancy, systemic lupus erythematosus, and hemolytic-uremic syndrome; in the presence of edema involving the external and extreme capsules and the claustrum, hemolytic-uremic syndrome is the most likely. If the globi pallidi, the insula, and perirolandic

https://CafePezeshki.IR

cortex are all hyperintense on T2-weighted or FLAIR images, the diagnosis of hyperammonemia (frequently due to a urea cycle disorder) should be suggested. If the involvement of the globus pallidus is manifested on MR as T2 hypointensity with central T2 hyperintensity, the diagnosis of pantothenate kinase-associated neuropathy (formerly called Hallervorden-Spatz disease) can be made with some confidence.

White Matter Disorders

White matter disorders can be divided into disorders in which white matter never myelinates completely (**hypomyelination**) and disorders in which myelin forms and breaks down (demyelination) with or without cavitation of white matter. The pattern of a lack of myelination, or hypomyelination, is seen in very few disorders, called the hypomyelinating leukoencephalopathies. These should be differentiated from delayed myelination, which has a very different differential diagnosis. If a follow-up MR in 6 months shows no change or minimal change in myelination, a hypomyelinating disorder can be diagnosed. The appearance of the brain in these disorders is often that of a normal, much more immature brain. For example, the MR of a 5-year-old child with hypomyelination might be mistaken for that of a 5-month-old infant; diffusivity is normal, while magnetization transfer is reduced. Such disorders include Pelizaeus-Merzbacher and like diseases, leukodystrophies with trichothiodystrophy and photosensitivity, Tay syndrome, 18q syndrome (deletion of a large portion of the long arm of chromosome 18), sialic acidemia (Salla disease), hypomyelination with atrophy of basal ganglia and cerebellum, and hypomyelination with congenital cataracts. Cerebral or cerebellar atrophy may develop over time in many of these patients.

When myelin develops but is subsequently damaged, the condition is called **demyelination** to differentiate it from breakdown of abnormal myelin, sometimes called **dysmyelination**. By the use of diffusion tensor imaging, it may eventually be possible to differentiate these 2 entities, but the differentiation cannot currently be made. Myelin destruction can, however, be differentiated from white matter cavitation (cystic degeneration). Cystic degeneration has much lower signal on FLAIR sequences, significantly less magnetization transfer, and greater diffusivity than areas of myelin destruction without cavitation. In disorders where inflammation is associated with demyelination (typically peroxisomal disorders), the inflammatory infiltrate causes reduced diffusivity and blood-brain barrier breakdown (resulting in regions of contrast enhancement). When myelin breakdown occurs, the white matter becomes more hypointense on T1-weighted images and more hyperintense on T2-weighted images. In these situations, analyze the brain to determine whether the region primarily affected is the periventricular white matter, the deep white matter, or the subcortical white matter.

Disorders Affecting Gray and White Matter

Disorders involving both gray and white matter are first separated by the type of gray matter involvement: Those involving only the cerebral cortex and those involving deep gray matter (with or without cortical involvement).

Disorders involving only cortical gray matter can be subdivided depending on the involvement of long bones and the spinal column. If the long bones are normal, the cortex should be analyzed for malformations of cortical development (MCD). If an MCD is present in addition to a lack of myelination, the differential diagnosis includes the generalized peroxisomal disorders, congenital cytomegalovirus disease, and the so-called cobblestone cortical malformations. If no MCD is found, differential considerations include Alpers disease and Menkes disease, both of which cause considerable cerebral cortical destruction. If the bones are abnormal, the differential diagnoses include primarily storage diseases, such as the mucopolysaccharidoses and lipid storage disorders.

If deep gray matter is involved, determine precisely which nuclei are affected. If thalami are involved, differential considerations include Krabbe disease and the GM1 and GM2 gangliosidoses; the thalami in these disorders display high attenuation on CT and short T1 and T2 relaxation times (hyperintense on T1-weighted images and hypointense on T2-weighted images) on MR. Krabbe disease is distinguished by the early presence of abnormal T2 hyperintensity along the corticospinal tracts and in the cerebellar dentate nuclei.

Another disorder with thalamic involvement is profound neonatal hypoxic-ischemic injury, which typically involves the ventrolateral thalami, posterior putamina, and perirolandic cortex; a characteristic history of perinatal distress and neonatal encephalopathy simplifies the diagnosis. Another consideration when thalamic involvement is identified is autosomal dominant acute necrotizing encephalitis, particularly if T2 hyperintensity is also seen in the dorsal brainstem. Thalami may also be affected in mitochondrial disorders, Wilson disease, and Canavan disease; typically other deep gray matter nuclei will be affected as well (e.g., putamina in mitochondrial disorders and Wilson disease, globi pallidi in Canavan disease). Globus pallidus involvement in association with diffuse white matter disease including the subcortical, deep, and periventricular regions suggests a diagnosis of Canavan disease, particularly if associated with macrocephaly. Association of globus pallidus involvement with affected subcortical white matter but sparing of periventricular white matter suggests a later phase of Kearns-Sayre syndrome or L-2-hydroxyglutaric aciduria; the latter will often show involvement of the cerebellar dentate nuclei.

Globus pallidus injury with sparing of subcortical white matter in early stages suggests methylmalonic academia (look for cavitation), maple syrup urine disease, carbon monoxide toxicity, or cyanide toxicity. MR of maple syrup urine disease during the acute neonatal phase of the disease shows involvement of the centrum semiovale, internal capsules, cerebral peduncles, dorsal pons, and cerebellar white matter, reduced diffusivity in the affected regions, and a peak at 0.9 ppm on proton MR spectroscopy. Carbon monoxide and cyanide toxicity typically involve the cerebral cortex, globi pallidi, and cerebellum. White matter disease associated with striatal involvement suggests Leigh syndrome, MELAS, propionic acidemia, glutaric aciduria type 1, molybdenum cofactor deficiency, isolated sulfite oxidase deficiency, hypomyelination with atrophy of the basal ganglia and cerebellum, toxic exposure, later infantile or childhood profound hypoxic-ischemic injury, or childhood hypoglycemia. Proper analysis of the MR scans using this pattern system can facilitate the work-up of patients with inborn errors of metabolism.

https://CafePezeshki.IR

Imaging Patterns

Metabolic Disorders With
T2 or FLAIR Hyperintensity of the Corpus Striatum
Leigh syndrome (includes pyruvate dehydrogenase deficiency, respiratory complex I and complex II disorders)
Wilson disease
Glutaric aciduria type 1
Juvenile Huntington disease
Molybdenum cofactor deficiency
Propionic acidemia
T2 or FLAIR Hyperintensity of Globi Pallidi
Methylmalonic acidemia
Succinic semialdehyde dehydrogenase deficiency
Urea cycle disorders
Guanidinoacetate methyltransferase deficiency
Pyruvate dehydrogenase (E2) deficiency
Systemic lupus erythematosus
Hemolytic-uremic syndrome
Bilirubin toxicity
Isovaleric acidemia
Carbon monoxide or cyanide toxicity
Early Involvement of Subcortical White Matter
Alexander disease
Kearns-Sayre syndrome
Galactosemia
Mitochondrial disorders
Early Involvement of Periventricular and Deep White Matter With Sparing of Subcortical White Matter
X-linked adrenoleukodystrophy
Krabbe disease (globoid cell leukodystrophy)
Metachromatic leukodystrophy
GM2 gangliosidoses
Childhood ataxia with CNS hypomyelination (vanishing white matter disease)
Merosin-deficient congenital muscular dystrophy with cortical malformation
Damage from radiation or chemotherapy
Globus Pallidus and White Matter Involvement
Canavan disease
Methylmalonic acidemia
Kearns-Sayre syndrome
L-2-hydroxyglutaric aciduria
Maple syrup urine disease
Carbon monoxide or cyanide poisoning
Striatal (Caudate and Putaminal) and White Matter Involvement
Leigh syndrome
Mitochondrial encephalopathy with lactic acidosis and stroke-like symptoms (MELAS)
Other mitochondrial leukoencephalopathies
Propionic acidemia
Glutaric acidemia type 1
Isolated sulfite oxidase deficiency
Late infantile/childhood profound hypoxic-ischemic injury
Childhood hypoglycemia

https://CafePezeshki.IR

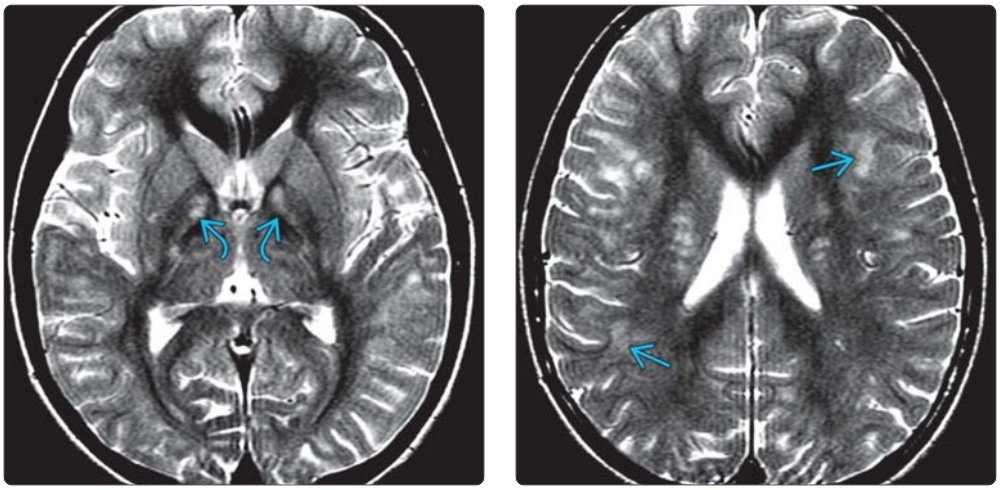

(Left) *Axial T2WI MR in a patient with Kearns-Sayre syndrome shows bilateral globus pallidus hyperintensity* ⇨. **(Right)** *More cephalad T2WI MR in the same case shows involvement of subcortical white matter* ⇨ *with sparing of periventricular regions.*

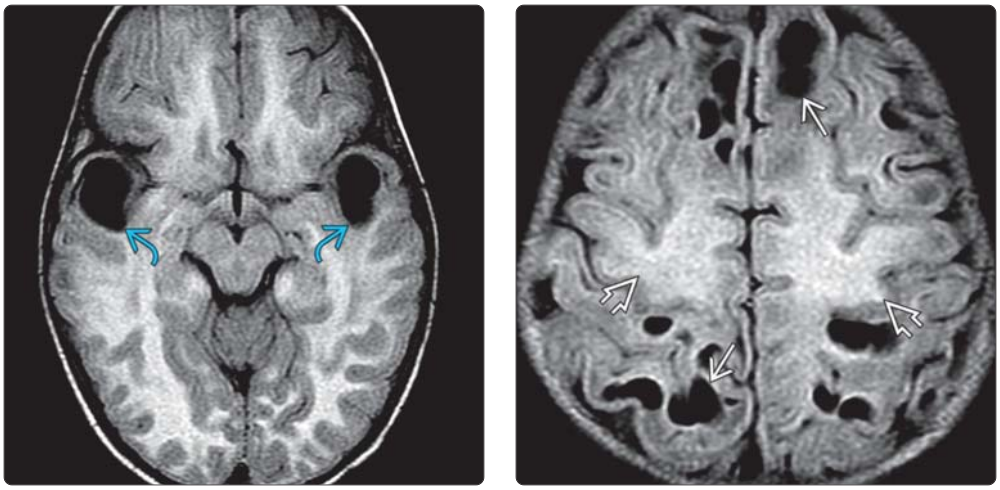

(Left) *Axial FLAIR MR in a 22-month-old child with macrocephaly and decreasing acquisition of developmental milestones shows large, bilateral temporal lobe cysts* ⇨ *typical of megalencephaly with leukoencephalopathy and cysts (MLC). The hypomyelinated white matter is swollen and diffusely hyperintense.* **(Right)** *Axial FLAIR MR in a 2-year-old child with MLC shows swollen, hyperintense hypomyelinated WM* ➡ *and numerous subcortical cysts* ➡.

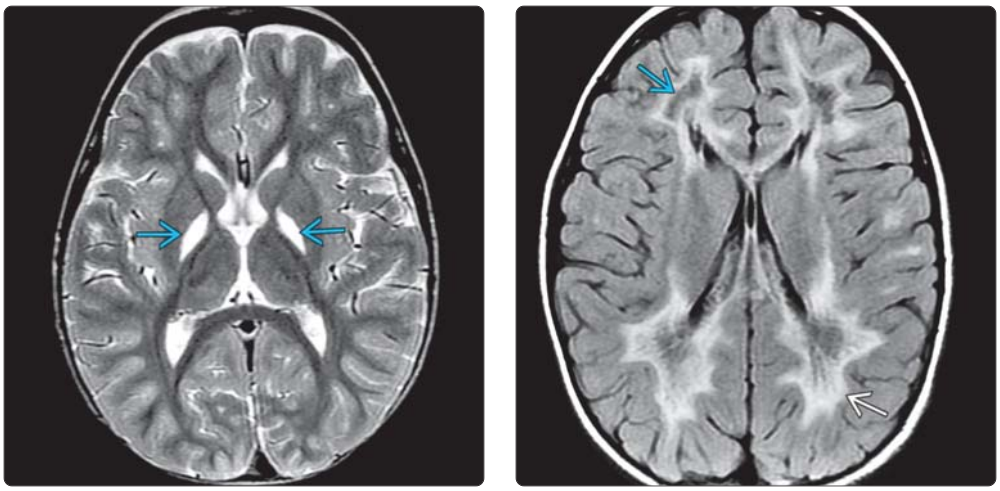

(Left) *Axial T2WI MR in a child with methylmalonic acidemia shows abnormal hyperintensity* ⇨ *of the bilateral globi pallidi. The white matter is unaffected in this patient.* **(Right)** *Axial FLAIR MR shows multiple areas of hypointense cavitation* ⇨ *in the cerebral white matter in this patient with vanishing white matter disease. The less affected subcortical white matter* ➡ *is hyperintense.*

https://CafePezeshki.IR

KEY FACTS

TERMINOLOGY

- Diminished or absent degree of white matter (WM) myelination for age
- May be primary hypomyelination syndrome or secondary to other pathology

IMAGING

- T1 shortening reflects presence of mature oligodendrocytes with proteolipid protein
  - Myelination on T1WI is complete by 1 year of age
- T2 shortening reflects displacement of interstitial water by myelin wrapping on axons
  - Myelination on T2WI is complete by 3 years of age, usually by 2 years of age

TOP DIFFERENTIAL DIAGNOSES

- Hypomyelinating leukodystrophies (Pelizaeus-Merzbacher disease, 4H syndrome)
- Mucopolysaccharidoses, mitochondrial encephalopathies
- Gray matter disease with secondary myelin loss

PATHOLOGY

- Hypomyelination often reflects impaired oligodendrocyte maturation/survival
  - Immature oligodendrocytes do not produce myelin
  - Without myelin, axons are not properly nourished

DIAGNOSTIC CHECKLIST

- Hypomyelination does not have bright T2/FLAIR signal like dys- or demyelination
- Define degree of myelination by age at which it would be appropriate → "degree of myelination appropriate for x months of age"
  - Assess myelination prior to learning chronologic age of patient

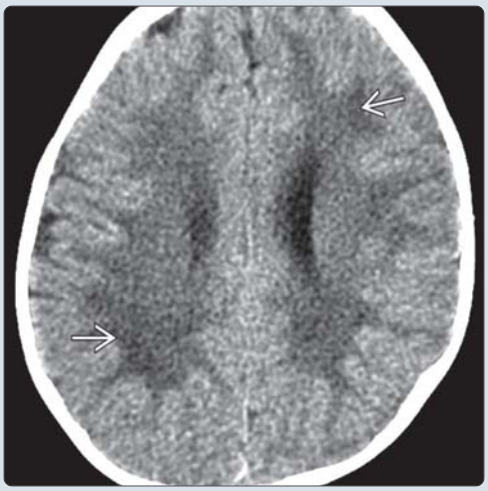

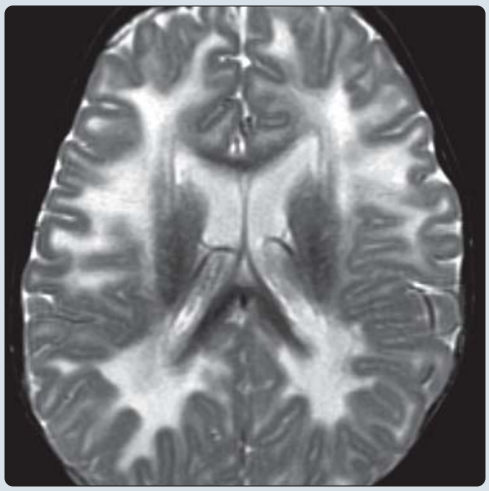

(Left) *Axial NECT in a 1 year old with Jacobsen syndrome (11q-chromosomal deletion) shows irregular hypoattenuation that is most severe in the subcortical cerebral white matter* ⇨. **(Right)** *Axial T2WI MR in the same patient confirms that the decreased attenuation on CT correlates with marked and diffuse hypomyelination. Hypomyelination has been described in numerous chromosomal deletion syndromes, although the prevalence is difficult to gauge.*

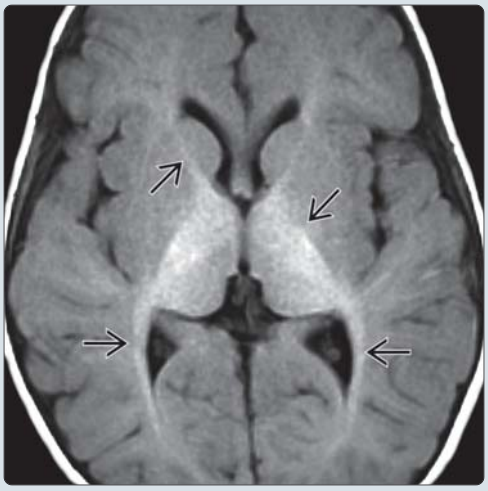

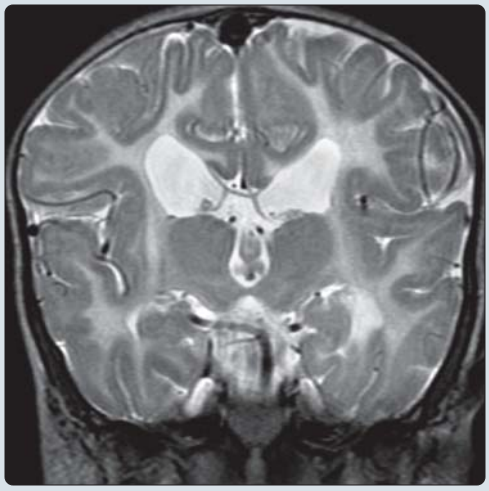

(Left) *Axial T1WI MR in a 9 month old with 18q-syndrome shows only faint T1 shortening that is limited to the internal capsules and optic radiations* ⇨. *At 9 months, only the most distal rami of white matter should be without bright signal on T1WI.* **(Right)** *Coronal T2WI MR in a 14 year old shows hypomyelination and atrophy of the basal ganglia and cerebellum (H-ABC). Note absence of visible caudate nuclei and corpus callosum in addition to the abnormal hyperintense signal of unmyelinated white matter.*

https://CafePezeshki.IR

TERMINOLOGY

Synonyms

- Delayed myelin maturation, undermyelination

Definitions

- Diminished or absent degree of white matter (WM) myelination for age
- Myelin "milestones" not achieved
- May be primary hypomyelination syndrome or secondary to other pathology

IMAGING

General Features

- Best diagnostic clue
  - Poor gray-white differentiation on T1WI in children > 1 year
  - Poor gray-white differentiation on T2WI in children > 2 years
- Location
  - Key areas to assess are internal capsule, pyramidal tracts, and peripheral frontal lobe WM rami
- Size
  - Hypomyelination will result in reduced brain volume
    - Thin corpus callosum evident on sagittal images
- Morphology
  - Typically normal

CT Findings

- NECT
  - Lack of myelin generally too subtle to identify on CT

MR Findings

- T1WI
  - Myelinated WM is hyperintense
    - T1 shortening reflects presence of mature oligodendrocytes with proteolipid protein
  - WM structures become hyperintense in stereotypical order
  - Myelination on T1WI is essentially complete by age 1 year
- T2WI
  - Myelinated WM is hypointense
    - T2 shortening reflects displacement of interstitial water by myelin wrapping on axons
  - Hypointensity on T2WI lags hyperintensity on T1WI by 4-8 months
  - Myelination on T2WI is complete by 3 years of age (usually by 2 years of age)
  - "Terminal zones"
    - Regions of persistent hyperintense signal on T2WI in otherwise normal brains
    - Typically around trigones of lateral ventricles
    - Likely due to concentration of interstitial water migrating to ventricles in these areas
    - Must be distinguished from periventricular leukomalacia or perivascular spaces
- PD/intermediate
  - Key for distinguishing gliosis from undermyelination
    - Gliosis is more hyperintense
- FLAIR
  - Not recommended in children < 2 years
    - Heterogeneous signal makes assessment of myelination and distinction of pathology more difficult
- DWI
  - ADC values predate T1- and T2-weighted signal changes
    - ADC, radial diffusivity decrease with maturation
  - Fractional anisotropy increases with brain maturation
- T1WI C+
  - Some leukodystrophies have abnormal enhancement
    - Not strictly hypomyelination
- MRS
  - Choline decreases as myelination progresses
  - Relative increases in myoinositol, choline, and lipid resonances with hypomyelination
  - Significant increases in choline may indicate demyelination or dysmyelination

Imaging Recommendations

- Best imaging tool
  - MR
- Protocol advice
  - T1WI most helpful in children < 10 months
  - T2WI most helpful in children > 10 months

DIFFERENTIAL DIAGNOSIS

Primary Hypomyelination Syndromes

- Pelizaeus-Merzbacher disease (PMD)
- Spastic paraplegia type 2 (SPG2)
- 18q-syndrome
- *TUBB4A*-related hypomyelinating disorders (with or without atrophy of basal ganglia &/or cerebellum)
- 4H syndrome (hypomyelination, hypodontia, hypogonadotropic hypogonadism)
- Oculodentodigital dysplasia
- Hypomyelination with congenital cataracts
- Hypomyelination with brainstem, spinal cord involvement/leg spasticity
- Fucosidosis
- Sialic acid storage disease
- Aicardi-Goutieres syndrome

Prematurity

- Use of normal milestones assumes full-term gestation
- Adjust chronologic age for degree of prematurity

External Stresses

- Chronic debilitating conditions in infancy
  - Congenital vascular malformations (AVF)
  - Malnutrition
- Treatments for diseases in neonate
  - Organ transplantation
  - Chemotherapy
- Myelination typically rebounds with treatment of primary illness

Syndromes With Hypomyelination and Other Findings

- Typically cause dysmyelination, not hypomyelination
- Mucopolysaccharidoses
  - Hunter, Hurler

https://CafePezeshki.IR

- Mitochondrial encephalopathies
  - Electron transport chain (ETC) defects
  - Mitochondrial membrane abnormalities
- Leukodystrophies
  - Metachromatic leukodystrophy
  - Globoid leukodystrophy (Krabbe)
- Trichothiodystrophy
  - Group of disorders of DNA repair
  - Osteosclerosis of axial skeleton
  - "Tiger-band hair" under polarized light
- Neurodegenerative disorders
  - Neuronal ceroid lipofuscinoses may have hypomyelination as cortical degeneration proceeds

PATHOLOGY

General Features

- Etiology
  - Hypomyelination often reflects deficiency of mature oligodendrocytes
  - Duplication of *PLP1* gene causes folded protein response, oligodendrocyte death
    - Result is nearly complete absence of myelin
  - Nutritional disorders, neurodegeneration are other causes
- Genetics
  - 10-30% of PMD and SPG2 caused by defects in proteolipid protein (*PLP*) gene (Xq21-q22)
  - 18q-syndrome causes hemizygous deletion (1 copy of gene missing) of *MBP* gene
- Associated abnormalities
  - Craniofacial-facial malformations associated with 18q-syndrome
  - PMD and 18q-syndrome are prototypes of hypomyelination

Microscopic Features

- Pelizaeus-Merzbacher disease
  - Diffuse myelin deficiency: Looks like much less mature brain
  - Islands of persistent perivascular myelin result in classic tigroid appearance
  - Absent or deficient compact myelin sheaths, "redundant myelin balls"

CLINICAL ISSUES

Presentation

- Most common signs/symptoms
  - Developmental delay, hypotonia
- Other signs/symptoms
  - Classic PMD: Head titubation, hypotonia, only 50% able to sit
  - 18q-syndrome: Developmental delays, short stature, delayed bone age, limb anomalies
  - Trichothiodystrophy: Short stature, osteosclerosis

Demographics

- Age
  - Primary hypomyelination syndromes typically present in infancy
- Gender
  - Classic PMD is X-linked recessive and thus exclusive to males
  - Other forms of PMD are autosomal recessive and equally distributed

Natural History & Prognosis

- Late progression of symptoms may occur in some

Treatment

- No treatment yet for heritable disorders of hypomyelination

DIAGNOSTIC CHECKLIST

Consider

- Hypomyelination may be difficult to distinguish from dys- and demyelination
- Remember to adjust chronologic age for degree of prematurity when imaging infants

Image Interpretation Pearls

- Assess myelination prior to learning chronologic age of patient
  - Avoid predetermination bias
- Correlate imaging findings with clinical history and neurological exam to narrow scope of differential

Reporting Tips

- Define degree of myelination by age at which it would be appropriate → "degree of myelination appropriate for x months of age"

SELECTED REFERENCES

1. Andronikou S et al: Corpus callosum thickness in children: an MR pattern-recognition approach on the midsagittal image. Pediatr Radiol. 45(2):258-72, 2015
2. Mayer JA et al: Modeling the natural history of Pelizaeus-Merzbacher disease. Neurobiol Dis. 75:115-30, 2015
3. Takanashi JI: Neurochemistry of Hypomyelination Investigated with MR Spectroscopy. Magn Reson Med Sci. ePub, 2015
4. Numata Y et al: Epidemiological, clinical, and genetic landscapes of hypomyelinating leukodystrophies. J Neurol. 261(4):752-8, 2014
5. Pizzino A et al: TUBB4A de novo mutations cause isolated hypomyelination. Neurology. 83(10):898-902, 2014
6. Pouwels PJ et al: Hypomyelinating leukodystrophies: translational research progress and prospects. Ann Neurol. 76(1):5-19, 2014
7. Steenweg ME et al: Novel hypomyelinating leukoencephalopathy affecting early myelinating structures. Arch Neurol. 69(1):125-8, 2012
8. Steenweg ME et al: Magnetic resonance imaging pattern recognition in hypomyelinating disorders. Brain. 133(10):2971-82, 2010
9. Schiffmann R et al: Invited article: an MRI-based approach to the diagnosis of white matter disorders. Neurology. 72(8):750-9, 2009
10. Rossi A et al: Hypomyelination and congenital cataract: neuroimaging features of a novel inherited white matter disorder. AJNR Am J Neuroradiol. 29(2):301-5, 2008
11. Barkovich AJ: Myelin mishaps. Ann Neurol. 62(2):107-9, 2007
12. van der Knaap MS et al: Hypomyelination with atrophy of the basal ganglia and cerebellum: follow-up and pathology. Neurology. 69(2):166-71, 2007
13. van der Voorn JP et al: Childhood white matter disorders: quantitative MR imaging and spectroscopy. Radiology. 241(2):510-7, 2006

https://CafePezeshki.IR

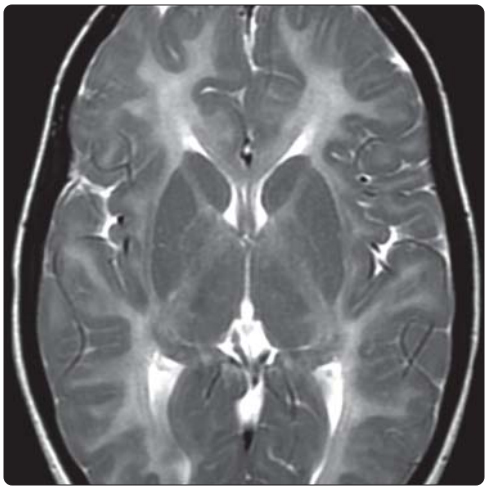

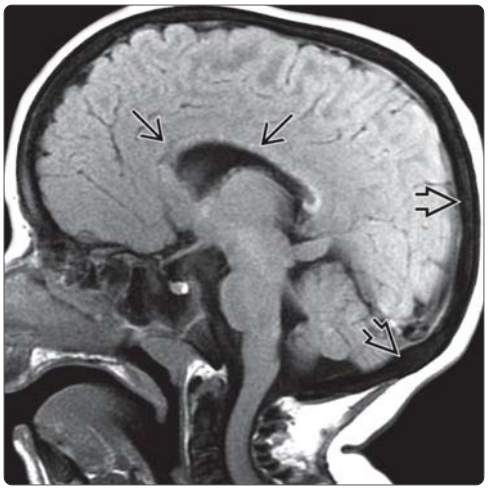

(Left) *Axial T2WI MR in this 12 year old with trichothiodystrophy shows essentially complete absence of myelination throughout the brain. Examination of the hair under polarized light demonstrated characteristic "tiger-tail" bands, and radiographs showed central osteosclerosis.* **(Right)** *Sagittal T1WI MR in the same child shows absence of myelin deposition throughout the brain, making the corpus callosum difficult to define on this midline image. Note the thickened skull posteriorly.*

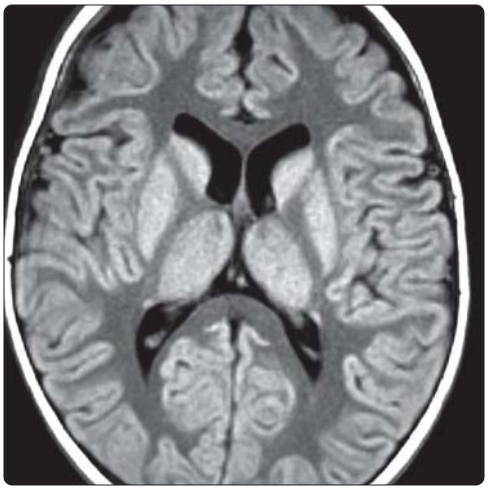

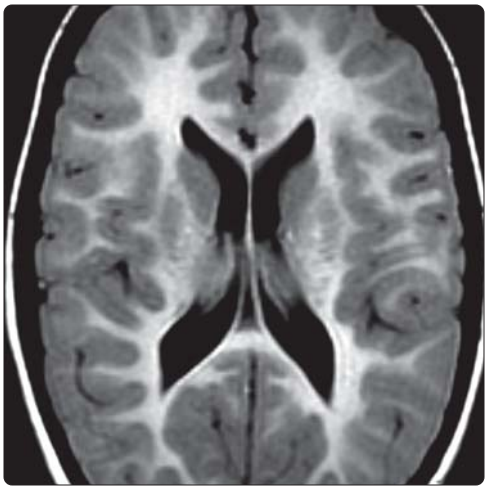

(Left) *Axial T1WI MR shows a 26 month old with nystagmus and head titubation, diagnosed with Pelizaeus-Merzbacher disease. The homogeneous absence of myelin deposition causes the appearance to mimic a normal FLAIR image in a mature brain.* **(Right)** *Conversely, this axial FLAIR image in a 6 year old with Pelizaeus-Merzbacher disease resembles a normal T1WI, with hyperintense signal of the white matter relative to gray matter throughout.*

(Left) *Axial T1WI MR in a 2 year old with nystagmus shows minimal T1 shortening in the posterior limb of internal capsule (PLIC); myelination should appear complete on T1WI at this age. Chromosomal analysis showed a mutation of PLP, confirming a diagnosis of Pelizaeus-Merzbacher disease.* **(Right)** *Axial T2WI MR in a 14 month old with an arteriovenous fistula shows hypointense signal of myelin maturation in the genu and internal capsules only. Concomitant illness is a common cause of delayed myelin maturation.*

https://CafePezeshki.IR

KEY FACTS

TERMINOLOGY

- Genetically heterogeneous mitochondrial disorder characterized by progressive neurodegeneration

IMAGING

- Best imaging: MR with DWI/MRS
  - Bilateral, symmetric ↑ T2/FLAIR corpora striata (putamen > caudate) > globi pallidi (GP), periaqueductal gray matter (PAG), substantia nigra/subthalamic nuclei, dorsal pons, cerebellar nuclei
  - Reduced diffusion in regions of acute disease
  - Lactate peak often present; may be large
  - Uncommon appearance: Predominant WM disease (simulates leukodystrophy)

TOP DIFFERENTIAL DIAGNOSES

- Profound perinatal asphyxia
- Mitochondrial encephalopathy, lactic acidosis, stroke-like episodes (MELAS)
- Glutaric aciduria type 1 (GA1)
- Wilson disease

PATHOLOGY

- Bioenergetic failure (ATP loss) and production of reactive oxygen species likely key factors in mitochondria-mediated cell apoptosis
- 50-75% of patients with LS have detectable biochemical or molecular abnormality

CLINICAL ISSUES

- Presentation: Psychomotor delay/regression, hypotonia
- Prenatal diagnosis: Chorionic villus sampling (mutations and biochemical defects)
- Majority present by age 2 years

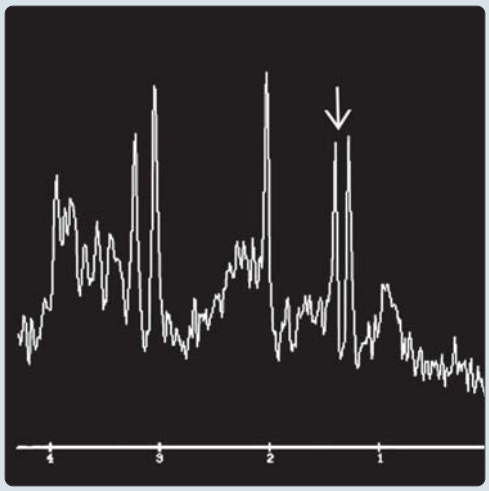

(Left) *Axial FLAIR MR shows swelling and abnormal hyperintensity in the caudate heads and putamina. Foci of hyperintensity are also present in the medial thalami, a typical location of involvement in Leigh syndrome.* **(Right)** *Single voxel proton MR spectroscopy (TE = 26 ms) of the same patient shows a large lactate doublet at 1.3 ppm. The identification of a lactate peak supports the diagnosis of mitochondrial disease, but is variably present.*

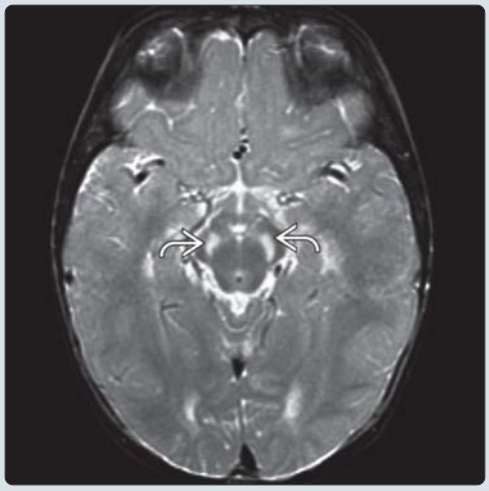

(Left) *Axial T2WI MR shows T2 hyperintensity and some swelling of the lentiform nuclei bilaterally. In addition, the genu and splenium of the corpus callosum are affected. Note that foci of unaffected tissue are present in the putamina; heterogeneous involvement is common.* **(Right)** *Axial T2WI MR in the same patient shows T2 hyperintensity of the cerebral peduncles. This is another common site of involvement in Leigh syndrome.*

https://CafePezeshki.IR

TERMINOLOGY

Abbreviations

- Leigh syndrome (LS)

Synonyms

- Subacute necrotizing encephalomyelopathy

Definitions

- Genetically heterogeneous mitochondrial disorder characterized by progressive neurodegeneration

IMAGING

General Features

- Best diagnostic clue
  - Bilateral, symmetric, ↑ T2/FLAIR putamina and periaqueductal gray matter (PAG)
- Location
  - Common
    - Basal ganglia (BG): Corpora striata (putamina > caudate heads) > globi pallidi (GP)
    - Brainstem (BS): PAG, substantia nigra/subthalamic nuclei, pons, medulla
    - Thalami, dentate nuclei
  - Infrequent: White matter (WM) (cerebral > cerebellar, may be cavitary), spine, cortical gray matter
- Size
  - BS: Small, discrete foci (< 1 cm)
    - Involvement of central WM tracts typical
  - BG: Involvement of posterior putamina classic but variable; may affect entire lentiform nuclei
  - Thalami: Focal involvement of dorsomedial nuclei classic but variable
- Morphology
  - Except WM, lesions are bilaterally symmetric
  - Edema, expansion characteristic of early disease; volume loss characteristic of late disease
    - PAG edema may cause hydrocephalus
  - Involvement of lower BS (pons, medulla) and lack of BG involvement characteristic of LS secondary to *SURF1* mutation
  - Uncommon appearance
    - Predominant WM disease (simulates leukodystrophy)

CT Findings

- NECT
  - Hypodense; occasionally normal
- CECT
  - Enhancement uncommon

MR Findings

- T1WI
  - Hypointense
    - Variable foci hyperintensity = blood or necrosis
- T2WI
  - Hyperintense
- FLAIR
  - Hyperintense
    - Resolution of signal abnormality or cystic encephalomalacia (hypointense) may be seen in chronic disease
- DWI
  - Reduced diffusion in regions of acute disease
- MRS
  - ↑ choline, ↓ NAA
  - Lactate peak often present; may be large

Ultrasonographic Findings

- Hyperechoic deep gray structures, WM

Imaging Recommendations

- Best imaging tool
  - MR with DWI/MRS

DIFFERENTIAL DIAGNOSIS

Profound Perinatal Asphyxia

- ↑ T2 & T1 dorsolateral putamina, lateral thalami, dorsal BS, perirolandic cortex
  - T2 hyperintensity difficult to identify in unmyelinated brain
  - T1 hyperintensity seen subacutely (3-10 days)
- History of perinatal asphyxia

Mitochondrial Encephalopathy, Lactic Acidosis, Stroke-Like Episodes (MELAS)

- ↑ T2/FLAIR putamina (Ca++ in chronic disease)
  - May be asymmetric or unilateral
- Stroke-like signal abnormality in parietooccipital lobes
  - Nonvascular distribution and (-) DWI typical

Glutaric Aciduria Type 1 (GA1)

- ↑ T2/FLAIR corpora striata, GP, ± WM disease
- Characteristic opercular widening

Wilson Disease

- ↑ T2/FLAIR putamina, GP, midbrain, thalami
  - T2 changes evident in older children, teens
- T1-hyperintense GP 2° to hepatic failure

PATHOLOGY

General Features

- Etiology
  - Exact mechanistic relationship between mitochondrial dysfunction and neurodegeneration unknown
  - Bioenergetic failure (ATP loss) and production of reactive oxygen species likely key factors in mitochondria-mediated cell apoptosis
  - Coenzyme Q10 deficiency and mitochondrial depletion also implicated in LS
- Genetics
  - LS characterized by extreme genetic heterogeneity
  - Autosomal recessive (AR), X-linked, and maternal inheritance of mutated proteins involved in mitochondrial energy production
    - Mutations frequently involve electron transport chain complexes (COs) I-V
    - AR: Mutation of *SURF1* gene (9q34) is most frequent cause of LS due to CO IV (cytochrome C oxidase, COX) deficiency

https://CafePezeshki.IR

  - Other AR mutations: *NDUFV1/NDUFS8* (11q13), *NDUFS4* (5q11.1), *NDUFS7* genes → CO I deficiency; *NDUFS3* gene → NADH dehydrogenase deficiency; *SDHA* gene (5p15) → CO II deficiency; *BCS1L* gene (2q33) → CO III deficiency, and non-*SURF1* mutations → COX deficiency
  - X-linked: *PDHA1* gene (Xp22.2-p22.1) → pyruvate dehydrogenase CO deficiency
  - Maternally inherited (mtDNA mutations): *MT-ATP6* gene → CO V deficiency (causes LS if mutation load > 90%), NARP (neuropathy, ataxia, retinitis pigmentosa) if load 70-90%); *MT-ND5*, *MT-ND6* genes → CO I deficiency; *MT-CO3* gene → COX deficiency; *MT-TK*, *MT-TV* tRNA genes
- Associated abnormalities
  - 50-75% of patients with LS have detectable biochemical or molecular abnormality
  - Embryology-anatomy
    - Main role of mitochondria = production of ATP via oxidative phosphorylation
    - Mitochondria contain own DNA (mtDNA, average of 5 mtDNA per mitochondrion)
    - mtDNA contribution to zygote exclusively from oocyte (maternal inheritance)
    - Mitochondria/mtDNA randomly distributed among daughter cells
    - mtDNA & nuclear DNA (nDNA) encode subunits of electron transport chain complexes (COs) I, III-V; nDNA encodes subunits CO II
  - Brain & striated muscle highly dependent on oxidative phosphorylation → most severely affected in mitochondrial disorders
  - Variable number of mitochondria/cell, random distribution of mitochondria/mtDNA into daughter cells → phenotypic heterogeneity typical of all mitochondrial disorders

Gross Pathologic & Surgical Features

- Brownish-gray, gelatinous or cavitary foci in corpora striata, GP, BS, dentate nuclei, thalami, spinal cord, white matter

Microscopic Features

- Spongiform degeneration, gliosis, neuronal loss, demyelination, capillary proliferation

CLINICAL ISSUES

Presentation

- Most common signs/symptoms
  - Presentation: Psychomotor delay/regression, hypotonia
    - LS is a clinical diagnosis; many mitochondrial disorders can cause it
  - Other signs/symptoms
    - Progressive BS & BG dysfunction
      - Ataxia, ophthalmoplegia, ptosis, vomiting, swallowing and respiratory difficulties, dystonia
  - Early presentation, BS dysfunction, peripheral neuropathy, & rapid neurologic deterioration typical of LS 2° to *SURF1* mutation
  - Metabolic stressors (e.g., infection) may unmask disease or cause deterioration
  - Elevated CSF, serum, urine lactate classic but not invariable
  - Clinical diagnosis
    - Progressive neurodegeneration
    - Signs/symptoms of BS & BG dysfunction
    - ↑ lactate in blood + CSF
    - Biochemical defect identified by mitochondrial analysis of muscle biopsy or cultured skin fibroblasts
    - MR → characteristic BG or BS lesions
  - Prenatal diagnosis: Chorionic villus sampling (mutations and biochemical defects)
- Clinical profile
  - Infant with psychomotor regression, hypotonia

Demographics

- Age
  - Majority present by age 2
  - Childhood & adult presentations uncommon
- Gender
  - No predilection
- Ethnicity
  - No predilection
- Epidemiology
  - Mitochondrial disorders = 1:8,500
  - LS in children < 6 years = 1:32,000 (most common mitochondrial disease in this age group)

Natural History & Prognosis

- Natural history: Progressive neurodegeneration leading to respiratory failure and death in childhood
- Prognosis: Dismal (particularly *SURF1*); childhood/adult LS more slowly progressive

Treatment

- No curative treatment
- Potential role of antioxidants and inhibitors in mtDNA replication

DIAGNOSTIC CHECKLIST

Image Interpretation Pearls

- Putaminal involvement classic but variable
- Thalamic and PAG involvement simulates Wernicke encephalopathy; however, mammillary bodies spared in Leigh syndrome
- Only brainstem involvement in *SURF1* mutations

SELECTED REFERENCES

1. Simon M et al: Mutations of human NARS2, encoding the mitochondrial asparaginyl-tRNA synthetase, cause nonsyndromic deafness and Leigh syndrome. PLoS Genet. 11(3):e1005097, 2015
2. Baertling F et al: A guide to diagnosis and treatment of Leigh syndrome. J Neurol Neurosurg Psychiatry. 85(3):257-65, 2014
3. Krishna SH et al: Congenital genetic inborn errors of metabolism presenting as an adult or persisting into adulthood: neuroimaging in the more common or recognizable disorders. Semin Ultrasound CT MR. 35(2):160-91, 2014
4. Sonam K et al: Clinical and magnetic resonance imaging findings in patients with Leigh syndrome and SURF1 mutations. Brain Dev. 36(9):807-12, 2014
5. Lee IC et al: SURF1-associated Leigh syndrome: a case series and novel mutations. Hum Mutat. 33(8):1192-200, 2012
6. Cakmakci H et al: Diagnostic value of proton MR spectroscopy and diffusion-weighted MR imaging in childhood inherited neurometabolic brain diseases and review of the literature. Eur J Radiol. 74(3):e161-71, 2010
7. Friedman SD et al: The use of neuroimaging in the diagnosis of mitochondrial disease. Dev Disabil Res Rev. 16(2):129-35, 2010
8. Lee HF et al: Leigh syndrome: clinical and neuroimaging follow-up. Pediatr Neurol. 40(2):88-93, 2009

https://CafePezeshki.IR

(Left) *Axial T2WI FSE MR in an infant with hypotonia and encephalopathy shows hyperintensity of caudate heads and putamina. Note involvement of most posterior putamina. Central putamina have increased hyperintensity.* **(Right)** *Axial ADC map in the same patient shows that the caudate heads and most of the affected putamina have reduced diffusivity, whereas the central putamina have increased diffusivity, indicating prior injury with cavitation.*

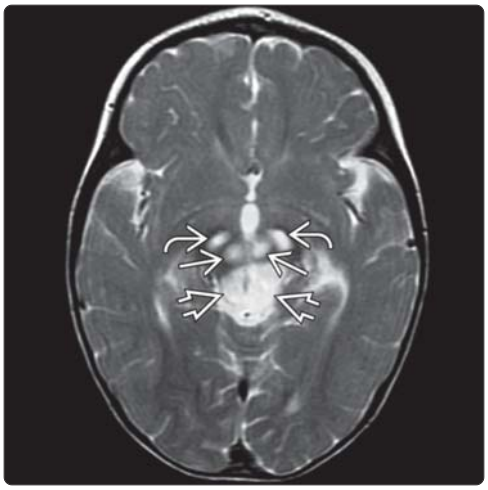

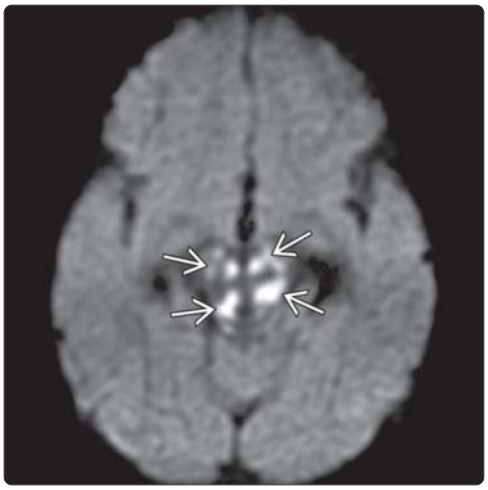

(Left) *Axial T2WI MR shows hyperintensity of cerebral peduncles, red nuclei, and midbrain tegmentum (including periaqueductal gray matter). These are common locations of brainstem involvement in Leigh syndrome.* **(Right)** *Axial DWI MR shows reduced diffusivity (hyperintense areas) in portions of the affected midbrain. The reduced diffusivity indicates acute injury, while normal or increased diffusivity indicates more chronic injury.*

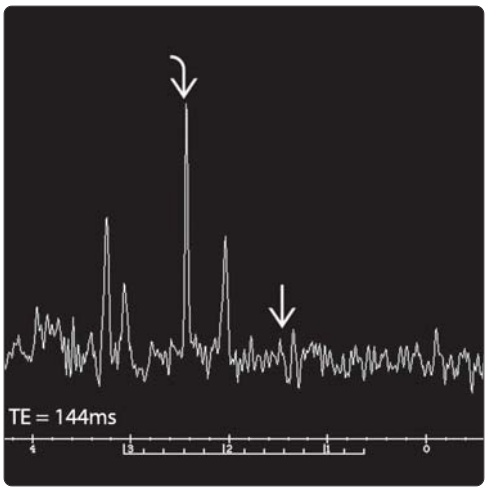

(Left) *Axial T2WI MR shows hyperintensity in the callosal genu and splenium, which extends into the periventricular and deep white matter, as well as the posterior limbs of the internal capsules.* **(Right)** *Single voxel proton MRS (TE = 144 ms) in the same patient shows minimal lactate at 1.33 ppm and an abnormal peak at 2.4 ppm, which corresponds to succinate. The diagnosis was succinate dehydrogenase deficiency from SDHA mutation.*

https://CafePezeshki.IR

KEY FACTS

TERMINOLOGY

- Mitochondrial myopathy, encephalopathy, lactic acidosis, and stroke-like episodes (MELAS)
- Inherited disorder of intracellular energy production caused by point mutation in mtDNA

IMAGING

- Stroke-like cortical lesions crossing vascular territories
  - Posterior location most common
- "Shifting spread" (appearance, disappearance, reappearance elsewhere) is classic
- Lactate (Lac) "doublet" at 1.3 ppm in 60-65%
  - Elevated lactate in CSF, "normal" brain on MRS
- Basal ganglia (BG) lesions and calcifications

PATHOLOGY

- mtDNA contribution to zygote exclusively maternal inheritance
- Caution: Relationship of phenotype to genotype complex, variable
- Mutations may present as MELAS but also as other mitochondrial phenotypes

CLINICAL ISSUES

- Classic MELAS triad: Lactic acidosis, seizures, stroke-like episodes
  - Onset of stroke-like episodes usually occurs in childhood/early adulthood
  - Also: Sensorineural hearing loss, diabetes, short stature

DIAGNOSTIC CHECKLIST

- Think MELAS in patient with acute stroke-like cortical lesion that crosses usual vascular territories
- Consider MELAS in adult presenting with unusual and recurrent stroke-like episodes

(Left) *Axial graphic shows pathology of MELAS. The acute onset of gyriform cortical swelling that crosses vascular territories is depicted ⇨. Note old lacunes, generalized/focal atrophy.* **(Right)** *Axial FLAIR MR in an 8-year-old girl with short stature and new-onset stroke-like symptoms reveals a focus of abnormally increased signal intensity in the right thalamus ⇨ and extensive hyperintensity and abnormal thickening of the cerebral cortex ⇨ in the right occipital lobe. The underlying WM is largely spared.*

(Left) *Axial T2WI MR in the same patient shows similar abnormal signal hyperintensity lesions in the same thalamic focus of signal increase ⇨ and in the edematous right occipital cortex ⇨. Note the prominent subarachnoid spaces, which may result from malnutrition, medications, or the disease process itself.* **(Right)** *Axial DWI MR demonstrates reduced diffusion in the affected regions of the brain ⇨, confirming the acuity of the lesion.*

https://CafePezeshki.IR

TERMINOLOGY

Abbreviations

- Mitochondrial myopathy, encephalopathy, lactic acidosis, and stroke-like episodes (MELAS)

Definitions

- Inherited disorder of intracellular energy production caused by point mutations in mitochondrial DNA (mtDNA)

IMAGING

General Features

- Best diagnostic clue
  - Acute: Stroke-like cortical lesions
    - "Shifting spread" (appearance, disappearance, reappearance elsewhere) is classic
    - Lesions cross typical vascular territories
- Location
  - Stroke-like: Parietooccipital > temporoparietal
  - Calcifications: Basal ganglia (BG)
- Size
  - Variable, progressive, multifocal
- Morphology
  - Acute: Gyral swelling
  - Chronic: Supra- and infratentorial atrophy, deep white matter (WM), & BG lacunar infarcts

CT Findings

- NECT
  - Symmetric BG calcification
- CECT
  - Variable gyral enhancement

MR Findings

- T1WI
  - Acute: Swollen gyri, compressed sulci
  - Subacute: Band of cortical hyperintensity consistent with laminar necrosis
  - Chronic: Progressive atrophy of BG, temporal-parietal-occipital cortex with preservation of hippocampal, entorhinal structures
- T2WI
  - Acute: Hyperintense cortex/subcortical WM
  - Chronic: Multifocal BG, deep WM hyperintensities
- FLAIR
  - Infarct-like swelling and mass effect
- T2* GRE
  - No hemorrhage; SWI may show cortical hypointensity
- DWI
  - Acute: DWI positive, ADC variable
- T1WI C+
  - Acute: Gyral enhancement
- MRA
  - Often normal; may show cerebral artery vasodilatation, hyperperfusion in acute states
- MRS
  - Lactate (Lac) "doublet" at 1.3 ppm in 60-65%
  - Caution: Lac presence variable
    - Lac may be elevated in CSF but not brain (measure ventricular Lac)
    - Lac not always elevated and may precede imaging changes of brain
    - Other causes of elevated CNS Lac (e.g., hypoxia, ischemia, neoplasm, infection) must be excluded

Angiographic Findings

- Conventional
  - Acute: Dilated cortical arteries, prominent capillary blush without arterial occlusion

Nuclear Medicine Findings

- SPECT
  - Acute: Tc-99m-HMPAO SPECT shows striking increase in tracer accumulation

Other Modality Findings

- Xenon CT shows focal hyperperfusion during acute stroke-like episode, hypoperfusion later
- Electromyographic findings consistent with myopathy found in majority of cases
- EEG may show focal periodic epileptiform discharges

Imaging Recommendations

- Best imaging tool
  - MR with multivoxel MRS
- Protocol advice
  - Confirm lactate in normal regions of brain

DIFFERENTIAL DIAGNOSIS

Myoclonic Epilepsy With Ragged-Red Fibers (MERRF)

- Propensity for BG, caudate nuclei
- Watershed ischemia/infarcts common

Leigh Disease

- Mutations commonly involve electron transport chain complexes (COs) I-V
- Subacute necrotizing encephalomyopathy
- *SURF1* gene mutation
  - Involvement of subthalamic nuclei, lower brainstem characteristic

Kearns-Sayre Syndrome (KSS)

- Ataxia, ophthalmoplegia, retinitis pigmentosa
- Diffuse symmetric Ca++ in BG, caudate nuclei, subcortical WM
- Hyperintense BG on T1 & T2WI; cerebellar WM, posterior columns of medulla often involved

Status Epilepticus

- May cause transient gyral swelling, enhancement
- No Lac elevation in normal unaffected brain, CSF

Maternally Inherited Diabetes and Deafness (MIDD)

- Also *A3243G* mutation of mitochondrial DNA
- Diabetes mellitus, sensorineural hearing loss, short stature, ± spontaneous abortion
- No stroke-like episodes
- NECT: Diffuse atrophy and BG calcification

PATHOLOGY

General Features

- Etiology

https://CafePezeshki.IR

- Pathophysiology remains unclear
  - Impaired oxidative cerebral metabolism
  - Mitochondrial angiopathy of small cerebral arteries, arterioles, capillaries
- May also be hyperperfusion, vasogenic edema with blood-brain barrier disruption during acute stroke-like episodes
- Genetics
  - mtDNA contribution to zygote exclusively maternal inheritance
  - Caution: Relationship of phenotype to genotype complex, variable
    - Mutations may present as MELAS, but also as other phenotypes
      - *MTT1*: A-to-G translation at nucleotide 3243 of mtDNA most common
    - Polygenetic: *MTTQ*, *MTTL1*, *MTTH*, *MTTK*, *MTTC*, *MTTS1*, *MTND1*, *MTND5*, *MTND6*, *MTTS2*
    - MELAS overlap syndromes with Leigh syndrome, MERRF, KSS, others
- Associated abnormalities
  - Some cortical malformations associated with *A3243G* mutations

Gross Pathologic & Surgical Features

- Diffuse generalized atrophy
- Multiple focal cortical, deep WM/BG infarcts
- Prominent mineralization of BG

Microscopic Features

- Trichrome stain shows increased numbers of ragged-red fibers in skeletal/cardiac muscle
- Perivascular Ca++ in both gray matter (GM), WM may occur
- Immunohistochemistry: COX(+) ragged-red fibers (may help distinguish from MERRF)
- Electron microscopy: Swelling, increase in number of dysfunctional mitochondria in smooth muscle, endothelial cells of small arteries, and pial arterioles

CLINICAL ISSUES

Presentation

- Most common signs/symptoms
  - Triad: Lactic acidosis, seizures, stroke-like episodes
  - Common: Sensorineural hearing loss, diabetes, short stature
  - Cognitive deficits, depression, psychosis, dementia
  - Ataxia, muscle weakness (myopathy), peripheral neuropathy
  - Acute-onset headache, migraines, episodic vomiting, intermittent dystonia, alternating hemiplegia
- Other signs/symptoms
  - Heteroplasmy and random mitotic mtDNA segregation, tissue-to-tissue variability → phenotypic heterogeneity and "overlap" with other mitochondrial syndromes
    - Cardiac: Cardiomyopathy, cardiac conduction defects
    - Ocular findings: Scotomata, hemianopsia, ophthalmoplegia, maculopathy (progressive macular retinal pigment epithelial atrophy)
    - Renal dysfunction (including Fanconi syndrome and focal segmental glomerular sclerosis)
    - GI dysmotility, gastroparesis, intestinal pseudo-obstruction
- Clinical profile
  - Older child or young adult with muscle weakness and epilepsy or acute stroke-like syndrome

Demographics

- Age
  - Onset of stroke-like episodes usually occurs in childhood/early adulthood
    - Mean age onset = 15 years
    - 90% symptomatic by 40 years
- Epidemiology
  - Uncommon but important cause of stroke in pediatric cases
  - Carrier prevalence of *m.3243A > G* mutation 0.6% or 60 per 100,000 individuals
  - Incidence (Finland): *3243A > G* =18.4 per 100,000 individuals

Natural History & Prognosis

- Recurrent stroke-like events with either permanent or reversible neurologic deficits
- Progressive course with periodic acute exacerbation

Treatment

- Cofactor and supplement therapy

DIAGNOSTIC CHECKLIST

Consider

- Think MELAS in patient with acute stroke-like cortical lesion that crosses usual vascular territories
- Consider MELAS in adult presenting with unusual and recurrent stroke-like episodes

Image Interpretation Pearls

- Obtain MRS in CSF, "uninvolved" brain

SELECTED REFERENCES

1. Finsterer J et al: Focal and Generalized Seizures May Occur in Mitochondrial Encephalomyopathy, Lactic Acidosis, and Strokelike Episodes (MELAS) Patients. J Child Neurol. ePub, 2015
2. Minobe S et al: Vasodilatation of multiple cerebral arteries in early stage of stroke-like episode with MELAS. J Clin Neurosci. 22(2):407-8, 2015
3. Rodan LH et al: Cerebral hyperperfusion and decreased cerebrovascular reactivity correlate with neurologic disease severity in MELAS. Mitochondrion. 22:66-74, 2015
4. Corr A et al: MELAS, an important consideration in the adult population presenting with unusual and recurrent stroke-like episodes. BMJ Case Rep. 2014, 2014
5. Prasad M et al: MELAS: A Multigenerational Impact of the MTTL1 A3243G MELAS Mutation. Can J Neurol Sci. 41(2):210-9, 2014
6. Sofou K et al: MRI of the brain in childhood-onset mitochondrial disorders with central nervous system involvement. Mitochondrion. 13(4):364-71, 2013
7. Goodfellow JA et al: Mitochondrial myopathy, encephalopathy, lactic acidosis and stroke-like episodes: an important cause of stroke in young people. Postgrad Med J. 88(1040):326-34, 2012
8. Friedman SD et al: The use of neuroimaging in the diagnosis of mitochondrial disease. Dev Disabil Res Rev. 16(2):129-35, 2010

https://CafePezeshki.IR

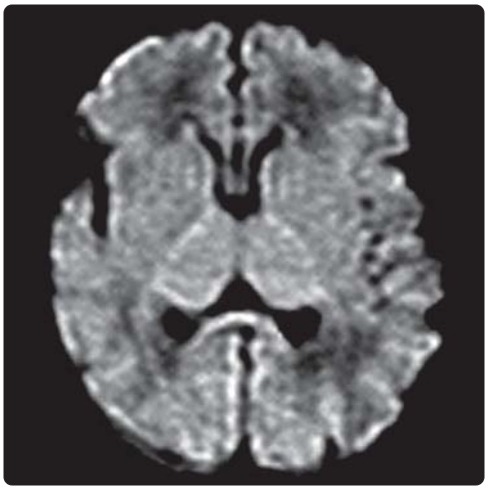

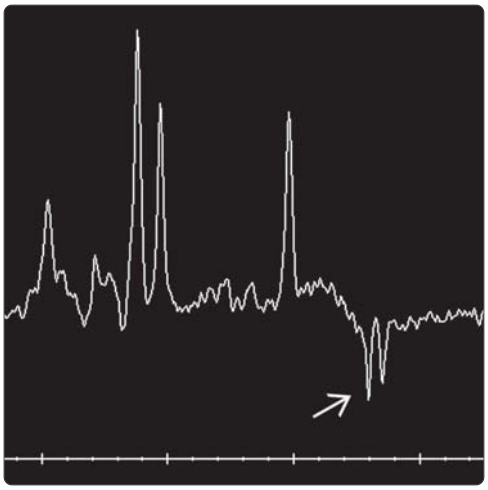

(Left) *Axial DWI MR in a 22-day-old girl with microcephaly and lactic acidosis is essentially normal; it fails to reveal any areas of reduced diffusion.* **(Right)** *Proton MRS with an echo time of 144 msec localized to the basal ganglia of the same patient confirms a lactate doublet ➡ at 1.3 ppm. Note that the lactate peak is inverted at an echo time of 135-144 msec. Proton MRS with this echo time can be a useful finding to distinguish lactate from lipid.*

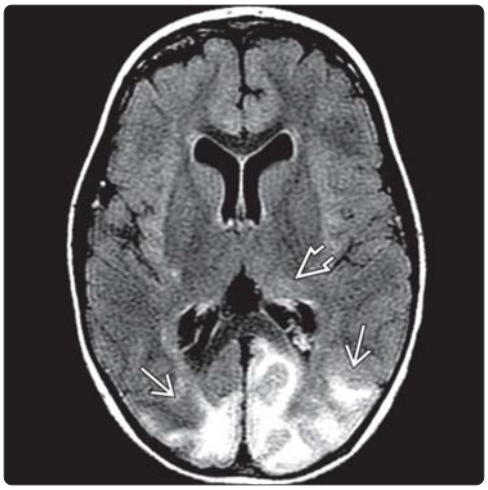

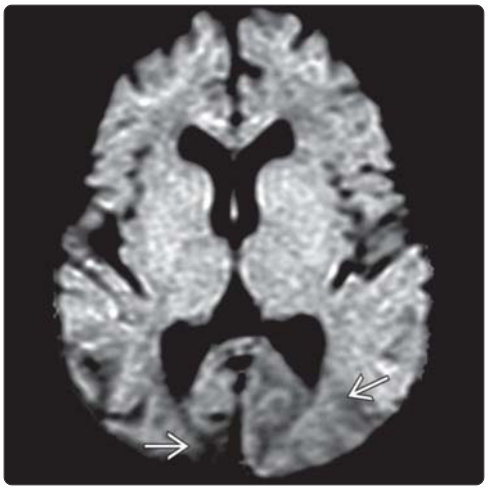

(Left) *Follow-up axial FLAIR MR in the same patient, now 3.5 years old, demonstrates a new subtle signal increase in the left thalamus ➡ as well as extensive new bilateral occipital cortical/subcortical hyperintensity and swelling ➡.* **(Right)** *Axial DWI MR shows hypointensity ➡ in the affected regions, indicating that the lesions are subacute. Proton MRS (not shown) showed the presence of lactate, often seen in the subacute phase.*

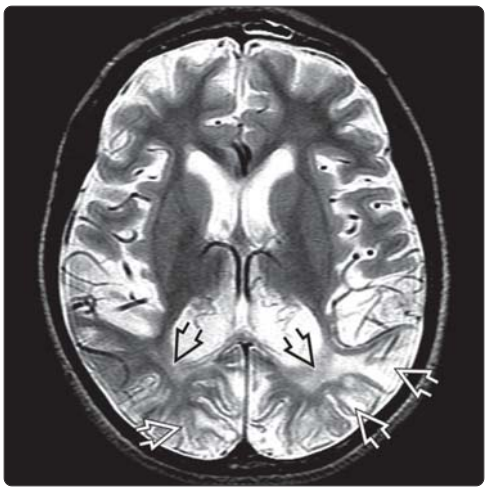

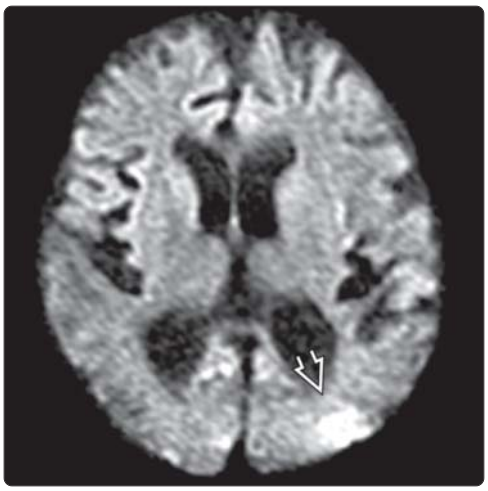

(Left) *Axial T2WI MR in a 12-year-old girl with longstanding diagnosis of MELAS reveals extensive volume loss in the cerebral cortex and subcortical white matter, in addition to increased signal intensity of peritrigonal white matter ⇨ and of the parietooccipital subcortical white matter/cortex ➡.* **(Right)** *Axial DWI MR in the same 12 year old demonstrates reduced diffusivity ➡ in the left occipital pole, indicating an acute exacerbation in superimposed upon chronic changes.*

https://CafePezeshki.IR

KEY FACTS

TERMINOLOGY

- Clinical phenotypes associated with single large-scale mtDNA deletions (SLSMDs)
  - Progressive external ophthalmoplegia (PEO)
  - Kearns-Sayre syndrome (KSS)
  - Pearson syndrome
    - Multisystem disorder characterized by bone marrow failure, pancreatic insufficiency
    - Children who survive develop KSS later in life
- Overlapping spectrum of disease
  - Multisystem disease with anemia, renal impairment, endocrine disturbance most frequent extraneurological features

IMAGING

- Diffuse symmetric Ca++ in BG on NECT
- ↑ T2 signal in peripheral subcortical WM, U-fibers, cerebellar WM, corpus callosum, globi pallidi, substantia nigra, posterior brainstem
- Early sparing of periventricular WM
- Occasional radial stripes in hyperintense WM

PATHOLOGY

- Polygenetic: Caused by various mtDNA rearrangements
- Status spongiosus, spongy myelinopathy
- Cerebellar atrophy
- Ragged-red fibers on muscle biopsy

CLINICAL ISSUES

- Common symptoms: Ophthalmoplegia, ataxia, retinitis pigmentosa, heart block present before 20 years old
- Additional symptoms: Dementia, sensorineural hearing loss, muscle weakness, short stature, diabetes
- Age of onset usually before 20 years
- Cardiac conduction problems may manifest during anesthetic care

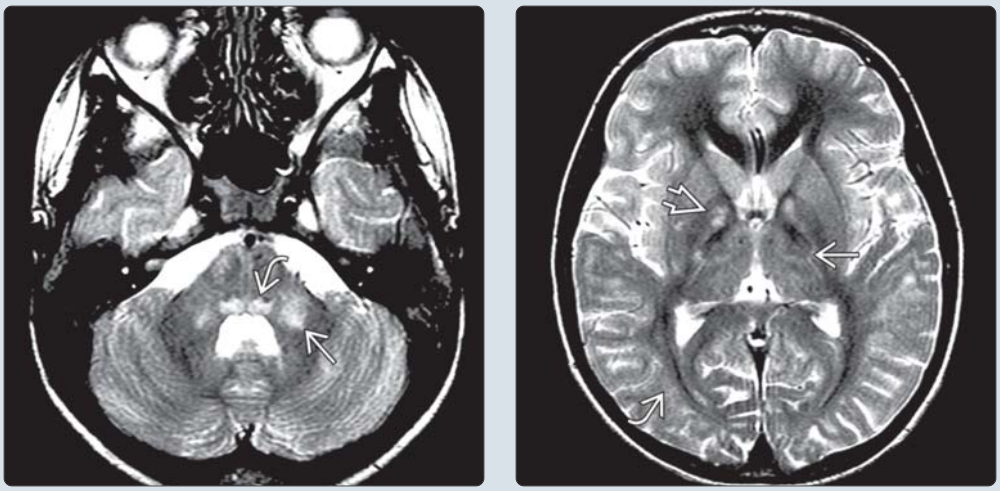

(Left) *Axial T2WI MR in a teenager with symptomatic Kearns-Sayre syndrome demonstrates abnormal increased signal intensity bilaterally in the brachium pontis ⇨ and the dorsal pons ⇨. Widening of the interfoliate sulci results from mild cerebellar atrophy.* **(Right)** *Axial T2WI MR in the same teenager demonstrates foci of abnormal signal bilaterally within the globi pallidi ⇨ and the corticospinal tracts ⇨. Note the subtle loss of myelin arborization into the subcortical U-fibers ⇨.*

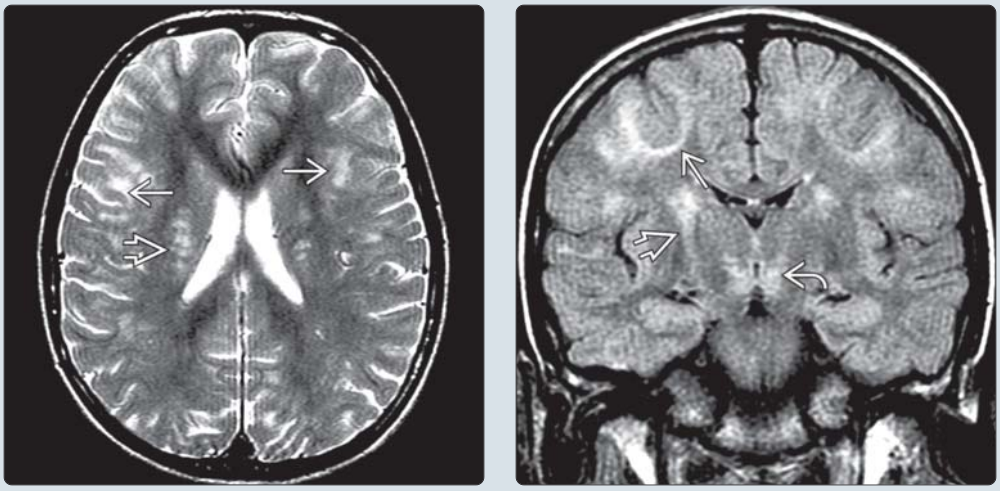

(Left) *Axial T2WI MR in the same teenager with symptomatic Kearns-Sayre syndrome reveals linear hyperintense white matter "stripes" in the corona radiata ⇨ and multifocal areas of abnormal hyperintense subcortical U-fibers ⇨. No lactate was identified on proton MRS (not shown) obtained at the same time as the routine MR imaging.* **(Right)** *Coronal FLAIR MR in the same patient shows abnormal hyperintense signal in corticospinal tracts ⇨, subcortical U-fibers ⇨, and thalami ⇨.*

https://CafePezeshki.IR

TERMINOLOGY

Definitions

- Clinical phenotypes associated with single large-scale mtDNA deletions (SLSMDs)
  - Progressive external ophthalmoplegia (PEO)
  - Kearns-Sayre syndrome (KSS)
  - Pearson syndrome
    - Multisystem disorder characterized by bone marrow failure, pancreatic insufficiency
    - Children who survive develop KSS later in life
- Overlapping spectrum of disease
  - Multisystem disease with anemia, renal impairment, endocrine disturbance most frequent extraneurological features

IMAGING

General Features

- Best diagnostic clue
  - Diffuse symmetric Ca++ BG
  - Hyperintense GP on T1 & T2WI
  - WM signal increase on T2/FLAIR involves subcortical WM
- Morphology
  - Spongy myelinopathy

CT Findings

- NECT
  - Basal ganglia calcifications

MR Findings

- T2WI
  - Occasional radial stripes in hyperintense WM
  - ↑ signal in peripheral subcortical WM, U-fibers, cerebellar WM, corpus callosum, globi pallidi, substantia nigra, posterior brainstem
  - Early sparing of periventricular WM
- DWI
  - Abnormal white matter (T2-DWI match) has reduced diffusion
  - DTI demonstrates brainstem white matter alterations

DIFFERENTIAL DIAGNOSIS

Other Mitochondrial (mtDNA) Deletion Syndromes

- MELAS
  - Stroke-like episodes
    - Parietooccipital lobe involvement common (rare in KSS)
  - Lactic acidosis
  - Seizures
- Chronic progressive external ophthalmoplegia (CPEO)
  - Upper eyelid ptosis
  - Progressive weakness of extraocular muscles
  - Normal imaging or atrophy common, lactate uncommon
    - Severe phenotype: Pyramidal tract T2/FLAIR hyperintensity
- Pearson marrow-pancreas syndrome
  - Refractory anemia, vacuolization of bone marrow cells, exocrine pancreatic dysfunction
  - Mild phenotype or progression to KSS

PATHOLOGY

General Features

- Genetics
  - Polygenetic: Caused by multiple mtDNA rearrangements
  - Identical mutations reported in KSS, MELAS, Pearson, and CPEO; however, mutant mtDNA tissue distribution is different in these disorders

Gross Pathologic & Surgical Features

- Status spongiosus, spongy myelinopathy
  - Spongy degeneration and vacuolization
- Cerebellar atrophy
- Ragged-red fibers on muscle biopsy

CLINICAL ISSUES

Presentation

- Most common signs/symptoms
  - Ophthalmoplegia, ataxia, retinitis pigmentosa, heart block
- Other signs/symptoms
  - Dementia, sensorineural hearing loss
  - Short stature, diabetes
  - Proximal muscle weakness, fatigue
  - ↑ CSF protein, ± ↑ lactate

Natural History & Prognosis

- Age of onset usually before 20 years
- Cardiac conduction problems may manifest during anesthetic care

Treatment

- Vitamins and cofactors
- Pacemaker or cochlear implant may be required

DIAGNOSTIC CHECKLIST

Image Interpretation Pearls

- White matter involvement spares periventricular WM, involves "subcortical U-fibers"
- SLSMDs should be considered in all children presenting with ptosis

SELECTED REFERENCES

1. Crippa BL et al: Biochemical abnormalities in Pearson syndrome. Am J Med Genet A. 167A(3):621-8, 2015
2. Mancuso M et al: Redefining phenotypes associated with mitochondrial DNA single deletion. J Neurol. ePub, 2015
3. Broomfield A et al: Paediatric single mitochondrial DNA deletion disorders: an overlapping spectrum of disease. J Inherit Metab Dis. ePub, 2014
4. Khambatta S et al: Kearns-Sayre syndrome: a case series of 35 adults and children. Int J Gen Med. 7:325-32, 2014
5. Duning T et al: Diffusion tensor imaging in a case of Kearns-Sayre syndrome: striking brainstem involvement as a possible cause of oculomotor symptoms. J Neurol Sci. 281(1-2):110-2, 2009
6. Wabbels B et al: [Chronic progressive external ophthalmoplegia and Kearns-Sayre syndrome : interdisciplinary diagnosis and therapy.] Ophthalmologe. 105(6):550-6, 2008
7. Yamashita S et al: Genotype and phenotype analyses in 136 patients with single large-scale mitochondrial DNA deletions. J Hum Genet. 53(7):598-606, 2008
8. Heidenreich JO et al: Chronic progressive external ophthalmoplegia: MR spectroscopy and MR diffusion studies in the brain. AJR Am J Roentgenol. 187(3):820-4, 2006
9. Hourani RG et al: Atypical MRI findings in Kearns-Sayre syndrome: T2 radial stripes. Neuropediatrics. 37(2):110-3, 2006

https://CafePezeshki.IR

KEY FACTS

TERMINOLOGY

- Mucopolysaccharidoses (MPS): 1-9
- Group of lysosomal storage disorders
  - Characterized by inability to break down glycosaminoglycans (GAGs)
  - Undegraded GAGs toxic, accumulate in multiple organs
  - Each type of MPS causes accumulation of particular GAG in lysosomes, extracellular matrix
  - 11 known enzyme deficiencies, resulting in 7 distinct forms of MPS
    - Prototype MPS = MPS 1H (Hurler)

IMAGING

- Perivascular spaces (PVS) dilated by accumulated GAG
- Favored sites of dilated VRS in MPS: Corpus callosum (CC), peritrigonal white matter (WM)
  - Can occur in other lobes
- Single to too many to count
- Dysostosis multiplex, broad ribs, trident hands
- Progressive odontoid dysplasia → risk atlantoaxial subluxation; some correction follows BMT

CLINICAL ISSUES

- Prognosis, deterioration rate depends upon specific enzyme deficiency
- Treatment: BMT or IV recombinant human enzyme (e.g., MPS 1H: α-L-iduronidase)
- Significant correlation exists between WM alterations and mental retardation

DIAGNOSTIC CHECKLIST

- Always visualize foramen magnum on any CNS study to seek CVJ compression
- Airway: Major sedation and anesthesia risk
- Not all MPS have typical facial features, dilated VRS may still signal less common MPS
- Look at upper cervical spine on sagittal images; aids in making diagnosis

(Left) *Axial graphic of a prototype mucopolysaccharidosis shows multiple dilated perivascular spaces that are radially oriented in the white matter of the brain. Note the posterior predominance and involvement of the corpus callosum.* **(Right)** *Axial T1WI MR in a toddler with MPS 1H demonstrates prominent perivascular spaces involving the white matter, including the corpus callosum. Note the posterior predominance of involvement, which is typical in MPS.*

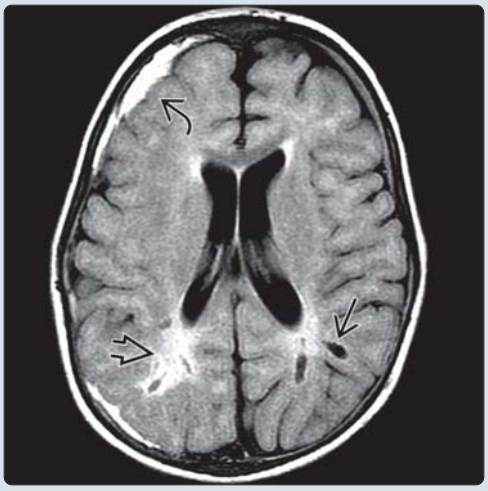

(Left) *Axial FLAIR MR in a male child with MPS 2 reveals a few dilated perivascular spaces surrounded by gliotic white matter. Note the unilateral subdural hematoma. Extraaxial bleeds, while uncommon, have been reported in MPS with vasculopathy, trauma, or large subdural effusions.* **(Right)** *Axial FLAIR MR in a different school-aged male with MPS 2 demonstrates dilated perivascular spaces, hyperintense white matter, and hydrocephalus. Note the typical anterior beaking.*

https://CafePezeshki.IR

TERMINOLOGY

Abbreviations

- Mucopolysaccharidoses (MPS)

Definitions

- Group of lysosomal storage disorders
  - Characterized by inability to break down glycosaminoglycans (GAGs)
  - Undegraded GAGs toxic, accumulate in multiple organs
  - Each type of MPS causes accumulation of particular GAG in lysosomes, extracellular matrix
  - 11 known enzyme deficiencies, resulting in 7 distinct forms of MPS
    - Prototype MPS = MPS 1H (Hurler)

IMAGING

General Features

- Best diagnostic clue
  - Perivascular spaces (PVS), a.k.a. Virchow-Robin spaces (VRS), dilated by accumulated GAG
- Location
  - Favored sites of dilated VRS in MPS: Corpus callosum (CC), peritrigonal white matter (WM)
    - Can occur in other lobes
- Size
  - Variably-sized dilated VRS, usually < 5 mm; occasional large obstructed VRS occur
  - Range: 1 to too many to count
- Morphology
  - Round, oval, spindle, parallel to veins

Radiographic Findings

- Radiography
  - Dysostosis multiplex, broad ribs, trident hands, J-shaped sella, "rosette" formation of multiple impacted teeth in single follicle

CT Findings

- NECT
  - Metopic beaking despite macrocrania
  - Macrocrania, ↓ density WM, dilated VRS rarely visible on CT
  - Progressive hydrocephalus **and** atrophy
    - MPS 1: Hydrocephalus is early finding in 25%
    - MPS 3B: Severe atrophy
- CECT
  - Enhancing pannus associated with ligaments and dura at craniocervical junction (CVJ)

MR Findings

- T1WI
  - Cribriform appearance WM, CC, basal ganglia (BG)
    - Dilated VRS filled with GAG: "Hurler holes"
    - Especially in severe MPS (MPS 1H, 2 > > other MPS types)
    - Except MPS 4 (Morquio): CNS spared
  - Occasional arachnoid cysts (meningeal GAG deposition)
- T2WI
  - ↑ signal of WM surrounding dilated VRS: Gliosis, edema, de- or dysmyelination
  - ± additional patchy WM signal
- FLAIR
  - VRS isointense with CSF
  - ↑ signal surrounds VRS
- T1WI C+
  - CV junction pannus enhances
- MRS
  - ↓ NAA, ↑ Cho/Cr ratio; ↑ peak at 3.7 ppm contains signals from MPS
    - Improvement in presumptive MPS peaks following bone marrow transplant (BMT)
- Spinal MR
  - Compression CVJ in majority of MPS
    - C2 meningeal hypertrophy
    - Progressive odontoid dysplasia → risk atlantoaxial subluxation; some correction reported following BMT
    - Short C1 posterior arch
  - ↑ T2 signal cord in 50% of CVJ compression
  - Upper lumbar gibbus
    - MPS 1H (Hurler): Inferior beaking
    - MPS 4 (Morquio): Middle beaking

Imaging Recommendations

- Best imaging tool
  - MR brain
- Protocol advice
  - Baseline MR/MRS
  - Follow-up: Complications (CVJ compression, hydrocephalus), therapeutic response to BMT
  - Always visualize foramen magnum on any CNS study to seek CVJ compression

DIFFERENTIAL DIAGNOSIS

Velocardiofacial Syndrome (22q11DS)

- Dilated VR spaces and plaques, typical frontal predominance
- Deviated carotid arteries in pharynx is clue

Macrocephaly With Dilated VRS

- Lacks typical beaked metopic suture and foramen magnum compression

Hypomelanosis of Ito

- Periventricular signal change (brighter and more persistent than MPS) with large VRS
- May also have hemimegalencephaly
- Typical whorled skin lesions
- Lack "beaked" metopic suture present in MPS

Perinatal Hypoxic-Ischemic Encephalopathy

- Transient phase of cystic change following hypoxic-ischemic encephalopathy → atrophy

Normal VR Spaces

- Vary in number and prominence

PATHOLOGY

General Features

- Etiology
  - Ganglioside accumulation (toxic to neurons)
- Genetics

https://CafePezeshki.IR

- Autosomal recessive (exception: X-linked MPS 2)
- Associated abnormalities
  - Dermal melanocytosis (mongolian-like spots)
    - Extensive, blue skin pigmentation differs from typical mongolian spots in persistence or progression
  - GAG accumulates in most organs/ligaments
    - Hepatosplenomegaly (HSM), umbilical hernia
    - Skeletal dysostosis multiplex, joint contractures
    - Arterial wall (mid aortic stenosis) and cardiac valve thickening
    - Thick dura (cord compressed at foramen magnum)
    - Coarse facies (formerly "gargoylism")
    - Upper airway obstruction (38%): Submucosal deposition → small, abnormally shaped trachea (difficult intubation); abnormal configuration vocal cords
  - Embryology-anatomy
    - Dilated VR spaces may be seen in utero

Staging, Grading, & Classification

- Diagnosis depends on specific enzyme deficiency
  - MPS 1H, 1HS (Hurler/Hurler-Scheie): α-L-iduronidase (4p16.3)
  - MPS 2 (Hunter): Iduronate 2-sulfatase (Xq28)
  - MPS 3A (Sanfilippo): Heparin N-sulfatase (17q25.3)
  - MPS 4A (Morquio): Galactose 6-sulfatase (16q24.3)
  - MPS 6 (Maroteaux-Lamy): Arylsulfatase B (5q11-q13)

Gross Pathologic & Surgical Features

- Thick meninges
- Cribriform appearance to cut surface of brain

Microscopic Features

- MPS: Glycosaminoglycans accumulate in leptomeninges and VR spaces

CLINICAL ISSUES

Presentation

- Most common signs/symptoms
  - Typical coarse facies develop (mild in MPS 3, 6, 7)
    - Macroglossia, bushy eyebrows, flat nasal bridge
- Clinical profile
  - Prototype MPS 1H, appear normal at birth
    - Corneal clouding (except MPS 2): Proteoglycans in keratocytes
    - Mental retardation (except MPS 2b, 4, 1HS)
    - Joint contractures, dysostosis multiplex, short stubby fingers, carpal tunnel syndrome
    - Loss of walking skills: Spinal claudication/myelopathy C1-2 and vascular claudication from mid-aortic stenosis
    - Recurrent upper respiratory infection, nasal discharge, ear infections, sleep apnea, sensorineural deafness
    - Middle ear effusions (73%), otolaryngologist notes this prediagnosis MPS
    - Cardiac valvular disease: Mitral > aortic
    - Skin blistering in MPS 3
  - MPS 7 may present with fetal nuchal translucency, hydrops fetalis, or isolated ascites

Demographics

- Age
  - MPS 1H presents in infancy
- Gender
  - MPS 2 (Hunter) is X-linked: Male
- Ethnicity
  - Geographic variability in prevalence of specific MPS disorders
- Epidemiology
  - 1:29,000 live births (series from Australia)
    - MPS 1H = 1:107,000 live births
    - MPS 2 = 1:165,000 male live births
    - MPS 3 = 1:58,000 live births
    - MPS 4A = 1:640,000 live births
    - MPS 6 = 1:320,000 live births

Natural History & Prognosis

- Significant correlation exists between WM alterations and mental retardation
- Rate of deterioration depends upon specific deficiency
  - MPS 1H death by 10 years, without therapy
  - MPS 2A death in late teens (cardiac)
  - Others variable

Treatment

- Enzyme replacement therapy (e.g., α-L-iduronidase for MPS 1H), hematopoietic stem cell transplantation, substrate reduction therapy, gene therapy, anti-inflammatory drugs
  - Goal: ↓ visceral accumulation MPS; ameliorate some manifestations

DIAGNOSTIC CHECKLIST

Consider

- Airway: Major sedation and anesthesia risk

Image Interpretation Pearls

- Not all MPS have typical facial features; dilated VRS may still signal less common MPS
- Not all dilated VRS are MPS
- Always look for CVJ compression
  - Treatable cause of morbidity in MPS
  - Lack of CVJ compression suggests there may be different etiology of dilated VRS than MPS

SELECTED REFERENCES

1. Andrade F et al: Sanfilippo syndrome: Overall review: Mucopolysaccharidosis type III. Pediatr Int. ePub, 2015
2. Aronovich EL et al: Lysosomal storage disease: gene therapy on both sides of the blood-brain barrier. Mol Genet Metab. 114(2):83-93, 2015
3. Leone A et al: Spinal involvement in mucopolysaccharidoses: a review. Childs Nerv Syst. 31(2):203-12, 2015
4. Krishna SH et al: Congenital genetic inborn errors of metabolism presenting as an adult or persisting into adulthood: neuroimaging in the more common or recognizable disorders. Semin Ultrasound CT MR. 35(2):160-91, 2014
5. Noh H et al: Current and potential therapeutic strategies for mucopolysaccharidoses. J Clin Pharm Ther. 39(3):215-24, 2014
6. Tylki-Szymańska A: Mucopolysaccharidosis type II, Hunter's syndrome. Pediatr Endocrinol Rev. 12 Suppl 1:107-13, 2014
7. Wraith JE et al: Mucopolysaccharidosis type I. Pediatr Endocrinol Rev. 12 Suppl 1:102-6, 2014
8. Xing M et al: Radiological and clinical characterization of the lysosomal storage disorders: non-lipid disorders. Br J Radiol. 87(1033):20130467, 2014
9. Zafeiriou DI et al: Brain and spinal MR imaging findings in mucopolysaccharidoses: a review. AJNR Am J Neuroradiol. 34(1):5-13, 2013

https://CafePezeshki.IR

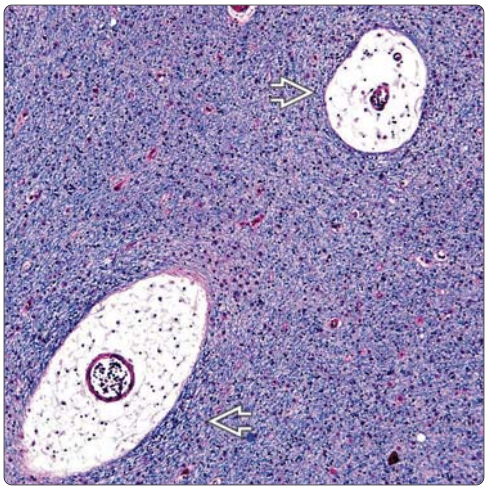

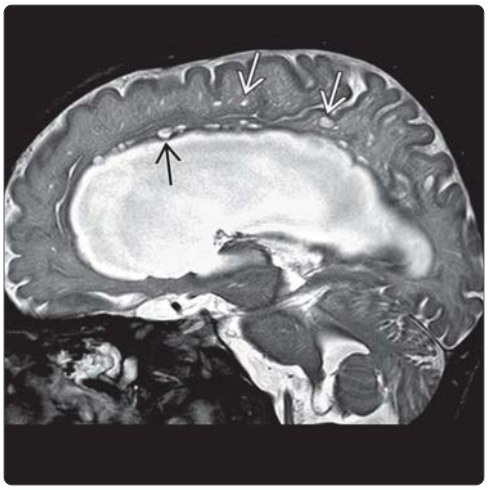

(Left) *Axial micropathology with Luxol fast blue stain in a teenager with MPS 1HS reveals dilated perivascular spaces filled by mucopolysaccharide. (Courtesy P. Shannon, MD.)* **(Right)** *Sagittal T2WI MR in a 10-year-old boy with MPS 2 demonstrates ventriculomegaly due to hydrocephalus, scaphocephaly, and numerous dilated perivascular spaces. Characteristic dilated perivascular spaces within the corpus callosum can be seen.*

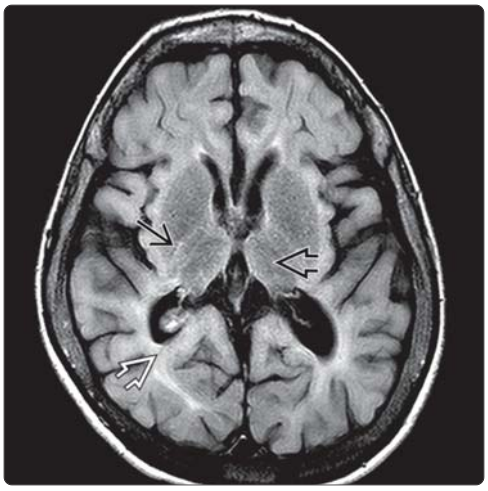

(Left) *Axial FLAIR MR in a child with MPS 3 reveals increased signal in the abnormal myelin of the peritrigonal white matter and the internal capsules. The thalami are dark and small. Thalamic findings are uncommon in the other MPS disorders but can be seen in MPS 3 and other lysosomal disorders.* **(Right)** *Axial T2WI MR in a 2-year-old child with MPS 3 reveals similar thalamic hypointensity. Notice the hypomyelination of the white matter manifested as abnormal hyperintensity.*

(Left) *Sagittal T2WI MR in a child with MPS 6 demonstrates dilated perivascular spaces in the corpus callosum (a typical location), scaphocephaly, and an abnormal sella turcica. The upper cervical spinal cord is significantly compressed by prominent pannus dorsal to the odontoid and by a short posterior arch of C1.* **(Right)** *Sagittal T2WI MR in MPS 1 demonstrates severe acute thoracolumbar kyphosis due to abnormal thoracic vertebra. Note the compression of the conus medullaris.*

https://CafePezeshki.IR

KEY FACTS

TERMINOLOGY

- Tay-Sachs disease (TS), Sandhoff disease (SD)
- Inherited lysosomal storage disorder characterized by GM2 ganglioside accumulation in brain
- TS & SD exist in infantile, juvenile, and adult forms

IMAGING

- Infantile: T2-hypointense, T1-hyperintense (CT hyperdense) thalami
- Juvenile/adult: Cerebellar atrophy

TOP DIFFERENTIAL DIAGNOSES

- Krabbe disease
- Juvenile GM1 gangliosidosis
- Neuronal ceroid lipofuscinosis
- Status marmoratus

PATHOLOGY

- Autosomal recessive inheritance
- Accumulation of GM2 ganglioside in neuronal lysosomes causes neuronal degradation, apoptosis with secondary hypo-/demyelination

CLINICAL ISSUES

- TS: 1:30 carrier frequency in Ashkenazi Jewish and French Canadians
- SD, GM2 variant AB, juvenile/adult GM2 = pan-ethnic (↑ in small gene pools)
- Presentation
  - Infant: Psychomotor retardation/regression
  - Juvenile/adult: Atypical spinocerebellar ataxia
- Poor prognosis for infantile onset GM2
  - Typically death by age 4 years
- Treatment: Supportive, seizure control; promising new therapies on horizon

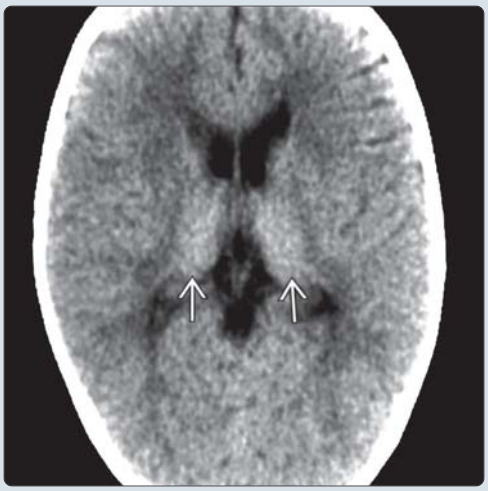

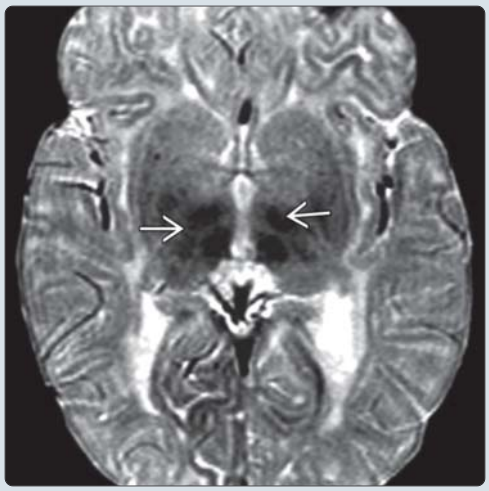

(Left) *Axial NECT shows classic hyperdense thalami ➡ in this developmentally delayed 1 year old with infantile Tay-Sachs disease. The basal ganglia appear small and were hypodense on lower images (not shown).* **(Right)** *Axial T2WI MR in a patient with infantile Tay-Sachs disease shows thalamic hypointensity limited to the ventral nuclei ➡, findings in contrast to those in patients with Sandhoff disease. The dorsal thalamus (not shown) is often mildly hyperintense.*

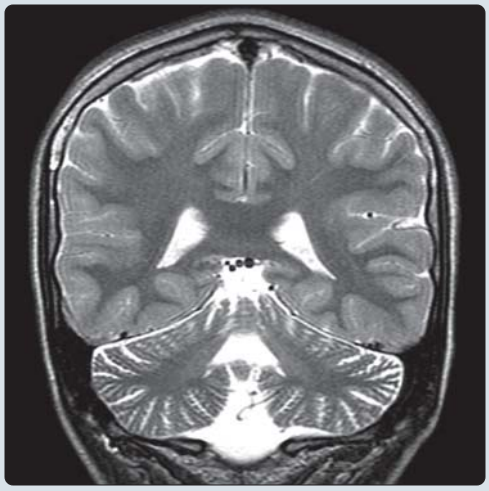

(Left) *Sagittal T1WI MR in an older child with psychosis and extrapyramidal symptoms shows enlarged vermian fissures, indicating volume loss. Cerebellar atrophy is the main finding in patients with juvenile or adult onset GM2.* **(Right)** *Coronal T2WI MR in a 15 year old with juvenile onset GM2 shows cerebellar atrophy. The supratentorial brain is normal. The cerebral WM is variably affected in juvenile/adult GM2. Rarely, deep gray structure and mass-like brainstem involvement can occur.*

https://CafePezeshki.IR

TERMINOLOGY

Abbreviations

- Gangliosidosis (GM2)

Synonyms

- Tay-Sachs (TS) disease, Sandhoff disease (SD)

Definitions

- Inherited lysosomal storage disorder
  - Characterized by GM2 ganglioside accumulation in brain
- 3 major biochemically distinct, but clinically indistinguishable types
  - TS disease
  - SD
  - GM2 variant AB (rare)
- TS and SD exist in infantile, juvenile, and adult forms
- GM2 variant AB exists in infantile form only

IMAGING

General Features

- Best diagnostic clue
  - Infantile
    - T2-hypointense, T1-hyperintense (CT hyperdense) thalami
    - Mild T2 hyperintensity striatum
  - Juvenile/adult
    - Cerebellar atrophy
- Location
  - Infantile: Thalami, striatum, cerebral > > cerebellar white matter (WM)
    - Corpus callosum (CC) spared
  - Juvenile/adult: Cerebellum, cerebral WM
    - Rare striatal and mass-like brainstem involvement
- Morphology
  - Symmetric involvement of deep gray structures
  - Late: Atrophy

CT Findings

- NECT
  - Infantile
    - Hyperdense thalami (classic but variable)
    - Hypodense striatum, WM
  - Juvenile/adult
    - Cerebellar atrophy
    - ± cerebral WM hypodensity
- CECT
  - No abnormal enhancement

MR Findings

- T1WI
  - Hyperintense thalami
  - Striatal intensity variable
  - Hypointense cerebral WM
- T2WI
  - TS: **Hypo**intense ventral thalami, **hyper**intense dorsal thalami
  - SD: Thalami diffusely hypointense
  - Mild striatal and cerebral WM hyperintensity
- DWI
  - Variably ↓ diffusivity ventral thalami (TS)
- T1WI C+
  - No abnormal enhancement
- MRS
  - Infantile: ↓ NAA, ↑ choline, ↑ myoinositol
  - Juvenile/adult: ↓ NAA; normal-appearing thalami, cerebral WM reported

Ultrasonographic Findings

- Infantile: Echogenic thalami

Imaging Recommendations

- Best imaging tool
  - MR (CT may confirm thalamic abnormality)

DIFFERENTIAL DIAGNOSIS

Krabbe Disease

- Hyperdense thalami, caudate and dentate nuclei
- T2-hyperintense cerebral, cerebellar WM
- CC involved

Juvenile GM1 Gangliosidosis

- Imaging findings identical to SD
- GM1 ganglioside accumulates in brain & viscera

Neuronal Ceroid Lipofuscinosis

- Thalami, globi pallidi hyperdense, T2 hypointense
- Cerebral, cerebellar atrophy

Status Marmoratus

- Hyperdense, atrophic thalami
- Atrophy putamina, perirolandic region
- History of profound perinatal ischemia

PATHOLOGY

General Features

- General pathology comments
  - Neuronal accumulation of GM2 ganglioside caused by deficient lysosomal enzyme, β-hexosaminidase A
- Embryology-anatomy
  - GM2 ganglioside resides in neuronal membranes; plays role in cell-cell recognition, synaptogenesis
  - β-hexosaminidase A (HexA) and GM2 activator protein (GMAP) required for lysosomal GM2 ganglioside catabolism
  - HexA is 1 of 3 isoenzymes of β-hexosaminidase formed by dimerization α and β subunits
    - HexA = αβ dimer, HexB = ββ, HexS = αα
  - HexA and HexB are major forms; HexS is minor form with unclear physiologic function
  - *HEXA*, Chr 15q23-24, encodes α subunit
  - *HEXB*, Chr 5q13, encodes β subunit
  - *GM2A*, Chr 5q31.3-q33.1, encodes GMAP
- Genetics
  - Autosomal recessive inheritance
  - > 100 different mutations of *HEXA* cause TS
  - > 30 different mutations of *HEXB* cause SD
  - ~ 4 mutations of *GM2A* cause GM2 variant AB
  - Mutations allowing residual HexA activity (0.5-4% normal activity) account for milder juvenile/adult phenotypes
- Etiology

https://CafePezeshki.IR

- Accumulation of GM2 ganglioside in neuronal lysosomes causes neuronal degradation, apoptosis with secondary hypo-/demyelination
  - GM2 ganglioside accumulation in myelin membrane may also contribute to demyelination
- Exact mechanism by which GM2 ganglioside accumulation → neuronal apoptosis is unknown
  - Activation microglia, macrophages, and astrocytes suggest inflammatory component
  - Identification of autoantibodies in mouse models of SD suggests autoimmune component

Gross Pathologic & Surgical Features

- Infantile: Early megalencephaly, late atrophy
  - Gelatinous, hemispheric WM, ± cavitation
- Juvenile/adult: Cerebellar atrophy

Microscopic Features

- GM2 ganglioside accumulation in cerebral neurons
- Less severe GM2 ganglioside accumulation in glial, Purkinje, anterior horn, and retinal ganglion cells
- EM: GM2 ganglioside contained in membranous cytoplasmic bodies (MCBs) in neuronal cytoplasm, proximal nerve processes, axons
  - MCBs in cytoplasm cause distortion and ballooning
  - MCBs in proximal nerve processes form meganeurites
- Hypomyelination, demyelination, wallerian degeneration
- Juvenile/adult GM2: Ganglioside accumulation in anterior horn cells, cerebellar neurons, basal ganglia, brainstem
  - MCBs occasionally absent
- SD: Additional storage of GM2 (and globoside) in viscera

CLINICAL ISSUES

Presentation

- Most common signs/symptoms
  - Infantile
    - Psychomotor retardation/regression
  - Juvenile/adult
    - Atypical spinocerebellar ataxia
  - Other signs/symptoms
    - Infantile: Macrocranium, hypotonia, seizures, blindness (90% with cherry-red spot macula), exaggerated startle response to noise
    - Juvenile/adult: Dysarthria, extrapyramidal and pyramidal dysfunction, peripheral neuropathy, stuttering, psychosis/depression (late, 30%)
- Clinical profile
  - Diagnosis: Documentation HexA deficiency in serum leukocytes, cultured skin fibroblasts, amniotic fluid, or chorionic villus sample
  - Abnormal results should be followed by DNA analysis to detect mutation &/or exclude pseudodeficiency allele

Demographics

- Age
  - Infantile
    - Symptom onset in 1st year
  - Juvenile
    - Symptom onset by 2-6 years old
  - Adult
    - Symptom onset in 1st-3rd decades
- Gender
  - No predilection
- Epidemiology
  - TS
    - 1:30 carrier frequency in Ashkenazi Jewish and French Canadians
    - ↑ incidence in Cajuns, French Canadians
    - Normal carrier frequency in general population
  - SD, GM2 variant AB, juvenile/adult GM2 = pan-ethnic (↑ in small gene pools)
    - 1:1,000 Jewish, 1:600 non-Jewish
    - 1:16-29 Creole population of Cordoba, Argentina
    - 1:7 Maronite Christian Cypriots
  - Incidence of TS in USA and Canada has decreased by > 90% since 1970 due to carrier screening and prenatal diagnosis

Natural History & Prognosis

- Infantile: Rapidly progressive psychomotor regression culminating in paralysis, blindness, deafness; death typically by 4 years of age
- Juvenile: More slowly progressive with death between 5-15 years of age
  - Death often 2° to respiratory infection
  - Often several years of decerebrate rigidity in vegetative state precede death
- Adult: Prolonged survival to age 60-80 can occur

Treatment

- Supportive therapy, seizure control
- Promising new therapies: Substrate deprivation, enzyme replacement, bone marrow transplantation, gene therapy, pharmacologic chaperone therapy

SELECTED REFERENCES

1. Pretegiani E et al: Pendular nystagmus, palatal tremor and progressive ataxia in GM2-gangliosidosis. Eur J Neurol. 22(6):e67-9, 2015
2. Bisel B et al: GM1 and GM2 gangliosides: recent developments. Biomol Concepts. 5(1):87-93, 2014
3. Cachón-González MB et al: Reversibility of neuropathology in Tay-Sachs-related diseases. Hum Mol Genet. 23(3):730-48, 2014
4. Deik A et al: Atypical presentation of late-onset Tay-Sachs disease. Muscle Nerve. 49(5):768-71, 2014
5. Hall P et al: Diagnosing Lysosomal Storage Disorders: The GM2 Gangliosidoses. Curr Protoc Hum Genet. 83:17.16.1-8, 2014
6. Harlalka GV et al: Mutations in B4GALNT1 (GM2 synthase) underlie a new disorder of ganglioside biosynthesis. Brain. 136(Pt 12):3618-24, 2013
7. Jamrozik Z et al: Late onset GM2 gangliosidosis mimicking spinal muscular atrophy. Gene. 527(2):679-82, 2013
8. Sandhoff K et al: Gangliosides and gangliosidoses: principles of molecular and metabolic pathogenesis. J Neurosci. 33(25):10195-208, 2013
9. Al-Maawali A et al: Diagnostic approach to childhood-onset cerebellar atrophy: a 10-year retrospective study of 300 patients. J Child Neurol. 27(9):1121-32, 2012

https://CafePezeshki.IR

(Left) *Axial FLAIR MR in a 1 year old with infantile Sandhoff disease shows diffusely hypointense thalami. The striatum is diffusely hyperintense. Evaluation of the cerebral WM on FLAIR MR is difficult at this age.* **(Right)** *Axial T1WI MR in the same patient shows symmetric thalamic hyperintensity and diffusely hypointense (hypo-/demyelinated) cerebral WM. WM should appear completely myelinated on T1WI at this age. Note the spared (hyperintense) corpus callosum.*

(Left) *Coronal T2WI MR in a 1 year old with infantile Sandhoff disease shows diffusely hypointense thalami. The striatum is abnormally hyperintense, particularly the caudate nuclei. The cerebral WM is also mildly hyperintense.* **(Right)** *Axial T2WI MR shows symmetric hypointense thalami in this 7 month old with infantile Sandhoff disease. The putamina are mildly hyperintense, more so posteriorly than anteriorly. Myelination appears within a normal range.*

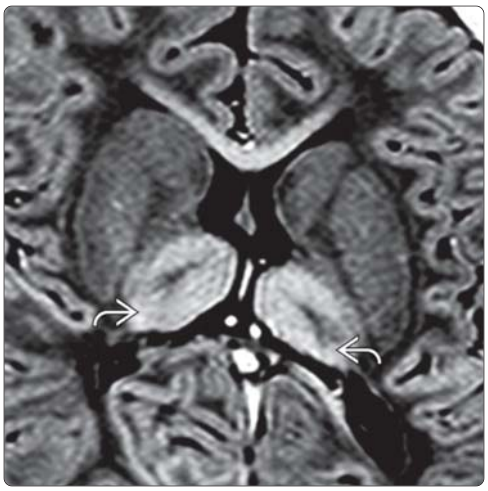

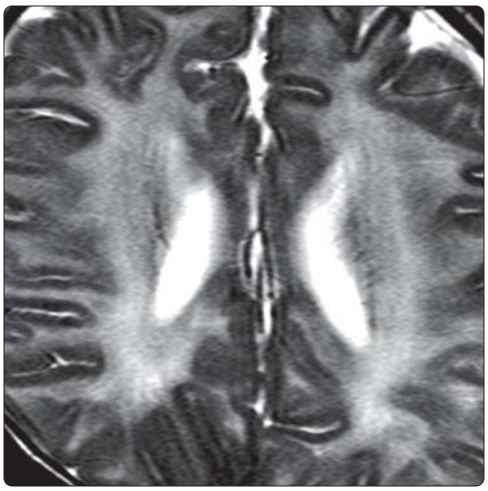

(Left) *Axial T1WI MR in a 2 year old with infantile Sandhoff disease shows symmetric thalamic hyperintensity. The central hypointense foci are atypical. The cerebral WM is grossly hypointense, with sparing of the corpus callosum.* **(Right)** *Axial T2WI MR in the same patient shows diffuse WM hyperintensity, confirming extensive hypo-/demyelination. The cerebral cortex has a normal appearance.*

https://CafePezeshki.IR

KEY FACTS

TERMINOLOGY

- Lysosomal storage disorder
  - Caused by ↓ arylsulfatase A (ARSA)
  - Results in CNS, PNS demyelination
- 3 clinical forms
  - Late infantile (most common), juvenile, adult

IMAGING

- Best diagnostic clue: Confluent butterfly-shaped ↑ T2 signal in deep cerebral hemispheric white matter (WM)
  - Early: Spares subcortical U-fibers
    - Corpus callosum splenium, parietooccipital WM initially
    - Rapid centrifugal spread to frontal, temporal WM
  - Late: Involves subcortical U-fibers
- Sparing of perivenular myelin = tigroid or leopard pattern
- No WM enhancement
  - Reports cranial nerve, cauda equina enhancement

TOP DIFFERENTIAL DIAGNOSES

- Pelizaeus-Merzbacher disease
- TORCH
- Pseudo-TORCH
- Periventricular leukomalacia
- Sneddon syndrome (arylsulfatase A pseudodeficiency)
- Krabbe disease
- Megalencephaly with leukoencephalopathy and cysts

CLINICAL ISSUES

- Clinical profile: Toddler with visuomotor impairment and abdominal pain

DIAGNOSTIC CHECKLIST

- Adult patients presenting with cryptic spasticity of legs should be screened for X-linked adrenoleukodystrophy/adrenomyeloneuropathy, lysosomal disorders (e.g., MLD)

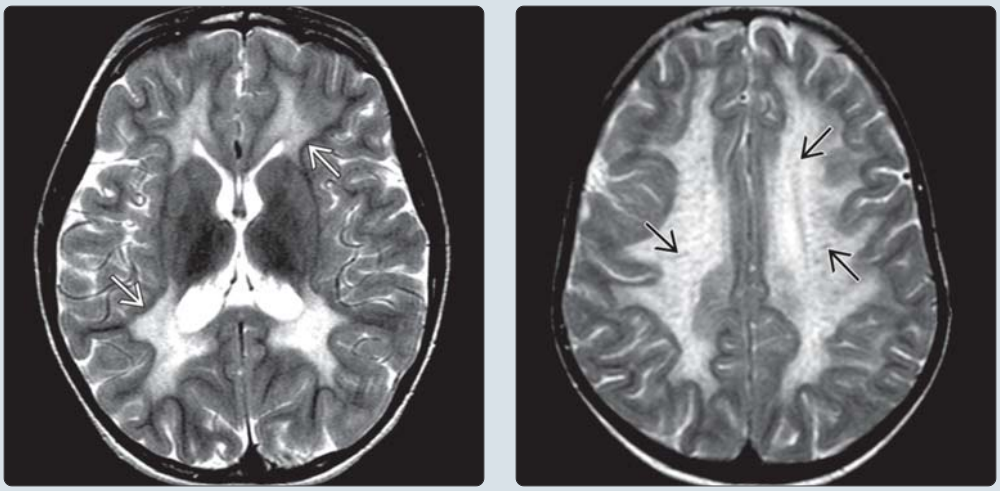

(Left) *Axial T2WI MR shows typical butterfly-shaped pattern of white matter (WM) involvement in metachromatic leukodystrophy (MLD). Note the sparing of internal/external capsules and subcortical U-fibers ⇨, typical of early disease.* **(Right)** *Axial T2WI MR shows confluent, symmetric WM hyperintensity with sparing of subcortical U-fibers. Perivenular myelin sparing causes the hypointense lines and dots within the WM ⇨, the characteristic tigroid or leopard pattern of MLD.*

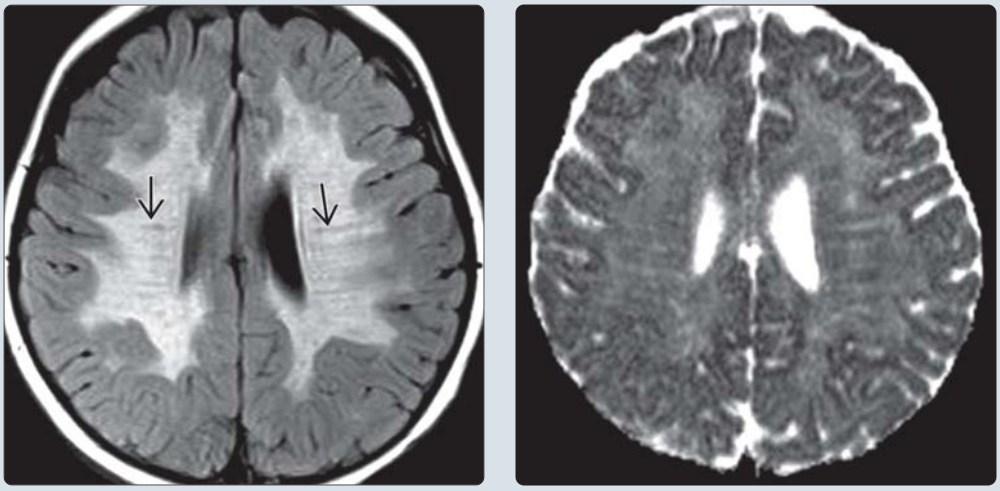

(Left) *Axial FLAIR MR demonstrates the characteristic confluent, symmetric, central WM involvement of MLD. The tigroid or leopard pattern of lines ⇨ and dots within the cerebral hemispheric WM is evident.* **(Right)** *Axial ADC map in the same patient shows high signal intensity within the affected WM consistent with increased diffusivity and probable interstitial edema. Reduced diffusivity (cytotoxic edema) is sometimes seen in areas of active demyelination.*

https://CafePezeshki.IR

TERMINOLOGY

Abbreviations

- Metachromatic leukodystrophy (MLD)

Synonyms

- Sulfatide lipoidosis

Definitions

- Lysosomal storage disorder
  - Caused by ↓ arylsulfatase A (ARSA)
  - Results in CNS, PNS demyelination
- 3 clinical forms: Late infantile (most common), juvenile, adult

IMAGING

General Features

- Best diagnostic clue: Confluent butterfly-shaped ↑ T2 signal in deep cerebral hemispheric white matter (WM)
- Location: Deep cerebral hemispheric WM
  - Early: Spares subcortical U-fibers
    - Corpus callosum, parietooccipital WM initially
    - Rapid centrifugal spread to frontal, temporal WM
  - Late: Involves subcortical U-fibers
- Morphology: Symmetric, confluent periventricular (PV) and deep WM high T2 signal

CT Findings

- NECT: Symmetric ↓ attenuation central cerebral hemispheric WM; late atrophy
- CECT: No enhancement (lacks inflammation)
- CT perfusion: ↓ perfusion hemispheric WM

MR Findings

- T1WI
  - Early: ↓ T1 signal within PV/deep WM
  - Late: Atrophy
- T2WI
  - Early
    - Confluent PV hyperintensity (butterfly shaped)
    - Sparing of perivenular myelin = tigroid or leopard pattern
    - Sparing of subcortical U-fibers
  - Late
    - Progressive subcortical WM extension
    - Involvement of U-fibers, corpus callosum, descending pyramidal tracts, internal capsules
    - Atrophy
- PD/intermediate: ↑ signal within PV/deep WM
- FLAIR: Butterfly-shaped periventricular hyperintensity
- T2* GRE: No petechial hemorrhage
- DWI: Reduced diffusivity in areas of active demyelination
- T1WI C+: No WM enhancement
  - Reports cranial nerve, cauda equina enhancement
- MRS: ↑ choline, ± ↑ myoinositol

Imaging Recommendations

- Best imaging tool
  - Early MR and MRS in presymptomatic enzyme-deficient siblings
- Protocol advice
  - MR: Include FLAIR
  - MRS: Sample central hemispheric WM

DIFFERENTIAL DIAGNOSIS

Pelizaeus-Merzbacher Disease

- Usually manifests in neonates and infants
- Lack of myelination without myelin destruction
- Cerebellum may be markedly atrophic

TORCH

- Variable WM hyperintensity (demyelination and gliosis)
- Not progressive
- Varied patterns of Ca++ depending on etiology

Pseudo-TORCH

- Progressive cerebral and cerebellar demyelination
- Brainstem, basal ganglia, and PV Ca++
- Elevated CSF neurotransmitters

Periventricular Leukomalacia

- Usually symmetric PV bright T2 signal
- PV volume loss (nonprogressive)
- Static spastic diplegia or quadriplegia

Sneddon Syndrome (Arylsulfatase A Pseudodeficiency)

- Demyelination
  - May be precipitated by hypoxic event
- PV WM bright T2 signal
- Confirmed by skin biopsy

Krabbe Disease

- Early involvement of cerebellar WM
- CT shows ↑ attenuation of thalami

Megalencephaly With Leukoencephalopathy and Cysts

- Slowly progressive, sparing of cognition, macrocephaly

PATHOLOGY

General Features

- General path comments
  - ↓ ARSA results in systemic storage of sulfatide
    - Symptomatic storage: CNS, PNS, gallbladder
    - Asymptomatic: Kidneys, adrenals, pancreas, liver
  - Diagnosis confirmed by
    - Excess urine sulfatide
    - Absent or deficient ARSA activity in fibroblasts &/or leukocytes
- Genetics: Autosomal recessive
  - *ARSA* gene located at 22q13.31-qter
  - > 110 different mutations
  - Late infantile form caused by mutations resulting in extremely low levels of ARSA
  - Juvenile/adult forms associated with residual ARSA activity
- Etiology
  - Absent or ↓ ARSA → increased lysosomal storage sulfatide → lethal demyelination
- Associated abnormalities: Gallbladder disease

https://CafePezeshki.IR

Gross Pathologic & Surgical Features

- Early
  - Enlarged brain and demyelination
  - Lack of inflammatory component to WM
- Late
  - Progressive cerebral hemispheric demyelination
  - Cerebral atrophy

Microscopic Features

- Central nervous system
  - PAS(+) metachromatic material accumulates in glial cells, neurons, Schwann cells, macrophages
  - Sulfatide deposition within plasma membranes
  - Sulfatide membrane-bound inclusions at inner layer of myelin sheaths
  - Demyelination may be extensive, yet inflammatory component is lacking
  - Sulfatide content in WM is considerably higher in late infantile form

CLINICAL ISSUES

Presentation

- Most common signs/symptoms
  - Late infantile
    - Insidious onset 2nd year of life
    - Strabismus, gait disturbance, ataxia, weakness, hypotonia
    - ± cherry-red macular spot
    - Bulbar signs → progressive hypotonia → decerebrate posturing → optic atrophy
    - Death frequently within 4 years of diagnosis
  - Juvenile
    - Appears between 5 and 10 years of age
    - Impaired school performance (nonverbal learning disability)
    - Spastic gait, ataxia, intellectual impairment
    - Brisk deep tendon reflexes
    - Progressive spasticity → progressive dementia → decerebrate posturing → seizures
    - Rare to survive longer than 20 years
  - Adult form
    - Can manifest as late as 6th decade
    - Presentation
      - May present as MS
      - Dementia, schizophrenia
      - Cryptic spasticity of legs
      - Progressive corticobulbar, corticospinal, and cerebellar changes
- Clinical profile: Toddler with visuomotor impairment and abdominal pain

Demographics

- Age: Variable depending on clinical form
- Gender: No predilection
- Epidemiology of all forms in USA: 1:100,000
  - ↑ in Habbanite Jewish (1:75 live births)
  - ↑ in Navajo Indians (1:2,500 live births)

Natural History & Prognosis

- Variable depending on clinical form

Treatment

- Hematopoietic stem cell, bone marrow, and umbilical cord blood transplant
  - May arrest motor and intellectual deterioration
  - Hematopoietic stem cell transplant shown to stabilize and even improve WM abnormalities
  - Mixed reports of effectiveness of bone marrow/cord blood transplants
    - Considered only in early phases of late infantile and juvenile/early adult forms
- Experimental: Lentivector-mediated *ARSA* gene transfer

DIAGNOSTIC CHECKLIST

Consider

- If WM involvement appears as "worst case MLD," involving internal capsule and brainstem → MLD look-alike, consider
  - Pseudo-TORCH
  - Megalencephaly with leukoencephalopathy and cysts
- Adult patients presenting with cryptic spasticity of legs should be screened for X-linked adrenoleukodystrophy/adrenomyeloneuropathy, lysosomal disorders (e.g., MLD)

Image Interpretation Pearls

- Butterfly pattern of cerebral hemispheric WM
- Tigroid or leopard pattern on T2WI
- Early sparing of subcortical U-fibers
- Lack of WM enhancement

SELECTED REFERENCES

1. Aronovich EL et al: Lysosomal storage disease: gene therapy on both sides of the blood-brain barrier. Mol Genet Metab. 114(2):83-93, 2015
2. Zerah M et al: Intracerebral Gene Therapy Using AAVrh.10-hARSA Recombinant Vector to Treat Patients with Early-Onset Forms of Metachromatic Leukodystrophy: Preclinical Feasibility and Safety Assessments in Nonhuman Primates. Hum Gene Ther Clin Dev. ePub, 2015
3. Ahmed RM et al: A practical approach to diagnosing adult onset leukodystrophies. J Neurol Neurosurg Psychiatry. 85(7):770-81, 2014
4. Musolino PL et al: Hematopoietic stem cell transplantation in the leukodystrophies: a systematic review of the literature. Neuropediatrics. 45(3):169-74, 2014
5. Müller vom Hagen J et al: Leukodystrophies underlying cryptic spastic paraparesis: frequency and phenotype in 76 patients. Eur J Neurol. 21(7):983-8, 2014
6. van Egmond ME et al: Improvement of white matter changes on neuroimaging modalities after stem cell transplant in metachromatic leukodystrophy. JAMA Neurol. 70(6):779-82, 2013
7. Groeschel S et al: Cerebral gray and white matter changes and clinical course in metachromatic leukodystrophy. Neurology. 79(16):1662-70, 2012
8. Gieselmann V et al: Metachromatic leukodystrophy–an update. Neuropediatrics. 41(1):1-6, 2010
9. Haberlandt E et al: Peripheral neuropathy as the sole initial finding in three children with infantile metachromatic leukodystrophy. Eur J Paediatr Neurol. 13(3):257-60, 2009
10. Singh RK et al: Isolated cranial nerve enhancement in metachromatic leukodystrophy. Pediatr Neurol. 40(5):380-2, 2009
11. Pierson TM et al: Umbilical cord blood transplantation for juvenile metachromatic leukodystrophy. Ann Neurol. 64(5):583-7, 2008
12. Görg M et al: Stabilization of juvenile metachromatic leukodystrophy after bone marrow transplantation: a 13-year follow-up. J Child Neurol. 22(9):1139-42, 2007
13. Maia AC Jr et al: Multiple cranial nerve enhancement: a new MR imaging finding in metachromatic leukodystrophy. AJNR Am J Neuroradiol. 28(6):999, 2007
14. Patay Z: Diffusion-weighted MR imaging in leukodystrophies. Eur Radiol. 15(11):2284-303, 2005
15. van der Voorn JP et al: Histopathologic correlates of radial stripes on MR images in lysosomal storage disorders. AJNR Am J Neuroradiol. 26(3):442-6, 2005

https://CafePezeshki.IR

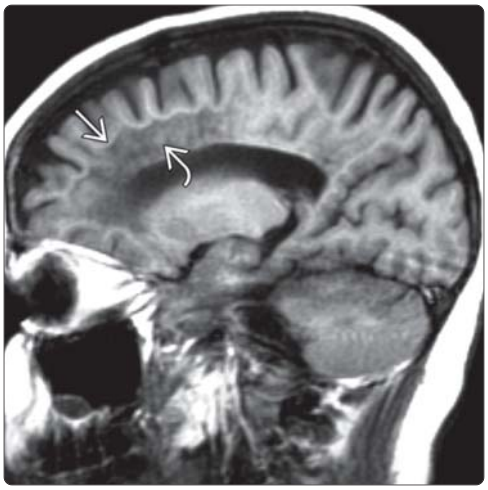

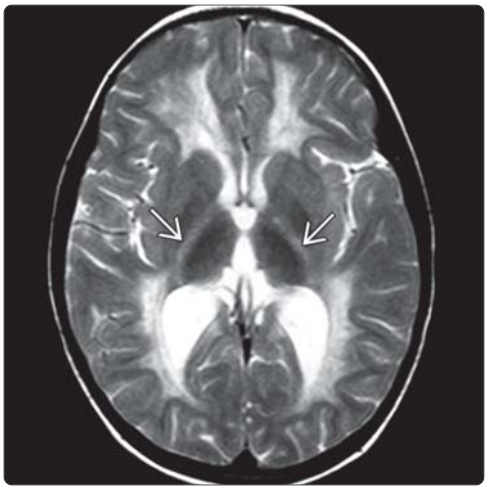

(Left) *Sagittal T1WI MR shows confluent hypointense signal in the periventricular and deep WM with sparing of the subcortical U-fibers ➡. Although less well evaluated in the sagittal plane, dot-like areas of spared perivenular myelin can be identified ➡.* **(Right)** *Axial T2WI MR shows the butterfly-shaped pattern of WM involvement typical in more advanced MLD. Although the subcortical U-fibers remain spared, the posterior limbs of the internal capsules ➡ are involved.*

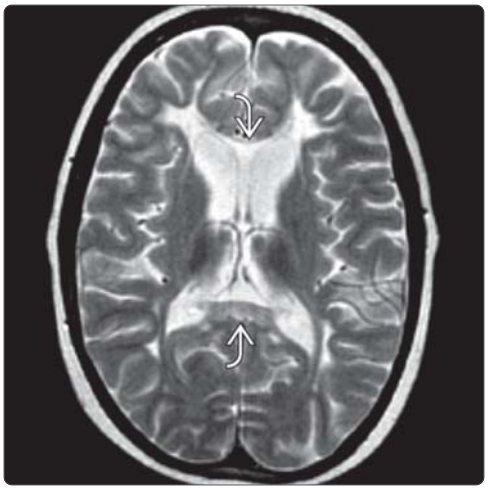

(Left) *In this axial T2WI MR of a patient with late MLD, the characteristic butterfly-shaped pattern of disease can be recognized despite severe loss of WM volume. Lateral ventricles are enlarged (ex vacuo), and the basal ganglia are atrophic. Hyperintense signal is present in the corpus callosum ➡.* **(Right)** *Axial T2WI MR in the same patient shows confluent hyperintense signal and severe volume loss of the WM. Although spared in this patient, the subcortical U-fibers are often affected in late disease.*

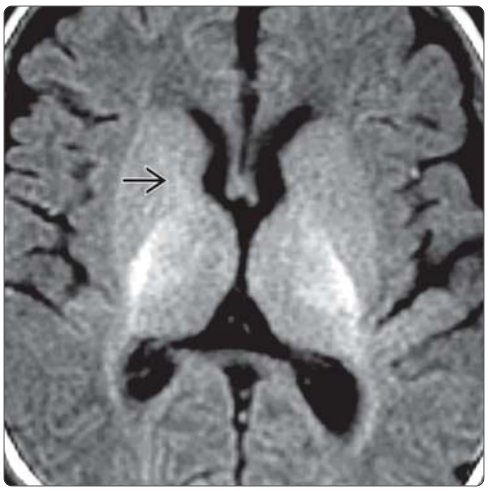

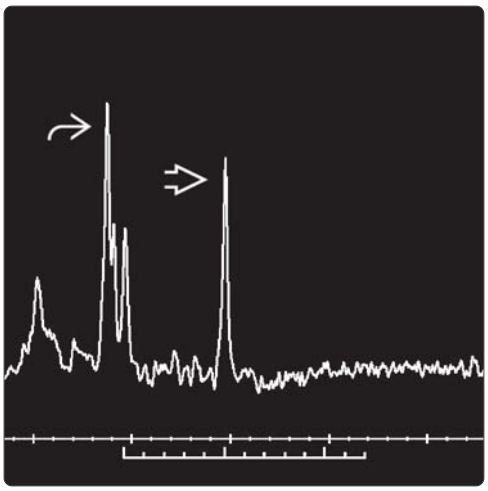

(Left) *Axial T1WI MR shows a 4-month-old infant with affected older siblings status post bone marrow transplant (BMT). Excepting mild myelin maturation delay in the anterior limbs of the internal capsule ➡, the conventional images were normal.* **(Right)** *Single voxel MRS (TE = 288 msec) obtained from the periventricular WM of the same patient shows increase in the choline peak ➡. The NAA peak ➡ should be the dominant peak at this age.*

https://CafePezeshki.IR

KEY FACTS

TERMINOLOGY

- Progressive autosomal recessive degenerative leukodystrophy of central (CNS) and peripheral (PNS) nervous systems

IMAGING

- Symmetric hyperdensity in thalami, basal ganglia on CT
- Enlargement of optic nerves and cranial nerves
- Confluent symmetric deep periventricular white matter (WM) hyperintensity
- Cerebellar WM hyperintense signal on T2WI
  - Ring-like appearance around dentate nuclei
- Fractional anisotropy values in corticospinal tracts are low compared to controls
- Enhancement of lumbar nerve roots
- MRS: Pronounced ↑ choline, myoinositol; moderate NAA reduction; mild lactate accumulation

PATHOLOGY

- Deficiency of lysosomal galactocerebroside β-galactosidase (GALC)
  - Accumulation of psychosine 100x normal concentrations
  - Psychosine is toxic to brain
- Infantile form is most common and most severe
- "Globoid" cells = macrophages containing PAS(+) galactocerebrosides
  - Identified in enlarged optic nerves

CLINICAL ISSUES

- Most common symptom is extreme irritability
- Neonatal screening has been instituted in New York and Illinois
- Stem cell transplant can halt disease progression

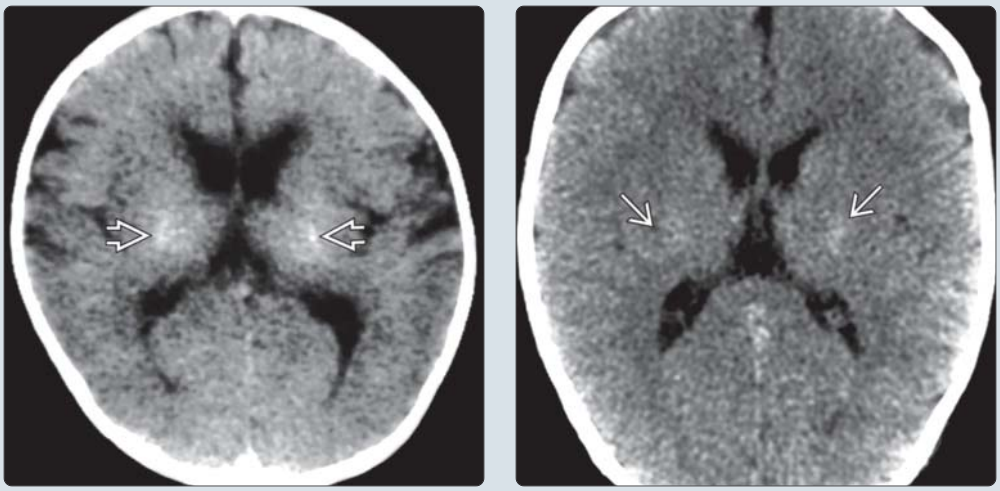

(Left) *Axial NECT in a 6 month old with irritability and feeding difficulties shows abnormal increased attenuation in the thalami* ⇨. **(Right)** *The hyperdensities are more punctate* ⇨ *in this axial NECT from an 18 month old with Krabbe disease. Infantile Krabbe is 1 of the few leukodystrophies in which CT features may be apparent before MR findings; however, DTI shows promise in detecting decreased fractional anisotropy in the corticospinal tracts in presymptomatic neonates.*

(Left) *Axial T1WI MR in an 8-month-old boy with Krabbe shows abnormal hypointensity* ⇨ *in the hila of the cerebellar nuclei bilaterally. Regions of increased density on CT often have hyperintense signal on T1WI.* **(Right)** *Axial T2WI MR in the same patient shows correlating alternating hyper- (edema in hila* ⇨*), hypo- (nuclei* ⇨*), and hyperintense (cerebellar white matter* ⇨*) signal around the cerebellar nuclei. Krabbe is 1 of the few leukodystrophies that has early cerebellar imaging findings.*

https://CafePezeshki.IR

TERMINOLOGY

Abbreviations

- Globoid cell leukodystrophy (GLD)

Synonyms

- Krabbe disease

Definitions

- Progressive autosomal recessive degenerative leukodystrophy of central (CNS) and peripheral (PNS) nervous systems

IMAGING

General Features

- Best diagnostic clue
  - Hyperdensity on CT in thalami, corona radiata, and body of caudate nuclei in irritable infant
- Location
  - Thalami, basal ganglia (BG), white matter (WM), corticospinal and pyramidal tracts, PNS

CT Findings

- NECT
  - Symmetric hyperdensity in thalami, BG, corona radiata, cerebellum
    - Globoid cell accumulation with calcifications
    - Fades over time
  - Deep, periventricular WM hypodensity
  - Atrophy develops, leads to 2° microcephaly

MR Findings

- T1WI
  - Deep, periventricular WM hypointensity
  - Faint hyperintensity in thalami and BG
  - Enlargement of optic nerves and cranial nerves
- T2WI
  - Confluent symmetric deep periventricular WM hyperintensity
    - Spares subcortical U-fibers
    - Starts in corticospinal tracts, becomes diffuse over time
    - Hypointense thalami
  - Cerebellar WM hyperintense signal
    - Ring-like appearance around dentate nuclei
  - Corpus callosum frequently involved in adult-onset disease
- FLAIR
  - Better delineates WM hyperintensities in older children
- DWI
  - Fractional anisotropy (FA) values in corticospinal tracts are significantly lower in neonates with Krabbe disease than in controls
  - Diffusion tensor-derived anisotropy maps → loss of diffusion anisotropy
    - Relative anisotropy (RA) differences found in BG, middle cerebellar peduncles, internal capsule, corpus callosum, periventricular WM
    - After stem cell transplantation, RA of untreated patients < mean RA treated < RA of control subjects
- T1WI C+
  - Enhancement of cranial nerves, lumbar nerve roots
- MRS
  - Infantile: Pronounced ↑ choline, myoinositol; moderate NAA reduction; mild lactate accumulation
  - Late infantile-juvenile: ↑ choline, myoinositol; mild NAA reduction
  - Adult: Mild ↑ choline and myoinositol, may be close to normal

Imaging Recommendations

- Best imaging tool
  - MR + contrast and DTI
- Protocol advice
  - Pay attention to cranial nerves
  - Consider NECT to look for hyperdense thalami

DIFFERENTIAL DIAGNOSIS

Neuronal Ceroid Lipofuscinosis

- Batten disease
- Hyperdense thalami on CT
- Progressive cerebral atrophy

GM2 Gangliosidoses

- e.g., Tay-Sachs disease
- Lysosomal lipid storage disorders caused by mutations in ≥ 1 of 3 recessive genes: *HEXA*, *HEXB*, *GM2A*
- Hypointense/hyperdense thalami; patchy hyperintense WM

Neurofibromatosis Type 1

- Optic nerve enlargement (optic nerve glioma)
- Patchy WM signal abnormalities
- Not progressive; does not present with irritability in infant

Metachromatic Leukodystrophy (MLD)

- Progressive WM hyperintensity on T2WI
- Initial sparing of subcortical U-fibers

PATHOLOGY

General Features

- Etiology
  - Gene defects result in deficiency of lysosomal galactocerebroside β-galactosidase (GALC)
    - Normally aids in cleavage of galactose from psychosine and galactosylceramide, leaving sphingosine and ceramide, respectively
      - Galactosylceramidase 2 and 3 can catalyze galactosylceramide but not psychosine
    - Results in accumulation of psychosine 100x normal concentrations
      - Psychosine is toxic to brain, especially oligodendroglia → destruction of oligodendrocytes
    - Accumulation of psychosine causes
      - Upregulation of AP-1 (proapoptotic pathway)
      - Downregulation of NF-κB pathway (antiapoptotic pathway)
  - Sulfotransferase may also be deficient; suggests that galactosylceramide degradation may be complex
- Genetics
  - Autosomal recessive lysosomal disorder
  - Gene mapped to chromosome 14 (14q24.3 to 14q32.1) and has been cloned

https://CafePezeshki.IR

  - Different mutations associated with differing severity for both age of onset and progression
  - 65 mutations and polymorphic changes described

Staging, Grading, & Classification

- Infantile: Before age 2
  - Most common and most severe
- Late infantile-juvenile: After age 2
- Adult: After age 10
  - Corticospinal, pyramidal tract symptoms
  - Mimics peripheral neuropathy
  - Often undiagnosed for many years

Gross Pathologic & Surgical Features

- Small, atrophic brain

Microscopic Features

- Myelin loss with astrogliosis and dysmyelination
  - Severe oligodendrocyte loss
- Perivascular large multinucleated "globoid" and mononuclear epithelioid cells in demyelinated zones
  - "Globoid" cells = macrophages containing PAS(+) galactocerebrosides
- Demyelination is marked within cerebrum, cerebellum, brainstem, spinal cord with segmental involvement of peripheral nerves
- "Globoid" cells identified in enlarged optic nerves
- "Globoid" cell inclusions in sweat gland epithelial cells

CLINICAL ISSUES

Presentation

- Most common signs/symptoms
  - Neonatal: Most common symptom is extreme irritability
    - Seizures result in medical attention
    - Hypersensitivity to sensory stimuli (e.g., hyperacusis), fevers, feeding problems, failure to thrive, optic atrophy, cortical blindness
  - Infantile-juvenile
    - Visual failure, cerebellar ataxia, spasticity, polyneuropathy, dementia, psychosis
  - Adult
    - Hemiparesis, spastic paraparesis, cerebellar ataxia, intellectual impairment, visual failure, peripheral polyneuropathy, talipes cavus
- Clinical profile
  - Diagnosis made from leukocyte or skin fibroblast β-galactosidase assay
  - Molecular assay available for genetic counseling, prenatal testing
  - Universal neonatal screening has been instituted in New York and Illinois

Demographics

- Gender
  - M = F
- Ethnicity
  - Most reported patients have European ancestry, but it can affect all populations
- Epidemiology
  - 1:100,000 in USA and Europe
  - 1:25-50,000 in Sweden
  - 6:1,000 in Druze community in Israel

Natural History & Prognosis

- Neonatal: Rapidly progressive, few live > 2 years
  - Motor deterioration → quadriparesis
  - Hypertonicity becomes flaccidity as PNS is involved
  - Blindness
- Infantile-juvenile: More protracted course, slower rate of progression
- Adult: Heterogeneous, progresses more slowly
  - MR may remain normal for many years, even in presence of symptoms
- Sequelae (e.g., infection) cause most deaths

Treatment

- Hematopoietic stem cell transplantation
  - Halts disease progression in mild forms of Krabbe
  - Both clinical and radiologic manifestations may reverse or retard

DIAGNOSTIC CHECKLIST

Consider

- Use contrast on MR when considering leukodystrophies
- Think of Krabbe when dealing with hyperirritable infant

Image Interpretation Pearls

- Look for faint hyperdensity on CT in deep cerebral nuclei

SELECTED REFERENCES

1. Gupta A et al: Regional differences in fiber tractography predict neurodevelopmental outcomes in neonates with infantile Krabbe disease. Neuroimage Clin. 7:792-8, 2015
2. Zuccoli G et al: Midbrain morphology reflects extent of brain damage in Krabbe disease. Neuroradiology. ePub, 2015
3. Ahmed RM et al: A practical approach to diagnosing adult onset leukodystrophies. J Neurol Neurosurg Psychiatry. 85(7):770-81, 2014
4. Krishna SH et al: Congenital genetic inborn errors of metabolism presenting as an adult or persisting into adulthood: neuroimaging in the more common or recognizable disorders. Semin Ultrasound CT MR. 35(2):160-91, 2014
5. Liao P et al: Phenotypic variability of krabbe disease across the lifespan. Can J Neurol Sci. 41(1):5-12, 2014
6. Poretti A et al: Novel diffusion tensor imaging findings in Krabbe disease. Eur J Paediatr Neurol. 18(2):150-6, 2014
7. Reddy AS et al: Central nervous system pathology progresses independently of KC and CXCR2 in globoid-cell leukodystrophy. PLoS One. 8(6):e64647, 2014
8. Udow S et al: Prolonged survival and serial magnetic resonance imaging/magnetic resonance spectroscopy changes in infantile Krabbe disease. Pediatr Neurol. 47(4):299-302, 2012
9. Beslow LA et al: Thickening and enhancement of multiple cranial nerves in conjunction with cystic white matter lesions in early infantile Krabbe disease. Pediatr Radiol. 38(6):694-6, 2008
10. Patel B et al: Optic nerve and chiasm enlargement in a case of infantile Krabbe disease: quantitative comparison with 26 age-matched controls. Pediatr Radiol. 38(6):697-9, 2008

https://CafePezeshki.IR

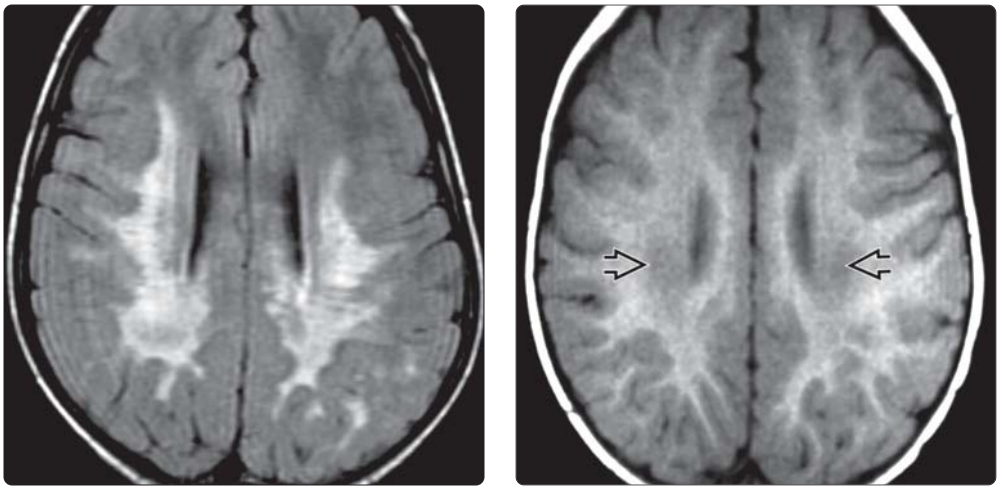

(Left) *Axial FLAIR MR in a 4 year old with Krabbe disease treated with stem cell transplantation shows confluent abnormal hyperintense signal in the periventricular white matter, primarily affecting the posterior frontal and parietal lobes.* **(Right)** *Axial T1WI MR in the same child shows subtle hypointense signal ⇨ that appears less extensive but is in the same distribution. These findings did not progress after the stem cell transplant.*

(Left) *Axial FLAIR MR in a 30 year old with juvenile-onset Krabbe disease demonstrates abnormal hyperintense signal ⇨ in the corona radiata on each side. Symmetric corticospinal tract involvement is a hallmark of globoid cell leukodystrophy.* **(Right)** *Axial FLAIR MR in the same patient shows focal symmetric hyperintensity in the capsular portion of the corticospinal tracts ⇨. The infantile juvenile-onset form is characterized by a more protracted course with a slower rate of progression.*

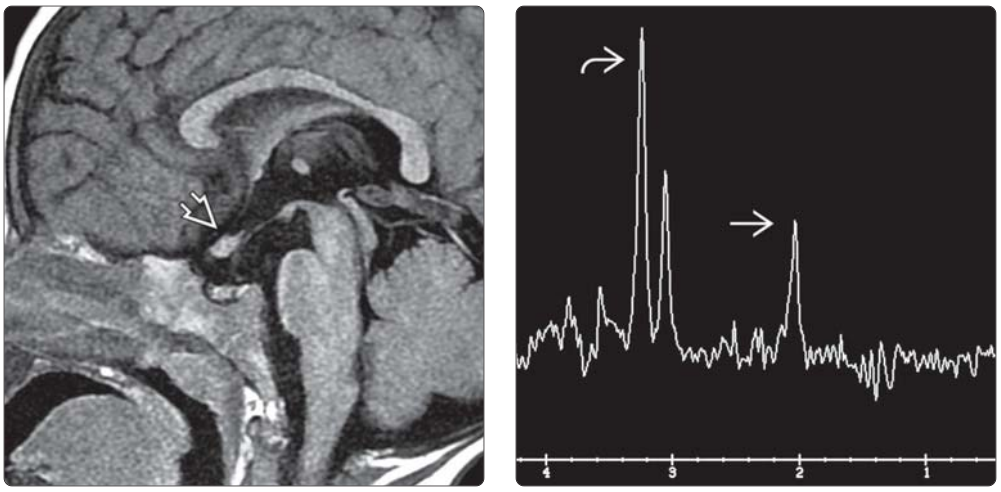

(Left) *Sagittal T1WI MR clearly shows focal enlargement of the optic chiasm ⇨ in this child with Krabbe disease. A unique feature of this leukodystrophy is the occasional enlargement of optic nerves described by Krabbe in his original paper on the condition.* **(Right)** *Axial MRS in the affected WM of a child with Krabbe shows elevated choline ⇨ and diminished NAA ⇨. Although nonspecific, this pattern is typical of Krabbe disease, and these alterations will worsen without treatment.*

https://CafePezeshki.IR

KEY FACTS

TERMINOLOGY
- Fabry disease (FD)

IMAGING
- NECT
  - Ca++ in lateral pulvinar, globus pallidus, putamen, substantia nigra, dentate nuclei
- MR may show earlier changes
  - ↑ T1 signal in deep gray nuclei
  - T1 lateral pulvinar hyperintensity considered pathognomonic of FD
  - T2/FLAIR hyperintensities in periventricular WM, deep gray matter

TOP DIFFERENTIAL DIAGNOSES
- Endocrinologic disorders
  - Hyperparathyroidism, hypoparathyroidism, pseudohypoparathyroidism, hypothyroidism
- HIV-associated mineralizing calcific microangiopathy
- Fahr disease

PATHOLOGY
- X-linked disorder of glycosphingolipid metabolism
- Deficient activity of α-galactosidase A
- Endothelial accumulation of glycosphingolipids
  - Compromises vessel lumen size
  - Leads to vascular events (myocardial ischemia, strokes)

CLINICAL ISSUES
- Neurologic complications in 4th/5th decades
- Enzyme replacement therapy may help

DIAGNOSTIC CHECKLIST
- Consider FD in young males with white matter disease, basal ganglia/pulvinar calcification

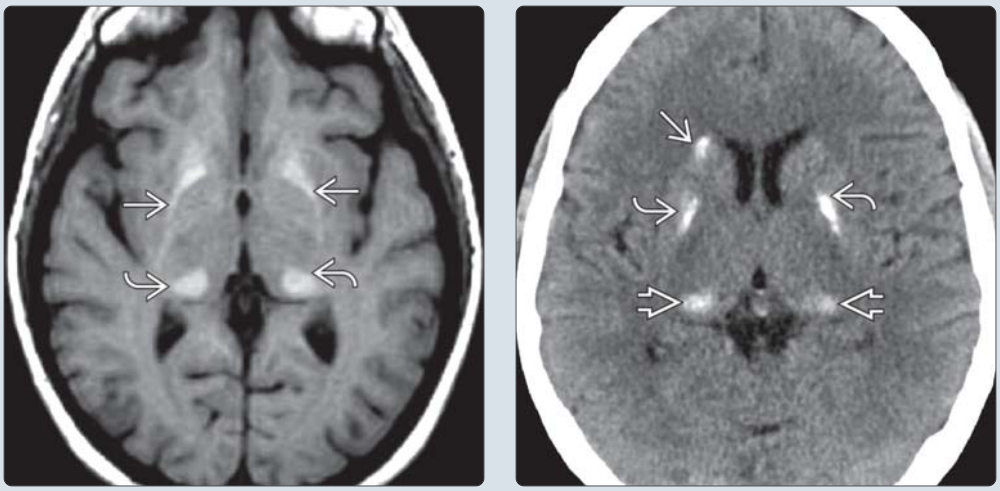

(Left) *Axial T1WI MR in a patient with Fabry disease shows bilateral hyperintense lesions in the lateral putamina ➡ and lateral aspects of both pulvinars ➡. T1 hyperintensity in the lateral pulvinar is considered a virtually pathognomonic sign of Fabry disease.* **(Right)** *Axial NECT in the same patient shows calcifications in the right caudate ➡, both putamina ➡, and lateral pulvinars ➡, corresponding to the T1 hyperintensities seen on the previous MR scan.*

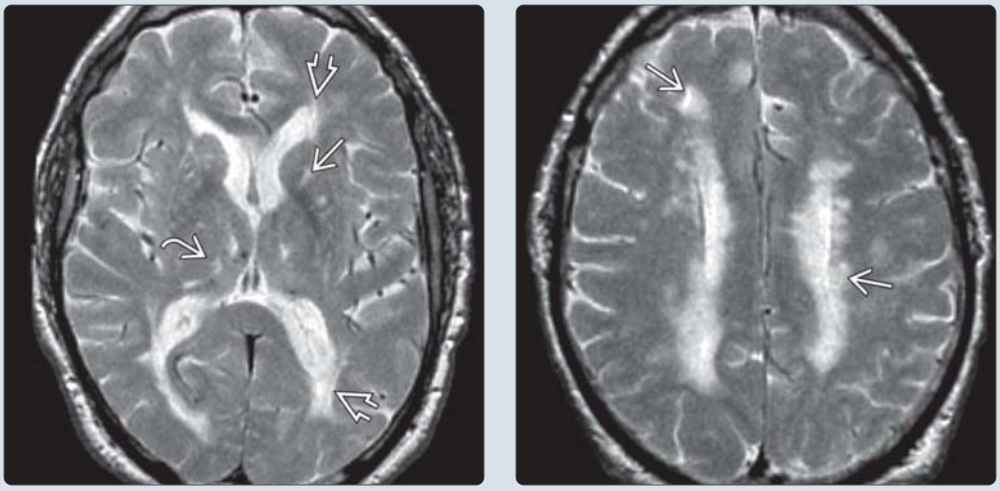

(Left) *Axial T2WI MR in a 50-year-old man with Fabry disease shows multifocal lacunar infarcts in the basal ganglia ➡ and thalami ➡, as well as confluent hyperintensities in the deep periventricular white matter ➡.* **(Right)** *Axial T2WI MR in the same patient shows multifocal, discrete, and confluent white matter hyperintensities in the deep cerebral white matter ➡. Deep white matter and basal ganglia infarcts are due to large and small vessel involvement in Fabry disease.*

https://CafePezeshki.IR

TERMINOLOGY

Abbreviations

- Fabry disease (FD)

Synonyms

- Anderson-Fabry disease

Definitions

- X-linked disorder of glycosphingolipid metabolism
- Deficient activity of α-galactosidase A

IMAGING

General Features

- Best diagnostic clue
  - Lateral pulvinar ↑ T1 signal (MR), Ca++ (CT)
- Location
  - Typical: Lateral pulvinar, globus pallidus, putamen
  - Other: Substantia nigra, dentate nuclei

Imaging Recommendations

- Best imaging tool
  - CT: Sensitive for small quantities of calcification
  - MR may show earlier changes, T1 hyperintensity
- Protocol advice
  - NECT + MR (T1-, T2WI; FLAIR best)

MR Findings

- T1WI
  - Increased T1 signal in deep gray nuclei
    - Lateral pulvinar ↑ T1 signal considered pathognomonic
  - T1 hyperintensity varies
    - Depends on stage, volume of Ca++
- T2WI
  - Patchy hyperintensities in WM, deep gray nuclei
    - ↑ in intensity, coalesce over time
- T2* GRE
  - Microbleeds (10%)

DIFFERENTIAL DIAGNOSIS

Fahr Disease

- Bilateral dense, thick Ca++ in BG/thalami
- Cortical atrophy

Endocrinologic Disorders

- Hyperparathyroidism, hypoparathyroidism, pseudohypoparathyroidism, hypothyroidism
  - Lacks multifocal infarcts but Ca++ similar to FD
  - Serum Ca, PTH, T3/T4, TSH levels helpful

HIV-Associated Mineralizing Calcific Microangiopathy

- Ca++ in basal ganglia (BG) and cerebral atrophy

PATHOLOGY

General Features

- Etiology
  - Disorder of glycosphingolipid metabolism
  - α-galactosidase A deficient activity
    - Causes progressive accumulation of glycosphingolipids (ceramide trihexoside)
      - Vascular endothelium and smooth muscle cells affected
      - Endothelial accumulation causes ↓ vessel lumen
      - Parenchymal cells in kidney, heart, and brain affected
    - Leads to myocardial ischemia and stroke
- Genetics
  - X-linked inheritance, abnormality in *GLA* gene
- Associated abnormalities
  - Left ventricular hypertrophy, short PR interval, AV block
  - Renal cysts (subcapsular predilection)

Microscopic Features

- Glycosphingolipid deposits
  - Form lamellate membrane-like structure (myeloid or "Zebra bodies")
  - Neurons (basal ganglia, brainstem, amygdala, hypothalamus)

CLINICAL ISSUES

Presentation

- Most common signs/symptoms
  - Cardiovascular (emboli, large vessel arteriopathy, microvascular disease)
    - Causes 1.5% of unexplained strokes in young patients
    - Angina, heart block, renal failure/HTN
  - Other
    - Acroparesthesias, neuropathic pain
    - Cutaneous angiokeratomas (infants)
      - Corneal inclusions, cataracts

Demographics

- Age
  - Neurologic complications in 4th/5th decades
    - Present in 4-5% of men with cryptogenic stroke or unexplained left ventricular hypertrophy
  - Hemizygous men: Onset in adolescence
- Gender
  - Heterozygous females are normally healthy carriers but may develop symptoms of FD

Treatment

- Recombinant human alpha-galactosidase A

DIAGNOSTIC CHECKLIST

Consider

- FD in young males with white matter disease, basal ganglia/pulvinar calcification

Image Interpretation Pearls

- T1 hyperintensity in pulvinar is pathognomonic

SELECTED REFERENCES

1. Kim SU: Lysosomal storage diseases: Stem cell-based cell- and gene-therapy. Cell Transplant. ePub, 2014
2. Mahmud HM: Fabry's disease--a comprehensive review on pathogenesis, diagnosis and treatment. J Pak Med Assoc. 64(2):189-94, 2014
3. Tuttolomondo A et al: Anderson-Fabry disease: a multiorgan disease. Curr Pharm Des. 19(33):5974-96, 2013

https://CafePezeshki.IR

KEY FACTS

TERMINOLOGY

- Zellweger syndrome: Cerebrohepatorenal syndrome
- Zellweger syndrome spectrum (ZSS): ZS + neonatal adrenoleukodystrophy + infantile Refsum disease
- Peroxisome biogenesis disorders: ZSS (80%) + rhizomelic chondrodysplasia punctata

IMAGING

- Microgyria, pachygyria, hypomyelination, germinolytic (caudothalamic) cysts
  - Microgyria most severe in perisylvian region (especially posterior insula)
  - Pachygyria most common frontoparietal
- Central volume loss common
- MRS: ↓ NAA, ↑ Cho
- Short TE MRS: Mobile lipid peaks at 0.9 and 1.33 ppm
- Diffuse hypomyelination, cerebellum, and brainstem may be involved especially if present > 1 year

TOP DIFFERENTIAL DIAGNOSES

- Congenital CMV
- Pseudo-TORCH
- Single peroxisomal enzyme deficiencies

PATHOLOGY

- Defect in biogenesis of peroxisomes
- Autosomal-recessive phenotype resulting from defect in any of at least 12 *PEX* genes

CLINICAL ISSUES

- Severe hypotonia, seizures, poor sucking
- Large fontanelle + sutures, high forehead, broad nasal bridge, hypertelorism
- Elevated liver enzymes, hepatomegaly
- Cataract, nystagmus, retinitis pigmentosa, or optic atrophy

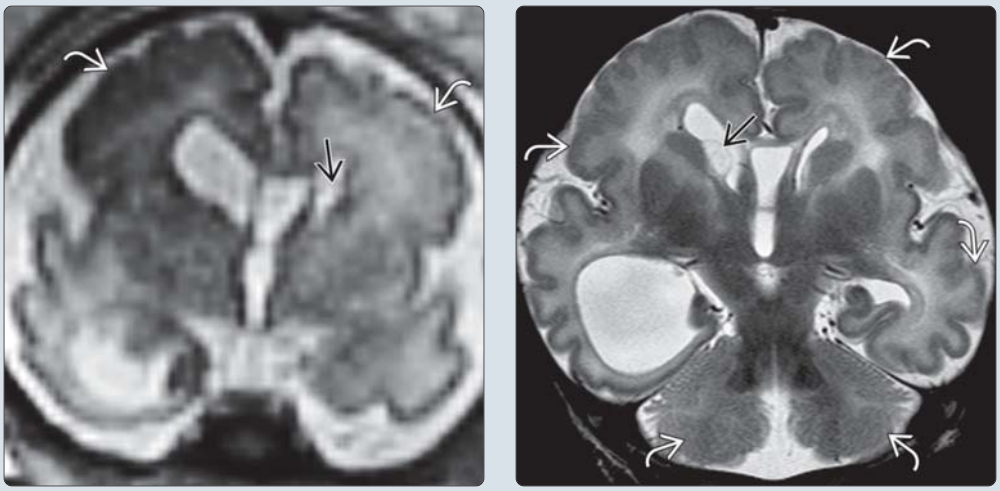

(Left) *Coronal T2WI MR of a fetus at 32 weeks gestational age shows right ventricular enlargement (30 mm), a subtle germinolytic cyst ⇨ in the left frontal horn, diffuse microgyria ⇨, and abnormal variation of white matter signal intensity.* **(Right)** *Coronal T2WI MR in the same patient 2 days after term delivery shows right ventricular enlargement, a germinolytic cyst ⇨ in the right frontal horn, diffuse cerebral and cerebellar microgyria ⇨, and abnormally increased signal in the deep white matter.*

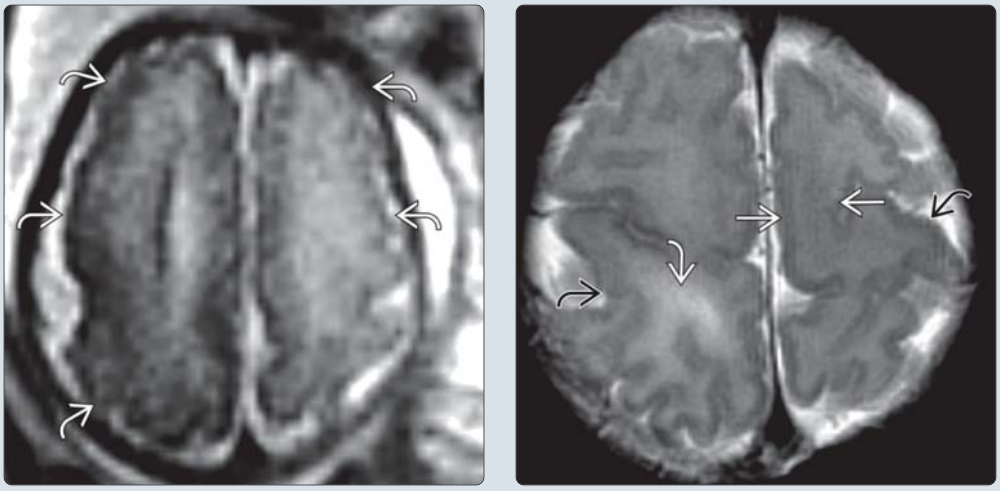

(Left) *Axial T2WI MR of the same fetus shows diffusely abnormal signal intensity in the cerebral hemispheric white matter, in addition to extensive cerebral microgyria ⇨.* **(Right)** *Axial T2WI MR in the same patient 2 days after term delivery shows the presence of diffuse cerebral cortical microgyria ⇨ along with areas of decreased sulcation ⇨, in addition to abnormally increased signal in the white matter ⇨.*

https://CafePezeshki.IR

TERMINOLOGY

Abbreviations

- Zellweger syndrome (ZS)

Synonyms

- Cerebrohepatorenal syndrome
- Zellweger syndrome spectrum (ZSS)

Definitions

- ZSS: ZS + neonatal adrenoleukodystrophy + infantile Refsum disease
- Peroxisome biogenesis disorders: ZSS (80%) + rhizomelic chondrodysplasia punctata (RCDP)

IMAGING

General Features

- Best diagnostic clue
  - Microgyria, pachygyria, hypomyelination, germinolytic cysts
  - Leukoencephalopathy; volume loss > 1 year
- Location
  - Microgyria most severe in perisylvian region, especially posterior insula
  - Pachygyria most common frontoparietal
  - Diffuse hypomyelination; cerebellum and brainstem may be involved, especially if present > 1 year
- Size
  - Central volume loss common
- Morphology
  - ± heterotopia (periventricular or subcortical)

MR Findings

- T1WI
  - Microgyria, pachygyria, germinolytic cysts (near foramina of Monro), ↓ white matter (WM) signal
  - ± ↑ globus pallidus signal from hyperbilirubinemia
- T2WI
  - Microgyria, pachygyria, germinolytic cysts, ↑ WM signal
- T1WI C+
  - May see enhancement of corticospinal tracts in brainstem
- MRS
  - Use short TE: ↓ NAA; ↑ Cho; lipid peaks at 0.9 and 1.33 ppm

Imaging Recommendations

- Best imaging tool
  - MR + MRS
- Protocol advice
  - Volumetric T1/FLAIR for cysts, TE = 20-30 ms for MRS

DIFFERENTIAL DIAGNOSIS

Congenital CMV

- Ca++, periventricular cysts usually not caudothalamic

Pseudo-TORCH

- Basal ganglia, thalamic, and periventricular Ca++

Single Peroxisomal Enzyme Deficiencies

- Brain MR may be similar; biochemistry different

PATHOLOGY

General Features

- Etiology
  - Defect in biogenesis of peroxisomes
    - Defective transport of proteins into peroxisomal matrix → accumulation of very long chain fatty acids
- Genetics
  - AR defect in any of at least 12 *PEX* genes
- Associated abnormalities
  - Eye: Brushfield spots, retinal pigment degeneration
  - Hepatomegaly, renal cortical cysts
  - Skeletal: Stippled chondral calcification

Gross Pathologic & Surgical Features

- Leukoencephalopathy, germinolytic cysts, cortical and cerebellar malformations
- Subcortical heterotopia, cerebellar hypoplasia

Microscopic Features

- Pachygyria, polymicrogyria, or microgyria
- Sudanophilic leukodystrophy

CLINICAL ISSUES

Presentation

- Most common signs/symptoms
  - Severe hypotonia, seizures, poor sucking
  - Large fontanelle + sutures, high forehead, broad nasal bridge, hypertelorism
- Other signs/symptoms
  - Elevated liver enzymes, hepatomegaly
  - Cataract, nystagmus, retinitis pigmentosa, or optic atrophy
- Clinical profile
  - Low Apgar scores; very floppy, dysmorphic facies

Demographics

- Age
  - Severe at birth, milder at < 6 months, rare adult

Natural History & Prognosis

- Most severely affected die < 3 months, milder may live > 20 years

Treatment

- Supportive, no proven therapy

SELECTED REFERENCES

1. Salpietro V et al: Zellweger syndrome and secondary mitochondrial myopathy. Eur J Pediatr. 174(4):557-63, 2015
2. Crane DI: Revisiting the neuropathogenesis of Zellweger syndrome. Neurochem Int. 69:1-8, 2014
3. van der Knaap MS et al: MRI as diagnostic tool in early-onset peroxisomal disorders. Neurology. 78(17):1304-8, 2012
4. Kulkarni KS et al: Contrast enhancement of brainstem tracts in Zellweger spectrum disorder: evidence of inflammatory demyelination? Neuropediatrics. 42(1):32-4, 2011
5. Krause C et al: Rational diagnostic strategy for Zellweger syndrome spectrum patients. Eur J Hum Genet. 17(6):741-8, 2009
6. Weller S et al: Cerebral MRI as a valuable diagnostic tool in Zellweger spectrum patients. J Inherit Metab Dis. 31(2):270-80, 2008

https://CafePezeshki.IR

KEY FACTS

TERMINOLOGY

- Abbreviations
  - X-linked adrenoleukodystrophy (X-ALD, ALD)
  - Classic childhood ALD (CCALD)
- Inherited peroxisomal disorder
  - *ABCD1* mutation → impaired β-oxidation (β-ox) of very long chain fatty acids (VLCFA)
  - Accumulation of VLCFAs in white matter (WM) causes severe inflammatory demyelination
- Several clinical forms of ALD and related disorders
  - Classic X-linked adrenoleukodystrophy (X-ALD)
    - Severe form almost exclusively in males 5-12 years
  - At least 6 variants other than classic childhood X-ALD
    - Presymptomatic X-ALD, adolescent (AdolCALD), adult (ACALD), adrenomyeloneuropathy (AMN), Addison only, symptomatic female carriers
  - AMN
    - "Mild" adult (spinocerebellar) form, cerebral involvement in up to 50%
    - X-ALD and AMN account for 80% of cases

IMAGING

- Three zones of myelin loss in CCALD
  - Innermost: Necrotic astrogliotic core
  - Intermediate: Enhancing active demyelination, inflammation
  - Peripheral: Advancing demyelination without inflammation

DIAGNOSTIC CHECKLIST

- X-ALD presenting at atypical ages
  - Atypical appearances common
    - Lacks enhancement, may have frontal (rather than posterior) "gradient"
- Always enhance unknown leukodystrophy

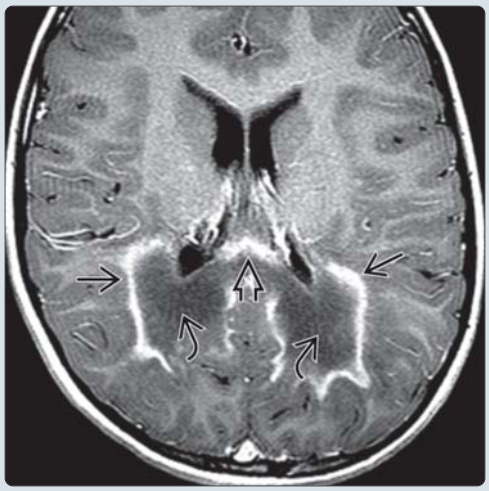

(Left) *Axial graphic demonstrates multiple layers of demyelination. The layers correspond to 3 zones histopathologically. The outer layer ⇨ consists of active destruction and the middle layer ⇨ of active inflammation. Note that the central area ⇨ is burnt out.* **(Right)** *Axial T1WI C+ MR reveals marked rim enhancement ⇨ surrounding the most severely damaged parietal white matter (WM) ⇨ and the splenium of the corpus callosum ⇨ in a preteen male with typical CCALD (Loes pattern 1).*

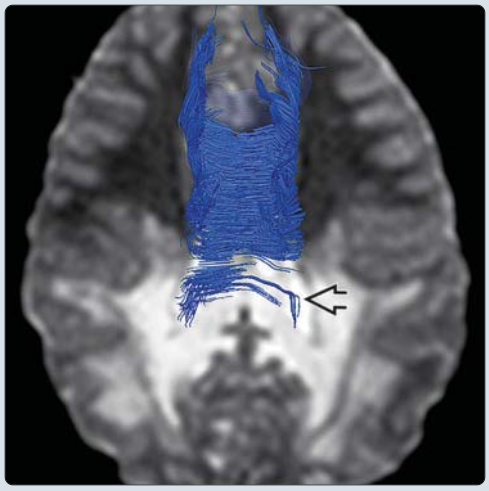

(Left) *Axial T2WI MR distinguishes the active inflammation of the outer zone ⇨ from the innermost "burnt-out" zone of WM destruction ⇨ in this preteen male who presented with well-developed brain involvement.* **(Right)** *Axial tractograph of the corpus callosum from a DTI sequence demonstrates significant loss of WM tracts crossing the splenium of the corpus callosum ⇨ and forceps major in another preteen symptomatic male with CCALD.*

https://CafePezeshki.IR

TERMINOLOGY

Abbreviations

- X-linked adrenoleukodystrophy (X-ALD, ALD)
  - Classic childhood ALD (CCALD)

Definitions

- Inherited peroxisomal disorder
  - *ABCD1* mutation → impaired β-oxidation (β-ox) of very long chain fatty acids (VLCFA)
  - Accumulation of VLCFAs in white matter (WM) causes severe inflammatory demyelination
- Several clinical forms of ALD and related disorders
  - Classic X-ALD
    - Severe progressive form almost exclusively in males 5-12 years
  - At least 6 variants other than classic childhood X-ALD exist: Presymptomatic X-ALD, adolescent (AdolCALD), adult (ACALD), adrenomyeloneuropathy (AMN), Addison only, symptomatic female carriers
    - AMN
      - "Mild" adult (spinocerebellar) form, cerebral involvement in up to 50%
  - X-ALD and AMN account for 80% of cases

IMAGING

General Features

- Best diagnostic clue
  - CCALD: Enhancing peritrigonal demyelination
- Location
  - Classic CCALD: Peritrigonal WM
    - Pattern: Splenium → peritrigonal WM → corticospinal tracts/fornix/commisural fibers/visual and auditory pathways
    - Typically spares subcortical U-fibers
- Morphology
  - Usually symmetrical, confluent, posterior involvement; rare frontal pattern occurs
  - Central (splenium) to peripheral gradient is usual

CT Findings

- NECT
  - ↓ density splenium/posterior WM
  - ± Ca++ of involved WM
- CECT
  - CCALD: Linear enhancement of intermediate zone

MR Findings

- T1WI
  - ↓ T1 signal of involved WM
- T2WI
  - ↑ T2 signal of involved WM
    - CCALD: Splenium → peritrigonal WM → corticospinal tracts/fornix/commisural fibers/visual and auditory pathways
    - AMN: Cerebellum, spinal cord; most common intracranial feature is corticospinal involvement but may resemble CCALD
- FLAIR
  - Same as T2WI
- DWI
  - Reduced diffusion in actively involved WM, increased in chronically involved WM
  - DTI: Reduced brain "connectivity," ↑ isotropic diffusion, and loss of fractional anisotropy in obvious WM change **and** in presymptomatic WM
- T1WI C+
  - Leading edge (intermediate zone) enhances
    - Enhancement strongly linked to progression
- MRS
  - Peaks between 0.9 and 1.4 ppm probably represent VLCFA macromolecules
  - X-ALD: ↓ NAA even in normal-appearing WM predicts progression; ↑ CHO, myoinositol, lactate
- Spinal MR: Spinal atrophy in AMN

Nuclear Medicine Findings

- PET
  - Hypometabolism of occipital lobes
- Tc-99m-HMPAO SPECT: ↑ regional cerebral blood flow in enhancing zone (decreased elsewhere)

Imaging Recommendations

- Best imaging tool
  - MR + contrast
- Protocol advice
  - DWI/DTI and MRS may predict onset of presymptomatic disease

DIFFERENTIAL DIAGNOSIS

Neonatal Hypoglycemia (Acute and Follow-Up)

- May involve splenium, calcar avis, and posterior peritrigonal WM but does not enhance

White Matter Disease With Lactate (WML)

- Involves splenium, peritrigonal WM, and corticospinal tracts but does not enhance

Alexander Disease

- Enhances, but frontal not peritrigonal WM

PATHOLOGY

General Features

- Etiology
  - Peroxisomes: Ubiquitous organelles involved in catabolic pathways
    - Involved with myelin formation/stabilization
    - Defect in VLCFA importer → impaired β-ox of VLCFA
    - VLCFA accumulate in WM → brittle myelin
- Genetics
  - X-ALD: X-linked recessive
    - Mutations of *ABCD1* gene at Xq28 (> 300 described)
    - ABCD1 is ATPase transporter protein: "Traffic" ATPase
    - Required for transport hydrophilic molecules across peroxisomal membrane
  - Phenotypic variability: CCALD, AMN, or presymptomatic presentations even within same family
  - Clinical heterogeneity attributed (in part) to specific mutations, modifying factors
    - Insertion allele of CBS c.844_845ins68 protects against CNS demyelination

https://CafePezeshki.IR

  - G allele of Tc2 c.776C > G more common in demyelinating forms (CCALD)
- Associated abnormalities
  - VLCFA accumulates in all tissues of body
  - Symptomatic accumulation: CNS myelin, adrenal cortex, Leydig cell testes
    - Adrenal failure: Skin bronzing
    - Testes: Early androgenetic alopecia in adults

Staging, Grading, & Classification

- Loes MR scoring system: Severity score based upon location, extent of disease, and atrophy
  - Pattern 1: Parietooccipital WM (rapid progression if contrast-enhancement present and very young)
  - Pattern 2: Frontal WM (same as pattern 1)
  - Pattern 3: Corticospinal tract (adults, slower progression)
  - Pattern 4: Corticospinal tract and cerebellar WM (adolescents, slower progression)
  - Pattern 5: Concomitant parietooccipital and frontal WM (mainly childhood, extremely rapid)

Gross Pathologic & Surgical Features

- Atrophy, WM softened

Microscopic Features

- Complete myelin loss (U-fibers preserved), astrogliosis
- Zone-specific features
  - Innermost zone of necrosis, gliosis ± Ca++
  - Intermediate zone of active demyelination and inflammation
  - Peripheral zone of demyelination without inflammation

CLINICAL ISSUES

Presentation

- Most common signs/symptoms
  - Skin bronzing, behavioral difficulties, hearing problems
- Clinical profile
  - Phenotypes unpredictable (even intrafamilial)
- Classic childhood cerebral X-ALD (CCALD): 35-50%, but percentage ↓ as new forms diagnosed
  - Preteen male (3-10 years): Behavioral, learning, gait, hearing, vision difficulties
  - Addison/adrenal insufficiency (skin bronzing, nausea and vomiting, fatigue) may predate X-ALD diagnosis
- AMN (25%)
  - 14-60 years
  - Spinal involvement > > brain involvement; peripheral nerve involvement
  - Brain inflammatory reaction eventually in 50%; variable demyelination/enhancement
- Presymptomatic ALD (12%)
  - Abnormal genetic testing (due to known symptomatic brother or maternal uncle)
- 20-50% female carriers develop AMN-like symptoms (milder, age related)
- Other presentations less common
  - AdolCALD: 10-20 years, symptoms and course similar to CCALD
  - ACALD: May be misdiagnosed as psychiatric disorder, very rapid progression, diffuse rather than posterior pattern

Demographics

- Age
  - CCALD: Preteen males
- Gender
  - Males in classic X-ALD
  - Female carriers may show AMN-like symptoms
- Ethnicity
  - CCALD predominates in North America and France
  - AMN predominates in Netherlands
- Epidemiology
  - X-ALD and variants = 1:16,800 North American births

Natural History & Prognosis

- CCALD: Progresses to spastic quadriparesis, blindness, deafness, vegetative state
- AMN: Spastic, weak legs; sphincter/sexual dysfunction

Treatment

- CCALD: Vegetative state, death in 2-5 years without bone marrow transplant (BMT)
  - Lorenzo oil delays symptoms in presymptomatic ALD
  - Early BMT stabilizes demyelination: RARE reversal demyelination

DIAGNOSTIC CHECKLIST

Consider

- X-ALD presenting at atypical ages → atypical appearances (may lack enhancement or have frontal rather than posterior "gradient")

Image Interpretation Pearls

- Always enhance unknown leukodystrophy

Reporting Tips

- Loes scoring aids pattern analysis

SELECTED REFERENCES

1. Parikh S et al: A clinical approach to the diagnosis of patients with leukodystrophies and genetic leukoencephelopathies. Mol Genet Metab. 114(4):501-515, 2015
2. Siddiqui S et al: MRI in X-linked adrenoleukodystrophy. Neurology. 84(2):211, 2015
3. de Beer M et al: Frequent occurrence of cerebral demyelination in adrenomyeloneuropathy. Neurology. 83(24):2227-31, 2014
4. Engelen M et al: X-linked adrenoleukodystrophy in women: a cross-sectional cohort study. Brain. 137(Pt 3):693-706, 2014
5. Engelen M et al: X-linked adrenoleukodystrophy: pathogenesis and treatment. Curr Neurol Neurosci Rep. 14(10):486, 2014
6. McKinney AM et al: Childhood cerebral X-linked adrenoleukodystrophy: diffusion tensor imaging measurements for prediction of clinical outcome after hematopoietic stem cell transplantation. AJNR Am J Neuroradiol. 34(3):641-9, 2013
7. Santosh Rai PV et al: Childhood adrenoleukodystrophy - Classic and variant - Review of clinical manifestations and magnetic resonance imaging. J Pediatr Neurosci. 8(3):192-7, 2013
8. Engelen M et al: X-linked adrenoleukodystrophy (X-ALD): clinical presentation and guidelines for diagnosis, follow-up and management. Orphanet J Rare Dis. 7:51, 2012
9. Semmler A et al: Genetic variants of methionine metabolism and X-ALD phenotype generation: results of a new study sample. J Neurol. 256(8):1277-80, 2009
10. Shukla P et al: Three novel variants in X-linked adrenoleukodystrophy. J Child Neurol. 24(7):857-60, 2009
11. Ratai E et al: Seven-Tesla proton magnetic resonance spectroscopic imaging in adult X-linked adrenoleukodystrophy. Arch Neurol. 65(11):1488-94, 2008

https://CafePezeshki.IR

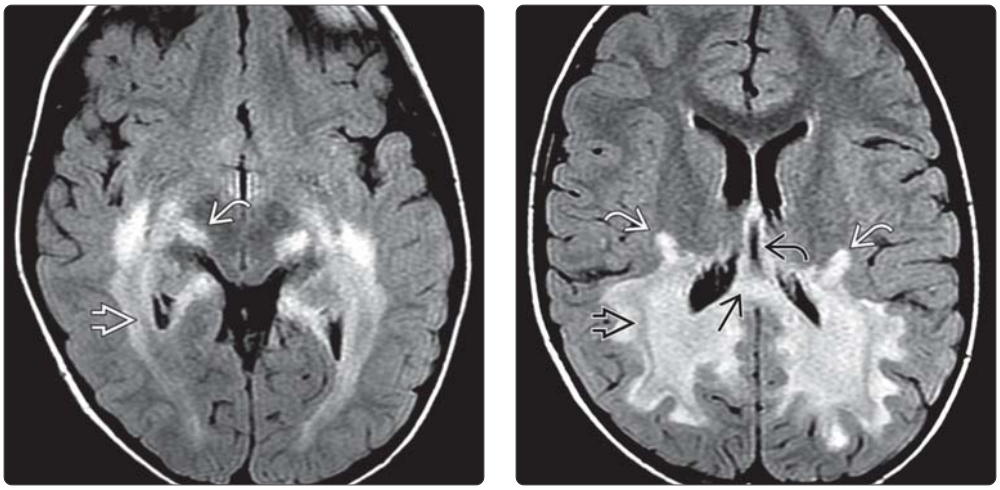

(Left) *Axial FLAIR MR in CCALD (ALD pattern 1) demonstrates hyperintensity of the medial geniculate body along with the periventricular and deep WM of the temporal and occipital lobes.* **(Right)** *Axial FLAIR MR in the same child with CCALD reveals hyperintensity of the posterior columns of the fornices, the splenium of the corpus callosum, and multilayered involvement in the peritrigonal WM and external/extreme capsules.*

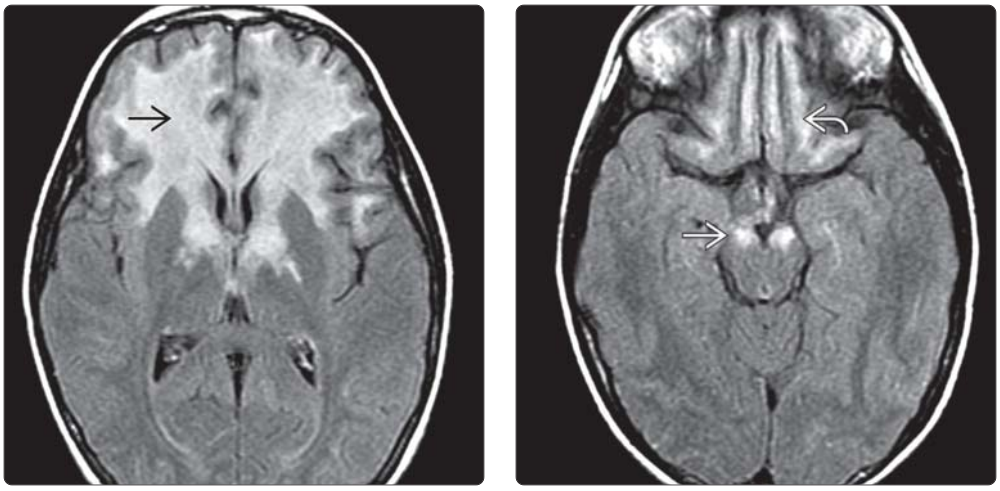

(Left) *Axial FLAIR shows confluent bifrontal white matter hyperintensity. Abnormal signal extends into the caudate heads, globi pallidi, and anterior limbs of internal capsules in this frontal variant case (Loes pattern 2) of proven X-ALD in a school-aged male.* **(Right)** *Axial FLAIR in the same patient shows symmetrical WM hyperintensities in the internal capsules as they extend into the cerebral peduncles and in the juxtacortical frontal WM.*

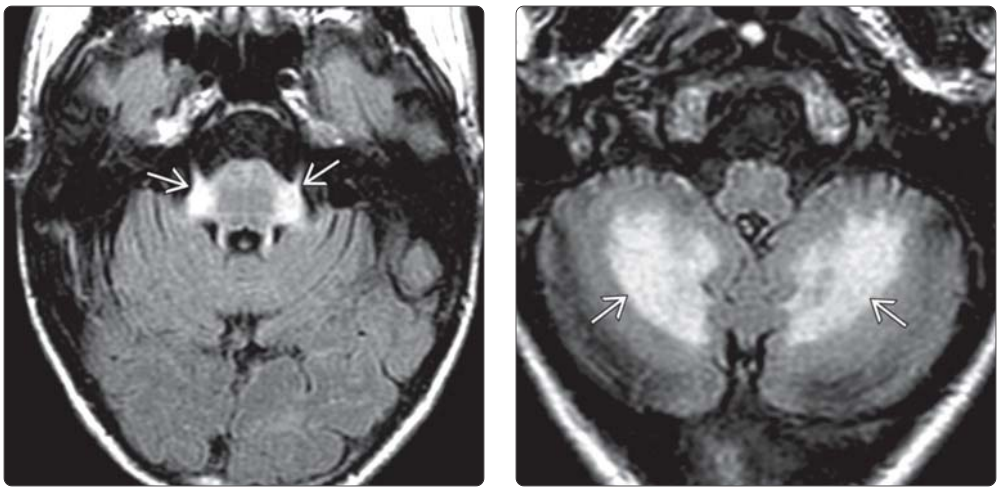

(Left) *Axial FLAIR MR through the mid pons shows striking demyelination in the lateral pons/root entry zones and both CN5s in an adult with Loes pattern 4.* **(Right)** *Axial FLAIR MR at the level of the medulla and lower cerebellum in the same adult with trigeminal nerve involvement shows symmetric hyperintensity in the cerebellar WM (Loes pattern 4 of ALD).*

https://CafePezeshki.IR

KEY FACTS

TERMINOLOGY

- Peroxisomal disorders; peroxisomal biogenesis or assembly disorders (PBD); single peroxisomal enzyme (transporter) deficiencies (PED)
- PBD: Zellweger syndrome (ZS), neonatal adrenoleukodystrophy (NALD), infantile Refsum disease (IRD), rhizomelic chondrodysplasia punctata (RCDP) type 1
- PED composed of ≥ 16 disorders with gene mutation affecting single protein in peroxisomal function
- Peroxisomes: Membrane-bound subcellular organelles involved in catabolic and anabolic pathways

IMAGING

- ZSD continuum: ZS most severe, NALD intermediate, IRD least severe
- D-bifunctional protein and Acyl-CoA oxidase deficiencies: ZS like
  - Look for WM disease in corticospinal tracts
  - Look for posterior perisylvian PMG
- RCDP: ↑ intensity periventricular white matter (WM), centrum semiovale, delayed occipital myelination

PATHOLOGY

- Intact peroxisomal function required for normal brain formation, deficiency → neocortical dysgenesis
- Peroxisomes normally located near developing myelin sheaths in oligodendroglial cells at peak of myelin formation
- Genetics: Phenotype depends on both gene mutated and effect of mutation on gene function

DIAGNOSTIC CHECKLIST

- Use MR with DWI, MRS

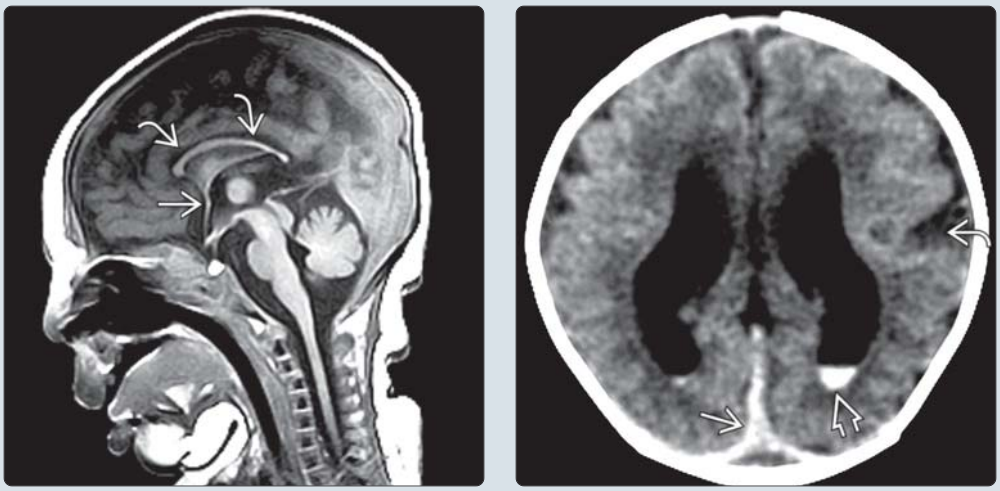

(Left) *Sagittal T1WI MR in a 28 day old with non-Zellweger peroxisomal biogenesis disorder and facial dysmorphism reveals flat face, significant retrognathia, microcephaly, thin corpus callosum ⇄, and small anterior commissure ⇒.* **(Right)** *Axial NECT in a 5 day old with non-Zellweger peroxisomal biogenesis disorder and hepatic dysfunction reveals primitive sylvian fissures ⇄, small subdural collection ⇒, and blood layering ⇒ within the posterior horns of the lateral ventricles.*

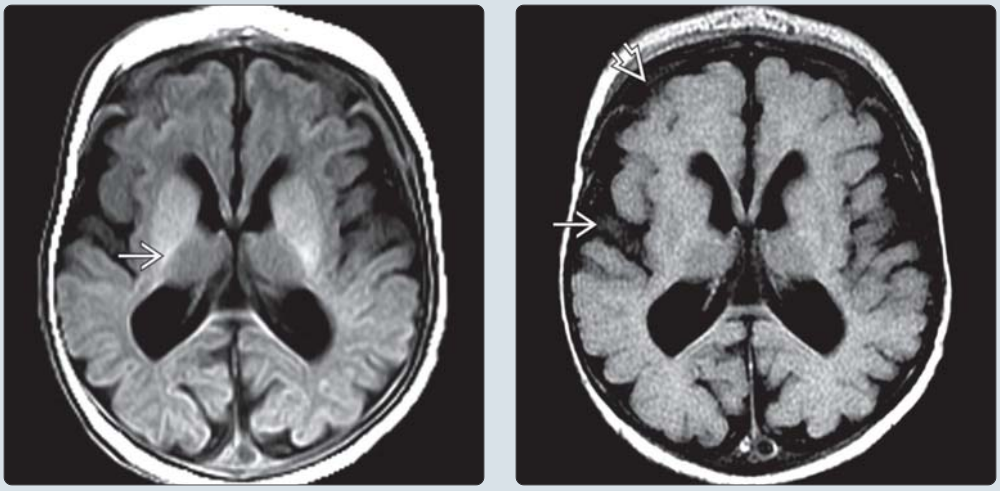

(Left) *Axial T1WI MR in a full-term infant with non-Zellweger peroxisomal biogenesis disorder demonstrates mild ventriculomegaly, enlarged subarachnoid spaces, and failure of myelin maturation within the posterior limb of the internal capsule ⇒. Lentiform nuclei are abnormally hyperintense.* **(Right)** *Axial FLAIR MR in the same microcephalic infant demonstrates prominent pericerebral fluid spaces ⇒ and underoperculized sylvian fissures ⇒.*

https://CafePezeshki.IR

TERMINOLOGY

Abbreviations

- Peroxisomal biogenesis or assembly disorders (PBD)
- Single peroxisomal enzyme (transporter) deficiencies (PED)
- PBD: Zellweger syndrome (ZS), neonatal adrenoleukodystrophy (NALD), infantile Refsum disease (IRD), rhizomelic chondrodysplasia punctata (RCDP) type 1, other nonspecific phenotypes
  - Zellweger spectrum disorders (ZSD): Triad of ZS, NALD, IRD (but not RCDP) phenotypes
  - RCDP type 1: Normal β-oxidation of very long chain fatty acids (VLCFA), therefore different profile
- PED composed of ≥ 16 disorders with gene mutation affecting single protein in peroxisomal function
  - Peroxisomal fatty acid β-oxidation
    - Adrenoleukodystrophy protein (X-ALD); deficiencies of alkyl-DHAP-synthase (RCDP type 3); Acyl-CoA oxidase, D-bifunctional protein (D-BP), sterol carrier protein X (SCPx), and 2-methylacyl CoA racemase (AMACR)
  - Ether phospholipid biosynthesis (especially plasmalogens)
    - DHAP-alkyl transferase (DHAPAT; RCDP type 2)
  - Phytanic acid α-oxidation: Adult Refsum disease (ARD)
  - Glyoxylate detox: Primary hyperoxaluria type 1
  - Hydrogen peroxide metabolism: Acatalasemia
  - Degradation of methy-branched phytanic acid: Phytanic acid accumulation

Definitions

- Peroxisomes: Membrane-bound subcellular organelles involved in catabolic and anabolic pathways, collaborate with other organelles
  - > 50 enzymes are contained within peroxisomes, majority in lipid metabolism

IMAGING

General Features

- Best diagnostic clue
  - PBD: Abnormal myelin in corticospinal tracts ± dentate nuclei, ± cortical dysplasia
- Location
  - Corticospinal tracts ± dentate nuclei

Radiographic Findings

- Radiography
  - ZS and RCDP: Rhizomelia, stippled epiphyses
  - RCDP and DHAP deficiencies: Coronal vertebral clefts
  - ARD: Short metacarpals/metatarsals (30%)

CT Findings

- NECT
  - X-ALD: Occasional punctate white matter (WM) calcifications

MR Findings

- T2WI
  - ZSD continuum: ZS most severe, NALD intermediate, IRD least severe
    - ZS: ↑ intensity WM/myelin delay, neocortical dysplasia/polymicrogyria (PMG), atrophy, late cerebral and cerebellar demyelination
      - PMG most common in posterior insula, posterior perisylvian cortex
    - NALD: PMG, progressive WM disease
    - IRD: No neuronal migration anomalies, WM nonprogressive ± improvement
  - D-BP and Acyl-CoA oxidase deficiencies: ZS like
    - D-BP: Occasional thalami and globus pallidus involvement (unlike PBD)
  - RCDP: ↑ intensity periventricular WM, centrum semiovale, delayed occipital myelination
  - SCPx: Thalamic, pons, occipital ↑ intensity
  - AMACR: Deep WM ↑ intensity
- DWI
  - X-ALD: Intermediate zone ↓ ADC
  - PBD: ↑ ADC values
- T1WI C+
  - X-ALD: Leading edge enhancement
  - Acyl-CoA oxidase deficiency: Enhancing centrum semiovale lesions

Ultrasonographic Findings

- ZS: Renal cysts
- ZSD and D-BP: Hepatomegaly

Imaging Recommendations

- Best imaging tool
  - MR
- Protocol advice
  - MR, DWI, MRS, C+

DIFFERENTIAL DIAGNOSIS

ZSD Mimics

- Bilateral perisylvian polymicrogyria
- Congenital cytomegalovirus infection

RCDP 1 Mimics

- X-linked dominant chondrodysplasia punctata: Conradi–Hünermann–Happle syndrome
- Warfarin embryopathy

PATHOLOGY

General Features

- Etiology
  - VLCFA and phytanic acid incorporated into cell membranes → cell dysfunction, atrophy, and death
- Genetics
  - Phenotype severity varies with nature of mutation
    - *PEX1*: G843D does not abolish peroxisomal protein import completely → mild (NALD, IRD), while c.2097-2098insT mutation abolishes import completely → severe (ZS)
    - *PEX7*: L292X → classical, severe RCDP phenotype, while A218V → milder RCDP
  - PED may clinically resemble PBD
    - D-BP and Acyl-CoA oxidase deficiencies: ZS like

https://CafePezeshki.IR

  - Defects involving first 2 steps of plasmalogens (DHAP-alkyl transferase, DHAP-synthase deficiencies): RCDP/*PEX7* like
- PBD: Organelle fails to form, multiple peroxisomal functions defective
- PBD have *PEX* gene mutations; disorder depends on both gene affected and specific mutation
  - *PEX1*, PEX*6*, *PEX12*, *PEX26*: ZS, NALD, IRD
  - *PEX2*: ZS, IRD
  - *PEX5*, *PEX10*, *PEX13*: ZS, NALD
  - *PEX3*, *PEX14*, *PEX16*, PEX *19*: ZS
  - *PEX 7*: RCDP 1
- PED: Single peroxisomal enzyme deficiency
  - ARD: Phytanoyl-CoA hydroxylase
  - X-ALD: *ABCD1* gene mutation
  - Acyl-CoA oxidase: ZS-like phenotype (less severe)
  - D-BP: ZS-like phenotype (severe)
  - SCPx: Sterol carrier protein X, single family
  - PH1: *AGXT* gene mutation, glyoxylate aminotransferase 1 (AGT) deficient (catalyzes transamination of glyoxylate to glycine) → ↑ glyoxylate oxidation to oxalate → renal stones ± systemic hyperoxaluria
  - Acatalasemia: Impaired hydrogen peroxide detoxification → ↑ risk of diabetes

Staging, Grading, & Classification

- Marked genetic heterogeneity complicates genotype-phenotype correlation

Gross Pathologic & Surgical Features

- Intact peroxisomal function required for normal brain formation, deficiency → neocortical dysgenesis
- Peroxisomes located near developing myelin sheaths in oligodendroglial cells at peak of myelin formation
  - Deficiency → defect in central WM formation/maintenance and myelin lipid reduction

Microscopic Features

- Neuropathologic lesions
  - Abnormalities in neuronal differentiation/migration
  - Inflammatory dysmyelination or noninflammatory demyelination
- Postdevelopmental neuronal degeneration
  - Adrenomyeloneuropathy (AMN): Spinal cord axonopathy
  - IRD, RCDP: Cerebellar atrophy
- PH1: Rare reports of oxalate crystals in brain
- ZS: Additional olivary dysplasia

CLINICAL ISSUES

Presentation

- Most common signs/symptoms
  - CNS involvement manifests during development &/or later in life
- Other signs/symptoms
  - BPD
    - ZSD: Frontal bossing, marked hypotonia, hepatomegaly, perinatal apnea, seizures, jaundice, cataracts, retinopathy, deafness
    - RCDP: Rhizomelia, dwarfism/short stature, broad nasal bridge (koala bear face), epicanthus, microcephaly, mental retardation, cataracts
  - PED
    - D-BP and Acyl-CoA oxidase deficiencies: ZS like
    - ARD: Classic tetrad of peripheral polyneuropathy, cerebellar ataxia, ↑ CSF protein, retinitis pigmentosa; also ichthyosis, psychiatric disorders, cardiac arrhythmias, anosmia, deafness
    - X-ALD: Behavioral, learning, and hearing difficulties, skin bronzing
    - SCPx: Dystonia, azoospermia/hypogonadism, hyposmia
    - AMACR: Rare, variable findings (tremor, pyramidal signs, seizures, sensory motor neuropathy)
    - PH1: Renal stones or renal failure with systemic oxalosis (bone pain, fractures, myocarditis, embolic stroke, retinopathy)

Demographics

- Age
  - Most: Neonatal
  - X-ALD, classic Refsum: Childhood or adult onset
- Epidemiology
  - Peroxisomal disorders in 1:5,000 births

Natural History & Prognosis

- PBD: Variable neurodevelopmental delays, retinopathy, deafness, liver disease
  - ZSD and look-alikes share imaging and clinical phenotype; most fail to gain milestones, severe phenotypes die within 1st year of life
  - RCDP and look-alikes: Severe and mild phenotypes
- PED: Variable
  - X-ALD: Progression to vegetative state if untreated
  - PH1: Progression to systemic oxalosis (myocardium, bone marrow, eyes, peripheral nerves); rapidly progressive (death in 1st year) and mild phenotypes

Treatment

- PBD: Limited by multiple malformations and metabolic defects originating in utero
- PED: X-ALD (cholesterol lowering drugs, VLCFA restriction, bone marrow transplant), ARD (phytanic acid restriction), PH1 (pyridoxine → ↓ production oxalate; alkalinize urine to ↑ oxalate solubility

DIAGNOSTIC CHECKLIST

Consider

- Plasma biochemical abnormalities may be absent
- Analysis of cultured skin fibroblasts indicated if strong imaging and clinical suspicion

SELECTED REFERENCES

1. Lamari F et al: An overview of inborn errors of complex lipid biosynthesis and remodelling. J Inherit Metab Dis. 38(1):3-18, 2015
2. Schrader M et al: Peroxisome-mitochondria interplay and disease. J Inherit Metab Dis. ePub, 2015
3. Crane DI: Revisiting the neuropathogenesis of Zellweger syndrome. Neurochem Int. 69:1-8, 2014
4. Barry DS et al: Peroxisomes: the neuropathological consequences of peroxisomal dysfunction in the developing brain. Int J Biochem Cell Biol. 45(9):2012-5, 2013
5. Braverman NE et al: Peroxisome biogenesis disorders: Biological, clinical and pathophysiological perspectives. Dev Disabil Res Rev. 17(3):187-96, 2013

https://CafePezeshki.IR

(Left) *Axial FLAIR MR in a 3 year old with peroxisomal chondrodysplasia punctata demonstrates increased signal intensity in the peritrigonal white matter ➡ and periventricular white matter (WM) of the right frontal horn ➡, as well as scattered foci of abnormal increased signal ➡.* **(Right)** *Anteroposterior radiograph in a 2 year old with peroxisomal chondrodysplasia punctata demonstrates coxa vara with stippling of the triradiate cartilage ➡. Bone radiographs can help to specify diagnosis.*

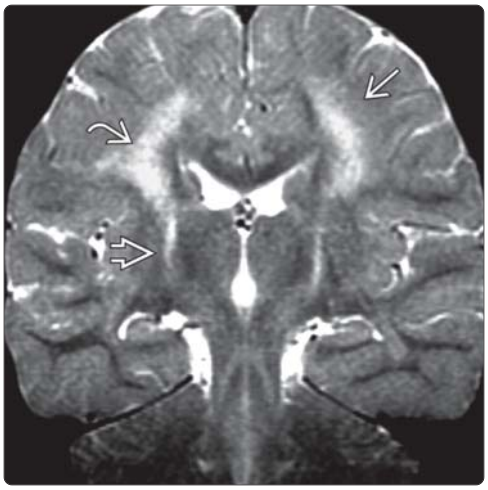

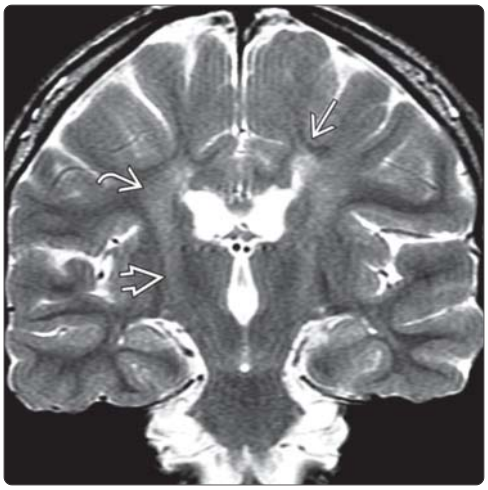

(Left) *Coronal T2WI MR in a 4 year old with infantile Refsum demonstrates abnormal signal intensity within the corticospinal tracts ➡ and periventricular white matter ➡. Note the poor myelin maturation in the subcortical U-fibers ➡.* **(Right)** *Follow-up coronal T2WI MR in the same patient at age 16 shows partial resolution of findings. Note the progressive myelin maturation of the subcortical U-fibers ➡ and (incomplete) improvement of periventricular white matter ➡ and corticospinal tracts ➡.*

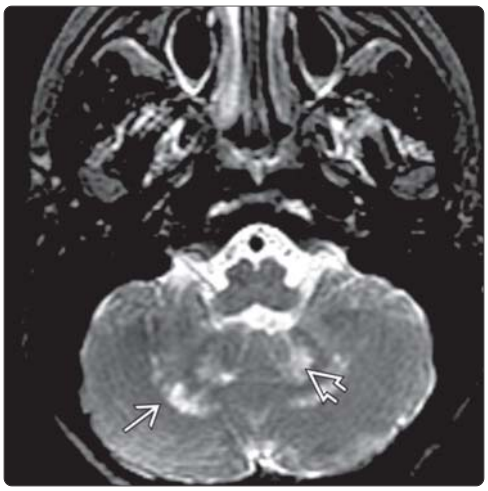

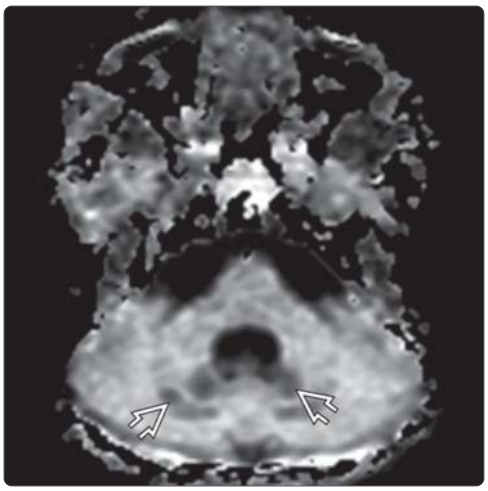

(Left) *Axial T2WI MR in the same patient demonstrates persistent and typical abnormal signal intensity in the cerebellar white matter ➡ and hila of the deep cerebellar nuclei ➡. The brainstem appears normal.* **(Right)** *Axial DWI MR in the same patient fails to demonstrate any evidence of reduced diffusion in the abnormal foci ➡, suggesting that the injury is subacute or chronic.*

https://CafePezeshki.IR

KEY FACTS

TERMINOLOGY

- Maple syrup urine disease (MSUD)
- Inherited disorder of branched-chain amino acid (BCAA) metabolism
- Typically presents at 4-10 days of age with neurologic deterioration, ketoacidosis, hyperammonemia

IMAGING

- MR with DWI best, but CT can make diagnosis in critically ill infant
- Classic MSUD edema/restriction pattern
  - Cerebellar white matter, dorsal brainstem, cerebral peduncles, thalami, globi pallidi
  - Pyramidal and tegmental tracts
  - Infratentorial > > > supratentorial edema
- Broad peak at chemical shift of 0.9 ppm

PATHOLOGY

- MSUD: ↓ activity branched-chain α-keto acid dehydrogenase complex (BCKD) → accumulation of branched-chain L-amino (BCAA) and metabolites (neuro- and leukotoxic)

CLINICAL ISSUES

- Initial symptoms of classic MSUD: Poor feeding, vomiting, poor weight gain, increasing lethargy, encephalopathy, seizures
- Patients in crisis often (but not always) smell like maple syrup (or burnt sugar)
- 1:850,000 in general population but as frequent as 1:170 in population isolates
- MSUD has potentially favorable outcome with strict dietary control and aggressive treatment of metabolic crises
- Response to therapy; however, can be variable

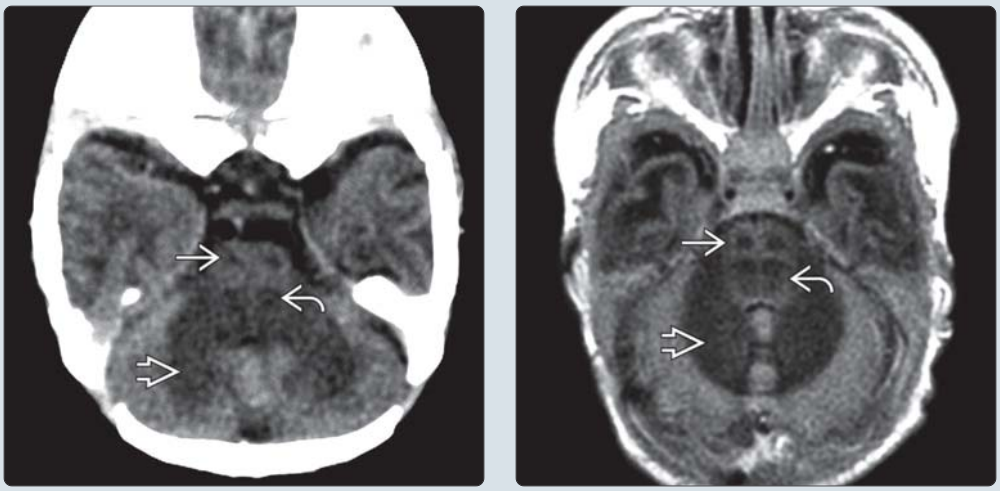

(Left) *Axial NECT in a seizing newborn who returned to the hospital at 10 days of age demonstrates classic MSUD edema pattern. Note hypodensity in cerebellar white matter ⇨, dorsal pons, and 4 foci in the anterior and middle pons, which are paired pyramidal ⇨ and tegmental tracts ⇨.* **(Right)** *Axial T1WI MR in a different infant with lethargy and feeding difficulty shows the same MSUD pattern: Hypointensity in the cerebellar white matter ⇨ and paired pyramidal ⇨ and tegmental tracts ⇨.*

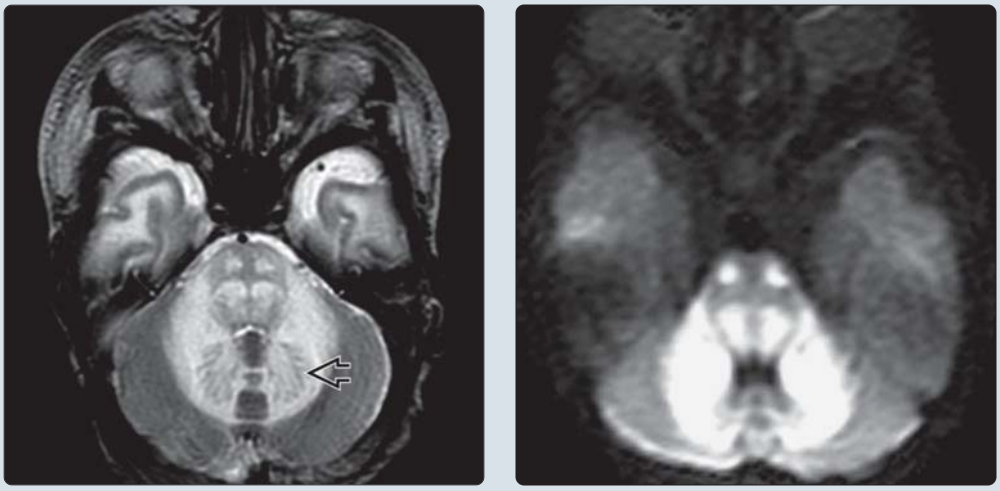

(Left) *Axial T2WI MR demonstrates crisp margins of the signal abnormality of the cerebellar white matter. Again seen are the paired tracts (4 bright pontine foci) superimposed on signal abnormality in the pons. The dentate nuclei ⇨ stand out against the abnormal MSUD edema.* **(Right)** *Axial DWI MR confirms intramyelinic edema in a MSUD pattern, showing reduced diffusivity (hyperintensity). DWI is extremely useful in the acute and subacute phase of MSUD.*

https://CafePezeshki.IR

TERMINOLOGY

Abbreviations

- Maple syrup urine disease (MSUD)

Synonyms

- Leucine encephalopathy

Definitions

- Inherited disorder of branched-chain amino acid (BCAA) metabolism presenting in newborns with neurologic deterioration, ketoacidosis, and hyperammonemia
- Intermediate form presents later with developmental delay and failure to thrive
- Intermittent form presents in late infancy (or later) with episodic decompensation
  - Ataxia, disorientation, altered behavior

IMAGING

General Features

- Best diagnostic clue
  - Radiologist may be 1st to suggest diagnosis based on classic-appearing MSUD edema
    - Cerebellar white matter, brainstem, thalamus, globus pallidus
    - Pyramidal and tegmental tracts
- Location
  - Cerebellar and brainstem edema > > > supratentorial hemispheres
    - Most prominent in dorsal brainstem, cerebellar white matter
    - Edema of corticospinal tracts
    - These areas show reduced diffusivity on ADC maps

CT Findings

- NECT
  - Early: Diffuse edema **not** sparing brainstem and cerebellum
    - Recognize here for best neurocognitive outcome
  - Subacute: Rapid formation of typical (classic) MSUD edema pattern
    - Cerebellar white matter, dorsal brainstem, cerebral peduncles, thalami, pyramidal, and tegmental tracts > supratentorial hemispheres
    - Margins become sharp during subacute phase

MR Findings

- T1WI
  - ↓ signal intensity; margins may be sharp
- T2WI
  - Late: Generalized and MSUD edema disappear
    - Resolve to "pallor" and volume loss
- FLAIR
  - Insensitive to fluid shifts in newborns
- DWI
  - Marked restriction (↑ intensity) and ↓ ADC (MSUD edema = cytotoxic/intramyelinic)
  - DTI: ↓ anisotropy
- MRS
  - Broad peak at chemical shift of 0.9 ppm; this is present with both short-echo and long-echo spectra

Ultrasonographic Findings

- Grayscale ultrasound
  - ↑ echogenicity of globi pallidi, periventricular white matter, brainstem, cerebellar white matter

Imaging Recommendations

- Best imaging tool
  - DWI during hyperacute and acute phases
- Protocol advice
  - MR with diffusion-weighted imaging best, but CT can make diagnosis in critically ill infant

DIFFERENTIAL DIAGNOSIS

Disorders Causing Brainstem and Cerebellar Swelling

- Mitochondrial *SURF1* mutations: Lactate may be seen in this **and** in MSUD during crisis
- Alexander disease: Abnormal signal and enhancement of brainstem and aqueduct
- Vanishing white matter: Findings are persistent

Hypoxic-Ischemic Encephalopathy

- No symptom-free interval, usually positive history
- Cerebellum, brainstem relatively spared (MSUD involves these areas)

Marchiafava-Bignami

- Myelin splitting disorder of adult red wine drinkers
- Splits corpus callosum

PATHOLOGY

General Features

- Etiology
  - MSUD: ↓ activity branched-chain α-keto acid dehydrogenase complex (BCKD) → accumulation of branched-chain L-amino (BCAA) and metabolites (neuro- and leukotoxic)
  - ↑ brain leucine displaces other essential amino → neurotransmitter depletion, disrupted brain growth and development
  - Branched-chain ketoacid accumulation → thought to disrupt Krebs cycle
- Genetics
  - > 50 different mutations in genes governing enzyme components of BCKD
    - e.g., E1α (33%), E1β (38%), E2 (19%)
  - Autosomal recessive
- Associated abnormalities
  - ↑ plasma isoleucine associated with maple syrup odor
  - Maternal ingestion of fenugreek during labor gives false impression of MSUD
    - Shares component and smell with MSUD urine

Staging, Grading, & Classification

- Classical, intermediate, and intermittent forms of MSUD; thiamine-responsive MSUD

Gross Pathologic & Surgical Features

- Brainstem edema
- Spongy degeneration: White matter, basal ganglia

https://CafePezeshki.IR

Microscopic Features

- ↓ oligodendrocytes and astrocytes
- Alterations in neuronal migration, maturation
  - Aberrant orientation of neurons
  - Abnormal dendrites/dendritic spines

CLINICAL ISSUES

Presentation

- Most common signs/symptoms
  - Initial symptoms of classic MSUD: Poor feeding, vomiting, poor weight gain, increasing lethargy
    - In neonates, develops within 4-7 days
  - Patients in crisis often (but not always) smell like maple syrup (or burnt sugar)
    - Resuscitation with non-protein-containing oral or IV hydrating fluids may "clear" odor
    - Maple syrup odor may be difficult to identify in 1st days of life unless urine-soaked diaper allowed to dry
    - Maple syrup odor of cerumen "more predictable"
  - Neonates in communities with known high MSUD risk diagnosed within hours of blood sampling
    - If tested **and** receive immediate results **and** therapy is instituted, then may have excellent outcome
    - Tandem mass spectrometry of whole blood filter paper shortens diagnosis time
    - Guthrie test insensitive before 24 hours, requires incubation period and has high false-positive rate
- Clinical profile
  - Normal at birth
  - Presents after disease-free interval, usually within 1st 48 hours to 2 weeks of life
  - Mimic of sepsis: Acute encephalopathy, vomiting, seizures, neurological distress, lethargy, coma, leukopenia/thrombopenia
    - Additionally, free water retention, renal salt wasting and hyponatremia, dehydration
  - Plasma detection of alloisoleucine diagnostic
    - May not appear until 6th day of life
  - Ketosis or ketoacidosis and hyperammonemia
  - Typical EEG: Comb-like rhythms
  - Prenatal diagnosis can be performed on cultured amniocytes or chorion villus cells

Demographics

- Age
  - May be diagnosed on day 1 of life if MSUD suspected
- Ethnicity
  - 1/170 live births in certain population isolates (founder effect in Old Order Mennonites)
  - High carrier rate in Middle East and Ashkenazi Jewish descendants
- Epidemiology
  - 1:850,000 in general population but as frequent as 1:170 in population isolates

Natural History & Prognosis

- Breastfeeding may delay onset of symptoms to 2nd week of life
- MSUD has potentially favorable outcome with strict dietary control and aggressive treatment of metabolic crises
  - Response to therapy, however, can be variable
  - Exposure to high levels, BCAAs and their metabolites neurotoxic
  - Uncontrolled BCAA levels → profound cognitive impairment/death
  - Pretreatment plasma leucine > 40 mg/100 mL **or** encephalopathy > days associated with poor cognitive outcome
- May survive to adulthood if well controlled
  - Metabolic "intoxication" **at any age** may be provoked by infection, injury, stress, fasting, or even pregnancy
- Reports of late (adulthood) development of peripheral neuropathy
- Exfoliative skin and corneal lesions from inadequate amino-acid intake

Treatment

- Acute "metabolic rescue" to reverse cerebral edema
- May require hemodialysis during acute crisis to limit neurotoxicity/damage
- Metabolically appropriate diet (protein modified) minimizes severity
  - Inhibit endogenous protein catabolism while sustaining protein synthesis
  - Prevent deficiencies of essential amino acids
  - Maintain normal serum osmolarity
  - Commercially available formulas, foods are available without BCAAs or with reduced levels of BCAAs
  - Dietary therapy must be lifelong
- Neonatal screening (tandem mass spectrometry) can diagnose
- Orthotopic liver transplantation increases availability of BCKD (rarely used)
- Gene therapy experimental

DIAGNOSTIC CHECKLIST

Consider

- Neonatal testing for MSUD is **not** universal
- Not all MSUD occurs in population isolates
- Even if testing performed, results may be available only after 1-2 weeks in nonendemic areas

Image Interpretation Pearls

- Neonatal brain edema that includes posterior fossa and brainstem is highly suggestive of MSUD

SELECTED REFERENCES

1. Xia W et al: Diffusion-weighted magnetic resonance imaging in a case of severe classic maple syrup urine disease. J Pediatr Endocrinol Metab. ePub, 2015
2. Sato T et al: Neonatal case of classic maple syrup urine disease: usefulness of (1) H-MRS in early diagnosis. Pediatr Int. 56(1):112-5, 2014
3. Strand JM et al: Genome instability in Maple Syrup Urine Disease correlates with impaired mitochondrial biogenesis. Metabolism. 63(8):1063-70, 2014
4. Yang E et al: Imaging manifestations of the leukodystrophies, inherited disorders of white matter. Radiol Clin North Am. 52(2):279-319, 2014
5. Terek D et al: Diagnostic tools of early brain disturbances in an asymptomatic neonate with maple syrup urine disease. Neuropediatrics. 44(4):208-12, 2013
6. Gropman AL: Patterns of brain injury in inborn errors of metabolism. Semin Pediatr Neurol. 19(4):203-10, 2012

https://CafePezeshki.IR

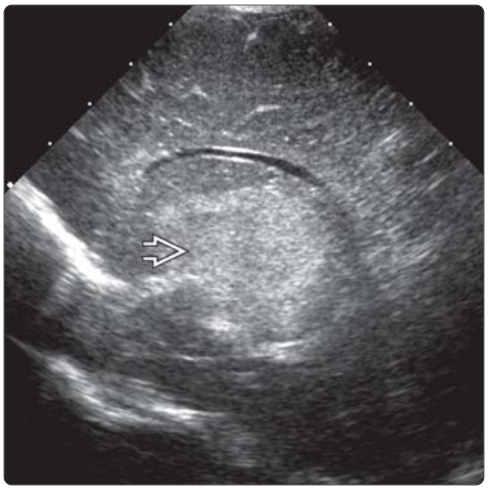

(Left) *Sagittal T1WI MR in an encephalopathic newborn reveals marked swelling of the entire brainstem. Low signal of the involved brainstem, cerebellar white matter, and subcortical cerebral white matter is also present.* **(Right)** *Parasagittal ultrasound in another symptomatic newborn with maple syrup urine disease (MSUD) demonstrates markedly increased echogenicity of the thalami due to the severe edema.*

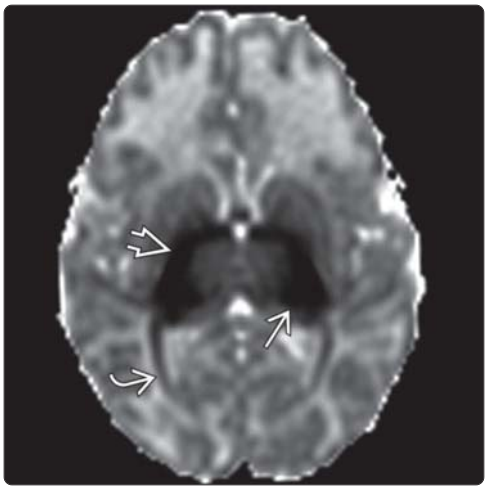

(Left) *Axial DWI MR shows markedly reduced diffusivity (hyperintensity) of the posterior limbs of the internal capsules and of the internal medullary lamina of the thalami during the acute phase of MSUD.* **(Right)** *Axial diffusivity (ADC) map in the same infant confirms reduced diffusivity of the posterior limbs of the internal capsules and of the internal medullary lamina of the thalami as well as the optic tracts.*

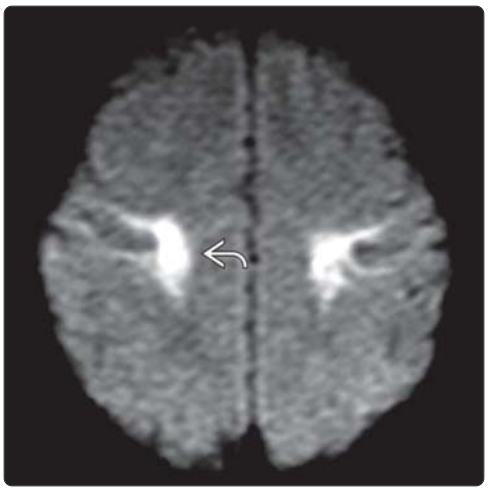

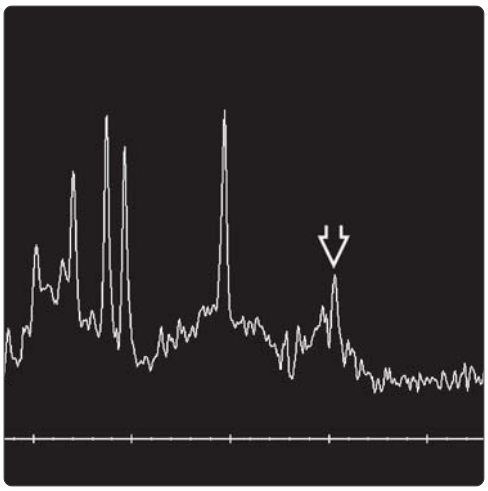

(Left) *Axial DWI MR demonstrates extension of intramyelinic edema (manifest as reduced diffusivity) in the corticospinal tracts as they extend upward to the perirolandic cortex.* **(Right)** *Peaks at 0.9-1.0 ppm on MRS with a TE of 30 milliseconds represent branched-chain α-keto acid peaks, which can be seen during acute metabolic decompensation in MSUD. They are also seen at longer echo times, a finding that helps to confirm the diagnosis.*

https://CafePezeshki.IR

KEY FACTS

TERMINOLOGY

- 6 disorders of urea cycle
  - Ornithine transcarbamylase deficiency (OTCD)
  - Carbamoyl phosphate synthetase 1 deficiency
  - Citrullinemia or argininosuccinate synthetase deficiency
  - Argininosuccinate aciduria or argininosuccinate lyase deficiency
  - Argininemia or arginase deficiency (AD)
  - N-acetylglutamate synthase deficiency

IMAGING

- Neonates: Deep gray nuclei, depths of sulci in frontal, parietal, and insular > temporal cortex
- Older: As above or asymmetric cortical/subcortical white matter mimicking stroke
- Posterior fossa spared
- Acute/subacute: ↑ T2 signal, swelling areas involved
- Acute/subacute: Iso/↑ DWI signal, iso/↓ ADC
- Acute/subacute: ↓ myoinositol (MI), ↑ glutamine-glutamate (glx), ↑ lipids/lactate

TOP DIFFERENTIAL DIAGNOSES

- Hypoxic-ischemic encephalopathy
- Arterial ischemic stroke
- Mitochondrial disorders
- Organic acidemias
- Nonketotic hyperglycinemia

PATHOLOGY

- Urea cycle incorporates nitrogen → urea → urine, prevents accumulation of toxic nitrogen products
- ↑ ammonia → ↑ glutamate → ↑ glutamine in astrocytes → swelling + dysfunction

CLINICAL ISSUES

- Triad of hyperammonemia, encephalopathy, respiratory alkalosis

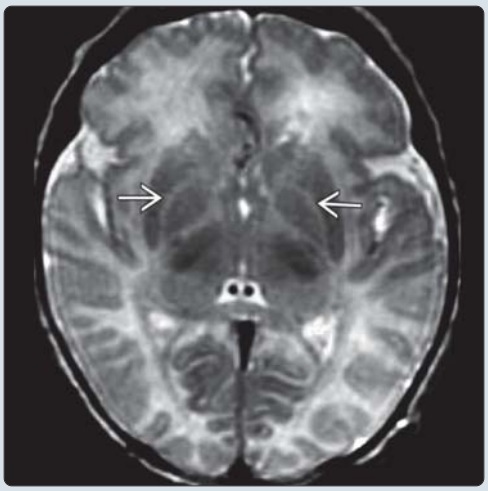

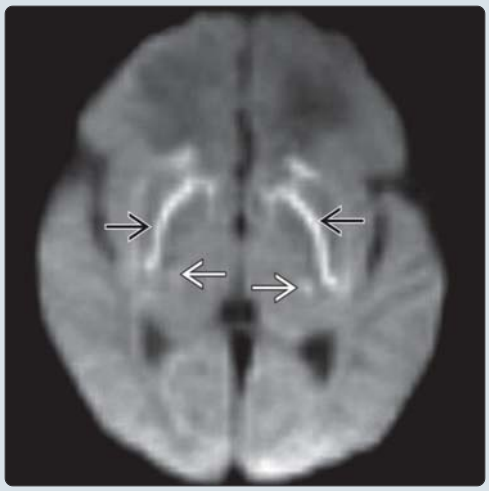

(Left) *Axial T2WI MR shows abnormally increased signal ⇨ between lateral nuclei of the globi pallidi and the putamina in a 2-day-old boy neonate presenting acutely with ornithine transcarbamylase deficiency (OTCD).* **(Right)** *Axial DWI MR in the same patient shows reduced diffusivity (abnormally increased signal ⇨) in the same location between the globi pallidi and putamina, extending into the caudates; this corresponded to decreased ADC. More subtle thalamic hyperintensity ⇨ (and low ADC) is also seen.*

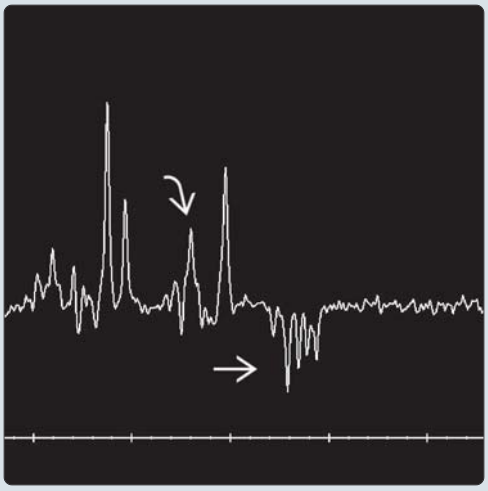

(Left) *Axial proton MRS (TE = 144 msec) in a neonate presenting acutely demonstrates 2 inverted doublets ⇨ of lactate (at 1.33 ppm) and 1,2-propene-diol (found in anticonvulsants, at 1.1 ppm). Also noted is a large glutamine-glutamate (glx) peak ⇨ at 2.1-1.4 ppm.* **(Right)** *Coronal FLAIR MR in the chronic stage of another child with OTCD shows cortical and subcortical posterior insular and temporoparietal increased signal ⇨ that is most marked at the depths of the sulci.*

https://CafePezeshki.IR

TERMINOLOGY

Definitions

- 6 disorders of urea cycle
  - Ornithine transcarbamylase deficiency (OTCD)
  - Citrullinemia or argininosuccinate synthetase deficiency
  - Carbamoyl phosphate synthetase 1 deficiency
  - Argininosuccinate aciduria or argininosuccinate lyase deficiency
  - Argininemia or arginase deficiency (AD)
  - N-acetylglutamate synthase deficiency

IMAGING

General Features

- Best diagnostic clue
  - Neonate presenting 24-48 hours with basal ganglia (BG) and cortical ↑ DWI signal
- Location
  - Neonates: Deep gray nuclei, depths of sulci in frontal, parietal, and insular > temporal cortex
  - Older: As above or asymmetric cortical/subcortical white matter (WM) mimicking stroke
  - Posterior fossa spared

CT Findings

- NECT
  - ↓ attenuation deep gray nuclei, WM + cortex with swelling → atrophy when chronic

MR Findings

- T1WI
  - Subacute/chronic: ↑ signal in cortical, deep gray nuclei areas involved
- T2WI
  - Acute/subacute: ↑ signal, swelling areas involved
  - Chronic: Volume loss, gliosis ± cystic change
- DWI
  - Acute/subacute: Iso/↑ DWI signal, iso/↓ ADC
- MRS
  - Acute/subacute: ↓ myoinositol, ↑ glutamine-glutamate, ↑ lipids/lactate

Imaging Recommendations

- Best imaging tool: MR
- Protocol advice: T1WI, T2WI, DWI, MRS

DIFFERENTIAL DIAGNOSIS

Hypoxic-Ischemic Encephalopathy

- Lateral putamen and ventrolateral thalamus involved; difficult to differentiate in chronic state

Arterial Ischemic Stroke

- Vascular distribution

Metabolic Disorders

- Mitochondrial disorders
- Organic acidemias: Globi pallidi but not cortex; metabolic acidosis/ketosis
- Nonketotic hyperglycinemia: No basal ganglia involvement

PATHOLOGY

General Features

- Etiology
  - Urea cycle incorporates nitrogen → urea → urine; prevents accumulation of toxic nitrogen products
  - ↑ ammonia → ↑ glutamate → ↑ glutamine in astrocytes → swelling + dysfunction
- Genetics
  - All autosomal recessive except OTCD (X-linked)

Gross Pathologic & Surgical Features

- Brain swelling in acute; atrophy + ulegyria in chronic

Microscopic Features

- GM Alzheimer type 2 astrocytes; GM, WM spongiosis

CLINICAL ISSUES

Presentation

- Most common signs/symptoms
  - Triad of hyperammonemia, encephalopathy, respiratory alkalosis
  - Progressive lethargy, hypothermia, vomiting, apnea
  - Neonates develop encephalopathy > 24-48 hours
  - Episodic in older patients (often when ↑ protein intake or ↑ catabolism)
- Clinical profile
  - ↑ ammonium blood levels (except AD)
  - Diagnosis: Liver cell enzyme assessment/DNA

Demographics

- Age
  - Neonate if severe, older if less severe
- Epidemiology
  - Whites > African Americans
  - OTCD most common

Natural History & Prognosis

- Improved with treatment but most mentally retarded
- Neonates: Worst prognosis with high mortality

Treatment

- Hemodialysis in acute crisis
- Liver transplant in severe cases
- ↓ protein intake, adequate caloric intake, supplements
- Sodium benzoate/phenylbutyrate/phenylacetate
- Valproate contraindicated; can cause death

SELECTED REFERENCES

1. Kölker S et al: The phenotypic spectrum of organic acidurias and urea cycle disorders. Part 1: the initial presentation. J Inherit Metab Dis. ePub, 2015
2. Kölker S et al: The phenotypic spectrum of organic acidurias and urea cycle disorders. Part 2: the evolving clinical phenotype. J Inherit Metab Dis. ePub, 2015
3. Helman G et al: The urea cycle disorders. Semin Neurol. 34(3):341-9, 2014
4. Pacheco-Colón I et al: Advances in urea cycle neuroimaging: Proceedings from the 4th International Symposium on urea cycle disorders, Barcelona, Spain, September 2013. Mol Genet Metab. 113(1-2):118-26, 2014
5. Gropman AL: Patterns of brain injury in inborn errors of metabolism. Semin Pediatr Neurol. 19(4):203-10, 2012
6. Häberle J et al: Suggested guidelines for the diagnosis and management of urea cycle disorders. Orphanet J Rare Dis. 7:32, 2012

https://CafePezeshki.IR

KEY FACTS

TERMINOLOGY

- Glutaric acidemia type 1 (GA1), mitochondrial glutaryl-coenzyme A dehydrogenase (GCDH) deficiency
- Inborn error of metabolism characterized by encephalopathic crises and resultant severe dystonic-dyskinetic movement disorder

IMAGING

- Large sylvian fissures (from hypoplastic frontal/temporal opercula) and bright T2/FLAIR basal ganglia
  - Common: ↑ signal caudate/putamina > globus pallidus
  - Occasional: Pallidal and dentate signal change may occur even in absence of crisis
  - Severe: White matter, thalami, dentate nuclei may be involved
  - Significant basal ganglia atrophy in late phases of disease
- Child abuse mimic: Easily torn bridging veins within enlarged cerebrospinal fluid spaces → subdural hematomas

TOP DIFFERENTIAL DIAGNOSES

- Nonaccidental injury
- Disorders with bilateral middle fossa cyst-Like spaces
  - Mucopolysaccharidoses
  - "Idiopathic" middle cranial fossae arachnoid cysts
- Other causes of macrocephaly
  - Hydrocephalus
  - Idiopathic enlargement of subarachnoid spaces (SAS) during 1st year of life
  - Benign familial macrocephaly

CLINICAL ISSUES

- Episodic crises follow trigger (infection, immunization, surgery)
- Hyperintensity/atrophy of basal ganglia worsens after each crisis
- Generally manifests during 1st year of life
- 10% carrier rate in Old Order Amish

(Left) *Axial graphic demonstrates the pattern of involvement in glutaric acidemia type 1 (GA1). The sylvian fissures are enlarged, and the basal ganglia are diffusely and symmetrically abnormal in signal.* **(Right)** *Axial T2WI in a 7 month old reveals enlarged sylvian fissures. Note the swelling and abnormally increased signal intensity of the basal ganglia, including the heads of caudate nuclei, the putamina, and the globi pallidi bilaterally. Myelination is delayed.*

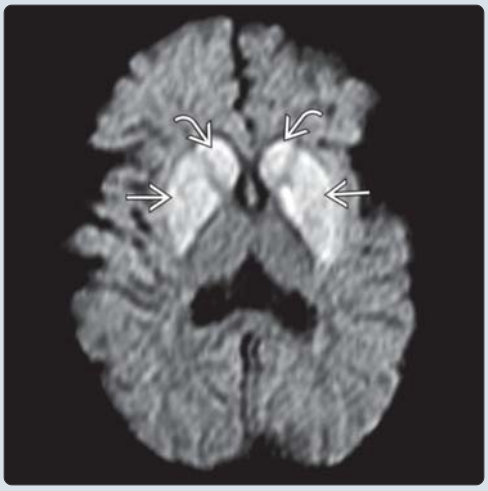

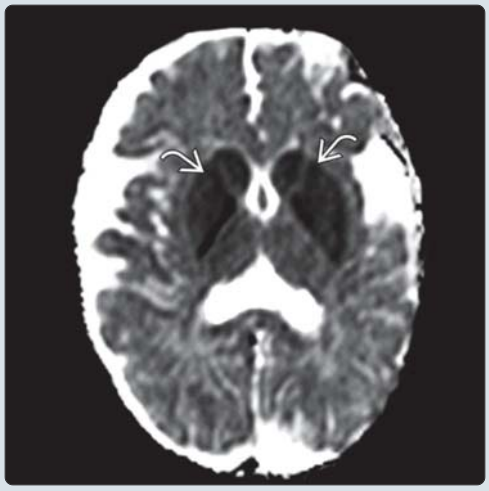

(Left) *Axial diffusion weighted MR of an infant in the midst of a severe metabolic crisis shows hyperintense signal resulting from reduced diffusion within the heads of the caudate nuclei and putamina bilaterally.* **(Right)** *ADC map shows hypointensity in the same areas, the caudates and putamina, confirming the presence of acute brain injury with resultant reduced diffusivity, rather than T2 shine through.*

https://CafePezeshki.IR

TERMINOLOGY

Abbreviations

- Glutaric acidemia type 1 (GA1)
- Mitochondrial glutaryl-coenzyme A dehydrogenase (GCDH) deficiency

Definitions

- Inborn error of metabolism characterized by encephalopathic crises and resultant severe dystonic-dyskinetic movement disorder

IMAGING

General Features

- Best diagnostic clue
  - Wide sylvian fissures and bright basal ganglia (BG)
- Location
  - Sylvian fissures, BG
- Size
  - Enlarged sylvian fissures
- Morphology
  - Small frontal and temporal opercula → bat wing dilatation of sylvian fissures

CT Findings

- NECT
  - > 95% have wide, cyst-like cerebrospinal fluid (CSF) spaces in middle cranial fossae
    - Sylvian fissure widening (93%), mesencephalic cistern widening (86%)
    - Frontal, temporal opercula, which normally cover insula, are hypoplastic
  - Striatal hypodensity
  - Early macrocephaly, late atrophy (mostly ventricular enlargement)
  - Subdural hematoma with minimal trauma
- CECT
  - No enhancement

MR Findings

- T1WI
  - Sylvian fissure cyst-like spaces isointense to CSF
    - May decrease in size over time
  - Subependymal pseudocysts (disappear by 6 months)
  - Frontotemporal hypoplasia
  - Delayed myelination
  - Occasional mild, immature-appearing gyral pattern
- T2WI
  - Common: ↑ signal caudate/putamina > globus pallidus
  - Occasional: Pallidal and dentate signal change may occur even in absence of crisis
    - May predate involvement of caudate & putamina
  - Striatal atrophy over time
  - If severe: White matter (WM), thalami, dentate nuclei may be involved
- FLAIR
  - Same as T2WI
- DWI
  - Acute phase: Reduced diffusion in BG and selected WM tracts; may show more extensive disease than apparent on either CT or MR
- T1WI C+
  - No enhancement
- MRS
  - ↑ Cho/Cr ratio, ↓ NAA
  - During crisis: ± increased lactate

Imaging Recommendations

- Best imaging tool
  - MR
- Protocol advice
  - MRS, DWI

DIFFERENTIAL DIAGNOSIS

Nonaccidental Injury

- Opercular hypoplasia may mimic atrophy
- GA1 does not cause fractures
- Subdural hematoma (SDH) in GA1 from torn-bridging veins in presence of large CSF, atrophy
- SDH in GA1 does not occur without enlarged CSF spaces
- Head trauma = most common cause of death
  - SDH most common finding, often interhemispheric
  - Skull fracture subarachnoid, epidural hemorrhage
  - Cerebral edema, contusion(s), shear injuries

Other Disorders With Bilateral Middle Cranial Fossa Cyst-Like Spaces

- Mucopolysaccharidoses
  - Types 1-4: Hurler, Hunter, Sanfilippo, Scheie, Maroteaux-Lamy, Sly
  - CSF-like mucopolysaccharide pachymeningeal deposition in all but Morquio type 4
- "Idiopathic" middle cranial fossae arachnoid cysts
  - 5% may be bilateral, usually asymptomatic
  - CSF intensity; may be slightly different on FLAIR
  - No DWI restriction

Causes of Macrocephaly

- Hydrocephalus
  - Congenital, post-traumatic, or obstructive
  - Ventricular prominence out of proportion to sulci
  - Enlarged temporal horns, rounded frontal horns, transependymal CSF flow
- Idiopathic enlargement of subarachnoid spaces (SAS) during 1st year of life
- Benign familial macrocephaly
  - Family tendency toward large head size

PATHOLOGY

General Features

- Etiology
  - GCDH required for metabolism of lysine, hydroxylysine, and tryptophan
  - ↓ GCDH → accumulation glutaric, glutaconic, and 3-OH-glutaric acid
  - Accumulated substances toxic to striate cells and white matter
- Genetics
  - Autosomal recessive
  - *GCDH* gene mutations (Chr 19p13.2) result in amino acid substitutions

https://CafePezeshki.IR

- Multiple mutations govern varied clinical presentation
  - European variant (most common): Arg402-to-trp
  - Amish variant, riboflavin sensitive: Ala421-to-val
  - Severe, 1% residual enzyme, symptoms despite treatment (Tx): Glu365-to-lys
- Rare adult onset: Compound heterozygosity with deletion and novel missense mutation
- Associated abnormalities
  - Embryology: Toxic effects in utero impede operculization during 3rd trimester
  - Mild hepatocellular dysfunction during crisis

Staging, Grading, & Classification

- Symptomatic: Frontotemporal atrophy, BG signal changes
- Presymptomatic: Symptom-free, lack BG changes, but CSF spaces still enlarged

Gross Pathologic & Surgical Features

- Macrocrania, frontotemporal atrophy/hypoplasia; ↑ CSF spaces ± SDH
- Hypo- and demyelination

Microscopic Features

- Myelin vacuolation and splitting, excess intramyelinic fluid
- Spongiform changes, neuronal loss BG

CLINICAL ISSUES

Presentation

- Most common signs/symptoms
  - Initially normal development
  - Acute encephalopathy, seizures, dystonia, choreoathetosis, mental retardation
- Acute onset group: Majority
  - Episodic crises follow trigger (infection, immunization, surgery)
    - Acute Reye-like encephalopathy, ketoacidosis, ↑ NH4, vomiting
    - Dystonia, opisthotonus, seizures, excessive sweating
    - Follow-up: Alert child (intellect preserved > > motor); rapid infantile head growth → frontal bossing; severe dystonia
- Insidious onset (25%): Dystonia without crisis
- Presymptomatic may remain asymptomatic: Diagnose, treat, avoid catabolic stress
- Rare asymptomatic without treatment: Still frontotemporal atrophy but normal BG
- Diagnosis: Frequent long interval between presentation and diagnosis
  - Tandem mass spectrometry of newborn filter-paper blood specimens
    - Chromatography of mass; spectroscopy of urine
  - Deficient or absent GCDH activity in fibroblasts
  - Laboratory (may be relatively normal between crises)
    - Metabolic acidosis/ketosis, hypoglycemia, ↓ carnitine
    - Urinary organic acids: ↑ glutaric, glutaconic, and 3-OH-glutaric acid

Demographics

- Age
  - Generally manifests during 1st year of life
- Gender
  - No predilection
- Ethnicity
  - 10% carrier rate in old order Amish
- Epidemiology
  - 1:30,000 newborns

Natural History & Prognosis

- Symptomatic: Most severely handicapped, 20% die before 5 years
- Presymptomatic: Many (not all) remain asymptomatic with diagnosis and therapy
- Treat before 1st encephalopathic crisis; avoiding catabolic crises may improve outcome
- Prognosis poor if has already presented with encephalopathic crisis

Treatment

- Intrauterine diagnosis available
  - DNA analysis: Cultured amniotic fluid cells and chorionic villi biopsy
  - Fetal sonography and MR: Dilated perisylvian CSF in 3rd trimester
- Early treatment may prevent or ameliorate symptoms and imaging
  - Low-protein diet (reduced tryptophan and lysine), synthetic protein drink
  - Riboflavin (vitamin B2) to ensure cofactor supply for GCDH
  - Oral carnitine replacement; gamma aminobutyric acid (GABA), analog (baclofen)

DIAGNOSTIC CHECKLIST

Image Interpretation Pearls

- Consider GA1 in young children with bilateral enlargement of sylvian fissures and abnormal basal ganglia
- Pallidal and dentate signal change may occur even in absence of crisis; may predate involvement of caudate and putamina

SELECTED REFERENCES

1. Harting I et al: ¹H-MRS in glutaric aciduria type 1: impact of biochemical phenotype and age on the cerebral accumulation of neurotoxic metabolites. J Inherit Metab Dis. ePub, 2015
2. Kölker S et al: The phenotypic spectrum of organic acidurias and urea cycle disorders. Part 1: the initial presentation. J Inherit Metab Dis. ePub, 2015
3. Kölker S et al: The phenotypic spectrum of organic acidurias and urea cycle disorders. Part 2: the evolving clinical phenotype. J Inherit Metab Dis. ePub, 2015
4. Couce ML et al: Glutaric aciduria type I: outcome of patients with early- versus late-diagnosis. Eur J Paediatr Neurol. 17(4):383-9, 2013
5. Nunes J et al: Brain MRI findings as an important diagnostic clue in glutaric aciduria type 1. Neuroradiol J. 26(2):155-61, 2013

https://CafePezeshki.IR

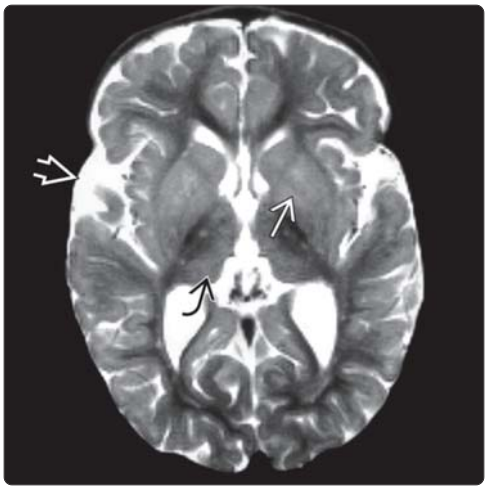

(Left) *Axial T2WI MR shows mild prominence of the sylvian fissures ➡ and mottled, early signal abnormalities in the basal ganglia ➡ and thalami ⇨. The presence of macrocrania is an additional clue when imaging findings are subtle in cases of GA1.* **(Right)** *Axial T2WI MR in a child 21 months of age, long after resolution of metabolic crisis, reveals slit-like atrophy, gliosis of the basal ganglia ⇨, and persistence of the sylvian fissure enlargement ➡.*

(Left) *Axial FLAIR MR demonstrates typical enlargement of the sylvian fissures ➡ in a 7-month-old child. Abnormal signal is identified within the globi pallidi ➡, as expected, and in cerebral white matter ➡. The latter finding is unusual and is felt to reflect the combination of GA1 and dihydropteridine reductase (DHPR) deficiency in this child.* **(Right)** *T2WI MR in the same child shows diffusely abnormal white matter ➡, abnormal signal within the globi pallidi ⇨, and thalami ⇨.*

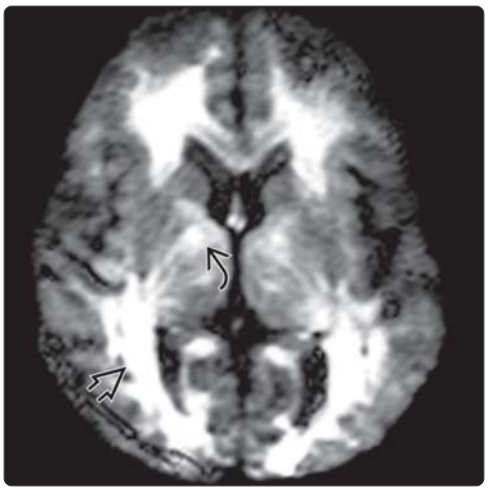

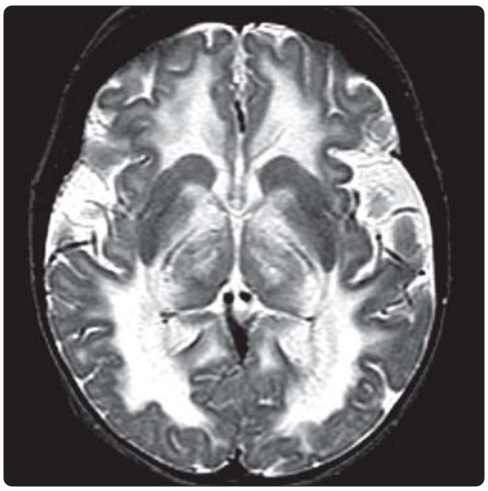

(Left) *Follow-up DWI MR in the same child at nearly 2 years of age shows reduced diffusivity, which confirms active disease and marked progression of disease, particularly within the white matter ⇨. There is also reduced diffusivity within the involved globi pallidi ⇨.* **(Right)** *T2WI MR at the same time as the DWI shows marked progression of white matter abnormality. White matter is now isointense to CSF. The prominent sylvian fissures remain a strong clue to the diagnosis of GA1.*

https://CafePezeshki.IR

KEY FACTS

TERMINOLOGY

- Progressive autosomal-recessive spongiform leukodystrophy

IMAGING

- White matter: Involves subcortical U-fibers, sparing internal capsule, and corpus callosum
- Thalami, globi pallidi (GP), ± dentate nuclei, sparing caudate, and putamen
- ↑ T2 + DWI signal, normal to ↓ ADC in involved areas
- ↑ NAA/Cr, ↓Ch/Cr

TOP DIFFERENTIAL DIAGNOSES

- Maple syrup urine disease
- Pelizaeus-Merzbacher disease
- Merosin-deficient congenital muscular dystrophy
- Alexander disease

PATHOLOGY

- Deficiency of aspartoacylase → N-acetyl aspartic acid ↑ in brain and urine
- Spongiform degeneration of white matter; GP and thalami with swollen astrocytes

CLINICAL ISSUES

- Early severe hypotonia and macrocephaly
- Evident by 4 months
- ↑ risk for Ashkenazi Jewish (1 in 40 carriers)
- Relentless, progressive neurodegenerative disorder: Chronic vegetative state with autonomic crises → death by end of 1st decade
- No proven treatment (gene therapy and acetate supplementation under evaluation)

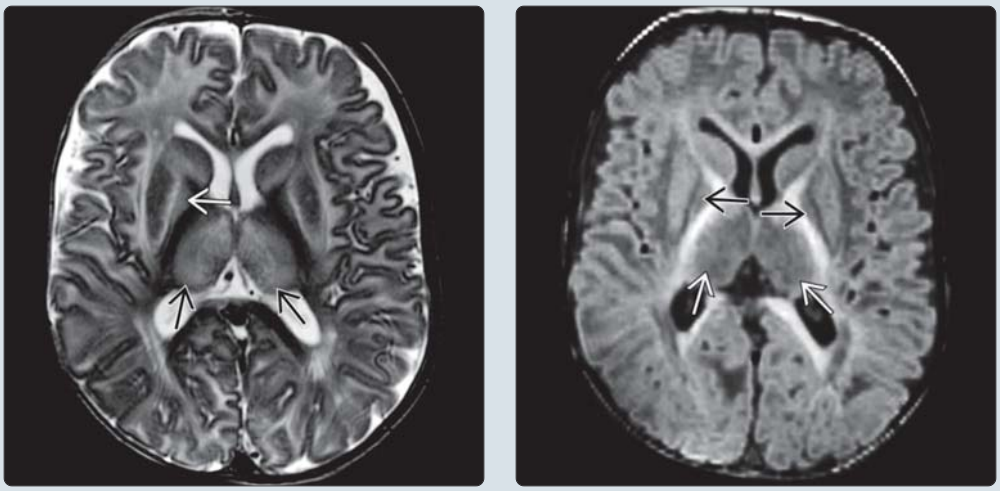

(Left) *Axial T2WI MR in a 6-month-old infant boy shows diffusely increased signal in the cerebral white matter, thalami ⇨, and right globus pallidus ➡ with relative sparing of the internal capsule, corpus callosum, caudate, and putamen.* **(Right)** *Axial T1WI MR in the same 6-month-old infant shows diffusely decreased signal in the white matter, thalami ➡, and globi pallidi ⇨. Normal signal intensity is present within the internal capsule, corpus callosum, caudates, and putamina.*

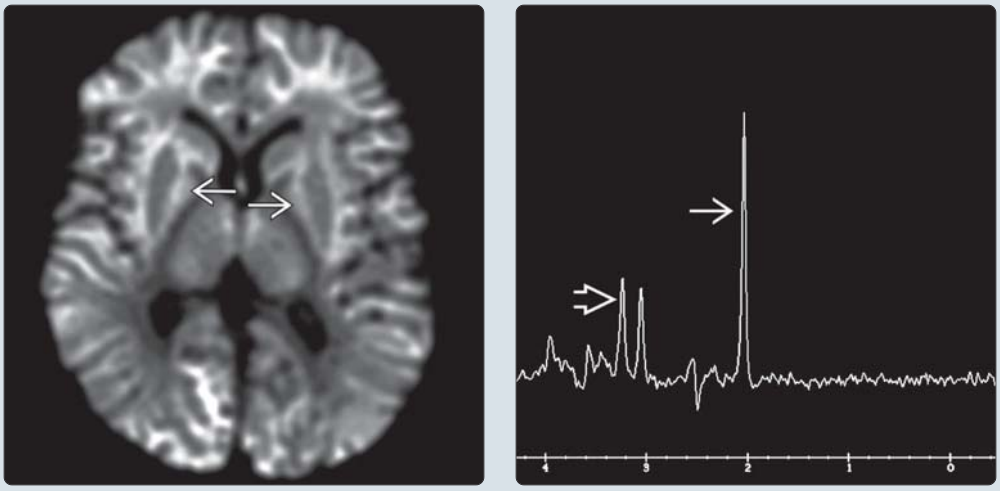

(Left) *Axial DWI MR in the same 6-month-old infant shows diffusely increased signal (reduced diffusivity) in the cerebral white matter and globi pallidi ➡. Normal diffusivity is seen in the myelinated internal capsule and corpus callosum. Caudates and putamina appear unaffected.* **(Right)** *Axial long echo (TE = 144 msec) proton MRS acquired in the centrum semiovale at 1.5T shows a marked relative increase in NAA ➡ and decrease in choline ➡ relative to Cr for age.*

https://CafePezeshki.IR

TERMINOLOGY

Abbreviations

- Canavan disease (CD)

Synonyms

- Spongiform leukodystrophy, spongy degeneration of CNS, Canavan-van Bogaert-Bertrand disease, aspartoacylase deficiency, *ASPA* deficiency, *ASP* deficiency, aminoacylase 2 deficiency, *ACY2* deficiency

Definitions

- Progressive fatal autosomal-recessive spongiform leukodystrophy

IMAGING

General Features

- Best diagnostic clue
  - Megalencephaly with diffuse ↑ white matter T2 and DWI signal and ↑ NAA
- Location
  - White matter (WM): Involves subcortical U-fibers, sparing internal capsule, and corpus callosum
  - Thalami, globi pallidi (GP), ± dentate nuclei, sparing caudate and putamen

CT Findings

- NECT
  - Diffuse ↓ attenuation in involved areas

MR Findings

- T1WI
  - Hypointense in involved areas
- T2WI
  - Hyperintense in involved areas
- DWI
  - Bright DWI signal, normal to ↓ ADC in involved areas
- T1WI C+
  - No enhancement
- MRS
  - ↑ NAA/Cr, ↓ Ch/Cr

Imaging Recommendations

- Best imaging tool
  - MR
- Protocol advice
  - T2WI, DWI, and MRS

DIFFERENTIAL DIAGNOSIS

Maple Syrup Urine Disease

- ↑ branched-chain AA + ketoacids

Pelizaeus-Merzbacher Disease

- ↑ ADC, spares GP and thalami

Merosin-Deficient Congential Muscular Dystrophy

- ↑ ADC, spares GP and thalami

Alexander Disease

- Predilection for frontal WM, enhances

PATHOLOGY

General Features

- Etiology
  - Deficiency of aspartoacylase (which metabolizes N-acetyl aspartate [NAA]) → ↑ ↑ NAA in brain and urine
- Genetics
  - Autosomal recessive → *ASPA* gene = long arm chromosome 17

Staging, Grading, & Classification

- Earlier onset → more rapid progression

Gross Pathologic & Surgical Features

- Swollen brain

Microscopic Features

- Spongiform degeneration of white matter; GP and thalami with swollen astrocytes

CLINICAL ISSUES

Presentation

- Most common signs/symptoms
  - 3 clinical variants (according to age at presentation)
    - Congenital (1st few days of life)
      - Hypotonia, rapid death
    - Infantile (3-6 months); most common form
      - Most common form
      - Hypotonia, head lag, macrocephaly → seizures, spasticity, visual loss
    - Juvenile
      - Onset at 4-5 years; most slowly progressive form of CD
- Clinical profile
  - Early severe hypotonia and macrocephaly

Demographics

- Ethnicity
  - ↑ risk for Ashkenazi Jewish (1 in 40 carriers)

Natural History & Prognosis

- Relentless, progressive neurodegenerative disorder: Chronic vegetative state with autonomic crises → death by end of 1st decade

Treatment

- No proven treatment (ablating NAA synthesis by disrupting Nat8l in mouse model)

DIAGNOSTIC CHECKLIST

Image Interpretation Pearls

- Swollen brain with ↑ T2, ↑ DWI signal in white matter, involvement of GP and thalami

SELECTED REFERENCES

1. Guo F et al: Ablating N-acetylaspartate prevents leukodystrophy in a Canavan disease model. Ann Neurol. 77(5):884-8, 2015
2. Baslow MH et al: Canavan disease, a rare early-onset human spongiform leukodystrophy: insights into its genesis and possible clinical interventions. Biochimie. 95(4):946-56, 2013
3. van der Knaap MS et al: Defining and categorizing leukoencephalopathies of unknown origin: MR imaging approach. Radiology. 213(1):121-33, 1999

https://CafePezeshki.IR

KEY FACTS

TERMINOLOGY

- Rare leukoencephalopathy characterized by Rosenthal fibers (RFs), intracytoplasmic astrocytic inclusions
- 3 clinical forms: Infantile (most common), juvenile, adult

IMAGING

- Infantile: Symmetric, ↑ T2 signal bifrontal WM
- Juvenile/adult: ↑ T2 signal brainstem (especially medulla), cerebellum, cervical cord
- Other findings: ↓ T2, ↑ T1 enhancing nodular periventricular rim
  - One of few metabolic disorders that enhances

TOP DIFFERENTIAL DIAGNOSES

- Canavan disease
- Megaloencephalic leukoencephalopathy with subcortical cysts (MLC)
- Glutaric aciduria type 1 (GA1)
- Mucopolysaccharidoses (MPS)

PATHOLOGY

- Dominant mutations *GFAP* (17q21) (> 95% of cases)

CLINICAL ISSUES

- Clinical profile: Infant with macrocephaly, seizures
- Natural history: Variable rate of progression ultimately leading to death in all forms
- Treatment: Supportive

DIAGNOSTIC CHECKLIST

- Consider adult Alexander disease (AD) if ↑ T2 signal and atrophy in medulla (inferior olives and gracile nuclei) & cervical cord
- Enhancing, symmetric bifrontal WM disease in macrocephalic infant highly characteristic of AD

(Left) *Axial NECT shows the typical appearance of infantile Alexander disease (AD). The striatum and periventricular rim ⇨ are hyperdense. Note the symmetric, frontal predominant, white matter (WM) hypodensity.* **(Right)** *Axial T2WI MR shows a nodular, hypointense, periventricular rim ⇨ with symmetric, mild hyperintensity in the striata and thalami ⇨. The cerebral white matter is diffusely hyperintense, greatest in the frontal lobes, where it extends from the ventricular margin to the subcortical U-fibers.*

(Left) *Axial T1WI MR shows diffusely hypointense, swollen-appearing WM with a frontal to occipital gradient. Only the occipital WM appears myelinated. The nodular periventricular rim ⇨ is hyperintense. The lateral ventricles are abnormally enlarged.* **(Right)** *Axial T1WI C+ MR shows enhancement of the periventricular rim, the caudate heads, and the putamina bilaterally. The nodular, rabbit ear appearance of the frontal periventricular rim ⇨ is typical of Alexander disease.*

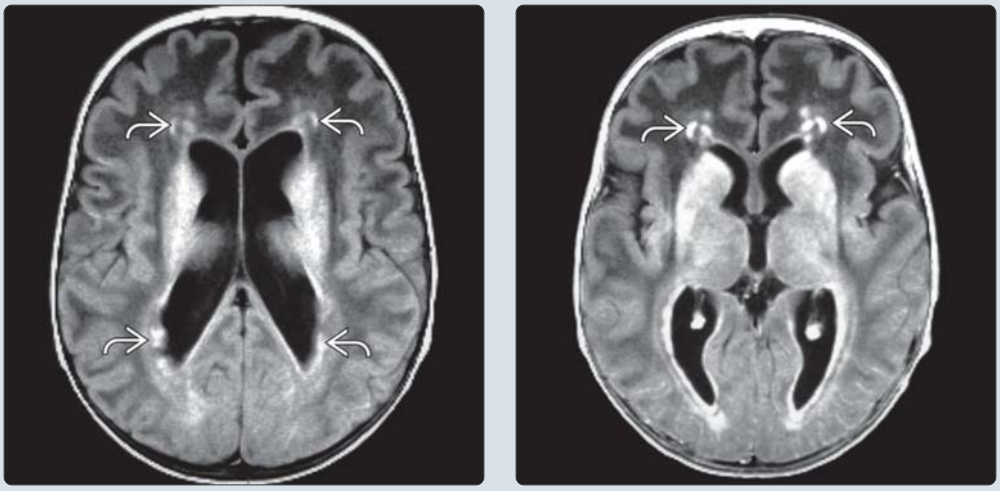

https://CafePezeshki.IR

TERMINOLOGY

Abbreviations

- Alexander disease (AD)

Synonyms

- Fibrinoid leukodystrophy

Definitions

- Rare leukoencephalopathy characterized by Rosenthal fibers (RFs), intracytoplasmic astrocytic inclusions
- 3 clinical forms: Infantile (most common), juvenile, adult
- Caused by dominant mutations in gene endocing GFAP

IMAGING

General Features

- Best diagnostic clue
  - Macrocephalic infant with
    - Symmetric, ↑ T2 signal bifrontal white matter (WM)
    - ↓ T2, ↑ T1, enhancing, nodular periventricular rim
  - Juvenile: Enhancing, ↑ T2 signal brainstem (BS), cerebellum
    - One of the few metabolic disorders that enhances
  - Adult: ↑ T2 signal, atrophy medulla, cervical cord
- Other findings
  - Infantile
    - ↑ T2 signal, enhancement striatum
    - Variable ↑ T2 signal, enhancement in BS (especially periaqueductal), dentate nuclei, optic chiasm, fornix
    - ± hydrocephalus (periaqueductal disease)
  - Juvenile/adult
    - Characterized by BS, cerebellar, spinal cord involvement
      - Inferior olives, gracile nuclei in medulla
    - Involvement cerebral WM, periventricular rim, striatum variable (usually mild)
  - Enhancement, swelling early in frontal WM, basal ganglia (infantile AD)
  - Atrophy, cystic encephalomalacia (infantile) late
- Location
  - WM
    - Frontal: Periventricular → subcortical
    - External/extreme capsules, ± callosal genu
  - Periventricular rim
  - Basal ganglia (BG), thalami, BS, cerebellum, fornix, optic chiasm, spinal cord
- Morphology
  - Posterior extension WM changes frequent with disease progression
  - Rostral caudal gradient less pronounced in juvenile/adult disease

CT Findings

- NECT
  - Hypodense frontal WM
  - Dense periventricular rim, caudate heads
- CECT: Intense enhancement typical of early disease

MR Findings

- T1WI
  - Hypointense frontal WM
  - Hyperintense periventricular rim, ± basal ganglia
- T2WI
  - Hyperintense frontal WM (subcortical WM included), caudate heads
  - Hypointense periventricular rim
  - Juvenile/adult: Hyperintense foci BS, ± cervical cord
- FLAIR
  - Cystic encephalomalacia frontal WM (late infantile)
- DWI: Normal to increased diffusivity
- T1WI C+: Intense enhancement typical of early disease
  - Infantile: Frontal periventricular WM, striatum, periventricular rim; rare BS, fornix, optic chiasm
  - Juvenile/adult: BS and cerebellar enhancement may mimic tumor
- MRS: ↓ NAA, ↑ myoinositol; ± ↑ choline, lactate

Nuclear Medicine Findings

- FDG-18 fluorodeoxyglucose PET
  - Hypometabolism in affected frontal white matter
  - Preserved overlying normal glucose metabolism

Imaging Recommendations

- Best imaging tool: MR C+/MRS
- Protocol advice: Enhance all "unknown" cases of hydrocephalus and abnormal WM
- Proposed MR criteria for infantile AD (4/5 required)
  - Extensive cerebral WM change with frontal predominance
  - ↓ T2, ↑ T1 periventricular rim
  - Abnormal signal basal ganglia, thalami
  - Abnormal signal BS
  - Enhancement of frontal WM, periventricular rim, BG, thalami, BS, dentate nuclei, cerebellum, optic chiasm, or fornix

DIFFERENTIAL DIAGNOSIS

Canavan Disease

- WM: Diffuse; subcortical U-fibers involved early
- Deep gray matter: Globi pallidi, thalami
- No enhancement
- Characteristic ↑ ↑ NAA peak on MRS

Megalencephaly With Leukoencephalopathy and Cysts (MLC)

- WM: Diffuse with subcortical U-fiber involvement
- No involvement deep gray structures
- No enhancement
- Characteristic temporal, frontoparietal, subcortical cysts

Glutaric Aciduria Type 1

- WM: Periventricular WM involved in severe disease
- Deep gray: Symmetric basal ganglia
- No enhancement
- Characteristic widened opercula

Mucopolysaccharidoses

- WM: Mild periventricular
- No involvement of deep gray structures
- Characteristic cribriform WM, corpus callosum

https://CafePezeshki.IR

PATHOLOGY

General Features

- General pathology comments
  - AD characterized by accumulation of Rosenthal fibers (RFs) in astrocytes and hypo-/demyelination
- Embryology and anatomy
  - Astrocytes play role in myelin formation by oligodendrocytes
  - Astrocytic end-feet form part of blood-brain barrier
  - Glial fibrillary acidic protein (GFAP): Major intermediate filament protein in astrocytes
- Genetics
  - Dominant mutations *GFAP* (17q21) (> 95% of cases)
    - > 80 different mutations identified
    - Same mutation may be seen in all clinical forms → additional epigenetic or environmental factors influence phenotype
    - Majority of mutations arise de novo; familial cases seen in adult AD
    - Mutations cause gain in function
- Etiology
  - RFs: Abnormal intracellular protein aggregates containing GFAP, αβ-crystalline, hsp27, & ubiquitin
  - Mechanism by which *GFAP* mutation induces RF formation uncertain
  - Mechanism by which RF accumulation leads to hypo-/demyelination uncertain
    - Theory: RF accumulation causes cell dysfunction
      - Includes blood-brain barrier disruption and loss of normal cell-cell interaction with oligodendrocytes
  - RFs also seen in astrocytomas, hamartomas, gliosis

Gross Pathologic & Surgical Features

- Megaloencephalic, heavy brain with large ventricles
- Swollen, gelatinous WM with cortical thinning
- Frontal WM cavitation
- BG swelling early; atrophy and cystic change late

Microscopic Features

- RFs: Eosinophilic, electron-dense, cytoplasmic inclusions in fibrous astrocytes
  - Greatest concentration in subependymal, subpial, and perivascular astrocytic end-feet areas of enhancement
- Hypomyelination/myelin loss frontal lobes > caudal brain, ± cerebellar WM, dentate nucleus, brainstem
- Generalized astrocytosis ± neuraxonal degeneration
- Abnormalities of muscle mitochondria reported

CLINICAL ISSUES

Presentation

- Most common signs/symptoms
  - Infantile: Macrocephaly, seizures, developmental delay/arrest, spasticity
  - Juvenile: Developmental regression, bulbar/pseudobulbar signs, ataxia, spasticity
  - Adult: Bulbar/pseudobulbar signs, ataxia
    - Palatal myoclonus (40%) is highly suggestive
- Other signs/symptoms in juvenile/adult
  - Bowel/bladder dysfunction, sleep disturbance, dysautonomia
- Clinical profile: Infant with macrocephaly, seizures
- CSF: Variable ↑ protein, αβ-crystalline, hsp27, lactate
- Diagnosis: MR findings & *GFAP* gene blood analysis

Demographics

- Age
  - Infantile: Birth to 2 years
  - Juvenile: 2-12 years
  - Adult: > 12 years old
- Gender: Slight male predominance in infantile AD
- Epidemiology: Rare; incidence unknown
  - Adult AD more common than previously thought

Natural History & Prognosis

- Natural History
  - Variable rate of progression ultimately leading to death in all forms
    - Neonatal variant of infantile form is most rapidly fatal; infantile form is next most severe
    - Juvenile form is more slowly progressive
    - Adult form is mildest
- Prognosis
  - Infantile: Average survival 3 years after disease onset
  - Juvenile: Average survival 8 years after disease onset
  - Adult: Average survival 15 years after disease onset

Treatment

- Supportive; hydrocephalus may respond to shunting
- Potential future therapeutic role for agents causing down-regulation of *GFAP* expression

DIAGNOSTIC CHECKLIST

Consider

- Adult AD if ↑ T2 signal, atrophy in medulla & cervical cord
- Infantile AD if macrocephaly with frontal predominant leukodystrophy

Image Interpretation Pearls

- Enhancing, symmetric bifrontal WM disease in macrocephalic infant highly characteristic of AD

SELECTED REFERENCES

1. Brenner M et al: A new mutation in GFAP widens the spectrum of Alexander disease. Eur J Hum Genet. 23(1):1-2, 2015
2. Graff-Radford J et al: Neuroimaging and clinical features in type II (late-onset) Alexander disease. Neurology. 82(1):49-56, 2014
3. Walker AK et al: Astrocytic TDP-43 pathology in Alexander disease. J Neurosci. 34(19):6448-58, 2014
4. Messing A et al: Alexander disease. J Neurosci. 32(15):5017-23, 2012
5. Mignot C et al: Tumor-like enlargement of the optic chiasm in an infant with Alexander disease. Brain Dev. 31(3):244-7, 2009
6. Farina L et al: Can MR imaging diagnose adult-onset Alexander disease?. AJNR Am J Neuroradiol. 29(6):1190-6, 2008
7. Matarese CA et al: Magnetic resonance imaging findings in Alexander disease. Pediatr Neurol. 38(5):373-4, 2008
8. Pareyson D et al: Adult-onset Alexander disease: a series of eleven unrelated cases with review of the literature. Brain. 131(Pt 9):2321-31, 2008
9. Quinlan RA et al: GFAP and its role in Alexander disease. Exp Cell Res. 313(10):2077-87, 2007
10. Dinopoulos A et al: Discrepancy between neuroimaging findings and clinical phenotype in Alexander disease. AJNR Am J Neuroradiol. 27(10):2088-92, 2006
11. van der Knaap MS et al: Alexander disease: diagnosis with MR imaging. AJNR Am J Neuroradiol. 22(3):541-52, 2001

https://CafePezeshki.IR

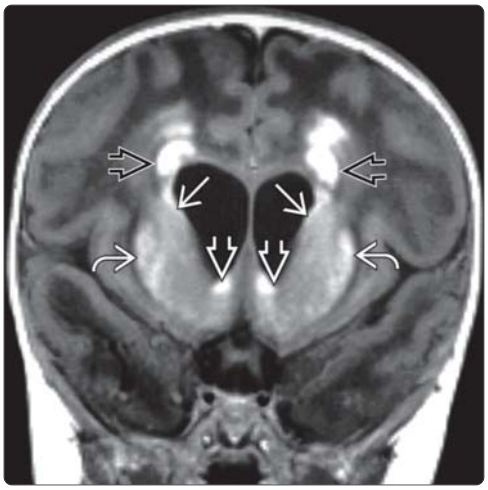

(Left) *Axial NECT shows swollen, hypodense, cerebral WM with frontal predominance. The hyperdense, nodular periventricular rim is made more conspicuous by the adjacent hypodense WM.* **(Right)** *Coronal T1WI C+ MR shows intense enhancement in the frontal periventricular rims and adjacent frontal WM. Enhancement is also present over the surface of the caudate heads and in the putamina and fornix. Note the symmetric, hypointense, swollen frontal and temporal lobe WM.*

(Left) *Axial T2WI MR in this more advanced case shows symmetric, hyperintense cerebral WM and deep gray structures with greatest hyperintensity in the frontal WM and striata. Note the swollen caudate heads and fornices. WM hyperintensity extends into the external and extreme capsules, causing the claustra to stand out.* **(Right)** *Axial T1WI C+ MR in the same patient shows intense enhancement of the fornices and mild enhancement over the surface of the caudate heads.*

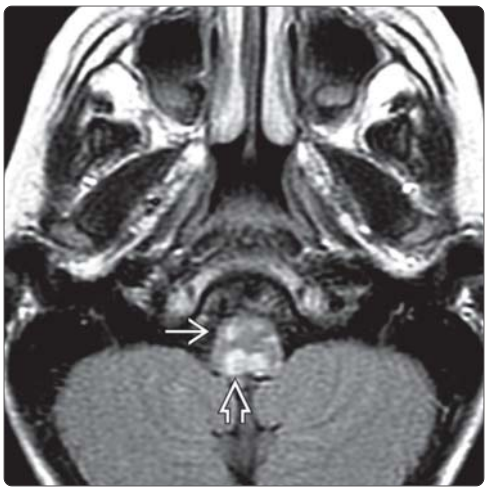

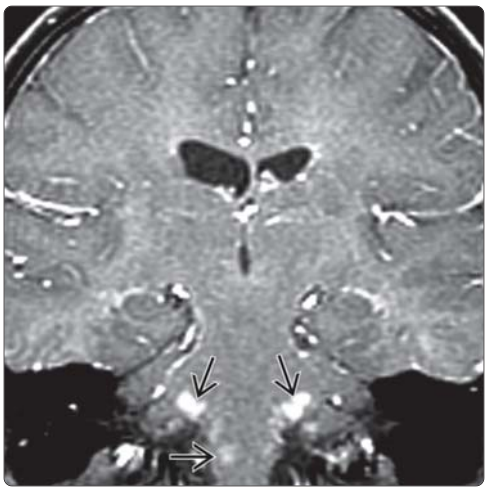

(Left) *Axial FLAIR MR in an older child shows multiple foci of hyperintensity within the inferior olives and gracile nuclei in the medulla.* **(Right)** *Coronal T1WI C+ MR in the same patient shows focal enhancement in the medulla and middle cerebellar peduncles. Note the normal cerebral WM. Juvenile and adult AD are characterized by involvement of the brainstem (especially medulla), cerebellum, and cervical cord (particularly adults), with little to no supratentorial involvement.*

https://CafePezeshki.IR

KEY FACTS

TERMINOLOGY

- PKU
  - Most common inborn error of amino acid metabolism
  - Results in ↑ phenylalanine (Phe)
- Hyperhomocysteinemia (HHcy)
  - Multiple disorders
    - Results in ↑ plasma homocysteine (Hcy) > 12 μmol/L
  - Risk factor for arteriosclerotic disease > venous thrombosis

IMAGING

- PKU, HHcy
  - ↑ T2 periventricular/deep cerebral WM
- CBSD, MTHFRD, late-onset Cbl-C
  - Arterial > venous infarcts

CLINICAL ISSUES

- Presentation
  - PKU
    - Severe mental retardation (untreated)
    - Subtle cognitive impairment (early-treated disease)
  - HHcy
    - Variable phenotype
  - Late-treated CBSD
    - Mental retardation, thrombosis
  - Untreated CBSD
    - 12-27% have thromboembolic event by age 15
    - 4-23% die by age 30
- Diagnosis
  - PKU, CBSD, MAT I/IIID = newborn screen
- Treatment
  - PKU treatment
    - Phe-free diet starts 1st month of life
    - Strict diet during childhood improves outcome
  - CBSD/MTHFRD
    - Vit B6, folate, betaine; Cbl-C: IM/IV Vit B12
  - MAT I/IIID: Most have normal development

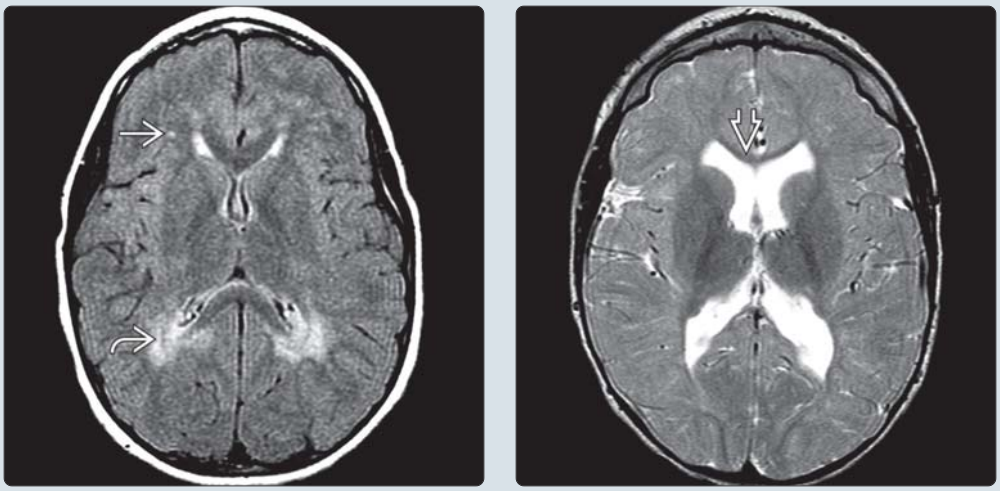

(Left) *Axial FLAIR MR in a 10 year old with PKU. Note the increased signal in the peritrigonal and frontal white matter. As is typical of PKU, the parietal white matter lesions are more pronounced than those in the frontal or temporal lobes.* **(Right)** *Axial T2WI MR in a 4 year old with MTHFRD. There is marked central white matter volume loss with associated ex vacuo ventricular enlargement and callosal thinning. Note the white matter is hypomyelinated for age.*

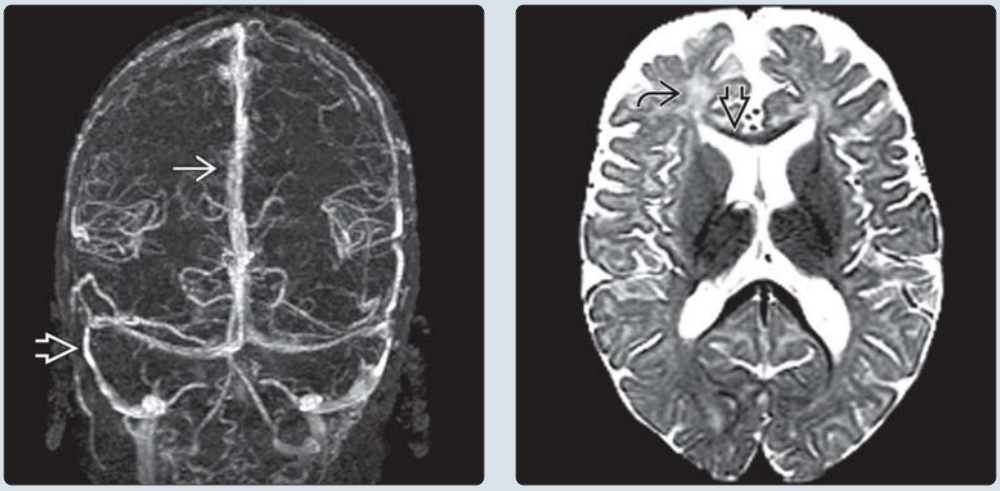

(Left) *Coronal maximum intensity projection from MR venogram in 4 year old with MTHFRD demonstrates irregular, recanalized sigmoid sinus and superior sagittal sinus several years following acute sinovenous thrombosis.* **(Right)** *Axial T2WI MR in an 8 month old with Cbl-C shows diffusely diminished white matter volume with increased signal in the periventricular and deep frontal white matter. Note mild ex vacuo ventricular enlargement and callosal thinning.*

https://CafePezeshki.IR

TERMINOLOGY

Abbreviations

- Phenylketonuria (PKU)
- Hyperhomocysteinemia (HHcy)
- Cystathionine β-synthase deficiency (CBSD)
- 5,10 methylenetetrahydrofolate reductase deficiency (MTHFRD)
- Methionine adenosyltransferase deficiency (MAT I/IIID)
- Cobalamin C (Cbl-C), disorder vitamin B12 metabolism

Definitions

- PKU: Most common inborn error of amino acid metabolism resulting in ↑ phenylalanine (Phe)
- Hyperhomocysteinemia: Multiple disorders resulting in ↑ plasma homocysteine (Hcy) > 12 μmol/L
  - ↑ risk arteriosclerotic disease > venous thrombosis
  - Caused by inborn errors of Hcy, folate, or vitamin B12 metabolism; ↓ vitamin B12/folate intake; renal failure
  - 4 most recognized metabolic disorders: CBSD, MTHFRD, Cbl-C, MAT I/IIID
  - Variable phenotype among & within each disorder

IMAGING

General Features

- PKU: ↑ T2 periventricular white matter (PVWM)
  - Posterior > anterior PVWM
  - Subcortical WM, corpus callosum late
- CBSD: Small foci ↑ T2 cerebral WM > cortical infarct > sinovenous thrombosis (SVT)
- MTHFRD: ↑ T2 PV/deep WM > arterial infarct, SVT
- Early onset Cbl-C: Swollen, ↑ T2 cerebral WM; ± hydrocephalus, ↑ T2 basal ganglia; Late: WM atrophy
- Late-onset Cbl-C: ↑ T2 PV/deep WM, atrophy > arterial infarct; ± ↑ T2 posterior spinal cord columns
- MAT I/IIID: Reversible ↑ T2 PV/deep WM, dorsal pons during severe hypermethioninemia (also with CBSD)
- PKU & HHcy: Imaging may be normal

CT Findings

- NECT
  - ↓ density cerebral WM, infarct

MR Findings

- T1WI: Variable ↓ signal cerebral WM
- T2WI/FLAIR: ↑ signal affected structures
- DWI: ↓ ADC PVWM reported PKU, HHcy
  - HHcy: ↓ ADC acute infarct, dorsal pons MAT I/IIID
- MRS: PKU: Phe peak 7.37 ppm; Cbl-C: (+) lactate

Imaging Recommendations

- PKU: MR/MRS; HHcy: MR/MRS/MRA

DIFFERENTIAL DIAGNOSIS

Metachromatic Leukodystrophy

- ↑ T2 central cerebral WM with tigroid appearance

Periventricular Leukomalacia

- ↑ T2 signal, volume loss PVWM, and positive hypoxia-ischemia history

PATHOLOGY

General Features

- General pathology comments
  - PKU: ↓ phenylalanine hydroxylase (PAH) → ↑ Phe
    - ↑ Phe toxic to developing brain
  - HHcy: ↑ Hcy → oxidative stress, ↓ methylation, vascular endothelial damage
- Genetics: Autosomal recessive
  - PKU: > 450 mutations *PAH* gene 12q24.1
  - CBSD: > 100 mutations *CBS* gene 21q22.3
  - MTHFRD: > 50 mutations *MTHFR* gene 1p36.3
  - MAT I/IIID: > 27 mutations *MAT1A* gene 10q22
- Associated abnormalities
  - CBSD: Ectopia lentis, marfanoid, ↓ bone density

CLINICAL ISSUES

Presentation

- Signs/symptoms
  - Untreated PKU: Severe mental retardation
    - Early treated: Subtle cognitive impairments
  - Late-treated CBSD: Mental retardation, thrombosis
  - MTHFRD: Developmental delay, gait difficulties, seizures, psychiatric symptoms > thrombotic events
  - Early-onset Cbl-C (infant): Neurologic, hematologic, renal, GI impairments
    - Late onset: Neurologic deterioration as adult
  - MAT I/IIID: Most normal, rare neurologic signs
- Diagnosis: PKU, CBSD, MAT I/IIID = newborn screen

Demographics

- Epidemiology
  - PKU: 1:8,000 Caucasians in USA (↓ African Americans)
  - 5-7% population have ↑ Hcy (from all causes)
  - 5-15% Caucasians homozygous *MTHFR* C667T allele

Natural History & Prognosis

- PKU: Strict diet during childhood improves outcome
- Untreated CBSD: 12-27% have thromboembolic event by age 15; 4-23% die by age 30
- MTHFRD/Cbl-C: Significant neurologic impairment, early death if late diagnosis/poor therapy compliance
- MAT I/IIID: Most have normal development

Treatment

- PKU: Phe-free diet begins 1st month of life
- CBSD/MTHFRD: Vit B6, folate, betaine; Cbl-C: IM/IV Vit B12; MAT I/IIID: None typically necessary

SELECTED REFERENCES

1. Kölker S et al: The phenotypic spectrum of organic acidurias and urea cycle disorders. Part 1: the initial presentation. J Inherit Metab Dis. ePub, 2015
2. Kölker S et al: The phenotypic spectrum of organic acidurias and urea cycle disorders. Part 2: the evolving clinical phenotype. J Inherit Metab Dis. ePub, 2015
3. Krishna SH et al: Congenital genetic inborn errors of metabolism presenting as an adult or persisting into adulthood: neuroimaging in the more common or recognizable disorders. Semin Ultrasound CT MR. 35(2):160-91, 2014
4. Makrides V et al: Transport of amino acids in the kidney. Compr Physiol. 4(1):367-403, 2014

https://CafePezeshki.IR

KEY FACTS

TERMINOLOGY

- Megalencephaly with leukoencephalopathy and subcortical cysts (MLC)
- Inherited leukodystrophy

IMAGING

- Swollen white matter
  - Early white matter swelling decreases over time; atrophy ensues
- Subcortical temporal and frontoparietal cysts
- Cysts increase in size and number over time
- No contrast enhancement or reduced diffusion

PATHOLOGY

- Genetics
  - Autosomal recessive; mutations of *MLC1* or *GLIALCAM* gene
  - Mutations mostly private mutations
  - Founder effect occurs in population subisolates

CLINICAL ISSUES

- Delayed onset of slow motor deterioration (despite very abnormal MR)
- Macrocephaly
- Seizures/deterioration after mild trauma
- Even slower cognitive decline
- Cerebellar ataxia
- Pyramidal tract involvement
- Rare disorder, but carrier rate in some communities with high levels of consanguinity as high as 1/40
- Prenatal diagnosis is option in families with known mutations

DIAGNOSTIC CHECKLIST

- Consider 1 of "new" leukodystrophies, such as MLC, when imaging features are more severe than metachromatic leukodystrophy

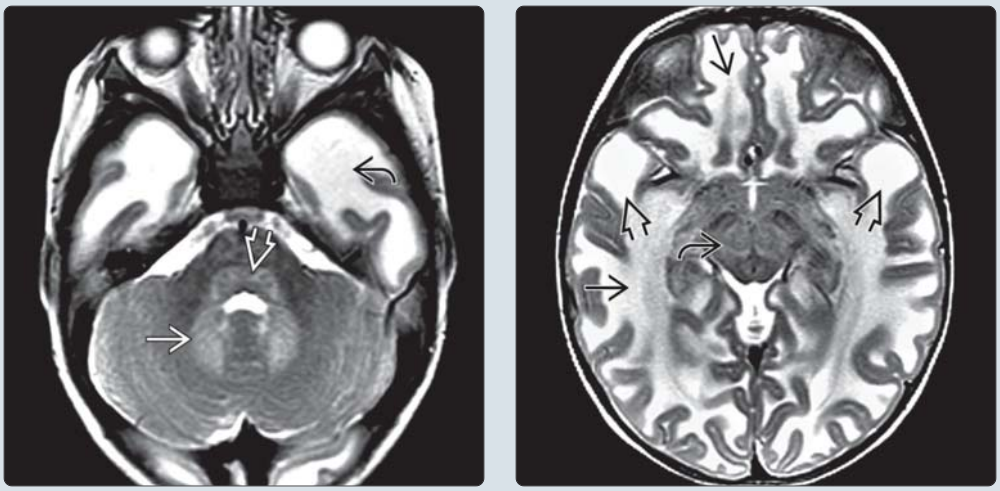

(Left) *Axial T2WI MR in a 10-month-old infant, with increasing head circumference but normal development, reveals abnormally increased signal intensity of the cerebellar white matter, dorsal brainstem, and anterior temporal lobes.* **(Right)** *Axial T2WI MR in the same infant confirms extensive swelling and increased signal of white matter of the cerebrum and the white matter tracts surrounding the red nuclei in the midbrain. Note the anterior temporal lobe cysts.*

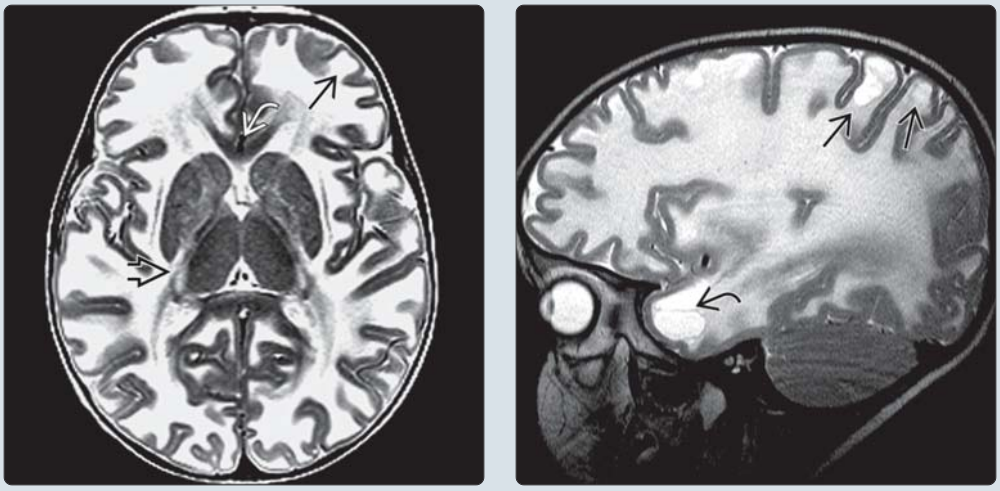

(Left) *Axial T2WI MR of the same 10-month-old infant reveals sparing (normal myelination) of the corpus callosum, diminished myelination of portions of the posterior limb of the internal capsule, and definitely impaired myelination of the subcortical U-fibers throughout the cerebral hemispheres.* **(Right)** *Sagittal T2WI MR in the same infant nicely confirms the presence of temporal and frontoparietal cysts, as well as extensive hypomyelination.*

https://CafePezeshki.IR

TERMINOLOGY

Abbreviations

- Megalencephaly with leukoencephalopathy and subcortical cysts (MLC)

Synonyms

- Formerly
  - Vacuolating megaloencephalic leukoencephalopathy with benign, slowly progressive course
  - Infantile-onset leukoencephalopathy with swelling and discrepantly mild course
  - van der Knaap disease
    - 1 of many disorders eponymously named after that author
  - Indian Agarwal megaloencephalic leukodystrophy

Definitions

- Autosomal recessive disorder of astrocytic volume-regulated anion currents
  - Characterized by macrocephaly, motor/cognitive decline, ataxia, spasticity

IMAGING

General Features

- Best diagnostic clue
  - Diffusely abnormal, swollen hemispheric white matter (WM)
  - Subcortical cysts predominately anterior temporal, frontoparietal
- Location
  - Diffuse WM, includes subcortical U-fibers
    - Subcortical cysts
      - Anterotemporal most common
      - Frontoparietal also common
    - ± involvement of posterior internal capsules
    - Cerebellar WM involvement subtle
- Size
  - Cysts increase in size and number over time

CT Findings

- NECT
  - Involved WM ↓ attenuation
- CECT
  - No contrast enhancement

MR Findings

- T1WI
  - Involved WM ↓ signal on T1WI
- T2WI
  - Involved WM ↑ signal on T2WI
    - Cerebral white matter
      - Relative sparing of corpus callosum
    - Posterior 1/3 of posterior limb of internal capsule ± involvement
    - WM tracts of brainstem ± involvement in very young
- FLAIR
  - Involved WM ↑ signal on FLAIR
  - Subcortical cysts
    - Anterotemporal and frontoparietal most common
    - Cysts approximate CSF signal
- DWI
  - DTI shows ↓ anisotropy, ↑ ADC values
    - Results from ↑ water in interstitial space
- T1WI C+
  - No contrast enhancement
  - Probably not necessary
- MRS
  - All metabolites ↓ in cystic regions
  - ↓ NAA in WM
  - Normal myoinositol
  - ± lactate signal

Imaging Recommendations

- Best imaging tool
  - MR with MRS
    - ± contrast administration (to exclude enhancing leukodystrophies)

DIFFERENTIAL DIAGNOSIS

Other Leukodystrophies, Nonenhancing

- Metachromatic leukodystrophy (MLD)
  - Look for WM "stripes" on T2WI
- Hypomyelination
- Canavan
  - Subcortical U-fibers involved early
  - Markedly elevated NAA on MRS
- Cree leukoencephalopathy
  - Involvement of WM
  - Deep structures
    - Involves globus pallidus, thalami, medulla
    - Spares olives, red nuclei, and caudate nuclei

Other Leukodystrophies, Enhancing

- Alexander disease
  - Abnormal signal + enhancement of frontal WM and ependymal surfaces
  - Basal nuclei involved
- X-linked adrenoleukodystrophy
  - Abnormal signal and enhancement of peritrigonal WM and splenium

PATHOLOGY

General Features

- Etiology
  - Inborn genetic errors
  - Disturbed water homeostasis and osmotic balance to abnormal function of volume-regulated anion channels (VRACs)
    - VRACs in astrocytes respond to changes in extracellular osmolarity
    - Display prominent cell volume changes as part of osmoregulatory process
    - MLC1 important in VRAC activity; GlialCAM is a chaperone of MLC1 in ion channels
- Genetics
  - Autosomal recessive; gene localized on Chr 22q(tel)
    - Many different mutations of *MLC1* and *GLIALCAM* genes
    - Mutations distributed along whole gene, types include

https://CafePezeshki.IR

        - Splice-site mutations
        - Nonsense mutations
        - Missense mutations
        - Deletions and insertions
    - Mutations identified in 80%; 2nd locus suspected
    - Mutations mostly private mutations
    - Founder effect occurs in population subisolates
- Associated abnormalities
    - *MLC1* in CNS expressed in astrocytic end-feet at blood-brain and CSF-brain barriers
        - GlialCAM is a chaperone for MLC1 in ion channels of astrocytes
    - *MLC1* also expressed in peripheral white blood cells, spleen
        - But no systemic or other organ involvement

Gross Pathologic & Surgical Features

- Spongiform leukoencephalopathy
    - Vacuolization in subcortical white matter

Microscopic Features

- Myelin splitting at intraperiod line
- Vacuolization of outermost lamellae of myelin sheaths

CLINICAL ISSUES

Presentation

- Most common signs/symptoms
    - Macrocephaly at birth or within 1st year of life
    - Delayed onset of slow motor deterioration (even slower cognitive decline) despite very abnormal MR
        - Development during 1st year often normal
- Other signs/symptoms
    - Rare early presentation with developmental delay
    - Rare transient coma following minor head trauma
- Clinical profile
    - Macrocephaly
    - Very slow cognitive decline
        - Eventual learning problems in 50%
    - Cerebellar ataxia and pyramidal tract involvement
    - Motor deterioration
        - Late loss of ability to walk
        - Occasional delayed autonomous walking
    - Minor head trauma → seizures and temporary deterioration

Demographics

- Age
    - Macrocephaly before 1 year of age
- Ethnicity
    - Increased in population isolates
        - Common *MLC* mutations in
            - Specific Indian community (Agarwal)
            - Libyan Jewish community
            - Turkish community
            - Some Japanese families due to founder effect
        - Agarwal community mutation
            - Insertion (c.135_136insC) usual, phenotypic variation occurs
- Epidemiology
    - Rare
    - Carrier rate in some communities with high levels of consanguinity as high as 1/40

Natural History & Prognosis

- Early white matter swelling
    - Swelling decreases over time
    - Atrophy ensues
- Clinical features progress slowly

Treatment

- Treat symptoms (seizures, spasticity)
- Prenatal diagnosis is option in families with known mutations

DIAGNOSTIC CHECKLIST

Consider

- 1 of "new" leukodystrophies when imaging involvement more severe than metachromatic leukodystrophy

Image Interpretation Pearls

- Always enhance unknown leukoencephalopathy

Reporting Tips

- Differentiation from MLD
    - Involvement of subcortical U-fibers
    - Subcortical cysts
- Differentiate from Canavan
    - No basal ganglia involvement in MLC
    - Normal NAA in MLC

SELECTED REFERENCES

1. Kariminejad A et al: Eight novel mutations in MLC1 from 18 Iranian patients with megalencephalic leukoencephalopathy with subcortical cysts. Eur J Med Genet. 58(2):71-4, 2015
2. Mahmoud IG et al: Clinical, neuroimaging, and genetic characteristics of megalencephalic leukoencephalopathy with subcortical cysts in Egyptian patients. Pediatr Neurol. 50(2):140-8, 2014
3. Capdevila-Nortes X et al: Insights into MLC pathogenesis: GlialCAM is an MLC1 chaperone required for proper activation of volume-regulated anion currents. Hum Mol Genet. 22(21):4405-16, 2013
4. Rodriguez D: Leukodystrophies with astrocytic dysfunction. Handb Clin Neurol. 113:1619-28, 2013
5. Renaud DL: Leukoencephalopathies associated with macrocephaly. Semin Neurol. 32(1):34-41, 2012
6. van der Knaap MS et al: Megalencephalic leukoencephalopathy with subcortical cysts: chronic white matter oedema due to a defect in brain ion and water homoeostasis. Lancet Neurol. 11(11):973-85, 2012
7. Miles L et al: Megalencephalic leukoencephalopathy with subcortical cysts: a third confirmed case with literature review. Pediatr Dev Pathol. 12(3):180-6, 2009
8. Boor I et al: MLC1 is associated with the dystrophin-glycoprotein complex at astrocytic endfeet. Acta Neuropathol. 114(4):403-10, 2007
9. Kiriyama T et al: SPECT revealed cortical dysfunction in a patient who had genetically definite megalencephalic leukoencephalopathy with subcortical cysts. Clin Neurol Neurosurg. 109(6):526-30, 2007
10. Teijido O et al: Expression patterns of MLC1 protein in the central and peripheral nervous systems. Neurobiol Dis. 26(3):532-45, 2007
11. Ilja Boor PK et al: Megalencephalic leukoencephalopathy with subcortical cysts: an update and extended mutation analysis of MLC1. Hum Mutat. 27(6):505-12, 2006
12. Morita H et al: MR imaging and 1H-MR spectroscopy of a case of van der Knaap disease. Brain Dev. 28(7):466-9, 2006

https://CafePezeshki.IR

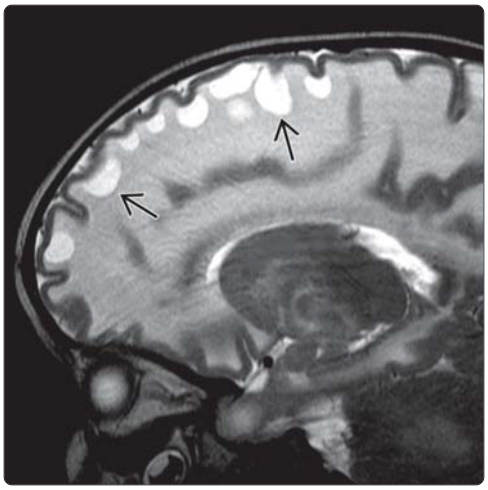

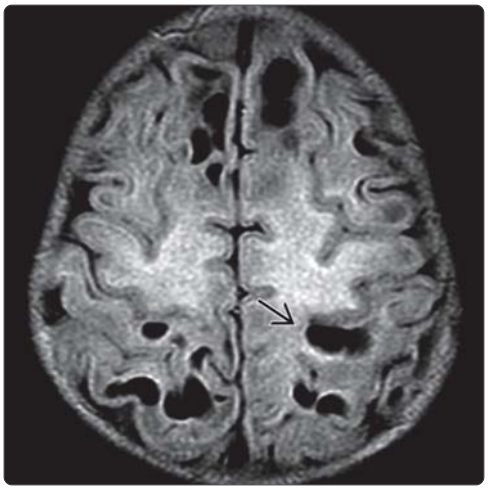

(Left) *Sagittal T2WI MR in a 2-year-old patient with megalencephaly and slowing of acquisition of developmental milestones shows swollen white matter, as well as fairly extensive subcortical cysts involving the frontal lobe.* **(Right)** *Axial FLAIR MR in the same 2-year-old patient shows white matter with abnormally high signal intensity due to hypomyelination, as well as extensive, bilateral, frontal and frontoparietal subcortical cysts.*

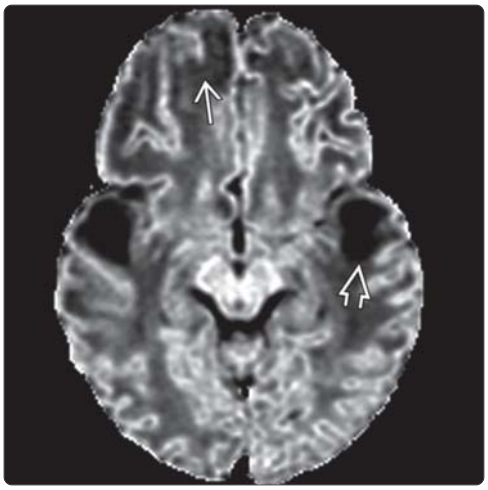

(Left) *Axial FLAIR MR in a 22-month-old child with macrocephaly and decreasing acquisition of developmental milestones shows large, bilateral temporal lobe cysts, typical of megalencephaly with leukoencephalopathy and cysts (MLC), on a background of swollen, abnormally hyperintense white matter.* **(Right)** *Axial DWI MR in the same 22-month-old infant confirms markedly increased diffusivity in the cysts and, less dramatically, in the subcortical white matter.*

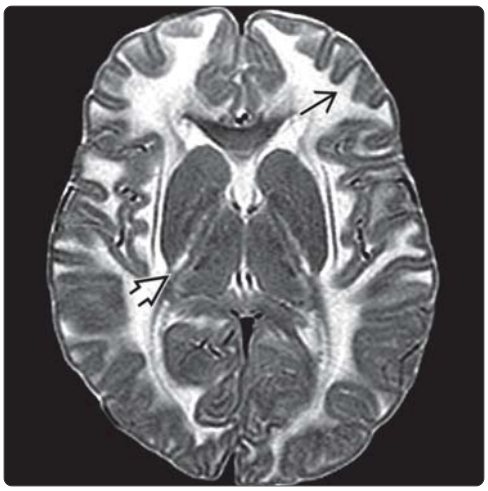

(Left) *Axial T2WI MR in a 6-year-old child with MLC shows less pronounced white matter swelling, although the posterior limbs of the internal capsules and subcortical U-fibers show persistence of abnormal signal hyperintensity.* **(Right)** *Axial T2WI MR in a 14-year-old patient with MLC demonstrates sulcal widening due to atrophy, a common finding as the disease progresses. Note the persistent hyperintensity of the cerebral white matter with involvement of the subcortical U-fibers.*

https://CafePezeshki.IR

KEY FACTS

TERMINOLOGY

- Group of neurodegenerative disorders characterized by dystonia, parkinsonism, and spasticity
  - Caused by mutations in L-ferritin gene *FTL1*
  - All characterized by abnormal Fe accumulation in basal ganglia
    - Lewy bodies, axonal swellings, hyperphosphorylated tau in some subtypes
  - Includes PKAN, INAD, aceruloplasminemia, etc.

IMAGING

- Globus pallidus T2 hypointensity with central hyperintensity of GP: Eye of the tiger sign
  - Specific to classic PKAN (*PANK2* mutations)
  - May also be seen in neuroferritinopathy
- GP ± SN, DN, cortex, striatum, & thalamus T2 dark without "eye of the tiger" = other NBIA
- Caution: Globus pallidus normally hypointense on T2 at 3T or above

PATHOLOGY

- Iron directly causes or facilitates cellular injury, or is a consequence of axonal disruption

CLINICAL ISSUES

- PKAN
  - Classic < 6 years, atypical during teenage years
- INAD
  - Classic < 2 years, atypical at 4-6 years
- Aceruloplasminemia and neuroferritinopathy
  - Mean age 40 years

DIAGNOSTIC CHECKLIST

- Look for: T2 hypointensity of globus pallidus in patient with movement disorder
- Consider: T2* (gradient echo) or susceptibility weighted imaging (SWI) in patients with movement disorders

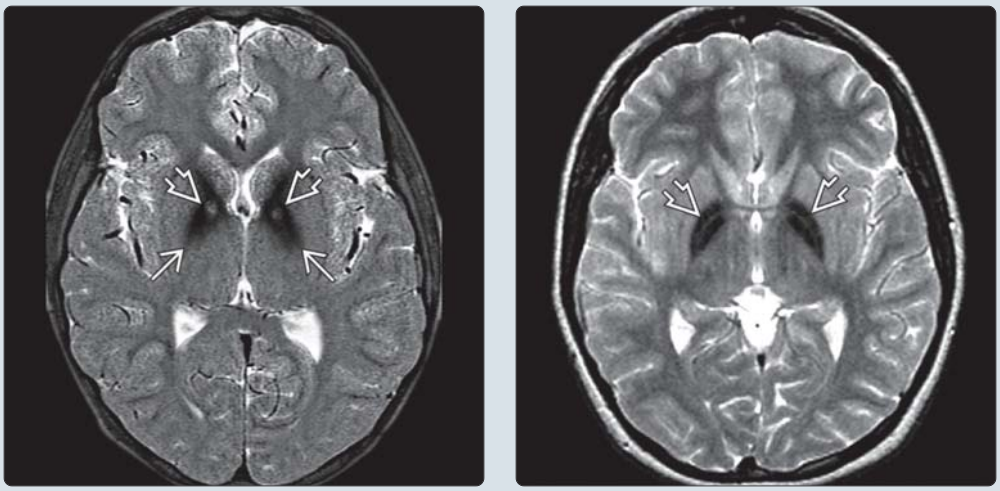

(Left) *Axial T2WI FS MR shows classic imaging of PKAN (Hallervorden-Spatz syndrome), which is within the spectrum of NBIA. Note the globus pallidi hypointensity related to iron deposition with central hyperintensity, consistent with the eye of the tiger sign, highly specific for the PANK2 mutation.* **(Right)** *Axial T2WI MR shows symmetric hypointensity within the globus pallidi. The eye of the tiger sign is absent; therefore, this is not PKAN. These findings are characteristic of NBIA.*

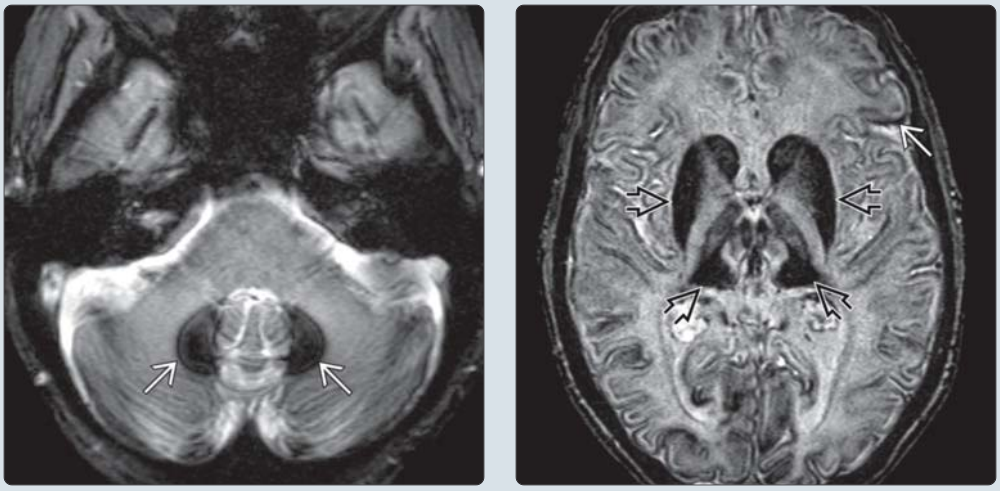

(Left) *Axial T2* GRE MR shows marked hypointensity related to iron deposition in the dentate nuclei of the cerebellum in this patient with aceruloplasminemia. Aceruloplasminemia and neuroferritinopathy occur in adults and have a similar imaging appearance.* **(Right)** *Axial T2* SWI MR in the same patient shows diffuse linear hypointensity in the cortex with marked "blooming" in the basal ganglia and thalami related to iron deposition. Substantia nigra involvement is also typical.*

https://CafePezeshki.IR

TERMINOLOGY

Abbreviations

- Pantothenate kinase-associated neurodegeneration (PKAN)
- Infantile neuroaxonal dystrophy (INAD)
- Neurodegeneration with brain iron accumulation (NBIA)

Definitions

- Group of neurodegenerative disorders characterized by dystonia, parkinsonism, and spasticity
  - Caused by mutations in L-ferritin gene *FTL1*
  - All characterized by abnormal Fe accumulation in basal ganglia
  - Includes PKAN, INAD, aceruloplasminemia, etc.
    - Lewy bodies, axonal swellings, hyperphosphorylated tau in some subtypes

IMAGING

General Features

- Best diagnostic clue
  - T2 hypointensity in globus pallidus (GP)
- Location
  - PKAN and INAD
    - GP, substantia nigra (SN), ± dentate nuclei (DN)
  - Neuroferritinopathy and aceruloplasminemia
    - GP, SN, DN, cortex, striatum, and thalamus

Imaging Recommendations

- Best imaging tool
  - MR with T2* (gradient echo) or susceptibility weighted imaging (SWI)

CT Findings

- NECT
  - Cerebral and cerebellar atrophy in non-*PANK2* NBIA

MR Findings

- T2WI
  - GP hypointensity with central hyperintensity of GP interna: Eye of the tiger sign
    - Specific to classic PKAN (*PANK2* mutations)
    - Can see only T2 hyperintensity early in disease
    - May also be seen in neuroferritinopathy
  - GP, ± SN, DN, cortex, striatum, and thalamus dark without "eye of the tiger" = other NBIA
  - GP normally hypointense on T2 at 3T or above
- T2* GRE
  - Accentuation of hypointense T2 findings
- Imaging findings do not always correlate with clinical symptoms

DIFFERENTIAL DIAGNOSIS

Normal Iron Deposition

- Imaging at 3T
- Seen in normal aging process

Parkinson and Alzheimer Diseases

- No "eye of the tiger"; older patients

Multiple Sclerosis

- Iron accumulation in basal ganglia associated with MS
- Should have other classic demyelinating lesions

Superficial Siderosis

- Iron overload from transfusions or recurrent CNS hemorrhage

Hemochromatosis

- Liver and spleen usually affected before CNS

PATHOLOGY

General Features

- Genetics
  - Autosomal recessive *PANK2*, *PLA2G6*, and *CP*
  - Autosomal dominant *FTL* mutation

Gross Pathologic & Surgical Features

- Iron accumulation, rust brown pigmentation

Microscopic Features

- Iron accumulation in GP and SN, neuronal loss, axonal swellings (spheroids)
- "Eye of the tiger" may represent cystic degeneration
- Neurofibrillary tangles and Lewy bodies suggest shared pathway with Alzheimer and Parkinson diseases

CLINICAL ISSUES

Presentation

- Most common signs/symptoms
  - Ataxia, dysarthria, dystonia
  - Retinal degeneration and optic atrophy
- Other signs/symptoms
  - Aceruloplasminemia: Adult onset triad of diabetes, retinal degeneration, and movement disorder
  - Neuroferritinopathy: Adult onset chorea or dystonia

Demographics

- Age
  - PKAN: Classic < 6 years, teenage atypical
  - INAD: Classic < 2 years, 4-6 years atypical
  - Adult onset NBIA: Mean age = 40 years

Natural History & Prognosis

- PKAN & INAD: Death is variable, usually from secondary causes such as malnutrition & aspiration
- Adult onset NBIA: Progressive motor decline

Treatment

- Symptom palliation: Medications and deep brain stimulator
- Aceruloplasminemia: Iron chelation with desferrioxamine and ceruloplasmin from fresh frozen plasma

SELECTED REFERENCES

1. Arber C et al: Insights into molecular mechanisms of disease in Neurodegeneration with Brain Iron Accumulation; unifying theories. Neuropathol Appl Neurobiol. ePub, 2015
2. Dusek P et al: Wilson disease and other neurodegenerations with metal accumulations. Neurol Clin. 33(1):175-204, 2015
3. Hogarth P: Neurodegeneration with brain iron accumulation: diagnosis and management. J Mov Disord. 8(1):1-13, 2015
4. Levi S et al: Neuroferritinopathy: From ferritin structure modification to pathogenetic mechanism. Neurobiol Dis. ePub, 2015
5. Miyajima H: Aceruloplasminemia. Neuropathology. 35(1):83-90, 2015

https://CafePezeshki.IR

KEY FACTS

TERMINOLOGY

- Pantothenate kinase-associated neurodegeneration (PKAN)
  - Most common form of neurodegeneration with brain iron accumulation (NBIA)
  - Caused by mutation pantothenate kinase 2 gene (*PANK2*)

IMAGING

- Best diagnostic clue: Eye of the tiger sign = diffuse pallidal T2 hypointensity with medial foci ↑ T2 signal
  - Highly suggestive of PKAN

TOP DIFFERENTIAL DIAGNOSES

- Disorders with ↑ T2 signal globus pallidus
  - Metabolic: Methylmalonic acidemia, Kearns-Sayre, L-2-Hydroxyglutaric aciduria, Canavan, neuroferritinopathy
  - Ischemic/toxic: Anoxic encephalopathy, carbon monoxide/cyanide poisoning, kernicterus

CLINICAL ISSUES

- Classic PKAN
  - Dystonia, dysarthria, rigidity, choreoathetosis in young child
- Atypical PKAN
  - Psychiatric, speech, pyramidal/extrapyramidal disturbances in older child/teenager
- Epidemiology
  - Rare; incidence unknown
- Prognosis
  - Classic PKAN: Fatal; mean disease duration after symptom onset is 11 years
  - Atypical PKAN: Eventual severe impairment/death
- No curative treatment

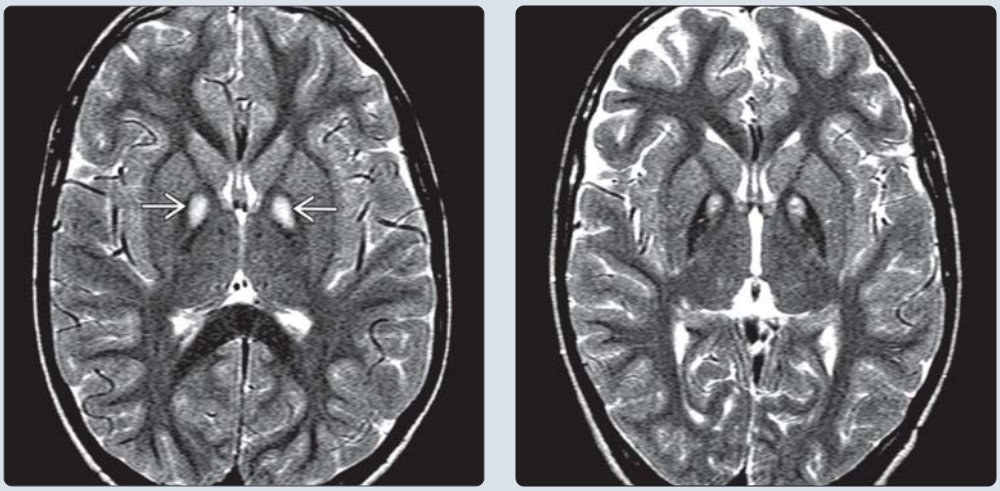

(Left) *Axial T2WI MR in a 5 year old with a diagnosis of cerebral palsy demonstrates an "eye of the tiger" sign typical of PKAN: Symmetric areas of high T2 signal within the medial globus pallidus with surrounding pallidal hypointensity.* **(Right)** *Four years later, dystonia prompted repeat MR imaging in the same patient. Axial T2WI MR shows that the "eyes" have diminished in size and intensity with greater surrounding pallidal hypointensity. Volume loss is now evident, particularly frontal.*

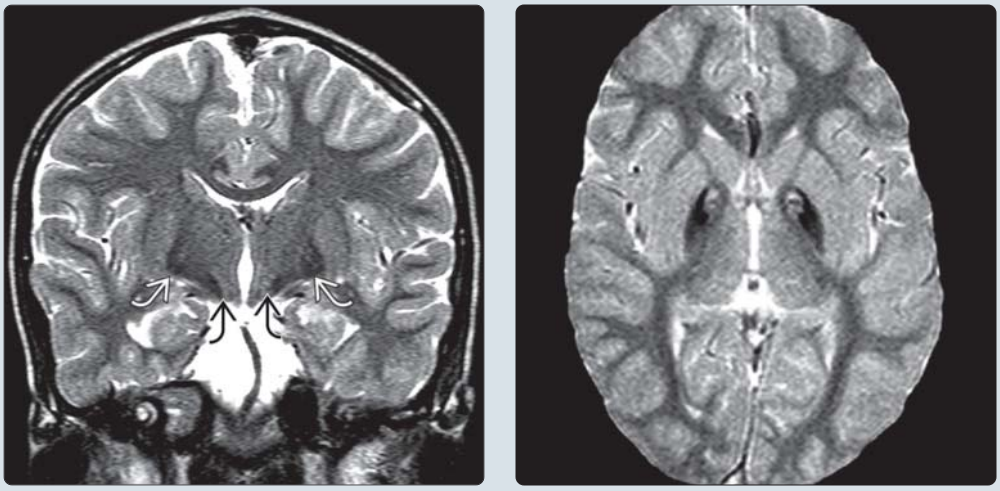

(Left) *Coronal T2WI MR of the same patient at 9 years of age shows abnormal hypointense signal in the globus pallidus and substantia nigra.* **(Right)** *Axial T2* GRE MR in same patient at 9 years of age shows "blooming" of hypointense signal in the globus pallidus secondary to the paramagnetic effect of iron. The findings in this patient are typical of the evolution of classic PKAN: Diminishing caliber of the "eye," increasing surrounding pallidal hypointensity, and progressive volume loss.*

https://CafePezeshki.IR

TERMINOLOGY

Abbreviations

- Pantothenate kinase-associated neurodegeneration (PKAN)

Synonyms

- Neurodegeneration with brain iron accumulation type 1 (NBIA-1)
- Hallervorden-Spatz syndrome
  - PKAN and NBIA-1 = preferred terms

Definitions

- Neurodegeneration with brain iron accumulation (NBIA) = umbrella term for neurodegenerative disorders characterized by brain iron accumulation
  - Known causes include PKAN (most common), aceruloplasminemia, neuroferritinopathy, and infantile neuroaxonal dystrophy
- PKAN caused by mutation pantothenate kinase 2 gene (*PANK2*)

IMAGING

General Features

- Best diagnostic clue: Eye of the tiger sign = diffuse pallidal T2 hypointensity with medial foci ↑ T2 signal
  - Highly suggestive of PKAN
  - Hyperintense "eye" may predate surrounding pallidal hypointensity
  - "Eye" caliber and intensity ↓ as disease progresses
  - Pallidal hypointensity increases as disease progresses
  - Eye of the tiger sign has been described in neuroferritinopathy
- Variable ↓ T2 signal substantia nigra > > dentate nuclei
- Atrophy in advanced diseases
- Location: Globus pallidus (GP), substantia nigra (SN), dentate nuclei (DN)
- Morphology: Signal alteration of globus pallidus resembles tiger eyes
- Iron deposition (ferritin bound) responsible for T2 hypointense imaging appearance

CT Findings

- NECT: Variable; hypodense, hyperdense, normal GP
- CECT: No abnormal enhancement

MR Findings

- T1WI: Variable (ferritin bound iron has > T1 shortening than hemosiderin bound)
- T2WI
  - Eye of the tiger sign = diffuse pallidal hypointensity with medial foci ↑ signal
  - Variable ↓ signal SN; more common in older patients
- FLAIR: "Eye" persists
- T2* GRE: ↓ T2 signal GP, SN "blooms" due to paramagnetic effect iron
- Susceptibility weighted imaging (SWI): Greater "blooming" artifact than T2* GRE
- T1WI C+: No abnormal enhancement
- MRS: ↓ NAA GP (neuronal loss)

Nuclear Medicine Findings

- Tc-99m SPECT: ↑ activity in medial GP
  - Possible chelation Tc-99m by pallidal cysteine

Imaging Recommendations

- Best imaging tool
  - MR
- Protocol advice
  - Consider SWI or T2* GRE sequence for mineralization
  - T2 hypointensity more conspicuous on spin-echo (vs. fast spin-echo) and high field strength magnets

DIFFERENTIAL DIAGNOSIS

Disorders With ↑ T2 Signal Globus Pallidus

- Metabolic
  - Methylmalonic acidemia (MMA): ↑ T2 signal GP ± periventricular white matter (WM)
  - Kearns-Sayre/L-2-hydroxyglutaric aciduria: ↑ T2 GP (> than other deep gray) and peripheral WM
  - Canavan: ↑ T2 GP (> than other deep gray) and subcortical WM; macrocephaly; ↑ NAA
  - Neuroferritinopathy: Variable-sized foci ↑ T2 signal GP, putamen, caudate heads with ↓ T2 SN, DN; disease of adults
  - Guanidinoacetate methyltransferase deficiency (impairs creatine synthesis)
- Ischemic/toxic
  - Anoxic encephalopathy: ↑ T2 GP (and other deep gray) and cortex
  - Carbon monoxide poisoning: ↑ T2 GP (± other deep gray, cortex, WM)
  - Cyanide poisoning: ↑ T2 basal ganglia followed by hemorrhagic necrosis
  - Kernicterus: ↑ T2/T1 globus pallidus in neonate

PATHOLOGY

General Features

- Iron accumulation likely secondary phenomenon in PKAN
  - Serial MRs in PKAN patients show hyperintense foci in GP predating surrounding hypointensity
- Embryology, anatomy
  - Progressive, physiologic brain iron accumulation occurs in GP, SN > red and dentate nuclei
  - ↓ T2 signal GP identified in majority of normal patients by age ≥ 25, but never before age 10
- Genetics
  - Autosomal recessive (50% sporadic)
  - > 100 *PANK2* mutations Chr 20p12.3-p13 identified
    - MR eye of the tiger sign highly correlative with *PANK2* mutation
    - *PANK2* gene encodes mitochondrial-targeted pantothenate kinase 2, key enzyme in biosynthesis of coenzyme A (CoA)
      - CoA essential to energy and fatty acid metabolism, among other functions
    - Null mutations are more common in early onset, rapidly progressive disease
    - Missense mutations more common in late onset, more slowly progressive disease
      - Suggests residual pantothenate kinase 2 activity in late onset (less severe) disease

https://CafePezeshki.IR

- HARP: **H**ypoprebetalipoproteinemia, **a**canthocytosis, **r**etinitis pigmentosa, and **p**allidal degeneration
  - Allelic with PKAN
  - Prominent orofacial dystonia; early onset parkinsonism
- Etiology
  - Leading theory
    - *PANK2* mutation → CoA deficiency → energy and lipid dyshomeostasis → production of oxygen free radicals → phospholipid membrane destruction
    - Basal ganglia and retina vulnerable to oxidative damage secondary to high metabolic demand
  - Additional factors
    - Cysteine accumulation in GP secondary to ↓ phosphopantothenate causes iron chelation and peroxidative cell membrane damage
    - Axonal spheroids further compromise glial and neuronal function

Gross Pathologic & Surgical Features

- Symmetric, rust-brown pigmentation GP (interna > externa), and pars reticulata SN
  - In addition to iron, intra-/extraneuronal ceroid lipofuscin and melanin contribute to pigmentation
- Variable atrophy

Microscopic Features

- Classic features
  - ↑ iron GP interna and pars reticulata SN
    - Iron located in astrocytes, microglial cells, neurons, and around vessels
  - Neuronal loss, gliosis, and glial inclusions primarily involving GP interna and pars reticulata SN
  - Round or oval, nonnucleated, axonal swellings ("spheroids") in GP, SN, cortex, and brainstem
- "Loose" tissue (consisting of reactive astrocytes, dystrophic axons, and vacuoles in anteromedial GP) corresponds to "eye" in eye of the tiger sign on MR
- Variably present acanthocytes (on blood smear)

CLINICAL ISSUES

Presentation

- Clinical classification into classic and atypical disease
  - Classic PKAN: Early onset, more rapidly progressive disease, uniform phenotype
  - Atypical PKAN: Late onset, more slowly progressive disease, heterogeneous phenotype
- Most common signs/symptoms
  - Classic PKAN: Dystonia
    - Other extrapyramidal signs/symptoms: Dysarthria, rigidity, choreoathetosis
    - Upper motor neuron signs/symptoms and cognitive decline are frequent
    - Pigmentary retinopathy (66%)
  - Atypical PKAN: Psychiatric and speech disturbances
    - Other signs/symptoms: Pyramidal/extrapyramidal disturbances (including freezing), dementia
- Clinical profile
  - Classic PKAN: Young child with gait, postural deficits
  - Atypical PKAN: Teenager with speech, psychiatric disturbance
- Normal serum and CSF iron levels
- Confirmatory *PANK2* mutation analysis should be performed in all suspected cases of PKAN

Demographics

- Age
  - Classic PKAN: Majority present before 6 years of age
  - Atypical PKAN: Mean age at presentation is 13 years
- Epidemiology: Rare; incidence unknown

Natural History & Prognosis

- Natural History
  - Classic PKAN: Rapid, nonuniform progression with periods of deterioration interspersed with stability, leading to early adulthood death
  - Atypical PKAN: More slowly progressive with loss of ambulation 15-40 years after disease onset
- Prognosis
  - Classic PKAN: Fatal; mean disease duration after symptom onset is 11 years
  - Atypical PKAN: Eventual severe impairment, ± death, adulthood

Treatment

- No curative treatment; iron chelation ineffective
- Palliative therapy
  - Baclofen, trihexyphenidyl frequently ineffective
  - Stereotactic pallidotomy
  - Promising initial results with pallidal deep brain stimulation

DIAGNOSTIC CHECKLIST

Image Interpretation Pearls

- Eye of the tiger sign highly suggestive of PKAN
- Physiologic GP hypointensity difficult to distinguish from pathologic hypointensity in teenager/adult

SELECTED REFERENCES

1. Arber C et al: Insights into molecular mechanisms of disease in Neurodegeneration with Brain Iron Accumulation; unifying theories. Neuropathol Appl Neurobiol. ePub, 2015
2. Dusek P et al: Wilson disease and other neurodegenerations with metal accumulations. Neurol Clin. 33(1):175-204, 2015
3. Hogarth P: Neurodegeneration with brain iron accumulation: diagnosis and management. J Mov Disord. 8(1):1-13, 2015
4. Ma LY et al: Novel gene mutations and clinical features in patients with pantothenate kinase-associated neurodegeneration. Clin Genet. 87(1):93-5, 2015
5. Stoeter P et al: Changes of cerebral white matter in patients suffering from Pantothenate Kinase-Associated Neurodegeneration (PKAN): A diffusion tensor imaging (DTI) study. Parkinsonism Relat Disord. ePub, 2015
6. Bosemani T et al: Susceptibility-weighted imaging in pantothenate kinase-associated neurodegeneration. J Pediatr. 164(1):212, 2014
7. Dusek P et al: The neurotoxicity of iron, copper and manganese in Parkinson's and Wilson's diseases. J Trace Elem Med Biol. ePub, 2014
8. Dezfouli MA et al: PANK2 and C19orf12 mutations are common causes of neurodegeneration with brain iron accumulation. Mov Disord. 28(2):228-32, 2013
9. Schipper HM: Neurodegeneration with brain iron accumulation - clinical syndromes and neuroimaging. Biochim Biophys Acta. 1822(3):350-60, 2012
10. Shah SO et al: Late-onset neurodegeneration with brain iron accumulation with diffusion tensor magnetic resonance imaging. Case Rep Neurol. 4(3):216-23, 2012
11. Kurian MA et al: Childhood disorders of neurodegeneration with brain iron accumulation (NBIA). Dev Med Child Neurol. 53(5):394-404, 2011
12. McNeill A et al: T2* and FSE MRI distinguishes four subtypes of neurodegeneration with brain iron accumulation. Neurology. 70(18):1614-9, 2008

https://CafePezeshki.IR

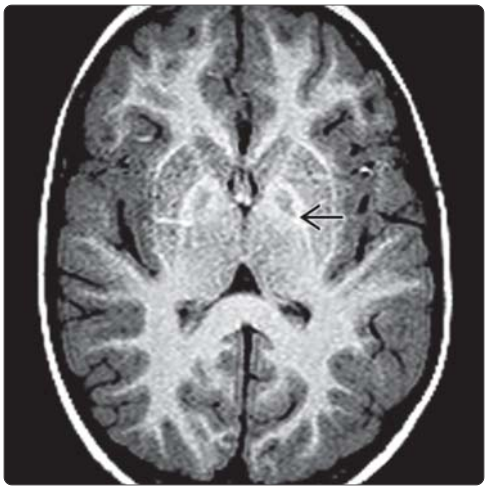

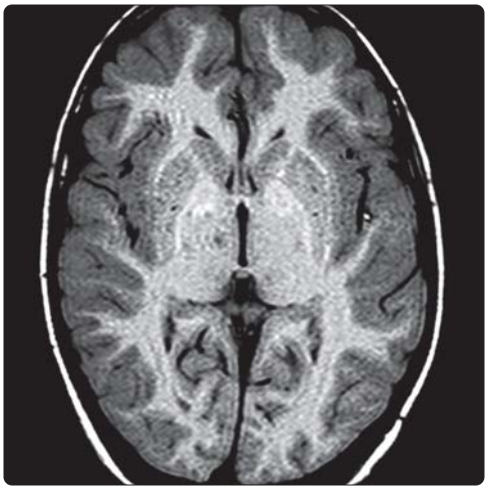

(Left) *Axial T1WI MR in a 5 year old with classic PKAN shows that the "eye" in the "eye of the tiger" is hypointense with few punctate areas of surrounding hyperintensity* ⇨. **(Right)** *Axial T1WI MR in the same patient at 9 years old shows the "eye" as mostly hyperintense. The appearance of the "eye" in "eye of the tiger" is variable depending on the stage of the disease. Progressive iron deposition within the globus pallidus likely accounts for greater T1 shortening seen in later disease.*

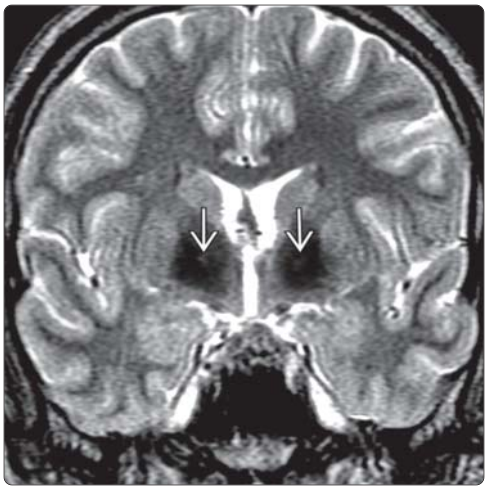

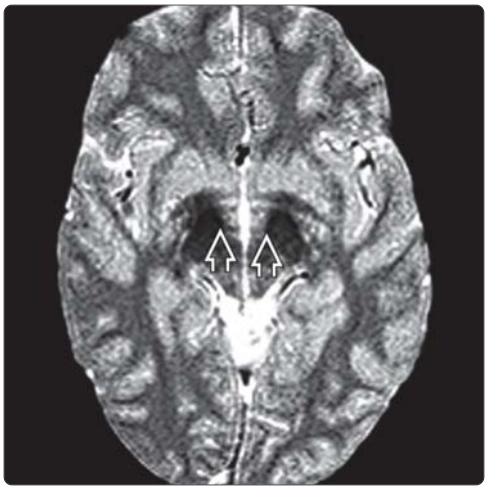

(Left) *Coronal T2WI MR in a patient with classic PKAN shows the classic "eye of the tiger" sign with small foci of increased T2 signal in the medial globi pallidi* ⇨ *surrounded by abnormal pallidal hypointensity.* **(Right)** *Axial T2* GRE MR in a patient with classic PKAN shows "blooming" of hypointense signal in the inferior globus pallidus and substantia nigra* ⇨. *Abnormal iron accumulation within the substantia nigra is more conspicuous on imaging as the disease progresses.*

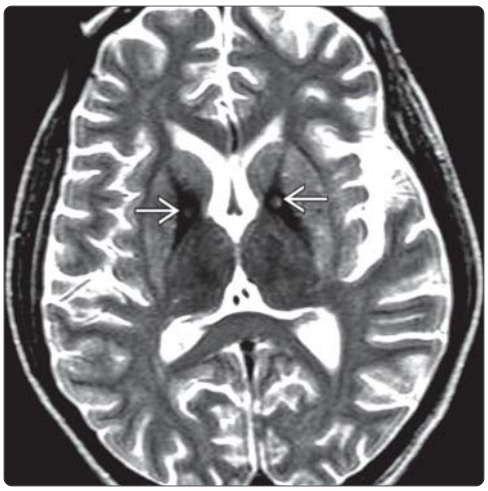

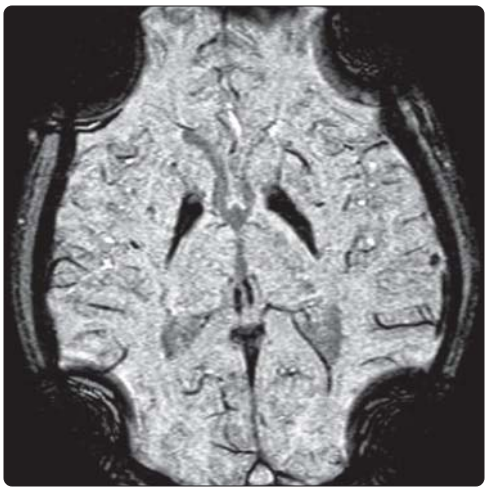

(Left) *Axial T2WI MR in a 12 year old with advanced classic PKAN undergoing preoperative imaging for pallidotomies shows globi pallidi hypointense and atrophic with subtle "eye of the tiger" signs* ⇨. *Note also the diffuse volume loss.* **(Right)** *Axial SWI in the same patient shows "blooming" of hypointense signal within the globi pallidi. The "eyes of the tiger" are no longer seen, obscured by the "blooming" effect. SWI is more sensitive than T2* GRE due to magnetic susceptibility effects.*

https://CafePezeshki.IR

KEY FACTS

TERMINOLOGY

- Autosomal dominant neurodegenerative disease
  - Loss of GABAergic neurons of basal ganglia (BG)

IMAGING

- Diffuse cerebral atrophy
- Atrophy of caudate nucleus → frontal horns enlarged
- ↑ CC:IT ratio (bicaudate ratio)
  - Shrinkage of caudate nucleus (CN) and ↑ intercaudate distance (CC)
  - Increased intercaudate distance (CC) between medial aspects of CN
  - Most specific & sensitive measure for HD
- Hyperintense signal in CN, putamina in juvenile HD
- ↓ FDG uptake in BG before any detectable atrophy
- ± frontal lobe hypometabolism

TOP DIFFERENTIAL DIAGNOSES

- Leigh disease
- Wilson disease
- Pantothenate kinase-associated neurodegeneration (formerly called Hallervorden-Spatz)
- Carbon monoxide poisoning

PATHOLOGY

- Autosomal dominant with complete penetrance
- CAG trinucleotide repeat disease affecting HD gene on chromosome 4p16.3

DIAGNOSTIC CHECKLIST

- Rule out reversible dementias, movement disorders
- Caudate atrophy is main radiologic feature of HD
- ↑ bicaudate diameter: Sensitive for CN atrophy
- Decline in size of GP, putamen correlates with disease progression
- Consider HD in child with ↑ signal in CN/putamina on PD-/T2WI

(Left) *Axial graphic shows the convex margins of the frontal horns due to atrophy of the heads of the caudate nuclei.* **(Right)** *Axial T2WI MR in a patient with juvenile Huntington disease shows generalized volume loss and striking atrophy and hyperintensity of both caudate nuclei. The frontal horns of the lateral ventricles are enlarged, and there is atrophy and hyperintensity in the putamina.*

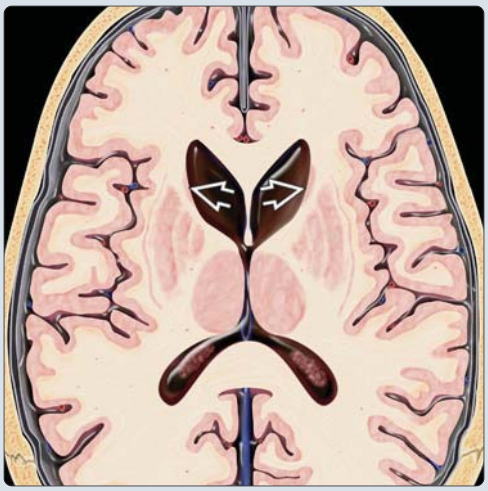

(Left) *Autopsy specimen sectioned in the coronal plane shows enlarged lateral ventricles and basal cisterns. Both caudate nuclei appear thinned and atrophic.* **(Right)** *Coronal CECT, cut in same plane to correspond to the autopsy specimen in the previous image, shows straightening of the lateral borders of the lateral ventricles due to caudate atrophy and increased intercaudate (CC) distance, which are characteristic findings of Huntington disease.*

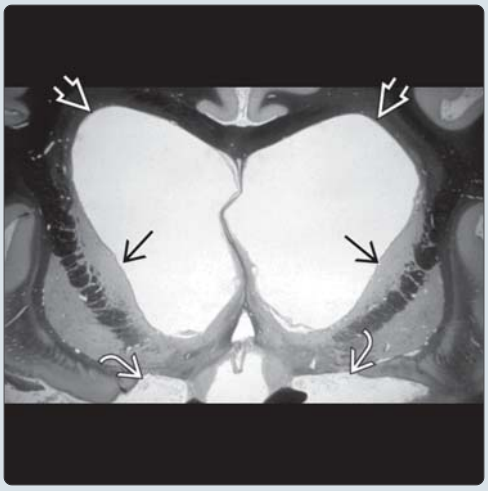

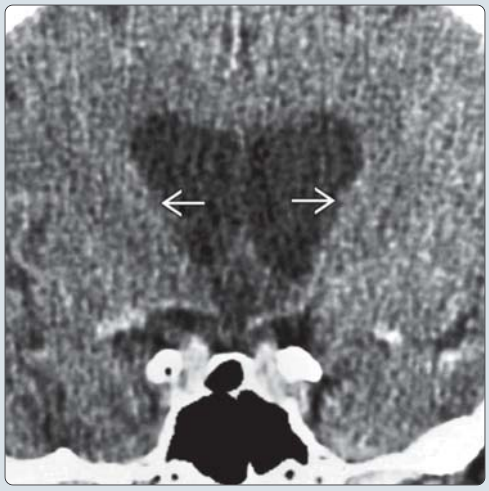

https://CafePezeshki.IR

TERMINOLOGY

Abbreviations

- Huntington disease (HD), huntingtin (HTT)

Synonyms

- Huntington chorea

Definitions

- Autosomal dominant neurodegenerative disease
  - Loss of GABAergic neurons of basal ganglia (BG)
- Clinical triad: Early onset dementia, choreoathetosis, psychosis

IMAGING

General Features

- Best diagnostic clue
  - Atrophy of caudate nucleus (CN) → frontal horns enlarged
- Location
  - Primarily striatum (especially CN, putamen)
  - Cerebral cortex, globus pallidus (GP), thalamus
  - Substantia nigra (SN), brainstem
- Size
  - Decreased caudate nucleus size
- Morphology
  - Loss of convex surface of caudate head

CT Findings

- NECT
  - Atrophy of CN, putamen, and (lesser degree) GP
  - Compensatory enlargement of frontal horns of lateral ventricles
  - Diffuse cerebral atrophy (reported to be predominantly frontal in some studies)
  - CN atrophy is measured on axial images at level of 3rd ventricle
    - Increased intercaudate distance (CC) between medial aspects of CN
    - CC can be compared with distance between inner tables (IT) of skull (CC:IT ratio)
    - In HD, CC is typically > 20 mm & often > 25 mm (compared to 10-14 mm in normal individuals)
    - CC:IT (bicaudate) ratio ↑ in HD; considered most specific & sensitive HD measurement
    - In HD, CC:IT ratio usually ranges from 0.175-0.185 compared to ~ 0.12 in normal individuals
    - CC compared with distance across lateral margins of frontal horns (FH) provides FH:CC ratio
    - In HD, FH:CC ratio typically ranges from 1.3-1.8 compared to 2.3-2.8 in normal individuals
- CECT
  - No contrast enhancement of affected structures

MR Findings

- T1WI
  - Shrinkage of CN and increased CC
  - MR measurements: ↓ volume in all BG structures
    - Reported even in presymptomatic stage of HD
  - Diffuse cerebral atrophy
- T2WI
  - Hyperintense signal in CN, putamina in juvenile HD
    - Related to gliosis
  - Shrinkage of CN; ↑ CC
  - Striatum may have ↓ signal due to iron deposition
  - Susceptibility weighted imaging (SWI) suggests iron accumulation
- MRS
  - ↑ lactate concentration in occipital cortex of symptomatic HD, also in BG in some patients
  - ↓ N-acetylaspartate to creatine ratio in BG (neuronal loss)
  - ↑ ↑ choline to creatine ratio in BG due to gliosis

Nuclear Medicine Findings

- PET
  - ↓ FDG uptake in BG precedes detectable atrophy
  - ± frontal lobe hypometabolism
- SPECT: Perfusion defects in motor cortex, prefrontal cortex, and BG correlate with clinical disease

Imaging Recommendations

- Best imaging tool
  - MR
- Protocol advice
  - T2WI

DIFFERENTIAL DIAGNOSIS

Leigh Disease

- Many metabolic causes
- Onset usually < 2 years old, but juvenile/adult forms also exist
- Changes in putamen, CN, and tegmentum
  - T1 hypointensities, T2 hyperintensities (infarcts)
  - No atrophy of CN and putamina
- Focal involvement of white matter, thalamus, brainstem, and cerebellum

Wilson Disease

- Rigidity, tremor, dystonia, gait difficulty, dysarthria
- T2WI: Symmetrical signal hyperintensity in CN, putamen, midbrain, and pons (gliosis and edema)
  - Asymmetrical hypointensity in frontal white matter
  - Characteristic irregular areas of hypointensity in CN and putamen
- Atrophy of CN and brainstem on CT, MR

Pantothenate Kinase-Associated Neurodegeneration

- Neurodegeneration with brain iron accumulation (formerly called Hallervorden-Spatz)
- Involuntary movements (choreoathetosis), spasticity
- Progressive dementia in young adults
- Characteristic iron deposition in GP, red nuclei, SN
  - "Eye of the tiger" sign: Central high signal in T2-hypointense GP
- GP atrophy, ± cortical, CN atrophy

Carbon Monoxide Poisoning

- Bilateral CT hypodensity, T2 hyperintensity in GP

Other Neurodegenerative Disorders, Adults

- Multiple system atrophy
- Corticobasal degeneration

https://CafePezeshki.IR

- Frontotemporal lobar degeneration

PATHOLOGY

General Features

- Etiology
  - Polyglutamine expansion → HTT fragments accumulate in nucleus; cytoplasm → aggregates in axonal terminals
- Genetics
  - Autosomal dominant with complete penetrance
  - CAG trinucleotide repeat disease affecting HD gene on chromosome 4p16.3
  - Genetic anticipation: ↑ severity or ↓ age of onset in successive generations
    - More commonly in paternal transmission of mutated allele
  - Homozygosity for HD mutation (very rare)
    - Associated with more severe clinical course

Staging, Grading, & Classification

- Based on gross striatal pathology, neuronal loss, gliosis
- Grade 0: Normal gross, histologic examination
- Grade 1: No gross striatal atrophy (only histologic changes)
- Grade 2: Striatal atrophy, convex CN
- Grade 3: More severe striatal atrophy, flat CN
- Grade 4: Most severe striatal atrophy, concave CN

Gross Pathologic & Surgical Features

- Diffuse cerebral atrophy (marked in CN, putamen)
- Juvenile HD: Involvement of GP, cerebellum (typically not involved in adults)

Microscopic Features

- Neuropathological hallmarks of HD
  - Intranuclear inclusions containing Huntington protein
  - Perinuclear aggregates in cortex, striatum

CLINICAL ISSUES

Presentation

- Most common signs/symptoms
  - Classic triad
    - Movement disorder (choreoathetosis)
    - Dementia of subcortical type
    - Behavioral changes/psychosis
- Other signs/symptoms
  - Dysarthria, dysphagia, abnormal eye movements
- Clinical profile
  - Pathognomonic feature of HD: Movement disorder
    - Chorea: Often facial twitching or writhing and twitching of distal extremities; ballism later on
    - Progressive cytoplasmic → impaired gait ("dancing" gait)
    - Rigidity and dystonia in later stages (adult HD)
  - Juvenile HD: Rigidity > chorea
    - Rigidity & dystonia may occur as initial symptoms
    - Cerebellar signs, dyslalia, rapid cognitive decline
    - Seizures, parkinsonism, dystonia, long-tract signs

Demographics

- Age
  - Mean at onset: 35-44 years in adult-onset HD
  - Juvenile HD (5-10% of cases): Onset at < 20 years
- Gender
  - M = F; gender-related factor affecting disease onset
    - Earlier onset, faster progression of HD in offspring of male patients
    - 70% of juvenile cases have affected father
- Ethnicity
  - Less common in African/Asian populations
- Epidemiology
  - Worldwide prevalence: 5-10/100,000 people
  - 3-7/100,000 in populations of Western European descent

Natural History & Prognosis

- Early symptoms: Personality changes and subtle movement disturbances
- Progression to choreoathetosis and dementia
- Behavioral disorganization, depression, suicidal behavior, psychotic features (visual hallucinations)
- Adult HD: Progressive deterioration until death 15-20 years after onset
- Higher degree of volume loss ↔ earlier age of onset
- Juvenile HD: More progressive clinical course

Treatment

- Antidepressants, high-potency antipsychotics
- Tetrabenazine (Dopamine depleters)
- Antiglutamatergic drugs (amantadine, memantine, riluzole)
- Ubiquinone (coenzyme Q10) → normalization of lactate levels in cortex and striatum
- Bilateral neural transplantation
- Experimental: Grafting of trophic factor-producing cell lines

DIAGNOSTIC CHECKLIST

Consider

- Reversible dementias & movement disorders

Image Interpretation Pearls

- Caudate atrophy is main radiologic feature of HD
  - Bicaudate diameter: Sensitive for CN atrophy
- Consider HD in child with ↑ signal in CN/putamina on PD-/T2WI

SELECTED REFERENCES

1. Goveas J et al: Diffusion-MRI in neurodegenerative disorders. Magn Reson Imaging. ePub, 2015
2. Mason S et al: Progress in Huntington's disease: the search for markers of disease onset and progression. J Neurol. ePub, 2015
3. Stroedicke M et al: Systematic interaction network filtering identifies CRMP1 as a novel suppressor of huntingtin misfolding and neurotoxicity. Genome Res. 25(5):701-13, 2015
4. Valor LM: Epigenetic-based therapies in the preclinical and clinical treatment of Huntington's disease. Int J Biochem Cell Biol. ePub, 2015
5. Wassef SN et al: T1ρ imaging in premanifest Huntington disease reveals changes associated with disease progression. Mov Disord. ePub, 2015
6. Macerollo A et al: Susceptibility-weighted imaging changes suggesting brain iron accumulation in Huntington's disease: an epiphenomenon which causes diagnostic difficulty. Eur J Neurol. 21(2):e16-7, 2014
7. Matsui JT et al: Diffusion weighted imaging of prefrontal cortex in prodromal huntington's disease. Hum Brain Mapp. 35(4):1562-73, 2014

https://CafePezeshki.IR

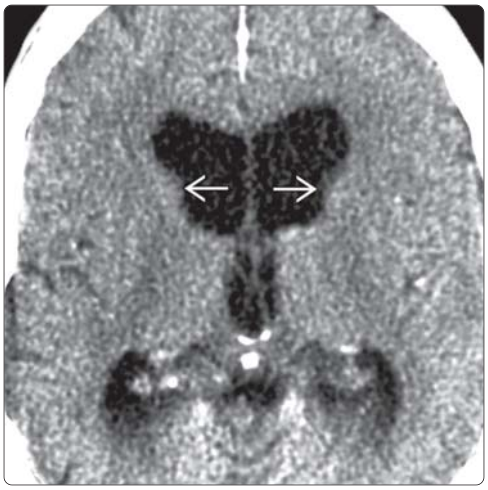

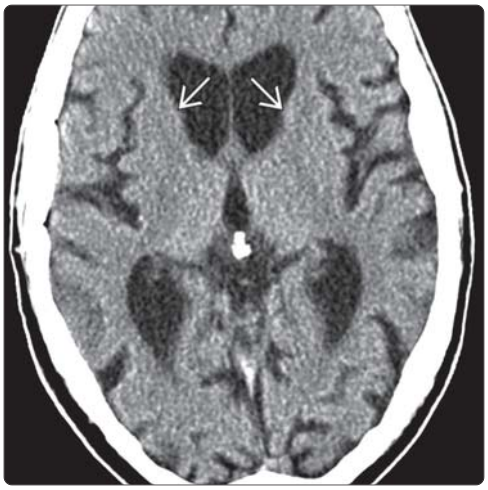

(Left) *Axial CECT shows classic CT findings of Huntington disease involving the caudate nuclei, including caudate atrophy and increased intercaudate distance* ➡. **(Right)** *Axial NECT in a patient with Huntington disease shows generalized atrophy. The frontal horns of the lateral ventricles are disproportionately enlarged and flattened, with a loss of normal concavity* ➡ *caused by marked caudate head atrophy.*

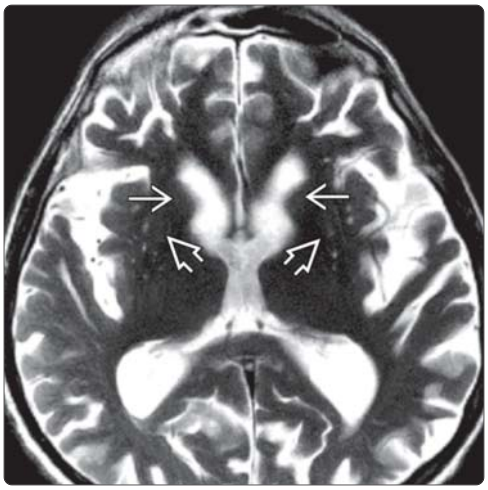

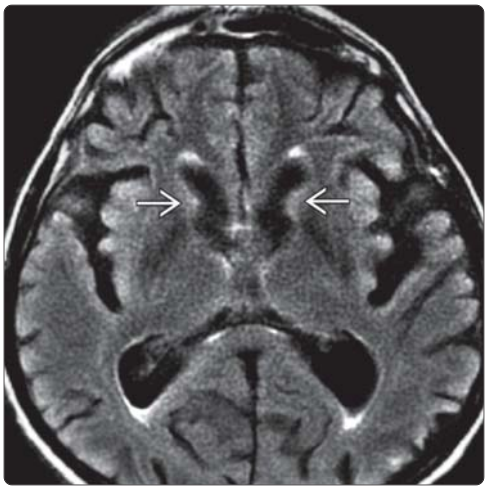

(Left) *Axial T2WI MR in a patient with Huntington disease shows atrophy in the bilateral caudate nuclei* ➡ *and putamina* ➡. *Also note the generalized brain atrophy with dilatation of the lateral ventricles and cortical sulci.* **(Right)** *Axial FLAIR MR in the same patient shows a slight increase in signal intensity of both caudate* ➡ *nuclei in addition to atrophy.*

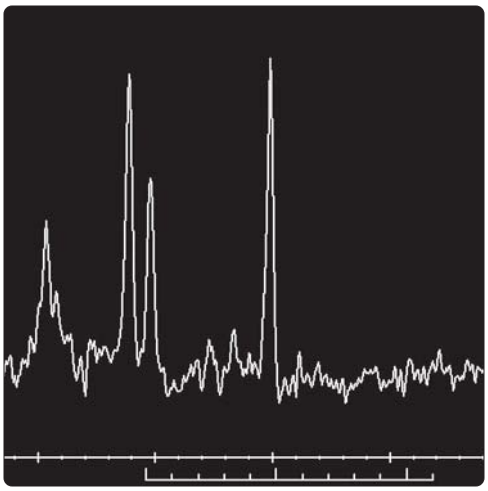

(Left) *Axial FLAIR MR in an 8 year old with dysarthria, rigidity, and a family history of HD demonstrates a combination of volume loss and ↑ signal intensity of the caudate heads* ➡ *& putamina* ➡. **(Right)** *MRS (TR of 144) in the same patient demonstrates abnormal choline to creatine peak and low NAA. Differential diagnosis would include mitochondrial disorders such as Leigh syndrome. No lactate doublet & a family history of Huntington favors HD over Leigh syndrome.*

https://CafePezeshki.IR

KEY FACTS

TERMINOLOGY

- Wilson disease (WD), hepatolenticular degeneration
- Autosomal recessive inherited copper metabolism disorder characterized by
  - Abnormal accumulation of copper in various tissues
  - Particularly in liver and brain (basal ganglia)

IMAGING

- Usually normal MR in presymptomatic patients
- SI improvement correlated with clinical response to copper-chelating therapy
- Symmetrical T2 hyperintensity or mixed intensity in putamina (with hyperintense peripheral putaminal rim), caudate nuclei, thalami, and globus pallidi (GP)
- Characteristic "face of giant panda" sign on axial sections at midbrain level

TOP DIFFERENTIAL DIAGNOSES

- Leigh disease
- Creutzfeldt-Jakob disease
- Japanese encephalitis
- Organic aciduria
- Hypoxic-ischemic encephalopathy

CLINICAL ISSUES

- Kayser-Fleischer ring in cornea
- Neurologic: Asymmetric tremor, ataxia, dyskinesia, dysarthria, dystonia (mainly face), incoordination
  - Chelation therapy prevents progression

DIAGNOSTIC CHECKLIST

- MR improvement correlated with clinical recovery

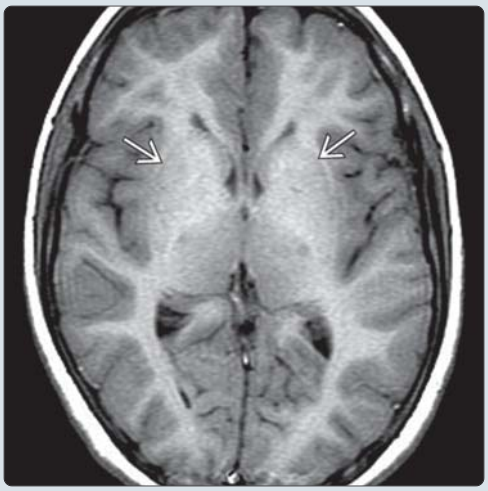

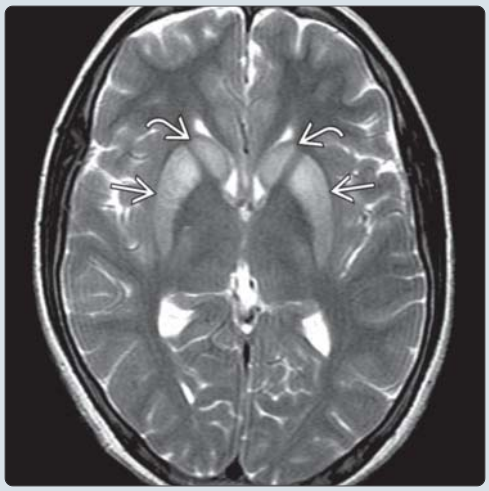

(Left) *Axial T1WI in a patient with Wilson disease shows basal ganglia hyperintensity* ➡. **(Right)** *Axial T2WI in the same case shows hyperintensity in the caudate nuclei* ➡ *and putamen* ➡. *The globi pallidi are spared.*

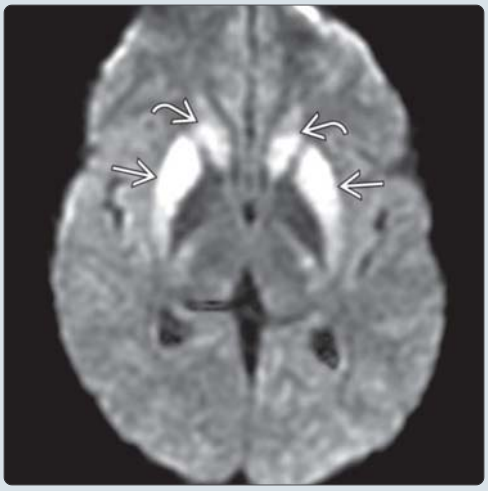

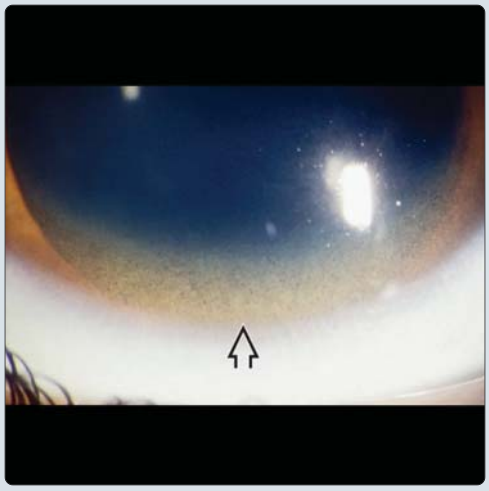

(Left) *Axial DWI in the same case shows restricted diffusion in the caudate nuclei* ➡ *and putamina* ➡. *The lesions did not enhance on T1C+ imaging. (Courtesy M. Ayadi, MD.)* **(Right)** *Slit-lamp examination shows a Kayser-Fleischer ring of the cornea* ⇨, *an important marker in Wilson disease that is almost always present in patients with neurological involvement.*

https://CafePezeshki.IR

TERMINOLOGY

Abbreviations

- Wilson disease (WD)

Synonyms

- Progressive hepatolenticular degeneration

Definitions

- Autosomal recessive inherited copper metabolism disorder characterized by abnormal accumulation of copper in various tissues

IMAGING

General Features

- Best diagnostic clue
  - Symmetrical T2 hyperintensity or mixed intensity in putamina, caudate nuclei, thalami, and globus pallidi (GP)
- Location
  - Most common: Putamen (predilection for outer rim)
  - Caudate nuclei, GP, thalami (ventrolateral nuclei)
  - Midbrain, pons, cerebellum (vermis and dentate nucleus)
  - Cortical and subcortical lesions (mostly frontal lobe)
- Size
  - Initially ↑ (swelling of basal ganglia [BG]), then ↓ (atrophy)
- Morphology
  - No change in shape of affected structures

CT Findings

- NECT
  - Widening of frontal horns of lateral ventricles; diffuse brain atrophy
  - ± hypodensity in lentiform nuclei and thalami
- CECT
  - Lesions do not contrast enhance

MR Findings

- T1WI
  - T1 signal generally reduced in BG
  - Signal intensity may ↑ in affected BG (paramagnetic effects of copper)
- T2WI
  - Usually normal MR in presymptomatic patients
  - Hyper-/hypo-/mixed intensity in putamen, GP, caudate, thalamus
    - Bilateral symmetric concentric-laminar T2 putaminal hyperintensity
    - BG can be hypointense due to ↑ iron content
  - Characteristic face of giant panda sign; normal signal intensity in red nucleus against background of hyperintense signal in tegmentum
  - ± hyperintensity in periaqueductal gray matter, pontine tegmentum, medulla oblongata, dentate nucleus, and cerebral and cerebellar white matter (WM), especially frontal lobe
  - Clinical response to copper-chelating therapy correlates with improvement in signal abnormalities
  - In adults, BG lesions may differ from those in children
    - Putaminal lesions may be absent; GP and substantia nigra may be hypointense on T2WI
- PD/intermediate
  - Symmetrical high signal intensity in affected BG
- DWI
  - Abnormally low ADC values immediately after onset of neurologic symptoms; subsequently high ADC values (necrosis, spongiform degeneration)
- T1WI C+
  - No contrast enhancement is typically seen
- MRS
  - ↓ N-acetyl aspartate to creatine ratio (neuronal loss) in BG, parietooccipital cortex, frontal WM
  - ↓ myoinositol to creatine ratio in BG and ↓ choline:creatine ratio in GP
  - ↓ myoinositol to creatine ratio in WD with portosystemic shunting (pattern of hepatic encephalopathy)

Nuclear Medicine Findings

- PET
  - ↓↓ glucose metabolism in cerebellum, striatum, and, to lesser extent, in cortex and thalamus
  - ↓↓ dopa-decarboxylase activity (impaired nigrostriatal dopaminergic pathway)
- SPECT
  - (I-123)2β-carbomethoxy-3β-(4(I-123)iodophenyl)tropane binds to presynaptic striatal dopamine carriers
  - (I-123)iodobenzamide binds to postsynaptic striatal dopamine D2R
  - In symptomatic WD patients
    - ↓↓ striatal binding ratios of both tracers
  - In all WD patients, highly correlated binding ratios of both tracers corresponding to severity of neurologic features

Imaging Recommendations

- Best imaging tool
  - MR more sensitive than CT for detection of early lesions
- Protocol advice
  - T2WI, FLAIR, DWI

DIFFERENTIAL DIAGNOSIS

Leigh Disease

- Subacute necrotizing encephalomyelopathy
- Symmetrical spongiform brain lesions with onset in infancy/early childhood
- Lesions predominantly bilateral and symmetrical, in brainstem, BG (particularly putamen), and cerebral WM

Hypoxic-Ischemic Encephalopathy

- Bilateral symmetric hyperintense lesions with restricted diffusion in putamen, caudate, thalamus, and cortex

Creutzfeldt-Jakob Disease

- Progressively hyperintense changes in BG, thalamus, and cerebral cortices on T2WI

Japanese Encephalitis (JE)

- Homogeneous T2 hyperintensities in BG and posteromedial thalami (very characteristic of JE, spared in WD)

Organic Aciduria

- Symmetrical diffuse WM changes, wide CSF spaces

https://CafePezeshki.IR

- BG changes (↑ T2 signal ± volume loss in caudate &/or lentiform nuclei)

Methanol Poisoning

- Bilateral symmetric T2 hyperintensity in putamen, caudate ± WM

Osmotic Demyelination Syndrome

- Involvement of pons (central median raphe), basal ganglia, and, rarely, midbrain

PATHOLOGY

General Features

- Etiology
  - Defective incorporation of copper into ceruloplasmin and impaired biliary copper excretion
  - Brain lesions caused by accumulation of copper, chronic ischemia, vasculopathy, or demyelination
- Genetics
  - Autosomal recessive: ATPase copper transporting β-polypeptide (*ATP7B*) gene on chromosome 13q14.3-q21.1
- General comments
  - Excess copper throughout brain (lesions often bilateral and symmetrical), with unexplained tendency for extensive BG damage

Staging, Grading, & Classification

- Stage 1: Initial period of accumulation of copper by hepatic binding sites
- Stage 2: Acute redistribution of copper within liver and release into circulation
- Stage 3: Chronic accumulation of copper in brain and other extrahepatic tissues

Gross Pathologic & Surgical Features

- Ventricular enlargement, sulcal widening

Microscopic Features

- Edema, necrosis, and spongiform degeneration of BG; gliosis and demyelination in WM
- Opalski cells = PAS(+) altered glial cells
- Deep pyramidal cell layers of cerebral cortex involved

CLINICAL ISSUES

Presentation

- Most common signs/symptoms
  - Neurologic: Asymmetric tremor, ataxia, incoordination, dyskinesia, dysarthria, dystonia (mainly facial)
    - Parkinsonian symptoms: Rigidity, bradykinesia
  - Psychiatric: Hyperkinetic behavior, irritability, emotional lability, difficulty in concentration, depression, psychosis, mania, personality change
  - Acute hepatitis
  - Kayser-Fleischer ring in cornea due to abnormal copper accumulation in Descemet membrane
- Clinical profile
  - 40-50% of patients present with liver disease
  - 40-50% present with neurological or psychiatric symptoms (corneal rings almost always present)
  - ↓ ceruloplasmin and total serum copper levels, ↑ 24-hour urinary copper excretion, and ↑ ↑ hepatic copper content

Demographics

- Age
  - Onset of liver disease usually at age 8-16 years
  - Neurological symptoms often 1st recognized in 2nd-3rd decade (rarely, age < 12 years)
- Gender
  - Generally M = F, but M:F = 1:4 for fulminant WD, i.e., liver failure, encephalopathy, coagulopathy
- Epidemiology
  - Prevalence: 1 in 30,000-40,000 people
  - Carrier frequency in USA: 1 in 90 individuals

Natural History & Prognosis

- Children: Liver disease most common presentation
- Older individuals: Neuropsychiatric symptoms
  - ↑ symptom severity with ↑ brain copper deposition
- Once symptomatic, WD is fatal if untreated; 70% mortality for patients with fulminant liver failure
- Good prognosis with early chelation treatment
  - Prevents progression; may improve symptoms
- Best prognosis: Treated asymptomatic siblings

Treatment

- Restriction of food abundant in copper (e.g., chocolate, liver, nuts, mushrooms, shellfish)
- Early administration of chelating therapy can ↓ brain damage
  - Penicillamine (side effect of initial neurological deterioration in 20-50%)
  - Other treatments: Trientine (better alternative chelator), ammonium tetrathiomolybdate, zinc (especially for presymptomatic and asymptomatic patients)
- Liver transplant (for severe hepatic decompensation)

DIAGNOSTIC CHECKLIST

Image Interpretation Pearls

- T2 hyperintensity in striatum with neurologic dysfunction
- T1 hyperintensity in BG with hepatic dysfunction
- MR improvement correlated with clinical recovery

SELECTED REFERENCES

1. Wu F et al: Wilson's Disease: A Comprehensive Review of the Molecular Mechanisms. Int J Mol Sci. 16(3):6419-6431, 2015
2. Fritzsch D et al: Seven-tesla magnetic resonance imaging in Wilson disease using quantitative susceptibility mapping for measurement of copper accumulation. Invest Radiol. 49(5):299-306, 2014
3. Dusek P et al: The neurotoxicity of iron, copper and manganese in Parkinson's and Wilson's diseases. J Trace Elem Med Biol. ePub, 2014
4. Gupta S: Cell therapy to remove excess copper in Wilson's disease. Ann N Y Acad Sci. 1315:70-80, 2014
5. Hermann W: Morphological and functional imaging in neurological and non-neurological Wilson's patients. Ann N Y Acad Sci. 1315:24-9, 2014
6. Kozić DB et al: Reversible lesions in the brain parenchyma in Wilson's disease confirmed by magnetic resonance imaging: earlier administration of chelating therapy can reduce the damage to the brain. Neural Regen Res. 9(21):1912-6, 2014
7. Krishna SH et al: Congenital genetic inborn errors of metabolism presenting as an adult or persisting into adulthood: neuroimaging in the more common or recognizable disorders. Semin Ultrasound CT MR. 35(2):160-91, 2014
8. Pulai S et al: Clinical features, MRI brain, and MRS abnormalities of drug-naïve neurologic Wilson's disease. Neurol India. 62(2):153-8, 2014

https://CafePezeshki.IR

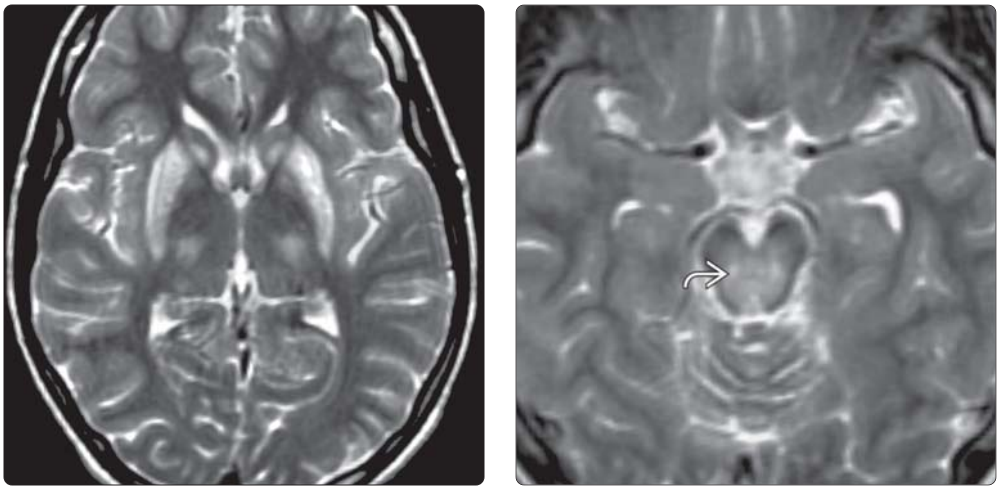

(Left) *Axial T2WI MR in a 13-year-old boy shows typical bilateral symmetric increased signal intensity in the putamen, head of caudate nuclei, and thalamus.* **(Right)** *Axial T2WI MR in the same patient shows typical areas of hyperintense signal without mass effect, primarily involving the dorsal part of midbrain.*

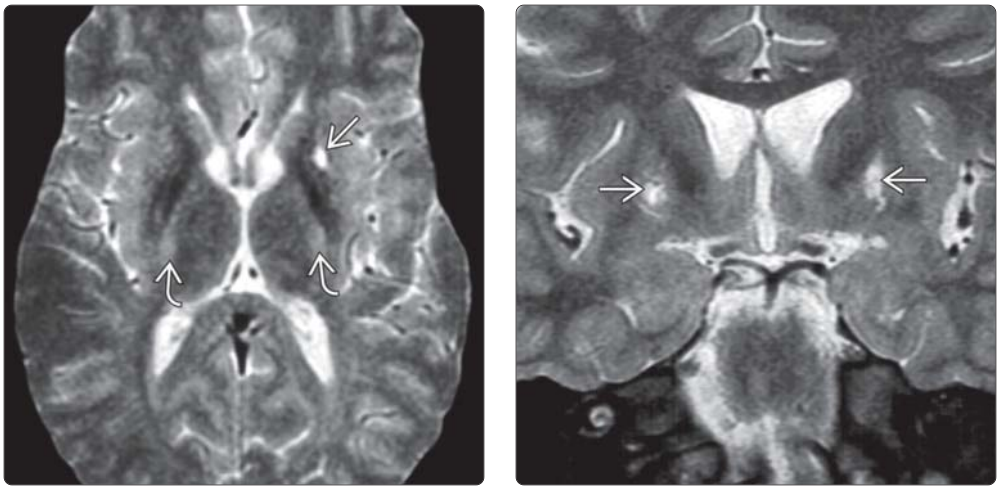

(Left) *Axial T2WI MR in a 19-year-old man shows laminar hyperintense signal in the anterior putamen and within the corticospinal tracts in the posterior limbs of the internal capsule.* **(Right)** *Coronal T2WI MR in the same patient shows hyperintense lesions in the putamina.*

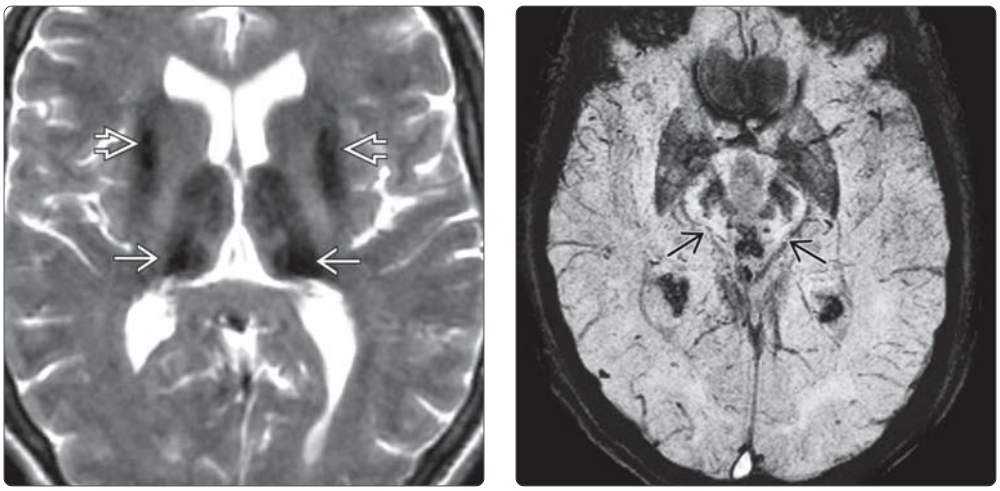

(Left) *Axial T2WI MR in a patient with Wilson disease shows hypointense signal within the thalami and basal ganglia.* **(Right)** *Axial T2* SWI MR in another patient with documented Wilson disease shows symmetric hypointensity in the midbrain with the so-called face of a giant panda sign.*

https://CafePezeshki.IR

PART I
SECTION 10

Acquired Toxic/Metabolic/Degenerative Disorders

Acquired Toxic/Metabolic Disorders Overview 858

Toxic, Metabolic, Nutritional, Systemic Diseases With CNS Manifestations

Pediatric Hypoglycemia 862
Adult Hypoglycemia 866
Kernicterus 868
Thyroid Disorders 870
Parathyroid Disorders 874
Fahr Disease 876
Alcoholic Encephalopathy 880
Hepatic Encephalopathy 884
Acute Hypertensive Encephalopathy, PRES 888
Chronic Hypertensive Encephalopathy 892
Idiopathic Intracranial Hypertension 896
Carbon Monoxide Poisoning 900
Drug Abuse 904
Methanol Poisoning 908
Cyanide Poisoning 910
Osmotic Demyelination Syndrome 912
Radiation and Chemotherapy 916
Pseudoprogression 920
Pseudoresponse 922
Mesial Temporal Sclerosis 924
Status Epilepticus 928
Transient Global Amnesia (TGA) 932

Dementias and Degenerative Disorders

Normal Aging Brain 934
Alzheimer Disease 938
Vascular Dementia 942
Frontotemporal Lobar Degeneration 946
Dementia With Lewy Bodies 950
Creutzfeldt-Jakob Disease (CJD) 952
Parkinson Disease 956

https://CafePezeshki.IR

Multiple System Atrophy	**960**
Corticobasal Degeneration	**964**
Progressive Supranuclear Palsy	**968**
Amyotrophic Lateral Sclerosis (ALS)	**972**
Wallerian Degeneration	**976**
Crossed Cerebellar Diaschisis	**980**
Hypertrophic Olivary Degeneration	**982**

https://CafePezeshki.IR

Approach to Toxic and Metabolic Disorders

Acquired toxic and metabolic disorders of the brain result from a wide variety of agents, including toxic exposures, substance abuse, radiation, and chemotherapy, as well as metabolic alterations, including hypertension, hepatic failure, hypoglycemia, and osmotic demyelination. The vast majority of toxic and metabolic disorders of the brain involve the deep gray nuclei (basal ganglia and thalamus) or the cerebral white matter. Typically, there is symmetric abnormality of the involved structures, which can provide a clue to the correct diagnosis. MR shows damage at both early and delayed phases of toxic and metabolic disorders. DWI and FLAIR are extremely valuable in differentiating among the various pathologies in this group and can help arrive at a correct diagnosis. Of course, clinical history of possible exposure or substance abuse is often the key to the patient's diagnosis.

Imaging Anatomy

Basal Ganglia

The basal ganglia (BG) are symmetric paired deep gray matter nuclei in cerebral hemispheres and form the core of the extrapyramidal system and regulate motor activity. The BG consists of caudate nucleus, putamen, and globus pallidus (GP). Caudate nucleus and putamen form the corpus striatum. The putamen and GB together are called the lentiform nuclei.

- **Caudate nucleus** is a C-shaped nucleus with a large head, tapered body, and down-curving tail. The head forms the floor and lateral wall of the anterior horn of the lateral ventricle. The caudate body parallels the lateral ventricles. The anterior limb of the internal capsule separates the caudate head from the putamen and GP.
- **Putamen** is the outermost part of the BG located lateral to GP and is separated by the lateral or external medullary lamina.
- **GP** consists of 2 segments, lateral (external) and medial (internal), separated by a thin layer of myelinated axons, the internal medullary lamina.

Thalamus

The thalamus is comprised of paired ovoid nuclear complexes that act as relay stations for most of the sensory pathways. The thalami extend from the foramen of Monro to the quadrigeminal plate of the midbrain. The medial aspect of the thalami form the 3rd ventricle lateral walls. The posterior limb of the internal capsule forms the lateral border of the thalami. The thalamus is subdivided into several nuclear groups, the anterior, medial, lateral, medial geniculate nuclei (part of the auditory system), lateral geniculate nuclei (part of the visual system), and pulvinar. These nuclear groups are further subdivided into 10 additional nuclei. The pulvinar is easily identified as it is the most posterior of the thalamic nuclei and overhangs the superior colliculus. The subthalamic nucleus is small, lens-shaped, lies superolateral to the red nucleus, and is rarely involved in toxic or metabolic disorders.

Pathologic Issues

The mechanisms for various toxic and metabolic lesions of the brain are complex and often represent a combination of various pathways. Since the deep gray nuclei are highly metabolically active and require significant oxygenation, they are commonly affected by toxins, metabolic abnormalities, and hypoxic-ischemic injury. Often, as in carbon monoxide (CO) and cyanide poisoning, there is a component of hypoxic injury that helps explain the predilection for involvement of the GP, which is extremely sensitive to hypoxia. Selective vulnerability of the deep gray nuclei is also related to dysfunction of selected excitatory neuronal circuits, inhibition of mitochondrial function, and selective loss of dopaminergic neurons.

Differential Diagnosis

Most of the pathologies that affect the brain have a characteristic location, which helps the radiologist arrive at a correct diagnosis. The following differential diagnosis considerations will provide clues to the common toxic and metabolic processes that affect the deep gray nuclei and white matter.

Basal Ganglia Calcification

Basal ganglia calcification is the end result of many toxic, metabolic, inflammatory, and infectious insults. Fahr disease is a rare neurodegenerative disorder that results in extensive bilateral BG calcifications. The GP is most commonly involved, followed by the putamen, caudate, and thalamus. Additionally, there may be involvement of the cerebellum, particularly the dentate nuclei and cerebral white matter.

Other endocrinologic disorders, including hypothyroidism and hypoparathyroidism, may cause calcification, particularly involving the GP, putamen, dentate nuclei, thalami, and subcortical white matter. Radiation and chemotherapy may result in mineralizing microangiopathy that commonly causes BG and subcortical white matter calcifications and atrophy. Physiologic calcification as part of the normal aging brain typically occurs in the GP more than the putamen.

T1 Hyperintense Basal Ganglia

Basal ganglia T1 hyperintensity is usually symmetric, related to calcification or other mineralization. T1 hyperintensity is often seen in the GP and substantia nigra in patients with a history of liver disease or hyperalimentation related to abnormal manganese metabolism. Kernicterus, related to toxic unconjugated bilirubin in a newborn, results in increased T1 signal in the GP, as well as the substantia nigra, hippocampus, and dentate nucleus.

Many endocrine disorders that result in BG calcification will also cause T1 hyperintensity. These include hypothyroidism, hyperparathyroidism, hypoparathyroidism, and pseudohypoparathyroidism. Fahr disease also results in T1 hyperintensity, particularly in the GP.

T2 Hyperintense Basal Ganglia

T2 hyperintensity within the BG is typically symmetric in toxic and metabolic disorders. Often DWI helps to differentiate the various lesions of the BG. CO poisoning classically causes symmetric GP hyperintensity but occasionally also involves the putamen, thalamus, and white matter. DWI may be positive acutely. Methanol toxicity typically results in putaminal necrosis and may be hemorrhagic. Drug abuse is another cause for abnormalities of the basal ganglia, often in young adults. Often, drug abuse results in strokes or vasculitis. Heroin and MDMA (ecstasy) often result in GP ischemia. Osmotic demyelination syndrome is acute demyelination caused by rapid shifts in serum osmolality, often in the setting of rapid correction of hyponatremia. Extrapontine myelinolysis commonly affects the caudate and putamen, as well as the white matter.

Wilson disease causes symmetric hyperintensity in the putamen, GP, caudate, and thalami. It also results in a face of

https://CafePezeshki.IR

the giant panda sign at the midbrain level with T2 hyperintense white matter tracts. Acute hypertensive encephalopathy (PRES) is a caused by hypertension and may be related to chemotherapy. PRES typically affects the cortex and subcortical white matter of the posterior circulation. However, involvement of the BG may occur. The main considerations besides toxic and metabolic insults that may cause T2 hyperintense BG are hypoxic-ischemic encephalopathy, deep venous occlusion, and infectious etiologies.

Globus Pallidus Lesions

Lesions that often only involve the GP include CO poisoning, cyanide poisoning, heroin and MDMA (ecstasy) abuse, kernicterus, neurodegeneration with brain iron accumulation (NBIA)-pantothenate kinase-associated neurodegeneration (PKAN), hyperalimentation, hepatic encephalopathy, and methylmalonic acidemia. NBIA is a group of progressive neurodegenerative disorders with extrapyramidal motor impairment and brain iron accumulation, resulting in GP T2 hypointensity. PKAN, also known as Hallervorden-Spatz syndrome or NBIA-1, has a classic eye of the tiger appearance with bilateral, symmetric GP T2 hyperintensity surrounded by hypointensity.

Other disorders that commonly affect the GP more prominently than the other BG nuclei include Fahr disease, hypothyroidism, and Wilson disease. As with other lesions of the BG, hypoxic-ischemic encephalopathy should also be considered.

Bilateral Thalamic Lesions

Thalamic lesions are most commonly caused by arterial or venous ischemia or hypoxic-ischemic encephalopathy. However, they are also involved in many toxic and metabolic processes. Alcoholic encephalopathy, particularly Wernicke encephalopathy, typically results in T2 hyperintense medial thalami, mammillary bodies, hypothalamus, and periaqueductal gray matter. Wernicke encephalopathy results from a vitamin B1 deficiency and is frequently associated with alcohol abuse. T1 hyperintensity in the pulvinar is a common and sensitive finding for Fabry disease and is considered by many as the T1 pulvinar sign. Fabry disease is a rare multisystem X-linked disorder that includes renal and cardiac dysfunction and strokes. Although Fahr disease most commonly causes extensive bilateral calcification of the BG, the thalami are frequently affected.

Other diseases that affect the thalami include PRES, vasculitis, osmotic demyelination, and acute disseminated encephalomyelitis. Additionally, many of the encephalitides affect the thalami, including Ebstein-Barr virus, Japanese encephalitis, and West Nile virus. Creutzfeldt-Jakob disease (CJD) often affects the basal ganglia and thalami symmetrically.

Diffuse White Matter Abnormality

Toxic and metabolic disorders often cause a confluent T2 hyperintense leukoencephalopathy. Radiation and chemotherapy classically causes a leukoencephalopathy with T2 hyperintensity throughout the cerebral white matter. Sparing of the subcortical U-fibers is typical. A diffuse necrotizing leukoencephalopathy may also result, commonly from a combination of radiation and chemotherapy, which causes white matter necrosis in addition to leukoencephalopathy. Heroin vapor inhalation, a.k.a. chasing the dragon syndrome, causes a toxic leukoencephalopathy that results in T2 hyperintense cerebellar white matter and the posterior limb of the internal capsule showing involvement of the posterior cerebral white matter, with relative sparing of the subcortical white matter.

Hypothyroidism related to Hashimoto thyroiditis may result in a diffuse confluent white matter encephalopathy that typically affects the anterior cerebral white matter. There is involvement of the subcortical U-fibers but relative sparing of the posterior hemispheres. Acute liver failure may also result in diffuse edema with T2 hyperintensity in the periventricular and subcortical white matter. Cortex involvement is typical. PRES typically involves the cortex and subcortical white matter in a posterior circulation. Alcoholic encephalopathy may rarely result in diffuse white matter T2 hyperintensity related to acute demyelination.

Selected References

1. Chokshi FH et al: Imaging of acquired metabolic and toxic disorders of the basal ganglia. Semin Ultrasound CT MR. 35(2):75-84, 2014
2. Bathla G et al: MRI and CT appearances in metabolic encephalopathies due to systemic diseases in adults. Clin Radiol. 68(6):545-54, 2013

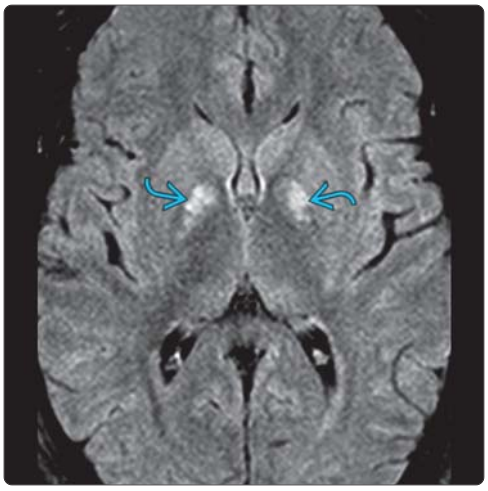

(Left) *Axial gross pathology section shows bilateral hemorrhagic necrosis in the putamen, characteristic of methanol injury to the brain. The right-sided injury extends to involve the globus pallidus and caudate head. (Courtesy R. Hewlett, MD.)* **(Right)** *Axial FLAIR MR in acute carbon monoxide (CO) poisoning with symmetric hyperintensity in the globi pallid. Carbon monoxide has a propensity to affect the globus pallidus. In CO poisoning, delayed leukoencephalopathy and T1 shortening in the globus pallidus may be encountered.*

https://CafePezeshki.IR

(Left) *Axial NECT shows extensive subcortical white matter, cerebellar, and basal ganglia calcification in this patient with a history of radiation and chemotherapy for a posterior fossa medulloblastoma. Mineralizing microangiopathy typically occurs 2 or more years after treatment.* **(Right)** *Coronal T1 C+ MR shows symmetric high signal in the globus pallidus in a patient with chronic cirrhosis. T1 hyperintense areas in globus pallidus and substantia nigra have been attributed to manganese deposition.*

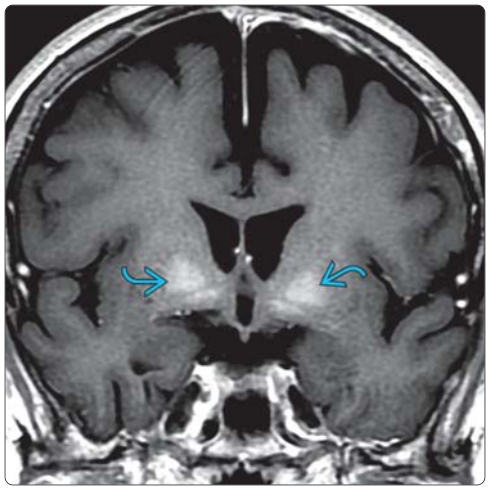

(Left) *Axial NECT shows symmetric calcifications in the caudate, putamen, and pulvinar nucleus of thalamus in a patient with Fahr disease. Numerous endocrine disorders can show similar calcifications.* **(Right)** *Axial FLAIR MR shows symmetric hyperintensity in both posteromedial thalami and in the region of the mammillary bodies related to Wernicke encephalopathy. DWI is often acutely positive. Wernicke encephalopathy is related to a thiamine deficiency and is often related to alcohol abuse.*

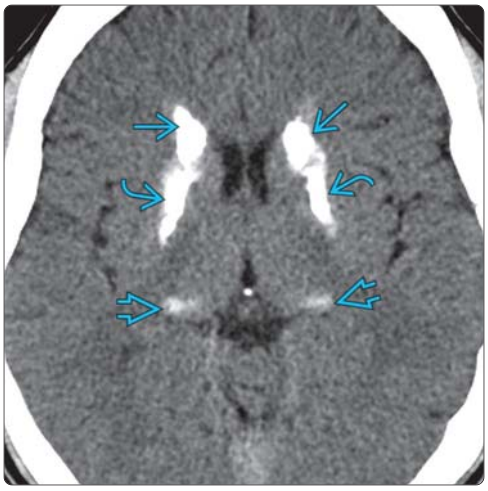

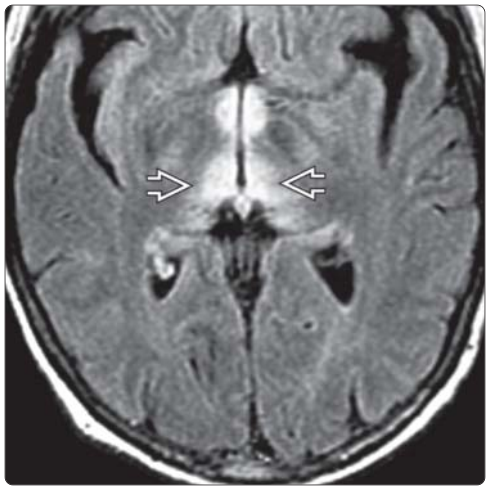

(Left) *Axial FLAIR MR shows symmetric hyperintensity in the caudate and putamen in this patient with both extrapontine and central pontine myelinolysis. Osmotic demyelination is often DWI positive and is typically related to a rapid correction of hyponatremia. Cerebral white matter demyelination may also occur.* **(Right)** *Axial gross pathology section shows bilateral necrosis of the putamen and globus pallidus with areas of cavitation related to neurotoxicity. (Courtesy R. Hewlett, MD.)*

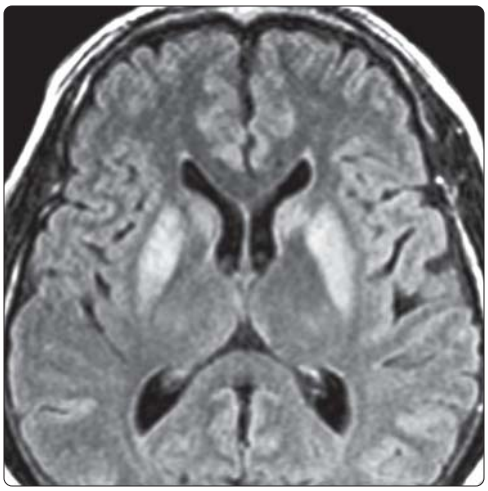

https://CafePezeshki.IR

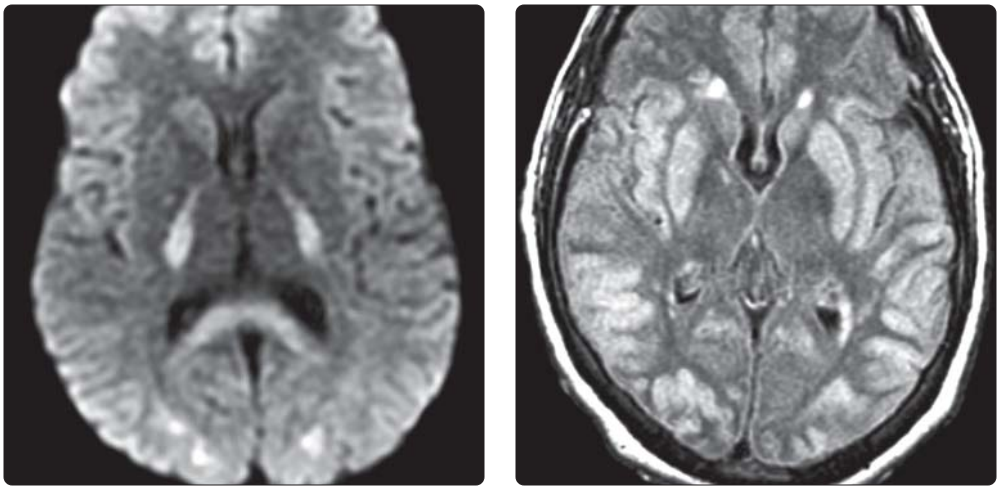

(Left) *Axial DWI MR shows hyperintensity in the internal capsule posterior limbs, corpus callosum splenium, and occipital white matter related to heroin-induced leukoencephalopathy, a.k.a. chasing the dragon syndrome.* **(Right)** *Axial FLAIR MR shows extensive, symmetric hyperintensity in the basal ganglia, cortex, and subcortical white matter related to profound hypoglycemia. Predilection for the parietal and occipital lobes is typical.*

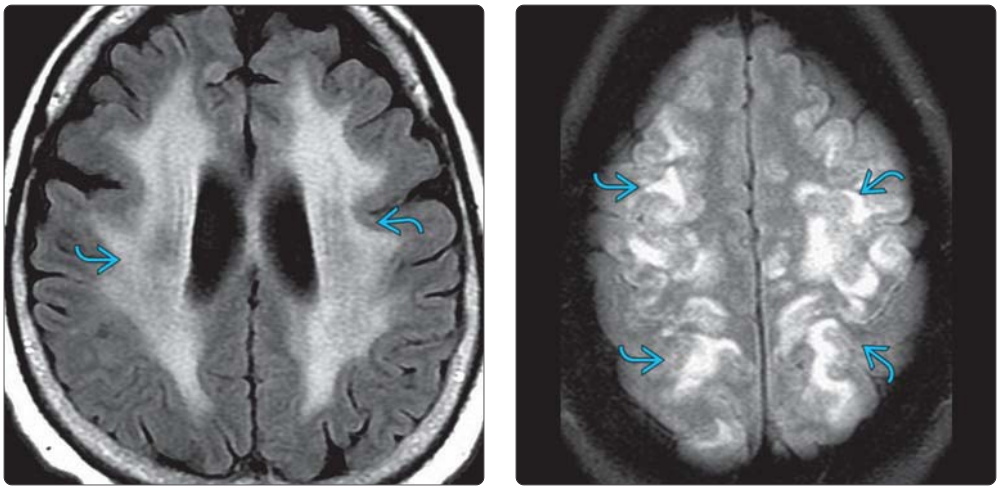

(Left) *Axial FLAIR MR in a patient with history of whole brain radiation shows extensive hyperintensity throughout the white matter* ⇨ *and sparing of the subcortical U-fibers, typical of treatment-related leukoencephalopathy. Radiation and chemotherapy cause a variety of toxic injuries to the brain, with leukoencephalopathy being the most common.* **(Right)** *Axial FLAIR MR shows bilateral cortical and subcortical hyperintensities* ⇨ *related to acute hypertensive encephalopathy or PRES.*

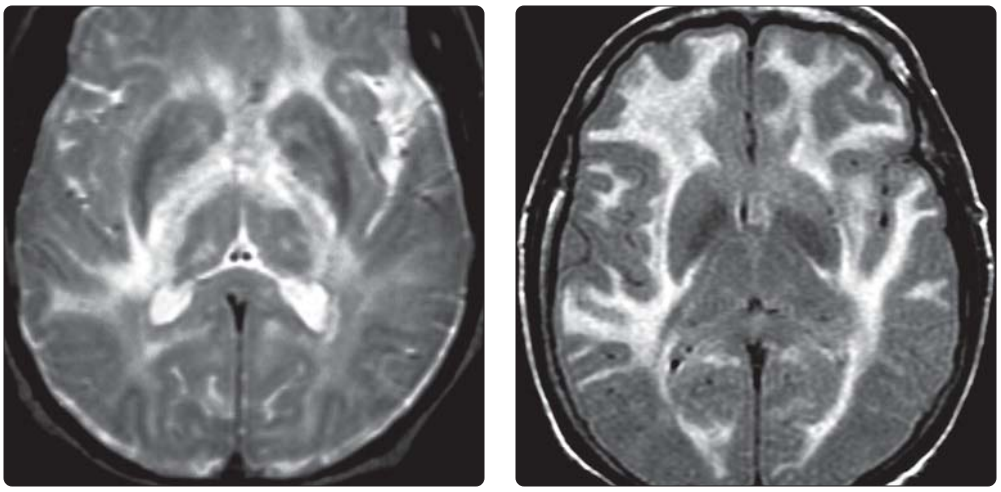

(Left) *Axial T2WI MR shows diffuse white matter hyperintensity related to severe alcohol poisoning from binge drinking and acute demyelination.* **(Right)** *Coronal FLAIR MR shows diffuse, symmetric white matter hyperintensity with involvement of the subcortical U-fibers. There is relative sparing of the occipital lobes, typical of Hashimoto encephalopathy, a rare complication of Hashimoto thyroiditis.*

https://CafePezeshki.IR

KEY FACTS

IMAGING

- Consider if bilateral occipital/parietal bright DWI signal in neonate with seizures
- Occipital > parietal > frontal, temporal lobe
- ± basal ganglia, thalamus, brainstem involvement
- White matter injury common, may be predominantly periventricular in premature
- Increased DWI signal corresponds to normal to low ADC acutely, DWI normalizes after 1st week
- Normal to low NAA, ± lactate

TOP DIFFERENTIAL DIAGNOSES

- Term hypoxic-ischemic injury
- Preterm hypoxic-ischemic injury
- MELAS
- Venous Infarct
- Acute Hypertensive Encephalopathy (PRES)

PATHOLOGY

- Upper cortical layers involved, not intermediate and deep layers as in hypoxic-ischemic injury
- No selective involvement of watershed areas

CLINICAL ISSUES

- Stupor, jitteriness, seizures, apnea, irritability, hypotonia
- Usually presents within first 3 days of life
- Threshold for injury unknown but likely a factor of severity and duration as well as associated insults
- M > F
- Prognosis depends on prompt recognition & treatment of hypoglycemia
- Long-term prognosis correlated with WM damage on MR

DIAGNOSTIC CHECKLIST

- Do not equate DWI abnormalities with infarcts (pan necrosis) as acute DWI abnormalities may result in only mild volume loss, especially if ADC not decreased

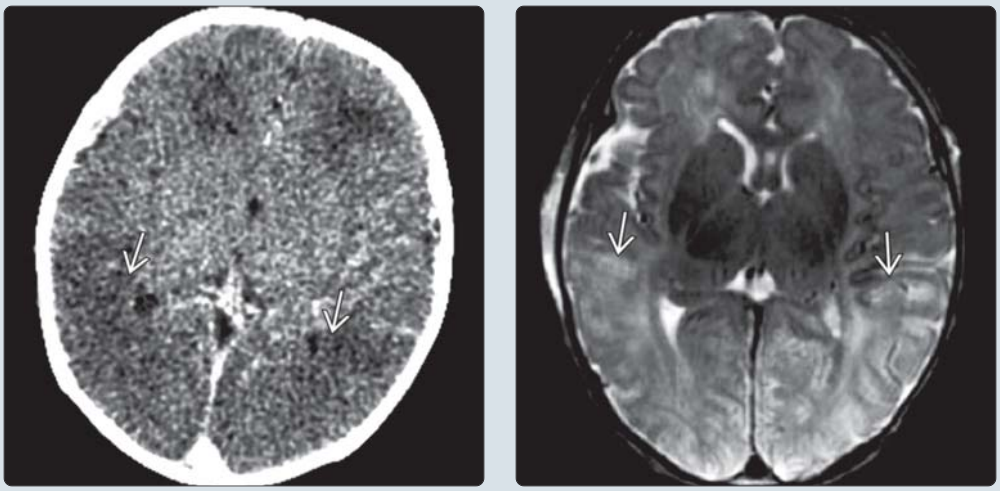

(Left) *Axial CECT in a 3 day old with severe hypoglycemia shows decreased attenuation in the posterior cerebrum involving the occipital, parietal (not shown), and posterior temporal lobes bilaterally with loss of gray-white differentiation.* **(Right)** *Axial T2WI MR in the same patient 1 day later shows posterior T2 cortical and subcortical hyperintensity involving occipital, parietal (not shown), and posterior temporal lobes bilaterally. Note the loss of gray-white differentiation.*

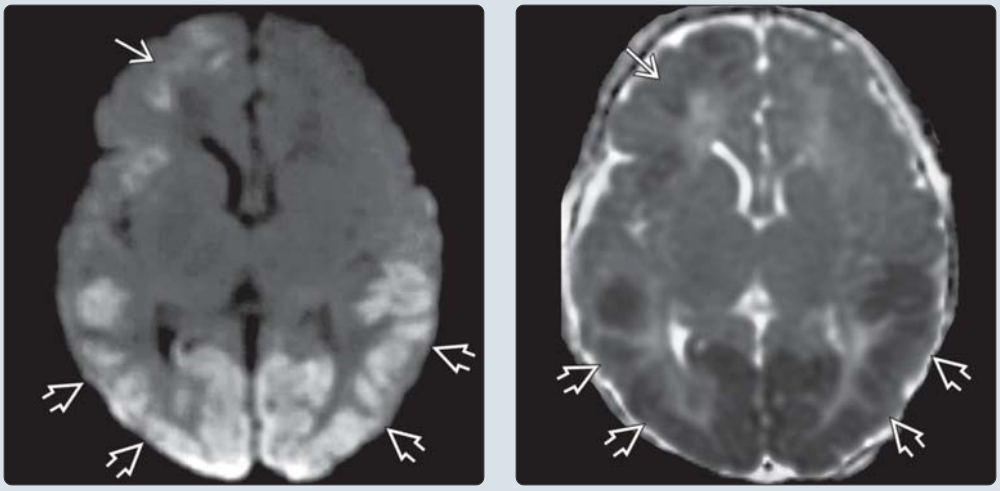

(Left) *Axial DWI MR in the same patient shows increased signal in the occipital, parietal (not shown), and posterior temporal lobe bilaterally, with less severe right frontal lobe and insular cortex involvement.* **(Right)** *Axial ADC in the same patient shows markedly decreased signal intensity in the posterior regions of the cerebral hemispheres. The right frontal lobe is actually reduced diffusivity and not a result of T2 effects "shining through."*

https://CafePezeshki.IR

TERMINOLOGY

Definitions

- Significant hypoglycemia
  - Plasma glucose level < 30-35 mg/dL in the first 24 hours of life
  - < 40- 45 mg/dL (after 24 hours)

IMAGING

General Features

- Best diagnostic clue
  - Bilateral occipital/parietal bright DWI in neonate with seizures
- Location
  - Occipital > parietal > frontal, temporal lobes
  - ± basal ganglia, thalamus, brainstem involvement
  - White matter injury common; may be predominantly periventricular in premature
  - Hypoglycemia that is less severe can accentuate watershed zone injuries in neonate hypoxic-ischemic injury

CT Findings

- NECT
  - Decreased attenuation with loss of gray-white differentiation in acute and subacute phase
  - Cortical Ca++ in chronic phase

MR Findings

- T1WI
  - Cortical ± deep gray hyperintensity in subacute phase
  - ± foci of increased T1 signal in white matter
- T2WI
  - Increased signal in gray and white matter with loss of gray-white distinction in acute phase
  - Increased signal in gray and white matter with variable cortical low signal in subacute phase
  - Volume loss ± gliosis that may be subtle to cystic encephalomalacia in chronic phase
- DWI
  - Increased DWI signal corresponds to low ADC acutely
  - DWI normalizes after 1st week
  - DWI most sensitive to identify parietal-occipital injury
- MRS
  - Normal to low NAA
  - ± lactate

Ultrasonographic Findings

- Grayscale ultrasound
  - Increased echogenicity

Imaging Recommendations

- Best imaging tool
  - MR with DWI
- Protocol advice
  - Higher b values (b = 1,000-1,500 s/mm²) make areas of decreased diffusion more conspicuous

DIFFERENTIAL DIAGNOSIS

Term Hypoxic-Ischemic Injury

- Hypoglycemia and hypoxic-ischemic injury (HII) often coexist & potentiates extent of brain injury
- HII causes hypoglycemia
- DWI in partial HII with hypoglycemia may be indistinguishable from posterior predominant normoglycemic partial HII

Preterm Hypoxic-Ischemic Injury

- Hypoglycemia potentiates periventricular leukomalacia

MELAS

- MELAS- mitochondrial encephalopathy with lactic acidosis & stroke-like episodes
- Consider if marked elevation in lactate or if no history of hypoglycemia

Status Epilepticus

- Seizures are typical response of newborn brain to injury
  - DWI abnormalities in newborns more likely to be cause (not consequence) of seizures
- Vicious cycle may develop where cerebral injury is exacerbated by seizures

Venous Infarct

- Often associated hemorrhage and edema; MRV to rule out

Acute Hypertensive Encephalopathy (PRES)

- Cortical & subcortical T2/FLAIR hyperintensity with predominant posterior distribution
- Predominantly increased ADC, older patients

PATHOLOGY

General Features

- Etiology
  - Inadequate energy substrate (oxygen, glucose, lactate) availability/reserve: IUGR, preeclampsia, maternal hypoglycemia, prolonged fasting, prematurity
  - ↑ glucose utilization: Hypoxia, stress
  - Hyperinsulinemia
    - Uncontrolled maternal diabetes
    - Hyperinsulinemic hypoglycemia, familial, 1 or 2 (HHF1 or HHF2)
  - Beckwith-Wiedemann syndrome (BWS)
    - Inherited disorder with macrosomia, macroglossia, visceromegaly, omphalocele, embryonal tumors, & renal abnormalities
    - BWS- associated hypoglycemia are mild & transient
  - Other endocrine abnormalities: Panhypopituitarism, hypothyroidism, adrenal insufficiency
  - Other: Polycythemia, congenital heart disease
  - Excitatory amino acids (glutamate) and oxidative stress are thought to play central role in neuronal death
- Glucose metabolism
  - Glucose primary metabolic fuel for brain
  - Brain is major determinant of hepatic glucose production
  - Neonates have disproportionally high glucose production relative to body size due to disproportionately large neonatal brain

https://CafePezeshki.IR

- Immature brain more resilient to hypoglycemia than adult
  - Lower absolute demand
  - Increased ability to increase cerebral blood flow
  - Utilization of other substrates (i.e., lactate)
  - Resistance of neonatal heart to hypoglycemia
- Hypoglycemia potentiates hypoxic-induced damage

Staging, Grading, & Classification

- Clinical categories
  - Transitional adaptive hypoglycemia
    - Very early onset; mild, brief hypoglycemia
    - Responds rapidly to treatment
    - Diabetic mothers, erythroblastosis, difficulty transitioning to extrauterine life
  - Secondary associated hypoglycemia
    - Early 1st day; mild, short-duration hypoglycemia
    - Responds rapidly to treatment
    - Associated CNS disorder (HII, intracranial hemorrhage, sepsis)
  - Classic transient hypoglycemia
    - End of 1st day; moderate to severe, often prolonged hypoglycemia
    - Requires large amounts of glucose
    - IUGR, ↓ substrate/impaired gluconeogenesis
  - Severe recurrent hypoglycemia
    - Variable onset; severe, prolonged hypoglycemia
    - May persist despite treatment
    - Most have primary disorder of glucose metabolism
      - e.g., BWS, HHF1 or HHF2/persistent hyperinsulinemia hypoglycemia of infancy (PHHI)/nesidioblastosis, β-cell hyperplasia, endocrine deficiencies, inborn errors in metabolism

Gross Pathologic & Surgical Features

- Pale, edematous brain; blurred gray-white junction

Microscopic Features

- Widespread injury to cerebral cortex, hippocampus, basal ganglia, thalamus, brainstem, spinal cord
- Upper cortical layers involved, not intermediate and deep layers as in hypoxic-ischemic injury
- No selective involvement of watershed areas
- Severe degeneration of glial cells
- Periventricular white matter injury may be prominent

CLINICAL ISSUES

Presentation

- Most common signs/symptoms
  - Stupor, jitteriness, seizures, apnea, irritability, hypotonia
  - May have no symptoms
  - When associated with neonatal HIE, may present with neonatal encephalopathy
- Clinical profile
  - Small or large neonates

Demographics

- Age
  - Usually presents within first 3 days of life
- Gender
  - M > F

Natural History & Prognosis

- Cerebral glucose metabolism probably flow limited, so dependent on CBF
- Threshold for injury unknown but likely a factor of severity and duration as well as associated insults
- < 45 mg/dL may have deleterious long-term effects even if no neonatal signs
- Epilepsy (may have intractable seizures), developmental delay, motor delay, learning and behavior problems, hyperactivity and attention difficulties, autistic features, microcephaly, cortical blindness
- DWI abnormalities associated with later deficits (occipital lobe low ADC associated with later cortical visual loss)
- Regions of bright DWI and minimal ADC decrease may have minimal to no volume loss on follow-up
- Prognosis depends on prompt recognition & treatment of hypoglycemia
- Long-term prognosis correlated with WM damage on MR

Treatment

- Glucose level to treat controversial; consider if 40-45 mg/dL
- Glucose infusion to restore normal glucose levels, often even if asymptomatic
- Frequent feeds, increased caloric density, continuous NG feeds ± cornstarch, continuous IV dextrose, hydrocortisone, diazoxide, octreotide, glucagon, Ca++ channel blocker, partial pancreatectomy

Prevention

- Control maternal diabetes, preeclampsia/eclampsia, nutrition, prevention/rapid treatment of perinatal asphyxia
- Identify high-risk infant, temperature control, oral feeds in 1st hours of life, glucose test when indicated

DIAGNOSTIC CHECKLIST

Reporting Tips

- Do not equate DWI abnormalities with infarcts (pan necrosis), as acute DWI abnormalities may result in only mild volume loss, especially if ADC not decreased

SELECTED REFERENCES

1. Bathla G et al: Neuroimaging in patients with abnormal blood glucose levels. AJNR Am J Neuroradiol. 35(5):833-40, 2014
2. Yoon HJ et al: Devastating metabolic brain disorders of newborns and young infants. Radiographics. 34(5):1257-72, 2014
3. Boardman JP et al: Hypoglycaemia and neonatal brain injury. Arch Dis Child Educ Pract Ed. 98(1):2-6, 2013
4. Wong DS et al: Brain injury patterns in hypoglycemia in neonatal encephalopathy. AJNR Am J Neuroradiol. 34(7):1456-61, 2013
5. Tam EW et al: Hypoglycemia is associated with increased risk for brain injury and adverse neurodevelopmental outcome in neonates at risk for encephalopathy. J Pediatr. 161(1):88-93, 2012
6. Sinclair JC et al: Interventions for prevention of neonatal hyperglycemia in very low birth weight infants. Cochrane Database Syst Rev. (10):CD007615, 2011
7. Musson RE et al: Diffusion-weighted imaging and magnetic resonance spectroscopy findings in a case of neonatal hypoglycaemia. Dev Med Child Neurol. 51(8):653-4, 2009
8. Burns CM et al: Patterns of cerebral injury and neurodevelopmental outcomes after symptomatic neonatal hypoglycemia. Pediatrics. 122(1):65-74, 2008
9. Kim SY et al: Neonatal hypoglycaemic encephalopathy: diffusion-weighted imaging and proton MR spectroscopy. Pediatr Radiol. 36(2):144-8, 2006
10. Barkovich AJ et al: Imaging patterns of neonatal hypoglycemia. AJNR Am J Neuroradiol. 19(3):523-8, 1998

https://CafePezeshki.IR

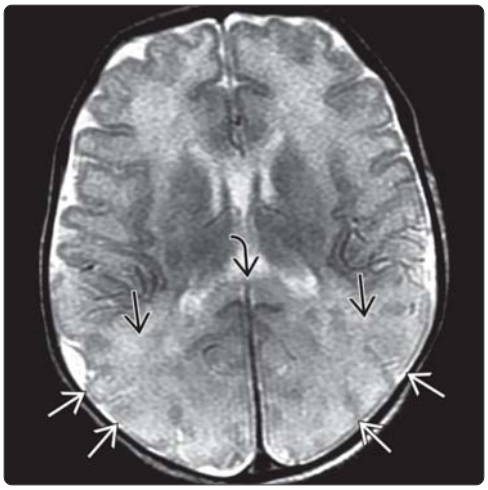

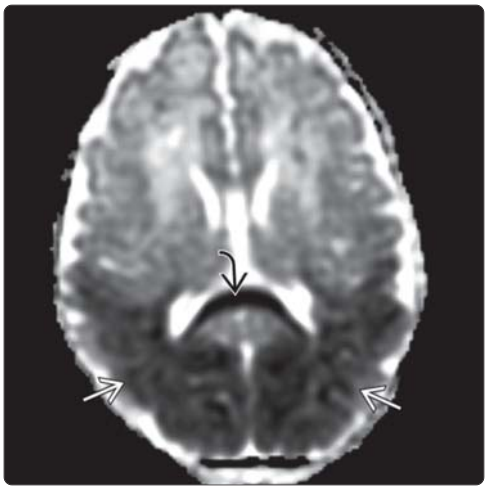

(Left) *Axial T2WI MR in a 5-day-old hypoglycemic infant shows increased signal in the parietal cortex ➡ and underlying parietal white matter ⇨ with loss of gray-white distinction. Note the extension of hyperintensity ⇨, probably representing interstitial edema, into the splenium of the corpus callosum.* **(Right)** *Axial ADC in the same infant shows reduced diffusivity in the parietal cortex and white matter ➡, as well as in the posterior corpus callosum ⇨.*

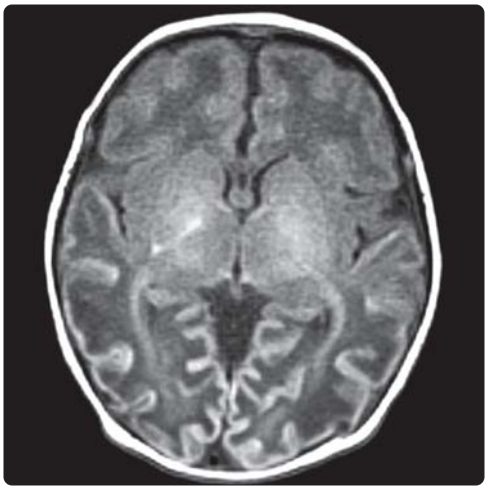

(Left) *Axial T2WI MR in the same patient at 7 days shows the evolution of hypoglycemic injury, with increased signal in the posterior white matter, including posterior limb of the internal capsules and pulvinar thalamus ⇨. The overlying cortex shows patchy increased and decreased signal.* **(Right)** *Axial T1WI MR at 7 days shows evolving injury: Decreased signal in the posterior white matter and pulvinar thalamus, increased signal in the overlying cortex and posterior limb internal capsule.*

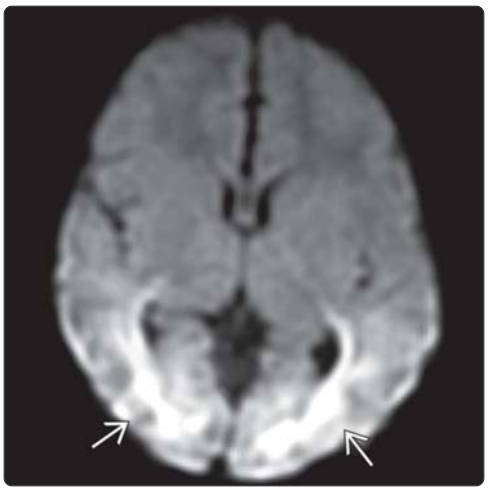

(Left) *Axial DWI MR at 7 days in the same patient with hypoglycemic injury shows increased signal ➡ in the posterior white matter and overlying cortex. At this stage, diffusivity is pseudonormalizing, so the increased signal is likely a result of T2 shine through.* **(Right)** *Axial T2WI MR in the same patient at 1 year of age shows chronic injury with marked volume loss and gliosis involving the cortex and white matter of the posterior temporal lobes, parietal lobes (not shown), and occipital lobes.*

https://CafePezeshki.IR

KEY FACTS

TERMINOLOGY

- Adult hypoglycemic encephalopathy (AHE)
- Imbalance between glucose supply, utilization → brain injury
- Hypoglycemia: Sudden decrease in serum glucose level < 50 mg/dL

IMAGING

- Stroke/coma in adult diabetic on insulin replacement therapy (IRT)
- Parietal/temporal/occipital lobes, basal ganglia, ± hippocampi
- Hyperintensity in parietooccipital cortex and basal ganglia
- Thalami, subcortical/deep white matter and cerebellum generally spared
- Restricted diffusion, ↓ ADC (may be transient)
- ↓ NAA, ↑ lactate

TOP DIFFERENTIAL DIAGNOSES

- Acute cerebral ischemia/infarction
- Hypoxia, hypoperfusion
- Acute hypertensive encephalopathy (PRES)

PATHOLOGY

- Caused by IRT either without adequate glucose intake or excessive glucose utilization
- Ingestion of oral hypoglycemic medication, either accidental or intentional
- Accumulation/release of excitatory neurotransmitters increases glucose utilization
- Patchy or diffuse laminar necrosis
  - Varying severity, WM generally spared

CLINICAL ISSUES

- Often elderly diabetic, altered dietary glucose intake
- Coma, depressed level of consciousness
- May be preceded by seizures

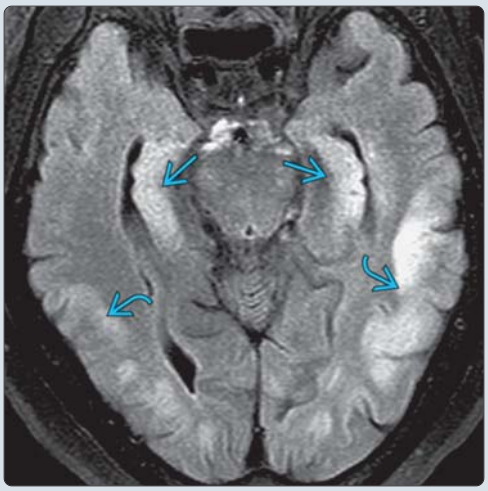

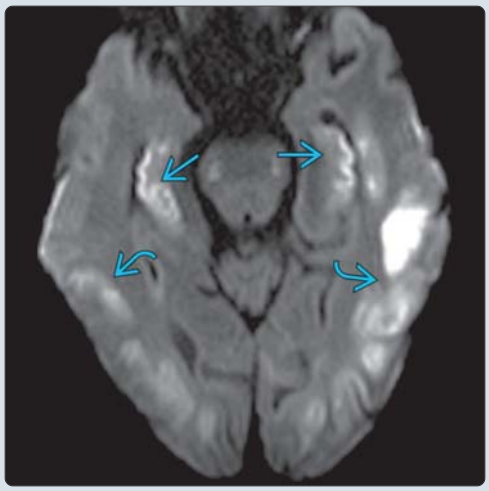

(Left) *Axial FLAIR MR in a diabetic patient with altered sensorium and a blood glucose of 36 mg/DL shows symmetric hyperintensity involving the hippocampus, temporal and occipital cortex bilaterally.* **(Right)** *Axial DWI image in the same patient shows corresponding areas of restricted diffusion in the hippocampus, temporal and occipital cortex. Prognosis in adult hypoglycemic encephalopathy varies with severity and duration of hypoglycemia, as well as extent of brain injury.*

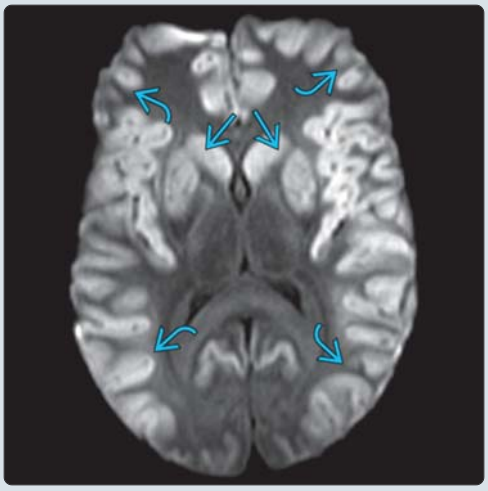

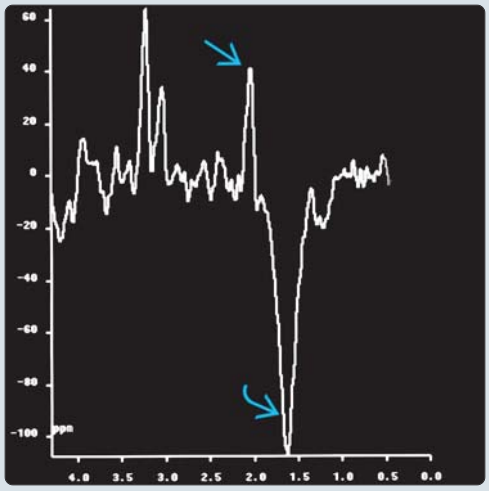

(Left) *Axial DWI images in patient with overdose of glipizide (sulfonylureas class of oral diabetes medicine) and blood glucose level of 20 mg/DL shows severe changes of hypoglycemic encephalopathy. There is extensive symmetric diffusion restriction in the basal ganglia and cerebral cortex.* **(Right)** *Intermediate TE MR spectroscopy in the a patient with hypoglycemia shows a relatively low NAA peak, as well as a prominent lactate peak.*

https://CafePezeshki.IR

TERMINOLOGY

Abbreviations

- Adult hypoglycemic encephalopathy (AHE)

Synonyms

- Hypoglycemic brain injury
- Diabetic coma (nonspecific; term may include AHE)

Definitions

- Imbalance between glucose supply, utilization → brain injury
- Hypoglycemia: Sudden decrease in serum glucose level < 50 mg/dL

IMAGING

General Features

- Best diagnostic clue
  - Stroke/coma in adult diabetic on insulin replacement therapy (IRT)
- Location
  - Parietal/temporal/occipital lobes, basal ganglia, ± hippocampi
  - Thalami usually spared

CT Findings

- NECT
  - Hypodense parietal, occipital lobes
    - Superimposed on diffuse edema

MR Findings

- T1WI
  - Early: Gyral swelling, sulcal effacement
  - Subacute and chronic: Curvilinear gyral hyperintensity (laminar necrosis)
- T2WI
  - Hyperintensity in parietooccipital cortex and basal ganglia
  - Thalami, subcortical/deep white matter and cerebellum generally spared
- DWI
  - Restricted diffusion, ↓ ADC (may be transient)
- MRS
  - ↓ NAA, ↑ lactate

Imaging Recommendations

- Best imaging tool
  - MR + DWI

DIFFERENTIAL DIAGNOSIS

Acute Cerebral Ischemia/Infarction

- Wedge-shaped, vascular distribution (MCA > PCA)
- Both cortex and underlying WM involved
- Patchy focal hemorrhage common
  - Uncommon in AHE

Hypoxia, Hypoperfusion

- Post cardiac arrest, global hypoperfusion
- Bilateral symmetric thalamic injury
  - Uncommon in AHE

Acute Hypertensive Encephalopathy (PRES)

- Uncontrolled HTN or immunosuppressive medication
- Usually no restriction on DWI

PATHOLOGY

General Features

- Etiology
  - Cellular glucose needs, supply imbalance
    - IRT without adequate dietary intake
    - Accidental/intentional ingestion of oral hypoglycemic agents
    - β-cell hypertrophy (nesidioblastosis)
      - Post gastric bypass similar to persistent hyperinsulinemic hypoglycemia of infancy (PHHI)
      - May require subtotal pancreatectomy
  - Glucose insufficiency-impaired oxygen utilization
    - Accumulation/release of excitatory neurotransmitters

Gross Pathologic & Surgical Features

- Pale/edematous brain, blurred GM-WM boundary
- Cortical ± basal ganglia injury

Microscopic Features

- Variable patchy/diffuse laminar necrosis
- WM generally spared

CLINICAL ISSUES

Presentation

- Most common signs/symptoms
  - Coma, depressed level of consciousness
  - May be preceded by seizures
- Clinical profile
  - Elderly diabetic with altered dietary intake
    - Due to deprivation or other factors (e.g., EtOH)

Natural History & Prognosis

- Prognosis varies with severity and duration of hypoglycemia as well as extent of brain injury
- Correlates with basal ganglia (BG) injury
  - If BG significantly involved, meaningful neurologic recovery diminished
  - If no/minimal BG injury, residual deficits are determined by extent and severity of cortical injury

Treatment

- Intravenous glucose, monitoring, supportive care

DIAGNOSTIC CHECKLIST

Image Interpretation Pearls

- WM sparing, lack of hemorrhage help differentiate from hypoxic-ischemic injury
- Bilateral thalamic injury more typical of hypoperfusion/hypoxia

SELECTED REFERENCES

1. Bathla G et al: MRI and CT appearances in metabolic encephalopathies due to systemic diseases in adults. Clin Radiol. 68(6):545-54, 2013
2. Cheah YS et al: Metabolic neuroimaging of the brain in diabetes mellitus and hypoglycaemia. Nat Rev Endocrinol. 8(10):588-97, 2012

https://CafePezeshki.IR

KEY FACTS

TERMINOLOGY

- Kernicterus or bilirubin encephalopathy: Pathological bilirubin staining of basal ganglia, brainstem, and hippocampi associated with hyperbilirubinemia

IMAGING

- Acute: ↑ T1 signal in globus pallidus (GP), subthalamic nuclei (STN), hippocampi, substantia nigra (SN)
- Chronic: ↑ T2 signal in GP, hippocampi
- MRS: ↑ Tau/Cr, ↑ Glx/Cr, ↑ mI/Cr, ↓ Cho/Cr

TOP DIFFERENTIAL DIAGNOSES

- Hyperalimentation, liver failure: ↑ T1 signal GP, SN
- Toxic: CO poisoning
- Metabolic: Methylmalonic acidemia, creatine deficiency, succinic semialdehyde dehydrogenase deficiency, L2-hydroxyglutaric aciduria
- Term hypoxic-ischemic injury

PATHOLOGY

- Encephalopathy due to ↑ unconjugated bilirubin crossing immature blood-brain barrier (BBB)
- Neurons > glia, neuropil spongiosis
- Yellow staining > MR abnormality

CLINICAL ISSUES

- Stupor, hypotonia, poor suckling, high-pitched cry
- Incidence ↑ with early discharge, ↑ breastfeeding
- Specific damage to brainstem auditory nuclei, ± deafness or abnormal auditory processing (most common)
- Athetosis, gaze abnormal in most; intellectual deficits in few

DIAGNOSTIC CHECKLIST

- Normal MR does not rule out long-term sequelae
- ↑ T1 signal in GP can be normal in neonates; look for other areas of involvement
- Findings may resolve with therapy

(Left) *Axial T1 MR in a neonate with hyperbilirubinemia, stupor, hypotonia, and increased irritability shows increased signal with the globi pallidi and hippocampal tails.* **(Right)** *Axial T1 MR in the same neonate shows abnormally increased signal within the substantia nigra and hippocampus bilaterally. The cerebral cortex and the underlying white matter have a normal appearance.*

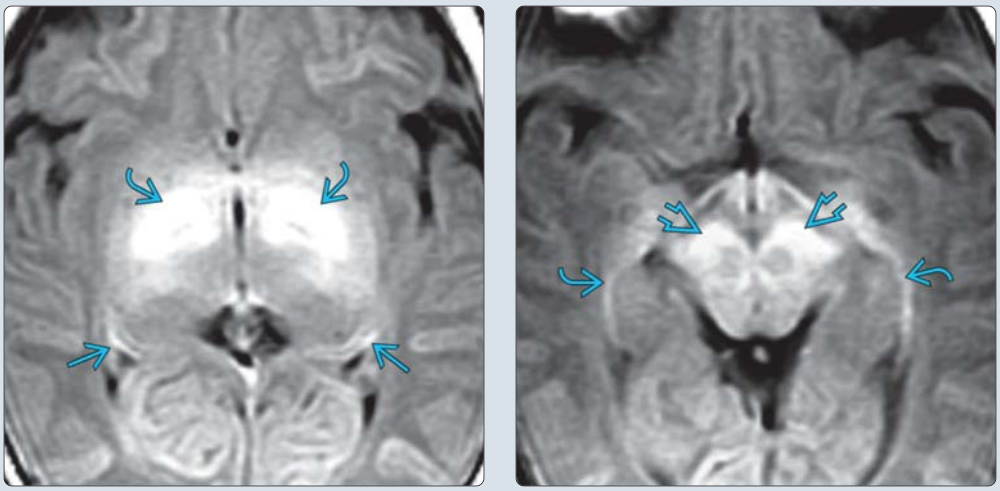

(Left) *Axial T2WI MR of the same infant at the age of 6 months shows high T2 signal intensity and volume loss in globus pallidus bilaterally. The volume of the cerebral white matter is somewhat diminished.* **(Right)** *Coronal T2WI MR in a young child who had severe neonatal hyperbilirubinemia shows increased T2 signal and volume loss in the bilateral globi pallidi, as well as in the hippocampal heads bilaterally.*

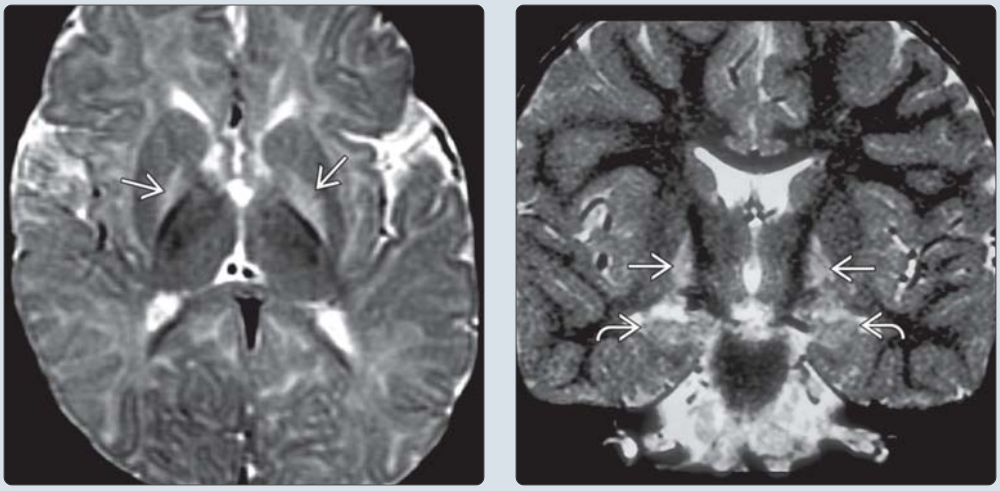

https://CafePezeshki.IR

TERMINOLOGY

Synonyms

- Bilirubin (BR) or posticteric encephalopathy

Definitions

- Kernicterus or bilirubin encephalopathy: Pathological bilirubin staining of basal ganglia, brainstem, and hippocampi associated with hyperbilirubinemia

IMAGING

General Features

- Best diagnostic clue
  - Acute: ↑ T1 signal in globus pallidus (GP), subthalamic nuclei (STN), hippocampi, substantia nigra (SN)
  - Chronic: ↑ T2 signal in GP, hippocampi

MR Findings

- T1WI
  - Acute: ↑ T1 signal in GP > STN > hippocampi > SN
    - Deposition of unconjugated BR (UBR) or ↑ manganese (Mn)
- T2WI
  - Subacute & chronic: ↑ T2 signal/volume loss in GP, hippocampi, ± SN
- MRS
  - ↑ Tau/Cr, Glx/Cr, mI/Cr, ↓ NAA/Cho,NAA/Cr, Cho/Cr

Imaging Recommendations

- Best imaging tool
  - MR

DIFFERENTIAL DIAGNOSIS

T1 Hyperintense Globus Pallidus

- Hyperalimentation, liver failure, asphyxia, neurofibromatosis

T2 Hyperintense Globus Pallidus

- Toxic: CO poisoning
- Metabolic: Methylmalonic acidemia, creatine deficiency, succinic semialdehyde dehydrogenase deficiency, L2-hydroxyglutaric aciduria
- Normotensive hypoxia

Term Hypoxic-Ischemic Injury

- Acute: ↑ T2 signal; subacute/chronic: ↑ T1 signal in ventrolateral thalamus, corticospinal tract

PATHOLOGY

General Features

- Etiology
  - Encephalopathy due to ↑ UBR crossing immature blood-brain barrier (BBB)
  - Risk factors for ↑ BR
    - Hemolytic disorders (especially erythroblastosis fetalis), breastfeeding, > 10% loss of birth weight, polycythemia, dehydration
  - Risk factors for ↑ susceptibility to brain damage at ~ normal BR levels
    - Drugs compete for albumin binding of bilirubin
    - Sulphonamides, ceftriaxone, salicylates, Na benzoate, hormones
    - Renal hypoalbuminemia, hepatic failure, ↓ thyroidism
    - Prematurity, asphyxia, sepsis
    - ↑ cerebral blood flow; abnormal BBB
- Genetics
  - Some 2q37 (Crigler-Najjar syndrome, etc.)

Gross Pathologic & Surgical Features

- Yellow staining > MR abnormality
  - GP, SN, STN, hippocampi > thalamus, striatum, cranial nerve nuclei (3, 8), dentate nuclei, reticular formation, spinal cord
  - Also Purkinje cells (premature infants)

Microscopic Features

- Neurons > glia, neuropil spongiosis

CLINICAL ISSUES

Presentation

- Most common signs/symptoms
  - Stupor, hypotonia, poor suckling, high-pitched cry
  - Over days, may develop stupor, irritability, ↑ tone
  - May have no or equivocal neurological signs

Demographics

- Age
  - Preterm > term; 1st days of life
- Gender
  - M > F
- Ethnicity
  - More prevalent in Asians, Hispanics
- Epidemiology
  - Incidence ↑ with early discharge, ↑ breastfeeding

Natural History & Prognosis

- Specific damage to brainstem auditory nuclei → ± deafness or abnormal auditory processing (common)
- Athetosis, gaze abnormality; intellectual deficits in few

Treatment

- Maternal screen, anti-Rh; fetal blood transfusion
- Hydration, phototherapy for moderate + exchange transfusion for severe
- Other, e.g., heme oxygenase inhibitors

DIAGNOSTIC CHECKLIST

Consider

- Normal MR does not rule out long-term sequelae

Image Interpretation Pearls

- ↑ T1 signal in GP can be normal in neonates; look for other areas; findings may resolve with therapy

SELECTED REFERENCES

1. Sarı S et al: Brain magnetic resonance imaging and magnetic resonance spectroscopy findings of children with kernicterus. Pol J Radiol. 80:72-80, 2015
2. Watchko JF et al: Bilirubin-induced neurologic damage. N Engl J Med. 370(10):979, 2014
3. Wisnowski JL et al: Magnetic resonance imaging of bilirubin encephalopathy: current limitations and future promise. Semin Perinatol. 38(7):422-8, 2014

https://CafePezeshki.IR

KEY FACTS

TERMINOLOGY

- Hashimoto encephalopathy (HE)
- HE synonym: Steroid-responsive encephalopathy associated with autoimmune thyroiditis (SREAT)

IMAGING

- Pituitary hyperplasia (PH): Symmetrical pituitary enlargement that is reversible with thyroid hormone replacement therapy (THRT)
- Basal ganglia variably hyperintense (Ca++)
- HE: Bilateral patchy or confluent subcortical and periventricular white matter (WM) T2 hyperintensity with relative sparing of occipital lobes, bilateral and symmetric or unilateral mesial temporal lobe edema

TOP DIFFERENTIAL DIAGNOSES

- Pituitary macroadenoma
- Physiologic pituitary hyperplasia
- Confluent white matter lesions

PATHOLOGY

- Diffuse hyperplasia of anterior pituitary responds to treatment
- **HE**
  - High titers of antithyroglobulin or anti-TPO (antimicrosomal) antibodies
  - Various studies reported no evidence of pathogenic role of antibodies in HE

CLINICAL ISSUES

- Hypothyroidism: Poor memory, psychomotor slowing, depression, reversible dementia
- In congenital hypothyroidism, thyroid hormone replacement ASAP (< 13 days)
- HE: 2 types of initial clinical presentation, acute stroke-like (vasculitic type) episode and gradual cognitive impairment
  - Confusion, focal/generalized seizure, focal neurological deficit, cognitive decline, dementia

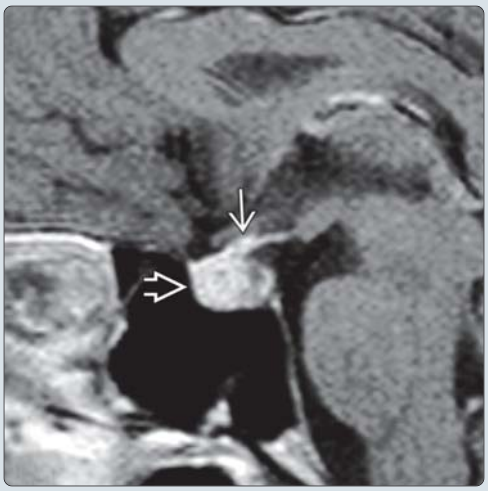

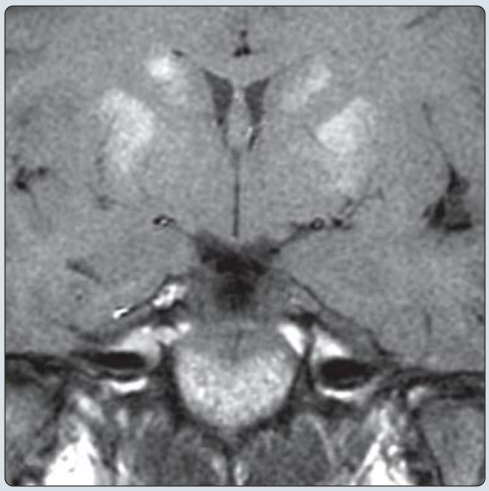

(Left) *Sagittal T1WI C+ MR shows an enlarged homogeneously enhancing pituitary gland* ⇨ *with infundibular thickening* ⇨ *related to hypothyroid-induced pituitary hyperplasia. The hyperplasia resolves with thyroid replacement therapy.* **(Right)** *Axial T1WI MR shows a focal T1 hyperintensity related to hypothyroidism, involving the caudate heads and globus pallidus bilaterally. These changes are related to mineralization of the basal ganglia, which are hyperdense on CT.*

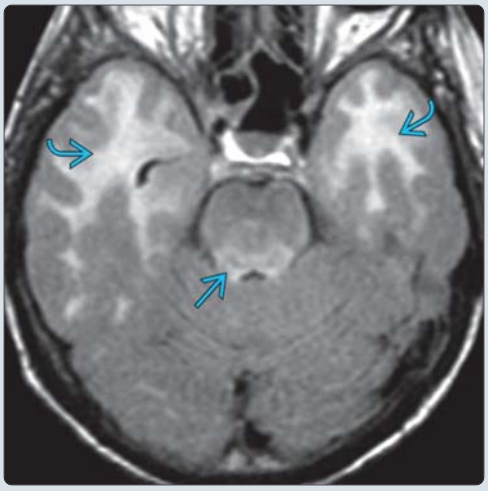

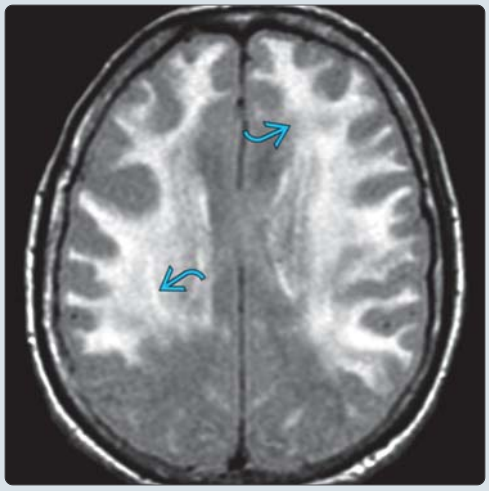

(Left) *Axial FLAIR MR shows extensive hyperintensity throughout the anterior temporal white matter* ⇨ *and dorsal pons* ⇨ *related to leukoencephalopathy in a patient with Hashimoto encephalopathy.* **(Right)** *Axial FLAIR MR in the same patient shows extensive involvement of the white matter* ⇨ *with relative sparing of the posterior cerebral hemispheres. Involvement of the subcortical U-fibers is typical of Hashimoto encephalopathy.*

https://CafePezeshki.IR

TERMINOLOGY

Abbreviations

- Hashimoto encephalopathy (HE)
- Pituitary hyperplasia (PH)

Synonyms

- HE: Steroid-responsive encephalopathy associated with autoimmune thyroiditis (SREAT)

Definitions

- Thyroid hormone deficiency affecting multiorgan systems

IMAGING

General Features

- Best diagnostic clue
  - PH: Symmetrical pituitary enlargement that is reversible with thyroid hormone replacement therapy (THRT)
  - HE: Bilateral patchy or confluent subcortical and periventricular white matter (WM) T2 hyperintensity with relative sparing of occipital lobes, bilateral and symmetric or unilateral mesial temporal lobe edema
- Location
  - PH: Pituitary enlarged, variable suprasellar extension/mass effect
  - HE: Subcortical and periventricular WM, mesial temporal lobe
- Size
  - Correlates with circulating thyrotropin levels, ↑ with hyperthyroid and ↓ with hypothyroid

CT Findings

- NECT
  - Sellar mass ± suprasellar extension
  - Basal ganglia (BG), variable cerebellar Ca++
  - HE: Subcortical and periventricular WM hypodensities
- CECT
  - Enhancing intra-/suprasellar mass

MR Findings

- T1WI
  - Enlarged pituitary isointense to cerebral WM
  - With THRT: Brain size ↑, ventricular size ↓
  - BG variably hyperintense (Ca++)
  - In endemic neurological cretinism
    - Bilateral globi pallidi, substantia nigra hyperintensity
    - Mild generalized atrophy
    - Enlargement of sylvian fissures
- T2WI
  - Pituitary hyperplasia
    - Homogeneous diffuse enlargement of pituitary gland, ± suprasellar extension, ± partial or complete obliteration of infundibulum, ± compression of optic chiasm
    - Enlarged pituitary gland is isointense to cerebral WM
  - Hashimoto encephalopathy
    - Diffuse/focal subcortical and periventricular WM T2 hyperintensity with relative sparing of occipital lobes
    - Bilateral or unilateral mesial temporal lobe edema
  - In patients with HT-associated ataxia
    - Cerebellar vermis or olivopontocerebellar atrophy
  - In endemic neurological cretinism
    - Hypointensity in area of globus pallidus and substantia nigra bilaterally
    - Mild generalized atrophy and enlarged sylvian fissures with hypothyroidism
- T1WI C+
  - Enlarged pituitary enhances homogeneously, intensely, similar to cavernous sinuses
  - No focal hypointensity (suggestive of adenoma)
  - HE: Typically no enhancement
- MRS
  - ↑ Cho in untreated congenital hypothyroidism reflecting blocked myelin maturation

Nuclear Medicine Findings

- PET
  - Severe hypothyroidism (short duration): Generalized ↓ regional CBF, glucose metabolism

Other Modality Findings

- Tc-99m HMPAO SPECT: Reversible cerebral hypoperfusion (25% ↓ mean CBF) in reversible dementia caused by hypothyroidism

Imaging Recommendations

- Best imaging tool
  - MR
- Protocol advice
  - Coronal T1WI C+, axial and coronal T2/FLAIR for white matter, temporal lobe

DIFFERENTIAL DIAGNOSIS

Pituitary Macroadenoma

- Difficult to differentiate adenoma from pituitary hyperplasia
- T1WI
  - Adenomas may be homogeneous or heterogeneous, typically with lower signal than normal pituitary gland
  - Isointense signal if hemorrhage or necrosis within adenoma
- T1WI C+: Focal hypointensity suggests macro- or microadenoma

Physiologic Pituitary Hyperplasia

- Puberty, pregnancy, post partum (1st week)
- Can be indistinguishable on imaging studies

Enlargement of Pituitary Gland With Spontaneous Intracranial Hypotension

- Look for diffuse dural thickening, "slumping midbrain," tonsillar herniation

Confluent White Matter Lesions

- Arteriosclerosis: Usually multiple T2 hyperintensities but can become confluent in late elderly
- Chronic hypertensive encephalopathy: BG lacuna, deep periventricular confluent T2 hyperintensities
- Cerebral amyloid disease: Multifocal juxtacortical small infarcts and hemorrhages of varying ages common, with little to no BG involvement

https://CafePezeshki.IR

PATHOLOGY

General Features

- Etiology
  - Primary hypothyroidism
    - Most common cause in North America: Autoimmune disease
    - Iatrogenic hypothyroidism (2nd most common): Post-thyroidectomy, post-radioactive I-131 therapy
    - Congenital hypothyroidism: Aplasia/hypoplasia or ectopic gland, enzymatic defects in thyroid hormone synthesis
    - Goitrous hypothyroidism: Endemic iodine deficiency; extinct in USA, but major cause of mental deficiency worldwide
  - Secondary hypothyroidism: Uncommon cause
    - Hypothalamic-pituitary axis failure (↓ thyroid releasing hormone [TRH]/thyroid stimulating hormone [TSH])
  - Lack of inhibition of hypothalamic TRH, pituitary TSH caused by insufficient quantity of thyroid hormones
  - High TRH levels increase TSH and prolactin release from pituitary
  - 2 mechanisms of cerebellar dysfunction in hypothyroidism
    - Endocrine disorder, reversible with THRT
    - Autoimmune-mediated HT, not reversed by THRT
  - **HE**
    - Rare disease with no specific known cause
    - High titers of antithyroglobulin or anti-TPO (antimicrosomal) antibodies
    - High titers of antithyroid antibodies not sufficient for diagnosis
    - Various studies reported no evidence of pathogenic role of antibodies in HE
    - Combination of encephalopathy, high serum antithyroid antibody concentrations, and responsiveness to steroid therapy seen in almost every case
- Associated abnormalities
  - Hypothyroidism is associated with other autoimmune diseases
    - Rheumatoid arthritis, systemic lupus erythematosus (SLE), insulin-dependent diabetes mellitus, ulcerative colitis, myasthenia gravis, MS, pernicious anemia
  - Cretinism
    - Malformed convolution, poor differentiation of cortical layers, reduction in quantity of WM, delayed myelination

CLINICAL ISSUES

Presentation

- Most common signs/symptoms
  - Hypothyroidism: Poor memory, psychomotor slowing, depression, reversible dementia
  - Acquired cerebellar ataxia
  - HE
    - 2 types of initial clinical presentation: Acute stroke-like (vasculitic type) episode and gradual cognitive impairment
    - Confusion, focal/generalized seizure, focal neurological deficit, cognitive decline, dementia
  - Other: Headache, visual impairment (bitemporal hemianopsia) if enlarged pituitary

Demographics

- Age
  - In acquired hypothyroidism, prevalence ↑ with age
  - HE reported in pediatric and adult patients
- Gender
  - Females commonly affected in acquired hypothyroidism
- Epidemiology
  - Acquired hypothyroidism affects 8-9 million Americans
  - Congenital hypothyroidism: 1:2,000-4,000 newborns

Natural History & Prognosis

- Rapid progression (3 weeks) of hyperplasia of anterior pituitary proven in acute development of hypothyroidism
- In congenital hypothyroidism: Main developmental delay originates during first 3 months after birth

Treatment

- Prompt regression of pituitary enlargement with THRT
- ↑ in brain size and ↓ in ventricular size with treatment correlate with changes in levels of circulating thyroid hormones
- In congenital hypothyroidism, thyroid hormone replacement ASAP (< 13 days)
  - Patients with early treated congenital hypothyroidism often develop subnormally and display subtle neurological defects
- Endemic cretinism is determined in utero, irreversible by postnatal treatment
- Acquired cerebellar ataxia is typically reversible with THRT
  - In few patients: Ataxia persists despite THRT
- HE: Responsive to corticosteroid

DIAGNOSTIC CHECKLIST

Consider

- Urgent thyroid function tests should be performed in all patients with pituitary enlargement prior to surgery to exclude hypothyroid-induced pituitary swelling
- Consider hypothyroidism in child (especially male) with diagnosis of "pituitary adenoma"
- HE: Exclude other toxic metabolic or infectious etiologies, high antithyroid antibodies

SELECTED REFERENCES

1. Nandi-Munshi D et al: Thyroid-related neurological disorders and complications in children. Pediatr Neurol. 52(4):373-82, 2015
2. Johnston PC et al: Thyrotroph hyperplasia. Postgrad Med J. 90(1059):56-7, 2014
3. Kirshner HS: Hashimoto's encephalopathy: a brief review. Curr Neurol Neurosci Rep. 14(9):476, 2014
4. Mills NJ et al: Reactive pituitary hyperplasia associated with paediatric primary hypothyroidism. J Paediatr Child Health. 49(5):421-2, 2013
5. Zhang WH et al: Magnetic resonance imaging findings of pituitary hyperplasia due to primary hypothyroidism. Zhongguo Yi Xue Ke Xue Yuan Xue Bao. 34(5):468-73, 2012

https://CafePezeshki.IR

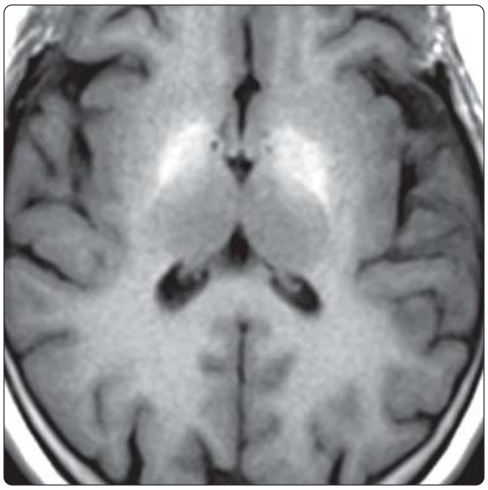

(Left) *Axial NECT shows diffuse calcifications within the basal ganglia and subcortical white matter in a patient with hypothyroidism. Imaging mimics that of other thyroid and parathyroid disorders.* **(Right)** *Axial T1WI MR shows focal hyperintensity in both globi pallidi related to longstanding hypothyroidism. NECT scan (not shown) disclosed dense calcifications in the basal ganglia, especially in the globi pallidi, typical of hypothyroidism.*

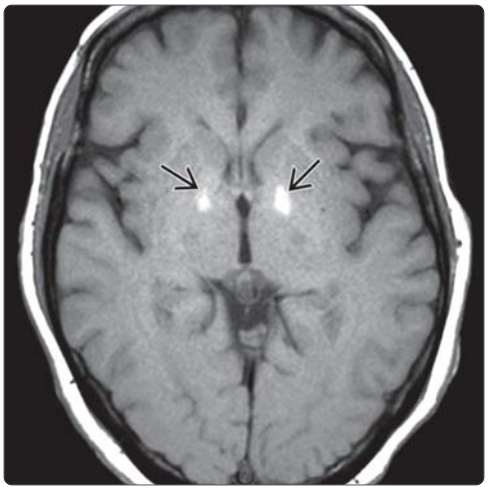

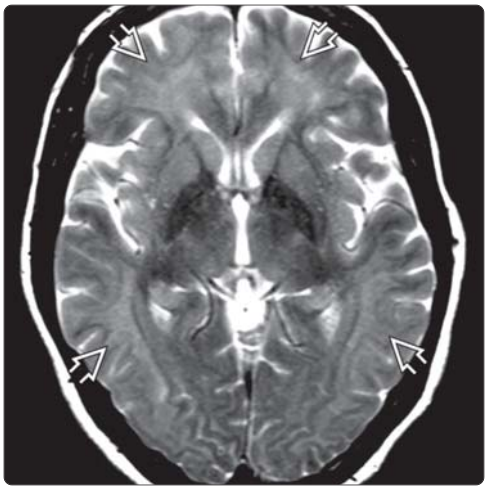

(Left) *Axial T1WI shows bilateral hyperintensities in the medial globi pallidi ⇨ in a patient status post thyroidectomy.* **(Right)** *Axial T2WI MR shows striking confluent, symmetric hyperintensity throughout the white matter ⇨ with involvement of the subcortical U-fibers. This diffuse white matter hyperintensity is a very rare but recognized manifestation of hypothyroidism. Sometimes called "myxedema madness," it is also known as Hashimoto encephalopathy.*

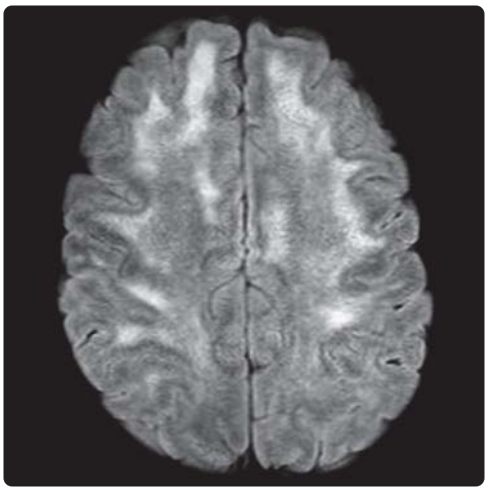

(Left) *Axial FLAIR MR in a 40-year-old woman who presented with altered mental status, hallucinations, and seizures shows diffuse confluent white matter hyperintensity ⇨ with relative sparing of the occipital lobes.* **(Right)** *Axial FLAIR in the same patient shows diffuse white matter hyperintensity extending to involve the subcortical U-fibers. Note the relative sparing of the occipital lobes.*

https://CafePezeshki.IR

KEY FACTS

TERMINOLOGY

- CNS manifestations related to parathyroid hormone (PTH) metabolic abnormalities

IMAGING

- Bilateral symmetric calcifications in globi pallidi, putamen, caudate nuclei
- Diffuse patchy "salt and pepper" lesions in skull in 1° HPTH
- Plaque-like dural calcification, "pipestem" calcifications of carotid arteries in 2° HPTH
- Brown tumors: Focal expansile lytic lesions with nonsclerotic margins in 1° HPTH and 2° HPTH
- T2WI: Hypointensity involving BG, cerebral cortex, or dentate nucleus due to Ca++ deposition

TOP DIFFERENTIAL DIAGNOSES

- Fahr disease
- Physiologic calcification
- Congenital HIV
- Hypoxic-ischemic encephalopathy

PATHOLOGY

- 1° HPTH: Parathyroid adenoma (75-85 %) , parathyroid hyperplasia (10-20 %), carcinoma (1-5%), ↑ PTH, ↑ Ca++
- 2° HPTH: Chronic renal failure, kidney fails to convert vitamin D to active form and excrete phosphate
- HP: Parathyroids are absent or atrophied; genetic autoimmune syndrome or DiGeorge syndrome (total absence of PT glands at birth)
- PHP: Insensitivity of end-organ to PTH, rather than decreased production of PTH

CLINICAL ISSUES

- HPTH: ↑ Ca++ affects transsynaptic nerve conduction, fatigue, pain, nausea, osteoporosis
- HP: Carpal-pedal spasm, tetany, seizure, and hyperreflexia

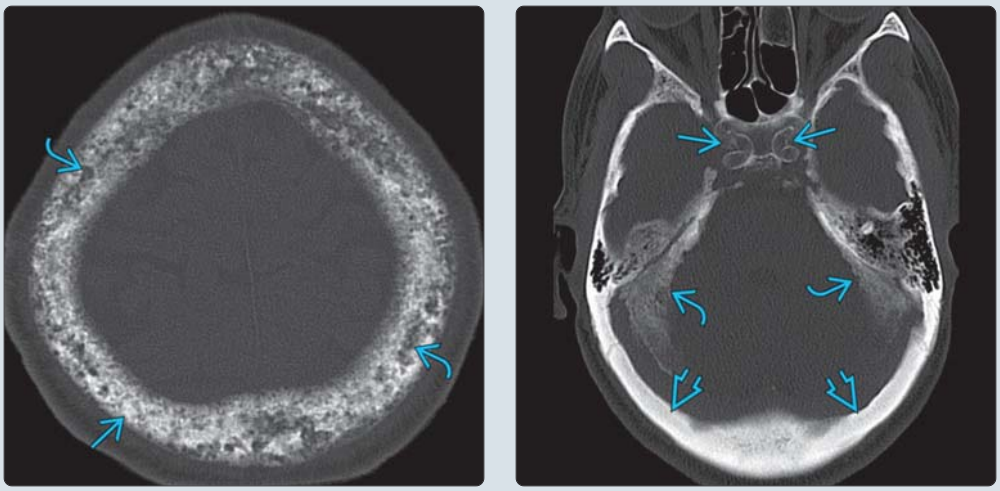

(Left) *Axial NECT in 1° hyperparathyroidism shows extensive patchy lytic and sclerotic areas involving the calvaria. This gives a classic "salt and pepper" appearance of the calvaria.* **(Right)** *Axial NECT in a patient with a long history of dialysis for chronic renal failure demonstrates classic changes in skull due to 2° hyperparathyroidism. There is extensive calcification of the tentorium, sclerosis of calvaria, and pipe-like calcification of the internal carotid arteries.*

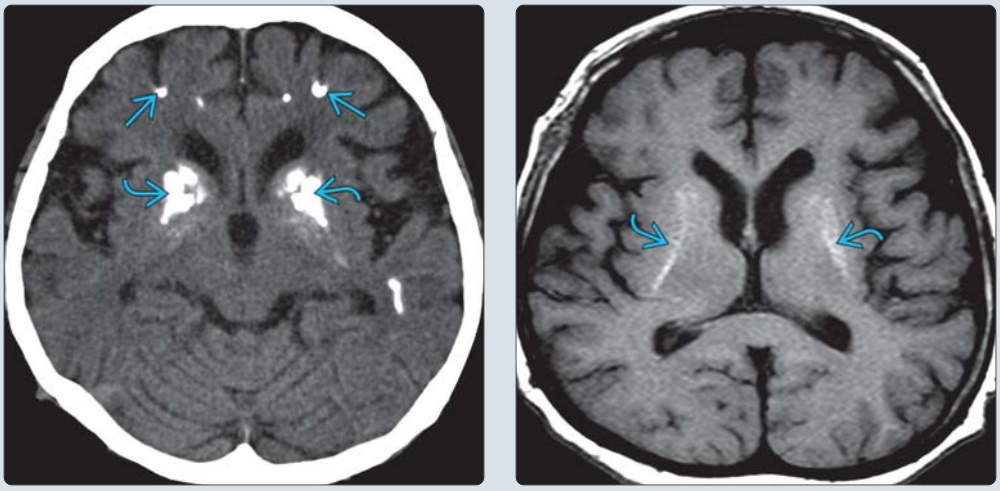

(Left) *Axial NECT in a patient with hypoparathyroidism shows symmetric bilateral basal ganglia calcifications. Focal calcifications are also seen in the subcortical white matter.* **(Right)** *Axial T1 MR in the same patient shows T1 shortening in the basal ganglia due to calcifications. Calcium deposition in the basal ganglia is seen in both hyper- and hypoparathyroidism. Additional sites for calcium deposition include thalamus, subcortical white matter, dentate nuclei, and dura.*

https://CafePezeshki.IR

TERMINOLOGY

Definitions

- CNS manifestations related to parathyroid hormone (PTH) metabolic abnormalities
  - 1° and 2° hyperparathyroidism (HPTH)
  - Hypoparathyroidism (HP)
  - Pseudohypoparathyroidism (PHP)
  - Pseudo-pseudohypoparathyroidism (PPHP)

IMAGING

General Features

- Best diagnostic clue
  - Calcium (Ca++) deposition in basal ganglia (BG) in HPTH and HP
  - "Salt and pepper" skull in 1° HPTH
- Location
  - Ca++ in globus pallidi (GP), putamen, caudate, thalamus, subcortical WM, dentate nucleus, dura
  - Skull

Imaging Recommendations

- Best imaging tool: CT and MR (T2WI and T2* GRE)

CT Findings

- NECT
  - Bilateral symmetric calcifications in globi pallidi, putamen, caudate nuclei
    - Thalami, subcortical WM, and dentate nuclei may be affected
  - Diffuse patchy "salt and pepper" lesions in skull in 1° HPTH
  - Plaque-like dural calcification, "pipestem" calcifications of carotid arteries in 2° HPTH
  - Brown tumors: Focal expansile lytic lesions with nonsclerotic margins in 1° HPTH and 2° HPTH

MR Findings

- T1WI: BG hyperintensity
- T2WI: Hypointensity involving BG, cerebral cortex, or dentate nucleus due to Ca++ deposition
- T2* GRE: "Blooming" artifact related to Ca++
- Brown tumors: Variable signal intensity

DIFFERENTIAL DIAGNOSIS

T1 Hyperintense Basal Ganglia

- Hepatic encephalopathy, hyperalimentation, Wilson disease, nonketotic hyperglycemia

Fahr Disease

- Symmetric Ca++ in BG, thalamus, and dentate nucleus

Physiologic Calcification

- Almost always GP, ↑ incidence with age

Congenital HIV

- Microangiopathy and infarction → Ca++ and atrophy

Hypoxic-Ischemic Encephalopathy

- GP, thalamus, and brainstem Ca++

PATHOLOGY

General Features

- Etiology
  - 1° HPTH: Parathyroid adenoma (75-85 %), parathyroid hyperplasia (10-20 %), carcinoma (1-5%), ↑ PTH, ↑ Ca++
    - Sporadic 1° HPTH more common than hereditary
    - Inherited syndromes associated with 1° HPTH : Multiple endocrine neoplasia (MEN) type 1, MEN type 2A, and familial isolated HPTH
  - 2° HPTH: Chronic renal failure commonly → kidneys fail to convert vitamin D to active form and excrete phosphate (P): ↑ PTH, normal or ↓ Ca++, ↑ P
    - Parathyroid hyperplasia less common
  - HP: Parathyroid glands are absent or atrophied; surgically removed; genetic autoimmune syndrome or DiGeorge syndrome (total absence of parathyroid glands at birth)
  - PHP: Insensitivity of end-organ to PTH, rather than ↓ production of PTH; dysfunction of G protein (Gs alpha subunit): ↓ Ca++, ↑ P, ↑ PTH
  - PPHP: Incomplete expression of PHP, normal Ca++ and P
- Associated abnormalities
  - Dialysis-associated encephalopathy: Dementia (aluminum accumulation), renal osteodystrophy, brown tumor
  - HP could be due to hemochromatosis or magnesium deficiency

CLINICAL ISSUES

Presentation

- Most common signs/symptoms
  - 1° HPTH: ↑ Ca++ affects transsynaptic nerve conduction; fatigue, pain, nausea, osteoporosis
    - "Stones, bones, abdominal groans, and psychic moans"
  - 2° HPTH: Progressive cranial nerve involvement due to massive thickening of calvaria and skull base
  - HP: Carpal-pedal spasm, tetany, seizure, and hyperreflexia
- Other signs/symptoms
  - HPT: Excessive secretion of PTH: ↑ Ca++ (1° HPTH) or response to low Ca++ level (2° HPTH)
  - HP: Dry, puffy, coarse skin, brittle nails, cataract, ↓ Ca++

Treatment

- Primary HPTH: Remove parathyroid adenoma
- Secondary HPTH: Calcimimetics → mimics Ca++ in body, reduce PTH secretion, lowering Ca++
- HP: Intravenous calcium with vitamin D3

DIAGNOSTIC CHECKLIST

Consider

- Excessive Ca++ in BG or heterotopic Ca++, consider PTH abnormality and other toxic-metabolic disorders

SELECTED REFERENCES

1. Bandeira F et al: Bone disease in primary hyperparathyroidism. Arq Bras Endocrinol Metabol. 58(5):553-61, 2014
2. Lachungpa T et al: Imaging features of primary hyperparathyroidism. BMJ Case Rep. 2014, 2014

https://CafePezeshki.IR

Fahr Disease

KEY FACTS

TERMINOLOGY

- Fahr disease (FD)
  - a.k.a. cerebrovascular ferrocalcinosis, bilateral striopallidodentate calcification
- Rare degenerative neurological disorder
  - Extensive bilateral basal ganglia (BG) calcifications (Ca++)
  - ± progressive dystonia, parkinsonism, neuropsychiatric manifestations

IMAGING

- Bilateral symmetric Ca++ in BG, thalami, dentate nuclei, and cerebral white matter on CT

TOP DIFFERENTIAL DIAGNOSES

- Normal (physiologic)
  - Symmetrical BG Ca++ in middle-aged, elderly
- Pathologic BG Ca++ (e.g., endocrinological)

PATHOLOGY

- FD is often familial, yet heterogeneous
- Characteristic feature: Diffuse neurofibrillary tangles with calcification (a.k.a. Fahr-type calcification)

CLINICAL ISSUES

- Most common signs/symptoms
  - Neuropsychiatric disturbance
  - Cognitive impairment (subcortical dementia)
  - Extrapyramidal movement disorders
- Ca++/P metabolism, PTH levels normal
- Bimodal pattern of clinical onset
  - Early adulthood (schizophrenic-like psychosis)
  - 6th decade (extrapyramidal syndrome, subcortical dementia)

DIAGNOSTIC CHECKLIST

- BG Ca++ if < 50 years old merits investigation

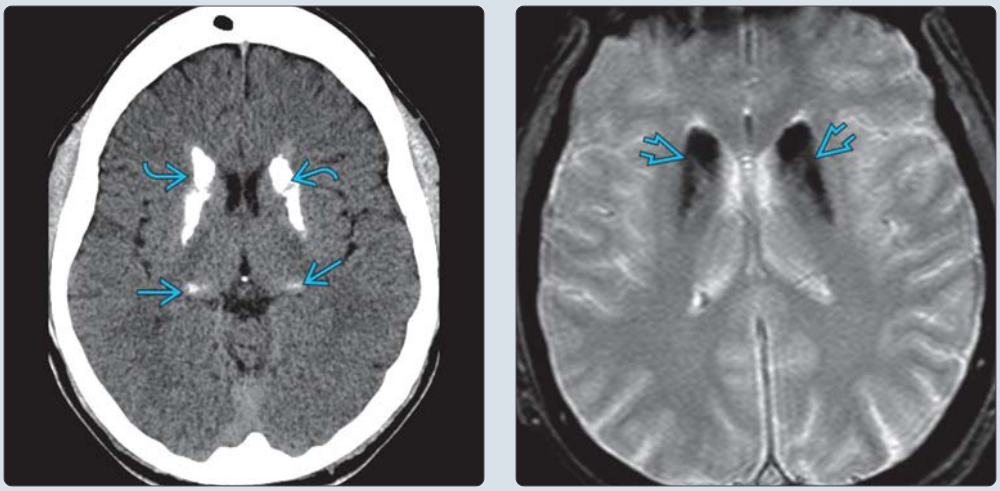

(Left) *Axial NECT in patient with Fahr disease demonstrates classic extensive calcifications in the basal ganglia and thalami.* **(Right)** *Axial T2* GRE MR image in the same patient shows low signal in the basal ganglia. This appearance on T2* GRE is due to a combination of calcification and iron deposition.*

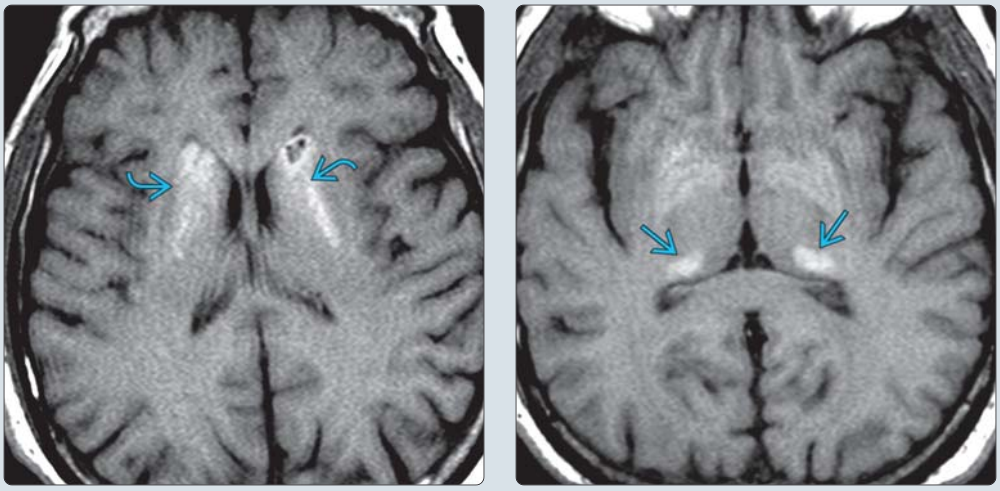

(Left) *Axial T1 MR image in the same patient shows T1 shortening in the basal ganglia. T1 shortening is typical and is secondary to the presence of Fahr-type calcification.* **(Right)** *Axial T1 MR in the same patient shows similar T1 shortening in the thalami. This corresponds to the calcification seen on CT. Fahr disease is a degenerative neurological disorder that manifests as bilateral symmetric calcifications in the basal ganglia, thalami, dentate nuclei, and cerebral white matter.*

https://CafePezeshki.IR

TERMINOLOGY

Abbreviations

- Fahr disease (FD)

Synonyms

- Familial idiopathic basal ganglia calcification
- Bilateral striopallidodentate calcification
- Idiopathic familial cerebrovascular ferrocalcinosis

Definitions

- Rare degenerative neurological disorder
  - Extensive bilateral basal ganglia (BG) calcifications (Ca++)
  - Can lead to progressive dystonia, parkinsonism, neuropsychiatric manifestations

IMAGING

General Features

- Best diagnostic clue
  - Bilateral symmetric Ca++ in BG, thalami, dentate nuclei, and cerebral white matter on CT
- Location
  - Globus pallidus = most common site of Ca++
    - Lateral pallidum > medial pallidum
  - Also putamen, caudate, thalami, cerebellum (especially dentate), internal capsule, cerebral white matter
- Morphology
  - Variable extent
  - Dense Ca++ often conforms to outline of BG

CT Findings

- NECT
  - Bilateral symmetric Ca++ in typical locations
- CECT
  - No enhancement

MR Findings

- T1WI
  - Varying signal intensities related to
    - Stage of disease, volume of calcium deposit
    - Differences in calcium metabolism
  - Ca++ usually hyperintense on T1WI
- T2WI
  - Dense Ca++ can appear hypo-/hyperintense
  - T2 hyperintense areas in white matter
    - Do not correspond to any calcification
    - May reflect metabolic or inflammatory brain process, which subsequently becomes calcified
    - Entire centrum semiovale may appear hyperintense in patients with dementia
    - Focal internal capsule hyperintense foci may correlate with contralateral hemiparesis
- FLAIR
  - Same as T2WI
- SWI
  - Marked hypointensity
  - SWI may prove to be more sensitive than CT

Nuclear Medicine Findings

- PET
  - May show ↓ bilateral FDG uptake in BG
    - Also seen in frontal and temporoparietal cortices and hippocampal area
  - Functional abnormalities may precede morphological changes in FD process
- SPECT with Tc-99-ethyl-cysteinate-dimer (ECD)
  - ↓ perfusion to calcified lesions
    - Especially in setting of dementia
    - Not associated with volume of calcium deposits
  - May see ↑ perfusion if acquired during symptomatology
    - Especially temporal lobes with auditory hallucinations

Imaging Recommendations

- Best imaging tool
  - NECT
- Protocol advice
  - MR SWI may prove to be superior

DIFFERENTIAL DIAGNOSIS

Normal

- Symmetrical BG Ca++ in middle-aged, elderly
- Localized in globus pallidus
- Usually punctate but can be quite heavy
- Detected on CT scan, no clinical significance
- Extremely common finding in older age group
- If accompanied by other calcifications, consider pathologic condition

Inherited, Acquired BG Ca++

- In children/young adults
- Associated with Down syndrome
- Trisomy 5
- Mitochondrial encephalopathies
  - Kearns-Sayre, MELAS, MERRF
  - T2 hyperintense lesions in BG
  - BG Ca++ can occur but not prominent feature
- Aicardi-Goutières syndrome
  - Autosomal recessive
  - Encephalopathy after birth → developmental arrest
- HIV encephalitis
  - BG Ca++ and cerebral atrophy
- Cockayne syndrome
  - Autosomal recessive disorder of DNA repair
  - CT: Cortico-subcortical atrophy, BG, and dentate nuclei Ca++
  - T2WI: Hyperintensity of periventricular white matter and subcortical U-fibers
  - T2WI hypointense putamina and caudate nuclei
  - Atrophy of cerebellar vermis and brainstem
  - Dwarfism, microcephaly, mental retardation
  - Photosensitivity, ocular abnormalities
  - Gait disturbance, progeroid appearance
- Long-term complications of radiation for childhood brain tumors and intrathecal chemotherapy
  - Bilateral BG Ca++, leukoencephalopathy
- Phakomatoses: Tuberous sclerosis and neurofibromatosis

Pathologic BG Ca++

- Endocrinologic disorders

https://CafePezeshki.IR

- Hyperparathyroidism, hypoparathyroidism, pseudohypoparathyroidism, pseudopseudohypoparathyroidism, post thyroidectomy
- Similar distribution of calcifications to FD
- Hypoparathyroidism: ↑ ionic calcium in interstitial tissues with ↓ levels of circulating calcium
- Calcification in primary hypoparathyroidism is more diffuse than in other etiologies of calcification
- Post-thyroidectomy hypoparathyroidism calcifications are more focal

- Neuropsychiatric (e.g., lupus, motor neuron disease)
- Postinfectious (e.g., TB, toxoplasmosis, cysticercosis)
- Toxic (e.g., carbon monoxide, lead intoxication)

PATHOLOGY

General Features

- Etiology
  - CNS Ca++ in FD could represent
    - Metastatic deposition secondary to local blood-brain barrier disruption
    - Disorder of neuronal calcium metabolism
  - Defective iron transport and free radicals → tissue damage → calcification
- Genetics
  - Autosomal dominant in most families with FD
    - Occasionally autosomal recessive
  - FD is often familial, yet heterogeneous
    - Variable expressivity and reduced penetrance can be found in same family, but most patients are symptomatic
    - "Genetic anticipation" = age of onset ↓ with each transmission in multigenerational family
    - In some kindreds, most individuals are largely asymptomatic
  - 1st locus identified: IBGC1 on chromosome 14q
    - IBGC1 region contains over 100 known genes, expressed sequence tags, and predicted genes
    - Now known not to be the main locus

Staging, Grading, & Classification

- Fahr disease = idiopathic calcifications with cognitive and neurobehavioral manifestations
  - Diagnosis of exclusion; requires normal calcium, phosphorous, and parathyroid hormone levels
- Fahr syndrome = same appearance as FD but secondary to underlying disorder (e.g., hypoparathyroidism)

Microscopic Features

- Characteristic feature: Diffuse neurofibrillary tangles with calcification (a.k.a. Fahr-type calcification)
  - Neurofibrillary tangles comprised of tau and phosphorylated-tau protein
- Predominant element is calcium
  - Other elements (Zn, P, Fe, Mg, Al, K) also present
- Ca++ in extracellular, extravascular space, often surrounding capillaries
  - Ca++ of medial walls and adventitia
  - Ca++ in areas of demyelination, lipid deposition
  - Ca++ incorporated into proteins or bound to polysaccharides

CLINICAL ISSUES

Presentation

- Most common signs/symptoms
  - Neuropsychiatric disturbance
  - Cognitive impairment (subcortical dementia)
  - Extrapyramidal movement disorders
- Clinical profile
  - Calcium–phosphorus metabolism and parathyroid hormone levels are normal
  - Usually asymptomatic in 1st 2 decades of life, despite presence of multiple brain calcifications
  - Neurological manifestations vary, but movement disorders are most common
    - Parkinsonism most common, usually permanent and progressive
    - Childhood transient parkinsonism also reported
    - Paroxysmal dystonic choreoathetosis

Demographics

- Age
  - Onset of clinical symptoms is typically 30-60 years
  - Infantile form also described
  - Bimodal pattern of clinical onset
    - Early adulthood (schizophrenic-like psychosis)
    - 6th decade (extrapyramidal syndrome, subcortical dementia)
- Gender
  - No gender predominance
- Epidemiology
  - Rare

Natural History & Prognosis

- Characterized by very slow progression
- Mental deterioration and loss of motor skills
  - Degenerative rather than developmental disorder
- Adult-onset FD: Calcium deposition begins in 3rd decade with neurological deterioration 2 decades later
- Symmetrical spastic paralysis and sometimes athetosis appear, progressing to decerebrate state
- Commonly develop neuropsychiatric disturbances
- Proposed disruption in thalamo-cortico-striatal circuit leads to disconnection syndrome, termed "cognitive dysmetria," producing symptoms of schizophrenia

DIAGNOSTIC CHECKLIST

Consider

- FD in parkinsonian patients with dementia and cerebellar signs
- Discovery of BG Ca++ if < 50 years old merits investigation

Image Interpretation Pearls

- Symmetric BG Ca++ in middle-aged/older adults
  - Common, of no clinical significance

SELECTED REFERENCES

1. Calabrò RS et al: Fahr's disease presenting with dementia at onset: a case report and literature review. Behav Neurol. 2014:750975, 2014
2. Mufaddel AA et al: Familial idiopathic basal ganglia calcification (Fahr`s disease). Neurosciences (Riyadh). 19(3):171-7, 2014
3. Bekiesinska-Figatowska M et al: Basal ganglia lesions in children and adults. Eur J Radiol. 82(5):837-49, 2013

https://CafePezeshki.IR

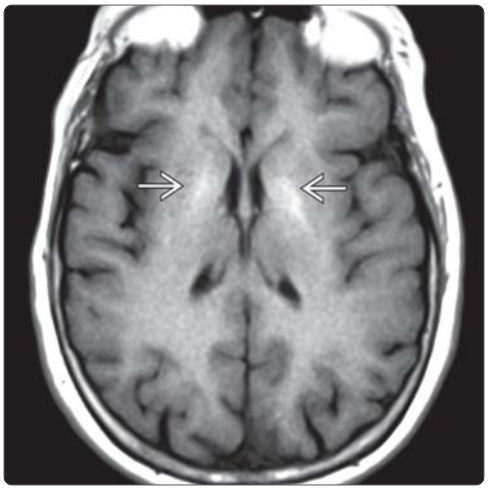

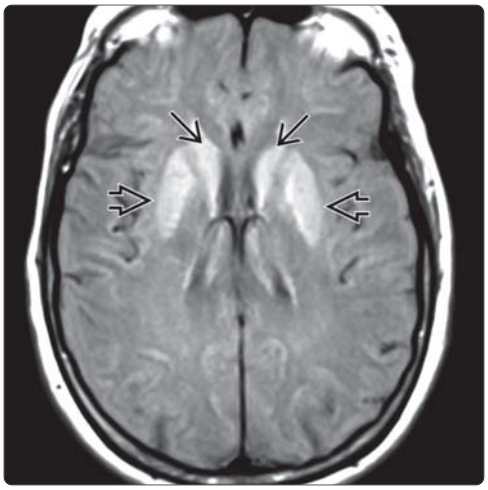

(Left) *Axial T1WI MR demonstrates the typical MR appearance of Fahr disease with T1 hyperintense basal ganglia calcifications ➡. These calcifications were also documented on head CT (not shown).* **(Right)** *Axial PD/intermediate MR in the same patient reveals the typical pattern of basal ganglia calcifications as T1 hyperintensity within a larger region of T2 hyperintense abnormality ⇨. Note that the T2 technique reveals that the caudate nuclei are also involved ⇨.*

(Left) *Axial NECT of a patient with Fahr disease shows extensive calcifications involving the periventricular deep white matter ➡. Patients with extensively affected centrum semiovale are more likely to present with dementia.* **(Right)** *Axial FLAIR MR in the same patient shows T2 hyperintensity within the areas of calcification ➡. In advanced cases, hyperintense abnormality may affect the entire centrum semiovale.*

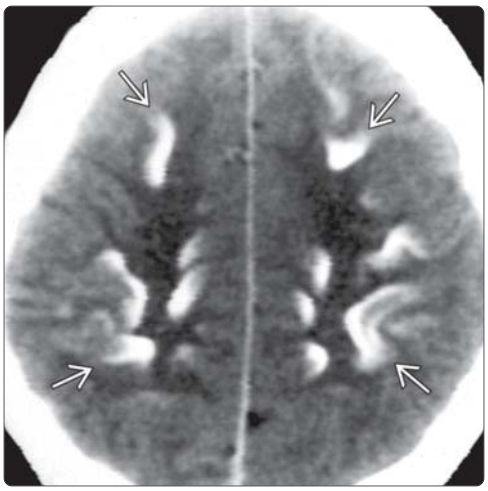

(Left) *Axial NECT demonstrates extensive Fahr-type calcifications at subcortical gray-white junctions ➡.* **(Right)** *Axial NECT illustrates both the typical dentate ➡, as well as atypical and extremely dense midbrain ➡ calcifications of Fahr disease, which is often familial, as in this case.*

https://CafePezeshki.IR

KEY FACTS

TERMINOLOGY

- Acute/subacute/chronic toxic effects of EtOH on CNS

IMAGING

- EtOH: Disproportionate superior vermian atrophy, enlargement of lateral ventricles, sulci with chronic EtOH
- WE: Mammillary body, medial thalamus, hypothalamus, periaqueductal gray abnormal signal/enhancement/diffusion restriction
- MBD: Abnormal signal and later necrosis in corpus callosum
- Protocol advice: Contrast-enhanced MR + DWI

TOP DIFFERENTIAL DIAGNOSES

- Nonalcoholic atrophy
- Diffuse demyelination
  - Toxic demyelination
  - Acquired/inherited metabolic disorders
- Corpus callosal hyperintensity
  - Status epilepticus
  - Drug toxicity
  - Encephalitis
  - Hypoglycemia

PATHOLOGY

- EtOH: Causes both direct/indirect neurotoxicity
- WE: Thiamine (vitamin B_1) deficiency
- WE can be alcoholic or nonalcoholic
- MBD: Chronic EtOH abuse, anecdotal association with red wine

CLINICAL ISSUES

- WE: Triad of ataxia, oculomotor abnormalities, confusion
- Classic clinical triad present in only a minority of patients
- EtOH: Cessation, establishment of adequate nutrition
- WE: Immediate administration of IV thiamine → quick response

DIAGNOSTIC CHECKLIST

- 50% of WE cases occur in nonalcoholics, including children

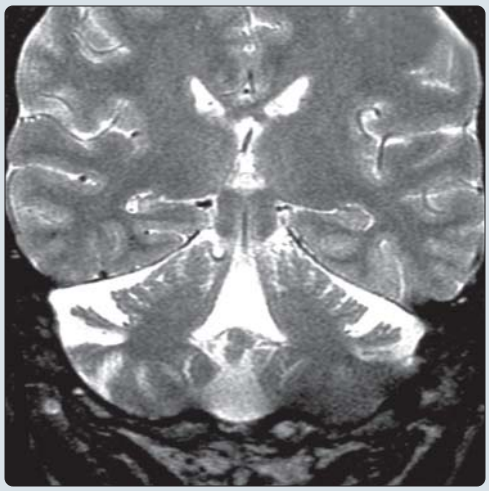

(Left) *Sagittal graphic shows generalized and superior vermian atrophy, as well as necrosis in the corpus callosum related to alcoholic toxicity. Mammillary body, periaqueductal gray necrosis is seen with Wernicke encephalopathy.* **(Right)** *Coronal T2WI MR demonstrates pronounced cerebellar atrophy.*

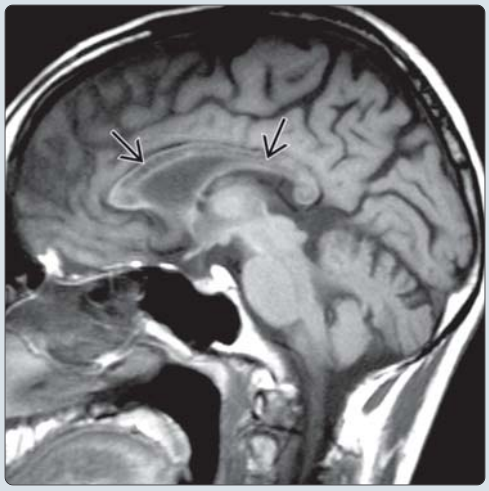

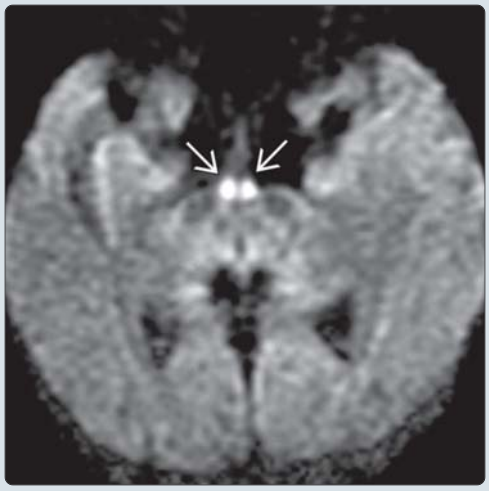

(Left) *Sagittal T1WI MR shows a classic finding for Marchiafava-Bignami disease with a thinned corpus callosum and hypointensity in the middle layers ⇨. Note that the genu, body, and splenium are all involved. (Courtesy A. Datir, MD.)* **(Right)** *Axial DWI MR shows restricted diffusion in the mammillary bodies ➡ in this patient with acute Wernicke encephalopathy.*

https://CafePezeshki.IR

TERMINOLOGY

Abbreviations

- Alcoholic (EtOH) encephalopathy
- Wernicke encephalopathy (WE)
- Marchiafava-Bignami disease (MBD)

Definitions

- Acute, subacute, or chronic toxic effects of EtOH on CNS
- Can be primary (direct) or secondary (indirect)
  - Primary (direct) effects of EtOH = neurotoxicity
    - Cortical/cerebellar degeneration, peripheral polyneuropathy
  - Secondary (indirect) effects
    - Trauma, malnutrition, coagulopathy
- Rare treatable complication = WE

IMAGING

General Features

- Best diagnostic clue
  - EtOH: Disproportionate superior vermian atrophy
  - WE: mammillary body, medial thalamus, hypothalamus, periaqueductal gray abnormal signal/enhancement
  - MBD: Abnormal signal and later necrosis in corpus callosum
- Location
  - EtOH
    - Cerebral hemispheres, especially frontal lobes
    - Cerebellum, superior vermis
    - Diffuse toxic demyelination = unusual manifestation of alcoholic encephalopathy
    - Basal ganglia (associated liver disease)
  - WE
    - Mammillary bodies, periaqueductal gray matter, hypothalamus
    - Thalami (adjacent to 3rd ventricle)
  - MBD
    - Corpus callosum ± lateral extension into adjacent white matter

CT Findings

- NECT
  - EtOH: Generalized atrophy; superior vermis atrophy
  - WE (acute): Often normal
    - May see hypodensity in periaqueductal gray matter, mammillary bodies, and medial thalamus
  - MBD: Hypodensity in corpus callosum

MR Findings

- T1WI
  - EtOH
    - Symmetric enlargement of lateral ventricles, sulci with chronic EtOH
    - ↑ size of cerebral sulci, interhemispheric/sylvian fissures
    - ± hyperintensity in basal ganglia (liver dysfunction)
  - WE
    - May see hypointensity in periaqueductal gray matter, mammillary bodies, hypothalamus, and medial thalamus
    - Chronic: Atrophic mammillary bodies (sagittal scan) and 3rd ventricular enlargement
- T2WI
  - EtOH
    - Nonspecific multifocal white matter hyperintensities
    - Less common: Diffuse white matter hyperintensity from toxic demyelination
  - WE
    - Hyperintensity around 3rd ventricle, mammillary bodies, hypothalamus, medial thalamus, midbrain (tectal plate and periaqueductal gray)
    - Atypical findings: Hyperintensity in cerebellum, cranial nerve nuclei, red nuclei, dentate nuclei, splenium, and cerebral cortex
  - MBD
    - Acute: Hyperintense corpus callosum (middle layers) virtually pathognomonic
    - Chronic: Callosal necrosis
- FLAIR
  - Lesions all typically hyperintense
- DWI
  - WE: Restriction in or around 3rd ventricle, periaqueductal region, bilateral dorsomedial thalami, and brainstem
  - MBD: Restricted diffusion in splenium of corpus callosum
- T1WI C+
  - WE: Enhancement of mammillary bodies, periaqueductal gray, medial thalamus
  - MBD: Acute phase white matter lesions may enhance
- MRS
  - EtOH: NAA/Cr, Cho/Cr decreased in frontal lobes, cerebellum; recover after detoxification

Nuclear Medicine Findings

- PET
  - EtOH
    - 18F-FDG PET: Significant decrease in whole-brain metabolism with chronic EtOH
  - WE: 18F-FDG PET: Diencephalic, medial temporal, limbic, and retrosplenial hypometabolism

Imaging Recommendations

- Best imaging tool
  - NECT for complications, such as subdural hematoma, related to trauma/coagulopathy
  - MR for possible Wernicke encephalopathy
    - Lack of imaging abnormalities does not exclude WE
- Protocol advice
  - Contrast-enhanced MR + DWI

DIFFERENTIAL DIAGNOSIS

Nonalcoholic Atrophy

- Alzheimer dementia (AD) = hippocampal, temporal atrophy, hypometabolism
- Multi-infarct dementia pattern = focal infarcts ± generalized atrophy
- Malnutrition, eating disorders = generalized
- Remote trauma = atrophy + cortical/axonal hemorrhages common
- Inherited cerebellar degeneration syndromes (Marie ataxia, olivopontocerebellar degeneration, etc.)

https://CafePezeshki.IR

- Longstanding phenytoin (Dilantin) use = cerebellar atrophy + thick skull

Diffuse Demyelination

- Toxic demyelination, including chemotherapy, CO poisoning, and inhaled heroin ("chasing the dragon")
- Acquired/inherited metabolic disorders
  - Osmotic demyelination syndrome = pontine > putamen, cortical involvement

Corpus Callosal Hyperintensity

- Status epilepticus
- Drug toxicity
- Encephalitis
- Hypoglycemia

PATHOLOGY

General Features

- Etiology
  - EtOH
    - Alcohol readily crosses blood-brain barrier
    - Causes both direct/indirect neurotoxicity
  - WE
    - Thiamine (vitamin B_1) deficiency impairs dependent enzymes, results in glutamate accumulation/cell damage
    - WE can be alcoholic or nonalcoholic
    - **Alcoholic WE**: Chronic thiamine deficiency due to associated malnourishment
    - **Nonalcoholic WE**: Same pathophysiology but different etiology
      - Malabsorption secondary to GI neoplasm/surgery
      - Hyperemesis (hyperemesis gravidarum, chemotherapy)
      - Malnutrition (starvation, anorexia nervosa)
      - Prolonged hyperalimentation
  - MBD
    - Chronic EtOH abuse, anecdotal association with red wine
- Associated abnormalities
  - EtOH
    - May ↑ stroke risk (especially in putamen, anterior cerebral artery)
    - Hepatic encephalopathy
  - Chronic EtOH
    - Brain shrinkage, cortical atrophy reflect lifetime consumption
    - EtOH modulates GABAergic neurotransmission

Gross Pathologic & Surgical Features

- EtOH
  - Atrophy (especially frontal), ↑ ventricles, sulci
  - Atrophy of folia of superior vermis & anterosuperior aspects of cerebellar hemispheres
- WE
  - Mammillary bodies; periventricular midbrain/brainstem
    - Petechial hemorrhage (acute)
    - Mammillary body atrophy (chronic)
  - Dorsal medial thalamic nuclei (may cause Korsakoff psychosis)
- MBD
  - Callosal necrosis, atrophy

Microscopic Features

- Axonal degeneration, demyelination (alcoholic polyneuropathy)
- Purkinje cell loss (alcoholic cerebellar degeneration)
- WE: Demyelination, neuronal loss in affected areas
- MBD: Demyelination middle layers of corpus callosum

CLINICAL ISSUES

Presentation

- Most common signs/symptoms
  - Chronic EtOH
    - Cognitive problems, impaired memory
    - Most common neurologic abnormality = polyneuropathy
    - Gait abnormalities, nystagmus (cerebellar degeneration)
  - WE: Triad of ataxia, oculomotor abnormalities, confusion
    - Classic clinical triad present in only a minority of patients
    - 50% nonalcoholic
    - Korsakoff psychosis (amnestic syndrome) may complicate WE
  - MBD: Sudden onset of altered mental status, seizures, dysarthria, ataxia, hypertonia, pyramidal signs

Demographics

- Age
  - Any age (Neuroblastoma: WE can occur in children)
- Epidemiology
  - EtOH, brain atrophy = dose dependent, independent of gender/ethnicity

Natural History & Prognosis

- EtOH: Ventricular, sulcal enlargement often reversible
- WE: Ocular palsies respond 1st to thiamine; ataxia, apathy, and confusion clear more slowly
  - High mortality if untreated
  - Only 25% of Korsakoff patients achieve full recovery
- MBD: Severe neurologic sequelae

Treatment

- EtOH: Cessation, establishment of adequate nutrition
- WE: Immediate administration of IV thiamine → quick response
- MBD: Vitamin B complex and steroids may reverse course in acute MBD

DIAGNOSTIC CHECKLIST

Consider

- 50% of WE cases occur in nonalcoholics, including children

SELECTED REFERENCES

1. Dujmović I et al: Teaching NeuroImages: Reversible widespread brain MRI lesions in Marchiafava-Bignami disease. Neurology. 84(11):e81-2, 2015
2. Kim TE et al: Wernicke encephalopathy and ethanol-related syndromes. Semin Ultrasound CT MR. 35(2):85-96, 2014
3. Leon-Hernandez A et al: [Marchiafava-Bignami disease.] Rev Neurol. 58(11):516-7, 2014
4. Manzo G et al: MR imaging findings in alcoholic and nonalcoholic acute Wernicke's encephalopathy: a review. Biomed Res Int. 2014:503596, 2014

https://CafePezeshki.IR

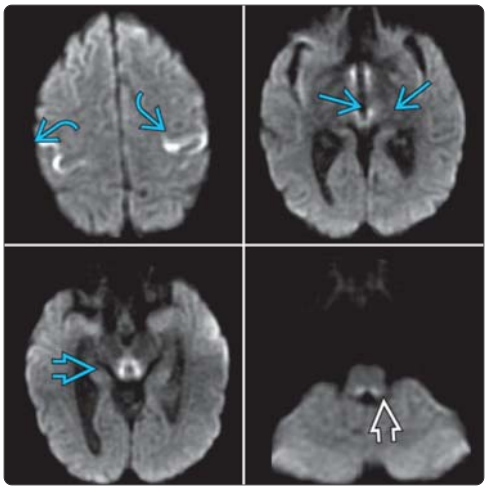

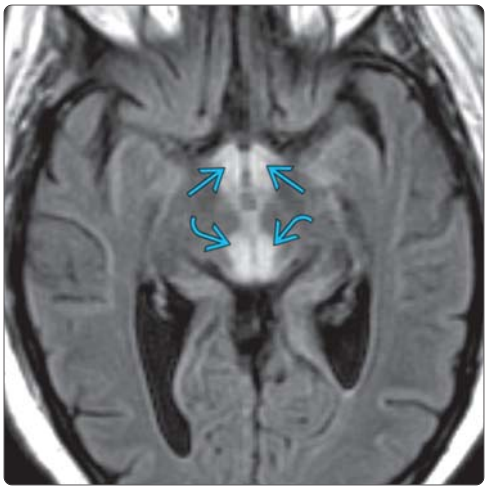

(Left) *Axial DWI MR images in a patient with acute Wernicke encephalopathy demonstrates restricted diffusion involving the perirolandic cortex, dorsomedial thalami, periaqueductal gray matter, and dorsal medulla.* **(Right)** *Axial FLAIR MR in the same patient shows hyperintensity in the dorsomedial thalami as well as the mammillary bodies. Acute Wernicke encephalopathy is caused by thiamine deficiency.*

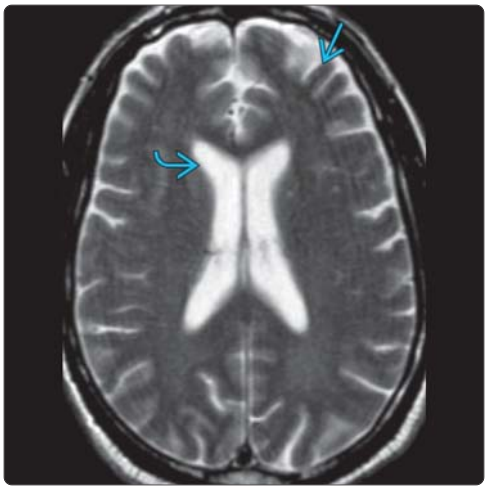

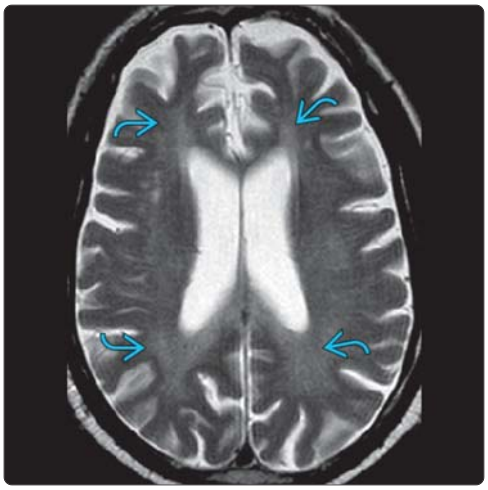

(Left) *Axial T2 MR in a 45-year-old patient with a history of chronic alcoholism shows prominence of the ventricles and cortical sulci due to diffuse atrophy.* **(Right)** *Axial T2 MR in the same patient after 4 years shows progression of the diffuse atrophy with development of periventricular and deep white matter hyperintensities. Alcohol readily crosses the blood-brain barrier and causes both direct/indirect neurotoxicity.*

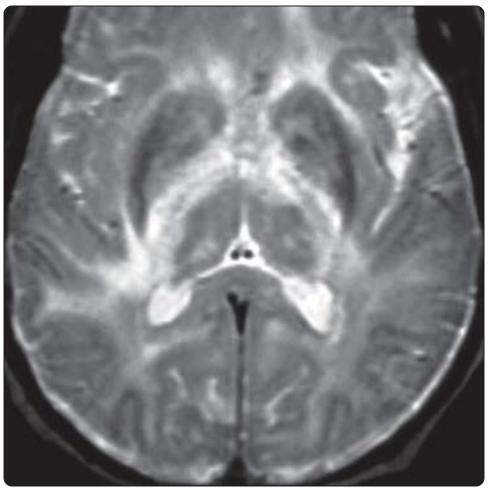

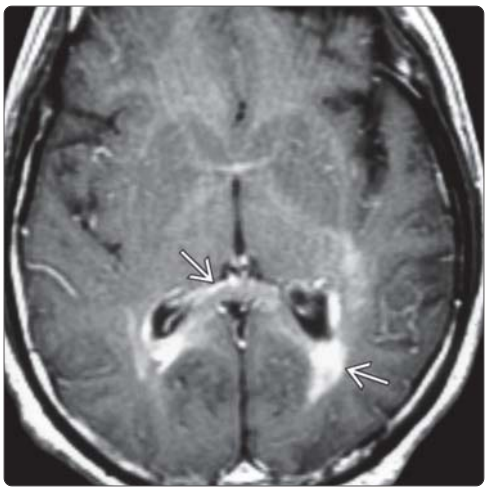

(Left) *Axial T2WI MR in a patient with acute alcohol poisoning caused by binge drinking shows symmetric, confluent white matter hyperintensity in the internal capsules, corpus callosum, and hemispheric white matter. Acute alcohol toxicity may induce striking demyelination, as occurred in this case.* **(Right)** *Axial T1WI C+ MR in the same patient with acute alcohol-induced demyelination shows enhancement in the corpus callosum splenium and forceps major.*

https://CafePezeshki.IR

KEY FACTS

TERMINOLOGY

- Functional, potentially reversible clinical syndrome during acute or chronic liver disease
- Characterized by psychiatric, cognitive, and motor components

IMAGING

- AHE
  - High T2 signal in most of cerebral cortex (preferential insular cortex and cingulate gyri) with diffusion restriction
  - Perirolandic/occipital regions relatively spared
- CHE
  - Bilateral T1WI hyperintensity in basal ganglia (BG), particularly globus pallidus (GP)
  - ↑ T1WI signal intensity in pituitary gland and hypothalamus less common
- FLAIR: Diffuse high signal intensity along hemispheric white matter in or around corticospinal tract

TOP DIFFERENTIAL DIAGNOSES

- Cholestatic diseases
- Liver copper overload
- Hyperalimentation
- Other causes of T1 hyperintense BG
  - Hypoxic-ischemic encephalopathy
  - Fahr disease (idiopathic calcification of BG)
  - Carbon monoxide poisoning
  - Neurofibromatosis type 1

PATHOLOGY

- Brain accumulation of neurotoxic &/or neuroactive substances
- Ammonia, manganese, aromatic amino acids

DIAGNOSTIC CHECKLIST

- After therapy, clinical features and MRS abnormalities improve 1st, followed 3-6 months later by normalization of BG signal

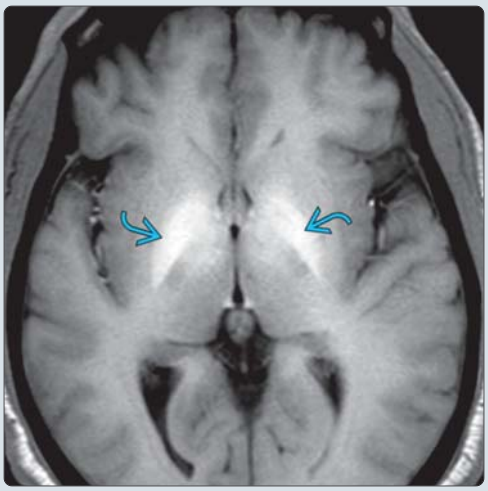

(Left) *Axial T1 MR in a patient with chronic liver disease demonstrates high T1 signal in the globus pallidus.* **(Right)** *Sagittal T1 MR in the same patient shows a hyperintense anterior pituitary gland. In patients with chronic liver disease, T1 hyperintensity is most commonly seen in the globus pallidus. The anterior pituitary and hypothalamus may also show similar T1 hyperintensity but is less common. T1 hyperintensity is thought to be due to manganese deposition.*

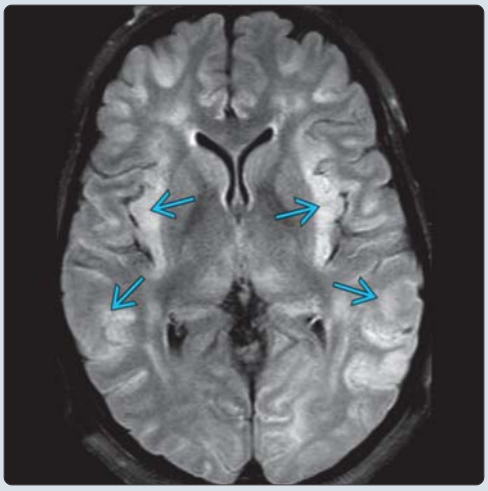

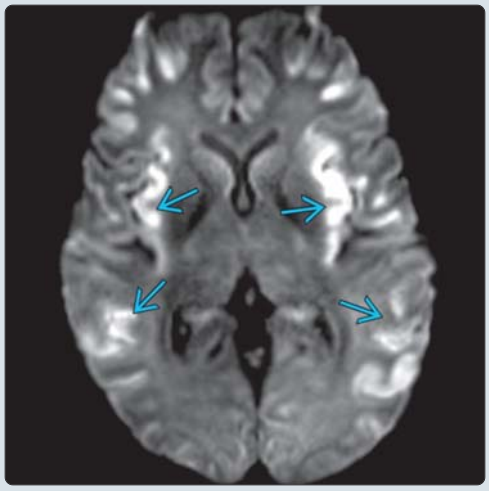

(Left) *Axial FLAIR MR in a patient with acute liver failure shows extensive cortical swelling and hyperintensity. There is relative sparing of the occipital cortex.* **(Right)** *Axial DWI MR in the same patient shows corresponding high signal due to diffusion restriction. Acute hepatic encephalopathy is caused by hyperammonemia. It is a life-threatening disorder with high morbidity and mortality.*

https://CafePezeshki.IR

TERMINOLOGY

Abbreviations

- Hepatic encephalopathy (HE)
- Acute hepatic encephalopathy (AHE)
- Chronic hepatic encephalopathy (CHE)

Synonyms

- Hepatic coma

Definitions

- Functional, potentially reversible clinical syndrome during acute or chronic liver disease
- Characterized by psychiatric, cognitive, and motor components

IMAGING

General Features

- Best diagnostic clue
  - AHE: Bilateral swollen T2/FLAIR hyperintense gyri (most severe insular cortex, cingulate gyri) with diffusion restriction
  - CHE: Bilateral T1WI hyperintensity in basal ganglia (BG), particularly globus pallidus (GP)
- Location
  - BG, particularly GP
  - Insular cortex, cingulate gyri in AHE
  - White matter in or around corticospinal tract

CT Findings

- NECT
  - AHE: Severe diffuse cerebral edema
  - CHE: Cerebral atrophy
- CECT
  - No enhancement of affected BG

MR Findings

- T1WI
  - Bilateral T1 hyperintensity in BG, particularly GP
    - Reported in 80-90% of chronic liver failure patients
    - Probably caused by manganese accumulation
    - Slow reversal following restoration of liver function
  - ↑ T1WI signal intensity in pituitary gland and hypothalamus less common
  - Atrophy, especially affecting cerebellum
  - AHE: Blurring of gray-white matter junction
- T2WI
  - AHE: Bilateral symmetric T2 hyperintensity in insular cortex, cingulate gyri, and basal ganglia
    - Relative sparing of perirolandic and occipital regions
  - Periventricular WM hyperintensity
- FLAIR
  - Diffuse high signal intensity along hemispheric white matter in or around corticospinal tract
    - Decreased to nearly normal after liver transplantation
  - WM hyperintensities similar to those seen in small vessel cerebrovascular disease and healthy elderly population
    - Partially reversible
- DWI
  - AHE: Restricted diffusion involving cortex (insular, cingulate gyri) & basal ganglia, corresponding ↓ ADC, ↓ mean diffusivity (MD), ↓ fraction anisotropy (FA)
  - ↑ MD, ↑ ADC in cirrhotic patients with minimal HE
- T1WI C+
  - No contrast enhancement
- MRS
  - ↓ myoinositol (mI), ↑ glutamine/glutamate (Glx), ↓ choline (Cho)
    - Brain glutamine concentrations ↑ in direct correlation with severity of HE in patients with chronic liver failure
    - Brain ammonia removal relies primarily on formation of glutamine
  - ↓ mI/Cr and Cho/Cr ratios and ↑ Glx/Cr ratios
    - After correction of hepatic dysfunction, these ratios normalize or may reverse
    - mI/Cr: Most sensitive (80-85%) indicator of HE
  - May play role in monitoring lactulose therapy

Nuclear Medicine Findings

- PET
  - NH_3-13-PET in chronic liver failure with mild HE
    - ↑ cerebral metabolic rate for ammonia
    - ↑ "permeability-surface area" product (measure of blood-brain barrier permeability to ammonia)
  - Redistribution of cerebral blood flow from cortical to subcortical areas (including BG)

Imaging Recommendations

- Best imaging tool
  - Multiplanar MR+DWI

DIFFERENTIAL DIAGNOSIS

Liver Copper Overload

- Wilson disease
  - Symmetrical hyperintensity in putamina, GP, caudate nuclei, and thalami on T2WI
  - Hyperintensity in dentatorubrothalamic, pontocerebellar, and corticospinal tracts on T2WI
  - Lesions appear hypointense (occasionally hyperintense) on T1WI, without enhancement
- Cholestatic disease
- Inefficient biliary excretion of copper in newborn

Hyperalimentation

- Bilateral hyperintense signal in GP and subthalamic nuclei on T1WI, without contrast
  - Caused by manganese deposition, astrogliotic reaction to such deposition, or both
- No corresponding abnormalities on T2WI or CT

Other Causes of T1 Hyperintense BG

- Microangiopathy and infarcts in AIDS patients
- Chorea-ballism associated with hyperglycemia
  - T1 hyperintense putamen, caudate nucleus: Unilateral
- Endocrine disorders leading to BG calcifications
  - Hyperparathyroidism, hypothyroidism
  - Hypoparathyroidism, pseudohypoparathyroidism, pseudopseudohypoparathyroidism
- Fahr disease (idiopathic calcification of BG)
- Hypoxic-ischemic encephalopathy

https://CafePezeshki.IR

- BG, parasagittal cortical areas most frequently involved
  - Hyperintense BG lesions on T1/T2WI
  - Diffuse laminar cortical hyperintensity on T1WI in subacute stage
  - Laminar cortical, BG enhancement
- Carbon monoxide poisoning
  - Most specific findings: GP hypodensity on CT and hyperintensity on T2WI
- Langerhans cell histiocytosis
- Neurofibromatosis type 1
  - Hyperintensities in BG (usually GP), internal capsule bilaterally on T1WI
  - Smaller foci of hyperintensity in brainstem, cerebellar WM, dentate nucleus, BG, and periventricular WM on T2WI

PATHOLOGY

General Features

- Etiology
  - Underlying cirrhosis, acute fulminant viral hepatitis
  - Drugs and toxins
  - Shock &/or sepsis
  - Childhood hepatic diseases associated with bright hypothalamus and pituitary gland
  - Portosystemic shunting through collateral vessels
  - Brain accumulation of neurotoxic &/or neuroactive substances
    - Ammonia, manganese, aromatic amino acids
  - Alterations in neurotransmission, blood-brain barrier permeability, and energy metabolism
  - Proinflammatory cytokines (TNF α, interleukin 1α) may affect brain by production of nitric oxide in endothelial or neural cells after crossing defective blood-brain barrier
  - HE precipitated by ammoniagenic situations
- Associated abnormalities
  - Parkinsonian signs especially with midbrain involvement
  - Hepatic myelopathy in chronic liver disease with extensive shunts

Staging, Grading, & Classification

- Based on mechanism causing hepatic condition, HE classified into 3 types
  - **Type A**: HE associated with acute liver failure
  - **Type B**: HE associated with portal-systemic bypass without intrinsic hepatocellular disease
  - **Type C**: HE associated with cirrhosis & portal hypertension (most common)

Gross Pathologic & Surgical Features

- Laminar and pseudolaminar necrosis of cerebral cortex
- Polymicrocavitation at gray-white matter junction

Microscopic Features

- AHE: Severe cytotoxic edema in astrocytes with anoxic neuronal damage
- HE in chronic liver failure
  - Astrocytosis: Alzheimer type 2 astrocytes
  - Neuronal degeneration

CLINICAL ISSUES

Presentation

- Most common signs/symptoms
  - Altered mental status leading to stupor and coma
  - Motor abnormalities: Tremor, bradykinesia, asterixis, ataxia, apraxia, hyperreflexia
  - Seizures: Rare manifestation of HE
- Clinical profile
  - HE classified into 3 main groups based on length or characteristics of neurological changes
    - **Episodic/acute**: Use neuroimaging to exclude other diseases
    - **Chronic HE**
      - Relapsing HE: Similar to episodic with completely normal neurocognition between attacks
      - Persistent HE: No reversal of manifestations despite treatment
    - **Minimal HE** (a.k.a. latent or subclinical HE)
      - Abnormalities that cannot be detected by standard examination

Demographics

- Age
  - Both pediatric and adult patients with severe hepatic dysfunction
- Gender
  - No gender preference
- Epidemiology
  - Occurs in > 50% of all cirrhosis cases

Natural History & Prognosis

- Acute HE: Severe brain edema may ↑ intracranial pressure → cerebral herniation → death
- Neuropsychologic signs of HE follow ^{1}H-MRS rather than MR changes

Treatment

- Identify and remove/treat precipitating factors
- Nonabsorbable disaccharides (lactulose, lactitol)
- Antibiotics (neomycin) with oto-/nephrotoxicity
- L-ornithine-L-aspartate
- Molecular adsorbents recirculating system (MARS) albumin dialysis: Improves encephalopathy grade

DIAGNOSTIC CHECKLIST

Image Interpretation Pearls

- After therapy, clinical features and MRS abnormalities improve 1st, followed 3-6 months later by normalization of BG signal
- BG signal abnormality typically normalizes within 1 year of liver transplantation

SELECTED REFERENCES

1. Su YY et al: PET and MR imaging of neuroinflammation in hepatic encephalopathy. Metab Brain Dis. 30(1):31-45, 2015
2. Alonso J et al: Brain magnetic resonance in hepatic encephalopathy. Semin Ultrasound CT MR. 35(2):136-52, 2014
3. Butterworth RF: Hepatic encephalopathy in alcoholic cirrhosis. Handb Clin Neurol. 125:589-602, 2014
4. Bathla G et al: MRI and CT appearances in metabolic encephalopathies due to systemic diseases in adults. Clin Radiol. 68(6):545-54, 2013

https://CafePezeshki.IR

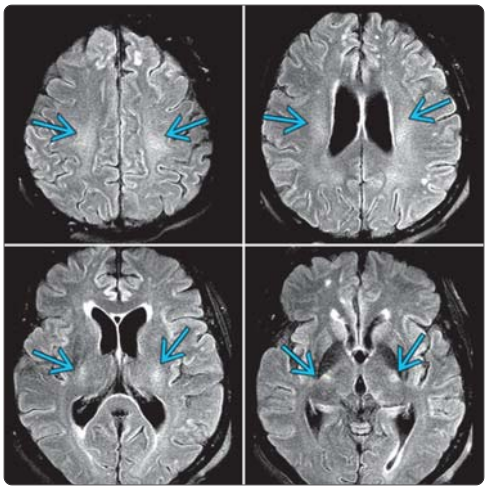

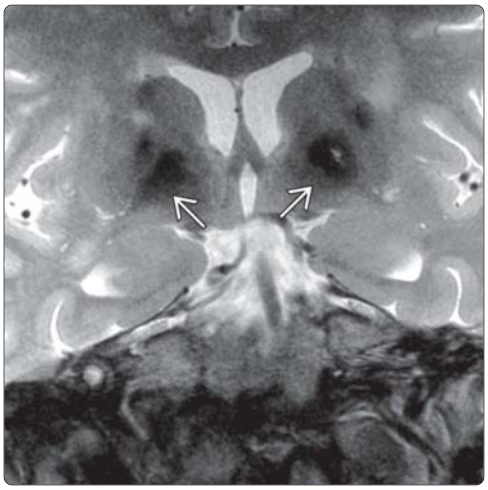

(Left) *Axial FLAIR MR in a patient with liver cirrhosis during an episode of hepatic encephalopathy shows symmetric areas of increased signal intensity along the corticospinal tract in both cerebral hemispheres. This signal abnormality reversed on a follow-up study obtained few months later (not shown).* **(Right)** *Coronal T2WI MR shows the typical T2 hypointense appearance of basal ganglia in a patient with chronic hepatic encephalopathy.*

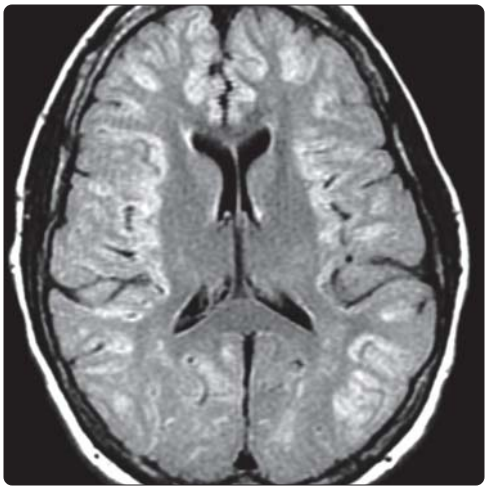

(Left) *Axial NECT shows diffuse cerebral edema in a patient with acute hepatic encephalopathy manifested by loss of gray-white matter distinction and obliteration of the sulci.* **(Right)** *Axial FLAIR MR in a patient with acute hepatic encephalopathy shows diffuse cortical hyperintensity with relative sparing of the occipital regions.*

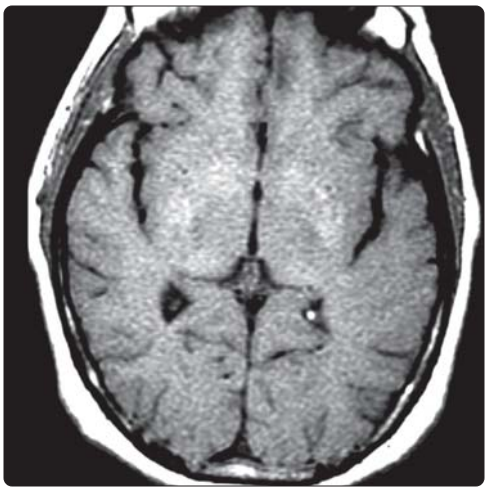

(Left) *Axial T1WI MR obtained prior to liver transplant shows bilateral symmetric hyperintensity in the globi pallidi, typical findings for chronic hepatic encephalopathy.* **(Right)** *Axial T1WI MR in the same patient obtained 14 months after transplant shows nearly complete interval resolution of the hyperintensity. The patient's movement disorder also resolved. Both clinical and imaging findings of hepatocerebral degeneration are potentially reversible. (Courtesy P. Hildenbrand, MD.)*

https://CafePezeshki.IR

KEY FACTS

TERMINOLOGY

- Cerebrovascular autoregulatory disorder
- Many etiologies with HTN as common component
  - Preeclampsia, eclampsia
  - Drug toxicity (e.g., chemotherapy)
  - Uremic encephalopathies

IMAGING

- General
  - Patchy parietooccipital cortical/subcortical edema in patient with severe acute/subacute HTN
- CT
  - Bilateral nonconfluent hypodense foci
  - ± symmetric lesions in basal ganglia
- MR
  - Parietooccipital T2/FLAIR hyperintensities in 95%
  - ± basal ganglia, pontine, cerebellar involvement
  - 3 patterns of hemorrhage: Focal parenchymal hemorrhage, microhemorrhages, convexity SAH
  - Generally no restriction on DWI
  - Variable patchy enhancement
  - However, atypical imaging patterns common

TOP DIFFERENTIAL DIAGNOSES

- Acute cerebral ischemia-infarction
- Status epilepticus
- Hypoglycemia
- Thrombotic microangiopathies (DIC, TTP, mHTN)

PATHOLOGY

- Acute HTN damages vascular endothelium
- Failed autoregulation causes blood-brain barrier disruption
- Result = vasogenic (not cytotoxic) edema

CLINICAL ISSUES

- Headache, seizure, ↓ mental status, visual symptoms
- Caution: Some patients may be normotensive or have only minimally elevated BP

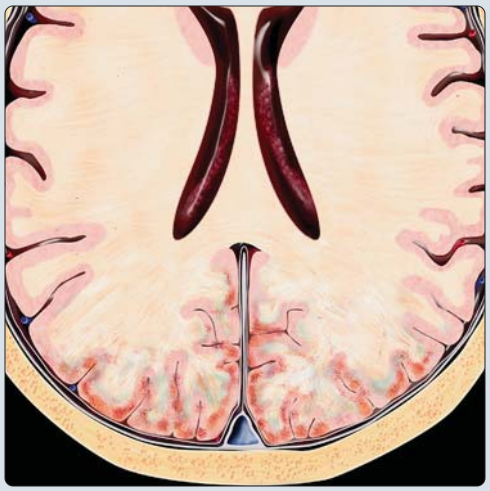

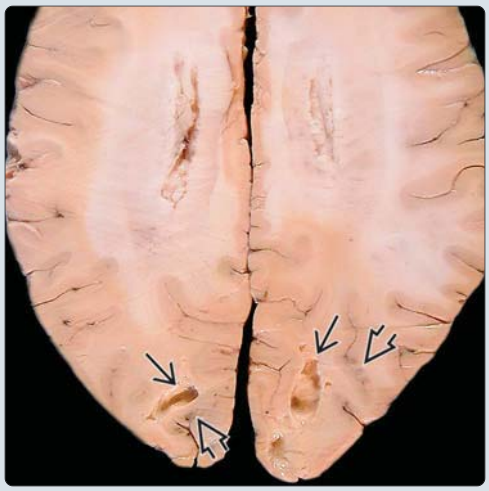

(Left) *Axial graphic shows the classic posterior circulation cortical/subcortical vasogenic edema characteristic of posterior reversible encephalopathy syndrome (PRES). Petechial hemorrhage occurs in some cases.* **(Right)** *Gross pathology of a patient with complicated PRES demonstrates diffuse cerebral edema with swollen gyri. Multifocal petechial microhemorrhages are present in the occipital cortex ⇨ with several areas of focal encephalomalacia secondary to infarction ⇨. (Courtesy R. Hewlett, MD.)*

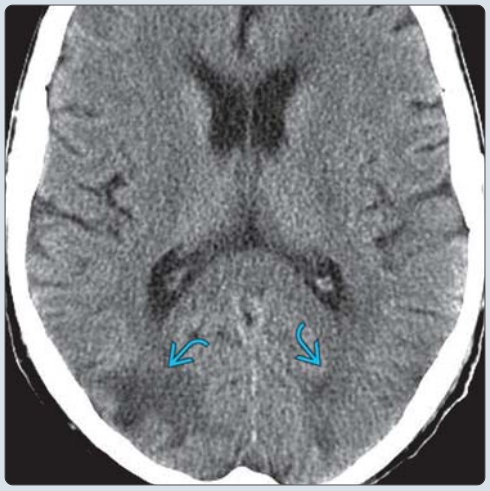

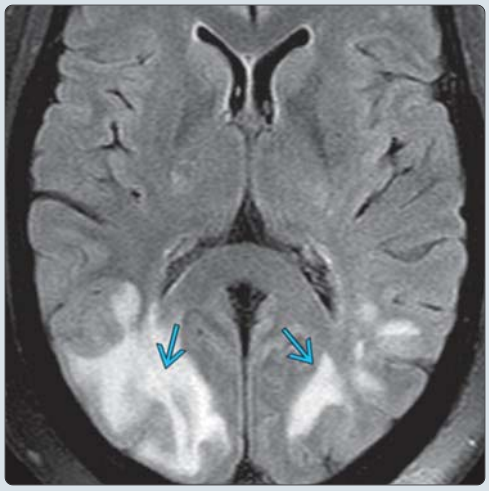

(Left) *Axial NECT in a 54-year-old patient with liver transplant on Tacrolimus FK 506 who presented with seizures demonstrates asymmetric subcortical edema in the occipital lobes bilaterally ⇨. Findings are typical of PRES.* **(Right)** *Axial FLAIR MR in a 20-year-old eclamptic woman who presented with severe hypertension, seizures, and altered sensorium shows classic findings of PRES with occipital cortical/subcortical edema ⇨. Her BP at presentation was 210/140.*

https://CafePezeshki.IR

TERMINOLOGY

Abbreviations

- Posterior reversible encephalopathy syndrome (PRES)

Synonyms

- Hypertensive encephalopathy
- Reversible posterior leukoencephalopathy syndrome (RPLS)

Definitions

- Variant of hypertensive encephalopathy characterized by headache, visual disturbances, altered mental function
- Cerebrovascular autoregulatory disorder
  - Multiple etiologies
  - Most caused by acute hypertension (HTN)

IMAGING

General Features

- Best diagnostic clue
  - Patchy parietooccipital cortical/subcortical edema in patient with severe acute/subacute HTN
- Location
  - Most common: Cortex, subcortical white matter
    - Parietooccipital lobes (85-95 %)
    - Frontal lobes (75-77%), temporal lobes (65%), cerebellum (50-55%)
    - At junctions of vascular watershed zones
    - Usually bilateral, often somewhat asymmetric
  - Less common: Basal ganglia
  - Rare: Predominant/exclusive brainstem involvement
- Size
  - Extent of abnormalities highly variable
- Morphology
  - Patchy > confluent; atypical patterns common

CT Findings

- NECT
  - May be normal or subtly abnormal
    - If PRES suspected, perform MR to confirm
  - Common: Bilateral nonconfluent hypodense foci
    - Posterior parietal, occipital lobes
    - Cortical watershed zones
  - Less common: Petechial cortical/subcortical or basal ganglionic hemorrhages
  - Uncommon: Thalamic, basal ganglia, brainstem, cerebellar hypodensities
- CECT
  - Usually no enhancement
  - Occasionally mild patchy/punctate enhancement
- CTA
  - Major vessels usually normal
  - Distal vessels may show diffuse vasoconstriction, focal irregularity, and beaded appearance

MR Findings

- T1WI
  - Hypointense cortical/subcortical lesions
- T2WI
  - **Typical** PRES: Hyperintense cortical/subcortical lesions
    - Parietooccipital lobes, cortical watershed zones
  - **Atypical** PRES: Almost as common as **typical** PRES
    - Frontal lobe, basal ganglia involvement
    - Extensive brainstem, cerebellar edema
- FLAIR
  - **Typical** PRES: Parietooccipital hyperintense cortical/subcortical lesions in 95%
  - **Atypical** PRES: Frontal lobe, basal ganglia, brainstem, cerebellar edema
  - "Leaky" blood-brain barrier may cause gadolinium accumulation in CSF, FLAIR hyperintensity
- T2* GRE
  - 3 patterns of hemorrhage: Focal parenchymal hemorrhage, microhemorrhages, convexity subarachnoid hemorrhage (SAH)
- DWI
  - Most common: No restriction
  - Less common: Hyperintense on DWI with "pseudonormalized" ADC
    - May indicate irreversible infarction
- PWI
  - May show ↑ rCBV
- T1WI C+
  - Variable patchy enhancement
- MRS
  - May show widespread metabolic abnormalities
    - ↑ Cho, Cr, mildly ↓ NAA
    - Usually return to normal within 2 months
- DTI
  - Shows foci of increased diffusivity and anisotropy loss
  - Vasogenic edema due to cerebrovascular autoregulatory dysfunction

Nuclear Medicine Findings

- SPECT
  - Variable findings reported; more common hypoperfusion in affected areas

Imaging Recommendations

- Best imaging tool
  - Contrast-enhanced MR + DWI
- Protocol advice
  - Repeat scan after blood pressure normalized

DIFFERENTIAL DIAGNOSIS

Acute Cerebral Ischemia-Infarction

- MCA distribution > > PCA
- Infarcts restrict on DWI; PRES usually does not

Status Epilepticus

- May cause transient gyral edema, enhancement
- Can mimic PRES, stroke, infiltrating neoplasm
- Unilateral (PRES often bilateral)

Hypoglycemia

- Severe parietooccipital edema
- Can resemble PRES, so history important

Thrombotic Microangiopathies

- Malignant hypertension, disseminated intravascular coagulation DIC, HUS, TTP
- Significant overlap as PRES common imaging manifestation

https://CafePezeshki.IR

Cerebral Hyperperfusion Syndrome

- Postcarotid endarterectomy, angioplasty, or stenting
  - Hyperperfusion syndrome occurs in 5-9% of cases
  - Perfusion MR imaging or CT scans show elevated rCBF
  - Aggressive control of blood pressure associated with clinical, radiological improvement

Gliomatosis Cerebri

- Entire lobe(s) involved
- Occipital lobe involvement less common
- Can mimic brainstem PRES

PATHOLOGY

General Features

- Etiology
  - Not yet completely understood
  - Diverse causes and clinical entities with acute HTN as common component
  - Acute HTN damages vascular endothelium
  - Failed autoregulation causes blood-brain barrier disruption
  - Result = vasogenic (not cytotoxic) edema
    - Arteriolar dilatation with cerebral hyperperfusion
    - Hydrostatic leakage (extravasation, transudation of fluid/macromolecules through arteriolar walls)
    - Interstitial fluid accumulates in cortex, subcortical white matter
    - Posterior circulation sparsely innervated by sympathetic nerves
      - Predilection for parietal, occipital lobes
  - Frank infarction with cytotoxic edema rare in PRES
- Associated abnormalities
  - Acute/subacute systemic HTN
  - Preeclampsia, eclampsia
    - Typically occurs after 20 weeks gestation
    - Rare: Headache, seizures up to several weeks post partum
  - Drug toxicity ± tumor lysis syndrome
    - Chemotherapeutic agents
      - e.g., cyclosporine, cisplatin
  - Thrombotic microangiopathies (DIC, TTP, malignant hypertension)
  - Uremic encephalopathies
    - Acute glomerulonephritis, lupus nephropathy, etc.
  - Severe infection
    - 25% of septic patients in shock develop PRES
    - Blood pressure can be normal or elevated

Gross Pathologic & Surgical Features

- Common
  - Cortical/subcortical edema
  - ± petechial hemorrhage in parietal, occipital lobes
- Less common
  - Anterior frontal lobes, basal ganglia, brainstem, cerebellum
- Uncommon
  - Lobar hemorrhage
  - Frank infarction

Microscopic Features

- Autopsy in severe cases shows microvascular fibrinoid necrosis, ischemic microinfarcts, variable hemorrhage
- Chronic: Demyelination, laminar necrosis, older hemorrhage

CLINICAL ISSUES

Presentation

- Most common signs/symptoms
  - Headache, seizure, ↓ mental status, visual disturbances
  - Caution: Some patients, especially children, may be normotensive or have only minimally elevated BP
- Clinical profile
  - Pregnant female with acute systemic HTN, headache ± seizure
  - Middle-aged, older adult on chemotherapy
  - Child with kidney disease or transplant

Demographics

- Age
  - Any, but young > old
- Gender
  - F >> M
- Epidemiology
  - Preeclampsia in 5% of pregnancies
  - Eclampsia has lower rate (< 1%)

Natural History & Prognosis

- Usually no residual abnormalities after HTN corrected
  - Reversibility related to blood pressure normalization
  - Brainstem, deep white matter lesions less reversible than cortical/subcortical
  - Eclampsia more reversible than drug-related PRES
- In rare cases, may be life threatening
- Permanent infarction rare
- 4% of patients develop recurrent PRES

Treatment

- Control blood pressure, remove precipitating factors
- Delayed diagnosis/therapy can result in chronic neurologic sequelae

DIAGNOSTIC CHECKLIST

Consider

- Patchy bilateral parietooccipital hypodensities may be earliest NECT manifestation of PRES

Image Interpretation Pearls

- Major DDx of PRES is cerebral ischemia; DWI is positive in latter, usually negative in former

SELECTED REFERENCES

1. Pereira PR et al: Clinical, imagiological and etiological spectrum of posterior reversible encephalopathy syndrome. Arq Neuropsiquiatr. 73(1):36-40, 2015
2. Gao B et al: Central-variant posterior reversible encephalopathy syndrome: more than meets the eye. AJR Am J Roentgenol. 203(4):W454, 2014
3. Junewar V et al: Neuroimaging features and predictors of outcome in eclamptic encephalopathy: a prospective observational study. AJNR Am J Neuroradiol. 35(9):1728-34, 2014
4. Rykken JB et al: Posterior reversible encephalopathy syndrome. Semin Ultrasound CT MR. 35(2):118-35, 2014

https://CafePezeshki.IR

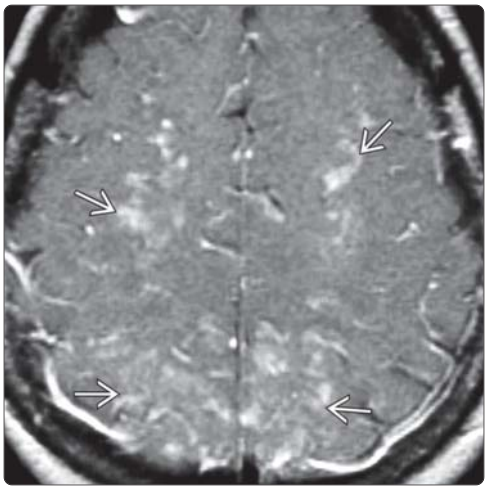

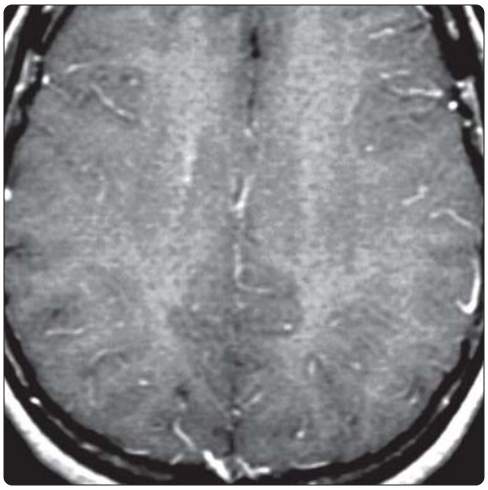

(Left) *Axial T1WI C+ MR in a patient with eclampsia shows numerous patchy cortical and subcortical enhancing foci in both occipital lobes and along the watershed zones. T2WIs (not shown) demonstrated hyperintensities in the same areas.* **(Right)** *Repeat scan was obtained 2 days after delivery and normalization of BP. MR is normal with the disappearance of the enhancing foci previously seen. Even florid MR changes of PRES usually resolve without clinical or imaging residua.*

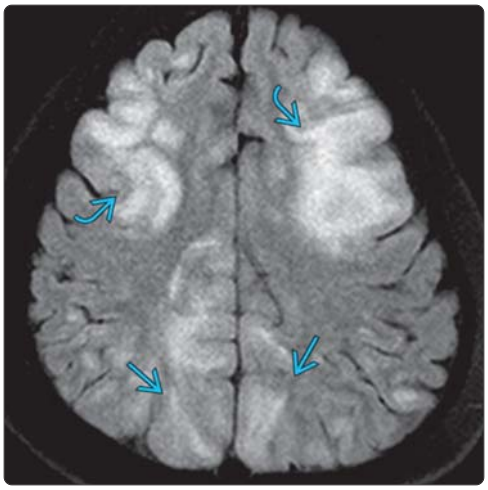

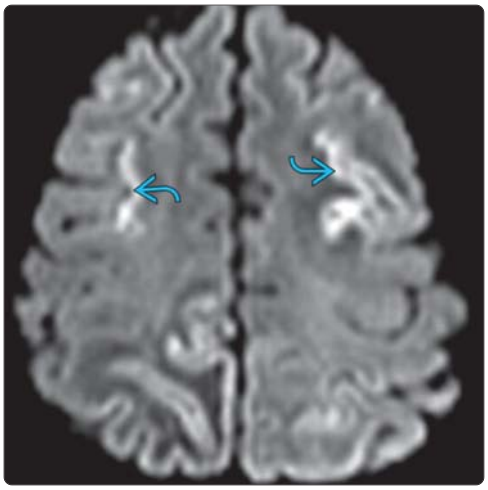

(Left) *Axial FLAIR MR in a patient with systemic lupus erythematosu (SLE) and renal failure demonstrates cortical/subcortical edema in the frontal and parietal lobes. The frontal lobes are involved in 75-7 % of PRES cases.* **(Right)** *Axial DWI in the same patient shows some patchy areas of frontal cortical restricted diffusion. Because most cases of PRES are caused by vasogenic and not cytotoxic edema DWI is usually negative. Diffusion restriction has been reported like in this case and may lead to residual abnormalities.*

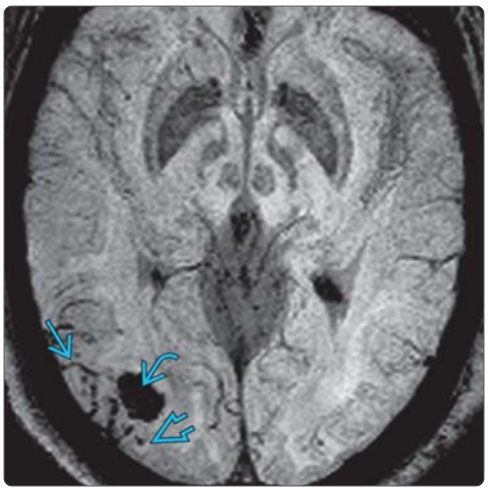

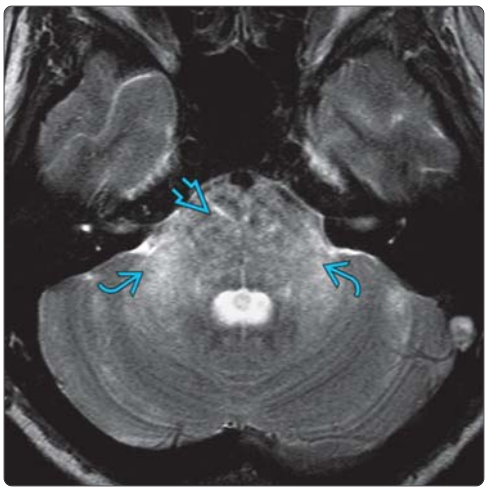

(Left) *Axial SWI in a hypertensive patient who presented with visual disturbances, headache, and seizures demonstrates the 3 pattern of hemorrhages which can be seen in PRES. This case shows lobar hemorrhage, cortical SAH, and microhemorrhages in the right occipital lobe.* **(Right)** *Axial T2 MR in a patient with sepsis and slightly elevated BP shows atypical findings of PRES. There is extensive edema involving the pons and both the middle cerebellar peduncles.*

https://CafePezeshki.IR

KEY FACTS

TERMINOLOGY

- Chronic hypertensive encephalopathy (CHE)
- Subcortical arteriosclerotic encephalopathy

IMAGING

- General features
  - Lacunae (lenticular nuclei, pons, thalamus, internal capsule, caudate)
  - Cerebral hemorrhage (basal ganglia/external capsule, thalamus)
  - Confluent WM disease (centrum semiovale, corona radiata)
- CT
  - Diffuse WM hypodensity on CT
  - Lacunar infarcts (BG, thalamus/brainstem)
- MR
  - Hyperintense lesions within corona radiata, centrum semiovale, basal ganglia
  - Multiple microhemorrhages (GRE, SWI)
    - Predilection for BG/thalami, brainstem, cerebellum
  - Acute WM lesions may restrict

TOP DIFFERENTIAL DIAGNOSES

- Amyloid angiopathy
- CADASIL
- Dementing disorders
  - Alzheimer dementia
  - Multi-infarct dementia
- Antiphospholipid antibody syndrome
- Neuropsychiatric systemic lupus erythematosus
- Vasculitis

PATHOLOGY

- Chronic HTN is associated with hyaline deposition within small arteries (so-called lipohyalinosis)

CLINICAL ISSUES

- Stepwise/gradual mental deterioration
- Acute strokes, lacunar syndrome

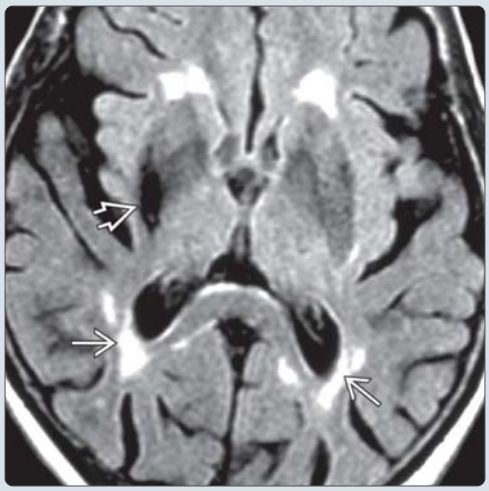

(Left) *Axial NECT shows the typical appearance of chronic hypertensive encephalopathy, seen here as diffuse confluent periventricular white matter hypodensity* ➡. **(Right)** *Axial FLAIR in a 72-year-old woman with longstanding systemic HTN demonstrates multifocal discrete and confluent hyperintensities scattered throughout the deep periventricular white matter, especially near the atria and occipital horns* ➡. *Note the old, hypertensive, basal ganglionic hemorrhage* ➡.

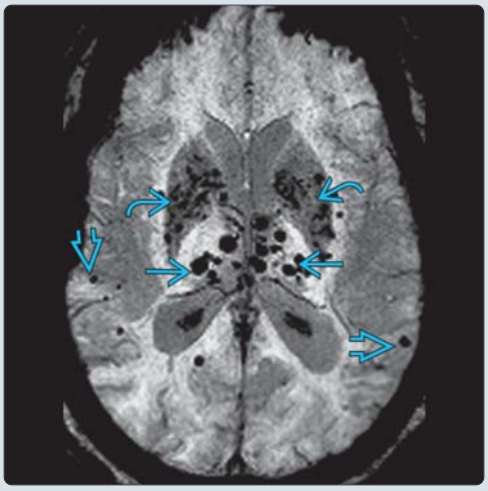

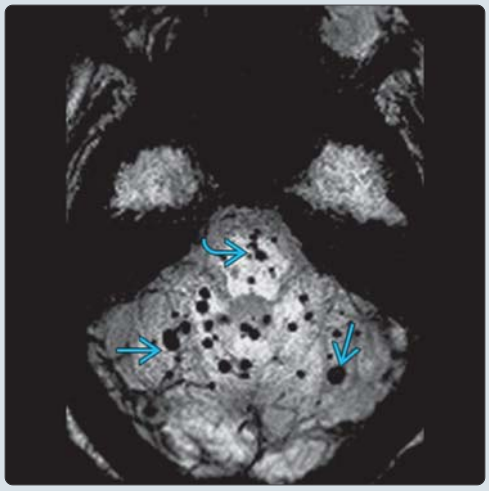

(Left) *Axial SWI image in a patient with long standing poorly controlled hypertension shows numerous microhemorrhages in the basal ganglia* ➡ *and thalami* ➡. *A few microhemorrhages are also seen in the subcortical white matter* ➡. **(Right)** *Axial SWI image in the same patient shows more microhemorrhages in the brainstem* ➡ *and both cerebellar hemispheres* ➡. *The distribution of these microhemorrhages is typical for chronic hypertensive encephalopathy.*

https://CafePezeshki.IR

TERMINOLOGY

Abbreviations

- Chronic hypertensive encephalopathy (CHE)

Synonyms

- Subcortical arteriosclerotic encephalopathy
  - a.k.a. Binswanger disease
- Hypertension-related microvascular disease

Definitions

- Brain parenchymal changes due to longstanding effects of untreated or poorly treated systemic hypertension (HTN)
  - CHE is most common cause of leukoaraiosis (diffuse rarefaction of white matter)
    - Others include diabetes
- CHE: Important cause of cognitive deficits caused by vascular disease (i.e., vascular dementia)

IMAGING

General Features

- Best diagnostic clue
  - 2 major features
    - Diffuse white matter (WM) lesions (hypodense on CT, hyperintense on T2WI)
    - Microhemorrhages ("bloom" on T2*)
- Location
  - WM lesions
    - Centrum semiovale, corona radiata
    - Brainstem, cerebellum
  - Gray matter lesions
    - Basal ganglia (BG), thalami, brainstem
  - Microhemorrhages
    - Basal ganglia/thalami, brainstem, cerebellum, subcortical WM
- Size
  - WM lesions initially small; may become confluent over time
- Morphology
  - Rounded or patchy, discrete or confluent

CT Findings

- NECT
  - Focal hypodensities (usually multiple)
    - BG, thalamus, brainstem
    - Often due to lacunar infarcts
  - Diffuse periventricular hypodensity
  - ± hyperdense lesions
    - Focal/confluent petechial hemorrhages

MR Findings

- T1WI
  - Lesions usually hypointense
    - Less conspicuous than on T2WI or FLAIR
- T2WI
  - Hyperintense lesions within corona radiata, centrum semiovale, basal ganglia
- FLAIR
  - Hyperintense or central hypointensities + peripheral hyperintensity
- T2* GRE
  - Multifocal hypointense lesions (microhemorrhages)
    - Predilection for BG/thalami, cerebellum
    - Subcortical WM (especially posterior brain regions)
- DWI
  - Acute WM lesions may restrict
  - ADC lower (acute) or higher (chronic)
- PWI
  - ↓ perfusion measurements in patients with confluent lesions
- T1WI C+
  - Generally no enhancement
- MRS
  - Older HTN patients have ↑ myoinositol to creatine ratio
    - Similar to patients with Alzheimer disease (AD)
  - Lower NAA levels in chronic hypertension
- DTI
  - ↑ mean diffusivity (MD), ↓ fractional anisotropy (FA)
    - Seen in both T2WI hyperintensities, normal-appearing WM

Nuclear Medicine Findings

- Frontal lobe (cingulate, superior frontal gyri) predominantly affected
- Regional CBF Tc-99m-HMPAO SPECT
  - Mild CHE: Reduced frontal CBF
  - Severe CHE: Diffuse cerebral hypoperfusion

Imaging Recommendations

- Best imaging tool
  - FLAIR (WM lesions) + T2* (GRE, SWI) for microhemorrhages

DIFFERENTIAL DIAGNOSIS

Amyloid Angiopathy

- Amyloid deposition in small/medium arteries of cerebral leptomeninges, cerebral cortex
- Recurrent cerebral hemorrhages, most common in frontal and parietal lobes, involving cortex and subcortical WM
- Rarely cerebellar, putaminal, thalamic, or brainstem

CADASIL

- Nonarteriosclerotic, amyloid-negative hereditary angiopathy primarily affecting leptomeningeal and long perforating arteries
- Characteristic subcortical lacunar infarcts and leukoencephalopathy in young adults
- Anterior temporal WM and external capsule lesions are highly suggestive of CADASIL

Various Dementias

- Alzheimer disease
  - Parietal and temporal cortical atrophy, volume loss in hippocampi, entorhinal cortex
  - Often coexisting microvascular disease, WM hyperintensities
- Multi-infarct dementia
  - Hyperintense lesions on T2WI and focal atrophy suggestive of chronic infarcts

Antiphospholipid Antibody Syndrome

- Early stroke, recurrent arterial and venous thromboses, spontaneous fetal loss, thrombocytopenia

https://CafePezeshki.IR

Systemic Lupus Erythematosus (SLE)

- Most common: Small multifocal WM lesions; usually diagnosed in 3rd or 4th decade (earlier than in CHE)
- Periventricular or more diffuse WM changes

Other Vasculitides

- Primary angiitis of CNS
- Granulomatous angiitis
- Polyarteritis nodosa, Behçet disease

Pseudoxanthoma Elasticum

- Systemic HTN, subcortical leukoencephalopathy, multiple strokes, and dementia in 3rd and 4th decades (younger than CHE patients)

PATHOLOGY

General Features

- Etiology
  - Chronic HTN is associated with hyaline deposition within small arteries (so-called lipohyalinosis)
  - 2 major mechanisms postulated for leukoaraiosis related to lipohyalinosis
    - Chronic hypoperfusion may cause ischemia of small brain regions, which later coalesce into large abnormal WM regions
    - Increased permeability of blood vessels may allow leakage of plasma contents
  - Chronic HTN impairs dilatation of collateral vessels in cerebral circulation
    - Impaired cerebral autoregulation and decreased vasodilatory capacity; ↑ susceptibility to cerebral infarction
- Associated abnormalities
  - Over time, lesions continue to accumulate, principally within subcortical WM
  - Various genetic factors, including DNA sequence variations occurring within single nucleotide (single-nucleotide polymorphisms), appear to place some patients at increased risk
  - Patients with HTN may also develop large parenchymal hemorrhages

Gross Pathologic & Surgical Features

- Demyelination of periventricular and central WM
- Multiple lacunae and infarctions
- Tortuosity of small arteries and small artery occlusions

Microscopic Features

- Multiple petechial microhemorrhages
- Leukoaraiosis: Partial loss of myelin, axons, oligodendroglia, glial cells
- Alterations of small penetrating arteries leading to luminal stenosis

CLINICAL ISSUES

Presentation

- Most common signs/symptoms
  - Usually seen in middle-aged or elderly
    - Memory loss, depression, various features of dementia
  - Long tract findings, pseudobulbar syndrome
- Other signs/symptoms
  - Risks: Hypertensive hemorrhage, acute hypertensive encephalopathy (posterior reversible encephalopathy syndrome)
- Clinical profile
  - Stepwise or gradual progression of mental deterioration
  - Acute strokes, lacunar syndrome
  - Subacute onset of focal, pseudobulbar, and extrapyramidal signs

Demographics

- Age
  - Incidence increases with age
- Gender
  - HTN more prevalent in men than women
- Ethnicity
  - HTN more prevalent in African Americans
- Epidemiology
  - In addition to HTN, higher prevalence in patients with diabetes mellitus and peritoneal dialysis for renal failure

Natural History & Prognosis

- Arteriolosclerosis associated with systemic HTN and increasing age
  - Small vessel occlusive changes are primary factor in pathogenesis of hyperintense WM lesions on T2WI in elderly
- Periventricular hyperintense WM lesions
  - Increased in patients with untreated systemic HTN
- Age, smoking, and HTN are independent predictors of hyperintense lesions on T2WI
- Untreated or poorly controlled systemic HTN → intracranial hemorrhages usually involving BG, thalamus, brainstem, or dentate nucleus of cerebellum
- CHE eventually causes vascular-type dementia

DIAGNOSTIC CHECKLIST

Consider

- Is history of chronic hypertension present
  - Many disease states have imaging findings like CHE

Image Interpretation Pearls

- SWI superior sensitivity for chronic microhemorrhages compared to T2*GRE

SELECTED REFERENCES

1. Prins ND et al: White matter hyperintensities, cognitive impairment and dementia: an update. Nat Rev Neurol. 11(3):157-165, 2015
2. van Dalen JW et al: Cortical microinfarcts detected in vivo on 3 Tesla MRI: clinical and radiological correlates. Stroke. 46(1):255-7, 2015
3. Marsh EB et al: Predicting symptomatic intracerebral hemorrhage versus lacunar disease in patients with longstanding hypertension. Stroke. 45(6):1679-83, 2014
4. Ritz K et al: Cause and mechanisms of intracranial atherosclerosis. Circulation. 130(16):1407-14, 2014
5. Cheng AL et al: Susceptibility-weighted imaging is more reliable than T2*-weighted gradient-recalled echo MRI for detecting microbleeds. Stroke. 44(10):2782-6, 2013
6. Wardlaw JM et al: Mechanisms of sporadic cerebral small vessel disease: insights from neuroimaging. Lancet Neurol. 12(5):483-97, 2013

https://CafePezeshki.IR

(Left) *Axial NECT demonstrates frontal and parietal periventricular confluent white matter hypodensities* ➡ *in a patient with chronic hypertensive encephalopathy and clinical Binswanger disease.* **(Right)** *Axial NECT slice through corona radiata in the same patient shows bilateral confluent hypodense lesions* ➡. *These findings are sometimes termed "subcortical arteriosclerotic encephalopathy."*

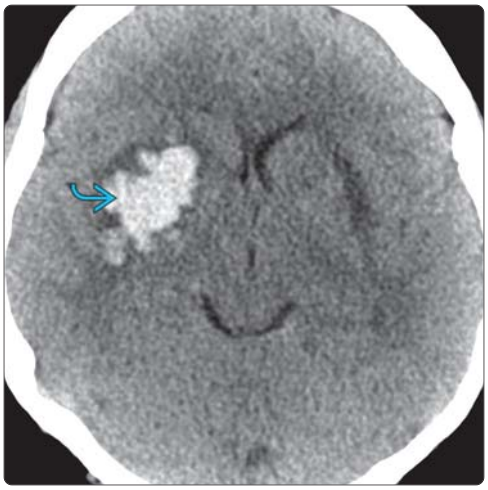

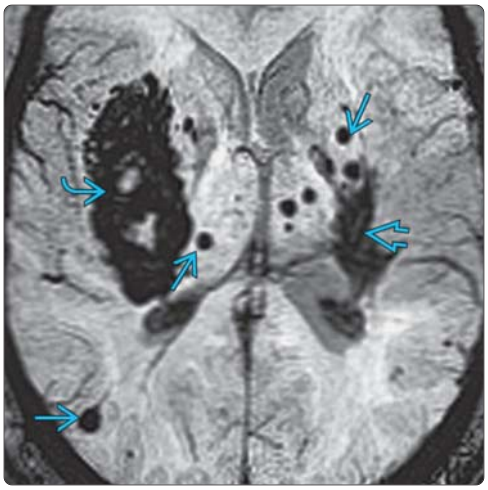

(Left) *Axial NECT shows classic location of an acute hypertensive hemorrhage* ➡ *involving the lateral aspect of the putamen and external capsule.* **(Right)** *Axial SWI in the same patient shows the acute right basal ganglionic hemorrhage* ➡ *and in addition findings of chronic hypertensive encephalopathy. There are microhemorrhages* ➡ *in the basal ganglia, thalami and subcortical white matter. Hemosiderin staining due to an old hemorrhage is seen in the left basal ganglia* ➡.

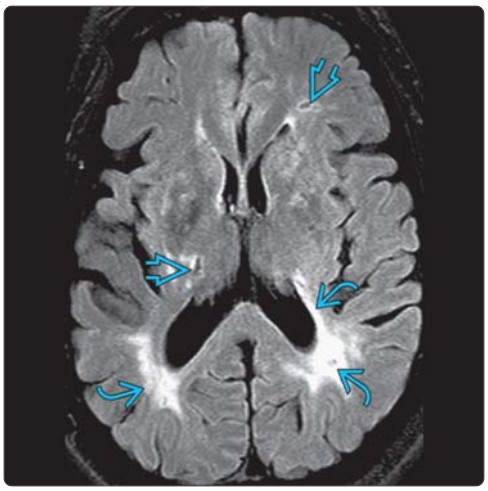

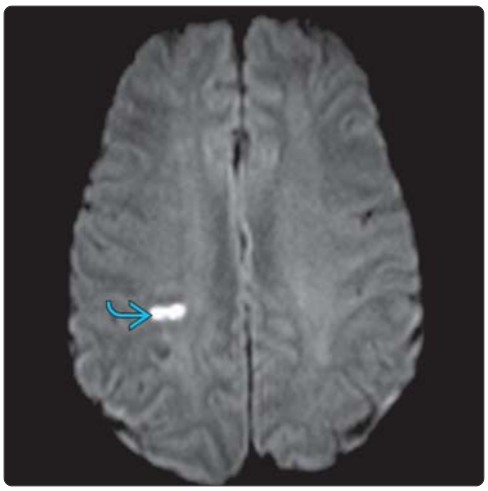

(Left) *Axial FLAIR MR in a patient with chronic hypertensive encephalopathy shows focal and confluent hyperintensities* ➡ *involving periventricular and deep white matter regions. Also noted are multiple old lacunar infarcts* ➡. **(Right)** *Axial DWI in the same patient shows a focal area of restricted diffusion in the right centrum semiovale* ➡ *consistent with a small acute infarct.*

https://CafePezeshki.IR

KEY FACTS

TERMINOLOGY

- Idiopathic intracranial hypertension (IIH)
- Pseudotumor cerebri
- Benign intracranial hypertension
- ↑ intracranial pressure (ICP) without identifiable cause

IMAGING

- Empty or partially empty sella
- Posterior globe flattening
- Intraocular protrusion of optic nerve head
- Optic nerve sheath enlargement: Widened ring of CSF around optic nerve
- Optic nerve tortuosity
- Slit-like ventricles, rare: Poor neuroimaging sign of IIH
- MRV: Often shows transverse sinus stenosis and "flow gaps"
  - Whether this is cause or consequence of raised ICP is controversial
- Best imaging tool: MR brain + T2 coronal fat-sat orbit + MRV

TOP DIFFERENTIAL DIAGNOSES

- Secondary pseudotumor syndromes
- Idiopathic or post-inflammatory (i.e., multiple sclerosis) optic nerve atrophy
- Idiopathic empty sella (normal variant)

CLINICAL ISSUES

- Obese woman age 20-44 years with headache and papilledema most common presentation
  - Headache in 90-95%
  - Papilledema (bilateral optic nerve head swelling) virtually universal
- Progressive visual loss ± CN6 paresis, diplopia
- Chief hazard: Vision loss from chronic papilledema
- Treatment: Medical or surgical (LP, shunt, optic nerve sheath fenestration)

(Left) *Axial T2WI MR shows dilated CSF spaces around the optic nerves ⇨ and protrusion of the optic nerve papilla into the posterior globes ⇨. Opening CSF pressure in this 32-year-old woman was 45 cm of H_2O. Prominent CSF space in the suprasellar cistern represents an empty sella ⇨. Note the tortuosity of the left optic nerve.* **(Right)** *Sagittal T1WI MR in the same patient shows a partially empty sella ⇨, suggesting high CSF pressure in this young obese woman with headaches.*

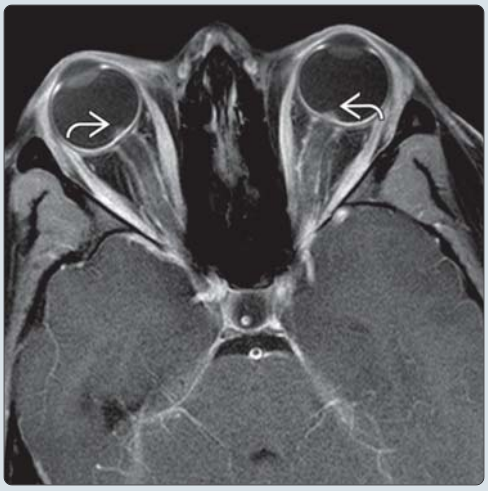

(Left) *Axial T1WI C+ MR in the same patient demonstrates enhancement, as well as protrusion of prelaminar optic nerves bilaterally ⇨. Mild diffuse optic nerve sheath enhancement is also present.* **(Right)** *Coronal T1WI C+ FS MR in the same patient shows diffuse enhancement of the optic nerve sheaths ⇨ associated with prominent subarachnoid spaces along the optic nerves. Treatment for pseudotumor cerebri includes weight loss and medications, as well as lumbar punctures, shunt, and optic nerve fenestration.*

https://CafePezeshki.IR

TERMINOLOGY

Abbreviations

- Idiopathic intracranial hypertension (IIH)
- Pseudotumor cerebri (PTC)

Synonyms

- Pseudotumor cerebri
- Benign intracranial hypertension

Definitions

- ↑ intracranial pressure (ICP) without identifiable cause
- Association of any medication or condition with IIH better termed "secondary pseudotumor syndrome"

IMAGING

General Features

- Best diagnostic clue
  - Flattening of posterior sclera, intraocular optic nerve protrusion, enlarged optic nerve sheath, increased tortuosity of optic nerve, partially empty sella, and venous sinus stenosis in patient with clinical findings of IIH
- Imaging in IIH
  - Exclude identifiable causes of ↑ ICP
  - Detect findings associated with IIH

CT Findings

- NECT
  - Usually normal
  - Enlarged optic nerve sheaths ± empty sella
  - Less common: Slit ventricles

MR Findings

- T1WI
  - Partially empty sella turcica
  - Enlarged/tortuous optic nerve sheaths
  - Posterior sclera flattened
  - Small "pinched" ventricles
  - Midline sagittal: Cerebellar tonsillar ectopia may mimic Chiari malformation type I
- T2WI
  - Empty or partially empty sella
  - Posterior globe flattening
  - Intraocular protrusion of optic nerve head
  - Optic nerve sheath enlargement: Widened ring of CSF around an optic nerve
  - Optic nerve tortuosity
  - Slit-like ventricles, rare: Poor neuroimaging sign of IIH
- T1WI C+
  - Enhancement of prelaminar optic nerve
- MRV
  - Often shows transverse sinus stenosis and "flow gaps"
  - Whether this is cause or consequence of raised ICP is controversial
- CTV
  - CT venogram helpful to differentiate hypoplastic sinus segment from thrombosis

Imaging Recommendations

- Best imaging tool
  - MR brain + T2 coronal fat-sat orbit + MRV

DIFFERENTIAL DIAGNOSIS

Secondary Pseudotumor Syndromes

- Cerebral venous abnormalities
  - Dural venous sinus thrombosis, bilateral jugular vein thrombosis, superior vena cava syndrome, arteriovenous fistula
  - Decreased CSF absorption from previous intracranial infection or subarachnoid hemorrhage, hypercoagulable states
- Medications and exposures
  - Tetracycline, minocycline, vitamin A, lithium, retinoids, anabolic steroids, withdrawal from chronic corticosteroids
- Medical conditions
  - Endocrine disorders (Addison disease, hypoparathyroidism), hypercapnia, sleep apnea, SLE

Idiopathic or Post-Inflammatory Optic Nerve Atrophy

- Small optic nerves without scleral flattening

Idiopathic Empty Sella

- Normal variant; normal optic nerve sheaths

Chiari I Malformation

- Peg-like tonsils ≥ 5 mm below the foramen magnum
- Low cerebellar tonsils in IIH may mimic Chiari I: Look for other neuroimaging signs of IIH and clinical findings (papilledema)

PATHOLOGY

General Features

- Etiology
  - Precise etiology of IIH unknown
  - 5 different proposed mechanisms resulting in ↑ ICP
    - ↑ cerebral volume
      - Possible etiology: ↑ interstitial fluid, ↑ blood volume, ↑ tissue volume
    - ↑ CSF volume
      - Possible etiology: ↑ CSF production rate, ↑ CSF outflow resistance
    - ↑ cerebral arterial pressure
      - Possible etiology: Loss of cerebral autoregulation
    - ↑ venous blood volume and interstitial fluid
      - Possible etiology: ↑ cerebral venous pressure
    - ↓ CSF outflow and ↑ CSF volume

Gross Pathologic & Surgical Features

- Bilateral papilledema

Microscopic Features

- Normal CSF cytology, chemistry

CLINICAL ISSUES

Presentation

- Most common signs/symptoms
  - Headache in 90-95%

https://CafePezeshki.IR

Diagnostic Criteria for Pseudotumor Cerebri Syndrome

1. Required for Diagnosis of Pseudotumor Cerebri Syndrome
A. Papilledema
B. Normal neurologic examination except for cranial nerve abnormalities
C. Neuroimaging: Normal brain parenchyma without evidence of hydrocephalus, mass, or structural lesion and no abnormal meningeal enhancement on MR, ± gadolinium, for typical patients (female and obese), and MR, ± gadolinium, and magnetic resonance venography for others; if MR is unavailable or contraindicated, contrast-enhanced CT may be used
D. Normal CSF composition
E. Elevated lumbar puncture opening pressure (> 250 mm CSF in adults and > 280 mm CSF in children [250 mm CSF if the child is not sedated and not obese]) in properly performed lumbar puncture
2. Diagnosis of Pseudotumor Cerebri Syndrome Without Papilledema
In absence of papilledema, a diagnosis of pseudotumor cerebri syndrome can be made if B–E from above are satisfied, and in addition the patient has unilateral or bilateral abducens nerve palsy
In absence of papilledema or 6th nerve palsy, diagnosis of pseudotumor cerebri syndrome can be suggested but not made if B–E from above are satisfied, and in addition at least 3 of the following neuroimaging criteria are satisfied
i. Empty sella
ii. Flattening of posterior aspect of globe
iii. Distention of perioptic subarachnoid space ± tortuous optic nerve
iv. Transverse venous sinus stenosis
Diagnosis of pseudotumor cerebri syndrome is definite if patient fulfills criteria A-E. The diagnosis is considered probable if criteria A-D are met, but the measured CSF pressure is lower than specified for a definite diagnosis.

Liguori C et al. Revised diagnostic criteria for the pseudotumor cerebri syndrome in adults and children. Neurology. 2014 May 13;82(19):1752-3.

  - Generalized, episodic, throbbing, aggravated by Valsalva
  - Papilledema (bilateral optic nerve head swelling) virtually universal
  - Progressive visual loss ± CN6 paresis, diplopia
  - Uncommon: Vertigo, tinnitus, occasional pituitary disfunction
  - In children: Irritability, "sunset" sign, bulging anterior fontanelle
- Clinical profile
  - Obese, young to middle-aged woman with headache, papilledema

Demographics

- Age
  - Peak = 15-40 years (occasionally seen in children)
- Gender
  - M:F = 1:4-8
- Epidemiology: ↑ prevalence with obesity

Natural History & Prognosis

- Chief hazard: Vision loss from chronic papilledema

Treatment

- Goal: Prevent visual loss, improve associated symptoms
- Options
  - Medical
    - Weight loss
    - Carbonic anhydrase inhibitors: cetazolamide
  - Therapeutic lumbar puncture
  - Surgical: Reserved for patients who continue to experience vision loss despite conservative management and those initially presenting with rapid vision loss
    - Lumboperitoneal shunt
    - Optic nerve sheath fenestration
  - Venous stent placement
    - Stent placement in transverse sinus stenosis with significant pressure differentials across stenosis has shown to improve symptoms and reduce papilledema
    - ↓ cerebral venous pressure, improve CSF resorption in venous system: ↓ intracranial (CSF) pressure, improving symptoms of IIH and ↓ papilledema
    - Venous stent placement is controversial

DIAGNOSTIC CHECKLIST

Image Interpretation Pearls

- Must exclude venous thrombosis/space-occupying lesion

SELECTED REFERENCES

1. Görkem SB et al: MR imaging findings in children with pseudotumor cerebri and comparison with healthy controls. Childs Nerv Syst. 31(3):373-80, 2015
2. Masri A et al: Intracranial Hypertension in Children: Etiologies, Clinical Features, and Outcome. J Child Neurol. ePub, 2015
3. Ahmed RM et al: Transverse sinus stenting for pseudotumor cerebri: a cost comparison with CSF shunting. AJNR Am J Neuroradiol. 35(5):952-8, 2014
4. Dave SB et al: Pseudotumor cerebri: an update on treatment options. Indian J Ophthalmol. 62(10):996-8, 2014
5. Liguori C et al: Revised diagnostic criteria for the pseudotumor cerebri syndrome in adults and children. Neurology. 82(19):1752-3, 2014
6. Passi N et al: MR imaging of papilledema and visual pathways: effects of increased intracranial pressure and pathophysiologic mechanisms. AJNR Am J Neuroradiol. 34(5):919-24, 2013
7. Aiken AH et al: Incidence of cerebellar tonsillar ectopia in idiopathic intracranial hypertension: a mimic of the Chiari I malformation. AJNR Am J Neuroradiol. 33(10):1901-6, 2012
8. Ahmed RM et al: Transverse sinus stenting for idiopathic intracranial hypertension: a review of 52 patients and of model predictions. AJNR Am J Neuroradiol. 32(8):1408-14, 2011
9. Degnan AJ et al: Pseudotumor cerebri: brief review of clinical syndrome and imaging findings. AJNR Am J Neuroradiol. 32(11):1986-93, 2011

https://CafePezeshki.IR

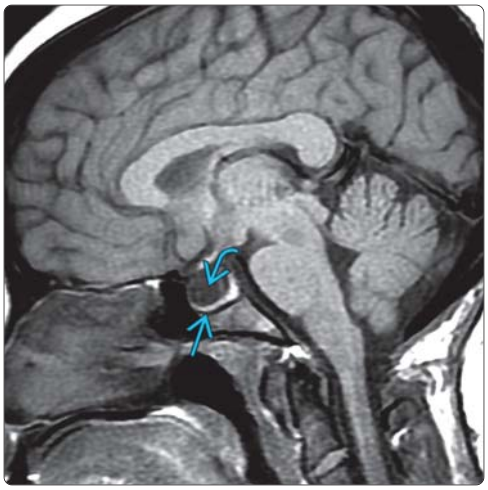

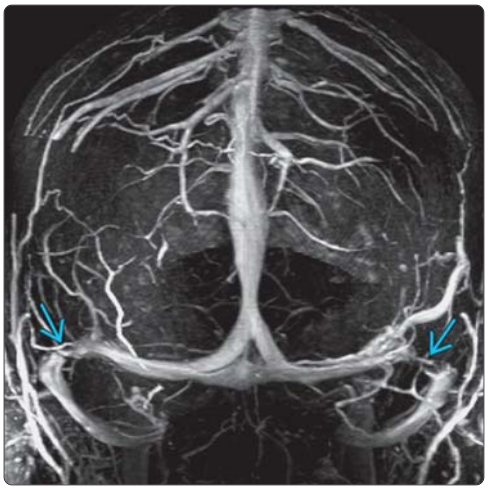

(Left) *Sagittal T1 MR in a patient with idiopathic intracranial hypertension shows a partially empty sella with the pituitary gland flattened along the floor of the sella.* **(Right)** *MIP image of a post-contrast MR venogram study in the same patient shows stenosis of the distal transverse sinuses bilaterally. Transverse sinus stenosis is common in patients with IIH.*

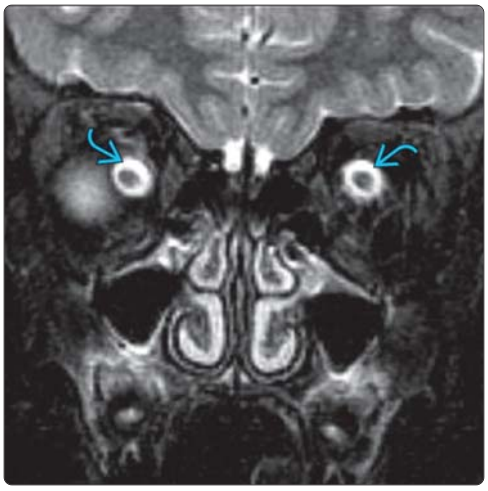

(Left) *Coronal T2 FS MR of orbits in a 6 year old with papilledema and opening CSF pressure of 32 of H_2O shows dilated optic nerve sheaths bilaterally.* **(Right)** *Sagittal T2 FS MR in the same patient shows tortuosity of the optic nerve, dilated optic nerve sheath, flattening of the posterior sclera, and mild bulging of the optic nerve disc head due to papilledema. Findings are typical of idiopathic intracranial hypertension (IIH). Childhood obesity has a strong association with an increased risk of pediatric IIH.*

(Left) *Axial T2WI MR in a young obese female with headaches and visual symptoms shows mild dilatation of the CSF spaces around the optic nerves. There is mild flattening of the posterior sclera and minimal protrusion of the optic nerve papilla into the posterior globe.* **(Right)** *3D TOF-MR venogram image in the same patient shows stenosis in the distal transverse sinuses bilaterally. Stent placement in sinus stenosis with significant pressure differentials has shown to reduce papilledema.*

https://CafePezeshki.IR

KEY FACTS

TERMINOLOGY

- Anoxic-ischemic encephalopathy, usually with bilateral lesions, caused by inhalation of carbon monoxide (CO) gas

IMAGING

- Best diagnostic clue: Globi pallidi (GP) T2/FLAIR hyperintensity
- T1 MR: Both hypointensity in GP (likely necrosis) and hyperintensity in GP (likely hemorrhage) reported
- T2 MR: Ischemia/infarct of GP
  - Cerebral hemispheric WM: Bilateral confluent hyperintense WM (periventricular, centrum semiovale)
  - Cortical hyperintensity (commonly temporal lobe)
  - Medial temporal lobe hyperintensity (uncommon despite frequent pathologic findings)
- DWI MR: Acute restriction is common
- MRS: Progressively ↓ NAA/Cr with time; ↑ Cho/Cr
  - Progressively ↑ Lac/Cr with time

TOP DIFFERENTIAL DIAGNOSES

- Wilson disease
- Japanese encephalitis (JE)
- Creutzfeldt-Jakob disease (CJD)

PATHOLOGY

- Impairs the ability of erythrocytes to transport oxygen, causing hypoxia and reducing cellular oxygen metabolism
- CO-induced parkinsonism
- Demyelination, edema, and hemorrhagic necrosis

CLINICAL ISSUES

- Acute toxicity: Nausea, vomiting, headache
- Neuropsychological sequelae
- Hyperbaric oxygen (HBO) therapy: Treatment of choice in acute carbon monoxide poisoning (COP) (within 6 hours for best effect)
- Delayed neurologic sequelae (10-30% of victims)

(Left) *Axial graphic shows the typical involvement of the brain by CO poisoning. The globi pallidi (GP) ⇨ are most affected, followed by the cerebral white matter. Pathologically, there is necrosis of the GP with variable areas of necrosis and demyelination in the white matter.* **(Right)** *Axial FLAIR MR in this patient with acute CO poisoning shows the classic appearance with symmetric GP hyperintensity. Note the additional involvement of the posterior temporal cortex ⇨ and hippocampi ⇨, a less common finding.*

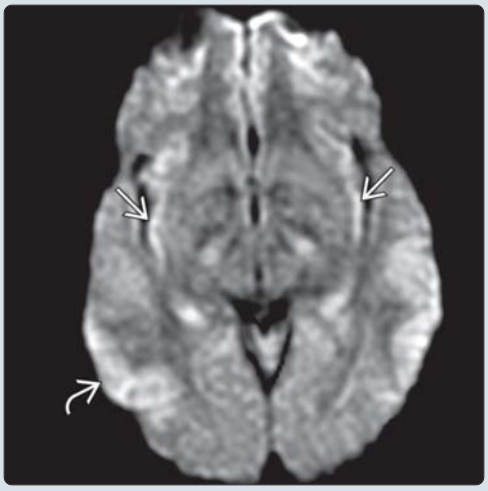

(Left) *Axial DWI MR in the same patient shows areas of restricted diffusion involving the posterior temporal cortex ⇨, hippocampal tail, and insular cortex ⇨ bilaterally. DWI often shows the affected areas more readily than corresponding T2 or FLAIR MR images.* **(Right)** *Axial FLAIR MR in the same patient shows symmetric hyperintensity involving the bilateral hippocampi ⇨ and posterior temporal cortex ⇨.*

https://CafePezeshki.IR

TERMINOLOGY

Abbreviations

- Carbon monoxide (CO) poisoning (COP)

Definitions

- Anoxic-ischemic encephalopathy, usually with bilateral lesions, caused by inhalation of CO gas

IMAGING

General Features

- Best diagnostic clue
  - Globi pallidi (GP) hyperintensity on T2WI or hypodensity on CT
- Location
  - GP: Most common site of abnormality
  - Cerebral white matter (WM): 2nd most common
  - Putamen, caudate nucleus, thalamus, substantia nigra, corpus callosum, fornix, hippocampus: Less common
- Morphology
  - Typically oval lesions confined to GP
  - Severe changes show loss of gray-white differentiation due to diffuse edema

CT Findings

- NECT
  - Symmetric hypodensity in GP and symmetric diffuse hypodensity in cerebral WM

MR Findings

- T1WI
  - In GP, both T1 hypointensity (likely due to necrosis) and T1 hyperintensity (likely due to hemorrhage) reported
- T2WI
  - Ischemia/infarct of GP
    - Bilateral T2 hyperintensities of GP surrounded by hypointense rim (likely due to hemosiderin)
    - Caudate nucleus and putamen may be affected, either alone or in addition to GP abnormality
  - Cerebral hemispheric WM: Bilateral, confluent, T2 hyperintense WM (periventricular, centrum semiovale)
    - Reflects diffuse demyelination
  - Abnormal signal in cerebral cortex (less frequent)
    - Cortical hyperintensity: Most common pattern, with predilection for temporal lobe
    - Abnormalities in perisylvian cortex, anterior temporal lobe, and insular cortex
    - Asymmetrical, diffuse cortical hyperintensity affecting parietal and occipital lobes also possible
  - Medial temporal lobe in region of hippocampus may show signal abnormality
    - Uncommon despite frequent pathological findings
  - Diffuse, bilateral high signal within cerebellar hemispheres, affecting cortex and WM
    - Not seen in acute setting; develops later
  - Delayed encephalopathy 2-3 weeks after recovery
    - Additional high intensity in corpus callosum, subcortical U-fibers, internal and external capsules
    - Associated with low intensity in thalamus and putamen (due to iron deposition)
- FLAIR
  - Same as T2WI
  - Additional periventricular high signal in acute COP
    - May not be visible on conventional T2 FSE
- DWI
  - Early (acute) stage of COP
    - Diffuse symmetric DWI hyperintensity in subcortical hemispheric WM (restricted diffusion due to cytotoxic edema)
      - WM may appear normal on FLAIR, particularly in low-dose exposure
    - Corresponding ADC maps: Low ADC values in same regions
  - Delayed stage of COP (weeks post exposure)
    - High signal area in cerebral WM
    - ± abnormal WM findings on T2WI
    - Low ADC values persist at this stage
  - Chronic stage of COP
    - Gradual increase in ADC values, consistent with macrocystic encephalomalacia
    - Hyperintense WM areas on T2WI and symmetric bright lesions in GP
  - Diffusion tensor imaging (DTI): FA values decreased in deep white matter including centrum semiovale
    - High correlation between FA and Mini-Mental State Examination
- T1WI C+
  - Variable enhancement in GP, often in patients with acute COP
- MRS
  - Serial ^{1}H-MRS scans performed after appearance of delayed sequelae in COP, disturbances of neuronal function, membrane metabolism, and anaerobic energy metabolism
    - Persistently ↑ Cho/Cr at DWI abnormal WM site
    - Progressively ↓ NAA/Cr with time
      - ↓ NAA suggests neuron and axon degeneration
    - Progressively ↑ Lac/Cr with time, often seen in high-dose exposure cases

Nuclear Medicine Findings

- SPECT studies show cerebral hypoperfusion deficits
  - ↓ regional cerebral blood flow in frontal and temporal cortices and diffuse hypoperfusion defects have been reported

Imaging Recommendations

- Best imaging tool
  - MR more sensitive than CT for detection of brain abnormalities following COP
  - DWI best for lesion detection in acute stage of COP
- Protocol advice
  - Multiplanar MR including DWI

DIFFERENTIAL DIAGNOSIS

Wilson Disease

- WM/GM lesions, involving BG, dentate nucleus, pons, mesencephalon
- T1 hypointense (occasionally hyperintense) lesions
- Variably T2 hyperintense/hypointense

https://CafePezeshki.IR

Japanese Encephalitis (JE)

- Homogeneous T2 hyperintensities in BG and thalami
- Most characteristic finding in JE
  - Bilateral thalamic hyperintensities ± hemorrhage
- JE is meningoencephalitis → meningeal enhancement

Creutzfeldt-Jakob Disease (CJD)

- Progressively symmetric hyperintense changes in BG, thalami, cerebral cortex
- DWI and FLAIR most sensitive

Leigh Syndrome

- Symmetrical spongiform brain lesions with onset in infancy/early childhood
- Lesions predominantly in brainstem, BG (particularly putamen), and cerebral WM
- Focal, bilateral, and symmetric T2 hyperintense lesions

PATHOLOGY

General Features

- Etiology
  - CO: Colorless, odorless, tasteless gas
  - 200x affinity for hemoglobin than O_2
  - Brain and heart damage once CO-Hgb level exceeds 20%
  - Mechanisms of brain injury
    - Impairs ability of erythrocytes to transport oxygen, causing hypoxia and reducing cellular oxygen metabolism
    - Lipid peroxidation leading to oxidative injury
    - Damage to vascular endothelium due to deposition of peroxynitrite
    - Excitotoxicity, apoptosis
- Associated abnormalities
  - CO-induced parkinsonism
    - GP lesions after COP or periventricular and deep WM hyperintensities without BG lesions
    - Extrapyramidal syndrome may be due to lesions of WM areas containing BG output &/or input
    - Improvement usually accompanied by ↓ extent and signal intensity of WM abnormalities, especially in frontoparietal centrum semiovale

Staging, Grading, & Classification

- 4 main pathological types
  - GP lesions: Variable degree of necrosis
  - WM lesions: Scattered/focal areas of necrosis or confluent areas of demyelination
  - Cortical lesions: Spongy changes, intense capillary proliferation, degeneration, and loss of neurons
  - Hippocampal lesions: Coagulation necrosis

Gross Pathologic & Surgical Features

- GP necrosis, WM pallor

Microscopic Features

- Demyelination, edema, and hemorrhagic necrosis
  - Necrotic lesions in GP, other BG, hippocampus, cortex, and cerebellum
  - WM lesions: Foci of necrosis or demyelination

CLINICAL ISSUES

Presentation

- Most common signs/symptoms
  - Nonspecific symptoms; controversial association of specific symptoms with known CO-Hgb levels
  - Acute toxicity: Nausea, vomiting, headache
    - Confusion, cognitive impairment, loss of consciousness, seizures, coma, death
  - Neuropsychological sequelae
    - Dementia, memory deficits, decreased attention, irritability, mood and personality disturbance
    - Gait disturbance, parkinsonian-like symptoms, apraxia, convulsive disorders, visual-spatial and speech impairment
- Clinical profile
  - Depends on duration and intensity of exposure

Demographics

- Age
  - Equivalent age-specific fatality rates in adults, death rates from COP: ↑ in patients > 65 years
- Epidemiology
  - Most common cause of accidental poisoning in Europe and North America
  - Causes 2-6,000 deaths/year in USA, from both accidental and nonaccidental overdoses
  - ↑ prevalence of COP during winter months

Natural History & Prognosis

- Persistent neurologic sequelae: Occur immediately following COP and persist over time
- Delayed neurologic sequelae (10-30% of victims)
  - Occur weeks after initial recovery from acute COP
- 2 categories with regard to outcome
  - Normal/mild functional impairment: No or minimal abnormality on brain MR
  - Death/severe functional impairment (coma): Diffuse brain damage on MR

Treatment

- Hyperbaric oxygen (HBO) therapy: Treatment of choice in acute COP (within 6 hours for best effect)
- Early administration of 100% oxygen or HBO may prevent long-term neuropsychiatric sequelae

DIAGNOSTIC CHECKLIST

Consider

- MR to monitor progression/resolution of lesions

SELECTED REFERENCES

1. Beppu T: The role of MR imaging in assessment of brain damage from carbon monoxide poisoning: a review of the literature. AJNR Am J Neuroradiol. 35(4):625-31, 2014
2. Betterman K et al: Neurologic complications of carbon monoxide intoxication. Handb Clin Neurol. 120:971-9, 2014
3. Mizuno Y et al: Delayed leukoencephalopathy after carbon monoxide poisoning presenting as subacute dementia. Intern Med. 53(13):1441-5, 2014
4. Wu PE et al: Carbon monoxide poisoning. CMAJ. 186(8):611, 2014
5. Huzar TF et al: Carbon monoxide and cyanide toxicity: etiology, pathophysiology and treatment in inhalation injury. Expert Rev Respir Med. 7(2):159-70, 2013

https://CafePezeshki.IR

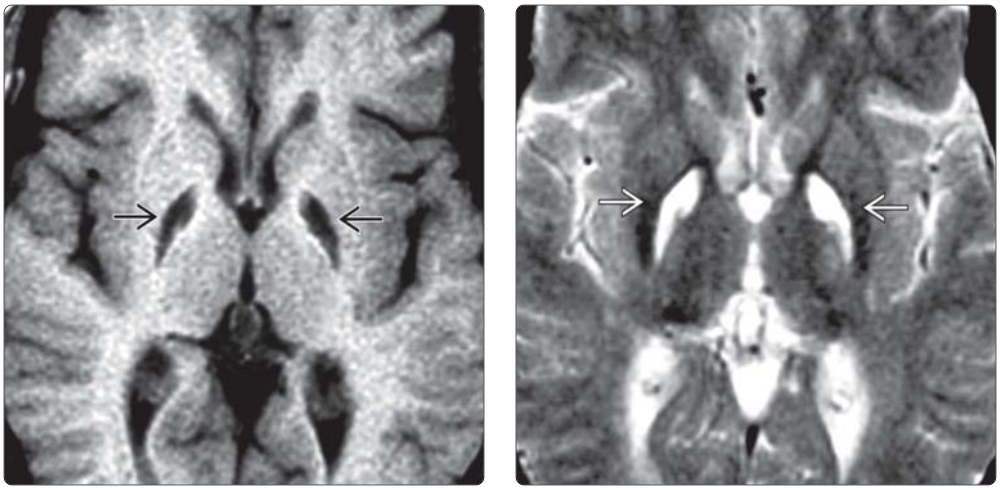

(Left) *Axial T1WI MR shows the appearance of chronic CO poisoning involving the basal ganglia. There are bilateral, nonenhancing, CSF intensity lesions present within the globi pallidi* ⇨. **(Right)** *Axial T2WI MR in the same patient shows symmetric, bilateral, CSF intensity lesions within the globi pallidi* ➡. *Often, there is a rim of hypointensity related to hemosiderin surrounding the injured deep gray nuclei. Up to 30% of patients with CO poisoning have delayed neurologic sequelae.*

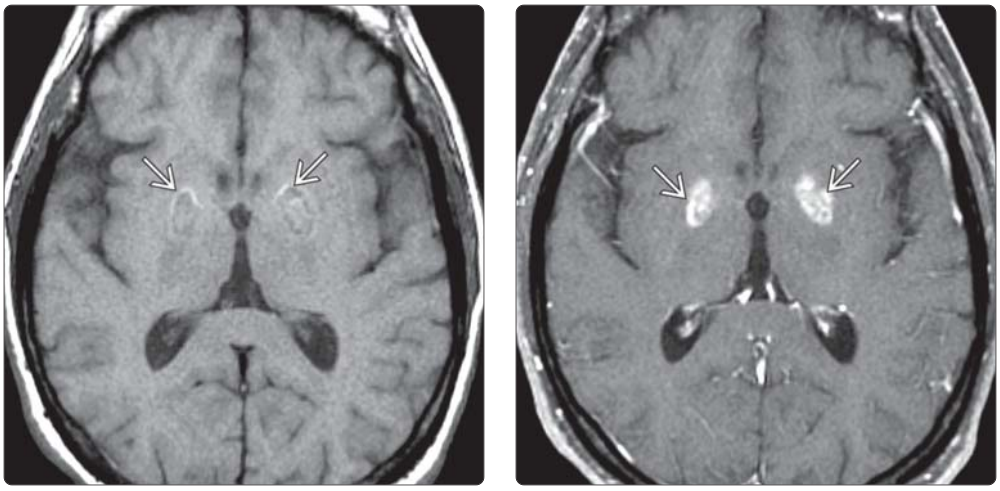

(Left) *Axial T1WI MR of a patient with acute CO poisoning shows heterogeneous signal in the globus pallidus bilaterally with areas of central hypointensity with a surrounding rim of hyperintensity* ➡. *The hyperintensity is likely related to blood products.* **(Right)** *Axial T1WI C+ FS MR in the same patient shows heterogeneous enhancement of the globus pallidus bilaterally* ➡. *Enhancement is variably seen in CO poisoning.*

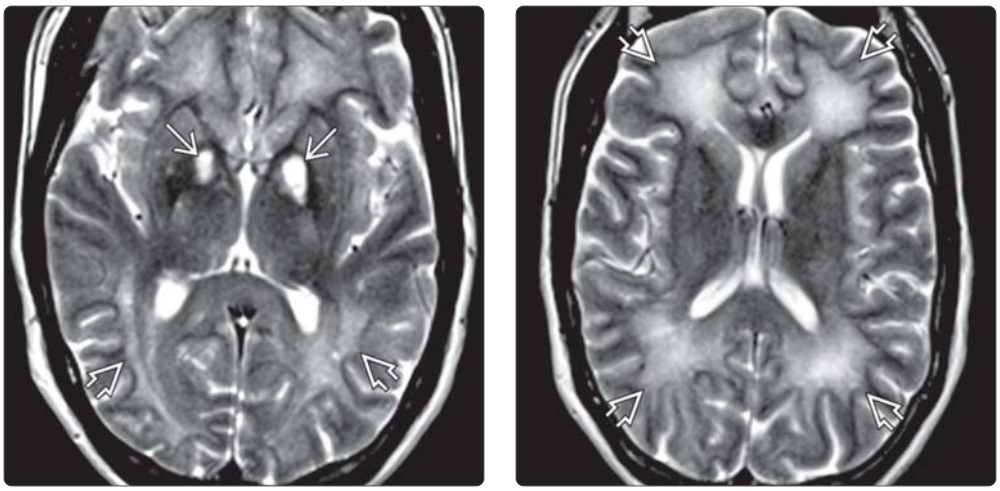

(Left) *Axial T2WI MR shows symmetric, bilateral, globus pallidus hyperintensities* ➡ *and diffuse hyperintensity throughout the white matter* ➡ *with sparing of the subcortical U-fibers.* **(Right)** *Axial T2WI MR in the same patient shows bilateral diffuse hyperintensity throughout the white matter* ➡ *with typical sparing of the subcortical U-fibers. The white matter hyperintensity is related primarily to demyelination with variable amounts of necrosis. The hyperintensity typically shows diffusion restriction.*

https://CafePezeshki.IR

KEY FACTS

TERMINOLOGY

- Many drugs (prescription, illicit, or street) have adverse CNS effects
  - Illicit drug use often causes cerebrovascular disease
  - Amphetamines, cocaine > opioids, cannabis
- Polydrug abuse (including EtOH) is common
- Nitrous oxide (NO_2) abuse → vitamin B12 inactivation → subacute combined degeneration

IMAGING

- Best imaging clue: Young/middle-aged adult with ischemic or hemorrhagic stroke in close temporal proximity to drug administration
  - Hemorrhage: Intracranial, subarachnoid, intraventricular
  - Nonhemorrhagic ischemic stroke: MCA territory most common
- Heroin, MDMA: Globus pallidus ischemia
- Amphetamines: Hemorrhage, vasculitis, pseudoaneurysm, infarcts
- NECT for suspected hemorrhage indicated: If NECT reveals hemorrhage, consider CTA/MRA/DSA
- Consider drug abuse or dissection in young or middle-aged patient with stroke

TOP DIFFERENTIAL DIAGNOSES

- Intracranial hemorrhage in young adults
  - Vascular malformations
  - Dural sinus thrombosis with hemorrhagic infarct
  - Severe posterior reversible encephalopathy syndrome with secondary hemorrhage
- Vasculitis

PATHOLOGY

- 40-50% of drug-related ICH is related to underlying vascular malformation (cerebral aneurysm, AVM)

CLINICAL ISSUES

- 30% of strokes in patients < 45 years old are drug related
- Cocaine, MDMA, amphetamines: Stroke, headache, seizures

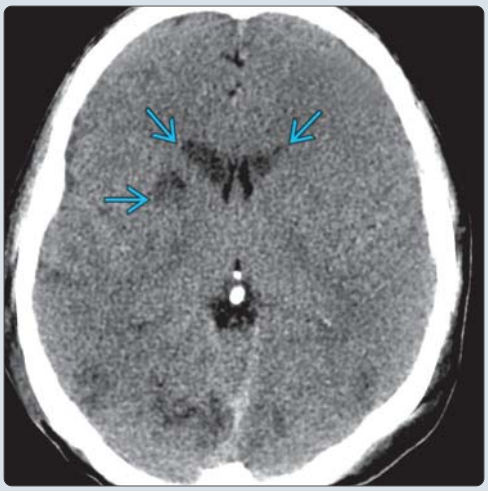

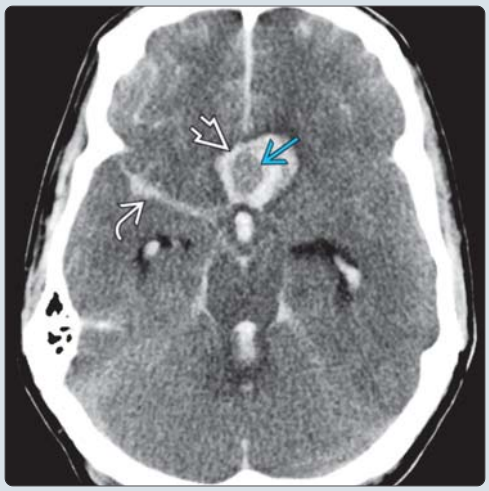

(Left) *Axial NECT in a comatose patient after cocaine abuse shows focal hypodensities in the basal ganglia related to ischemia. Note also the diffuse loss of the corticomedullary differentiation due to severe anoxia.* **(Right)** *A 32-year-old female methamphetamine abuser had sudden severe headache followed by coma. NECT shows diffuse subarachnoid, intraventricular hemorrhage. A focal interhemispheric hematoma surrounds a ruptured ACoA aneurysm.*

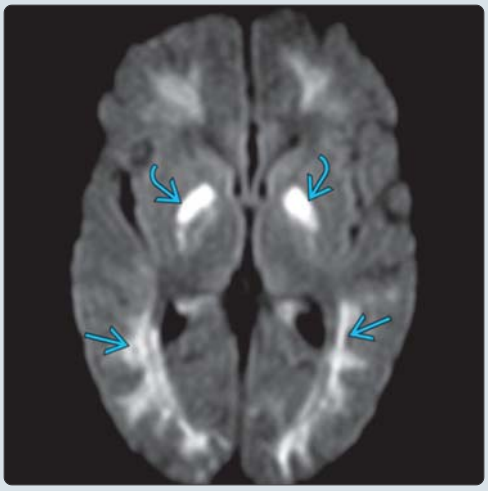

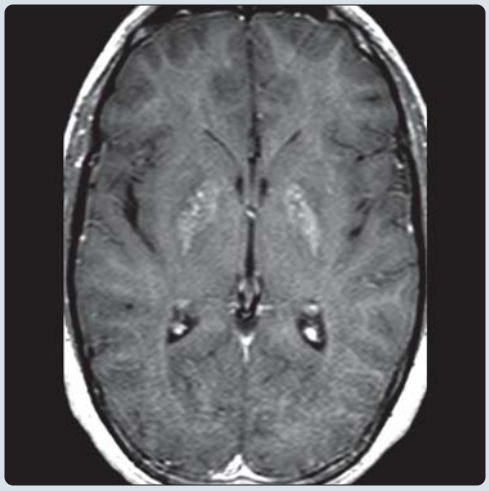

(Left) *Axial DWI MR in a young male patient following ingestion of ecstasy (MDMA) shows symmetric diffusion restriction in the globi pallidi and deep white matter.* **(Right)** *Axial T1 C+ MR in the same patient shows enhancement within the globi pallidi due to necrosis. MDMA causes rapid release of 5-hydroxytryptamine, which is 1 of the most potent vasoconstrictors in the brain and it ultimately leads to necrosis of the involved regions of the brain. The occipital cortex and globi pallidi are most vulnerable.*

https://CafePezeshki.IR

TERMINOLOGY

Definitions

- Many drugs (prescription, illicit, or street) have adverse effects on CNS
  - Major pathology is generally vascular or metabolic
  - Polydrug abuse (including EtOH) is common
- Cerebrovascular disease caused by illicit drug use
  - Amphetamines and derivatives
    - Cocaine
      - Cocaine hydrochloride (HCl) is water soluble, ingested via mucosal membrane
      - Alkaloid form (freebase, crack) is smokable
    - 3,4-methylenedioxymethamphetamine (MDMA, ecstasy)
  - Opioids and derivatives
    - Heroin: IV use, inhaled ("chasing the dragon")
    - Other derivatives include morphine, hydrocodone, oxycodone, codeine
  - Cannabis/marijuana
  - EtOH abuse: Interference with normal clotting increases risk of spontaneous hemorrhage and extent of hemorrhage due to primary pathology
    - Traumatic brain injury
    - Hypertensive cerebral vascular disease
- May interfere with critical metabolic pathways
  - Nitrous oxide (NO_2) abuse → vitamin B12 inactivation → subacute combined degeneration
- May lead to nutritional deficiencies
  - Chronic EtOH abuse → thiamine deficiency → Wernicke encephalopathy
- Organ damage from chronic drug abuse
  - EtOH → liver failure → manganese deposition in basal ganglia (BG)

IMAGING

General Features

- Best diagnostic clue
  - Young/middle-aged adult with ischemic or hemorrhagic stroke in close temporal proximity to drug administration
- Location
  - Hemorrhage: Intracranial (ICH), subarachnoid (SAH), intraventricular (IVH)
  - Nonhemorrhagic ischemic stroke: Usually, middle cerebral artery (MCA) territory
  - Vascular: Vasculitis, pseudoaneurysm
  - Cocaine: Infarctions in cerebrum, thalamus, brainstem, cerebellum, retina
  - Heroin, MDMA: Globus pallidus (GP) ischemia

CT Findings

- NECT
  - Cocaine: ICH, SAH, IVH
  - Heroin inhalation: Symmetric hypodensity in cerebellar and posterior cerebral white matter (WM), posterior limb of internal capsule, GP
- CTA
  - May show segmental narrowing in vasculitis

MR Findings

- T1WI
  - Heroin vapor inhalation: Leukoencephalopathy
- T2WI
  - Cocaine: May have severe T2-hyperintense lesions
    - Cerebral, insular subcortex WM lesions, transient arterial occlusion in MCA territory: Small infarctions
  - MDMA: Ischemic necrosis in occipital cortex and globus pallidus
  - Heroin vapor inhalation
    - Hyperintense cerebral, cerebellar tracts
    - WM cerebellum, posterior cerebral, posterior limb of internal capsule, sparing of subcortical WM
  - Cannabis
    - T2-hyperintense lesions in basal ganglia, periventricular white matter, striatocapsular region, cerebellum
  - Wernicke encephalopathy
    - Hyperintensity in medial thalami, tectum, periaqueductal gray matter, mammillary bodies, rarely cortex
  - Subacute combined degeneration
    - Hyperintensity in posterior spinal cord (cervical and thoracic)
- T2* GRE
  - Hemorrhagic lesions have decreased signal
  - Cocaine: Hemorrhage in basal ganglia and thalami
- DWI
  - Restricted diffusion in acute ischemic and metabolic lesions
- MRA
  - Arterial spasm &/or vasculitis
    - Vasculitis is difficult to diagnose on MRA unless high quality; 3T MRA > 1.5T MRA

Other Modality Findings

- Cerebral angiography may show irregularity of medium-sized intracranial vessels consistent with amphetamine-induced vasculitis

Imaging Recommendations

- Protocol advice
  - NECT for suspected hemorrhage
    - If CT reveals hemorrhage, consider CTA/MRA/DSA
  - MR: Include DWI, GRE, T1WI C+

DIFFERENTIAL DIAGNOSIS

Spontaneous ICH in Young Adults

- Hypertension: BG hemorrhages
- Vascular malformations
  - Cavernous angiomas
  - Arteriovenous malformations (AVMs)
- Intratumoral hemorrhage
  - Incomplete hemosiderin rings, enhancing nodule, persistent mass effect
- Dural sinus thrombosis with hemorrhagic infarct
  - Underlying coagulable state is often present
- Severe posterior reversible encephalopathy syndrome (PRES) with secondary hemorrhage
- Mycotic aneurysm with parenchymal hemorrhage

https://CafePezeshki.IR

- Often related to infectious endocarditis

Vasculitis

- Inflammation and necrosis of vessel walls
- Multiple etiologies: Infectious, granulomatous, autoimmune, collagen vascular disease
- Drug-induced differentiated by history

PATHOLOGY

General Features

- Etiology
  - Amphetamines: Cocaine, MDMA
    - Systemic vasoconstriction → acute arterial hypertension → hemorrhagic stroke (rupture of preexisting aneurysms, bleeding from AVM)
    - Cerebral vasoconstriction, vasculitis → infarction
  - Cocaine
    - ↑ platelet aggregation with thrombosis
    - Heart disease: Source of emboli
  - MDMA abuse: Loss of serotoninergic neurons
  - Parenteral drugs
    - Infective endocarditis (IE) → emboli → cerebral infarction, hemorrhage, abscess, mycotic aneurysm
    - Bacteremia in absence of IE: Brain abscess
  - Heroin: Toxic leukoencephalopathy, hypoxic brain injury, ischemic stroke, brain abscess
    - Generalized hypoxia and hypotension
    - Possible immunologic-mediated vasculitis
    - Nephropathy → severe hypertension
  - Concomitant alcohol use may potentiate illicit drug effects (↓ hepatic metabolism)
- Associated abnormalities
  - 40-50% of drug-related ICH is related to underlying vascular malformation (cerebral aneurysm, AVM)
  - Drug-induced IE, vasculitis
  - Alkaloidal cocaine (crack): Hemorrhagic = ischemic stroke
  - Cocaine hydrochloride: Hemorrhagic > ischemic stroke
  - Heroin: Cerebral infarctions (MCA area, not watershed distribution), toxic leukoencephalopathy

Gross Pathologic & Surgical Features

- Amphetamine, cocaine: Arterial spasm/vasculitis
- Amphetamine, cocaine, MDMA: ICH, SAH
- MDMA: Bilateral GP necrosis (secondary prolonged vasospasm)

Microscopic Features

- Amphetamines: Inflammatory vasculitis with vessel wall necrosis (speed arteritis) similar to polyarteritis nodosa
- Cocaine: Vasculitis affecting CNS
- Heroin: Vasculitis (rare), probably related to drug contaminants
  - Inhaled heroin vapors: Symmetric spongiform degeneration in cerebral/cerebellar WM, corticospinal tracts

CLINICAL ISSUES

Presentation

- Most common signs/symptoms
  - Cocaine, MDMA, amphetamines: Stroke, headache, seizures
  - Heroin: BG damage (parkinsonism, hemiballismus)
    - Toxic leukoencephalopathy: Cerebellar, pyramidal, and pseudobulbar signs, spasms, death
- Clinical profile
  - Cerebral infarcts, TIAs, ICH, SAH
    - Temporal proximity of stroke to drug use

Demographics

- Age
  - 85-90% of drug-related strokes in 4th-5th decades
- Epidemiology
  - 30% of strokes in patients < 45 are drug related
  - Estimated relative risk for stroke among drug abusers (after controlling for other stroke risk factors): 6.5 out of 10
  - Subacute combined degeneration
    - Individuals with access to medical NO_2
    - Abuse of NO_2 canisters (poppers)

Natural History & Prognosis

- Time interval between drug use and stroke onset: ≤ 1 week
  - Stroke risk is highest within first 6 hours after drug use
- IE-related strokes may be delayed
- Cocaine worsens presentation and outcome of aneurysmal SAH patients

Treatment

- Management of drug-related stroke largely supportive
- Antibiotics for embolic stroke due to IV-drug-induced IE ↓ risk of recurrent infarction
- Aggressive addiction rehabilitation
- Experimentally, magnesium reverses cocaine-induced vasospasm
- Wernicke encephalopathy: Supplementary thiamine
- Subacute combined degeneration: B12 injection

DIAGNOSTIC CHECKLIST

Consider

- Drug abuse in young/middle-aged patient with hemorrhagic or ischemic stroke
- Vascular imaging CTA/MRA/DSA in drug-related hemorrhages

Image Interpretation Pearls

- Drug-related hemorrhages may indicate underlying vascular abnormality
- Vasculitis can be very difficult to distinguish from drug-related vasospasm

SELECTED REFERENCES

1. Niciu MJ et al: Neuroimaging in Alcohol and Drug Dependence. Curr Behav Neurosci Rep. 1(1):45-54, 2014
2. Fonseca AC et al: Drug abuse and stroke. Curr Neurol Neurosci Rep. 13(2):325, 2013
3. Agarwal A et al: Toxic encephalopathy. J Gen Intern Med. 27(7):876-7, 2012
4. Singh NN et al: Cannabis-related stroke: case series and review of literature. J Stroke Cerebrovasc Dis. 21(7):555-60, 2012
5. Tamrazi B, Almast J. Your brain on drugs: imaging of drug-related changes in the central nervous system. Radiographics. 32(3):701-19, 2012
6. Geibprasert S et al: Addictive illegal drugs: structural neuroimaging. AJNR Am J Neuroradiol. 31(5):803-8, 2010

https://CafePezeshki.IR

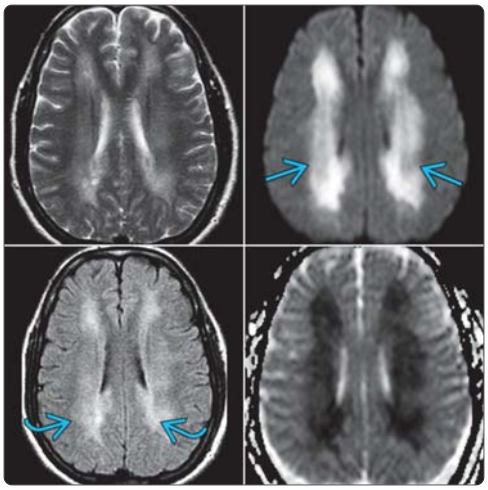

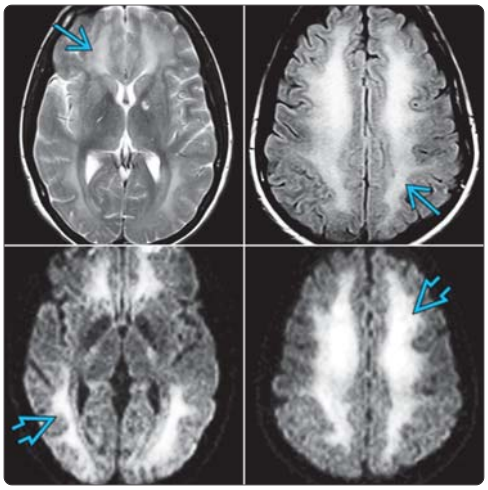

(Left) *A 57-year-old man developed acute leukoencephalopathy after "chasing the dragon." MR shows diffuse WM hyperintensity on T2/FLAIR (L) and acute diffusion restriction (R). (Courtesy M. Michel, MD.)* **(Right)** *A 32-year-old woman overdosed on methadone. MR scans show symmetric hyperintensity on T2/FLAIR with acute diffusion restriction on DWI.*

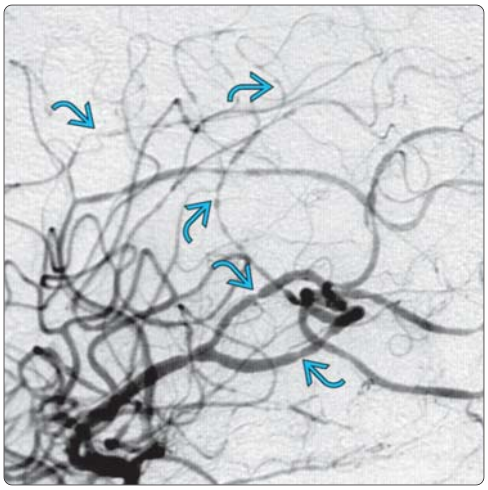

(Left) *Axial NECT in a 42-year-old man presenting with history of recurrent severe headache and longstanding history of amphetamine abuse shows hyperdensity related to lobar hemorrhage with surrounding edema in the right frontal lobe.* **(Right)** *Lateral DSA of a right internal carotid artery injection shows an irregularity and a beaded appearance of the medium to small-sized vessels in the MCA and anterior cerebral artery distributions. Findings are consistent with drug-induced vasculitis.*

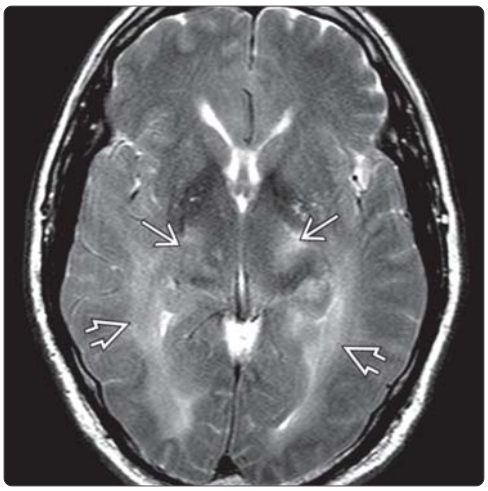

(Left) *Axial FLAIR MR in a patient with intravenous heroin abuse who presented with right hemiparesis shows an infarct in the left precentral gyrus. There was corresponding diffusion restriction (not shown). Ischemia is the most common acute neurovascular complication caused by heroin.* **(Right)** *T2WI MR in a comatose patient who drank a gallon of vodka or whisky daily for a full week shows diffuse brain swelling, hyperintense white matter, and bithalamic lesions, indicative of acute alcohol poisoning.*

https://CafePezeshki.IR

KEY FACTS

TERMINOLOGY

- Acute toxic effects of methanol on CNS

IMAGING

- Bilateral hemorrhagic putaminal necrosis
- Putamen, hemispheric white matter
  - Caudate nuclei may be involved
  - Uncommon: Corpus callosum, brainstem, cerebellum
- Cerebral and intraventricular hemorrhage
- DWI: Restriction in putamina ± white matter
- Protocol: MR (including GRE + DWI)

TOP DIFFERENTIAL DIAGNOSES

- Hypertensive intracranial hemorrhage
- Anoxic infarcts
- Carbon monoxide (CO) poisoning
- Osmotic demyelination syndrome
- Wilson disease
- Leigh disease
- Creutzfeldt-Jakob disease (CJD)
- Huntington disease

PATHOLOGY

- Methanol metabolized to formaldehyde, formic acid
- Causes "anion gap acidosis"

CLINICAL ISSUES

- Blurred vision
- Drowsiness, confusion, seizure, coma
- Nausea/vomiting, abdominal pain
- Respiratory arrest → death
- Untreated methanol poisoning
  - Visual deficits in ~ 1/3
  - Death rate of ~ 1/3
- Treatment: Fomepizole or ethanol
- General supportive care (e.g., intravenous fluids, correction of electrolytes and acidemia)

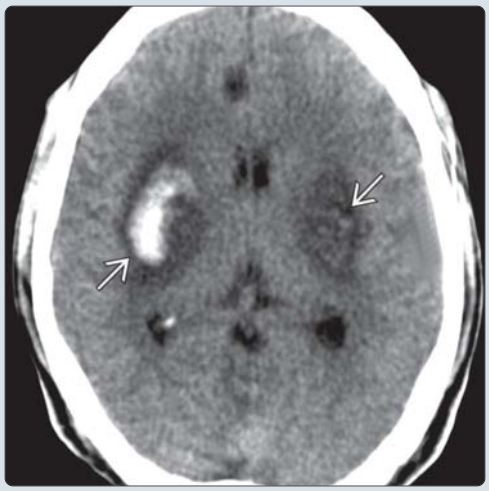

(Left) *Axial gross pathology specimen sectioned through the basal ganglia in a patient who died from methanol poisoning shows bilateral hemorrhagic necrosis of both basal ganglia and the right caudate. The putamina are most severely affected. Note sparing of the thalami. (Courtesy R. Hewlett, MD.)* **(Right)** *Axial NECT shows mixed density lesions in the basal ganglia in a patient who had been drinking methanol. Note gross and petechial hemorrhage in the putamen ➡, typical of acute methanol toxicity.*

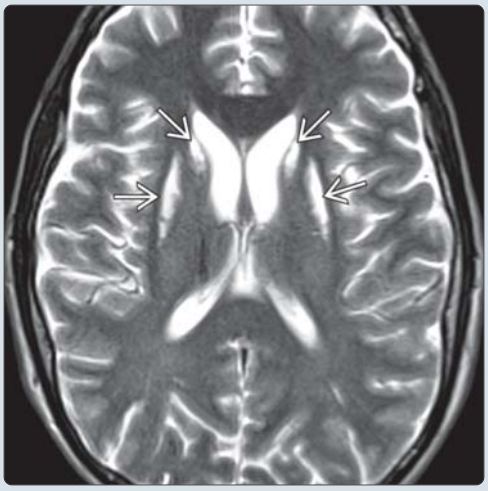

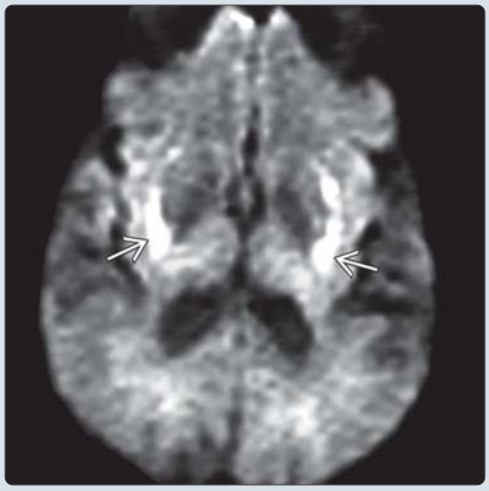

(Left) *Axial T2WI MR shows striking hyperintensities in the putamina and caudate nuclei ➡ in a 37-year-old man with longstanding abuse of both ethanol and methanol. Generalized volume loss is consistent with a history of chronic substance abuse.* **(Right)** *Axial DWI MR in a patient with acute methanol poisoning shows restricted diffusion in both putamina ➡. Follow-up NECT scans obtained 1 week later (not shown) demonstrated symmetrical low density in the putamina, as well as subcortical WM.*

https://CafePezeshki.IR

TERMINOLOGY

Abbreviations

- Methanol (MtOH) encephalopathy

Definitions

- Acute toxic effects of MtOH on CNS

IMAGING

General Features

- Best diagnostic clue
  - Bilateral hemorrhagic putaminal necrosis
- Location
  - Putamen, hemispheric white matter
    - Caudate nuclei may be involved
    - Uncommon: Corpus callosum, brainstem, cerebellum

CT Findings

- NECT
  - Bilateral hemorrhagic putaminal necrosis
  - White matter hypodensity may be seen
  - Cerebral and intraventricular hemorrhage

MR Findings

- T1WI
  - Bilateral hemorrhagic putaminal necrosis is characteristic
  - Hemorrhagic subcortical necrosis
  - White matter hypointense lesions (confluent hemispheric ± optic nerves)
- T2WI
  - Lesions typically hyperintense
  - Acute hemorrhagic necrosis may cause hypointense foci
- FLAIR
  - Lesions all typically hyperintense
- T2* GRE
  - Hypointense foci in putamina
  - Cerebral and intraventricular hemorrhage
- DWI
  - Restriction (high signal) in putamina ± white matter
- T1WI C+
  - Enhancement of necrotic lesions

Imaging Recommendations

- Best imaging tool
  - NECT initially
- Protocol advice
  - MR (including GRE + DWI)

DIFFERENTIAL DIAGNOSIS

Hypertensive Intracranial Hemorrhage

- Usually unilateral

Anoxic Infarcts

- Most are nonhemorrhagic vs. hemorrhagic necrosis in MtOH
- Symmetric ↑ T2 in basal ganglia (BG) typical

Carbon Monoxide (CO) Poisoning

- ↑ T2 in globus pallidus (GP) > putamen typical ± hemispheric WM

Osmotic Demyelination Syndrome

- Extrapontine myelinolysis results in ↑ T2 in BG
- High signal in central pons common

Wilson Disease

- ↑ T2 in the BG, brainstem typical

Leigh Disease

- ↑ T2 lesions (brainstem, BG, and WM) with onset in infancy/early childhood

Creutzfeldt-Jakob Disease (CJD)

- Progressive ↑ T2 of BG (putamen and caudate > GP), thalamus, and cerebral cortex

Huntington Disease

- Caudate atrophy, ↑ T2 caudate/putamen

PATHOLOGY

General Features

- Etiology
  - Methanol metabolized to formaldehyde, formic acid
  - Causes "anion gap acidosis"
  - Select toxic effect on putamen, optic nerves
  - Commercial products containing methanol include antifreeze, paint remover, photocopying fluid

Gross Pathologic & Surgical Features

- Pallidal necrosis
- Optic nerve demyelination and atrophy

CLINICAL ISSUES

Presentation

- Most common signs/symptoms
  - Blurred vision
    - May progress to blindness
  - Drowsiness, confusion, seizure, coma
  - Nausea/vomiting, abdominal pain
  - Respiratory arrest → death

Natural History & Prognosis

- Latency period between ingestion and symptoms because of time required for enzymatic oxidation
- Untreated methanol poisoning
  - Visual deficits in ~ 1/3 of survivors
  - Death rate of ~ 1/3

Treatment

- Fomepizole or ethanol
  - Inhibit alcohol dehydrogenase
  - Prevents metabolism of methanol to formic acid
- General supportive care (e.g., intravenous fluids, correction of electrolytes, and acidemia)

SELECTED REFERENCES

1. Grasso D et al: Lentiform fork sign: a magnetic resonance finding in a case of acute metabolic acidosis. Neuroradiol J. 27(3):288-92, 2014
2. Rietjens SJ et al: Ethylene glycol or methanol intoxication: which antidote should be used, fomepizole or ethanol? Neth J Med. 72(2):73-9, 2014
3. Jain N et al: Methanol poisoning: characteristic MRI findings. Ann Saudi Med. 33(1):68-9, 2013
4. Thirunavukkarasu S et al: Acute bilateral putaminal haemorrhagic necrosis in methanol poisoning. BMJ Case Rep. 2013, 2013

https://CafePezeshki.IR

KEY FACTS

TERMINOLOGY

- Anoxic encephalopathy caused by exposure to cyanide (CN)

IMAGING

- Hemorrhagic striatal, cortical laminar necrosis
  - Basal ganglia (BG)
  - Cortex (especially sensorimotor)
- T2/FLAIR hyperintense foci in BG, cortex
- Restricted diffusion in BG, cortex
- May see T1 hyperintensity, enhancement in BG/cortex

TOP DIFFERENTIAL DIAGNOSES

- Hypoxic-ischemic encephalopathy
- Toxic exposure, especially carbon monoxide (CO)
- Inherited/metabolic disease
- Infectious etiologies

PATHOLOGY

- Inhibits mitochondrial cytochrome c oxidase
  - Compromises aerobic oxidative metabolism, phosphorylation
  - Cellular hypoxia, lactic acidosis ensues

CLINICAL ISSUES

- Odor of bitter almond
- Tachypnea, tachycardia, hypertension
  - Cardiorespiratory collapse ensues
- Seizure ± coma ± death
- Often overlaps with signs/symptoms of CO exposure
- Smoke inhalation, ingestion, or dermal absorption
- Accidental exposure (work-related)
- Nonaccidental exposure

DIAGNOSTIC CHECKLIST

- May have overlapping features related to CN and CO poisoning, especially in smoke inhalation

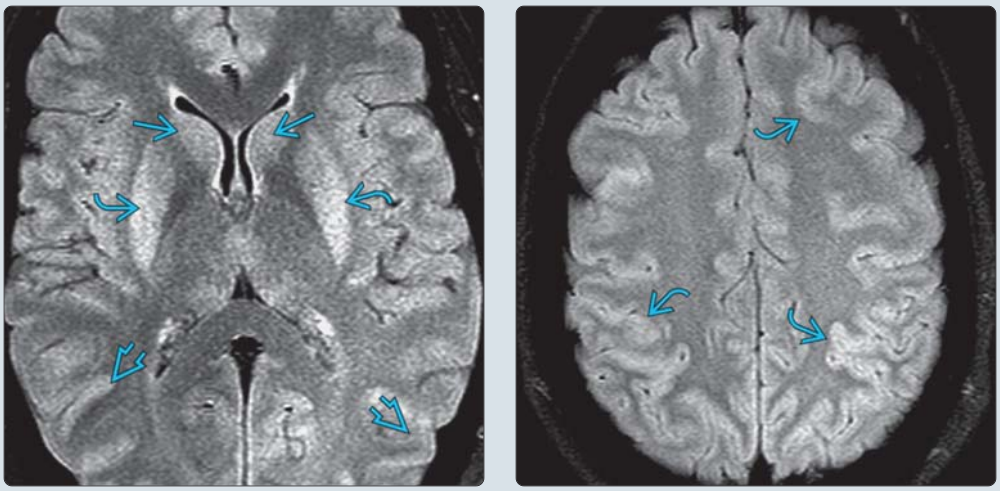

(Left) *Axial FLAIR MR in a 22-year-old woman found unconscious after smoke inhalation in a residential fire demonstrates increased signal in the putamina, caudate nuclei, and cortex.* **(Right)** *Axial FLAIR MR in the same patient shows extensive cortical swelling and subtle hyperintensity.*

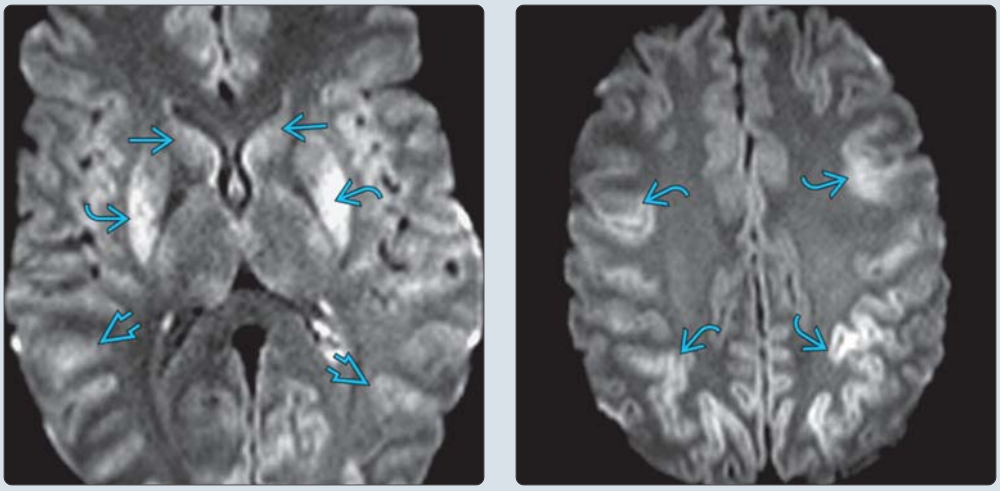

(Left) *Axial DWI shows corresponding areas or restricted diffusion in the putamina, caudate nuclei, and cortex.* **(Right)** *Axial DWI in the same patient shows extensive cortical restricted diffusion. Findings are more pronounced on DWI as compared to FLAIR. Although these imaging findings are nonspecific, the bilateral symmetric appearance should raise the possibility of a global hypoxic/toxic/metabolic insult. Clinical history is vital to confirm the diagnosis.*

https://CafePezeshki.IR

TERMINOLOGY

Abbreviations

- Cyanide (CN) poisoning

Definitions

- Anoxic encephalopathy caused by exposure to CN

IMAGING

General Features

- Best diagnostic clue
  - Hemorrhagic striatal, cortical laminar necrosis
- Location
  - Basal ganglia (BG)
    - Bilateral involvement typical
      - Putamen, caudate nucleus can involve globus pallidus
  - Cortex
    - Multifocal lesions, especially sensorimotor cortex
  - Cerebellum

CT Findings

- NECT
  - Hypodense foci in BG

MR Findings

- T1WI
  - Early: Hypointense BG foci
  - Late: Hyperintensity in BG, curvilinear cortical hyperintensity
- T2WI
  - Hyperintense foci in BG
  - Cortical hyperintensity
- FLAIR
  - Same as T2WI
- DWI
  - Restricted diffusion in BG, cortex
- T1WI C+
  - May see enhancement in BG, cortex

Imaging Recommendations

- Best imaging tool
  - MR with FLAIR, DWI

Nuclear Medicine Findings

- PET
  - 18F-fluorodopa: ↓ striatal uptake
  - 18F-FDG PET: ↓ metabolism in putamen, temporo-parietooccipital, and cerebellar cortices

DIFFERENTIAL DIAGNOSIS

Hypoxic-Ischemic Encephalopathy

- Includes anoxia, hypoxia, near drowning, and cerebral hypoperfusion injury

Toxic Exposure

- Methanol, alcohol, carbon monoxide (CO), heroin

Inherited/Metabolic Disease

- Wilson disease, Leigh disease, Huntington disease

Infectious Etiologies

- Japanese encephalitis, Creutzfeldt-Jakob disease (CJD), etc.

PATHOLOGY

General Features

- Etiology
  - Inhibits mitochondrial cytochrome c oxidase
    - Compromised aerobic oxidative metabolism, phosphorylation
    - Cellular hypoxia, lactic acidosis ensue

Gross Pathologic & Surgical Features

- Hemorrhagic BG necrosis
- Cortical laminar necrosis

CLINICAL ISSUES

Presentation

- Most common signs/symptoms
  - Often overlaps with signs/symptoms of CO exposure
  - Odor of bitter almond
  - Tachypnea, tachycardia, hypertension
    - Cardiorespiratory collapse
  - Seizure, coma, death

Demographics

- Epidemiology
  - Smoke inhalation, ingestion, or dermal absorption
  - Accidental exposure (work-related)
    - Metal industry, mining, jewelry manufacture, inhaling smoke
  - Nonaccidental exposure
    - Suicide and murder attempts

Natural History & Prognosis

- Symptom onset varies with exposure type
  - Gaseous hydrocyanic acid → seconds
  - Solid or liquid cyanide salts → minutes
  - Some cyanogenic compound (nitriles and nitroprusside) → hours
- Range of outcomes
  - From full recovery to death
  - Permanent neurological disability
    - Extrapyramidal syndromes and vegetative state

Treatment

- Decontamination, supportive
- Oxygen therapy: Normobaric and hyperbaric
- Cyanide antidotes

DIAGNOSTIC CHECKLIST

Consider

- May have overlapping features related to CN and CO poisoning, especially in smoke inhalation

SELECTED REFERENCES

1. Borron SW et al: Asphyxiants. Emerg Med Clin North Am. 33(1):89-115, 2015
2. Huzar TF et al: Carbon monoxide and cyanide toxicity: etiology, pathophysiology and treatment in inhalation injury. Expert Rev Respir Med. 7(2):159-70, 2013

https://CafePezeshki.IR

KEY FACTS

TERMINOLOGY

- Osmotic demyelination syndrome (ODS)
  - Formerly called central pontine myelinolysis (CPM) &/or extrapontine myelinolysis (EPM)
- Acute demyelination from rapid shifts in serum osmolality
  - Classic setting: Rapid correction of hyponatremia
  - ODS may occur in normonatremic patients

IMAGING

- Central pons T2 hyperintensity with sparing of periphery
- 50% in pons (CPM); 50% in extrapontine sites (EPM)
  - Central fibers involved; peripheral fibers spared
  - Basal ganglia (BG)
  - Cerebral white matter (WM)
- CPM + EPM = almost pathognomonic for ODS
- Acute: Confluent hyperintensity in central pons with sparing of periphery and corticospinal tracts
- Round, triangular, or batwing-shaped
- DWI earliest and sensitive for ODS
- Subacute: Hyperintensity often normalizes
- Best imaging tool: MR > > CT

TOP DIFFERENTIAL DIAGNOSES

- Pontine ischemia/infarction
- Demyelinating disease
- Pontine neoplasm (astrocytoma, metastasis)
- Metabolic disease (Wilson, Leigh, diabetes, hypertensive encephalopathy)

PATHOLOGY

- Heterogeneous disorder with common etiology: Osmotic stress

CLINICAL ISSUES

- Alcoholic, hyponatremic patient with rapid correction of serum sodium
- ODS symptoms emerge 2-8 days (occasionally weeks) after correction of hyponatremia
- "Comorbid" conditions common, poorer prognosis

(Left) *Axial graphic shows acute osmotic demyelination affecting the central pons. The pons is slightly swollen with mild mass effect on the 4th ventricle.* **(Right)** *Axial NECT in a chronic alcoholic patient who presented with altered sensorium demonstrates central pontine hypodensity due to osmotic demyelination syndrome. Osmotic demyelination syndrome is an acute demyelination caused by rapid shifts in serum osmolality.*

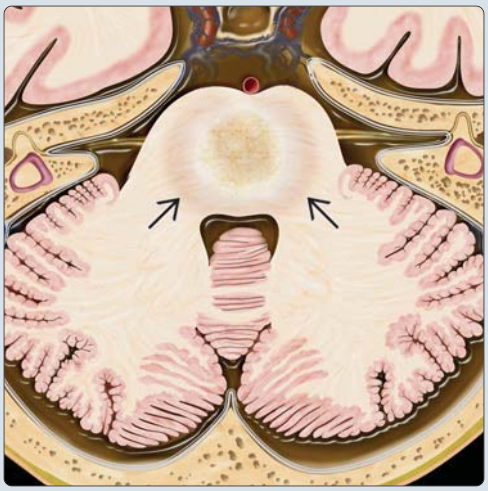

(Left) *Axial DWI in the same patient shows restricted diffusion in the pons corresponding to the hypodensity on CT. There is sparing of the corticospinal tracts and peripheral pontine pons.* **(Right)** *Axial DTI in the same patient shows disruption of the central pontine white matter with preservation of the corticospinal tracts and peripheral pontine fibers. Pontine osmotic demyelination is round, triangular, or batwing-shaped.*

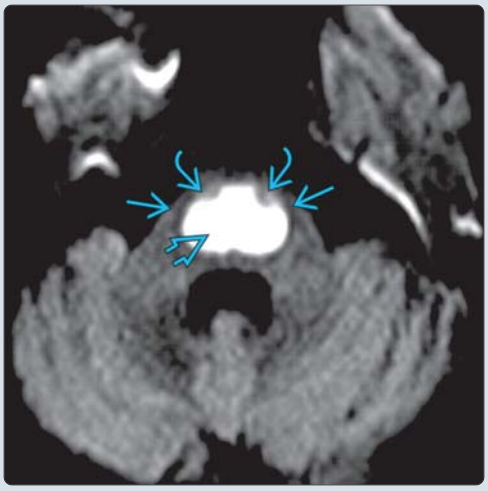

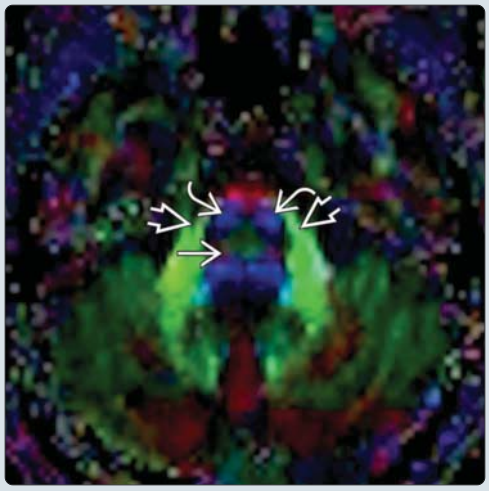

https://CafePezeshki.IR

TERMINOLOGY

Abbreviations

- Osmotic demyelination syndrome (ODS)

Synonyms

- Formerly called central pontine myelinolysis (CPM) &/or extrapontine myelinolysis (EPM)

Definitions

- Acute demyelination caused by rapid shifts in serum osmolality
- Classic setting: Rapid correction of hyponatremia
  - ODS may occur in normonatremic patients

IMAGING

General Features

- Best diagnostic clue
  - Central pons T2 hyperintensity with sparing of periphery
- Location
  - 50% in pons (CPM)
    - Central fibers involved; peripheral fibers spared
  - 50% in extrapontine sites (EPM)
    - Cerebellum (middle cerebellar peduncles)
    - Lateral geniculate bodies
    - Basal ganglia (BG), external capsule, thalamus
    - Cerebral white matter (WM)
    - Uncommon: Peripheral cortex, hippocampi
  - CPM + EPM = almost pathognomonic for ODS
- Morphology
  - Round or triangular (pons)
  - Regardless of site, demyelination often bilateral/symmetric
  - Rare: Gyriform (cortical involvement)

CT Findings

- NECT
  - Low density in affected areas (pons, BG, etc.)
  - Hypodensity in the central pons may be obscured by beam-hardening artifact
  - Look for other abnormalities (e.g., vermian atrophy)
  - No hemorrhage
- CECT
  - Classic: No enhancement
  - Early, acute/severe demyelination may show intense enhancement

MR Findings

- T1WI
  - Acute
    - Classic: Mildly/moderately hypointense
    - Less common: Can be isointense with surrounding normal brain
    - Findings may be transitory, resolve completely
    - Initial study may be normal
  - Subacute
    - May resolve completely
    - Less common: Hyperintensity at 1-4 months (coagulative necrosis)
- T2WI
  - Acute: Confluent hyperintensity in central pons with sparing of periphery and corticospinal tracts
    - Round, triangular, or batwing-shaped
    - Symmetric hyperintensity in BG, white matter (EPM)
  - Subacute: Hyperintensity often normalizes, may resolve completely
- PD/intermediate
  - Hyperintense
- FLAIR
  - Hyperintense
- T2* GRE
  - Hemorrhage, "blooming" rare
- DWI
  - Acute
    - DWI: Hyperintense (restricted); ↓ ADC
    - DWI earliest and sensitive for ODS
    - DWI changes occur within 24 hours of symptoms, improves significantly within 1st week
  - Delayed
    - DWI: Isointense
    - ADC values to baseline within 3-4 weeks
- T1WI C+
  - Common: Usually does not enhance
  - Less common: Moderate confluent/peripheral enhancement
- MRS
  - Acute: ↓ NAA, ↑ choline , ↑ Cho:Cr ratio

Nuclear Medicine Findings

- PET
  - Early metabolic stress = variable hypermetabolism
  - Late = hypometabolic areas in affected sites

Imaging Recommendations

- Best imaging tool
  - MR > > CT
- Protocol advice
  - FLAIR, DWI, T1WI C+
  - Repeat imaging as needed

DIFFERENTIAL DIAGNOSIS

Pontine Ischemia/Infarction

- Often asymmetric
- Usually involves both central, peripheral pontine fibers
- Caution: Perforating basilar artery infarct(s) may involve central pons; imaging can mimic CPM (including DWI)

Demyelinating Disease

- Look for typical lesions elsewhere
- Horseshoe (incomplete ring) enhancement pattern in acute multiple sclerosis common

Pontine Neoplasm (Astrocytoma, Metastasis)

- Primary neoplasm (e.g., pontine "glioma")
  - Typically pediatric/young adult patients
- Pons is rare site for solitary metastasis

Metabolic Disease

- e.g., Wilson, Leigh, diabetes, hypertensive encephalopathy
- Basal ganglia > pons in Wilson disease
- Basal ganglia, midbrain in Leigh disease

https://CafePezeshki.IR

- Parietooccipital lobes = most common site in hypertensive encephalopathy
- Pontine hypertensive encephalopathy
  - Typically does not spare peripheral fibers
  - Other lesions common

PATHOLOGY

General Features

- Etiology
  - Heterogeneous disorder with common etiology: Osmotic stress
    - Osmotic stress: Any change in osmotic gradient
  - Most common: Iatrogenic correction of hyponatremia
  - Less common: Osmotic derangement with azotemia, hyperglycemia, hypokalemia, ketoacidosis
  - Precise mechanism of osmotic stress-related myelinolysis unknown
    - Osmotic insult, change in serum osmolality
    - Relative intracellular hypotonicity
    - Serum osmolality change causes endothelial damage
    - Organic osmolyte deficiency predisposes to endothelial breakdown
    - Endothelial cells shrink, causing blood-brain barrier breakdown
    - Accumulation of hypertonic sodium-rich fluid in extracellular fluid (ECF)
    - Hypertonic ECF, release of myelin toxins damages WM
    - Cell death ensues
  - Oligodendrocytes particularly vulnerable to osmotic changes
  - Astrocytic AQP (aquaporin water channels) loss in a subset of human CPM cases suggests AQP1 and AQP4 may be involved in pathogenesis of CPM
- Associated abnormalities
  - Demyelination without associated inflammation

Gross Pathologic & Surgical Features

- Bilateral/symmetrical, soft, gray-tan discoloration

Microscopic Features

- Extensive demyelination, gliosis
- Macrophages contain engulfed myelin bits and fragments
- Axis cylinders, nerve cells preserved
- Reactive astrocytes, abundant foamy, lipid-laden macrophages

CLINICAL ISSUES

Presentation

- Most common signs/symptoms
  - Seizures, altered mental status
  - Often biphasic when hyponatremia present
    - ODS symptoms emerge 2-8 days (occasionally weeks) after correction of hyponatremia
    - Changing level of consciousness, disorientation
    - Pseudobulbar palsy, dysarthria, dysphagia (CPM)
    - Movement disorder (EPM)
  - Symptoms may resolve with increase in serum osmolality
- Clinical profile
  - Alcoholic, hyponatremic patient with rapid correction of serum sodium
  - "Comorbid" conditions that may exacerbate ODS
    - Hepatic, renal, adrenal, pituitary, paraneoplastic disease
    - Nutritional (alcohol, malnutrition, vomiting)
    - Burn, transplantation, other surgery

Demographics

- Age
  - Occurs at all ages
    - Most common: Middle-aged patients
    - Uncommon: Pediatric patients (diabetes, anorexia)
- Gender
  - M > F
- Epidemiology
  - Autopsy prevalence in alcoholic individuals varies from < 1% to 10%

Natural History & Prognosis

- Spectrum of outcomes
  - Complete recovery may occur
  - Minimal residual deficits
    - Memory, cognitive impairment
    - Ataxia, spasticity, diplopia
  - May progress to
    - Spastic quadriparesis
    - "Locked in," may progress to coma, death
  - Variable behavioral and psychiatric disorders, movement disorders, seizures, depression, polyradiculopathy, and neuropathy
- "Comorbid" conditions common, poorer prognosis
- Mortality ranging from 6% to 90%

Treatment

- No consensus; no "optimal" correction rate for hyponatremia
- Self-correction (fluid restriction, discontinue diuretics) if possible
- Supportive treatment

DIAGNOSTIC CHECKLIST

Consider

- Diagnosis of ODS in alcoholic patient with basal ganglia, white matter disease (EPM)

Image Interpretation Pearls

- Classic CPM spares peripheral pontine fibers
- EPM can occur without CPM
- Repeat MR may be necessary as initial study may be normal

SELECTED REFERENCES

1. Buffington MA et al: Hyponatremia: A Review. J Intensive Care Med. ePub, 2015
2. Alleman AM: Osmotic demyelination syndrome: central pontine myelinolysis and extrapontine myelinolysis. Semin Ultrasound CT MR. 35(2):153-9, 2014
3. Harring TR et al: Disorders of sodium and water balance. Emerg Med Clin North Am. 32(2):379-401, 2014
4. Landais A: Central pontine myelinolysis without electrolyte disorder, alcoholism or denutrition. J Neurol Sci. 343(1-2):235-6, 2014
5. Singh TD et al: Central pontine and extrapontine myelinolysis: a systematic review. Eur J Neurol. 21(12):1443-50, 2014
6. Popescu BF et al: Evidence of aquaporin involvement in human central pontine myelinolysis. Acta Neuropathol Commun. 1(1):40, 2013

https://CafePezeshki.IR

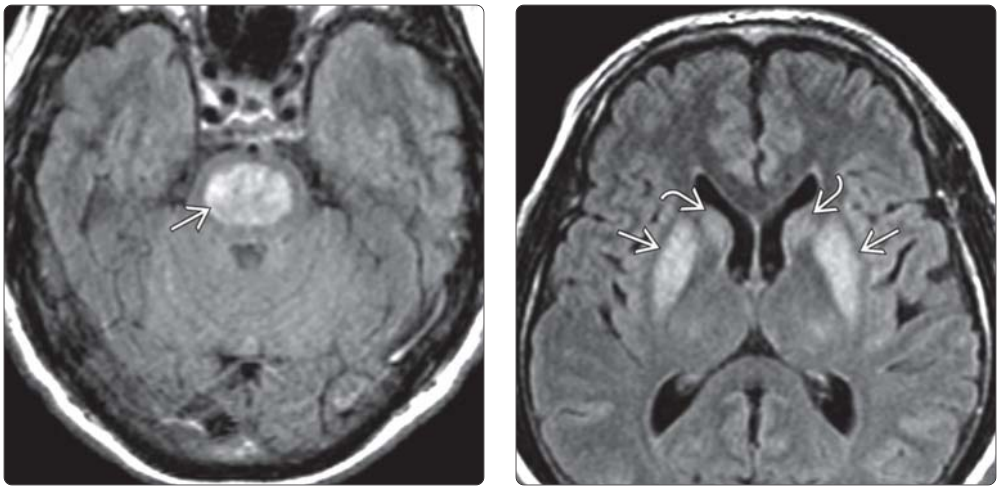

(Left) *Axial FLAIR MR shows abnormal signal intensity in the pons* ➡. **(Right)** *Axial FLAIR MR in the same patient demonstrates abnormal signal intensity in the putamina* ➡ *and in the caudate nuclei* ➡. *Osmotic demyelination syndrome may have manifestations of both central pontine and extrapontine myelinolysis.*

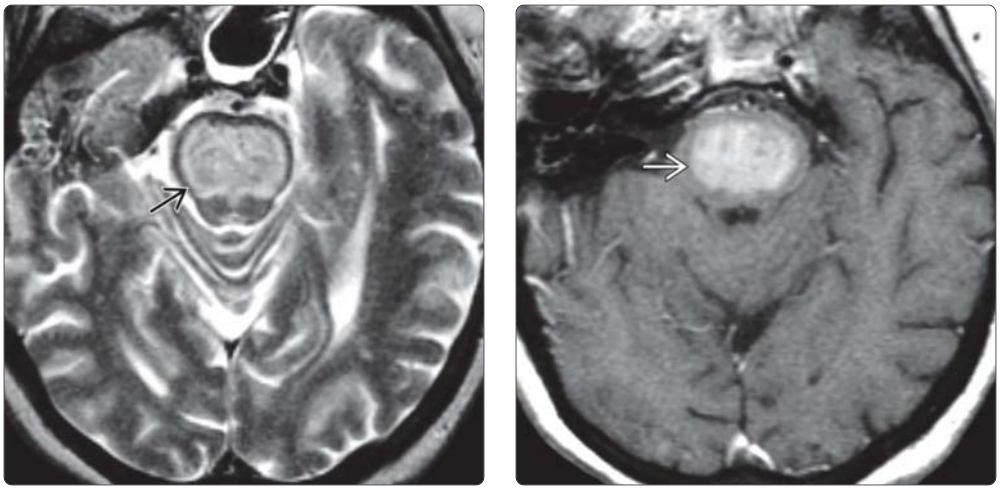

(Left) *Axial T2WI MR demonstrates striking hyperintensity within the central pons* ⇨, *which is a classic finding in osmotic demyelination syndrome.* **(Right)** *T1WI C+ MR in the same patient shows enhancement of the acutely demyelinating area* ➡.

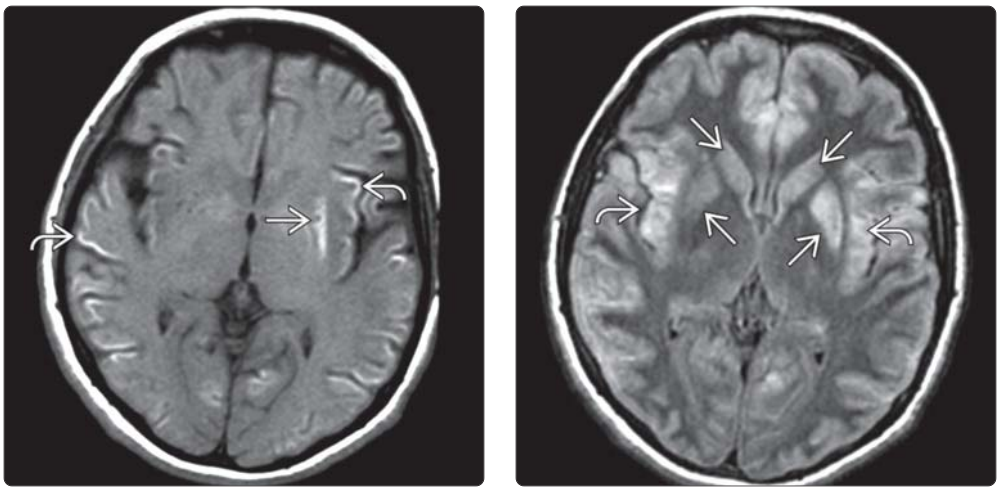

(Left) *Axial T1WI MR in a patient with hyponatremia shows diffuse high signal in the cortex* ➡ *and left putamen* ➡. **(Right)** *Axial FLAIR MR in the same patient shows diffuse high signal in the cortex* ➡ *and striatum* ➡. *Frank cortical laminar necrosis is an atypical manifestation of osmotic demyelination syndrome. Some cases, such as this one, spare the pons (not shown) completely and affect only the basal ganglia &/or cortex. The hemispheric white matter is not involved in this case.*

https://CafePezeshki.IR

KEY FACTS

TERMINOLOGY

- Radiation-induced injury may be divided into acute, subacute/early delayed, late injury

IMAGING

- **Radiation injury**: Mild vasogenic edema to necrosis
- **Radiation necrosis**: Irregular enhancing lesion(s)
  - MRS: Markedly ↓ metabolites (NAA, Cho, Cr), ± lactate/lipid peaks
  - Perfusion MR: ↓ rCBV compared with tumor
- **Leukoencephalopathy**: T2 white matter (WM) hyperintensity, spares subcortical U-fibers
- **Mineralizing microangiopathy**: Basal ganglia (BG), subcortical WM Ca++, atrophy
- **Necrotizing leukoencephalopathy**: WM necrosis
- **PRES**: Posterior circulation subcortical WM edema
- MRS, MR perfusion, PET, or SPECT may help delineate recurrent tumor from radiation necrosis

TOP DIFFERENTIAL DIAGNOSES

- Neoplasm
- Abscess
- Multiple sclerosis
- Vascular dementia
- Progressive multifocal leukoencephalopathy

PATHOLOGY

- 2nd neoplasms: Meningiomas (70%), gliomas (20%), sarcomas (10%)
  - More aggressive tumors, highly refractory
  - Incidence: 3-12%
- Radiation-induced vascular malformations: Capillary telangiectasias ± cavernomas (CM)

CLINICAL ISSUES

- Overall incidence of radionecrosis: 3-9%
- Worse prognosis: Younger patient at treatment

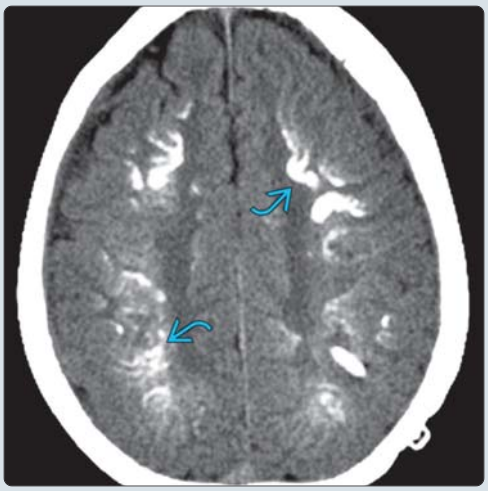

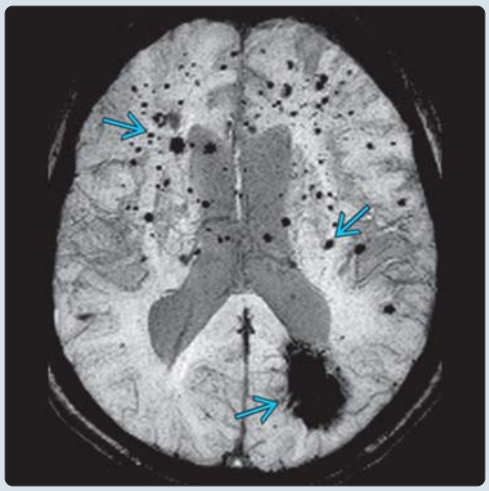

(Left) *Axial NECT shows extensive calcification in the subcortical white matter (WM) in a 20-year-old patient. Mineralizing microangiopathy usually results after a combination of radiation therapy and chemotherapy 2 or more years after treatment.* **(Right)** *Axial SWI in an adult patient with neurofibromatosis and optic nerve glioma status post radiation therapy in childhood shows innumerable "blooming" hypointense foci consistent with radiation-induced vascular malformations.*

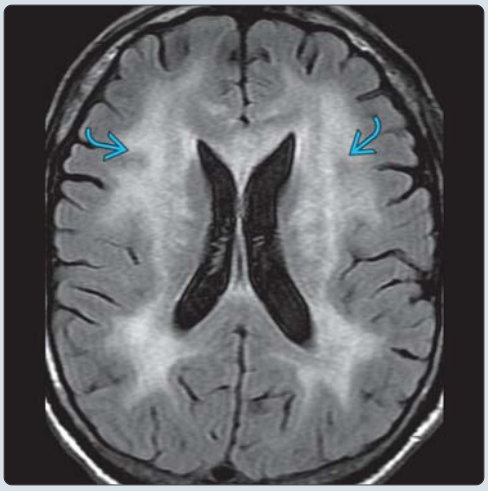

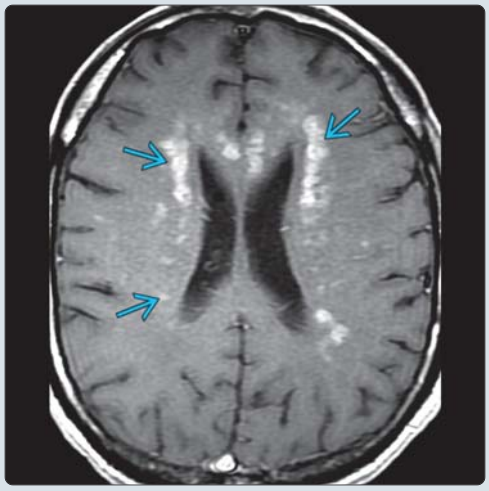

(Left) *Axial FLAIR MR in a 22 year old with acute leukemia treated with intrathecal methotrexate shows confluent periventricular and deep white matter hyperintensities with sparing of the subcortical white matter.* **(Right)** *Axial T1 C+ MR in the same patient shows multiple nodular enhancing lesions in the WM. Findings are consistent with chemotherapy-induced necrotizing leukoencephalopathy. Leukoencephalopathy is a potentially serious complication of chemotherapy.*

https://CafePezeshki.IR

TERMINOLOGY

Abbreviations

- Radiation-induced injury (RII)

Synonyms

- Radiation (XRT) changes, chemotherapy effects, treatment-related changes

Definitions

- RII may be divided into acute (during or shortly after radiation), subacute/early delayed (typically up to 12 weeks after radiation), and late (months to years after completion of radiation)
- Includes radiation injury (edema, arteritis), radiation necrosis, leukoencephalopathy, mineralizing microangiopathy, necrotizing leukoencephalopathy, posterior reversible encephalopathy syndrome (PRES), radiation-induced tumors

IMAGING

General Features

- Best diagnostic clue
  - Radiation injury: Mild vasogenic edema to necrosis
  - Radiation necrosis: Irregular enhancing lesion(s)
  - Leukoencephalopathy: T2 white matter (WM) hyperintensity, spares subcortical U-fibers
  - Mineralizing microangiopathy: Basal ganglia (BG), subcortical WM Ca++, atrophy
  - Necrotizing leukoencephalopathy (NLE): WM necrosis ± Ca++
  - PRES: Posterior circulation subcortical WM edema
- Location
  - Radiation injury occurs in radiation port
  - Periventricular WM especially susceptible
  - Subcortical U-fibers and corpus callosum spared

CT Findings

- NECT
  - Subacute/early delayed RII: Confluent WM low-density edema
  - Late RII: Focal/multiple WM low density
  - **Leukoencephalopathy**: Symmetric WM hypodensity
  - **Mineralizing microangiopathy**: BG, subcortical WM Ca++, atrophy
  - **NLE**: Extensive areas of WM necrosis, Ca++
  - **PRES**: Subcortical WM edema, posterior circulation

MR Findings

- T1WI
  - Subacute/early delayed RII: Periventricular WM hypointense edema
  - Late RII: Focal or multiple WM hypointensities
  - **Leukoencephalopathy**: Diffuse, symmetric WM hypointensity; spares subcortical U-fibers
  - **Mineralizing microangiopathy**: Putamen hyperintensity, atrophy
- T2WI
  - Acute RII: Usually normal or transient diffuse brain swelling
  - Subacute/early delayed RII: Focal or multiple hyperintense WM lesions with edema, demyelination
    - Spares subcortical U-fibers and corpus callosum
  - Late RII: Diffuse WM injury or necrosis
    - Hyperintense WM lesion(s), ± hypointense rim
    - Mass effect and edema
  - **Leukoencephalopathy**: Diffuse, symmetric involvement of central and periventricular WM, relative sparing of subcortical U-fibers
  - **Mineralizing microangiopathy**: ↓ signal
  - **NLE**: Extensive WM necrosis
  - **PRES**: Confluent, symmetric hyperintensity in subcortical WM, ± cortex, posterior circulation
    - Occipital, parietal, posterior temporal lobes, cerebellum typical
    - May involve frontal lobes, BG, brainstem
- T2* GRE
  - **Radiation-induced vascular malformations**: "Blooming" related to blood products
- DWI
  - Recurrent tumor lower ADC values than radiation necrosis
- T1WI C+
  - Subacute/early delayed RII: ± patchy enhancement
  - Late RII: Enhancement often resembles residual/recurrent tumor
    - May see nodular, linear, curvilinear, "soap bubble," or "Swiss cheese" enhancement
    - May have multiple lesions remote from tumor site
  - **NLE**: Marked enhancement, possibly ring
- **MRS**: Markedly ↓ metabolites (NAA, Cho, Cr), ± lactate/lipid peaks in radiation necrosis
- **Perfusion MR**: ↓ rCBV in radiation necrosis

Angiographic Findings

- Radiation-induced vasculopathy: Progressive narrowing of supraclinoid ICA and proximal anterior circulation vessels; may develop moyamoya pattern

Nuclear Medicine Findings

- FDG PET: Radiation necrosis is hypometabolic
- Th-201 SPECT: Radiation necrosis is hypometabolic, ↓ uptake

Imaging Recommendations

- Protocol advice
  - Enhanced MR ± MRS, MR perfusion, PET if question of RII vs. recurrent neoplasm

DIFFERENTIAL DIAGNOSIS

Recurrent Glioblastoma Multiforme (GBM)

- Enhancing mass with central necrosis, mass effect
- MRS shows ↑ Cho, ↓ NAA, ± lactate

Metastasis

- Typically multiple lesions at gray and white matter junctions, significant edema
- MRS shows ↑ Cho, ↓ NAA, ± lactate
- Ring-enhancing mass may mimic radiation necrosis

Abscess

- Ring-enhancing mass, thinner margin along ventricle

https://CafePezeshki.IR

- T2-hypointense rim, diffusion restriction characteristic
- MRS shows metabolites, such as succinate, amino acids

Multiple Sclerosis

- Often incomplete, horseshoe-shaped enhancement, open toward cortex
- Other lesions in typical locations, young patients

Vascular Dementia

- Large and small infarcts, WM disease
- Typically older patients, clinical diagnosis

Progressive Multifocal Leukoencephalopathy

- WM T2 hyperintensity, involves subcortical U-fibers
- May cross corpus callosum; usually no enhancement
- Immunosuppressed patients

Foreign Body Reaction

- Granulomatous reaction (i.e., to gelatin sponge)
- Can mimic tumor recurrence, radiation necrosis

PATHOLOGY

General Features

- Etiology
  - **Radiation-induced vascular injury**
    - Permeability alterations, endothelial and basement membrane damage, accelerated atherosclerosis, telangiectasia formation
  - **Radiation-induced neurotoxicity**
    - Glial and WM damage (sensitivity of oligodendrocytes > > neurons)
  - **Radiation-induced tumor** (i.e., sarcoma)
    - Increased risk in patients with XRT ≤ 5 years old, those with genetic predisposition (NF1, retinoblastoma), bone marrow transplant survivors
  - **Radiation-induced cryptic vascular malformations**: Predominantly capillary telangiectasias ± cavernomas
  - **Mineralizing microangiopathy**: Common with chemotherapy and XRT, appears ≥ 2 years after XRT
  - **Necrotizing leukoencephalopathy**: Combined XRT and chemotherapy, progressive disease
  - **PRES**: Related to elevated blood pressure that exceeds autoregulatory capacity of brain vasculature
  - Many chemotherapy agents cause CNS effects: Methotrexate, cytarabine, carmustine, cyclophosphamide, cisplatin
  - **RII variables**: Total dose, field size, fraction size, number/frequency of doses, adjuvant therapy, survival duration, patient age

Staging, Grading, & Classification

- Neurotoxic reaction to radiation therapy divided into acute, early, and late delayed injury
  - **Acute** injury: Mild and reversible, vasogenic edema
  - **Subacute/early delayed** injury: Edema and demyelination
  - **Late** injury: More severe, irreversible

Gross Pathologic & Surgical Features

- XRT: Spectrum from edema to cavitating WM necrosis
- Radiation necrosis: Coagulation necrosis that favors WM, may extend to deep cortex

Microscopic Features

- Acute RII: WM edema from capillary damage
- Subacute/early delayed RII: Vasogenic edema, demyelination, perivascular lymphocytic infiltrates, gliosis
- Late RII: WM necrosis, demyelination, astrocytosis, vasculopathy,
- Radiation necrosis: Confluent coagulative necrosis, Ca++, hyaline thickening and fibrinoid necrosis of vessels, thrombosis
- Mineralizing microangiopathy: Hyalinization and fibrinoid necrosis of small arteries and arterioles with endothelial proliferation, Ca++ deposition

CLINICAL ISSUES

Presentation

- Most common signs/symptoms
  - Highly variable
  - Acute RII: Signs of ↑ intracranial pressure with headache, nausea/vomiting, &/or mental status changes
  - Subacute/early delayed RII: Somnolence syndrome characterized by fatigue and lethargy
  - Radiation necrosis: Usually seen 2-32 months after therapy
    - 85% of cases occurring within 2 years

Demographics

- Epidemiology
  - Overall incidence of radionecrosis: 3-9%
    - < 5% with 60 Gy of radiation in daily 2 Gy fractions
  - Radiation-induced neoplasms: 3-12%
    - Meningiomas (70%), gliomas (20%), sarcomas (10%)

Natural History & Prognosis

- Younger patient at time of treatment: Worse prognosis
- Radiation necrosis is dynamic pathophysiological process; often progressive, irreversible

Treatment

- Biopsy if imaging does not resolve tumor vs. radionecrosis
- Surgery if mass effect, edema
- Acute radiation injury may respond to steroids

DIAGNOSTIC CHECKLIST

Consider

- Distinguishing residual/recurrent neoplasm from XRT necrosis difficult using morphology alone

Image Interpretation Pearls

- MRS, MR perfusion, PET, or SPECT may help delineate recurrent tumor from radiation necrosis

SELECTED REFERENCES

1. Nolan CP et al: Neurologic complications of chemotherapy and radiation therapy. Continuum (Minneap Minn). 21(2 Neuro-oncology):429-51, 2015
2. Zhang H et al: Role of magnetic resonance spectroscopy for the differentiation of recurrent glioma from radiation necrosis: a systematic review and meta-analysis. Eur J Radiol. 83(12):2181-9, 2014
3. Reddy K et al: MRI patterns of T1 enhancing radiation necrosis versus tumour recurrence in high-grade gliomas. J Med Imaging Radiat Oncol. 57(3):349-55, 2013
4. Shah R et al: Radiation necrosis in the brain: imaging features and differentiation from tumor recurrence. Radiographics. 32(5):1343-59, 2012

https://CafePezeshki.IR

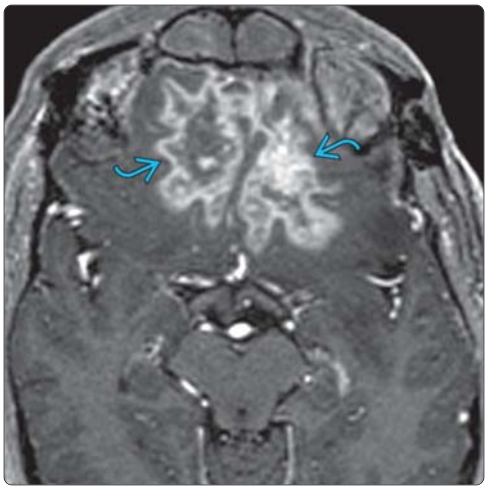

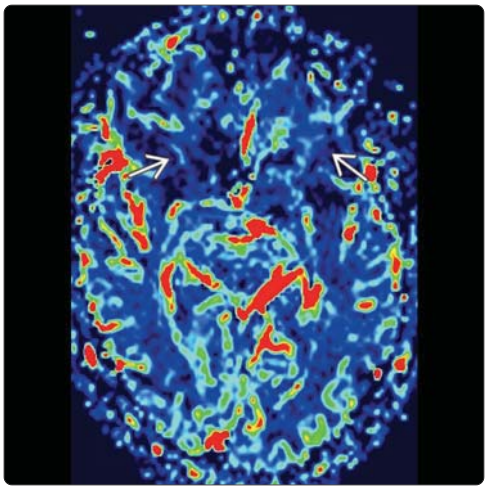

(Left) *Axial T1WI C+ MR in a patient with esthesioblastoma 6 months post radiation shows masses in the inferior frontal lobes with a spreading wavefront enhancement pattern.* **(Right)** *MR perfusion rCBV map in the same patient does not show any significant increase in the relative cerebral volume in the regions of enhancement. Findings are typical of radiation necrosis. Radiation necrosis can occur months to years after radiation therapy. More than 85% of cases occur within 2 years.*

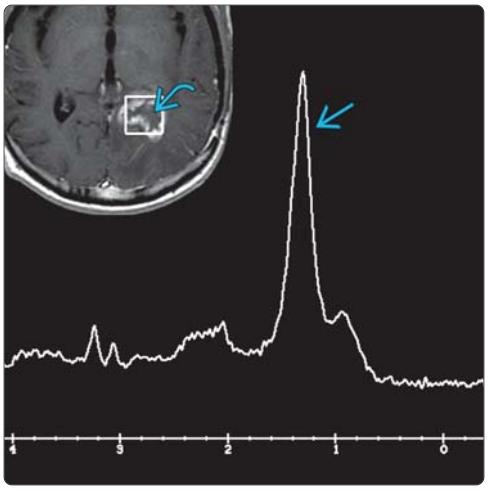

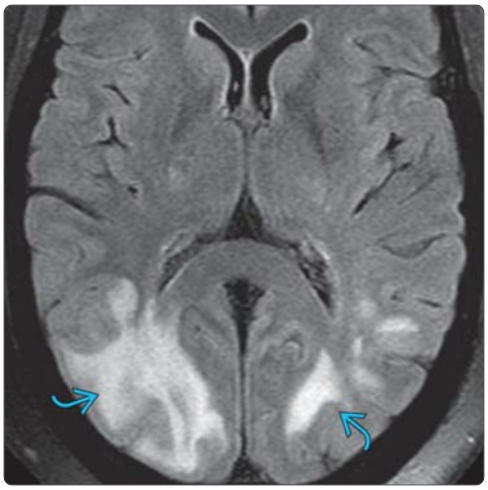

(Left) *Single-voxel MR spectroscopy at 35 TE in a patient status post resection of a metastasis and radiation therapy who developed a necrotic enhancing lesion in the left parietal lobe shows markedly elevated lipid/lactate peak with reduction in the rest of the metabolites.* **(Right)** *Axial FLAIR MR in a patient status post renal transplant on cyclosporine shows characteristic changes of PRES with asymmetric occipital cortical/subcortical edema.*

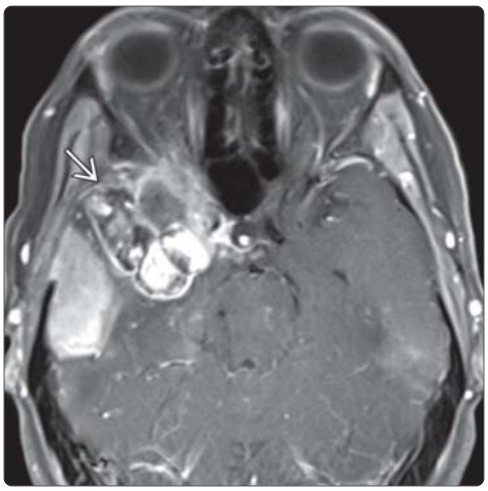

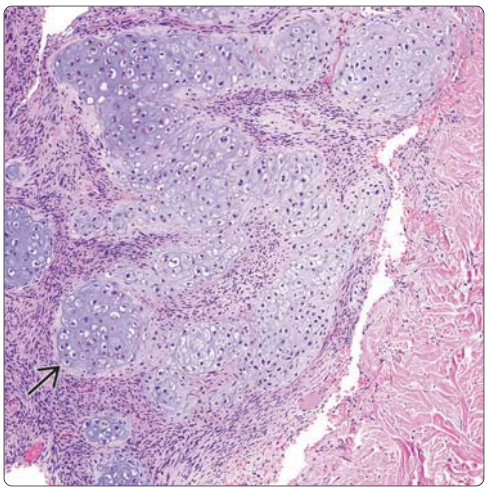

(Left) *Axial T1WI C+ FS MR shows a heterogeneous mass in the anterior middle cranial fossa in a patient with prior surgery and radiation therapy for a WHO grade I meningioma.* **(Right)** *High-power micropathology (same patient) shows chondrosarcoma elements at repeat resection. A 2nd neoplasm occurs in 3-12% of patients treated with radiation therapy. Though radiation-induced tumors are rare (seen in 3-12% of cases), they are most commonly meningiomas (70%), gliomas (20%), or sarcomas (10%).*

https://CafePezeshki.IR

Pseudoprogression

KEY FACTS

TERMINOLOGY

- Treatment-related increase in contrast enhancement mimics tumor progression
- Classically described after treatment with chemoradiation (temozolomide with radiation therapy)
- Typically occurs within 3-6 months after conclusion of radiation therapy (XRT)

IMAGING

- New enhancing lesion + ↑ FLAIR hyperintensity in treated malignant glioma at 3-4 months after XRT completion
- T2/FLAIR: Increased hyperintensity with mass effect
- DWI: Higher ADC values in PsP compared with tumor
- DSC: Lower mean rCBV values in PsP compared with tumor
- DCE: Mean K trans (volume transfer constant) is lower in PsP compared with true progression
- MRS: No significant elevation of choline in Psp
- Best Imaging: Contrast-enhanced MR, DWI, ± MRS, MRP
- Follow-up studies may be necessary to make accurate diagnosis of PsP
- Knowing clinical history and timing of therapy is key to accurate brain tumor imaging

TOP DIFFERENTIAL DIAGNOSES

- Recurrent malignant glioma
- Radiation necrosis

CLINICAL ISSUES

- Current standard of care for malignant gliomas is surgical resection followed by concurrent XRT and chemotherapy with temozolomide (Temodar)
  - PsP occurs in ~ 35-50% of patients
- PsP is self-limited, enhancing lesions resolve without new treatment
- PsP has been associated with **improved survival**
- Important to recognize that not all new enhancement in a patient with a treated GBM is progressive tumor

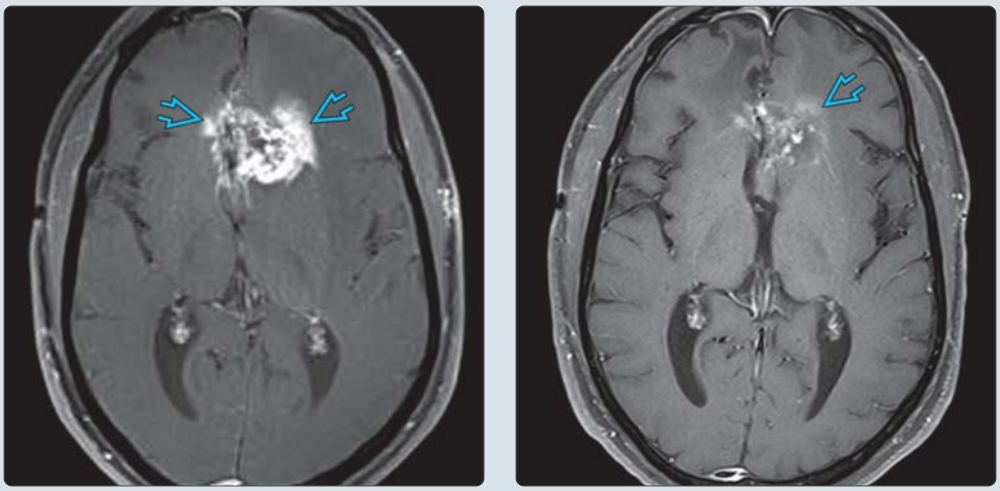

(Left) *Axial T1 C+ MR in a 48-year-old man treated with radiation therapy and Temodar for 3 months for his malignant glioma shows new enhancement in the frontal lobes bilaterally. His initial postoperative MR study showed no enhancement. He was clinically doing well.* **(Right)** *Axial T1 C+ MR in the same patient 4 weeks later shows a marked decrease in the enhancement without a change in therapy. Imaging findings are related to pseudoprogression, not true progression, likely related to an inflammatory response.*

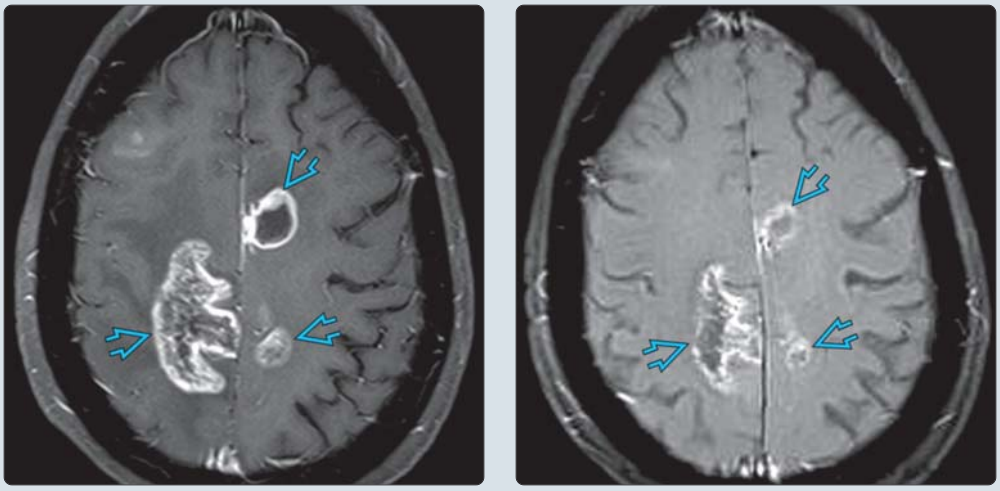

(Left) *Axial T1 C+ MR in a 62-year-old woman with a multifocal glioblastoma (GBM) treated with Temodar and radiation therapy shows new enhancement in the hemispheres on her 4-month scan, concerning for progressive tumor.* **(Right)** *Axial T1 C+ MR in the same patient 8 weeks later with no therapy change shows a marked decrease in the enhancing lesions. The new enhancement was related to pseudoprogression (PsP), which is associated with an increased survival.*

https://CafePezeshki.IR

TERMINOLOGY

Abbreviations

- Pseudoprogression (PsP)

Synonyms

- Treatment-related enhancement

Definitions

- Treatment-related increase in contrast enhancement mimicking tumor progression
  - Classically described after treatment with chemoradiation (temozolomide with radiation therapy)
- Typically occurs within 3-6 months after conclusion of radiotherapy (XRT)
- Self-limited, enhancing lesions resolve without new treatment

IMAGING

General Features

- Best diagnostic clue
  - New enhancement with ↑ FLAIR hyperintensity in treated glioblastoma (GBM) at 3-4 months after XRT completion
- Location
  - Region of previously treated neoplasm or in adjacent brain
  - Typically within radiation field

MR Findings

- T1WI
  - Typically hypointense
- T2WI
  - Hyperintense with mass effect, ± focal mass
- FLAIR
  - Hyperintense with mass effect, ± focal mass
- DWI
  - Higher ADC values and ratios in PsP compared with tumor
- PWI
  - DSC: Lower mean rCBV values in PsP compared with recurrent tumor
    - Significant overlap in values
  - DCE: Mean K trans (volume transfer constant) is lower in PsP compared with true progression
  - Extravascular extracellular space per unit volume of tissue (Ve) is lower in PsP
- T1WI C+
  - Enhancing mass

DIFFERENTIAL DIAGNOSIS

Recurrent Malignant Glioma

- New enhancement in previously treated neoplasm
- Subependymal spread is suggestive of recurrent tumor
- DWI: Low ADC values
- PWI: High CBV suggestive of recurrent tumor

Radiation Necrosis

- Enhancement in region of previously treated neoplasm or vascular lesion
- T2/FLAIR hyperintensity with mass effect
- Imaging overlap with pseudoprogression
- MRS, MR perfusion may help differentiate
- Typically occurs ≥ 12-18 months to many years after therapy

Pseudoresponse

- Decreased enhancement related to antiangiogenic agents (i.e., Avastin) rather than true response
- Tumor typically hyperintense on FLAIR and DWI
- Related to reduced vascular permeability
- Often results in growth of nonenhancing infiltrative tumor

PATHOLOGY

General Features

- Etiology is thought to be related to vascular and oligodendroglial injury leading to inflammation and increased permeability of blood-brain barrier

Gross Pathologic & Surgical Features

- Vascular dilation, fibrinoid necrosis, endothelial damage of normal cerebral vasculature

CLINICAL ISSUES

Presentation

- Most common signs/symptoms
  - Typically asymptomatic
  - May have symptoms related to increased mass effect

Natural History & Prognosis

- Current standard of care for malignant gliomas is surgical resection followed by concurrent XRT and chemotherapy with temozolomide (Temodar)
  - Incidence of PsP is 30-50% of treated patients
- Likely increases with increasing radiation dose
- PsP has been associated with **improved survival**
  - May be related to favorable correlation with methylated O6-methylguanine-DNA methyltransferase (MGMT) promoter status

Treatment

- No change in therapy is required
- Some oncologists treat with steroids

DIAGNOSTIC CHECKLIST

Consider

- New enhancement and mass effect in a malignant glioma does not always mean disease progression
- Follow-up studies may be necessary to make accurate diagnosis of pseudoprogression

SELECTED REFERENCES

1. Boxerman JL et al: Response Assessment and Magnetic Resonance Imaging Issues for Clinical Trials Involving High-Grade Gliomas. Top Magn Reson Imaging. 24(3):127-36, 2015
2. Yun TJ et al: Glioblastoma treated with concurrent radiation therapy and temozolomide chemotherapy: differentiation of true progression from pseudoprogression with quantitative dynamic contrast-enhanced MR imaging. Radiology. 274(3):830-40, 2015
3. Hygino da Cruz LC Jr et al: Pseudoprogression and pseudoresponse: imaging challenges in the assessment of posttreatment glioma. AJNR Am J Neuroradiol. 32(11):1978-85, 2011

https://CafePezeshki.IR

KEY FACTS

TERMINOLOGY

- Antiangiogenic agents may substantially reduce contrast enhancement in GBM related to reduced vascular permeability rather than actual tumor response
  - **Bevacizumab** (Avastin): An anti-VEGF is main antiangiogenic agent currently used for treatment of recurrent malignant gliomas
  - **Cediranib**: VEGF receptor tyrosine kinase inhibitor, has been tested in recent high-grade glioma treatment trials

IMAGING

- Decreased enhancement in a patient with malignant glioma treated with anti-VEGF agent
  - May see persistent FLAIR and diffusion restriction, despite decreased enhancement
- DWI and ADC have been proposed as imaging markers for tumor response in presence of antiangiogenic agents to address pseudoresponse
- Beware, decreased enhancement in tumor follow-up study may be true treatment response or pseudoresponse in setting of newer therapies
- DSC: Early changes in rCBV after initiation of antiangiogenic therapy may distinguish pseudoresponse from true treatment response

TOP DIFFERENTIAL DIAGNOSES

- Treatment response
- Steroid effect

CLINICAL ISSUES

- Antiangiogenic agents normalize hyperpermeable tumor vasculature and restore blood-brain barrier
- Local response to tumor growth is controlled, but diffuse infiltration and distant metastases are common
- Antiangiogenic agents significantly improve 6-month progression-free survival, but may not affect overall survival

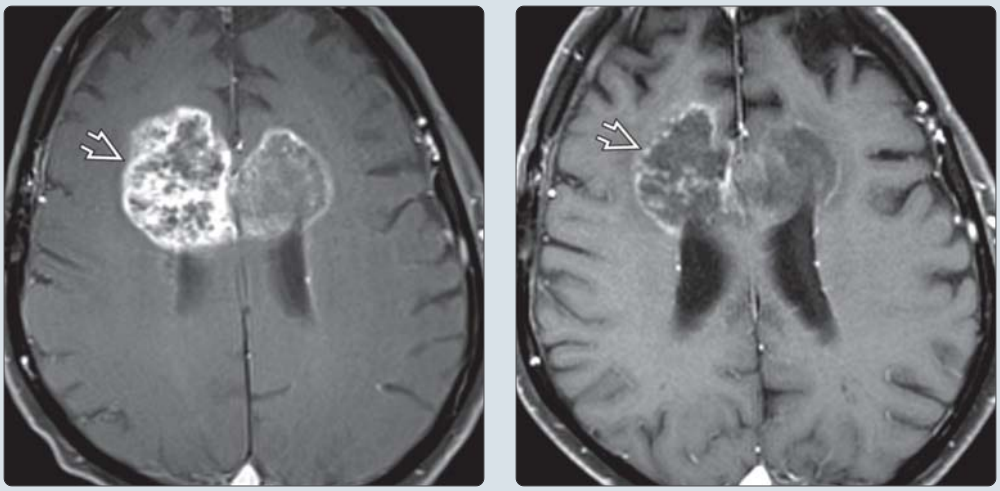

(Left) *Axial T1 C+ MR in a GBM patient who progressed on standard therapy with radiation and Temodar shows there is a heterogeneously enhancing mass involving the genu of the corpus callosum ⇨. Avastin therapy was started immediately after this MR examination.* **(Right)** *Axial T1 C+ MR in the same patient 4 weeks after the start of Avastin shows a marked decrease in the enhancing mass involving the genu of the corpus callosum ⇨. The FLAIR and DWI image showed stable hyperintensity and mass effect.*

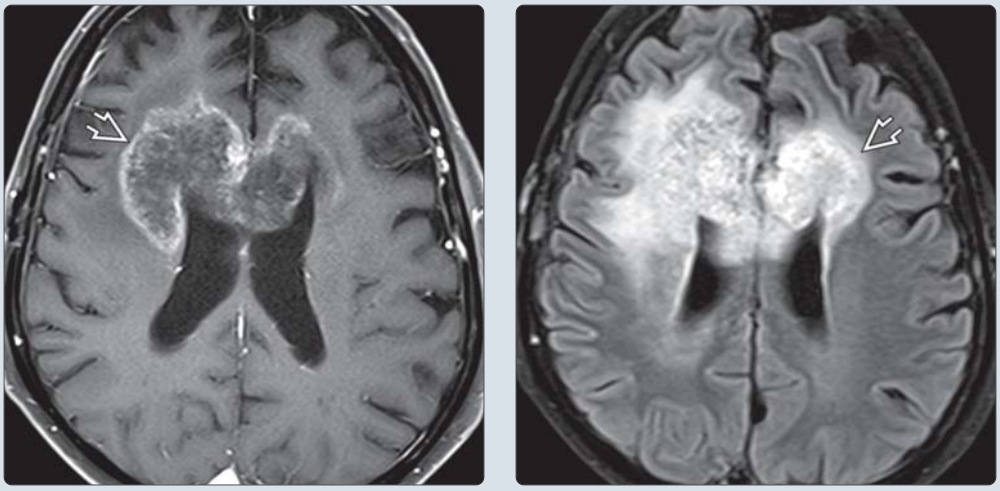

(Left) *Axial T1 C+ MR in the same patient 8 weeks later shows an increase in the size of the corpus callosum enhancing mass ⇨.* **(Right)** *Axial FLAIR MR in the same patient shows a marked increase in the size ⇨ and associated mass effect of the corpus callosum mass related to progressive tumor. Decreased enhancement on the prior MR is a result of pseudoresponse from the antiangiogenic therapy, rather than true tumor response. Diffuse tumor infiltration is common after antiangiogenic therapy.*

https://CafePezeshki.IR

TERMINOLOGY

Abbreviations

- Vascular endothelial growth factor (VEGF)

Synonyms

- Treatment effect, Avastin effect

Definitions

- Antiangiogenic agents may substantially reduce contrast enhancement in glioblastoma multiforme (GBM) related to reduced vascular permeability rather than actual tumor response
  - **Bevacizumab** (Avastin): An anti-VEGF antibody is the main antiangiogenic agent currently used for treatment of recurrent malignant gliomas
  - **Cediranib**: A VEGF receptor tyrosine kinase inhibitor, has been tested in recent high-grade glioma treatment trials with similar effects

IMAGING

General Features

- Best diagnostic clue
  - Decreased enhancement +/- decreased FLAIR in patient with malignant glioma treated with anti-VEGF agent, typically bevacizumab
  - May see persistent FLAIR and diffusion restriction, despite decreased enhancement

MR Findings

- T2WI
  - Hyperintense, +/- focal mass
- FLAIR
  - Hyperintense, +/- focal mass
- DWI
  - Diffusion restriction with low ADC in actual tumor
  - Some suggest increased ADC in patients with favorable response to therapy
  - Decreased ADC suggest poor prognosis
- PWI
  - DSC: Early changes in rCBV after initiation of antiangiogenic therapy may distinguish pseudoresponse from true treatment response
    - Greater decrease in rCBV of the tumor microvessels associated with increased overall survival
    - Increased CBF may be associated with favorable survival
  - DCE: Greater reduction in Ktrans seen in patients with increased survival
  - Use of indices, such as the vascularization normalization index (VNI), may help predict those patients who will respond better to treatment
- T1WI C+
  - Decreased enhancement

DIFFERENTIAL DIAGNOSIS

Treatment Response

- True reduction in tumor volume
- Decreased enhancement
- Decreased FLAIR hyperintensity, mass effect

Steroid Effect

- Steroids reestablish blood-brain barrier
- May decrease enhancement of tumor without decrease in actual tumor
- Imaging similar to pseudoresponse

Pseudoprogression

- Increased enhancement and mass effect without actual change in tumor
- Typically seen at 3-4 months following temozolomide, external radiation therapy (XRT)

PATHOLOGY

General Features

- Decrease in contrast enhancement from antiangiogenic therapy results in change in vascular permeability, with "normalization" of blood brain barrier
  - Not true tumor reduction
- Local response to tumor growth is controlled, but diffuse infiltration and distant metastases are common
- Antiangiogenic agents improve 6-month progression-free survival, may not change overall survival

CLINICAL ISSUES

Presentation

- Most common signs/symptoms
  - No corresponding clinical response

Natural History & Prognosis

- Antiangiogenic agents produce rapid ↓ in contrast enhancement with high response rate and 6-month progression-free survival, with modest effects on overall survival
- Tendency for growth of nonenancing infiltrative tumor prior to emergence of contrast enhancement in ~ 30-40%

DIAGNOSTIC CHECKLIST

Consider

- Significant rapid improvement in imaging appearance of tumor without affecting biologic activity of tumor itself is related to pseudoresponse

Image Interpretation Pearls

- DWI and ADC have been proposed as imaging markers for tumor response in presence of antiangiogenic agents to address this issue of pseudoresponse
- Beware, decreased enhancement in tumor follow-up study may be true treatment response or pseudoresponse in setting of newer therapies (bevacizumab)

SELECTED REFERENCES

1. Boxerman JL et al: Response Assessment and Magnetic Resonance Imaging Issues for Clinical Trials Involving High-Grade Gliomas. Top Magn Reson Imaging. 24(3):127-36, 2015
2. Hygino da Cruz LC Jr et al: Neuroimaging and genetic influence in treating brain neoplasms. Neuroimaging Clin N Am. 25(1):121-40, 2015
3. Shim H et al: Use of high-resolution volumetric MR spectroscopic imaging in assessing treatment response of glioblastoma to an HDAC inhibitor. AJR Am J Roentgenol. 203(2):W158-65, 2014
4. Hygino da Cruz LC Jr et al: Pseudoprogression and pseudoresponse: imaging challenges in the assessment of posttreatment glioma. AJNR Am J Neuroradiol. 32(11):1978-85, 2011

https://CafePezeshki.IR

KEY FACTS

TERMINOLOGY

- Seizure-associated neuronal loss and gliosis in hippocampus and adjacent structures

IMAGING

- Primary features: Abnormal T2 hyperintensity, hippocampal volume loss/atrophy, obscuration of internal architecture
- Secondary signs: Ipsilateral fornix and mammillary body atrophy, enlarged ipsilateral temporal horn, and choroidal fissure
- ↑ hyperintensity on DWI (T2 shine through)
- ↓ NAA in hippocampus, temporal lobe

TOP DIFFERENTIAL DIAGNOSES

- Status epilepticus
- Low-grade astrocytoma
- Choroidal fissure cyst
- Hippocampal sulcus remnant

PATHOLOGY

- Prolonged febrile seizures may produce acute hippocampal injury → subsequent atrophy
- Coexistent 2nd developmental lesion in 15% of mesial temporal sclerosis (MTS) patients

CLINICAL ISSUES

- Partial complex seizures
- Often history of childhood febrile or medically intractable seizures
- Surgical temporal lobectomy reserved for medically intractable seizures, intolerable drug side effects

DIAGNOSTIC CHECKLIST

- Most common cause of partial complex epilepsy in adult age group
- Low-grade neoplasms and cortical dysplasia more common causes of partial complex epilepsy than MTS in pediatric age group

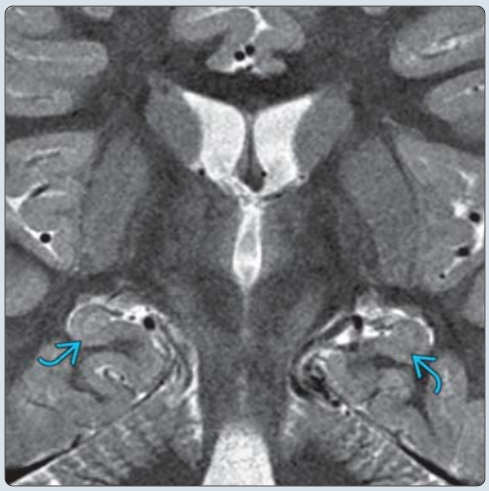

(Left) *Coronal graphic depicts the characteristic appearance of mesial temporal sclerosis (MTS). The right hippocampus ➡ is small (atrophic) with loss of normal internal architecture reflecting neuronal loss and gliosis. Note concordant atrophy of the ipsilateral fornix ⇨ and widening of the ipsilateral temporal horn and choroidal fissure.* **(Right)** *Coronal STIR MR at 3.0 tesla in a normal nonepileptic patient imaged for headaches demonstrates normal bilateral hippocampal anatomy ⇨, size, and signal intensity.*

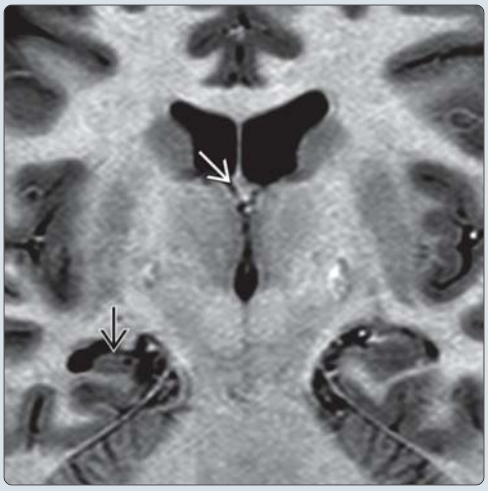

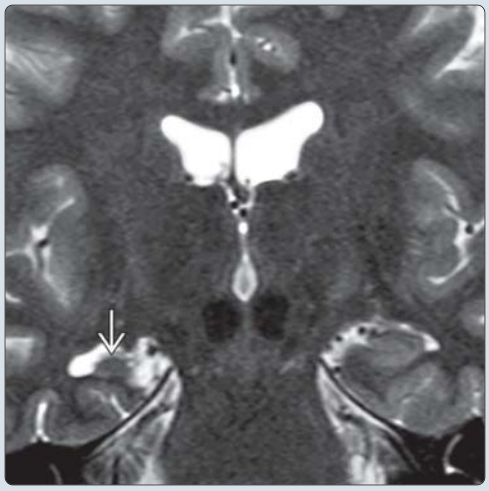

(Left) *Coronal T1-weighted true inversion recovery MR at 3.0 tesla shows asymmetric right hippocampal volume loss ⇨ and obscuration of normal internal gray-white differentiation. The ipsilateral fornix ➡ is smaller than the normal left fornix.* **(Right)** *Coronal T2-weighted MR at 3.0 tesla in the same patient with right hippocampal sclerosis (HS) ➡ shows hippocampal volume loss and obscuration of normal internal architecture, but normal T2 signal intensity. FLAIR better shows the increase in signal intensity.*

https://CafePezeshki.IR

TERMINOLOGY

Abbreviations

- Mesial temporal sclerosis (MTS)

Synonyms

- Ammons horn sclerosis, hippocampal sclerosis (HS)

Definitions

- Seizure-associated neuronal loss and gliosis in hippocampus and adjacent structures

IMAGING

General Features

- Best diagnostic clue
  - Primary features: Abnormal T2 hyperintensity, hippocampal volume loss/atrophy, obscuration of internal architecture
  - Secondary signs: Ipsilateral fornix and mammillary body atrophy, enlarged ipsilateral temporal horn, and choroidal fissure
  - Additional findings: Loss of ipsilateral hippocampal head (pes) digitations, parahippocampal gyrus white matter atrophy, ↑ T2 signal in anterior temporal white matter
- Location
  - Mesial temporal lobe(s), 10-20% bilateral
  - Hippocampus > amygdala > fornix > mammillary bodies
- Size
  - Slight to marked ↓ in hippocampal volume
- Morphology
  - Abnormal shape, size of affected hippocampus

CT Findings

- NECT
  - Usually normal; CT insensitive to MTS

MR Findings

- T1WI
  - ↓ hippocampal size
  - Loss of normal hippocampal gray-white differentiation
  - ± ipsilateral fornix, mammillary body atrophy
  - Quantitative hippocampal volumetry: ↑ sensitivity of MTS detection (particularly bilateral MTS)
- T2WI
  - Hippocampal atrophy
  - Obscuration of normal internal architecture
  - ↑ hippocampal signal intensity
  - ± ipsilateral fornix, mammillary body atrophy, dilatation of ipsilateral temporal horn
  - ± abnormal hyperintensity, volume loss in ipsilateral anterior temporal lobe
- FLAIR
  - Hyperintense signal in abnormal hippocampus
- DWI
  - ↑ hyperintensity on DWI (T2 shine through)
  - ↑ diffusivity on ADC
- T1WI C+
  - No enhancement
- MRS
  - ↓ NAA in hippocampus, temporal lobe
  - ↓ NAA/Cho and ↓ NAA/Cho+Cr suggests MTS
  - ± lactate/lipid peaks after 24 hours of continual seizure

Angiographic Findings

- Presurgical Wada testing: Neuropsychological testing after intracarotid amobarbital (Amytal) injection
  - Lateralize memory and language functions
  - Predict postoperative memory loss, feasibility of surgery
  - May help lateralize seizure onset
- fMRI mapping replacing Wada testing

Nuclear Medicine Findings

- FDG PET: Hypometabolism in abnormal mesial temporal lobe
- SPECT: Hypoperfusion (interictal) or hyperperfusion (ictal) in epileptogenic zone
  - Sensitivity of ictal > interictal

Imaging Recommendations

- Best imaging tool
  - High-resolution MR imaging
  - MRS, quantitative volumetry may help lateralize MTS in difficult cases
- Protocol advice
  - Thin-section coronal T2WI and FLAIR (3 mm), angled perpendicular to long axis of hippocampus
  - Thin-section coronal 3D SPGR (1-2 mm), angled perpendicular to long axis of hippocampus

DIFFERENTIAL DIAGNOSIS

Status Epilepticus

- Clinical history of multiple seizures or status epilepticus
- Temporary T2 hyperintensity ± gyriform enhancement in affected cortex, hippocampus

Low-Grade Astrocytoma

- Hyperintense temporal lobe white matter mass (usually nonenhancing)
- ± seizures, young adults typical

Choroidal Fissure Cyst

- Asymptomatic CSF signal cyst in choroidal fissure distorts normal hippocampus
  - Round on axial, coronal images
  - Oval, parallels temporal lobe long axis on sagittal imaging
- No abnormal T2 hyperintensity in mesial temporal lobe

Hippocampal Sulcus Remnant

- Failure of normal hippocampal sulcus involution → asymptomatic cyst between dentate gyrus, cornu ammonis
- Common normal variant (10-15%)

Cavernous Malformation

- Heterogeneous hyperintense "popcorn" lesion with dark complete hemosiderin rim
- ± seizures

Dysembryoplastic Neuroepithelial Tumor (DNET)

- Demarcated "bubbly," variably enhancing cortical mass ± regional cortical dysplasia
- Partial complex seizures

https://CafePezeshki.IR

Cortical Dysplasia

- Most common dual pathology associated with MTS
- T2 hyperintensity in anterior temporal white matter

PATHOLOGY

General Features

- Etiology
  - Controversial whether acquired or developmental
    - Acquired: Follows complicated febrile seizures, status epilepticus, encephalitis
    - Developmental: 2nd developmental lesion identified in 15%
    - "Two-hit" hypothesis: 1st an initial precipitating injury (like complicated seizures), 2nd an increased vulnerability (such as genetic predisposition or developmental anomaly)
    - Most likely MTS represents common outcome of both acquired and developmental processes
  - Febrile seizures (FS) most common childhood seizure disorder (2-5%)
    - Prolonged FS may produce acute hippocampal injury → subsequent atrophy
- Genetics
  - Familial cases of mesial temporal lobe epilepsy (TLE), FS reported
  - Recent studies suggest relationship between FS and later epilepsy development may be genetic
  - Syndrome-specific genes for FS (channelopathies) account for small proportion of FS cases
- Associated abnormalities
  - Coexistent 2nd developmental lesion (15%)

Gross Pathologic & Surgical Features

- Normal hippocampus divided anatomically into head (pes), body, tail
  - Subdivision into Ammons horn, dentate gyrus, hippocampal sulcus, fimbria, alveus, subiculum, parahippocampal gyrus, collateral sulcus
- Mesial temporal lobe atrophy: Hippocampal body (88%), tail (61%), head (51%), amygdala (12%)
- Absence of hemorrhage or necrosis

Microscopic Features

- Chronic astrogliosis with fine fibrillary background of bland astrocytic nuclei and decreased residual neurons
- Ammons horn, cornu ammonis (CA), contains 4 zones of granular cells: CA1, CA2, CA3, CA4
  - CA1, CA4 pyramidal cell layers most susceptible to ischemia
  - All hippocampal regions may show varying neuronal cell loss

CLINICAL ISSUES

Presentation

- Most common signs/symptoms
  - Partial complex seizures, automatisms
    - Simple at younger ages and increasingly complex and discrete with age
- Other signs/symptoms
  - May progress to generalized tonic-clonic seizures
- Clinical profile
  - Often history of childhood febrile or medically intractable seizures
    - History of complex or prolonged febrile seizures ↑ risk for development of hippocampal injury, MTS
  - Surface electro- (EEG) or magneto- (MEG) encephalogram helpful for localization (60-90%)
  - Intracranial EEG (subdural or depth electrodes) may be indicated if noninvasive studies discordant

Demographics

- Age
  - Disease of older children, young adults
- Gender
  - No gender predominance
- Epidemiology
  - MTS accounts for majority of epilepsy patients undergoing temporal lobe seizure surgery

Natural History & Prognosis

- Anterior temporal lobectomy 70-95% successful if MR findings are of MTS
- Success of anterior temporal lobectomy 40-55% if MR normal
- ↓ surgical success when amygdala involved

Treatment

- Clinical management based on phenotypic features of initial febrile and subsequent seizures
- Medical treatment initial approach
- Surgical temporal lobectomy reserved for medically intractable seizures, intolerable drug side effects
  - Resection includes anterior temporal lobe, majority of hippocampus, variable portions of amygdala

DIAGNOSTIC CHECKLIST

Consider

- Most common cause of partial complex epilepsy in adults
- Bilateral in 10-20%; difficult to detect without quantitative volumetry unless severe

Image Interpretation Pearls

- Coronal high-resolution T2WI, FLAIR MR most sensitive for MTS
- Dual pathology in 15%
- In pediatric age group, low-grade neoplasms and cortical dysplasia more common causes of partial complex epilepsy than MTS

SELECTED REFERENCES

1. Azab M et al: Mesial Temporal Sclerosis: Accuracy of NeuroQuant versus Neuroradiologist. AJNR Am J Neuroradiol. ePub, 2015
2. Hamelin S et al: Revisiting hippocampal sclerosis in mesial temporal lobe epilepsy according to the "two-hit" hypothesis. Rev Neurol (Paris). 171(3):227-35, 2015
3. French JA et al: Can febrile status cause hippocampal sclerosis? Ann Neurol. 75(2):173-4, 2014
4. Thom M: Review: Hippocampal sclerosis in epilepsy: a neuropathology review. Neuropathol Appl Neurobiol. 40(5):520-43, 2014
5. Blümcke I et al: Defining clinico-neuropathological subtypes of mesial temporal lobe epilepsy with hippocampal sclerosis. Brain Pathol. 22(3):402-11, 2012
6. Malmgren K et al: Hippocampal sclerosis–origins and imaging. Epilepsia. 53 Suppl 4:19-33, 2012

https://CafePezeshki.IR

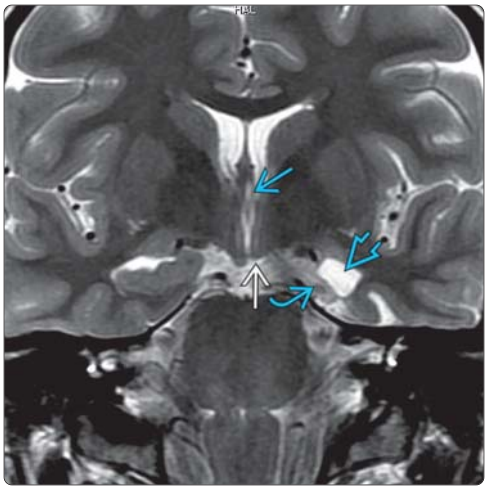

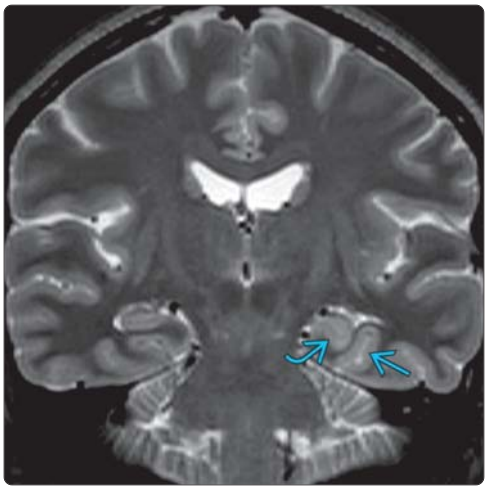

(Left) *Coronal T2 MR in a patient with temporal lobe epilepsy demonstrates primary and secondary imaging features of mesial temporal sclerosis. There is severe left hippocampal atrophy and signal alteration. Note secondary features such as atrophy of the left fornix and mammillary body as well as dilation of temporal horn.* **(Right)** *Coronal T2 MR in a patient with epilepsy shows a vertical left collateral sulcus and a globular hippocampus. This common variation can be mistaken for hippocampal sclerosis.*

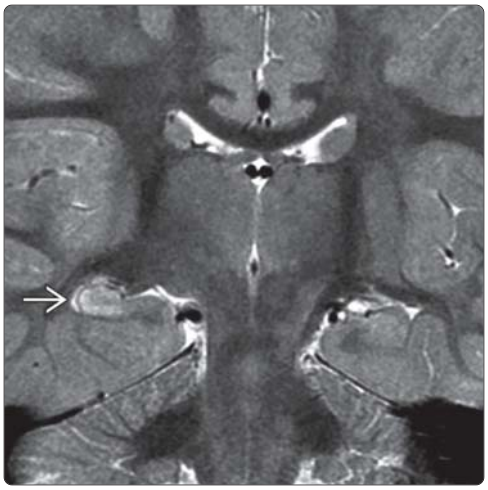

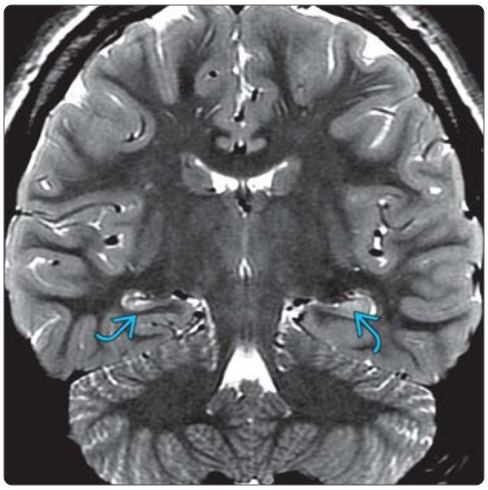

(Left) *Coronal T2-weighted MR at 3.0 tesla in a patient with prolonged febrile seizure shows abnormal enlargement and T2 hyperintensity in the right hippocampus. DWI (not shown) revealed reduced diffusion. The patient later developed hippocampal sclerosis.* **(Right)** *Coronal T2 MR in a patient with longstanding partial complex epilepsy shows bilateral hyperintense hippocampi with volume loss, right greater than left, consistent with bilateral mesial temporal sclerosis.*

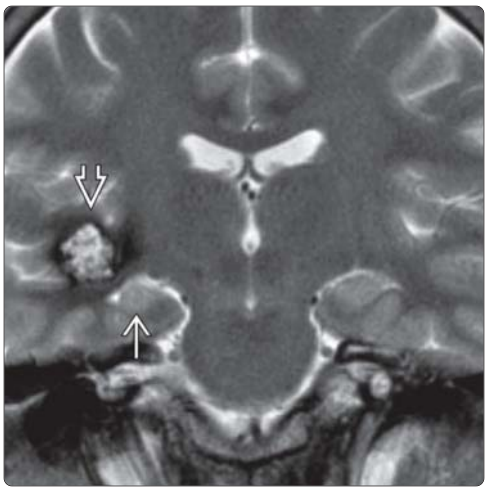

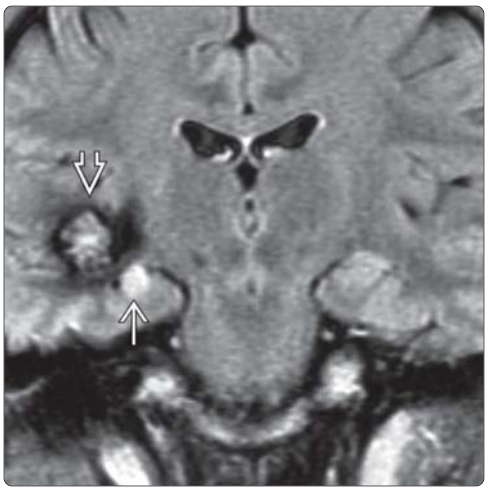

(Left) *Coronal T2WI MR in a chronic seizure patient with large right temporal lobe cavernous malformation demonstrates all 3 primary determinants of right hippocampal sclerosis (volume loss, T2 hyperintensity, and loss of internal architecture).* **(Right)** *Coronal FLAIR MR in the same patient with right temporal lobe cavernous malformation better shows hippocampal sclerosis. Hyperintensity is usually more conspicuous on FLAIR, while T2 is better for depicting internal structure.*

https://CafePezeshki.IR

KEY FACTS

TERMINOLOGY

- Status epilepticus: > 30 minutes of continuous seizures or ≥ 2 seizures without full recovery of consciousness between seizures
- Synonyms: Transient seizure-related MR changes, reversible postictal cerebral edema

IMAGING

- Best diagnostic clue: T2 hyperintensity in gray matter &/or subcortical white matter (WM) with mild mass effect
  - Supratentorial, related to epileptogenic focus
  - Typically cortex &/or subcortical WM
  - May involve hippocampus, corpus callosum, thalamus (particularly pulvinar nucleus)
- Swelling and increased volume of involved cortex
- DWI: Restricted diffusion acutely
- T1WI C+: Variable enhancement, none to marked
- PWI: Marked hyperemia, ↑ rCBF and rCBV

TOP DIFFERENTIAL DIAGNOSES

- Cerebritis
- Cerebral ischemia-infarction
- Herpes encephalitis
- Astrocytoma

CLINICAL ISSUES

- Active seizures &/or status epilepticus
- Other signs/symptoms: Location dependent

DIAGNOSTIC CHECKLIST

- Acute seizures or status epilepticus may mimic other pathology, such as tumor progression or cerebritis
- Clinical information and follow-up imaging often differentiates from other etiologies
- Look for underlying mass that may have caused seizures/status epilepticus
- Seizure-related changes usually resolve within days to weeks

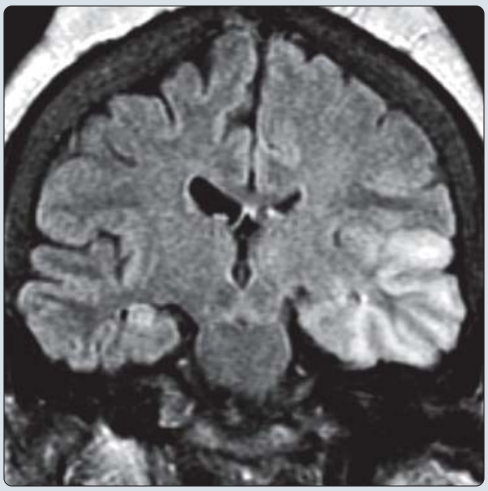

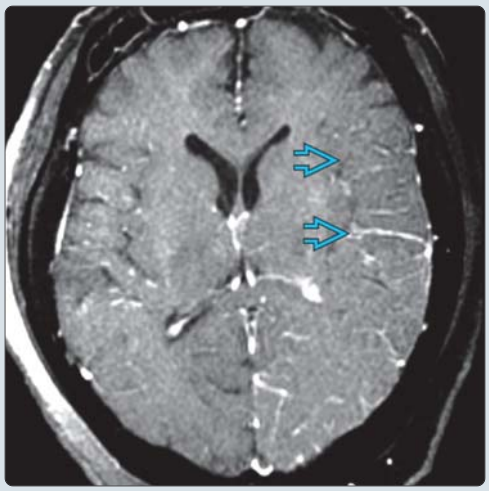

(Left) *Coronal FLAIR MR performed shortly after a long episode of status epilepticus shows increased signal involving the left temporal lobe cortex and associated subcortical white matter.* **(Right)** *Axial T1WI C+ FS MR in the same patient shows mild edema and vascular congestion in the left temporal lobe. Imaging 1 month later showed near complete resolution of the signal abnormalities. Status epilepticus may result in MR changes that are likely related to transient cerebral edema.*

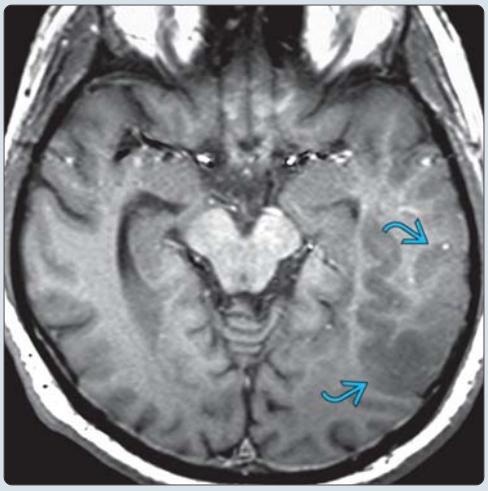

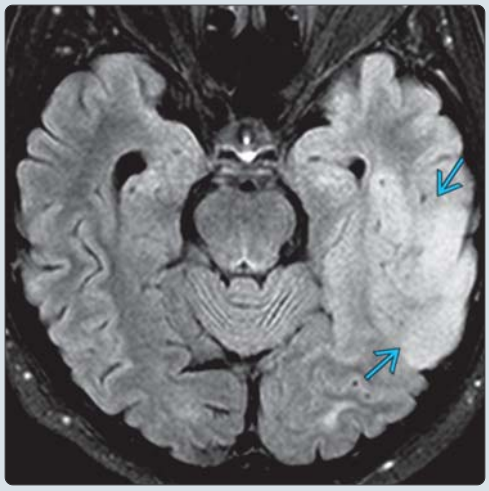

(Left) *Axial T1WI MR in a patient with status epilepticus shows mild thickening of the left temporal cortex.* **(Right)** *Axial FLAIR MR in the same patient shows cortical and subcortical white matter edema. MR signal abnormalities are related to transient vasogenic &/or cytotoxic edema. Follow-up imaging in such cases usually shows resolution of the acute imaging abnormalities in treated patients. Atrophy may be seen chronically.*

https://CafePezeshki.IR

TERMINOLOGY

Abbreviations

- Status epilepticus (SE)

Synonyms

- Transient seizure-related MR changes, reversible postictal cerebral edema

Definitions

- Status epilepticus: > 30 minutes of continuous seizures or ≥ 2 seizures without full recovery of consciousness between seizures
- MR changes associated with seizures likely related to transient cerebral edema

IMAGING

General Features

- Best diagnostic clue
  - T2 hyperintensity in gray matter (GM) &/or subcortical white matter (WM) with mild mass effect
  - May focally involve hippocampus, corpus callosum, thalamus (particularly pulvinar nucleus)
- Location
  - Supratentorial, related to epileptogenic focus
    - Typically cortex &/or subcortical WM
  - May involve focal structures
    - Hippocampus (febrile or partial complex seizures)
    - Splenium of corpus callosum
    - Pulvinar of thalamus
  - Occasionally cerebellar involvement

CT Findings

- NECT
  - Hypodensity in cortex &/or subcortical WM
  - Blurring of corticomedullary junction
  - Hippocampus, splenium of corpus callosum, thalamus (particularly pulvinar nucleus) may be involved
  - No hemorrhage
- CECT
  - Variable enhancement: None to marked

MR Findings

- T1WI
  - Hypointensity in cortex &/or subcortical WM
    - Swelling and increased volume of involved cortical gyri
  - Blurring of corticomedullary junction
  - Mild mass effect
  - Hippocampus, splenium of corpus callosum, thalamus (particularly pulvinar nucleus) may be involved
  - Rarely cerebellar involvement due to crossed cerebellar diaschisis
- T2WI
  - Hyperintensity in cortex &/or subcortical WM
    - Swelling and increased volume of involved cortical gyri
  - Mild edema and mass effect
  - Hippocampus, corpus callosum splenium, thalamus (particularly pulvinar nucleus) may be involved
  - No hemorrhage
- FLAIR
  - Hyperintensity in cortex &/or subcortical WM
  - Mild edema and mass effect
  - Hippocampus, splenium of corpus callosum, pulvinar may be involved
- DWI
  - Restricted diffusion with decrease in ADC map acutely
  - ADC maps normal interictally, elevated in chronic seizures
- T1WI C+
  - Variable enhancement: None to marked
  - May see gyriform or leptomeningeal enhancement
- MRS
  - Lipids &/or lactate shown in hippocampi of temporal lobe epilepsy (TLE) patients within 24 hours of last seizure
  - Follow-up MRS after seizures under control show no lipids/lactate
- Perfusion imaging (PWI): Marked hyperemia on side of epileptic focus, elevated rCBF and rCBV maps

Nuclear Medicine Findings

- Seizures: Increased metabolism and perfusion
- PET: Increased glucose metabolism and metabolic rate
- HMPAO SPECT: High uptake in affected cerebral lobe during or immediately after seizure

Imaging Recommendations

- Best imaging tool
  - MR is most sensitive
- Protocol advice
  - Contrast-enhanced MR with DWI
  - MRS may be helpful in TLE patients

DIFFERENTIAL DIAGNOSIS

Cerebritis

- T2 hyperintense "mass" with mass effect
- Typically DWI positive
- Patchy enhancement typical

Cerebral Ischemia-Infarction

- Typical vascular distribution (ACA, MCA, PCA)
- Acute/subacute DWI positive
- Wedge-shaped, involves GM and WM
- Gyriform enhancement in subacute ischemia

Herpes Encephalitis

- Confined to limbic system, temporal lobes
- Blood products, enhancement typical
- Acute onset, often with fever
- May present with seizures

Astrocytoma

- Infiltrating WM mass
- May extend to involve cortex
- Variable enhancement in anaplastic (grade III)
- May cause epilepsy

MELAS

- Mitochondrial encephalopathy, lactic acidosis, and stroke-like episodes
- Multifocal bilateral T2 hyperintensities
- Predominantly GM involvement, may involve subcortical WM

https://CafePezeshki.IR

- Ischemia in > 1 vascular territory
- MRS shows lactate peak

Mesial Temporal Sclerosis

- Abnormal T2 hyperintensity in mesial temporal lobe
- Hippocampal volume loss and architectural distortion

Vasculitis

- Multiple small areas of T2 hyperintensity in deep and subcortical WM, often bilateral, ± enhancement
- GM involvement may be seen

Demyelination

- Multifocal WM lesions, deep gray nuclei
- Incomplete rim or horseshoe-shaped enhancement
- Lesions often in typical locations

PATHOLOGY

General Features

- Etiology
  - SE evolves through initiation phase to maintenance phase
    - Initiation phase: Triggering stimuli evoke discrete seizures, tend to abate as soon as stimulus is removed
    - Maintenance phase: Discrete seizures coalesce, triggering stimuli no longer required to sustain seizures
    - Intensity and duration of stimulation has direct influence on transition from initiation to maintenance phase
    - Signaling molecules: GABA-A (γ-aminobutyric acid) antagonists, glutamate agonists, cholinergic agonists found to be involved in initiation phase
    - Molecules that block maintenance phase: NMDA (N-methyl-D aspartate) antagonists, substance P antagonist
  - MR signal abnormalities related to transient vasogenic &/or cytotoxic edema
    - Redistribution of intracellular and extracellular water, related to alteration in cell membrane permeability or cytotoxic edema
  - Hippocampus involvement by SE may result in mesial temporal sclerosis
  - Involvement of corpus callosum splenium, 2 theories
    - Transient focal edema related to transhemispheric connection of seizure activity
    - Reversible demyelination related to antiepileptic drugs
- Anatomic considerations
  - Portions of brain most vulnerable to damage from SE
    - CA1, CA3 of hippocampus, amygdala, piriform cortex, cerebellar cortex, thalamus, cerebral cortex

Staging, Grading, & Classification

- SE classified broadly as convulsive and nonconvulsive
  - Convulsive SE further classified
    - Tonic–clonic
    - Tonic
    - Clonic
    - Myoclonic
  - Nonconvulsive SE

Gross Pathologic & Surgical Features

- Acutely
  - Swelling of cortex &/or subcortical WM or hippocampus
- Chronic
  - Atrophy of involved cortex &/or subcortical WM

Microscopic Features

- Acutely
  - Reactive astrocytes with swollen cytoplasm and neuropil, consistent with cytotoxic edema
- Chronic
  - Marked neuronal loss with intense astrocytic reaction; reactive astrocytes replacing absent neurons
- Gliosis and neuronal loss affecting GM-WM matter junction with extension to cortex

CLINICAL ISSUES

Presentation

- Most common signs/symptoms
  - Active seizures &/or status epilepticus
  - Other signs/symptoms: Location dependent
  - Nonconvulsive SE: Abnormal mental status, unresponsiveness, ocular motor abnormalities
- Clinical profile
  - EEG shows seizure activity

Demographics

- Age
  - Occurs at all ages, commonly young adults
- Gender
  - No gender predominance

Natural History & Prognosis

- Typically complete resolution with treatment of seizures
- May be complicated by infarction related to hypoxemia

Treatment

- Treatment of underlying seizure disorder
  - Antiepileptic medicines primary therapy
- Surgical resection in patients with intractable epilepsy

DIAGNOSTIC CHECKLIST

Consider

- Acute seizures or SE may mimic other pathology, such as tumor progression or cerebritis
- Clinical information and follow-up imaging often differentiates seizure-related MR changes from other etiologies

Image Interpretation Pearls

- Look for underlying mass that may have caused seizures/SE
- Seizure-related changes will usually resolve within days to weeks on follow-up imaging

SELECTED REFERENCES

1. Betjemann JP et al: Status epilepticus in adults. Lancet Neurol. ePub, 2015
2. Cartagena AM et al: Reversible and irreversible cranial MRI findings associated with status epilepticus. Epilepsy Behav. 33:24-30, 2014
3. Ohe Y et al: MRI abnormality of the pulvinar in patients with status epilepticus. J Neuroradiol. 41(4):220-6, 2014

https://CafePezeshki.IR

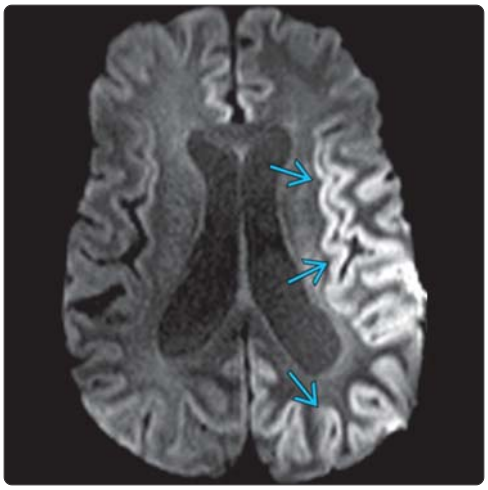

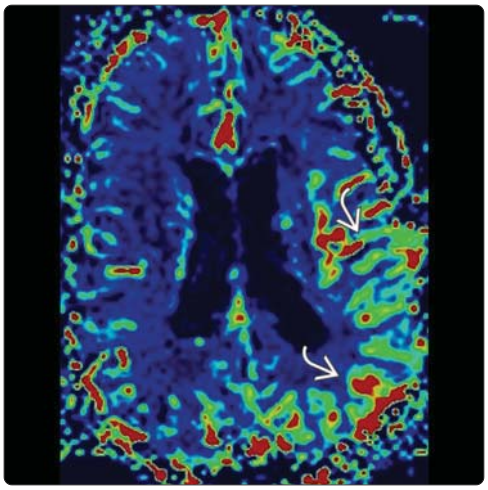

(Left) *Axial DWI MR shows cortical restricted diffusion in a patient with status epilepticus. Transient diffusion changes related to seizures can involve the cortex/subcortical white matter, corpus callosum, hippocampus, and pulvinar nucleus of thalamus.* **(Right)** *Axial rCBV map in the same patient shows increased CBV in the same region as the diffusion abnormality. Cerebral hyperperfusion may occur after seizures, particularly with status epilepticus.*

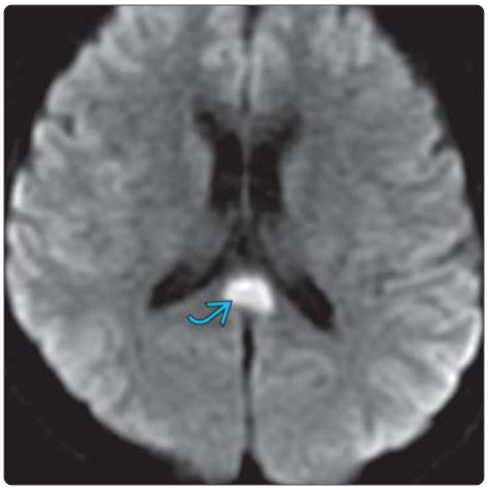

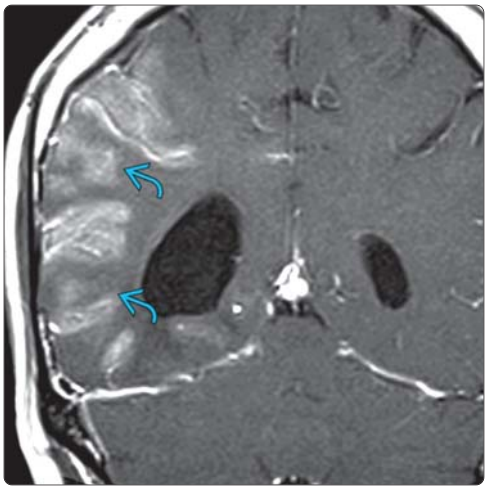

(Left) *Axial DWI MR shows restricted diffusion in the splenium of the corpus callosum. Follow-up MR showed complete resolution. A transient splenial lesion can be seen with seizures, antiepileptic medications, PRES, viral infections, and hypoglycemia.* **(Right)** *Coronal T1 C+ MR shows gyriform and meningeal enhancement related to status epilepticus. After treatment, the MR changes completely resolved. This enhancement pattern is often seen in subacute stroke and encephalitis.*

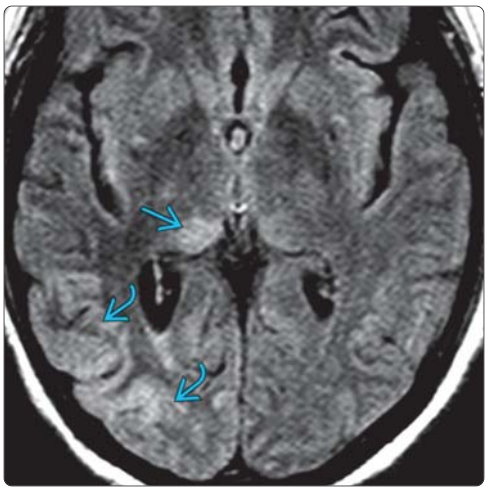

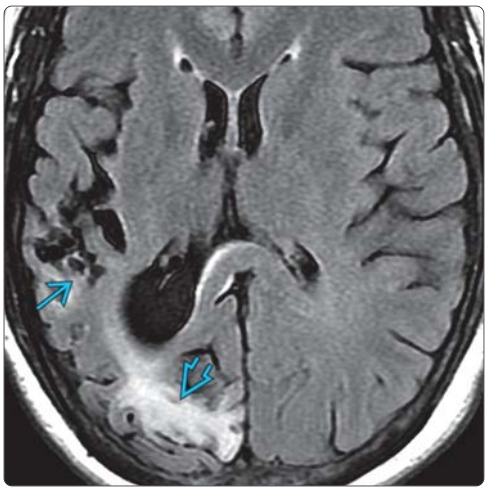

(Left) *Axial FLAIR MR in a patient with status epilepticus shows right temporal and parietal cortex/subcortical hyperintensity. Note high signal in the pulvinar nucleus of right thalamus.* **(Right)** *Axial FLAIR MR in the same patient after 1 year shows cystic encephalomalacia, gliosis, and volume loss in the same regions. Although in most cases imaging findings of status epilepticus are reversible, persistent imaging abnormalities such as focal atrophy due to permanent neuronal damage can occur as in this case.*

https://CafePezeshki.IR

KEY FACTS

TERMINOLOGY

- Sudden memory loss without other signs of cognitive or neurologic impairment that recovers completely within 24 hours

IMAGING

- NECT, CECT almost invariably normal
- MR
  - T2/FLAIR usually normal
  - DWI: Focal dot-like area of diffusion restriction in hippocampus
    - Single (55%)
    - Multiple (45%)
    - Unilateral (50-55%)
    - Bilateral (45-50%)
  - DWI abnormalities increase with time
    - From 35% at 0-6 hours to 65-70% by 12-24 hours
    - Complete resolution by day 10
- PWI, PET/CT may show hippocampal hypoperfusion/hypometabolism

TOP DIFFERENTIAL DIAGNOSES

- Cerebral ischemia-infarction
- Seizure/postictal state
- Hypoglycemia

PATHOLOGY

- Underlying pathophysiology still unknown
- Functional, reversible modification of hippocampus

CLINICAL ISSUES

- Most common in middle aged, elderly (rare < 40 years)
- Abrupt onset of massive episodic memory impairment
  - Both anterograde and retrograde
  - Often accompanied by repetitive questioning
  - Other neurologic functions intact
- Self-limited (spontaneous resolution within 24 hours)

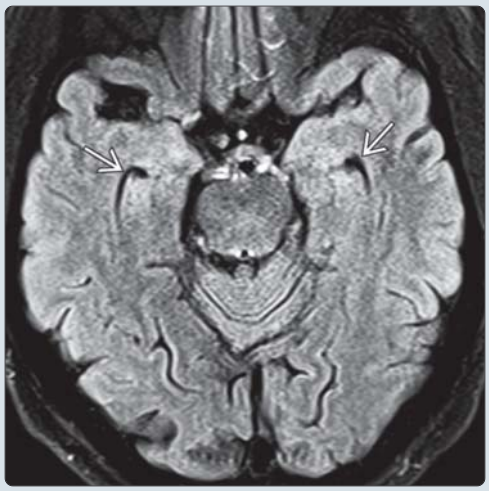

(Left) *Axial T2WI in a 54-year-old male with sudden onset of amnesia is normal.* **(Right)** *Axial FLAIR MR shows no abnormalities. Both temporal horns ⇨ are well visualized and are normal. The hippocampi, just medial to the CSF-filled temporal horns, also appear completely normal.*

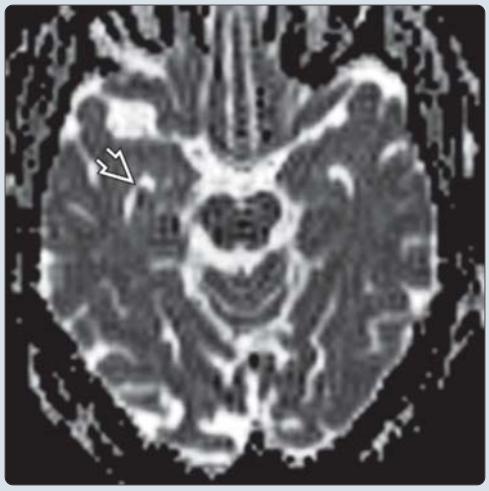

(Left) *Axial DTI trace image in the same patient shows a dot-like focus of restricted diffusion in the right hippocampus ⇨, just inside the temporal horn of the lateral ventricle.* **(Right)** *The hyperintense focus seen on the DTI trace image is dark on ADC (hypointense to the adjacent parenchyma) ⇨, confirming the reduced diffusivity. The patient's memory recovered within a few days. This is a classic case of transient global amnesia with the classic findings on DWI.*

https://CafePezeshki.IR

TERMINOLOGY

Abbreviations

- Transient global amnesia (TGA)

Definitions

- Sudden memory loss without other signs of cognitive or neurologic impairment that recovers completely within 24 hours
  - Both antero- and retrograde amnesia

IMAGING

General Features

- Best diagnostic clue
  - Focal dot-like area of diffusion restriction in hippocampus
- Location
  - Hippocampus
    - Body most common site, followed by head
  - Number
    - Single (55%)
    - Multiple (45%)
    - Unilateral (50-55%)
    - Bilateral (45-50%)
- Size
  - Between 1-2 mm
- Morphology
  - Rounded dot-like foci

CT Findings

- NECT, CECT almost invariably normal

MR Findings

- T1WI
  - Normal
- T2WI
  - T2/FLAIR usually normal
  - Small hyperintense foci occasionally identified but are typically reversible
- DWI
  - Tiny "dot" of restricted diffusion in hippocampus (just inside temporal horn) in 80%
    - Abnormalities increase with time
      - 0-6 hours: 35%
      - 6-12 hours: 60%
      - 12-14 hours: 65-70%
      - 3 days: 75%
      - 10 days: Complete resolution
- DSC perfusion-weighted imaging (PWI)
  - Negative to visual inspection
  - Hypoperfusion
    - Lower rCBF, rCBV in both hippocampus, thalamus compared to normal
    - Inconsistently present, reversible

Nuclear Medicine Findings

- May show hippocampal hypoperfusion, hypometabolism on PET/CT

Imaging Recommendations

- Best imaging tool
  - MR with DWI

DIFFERENTIAL DIAGNOSIS

Cerebral Ischemia-Infarction

- TIA or stroke
- Not in clear arterial territory

Seizure/Postictal State

- Shorter in duration than TGA
- Recur more frequently
- No epileptiform abnormalities during/after TGA

Hypoglycemia

- Cortex, usually parietooccipital

PATHOLOGY

General Features

- Etiology
  - Underlying pathophysiology still unknown
    - Possible etiologies
      - Spreading depression in hippocampus (similar to cortical spreading depression in migraine with aura)
      - Ischemic stroke
      - Venous congestion/hypertension
    - Functional, reversible modification of hippocampus
      - Specifically the CA1 area
      - Vascular vs. neurochemical

CLINICAL ISSUES

Presentation

- Most common signs/symptoms
  - Abrupt onset of massive episodic memory impairment
    - Both anterograde and retrograde
    - Often accompanied by repetitive questioning
  - Other neurologic functions intact

Demographics

- Age
  - Middle aged, elderly
    - Rare < 40 years
- Epidemiology
  - 23.5/100,000 per year in population > 50 years

Natural History & Prognosis

- Self-limited, with spontaneous resolution within 24 hours of onset
  - Rarely recur (5-10%/year)

SELECTED REFERENCES

1. Arena JE et al: Transient global amnesia. Mayo Clin Proc. 90(2):264-72, 2015
2. Förster A et al: Value of dynamic susceptibility contrast perfusion MRI in the acute phase of transient global amnesia. PLoS One. 10(3):e0122537, 2015
3. Quinette P et al: Hippocampal modifications in transient global amnesia. Rev Neurol (Paris). ePub, 2015

https://CafePezeshki.IR

KEY FACTS

TERMINOLOGY

- ↓ overall brain volume with advancing age
  - Reflected in relative ↑ CSF spaces

IMAGING

- Broad spectrum of "normal" on imaging in elderly
- "Successfully aging brain"
  - Smooth, thin, periventricular, high signal rim on FLAIR is normal
  - White matter hyperintensities (WMHs) absent/few
- Decreased total brain volume
  - Selective atrophy of white matter (not gray matter) predominates
- WMHs ↑ in number/size after 50 years
  - Approximately universal after 65 years
- GRE/SWI
  - Increasing mineralization of basal ganglia with age
  - Microbleeds are not characteristic of successful aging brain
- Age-related shift from anterior to posterior cortical metabolism

TOP DIFFERENTIAL DIAGNOSES

- Mild cognitive impairment
- Alzheimer disease
- Sporadic subcortical arteriosclerotic encephalopathy
- Vascular dementia
- Frontotemporal lobar degeneration (Pick disease)

CLINICAL ISSUES

- WMHs correlate with age, silent stroke, hypertension, female sex

DIAGNOSTIC CHECKLIST

- Cannot predict cognitive function from CT/MR
  - Imaging only roughly correlates with cognitive function
  - Significant overlap with dementias

(Left) *Axial graphic depicts a normally aging brain in an 80-year-old patient. Note the widening of sulci and ventricles in the absence of any brain parenchymal abnormalities.* **(Right)** *Axial NECT demonstrates mild sulcal enlargement and mild ventriculomegaly in a 70-year-old patient. The white matter appears completely normal, without periventricular hypodensities or white matter lacunar infarcts.*

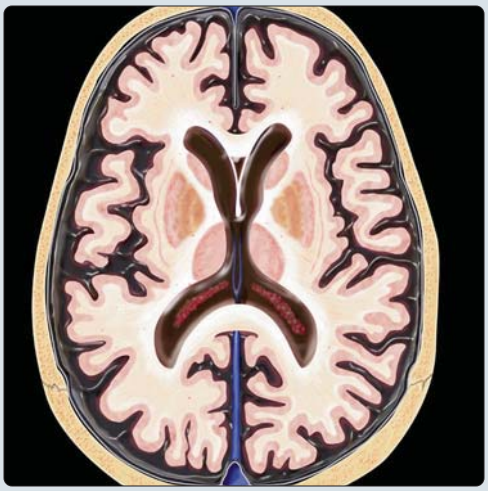

(Left) *Axial SWI in a 67-year-old woman shows striking hypointensity in the globi pallidi ⇨ with less prominent hypointensity in the putamina ⇨ due to iron deposition.* **(Right)** *Axial FLAIR MR in a 79-year-old man shows enlargement of ventricles and sulci due to age-related volume loss. Smooth, thin, periventricular hyperintense rim ⇨ and subtle hyperintensity in the splenium ⇨ of corpus callosum is common and normal.*

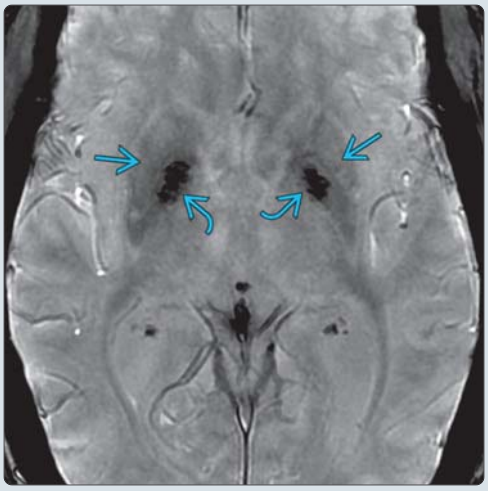

https://CafePezeshki.IR

TERMINOLOGY

Definitions

- ↓ overall brain volume with advancing age
  - Reflected in relative ↑ CSF spaces

IMAGING

General Features

- Best diagnostic clue
  - "Successfully aging brain"
    - Thin, periventricular, high signal rim
    - Absent/few white matter hyperintensities (WMHs)
    - Mild shrinkage of selected cerebellar regions
- Location
  - Selective atrophy of white matter (WM) predominates, not gray matter (GM)
  - Striatum (primarily caudate nucleus, putamen)
- Size
  - Decreased total brain volume
  - Absolute striatal size
    - Caudate decreases linearly with age
    - Putamen remains relatively stable
- Morphology
  - Brain tissue ↓, CSF volume ↑
    - Reflects overall WM volume loss > focal WMHs
    - Rounded appearance of dilated ventricles, sulci ↑

CT Findings

- NECT
  - Enlarged ventricles, widened cortical sulci
  - Patchy periventricular low densities
  - ± symmetrical, punctate calcifications in globi pallidi (GP)
  - ± curvilinear vascular Ca++

MR Findings

- T1WI
  - Mild but symmetric ventricular enlargement, proportionate prominence of subarachnoid spaces
  - Mild but significant age-related shrinkage of
    - Posterior vermis (lobules 6, 7, and 8-10)
    - Cerebellar hemispheres
  - Dilated perivascular Virchow-Robin spaces
    - Isointense to CSF on all sequences
    - Conform to course of penetrating arteries
    - Round/oval/curvilinear
    - Smooth, well-defined margins
    - Bilateral, often symmetrical; usually no mass effect
    - Increase in number, size (> 2 mm) with age
    - Can be found in most all areas
      - Tend to cluster around anterior commissure
      - Inferior 1/3 of putamen, external capsule
- T2WI
  - Focal/confluent periventricular WMHs
    - Number/size ↑ after 50 years; ~ universal after 65 years
    - Only rough correlation with cognitive function
    - Significant overlap with dementias
  - Infarct-like T2-hyperintense lesions
    - Seen in 1/3 of asymptomatic patients > 65 years
    - Mostly in basal ganglia (BG), thalami
    - Probably represent clinically silent lacunar infarcts
  - T2 shortening
    - "Black line" in visual, motor/sensory cortex
      - Common, normal in older patients
    - Ferric iron deposition
      - Normal in GP, abnormal in thalamus
    - With aging, hypointensity in caudate/putamen ↑
      - Putamen hypointensity may equal GP in 8th decade
- FLAIR
  - Smooth, thin, periventricular hyperintense rim normal
  - BG and thalamic foci
    - Perivascular spaces suppress
    - Lacunar infarcts hyperintense
- T2* GRE
  - SWI: Increasing mineralization of BG with age
    - Can see linear "waves" or conglomerate mineralization in GP
    - Putaminal hypointensity less prominent until 8th decade
  - Microbleeds are common in aging brain
    - SWI demonstrates microbleeds in 20% of patients > 60 of age years and in 1/3 of patients > 80 years old
    - Microbleeds are not characteristic of successful aging brain
    - Basal ganglia, brainstem and cerebellar microbleeds indicative of chronic hypertensive encephalopathy
    - Lobar and cortical microbleeds typical of amyloid angiopathy
- DWI
  - Small but significant increased water diffusibility
    - ADC increases
  - DTI: Loss of fractional anisotropy in "normal-appearing" WM
- T1WI C+
  - Age-related WMHs do not enhance
  - If enhancing, consider acute lacunar infarct or metastases
- MRS
  - Metabolite distribution varies among different brain regions
    - Choline (Cho) content ↑ with aging
    - Creatine (Cr) ↑ with aging
    - N-acetyl aspartate (NAA) ↓ in cortex, centrum semiovale, temporal lobes

Nuclear Medicine Findings

- PET
  - Metabolic alterations common
    - Global, regional changes in CBF
  - Gradual ↓ in regional cerebral blood flow (CBF) of GM, WM
    - Particularly in frontal lobes
  - Age-related shift from anterior to posterior cortical metabolism
  - Relative glucose metabolic rate (rGMR) measured by FDG PET
    - With age, rGMR ↑ in putamen and ↓ in caudate
  - ↓ pre-/postsynaptic dopamine markers in BG
- Tc-99m HMPAO SPECT, Xe-133 inhalation show regional, global reduction in CBF

https://CafePezeshki.IR

Imaging Recommendations

- Best imaging tool
  - MR with FLAIR, DWI, T2* GRE/SWI

DIFFERENTIAL DIAGNOSIS

Mild Cognitive Impairment

- Overlap with normal on standard imaging studies
- ↓ NAA

Alzheimer Disease

- Parietal and temporal cortical atrophy
- Striking volume loss in hippocampi, entorhinal cortex
- ↓ NAA, ↑ myoinositol (mI)

Sporadic Subcortical Arteriosclerotic Encephalopathy

- Numerous WMHs (overlap with normal)
- Multiple lacunar infarcts

Vascular Dementia

- Hyperintense lesions on T2WI and focal atrophy suggestive of chronic infarcts

Frontotemporal Lobar Degeneration

- Asymmetric frontal, anterior temporal atrophy

PATHOLOGY

General Features

- Etiology
  - Previous conception of aging: Substantial cortical neuronal loss with age
  - New: Predominant neuroanatomic changes
    - WM alterations, subcortical neuronal loss
    - Reduction in cell size > cell number
  - Neuronal dysfunction rather than loss of neurons/synapses
    - ↓ neuronal viability or function associated with accelerated membrane degradation &/or ↑ glial cell numbers
    - Loss of synapses and dendritic pruning in selected areas rather than globally
  - Some investigators consider accumulation of neurofibrillary tangles (NFTs) may be responsible for memory loss associated with aging
- Genetics
  - Clearly affect aging of brain
  - Apolipoprotein E (ApoE) and 6 novel risk-associated single nucleotide polymorphisms (SNPs) on chromosome 17q25 associated with brain pathology in aging

Gross Pathologic & Surgical Features

- Widened sulci, proportionate large ventricles
- Minor thinning of cortical mantle, predominant changes in subcortical WM

Microscopic Features

- Degeneration of neurons and oligodendrocytes
- Decreased myelinated fibers in subcortical WM
- Increased extracellular space, gliosis
- Iron deposition in globus pallidus, putamen
- WM capillaries lose pericytes, have thinner endothelium
- Dilated perivascular spaces of Virchow-Robin
  - Extension of subarachnoid space that accompanies penetrating vessels into brain to level of capillaries
- Senile plaques
  - Extracellular amyloid deposits in cerebral gray matter
- Lewy bodies
  - Intraneuronal clumps of α-synuclein and ubiquitin proteins
  - Found in 5-10% of cognitively intact individuals
- Neurofibrillary tangles (NFTs)
  - Tau phosphorylation, mitochondrial dysfunction may precede full NFT formation
  - NFTs appear in small numbers in entorhinal and transentorhinal cortices early in aging (patients ~ 60 years old)
  - NFTs may induce neural dysfunction, destruction of synapses, and, eventually, neuronal death

CLINICAL ISSUES

Presentation

- Most common signs/symptoms
  - Normal cognitive function
  - Mild cognitive impairment correlates with ↑ risk of Alzheimer disease

Demographics

- Age
  - > 60 years old
- Gender
  - Differences in striatal size
    - Relatively constant across lifespan in men
    - Variable across lifespan in women: Smaller in women aged 50-70 years than in men
- Epidemiology
  - WMHs correlate with age, silent stroke, hypertension, female sex

Natural History & Prognosis

- Parenchymal volume ↓, CSF spaces ↑ progressively
- WMHs progressively ↑ with age

DIAGNOSTIC CHECKLIST

Consider

- Striatum may mediate age-associated cognitive decline
  - ↓ volume, functional activity with age

Image Interpretation Pearls

- Broad spectrum of "normal" on imaging in elderly
- Cannot predict cognitive function from CT/MR

SELECTED REFERENCES

1. Xekardaki A et al: Neuropathological changes in aging brain. Adv Exp Med Biol. 821:11-7, 2015
2. van Velsen EF et al: Brain cortical thickness in the general elderly population: the Rotterdam Scan Study. Neurosci Lett. 550:189-94, 2013
3. Poels MM et al: Arterial stiffness and cerebral small vessel disease: the Rotterdam Scan Study. Stroke. 43(10):2637-42, 2012
4. Ikram MA et al: The Rotterdam Scan Study: design and update up to 2012. Eur J Epidemiol. 26(10):811-24, 2011
5. Poels MM et al: Incidence of cerebral microbleeds in the general population: the Rotterdam Scan Study. Stroke. 42(3):656-61, 2011

https://CafePezeshki.IR

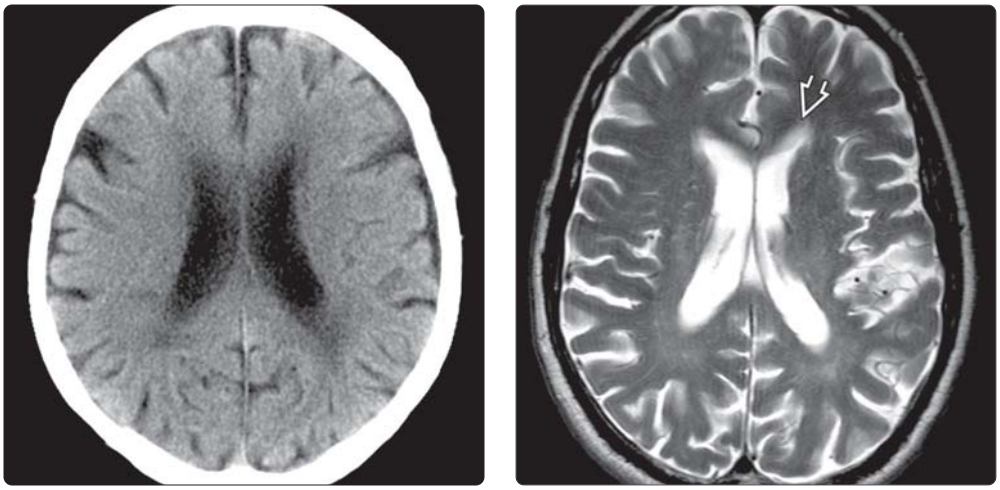

(Left) *Axial NECT in an 85-year-old patient without cognitive impairment shows wide sulci and lateral ventricles, as well as moderate periventricular hypodense white matter.* **(Right)** *Axial T2WI 3T MR in a 76-year-old patient shows mild periventricular hyperintensity ⇨, mild ventriculomegaly, and mild sulcal enlargement.*

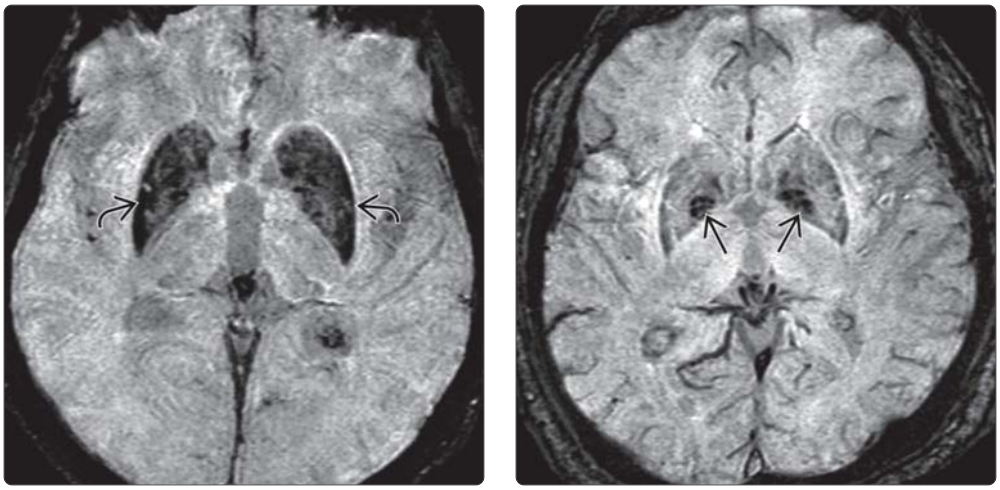

(Left) *Axial T2* SWI MR demonstrates marked hypointensity in the basal ganglia ⇨ related to normal mineralization with age.* **(Right)** *Axial T2* SWI MR demonstrates horizontal linear "waves" of mineralization in the globus pallidi ⇨, a normal finding in the aging brain.*

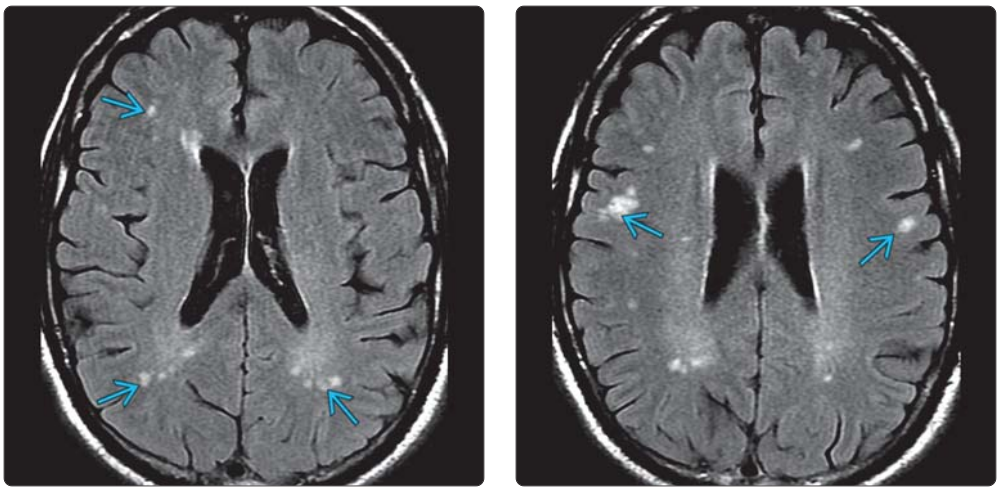

(Left) *Axial FLAIR in a 72-year-old man shows scattered white matter hyperintensities ⇨. Aging brains may demonstrate a few scattered nonconfluent white matter hyperintensities. Increased prevalence of white matter hyperintensities with cardiovascular risk factors such as diabetes and hyperlipidemia is shown.* **(Right)** *Axial FLAIR in the same patient shows additional subcortical white matter hyperintensities ⇨.*

https://CafePezeshki.IR

KEY FACTS

TERMINOLOGY

- Alzheimer disease (AD)
  - Slowly progressive neurodegenerative disease

IMAGING

- Current role of imaging in AD
  - Exclude other causes of dementia
  - Identify region-specific patterns of brain volume loss
  - Identify imaging markers of coexistent disease such as amyloid angiopathy
  - Identify early AD for possible innovative therapy
- Best imaging = volumetric MR, FDG-18 PET
- Thinned gyri, widened sulci, and enlarged ventricles
- Medial temporal lobe particularly hippocampus and entorhinal cortex disproportionately affected
- FDG-18 PET
  - Early stage AD: ↓ metabolism in parietotemporal association cortices, posterior cingulate, and precuneus regions
  - Moderate to severe AD: Additional frontal lobe involvement
- Amyloid PET imaging: High sensitivity in detecting amyloid plaques and vascular amyloid in vivo

TOP DIFFERENTIAL DIAGNOSES

- Frontotemporal lobar degeneration
- Dementia with Lewy bodies
- Normal pressure hydrocephalus
- Vascular dementia
- Normal aging

CLINICAL ISSUES

- Most common cause of dementia over age 65
- Age is biggest risk factor
  - 1-2% prevalence at age 65
  - Incidence doubles every 5 years after age of 60

DIAGNOSTIC CHECKLIST

- Look for reversible causes of dementia

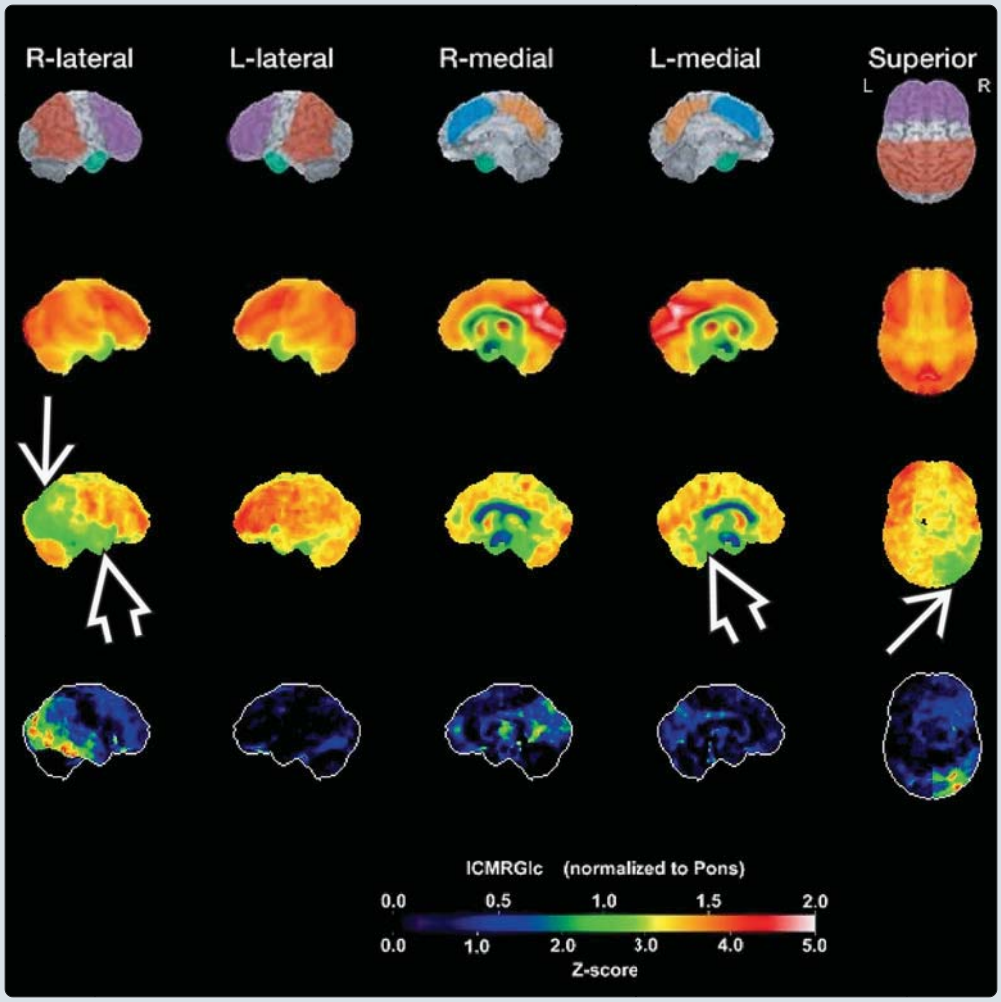

Sagittal FDG-18 PET with stereotaxic surface projections in a 70-year-old woman with possible Alzheimer disease (AD) is shown. Standard MR (not shown) disclosed no definite abnormalities. The top row shows a reference map. The 2nd row shows glucose metabolism in the normal elderly control group (n = 27). The 3rd row shows the patient's glucose metabolism map. Note the decrease in medial temporal ➡ and parietal lobes ➡ with sparing of the frontal, occipital lobes. The bottom row shows a Z-score map. (Courtesy N. Foster, MD.)

https://CafePezeshki.IR

TERMINOLOGY

Abbreviations

- Alzheimer disease (AD)

Synonyms

- Senile/presenile dementia of Alzheimer type

Definitions

- AD is progressive neurodegenerative condition characterized by progressive cognitive decline, memory impairment, and adverse impact on activities of daily living
- National Institute on Aging and Alzheimer's Association workgroup recommendations 2011
  - Phases of AD pathophysiological processes
    - Preclinical AD
    - Mild cognitive impairment (MCI) in AD
    - AD dementia

IMAGING

General Features

- Best diagnostic clue
  - MR: Temporal/parietal cortical atrophy
    - Disproportionate hippocampal volume loss
  - FDG PET: Regional ↓ glucose metabolism
    - Temporoparietal lobes, posterior cingulum
- Current role of imaging in AD
  - Exclude other structural abnormalities
  - Evaluate degree and location of atrophic changes
  - Evaluate metabolic abnormalities
    - When structural abnormalities absent/uncharacteristic (i.e., early in disease course)
  - Identify preclinical and MCI in AD for possible innovative therapy

CT Findings

- NECT
  - Screening to exclude potentially reversible or treatable causes of dementia
  - Medial temporal lobe atrophy earliest finding on CT
  - Late finding: Generalized cortical atrophy

MR Findings

- Current role of MR
  - Exclude other causes of dementia
  - Identify region-specific patterns of brain volume loss
  - Identify imaging markers of coexistent disease such as amyloid angiopathy
- T1WI (assess structure, atrophy patterns)
  - High resolution (MP-RAGE or SPGR) for volumetric analysis
  - Thinned gyri, widened sulci, and enlarged ventricles
  - Medial temporal lobe particularly hippocampus and entorhinal cortex disproportionately affected
    - May help distinguish patients with MCI from normal elderly
    - Average hippocampal volume reduction 20-25% in AD and 10-15% in MCI
- T2* GRE for microhemorrhages, amyloid angiopathy
- MRS
  - ↓ NAA and ↑ mI in AD even in early stage
  - NAA:mI ratio relatively sensitive and highly specific in differentiating AD from normal elderly
  - NAA:Cr ratio in posterior cingulate gyrus & left occipital cortex predicts conversion of MCI to probable AD
- DTI: ↓ FA in multiple regions especially superior longitudinal fasciculus and splenium
- Perfusion MR: ↓ rCBV in temporal, parietal regions

Nuclear Medicine Findings

- FDG-18 PET
  - Early stage AD
    - ↓ metabolism in parietotemporal association cortices, posterior cingulate, and precuneus regions
    - Most reliable early changes in posterior cingulate
  - Moderate to severe AD
    - Additional frontal lobe involvement
  - MCI in AD
    - Same pattern of ↓ metabolism as AD
  - Higher accuracy than MR for diagnosing early AD and predicting rapid conversion of MCI to early AD
- Amyloid PET imaging
  - High sensitivity in detecting amyloid plaques and vascular amyloid in vivo
  - 11C-Pittsburg compound-B (PiB): High affinity to amyloid β peptide (Aβ) aggregates
  - 18F-labeled amyloid tracers like 18F-AV-45 (florbetapir) becoming more widely used
  - Criteria for appropriate use of amyloid PET
    - Persistent or progressive unexplained MCI
    - Possible AD with unclear presentation
    - Progressive dementia and atypically early age of onset

Imaging Recommendations

- Best imaging tool
  - Volumetric MR
  - 18F-FDG PET
- Protocol advice
  - MP-RAGE or SPGR for volumetric measurement

DIFFERENTIAL DIAGNOSIS

Causes of Reversible Dementia

- Alcohol abuse (thiamine deficiency)
- Endocrinopathies (e.g., hypothyroidism)
- Vitamin B12 deficiency
- Depression ("pseudodementia")
- Normal pressure hydrocephalus
- Mass lesions (chronic subdural hematoma, tumor, etc.)

Frontotemporal Lobar Degeneration

- Frontal &/or anterior temporal atrophy

Vascular Dementia

- 2nd most common dementia (15-30%)
- Parenchymal hyperintensities, focal atrophy (infarcts)

Dementia With Lewy Bodies

- Hypometabolism of entire brain

Corticobasal Degeneration

- Prominent extrapyramidal, cortical symptoms
- Asymmetric severe frontoparietal atrophy

https://CafePezeshki.IR

Creutzfeldt-Jakob Disease

- Dementia with myoclonus, EEG abnormalities
- Hyperintensity in anterior basal ganglia, cortex

Cerebral Amyloid Angiopathy

- Often coexists with AD
- Microhemorrhages on T2* GRE/SWI

PATHOLOGY

General Features

- Etiology
  - Extracellular β-amyloid plaques
    - Located in cerebral cortex
  - Intracellular accumulation of neurofibrillary tangles (NTs)
    - Initially around hippocampus, later spread to other cortical areas
- Genetics
  - Most cases late onset sporadic AD
    - Deterministic genetic mutation not found
    - Apolipoprotein E (*ApoE*) ε4 allele is major genetic risk factor
  - Rare early-onset AD
    - Mutations in 1 of 3 genes
      - Amyloid precursor protein gene on chromosome 21
      - Presenilin-1 (*PSEN1*) gene on chromosome 14
      - Presenilin-2 (*PSEN2*) gene on chromosome 1

Gross Pathologic & Surgical Features

- Shrunken gyri, widened sulci

Microscopic Features

- 2 abnormal protein aggregates characterize AD pathologically
- Neurofibrillary tangles
  - Intracellular aggregates in neurons due to hyperphosphorylation of tau protein
  - Begins in entorhinal cortex, progresses to hippocampus, paralimbic system, and adjacent medial-basal temporal lobe
- Aβ deposition
  - Hallmark of Aβ peptide deposit in AD is neuritic plaque
  - Dense Aβ core with inflammatory cells and dystrophic neurites in its periphery
- Neurodegeneration: Synapse loss, neuron loss

CLINICAL ISSUES

Presentation

- Most common signs/symptoms
  - Slowly progressive neurodegenerative disease
  - Initially affects episodic memory
    - Then at least 1 other area of cognition
- Clinical profile
  - Clinical subtypes
    - Mild cognitive impairment: Early, mild memory impairment; no deficits in cognitive domains other than memory, not impairing daily function
    - Possible AD: Dementia features in presence of 2nd disease that could cause memory deficit but is not likely cause
    - Probable AD: Memory deficits on neuropsychological testing, progressive worsening of memory and ≥ 2 cognitive functions
    - Definite AD: Pathologic diagnosis
  - 5 major biomarkers for AD
    - Amyloid accumulation: CSF Aβ 42, PET amyloid plaque imaging
    - Neurogeneration or neuronal injury: CSF tau (total and phosphorylated), structural MR, FDG PET

Demographics

- Age
  - Biggest risk factor
    - 1-2% prevalence at age 65
    - Incidence doubles every 5 years after age of 60
- Gender
  - Women more commonly affected
- Epidemiology
  - AD most common neurodegenerative dementia
  - Currently ~ 5.3 million in US
  - 1/8, or 13% of individuals, in US > 65 years and > 50 % of individuals older than 85

Natural History & Prognosis

- Chronic, progressive
- Patients live average 8-10 years after diagnosis

Treatment

- No established treatments to prevent or reverse AD
- May transiently improve cognitive function
  - Cholinesterase inhibitors, NMDA receptor antagonists
- Many current disease-modifying drugs focus on reducing Aβ

DIAGNOSTIC CHECKLIST

Consider

- Look for
  - Reversible causes of dementia
  - Ventricular enlargement, sulcal widening proportionate
  - ↑ temporal horns of lateral ventricle
  - Hippocampal, entorhinal cortex volume loss

Image Interpretation Pearls

- MR volumetric analysis helps distinguish MCI in AD from normal elderly subjects
  - Measure change hippocampus/parahippocampal gyri over time
- FDG-18 PET
  - Helps distinguish AD from frontotemporal dementia
  - May identify early AD when MR normal

SELECTED REFERENCES

1. Brown RK et al: Brain PET in suspected dementia: patterns of altered FDG metabolism. Radiographics. 34(3):684-701, 2014
2. Nasrallah IM et al: Multimodality imaging of Alzheimer disease and other neurodegenerative dementias. J Nucl Med. 55(12):2003-11, 2014
3. Ishii K: PET Approaches for Diagnosis of Dementia. AJNR Am J Neuroradiol. Epub ahead of print, 2013
4. Petrella JR: Neuroimaging and the search for a cure for Alzheimer disease. Radiology. 269(3):671-91, 2013
5. Jack CR Jr: Alzheimer disease: new concepts on its neurobiology and the clinical role imaging will play. Radiology. 263(2):344-61, 2012

https://CafePezeshki.IR

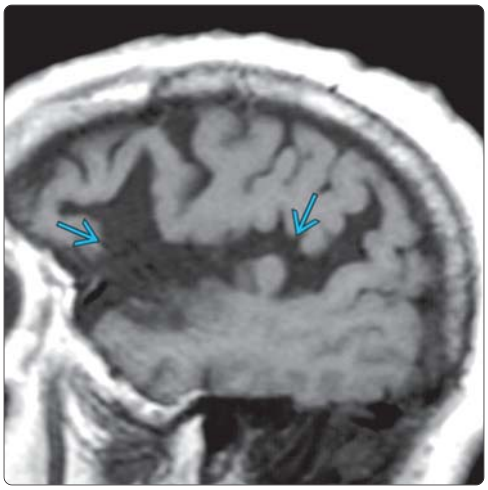

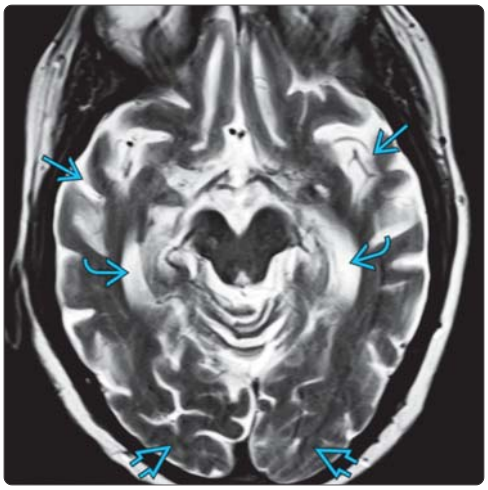

(Left) *Sagittal T1WI MR in a 72-year-old patient with suspected AD shows marked enlargement of the sylvian fissure compared to the other subarachnoid spaces. Cortical atrophy of structures around the sylvian fissures can be striking, as in this case.* **(Right)** *Axial T2 MR in a patient with AD demonstrates enlarged temporal horns disproportionate volume loss in the temporal lobes as compared to the normal appearing occipital lobes.*

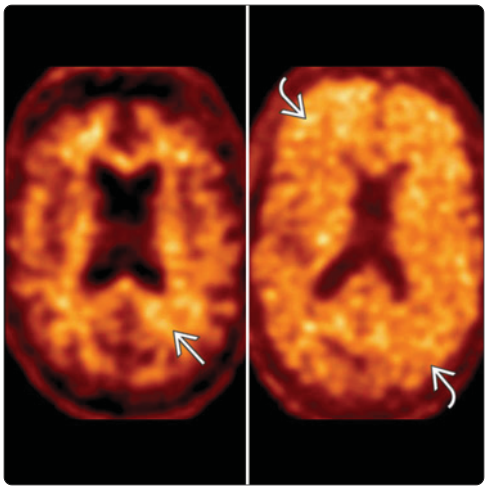

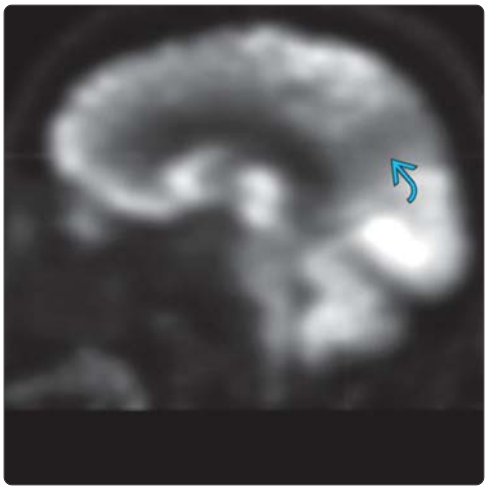

(Left) *18F-AV-45 (florbetapir) PET in a healthy control (left) demonstrates nonspecific white matter uptake and preserved gray-white matter differentiation. In a patient with AD (right), there is marked cerebral gray matter uptake due to Aβ deposition that makes gray-white matter differentiation difficult. (Courtesy C. Singh, MD, A. Ali, MD.)* **(Right)** *Sagittal PET in early AD shows a classic pattern of hypometabolism in the posterior cingulate gyrus and precuneus. (Courtesy S. Nayak, MD.)*

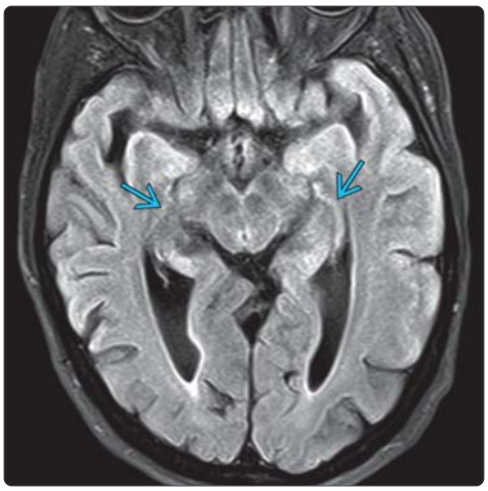

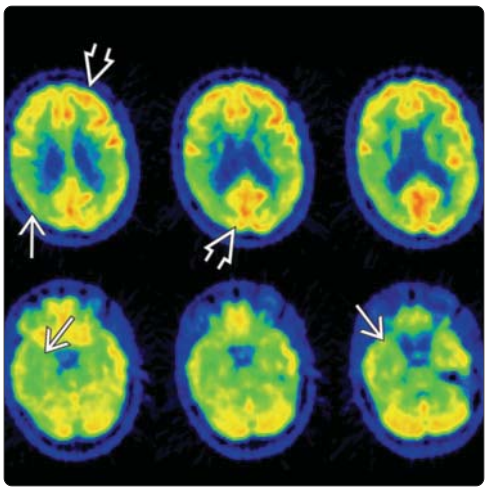

(Left) *Axial FLAIR scan in a 54-year-old woman with possible AD. While the sylvian fissures are slightly enlarged and the lateral ventricles are prominent for the patient's age, the hippocampi appear normal with no evidence for parenchymal ischemic lesions.* **(Right)** *Selected axial images from a FDG-18 PET study in the same patient show a subtle decrease in glucose metabolism in the temporal and parietal lobes compared to the frontal and occipital lobes.*

https://CafePezeshki.IR

KEY FACTS

TERMINOLOGY

- Vascular dementia (VaD), multi-infarct dementia (MID)
- Stepwise progressive ↓ in cognitive function
- Heterogeneous group of disorders with varying etiologies, pathologic subtypes
  - VaD often mixed etiology
  - Can occur alone or in association with AD
  - MID secondary to repeated cerebral infarctions

IMAGING

- General features
  - Multifocal infarcts (cortical GM, subcortical WM)
  - Basal ganglia (BG), pons
  - Territorial as well as lacunar lesions
  - Coexisting microvascular WM disease common
  - Multiple remote microhemorrhage
- CT
  - Multifocal infarcts
  - Single or multiple, lacunar to territorial
  - WM hypointensities (discrete to confluent)
- FDG PET
  - Multifocal regions ↓ metabolism in cortex, WM

TOP DIFFERENTIAL DIAGNOSES

- Alzheimer disease (AD)
- Frontotemporal lobar degeneration
- CADASIL
- Dementia with Lewy bodies

CLINICAL ISSUES

- 2nd most common dementia (after AD)
- Mood and behavioral changes more typical than memory loss

DIAGNOSTIC CHECKLIST

- Report strategically placed infarcts
- Look for hemorrhage, DWI abnormalities

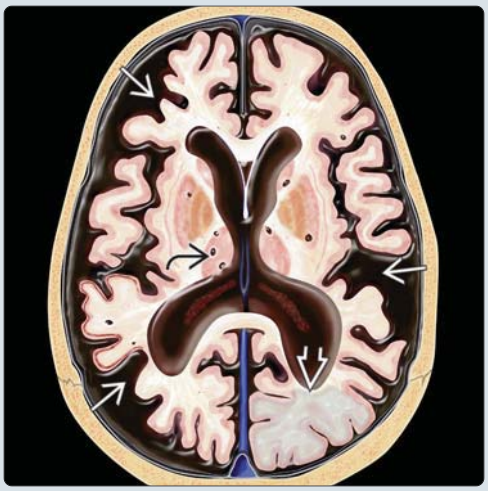

(Left) *Axial diagram of vascular dementia shows diffuse cerebral atrophy, focal volume loss due to multiple chronic infarcts, an acute left occipital lobe infarct, and small lacunar infarcts in the basal ganglia/thalami.* **(Right)** *Axial NECT demonstrates periventricular white matter hypodensity, as well as bilateral MCA and right PCA infarcts, in a patient with vascular dementia. The clinical history plus findings of infarcts in multiple separate vascular distributions is consistent with vascular dementia (VaD).*

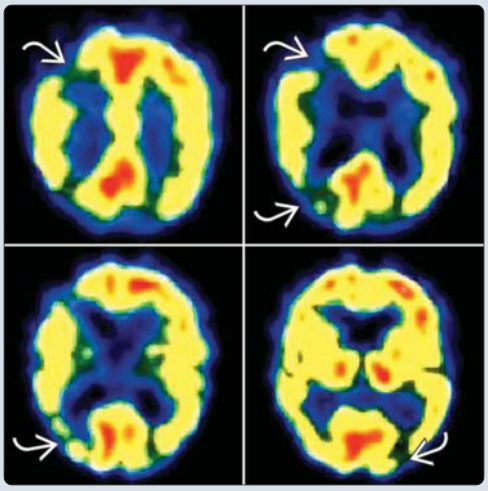

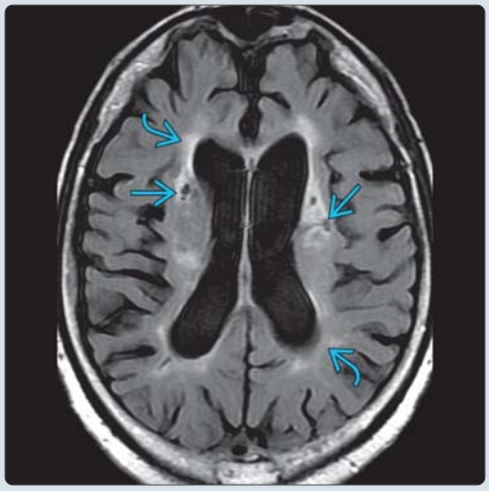

(Left) *Axial FDG PET in a patient with multi-infarct dementia demonstrates multiple wedge-shaped areas of hypometabolism due to chronic infarcts. (Courtesy A. Ali, MD.)* **(Right)** *Axial FLAIR MR in a 72-year-old man with chronic hypertension and diabetes presenting with mood and behavioral changes shows confluent white matter hyperintensities in the periventricular regions. Note the multiple chronic lacunar infarcts in the basal ganglia as well as enlargement of the ventricles and cortical sulci.*

https://CafePezeshki.IR

TERMINOLOGY

Abbreviations

- Vascular dementia (VaD)

Synonyms

- Multi-infarct dementia (MID)
- Vascular cognitive disorder (VCD)
- Vascular cognitive impairment (VCI)
- Subcortical ischemic vascular dementia
- Poststroke dementia

Definitions

- Stepwise progressive deterioration of cognitive function
  - VaD: Heterogeneous group of disorders with varying etiologies, pathologic subtypes
    - Often mixed etiology
  - Can occur alone or in association with Alzheimer disease (AD)
  - MID secondary to repeated cerebral infarctions

IMAGING

General Features

- Best diagnostic clue
  - Multifocal infarcts
    - Cortical gray matter (GM), subcortical white matter (WM)
    - Basal ganglia (BG), pons
    - Territorial as well as lacunar infarcts
    - Changes of microvascular WM ischemia common
- Location
  - Typically involve cerebral hemispheres and BG
  - Usually bilateral but may be unilateral
- Size
  - Vary from single to multiple, punctate to large/confluent
- Morphology
  - Small infarcts are rounded or oval; large confluent abnormalities are ill defined

CT Findings

- NECT
  - Hypodensity in periventricular WM
  - Cortical, subcortical, BG infarcts
  - Generalized atrophy with focal cortical infarcts typical

MR Findings

- T1WI
  - Generally have hypointense BG lacunar infarcts
  - Atrophy with enlargement of ventricles and sulci
- T2WI
  - Punctate or confluent regions of hyperintense WM
  - Central pontine infarcts
  - Large areas of volume loss with widened sulci
- FLAIR
  - Hyperintense foci within BG
  - Multifocal diffuse and confluent WM hyperintensities
- T2* GRE
  - Multiple "blooming" hypointensities in cortex and along pial surface
- DWI
  - ↓ FA and ↑ ADC within lesions, normal-appearing WM (NAWM) ↓
  - Increase in mean diffusivity of NAWM correlates with disability found on tests of executive function
- MRA
  - Most abnormalities in small arteries, generally not well seen on MRA
- MRS
  - ↓ NAA in both cortical and WM regions
  - Frontal cortex NAA negatively correlated with volume of WM signal hyperintensity

Ultrasonographic Findings

- Transcranial Doppler sonography: Pulsatility indices in large arteries are increased compared to AD

Nuclear Medicine Findings

- FDG PET
  - Multiple areas of hypometabolism without specific lobar predominance
  - Severity of MID neuropsychiatric symptoms correlates with extent of ↓ metabolism in cortex and WM
- SPECT
  - Iodine-123-iodoamphetamine: ↓ frontal and BG CBF, which correlates with low cognitive scores
  - Tc-99m hexamethyl propyleneamine oxime: CBF heterogeneity more prominent in anterior portion of brain
    - Unlike pattern in Alzheimer disease, in which posterior abnormalities predominate

Imaging Recommendations

- Best imaging tool
  - MR
  - PET/SPECT may also provide specificity
- Protocol advice
  - Axial FLAIR to detect white matter infarcts
  - Axial and coronal T2WI to assess regions of atrophy
  - T2* GRE/SWI to identify hemorrhage

DIFFERENTIAL DIAGNOSIS

Alzheimer Disease

- Striking hippocampus and amygdala atrophy
- PET: Bilateral temporoparietal hypoperfusion/hypometabolism (BG spared)
- Often coexists with VaD

Frontotemporal Lobar Degeneration

- Characterized by early onset of behavioral changes with intact visual, spatial skills
- Frontal, temporal lobe atrophy
- Marked atrophy → knife-like gyri

Alcoholic Encephalopathy

- 3rd most common cause of dementia
- Generalized > focal atrophy; superior vermis atrophy

CADASIL

- Most common heritable cause of stroke, VaD in adults
- Earlier age of onset
- Imaging looks like "small vessel" disease

https://CafePezeshki.IR

Dementia With Lewy Bodies

- Hypometabolism of entire brain
- Without infarcts or significant atrophy

PATHOLOGY

General Features

- Etiology
  - MID is usually due to multiple small infarctions
    - Infarcts involving entire major vessel territories are usually absent
    - Minority may be secondary to single or a few large infarctions
  - ~ 75% of all MID patients exhibit small vessel disease rather than thromboembolism
  - Growing evidence exists for involvement of cholinergic system in VaD
    - Cholinergic deficits well documented in VaD, independent of concomitant AD pathology
    - Cholinergic neuron loss in 70% of AD, 40% of VaD
- Genetics
  - Apolipoprotein E (*APOE*)
    - Serum protein involved in lipid metabolism
    - Encoded at single gene locus on chromosome 19 by 3 alleles: ε2, ε3, ε4
    - Frequency of ε4 allele significantly higher among patients with AD and VaD compared to controls
    - Odds of developing AD or VaD are 4.4x and 3.7x higher (respectively) in presence of even a single ε4 allele
  - Paraoxonase (*PON1*)
    - Component of high-density lipoproteins with antioxidative potential
    - 2 *PON1* polymorphisms (Gln192Arg associated with enzyme activity and T-107C associated with enzyme concentration) are independent risk factors for VaD, particularly in *APOE* (ε4)

Staging, Grading, & Classification

- 8 subtypes of VaD
  - Multi-infarct dementias: Due to large cerebral emboli, usually readily identifiable
  - Strategically placed infarctions causing dementia
  - Multiple subcortical lacunar lesions: Develop VaD 5-25x more frequently than age-matched controls
  - Binswanger disease: Small vessel disease → widespread incomplete infarction of WM
  - Mixtures of 2 or more VaD subtypes
  - Hemorrhagic lesions causing dementia
  - Subcortical dementias due to other causes (e.g., cerebral autosomal dominant arteriopathy with subcortical infarcts and leukoencephalopathy [CADASIL])
  - Hybrid forms of Alzheimer dementia and VaD

Gross Pathologic & Surgical Features

- Multifocal infarctions with atrophy

Microscopic Features

- Arteriosclerosis and amyloid angiopathy major underlying pathologies in small vessel vascular disease
- Vessels display atheromata, lipohyalinosis, subintimal thickening, fibrinoid necrosis
- Infarcted tissue undergoes necrosis → gliotic wall surrounding CSF cavity
- Myelin and axonal loss with astrocytosis

CLINICAL ISSUES

Presentation

- Most common signs/symptoms
  - Infarcts with transient focal neurologic deficits
    - Most deficits persist
  - Mood and behavioral changes
  - Deterioration of executive function and attention, changes in personality (rather than memory loss) predominate
  - Severe depression is more common in VaD than AD
- Clinical profile
  - Main risk factors
    - Advanced age, hypertension, diabetes, smoking
    - Hypercholesterolemia, hypercoagulable states

Demographics

- Age
  - Generally earlier age than AD
  - Incidence ↑ with age
- Gender
  - M > F
- Epidemiology
  - 10 % of dementias
  - 2nd most common dementia (after AD)
  - ~ 25% of elderly stroke patients meet VaD criteria

Natural History & Prognosis

- Progressive, episodic, stepwise downward course
- Intervals of clinical stabilization ± limited recovery
- 5-year survival with VaD ~ 50% of age-matched controls

Treatment

- Prevent further vascular insult
  - Control precipitating factors (e.g., HTN, diabetes)

DIAGNOSTIC CHECKLIST

Image Interpretation Pearls

- Not a single entity, but a large group of conditions with variable clinical and imaging findings

Reporting Tips

- Report strategically placed infarcts, hemorrhagic components, DWI abnormalities, pattern of cortical volume loss if present

SELECTED REFERENCES

1. Shivamurthy VK et al: Brain FDG PET and the diagnosis of dementia. AJR Am J Roentgenol. 204(1):W76-85, 2015
2. Venkat P et al: Models and mechanisms of vascular dementia. Exp Neurol. ePub, 2015
3. Villeneuve S et al: Imaging Vascular Disease and Amyloid in the Aging Brain: Implications for Treatment. J Prev Alzheimers Dis. 2(1):64-70, 2015
4. Yamada M: Cerebral amyloid angiopathy: emerging concepts. J Stroke. 17(1):17-30, 2015
5. Ihara M et al: Understanding and preventing the development of post-stroke dementia. Expert Rev Neurother. 14(9):1067-77, 2014

https://CafePezeshki.IR

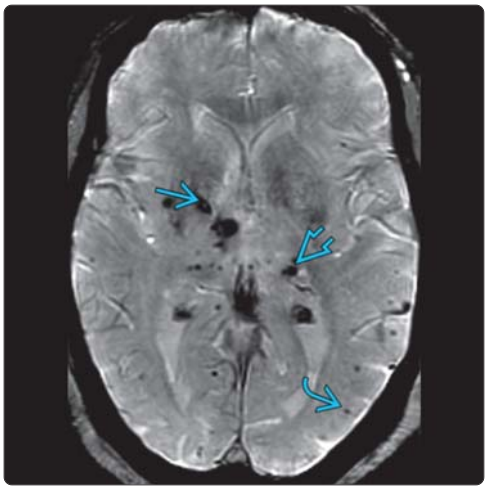

(Left) *Axial FLAIR MR in a patient with vascular dementia shows confluent periventricular white matter hyperintensities with volume loss.* **(Right)** *Axial SWI image in the same patient shows multiple "blooming" hypointense foci due to remote microhemorrhages in the basal ganglia, thalami, and cerebral cortex. This patient had long-standing uncontrolled hypertension and the distribution of the microhemorrhages predominantly in the deep gray nuclei supports that.*

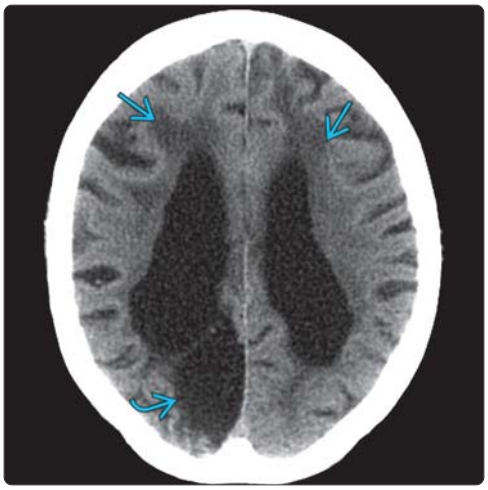

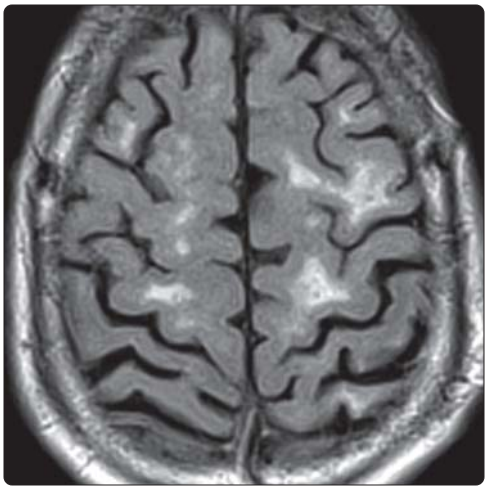

(Left) *Axial NECT in a 81-year-old woman with MID shows cystic encephalomalacia in the right parietal lobe due to an old infarct. There is marked volume loss with ventricular enlargement. There are confluent white matter hypodensities consistent with arteriolosclerosis and lipohyalinosis.* **(Right)** *Axial FLAIR MR shows multiple subcortical hyperintensities in a 76-year-old normotensive man with clinical diagnosis of vascular dementia. No focal infarcts are seen.*

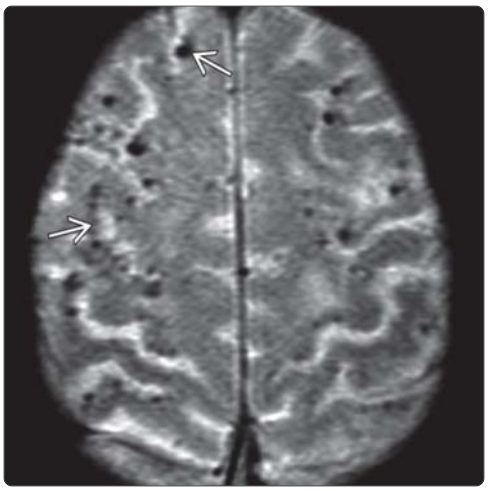

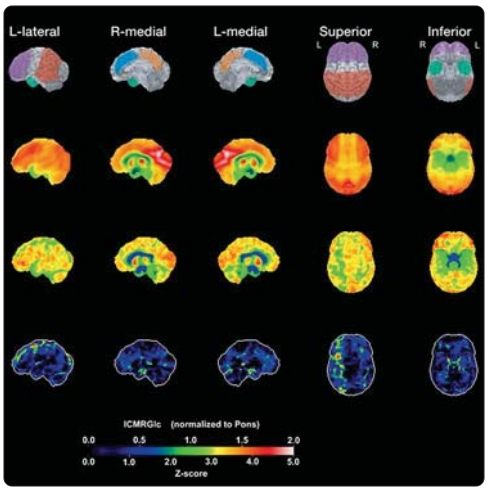

(Left) *Axial T2* GRE MR in the same patient shows multifocal cortical/subcortical blooming "black dots". The cerebellum and basal ganglia were spared, suggesting amyloid angiopathy as the most likely diagnosis.* **(Right)** *PET scan in the same patient shows multifocal areas of diminished glucose metabolism (3rd row) compared to normal age-matched controls (2nd row). Z-score maps (bottom row) confirm the multifocal, diffuse nature of this patient's vascular disease. (Courtesy N. Foster, MD.)*

https://CafePezeshki.IR

KEY FACTS

TERMINOLOGY

- Clinical subtypes
  - Behavioral-variant frontotemporal dementia (bvFTD)
  - Primary progressive aphasia syndromes (PPA)
    - Semantic variant (sv-PPA): Previously known as semantic dementia
    - Nonfluent/agrammatic variant (nfv-PPA): Previously known as progressive nonfluent aphasia
    - Logopenic variant (lv-PPA)
  - Frontotemporal dementia with motor symptoms

IMAGING

- Early
  - PET shows frontotemporal ↓ glucose metabolism
- Late: Frontotemporal atrophy with knife-like gyri on MR
- Subtypes have characteristic cortical atrophy patterns

TOP DIFFERENTIAL DIAGNOSES

- Alzheimer dementia (AD)
- Vascular dementia
- Corticobasal ganglionic degeneration (CBD)
- Dementia with Lewy bodies (DLB)

CLINICAL ISSUES

- Clinical syndromes (some overlap)
  - **bvFTD**: Marked changes in personality & behavior, mixture of apathy & disinhibition
  - **sv-PPA**: Progressive loss of "semantic" knowledge about words, objects & concepts, fluent speech
  - **nfv-PPA**: Effortful speech production & orofacial apraxia
  - **lv-PPA**: Word finding pauses & poor sentence repetition
- Younger age group than Alzheimer disease
- FTLD most common cause of early-onset age (< 65 years) dementia
- Median survival: 6-11 years from symptom onset & 3-4 years from diagnosis

(Left) *Graphic depicts the classic disproportionate frontal lobe atrophy of late-stage frontotemporal dementia (FTD). The sulci are widened and gyri are knife-like ⇨. Parietal occipital lobes are spared. Gyri around the central sulcus are normal.* **(Right)** *Parasagittal image (3D-MPRAGE) was obtained as part of the initial evaluation in a patient with suspected FTD. Note the frontal lobe knife-like gyri ⇨ with markedly widened sulci and preservation of the parietal and occipital lobes.*

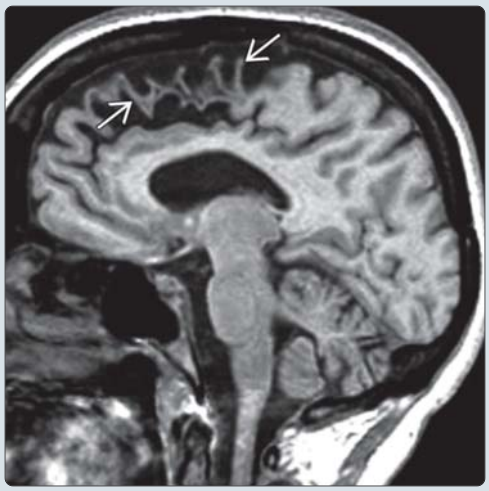

(Left) *Sagittal SSP FDG PET scan in a 72-year-old man with FTD shows a normal elderly control map (2nd row), the patient's glucose metabolism (3rd row), and Z-score statistical map (bottom row). The frontal lobes ⇨ are strikingly hypometabolic. The temporal lobes ⇨ are somewhat less severely affected.* **(Right)** *Axial T2WI MR in a patient with semantic dementia subtype of FTLD shows marked atrophy of anterolateral temporal lobes ⇨. Note the relative preservation of the hippocampi ⇨.*

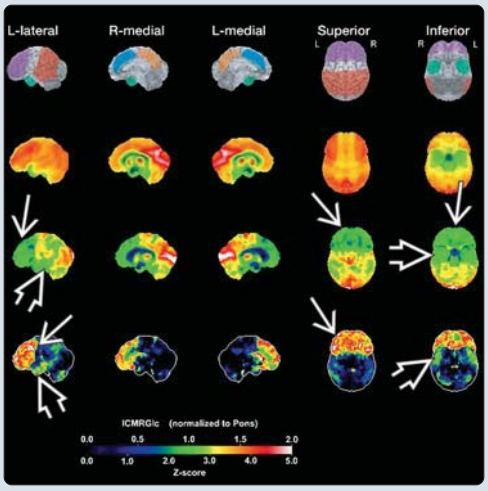

https://CafePezeshki.IR

TERMINOLOGY

Abbreviations

- Frontotemporal lobar degeneration (FTLD)
- Clinical subtypes
  - Behavioral-variant frontotemporal dementia (bvFTD)
  - Primary progressive aphasia syndromes (PPA)
    - Semantic variant (sv-PPA): Previously known as semantic dementia
    - Nonfluent/agrammatic variant (nfv-PPA): Previously known as progressive nonfluent aphasia
    - Logopenic variant (lv-PPA)
- Frontotemporal dementia with motor symptoms
  - Corticobasal degeneration (CBD)
  - Progressive supranuclear palsy (PSP)
  - FTD with motor neuron disease
  - FTD with amyotrophic lateral sclerosis (ALS)

Synonyms

- Pick disease no longer used
  - Referred to pathologic variant with Pick bodies

Definitions

- Heterogenous family of neurodegenerative disorders characterized by focal lobar degeneration of frontal &/or temporal lobes

IMAGING

General Features

- Best diagnostic clue
  - PET scan showing frontotemporal ↓ glucose metabolism
  - Anterior frontotemporal atrophy with knife-like gyri
- Location
  - Anterior temporal/frontal lobes, orbital frontal lobe, medial temporal lobes
  - Relative sparing of
    - Parietal, occipital lobes
- Morphology
  - Knife blade appearance of atrophic gyri
  - ± marked asymmetry
    - May have worst atrophy in dominant hemisphere

CT Findings

- NECT
  - Frontal lobe atrophy often most prominent feature
    - Increased size of frontal horns (larger than rest of lateral ventricles)

MR Findings

- T1WI
  - Atrophy of frontal & temporal lobes, often asymmetric
  - Knife-like gyri with normal signal
  - Dilated frontal sulci reflecting atrophy
  - Relative sparing of parietal & occipital lobes
- T2WI
  - ± hyperintensity in frontotemporal WM
- MRS
  - ↓ NAA and glutamate-plus-glutamine (neuronal loss), ↑ myoinositol (↑ glial content) in frontal lobes
    - Reflects ↓ neuronal population, viability
  - ± lactate peak in frontal lobes
- MR voxel based morphometry
  - Subtypes have characteristic cortical atrophy patterns
  - Frontal vs. temporal, L vs. R help discriminate
  - **bvFTD**: Atrophy of frontal & temporal lobes
    - Asymmetric right frontal &/or right temporal atrophy may occur
  - **sv-PPA**: Typically atrophy of left anterior inferior temporal lobe
    - Entire temporal lobe can be involved
    - Ventromedial & superior frontal lobes
    - Right temporal atrophy as disease progresses
  - **nfv-PPA**: Selective left perisylvian & frontal atrophy
  - **lv-PPA**: Atrophy mainly left-sided & more posterior involving angular & middle temporal gyri
- DTI
  - Wide spread damage to WM tracts reported
  - **bvFTD**: Uncinate fasciculus, inferior longitudinal fasciculus, & anterior commissural fibers
  - **sv-PPA**: Inferior longitudinal & uncinate fasciculi
  - **nfv-FTD**: Left superior longitudinal fasciculus
  - **lv-PPA**: Widespread dorsal & ventral WM tracts

Nuclear Medicine Findings

- PET
  - FDG PET: ↓ metabolic activity in frontotemporal cortex
  - Amyloid imaging (11C-labeled Pittsburgh compound-B) helps differentiate FTLD from Alzheimer disease
- HMPAO-SPECT
  - Sensitive technique for early detection of FTD
    - Occurs before atrophy is evident
  - **bvFTD**: ↓ perfusion frontal & anterior temporal lobes
    - Asymmetric, left or right dominant
  - **sv-PPA**: Prominent anterior temporal hypoperfusion, L > R
  - **nfv-PPA**: Asymmetric frontal hypoperfusion often involving insular cortex
  - **lv-PPA**: ↓ perfusion in left parietal inferior lobule & posterolateral temporal lobe
- SPECT perfusion deficits predominantly in frontal and anterior temporal lobes with preserved perfusion posteriorly
  - Helps distinguishes FTD from Alzheimer disease
- Reduced frontal perfusion is not specific to FTD but also occurs in some cases of schizophrenia, depression, HIV encephalopathy, Creutzfeldt-Jakob disease, Alzheimer disease

Imaging Recommendations

- Best imaging tool
  - PET/SPECT; MR voxel-based morphometry
- Protocol advice
  - Routine T1WI, T2WI, coronal T2WI

DIFFERENTIAL DIAGNOSIS

Alzheimer Disease (AD)

- Parietal and temporal cortical atrophy with disproportionate hippocampal volume loss
- Increased rate of atrophy in FTD compared to AD

https://CafePezeshki.IR

- Often coexisting microvascular disease, white matter hyperintensities, microhemorrhages
- Amyloid imaging (11C-labeled Pittsburgh Compound-B) helps to differentiate AD from other dementias

Vascular Dementia

- 2nd most common dementia (15-30%)
- White matter and deep gray lacunae
- Hyperintense lesions on T2WI and focal atrophy is suggestive of chronic infarcts

Corticobasal Degeneration

- Prominent extrapyramidal, cortical symptoms
- Severe frontoparietal atrophy contralateral to more severely affected clinically
- Atrophy of paracentral structures

Dementia With Lewy Bodies (DLB)

- Hypometabolism of entire brain, especially visual cortex
- Visual and auditory hallucinations, paranoid delusions

PATHOLOGY

General Features

- Etiology
  - Tau protein (hyperphosphorylated microtubular protein) or TDP-43 (TAR DNA-binding protein-43)
  - Rare cases change on fused-in-sarcoma (FUS) protein
- Genetics
  - 25-40% of FTD is familial
  - Most common: Mutations in tau gene (microtubule-associated protein tau [MAPT])
  - Progranulin gene (*PGRN*) results in TDP-43 pathology

Staging, Grading, & Classification

- Histopathologic classification of FTLD
  - FTLD- tau: Tau inclusion
  - FTLD-TDP: Tau-negative & TDP-43-positive inclusions
  - FTLD-FUS: Tau/TDP-negative & FUS-positive inclusions
  - FTLD-UPS: Positive immunohistochemistry against proteins of ubiquitin protease system (UPS)
  - FTLD-ni: No inclusions

Gross Pathologic & Surgical Features

- Gross atrophy of frontal & anterior temporal lobes
- Firm cortical gray matter (gliosis)
- Soft, retracted subcortical white matter

Microscopic Features

- Loss of pyramidal neurons & microvacuolar degeneration in layer II & III of frontal & temporal cortex
- Subjacent WM shows axonal & myelin loss
- FTLD-related tauopathies
  - Pick disease: Prototypical tauopathy of FTLD
  - Characterized by Pick bodies: Solitary, round or oval, argyrophilic inclusions in cytoplasm of neurons
  - Commonly found in dentate gyrus of hippocampus, amygdala, frontal & temporal neocortex

CLINICAL ISSUES

Presentation

- Most common signs/symptoms
  - Personality, behavior, and language changes
  - Memory loss, confusion, cognitive and speech dysfunction, apathy, and abulia
- Clinical profile
  - **bvFTD**: Marked changes in personality & behavior, mixture of apathy & disinhibition
    - Repetitive motor behaviors, cognitive decline
  - **sv-PPA**: Progressive loss of "semantic" knowledge about words, objects & concepts, fluent speech
  - **nfv-PPA**: Effortful speech production & orofacial apraxia
  - **lv-PPA**: Word finding pauses & poor sentence repetition

Demographics

- Age
  - Younger age group than Alzheimer disease
    - Onset usually < 70 years
    - Peak incidence 45-65 years
- Gender
  - bvFTD & sv-FTD: Male preponderance
  - nfv-PPA: Female predominance
- Ethnicity
  - Familial forms of Pick-complex dementias particularly common in people of Scandinavian origin
- Epidemiology
  - FTLD most common cause of early-onset (age < 65 years) dementia
  - Age > 65 years account for 20-25 % of cases of FTLD
  - Prevalence: 2.7-15.1/100,000

Natural History & Prognosis

- Insidious onset of behavioral and cognitive dysfunction
- Speech and language disturbance are often more profound than memory disorder
- Median survival 6-11 years from symptom onset & 3-4 years from diagnosis

DIAGNOSTIC CHECKLIST

Consider

- Other common forms of dementia (AD, DLB)

Image Interpretation Pearls

- Bilateral frontal lobe atrophy should cause diagnosis of FTD to be considered
- Bilateral asymmetric anterior temporal lobe atrophy: sv-FTD

Reporting Tips

- Report pattern of cortical volume loss

SELECTED REFERENCES

1. Shivamurthy VK et al: Brain FDG PET and the diagnosis of dementia. AJR Am J Roentgenol. 204(1):W76-85, 2015
2. Bott NT et al: Frontotemporal dementia: diagnosis, deficits and management. Neurodegener Dis Manag. 4(6):439-54, 2014
3. Chare L et al: New criteria for frontotemporal dementia syndromes: clinical and pathological diagnostic implications. J Neurol Neurosurg Psychiatry. 85(8):865-70, 2014

https://CafePezeshki.IR

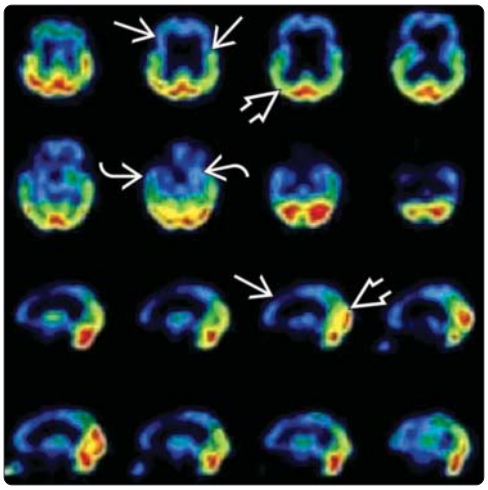

(Left) *Axial NECT in a 78-year-old patient diagnosed with late-stage FTD through the upper lateral ventricles shows striking frontal lobar atrophy, with classic knife-like gyri characteristic of FTD. In contrast, the parietal and occipital lobes appear relatively spared.* **(Right)** *FDG PET in a patient with frontotemporal dementia shows marked hypometabolism in the frontal and temporal lobes. There is relative preservation of glucose metabolism in the occipital and parietal lobes.*

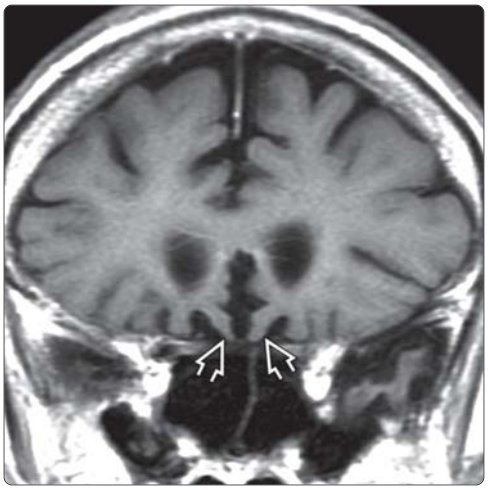

(Left) *Axial T2WI MR in a patient with classic FTD shows predominantly frontal lobar atrophy with knife-like gyri. In this case, an associated region of hyperintense white matter is present.* **(Right)** *Coronal T1WI MR in the same patient shows focal atrophy of the olfactory gyri. This finding was initially overlooked, and the patient was given the imaging diagnosis of Alzheimer disease. Review and subsequent clinical evaluation confirmed frontotemporal dementia.*

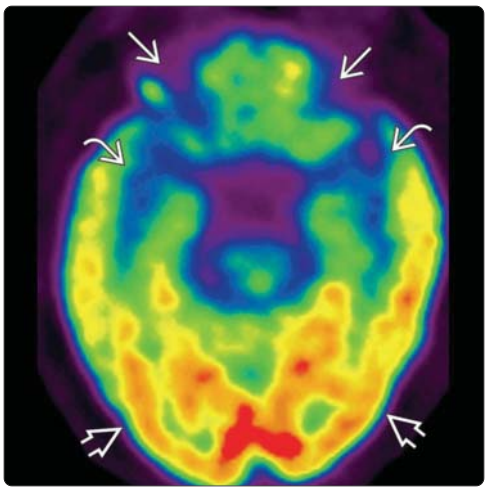

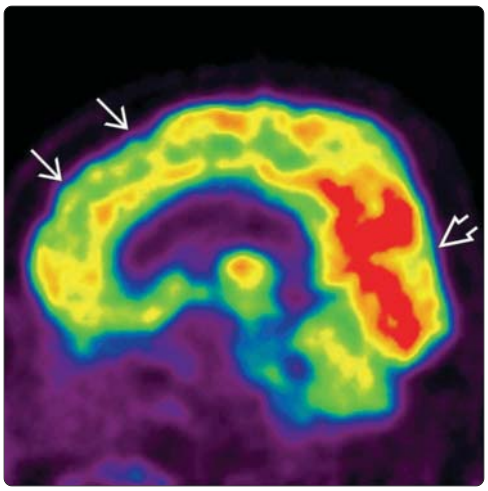

(Left) *Axial FDG PET in a patient with FTD shows decreased glucose metabolism in frontal and temporal lobes. The parietal and occipital lobes are spared.* **(Right)** *Sagittal FDG PET in the same patient with FTD depicts glucose hypometabolism in the frontal lobes. The occipital lobes are normal.*

https://CafePezeshki.IR

KEY FACTS

TERMINOLOGY

- Progressive neurodegenerative dementia
  - Parkinsonism, visual hallucinations prominent
  - Caused by abnormal accumulation of α-synuclein protein

IMAGING

- MR may differentiate Alzheimer disease (AD) from dementia with Lewy bodies (DLB)
- PET, SPECT most useful for DLB diagnosis
- Voxel-based morphometry
  - Relatively preserved hippocampal/medial temporal lobe volume in DLB compared to AD
  - Reduced volume of hypothalamus, substantia innominata and putamen in DLB compared to AD
- FDG PET
  - ↓ in glucose metabolism in occipital cortex, especially primary visual cortex
  - 18F-fluorodopa-PET: ↓ striatal dopamine uptake in DLB vs. AD
- SPECT: Occipital lobe hypoperfusion, especially visual cortex
- 123FP-CIT-SPECT: ↓ uptake in striatum in DLB vs. AD

TOP DIFFERENTIAL DIAGNOSES

- Parkinson disease-associated dementia (PDD)
  - Similar clinical, pathological, imaging features with DLB
- Alzheimer disease (AD)
- Frontotemporal lobar degeneration (FTLD)
- Vascular dementia

PATHOLOGY

- Pathologic aggregation of α-synuclein protein in neurites (Lewy bodies)

DIAGNOSTIC CHECKLIST

- Unlike Alzheimer disease, medial temporal lobe atrophy not a prominent feature

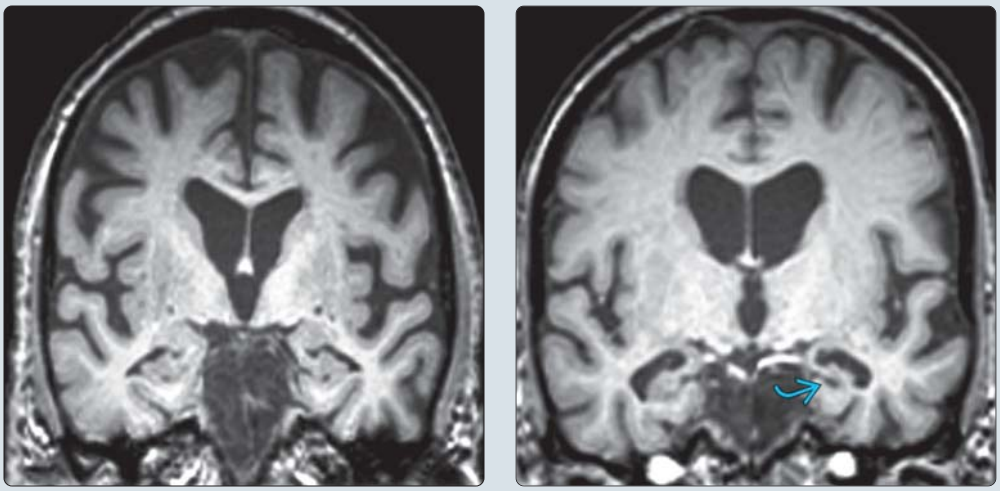

(Left) *Coronal T1WI MR in a patient with dementia with Lewy bodies shows prominent frontal lobe volume loss with relative sparing of hippocampal volume. (Courtesy M.J. Firbank, MD, and J.T. O'Brien, MD.)* **(Right)** *Coronal T1WI MR in a patient with Alzheimer disease (AD) shows marked hippocampal volume loss and relative sparing of frontal lobes. (Courtesy M.J. Firbank, MD, and J.T. O'Brien, MD.)*

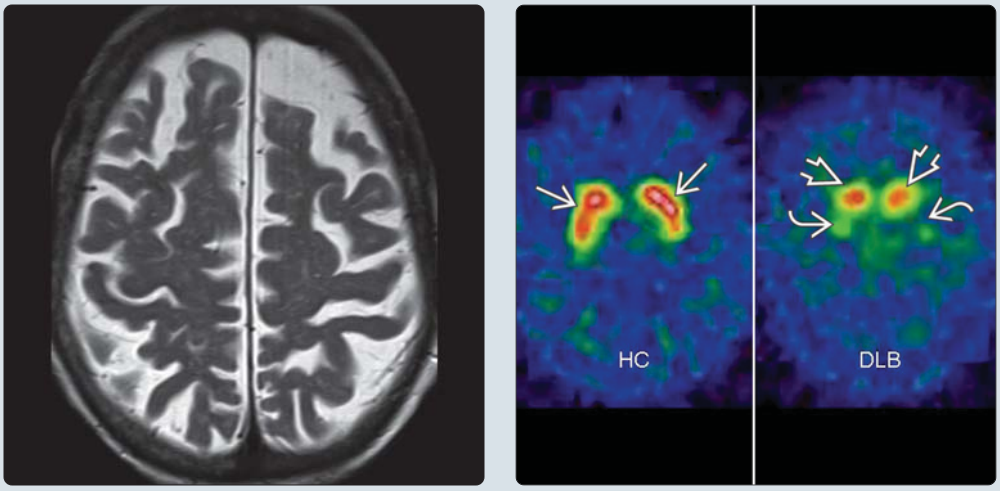

(Left) *Axial T2WI MR in a patient with DLB shows nonspecific diffuse cortical atrophy. Conventional MR findings are frequently nonspecific in DLB.* **(Right)** *123FP-CIT-SPECT, DAT imaging (dopamine transporter) shows normal symmetric uptake in the striatum of a healthy control (HC). In DLB, there is marked reduced update in the putamen and mild in the caudate nuclei. Using DAT imaging it is not possible to distinguish DLB from atypical parkinsonian syndromes like MSA, PSP, and CBD.*

https://CafePezeshki.IR

TERMINOLOGY

Abbreviations

- Dementia with Lewy bodies (DLB)

Definitions

- Neurodegenerative dementia characterized by cognitive fluctuations, visual hallucinations, and motor parkinsonism
  - Caused by pathologic aggregation of α-synuclein protein in neurites (Lewy bodies)

IMAGING

General Features

- Best diagnostic clue
  - MR may differentiate Alzheimer disease (AD) from DLB
  - PET, SPECT most useful for DLB diagnosis

Imaging Recommendations

- Best imaging tool
  - PET or SPECT

MR Findings

- T1WI
  - Mild generalized atrophy
- T2WI
  - Nonspecific white matter (WM) hyperintensities
- MRS
  - ↓ WM NAA/Cr in DLB compared to healthy controls (HC)
  - ↑ Cho/Cr ratios in DLB compared to HC
  - Normal levels of NAA/Cr and myoinositol in DLB compared to AD
- Voxel-based morphometry
  - Relatively preserved hippocampal/medial temporal lobe volume in DLB compared to AD
  - Reduced volume of hypothalamus, substantia innominata, and putamen in DLB compared to AD
  - Reduced gray matter in temporal, parietal, and occipital regions compared to HC
- DTI
  - ↑ mean diffusivity in amygdala
  - ↓ FA in pons and left thalamus compared to AD
  - ↓ FA in inferior longitudinal fasciculus and inferior occipitofrontal fasciculi compared to HC

Nuclear Medicine Findings

- PET
  - FDG PET: ↓ in glucose metabolism in occipital cortex and visual association cortex with relative preservation of posterior cingulate
  - 18F-fluorodopa-PET: ↓ striatal dopamine uptake in DLB vs. AD
- SPECT
  - Occipital lobe hypoperfusion, especially visual cortex
  - 123FP-CIT-SPECT: To visualize DAT (dopamine transporter) loss
    - ↓ uptake in striatum in DLB vs. AD (caudate, anterior, and posterior putamen)

DIFFERENTIAL DIAGNOSIS

Parkinson Disease-Associated Dementia

- Similar clinical, pathological, imaging features to DLB
- Less pronounced atrophy in temporal, occipital, and parietal lobes compared to DLB

Alzheimer Disease (AD)

- Parietal/temporal cortical atrophy
  - Disproportionate hippocampal volume loss
- More severe, faster rate of progression than DLB

Frontotemporal Lobar Degeneration (FTLD)

- Asymmetric frontal, anterior temporal lobar atrophy

Vascular Dementia

- 2nd most common dementia (15-30%)
- Infarcts of different ages

PATHOLOGY

General Features

- Etiology
  - Accumulation of α- synuclein protein (Lewy bodies)
- Genetics
  - Majority of DLB is sporadic; some are familial

Microscopic Features

- Lewy bodies in substantia nigra, neocortex, limbic system
  - α-synuclein protein aggregates: Pale eosinophilic inclusions

CLINICAL ISSUES

Presentation

- Most common signs/symptoms
  - Cognitive decline, fluctuations in level of alertness
  - Visual hallucinations, parkinsonian features

Demographics

- Age
  - 55-85 years; age is only risk factor
- Gender
  - Men more commonly affected
- Epidemiology
  - 15-20% of dementia cases
  - 2rd most common neurodegenerative dementia (after AD)

Natural History & Prognosis

- Average survival after diagnosis = 8 years

DIAGNOSTIC CHECKLIST

Image Interpretation Pearls

- No characteristic features on standard MR

SELECTED REFERENCES

1. Orimo S: [Differential diagnosis of dementia with lewy bodies.] Brain Nerve. 67(4):413-25, 2015
2. Broski SM et al: Structural and functional imaging in parkinsonian syndromes. Radiographics. 34(5):1273-92, 2014
3. Mak E et al: Neuroimaging characteristics of dementia with Lewy bodies. Alzheimers Res Ther. 6(2):18, 2014

https://CafePezeshki.IR

KEY FACTS

TERMINOLOGY

- Creutzfeldt-Jakob disease (CJD): Rapidly progressing, fatal, potentially transmissible dementia caused by prion

IMAGING

- Best imaging clue: Progressive T2 hyperintensity of basal ganglia (BG), thalamus, and cerebral cortex
- Predominantly gray matter (GM): Caudate and putamen > globus pallidus (GP)
  - Thalamus: Common in variant CJD (vCJD)
  - Cerebral cortex: Frontal, parietal, and temporal
- Heidenhain variant: Occipital lobe
- 2 signs seen in 90% of vCJD but can also occur in sporadic CJD (sCJD)
  - "Pulvinar" sign: Symmetric T2 hyperintensity of pulvinar of thalamus
  - "Hockey stick" sign: Symmetric pulvinar and dorsomedial thalamic nuclear hyperintensity
- Best imaging tool: MR with DWI

TOP DIFFERENTIAL DIAGNOSES

- Hypoxic-ischemic injury
- Osmotic demyelination syndrome
- Other causes of dementia
  - Alzheimer, frontotemporal, multi-infarct dementia, dementia in motor neuron disease
- Leigh syndrome
- Corticobasal degeneration

CLINICAL ISSUES

- Definite CJD diagnosed by brain biopsy or autopsy
- Progressive dementia associated with myoclonic jerks and akinetic mutism; variable constellation of pyramidal, extrapyramidal, and cerebellar signs
- CSF protein biomarkers: 14-3-3 protein, total tau (t-tau) and neuron-specific enolase (NSE)
- DWI MR has higher diagnostic accuracy, 97% than any or all of these 3 CSF biomarkers
- Death usually ensues within months of onset

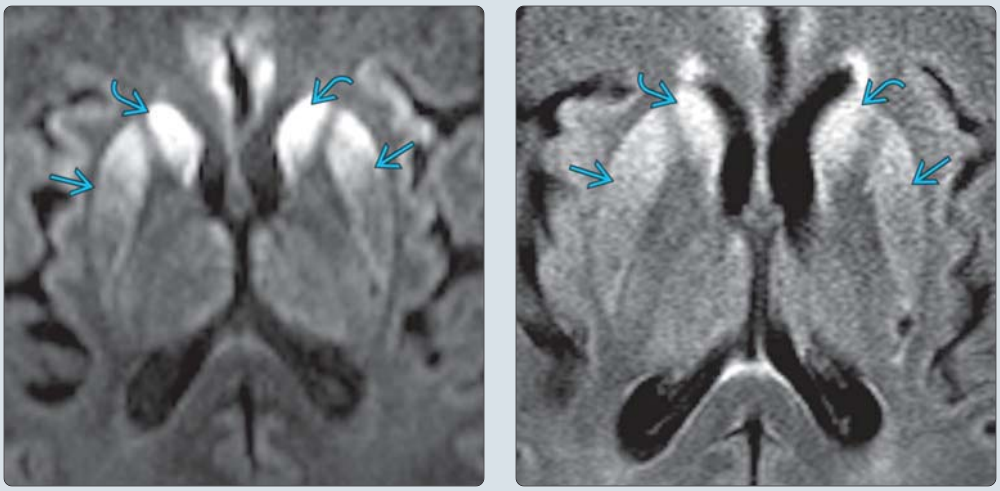

(Left) *Axial DWI in a 67-year-old man with rapidly progressing dementia shows typical findings of sporadic Creutzfeldt-Jakob disease (sCJD). There is symmetric restricted diffusion involving the caudate nuclei and putamina.* **(Right)** *Axial FLAIR MR in the same patient shows corresponding high signal in the caudate nuclei and putamina. Creutzfeldt-Jakob disease (CJD) is a rapidly progressing, fatal, neurodegenerative disorder caused by a prion. MR with DWI is the imaging procedure of choice.*

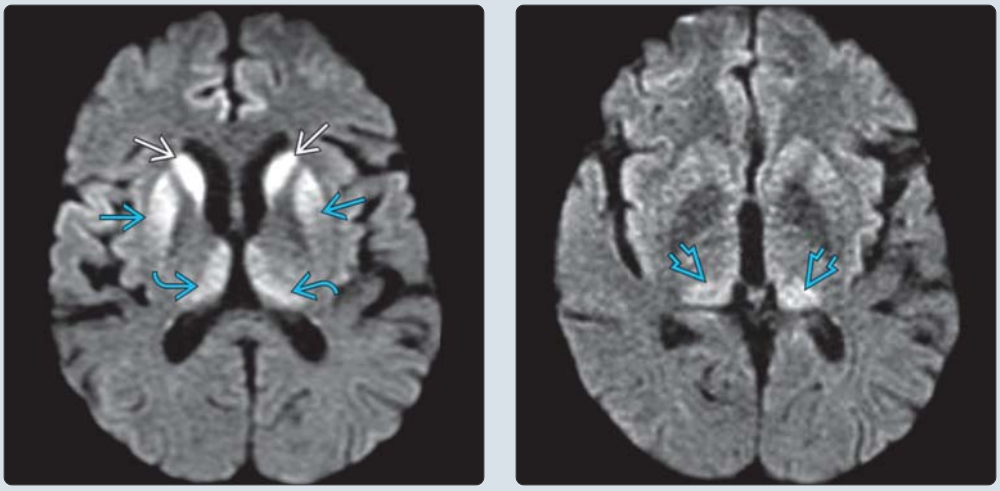

(Left) *Axial DWI in a patient with sCJD demonstrates restricted diffusion involving the caudate nuclei and putamina. There is also involvement of the posteromedial thalami giving the classic "hockey stick" sign.* **(Right)** *Axial DWI in a patient with variant CJD (vCJD) shows classic "pulvinar" sign with symmetric hyperintensity in the posterior thalami. The "hockey stick" and "pulvinar" signs are seen in 90% of vCJD but can also occur in sCJD.*

https://CafePezeshki.IR

TERMINOLOGY

Abbreviations

- Creutzfeldt-Jakob disease (CJD)
- Sporadic Creutzfeldt-Jakob disease (sCJD)
- Variant Creutzfeldt-Jakob disease (vCJD)

Definitions

- Rapidly progressing, fatal, neurodegenerative disorder caused by prion (proteinaceous infectious particle devoid of DNA and RNA)
  - Transmissible spongiform encephalopathy

IMAGING

General Features

- Best diagnostic clue
  - Progressive T2 hyperintensity of basal ganglia (BG), thalamus, and cerebral cortex
- Location
  - Predominantly gray matter (GM)
    - BG: Caudate and putamen > globus pallidus (GP)
    - Thalamus (common in vCJD)
    - Cerebral cortex (most commonly frontal, parietal, and temporal lobes)
      - Cortical involvement often asymmetric
      - Heidenhain variant: Occipital lobe
      - Brownell-Oppenheimer: Cerebellum
  - White matter (WM) usually not involved

CT Findings

- NECT: Usually normal
  - May show rapidly progressive atrophy and ventricular dilatation on serial CT

MR Findings

- T1WI
  - Normal
- T2WI
  - Hyperintense signal in BG, thalami, cortex
  - Cerebral atrophy
  - With time, hyperintense foci may develop in WM
- FLAIR
  - 2 signs seen in 90% of vCJD but can also occur in sCJD
    - "**Pulvinar**" sign: Bilateral symmetrical hyperintensity of **pulvinar** (posterior) nuclei of **thalamus**
    - "**Hockey stick**" sign: Symmetrical **pulvinar and dorsomedial thalamic** nuclear hyperintensity
  - Periaqueductal GM hyperintensity
  - Cortical hyperintensity (common in sCJD)
- DWI
  - Progressive hyperintensity in striatum and cortex
  - Gyriform hyperintense areas in cerebral cortex ("cortical ribbon" sign)
    - Correspond to localization of periodic sharp-wave complexes on EEG
  - DWI hyperintensity may disappear late in disease
- T1WI C+: No enhancement of lesions

Nuclear Medicine Findings

- PET: Regional glucose hypometabolism correlates with sites of neuropathologic lesions
- SPECT with N-isopropyl-p-(I-123) iodoamphetamine
  - ↓ uptake of tracer and ↓ absolute values of rCBF in various parts of cerebral cortex

Imaging Recommendations

- Best imaging tool: MR with DWI and FLAIR

DIFFERENTIAL DIAGNOSIS

Hypoxic-Ischemic Injury

- BG and parasagittal cortical areas involved
- Hyperintense BG lesions on T1WI and T2WI
- DWI + symmetric GM involvement

Osmotic Demyelination Syndrome

- Extrapontine: T2 hyperintense putamen and caudate
- DWI positive acutely

Leigh Syndrome

- Primarily seen in pediatric patients
- T2 hyperintensity in putamen and GP

Other Causes of Dementia

- Alzheimer disease
- Dementia in motor neuron disease
- Frontotemporal dementia
- Multi-infarct dementia

Corticobasal Degeneration

- Neuronal loss in substantia nigra, frontoparietal cortex, and striatum (BG atrophy may be subtle)
- MR: Symmetric/asymmetric atrophy of pre- and postcentral gyri; prominent parasagittal involvement
- Subcortical gliosis: High intensity on T2WI

Wilson Disease

- WM and deep GM lesions (BG, dentate nucleus, brainstem); variably T2 hyperintense
- T1 hypointense (rarely hyperintense) lesions

Arteriolosclerosis

- BG involvement: Typically asymmetric and multifocal (rather than diffuse as in CJD)
- Focal hyperintensities in deep WM
- DWI negative, unless acute

PATHOLOGY

General Features

- Etiology
  - Prion protein is misfolded isoform (PrPSc) of normal host-encoded protein (PrPc)
  - PrPSc introduced into healthy cells → initiates self-perpetuating vicious cycle: PrPc → PrPSc
  - sCJD : Spontaneous PrPc → PrPSc or somatic mutation
  - Familial CJD (fCJD): Mutations in *PRNP*
  - Iatrogenic CJD: Infection from prion-containing material
    - Surgical instruments, dura mater grafts
    - Cadaveric corneal transplants, human growth hormone preparations
  - vCJD: Bovine spongiform encephalopathy in cattle is transmitted to humans through infected beef
    - a.k.a. new variant CJD (nvCJD)
- Genetics

https://CafePezeshki.IR

CDC Diagnostic Criteria for CJD 2010

(I) Clinical Signs	(II) Tests
(1) Dementia	(1) PSWCs on EEG
(2) Cerebellar or visual	(2) 14-3-3 detection in CSF (disease duration < 2 years)
(3) Pyramidal or extrapyramidal	(3) High signal abnormalities in caudate and putamen or at least 2 cortical regions (temporal-parietal-occipital) either on DWI or FLAIR
(4) Akinetic mutism	
Probable CJD: 2 out of 1 clinical signs and at least 1 out of 2 tests	
Probable CJD: 2 out of 1 clinical signs and at least 1 out of 2 tests	

Updated clinical diagnostic criteria for sporadic Creutzfeldt-Jakob disease. Zerr I et al: Updated clinical diagnostic criteria for sporadic Creutzfeldt-Jakob disease. Brain. 132(Pt 10):2659-68, 2009

- Can be inherited, sporadic, or acquired (infectious)
- 10-15% of human prion disease cases associated with dominant mutations in autosomal prion protein (PrPc) gene (*PRNP*) on chromosome 20
- Associated abnormalities
  - EEG: Periodic [high-voltage] sharp waves complexes (PSWCs) on background of low-voltage activity

Gross Pathologic & Surgical Features

- Mild cortical atrophy
- Ventricular enlargement

Microscopic Features

- Spongiform encephalopathy: GM most affected
  - Marked neuronal loss with reactive astrocytosis
  - Replacement gliosis
  - Neuronal vacuolation with spongiform changes
- 10% of patients with CJD have amyloid plaques in cerebellum or cerebral hemispheres
- Variable accumulation of PrPSc in brain tissue

CLINICAL ISSUES

Presentation

- Most common signs/symptoms
  - Rapidly progressive dementia associated with myoclonic jerks and akinetic mutism
  - Variable constellation of pyramidal, extrapyramidal, and cerebellar signs
- Clinical profile
  - **sCJD**: Cerebellar dysfunction, rapidly progressive cognitive impairment, both
    - 6 molecular subtypes: MM1, MM2, MV1, MV2, VV1, and VV2
      - Vary with respect to age at onset, disease duration, early symptoms, and neuropathology
  - **vCJD**: Psychiatric and sensory symptoms
    - **Heidenhain variant** of CJD
      - Isolated visual signs/symptoms (initially)
      - Predominantly occipital lobe degeneration
    - **Brownell-Oppenheimer**: Cerebellar signs/symptoms
    - Extrapyramidal type of CJD
      - May show ↑ signal intensity in BG
    - Pyramidal involvement with disease progression
  - **CSF studies**
    - CSF protein biomarkers: 14-3-3 protein, total tau (t-tau) and neuron-specific enolase (NSE)
    - DWI MR has higher diagnostic accuracy than any or all 3 CSF biomarkers
  - Real-time quaking induced conversion (RT-QUIC) testing of CSF to detected PrPsc
    - More sensitive using olfactory epithelium (nasal brushing) than CSF

Demographics

- Age
  - Young in vCJD, older in sCJD (6th to 7th decades)
- Ethnicity
  - sCJD occurs throughout world, in all races
  - vCJD limited to Europe (~ all cases in UK)
- Epidemiology
  - Incidence 1-1.5 per million in US
  - sCJD (85%), familial (15%), infectious/iatrogenic (less than 1%)

Natural History & Prognosis

- Long incubation period but rapidly progressive once clinical symptoms begin
- Rapidly progressing dementia, with death usually ensuing within months of onset
  - Median survival from time of onset of symptoms to death is 4.5 months
  - 90% live < 1 year

Treatment

- No effective treatment

DIAGNOSTIC CHECKLIST

Consider

- Heidenhain variant of CJD in patients with visual disorders of unclear origin and dementia

Image Interpretation Pearls

- Lack of BG findings does not rule out CJD

SELECTED REFERENCES

1. Caobelli F et al: The role of neuroimaging in evaluating patients affected by Creutzfeldt-Jakob disease: a systematic review of the literature. J Neuroimaging. 25(1):2-13, 2015
2. Kim MO et al: Clinical update of Jakob-Creutzfeldt disease. Curr Opin Neurol. 28(3):302-10, 2015
3. Felix-Morais R et al: Creutzfeldt-Jakob disease: typical imaging findings. BMJ Case Rep. 2014, 2014

https://CafePezeshki.IR

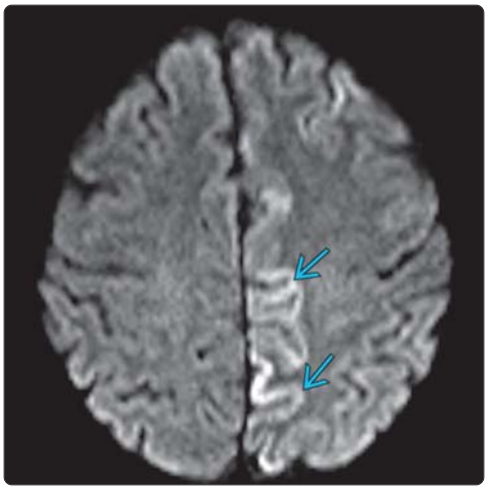

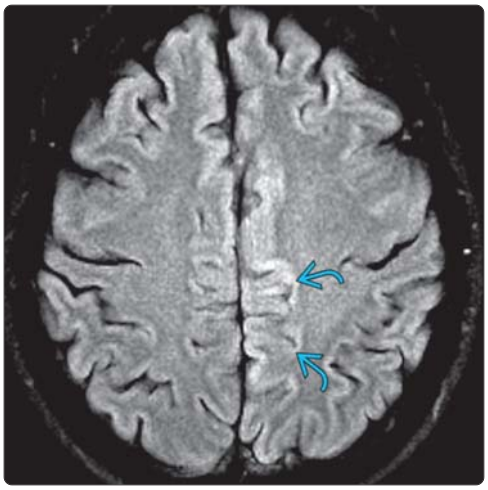

(Left) *Axial DWI in a patient with sCJD shows cortical restricted diffusion* ⇨ *also called "cortical ribbon" sign.* **(Right)** *Axial FLAIR in the same patient shows subtle corresponding cortical hyperintensity* ⇨*. The cortical signal abnormality corresponds to localization of periodic sharp-wave complexes on EEG. DWI MR has higher diagnostic accuracy, 97% than any or all of the 3 CSF biomarkers: 14-3-3 protein, total tau (t-tau), and neuron-specific enolase (NSE).*

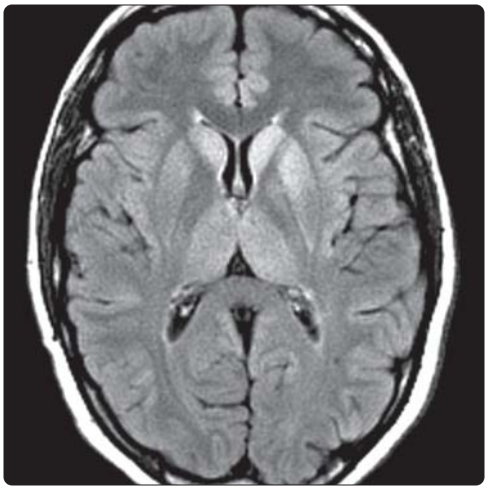

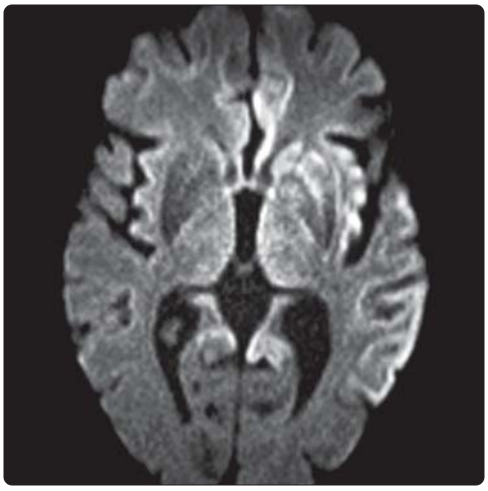

(Left) *Axial FLAIR MR shows asymmetric hyperintensity in the caudate heads, left greater than right, and the left putamen.* **(Right)** *Axial DWI MR in the same patient a few weeks later shows asymmetric hyperintensity in the basal ganglia, left greater than right, and the cerebral cortex. Asymmetric cortical involvement is more common than asymmetric basal ganglia involvement in CJD. This elderly man had rapidly progressive dementia and probable CJD, as EEG showed characteristic features.*

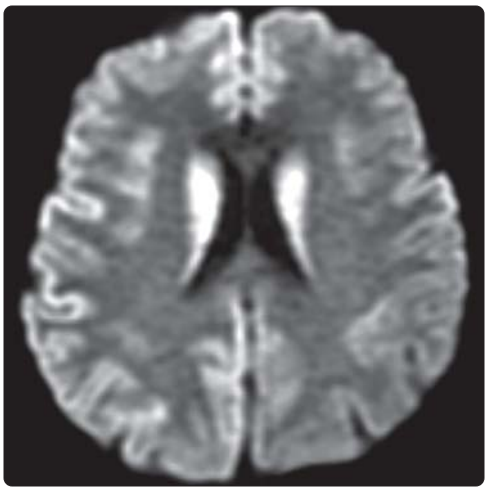

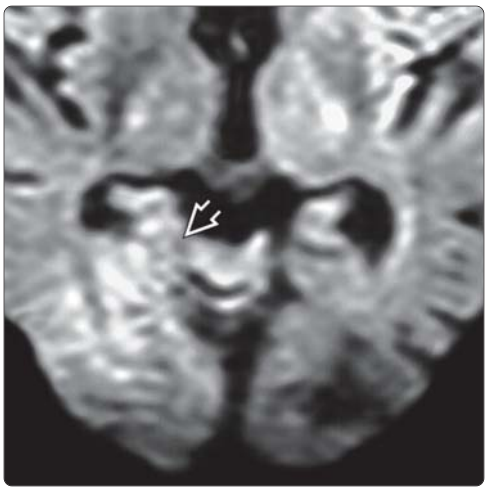

(Left) *Axial DWI MR shows marked hyperintensity related to decreased diffusivity in the caudate nuclei and cortex in this patient with CJD. DWI is the most sensitive sequence for diagnosis of CJD.* **(Right)** *Axial DWI MR shows marked hyperintensity in the right occipital lobe* ⇨ *and left insula in a patient with primarily visual complaints. The Heidenhain variant of CJD is characterized by isolated visual signs and symptoms initially. Occipital lobe involvement predominates on imaging.*

https://CafePezeshki.IR

KEY FACTS

TERMINOLOGY

- Parkinson disease (PD)
  - Progressive neurodegenerative disease
  - Primarily affects pars compacta of substantia nigra (SNpc)

IMAGING

- MR
  - SNpc narrowed/inapparent (T2WI)
  - SNpc progressively loses normal hyperintensity (from lateral to medial)
  - Border between SNpc, red nucleus blurred on PD
  - ↑ R2' relaxation at 3T in SNpc, caudal putamen (reflects ↑ iron content)
  - DWI may differentiate PD from PSP, MSA-P
  - MRS: Nonspecific, ↓ NAA/Cr and NAA/choline ratios in basal ganglia
- PET/SPECT helpful for distinction from "Parkinson-plus" syndromes
- ↑ ADC in putamen and caudate nucleus

TOP DIFFERENTIAL DIAGNOSES

- Multiple system atrophy (MSA)
  - Parkinsonian variant of MSA (MSA-P)
- Progressive supranuclear palsy
- Corticobasal ganglionic degeneration
- Dementia with Lewy bodies

PATHOLOGY

- Lewy bodies (eosinophilic intracytoplasmic inclusions with peripheral halos and dense cores), gliosis

CLINICAL ISSUES

- Resting tremor
- "Cogwheel" rigidity
- Bradykinesia
- Shuffling gate
- "Masked" facies

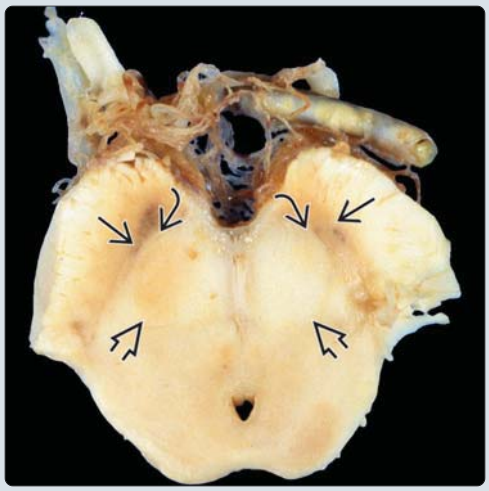

(Left) *Axial midbrain diagram shows narrowing and depigmentation of the substantia nigra in Parkinson disease (upper) relative to normal anatomy (lower).* **(Right)** *Axial slice through the midbrain of a patient with severe Parkinson disease shows gross pathologic changes. Note the striking narrowing and depigmentation of the pars reticulata of the substantia nigra. The pars compacta, which is the region between the pars reticulata and the red nucleus, is markedly narrowed.*

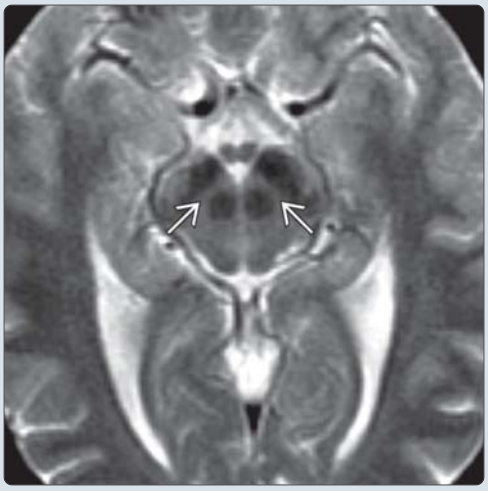

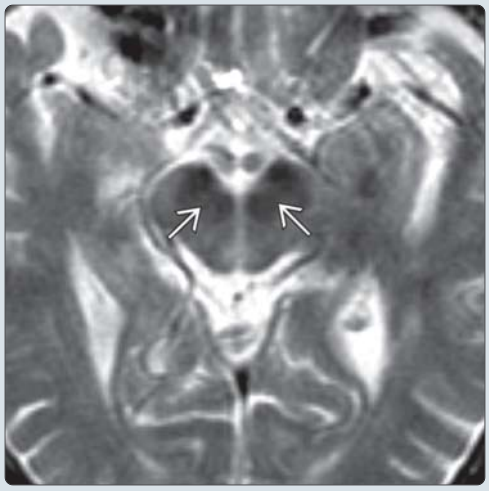

(Left) *Axial T2WI MR in a normal individual shows the appropriate width of the pars compacta, a striking contrast to the abnormal findings seen in a patient with Parkinson disease.* **(Right)** *Axial T2WI MR in a patient with Parkinson disease shows classic midbrain findings. Note the "blurring" and thinning of pars compacta between 2 hypointense structures (i.e., the pars reticulata of substantia nigra and red nucleus). As a result, the red nuclei and substantia nigra are almost touching.*

https://CafePezeshki.IR

TERMINOLOGY

Abbreviations

- Idiopathic Parkinson disease (PD), paralysis agitans

Definitions

- Progressive neurodegenerative disease predominantly caused by primary disorder of pars compacta of substantia nigra (SNpc)
- Parkinsonism: Syndrome characterized by rigidity, tremor, bradykinesia, and postural imbalance
  - Idiopathic PD (typically responsive to L-dopa therapy)
  - "Parkinson-plus" syndrome: Parkinsonism combined with other clinical signs
    - e.g., dementia with Lewy bodies, multiple system atrophy, progressive supranuclear palsy, corticobasal degeneration

IMAGING

General Features

- Best diagnostic clue
  - Thinning of pars compacta of substantia nigra
- Location
  - Substantia nigra (SN), caudate nucleus, and putamen
- Size
  - Decreased (atrophy)

CT Findings

- NECT
  - Nonspecific cerebral atrophy

MR Findings

- T1WI
  - Most commonly, generalized enlargement of sulci, ventricles, which is nonspecific
  - Voxel-based morphometry
    - Nonspecific gray matter (GM) loss of limbic, paralimbic and prefrontal cortices
- T2WI
  - In normal subjects, SN is 2-layered GM structure at upper midbrain level
    - Hypointense area in posterior region of crus cerebri = pars reticulata of SN (SNpr)
    - Relatively hyperintense area between SNpr and red nucleus (RN) = SNpc
      - Some authors maintain this is best seen on PD images rather than T2WI
    - Hypointense area normally seen on axial T2WI corresponds to anterosuperior aspect of SN, adjacent crus cerebri (upper midbrain), anteromedial part of peduncular fibers (lower midbrain)
  - SNpc narrows in PD, difficult to distinguish from adjacent SNpr and RN
  - T2 hyperintense foci can be seen in putamen and globus pallidus (GP) in some PD patients; in addition, volume of putamen is decreased
  - At 3.0T imaging, increased R2 relaxation rates, indicative of increased iron content, are seen in SNpc and caudal portion of putamen in PD
- PD/intermediate
  - Axial intermediate-weighted SE images in normal subjects: Anatomic location of SN can be accurately identified
    - SN seen as area of hyperintense GM surrounded by hypointense RN and crural fibers at upper midbrain level
    - SNpr and SNpc cannot be distinguished
  - Axial intermediate TE images in PD
    - Progressive loss of normal signal of SNpc from lateral to medial; SNpc no longer appears hyperintense
    - Indistinct border between SNpr and RN, which reflects neuronal loss and iron deposition
- STIR
  - Fast STIR images: Same findings as proton density-weighted images
- DWI
  - Significantly ↑ putaminal ADC in Parkinson variant of multiple system atrophy (MSA-P) compared to PD
  - ↑ ADC in putamen and caudate nucleus
    - vs. progressive supranuclear palsy (PSP) and Parkinson variant of multiple system atrophy (MSA-P), which have ↑ putaminal ADC values
  - ↑ ADC of olfactory tracts in PD compared to healthy controls
- MRS
  - Nonspecific, ↓ NAA/Cr and NAA/choline ratios in basal ganglia
- DTI
  - ↓ FA in SN and along path of nigrostriatal projection
    - FA values correlate inversely with clinical severity of PD
  - ↓ FA in frontal lobe (supplementary motor area, presupplementary motor area, cingulum)
- T2 or T2* mapping
  - Sensitive to iron content in brain; ↑ ↑ R2' relaxation rate in SN of PD correlates with patient's motor symptoms but not with disease duration

Ultrasonographic Findings

- Brain parenchyma sonography: Hyperechoic appearance of SN in PD
  - Hypointense appearance of putamen (iron accumulation) in Parkinson-plus syndromes (PSP, MSA), not in PD

Nuclear Medicine Findings

- PET
  - May be used to study functional status of dopaminergic neurons in SN, dopamine D2 receptors in basal ganglia, or opiate receptors in basal ganglia
  - Dopaminergic neurons in SN
    - 18F-fluorodopa PET: ↓ striatal uptake proportional to decreased number of dopaminergic neurons; correlated with clinical severity
      - More pronounced reduction in striatal uptake in putamen than in caudate nucleus
      - May diagnose early/relatively asymptomatic PD
  - Dopamine D2 receptors in basal ganglia
    - 11C-raclopride PET; putaminal dopamine terminals are normal or increased in early stages of PD but normalize in advanced PD, reduced in MSA
  - Opiate receptors in basal ganglia

https://CafePezeshki.IR

  - 11C-diprenorphine; reduced uptake in putamen, thalamus, and anterior cingulate in PD patients with dyskinesias, normal in nondyskinetic PD patients
- SPECT: Like PET, may be used to study dopaminergic neurons in SN or dopamine D2 receptors in basal ganglia
  - Dopaminergic neurons in SN
    - I-123-FP-CIT SPECT findings in putamen similar to those seen with 18F-fluorodopa PET
  - Dopamine D2 receptors in basal ganglia
    - I-123 SPECT findings similar to those seen with 11C-raclopride PET

Imaging Recommendations

- Best imaging tool
  - Proton density-weighted SE MR and PET/SPECT
- Protocol advice
  - Proton density-weighted SE, fast STIR images allow direct visualization of SN as GM structure

DIFFERENTIAL DIAGNOSIS

Multiple System Atrophy (MSA)

- MSA-P: Prominent T2 hypointensity in putamen and caudate nucleus (abnormal iron deposition), putamen may show rim of ↑ T2 signal
- MSA-C: ↑ T2 signal in middle cerebellar peduncles, pontine transverse fibers (hot cross bun sign)

Progressive Supranuclear Palsy (PSP)

- Sag T1 MR: Tectal atrophy with a hummingbird appearance
- Concave posterolateral borders of atrophic midbrain giving morning glory flower appearance

Corticobasal Degeneration

- Thinning of pre-/postcentral gyri with central sulcus dilatation with marked parasagittal involvement

Dementia With Lewy Bodies

- Lewy bodies found diffusely in brain
- Brainstem, SN, and cortical atrophy

Parkinsonism-Dementia-Amyotrophic Lateral Sclerosis Complex

- Corticospinal tract abnormalities

PATHOLOGY

General Features

- Etiology
  - Various genetic markers are under study for increased susceptibility to developing PD
  - Environmental exposure: MPTP (1-methyl-4-phenyl-1,2,3,6-tetrahydropyridine); possibly pesticide exposure
  - Aging: Normal aging is associated with decrease of neurons in SNpc
- Genetics
  - Sporadic (3-5% of cases familial)
- Associated abnormalities
  - Increased iron content in SNpc

Gross Pathologic & Surgical Features

- Loss of pigmentation in SN and locus ceruleus

Microscopic Features

- Loss of dopaminergic neurons in SN (especially SNpc), locus ceruleus, dorsal vagal nucleus, and substantia innominata
- Lewy pathology: Misfolded α-synuclein aggregates to form intracellular inclusions within cell bodies (Lewy bodies) and processes of neurons (Lewy neurites)

CLINICAL ISSUES

Presentation

- Most common signs/symptoms
  - Resting tremor with frequency of 3-5 Hz (pill-rolling tremor), "cogwheel" rigidity, bradykinesia, shuffling gate, masked facies, later dementia in 40%
- Other signs/symptoms
  - Autonomic dysfunction, depression, sleep disturbance

Demographics

- Age
  - Onset typically between 50-60 years
- Gender
  - M:F = 1.5:1
- Epidemiology
  - Idiopathic PD is most common movement disorder
  - PD is 2nd most common neurodegenerative disorder after Alzheimer disease
  - Prevalence: 1% of population > 50 years old

Natural History & Prognosis

- Onset of PD is typically asymmetric
- Slowly progressive course of bradykinesia, rigidity, and gait difficulty → eventual disability after several years

Treatment

- Medical (favored for some younger patients): Levodopa, bromocriptine, amantadine, selegiline
- Surgical (for medically refractive cases): Stereotactic pallidotomy or deep brain stimulation for subthalamic nucleus, thalamus, globus pallidus

DIAGNOSTIC CHECKLIST

Consider

- Parkinson-plus syndromes

Image Interpretation Pearls

- Role of imaging in parkinsonism: Exclude treatable bradykinesia (tumor, hematoma, hydrocephalus)
- Minimal correlation between hypointense areas on T2WI and SN location on anatomical specimens/PD-weighted/fast STIR images

SELECTED REFERENCES

1. Booth TC et al: The role of functional dopamine-transporter SPECT imaging in parkinsonian syndromes, part 2. AJNR Am J Neuroradiol. 36(2):236-44, 2015
2. Goveas J et al: Diffusion-MRI in neurodegenerative disorders. Magn Reson Imaging. ePub, 2015
3. Kalia LV et al: Parkinson's disease. Lancet. ePub, 2015
4. Broski SM et al: Structural and functional imaging in parkinsonian syndromes. Radiographics. 34(5):1273-92, 2014
5. Cosottini M et al: MR imaging of the substantia nigra at 7 T enables diagnosis of Parkinson disease. Radiology. 271(3):831-8, 2014
6. Brooks DJ et al: Imaging biomarkers in Parkinson's disease. Prog Neurobiol. 95(4):614-28, 2011

https://CafePezeshki.IR

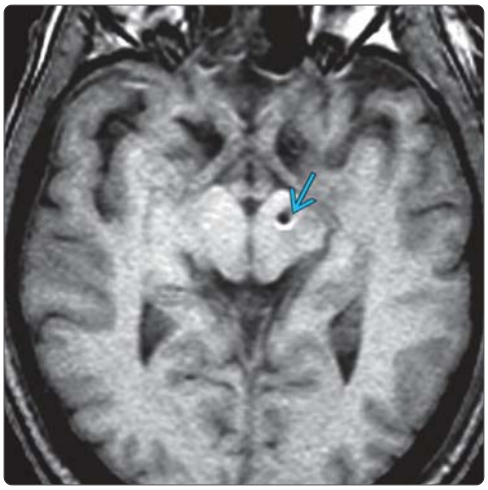

(Left) *Axial T2*GRE in a 61 year old with Parkinson disease shows narrowed pars compacta of substantia nigra ⇨ especially on the right with loss of clear distinction between the substantia nigra and red nucleus.* **(Right)** *Axial T1 MR in a patient with Parkinson disease shows the position of a deep brain stimulator ⇨. Correct positioning in the subthalamic nucleus is seen when the tip of electrode is ~ 9 mm from the midline and located just inside the upper margin of the cerebral peduncles.*

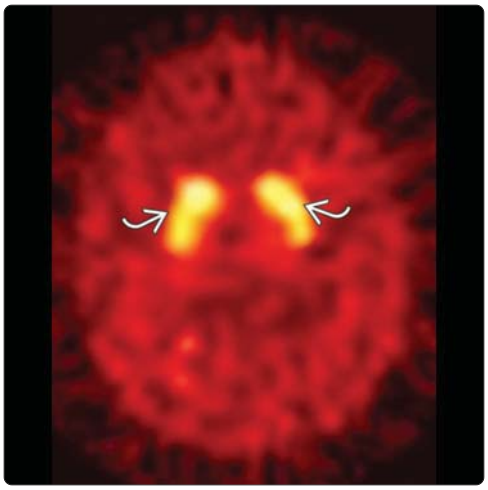

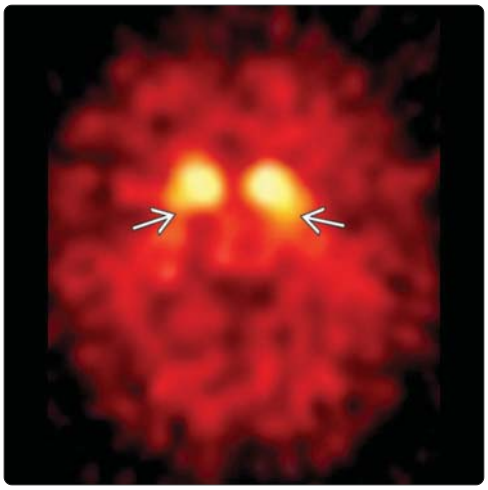

(Left) *Axial 123-FP-CIT DAT-SPECT image demonstrates normal symmetric tracer uptake in the caudate nuclei and putamina ⇨ with very low-grade, almost absent, background activity.* **(Right)** *Axial 123-FP-CIT DAT-SPECT image in a patient with idiopathic Parkinson disease shows asymmetric reduction in putaminal uptake ⇨, right greater than left. Note the normal tracer uptake in the caudate nuclei. (Courtesy A. Ali, MD and C. Singh, MD.)*

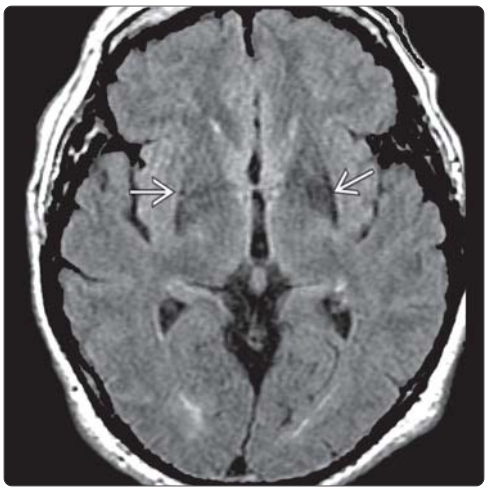

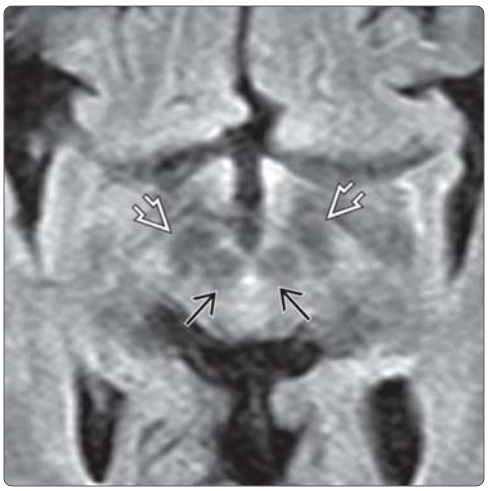

(Left) *Axial FLAIR MR in a patient with Parkinson disease shows abnormally decreased signal intensity of the posterior basal ganglia ⇨, as well as mildly decreased volume of the putamina.* **(Right)** *Axial FLAIR MR in the same patient shows the red nuclei ⇨ and pars reticulata ⇨ of the substantia nigra almost touching each other, indicating thinning of the pars compacta.*

https://CafePezeshki.IR

KEY FACTS

TERMINOLOGY

- Adult onset fatal neurodegenerative disease
- Multiple system atrophy (MSA) has 3 clinical subtypes
- Cerebellar (MSA-C)
  - Sporadic olivopontocerebellar atrophy (sOPCA)
- Extrapyramidal (MSA-P)
  - Striatonigral degeneration (SND)
- Autonomic (MSA-A)
  - Shy-Drager syndrome (SDS)

IMAGING

- General findings
  - ↓ ("flat") pons/medulla
  - Cerebellar vermis/hemispheres atrophic
- MSA-C
  - Selective atrophy of lower portion of basis pontis, medulla, MCPs, and cerebellar hemispheres
  - Corresponding ↑ T2 signal in pons, MCPs, and cerebellar white matter
  - Cruciform pontine hyperintensity ("hot cross bun" sign)
- MSA-P
  - ↓ T2 signal in dorsolateral putamen
  - ± ↑ T1 signal in lateral putamen rim
- FDG PET shows ↓ metabolism in putamen in MSA-P & ↓ FDG activity in cerebellar hemispheres and MCPs in MSA-C

TOP DIFFERENTIAL DIAGNOSES

- Parkinson, Parkinson-plus syndromes
- Friedreich ataxia (spinocerebellar ataxia)
- Progressive nonfamilial adult onset cerebellar degeneration
- Hereditary olivopontocerebellar atrophy (OPCA)
- Hereditary cerebellar atrophy

DIAGNOSTIC CHECKLIST

- MR features may overlap
- All MR findings may be observed in every MSA subtype

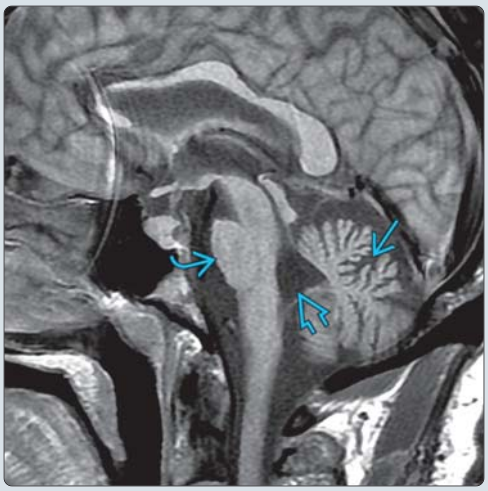

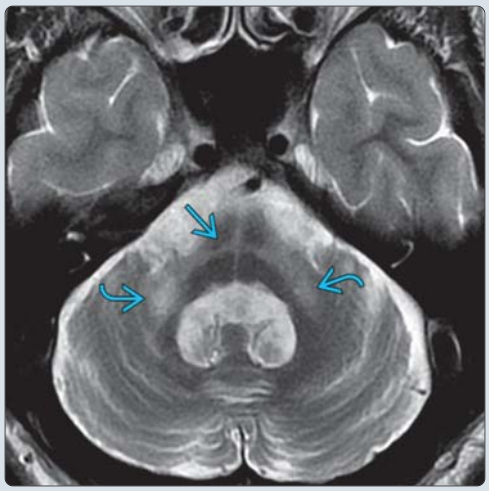

(Left) *Sagittal T1 MR in a patient with MSA-C type shows atrophy with flattening of the belly of pons. There is atrophy of the cerebellar vermis with prominence of the 4th ventricle.* **(Right)** *Axial T2 MR in the same patient shows characteristic pontine "hot cross bun" sign as well as symmetric hyperintensity in the middle cerebellar peduncles. The "hot cross bun" sign is caused by loss of myelinated transverse pontocerebellar fibers in the pontine raphe.*

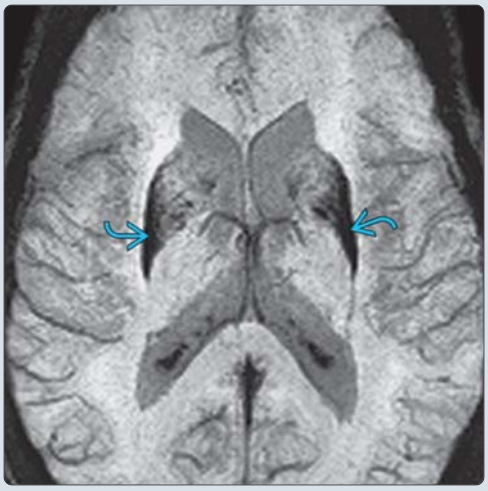

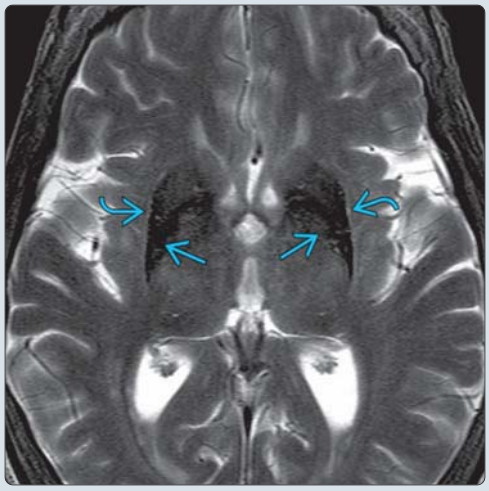

(Left) *Axial SWI in a patient with MSA-P type shows abnormal putaminal hypointensity with greater involvement of the lateral putamen. This is caused by higher iron deposition in MSA.* **(Right)** *Axial T2 MR in the same patient shows putaminal hypointensity due to iron deposition. In addition there is subtle T2 hyperintensity at the lateral margin of the putamen "hyperintense putaminal rim" sign.*

https://CafePezeshki.IR

TERMINOLOGY

Definitions

- Multiple system atrophy (MSA)
  - Adult onset fatal neurodegenerative disease, unknown etiology
  - Various combination of cerebellar/pyramidal/extrapyramidal/autonomic features
- 3 clinical subtypes characterized by signs and symptoms
  - Predominantly cerebellar (MSA-C)
    - a.k.a. sporadic olivopontocerebellar atrophy (sOPCA)
  - Extrapyramidal (MSA-P)
    - a.k.a. striatonigral degeneration (SND)
  - Autonomic (MSA-A)
    - a.k.a. Shy-Drager syndrome (SDS)
- 2 distinct imaging subtypes: MSA-C and MSA-P

IMAGING

General Features

- Best diagnostic clue
  - MSA-C: Cruciform shape of hyperintense signal in pons on T2WI; atrophy of pons, inferior olives, and cerebellum
  - MSA-P: Putamen atrophy, ↓ T2 signal in dorsolateral putamen ± ↑ T2 signal in lateral rim of putamen
- Location
  - Striatum (mainly putamen), middle cerebellar peduncles (MCP), pons, cerebellum
- Size
  - Decreased (atrophy)

CT Findings

- NECT
  - Pontine atrophy, enlarged 4th ventricle (4th V)
  - Cerebellar atrophy (hemispheres > vermis)
  - Cortical atrophy (especially frontal and parietal lobes)

MR Findings

- T1WI
  - On sagittal images
    - ↓ size of pons and medulla with flat ventral surface of pons
    - Atrophy of cerebellar vermis and hemispheres
  - On axial images
    - ↓ anteroposterior diameter of pons
    - ↓ width of MCP
    - Enlargement of 4th V and cerebellopontine angle
    - Cerebellar atrophy
  - Atrophy of MCP and cerebellum is greater in MSA-C than other MSA subtypes
  - Lateral putaminal T1 hyperintensity in MSA-P
  - Frontal, parietal atrophy
- T2WI
  - MSA-C type
    - Selective atrophy of lower portion of basis pontis, medulla, MCPs, and cerebellar hemispheres
    - Corresponding ↑ T2 signal in pons, MCPs, and cerebellar white matter (WM)
    - Hyperintense signal in cruciform shape in pons ("hot cross bun" sign)
      - Reflects degeneration of pontine neurons and transverse pontocerebellar fibers (TPF)
  - MSA-P type
    - Atrophy of putamen
    - ↓ signal in dorsolateral putamen ± ↑ signal in lateral rim of putamen
    - ↑ signal lateral rim putamen normal finding at 3.0 T
  - Atrophy of cerebral hemispheres
    - Especially frontal and parietal lobes
    - Not significantly different in various subtypes
  - All MR findings may be observed in every MSA subtype
- T2* GRE
  - SWI: Severe putaminal hypointensity in MSA-P type
- DWI
  - ↑ ADC in MCP helps differentiating MSA-C from PD and progressive supranuclear palsy
  - ↑ ADC in putamen helps differentiating MSA-P from Parkinson disease
  - Diffusion tensor MR (DTI)
    - MSA-C: ↓ FA in MCP, TPF, and cerebellum
- MRS
  - ^{1}H-MRS: Significantly ↓ pontine and cerebellar NAA/Cr, Cho/Cr ratios in MSA-C
    - Pontine NAA/Cr ratio correlates with disability
  - Phosphorus MRS: ↓ phosphocreatine, ↑ phosphate
- MR volumetry
  - Volumetry and voxel-based morphometry show striatal and cerebellar volume loss in MSA-P compared to PD and healthy controls
  - MCP width < 8 mm: In MSA compared to PD and healthy controls

Ultrasonographic Findings

- Transcranial ultrasound in MSA-P
  - Hyperechogenicity of lentiform nucleus and normal appearance of substantia nigra (SN) helps differentiating MSA-P from PD

Nuclear Medicine Findings

- PET
  - FDG PET in MSA-P: Relatively symmetric ↓ putaminal FDG activity
    - 11C-raclopride PET shows ↓ postsynaptic D2 receptor density in putamen
  - FDG PET in MSA-C: ↓ FDG activity in cerebellar hemispheres and MCPs
- SPECT
  - Dopamine transporter (DaT) selective radiotracers 123 I β CIT and 123 I ioflupane most widely used
  - 123 I ioflupane SPECT shows varying degree of unilateral or bilateral ↓ striatal uptake in MSA
  - DaT-SPECT shows no discernible difference in pattern of nigrostriatal degeneration between MSA and PD
  - D2 receptor SPECT may demonstrate reduction in D2 receptors in MSA compared to PD

Imaging Recommendations

- Best imaging tool
  - MR
- Protocol advice
  - Axial T2WI or FLAIR for "hot cross bun" sign, SWI

https://CafePezeshki.IR

DIFFERENTIAL DIAGNOSIS

Parkinson Disease

- Thinned pars compacta
- ↓ width of MCP in MSA but not in PD
- Putaminal iron deposition appears earlier and more prominent in MSA-P compared to PD

Other Parkinson-Plus Syndromes

- Progressive supranuclear palsy
- Corticobasal degeneration
- MCP widths are normal

Friedreich Ataxia (Spinocerebellar Ataxia)

- Severe atrophy of spinal cord (flat posterior aspect) and medulla oblongata
- Mild atrophy of vermian and paravermian structures

Progressive Nonfamilial Adult Onset Cerebellar Degeneration

- May occur in association with many conditions
  - Hashimoto thyroiditis (even in euthyroid state)
  - Paraneoplastic syndromes
  - Nutritional deficiency, alcohol abuse
  - Prolonged phenytoin/phenobarbital use
- Midline cerebellar atrophy on MR

Hereditary Olivopontocerebellar Atrophy (OPCA)

- Dominant OPCA
  - "Fine comb" type of cerebellar atrophy, involving hemispheres > vermis; atrophy of pons and MCP
- Recessive OPCA: Marked atrophy in lateral part of cerebellar hemispheres with "fish-mouth deformity"

Hereditary Cerebellar Atrophy

- Middle-aged patients; severe superior vermian atrophy

PATHOLOGY

General Features

- Etiology
  - Unknown; genetic and environmental factors contribute
- Genetics
  - Genetic factors play an etiological role in some families
  - Mutations in *COQ2* gene in familial and sporadic cases

Gross Pathologic & Surgical Features

- Variable degrees of olivopontocerebellar atrophy and striatonigral degeneration
- Frontal and parietal lobe atrophy

Microscopic Features

- Proteinaceous oligodendroglial cytoplasmic inclusions (glial cytoplasmic inclusion [GCIs]) are hallmark of MSA
  - Also called Papp-Lantos bodies
  - Main constituent of GCLs is misfolded α-synuclein
- Loss of cerebellar Purkinje cells
- Severe degeneration and gliosis in deep cerebellar WM
- ↑ accumulation of intracellular ferritin in basis pontis and putamen

CLINICAL ISSUES

Presentation

- Most common signs/symptoms
  - Parkinsonian features predominate in 80% of patients (MSA-P subtype)
    - Bradykinesia, rigidity, postural and rest tremor, unsteady gait, dysequilibrium
    - Differentiation from Parkinson disease is important
      - MSA-P more rapidly progressing, nonresponsive to L-Dopa
  - Cerebellar symptoms predominate in 20% of patients (MSA-C subtype)
    - Gait ataxia, limb akinetic ataxia, dysarthria, cerebellar oculomotor disturbance
  - Autonomic failure (MSA-A)
    - Symptomatic orthostatic hypotension
    - Erectile and urologic disturbance, constipation, hypo-/anhidrosis
  - Neuropsychological dysfunction, particularly in memory and other higher order cognitive functions
    - Cognitive dysfunction correlated with frontal, parietal atrophy

Demographics

- Age
  - Onset of MSA: Usually 6th decade
- Gender
  - No gender preference
- Epidemiology
  - Prevalence of MSA in USA: 3-5/100,000
  - Incidence rate of MSA: 0.6-3/100,000 per year
  - Associated with history of high exposure to exogenous toxins, organic solvents, plastic monomers, pesticides and metals

Natural History & Prognosis

- Progressive neurodegenerative disease
- Death usually occurs within 10 years from onset

Treatment

- Options, risks, complications
  - 90% of MSA-P patients are unresponsive to L-dopa

DIAGNOSTIC CHECKLIST

Image Interpretation Pearls

- "Hot cross bun" sign (cruciform shape of hyperintense signal in pons on T2WI) suggests diagnosis of MSA-C

SELECTED REFERENCES

1. Booth TC et al: The role of functional dopamine-transporter SPECT imaging in parkinsonian syndromes, part 2. AJNR Am J Neuroradiol. 36(2):236-44, 2015
2. Fanciulli A et al: Multiple-system atrophy. N Engl J Med. 372(3):249-63, 2015
3. Ramli N et al: Differentiating multiple-system atrophy from Parkinson's disease. Clin Radiol. 70(5):555-564, 2015
4. Reiter E et al: Dorsolateral nigral hyperintensity on 3.0T susceptibility-weighted imaging in neurodegenerative Parkinsonism. Mov Disord. ePub, 2015
5. Peeraully T: Multiple system atrophy. Semin Neurol. 34(2):174-81, 2014
6. Wenning GK et al: Multiple system atrophy. Handb Clin Neurol. 117:229-41, 2013

https://CafePezeshki.IR

(Left) *Axial NECT in a 62-year-old woman with multiple system atrophy of the cerebellar type shows cerebellar cortical atrophy demonstrated by the prominence of the horizontal fissure ⇨ and enlargement of the 4th ventricle ⇨.* **(Right)** *Axial T2WI MR through the lower pons in the same patient confirms cerebellar atrophy. The most striking feature is the cruciform region of the hyperintense signal ➡ within the atrophic pons, the "hot cross bun" sign.*

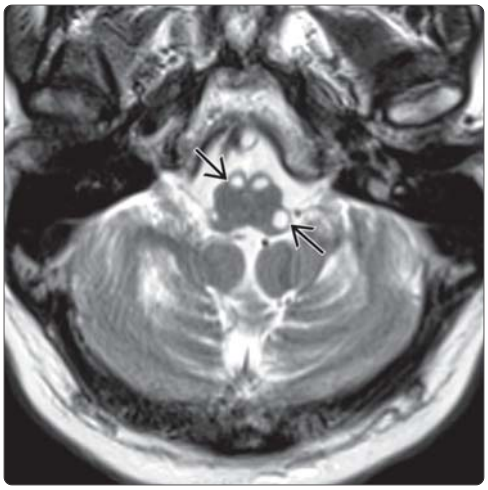

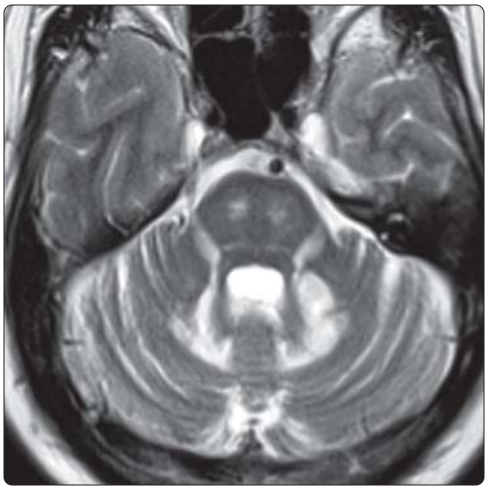

(Left) *Axial T2WI MR in a 55-year-old woman with sporadic olivopontocerebellar atrophy shows striking, symmetric high signal intensity in the pyramids and inferior cerebellar peduncles ⇨.* **(Right)** *Axial T2WI MR in the same patient shows hyperintensity in the middle cerebellar peduncles, dentate nuclei, and pons. The cerebellum appears moderately atrophic for the patient's age. The basal ganglia and cerebral hemispheres (not shown) were normal.*

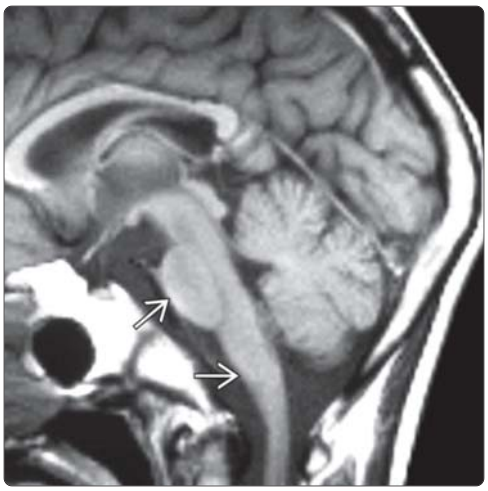

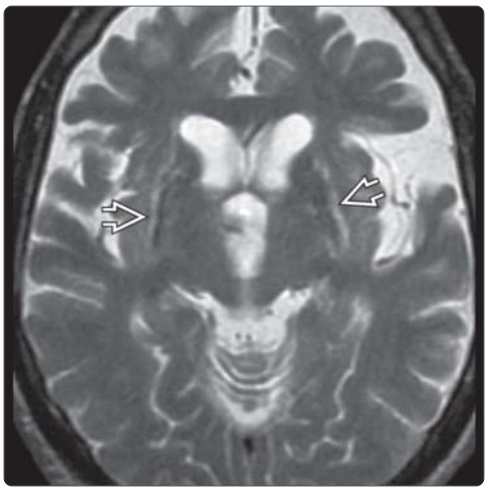

(Left) *Sagittal T1WI MR shows relatively "flat" pons and medulla ➡.* **(Right)** *Axial T2WI MR also demonstrates that the putamina appear small and hypointense, with a thin peripheral rim of high signal intensity ➡. The white matter (WM) appears quite normal compared to the overall degree of sulcal and ventricular enlargement.*

https://CafePezeshki.IR

KEY FACTS

TERMINOLOGY

- Corticobasal degeneration (CBD)
  - Progressive neurodegenerative disease
  - Presents with cognitive dysfunction, "asymmetrical" parkinsonism

IMAGING

- Severe focal asymmetric cortical atrophy
  - Perirolandic (posterior frontal, parietal cortex)
  - Relative sparing of temporal, occipital regions
- ↑ signal intensity in frontal &/or parietal subcortical white matter
- Marked T2 hypointensity
  - Putamen, globus pallidi
- 18F-FDG PET decreased uptake in cortical and subcortical regions (frontal, temporal, sensorimotor, and parietal association cortices), caudate, lentiform nucleus, and thalamus
- SPECT: Asymmetric hypoperfusion in frontoparietal lobes, basal ganglia (putamen), thalamus, and cerebellar hemispheres

TOP DIFFERENTIAL DIAGNOSES

- Progressive supranuclear palsy
- Frontotemporal lobar dementia/degeneration
- Alzheimer disease
- Dementia with Lewy bodies
- Amyotrophic lateral sclerosis (ALS)

PATHOLOGY

- Hyperphosphorylated tau/abnormal filamentous inclusions accumulate in neurons/glia

CLINICAL ISSUES

- Unilateral or asymmetrical parkinsonism
  - Dystonia, tremor
  - Ideomotor apraxia, "alien limb" phenomenon
- Cognitive decline

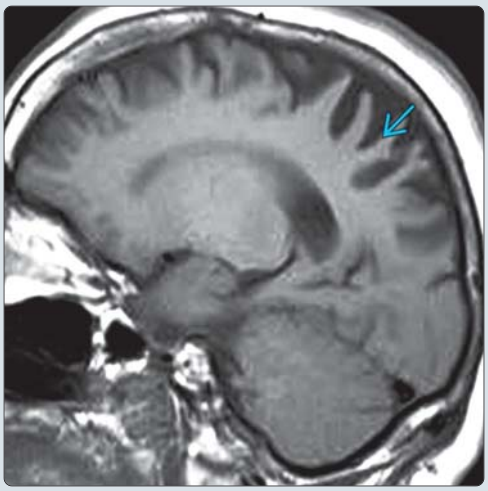

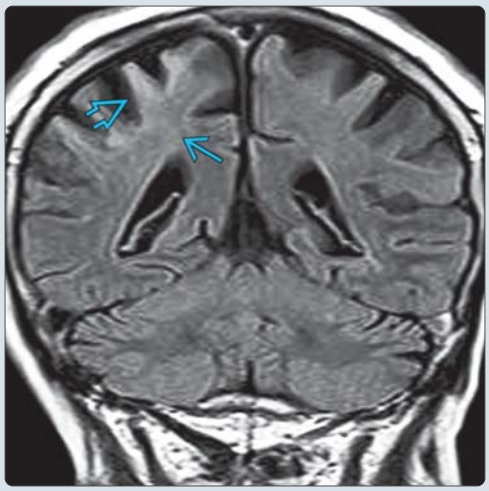

(Left) *Parasagittal T1WI MR through the right hemisphere in a 63-year-old man with corticobasal degeneration shows prominent volume loss in the posterior frontal and parietal cortex. The anterior frontal lobe cortex is normal in appearance.* **(Right)** *Coronal FLAIR MR in the same patient shows asymmetric parietal atrophy, worse on the right, with subcortical white matter hyperintensity. (Courtesy A. Erbetta, MD.)*

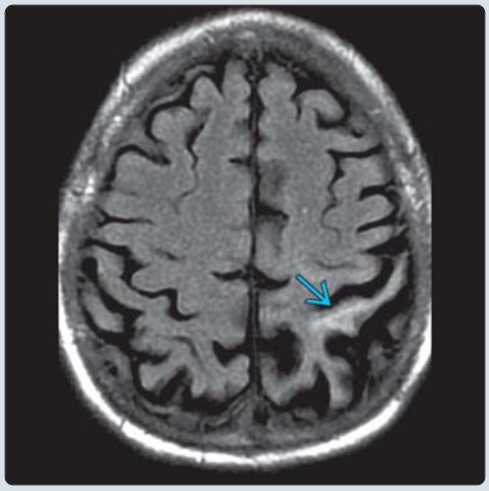

(Left) *Axial T2 MR in a 71-year-old male with corticobasal degeneration demonstrates asymmetric atrophy and thin cortex in the left perirolandic region.* **(Right)** *Axial FLAIR MR in the same patient shows subcortical white matter hyperintensity in the region of perirolandic atrophy. In CBD the dorsal prefrontal and perirolandic cortex, striatum, and midbrain tegmentum are most severely involved. Asymmetric frontoparietal atrophy is contralateral to the side that is more severely affected clinically.*

https://CafePezeshki.IR

TERMINOLOGY

Abbreviations

- Corticobasal degeneration (CBD)

Synonyms

- Corticobasal ganglionic degeneration (CBGD)
- Corticodentatonigral degeneration with neuronal achromasia

Definitions

- Progressive neurodegenerative disease
  - Presents with cognitive dysfunction, "asymmetrical" parkinsonism
  - Characterized pathologically by cortical and striatal tau protein accumulation

IMAGING

General Features

- Best diagnostic clue
  - Asymmetric cerebral atrophy (frontoparietal cortex ± cerebral peduncle)
- Size
  - Atrophy

Imaging Recommendations

- Best imaging tool
  - MR
- Protocol advice
  - Axial and coronal T2WI and FLAIR

CT Findings

- NECT
  - Asymmetric cerebral atrophy

MR Findings

- T1WI
  - Asymmetric cerebral atrophy
    - Posterior frontal, parietal cortex
    - ± cerebral peduncle, midbrain tegmentum, corpus callosum
- T2WI
  - Asymmetric hyperintensity in subcortical white matter (SCWM)
  - Marked hypointensity in putamen, globus pallidi
- FLAIR
  - Asymmetric ↑ signal intensity in frontal &/or parietal subcortical white matter
    - Seen more frequently in more cephalad brain regions
- MRS
  - Marked ↓ in N-acetylaspartate (NAA)/creatine ratio compared with controls in centrum semiovale
  - ↓ NAA/choline ratio in lentiform nucleus and parietal cortex
- DTI
  - Corticospinal tract atrophy on tractography
  - ADC
    - ↑ in motor (lateral) thalamus, precentral/postcentral gyri (ipsilateral to affected frontoparietal cortex) and bilaterally in the caudate and supplementary motor area (SMA)
  - FA
    - ↓ in precentral gyrus, SMA, postcentral gyrus, cingulum

Nuclear Medicine Findings

- PET
  - 18F-FDG decreased uptake in cortical and subcortical regions (frontal, temporal, sensorimotor, and parietal association cortices), caudate, lentiform nucleus, and thalamus
  - 18F-dopa-PET: Decreased uptake in putamen, caudate
- SPECT
  - Asymmetric hypoperfusion in frontoparietal lobes, basal ganglia (putamen), thalamus, and cerebellar hemispheres
  - Site of hypoperfusion is contralateral to side more severely affected clinically
  - DaT (dopamine transporters) SPECT: ↓ presynaptic dopamine transporter binding in striatum
  - Dopamine D2 receptor SPECT: Limited value, normal or slightly reduced D2 receptor binding

DIFFERENTIAL DIAGNOSIS

Progressive Supranuclear Palsy

- Prominent atrophy of midbrain ± pons ("penguin silhouette" sign)
- Postural instability, vertical gaze palsy
- Most common Parkinson-plus syndrome
- No subcortical hyperintense regions

Frontotemporal Lobar Degeneration

- Abnormalities of behavior and personality
- Bilateral frontal, anterior temporal lobar atrophy
- No subcortical hyperintense regions

Alzheimer Disease

- Parietotemporal lobar atrophy (entorhinal cortex, hippocampus)
- Major dysfunction in memory and cognition
- No subcortical hyperintense regions
- Amyloid PET: Uptake of radiotracer Pittsburgh compound-B (PiB) in temporoparietal cortex

Dementia With Lewy Bodies

- Mild diffuse brain atrophy
- No subcortical hyperintense regions
- PET: Hypometabolism in occipital cortex

Amyotrophic Lateral Sclerosis (ALS)

- No significant brain atrophy
- Abnormal high signal intensity of corticospinal tracts on T2WI/FLAIR

PATHOLOGY

General Features

- Etiology
  - Accumulation of hyperphosphorylated tau
  - Abnormal filamentous inclusions in neurons, glia
- Genetics
  - Tau gene is located on chromosome 17 (13 exons)

https://CafePezeshki.IR

Clinical Phenotypes Associated With Corticobasal Degeneration

Syndrome	Features
Probable corticobasal syndrome	Asymmetric presentation of 2 of the following: (a) limb rigidity or akinesia, (b) limb dystonia, &/or (c) limb myoclonus, plus 2 of the following: (d) orobuccal or limb apraxia, (e) cortical sensory deficit, &/or (f) alien limb phenomena (more than simple levitation)
Possible corticobasal syndrome	May be asymmetric with 1 of the following: (a) limb rigidity or akinesia, (b) limb dystonia, or (c) limb myoclonus, plus 1 of the following: (d) orobuccal or limb apraxia, (e) cortical sensory deficit, or (f) alien limb phenomena (more than simple levitation)
Frontal behavioral-spatial syndrome (FBS)	2 of the following: Executive dysfunction, behavioral or personality changes, visuospatial deficits
Nonfluent/agrammatic variant of primary progressive aphasia (naPPA)	Effortful, agrammatic speech plus at least 1 of the following: Impaired grammar/sentence comprehension with relatively preserved single-word comprehension, groping &/or distorted speech production (apraxia of speech)
Progressive supranuclear palsy syndrome (PSPS)	3 of the following: Axial or symmetric limb rigidity or akinesia, postural instability or falls, urinary incontinence, behavioral changes, supranuclear vertical gaze palsy, or decreased velocity of vertical saccades

Armstrong MJ, Litvan I, Lang AE, et al. Criteria for the diagnosis of corticobasal degeneration. Neurology 2013;80:496–503.

- Selective aggregation of 4R tau occurs in BG, cerebral cortex
- Tau haplotype H1 associated with both CBD, progressive supranuclear palsy
  - Suggests tau abnormality on chromosome 17 causes both diseases

Gross Pathologic & Surgical Features

- Severe focal cortical atrophy
  - Perirolandic (posterior frontal, parietal cortex)
  - Relative sparing of temporal and occipital regions
- Striatonigral degeneration: Atrophy and discoloration of substantia nigra

Microscopic Features

- Core features
  - Focal cortical neuronal loss, substantia nigra neuronal loss
  - Tau-positive neuronal, glial lesions
    - Astrocytic plaques and threads
    - In cortex, corpus striatum
- Supportive features
  - Cortical atrophy, commonly with superficial spongiosis
  - Ballooned neurons, typically mainly in atrophic cortices
  - Tau-positive oligodendroglial coiled bodies

CLINICAL ISSUES

Presentation

- Most common signs/symptoms
  - Unilateral or asymmetrical parkinsonism (typically in arm), dystonia, tremor
  - Ideomotor apraxia, "alien limb" phenomenon, cognitive decline
- Other signs/symptoms
  - Depression, apathy

Demographics

- Age
  - Typically 50-70 years old
    - Mean age = 63 years
- Gender
  - No gender preference
- Epidemiology
  - True prevalence unknown (but likely ~ 5-7 per 100,000)
  - ~ 5% of cases of parkinsonism

Natural History & Prognosis

- Mean survival of 8 years after diagnosis
- Most common initial presentations: "Useless arm" (55%), gait disorder (27%) are common
- Subsequent development of unilateral limb rigidity or dystonia, bradykinesia, dementia

Treatment

- No curative treatment is available
- Motor symptoms: Levodopa and other dopaminergic drugs may help; botulinum toxin injections for dystonic clenched fist

DIAGNOSTIC CHECKLIST

Consider

- Consider CBD in case of asymmetric parkinsonism and cortical dysfunction

Image Interpretation Pearls

- Asymmetry atrophy of brain cortex and cerebral peduncle can be helpful MR findings

SELECTED REFERENCES

1. Booth TC et al: The role of functional dopamine-transporter SPECT imaging in parkinsonian syndromes, part 2. AJNR Am J Neuroradiol. 36(2):236-44, 2015
2. Josephs KA: Key emerging issues in progressive supranuclear palsy and corticobasal degeneration. J Neurol. 262(3):783-8, 2015
3. Shimohata T et al: [Criteria for the diagnosis of corticobasal degeneration.] Brain Nerve. 67(4):513-23, 2015
4. Grijalvo-Perez AM et al: Corticobasal degeneration. Semin Neurol. 34(2):160-73, 2014

https://CafePezeshki.IR

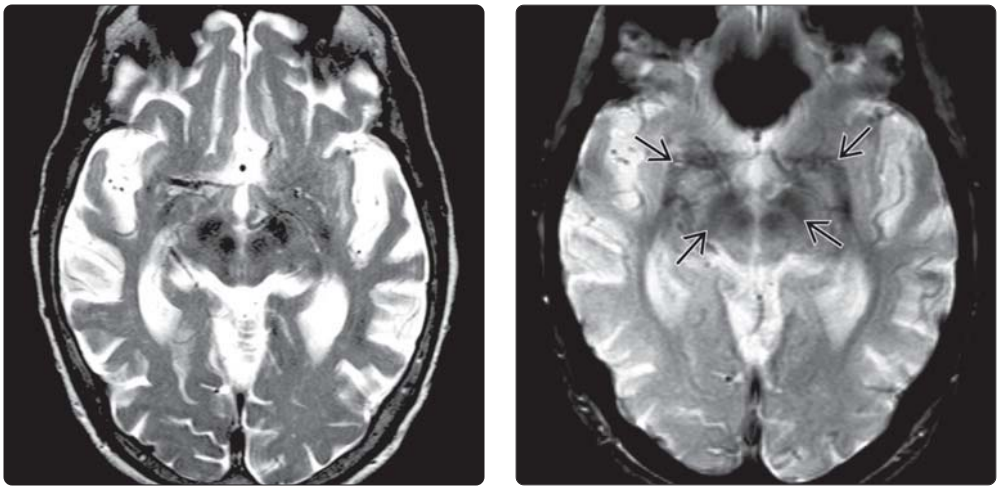

(Left) *Axial T2WI MR in a patient with corticobasal degeneration shows disproportionate enlargement of the basal cisterns and frontotemporal sulci. The red nucleus and substantia nigra are unusually hypointense. The pattern of volume loss is not typical.* **(Right)** *Axial T2* GRE MR in the same patient shows "blooming" in the heavily mineralized red nucleus, substantia nigra, and inferior basal ganglia ⇨.*

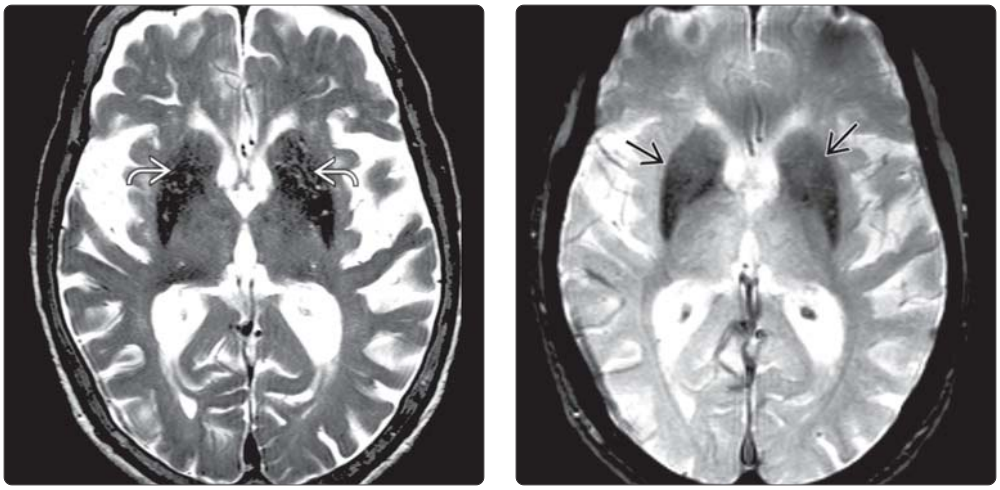

(Left) *Axial T2WI MR in the same patient shows prominent frontotemporoparietal atrophy. Both the putamen and the globus pallidi show prominent hypointense signal abnormality ⇨.* **(Right)** *Axial T2* GRE MR in the same patient shows extensive mineralization of the putamen and globi pallidi ⇨. This patient had progressive memory loss, limb dystonia, myoclonus, and the clinical diagnosis of corticobasal degeneration.*

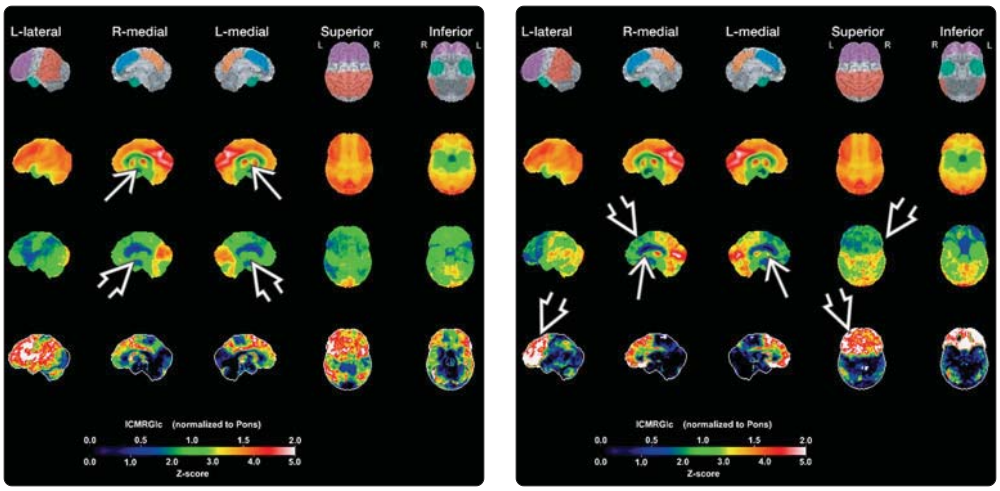

(Left) *SSP PET scan in a patient with severe CBD is illustrated. The 2nd row shows glucose metabolism in normal age-matched controls. Note the normal basal ganglia ⇨. The 3rd row illustrates diffuse, severely diminished cortical metabolism, as well as markedly decreased glucose utilization, in the basal ganglia ⇨ compared to the normal control.* **(Right)** *SSP PET shows less severely diminished glucose metabolism in the basal ganglia ⇨ and cortex ⇨. (Courtesy N. Foster, MD.)*

https://CafePezeshki.IR

KEY FACTS

TERMINOLOGY

- Neurodegenerative disease characterized by supranuclear palsy, postural instability, mild dementia

IMAGING

- Midbrain atrophy ("penguin" or "hummingbird" sign)
  - Sagittal T1WI shows concave/flat upper border of midbrain (normally convex)
  - Axial T1WIs show abnormal concavity of lateral margins of midbrain tegmentum ("morning glory" or "Mickey Mouse" sign)
  - Thinning of superior colliculus
- Midsagittal 3D-MPRAGE or FSPGR images
  - Voxel-based morphometry used to calculate ratio of midbrain to pons area
  - Midbrain area < 70 mm² (50% of normal)
  - Midbrain to pons ratio < 0.15 strongly suggests PSP
  - MR Parkinsonism index: Allows discrimination of PSP from MSA-P, PD, and control

TOP DIFFERENTIAL DIAGNOSES

- Multiple system atrophy, Parkinsonian type
- Corticobasal degeneration
- Dementia with Lewy bodies
- Parkinson disease

PATHOLOGY

- Neurofibrillary tangles and neuropil threads in globus pallidus, subthalamic nucleus, substantia nigra; cerebral cortex relatively preserved except for perirolandic cortex
- Neuronal loss, gliosis

CLINICAL ISSUES

- PSP-RS (Richardson syndrome)
- Lurching gait, axial dystonia, vertical supranuclear palsy
- PSP-P (Parkinsonian type)
- Bradykinesia, rigidity, normal eye movements
- 2nd most common neurodegenerative cause of Parkinsonism overall

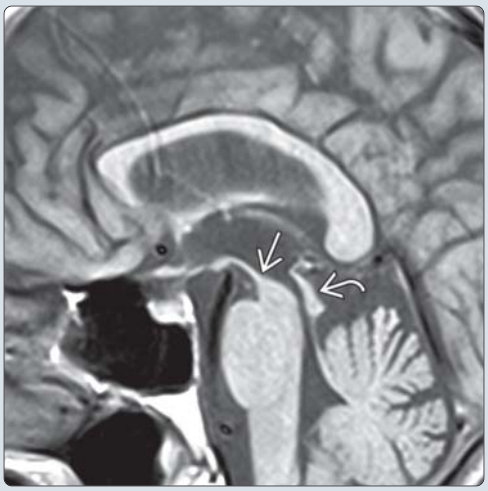

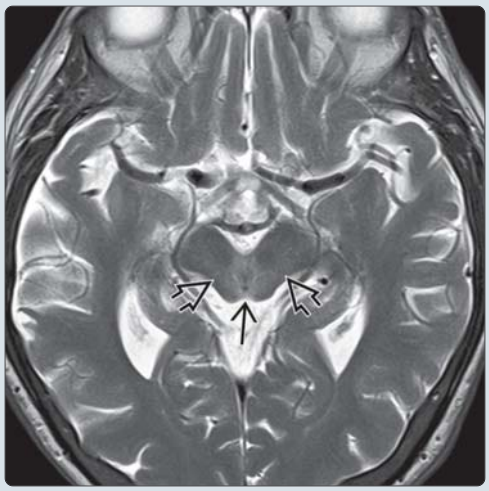

(Left) *Sagittal T1WI MR in a patient with bradykinesia and suspected Parkinson disease shows the classic "penguin" or "hummingbird" sign of progressive supranuclear palsy (PSP). Note thinning of the midbrain ⇨ with atrophy of the tectum ⇨, also consistent with PSP. In contrast to the strikingly abnormal midbrain findings, here the pons appears normal.* **(Right)** *Axial T2WI MR in the same patient shows volume loss of the midbrain with thinned tectum ⇨ and concave lateral midbrain margins ⇨.*

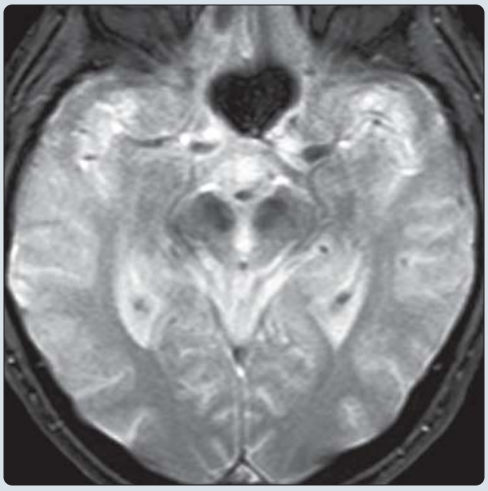

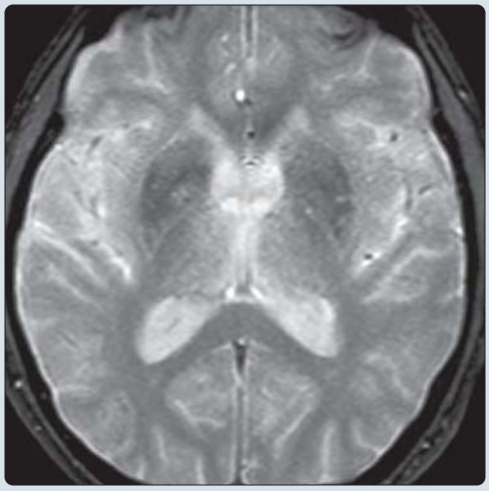

(Left) *Axial T2* GRE MR in the same patient shows no evidence for abnormal iron accumulation in the midbrain, which helps to distinguish PSP from Parkinson disease.* **(Right)** *Axial T2* GRE MR shows no evidence for abnormal iron accumulation in the striatum, another location in which iron is commonly found in Parkinson disease.*

https://CafePezeshki.IR

TERMINOLOGY

Abbreviations

- Progressive supranuclear palsy (PSP)

Synonyms

- Steele-Richardson-Olszewski syndrome

Definitions

- Neurodegenerative disease characterized by supranuclear palsy, Parkinsonism, postural instability, pseudobulbar syndrome, & dementia

IMAGING

General Features

- Best diagnostic clue
  - Midbrain tegmentum atrophy ("penguin" or "hummingbird" sign)
  - Most accurate: Calculation of midbrain area/pons area ratio
    - Distinguishes PSP from other conditions
      - PSP vs. Parkinsonian form of multisystem atrophy (MSA-P)
- Location
  - Midbrain
    - Tegmentum
    - Tectum (superior colliculus)
- Morphology
  - Prominent midbrain volume loss
    - Pons normal

Imaging Recommendations

- Best imaging tool
  - MR
  - PET
- Protocol advice
  - Midsagittal T1WI
  - 3D MP-RAGE or FSPGR images
    - Use voxel-based morphometry to calculate ratio of midbrain to pons area

CT Findings

- NECT
  - Atrophy of midbrain with prominent mesencephalic cisterns and enlarged 3rd ventricle

MR Findings

- T1WI
  - Sagittal T1WI helpful in detecting midbrain tectal atrophy ("penguin" or "hummingbird" sign)
    - Concave or flat profile of cephalad surface of midbrain (as opposed to normal convex superior profile)
    - Thinning of superior colliculus
  - Axial T1WIs show abnormal concavity of lateral margins of midbrain tegmentum ("morning glory" or "Mickey Mouse" sign)
  - Atrophic superior cerebellar peduncles
  - Midbrain area approximately 1/2 that of normal individuals
  - Ratio of area of midbrain to area of pons in PSP (0.124) was significantly smaller than in Parkinson Disease (PD) (0.208), MSA-P (0.266), and normal control (0.237)
  - Sagittal midbrain area < 70 mm², ratio of midbrain tegmentum to pons area < 0.15 → diagnostic of PSP
    - Sensitivity: 100%; specificity: 91-100%
  - MR Parkinsonism index = (pons area/midbrain area x middle cerebellar peduncle width/superior cerebellar peduncle width)
    - Allows discrimination of patients with PSP from MSA-P, PD, and control with 100% sensitivity, 100 % specificity, and 100% PPV
  - AP midbrain diameter < 17 mm
- T2WI
  - Decreased AP diameter of midbrain on axial T2WI < 17 mm, 75% positive predictive value in differentiating PSP from MSA
  - Hyperintense signal in midbrain tegmentum = periaqueductal
  - Prominent mesencephalic cisterns and enlarged 3rd ventricle
  - Occasionally abnormal hypointense signal in striatum
- DWI
  - ↑ ADC in putamen might discriminate PSP from PD
  - ↑ ADC in decussation of superior cerebellar peduncles
- DTI
  - ↑ mean diffusivity in decussation of superior cerebellar peduncle
  - DTI indices (fractional anisotropy, mean diffusivity) demonstrate widespread white matter abnormalities
  - ↑ mean diffusivity in midbrain of PSP patients compared with PD & MSA

Nuclear Medicine Findings

- PET
  - 18 F-FDG ↓ in putamen, thalamus, medial frontal cortex, & midbrain
  - 11C-raclopride PET ↓ striatal dopamine receptor binding
  - Fluorodopa-PET: Reduction of F-dopa uptake in caudate, putamen (more severe than in PD)
- SPECT
  - I-123-IBZM SPECT: Reduced dopamine receptor binding in striatum

DIFFERENTIAL DIAGNOSIS

Multiple System Atrophy, Parkinsonian Type (MSA-P)

- T2 hypointensity in putamen without prominent midbrain atrophy
- Cerebellar and pontine atrophy
- Prominent cerebellar symptoms, autonomic dysfunction, parkinsonism

Corticobasal Degeneration

- Severe frontoparietal atrophy in asymmetrical pattern
- Unilateral parkinsonism
- "Alien limb" phenomenon, cortical sensory deficit

Dementia With Lewy Bodies

- Cortical atrophy without prominent midbrain atrophy
- Hallucinations, cortical dementia with aphasia, Parkinsonism

Parkinson Disease

- No prominent midbrain atrophy

https://CafePezeshki.IR

- Tremor-dominant clinical symptoms, good response to levodopa

PATHOLOGY

General Features

- Etiology
  - PSP is a tauopathy
  - Abnormal accumulation of phosphorylated tau protein in brain
    - Pallidum, subthalamic nucleus, red nucleus, substantia nigra, pontine tegmentum, striatum, oculomotor nucleus, medulla, dentate nucleus
- Genetics
  - Associated with tau, *MTAP* gene on chromosome 17
- Tau haplotype H1 associated with both PSP and corticobasal degeneration
  - Suggests that gene on chromosome 17 for tau abnormality causes both diseases

Gross Pathologic & Surgical Features

- Atrophy of subthalamic nucleus and brainstem (midbrain tectum and superior cerebellar peduncle)
- Loss of pigmentation in substantia nigra → nigrostriatal dopaminergic degeneration

Microscopic Features

- Neuronal loss, astrocytic gliosis
- Neurofibrillary tangles and neuropil threads in globus pallidus, subthalamic nucleus, substantia nigra; cerebral cortex relatively preserved except for perirolandic cortex
- Tau pathology is also noted in glia: Tufted astrocytes, coiled bodies of oligodendrocyte

CLINICAL ISSUES

Presentation

- Most common signs/symptoms
  - 2 PSP phenotypes
  - PSP-RS (Richardson syndrome)
    - Classic, more common presentation of lurching gait, axial dystonia, vertical supranuclear palsy
  - PSP-P (Parkinsonian type) 1/3 patients
    - Bradykinesia, rigidity, normal eye movements, & transient response to levodopa
  - Personality change, memory problems, sleep disturbance, apathy
- Most common cause of atypical parkinsonian syndrome
  - 2nd most common neurodegenerative cause of parkinsonism overall
- Clinical criteria for "probable" PSP
  - Gradually progressive bradykinetic disorder
  - Onset at age 40 or later
  - No evidence for competing diagnostic possibilities
  - Vertical gaze palsy
  - Slowing of vertical saccades and prominent postural instability with falls in 1st year
  - Exclusion criteria
    - Recent encephalitis, alien limb syndrome, cortical sensory defects or temporoparietal atrophy, psychosis unrelated to dopaminergic treatment, important cerebellar signs, severe, asymmetric parkinsonian signs, relevant structural abnormality of basal ganglia on neuroimaging

Demographics

- Age
  - Generally 45-75 years
  - Peak onset: 63 years
- Gender
  - Slight male predominance
- Epidemiology
  - 5-6 cases per 100,000

Natural History & Prognosis

- Disease course variable
- Survival from time of symptom onset in PSP ranges from 5.3 to 9.7 years
- Neuropsychiatric symptoms develop > 50 % patients within 2 years of disease onset

Treatment

- Symptomatic
- Levodopa may help the rigidity and bradykinesia of PSP
- Mitochondrial nutrient coenzyme Q10 can give modest benefit

Variant PSP Syndrome

- PSP-parkinsonism
- PSP-pure akinesia with gait freezing
- PSP-corticobasal syndrome
- PSP-progressive nonfluent aphasia

DIAGNOSTIC CHECKLIST

Consider

- Consider PSP when MR shows marked midbrain atrophy in patients with atypical parkinsonism, vertical gaze palsy, and cognitive dysfunction

Image Interpretation Pearls

- Sagittal images helpful in identifying "penguin silhouette" sign
- Minimal or no lobar atrophy

SELECTED REFERENCES

1. Booth TC et al: The role of functional dopamine-transporter SPECT imaging in parkinsonian syndromes, part 1. AJNR Am J Neuroradiol. 36(2):229-35, 2015
2. Booth TC et al: The role of functional dopamine-transporter SPECT imaging in parkinsonian syndromes, part 2. AJNR Am J Neuroradiol. 36(2):236-44, 2015
3. Josephs KA: Key emerging issues in progressive supranuclear palsy and corticobasal degeneration. J Neurol. 262(3):783-8, 2015
4. Broski SM et al: Structural and functional imaging in parkinsonian syndromes. Radiographics. 34(5):1273-92, 2014
5. Colosimo C et al: Fifty years of progressive supranuclear palsy. J Neurol Neurosurg Psychiatry. 85(8):938-44, 2014
6. Golbe LI: Progressive supranuclear palsy. Semin Neurol. 34(2):151-9, 2014
7. Stamelou M et al: Atypical parkinsonism: an update. Curr Opin Neurol. 26(4):401-5, 2013
8. Williams DR et al: Parkinsonian syndromes. Continuum (Minneap Minn). 19(5 Movement Disorders):1189-212, 2013

https://CafePezeshki.IR

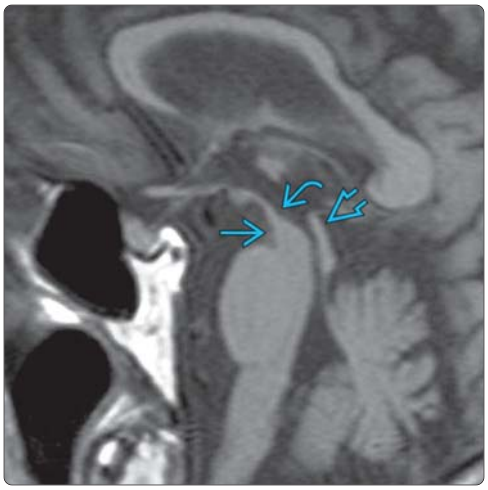

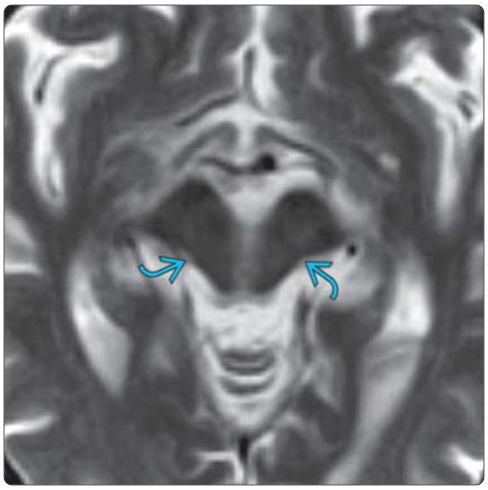

(Left) *Sagittal T1WI MR in a patient with progressive supranuclear palsy shows markedly atrophy of the midbrain relative to pons. There is upper concavity of the midbrain tegmentum with a "penguin" or "hummingbird" sign and thinning of superior tectum.* **(Right)** *Axial T2 MR in the same patient shows abnormal concavity of the lateral margin of midbrain tegmentum referred to as the " morning glory" or "Mickey Mouse" sign.*

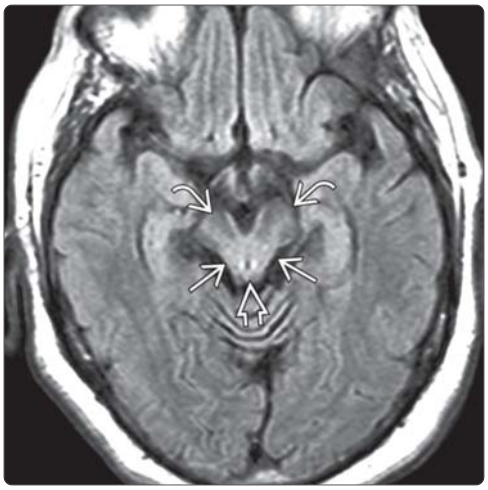

(Left) *Sagittal T1WI MR (3D MP-RAGE) in an 80-year-old woman with PSP shows striking midbrain volume loss, with the "penguin" or "hummingbird" sign manifested by a concave upper border of the midbrain. Note extreme thinning of the tectal plate. An incidental subependymoma was found.* **(Right)** *Axial FLAIR MR in the same patient shows the tectal plate is extremely thin, the lateral aspects of the midbrain are concave ("morning glory" sign), and the cerebral peduncles are atrophic.*

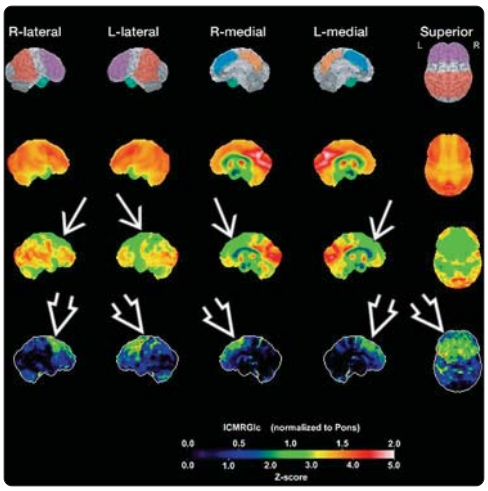

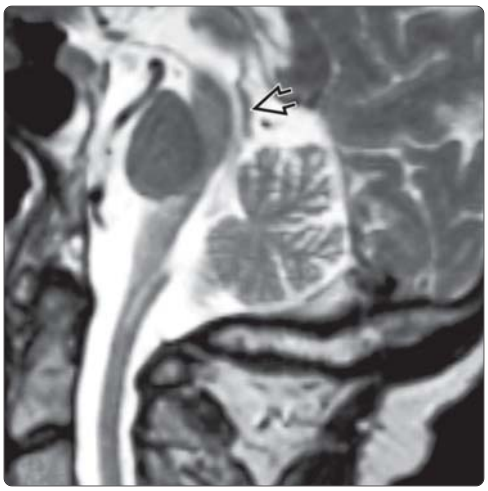

(Left) *PET scan with stereotaxic surface projections in the same patient: The top row is the reference map. The 2nd row illustrates glucose metabolism in elderly normal controls (n = 27). The 3rd row is the patient's glucose metabolism map. The 4th row is the Z-score map. The glucose metabolism and Z-score maps show markedly reduced metabolism in both frontal lobes. (Courtesy N. Foster, MD.)* **(Right)** *Sagittal T2WI MR in a patient with PSP shows diminished midbrain volume and thinned tectum.*

https://CafePezeshki.IR

KEY FACTS

TERMINOLOGY

- Amyotrophic lateral sclerosis (ALS)
- Selective degeneration of somatic motor neurons of brainstem/spinal cord and large pyramidal neurons of motor cortex
  - Eventual loss of corticospinal tract (CST) fibers

IMAGING

- Small percentage demonstrate CST hyperintensity
- As CST is normally slightly hyperintense especially at 3.0 T, this finding lacks sensitivity & specificity
- T2 hyperintense CST may be specific for ALS when seen on corresponding PD images
- Consider FLAIR and PD in suspected ALS
- DWI hyperintensity (↓ diffusivity) in CST
- Hypointense GM in precentral gyrus (motor cortex)

TOP DIFFERENTIAL DIAGNOSES

- Primary lateral sclerosis
- Wallerian degeneration
- Hypertrophic olivary degeneration
- Metabolic diseases involving bilateral CSTs
- Demyelinating and inflammatory diseases
- Neoplasms: Brainstem glioma, malignant lymphoma
- CST can appear hyperintense on 3T MR normally

PATHOLOGY

- Majority of ALS cases are sporadic (sALS)
- 15-20% are familial (fALS)

CLINICAL ISSUES

- UMN signs: Babinski sign, spasticity, hyperreflexia
- LMN signs: Asymmetric muscle weakness, atrophy, fasciculations, hyporeflexia
- Bulbar signs: Slurred speech, dysphagia
- Onset usually between 4th-7th decades of life
- Complete disability and death within a decade

(Left) *Axial FLAIR MR shows increased signal in the precentral gyri in this ALS patient. There is also atrophy of bilateral motor cortices.* **(Right)** *Coronal FLAIR MR shows linear hyperintensity along the corticospinal tract (CST) from the precentral gyrus to the cerebri crus. Right CST signal abnormality is out of this imaging slice. Hyperintensity of the precentral gyrus subcortical white matter on FLAIR is a potentially useful and specific sign of ALS that is not seen in healthy, asymptomatic patients.*

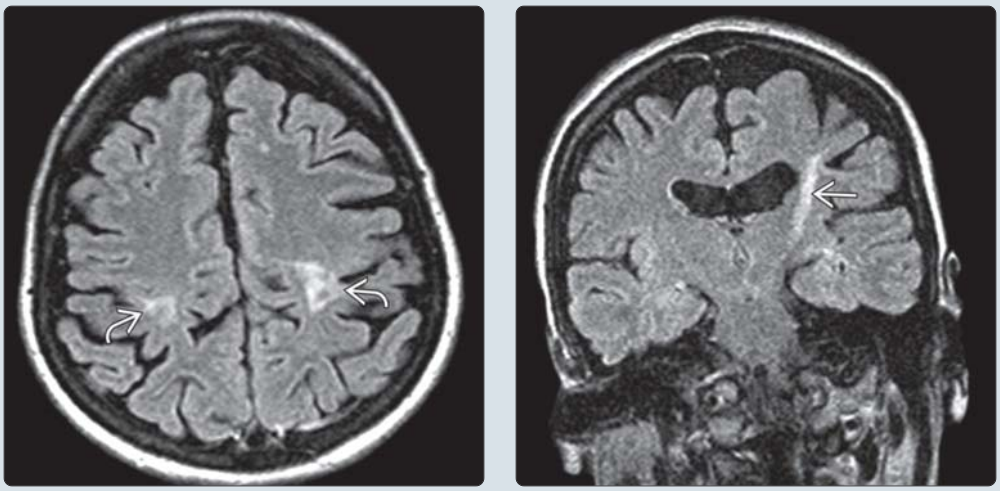

(Left) *Axial T2WI FS MR demonstrates ovoid hyperintensity along the CSTs bilaterally. The atrophy and hyperintensity are due to myelin loss and gliosis. There is frequently involvement of the prefrontal motor neurons, which play a role in planning or orchestrating the work of the upper and lower motor neurons.* **(Right)** *Axial T2 MR in a patient with ALS shows hyperintensity along the course of the corticospinal tracts (CST) bilaterally. Important to note that CST is typically slightly hyperintense on T2 especially at 3.0 T.*

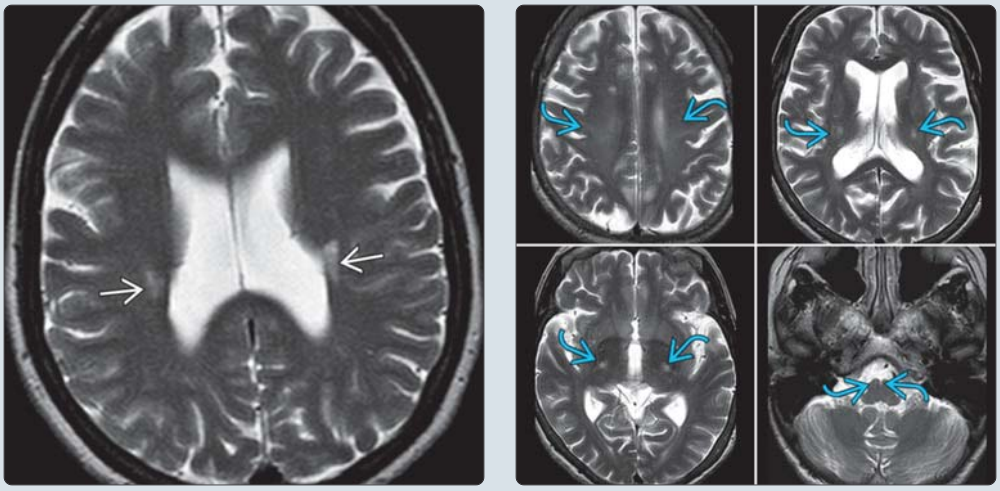

https://CafePezeshki.IR

TERMINOLOGY

Abbreviations

- Amyotrophic lateral sclerosis (ALS)

Synonyms

- Lou Gehrig disease, motor neuron disease (MND)

Definitions

- Selective degeneration of somatic motor neurons of brainstem/spinal cord (lower motor neurons [LMN]) and large pyramidal neurons of motor cortex (upper motor neurons [UMN])
  - Eventual loss of corticospinal tract (CST) fibers

IMAGING

General Features

- Best diagnostic clue
  - Bilateral hyperintensities along CST extending from corona radiata to brainstem on T2WI/PD/FLAIR
- Location
  - Hallmark is CST and LMN degeneration
    - LMN in anterior horn of spinal cord and brainstem
    - Corticospinal UMN in precentral gyrus (motor cortex)
  - White matter (WM) and gray matter (GM)
- Size
  - Atrophy of motor system, particularly pyramidal tract, in advanced stages of ALS
- Morphology
  - Oval or thin curvilinear hyperintensities conforming to CST

CT Findings

- NECT
  - Serial CT exams may show progressive atrophy
    - Frontal, anterior temporal lobes → precentral gyrus → postcentral gyrus, anterior cingulate gyrus, corpus callosum, tegmentum

MR Findings

- T1WI
  - Different T1 appearances of CST
    - Isointensity (most common) may reflect ↑ content of free radicals
    - Hypointense or mild hyperintense signal
- T2WI
  - Small percentage demonstrate CST hyperintensity
  - Hyperintensity can occur anywhere from subcortical white matter of precentral gyrus to posterior limb internal capsules, cerebral peduncles, & pons
  - As CST is normally slightly hyperintense especially at 3.0 T, this finding lacks sensitivity & specificity
  - T2 hyperintense CST may be specific for ALS when seen on corresponding PD images
  - Hypointense GM in precentral gyrus (motor cortex)
    - Nonspecific; may be due to iron and heavy metals accumulation in cortex of aged patients
- PD/intermediate
  - Hyperintense CST
- FLAIR
  - More sensitive and less specific than T2 FSE for detecting hypointensity in precentral gyrus
  - Hyperintense CST
- DWI
  - Hyperintensity in CST
    - May be seen in the absence of T2 hyperintensity
- Diffusion tensor imaging (DTI)
  - ROI-based approaches & tractography demonstrates significant changes in diffusion parameters along CST
  - Most common finding: ↓ fractional anisotropy (FA) in CST due to neuronal degeneration of UMN
  - FA ↓ demonstrated at all levels of CST; most significant reduction in posterior limb internal capsule
  - FA correlates with UMN involvement, disease severity
  - ↑ mean diffusivity (MD) along CST
  - MD more constant over different levels of CST; tends to be elevated at cranial level of CST
    - MD positively correlates with disease duration
- ^{1}H-MRS useful for assessing UMN involvement
  - ↓ NAA, ↓ NAA/Cr, ↓ NAA/Cho, & ↓ NAA/(Cr + Cho) in motor cortex
  - NAA present primarily in neurons; these metabolic changes reflect loss or dysfunction of motor neurons
  - ↓ NAA/Cr & NAA/Cho ratio along CST; most pronounced in precentral gyrus & corona radiata
  - ↓ NAA in pons & upper medulla in patients with prominent UMN or bulbar signs
  - ↑ Cho in posterior limb internal capsule
  - ↑ myo-inositol in motor cortex
- Magnetization-transfer ratio (MTR) measurements
  - ↓ MTR in posterior limb of IC in ALS
  - CST hyperintensity on T1 MT contrast-enhanced images: 80% sensitivity, 100% specificity
  - May detect CST degeneration of ALS at early stage
- Voxel-based morphometry (VBM)
  - Regional gray matter loss in motor cortex, frontal, temporal, parietal & limbic regions
  - Frontal severe atrophy in ALS & frontotemporal dementia
  - WM loss in corpus callosum, cerebellum, frontotemporal & occipital regions
  - Global brain atrophy relatively mild
- Functional MR
  - Pattern of cortical reorganization
  - ↑ activation of contralateral sensorimotor cortex, supplementary motor area, basal ganglia, & cerebellum during motor tasks

Nuclear Medicine Findings

- PET, Tc-99m-HMPAO SPECT
  - ↓ regional cerebral metabolism or perfusion throughout brain
  - ↑ ALS severity correlated with ↓ gray matter perfusion

Imaging Recommendations

- Best imaging tool: MR with T2, PD, FLAIR, DTI

DIFFERENTIAL DIAGNOSIS

Primary Lateral Sclerosis

- Neurodegeneration restricted to UMN
  - T2WI shows changes in motor pathways

https://CafePezeshki.IR

- Autosomal recessive disease with juvenile onset

Wallerian Degeneration

- Dynamic signal intensities change along CST in patients with various cortical/subcortical lesions

Hypertrophic Olivary Degeneration

- Secondary degeneration of inferior olivary nucleus (ION), usually caused by primary lesions in dento-rubro-olivary pathway

Conditions With T2 Hyperintense Lesions Along CST

- Metabolic diseases may involve CST bilaterally
  - X-linked adrenoleukodystrophy, Wilson disease
  - Hypoglycemic coma: Reversible CST changes
- Demyelinating and inflammatory diseases
  - Multiple sclerosis, ADEM, Behçet disease, AIDS, cervical myelopathy
- Neoplasms: Brainstem glioma, malignant lymphoma

Normal Individuals

- CST can appear hyperintense on 3T MR (normal fully myelinated brain at any age) and mimic ALS

PATHOLOGY

General Features

- Etiology
  - Etiology of sporadic ALS (sALS) is largely unknown
  - Pathological hallmarks include loss of MNs with intraneuronal ubiquitin-immunoreactive inclusions in UMN and TDP-43 immunoreactive inclusions in degenerating LMN
  - Increased expression of cyclooxygenase-2 in spinal cord, frontal cortex, and hippocampus
  - Apoptosis, free radical-mediated oxidative stress, excessive glutamate-mediated excitotoxicity
  - Biochemical studies have shown ↓ glutamate levels in CNS tissue and ↑ levels in CSF
- Genetics
  - Majority of ALS cases are sporadic (sALS)
  - 15-20% of ALS cases are familial (fALS)
    - 10-20% of fALS cases are caused by mutations in copper/zinc superoxide dismutase 1 gene (*SOD1*) on chromosome 21q
  - Rare autosomal recessive juvenile-onset ALS
    - *ALS2* gene on chromosome 2q encodes alsin
- Associated abnormalities
  - ALS-plus syndrome: Typical ALS phenotype associated with dementia, parkinsonism, or both
    - 2–3% of cases, ALS is accompanied by frontotemporal dementia
    - ~ 50% of cases show cognitive impairment
  - ALS-like motor neuron disease can occur as paraneoplastic syndrome

Gross Pathologic & Surgical Features

- Focal atrophy of motor cortex & along course of CST
- Atrophy of anterior & lateral portions of spinal cord

Microscopic Features

- Loss of cortical pyramidal motor neurons and astrocytosis
- Histologically uneven involvement of CST showing variable patterns of degeneration
- "Senescent changes" with lipofuscin pigment atrophy
- Proximal and distal axonopathy with axonal spheroids
- Surviving motor neurons are smaller and abnormal

CLINICAL ISSUES

Presentation

- Most common signs/symptoms
  - UMN signs: Babinski sign, spasticity, hyperreflexia
  - LMN signs: Asymmetric muscle weakness, atrophy, fasciculations, hyporeflexia
  - Bulbar signs: Slurred speech, dysphagia
  - Difficulty walking, unexplained weight loss
- Clinical profile
  - Classic ALS: Both UMN and LMN affected
  - UMN-dominant ALS can be difficult to distinguish from primary lateral sclerosis
  - Predominantly bulbar form usually leads to more rapid deterioration and death
  - fALS associated with *SOD1* abnormality has mean age at 42 years limb onset, slow evolution

Demographics

- Age
  - Onset usually between 4th-7th decades of life
- Gender
  - M:F = 1.5:1
- Epidemiology
  - Incidence: 1-2 cases/100,000 persons
  - Prevalence: 5.2/100,000 persons

Natural History & Prognosis

- Progressive (distal to proximal)
  - Median survival from diagnosis to death: 3-4 years
  - 10% of patients survive > 10 years
- Some patients with familial, juvenile-onset ALS survive for longer periods (2-3 decades)

Treatment

- Riluzole (glutamate release inhibitor and insulin-like growth factor) may prolong survival
  - ↑ NAA/Cr in precentral gyrus and supplementary motor area after riluzole therapy

DIAGNOSTIC CHECKLIST

Consider

- FLAIR and PD in all patients with suspected ALS

Image Interpretation Pearls

- High-signal intensity in posterior limb of IC is suggestive for ALS when also visible on PD
- T1- and PD-weighted images differentiate real degeneration from normal areas
- DTI can assess CST lesions before pyramidal symptoms

SELECTED REFERENCES

1. Barthel H et al: PET/MR in Dementia and Other Neurodegenerative Diseases. Semin Nucl Med. 45(3):224-233, 2015
2. Verstraete E et al: Neuroimaging as a new diagnostic modality in amyotrophic lateral sclerosis. Neurotherapeutics. 12(2):403-16, 2015

https://CafePezeshki.IR

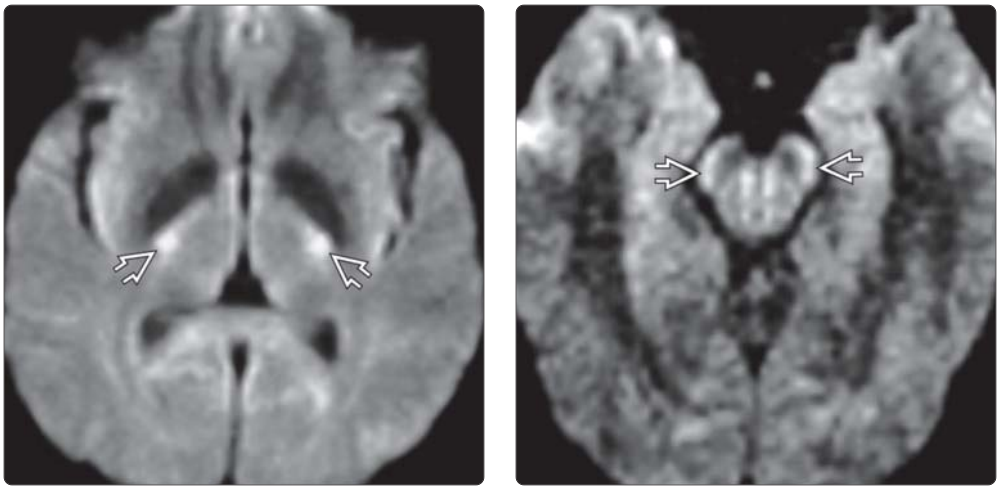

(Left) *Axial DTI trace image shows symmetric hyperintensity in the internal capsule posterior limbs ⇨. Fractional anisotropy (FA) correlates with measures of disease severity and UMN involvement, whereas the mean diffusivity correlates with disease duration.* **(Right)** *Axial DWI MR shows round hyperintensities in bilateral cerebral peduncles ⇨. Signal abnormality can be seen in the precentral gyrus, centrum semiovale, posterior 3rd of posterior limb of internal capsules, cerebral peduncles, and ventral brainstem.*

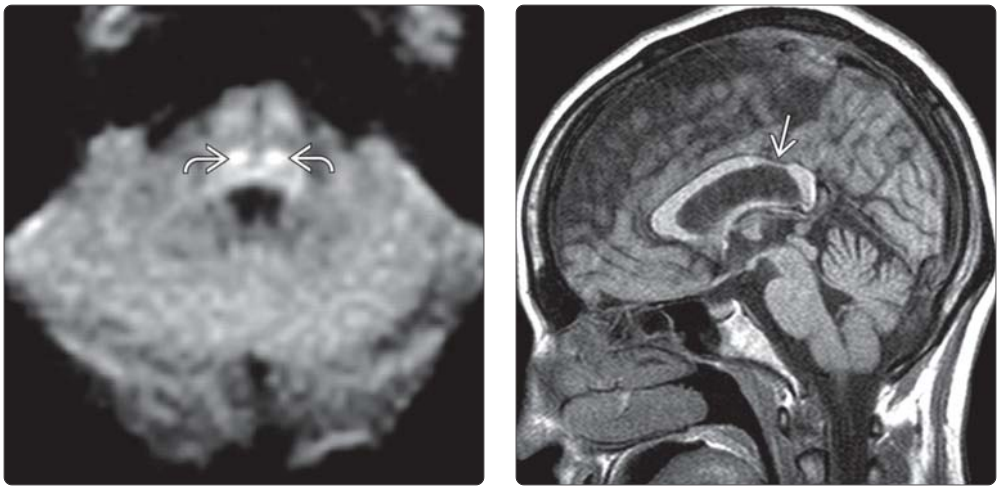

(Left) *Axial DWI MR shows oval hyperintensities corresponding to CSTs in the pons ⇨. DWI/DTI can help differentiate progressive muscular atrophy (no change in FA or MD) from ALS (↑ MD, ↓ FA), which can be clinically difficult.* **(Right)** *Sagittal T1WI MR shows atrophy of the posterior corpus callosum body ⇨. DTI showed ↓ FA in the corpus callosum. Voxel-based morphometry has a high sensitivity in detecting local tissue atrophy in the motor cortex and along the corticospinal tracts.*

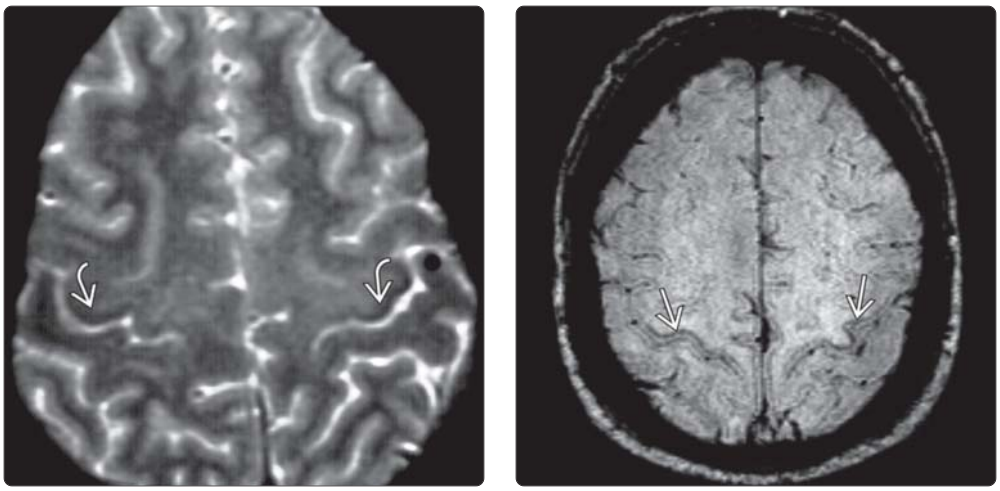

(Left) *Axial T2WI FS MR shows central cortical hypointense signal intensity ⇨ in the precentral gyri due to iron deposition. While this is common in ALS patients, it is nonspecific and may be seen in aged patients due to iron and heavy metals accumulation.* **(Right)** *Axial T2* SWI MR demonstrates curvilinear hypointensity along the cortical gray matter of bilateral precentral gyri ⇨. The T2* SWI technique accentuates the T2 hypointensity seen in the precentral gyrus gray matter of ALS patients.*

https://CafePezeshki.IR

KEY FACTS

TERMINOLOGY

- Wallerian degeneration (WaD)
- Secondary anterograde degeneration of axons and their myelin sheaths caused by interruption of the axonal integrity or damage to the neuron

IMAGING

- Primary lesion is cortical or subcortical with WaD in descending white matter (WM) tracts ipsilateral to neuronal injury
  - WaD can be seen in fibers crossing the corpus callosum, fibers of optic radiations, fornices, and cerebellar peduncles
- CT is not sensitive for WaD in acute-subacute stages
  - Detects atrophy of CSTs in chronic stage
- Time-dependent changes in CSTs on MR
  - Strong correlation between WaD detected on T2WI and DWI and long-term morbidity
  - DWI findings precede development of WaD assessed by conventional MR
- DTI may distinguish between primary lesion and associated WaD
  - Reduced fractional anisotropy (FA) with increased mean diffusivity (MD) in infarct
  - Reduced FA with preserved MD in CST

TOP DIFFERENTIAL DIAGNOSES

- Neurodegenerative diseases
- Brainstem glioma
- Demyelinating and inflammatory diseases
- Hypertrophic olivary degeneration
- Metabolic diseases
- Intoxication (heroin inhalation)
- Normal appearance of hyperintensity on high field strength MR

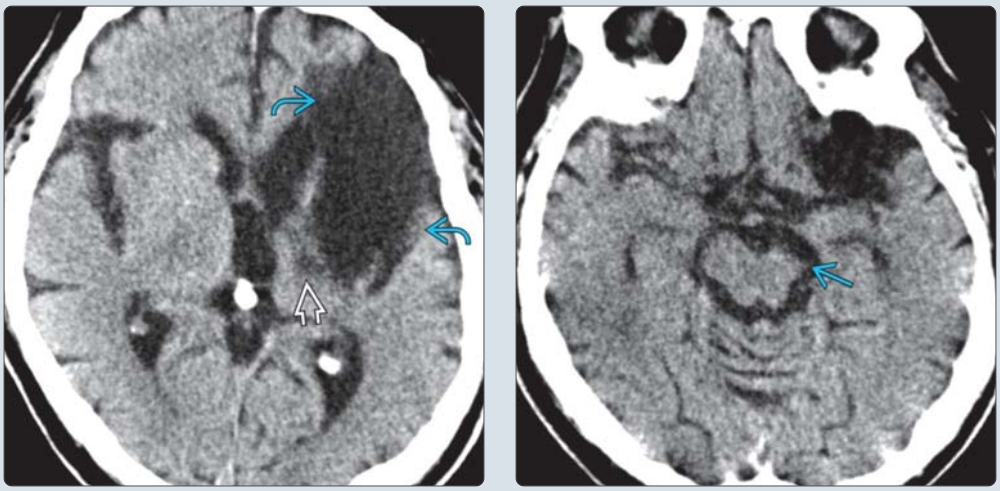

(Left) *Axial NECT shows encephalomalacia in the left frontal and temporal opercula related to a chronic stroke. Hypodensity and volume loss in the thalamus is likely due to wallerian degeneration of the corticothalamic fibers.* **(Right)** *Axial NECT in the same patient shows atrophy of the left cerebral peduncle due to chronic wallerian degeneration of the corticospinal tracts. NECT is not sensitive for acute-subacute stages but detects atrophy of the pyramidal tracts in the chronic stage of wallerian degeneration.*

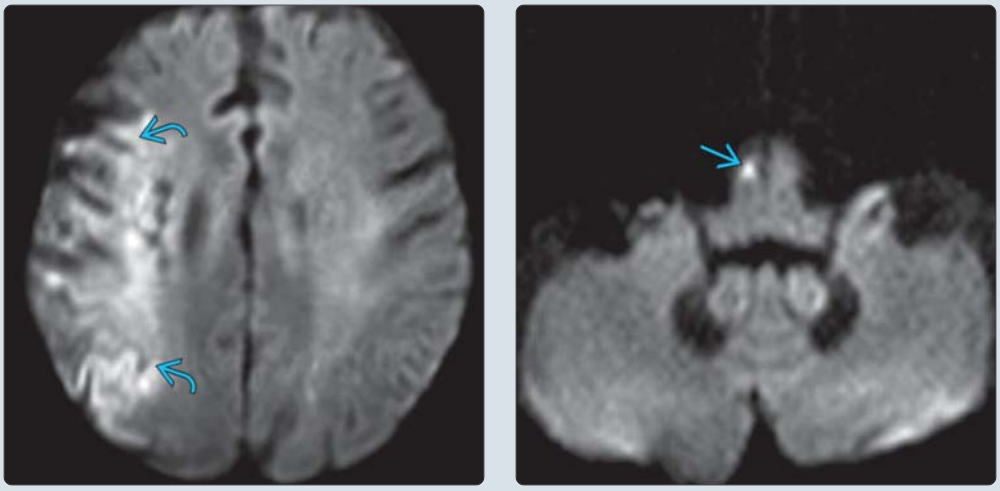

(Left) *Axial DWI image demonstrates restricted diffusion in the right frontal and parietal lobes due to an acute infarct in the right MCA distribution.* **(Right)** *Axial DWI image in the same patient demonstrates restricted diffusion in the ventral medulla in the region of the corticospinal tract due to acute wallerian degeneration. DWI is more sensitive at detecting early Wallerian degeneration when compared to standard MR sequences.*

https://CafePezeshki.IR

TERMINOLOGY

Abbreviations

- Wallerian degeneration (WaD)

Definitions

- Secondary anterograde degeneration of axons and their myelin sheaths caused by interruption of the axonal integrity or damage to the neuron

IMAGING

General Features

- Best diagnostic clue
  - Contiguous T2 hyperintensity along topographic distribution of corticospinal tract (CST) in internal capsule (IC) and brainstem in patients with various cerebral pathologies
- Location
  - Primary lesion: Cortical or subcortical
  - WaD: Descending white matter (WM) tracts ipsilateral to neuronal injury
    - CST, corticobulbar, corticopontine tracts
  - WaD can be seen in corpus callosum, optic radiations, fornices, and cerebellar peduncles
  - Corpus callosum has been shown to be susceptible to atrophy in Alzheimer disease mainly as correlate of wallerian degeneration of commissural nerve fibers of neocortex
  - Seizure-induced damage may cause secondary white matter degeneration along tapetum and through splenium of corpus callosum
- Morphology
  - Signal changes conforming to WM tract shape
    - Oval regions in posterior limb of IC and cerebral peduncle; thin curvilinear regions in pons

CT Findings

- NECT
  - Not sensitive for WaD in acute-subacute stages
  - Detects atrophy of CSTs in chronic stage
    - ↓ size of corresponding aspect of brainstem

MR Findings

- T1WI
  - Time-dependent changes in descending WM tracts
    - Stage 1: No changes
    - Stage 2: T1 hyperintense
    - Stage 3: T1 hypointense
    - Stage 4: Ipsilateral brainstem atrophy ± hypointensity
- T2WI
  - Time-dependent changes in descending WM tracts
    - Stage 1: No changes in adult CNS
    - Stage 2: T2 hypointense
    - Stage 3: T2 hyperintense
    - Stage 4: Atrophy, best seen in brainstem
      - Sometimes, T2 hyperintense signal may persist
  - Neonates and infants: Identification of WaD by T2WI complicated by high water content and lack of myelination in immature WM
  - Adults: Strong correlation between T2WI detected WaD and long-term morbidity
- FLAIR
  - Same as T2WI
- DWI
  - Neonates and infants: Indicates acute WM injury
    - DWI findings precede development of WaD assessed by conventional MR
    - May portend poor clinical outcome
  - Adults: Correlation of DW changes in descending motor pathways at presentation with long-term neurologic disability
  - Extent and severity of territorial ischemia is related to development of descending WM tract injury detectable by DWI
  - Hyperintense DW signal intensity and ↓ ADC values within territorial infarct and ipsilateral CST
    - DW and ADC time courses in region of territorial injury and CST injury may be different
      - Relatively delayed development of diffusion abnormality in descending WM tracts
  - DW signal intensity abnormality in descending WM tracts may persist, even as DW hyperintensity in ipsilateral cerebral hemisphere fades
- T1WI C+
  - No contrast enhancement of degenerated tracts
- MRS
  - ^{1}H-MRS enables in vivo assessment of axonal injury based on signal intensity of N-acetyl aspartate (NAA)
  - ↓ NAA concentration in normal-appearing WM in pons and cerebellar peduncles in early stages of relapsing-remitting multiple sclerosis (MS)
    - Correlates best with disability, MS duration, and relapse rate
- Diffusion tensor imaging (DTI)
  - Myelin breakdown leads to ↓ diffusion anisotropy
  - Reduced FA with increased mean diffusivity (MD) in infarct
  - Reduced FA with preserved MD in CST
  - In patients with motor pathway infarction, diffusion indices in degenerated CST stabilize within 3 months and early changes in CST FA may predict long-term clinical outcomes

Imaging Recommendations

- Best imaging tool
  - MR
- Protocol advice
  - DWI allows early detection (stage 1)
  - T2WI detects changes after 4 weeks

DIFFERENTIAL DIAGNOSIS

Neurodegenerative Diseases

- Amyotrophic lateral sclerosis (upper &/or lower motor neuron involvement)
  - Bilateral hyperintensities along CST extending from corona radiata to brainstem on T2WI/PD/FLAIR
- Primary lateral sclerosis and infantile-onset hereditary spastic paraplegia
  - Upper motor neuron degeneration only

Brainstem Glioma

- T2 hyperintense mass ± enhancement

https://CafePezeshki.IR

Demyelinating and Inflammatory Diseases

- Multiple sclerosis: Periventricular T2 hyperintensity
- ADEM: Asymmetric T2 hyperintensity in white and gray matter after viral prodrome
- Behçet disease: Enlarged, T2 hyperintense brainstem ± thalamus

Hypertrophic Olivary Degeneration

- Secondary degeneration of inferior olivary nucleus (ION), usually caused by primary lesions in dentato-rubro-olivary pathway

Metabolic Diseases

- X-linked adrenoleukodystrophy: Enhancing peritrigonal demyelination
- Wilson disease: White and gray matter lesions involving basal ganglia, dentate nucleus, brainstem
- Hypoglycemic coma: Reversible CST changes

Heroin Inhalation

- Symmetric T2 hyperintensity in posterior WM, including posterior limb of internal capsule

Normal Individuals

- CST can appear T2/FLAIR hyperintense on 3T MR (normal fully myelinated brain)

PATHOLOGY

General Features

- Etiology
  - Infarction, hemorrhage, neoplasm, encephalitis
  - Demyelinating disease, trauma, AV malformations
  - Reported also in patients with movement disorder
- Genetics
  - Process of axonal degeneration is genetically regulated
- Associated abnormalities
  - Primary lesion/disorder that caused secondary WM tract degeneration

Staging, Grading, & Classification

- Stage 1 (0-4 weeks): Degradation of axon; mild changes in myelin
- Stage 2 (4-14 weeks): Myelin protein breakdown; lipids remain intact
- Stage 3 (> 14 weeks): Myelin lipid breakdown, gliosis, changes in water content and structure
- Stage 4 (after months to years): Atrophy of ipsilateral brainstem

Gross Pathologic & Surgical Features

- Brainstem asymmetry due to atrophy in chronic stage

Microscopic Features

- Stage 1: Beginning of myelin and axon breakdown
  - Myelin sheaths break up into ellipsoids and spheres but retain myelin staining properties
- Stage 2: Decreased protein:lipid ratio
- Stage 3: Increased edema and further lipid breakdown
- Stage 4: Atrophy due to volume loss; removal of axonal debris by microglia continues for 2 years (vs. completed in 3 weeks in peripheral nervous system)
- Expression of transcription factors ATF3 and c-Jun by nonneuronal cells during WaD
- In CNS, astrocyte-dominated matrix fails to accommodate new axonal growth

CLINICAL ISSUES

Presentation

- Most common signs/symptoms
  - WaD in CST is associated with persistent hemiparesis

Demographics

- Age
  - Reported in all ages
- Gender
  - No gender preference
- Epidemiology
  - WaD commonly follows CNS lesions
    - WaD in pyramidal tract reported in 78.6% of cases of capsular infarct

Natural History & Prognosis

- WaD may begin within 1 week of fiber tract damage
- Demyelination can continue during next 6 months
- Signifies irreversible loss of neuronal function
- Extent of WaD is related to severity of motor deficit
  - Abnormal DWI signal in CST can be acute predictor of motor outcome in childhood infarction

Treatment

- No specific therapy

DIAGNOSTIC CHECKLIST

Image Interpretation Pearls

- In ischemic stroke: Important to differentiate DWI abnormality related to WaD from additional infarction
- Time-specific signal intensity changes of WaD → able to ascertain age of primary lesion

SELECTED REFERENCES

1. Kleinman JT: Early Wallerian degeneration on magnetic resonance imaging: underappreciated but highly relevant. Dev Med Child Neurol. 55(2):104-5, 2013
2. Saksena S et al: The Corpus Callosum Wallerian Degeneration in the Unilateral Brain Tumors: Evaluation with Diffusion Tensor Imaging (DTI). J Clin Diagn Res. 7(2):320-5, 2013
3. Venkatasubramanian C et al: Natural history and prognostic value of corticospinal tract Wallerian degeneration in intracerebral hemorrhage. J Am Heart Assoc. 2(4):e000090, 2013
4. Domi T et al: Corticospinal tract pre-wallerian degeneration: a novel outcome predictor for pediatric stroke on acute MRI. Stroke. 40(3):780-7, 2009
5. Liang Z et al: Progression of pathological changes in the middle cerebellar peduncle by diffusion tensor imaging correlates with lesser motor gains after pontine infarction. Neurorehabil Neural Repair. 23(7):692-8, 2009
6. Oh MY et al: Ipsilateral wallerian degeneration of the distal optic radiations after infarction at their root. J Neuroophthalmol. 29(2):146-8, 2009
7. Yu C et al: A longitudinal diffusion tensor imaging study on Wallerian degeneration of corticospinal tract after motor pathway stroke. Neuroimage. 47(2):451-8, 2009
8. De Simone T et al: Wallerian degeneration of the pontocerebellar fibers. AJNR Am J Neuroradiol. 26(5):1062-5, 2005

https://CafePezeshki.IR

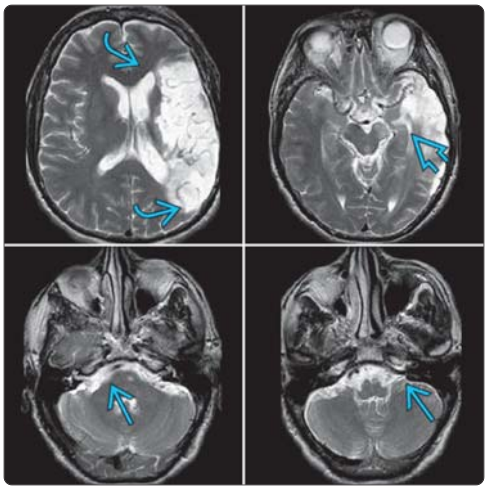

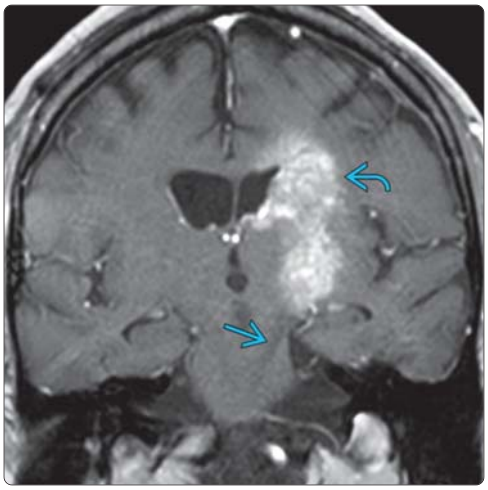

(Left) *Axial T2 MR images demonstrate an old infarct in the distribution of the left MCA. There is T2 hyperintensity with atrophy of the left cerebral peduncle due to wallerian degeneration of the corticospinal tract. T2 hyperintensity is also noted along the entire course of the corticospinal tract.* **(Right)** *Coronal T1WI C+ MR shows an infiltrative, enhancing mass along the left corona radiata. Note T1 hypointensity along the corticospinal tract due to wallerian degeneration caused by lipid breakdown and edema.*

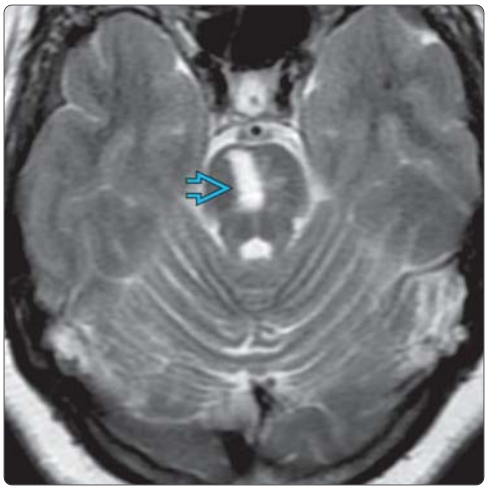

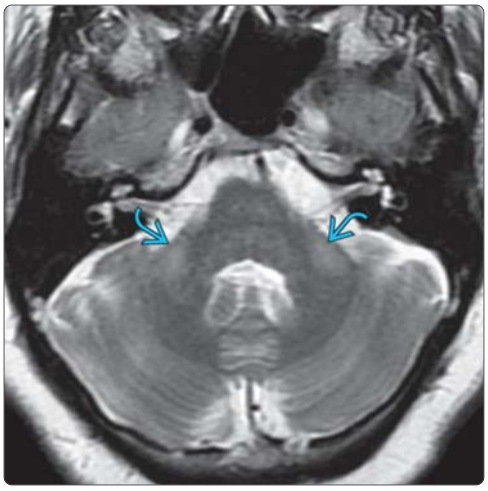

(Left) *Axial T2 MR shows an old infarct involving the right half of the pons.* **(Right)** *Axial T2 MR in the same patient shows mild atrophy of both middle cerebellar peduncles (MCP) with T2 hyperintensity due to wallerian degeneration. This is as a result of the decussation of fibers in the pons. An infarct in the pons affects the nuclei and the tracts in the pons at the site of the infarct which pass to the contralateral middle cerebellar peduncle and also the tracts passing across from the contralateral nuclei.*

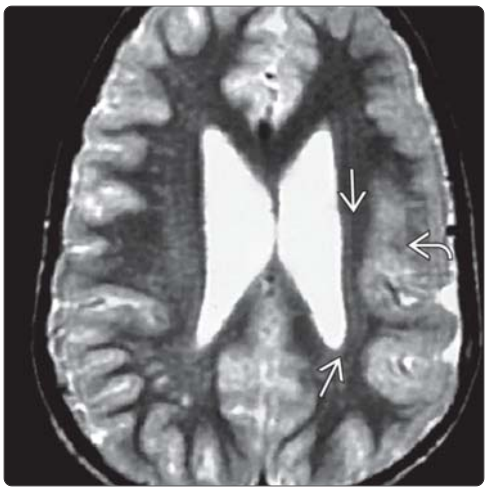

(Left) *Axial T2WI MR shows a left hemispheric lissencephaly with pachygyria. When due to toxins or infections, as in this case, reactive gliosis with macrophage infiltration disturbs neuronal migration, resulting in abnormal cortex and sparse underlying white matter.* **(Right)** *Axial T1WI MR in the same patient shows a diminutive left cerebral peduncle. This neuronal migrational abnormality results in 4-layer cortex with sparse underlying white matter. There is consequent hypoplasia of the corticospinal tract.*

https://CafePezeshki.IR

KEY FACTS

TERMINOLOGY

- Diaschisis = sudden loss of function in brain connected to (but at distance from) damaged area
- CCD = decreased blood flow/metabolism in cerebellar hemisphere contralateral to supratentorial infarct

IMAGING

- Acute: CT/MR perfusion shows ↓ CBF in cerebellar hemisphere opposite acute hemispheric infarct
  - ↑ TTP, ↓ CBF in cerebellum contralateral to infarct
  - Add DTI as subtle cases may show ↓ FA when conventional MR normal
  - 18F-FDG PET/CT shows diffusely reduced uptake in contralateral cerebellar hemisphere
- Chronic: CT or MR shows atrophic cerebellar hemisphere opposite old cerebral hemispheric infarct

TOP DIFFERENTIAL DIAGNOSES

- Superior cerebellar artery infarct
  - CCD involves > just SCA territory
- Encephalomalacia
  - Trauma, infection, surgery
- Cerebellitis
  - Cerebellum swollen, hyperintense (not shrunken, atrophic)

PATHOLOGY

- Corticopontocerebellar (CPC) tract
  - Input to cerebellum via corticopontocerebellar tracts 40x all other afferent sources combined
  - Injury at any point along CPC can result in ↓ CBF, metabolism in contralateral cerebellar hemisphere
  - Most common cause = MCA infarct
  - Others = status epilepticus, neoplasm, trauma, surgery,migraine, Rasmussen encephalitis, etc.

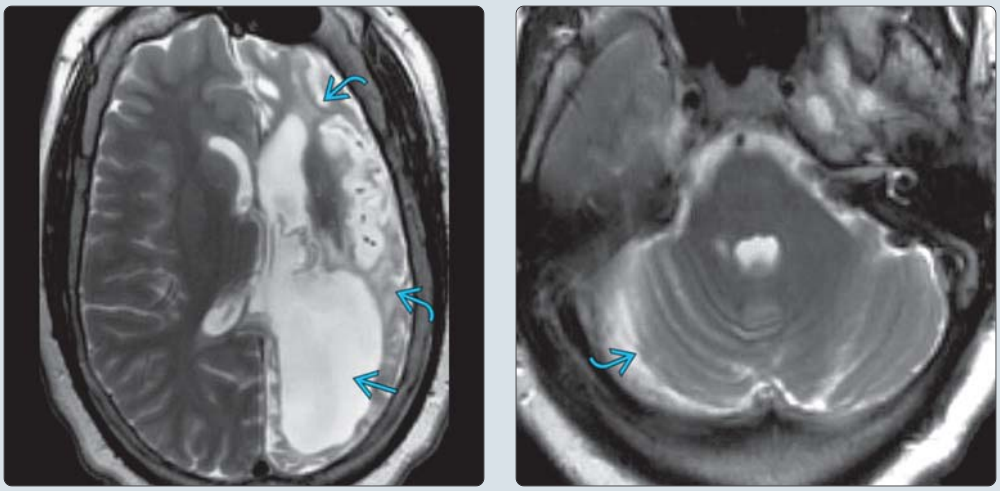

(Left) *Axial T2WI MR in a patient with a remote left middle cerebral artery infarct shows the typical changes of encephalomalacia and volume loss. The ipsilateral ventricle is enlarged.* **(Right)** *Axial T2 MR in the same patient shows volume loss with enlarged horizontal sulci in the contralateral cerebellar hemisphere. These findings are consistent with chronic crossed cerebellar diaschisis.*

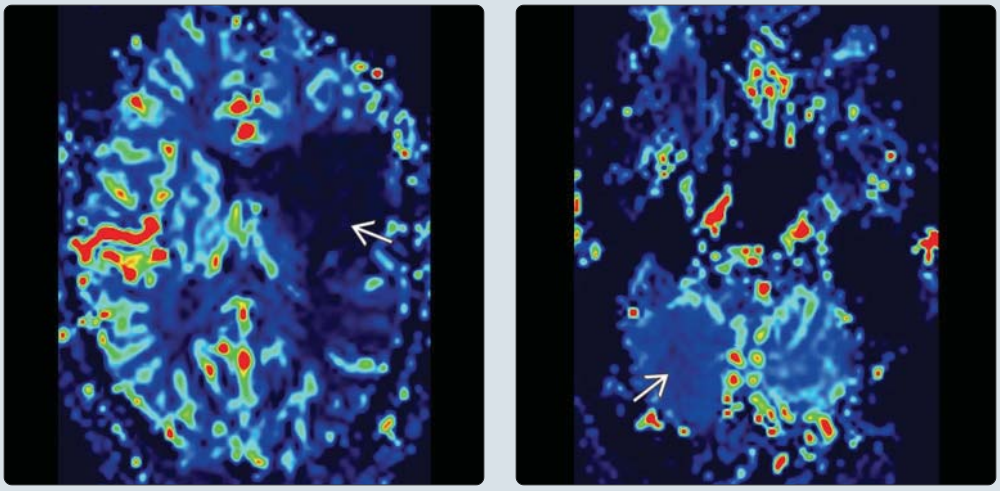

(Left) *MR perfusion study CBF (cerebral blood flow) map in a patient with acute right hemiparesis shows diminished blood flow (blue area) in the left middle cerebral artery distribution.* **(Right)** *CBF map in the same patient demonstrates reduced CBF in the right cerebellar hemisphere consistent with acute crossed cerebellar diaschisis (CCD). CCD is caused by an interruption of the corticopontocerebellar fibers. As a result of ↓ afferent input, there is a ↓ in cerebellar metabolism, coupled with a ↓ in cerebellar perfusion.*

https://CafePezeshki.IR

TERMINOLOGY

Abbreviations

- Crossed cerebellar diaschisis (CCD)

Definitions

- Diaschisis = sudden loss of function in brain connected to (but at distance from) damaged area
- CCD = decreased blood flow/metabolism in cerebellar hemisphere contralateral to supratentorial infarct
  - Caused by interrupted input through corticopontocerebellar tract (CPC)
- CCD occurs in both acute and chronic phases
  - Acute CCD results from functional deafference
  - Subacute, chronic CCD reflects transneuronal degeneration

IMAGING

General Features

- Best diagnostic clue
  - Acute: CT/MR perfusion shows ↓ cerebral blood flow (CBF) in cerebellar hemisphere opposite acute cerebral hemispheric infarct
  - Chronic: CT or MR shows atrophic cerebellar hemisphere opposite old cerebral hemispheric infarct
- Location
  - Cerebellar hemisphere opposite cerebral hemispheric infarct

Imaging Recommendations

- Best imaging tool
  - Acute: CT or MR perfusion
    - PET/CT also effective but expensive; variable availability
  - Chronic: MR with T2WI, FLAIR, DTI
- Protocol advice
  - Add DTI as subtle cases may show ↓ fractional anisotropy when conventional MR normal

CT Findings

- NECT
  - Acute: Normal
  - Chronic: Cerebellar atrophy contralateral to supratentorial infarct
- CTA
  - MCA occlusion
  - Cerebellar vessels appear normal
- CT perfusion
  - ↑ TTP, ↓ CBF in cerebellum contralateral to infarct

MR Findings

- T1WI
  - Unilateral cerebellar atrophy
- T2WI
  - Folia shrunken, fissures enlarged
- FLAIR
  - Except for atrophy, cerebellum usually normal
- MRA
  - Posterior fossa vasculature normal
- DTI
  - Shows ↓ FA in middle cerebellar peduncle
  - Visualizes altered CPC in chronic CCD that may not be seen on conventional MR

Nuclear Medicine Findings

- PET/CT
  - 18F-FDG PET/CT shows diffusely reduced uptake in contralateral cerebellar hemisphere
  - L-(methyl-11C) methionine (MET) uptake not reduced
- Tc-99m sulfur colloid
  - Tc-99m ECD, HMPAO SPECT can demonstrate distant areas of ↓ CBF, metabolism (diaschisis)

DIFFERENTIAL DIAGNOSIS

Superior Cerebellar Artery Infarct

- CCD involves most of cerebellum, not just SCA territory
- Contralateral MCA infarct absent

Encephalomalacia

- No history of trauma, contralateral MCA infarct

Cerebellitis

- Cerebellum swollen, not shrunken

PATHOLOGY

General Features

- Etiology
  - Corticopontocerebellar (CPC) tract
    - Large afferent pathway derived from very extensive areas of cortex
    - Input to cerebellum via corticopontocerebellar tracts 40x all other afferent sources combined
      - 1st-order neurons arrive in ipsilateral pons
      - Synapse with 2nd-order neurons
      - Then cross to opposite cerebellar hemisphere via middle cerebellar peduncle
  - Injury at any point along CPC can result in ↓ CBF, metabolism in contralateral cerebellar hemisphere
    - Most common cause = MCA infarct
    - Others = status epilepticus, neoplasm, trauma, surgery, migraine, Rasmussen encephalitis, etc.

CLINICAL ISSUES

Natural History & Prognosis

- CCD represents temporal continuum
  - Early, reversible functional hypometabolism
    - Cerebellum recovers (typical)
  - Irreversible degeneration in up to 20%
    - Cerebellar atrophy
    - Can be seen decades after initial insult

SELECTED REFERENCES

1. Chen S et al: Crossed cerebellar diaschisis detected by arterial spin-labeled perfusion magnetic resonance imaging in subacute ischemic stroke. J Stroke Cerebrovasc Dis. 23(9):2378-83, 2014
2. Zaidi SA et al: Crossed cerebellar diaschisis: a radiological finding in status epilepticus not to miss. BMJ Case Rep. 2013, 2013
3. Jeon YW et al: Dynamic CT perfusion imaging for the detection of crossed cerebellar diaschisis in acute ischemic stroke. Korean J Radiol. 13(1):12-9, 2012
4. Massaro AM: Teaching neuroimages:crossed cerebellar diaschisis in hemispheric status epilepticus. Neurology. 79(20):e182, 2012

https://CafePezeshki.IR

KEY FACTS

TERMINOLOGY

- Inferior olivary nucleus (ION) degeneration
  - Unique type of trans-synaptic neuronal degeneration
  - Olivary deafferentation thought to be source of ensuing hypertrophic olivary degeneration (HOD)
- Usually caused by primary lesions in dento-rubro-olivary pathway (anatomical triangle of Guillain-Mollaret)
- Triangle of Guillain-Mollaret defined by 3 anatomic structures
  - Dentate nucleus (DN) of cerebellum
  - Ipsilateral red nucleus (RN)
  - ION ipsilateral to RN

IMAGING

- ION initially hypertrophies rather than atrophies
- 3 distinct MR stages in HOD
  - Hyperintense signal without hypertrophy of ION: Within 1st 6 months of ictus
  - Increased signal + ION hypertrophy: Between 6 months and 3-4 years after ictus
  - Only ION hyperintensity: Begins when hypertrophy resolves (can persist indefinitely)
- MR also detects primary lesion located in ipsilateral central tegmental tract or contralateral DN

TOP DIFFERENTIAL DIAGNOSES

- Vertebrobasilar perforating artery infarct
- Demyelination (MS, microvascular disease)
- Amyotrophic lateral sclerosis
- HIV/AIDS
- Rhombencephalitis

CLINICAL ISSUES

- Palatal myoclonus (palatal "tremor")
- Usually develops 10-11 months after primary lesion
- Clinical symptoms (tremors) rarely improve

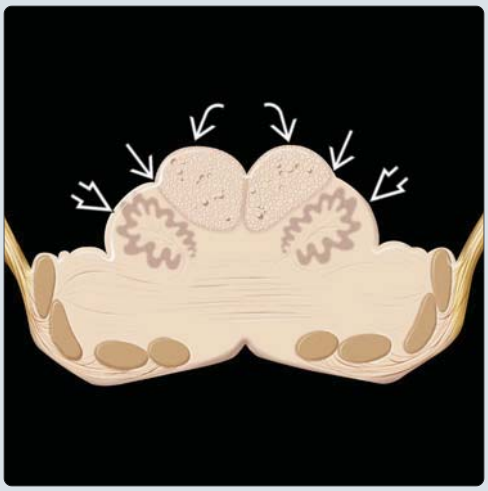

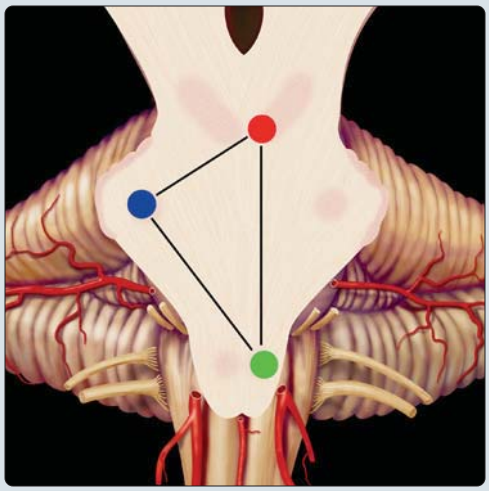

(Left) *Axial graphic of the upper medulla shows the medullary pyramids on each side of the ventral median fissure. The olives lie just posterior to the preolivary sulci.* **(Right)** *Coronal graphic of the midbrain, pons, and medulla is sectioned to depict the Guillain-Mollaret triangle. The triangle of Guillain-Mollaret is composed of the ipsilateral inferior olivary nucleus (green), dentate nucleus (blue) of the contralateral cerebellum, and the ipsilateral red nucleus (red).*

(Left) *Axial T2WI MR (CISS) shows the normal shape of the medullary olives.* **(Right)** *Axial T2WI MR in a patient who developed palatal myoclonus approximately 6 months after resection of a midbrain cavernous malformation shows hyperintensity and enlargement of both olives. This pattern is typical in the subacute stage of hypertrophic olivary degeneration, which typically appears between 6 months and 3-4 years after injury to the dento-rubro-olivary pathway.*

https://CafePezeshki.IR

TERMINOLOGY

Abbreviations

- Hypertrophic olivary degeneration (HOD)

Synonyms

- Pseudohypertrophy of inferior olivary nucleus

Definitions

- Secondary degeneration of inferior olivary nucleus (ION), usually caused by primary lesions in dento-rubro-olivary pathway (anatomical triangle of Guillain and Mollaret)

IMAGING

General Features

- Best diagnostic clue
  - T2 hyperintense, nonenhancing enlargement of ION
- Location
  - Triangle of Guillain and Mollaret defined by 3 anatomic structures
    - Red nucleus (RN)
    - ION ipsilateral to RN
    - Contralateral dentate nucleus (DN) of cerebellum
  - Central tegmental tract connects RN to ipsilateral ION
  - Superior cerebellar peduncle (dentatorubral tract) connects DN to contralateral RN
  - Inferior cerebellar peduncle connects ION to contralateral cerebellar cortex and contralateral DN
  - 3 patterns of HOD in relation to primary lesion
    - Ipsilateral HOD: Primary lesion is limited to brainstem (central tegmental tract)
    - Contralateral HOD: Primary lesion is in cerebellum (DN or superior cerebellar peduncle)
    - Bilateral HOD: Primary lesion involves both central tegmental tract and superior cerebellar peduncle
- Size
  - Variable (time-dependent) size of affected ION
    - Normal in acute stage
    - Increased (hypertrophy) between 6 months to 3-4 years
    - Decreased (atrophy) in advanced stage (> 3-4 years)
- Morphology
  - Unique type of trans-synaptic neuronal degeneration
    - ION initially hypertrophies rather than atrophies

CT Findings

- NECT
  - May show acute primary injury (e.g., hemorrhage) in tegmentum
  - HOD typically not depicted on CT

MR Findings

- T1WI
  - Acute phase: Normal ION
    - Shows primary lesion in brainstem (cerebellum or tegmentum)
  - After HOD ensues
    - Enlargement confined to ION, isointense to slightly hypointense to gray matter
    - Slightly increased olivary T1 signal also reported
    - ± residual primary lesion
- T2WI
  - 3 distinct MR stages in HOD
    - Hyperintense signal without hypertrophy of ION: Within 1st 6 months of ictus
    - Both increased signal and hypertrophy of ION: Between 6 months and 3-4 years after ictus
    - Increased signal only in ION: Begins when hypertrophy resolves and can persist indefinitely
  - Axial MR: Disappearance of pre- and postolivary sulci in hypertrophic stage
  - MR also detects primary lesion located in ipsilateral central tegmental tract or contralateral DN
    - Old hematomas: Low signal areas on T2WI revealing hemosiderin deposition
  - ± decreased size of contralateral ION, with higher than normal signal intensity
  - ± mild to severe atrophic changes of cerebellar cortex contralateral to HOD
- PD/intermediate
  - High signal intensity of ION better detected on PD images than on T2WI
- FLAIR
  - Similar to T2WI
- T1WI C+
  - No contrast enhancement of degenerated ION

Nuclear Medicine Findings

- PET
  - Hypermetabolism of glucose in medulla in patients with HOD

Imaging Recommendations

- Best imaging tool
  - MR imaging
- Protocol advice
  - T2WI (include coronal or sagittal sections)

DIFFERENTIAL DIAGNOSIS

Other Causes of High T2 Signal Intensity in Anterior Part of Medulla

- Demyelination related to multiple sclerosis
- Tumor (astrocytoma, metastasis, lymphoma)
- Lesions involving corticospinal tract
  - Wallerian degeneration, adrenoleukodystrophy
  - Amyotrophic lateral sclerosis
- Vertebrobasilar perforating artery infarct
  - Most medullary infarctions occur in posteroinferior cerebellar artery territory and involve posterolateral medulla (e.g., vertebral artery dissection)
  - Alternatively, medullary infarcts could be related to perforating branches of anterior spinal or vertebral arteries and have paramedial location
- Infectious/inflammatory processes
  - Tuberculosis
  - Sarcoidosis
  - HIV/AIDS
  - Rhombencephalitis

https://CafePezeshki.IR

PATHOLOGY

General Features

- Etiology
  - Transsynaptic degeneration caused by interruption of pathways composing Guillain-Mollaret triangle
  - Olivary deafferentation thought to be source of ensuing HOD
  - Primary lesions usually located in contralateral DN or ipsilateral central tegmental tract
  - Focal brainstem insults that may lead to dentatorubral-olivary pathway interruption
    - Ischemic infarction, demyelination
    - Hemorrhage (related to hypertensive disease, occult cerebrovascular malformation, or diffuse axonal injury following severe head trauma)
    - Cavernous malformation
- Associated abnormalities
  - Primary brainstem insult
    - Most commonly pontine hemorrhage from trauma (including surgery), hypertension, tumor, and infarction
- Olivary enlargement: Histologically unusual vacuolar cytoplasmic degeneration → hypertrophy related in part to ↑ number of astrocytes
- After onset of primary lesion
  - Vacuolar cytoplasmic degeneration in 6-15 months
  - Gliosis follows at 15-20 months

Staging, Grading, & Classification

- 6 phases of pathologic change
  - No olivary changes within 1st 24 hours
  - Degeneration of olivary amiculum (white matter capsule at olive periphery) at 2-7 days or more
  - Olivary hypertrophy (mild enlargement with neuronal hypertrophy, no glial reaction) at 3 weeks
  - Maximal olivary enlargement (hypertrophy of neurons and astrocytes) at 8.5 months
  - Olivary pseudohypertrophy (neuronal dissolution with gemistocytic astrocytes) after 9.5 months
  - Olivary atrophy (neuronal disappearance with olivary atrophy and prominent degeneration of amiculum olivae) after a few years

Gross Pathologic & Surgical Features

- Focal swelling of ION
- Unilateral HOD
  - Asymmetric enlargement of anterior medulla
  - "Pallor" in contralateral DN
  - Atrophy of contralateral cerebellar cortex
- Bilateral HOD: More difficult to observe
  - No left-right asymmetry

Microscopic Features

- Changes in hypertrophic degenerated ION
  - Hypertrophic, thickened neurites
  - Vacuolation of neurons
  - Fibrillary gliosis
  - Demyelination and astrocytic proliferation of WM
- In contralateral cerebellar cortex
  - Decreased number of Purkinje cells
- Contralateral DN reduced in size, possibly due to
  - Iron depletion secondary to axonal iron transport block
  - Loss of cells in nucleus

CLINICAL ISSUES

Presentation

- Most common signs/symptoms
  - Symptomatic palatal tremor/myoclonus
    - Rhythmic involuntary movement of soft palate, uvula, pharynx, and larynx
  - Severe myoclonus may also affect cervical muscles and diaphragm
  - ± dentatorubral tremor (Holmes tremor)
    - 2-5 Hz rest, postural, and kinetic tremor of upper extremity
    - May occur before onset of palatal tremor
  - Symptoms of cerebellar or brainstem dysfunction
    - Associated with acute lesion within triangle of Guillain-Mollaret
- Clinical profile
  - Palatal myoclonus (palatal "tremor")
    - Usually develops 10-11 months after primary lesion
    - Virtually all patients who develop palatal myoclonus after brain insult will have HOD
    - Not all HOD patients develop palatal myoclonus
    - May result from hypermetabolism of ION

Demographics

- Age
  - Rare; reported in all ages, both genders

Natural History & Prognosis

- After primary brainstem injury, olivary hypertrophy typically appears in delayed fashion
  - May occur between 3 weeks to 11 months (usually within 4-6 months)
- Maximum hypertrophy at 5-15 months
- Olivary hypertrophy typically resolves in 10-16 months
- Olivary hyperintensity on T2WI may persist for years after resolution of hypertrophy
- Finally ION undergoes atrophy
- Clinical symptoms (tremors) rarely improve

DIAGNOSTIC CHECKLIST

Image Interpretation Pearls

- Avoid misdiagnosis of tumor or multiple sclerosis
- Bilateral and symmetrical lesions in ION argue against subacute infarct and vertebral artery dissection

SELECTED REFERENCES

1. Blanco Ulla M et al: Magnetic resonance imaging of hypertrophic olivary degeneration. Radiologia. ePub, 2015
2. Carr CM et al: Frequency of bilateral hypertrophic olivary degeneration in a large retrospective cohort. J Neuroimaging. 25(2):289-95, 2015
3. Sen D et al: MRI and MR tractography in bilateral hypertrophic olivary degeneration. Indian J Radiol Imaging. 24(4):401-5, 2014
4. Khoyratty F et al: The dentato-rubro-olivary tract: clinical dimension of this anatomical pathway. Case Rep Otolaryngol. 2013:934386, 2013
5. Ogawa K et al: Pathological study of pseudohypertrophy of the inferior olivary nucleus. Neuropathology. 30(1):15-23, 2010

https://CafePezeshki.IR

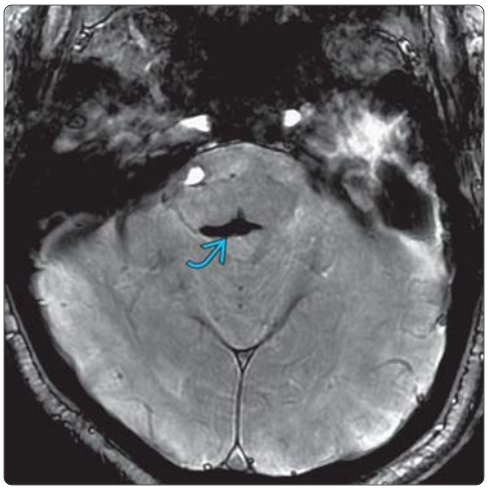

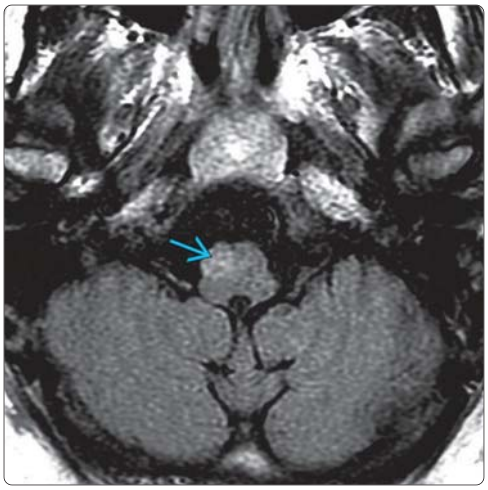

(Left) *Axial SWI MR demonstrates hemosiderin staining in the dorsal aspect of the brainstem in the midline and to the right due to an old hemorrhage.* **(Right)** *Axial FLAIR MR in the same patient at the level of the medulla shows mild hypertrophy with hyperintensity in the region of the right inferior olivary nucleus. Findings are typical for hypertrophic olivary degeneration caused by primary lesions in dento-rubro-olivary pathway (anatomical triangle of Guillain and Mollaret).*

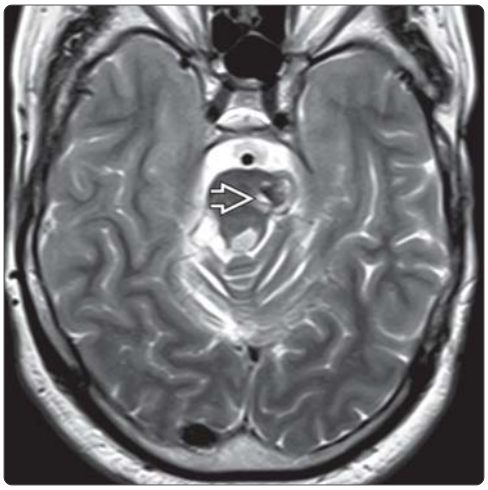

(Left) *Axial T2WI MR in a patient who developed palatal myoclonus several months following midbrain surgery for cavernous malformation. Imaging obtained 1 year later shows residual cavernous malformation.* **(Right)** *Axial T2WI MR through the medulla shows that the ipsilateral olive is atrophic and hyperintense. This patient also has crossed cerebellar atrophy due to interruption of the ponto-cerebellar pathway.*

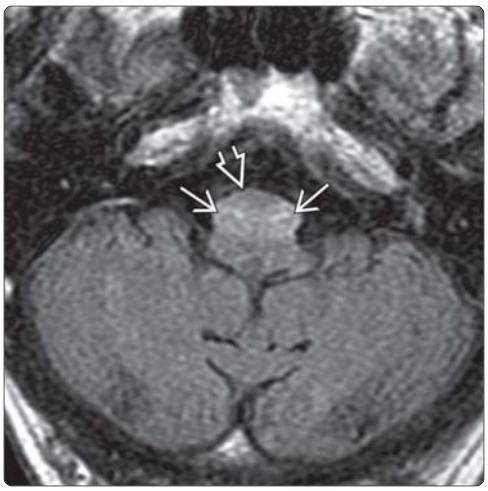

(Left) *Axial FLAIR MR in the same patient delineates the somewhat wavy appearance of the hyperintensity conforming to the configuration of the olives. The pyramids are spared, helping differentiate hypertrophic olivary degeneration from perforating artery infarction.* **(Right)** *Axial graphic of the midbrain at the level of the hypoglossal nuclei shows the distinct wavy pattern of the olives corresponding to the FLAIR hyperintensity in the previous image.*

https://CafePezeshki.IR

This page intentionally left blank

https://CafePezeshki.IR

PART II
SECTION 1

Ventricles and Cisterns

Ventricles and Cisterns Overview 988

Normal Variants

Cavum Septi Pellucidi (CSP) 994
Cavum Velum Interpositum (CVI) 995
Enlarged Subarachnoid Spaces 996

Hydrocephalus

Intraventricular Obstructive Hydrocephalus 1000
Extraventricular Obstructive Hydrocephalus 1004
Aqueductal Stenosis 1006
Normal Pressure Hydrocephalus 1010
CSF Shunts and Complications 1014

https://CafePezeshki.IR

Gross and Imaging Anatomy

Ventricles and Choroid Plexus

Basic embryology: Early in embryonic development, the forebrain cavity divides into two lateral ventricles, which develop as outpouchings from the rostral third ventricle and are connected to it by the interventricular foramen (a.k.a. foramen of Monro). In the coronal plane, these form a central H-shaped "monoventricle." The cerebral aqueduct develops from the midbrain vesicle. The fourth ventricle develops from a cavity within the hindbrain and merges caudally with the central canal of the spinal cord.

Anatomic overview: The brain CSF spaces include both the ventricular system and subarachnoid spaces (SAS). The ventricular system is comprised of four interconnected CSF-filled, ependymal-lined cavities that lie deep within the brain. The paired **lateral ventricles** communicate with the third ventricle via the Y-shaped **foramen of Monro**. The **third ventricle** communicates with the fourth ventricle via the **cerebral aqueduct** (of Sylvius). In turn, the **fourth ventricle** communicates with the SAS via its outlet foramina (the midline **foramen of Magendie** and the two lateral **foramina of Luschka**).

Lateral ventricles: Each lateral ventricle has a body, atrium, and three projections ("horns"). The roof of the **frontal horn** is formed by the corpus callosum genu. It is bordered laterally and inferiorly by the head of the caudate nucleus. The septi pellucidi is a thin, bilayered membrane that extends from the corpus callosum genu anteriorly to the foramen of Monro posteriorly and forms the medial borders of both frontal horns.

The **body** of the lateral ventricle passes posteriorly under the corpus callosum. Its floor is formed by the dorsal thalamus and its medial wall is bordered by the fornix. Laterally, it curves around the body and tail of the caudate nucleus.

The **atrium** contains the choroid plexus glomus and is formed by the confluence of the body with the temporal and occipital horns. The **temporal horn** extends anteroinferiorly from the atrium and is bordered on its floor and medial wall by the hippocampus. Its roof is formed by the tail of the caudate nucleus. The **occipital horn** is surrounded entirely by white matter fiber tracts, principally the geniculocalcarine tract and the forceps major of the corpus callosum.

Foramen of Monro is a Y-shaped structure with two long arms extending towards each lateral ventricle and a short inferior common stem that connects with the roof of the third ventricle.

Third ventricle: The third ventricle is a single, slit-like, midline, vertically oriented cavity that lies between the thalami. Its roof is formed by the tela choroidea, a double layer of invaginated pia. The lamina terminalis and anterior commissure lie along the anterior border of the third ventricle.

The floor of the third ventricle is formed by several critical anatomic structures. From front to back these include the optic chiasm, hypothalamus with the tuber cinereum and infundibular stalk, mammillary bodies, and roof of the midbrain tegmentum.

The third ventricle has two inferiorly located CSF-filled projections: The slightly rounded **optic recess** and the more pointed **infundibular recess**. Two small recesses, the **suprapineal and pineal recesses**, form the posterior border of the third ventricle. A variably sized interthalamic adhesion (also called the **massa intermedia**) lies between the lateral walls of the third ventricle. The massa intermedia is not a true commissure.

Cerebral aqueduct is an elongated tubular conduit that lies between the midbrain tegmentum and the quadrigeminal plate. It connects the third ventricle with the fourth ventricle.

Fourth ventricle: The fourth ventricle is a roughly diamond-shaped cavity that lies between the pons anteriorly and the cerebellar vermis posteriorly. Its roof is covered by the anterior (superior) medullary velum above and the inferior medullary velum below.

The fourth ventricle has five distinctly shaped recesses. The **posterior superior recesses** are paired, thin, flat, CSF-filled pouches that cap the cerebellar tonsils. The **lateral recesses** curve anterolaterally from the fourth ventricle, extending under the brachium pontis (major cerebellar peduncle) into the lower cerebellopontine angle cisterns. The lateral recesses transmit choroid plexus through the foramina of Luschka into the adjacent subarachnoid spaces. The **fastigium** is a triangular, blind-ending, dorsal midline outpouching that points towards the cerebellar vermis. The fourth ventricle gradually narrows as it courses inferiorly, forming the **obex**. Near the cervicomedullary junction, the obex becomes continuous with the central canal of the spinal cord.

Choroid plexus and the production of CSF: The choroid plexus is comprised of highly vascular papillary excrescences with a central connective tissue core coated by an ependyma-derived secretory epithelium. The embryonic choroid plexus forms where the infolded tela choroidea contacts the ependymal lining of the ventricles, thus developing along the entire choroidal fissure.

The largest mass of choroid plexus, the **glomus**, is located in the atrium of the lateral ventricles. The choroid plexus extends anteriorly along the floor of the lateral ventricle, lying between the fornix and thalamus. It then dives through the interventricular foramen (of Monro) and curves posteriorly along the roof of the third ventricle. The choroid plexus, in the body of the lateral ventricle, curls around the thalamus into the temporal horn, where it fills the choroidal fissure and lies superomedial to the hippocampus.

CSF is predominantly, but not exclusively, secreted by the choroid plexuses. Brain interstitial fluid, ependyma, and capillaries may also play a poorly defined role in CSF secretion. The choroid plexus epithelium secretes CSF at the rate of about 0.2-0.7 mL/minute or 600-700 mL/day. The mean CSF volume is 150 ml, with 25 ml in the ventricles and 125 ml in subarachnoid spaces. CSF flows through the ventricular system and passes through the exit foramina of the fourth ventricle into the SAS. The bulk of CSF resorption is through the arachnoid villi along the superior sagittal sinus. CSF also drains into lymphatic vessels around the cranial cavity and spinal canal.

Not all CSF is produced in the choroid plexus. Drainage of brain interstitial fluid is a significant extrachoroidal source.

CSF plays an essential role in the maintenance of brain interstitial fluid homeostasis and regulation of neuronal functioning.

Cisterns and Subarachnoid Spaces

Overview: The SASs lie between the pia and arachnoid. The sulci are CSF-filled spaces between the gyral folds. Focal

https://CafePezeshki.IR

expansions of the SASs form the brain CSF cisterns. These cisterns are found at the base of the brain around the brainstem, tentorial incisura, and foramen magnum. Numerous pial-covered septa cross the SAS from the brain to the arachnoid. All SAS cisterns communicate with each other and the ventricular system, providing natural pathways for disease spread (e.g., meningitis, neoplasms).

The brain cisterns are conveniently grouped into supra-, peri-, and infratentorial cisterns. All contain numerous important critical structures, such as vessels and cranial nerves.

Supratentorial/peritentorial cisterns: The **suprasellar cistern** lies between the diaphragma sellae and the hypothalamus. Critical contents include the infundibulum, optic chiasm, and circle of Willis.

The **interpeduncular cistern** is the posterior continuation of the suprasellar cistern. Lying between the cerebral peduncles, it contains the oculomotor nerves as well as the distal basilar artery and proximal segments of the posterior cerebral arteries. Important perforating arteries, the thalamoperforating and thalamogeniculate arteries, arise from the top of the basilar artery and cross the interpeduncular cistern to enter the midbrain.

The **perimesencephalic(ambient) cisterns** are thin wings of CSF that extend posterosuperiorly from the suprasellar cistern to the quadrigeminal cistern. They wraparound the midbrain and contain the trochlear nerves, P2 PCA segments, superior cerebellar arteries, and basal vein of Rosenthal.

The **quadrigeminal cistern** lies under the corpus callosum splenium, behind the pineal gland and tectal plate. It connects with the ambient cisterns laterally and the superior cerebellar cistern inferiorly. The quadrigeminal cistern contains the pineal gland, trochlear nerves, P3 PCA segments, proximal choroidal arteries, and vein of Galen. An anterior extension, the **velum interpositum**, lies below the fornix and above the third ventricle. The velum interpositum contains the internal cerebral veins and medial posterior choroidal arteries.

Infratentorial cisterns: The unpaired posterior fossa cisterns that lie in the midline are the prepontine, premedullary, and superior cerebellar cisterns, as well as the cisterna magna. The lateral cisterns are paired and include the cerebellopontine and cerebellomedullary cisterns.

The **prepontine cistern** lies between the upper clivus and the "belly" of the pons. It contains numerous important structures including the basilar artery, the anterior inferior cerebellar arteries (AICAs), and the trigeminal and abducens nerves (CN5 and CN6).

The **premedullary cistern** is the inferior continuation of the prepontine cistern. It lies between the lower clivus in front and the medulla behind. It extends inferiorly to the foramen magnum and contains the vertebral arteries and branches (e.g., PICAs) and the hypoglossal nerve (CN12).

The **superior cerebellar cistern** lies between the straight sinus above and the vermis below. It contains the superior cerebellar arteries and veins. It connects superiorly through the tentorial incisura with the quadrigeminal cistern and inferiorly with the cisterna magna. The **cisterna magna** lies below the inferior vermis between the medulla and the occiput. It contains the cerebellar tonsils and the tonsillohemispheric branches of posterior inferior cerebellar artery (PICA). The cisterna magna merges imperceptibly with the SAS of the upper cervical spinal canal.

The **cerebellopontine angle cisterns** (CPAs) lie between the pons/cerebellum and the petrous temporal bone. Their most important contents are the trigeminal, facial, and vestibulocochlear nerves (CN5, CN7, and CN8). Other structures found here include the petrosal veins and AICAs. The CPA cisterns are contiguous inferiorly with the cerebellomedullary cisterns, sometimes termed the "lower" cerebellopontine angle cisterns.

The **cerebellomedullary cisterns** extend laterally around the medulla and are continuous with the cisterna magna below and the CPAs above. They contain the vagus, glossopharyngeal, and spinal accessory nerves (CN9, CN10, and CN11). A tuft of choroid plexus exits each foramen of Luschka into the cerebellomedullary cistern. The flocculus of the cerebellum that projects into this cistern can appear very prominent. The flocculus and choroid plexus are normal contents of the cerebellomedullary cisterns and should not be mistaken for pathology.

Imaging Recommendations

MR: Thin-section 3D T2WI or FIESTA/CISS best detail CSF within the ventricular system, SASs, and basal cisterns, and exquisitely delineates their contents. Whole brain FLAIR is especially useful for evaluating potential abnormalities in the SASs. Spin dephasing with pulsatile CSF flow is common and can mimic intraventricular pathology, especially in the basal cisterns and around the interventricular foramen. Incomplete CSF suppression with "bright" CSF can mimic pathologic SASs.

Differential Diagnosis Approach

Ventricles and Choroid Plexus

Overview: Approximately 10% of intracranial neoplasms involve the cerebral ventricles, either primarily or by extension. An anatomy-based approach is most effective, as there is a distinct predilection for certain lesions to occur in one ventricle or cistern and not others. Age is also a helpful consideration. Specific imaging findings, such as signal intensity, enhancement, and the presence or absence of calcification are relatively less important than location and age.

Normal variants: Asymmetry of the lateral ventricles is a common normal variant, as is flow-related CSF pulsation artifact. A cavum septi pellucidi (CSP) is a common normal variant, seen as a CSF cleft between the two leaves of the septum pellucidum. An elongated, finger-like posterior continuation of the CSP between the fornices, a cavum vergae (CV), may be associated with a CSP.

Lateral ventricle mass:Choroid plexus cysts (xanthogranulomas) are a common, generally age-related, degenerative finding with no clinical significance. They are nonneoplastic noninflammatory cysts, usually bilateral with rim calcification. They may be hyperintense on FLAIR and 60-80% appear quite bright on DWI. A strongly enhancing choroid plexus mass in a child is most likely a choroid plexus papilloma. With the exception of the fourth ventricle, a choroid plexus mass in an adult is usually meningioma or metastasis, not a choroid plexus papilloma.

Some lateral ventricle lesions display a distinct predilection for specific sublocations within the lateral ventricles. An innocent-appearing frontal horn mass in a middle-aged or older adult is

https://CafePezeshki.IR

most often a subependymoma. A bubbly mass in the body of the lateral ventricle is usually a central neurocytoma. Neurocysticercosis cysts can occur in all ages and in virtually every CSF space.

Foramen of Monro mass: The most common "abnormality" here is a pseudolesion caused by CSF pulsation artifact. Colloid cyst is the only relatively common pathology here. It is rare in children and typically a lesion of adults. Flow artifact can mimic a colloid cyst, but mass effect is absent. In a child with an enhancing mass in the interventricular foramen, tuberous sclerosis with subependymal nodule &/or giant cell astrocytoma should be a consideration. Masses such as ependymoma, papilloma, and metastasis are rare.

Third ventricle mass: Again, the most common "lesion" in this location is either CSF flow artifact or a normal structure (the massa intermedia). Colloid cyst is the only common lesion that occurs in the third ventricle; 99% are wedged into the foramen of Monro. Extreme vertebrobasilar dolichoectasia can indent the third ventricle, sometimes projecting upward as high as the interventricular foramen, and should not be mistaken for colloid cyst.

Primary neoplasms in children are uncommon here but include choroid plexus papilloma, germinoma, craniopharyngioma, and a sessile-type tuber cinereum hamartoma. Primary neoplasms of the third ventricle in adults are also uncommon, though an intraventricular macroadenoma and chordoid glioma are examples. Neurocysticercosis occurs here but is uncommon.

Cerebral aqueduct: Other than aqueductal stenosis, intrinsic lesions of the cerebral aqueduct are rare. Most are related to masses in adjacent structures (e.g., tectal plate glioma).

Fourth ventricle mass: Pediatric masses are the most common intrinsic abnormalities of the fourth ventricle. Medulloblastoma, ependymoma, and astrocytoma predominate. Atypical teratoid/rhabdoid tumor (AT/RT) is a less common neoplasm that may occur here. It usually occurs in children under the age of three and can mimic medulloblastoma.

Metastases to the choroid or ependyma are probably the most common fourth ventricle neoplasm of adults. Primary neoplasms are rare. Choroid plexus papilloma does occur here, as well as in the CPA cistern. Subependymoma is a lesion of middle-aged adults that is found in the inferior fourth ventricle, lying behind the pontomedullary junction. A newly described rare neoplasm, rosette-forming glioneuronal tumor, is a midline mass of the fourth ventricle. It has no particular distinguishing imaging features and, although it may appear aggressive, it is a benign (WHO grade I) lesion. Hemangioblastomas are intraaxial masses but may project into the fourth ventricle. Epidermoid cysts and neurocysticercosis cysts can be found in all ages.

Subarachnoid Spaces and Cisterns

Overview: The subarachnoid spaces are a common site of pathology that varies from benign congenital lesions (such as arachnoid cyst) to infection (meningitis) and neoplastic involvement ("carcinomatous meningitis"). Anatomic location is key to the differential diagnosis, as imaging findings, such as enhancement and hyperintensity on FLAIR, are often nonspecific. Patient age is also helpful though generally of secondary importance.

Normal variants: CSF flow-related artifacts are common, especially in the basal cisterns on FLAIR imaging. Mega cisterna magna may be considered a normal variant, as is a cavum velum interpositum (CVI). A CVI is a thin, triangular-shaped CSF space between the lateral ventricles that lies below the fornices and above the third ventricle. Occasionally a CVI may become quite large.

Suprasellar cistern mass: Common masses in adults are upward extensions of macroadenoma, meningioma, and aneurysm. The two most common suprasellar masses in children are astrocytoma of the optic chiasm/hypothalamus and craniopharyngioma.

Cerebellopontine angle mass: In adults, vestibular schwannoma accounts for almost 90% of all CPA-IAC masses. Meningioma, epidermoid cyst, aneurysm, and arachnoid cyst **together** represent about 8% of lesions in this location. All other less common entities, such as lipoma, schwannomas of other cranial nerves, metastases, neurenteric cysts, etc., account for about 2%.

In the absence of neurofibromatosis type 2, vestibular schwannomas are very rare in children. CPA epidermoid and arachnoid cysts may occur in children. Extension of ependymoma laterally through the foramina of Luschka may involve the CPA.

Cystic-appearing CPA masses comprise their own special differential diagnosis. While vestibular schwannoma with intramural cysts can occur, it is less common than epidermoid and arachnoid cysts. Neurocysticercosis may occasionally involve the CPA. Large endolymphatic sac anomaly (IP-2) shows a CSF-like mass within the posterior wall of the temporal bone. Hemangioblastoma and neurenteric cysts are other less common cystic masses that occur in the CPA.

Cisterna magna mass: Tonsillar herniation, whether congenital (Chiari 1) or secondary to posterior fossa mass effect or intracranial hypotension, is the most common "mass" in this location. Nonneoplastic cysts (arachnoid, epidermoid, dermoid, neurenteric) may also occur here.

Neoplasms in and around the cisterna magna, such as meningioma and metastasis, are typically anterior to the medulla. Subependymoma of the fourth ventricle originates in the obex and lies behind the medulla.

FLAIR hyperintensity: Hyperintense sulci and subarachnoid spaces are seen with MR artifacts, as well as a variety of lesions. Pathologic FLAIR hyperintensity is typically related to blood (e.g., subarachnoid hemorrhage), protein (meningitis), or cells (pia-subarachnoid space metastases). Less commonly, gadolinium-based contrast agents in patients with blood-brain barrier leakage or renal failure can cause FLAIR hyperintensity.

Rare causes of FLAIR hyperintensity include ruptured dermoid cyst, moyamoya ("ivy" sign), and acute cerebral ischemia. Contrast enhancement helps distinguish meningitis and metastases from subarachnoid hemorrhage and CSF artifacts.

Selected References

1. Sakka L et al: Anatomy and physiology of cerebrospinal fluid. Eur Ann Otorhinolaryngol Head Neck Dis. 128(6):309-16, 2011

https://CafePezeshki.IR



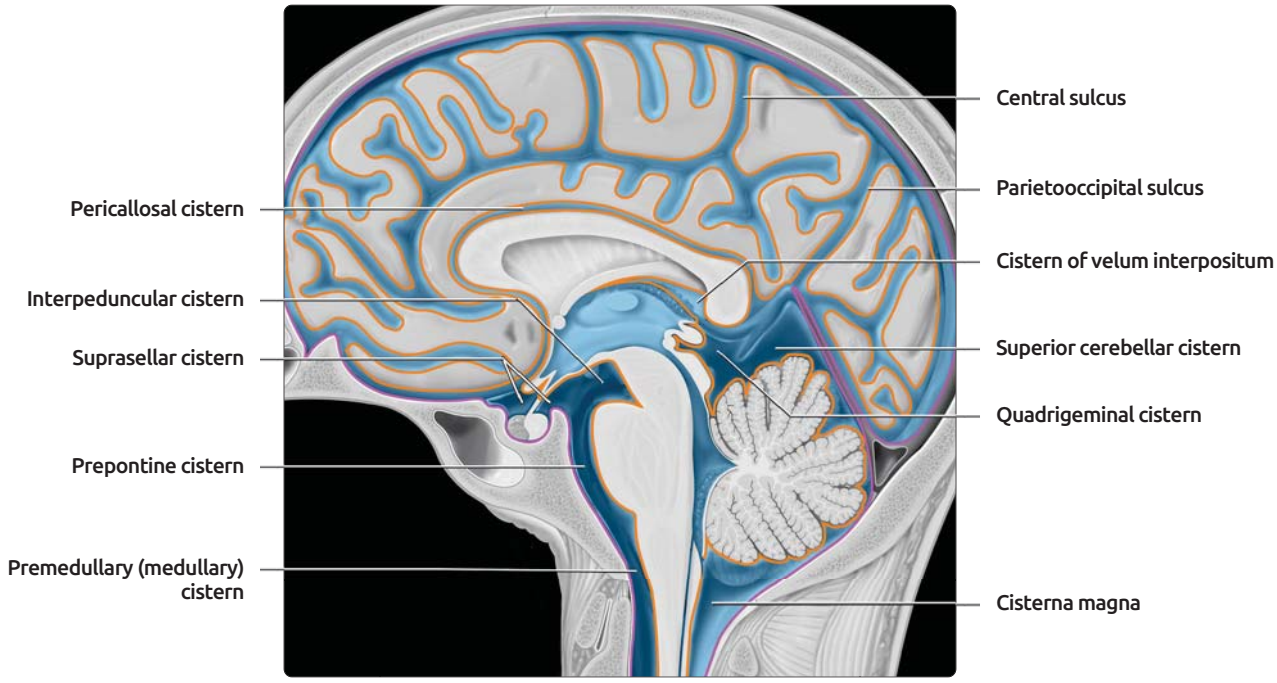

(Top) *Schematic 3D representation of the ventricular system, viewed in the sagittal plane, demonstrates the normal appearance and communicating pathways of the cerebral ventricles.* **(Bottom)** *Sagittal midline graphic through the interhemispheric fissure depicts SASs with CSF (blue) between the arachnoid (purple) and pia (orange). The central sulcus separates the frontal lobe (anterior) from the parietal lobe (posterior). The pia mater is closely applied to the brain surface, whereas the arachnoid is adherent to the dura. The ventricles communicate with the cisterns and subarachnoid space via the foramina of Luschka and Magendie. The cisterns normally communicate freely with each other.*

https://CafePezeshki.IR

(Left) *Axial T2 MR demonstrates normal anatomy at the level of the lateral ventricles. The frontal horns of the lateral ventricle are separated by a tiny septi pellucidi. Note the foramen of Monro connecting the lateral ventricles to the 3rd ventricle.* **(Right)** *Axial T2 MR at the level of the cerebral aqueduct demonstrates the infundibular recess of the 3rd ventricle, mammillary bodies, interpeduncular cistern, and the quadrigeminal cisterns.*

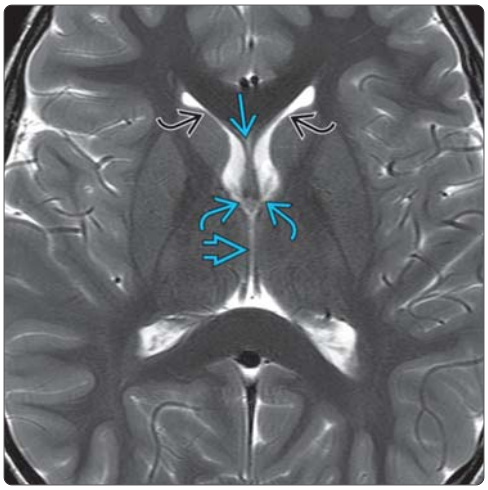

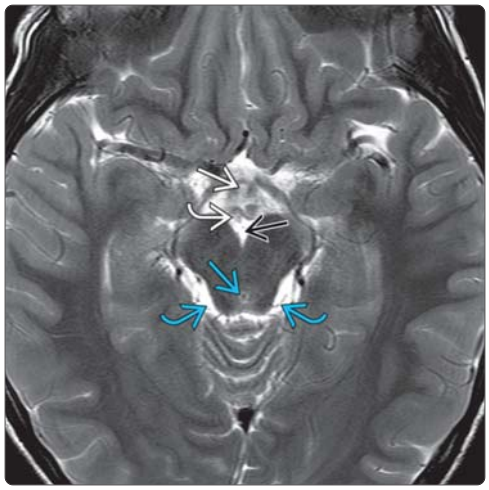

(Left) *Axial T2 MR at the level of the 4th ventricular outlet shows the foramen of Magendie and foramina of Luschka.* **(Right)** *Sagittal T2 SPACE MR image shows the normal flow void due to CSF flow at the cerebral aqueduct and foramen of Magendie. Note the chiasmatic and infundibular recesses of the 3rd ventricle and fastigium of the 4th ventricle.*

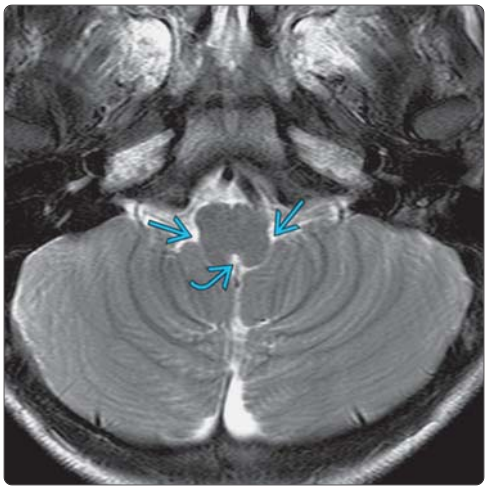

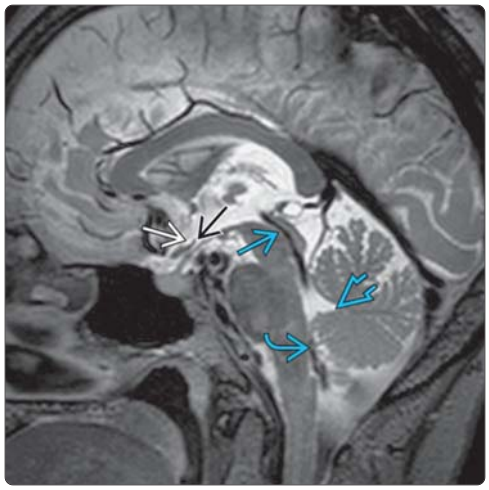

(Left) *Axial T2 MR shows normal asymmetry of the lateral ventricles with the right being larger than the left. The septi pellucidi are slightly bowed and displaced across the midline. When there is lateral ventricular asymmetry it is important to scrutinize the region of foramen of Monro to exclude any obstructing pathology.* **(Right)** *Axial FLAIR image in a patient with hydrocephalus demonstrates a prominent pseudomasses of the 3rd ventricle caused by pulsatile CSF.*

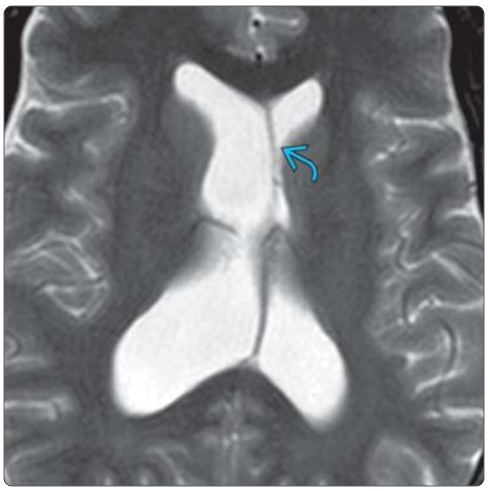

https://CafePezeshki.IR

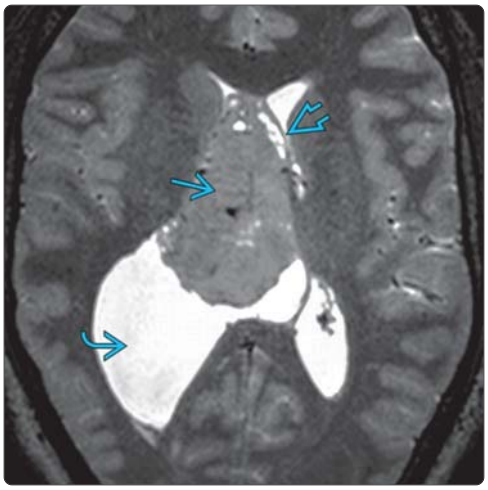

(Left) *Axial T2 MR shows a large ventricular mass in the frontal horn and anterior body of the right lateral ventricle. There is dilatation of the posterior body of the right lateral ventricle and displacement of the septi pellucidi to the left. On histopathology, this was a central neurocytoma.* **(Right)** *Axial FLAIR MR demonstrates an intraventricular neurocysticercosis in the posterior 3rd ventricle with dilatation of the anterior 1/3 and lateral ventricles. Note the mild periventricular interstitial edema*

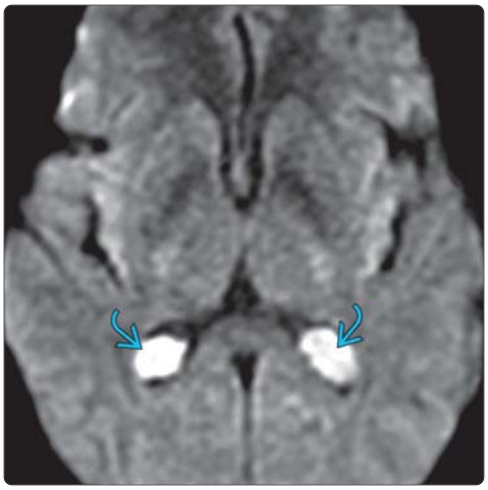

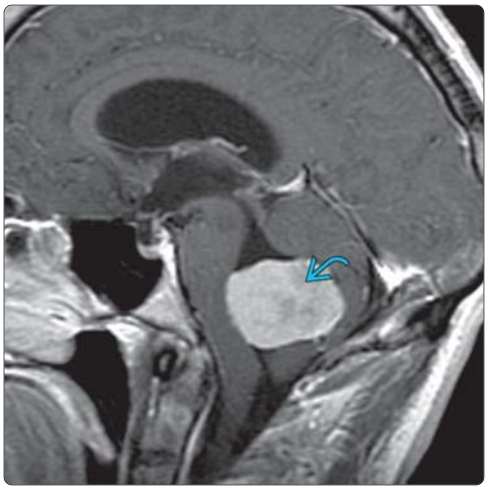

(Left) *Axial DWI shows characteristic large choroid plexus cysts in the atria of both lateral ventricles, within the choroid plexus glomi. Choroid plexus cysts, often called choroid plexus xanthogranuloma, are nonneoplastic noninflammatory cysts. Between 60-80% appear quite bright on DWI, as in this case.* **(Right)** *Sagittal T1 C+ MR shows a large homogenously enhancing 4th ventricular mass, which on pathology was a meningioma. There is dilatation of the ventricular system proximal to the mass.*

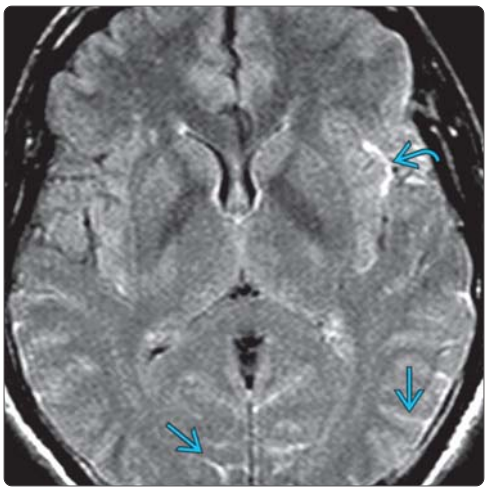

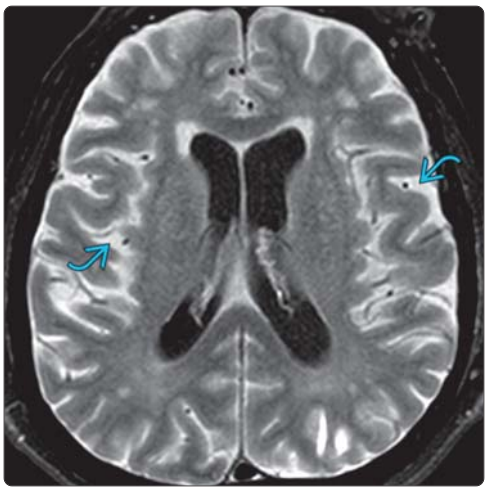

(Left) *Axial FLAIR MR in a patient with acute subarachnoid hemorrhage due to aneurysm rupture shows high signal in the left sylvian fissure and posterior cortical sulci.* **(Right)** *Axial FLAIR MR in a patient with chronic renal disease who received IV gadolinium 48 hours prior shows marked FLAIR hyperintensity in the cortical sulci. Sulcal hyperintensity on FLAIR can be caused by pia-subarachnoid metastases, blood, protein (meningitis), high oxygen content, and retained contrast (renal failure as in this case).*

https://CafePezeshki.IR

KEY FACTS

TERMINOLOGY

- Cystic CSF cavity of septum pellucidum (SP)
  - Occurs ± cavum vergae (CV)

IMAGING

- Elongated finger-shaped CSF collection between lateral ventricles
  - Cavum septi pellucidi (CSP): Between frontal horns of lateral ventricles
  - CV: Posterior extension between fornices
- Size varies from slit like to several mm, occasionally > 1 cm
- SP invariably cystic in fetus
  - Width of fetal CSP increases between 19-27 weeks
  - Plateaus at 28 weeks
  - Gradually closes in rostral direction between 28 weeks and term
  - CSP present in 100% of premature, 85% of term infants
- CSP seen in up to 15-20% of adults

TOP DIFFERENTIAL DIAGNOSES

- Asymmetric lateral ventricles
- Cavum velum interpositum
- Ependymal cyst
- Absent SP

PATHOLOGY

- CSP forms if fetal SP fails to obliterate
- CSP is not "5th ventricle"
- CV is not "6th ventricle"

CLINICAL ISSUES

- Usually asymptomatic, incidental
- Headache (relationship to cyst unclear)
- CSP frequent among athletes with history of repeated traumatic brain injury, such as boxers

DIAGNOSTIC CHECKLIST

- CV almost never occurs without CSP

(Left) *Coronal graphic with axial insert shows classic cavum septi pellucidi (CSP) with cavum vergae (CV).* *Note the finger-like CSF collection between the lateral ventricles.* **(Right)** *Axial T2WI MR shows cavum septi pellucidi as a CSF collection between the leaves of the septum pellucidum.* *Although seen incidentally, some studies have report that CSP is frequent among athletes with a history of repeated traumatic brain injury (TBI), such as boxers, and American professional football players.*

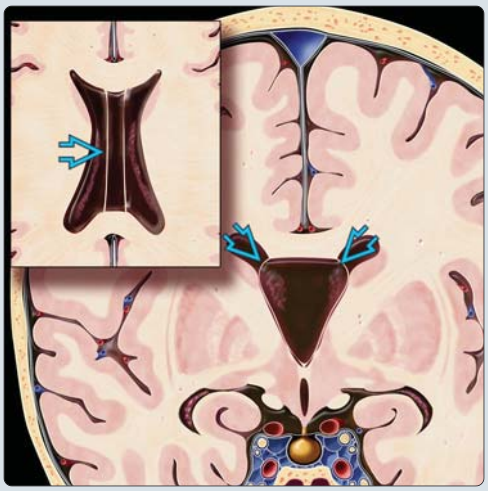

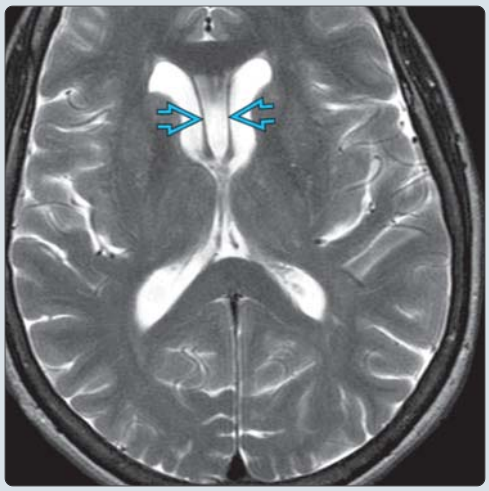

(Left) *Coronal T1WI MR shows a classic large CSP between the frontal horns bowing the leaves of the septum pellucidum laterally.* **(Right)** *Axial FLAIR MR shows a large CSP with CV as a large CSF collection between the leaves of the septum pellucidum continuing directly posteriorly with the CSF collection, splaying the fornices laterally.*

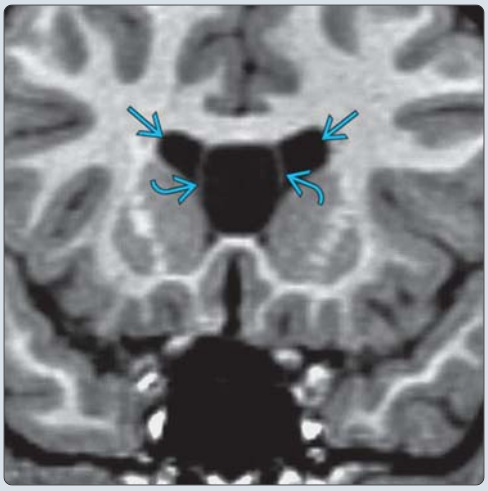

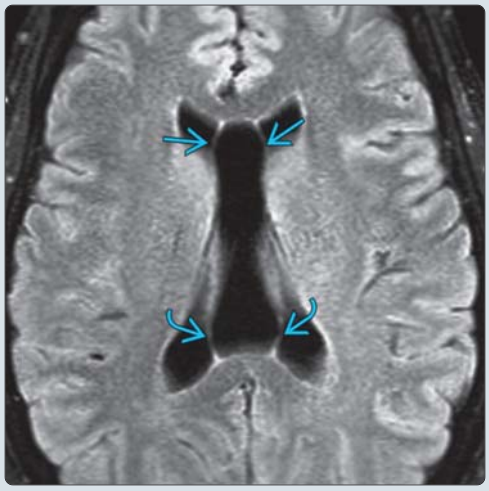

https://CafePezeshki.IR

KEY FACTS

TERMINOLOGY

- Cavum velum interpositum (CVI); cyst of velum interpositum (VI)

IMAGING

- Triangular CSF space
  - Between lateral ventricles, over thalami
  - Apex points toward foramen of Monro
  - Elevates, splays fornices
  - Flattens, displaces internal cerebral veins inferiorly
- Size varies from slit-like linear to triangular to round/ovoid CSF collection
- Isodense/isointense with CSF
  - Suppresses completely on FLAIR
  - Does not restrict on DWI
  - Does not enhance
- US shows hypoechoic midline interhemispheric cyst

TOP DIFFERENTIAL DIAGNOSES

- Normal cistern of velum interpositum
- Cavum septi pellucidi, cavum vergae
- Arachnoid cyst
- Epidermoid cyst

CLINICAL ISSUES

- Can be found at any age
  - Common in infants, rare in adults
- Symptoms
  - Usually asymptomatic, found incidentally
  - Headache (relationship to cyst unclear)
  - Large CVI can obstruct normal CSF flow; treated by endoscopic fenestration

DIAGNOSTIC CHECKLIST

- CSF-like "cyst" could be epidermoid
- Include FLAIR and DWI to distinguish between CVI, epidermoid cyst

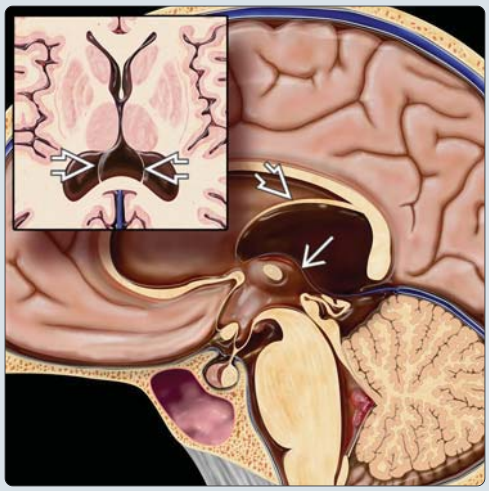

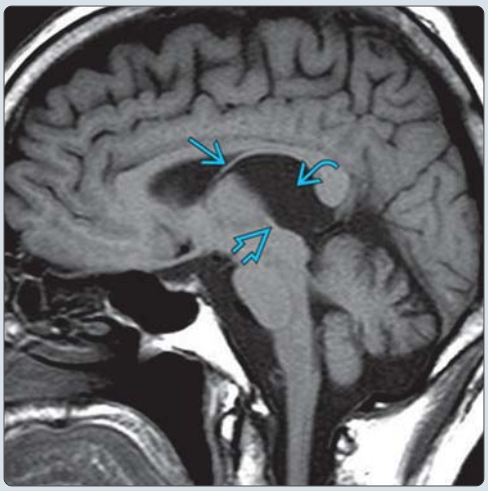

(Left) *Sagittal graphic with axial insert shows a cavum velum interpositum (CVI). Note the elevation and splaying of the fornices. Also noted is the inferior displacement of the internal cerebral veins and 3rd ventricle.* **(Right)** *Sagittal T1WI MR shows a classic CVI as a CSF-like enlargement that elevates the fornix and flattens and displaces the internal cerebral vein inferiorly. These are usually asymptomatic, however large ones can cause CSF obstruction and can be treated by fenestration.*

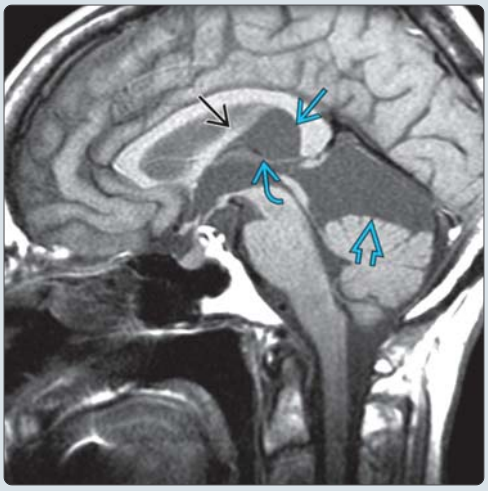

(Left) *Axial T2WI MR in a 37-year-old man with headaches shows a classic cavum velum interpositum with a triangular-shaped CSF collection between the lateral ventricles spreading the fornices laterally.* **(Right)** *Sagittal T1WI MR shows a variant CVI that elevates the fornix, flattens the internal cerebral vein, and extends into the quadrigeminal and suprasellar cisterns. This case probably represents an arachnoid cyst of the cavum velum interpositum.*

https://CafePezeshki.IR

KEY FACTS

TERMINOLOGY

- Idiopathic enlargement of SAS during 1st year of life

IMAGING

- Enlarged SAS and ↑ head circumference (> 95%)
- CSF space follows (not flattens) gyral contour
- Right and left subarachnoid spaces are symmetric
- Macrocephaly, frontal bossing on radiography
- CECT demonstrates veins traversing SAS
- Spaces must follow CSF signal on all MR sequences

TOP DIFFERENTIAL DIAGNOSES

- Atrophy
- Acquired extraventricular obstructive hydrocephalus (EVOH)
- Nonaccidental trauma (NAT)

PATHOLOGY

- Underlying mechanism poorly understood
- Disproportion between rapidly increasing CSF secretion rate and immature CSF drainage pathways is most commonly held theory

CLINICAL ISSUES

- Increasing neurological signs or lack of development is not consistent with benign enlarged SAS
- No signs of elevated intracranial pressure; normal pressure on lumbar puncture
- Self-limited; SAS enlargement resolves without therapy by 12-24 months
- No treatment necessary
- Majority are physically, neurologically, & developmentally normal on follow-up

DIAGNOSTIC CHECKLIST

- Consider nonaccidental trauma if enlarged SAS atypical in any way
- Crucial: Know head circumference

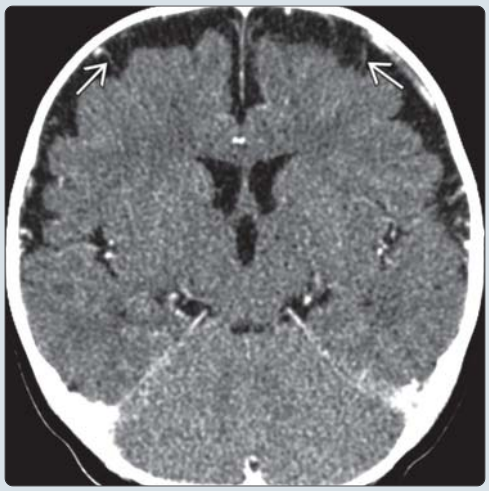

(Left) *Axial graphic shows classic enlarged subarachnoid spaces in a macrocephalic infant with symmetric bifrontal enlargement, multiple bridging veins ➡, and mild ventriculomegaly. The craniocortical distance between the brain and calvaria is ≥ 5 mm.* **(Right)** *Axial CECT shows enlarged subarachnoid spaces with enhancing traversing veins ➡ and mildly enlarged ventricles in a macrocephalic infant. This benign condition usually peaks at 7 months and resolves spontaneously by 12-24 months of age.*

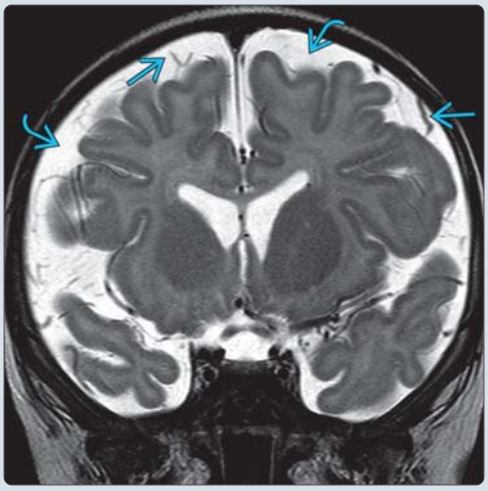

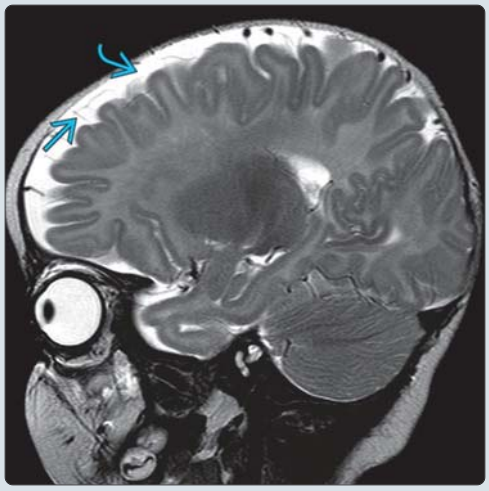

(Left) *Coronal T2 MR shows enlarged subarachnoid spaces ⇨ overlying the frontal lobes. Note the flow voids ⇨ of the traversing vessels in the subarachnoid space. This helps to distinguish from enlarged subdural spaces.* **(Right)** *Sagittal MR in the same patient again demonstrates enlarged frontal subarachnoid spaces ⇨ and multiple bridging vessels ⇨. The definition of normal subarachnoid space width varies in literature and there is no consensus. Craniocortical width > 10 mm is considered an absolute sign of pathology.*

https://CafePezeshki.IR

TERMINOLOGY

Abbreviations

- Subarachnoid space (SAS) enlargement

Synonyms

- Benign subarachnoid space enlargement
- Benign external hydrocephalus, benign extracerebral fluid collections of infancy
- Benign communicating hydrocephalus, physiologic extraventricular obstructive hydrocephalus
- Benign macrocrania of infancy

Definitions

- Idiopathic enlargement of SAS during 1st year of life

IMAGING

General Features

- Best diagnostic clue
  - Enlarged SAS and increased head circumference (> 95%)
- Location
  - Subarachnoid space
- Size
  - Definition of normal SAS width varies in literature: No consensus
  - Craniocortical width (CCW): Widest vertical distance between brain and calvaria
    - CCW upper limits range from 3 to 5 mm
    - Infants < 1 year range from 4 to 10 mm
    - > 10 mm considered absolute sign of pathology
  - Sinocortical width (SCW): Widest distance between lateral wall of superior sagittal sinus and brain surface
    - Normal range 2-10 mm
  - Interhemispheric: Widest distance between hemispheres
    - Enlargement defined as > 8.5 mm
  - **Note**: Normal maximum width peaks at 28 postnatal weeks (7 months) of life
- Morphology
  - CSF space follows (not flattens) gyral contour
  - Right and left subarachnoid spaces are symmetric

Radiographic Findings

- Radiography
  - Macrocephaly, frontal bossing

CT Findings

- NECT
  - Widening bifrontal/anterior interhemispheric SAS
  - Enlarged cisterns (especially suprasellar/chiasmatic)
  - Normal or mildly enlarged ventricles
  - Sulci generally normal (especially posteriorly)
  - Postural unilateral lambdoid flattening is common
  - Posterior fossa normal
- CECT
  - Demonstrates veins traversing SAS
  - No abnormal enhancement of meninges

MR Findings

- T1WI
  - Similar to NECT
- T2WI
  - No abnormal brain tissue or signal abnormalities
  - Single layer of fluid (SAS) with traversing vessels
  - Normal flow void in aqueduct
  - Normal or mildly enlarged ventricles
- FLAIR
  - Homogeneous hypointense fluid in SAS (follows normal CSF signal)
- T2* GRE
  - No blood products
- DWI
  - No restriction, normal diffusivity
- T1WI C+
  - Enhancing veins traverse SAS
- Fetal MR: Distribution of fluid/ventricular prominence related to positioning of fetus
  - Usually frontal prominence after birth due to position of child lying on back for scan

Ultrasonographic Findings

- Grayscale ultrasound
  - Enlarged frontal subarachnoid space
  - CCW and sinocortical width (SCW) < 10 mm in neurologically normal infants
  - Veins as "dots" floating in SAS
- Pulsed Doppler
  - Increased cerebral blood flow may identify "progressive" cases
- Color Doppler
  - Veins traverse SAS

Angiographic Findings

- Conventional
  - Widened space between skull and arteries of brain surface

Nonvascular Interventions

- Myelography
  - Cisternography confirms communication of SAS, but not necessary

Imaging Recommendations

- Best imaging tool
  - MR to exclude chronic subdural collections
- Protocol advice
  - Doppler sonography: Documents veins traversing SAS
  - MR or CECT: To exclude underlying etiology
  - MR: To exclude chronic subdural collections
    - SAS isointense with CSF on all sequences if benign
  - Phase-contrast MR shows normal intraventricular CSF flow
  - After diagnosis, best follow-up = tape measure and assess for normal development; not imaging

DIFFERENTIAL DIAGNOSIS

Atrophy

- Small head circumference (HC)
  - Forehead "pointed" due to metopic fusion
- Patients with benign SAS enlargement have large head
  - Forehead "flat" due to frontal bossing
- Knowledge of HC critical for diagnosis

https://CafePezeshki.IR

Acquired Extraventricular Obstructive Hydrocephalus (EVOH)

- Often hemorrhagic/postinflammatory/neoplastic
  - Density of extraaxial collection greater than CSF
- Achondroplasia and other skull base anomalies
  - Coarctation of foramen magnum (narrow)
- Intermittent intracranial pressure waves

Nonaccidental Trauma (NAT)

- Predisposition to bleed with minor trauma is controversial
  - Venous "stretching" implicated

Glutaric Aciduria Type 1

- Enlarged sylvian fissures with delayed myelination
- T2-hyperintense basal ganglia

Elevated Venous Pressures

- May be due to cardiac issues or bilateral transverse sinus/jugular vein thrombosis

PATHOLOGY

General Features

- Etiology
  - Underlying mechanism poorly understood
  - Disproportion between rapidly increasing CSF secretion rate and immature CSF drainage pathways is most commonly held theory
    - CSF primarily drained via extracellular space → capillaries
    - Arachnoid granulations (AGs) do not mature until 18 months
    - AGs are then displaced into veins (as Starling-type resistors)
    - AGs regulate pulse pressure/venous drainage CSF when fontanels close
    - Benign SAS enlargement usually resolves at that time
- Genetics
  - No documented genetic predisposition, although common in benign familial macrocrania
    - Family history of macrocephaly > 80%
- Associated abnormalities
  - Possibility of increased risk for bridging vein injury and resultant subdural hematoma in absence of trauma
  - May constitute a significant risk factor for development of de novo arachnoid cysts

Staging, Grading, & Classification

- Danger signs
  - Elevated intracranial pressure (ICP)
  - Rapid enlargement of head circumference
  - Increasing lack of development or neurological signs
  - Onset or persistence > 1 year old

Gross Pathologic & Surgical Features

- Deep/prominent but otherwise normal-appearing SAS
- No pathologic membranes

Microscopic Features

- Ependymal damage not seen in benign SAS enlargement

CLINICAL ISSUES

Presentation

- Most common signs/symptoms
  - Macrocrania: Head circumference > 95%
  - Frontal bossing
  - No signs of elevated ICP; normal pressure on lumbar puncture
- Other signs/symptoms
  - Possible mild developmental delay (50%), which usually resolves
- Clinical profile
  - Family history of benign macrocephaly common
  - Male infants, sometimes late to walk

Demographics

- Age
  - Usually present at 3-8 months
- Gender
  - 80% male
- Epidemiology
  - Reported on 2-65% of neuroimaging for macrocrania < 1 year old

Natural History & Prognosis

- Enlarged SAS → ↑ suture/calvarial malleability/compliance → predisposes to posterior plagiocephaly
- Self-limited; SAS enlargement resolves without therapy by 12-24 months
  - Spontaneous resolution of spaces and symptoms
- Calvaria outgrows brain, brain eventually catches up
- Macrocephaly often persists
- Majority are physically, neurologically, and developmentally normal on follow-up

Treatment

- No treatment necessary
- Normal outcome (developmental delay resolves as prominent SAS resolves)

DIAGNOSTIC CHECKLIST

Consider

- Nonaccidental injury if enlarged SAS atypical in any way

Image Interpretation Pearls

- Crucial: Know head circumference
- Consider enhanced CT or MR to confirm veins traversing SAS and search for membranes or nonisointense fluid collections (chronic subdural)

SELECTED REFERENCES

1. Halevy A et al: Development of Infants With Idiopathic External Hydrocephalus. J Child Neurol. ePub, 2014
2. Kuruvilla LC: Benign enlargement of sub-arachnoid spaces in infancy. J Pediatr Neurosci. 9(2):129-31, 2014
3. Marino MA et al: Benign external hydrocephalus in infants. A single centre experience and literature review. Neuroradiol J. 27(2):245-50, 2014
4. Mattei TA et al: Benign extracerebral fluid collection in infancy as a risk factor for the development of de novo intracranial arachnoid cysts. J Neurosurg Pediatr. 12(6):555-64, 2013

https://CafePezeshki.IR

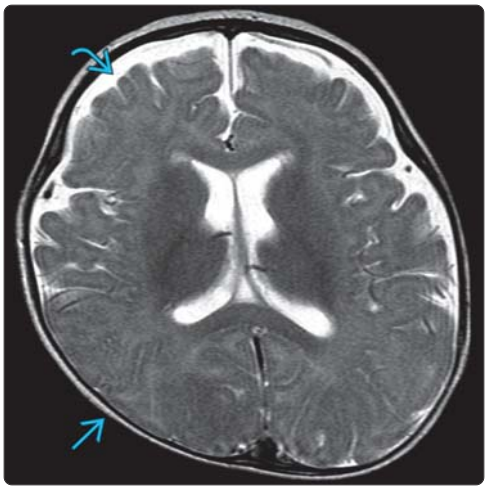

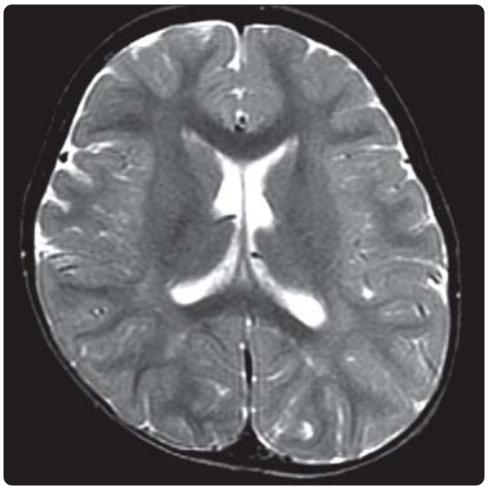

(Left) *Axial T2WI MR shows enlarged frontal and anterior interhemispheric pericerebral fluid spaces, mild ventriculomegaly, and right-sided posterior plagiocephaly in a 7-month-old male with macrocephaly.* **(Right)** *Axial T2WI MR follow-up of the same patient at 17 months of age shows that the pericerebral and anterior interhemispheric fluid spaces have normalized. A family history of benign macrocephaly is common in these patients.*

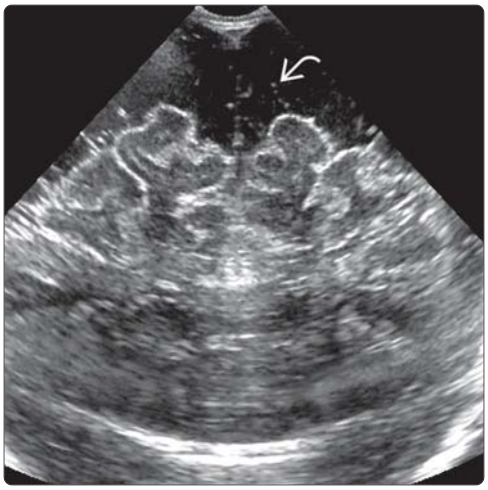

(Left) *Coronal brain ultrasound shows increased sinocortical distance in this case of markedly enlarged subarachnoid spaces in this young infant with macrocephaly. Echogenic foci within the CSF collection correspond to bridging veins. CSF spaces are most prominent at 7 months of life.* **(Right)** *Coronal color Doppler ultrasound demonstrates venous structures traversing the dilated subarachnoid space. Enlarged subarachnoid spaces are related to immature CSF drainage pathways.*

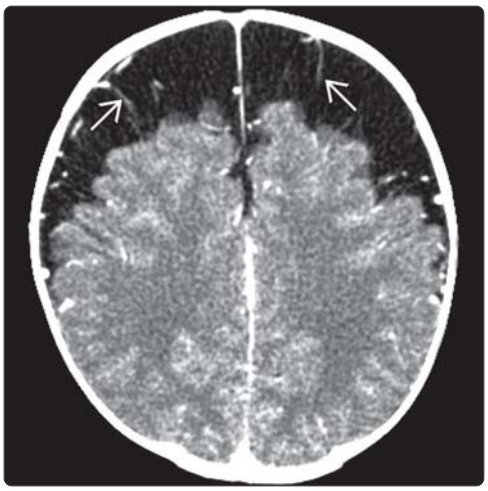

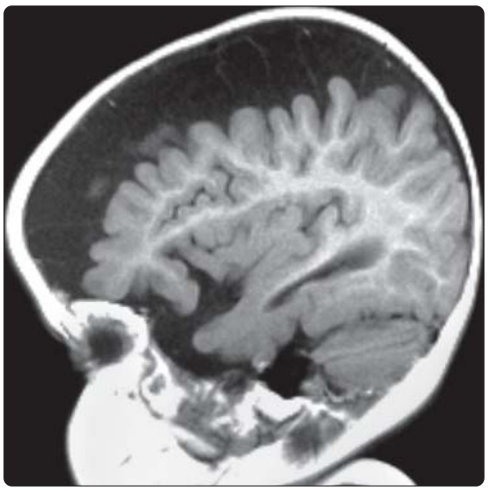

(Left) *Axial CECT shows markedly enlarged frontal subarachnoid spaces with traversing bridging veins. The distance between the brain surface and the dura is 1.5 cm.* **(Right)** *Sagittal T1WI MR shows markedly enlarged subarachnoid spaces. Note the large calvarial size compared to the face, related to macrocephaly. Bridging veins traverse the enlarged subarachnoid spaces. It is important to ensure that the fluid follows CSF on all sequences to exclude nonaccidental trauma.*

https://CafePezeshki.IR

KEY FACTS

TERMINOLOGY

- Intraventricular obstructive hydrocephalus (IVOH) = obstruction proximal to foramina of Luschka, Magendie
  - Acute (aIVOH)
  - Chronic "compensated" (cIVOH)

IMAGING

- aIVOH = "ballooned" ventricles plus indistinct ("blurred") margins
  - "Fingers" of CSF extend into periventricular WM
  - Most striking around ventricular horns (periventricular "halos")
  - After decompression, corpus callosum may show hyperintensity
- cIVOH = "ballooned" ventricles without periventricular "halo"

TOP DIFFERENTIAL DIAGNOSES

- Ventricular enlargement 2° to parenchymal loss
- Normal pressure hydrocephalus
- Extraventricular obstructive hydrocephalus
- Choroid plexus papilloma
- Longstanding overt ventriculomegaly in adults

PATHOLOGY

- Intraventricular obstruction to CSF flow
  - CSF production continues, ventricular pressure ↑
- Ventricles expand, compress adjacent parenchyma
- Periventricular interstitial fluid increases
  - Leads to myelin vacuolization, destruction
- Pathology varies depending on obstruction etiology

CLINICAL ISSUES

- Headache, papilledema (aIVOH)
- Nausea, vomiting, diplopia (6th nerve palsy)

DIAGNOSTIC CHECKLIST

- Size of ventricles generally correlates poorly with intracranial pressure

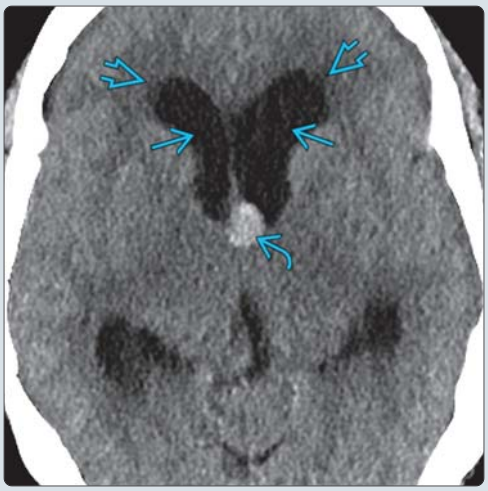

(Left) *Axial NECT in a patient with headache demonstrates a classic colloid cyst at the foramen of Monro causing intraventricular obstructive hydrocephalus with dilatation of both lateral ventricles. Note the periventricular hypodensities due to transependymal leakage of CSF.* **(Right)** *Axial FLAIR in a patient with tuberous sclerosis shows large subependymal giant cell astrocytoma causing obstructive hydrocephalus with mild periventricular edema. Note the subtle hyperintensity in the occipital lobe tuber.*

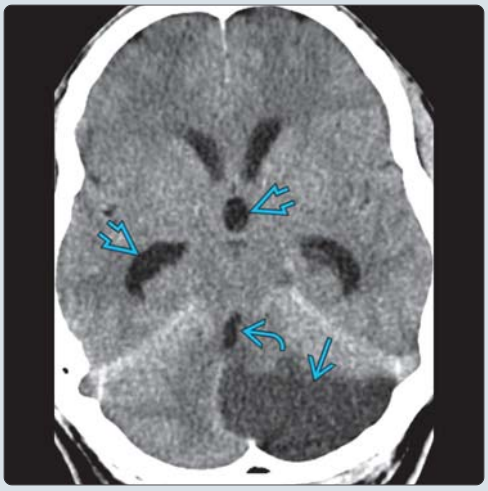

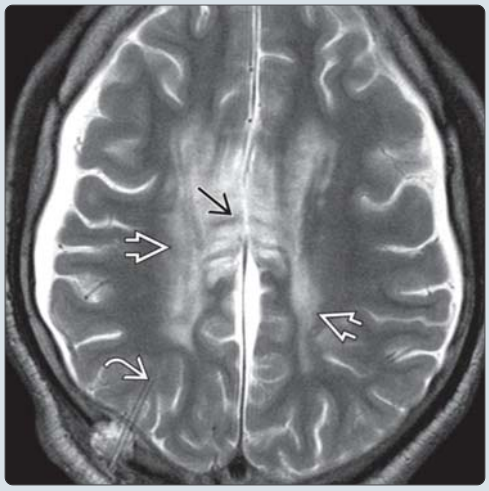

(Left) *Axial CECT demonstrates a subacute left posterior inferior cerebellar infarct causing mass effect on the 4th ventricle and resulting in obstructive hydrocephalus.* **(Right)** *Axial T2WI MR in a patient with corpus callosum impingement syndrome, after shunting for severe IVOH, shows a shunt tube, bilateral subdural fluid collections, and "striated" hyperintensity in the corpus callosum with somewhat less striking changes in the periventricular WM. (Courtesy S. Candy, MD.)*

https://CafePezeshki.IR

TERMINOLOGY

Abbreviations

- Intraventricular obstructive hydrocephalus (IVOH)
  - Acute IVOH (aIVOH)
  - Chronic "compensated" IVOH (cIVOH)

Synonyms

- "Noncommunicating" hydrocephalus

Definitions

- Enlarged ventricles caused by obstruction proximal to 4th ventricular outflow foramina (of Luschka, Magendie)

IMAGING

General Features

- Best diagnostic clue
  - aIVOH
    - "Ballooned" ventricles with indistinct ("blurred") margins
  - cIVOH
    - "Ballooned" ventricles without periventricular "halo"
- Size
  - Bifrontal horn to intracranial diameter ratio > 0.33
  - Temporal horn width > 3 mm
- Morphology
  - Varies with site, duration of blockage
  - Global/focally enlarged ventricle(s) ± elevated ICP
  - Ventricles proximal to obstruction enlarge, appear more rounded
  - Look for enlarged anterior recesses of 3rd ventricle

CT Findings

- NECT
  - Large ventricles proximal to obstruction
    - aIVOH
      - "Ballooned" ventricles with periventricular low-density "halo"
    - cIVOH
      - "Ballooned" ventricles, periventricular "halo"
  - Basal cisterns, sulci compressed/obliterated

MR Findings

- T1WI
  - Lateral ventricles enlarged
  - Corpus callosum (CC) thinned, stretched upward
    - May be impinged against falx
    - Impaction may cause pressure necrosis
  - Fornix, internal cerebral veins (ICV) displaced downward
  - Enlarged 3rd ventricle often herniated into expanded sella
  - Funnel-shaped aqueduct of Sylvius in aqueductal stenosis
- T2WI
  - aIVOH
    - "Fingers" of CSF-like hyperintensity extend into periventricular white matter (WM), most striking around ventricular horns (periventricular "halos")
    - Disturbed/turbulent CSF flow
    - Absent aqueductal "flow void" common
    - CC may appear hyperintense
  - cIVOH
    - Large ventricles, normal CSF pressure
    - No periventricular "halo"
    - CC may show hyperintensity after decompression (15% of shunted IVOH cases)
  - Thin section T2WI, FIESTA or CISS sequences
    - exquisitely delineate CSF spaces
    - May demonstrate subtle abnormalities not detected on standard images
- T1WI C+
  - Neoplasm causing IVOH may enhance
  - aIVOH may cause leptomeningeal vascular stasis, enhancement
    - Can mimic meningitis, metastases

Other Modality Findings

- Contrast-enhanced ventriculography
  - MR/CT used to identify site of obstruction, status of 3rd ventriculostomies
  - MR can be used for assessing CSF flow
- Cardiac-gated phase contrast MR
  - May show absent aqueductal CSF flow

Imaging Recommendations

- Best imaging tool
  - MR with contrast to evaluate cause of CSF obstruction
- Protocol advice
  - 3D FEISTA/CISS
    - Decreases CSF flow artifact
    - Allows better delineation of ventricular contour, septa

DIFFERENTIAL DIAGNOSIS

Ventricular Enlargement Secondary to Parenchymal Loss

- Old term: Ex vacuo hydrocephalus (not used)
- Age related (ventricular volume increases 1.2-1.4 mL/after 60 years)
  - Ischemia/infarction, trauma, infection, toxic
- Obtuse frontal angle (> 110°)
- Diffuse/focal enlargement of sulci, cisterns
- Normal lateral ventricles can be asymmetric (related to handedness, not gender)
- May correlate with some psychiatric disorders (e.g., schizophrenia)

Normal Pressure Hydrocephalus

- Progressive dementia, gait disturbance, incontinence
- Ventricular dilation with normal CSF pressure
- Sulci normal/minimally enlarged
- Increased CSF displacement through aqueduct
- MRS shows lactate peak

Extraventricular Obstructive Hydrocephalus (EVOH)

- Dilated ventricles due to mismatch between CSF formation, absorption
- Decreased CSF absorption through arachnoid villi
- Subarachnoid hemorrhage most common cause
  - Others: Meningitis, carcinomatosis, granulomatous disease

https://CafePezeshki.IR

Choroid Plexus Papilloma

- Accounts for 2-5% of childhood intracranial tumors
- Child < 5 years with ↑ ICP
- Most common lateral ventricle trigone
- May "overproduce" CSF
- Hemorrhage, tumor spread may cause IVOH

Longstanding Overt Ventriculomegaly in Adults

- Early childhood onset or longstanding progression of hydrocephalus into adulthood
- Markedly enlarged ventricles, high ICP

Benign Enlargement of Subarachnoid Spaces and Ventricles

- Seen in association with macrocephaly in infants
- Not associated with developmental delay

PATHOLOGY

General Features

- Etiology
  - Normal CSF production = 0.20-0.35 mL/min
    - Capacity of lateral, 3rd ventricles in adult = 20 mL
    - Total volume of CSF in adult = 120 mL
  - Intraventricular obstruction to CSF flow; as CSF production continues, ventricular fluid pressure ↑
  - Ventricles expand, compress adjacent parenchyma; stretching may rupture/open ependymal cell junctions
  - Periventricular interstitial fluid increases → myelin destruction
  - Etiology depends on site
    - Foramen of Monro
      - Colloid cyst
      - Subependymal nodule, tuberous sclerosis complex
      - Subependymal giant cell astrocytoma
    - 3rd ventricle
      - Pituitary macroadenoma
      - Craniopharyngioma
    - Aqueduct of Sylvius
      - Aqueductal stenosis
      - Tectal glioma
      - Pineal region tumors
    - 4th ventricle
      - Medulloblastoma, ependymoma
      - Glioma, pilocytic astrocytoma, hemangioblastoma
      - Cerebellar infarct
      - Congenital anomalies (Chiari malformations, Dandy-Walker malformations, rhombencephalosynapsis)
    - Metastasis, neurocysticercosis, or meningioma can occur at multiple intraventricular locations
- Genetics
  - Cell adhesion molecule L1 (*L1CAM*) only gene recognized to cause human hydrocephalus
    - Located on X chromosome (Xq28)

Gross Pathologic & Surgical Features

- Focal/generalized ventricular enlargement
- Ependyma, adjacent WM are secondarily injured
- Variable pathology depending on causative factor

Microscopic Features

- Increased periventricular extracellular space
- Ependymal lining damaged or lost; surrounding WM becomes pale and rarefied

CLINICAL ISSUES

Presentation

- Most common signs/symptoms
  - Headache, papilledema (aIVOH)
  - Nausea, vomiting, diplopia (6th nerve palsy)
- Clinical profile
  - Varies with etiology, severity, age of onset

Demographics

- Age
  - May be any age from in utero (congenital hydrocephalus) to adult
- Epidemiology
  - Epidemiological data varies widely, depending upon etiology and type of hydrocephalus

Natural History & Prognosis

- Usually progressive unless treated

Treatment

- Medical management to delay surgical intervention
- CSF diversion (shunt), endoscopic intervention, and ventriculostomy
- Surgery to alleviate primary cause of obstruction
- Most common neurosurgical procedure in children = CSF shunting for hydrocephalus

DIAGNOSTIC CHECKLIST

Consider

- Longstanding aqueductal stenosis can be caused by slow-growing tectal tumor

Image Interpretation Pearls

- Size of ventricles generally correlates poorly with intracranial pressure
- Pulsatile CSF may create confusing signal intensity, even mimic intraventricular mass
- Ventricular asymmetry can be normal variant
- If seen with absent septum pellucidum in fetus/neonate, look for vermis (r/o rhombencephalosynapsis)

SELECTED REFERENCES

1. Algin O et al: Assessment of third ventriculostomy patency with the 3D-SPACE technique: a preliminary multicenter research study. J Neurosurg. 122(6):1347-55, 2015
2. Russo N et al: Endoscopic Approaches to Intraventricular Lesions. J Neurol Surg A Cent Eur Neurosurg. ePub, 2015
3. Flannery AM et al: Pediatric hydrocephalus: systematic literature review and evidence-based guidelines. Part 1: Introduction and methodology. J Neurosurg Pediatr. 14 Suppl 1:3-7, 2014
4. Dinçer A et al: Radiologic evaluation of pediatric hydrocephalus. Childs Nerv Syst. 27(10):1543-62, 2011
5. Oi S: Classification of hydrocephalus: critical analysis of classification categories and advantages of "Multi-categorical Hydrocephalus Classification" (Mc HC). Childs Nerv Syst. 27(10):1523-33, 2011
6. Dinçer A et al: Is all "communicating" hydrocephalus really communicating? Prospective study on the value of 3D-constructive interference in steady state sequence at 3T. AJNR Am J Neuroradiol. 30(10):1898-906, 2009

https://CafePezeshki.IR

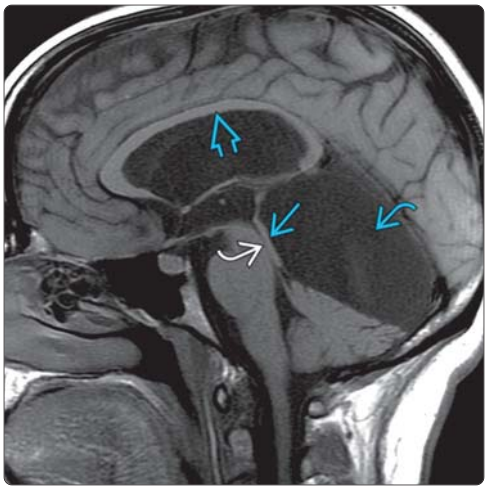

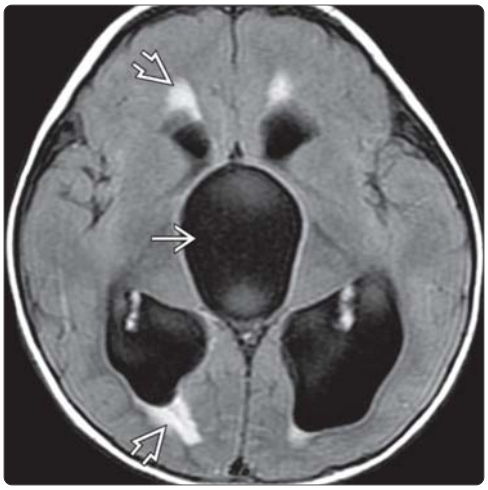

(Left) *Sagittal T1 MR shows a large arachnoid cyst in the superior cerebellar cistern causing severe mass effect on the tectal plate and aqueduct. There is dilatation of the 3rd and lateral ventricles with thinning of the corpus callosum.* **(Right)** *Axial FLAIR MR shows massive enlargement of the 3rd and lateral ventricles by a CSF-like mass within the 3rd ventricle. There is periventricular interstitial edema. At surgery, an ependymal cyst of the 3rd ventricle was found and fenestrated.*

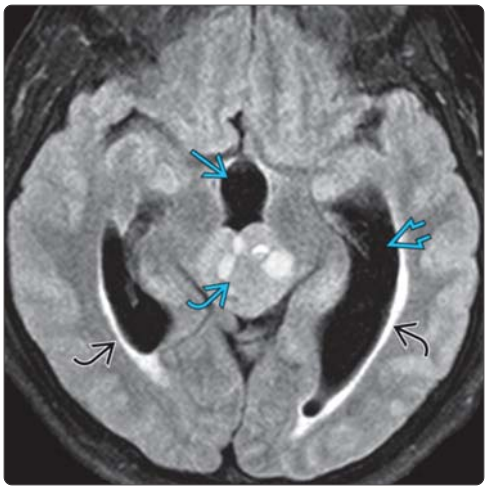

(Left) *Axial FLAIR MR in a patient with a pineal region germinoma shows intraventricular obstructive hydrocephalus with dilatation of the 3rd and lateral ventricles. Note the periventricular FLAIR hyperintensity due to transependymal CSF leakage.* **(Right)** *Sagittal T1WI MR reveals typical findings in aqueductal stenosis: Funnel-shaped aqueduct of Sylvius, normal 4th ventricle, thinned and stretched corpus callosum, and downward displacement of the floor of the 3rd ventricle.*

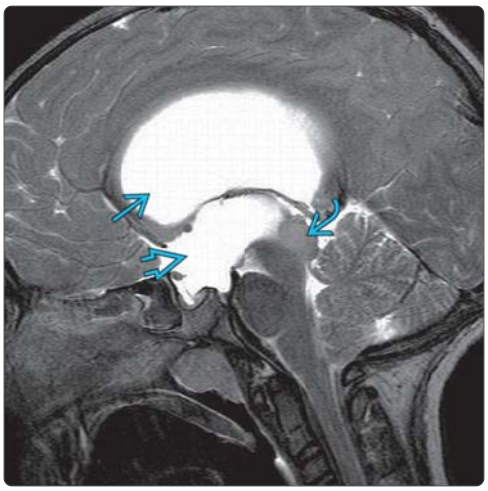

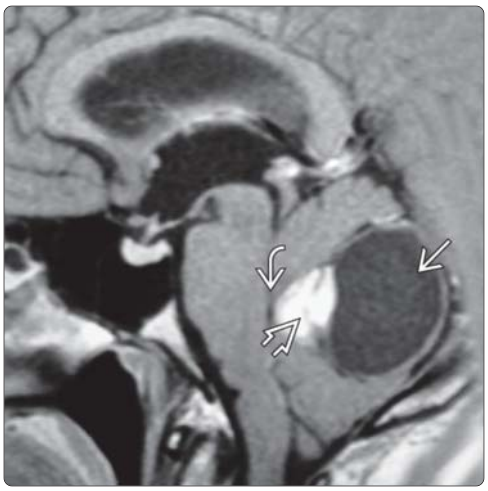

(Left) *Sagittal T2 MR demonstrates an enlarged T2 hyperintense tectal plate glioma, which causes obstruction at the aqueduct and dilatation of the lateral and 3rd ventricles.* **(Right)** *Sagittal T1WI C+ MR shows a cyst with an enhancing mural nodule of hemangioblastoma in the vermis, causing severe effacement of the 4th ventricle and obstructive hydrocephalus.*

https://CafePezeshki.IR

KEY FACTS

TERMINOLOGY

- Extraventricular obstructive hydrocephalus (EVOH): Enlarged ventricles due to mismatch between CSF formation, absorption
- Synonym: "Communicating" hydrocephalus

IMAGING

- Impaired absorption of CSF distal to 4th ventricle outlet foramina
- Ventricular size varies with duration of obstruction
- All ventricles enlarged with no intraventricular obstructive cause
- Lateral, 3rd, and 4th ventricles dilated
- ± periventricular white matter interstitial edema
- ± abnormal density/intensity of cisternal CSF ± leptomeningeal enhancement

TOP DIFFERENTIAL DIAGNOSES

- Intraventricular obstructive hydrocephalus
- Ventricular enlargement 2° to parenchymal loss
- Normal pressure hydrocephalus

PATHOLOGY

- Hemorrhage → fibrosis/obstruction of subarachnoid space
  - Most common cause of EVOH
- Other etiologies include suppurative meningitis, neoplastic or inflammatory exudates
- Subarachnoid hemorrhage (SAH), exudates may fibrose/occlude subarachnoid space, reduce CSF pulsations

CLINICAL ISSUES

- Headache, papilledema
- Nausea, vomiting, diplopia (cranial nerve palsy)

DIAGNOSTIC CHECKLIST

- EVOH: Generalized ventricular enlargement with abnormal density/intensity in basal cisterns ± leptomeningeal enhancement

(Left) *Axial NECT shows acute subarachnoid hemorrhage in the basal cisterns and sylvian fissures. There is early extraventricular obstructive hydrocephalus with mild periventricular hypodensity due to interstitial edema.* **(Right)** *Axial T1WI C+ MR shows extensive leptomeningeal enhancement of the basal cisterns in neurosarcoidosis. Notice the early communicating hydrocephalus with the dilated 3rd ventricle and temporal horns.*

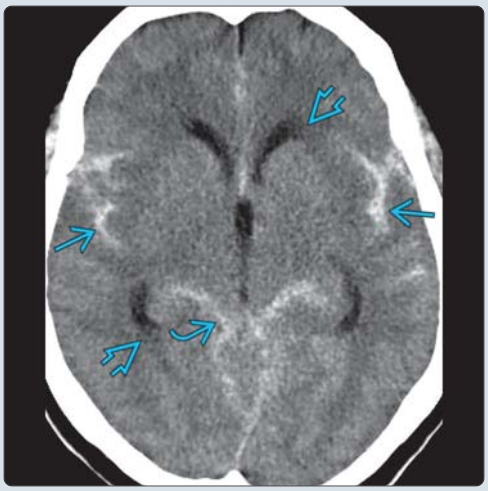

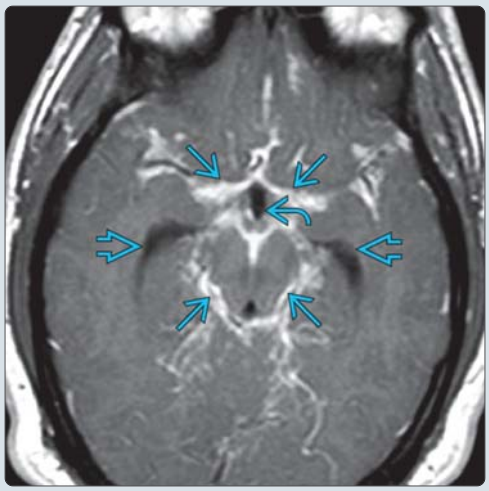

(Left) *Axial T2 MR in a 21-year-old patient with a remote history of meningitis shows chronic "compensated" extraventricular communicating hydrocephalus with marked dilatation of the lateral and 3rd ventricles.* **(Right)** *Sagittal T1 MR in the same patient shows a patent widened cerebral aqueduct and foramen of Magendie with dilatation 4th ventricle. In long standing "compensated" hydrocephalus, there is no periventricular interstitial edema around the ventricles, as in this case.*

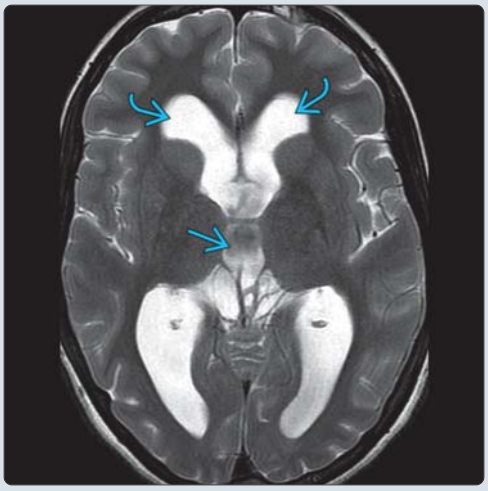

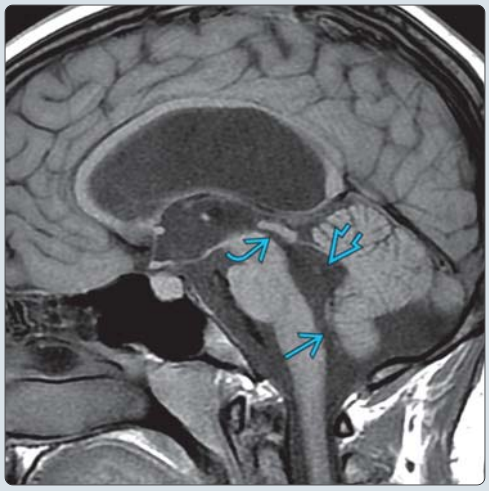

https://CafePezeshki.IR

TERMINOLOGY

Abbreviations

- Extraventricular obstructive hydrocephalus (EVOH)

Synonyms

- "Communicating" hydrocephalus

Definitions

- Enlarged ventricles due to mismatch between CSF formation, absorption

IMAGING

General Features

- Best diagnostic clue
  - Lateral, 3rd, and 4th ventricles all dilated
  - ± abnormal density/intensity of cisternal CSF ± leptomeningeal enhancement
- Location
  - Obstruction distal to 4th ventricle outlet foramina
- Size
  - Bifrontal horn to intracranial diameter ratio > 0.33
  - Temporal horn width > 3 mm
- Morphology
  - All ventricles enlarged
    - Generally proportionate, symmetrical increase
    - No intraventricular obstructive cause

CT Findings

- NECT
  - Variable ventricular dilatation ± basal cisterns effaced
  - If subarachnoid hemorrhage (SAH), look for hyperdense CSF
- CECT
  - Look for sulcal/cisternal enhancement

MR Findings

- T1WI
  - "Dirty" CSF, ventricular dilatation
- T2WI
  - Dilated ventricles ± periventricular white matter interstitial edema
  - Effacement of cortical sulci
  - Hyperintense CSF-SAH, exudates
- FLAIR
  - ± periventricular white matter interstitial edema better delineated than T2
- T1WI C+
  - ± enhancement of basal cisterns/sulci
    - Meningitis, carcinomatosis, etc.
- 3D CISS/FIESTA
  - Exquisitely delineates CSF spaces and helps to exclude intraventricular obstruction

Imaging Recommendations

- Best imaging tool
  - MR with T1WI C+
  - 3D CISS/FIESTA

DIFFERENTIAL DIAGNOSIS

Intraventricular Obstructive Hydrocephalus

- Global/focal enlarged ventricles due to obstruction proximal to 4th ventricle outflow

Ventricular Enlargement Secondary to Parenchymal Loss

- Neurodegenerative disease, cerebritis, hypoxia/ischemia
- Diffuse/focal enlargement of sulci, cisterns

Normal Pressure Hydrocephalus

- Ventricular enlargement with normal CSF pressure
- Sulci normal/minimally enlarged
- Progressive dementia, gait disturbance, incontinence

PATHOLOGY

General Features

- Etiology
  - Obstruction to CSF flow at level of basal cisterns or arachnoid villi
    - Also reduced CSF pulsations reduce venous resorption of CSF
  - SAH: Most common cause of EVOH
  - Other etiologies include suppurative meningitis, neoplastic inflammatory exudates
    - All lead to subarachnoid scarring, reduced CSF pulsations

Gross Pathologic & Surgical Features

- SAH, exudates may fibrose/occlude subarachnoid space
- Generalized ventricular dilatation

CLINICAL ISSUES

Presentation

- Most common signs/symptoms
  - Headache, papilledema
  - Nausea, vomiting, diplopia (cranial nerve palsy)

Natural History & Prognosis

- Usually progressive unless shunted and primary cause treated

Treatment

- CSF diversion (shunt)
- Directed to primary cause

DIAGNOSTIC CHECKLIST

Consider

- EVOH: Generalized ventricular enlargement with abnormal density/intensity in basal cisterns ± leptomeningeal enhancement

SELECTED REFERENCES

1. Fink KR et al: Imaging of Nontraumatic Neuroradiology Emergencies. Radiol Clin North Am. 53(4):871-890, 2015
2. Flannery AM et al: Pediatric hydrocephalus: systematic literature review and evidence-based guidelines. Part 1: Introduction and methodology. J Neurosurg Pediatr. 14 Suppl 1:3-7, 2014
3. Grunwald IQ et al: Aneurysmal SAH: current management and complications associated with treatment and disease. J Invasive Cardiol. 26(1):30-7, 2014

https://CafePezeshki.IR

KEY FACTS

TERMINOLOGY

- Focal reduction of cerebral aqueduct diameter

IMAGING

- Ventriculomegaly of lateral and 3rd ventricles with normal-sized 4th ventricle
- ± periventricular interstitial edema (uncompensated hydrocephalus)
- Multiplanar MR with sagittal 3D heavily T2WI sequences and sagittal cardiac-gated cine MR

TOP DIFFERENTIAL DIAGNOSES

- Obstructing extraventricular pathology
  - Neoplasm
  - Vein of Galen malformation
  - Quadrigeminal cistern arachnoid cyst
- Obstructing intraventricular (aqueductal) pathology
- Postinflammatory gliosis (aqueductal gliosis)
- Rhombencephalosynapsis

PATHOLOGY

- Congenital aqueductal stenosis (AS) is common cause of fetal hydrocephalus
- Aqueductal web and fork are pathological subsets

CLINICAL ISSUES

- Symptoms depend upon patient age at time of diagnosis
- Onset often insidious, may occur at any time from birth to adulthood
- Headache, papilledema, 6th nerve palsy, bulging fontanelle
- Parinaud syndrome (sun-setting eyes, lid retraction, and tonic downgaze)

DIAGNOSTIC CHECKLIST

- Consider postinflammatory gliosis (aqueductal gliosis), particularly if history of prematurity or meningitis
- Carefully scrutinize posterior 3rd ventricle, tectum, and tegmentum for obstructing neoplastic mass

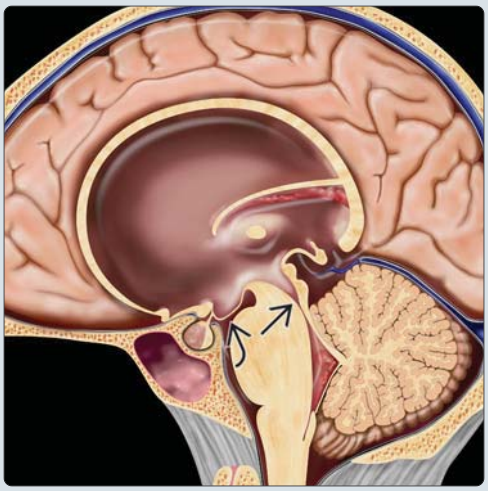

(Left) *Sagittal graphic shows obstructive hydrocephalus with markedly enlarged lateral and 3rd ventricles, stretched (thinned) corpus callosum, and a funnel-shaped cerebral aqueduct ⇨ related to distal obstruction. Note the normal size of the 4th ventricle and herniation of the floor of the 3rd ventricle ⇨ from the hydrocephalus.* **(Right)** *Sagittal T1WI C+ MR demonstrates aqueductal web ➡ causing dilation of the proximal cerebral aqueduct and lateral 3rd ventriculomegaly. The 4th ventricle is normal.*

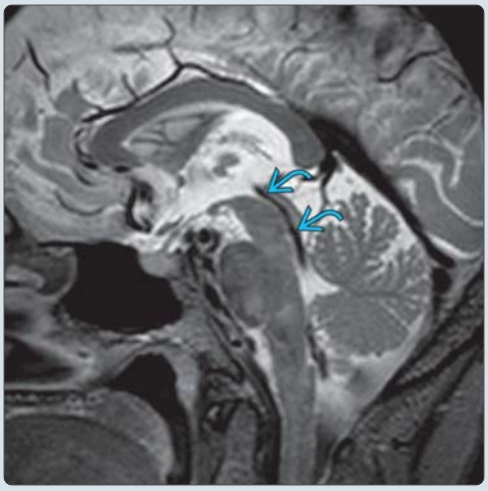

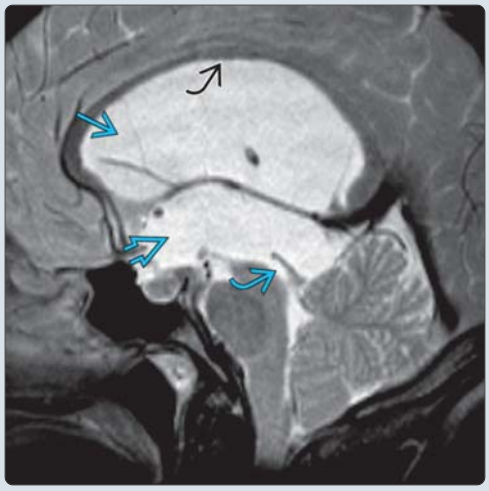

(Left) *Sagittal T2 SPACE MR demonstrates a normal aqueduct with a "flow void" ⇨ due to CSF flow from the 3rd ventricle into the 4th ventricle.* **(Right)** *Sagittal T2 SPACE MR demonstrates classic findings of aqueductal stenosis. There is an enlarged, funnel-shaped cerebral aqueduct ⇨ and marked dilatation of the lateral ⇨ and 3rd ventricles ⇨ with thinning and upward bowing of the corpus callosum ⇨. Note the normal size of the 4th ventricle*

https://CafePezeshki.IR

TERMINOLOGY

Abbreviations

- Aqueductal stenosis (AS)

Definitions

- Focal reduction of cerebral aqueduct diameter with concomitant lateral and 3rd ventriculomegaly

IMAGING

General Features

- Best diagnostic clue
  - Ventriculomegaly of lateral and 3rd ventricles, foramina of Monro proximal to obstruction
  - Normal size of 4th ventricle, basilar foramina (Luschka, Magendie) distal to obstruction
- Location
  - Cerebral aqueduct; most commonly at superior colliculi or intercollicular sulcus level
- Size
  - Normal mean aqueductal cross-sectional area at birth is 0.2-1.8 mm²
- Morphology
  - Funnel-shaped enlargement of proximal cerebral aqueduct or diffuse ↓ caliber of entire aqueduct

CT Findings

- NECT
  - Ventriculomegaly of lateral and 3rd ventricles, normal-sized 4th ventricle
    - Caveat: 4th ventricle is (near) normal size in many patients with communicating hydrocephalus
  - ± periventricular interstitial edema from uncompensated hydrocephalus (HCP)
  - No obstructing midbrain/thalamic mass
    - Tectal tumors may be occult on CT; asymmetry of posterior 3rd ventricle prompts MR imaging
- CECT
  - No pathologic brain enhancement
  - ± tectal tumor enhancement

MR Findings

- T1WI
  - Ventriculomegaly of lateral and 3rd ventricles, foramina of Monro
    - Corpus callosum (CC) thinned, stretched upward
    - Fornix, internal cerebral veins, 3rd ventricle floor displaced downward
    - Enlarged rounded optic and infundibular recesses of 3rd ventricle
  - Normal size of 4th ventricle, basilar foramina
  - Aqueductal narrowing commonly proximal in more severe hydrocephalus, distal in milder hydrocephalus
  - Aqueductal web: Thin tissue membrane separating dilated aqueduct from normal-sized 4th ventricle
- T2WI
  - Aqueductal "flow void" diminished or absent
  - Disturbed/turbulent CSF flow in lateral and 3rd ventricles
  - ± periventricular interstitial edema
- T1WI C+
  - Tumor enhancement differentiates neoplastic from benign AS
  - Hydrocephalus may induce leptomeningeal venous stasis → mimics meningitis or CSF metastases
- MRA
  - Upward displacement of anterior cerebral artery branches secondary to hydrocephalus
- MRV
  - Downward displacement of internal cerebral veins secondary to hydrocephalus
- MR cine
  - Phase contrast imaging: Absent or diminished CSF flow in aqueduct

Ultrasonographic Findings

- Grayscale ultrasound
  - Use mastoid (posterolateral) fontanelle window to supplement standard views in newborn
  - Obstetrical ultrasound may permit prenatal diagnosis

Imaging Recommendations

- Best imaging tool
  - Multiplanar MR with sagittal 3D heavily T2WI sequences and sagittal cardiac-gated cine MR

DIFFERENTIAL DIAGNOSIS

Obstructing Extraventricular Pathology

- Neoplasm
  - Tectal astrocytoma
  - Pineal region tumor
  - Thalamic tumor
- Vein of Galen malformation
- Quadrigeminal cistern arachnoid cyst

Obstructing Intraventricular (Aqueductal) Pathology

- Neurocysticercosis with aqueductal cyst

Postinflammatory Gliosis (Aqueductal Gliosis)

- Destruction of aqueductal ependymal lining → fibrillary gliosis of adjacent tissue
- Perinatal infection or hemorrhage (ICH)
  - Increasing prevalence reflects improved neonatal survival following bacterial meningitis or ICH
- Difficult to distinguish congenital AS from aqueductal gliosis on imaging
  - GRE MR can detect hemosiderin deposition from previous interventricular hemorrhage

Rhombencephalosynapsis

- Developmental midline anomaly of unknown cause
  - Continuity of cerebellar hemispheres with partial or complete absence of vermis
  - Other midline anomalies include fusion of inferior/superior colliculi, aqueductal stenosis, absence of septum pellucidum
  - When associated with trigeminal anesthesia, parietal alopecia, or brachy/turricephaly, consider Gomez-Lopez-Hernandez syndrome
- Consider this diagnosis in severe congenital HCP; carefully assess cerebellum

https://CafePezeshki.IR

PATHOLOGY

General Features

- Etiology
  - Aqueductal stenosis
    - Common cause of fetal hydrocephalus
    - May be congenital or acquired, benign or neoplastic
    - AS pathologically obstructs CSF flow into 4th ventricle, basilar foramina
    - CSF production in choroid plexus continues → lateral/3rd ventricular fluid ↑ pressure, ventriculomegaly
    - Ventricles expand, compress adjacent parenchyma, stretch corpus callosum
      - May rupture/open ependymal cell junctions → transependymal CSF flow
  - Aqueductal web
    - Subset of aqueductal stenosis
    - Thin membrane of brain tissue within distal aqueduct restricts CSF flow into 4th ventricle
  - Aqueductal fork
    - Branching of aqueduct into dorsal and ventral channels
- Genetics
  - Cell adhesion molecule L1 (*L1CAM*) gene recognized cause of human hydrocephalus
    - *L1CAM* expression is essential during normal embryonic development of nervous system
    - Mutations in *L1CAM* gene responsible for 4 related disorders (X-linked hydrocephalus/HSAS, MASA, X-linked complicated spastic paraplegia type 1, and X-linked agenesis of corpus callosum)
      - Now collectively CRASH syndrome: **C**allosal hypoplasia, mental **r**etardation, **a**dducted thumbs, **s**pastic paraplegia, and X-linked **h**ydrocephalus)
      - Site of mutation within L1 protein correlates with disease severity
- Associated abnormalities
  - CRASH syndrome
    - Absence/diminution of corticospinal tracts, thalamic fusion, collicular fusion, absence of septum pellucidum, corpus callosum dysgenesis
    - Thin cerebral mantle, malformations of cortical development, hypoplastic white matter
  - Aqueductal fork
    - Fusion of quadrigeminal bodies and cranial nerve 3 nuclei, tectal molding (beaking)

Microscopic Features

- Malformations of cortical development with poor differentiation and maturation of cortical neurons on histology
- Aqueductal fork shows branching of aqueduct into dorsal and ventral channels
  - Dorsal channel usually divided into several ductules

CLINICAL ISSUES

Presentation

- Most common signs/symptoms
  - Symptoms depend upon patient age at time of diagnosis
  - Onset often insidious, may occur at any time from birth to adulthood
- Other signs/symptoms
  - Headache, papilledema, 6th nerve palsy, bulging fontanelles
  - Macrocrania, especially if sutures open
  - Parinaud syndrome (sun-setting eyes, lid retraction, and tonic downgaze)
  - Bobble-head doll syndrome (rare)

Demographics

- Age
  - Age at presentation depends on severity of stenosis, hydrocephalus
- Gender
  - M:F = 2:1
- Epidemiology
  - 0.5-1 per 1,000 births, recurrence rate of 1-4.5% in siblings
  - AS responsible for ~ 20% of congenital hydrocephalus

Natural History & Prognosis

- Hydrocephalus usually progressive unless treated
  - May stabilize as "arrested" or compensated hydrocephalus
- Neonates with aqueductal stenosis and normal development ~ 24-86%

Treatment

- CSF shunt diversion
- Endoscopic 3rd ventriculostomy
- Cerebral aqueductoplasty for membranous and short-segment aqueductal stenoses (selected cases)

DIAGNOSTIC CHECKLIST

Consider

- Postinflammatory gliosis (aqueductal gliosis), particularly if history of prematurity or meningitis
- Carefully scrutinize posterior 3rd ventricle, tectum, and tegmentum for neoplastic mass

Image Interpretation Pearls

- Tectal astrocytomas large enough to obstruct aqueduct may be missed on routine CT scanning
  - MR more sensitive than CT for detecting obstructing mass lesion
  - Consider neurofibromatosis type 1 when tectal astrocytoma is identified
- Consider rhombencephalosynapsis in severe congenital AS

SELECTED REFERENCES

1. Yamada S et al: Current and emerging MR imaging techniques for the diagnosis and management of CSF flow disorders: a review of phase-contrast and time-spatial labeling inversion pulse. AJNR Am J Neuroradiol. 36(4):623-30, 2015
2. Kartal MG et al: Evaluation of hydrocephalus and other cerebrospinal fluid disorders with MRI: An update. Insights Imaging. 5(4):531-41, 2014
3. Tully HM et al: Infantile hydrocephalus: a review of epidemiology, classification and causes. Eur J Med Genet. 57(8):359-68, 2014
4. Ucar M et al: Evaluation of aqueductal patency in patients with hydrocephalus: three-dimensional high-sampling-efficiency technique (SPACE) versus two-dimensional turbo spin echo at 3 Tesla. Korean J Radiol. 15(6):827-35, 2014

https://CafePezeshki.IR

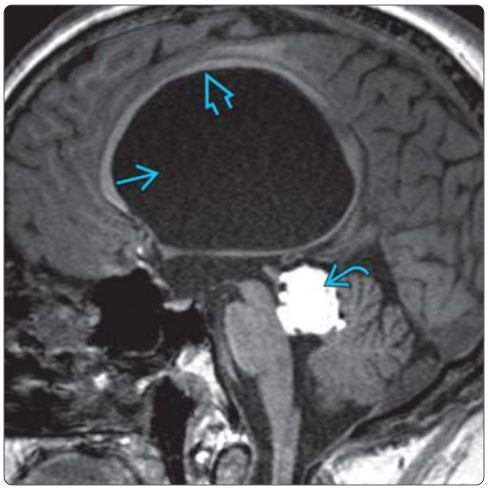

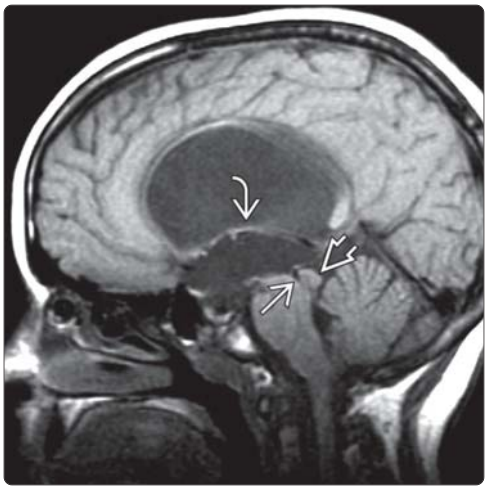

(Left) *Sagittal T1 MR demonstrates acquired aqueductal stenosis secondary to a lipoma of the quadrigeminal plate. There is marked dilatation of the lateral ventricles with thinning and upward bowing of the corpus callosum.* **(Right)** *Sagittal T1WI MR depicts proximal aqueductal stenosis producing enlargement of the lateral and 3rd ventricles with depression of the fornices in conjunction with normal 4th ventricle size. Tectum is dysplastic and thickened with collicular fusion.*

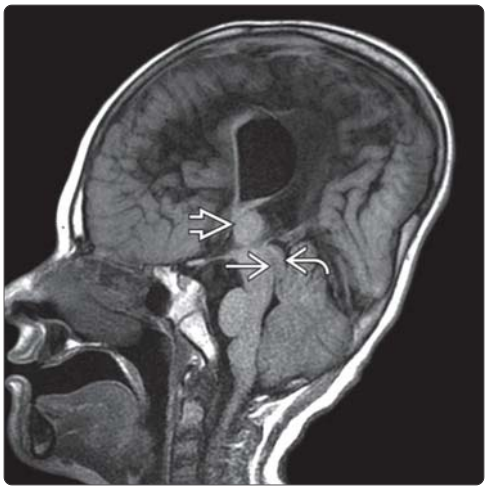

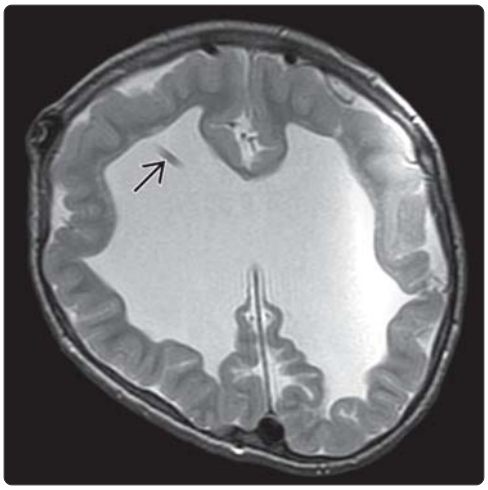

(Left) *Sagittal T1WI MR (CRASH syndrome) shows characteristic marked aqueductal stenosis with small 4th ventricle size, dysplastic tectal thickening, callosal dysgenesis, and large massa intermedia from thalamic fusion.* **(Right)** *Axial T2WI MR (CRASH syndrome) confirms marked ventriculomegaly of the lateral ventricles with abnormal cortical sulcation, striking white matter volume loss, and absent septum pellucidum. A VP shunt was placed for treatment of hydrocephalus.*

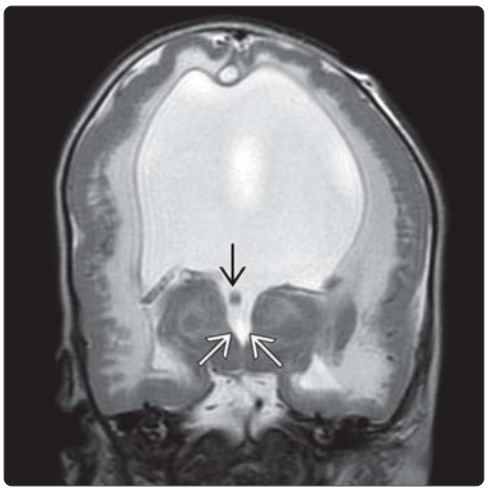

(Left) *Sagittal T1WI MR in a patient with Walker-Warburg syndrome shows severe tectal dysgenesis with aqueductal occlusion. Marked enlargement of the lateral > 3rd ventricle is present. "Zigzag" brainstem and very small cerebellum are characteristic of this syndrome.* **(Right)** *Coronal T2WI MR in the same patient with Walker-Warburg syndrome confirms marked ventriculomegaly, funnel-shaped cerebral aqueductal stenosis, fused fornices, and classic cobblestone lissencephaly.*

https://CafePezeshki.IR

KEY FACTS

TERMINOLOGY

- Ventriculomegaly with normal CSF pressure, altered CSF dynamics

IMAGING

- Enlarged lateral & 3rd ventricles, 4th ventricle relatively normal
- Ventricular enlargement out of proportion to cortical sulcal enlargement
- Disproportionately enlarged subarachnoid space hydrocephalus (DESH) (particularly sylvian fissures and basal cisterns) with effacement of subarachnoid space over convexity
- ± aqueductal flow void
- Periventricular high signal transependymal CSF flow
- 18F-FDG PET shows decreased regional cerebral metabolism

TOP DIFFERENTIAL DIAGNOSES

- Normal aging brain
- Alzheimer disease
- Multi-infarct dementia (MID)
- Subcortical arteriosclerotic encephalopathy

PATHOLOGY

- Pathogenesis of NPH poorly understood
- Leading theory: Poor venous compliance in superior sagittal sinus impairs CSF pulsations and CSF absorption through arachnoid granulations

CLINICAL ISSUES

- Heterogeneous syndrome (classic clinical triad = dementia, gait apraxia, urinary incontinence)

DIAGNOSTIC CHECKLIST

- Is ventricular dilation solely due to atrophy?
- Diagnostic challenge = identify shunt-responsive NPH

(Left) *Sagittal T1WI MR shows large lateral ventricles ⇨, thinning of the corpus callosum ⇨, and a relatively normal 4th ventricle ⇨ in a patient with NPH.* **(Right)** *Axial CECT demonstrates typical findings suggestive of NPH. There is enlargement of the lateral ventricles and sylvian fissures ⇨ out of proportion to the amount of general sulcal enlargement. The frontal horns show a characteristic rounded appearance. Periventricular hypodensities ⇨ could reflect transependymal migration of CSF.*

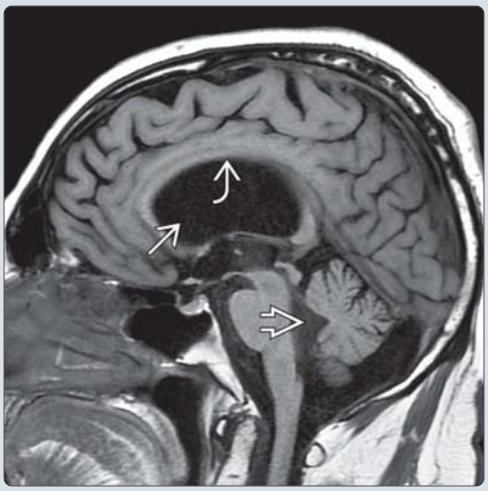

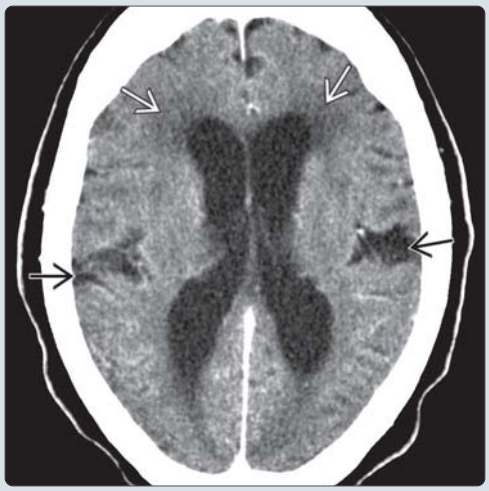

(Left) *Axial FLAIR MR shows enlarged ventricles out of proportion to the sulcal enlargement. Notice that periventricular hyperintensity is also present ⇨.* **(Right)** *Axial T2WI MR in the same patient shows dilated ventricles. Normal pressure hydrocephalus accounts for approximately 5-6 % of all dementias. The classic Hakim triad of dementia, gait apraxia, and urinary incontinence is present in a minority of patients.*

https://CafePezeshki.IR

TERMINOLOGY

Abbreviations

- Normal pressure hydrocephalus (NPH)

Synonyms

- Idiopathic adult hydrocephalus syndrome

Definitions

- Ventriculomegaly with normal CSF pressure, altered CSF dynamics

IMAGING

General Features

- Best diagnostic clue
  - Enlarged lateral & 3rd ventricles, 4th ventricle relatively normal
  - Ventricular enlargement out of proportion to cortical sulcal enlargement
  - Disproportionately enlarged subarachnoid space hydrocephalus (DESH) (particularly sylvian fissures and basal cisterns) with effacement of subarachnoid space over convexity
- Location
  - Ventriculomegaly involves all 3 horns of lateral ventricles, plus 3rd ventricle
    - 4th ventricle relatively spared
- Size
  - Increased ventricular volume
  - Evans index (ratio of widest diameter of frontal horns to widest diameter of brain on same axial slice) ≥ 0.3
  - Callosal angle (angle between lateral ventricles on coronal image) ≤ 90°
  - Dilatation of sylvian fissures
- Morphology
  - Diffuse expansion of ventricles

CT Findings

- NECT
  - Ventriculomegaly with rounded frontal horns, out of proportion to sulcal atrophy (ventriculosulcal disproportion)
  - Frontal/occipital periventricular hypodensities (representing transependymal CSF flow) may be present
  - Corpus callosal thinning (nonspecific)
  - Prominent basal cisterns & sylvian fissures

MR Findings

- T1WI
  - Lateral ventricles enlarged with rounded frontal horns
  - Moderately dilated 3rd ventricle, relatively normal 4th ventricle
  - ± aqueductal flow void
- T2WI
  - Periventricular high signal, primarily anterior to frontal horns or posterior to occipital horns of lateral ventricles (transependymal CSF flow)
  - 50-60% have periventricular and deep white matter lesions
    - More frequent, severe compared to age-matched controls
    - Positive outcome after shunting and should not exclude patients from surgery
- Enlarged basal cisterns, sylvian fissures
- Dilatation of optic and infundibular recesses of anterior 3rd ventricle and downward displacement of hypothalamus
- Focal bulging of roof of lateral ventricles
- Corpus callosum bowed upward (may be impinged by falx)
- Aqueductal flow void sign
  - Reflects increased CSF velocity through cerebral aqueduct
    - May be reduced if flow compensation, FSE techniques used
- Cortical and subcortical lacunar infarctions (basal ganglia, internal capsule)
- Diffusion tensor imaging
  - ↑ fractional anisotropy (FA) values in posterior limb of internal capsule

Nuclear Medicine Findings

- PET
  - FDG-18 PET shows decreased regional cerebral metabolism
- SPECT: Cerebral blood flow ↓ in patients with NPH
- In-111 DTPA cisternography
  - Prominent ventricular reflux, with no flow over convexities at 24-48 hours
  - High false-positive rate

Other Modality Findings

- Phase-contrast cine MR imaging
  - Cardiac gated CSF flow studies to detect increased velocity ("hyperdynamic" flow)
  - Aqueduct stroke volume (ASV): Lack of correlation between ASV and symptom severity
  - Some patients with normal CSF flow values also improve
- ICP monitoring: Wave amplitude > 9 mm Hg correlates with post-shunt cognitive improvement

Imaging Recommendations

- Best imaging tool
  - MR with CSF flow studies
  - CT helpful

DIFFERENTIAL DIAGNOSIS

Normal Aging Brain

- Thin periventricular high signal rim is normal
- Few/no white matter hyperintensities ("successfully aging brain")

Alzheimer Disease

- Dementia out of proportion to gait disturbance
- Large parahippocampal fissures, small hippocampi, sulcal enlargement

Multi-Infarct Dementia (MID)

- Multiple infarcts on imaging

Subcortical Arteriosclerotic Encephalopathy (Binswanger Disease)

- Continuous, irreversible ischemic degeneration of periventricular and deep white matter

https://CafePezeshki.IR

- MR shows extensive periventricular and deep white matter hyperintensities, enlarged ventricles
  - Reflect microinfarctions and demyelination

PATHOLOGY

General Features

- Etiology
  - Pathogenesis of NPH poorly understood
  - 50% idiopathic
  - 50% other (e.g., subarachnoid hemorrhage, meningitis, neurosurgery, or head trauma)
  - Age-related changes in CSF formation/absorption
    - Increased resistance to CSF outflow
    - May be exacerbated in NPH
  - Dysfunctional CSF dynamics
    - Reduced absorption through arachnoid villi
    - Compensatory CSF flow into periventricular white matter
    - Transcapillary CSF resorption
  - NPH: Reduced CBF, altered CSF resorption without increased CSF pressure
    - Brain expands in systole, causes CSF displacement
    - Loss of parenchymal compliance, altered viscoelastic properties of ventricular wall
    - Increased interstitial fluid
    - Pulsation pressure directed toward ventricles
    - "Water hammer" effect
    - May be further complicated by microangiopathy (including venous compromise), atrophy
  - Leading theory: Poor venous compliance in superior sagittal sinus impairs CSF pulsations and CSF absorption through arachnoid granulations

Gross Pathologic & Surgical Features

- Enlarged ventricles, normal CSF pressure
- Periventricular white matter stretched, dysfunctional
  - Inadequate perfusion without frank infarction

Microscopic Features

- Arachnoid fibrosis (50%)
- Periventricular tissue
  - Disruption of ependyma
  - Edema, neuronal degeneration, and gliosis
- Cerebral parenchyma
  - Almost 50% show no significant pathology
  - 20% neurofibrillary tangles, other Alzheimer disease changes
  - 10% arteriosclerosis, ischemic encephalomalacia

CLINICAL ISSUES

Presentation

- Most common signs/symptoms
  - Heterogeneous syndrome (classic clinical triad = dementia, gait disorder, urinary incontinence)
  - Gait disorder: Disturbed postural and locomotor reflexes in absence of primary sensorimotor deficits
  - Bladder dysfunction: Urinary urgency with difficulty inhibiting bladder emptying
  - Dementia: Apathy or amotivation, daytime sleepiness, psychomotor slowing
- Clinical profile
  - Reversible cause of dementia

Demographics

- Age
  - Most common in patients > 60 years
  - Idiopathic form of NPH tends to present in elderly
- Gender
  - M > F
- Ethnicity
  - No racial predilection
- Epidemiology
  - Accounts for ~ 5-6 % of dementias

Natural History & Prognosis

- Continuing cognitive and motor decline, akinetic mutism, and eventual death
- Potentially reversible cause of dementia when shunted

Treatment

- Large-volume lumbar puncture (also known as the tap test) has high positive predictive value
  - Test is used to assess patient's response to CSF removal
  - Patient must be examined before and after LP
  - Typical "tap test" protocols remove 30–50 mL of CSF and observe change in gait & cognition 30 minutes to 4 hours afterward
- Shunt surgery indicated for patients who respond to CSF drainage or have CSF hydrodynamic variables consistent with NPH
- Recent studies have suggested positive effect of endoscopic 3rd ventriculostomy
- Predictors of positive response to shunting remains elusive
- After shunt surgery, variable outcome
  - Clinical response to shunting ranges from 29% to 90%
  - Gait disturbance is clinical symptom most likely to respond to surgery
  - Irregular periventricular hyperintensities seem to be key reversible white matter change at MR imaging

DIAGNOSTIC CHECKLIST

Consider

- Whether ventricular dilation is solely due to atrophy
- Diagnostic challenge = identify shunt-responsive NPH

Image Interpretation Pearls

- Intraventricular lactate level may be useful in differentiating NPH from other types of dementia

SELECTED REFERENCES

1. Bradley WG Jr: CSF Flow in the Brain in the Context of Normal Pressure Hydrocephalus. AJNR Am J Neuroradiol. 36(5):831-838, 2015
2. Ringstad G et al: Aqueductal Stroke Volume: Comparisons with Intracranial Pressure Scores in Idiopathic Normal Pressure Hydrocephalus. AJNR Am J Neuroradiol. ePub, 2015
3. Chotai S et al: External lumbar drain: A pragmatic test for prediction of shunt outcomes in idiopathic normal pressure hydrocephalus. Surg Neurol Int. 5:12, 2014
4. Torsnes L et al: Treatment and clinical outcome in patients with idiopathic normal pressure hydrocephalus–a systematic review. Dan Med J. 61(10):A4911, 2014
5. Virhammar J et al: Preoperative prognostic value of MRI findings in 108 patients with idiopathic normal pressure hydrocephalus. AJNR Am J Neuroradiol. 35(12):2311-8, 2014

https://CafePezeshki.IR

(Left) *Axial NECT shows large ventricles out of proportion to the sulcal prominence with a rounded appearance of the frontal horns.* **(Right)** *Axial T2WI MR in the same patient shows ventriculomegaly. The patient presented with the classic clinical triad of normal pressure hydrocephalus (NPH): Dementia, gait apraxia, and urinary incontinence. One treatment option is ventricular shunting. The favorable response to shunting varies from 29% to 90%.*

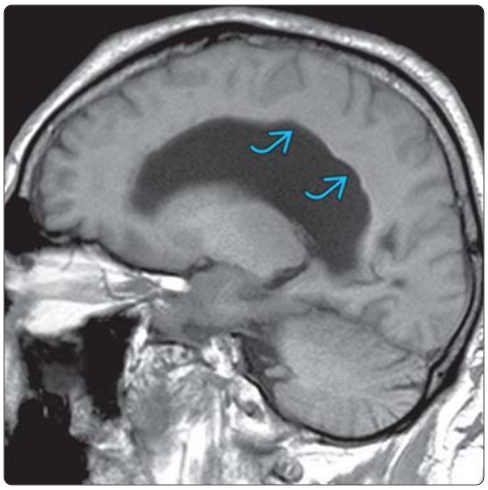

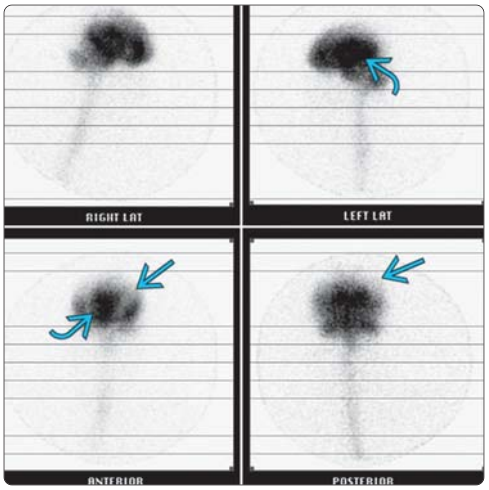

(Left) *Sagittal T1 MR in a patient with NPH demonstrates focal bulging of the roof of the lateral ventricles, which has been recently described.* **(Right)** *24-hour multiplanar In-111 DTPA cisternography in a patient with NPH shows radiotracer in the lateral ventricles with lack of activity over the convexity. Normally, there should be radiotracer movement over the convexities at 24-hour. (Courtesy C. Singh, MD, A. Ali, MD.)*

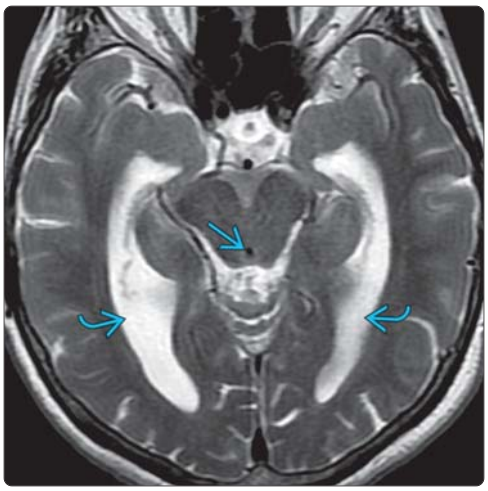

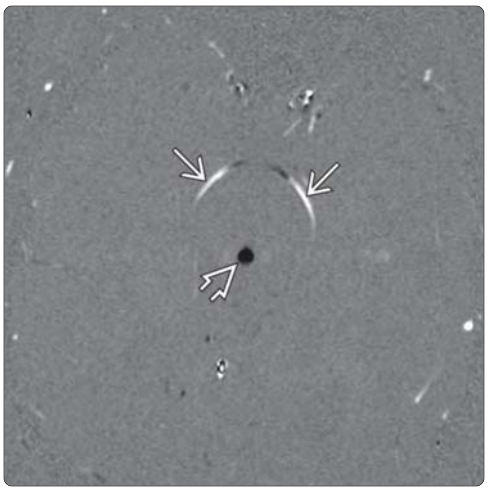

(Left) *Axial T2WI MR in 65 year old with NPH shows dilated temporal horns and low signal flow void in the aqueduct caused by hyperdynamic flow of CSF.* **(Right)** *Axial MR phase contrast cine CSF flow study shows increased velocity of CSF through the dilated aqueduct. There is more hyperdynamic flow through the aqueduct than the cisterns, where no high velocity signal change is seen. Flow is incidentally noted in the posterior cerebral arteries.*

https://CafePezeshki.IR

KEY FACTS

TERMINOLOGY

- Hydrocephalus
  - Enlargement of cerebral ventricles secondary to abnormal CSF formation, flow, or absorption resulting in ↑ CSF volume

IMAGING

- Shunt failure → dilated ventricles + edema around ventricles, along catheter and reservoir
- Use CT or MR to evaluate ventricle size, plain radiograph shunt series to identify mechanical shunt failure
- Baseline CT/MR following shunt insertion, follow-up at 1 year and as clinically needed
- Shunt radionuclide studies: Used to confirm distal obstruction

TOP DIFFERENTIAL DIAGNOSES

- Shunt failure with normal ventricle size or lack of interstitial edema
- Noncompliant ("slit") ventricle syndrome
- Acquired Chiari 1 malformation/tonsillar ectopia

PATHOLOGY

- Obstructive hydrocephalus: Secondary to physical blockage by tumor, adhesions, cyst
- Communicating hydrocephalus: Secondary to ↓ CSF absorption across arachnoid granulations

CLINICAL ISSUES

- Older children/adults: Headache, vomiting, lethargy, seizure, neurocognitive symptoms
- Infants: Bulging fontanelle, ↑ head circumference, irritability, lethargy

DIAGNOSTIC CHECKLIST

- Shunt + headache not always shunt failure
- Confirm programmable shunt valve setting after MR
- Compare current CT with prior studies to detect subtle changes in ventricle size

(Left) *Lateral radiograph from a plain film shunt series in an infant with acute shunt failure demonstrates that the ventricular catheter has pulled out of the head and is laying along the distal catheter within the scalp (tip ➡).* **(Right)** *AP radiograph of the pelvis in a 4 year old with a ventriculoperitoneal shunt who presented with left scrotal swelling demonstrates a coiled distal shunt catheter ⇨ in the left scrotum. The migration of the catheter to the scrotum is due to a patent processes vaginalis.*

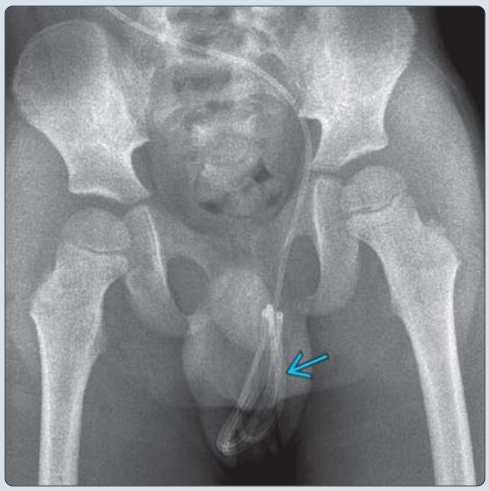

(Left) *Lateral skull radiograph of acute VP shunt failure from a plain radiograph shunt series demonstrates a mechanical shunt catheter disconnection ➡ between the programmable valve and the reservoir.* **(Right)** *Axial bone CT in the same patient reveals the mechanical catheter disconnection ➡ between the reservoir and the programmable shunt valve. This finding had not appeared on the most recent comparison CT scan (not shown).*

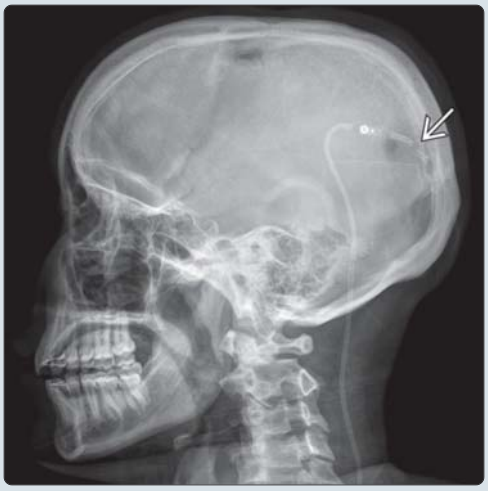

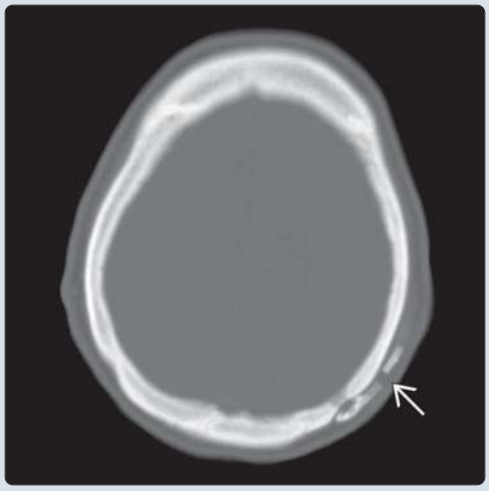

https://CafePezeshki.IR

TERMINOLOGY

Abbreviations

- Shunt types: Ventriculoperitoneal (VP), ventriculoatrial (VA), ventriculopleural (VPL), lumboperitoneal (LP)

Definitions

- Ventriculomegaly
  - General term for enlargement of cerebral ventricles
- Hydrocephalus (HCP)
  - Enlargement of cerebral ventricles secondary to abnormal CSF formation, flow, or absorption resulting in ↑ CSF volume
    - Onset over days (acute), weeks (subacute), or months to years (chronic)

IMAGING

General Features

- Best diagnostic clue
  - Shunt failure: Dilated ventricles + edema ("blurring") around ventricles and along catheter, reservoir
- Location
  - VP shunt common; VA and VPL used rarely unless VP contraindicated
- Size
  - Ventricular size is relative → ventriculomegaly may indicate shunt failure in 1 patient and be stable finding in another
    - Change in ventricular size in individual patient probably significant
    - Conversely, some patients manifest shunt failure with minimal to no change in ventricular size
  - Distal catheter must be sized long enough to permit somatic growth, prevent retraction out of abdomen or chest
- Morphology
  - Shunt system components
    - Proximal catheter in ventricles, subarachnoid space, syrinx cavity, or thecal sac
    - Unidirectional valve prevents reflux into ventricles
    - Reservoir used to sample CSF, acutely relieve pressure
    - Distal catheter tunneled through subcutaneous tissues → tip in peritoneal cavity, cardiac atrium, or pleural cavity

Radiographic Findings

- Radiography
  - Evaluate shunt catheter system integrity
    - Shunt fracture, separation, migration
    - Distal catheter may retract out of abdomen if significant somatic growth since shunt placement

CT Findings

- NECT
  - Ventricular dilatation (diffuse or loculated)
    - "Isolated" ventricle after infection, hemorrhage → interventricular synechia
    - Periventricular interstitial edema ("blurred" ventricle margins) → acute hydrocephalus
  - Small, "slit" ventricles → noncompliant ventricle syndrome, chronic overdrainage
  - ± subdural hematoma (CSF overdrainage)

MR Findings

- T1WI
  - Assess ventricular size, characterize brain anatomy
- T2WI
  - ± interstitial parenchymal edema (transependymal CSF flow) → acute shunt failure
- FLAIR
  - Interstitial edema more conspicuous than on T1WI or T2WI
- T1WI C+
  - ± enhancement with ventriculitis, abscess, neoplasm
  - Pachymeningeal enhancement due to low intracranial pressure
- MRA
  - Stretched, displaced arteries around dilated ventricles secondary to ventriculomegaly
- MRV
  - Venous thrombosis may precede hydrocephalus or follow shunting
    - Leads to increased intraventricular/intracranial pressure (ICP)
- MR cine
  - Evaluate patency of normal CSF pathways, 3rd ventriculostomy

Ultrasonographic Findings

- Grayscale ultrasound
  - Useful in neonates for serial assessment of ventricular size (requires open fontanelle)

Nonvascular Interventions

- Interventricular contrast injection through shunt plus NECT→ detect ventricular isolation needing additional catheter

Nuclear Medicine Findings

- Shunt radionuclide studies
  - Radiotracer injected into shunt reservoir, serial imaging to document timing of radiotracer egress from distal catheter tip
  - Used to confirm distal obstruction

Imaging Recommendations

- Best imaging tool
  - Brain NECT to assess for acute ventricular size change
  - Fast MR imaging protocols (HASTE, SSFSE) used in many centers with 24-hour MR availability to avoid cumulative radiation exposure
- Protocol advice
  - Brain CT or MR to evaluate ventricle size
  - Plain film shunt series to identify mechanical shunt fracture or disconnection

DIFFERENTIAL DIAGNOSIS

Shunt Failure With Normal Ventricle Size or Lack of Interstitial Edema

- Look for fluid along shunt catheter or reservoir as only sign of malfunction
- May require diagnosis on clinical grounds

https://CafePezeshki.IR

Noncompliant ("Slit") Ventricle Syndrome

- Usually older child (shunted in infancy)
- Small ventricles plus intermittent signs of shunt obstruction
- Ventricles normal/small even if shunt malfunctioning

Acquired Chiari 1 Malformation/Tonsillar Ectopia

- Functioning LP shunt produces tonsillar descent through foramen magnum
- More common with valveless systems

PATHOLOGY

General Features

- Etiology
  - Impairment of CSF circulation
    - Obstructive
      - Usually at narrowest points in CSF circulation (aqueduct, foramina of Monro)
      - Tumor, web/synechia, congenital aqueductal stenosis
    - Inadequate reabsorption across arachnoid granulations into venous sinuses
      - Arachnoid granulations "clogged" after hemorrhage, inflammation
      - Diminished pressure gradient from subarachnoid space to venous sinuses secondary to venous hypertension
      - Impaired CSF absorption → CSF accumulation, ↑ ICP
  - CSF shunt establishes accessory drainage pathway to bypass obstructed natural CSF flow pathways
    - Restores or maintains normal intracranial pressure
  - Each shunt, valve, device carries its own set of complications
    - All types → material degradation/fatigue, mechanical stress (especially craniocervical junction, inferior ribs)
    - VP → abdominal complications (CSF pseudocyst, ascites, bowel perforation)
    - VPL → symptomatic pleural effusion
    - VA → shunt nephritis, cor pulmonale, pulmonary embolus
    - LP → arachnoiditis, cerebellar tonsillar herniation, high catheter migration rate
    - Programmable shunt → unintentional reprogram during MR imaging
- Associated abnormalities
  - Shunts placed with CSF blood/protein > 1 g/dL prone to early blockage, failure
  - Shunt infection
  - Ventricular loculation or isolation
  - Overshunting

Gross Pathologic & Surgical Features

- Ventricular ependymal adhesions ("scar")
- Extracranial shunt tubing calcification

Microscopic Features

- Gliosis along intracranial shunt tract

CLINICAL ISSUES

Presentation

- Most common signs/symptoms
  - Children, adults
    - Headache, vomiting, lethargy, seizure
    - Neuropsychologic, cognitive, or behavioral
  - Infants
    - Bulging fontanelle, increasing head circumference, irritability, lethargy

Demographics

- Epidemiology
  - 160,000 shunts implanted each year worldwide
  - CSF shunts in USA ~ 125,000 total
    - 33,000 placed per year (~ 50% revisions)

Natural History & Prognosis

- Acute shunt obstruction in shunt-dependent patients may lead to death
- Majority of shunts eventually fail, complication rate 25-37%
  - ≤ 40% shunts fail in 1st year, 80% fail by 10 years
  - 50% of patients need multiple revisions, progressively shorter time interval to next failure

Treatment

- Shunt revision
  - Replace intraventricular component/valve for proximal obstruction
  - Alter valve pressure setting/type if over- or underdraining
    - Programmable shunt valves permit transcutaneous adjustment of pressure setting
  - Lengthen distal shunt as child grows
- 3rd ventriculostomy to avoid indwelling shunt if blockage is distal to 3rd ventricle
- Laparoscopic or open abdominal procedure for distal obstruction related to CSF pseudocyst

DIAGNOSTIC CHECKLIST

Consider

- Shunt + headache does not always mean shunt failure
  - Consider sinusitis, trauma, sinovenous thrombosis, viral infection
- Confirm programmable shunt valve setting after MR
- Plain film shunt series has extremely low yield in absence of clinical evidence for mechanical shunt failure

Image Interpretation Pearls

- Compare with prior studies to detect subtle ventricular size changes
- Fluid tracking along shunt may be only sign of failure, possible even if ventricles normal or unchanged size

SELECTED REFERENCES

1. Rinker EK et al: CSF shunt complications: what the abdominal imager needs to know. Abdom Imaging. ePub, 2015
2. Symss NP et al: Is there an ideal shunt? A panoramic view of 110 years in CSF diversions and shunt systems used for the treatment of hydrocephalus: from historical events to current trends. Childs Nerv Syst. 31(2):191-202, 2015
3. Sivaganesan A et al: Neuroimaging of ventriculoperitoneal shunt complications in children. Pediatr Radiol. 42(9):1029-46, 2012

https://CafePezeshki.IR

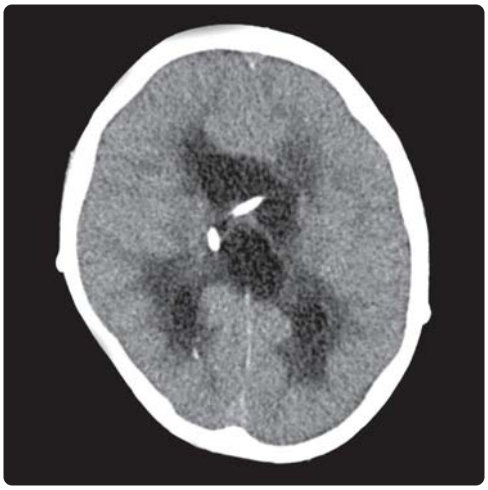

(Left) *Axial NECT in a patient with acute ventriculoperitoneal (VP) shunt failure shows symmetric interstitial edema within the periventricular white matter. Ventricular size is significantly larger than demonstrated on a prior CT (not shown), supporting the diagnosis of acute shunt failure.* **(Right)** *Axial NECT in an adult with a ventriculoperitoneal shunt demonstrates chronic bilateral subdural collections overlying the frontal convexities due to over shunting. These collections resolved after adjustment of the shunt valve.*

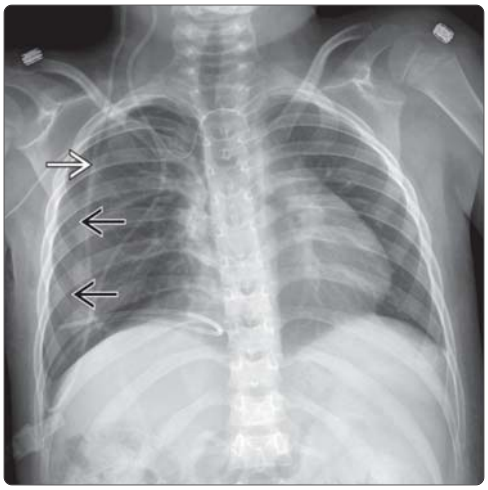

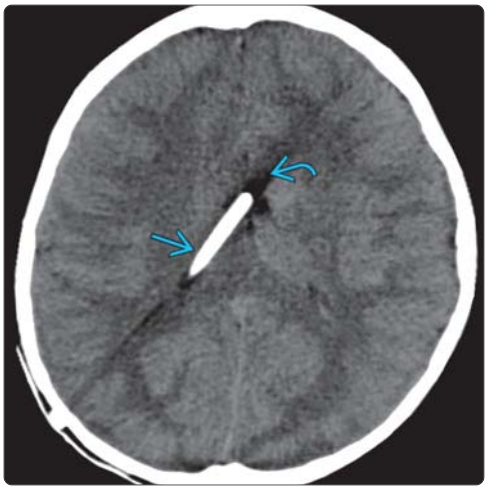

(Left) *Anteroposterior radiograph in a patient with chest pain after ventriculopleural (VPL) shunt placement depicts a right pneumothorax ⇨ related to the shunt placement. Note the abandoned catheter fragment ➡ from a prior VP shunt system.* **(Right)** *Axial NECT in a patient with VP shunt ⇨ who presented with severe headaches shows collapsed lateral ventricles ⇨. Slit ventricle syndrome presents as a severe headaches due to noncompliant ventricles and should not be confused with radiological slit ventricles.*

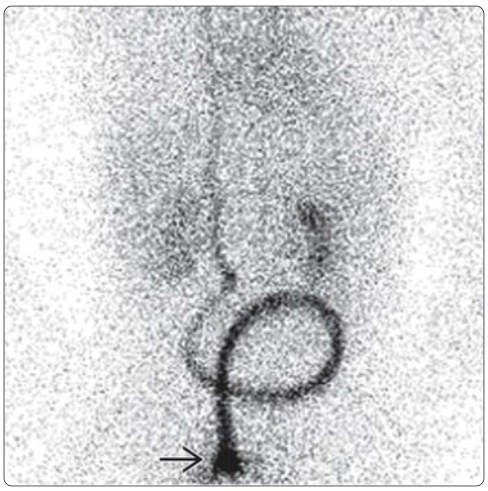

(Left) *Axial NECT in a hydrocephalic patient presenting with distal VP shunt failure shows the peritoneal catheter tip ➡ within a loculated pelvic fluid collection (CSF pseudocyst ➡).* **(Right)** *Frontal cisternogram-radionuclide shuntogram examination performed after injecting the shunt valve reservoir reveals no spillage from the distal catheter ⇨ after 10 minutes. Further delayed imaging (not shown) confirmed absence of spillage from the catheter, substantiating distal shunt obstruction.*

https://CafePezeshki.IR

This page intentionally left blank

https://CafePezeshki.IR

PART II
SECTION 2

Sella and Pituitary

Sella and Pituitary Overview 1020

Congenital

Pituitary Anomalies 1024
Tuber Cinereum Hamartoma 1028
Rathke Cleft Cyst 1032

Neoplasms

Pituitary Microadenoma 1036
Pituitary Macroadenoma 1040
Pituitary Apoplexy 1044
Craniopharyngioma 1048
Pituicytoma 1052
Spindle Cell Oncocytoma 1054
Granular Cell Tumor 1055

Miscellaneous

Empty Sella 1056
Pituitary Hyperplasia 1060
Lymphocytic Hypophysitis 1062

https://CafePezeshki.IR

Gross Anatomy

Sella

Bony anatomy: The sella turcica ("Turkish saddle") is a concave, midline depression in the basisphenoid that contains the pituitary gland (also called the hypophysis). The anterior borders of the sella are formed by the anterior clinoid processes of the lesser sphenoid wing and the tuberculum sellae, while the posterior border is formed by the dorsum sellae. The top of the dorsum sellae expands to form the posterior clinoid processes, which in turn form the upper margin of the clivus. The floor of the sella is part of the sphenoid sinus roof, which is partially or completely aerated. The cavernous segments of the internal carotid artery lie in shallow grooves, called the carotid sulci, which are located inferolateral to the sella.

Meninges: The meninges in and around the sella turcica form important anatomic landmarks. Dura covers the bony floor of the sella itself. A thin dural reflection borders the pituitary fossa laterally and forms the medial cavernous sinus wall. A small circular dural shelf, the diaphragma sellae, forms a roof over the sella turcica that, in most cases, almost completely covers the pituitary gland. The diaphragma sella has a variably sized central opening that transmits the pituitary stalk. In some cases, this dural opening is large and gapes widely. In such cases, arachnoid with or without accompanying CSF may protrude from the suprasellar cistern inferiorly through the diaphragma sellae opening into the sella turcica and cause the imaging appearance of an empty sella.

Pituitary Gland

Overview: The pituitary gland, also called the hypophysis cerebri, consists of three major parts: The adenohypophysis (AH), the neurohypophysis (NH), and the pars intermedia (PI) plus the infundibulum, which are generally considered together as a unit.

Adenohypophysis: The AH, also called the anterior lobe, wraps anterolaterally around the NH in a U-shaped configuration. The AH contains acidophil, basophil, and chromophobe cells, as well as other cells, such as tanycytes. Cells of the AH secrete trophic hormones (TSH, ACTH, LH, and FSH) as well as growth hormones (GHs). The AH forms 80% of the pituitary gland by volume.

Pars intermedia: The PI is derived from the buccal ectoderm of the embryonic Rathke pouch. It is relatively small (less than 5% of the pituitary volume). Axons from the hypothalamus carry granules of releasing hormones to the AH.

Neurohypophysis: The NH, sometimes called the pars nervosa, consists of the posterior lobe of the pituitary gland, infundibular stem, and median eminence of the hypothalamus. The NH is formed from the embryonic diencephalon (forebrain) as a downward extension of the hypothalamus. Vasopressin and oxytocin are formed within the hypothalamus, pass inferiorly along the hypothalamohypophysial tract, and are stored in the NH. The NH comprises approximately 20% of the pituitary gland.

Imaging Recommendations

MR

MR is generally the imaging procedure of choice. Recommended sequences include pre-contrast thin-section, small FOV sagittal and coronal T1- and T2WIs followed by post-contrast sagittal and coronal T1WI C+ FS images. Whole-brain FLAIR is a useful sequence to add. T2*/SWI may be helpful in detecting pituitary hemorrhage. If microadenoma is suspected, dynamic imaging with coronal thin-section T1WIs obtained at 5-10 second intervals following rapid bolus injection of contrast are recommended. At least three sections (3 mm or less with no interslice gap), sorted by slice, are typically obtained. Some 20-30% of microadenomas are detected only on dynamic contrast-enhanced MR imaging.

CT

Thin-section coronal CT with sagittal/coronal reconstruction may be a useful imaging adjunct when lesions affecting the sella &/or cavernous sinus arise in the basisphenoid.

Imaging Anatomy

Size: The overall height of the pituitary gland varies with both gender and age. In prepubescent children, 6 mm or less is considered normal. Physiologic hypertrophy, with a normal height of up to 10 mm, is common in young menstruating females. An upwardly convex gland is common in these patients. Pregnant and lactating females can have an even larger gland with a height of 12 mm. The upward limit of normal in adult males and postmenopausal females is 8 mm.

Signal intensity: Pituitary gland signal varies. With the exception of neonates (in whom the AH can be large and very hyperintense), the AH is typically isointense to gray matter on pre-contrast T1WIs. A dark or black pituitary gland seen on T2* is found in iron overload states (thalassemia, hemochromatosis). A uniformly white pituitary gland on T1WI is uncommon and can be seen in liver failure.

The NH usually has a short T1 (posterior pituitary "bright spot" or PPBS) likely caused by vasopressin/oxytocin neurosecretory granules. The "bright spot" does not suppress with FS as it does not contain fat. Although the absence of a PPBS is common in central diabetes insipidus, up to 20% of normal imaged patients lack a PPBS.

Enhancement: The pituitary gland does not have a blood-brain barrier so it enhances rapidly and strongly following contrast administration. Enhancement is typically slightly less intense than that of venous blood in the adjacent cavernous sinuses.

Pituitary "incidentalomas" are common on T1WI C+ scans (found in 15-20% of cases). Seen as focal areas of hypointensity within the intensely enhancing pituitary gland, they can be caused by intrapituitary cysts as well as nonfunctioning microadenomas. Both are very common at autopsy. If a pituitary "incidentaloma" does not enhance at all, then a benign nonneoplastic cyst (such as a pars intermedia or Rathke cleft cyst) is more likely than a microadenoma.

Differential Diagnosis Approach

Overview: Because the sellar region is anatomically very complex, at least 30 different lesions occur in and around the pituitary gland. They can arise from the pituitary gland or any adjacent structure (brain, third ventricle, meninges, cavernous sinus, arteries, cranial nerves, etc.). At least 75-80% of all sellar/juxtasellar masses are in the "Big 5": Macroadenoma, meningioma, aneurysm, craniopharyngioma, and astrocytoma. All other lesions (e.g., Rathke cleft and arachnoid cysts, germinoma, lymphoma, metastasis, etc.) are each 1-2% or less.

Keys to diagnosis: Anatomic sublocation is the most important key to establishing an appropriate differential diagnosis. Initially dividing lesions into three categories, (1) intrasellar (2) suprasellar and (3) infundibular, is the first step.

https://CafePezeshki.IR

The key to determining anatomic sublocation accurately is asking the question, "Can I find the pituitary gland separate from the mass?" If the gland **is** the mass, it is most likely a macroadenoma. Less likely pathologies that can enlarge the pituitary gland and sometimes appear indistinguishable from macroadenoma include infiltrating lesions, such as sarcoidosis, histiocytosis, hypophysitis, lymphoma, germinoma, and metastasis. If the mass can indeed be identified as separate from the pituitary gland, it is most likely not macroadenoma and arises from structures other than the hypophysis.

Clinical considerations: Patient age is an important consideration in differential diagnosis. Lesions that are common in children (craniopharyngioma and astrocytoma of the optic chiasm/hypothalamus) are less common in adults, in whom the most common masses are macroadenoma, meningioma, and aneurysm. Macroadenomas are very common in adults but, with the exception of adolescent females, are quite rare in children. Beware: A lesion in a prepubescent male that looks like a macroadenoma usually isn't; it is more often nonphysiologic nonneoplastic hyperplasia from end-organ failure.

Imaging appearance: Imaging appearance can be very helpful in evaluating a sellar/juxtasellar lesion. Is the lesion calcified? Does it appear cystic? Does it contain blood products? Is it focal or infiltrating? Does it enhance?

Intrasellar Lesions

Empty sella: Empty sella is seen in 5-10% of patients as an intrasellar CSF collection that flattens the pituitary gland against the sellar floor. Other than empty sella, most intrasellar masses are lesions of the pituitary gland itself.

Pituitary hyperplasia: Diffuse pituitary enlargement or hyperplasia is common and can be physiologic in young menstruating females and postpartum/lactating women. Less commonly, pituitary hyperplasia occurs as a result of end-organ failure, such as hypothyroidism. Rarely, intracranial hypotension and dAVFs cause pituitary enlargement, probably due to passive venous congestion.

Macro- and microadenomas: The most common "real" intrasellar masses are pituitary microadenomas (defined as < 10 mm) and macroadenomas. Macroadenomas may extend superiorly through the diaphragma sella opening into the suprasellar compartment. Occasionally macroadenomas can appear very aggressive and extremely invasive, extending into the cavernous sinus and eroding the skull base. Pituitary carcinoma is exceptionally rare, typically diagnosed at the time of metastatic spread.

Miscellaneous lesions: A number of neoplastic and nonneoplastic processes can infiltrate the pituitary gland and adjacent structures, such as neurosarcoid, lymphoma, and metastases.

Suprasellar Lesions

Children vs. adults*:* Once a lesion is defined as suprasellar, patient age is key to the differential diagnosis. Pediatric suprasellar masses are most often either craniopharyngiomas or pilocytic astrocytomas (hypothalamus, optic chiasm). All other lesions, such as germinoma and histiocytosis, are much less common.

At least 1/2 of all suprasellar masses in adults are upward extensions of macroadenomas through the diaphragma sella. Macroadenomas are typically heterogeneously enhancing masses that may contain cysts or blood products. Macroadenomas often enlarge or remodel the sella turcica. Meningioma and aneurysm are common in adults, accounting for approximately 10% each of all adult suprasellar masses. Both are rare in children. Meningiomas are homogeneously enhancing masses, separate from the pituitary gland. Aneurysms may be identified on MR by a flow void or pulsation artifact. If thrombosed, an aneurysm may have a laminated appearance. CTA or MRA may be helpful in further characterizing a sellar region aneurysm.

Imaging appearance: Cystic-appearing suprasellar masses are often nonneoplastic (enlarged third ventricle, Rathke cleft cyst [RCC], suprasellar arachnoid cyst, and inflammatory cysts, such as neurocysticercosis). RCCs may be intrasellar (40%) or suprasellar (60%). RCCs may be asymptomatic or present with pituitary dysfunction, visual changes, or headache. RCCs are noncalcified, nonenhancing, cystic lesions on CT and MR. A helpful clue on MR is the presence of an intracystic nodule. Craniopharyngioma is the most common suprasellar mass in a child and is often known as the 90% tumor; 90% are cystic, 90% are calcified, and 90% enhance. With the exception of craniopharyngioma, cystic-appearing neoplasms are rare in this location. Pilocytic astrocytoma is the overall most common pediatric glial neoplasm in this area. Pilocytic astrocytomas of the optic chiasm/hypothalamus are solid, not cystic (as they often are when they occur in the posterior fossa).

The presence of calcification is helpful. In older patients, atherosclerosis (cavernous and supraclinoid internal carotid arteries), saccular aneurysm, and meningioma are common lesions that calcify. In children, a calcified suprasellar mass is most often a craniopharyngioma. Neurocysticercosis (NCC) can calcify and may be found in both children and adults, but the suprasellar cistern is a rare location for NCC cysts.

Hemorrhage into a sellar/suprasellar mass can be detected with T2* imaging or SWI. Hemorrhagic macroadenoma, pituitary apoplexy, and thrombosed aneurysm can show "blooming." The pilomyxoid variant of pilocytic astrocytoma is a rare but important cause of a hemorrhagic suprasellar mass in a child or young adult.

Infundibular Stalk Lesions

Infundibular stalk lesions are a distinct differential diagnosis. The normal infundibular stalk should be 2 mm or less in transverse diameter and taper gradually from top to bottom.

A "thick stalk" in a child is usually histiocytosis or germinoma. In an adult, neurosarcoid, lymphocytic hypophysitis, lymphoma, and metastasis are more common. Lesions of the infundibulum often present with diabetes insipidus. Enhancement is often unhelpful as the normal infundibulum lacks a blood-brain barrier and enhances intensely following contrast administration. Neurosarcoid may affect the infundibulum only and appear as a thickened, enhancing stalk, but more commonly presents with other CNS lesions. Hypophysitis may be related to an autoimmune inflammatory disorder, granulomatous disease, IgG4 related, or drug related. A recent cancer immunotherapy (ipilimumab) has been associated with lymphocytic hypophysitis, which may affect the gland &/or only the infundibulum.

https://CafePezeshki.IR

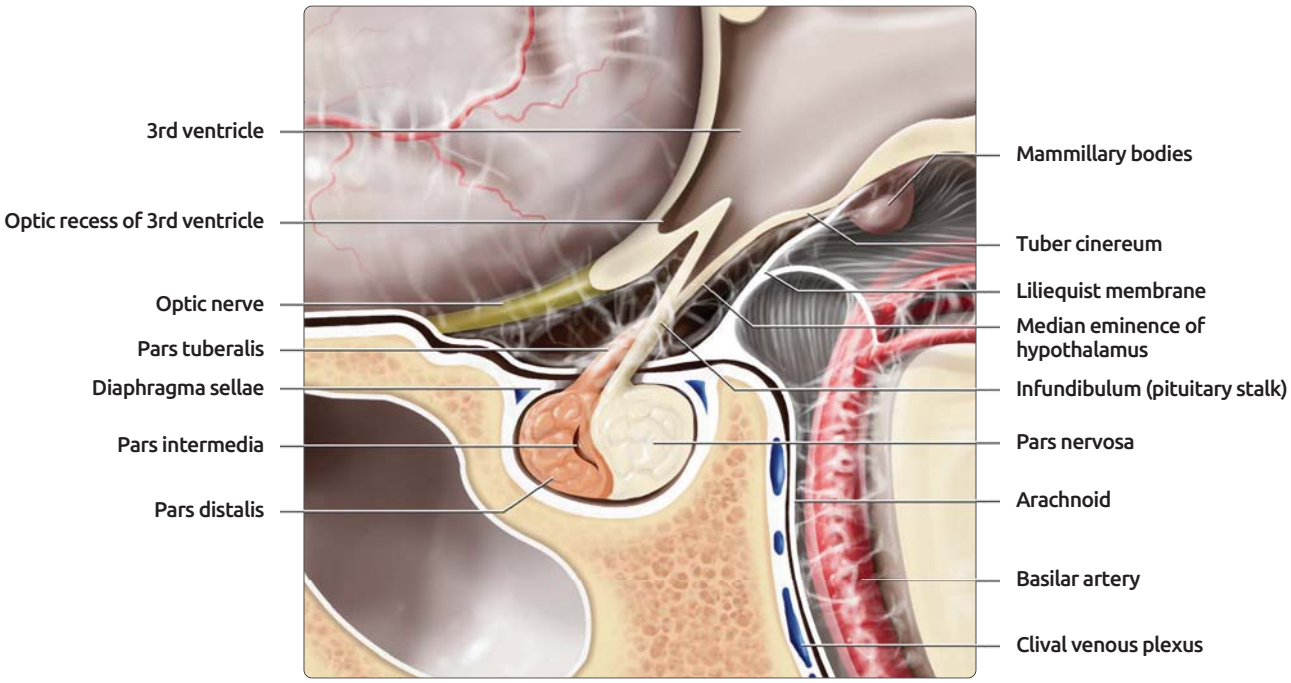

(Top) *Lateral graphic of a normal pituitary shows the adenohypophysis composed of the pars tuberalis, pars intermedia, and pars distalis. The neurohypophysis is composed of the median eminence of the hypothalamus, infundibulum, and pars nervosa. Periosteal dural layer covers the sellar floor.* **(Bottom)** *Coronal graphic depicts the cavernous sinus contents. The cranial nerves that traverse the cavernous sinus within the lateral wall, from superior to inferior, are oculomotor (CN3), trochlear (CN4), and the 1st (ophthalmic or V1) and 2nd (maxillary or V2) divisions of trigeminal (CN5) nerves. The only cranial nerve actually within the venous sinusoids of the cavernous sinus is the abducens nerve (CN6). The abducens nerve is often the 1st cranial nerve affected by a cavernous carotid artery aneurysm.*

https://CafePezeshki.IR

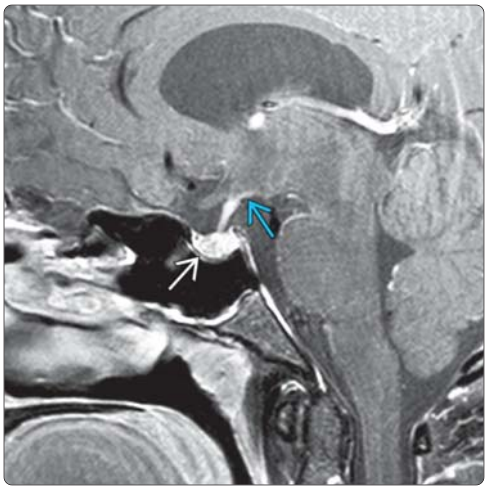

(Left) *Sagittal 3T T1WI with FS MR shows the normal adenohypophysis is isointense with gray matter; the posterior pituitary is hyperintense. This posterior pituitary "bright spot" does not suppress on FS sequences. Note the gradual top-to-bottom tapering of the infundibulum.* **(Right)** *Sagittal T1 C+ FS MR in the same patient shows intense, slightly inhomogeneous enhancement of the pituitary gland. The stalk enhances, as does the tuber cinereum of the hypothalamus, anterior to the mammillary bodies.*

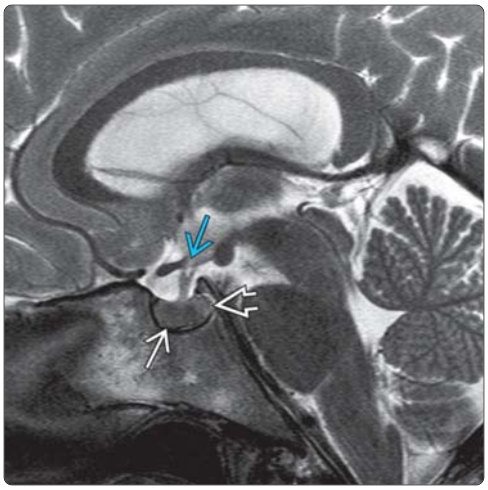

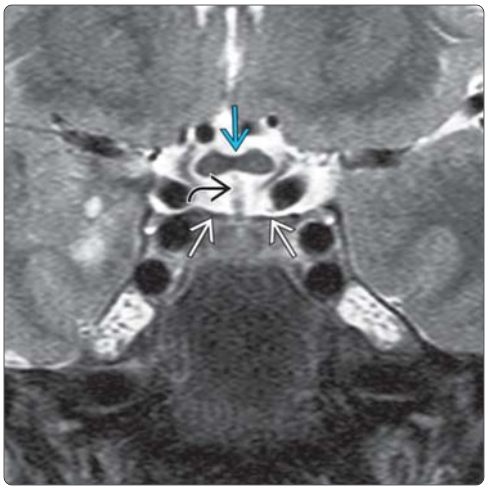

(Left) *Sagittal T2WI MR shows the adenohypophysis (AH) is isointense with brain. The neurohypophysis is slightly hyperintense compared to the AH. Note the infundibular recess of the 3rd ventricle.* **(Right)** *Coronal T2WI MR shows the infundibular stalk passing inferiorly through a small discontinuity in the thin shelf of dura, the diaphragma sellae, seen here as thin black lines forming the roof of the pituitary fossa. The optic chiasm is present superiorly within the suprasellar cistern and is often affected by suprasellar masses.*

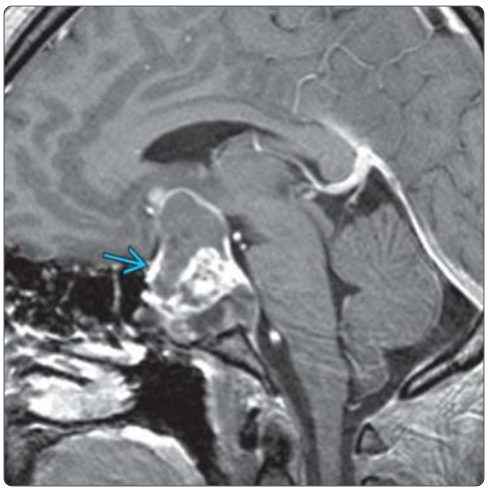

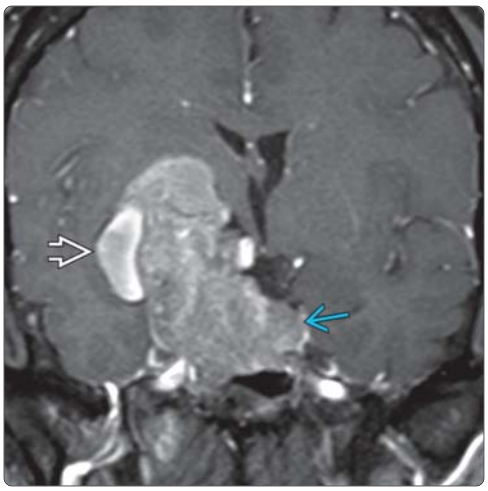

(Left) *Sagittal T1 C+ MR in a child shows a complex, cystic, and solid sellar and suprasellar mass related to an adamantinomatous craniopharyngioma. These masses represent > 50% of pediatric suprasellar neoplasms.* **(Right)** *Coronal T1 C+ MR in an adult with visual symptoms shows a complex sellar and suprasellar macroadenoma with regions of hemorrhage. Macroadenomas are among the most common of all CNS neoplasms, accounting for 10-15% of primary intracranial neoplasms.*

https://CafePezeshki.IR

KEY FACTS

TERMINOLOGY

- Congenital anomalies of pituitary stalk → potential hypothalamic/pituitary axis malfunction

IMAGING

- Posterior pituitary ectopia (PPE)
- Duplicated pituitary gland/stalk (DP)
- PPE: No (or tiny) pituitary stalk, ectopic posterior pituitary (EPP) on midline sagittal T1WI MR
  - Look for associated anomalies: Heterotopia, optic nerve hypoplasia, corpus callosum anomalies
- DP: 2 pituitary stalks on coronal view, thick tuber cinereum on midline sagittal view

TOP DIFFERENTIAL DIAGNOSES

- Posterior pituitary ectopia (PPE)
  - Surgical or traumatic stalk transection
  - Central diabetes insipidus
  - Hypothalamic lipoma (in tuber cinereum)
- Duplicated pituitary gland/stalk (DP)
  - Dilated infundibular recess of 3rd ventricle ("pseudoduplication")
  - Tuber cinereum hamartoma

PATHOLOGY

- PPE: Genetic mutation → defective neuronal migration during embryogenesis
- DP: Genetic mutation unknown; may constitute polytopic field defect due to splitting of notochord

CLINICAL ISSUES

- PPE: Short stature
- DP: Unsuspected finding on craniofacial imaging for other indications

DIAGNOSTIC CHECKLIST

- PPE: Assess optic and olfactory nerves, frontal cortex
- DP: Oral tumors compromise airway patency

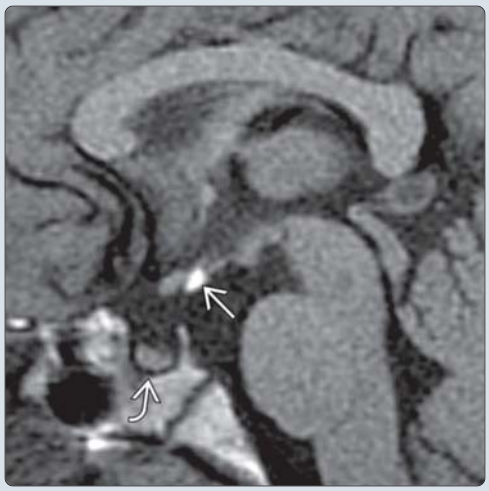

(Left) *Sagittal graphic demonstrates ectopia of the posterior pituitary gland located at the distal end of a truncated pituitary stalk along the median eminence of the hypothalamus. The sella turcica and adenohypophysis are both small.* **(Right)** *Sagittal T1WI MR shows an ectopic posterior pituitary gland located at the median eminence. The pituitary infundibulum is absent, the anterior pituitary gland is small, and the normal bright posterior pituitary gland is not identified in its typical location.*

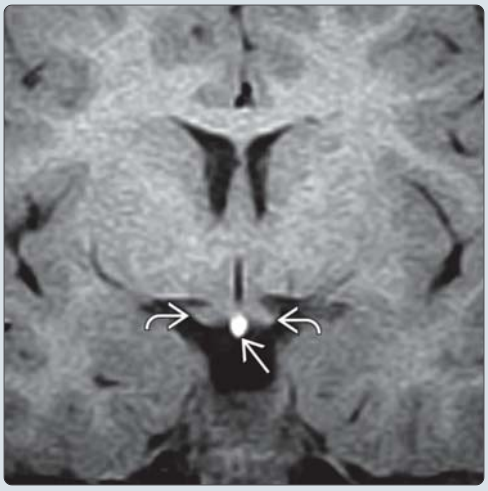

(Left) *Coronal T1WI MR depicts the ectopic posterior pituitary gland location at the median eminence. A pituitary stalk is not visualized below the ectopic posterior pituitary. The septum pellucidum is present, and the optic tracts are of normal size.* **(Right)** *Sagittal T2 MR in a patient with complete absence of the posterior pituitary bright spot shows a small sella turcica and pituitary gland. The optic apparatus is also hypoplastic. A clearly defined pituitary stalk is present.*

https://CafePezeshki.IR

TERMINOLOGY

Definitions

- Congenital anomalies of pituitary stalk → potential hypothalamic/pituitary axis malfunction

IMAGING

General Features

- Best diagnostic clue
  - Posterior pituitary ectopia (PPE): No (or tiny) pituitary stalk, ectopic posterior pituitary (EPP) on midline sagittal T1WI MR
  - Duplicated pituitary gland/stalk (DP): 2 pituitary stalks on coronal view, thick tuber cinereum on midline sagittal view
    - Tuberomammillary fusion: Tuber cinereum/mammillary bodies fused into single mass
  - Pituitary hypoplasia: Small sella turcica and adenohypophysis
- Location
  - PPE: EPP located along median eminence of tuber cinereum or truncated pituitary stalk
  - DP: Paired lateral stalks, pituitary glands, bony fossae
- Size
  - PPE: Anterior pituitary (adenohypophysis) is small
  - DP: Each pituitary gland is normal in size
- Morphology
  - PPE: Small adenohypophysis and osseous sella
  - DP: Each pituitary gland and osseous sella is normal in morphology but laterally located

Radiographic Findings

- Radiography
  - PPE: Small sella turcica on lateral radiography
  - DP: Craniofacial/craniocervical anomalies common; may observe 2 fossae on AP view

CT Findings

- NECT
  - PPE: Narrow pituitary fossa and skull base structures and clivus, ± persistent sphenopharyngeal foramen
  - DP: 2 widely separated pituitary fossae, ± midline basisphenoid cleft or frontonasal dysplasia
- CTA
  - PPE: Medial deviation of juxtasellar/supraclinoid carotid arteries ("kissing" carotids)
  - DP: Duplicated basilar artery, ± widely separated juxtasellar/supraclinoid carotid arteries

MR Findings

- T1WI
  - PPE: Absent, truncated, or thread-like pituitary stalk; small adenohypophysis
    - EPP located along truncated stalk or median eminence of tuber cinereum
      - Usually ↑ signal on T1WI (phospholipids/secretory granules)
      - Posterior pituitary may "dim" as patient outgrows available hormone levels
  - DP: Mass-like thickening of tuber cinereum on sagittal view portends duplicated pituitary axis
    - Mammillary bodies fused with tuber cinereum into thickened 3rd ventricle floor
    - 2 lateralized but otherwise normal pituitary glands/stalks
- T2WI
  - PPE: Variable signal of posterior pituitary
  - DP: Normal signal of glands, stalk, tuberomammillary fusion mass
- T1WI C+
  - Both: Stalks and remnants enhance (absent blood-brain barrier)
  - PPE: Hyperintensity absent if multiple endocrine anomalies/diabetes insipidus; contrast enhancement helps find neurohypophysis
- MRA
  - PPE: Supraclinoid carotid arteries medially deviated, "kiss" in midline; rare absent carotid artery/canal
  - DP: Fenestration (common) or total duplication (rare) of basilar artery (BA); widely separated juxtasellar carotid arteries

Imaging Recommendations

- Best imaging tool
  - Multiplanar T1WI MR
- Protocol advice
  - Both: Sagittal and coronal T1WI of hypothalamic/pituitary axis
  - PPE: Assess olfactory nerves, anterior frontal lobes with coronal FSE T2WI
    - 3D T1WI SPGR can identify small posterior pituitaries, occult on conventional 2D sagittal T1WI
  - DP: 3D CT of skull base and face in selected patients

DIFFERENTIAL DIAGNOSIS

Posterior Pituitary Ectopia

- Central diabetes insipidus
  - Hyperintensity of posterior pituitary lobe is absent but normal location of stalk and gland
- Surgical or traumatic stalk transection
  - Permits build-up of neurosecretory granules along stump
- Hypothalamic lipoma (located at tuber cinereum)
  - Posterior pituitary is not suppressed by fat saturation; lipoma is suppressed

Duplicated Pituitary Gland/Stalk

- Dilated infundibular recess of 3rd ventricle ("pseudoduplication")
  - Simulates duplicated stalk but only 1 gland and 1 pituitary fossa
- Tuber cinereum hamartoma
  - Round mass of 3rd ventricle floor but 1 midline pituitary stalk/gland

PATHOLOGY

General Features

- Etiology
  - PPE: Genetic mutation → defective neuronal migration during embryogenesis

https://CafePezeshki.IR

  - Adenohypophysis (anterior pituitary) grows up from stomodeal ectoderm (Rathke pouch)
    - Hypothalamic releasing hormones reach adenohypophysis via infundibular portal system
    - Anterior pituitary dysfunction thought to be related to absent infundibulum
  - Neurohypophysis (posterior pituitary) grows down from diencephalic neuroectoderm, remains attached by stalk
    - Antidiuretic hormone and oxytocin transported to neurohypophysis via neurosecretory cells along infundibulum
  - DP: Congenital anomaly, presumed genetic duplication of stomodeal origin structures 2° to aberrant ventral induction
    - Theory: Duplication prechordal plate and tip of rostral notochord leads to duplicated pituitary primordium
- Genetics
  - PPE: Mutations in genes encoding developmental transcription factors allow maldevelopment
    - *HESX1* (homeobox gene), *PIT1*, *PITX2*, *LHX3*, *LHX4*, *PROP1*, *SF1*, and *TBX19 (TPIT)*
  - DP: Gene mutation unknown; may constitute polytopic field defect due to splitting of notochord
- Associated abnormalities
  - Duplicated pituitary gland/stalk
    - Midline tumors in oral, nasopharyngeal, palate
      - Epignathus, hamartomas, teratomas, dermoids, lipomas
    - Spinal anomalies include segmentation/fusion anomalies, schisms, hydromyelia, enteric cysts
    - Rib and cardiac anomalies, Pierre-Robin anomaly
  - **Both**: Common midline CNS anomalies
    - Posterior pituitary ectopia
      - ± anomalies of structures formed at same time (anterior pituitary lobe, forebrain, eyes, olfactory bulbs)
      - ± lobar holoprosencephaly, septo-optic dysplasia, Joubert syndrome
    - Duplicated pituitary gland/stalk
      - Callosal dysgenesis, Dandy-Walker spectrum, frontonasal dysplasia
      - Craniofacial clefting and duplication anomalies: Frontonasal dysplasia; clefts/duplication of skull base, face, mandible, nose, palate
  - Pituitary hypoplasia associated with Kallmann syndrome

Gross Pathologic & Surgical Features

- PPE: Hypoplastic anterior lobe, stalk truncation or aplasia
  - Sella may be covered over with dura
- DP: Tuberomammillary fusion, 2 normal glands/stalks

CLINICAL ISSUES

Presentation

- Most common signs/symptoms
  - PPE: Short stature
  - DP: Unsuspected finding on craniofacial imaging for other indications
- Other signs/symptoms
  - PPE: Multiple pituitary hormone deficiencies common
  - DP: Rarely symptomatic from pituitary causes
- Clinical profile
  - PPE: Short stature (growth hormone deficiency), ± multiple endocrine deficiencies
    - Peak growth hormone levels < 3 g/L more likely to have abnormal MR
    - ± anosmia, poor vision, seizures (cortical malformations)
    - Neonatal hypoglycemia or jaundice, micropenis, single central incisor
  - DP: ± facial midline anomalies, oral or nasal mass (hamartoma or teratoma)
    - Face: ± hypertelorism or frontonasal dysplasia
    - Craniocervical segmentation and fusion anomalies
    - Airway or oral obstruction from pharyngeal tumor

Demographics

- Age
  - PPE: Early growth failure apparent in childhood
  - DP: Usually discovered in early infancy during imaging for complicated facial anomalies
- Gender
  - PPE: M > F
  - DP: M < F
- Epidemiology
  - PPE: Prevalence 1:4,000 to 1:20,000 births
  - DP: Extremely rare (reported in 20+ reported cases)

Natural History & Prognosis

- PPE: Stable if no pituitary/hypothalamic crises; growth may be normal for a while
  - Severity and number of hormone deficiencies predicted by degree of stalk and gland hypoplasia
- DP: Usually significant intracranial, upper airway, or craniocervical malformations (some lethal)
  - Clinical outcome unrelated to pituitary function

Treatment

- Assess/treat endocrine malfunction

DIAGNOSTIC CHECKLIST

Consider

- PPE: Assess optic and olfactory nerves, frontal cortex
- DP: Oral tumors compromise airway patency

Image Interpretation Pearls

- PPE & DP: Can miss findings/diagnosis if thick sections (MR) are used or osseous structures (bone CT) not evaluated

SELECTED REFERENCES

1. Ören NC et al: Panhypopituitarism with ectopic posterior pituitary lobe, heterotopia, polymicrogyria, corpus callosum dysgenesis, and optic chiasm/nerve hypoplasia: is that an undefined neuronal migration syndrome? AJNR Am J Neuroradiol. ePub, 2015
2. Ramakrishnaiah RH et al: Reliability of magnetic resonance imaging for the detection of hypopituitarism in children with optic nerve hypoplasia. Ophthalmology. 121(1):387-91, 2014
3. Ginat DT et al: Nasal hamartoma associated with duplicated pituitary. J Comput Assist Tomogr. 37(3):369-70, 2013

https://CafePezeshki.IR

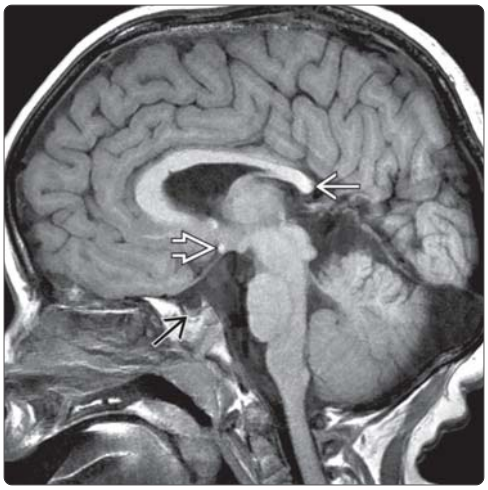

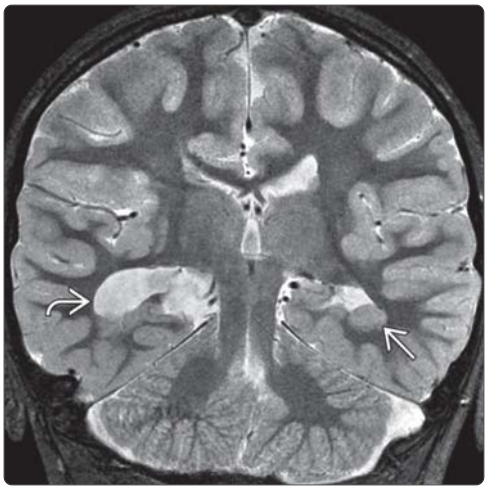

(Left) *Sagittal T1WI shows a small pituitary gland ⇨ and absent pituitary stalk. The hyperintense ectopic posterior pituitary gland ⇨ is located at the median eminence. The corpus callosum is also dysmorphic with characteristic small splenium ⇨.* **(Right)** *Coronal T2WI MR in the same patient demonstrates associated left periventricular nodular gray matter heterotopia ⇨ and dysplastic inferior temporal lobe gray matter. Right choroid fissure cyst ⇨ is probably unrelated.*

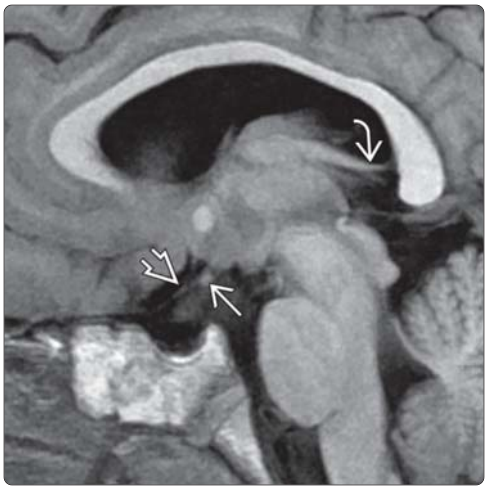

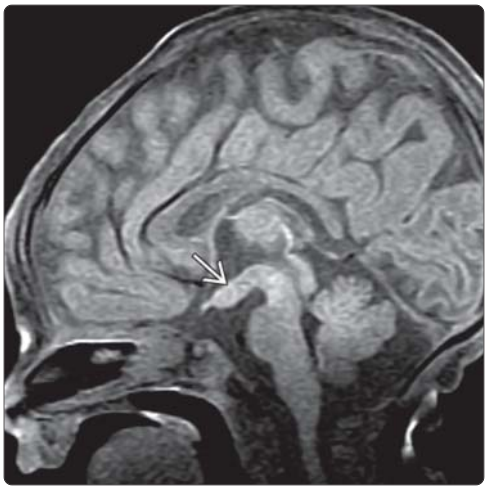

(Left) *Sagittal T1WI MR demonstrates a bright ectopic posterior pituitary gland ⇨ in a patient with septo-optic dysplasia. Note the small optic chiasm ⇨ and the low location of the fornices ⇨.* **(Right)** *Sagittal T1WI MR in a patient with duplicated pituitary glands shows a thickened floor of sella and fusion of the tuber cinereum and mammillarymammillary bodies (tuberomammillary fusion) ⇨. Note the absence of a midline sella turcica and pituitary infundibulum.*

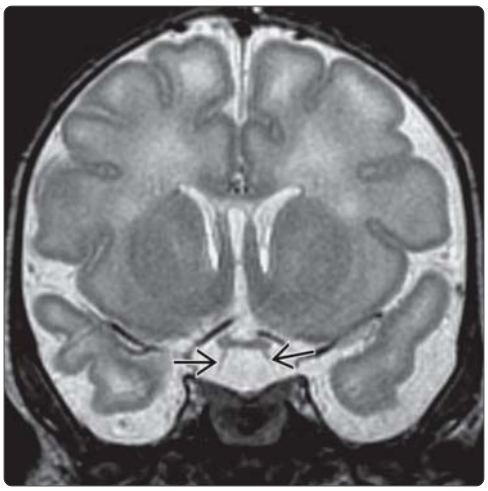

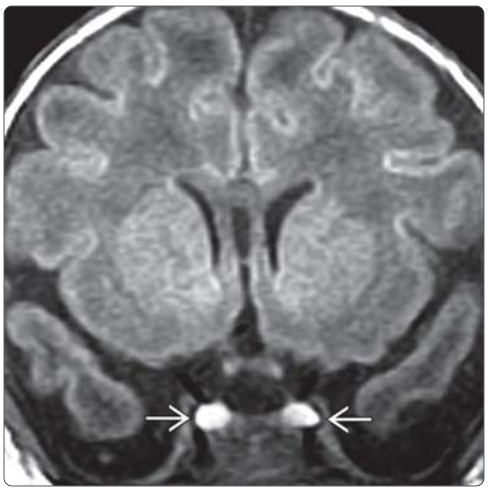

(Left) *Coronal T2WI MR in a newborn with midline skull base clefting reveals 2 pituitary stalks ⇨. The normal-sized pituitary stalks project below the optic chiasm toward duplicated pituitary glands.* **(Right)** *Coronal T1WI MR demonstrates 2 normal-sized pituitary glands ⇨ laterally displaced within the abnormal skull base. The glands are uniformly hyperintense due to maternal hormonal influences. The pituitary gland is normally diffusely hyperintense on T1WI in newborns.*

https://CafePezeshki.IR

KEY FACTS

TERMINOLOGY

- a.k.a. hypothalamic hamartoma (HH)
- Nonneoplastic; congenital gray matter heterotopia

IMAGING

- Hypothalamic mass contiguous with tuber cinereum
  - Located between mammillary bodies and infundibulum
  - Can be sessile or pedunculated ("collar button")
  - Size ranges from few mm to several centimeters
- Isointense with GM on T1WI
  - Can be slightly hyperintense on T2/FLAIR
  - Large lesions can be heterogeneous, contain cysts
  - No enhancement on T1C+

TOP DIFFERENTIAL DIAGNOSES

- Chiasmatic/hypothalamic astrocytoma
- Craniopharyngioma
- Ectopic posterior pituitary
- Lipoma
- Germinoma
- Langerhans cell histiocytosis

PATHOLOGY

- Mature but dysplastic neuronal ganglionic tissue

CLINICAL ISSUES

- Infant with epilepsy or precocious puberty
  - Cognitive, neuropsychiatric comorbidities common
- Older children with precocious puberty
  - Often tall, overweight, with advanced bone age
- Shape, size of hamartoma often predicts symptoms, presentation
  - Large sessile lesions → seizures
  - Small pedunculated lesions → central precocious puberty

DIAGNOSTIC CHECKLIST

- If hypothalamic mass in seizure imaging, think HH

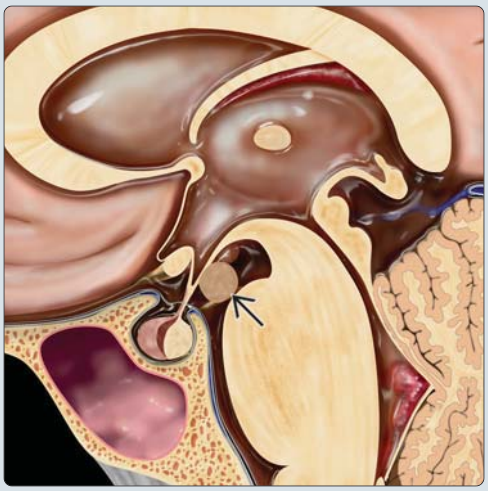

(Left) *Sagittal graphic shows a classic pedunculated tuber cinereum hamartoma interposed between the infundibulum anteriorly and the mammillary bodies posteriorly. The mass resembles gray matter.* **(Right)** *Sagittal T1WI MR in an 8-year-old female with precocious puberty shows a classic pedunculated "collar button" hypothalamic hamartoma. The lesion is interposed between the infundibular stalk anteriorly and the mammillary bodies posteriorly. HHs are classically isointense with gray matter.*

(Left) *Sagittal T2WI MR in a patient presenting with precocious puberty reveals a pedunculated hypothalamic mass located between the median eminence and mammillary bodies. The mass is isointense with cortex.* **(Right)** *Sagittal T1WI C+ MR in the same case shows the mass does not enhance. This is classic pedunculated hypothalamic hamartoma (HH).*

https://CafePezeshki.IR

TERMINOLOGY

Synonyms

- Hypothalamic hamartoma (HH), diencephalic hamartoma

Definitions

- Nonneoplastic congenital gray matter heterotopia in region of tuber cinereum

IMAGING

General Features

- Best diagnostic clue
  - Nonenhancing hypothalamic mass contiguous with tuber cinereum
- Location
  - Tuber cinereum of hypothalamus
  - Located between pons/mammillary bodies and hypothalamic infundibulum
- Size
  - Variable, few mm to giant (3-5 cm)
- Morphology
  - Sessile or pedunculated mass
  - Similar in density/intensity to gray matter

Radiographic Findings

- Radiography
  - ± suprasellar calcifications, eroded dorsum, enlarged sella (rare)

CT Findings

- NECT
  - Homogeneous suprasellar mass
    - Isodense → slightly hypodense
    - Cysts and calcification are uncommon
    - ± patent craniopharyngeal canal (very rare)
- CECT
  - No pathologic enhancement

MR Findings

- T1WI
  - Mass located between mammillary bodies and infundibulum
  - Isointense → slightly hypointense to gray matter
- T2WI
  - Isointense → slightly hyperintense (secondary to fibrillary gliosis)
- FLAIR
  - Isointense → slightly hyperintense to gray matter
- T1WI C+
  - Nonenhancing; if enhances, consider other diagnosis
- MRS
  - ↓ NAA and NAA/Cr, mild ↑ choline (Cho) and Cho/Cr, ↑ myoinositol (mI) and mI/Cr
    - ↓ NAA and ↑ Cho indicate reduced neuronal density and relative gliosis, respectively, compared to normal gray matter
    - ↑ mI/Cr correlates with ↑ glial component and lesion T2 hyperintensity

Imaging Recommendations

- Best imaging tool
  - Multiplanar MR imaging
- Protocol advice
  - Thin-section sagittal and coronal T2, T1WI C+ MR

DIFFERENTIAL DIAGNOSIS

Craniopharyngioma

- Most common suprasellar mass in children
- Variable signal intensity cysts (90%), calcifications (90%), and enhancement (90%)
- Longstanding lesion, frequently with short stature and pituitary abnormalities

Chiasmatic/Hypothalamic Astrocytoma

- 2nd most common pediatric suprasellar mass (± NF1)
- Hyperintense on T2WI MR ± contrast enhancement (heterogeneous, often vigorous)
- Optic pathway or hypothalamus ± optic tract extension

Ectopic Posterior Pituitary

- Ectopic hyperintense focus on T1WI MR
- No normal orthotopic posterior pituitary hyperintensity

Germinoma

- Thickening, abnormal enhancement of pituitary stalk rather than tuber cinereum
- Diabetes insipidus common
- ± multicentric: Suprasellar, pineal, thalamus, basal ganglia
- Early leptomeningeal metastatic dissemination

Langerhans Cell Histiocytosis

- Thickening, abnormal enhancement of pituitary stalk rather than tuber cinereum
- Diabetes insipidus common
- Look for lytic bone lesions in typical locations

Lipoma

- Hyperintense fat signal on T1WI MR
- Hypointense on STIR or fat-saturated sequences

PATHOLOGY

General Features

- Etiology
  - Neuronal migration anomaly (occurs between gestational days 33-41)
  - Affects normal hypothalamic regulation of autonomic, endocrine, neurological, behavioral functions
  - Shape and size of hamartoma postulated to predict symptoms
    - Large sessile lesions → seizures
    - Small pedunculated lesions → central precocious puberty (CPP)
    - Presentation with both seizures and CPP common
- Genetics
  - *GLI3* mutation
    - Pallister-Hall syndrome (PHS)
      - Hamartoma or hamartoblastoma of tuber cinereum; often large mass
      - Digital malformations (short metacarpals, syndactyly, polydactyly)
      - Other midline (epiglottis/larynx) and cardiac/renal/anal anomalies

https://CafePezeshki.IR

- Greig cephalopolysyndactyly syndrome (GCPS)

Staging, Grading, & Classification

- Valdueza classification
  - Pedunculated, central precocious puberty or asymptomatic
    - Originates in tuber cinereum
    - Originates in mammillary bodies
  - Sessile, hypothalamus displaced, seizures
    - More hypothalamic dysfunction and abnormal behavior

Gross Pathologic & Surgical Features

- Mature neuronal ganglionic tissue projecting from hypothalamus, tuber cinereum, or mammillary bodies
- Pedunculated or sessile, rounded or nodular

Microscopic Features

- Well-differentiated neurons interspersed with glial cells, myelinated/unmyelinated axons, variable amounts of fibrillary gliosis
  - Hamartoblastomas include primitive undifferentiated cells

CLINICAL ISSUES

Presentation

- Most common signs/symptoms
  - Luteinizing hormone-releasing hormone (LHRH) dependent CPP presenting at very young age
  - Refractory symptomatic mixed seizure types, including gelastic seizures
    - Gelastic seizures are recurrent automatic bursts of laughter without mirth
    - Rarely occur in conjunction with focal cortical dysplasia or hypothalamic astrocytoma
  - Other seizure types frequent with HH; always look for HH in child with epilepsy
- Clinical profile
  - Infant with gelastic seizures or precocious puberty
  - Older children with precocious puberty; tall, overweight, and advanced bone age

Demographics

- Age
  - Usually present between 1-3 years of age
- Gender
  - No predilection; some reports M > F
- Ethnicity
  - No predilection
- Epidemiology
  - Of histologically verified lesions, 3/4 have precocious puberty and 1/2 seizures
  - Up to 33% of patients with central precocious puberty have HH

Natural History & Prognosis

- Size should remain stable; if growth is detected, surgery/biopsy is indicated
- Symptomatic lesions: Sessile >> pedunculated

Treatment

- Medical: Hormonal-suppressive therapy, treat seizures
- Surgical: If medical therapy failure or rapid lesion growth

DIAGNOSTIC CHECKLIST

Consider

- If hypothalamic mass identified in seizure imaging, think HH

Image Interpretation Pearls

- Classic = nonenhancing hypothalamic mass
  - Isointense to gray matter on T1WI, slightly ↑ signal on T2WI/FLAIR

SELECTED REFERENCES

1. Démurger F et al: New insights into genotype-phenotype correlation for GLI3 mutations. Eur J Hum Genet. 23(1):92-102, 2015
2. Wu J et al: Mechanisms of intrinsic epileptogenesis in human gelastic seizures with hypothalamic hamartoma. CNS Neurosci Ther. 21(2):104-11, 2015
3. Li CD et al: Classification of hypothalamic hamartoma and prognostic factors for surgical outcome. Acta Neurol Scand. 130(1):18-26, 2014
4. Alves C et al: Giant hypothalamic hamartoma: case report and literature review. Childs Nerv Syst. 29(3):513-6, 2013
5. Mittal S et al: Hypothalamic hamartomas. Part 1. Clinical, neuroimaging, and neurophysiological characteristics. Neurosurg Focus. 34(6):E6, 2013
6. Pati S et al: Diagnosis and management of epilepsy associated with hypothalamic hamartoma: an evidence-based systematic review. J Child Neurol. 28(7):909-16, 2013
7. Parvizi J et al: Gelastic epilepsy and hypothalamic hamartomas: neuroanatomical analysis of brain lesions in 100 patients. Brain. 134(Pt 10):2960-8, 2011
8. Beggs J et al: Hypothalamic hamartomas associated with epilepsy: ultrastructural features. J Neuropathol Exp Neurol. 67(7):657-68, 2008
9. Ng YT: Clarification of the term "status gelasticus" and treatment and prognosis of gelastic seizures. Pediatr Neurol. 38(4):300-1; author reply 301-2, 2008
10. Pleasure SJ et al: Hypothalamic hamartomas and hedgehogs: not a laughing matter. Neurology. 70(8):588-9, 2008
11. Castro LH et al: Epilepsy syndromes associated with hypothalamic hamartomas. Seizure. 16(1):50-8, 2007
12. Coons SW et al: The histopathology of hypothalamic hamartomas: study of 57 cases. J Neuropathol Exp Neurol. 66(2):131-41, 2007
13. Amstutz DR et al: Hypothalamic hamartomas: Correlation of MR imaging and spectroscopic findings with tumor glial content. AJNR Am J Neuroradiol. 27(4):794-8, 2006
14. Boudreau EA et al: Hypothalamic hamartomas and seizures: distinct natural history of isolated and Pallister-Hall syndrome cases. Epilepsia. 46(1):42-7, 2005
15. Freeman JL et al: MR imaging and spectroscopic study of epileptogenic hypothalamic hamartomas: analysis of 72 cases. AJNR Am J Neuroradiol. 25(3):450-62, 2004

https://CafePezeshki.IR

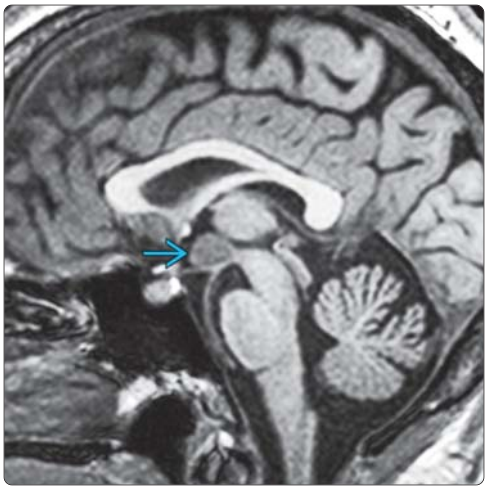

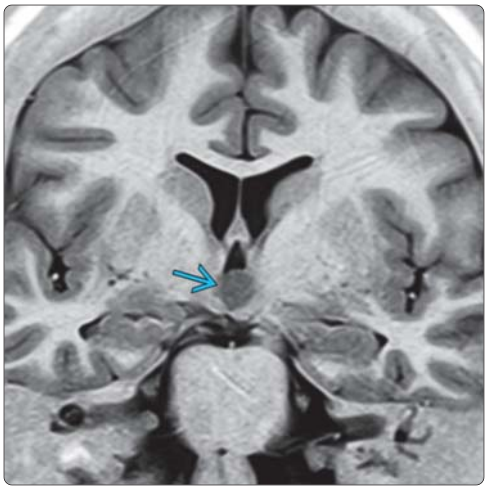

(Left) *Sagittal T1WI MR in a 36-year-old woman being evaluated for seizures shows a well-delineated suprasellar mass* ⇨ *that appears to lie within the 3rd ventricle.* **(Right)** *Coronal thin-section IR shows the mass* ⇨ *is actually in the hypothalamus. The mass is clearly isointense with gray matter.*

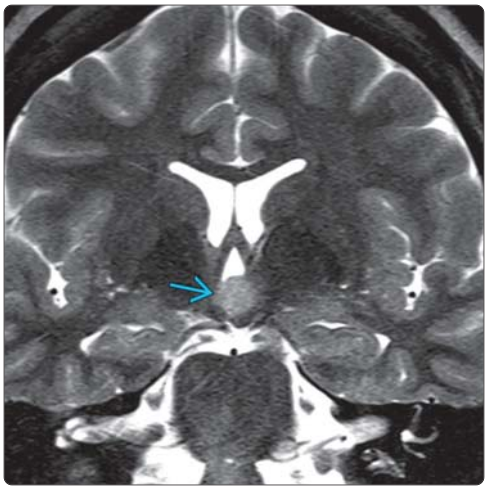

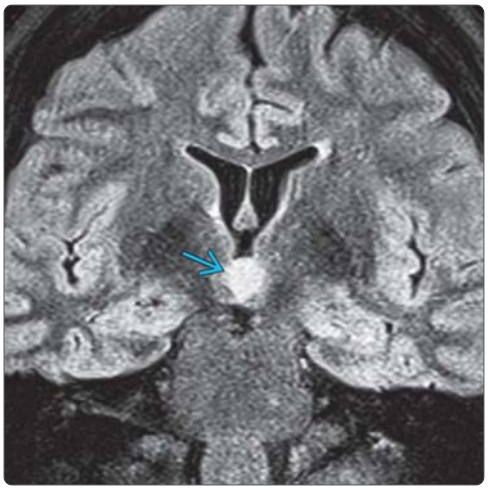

(Left) *Coronal T2WI MR in the same patient shows the mass* ⇨ *remains isointense with gray matter and elevates, but does not obstruct, the 3rd ventricle.* **(Right)** *Coronal FLAIR in the same patient shows the lesion* ⇨ *appears slightly hyperintense relative to cortex. The mass did not enhance following contrast administration. This is a classic sessile HH.*

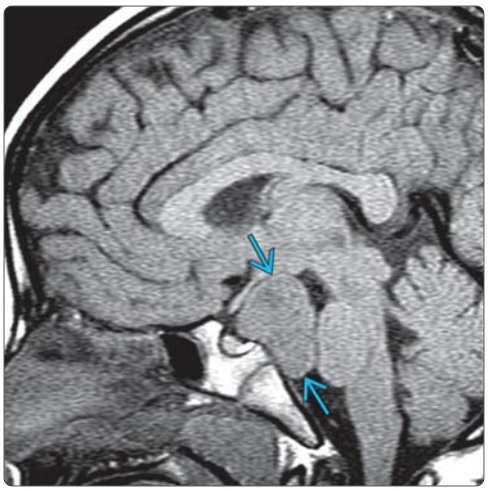

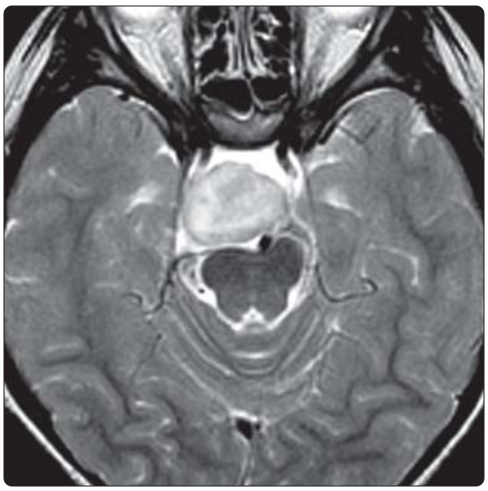

(Left) *Sagittal T1WI in a child with precocious puberty shows a large lobulated suprasellar mass* ⇨ *that is isointense with cortex & is clearly separate from the pituitary gland & optic chiasm. The mass is so large it displaces the brainstem posteriorly.* **(Right)** *Axial T2WI in the same patient shows the mass is heterogeneously hyperintense compared to cortex. HHs can be huge, measuring up to several centimeters in diameter. A mass of dysplastic, disorganized gray matter was removed at surgery and was consistent with HH.*

https://CafePezeshki.IR

Rathke Cleft Cyst

KEY FACTS

TERMINOLOGY

- Nonneoplastic cyst arising from remnants of embryonic Rathke cleft
- Benign sellar region endodermal cyst lined by ciliated, mucus-producing epithelium

IMAGING

- Nonenhancing, noncalcified, intrasellar &/or suprasellar cyst with intracystic nodule
  - Completely intrasellar (40%), suprasellar extension (60%)
  - Density/signal intensity varies with cyst content (serous vs. mucoid)
- Most symptomatic RCCs: 5-15 mm in diameter
- Occasionally RCCs can become very large
- Claw sign = enhancing rim of compressed pituitary surrounding nonenhancing cyst
- No internal enhancement

TOP DIFFERENTIAL DIAGNOSES

- Craniopharyngioma
- Cystic pituitary adenoma
- Arachnoid cyst
- Other nonneoplastic cyst (pars intermedia, colloid cyst)

CLINICAL ISSUES

- Most are asymptomatic, found incidentally at imaging or autopsy
- Common presenting features when symptomatic: Headache, pituitary dysfunction, visual changes
- Rare but important: Apoplexy, cavernous sinus syndrome
  - Can be indistinguishable from pituitary apoplexy
- Conservative management if asymptomatic
  - Have been reported to resolve without therapy
- Surgical aspiration, partial excision, or resection if symptomatic
  - Recurrence rates in up to 18% of patients

(Left) *Coronal graphic shows a typical suprasellar Rathke cleft cyst interposed between the pituitary gland ⇨ and the optic chiasm ⇨.* **(Right)** *Sagittal T1WI MR in a 32-year-old woman with amenorrhea shows a hyperintense mass within the pituitary gland ⇨ anterior to the normal T1-hyperintense neurohypophysis ⇨. Imaging mimics a hemorrhagic pituitary microadenoma. Rathke cleft cyst was found at resection. Small Rathke cleft cysts are most commonly asymptomatic and may be managed conservatively.*

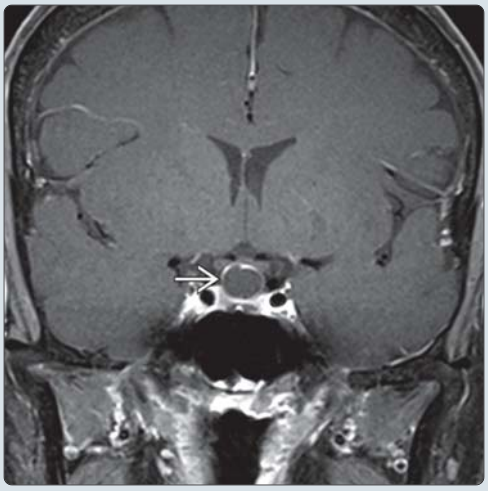

(Left) *Coronal T1WI C+ MR in a 62-year-old woman with headaches shows a cystic suprasellar mass ⇨ with mild peripheral enhancement, a claw sign related to compression of the adjacent normal pituitary gland by the Rathke cleft cyst. Note the lack of enhancement within the cyst.* **(Right)** *Coronal T2WI MR in the same patient shows a hyperintense cyst with a hypointense intracystic nodule ⇨. An intracystic nodule may be seen in up to 75% of Rathke cleft cysts and is a helpful clue to the correct diagnosis.*

https://CafePezeshki.IR

TERMINOLOGY

Abbreviations

- Rathke cleft cyst (RCC)

Definitions

- Nonneoplastic cyst arising from remnants of embryonic Rathke cleft
- Benign sellar region endodermal cyst lined by ciliated, mucus-producing epithelium

IMAGING

General Features

- Best diagnostic clue
  - Nonenhancing, noncalcified, intrasellar &/or suprasellar cyst with intracystic nodule
  - Uncommon but pathognomonic = posterior ledge sign
    - Upward extension through diaphragma sellae
    - Ledge of tissue overlies posterior lobe
- Location
  - Completely intrasellar (40%), suprasellar extension (60%)
  - Most Rathke cleft cysts are limited to sella
    - Between anterior, intermediate lobes
  - Symptomatic Rathke clef cysts involve suprasellar location
- Size
  - Most symptomatic Rathke cleft cysts are between 5-15 mm in diameter
  - Occasionally become very large
    - May cause expansile intrasellar/suprasellar mass
    - Rare: Erode skull base
  - Size usually constant, does not enlarge
    - Transient decrease reported in response to glucocorticoids
- Morphology
  - Well defined, round/ovoid

CT Findings

- NECT
  - Well-delineated, round/lobulated, intra-/suprasellar mass
    - Hypodense (75%), mixed iso-/hypodense (20%)
    - Hyperdense (5-10%)
    - Ca++ (10-15%), curvilinear, in cyst wall
  - Rare: May cause sphenoid sinusitis
- CECT
  - Does not enhance
  - Occasionally see claw sign with normal pituitary gland surrounding the cyst

MR Findings

- T1WI
  - Varies with cyst content (serous vs. mucoid)
    - Hyperintense (50%), hypointense (50%)
    - Hyperintense intracystic nodule (75%)
    - Mixed (5-10%), may have fluid-fluid level
- T2WI
  - Varies with cyst content
    - Hyperintense (70%), iso-/hypointense (30%)
    - Hypointense intracystic nodule (75%)
- FLAIR
  - Hyperintense
- T2* GRE
  - Rarely blooms
- T1WI C+
  - No internal enhancement
    - Claw sign = enhancing rim of compressed pituitary surrounding nonenhancing cyst
    - Small nonenhancing intracystic nodule (75%)
    - If enhancing nodule present, likely a craniopharyngioma

Imaging Recommendations

- Best imaging tool
  - MR
- Protocol advice
  - Thin-section high-resolution imaging of sellar region
  - Sagittal, coronal pre-contrast T1/T2WI
  - "Dynamic" contrast-enhanced coronal T1WI through sella
  - Sagittal, coronal thin-section T1WI C+

DIFFERENTIAL DIAGNOSIS

Craniopharyngioma

- Histologic continuum between Rathke cleft cyst, craniopharyngioma
- Floccular Ca++ common in craniopharyngioma, rare in Rathke cleft cyst
- Noncalcified RCC can be indistinguishable from craniopharyngioma on imaging
- Rim or nodular enhancement (90%)
- Cytokeratin profile helps distinguish from Rathke cleft cyst
  - RCCs express cytokeratins 8, 20

Cystic Pituitary Adenoma

- Ca++ rare
- Signal intensity often heterogeneous
- Rim or rim with nodular enhancement common

Arachnoid Cyst

- Follows CSF signal intensity
- Does not occur within pituitary gland
- No intracystic nodule

Other Nonneoplastic Cyst

- Dermoid cyst
  - May have short T1 signal related to fat or Ca++
  - Look for evidence of rupture
- Epidermoid cyst
  - Mild irregular enhancement, Ca++ (25%)
  - DWI hyperintensity, FLAIR lack of suppression
  - Otherwise follow CSF signal
- Miscellaneous intrasellar cyst
  - Pars intermedia, colloid cysts
- Rare: Sellar/hypophyseal neurocysticercosis (NCC)
  - May see racemose NCC in sellar/suprasellar region
  - May rarely see scolex

PATHOLOGY

General Features

- Etiology

https://CafePezeshki.IR

- One of spectrum of midline sellar/juxtasellar endodermal cysts
- Arises from embryonic remnants of fetal Rathke pouch
  - Rathke cleft normally regresses by 12th gestational week
- Genetics
  - No known heritable conditions
- Associated abnormalities
  - Sphenoid sinusitis (rare)
  - Compression of optic chiasm, pituitary gland, hypothalamus
    - May cause hyperintensity on T2WI/FLAIR along optic chiasm, tracts
  - Embryology
    - Persistence of Rathke pouch
    - Stomodeum (primitive oral cavity) invaginates
    - Extends dorsally, forms craniopharyngeal duct
    - Meets infundibulum (outgrowth of 3rd ventricle) by 11th fetal week, gives rise to hypophysis
    - Anterior wall of pouch forms anterior lobe, pars tuberalis
    - Posterior wall forms pars intermedia
    - Lumen forms narrow cleft (Rathke cleft) that normally regresses by 12th week of gestation
    - Persistence, expansion gives rise to RCC

Gross Pathologic & Surgical Features

- Smoothly lobulated, well-delineated, intrasellar/suprasellar cystic mass
  - Content varies from clear CSF-like fluid to thick mucoid material

Microscopic Features

- Wall = single layer of ciliated cuboidal/columnar epithelium ± goblet cells
  - Changes of mixed acute, chronic inflammation may be present
- May see squamous metaplasia (associated with increased rates of recurrent cysts)
- Variable cyst content
  - Clear or serous
  - ± hemorrhage, hemosiderin
  - Amorphous, inspissated, eosinophilic, mucicarmine(+) colloid ± cholesterol clefts
  - Firm, waxy, yellow, inspissated material
  - Rare: Hemorrhage (cyst apoplexy)
- Immunohistochemical stains positive for cytokeratin
  - Express cytokeratins 8, 20

CLINICAL ISSUES

Presentation

- Most common signs/symptoms
  - Most are asymptomatic, found incidentally at imaging or autopsy
    - Found in up to ~ 20% of autopsy cases
  - Symptomatic Rathke cleft cyst
    - Larger lesions, typically > 1 cm
    - Pituitary dysfunction (70%)
      - Amenorrhea/galactorrhea, diabetes insipidus, panhypopituitarism, hyperprolactinemia
    - Visual disturbances (45-55%)
    - Headache (50%)
  - Other signs/symptoms
    - Head pain, visual disturbance
    - Hypopituitarism
    - Central diabetes insipidus
  - Rare but important: Apoplexy, cavernous sinus syndrome
    - Cyst apoplexy
      - Can occur ± intracystic hemorrhage
      - Can be indistinguishable from pituitary apoplexy
    - Cavernous sinus syndrome
      - Caused by lateral extension of Rathke cleft cyst into cavernous sinus
- Clinical profile
  - Asymptomatic most commonly

Demographics

- Age
  - Mean: = 45 years
- Gender
  - Slight female predominance
- Epidemiology
  - Common intrasellar/suprasellar nonneoplastic cyst
  - Usually incidental, found in up to 20% of all autopsies

Natural History & Prognosis

- Most are stable, do not change in size/signal intensity
- Some cysts may shrink/disappear spontaneously
- Iso-/hyperintense cysts on T1WI more often cause symptoms
- Rathke cleft cysts do not undergo neoplastic degeneration
- Some authors propose a continuum from RCC to craniopharyngioma

Treatment

- Conservative if asymptomatic
- Surgical aspiration/partial excision/resection if symptomatic
  - Persistent/recurrent cyst formation occurs in approximately 15-18% of patients
  - May occur many years after surgery

DIAGNOSTIC CHECKLIST

Consider

- Obtaining endocrine profile

Image Interpretation Pearls

- Look for hypointense intracystic nodule on T2WI

SELECTED REFERENCES

1. Alomari AK et al: Craniopharyngioma arising in a Rathke's cleft cyst: case report. J Neurosurg Pediatr. 15(3):250-4, 2015
2. Chotai S et al: Characteristics of Rathke's cleft cyst based on cyst location with a primary focus on recurrence after resection. J Neurosurg. 1-10, 2015
3. Esteves C et al: Pituitary incidentalomas: analysis of a neuroradiological cohort. Pituitary. ePub, 2015
4. Han SJ et al: Rathke's cleft cysts: review of natural history and surgical outcomes. J Neurooncol. 117(2):197-203, 2014
5. Ogawa Y et al: Spontaneous alteration from Rathke's cleft cyst to craniopharyngioma–possible involvement of transformation between these pathologies. Endocr Pathol. 25(4):422-6, 2014
6. Oh YJ et al: Clinical and radiological findings of incidental Rathke's cleft cysts in children and adolescents. Ann Pediatr Endocrinol Metab. 19(1):20-6, 2014

https://CafePezeshki.IR

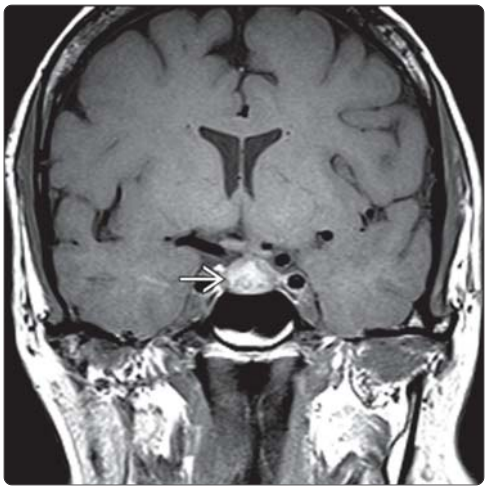

(Left) *Coronal T1 MR in a 48-year-old man with headache shows a hypertense sellar mass ⇨ with normal surrounding pituitary tissue.* **(Right)** *Coronal T2 MR in the same patient shows the mass is hypointense ⇨ and enlarges the pituitary gland. There is no compression of the optic chiasm ⇨. No enhancement of the lesion was present on post-contrast imaging (not shown). Rathke cleft cyst was confirmed at resection.*

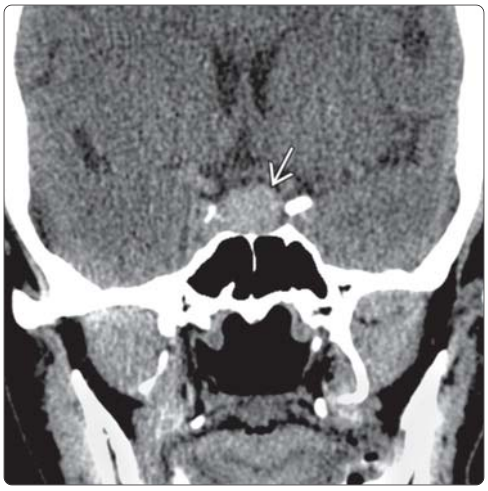

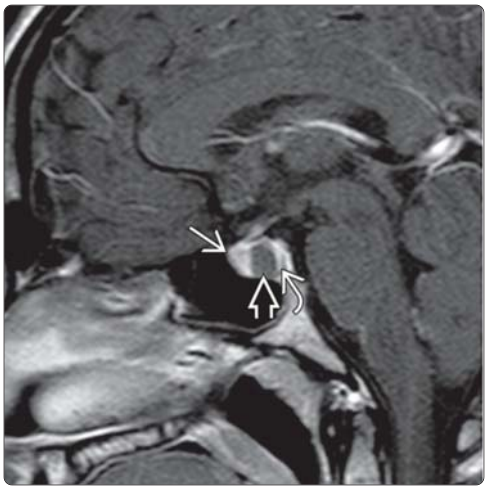

(Left) *Coronal NECT in a patient with a headache shows a hyperdense intrasellar mass with minimal suprasellar extension ⇨. Rathke cleft cysts are most commonly hypodense on CT imaging. Note the lack of calcification, which helps distinguish RCC from craniopharyngiomas, which are typically calcified (90%).* **(Right)** *Sagittal T1 C+ MR shows the typical imaging of a nonenhancing Rathke cleft cyst ⇨ between the normal adenohypophysis anteriorly ⇨ and the neurohypophysis posteriorly ⇨.*

(Left) *Sagittal T1 C+ MR shows a sellar and suprasellar Rathke cleft cyst with a classic claw sign of compressed pituitary gland ⇨ surrounding the nonenhancing mass. Rathke cleft cyst was confirmed at surgery.* **(Right)** *Coronal T2 MR in the same patient shows marked hypointensity throughout the cyst ⇨. There is mild mass effect and superior displacement of the optic chiasm ⇨ in this male patient who presented with visual changes.*

https://CafePezeshki.IR

KEY FACTS

TERMINOLOGY

- Microadenoma: ≤ 10 mm in diameter

IMAGING

- Intrasellar mass is typical location
  - Rare: Ectopic origin outside pituitary fossa
- Best technique = dynamic contrast-enhanced thin-section T1-weighted MR
  - Generally enhance more slowly than adjacent normal pituitary
  - Beware: 10-30% can be seen only on dynamic contrast-enhanced scans
  - Occasionally, the adenoma may be cystic or hemorrhagic
- Intrapituitary "filling defect" may be benign nonneoplastic cyst, as well as incidental microadenoma

TOP DIFFERENTIAL DIAGNOSES

- Rathke cleft cyst
- Craniopharyngioma
- Pituitary hyperplasia
- Other nonneoplastic cyst (e.g., pars intermedia cyst)

PATHOLOGY

- Adenomas are almost always WHO grade I
  - Pituitary carcinoma exceedingly rare (diagnosed when metastatic disease identified)
- Can occur as part of MEN type 1, Carney complex, or McCune-Albright syndrome

CLINICAL ISSUES

- Symptoms of secreting tumors vary according to type
  - Prolactinoma is most common functional adenoma
  - Asymptomatic/nonfunctioning adenoma most common
- ~ 20-25% incidental finding at autopsy
- Medical therapy (bromocriptine, cabergoline) reduces PRL secretion to normal in 80%
- Surgical (transsphenoidal) curative in 60-90%

(Left) *Coronal graphic shows a small microadenoma that slightly enlarges the right side of the pituitary gland and deviates the infundibulum toward the left.* **(Right)** *Coronal T1 C+ MR in a 41-year-old woman with amenorrhea and elevated prolactin levels shows a mass in the left pituitary gland with displacement of the infundibulum to the right. Prolactin-secreting microadenoma was found at resection. The microadenoma enhances less than the normal pituitary gland.*

(Left) *Axial T1 C+ MR in a 31-year-old woman with elevated prolactin shows a discrete mass related to a microadenoma in the anterior right pituitary gland. Prolactinomas are typically located laterally within the adenohypophysis as the prolactin secreting cells are present laterally within the normal gland.* **(Right)** *Coronal microscopic image shows a normal pituitary gland surrounding a small nonfunctioning microadenoma that was found incidentally at autopsy. (Courtesy J. Townsend, MD.)*

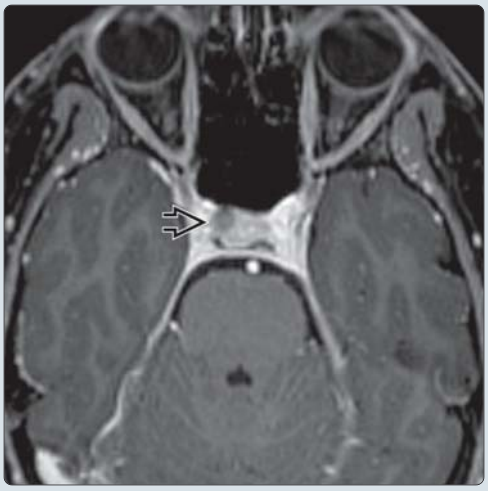

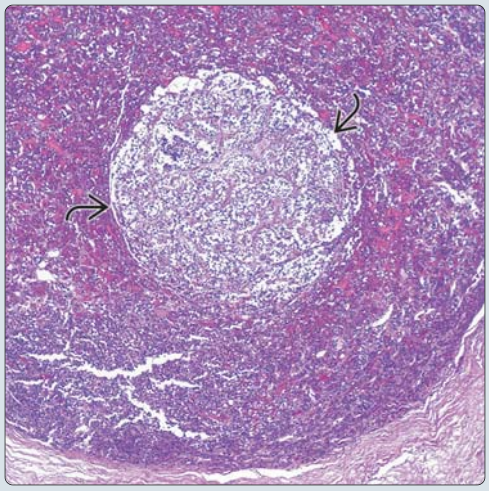

https://CafePezeshki.IR

TERMINOLOGY

Abbreviations

- Pituitary microadenoma

Synonyms

- Prolactinoma, adenoma

Definitions

- Microadenoma: ≤ 10 mm in diameter

IMAGING

General Features

- Best diagnostic clue
  - Intrapituitary lesion that enhances less rapidly than surrounding normal gland
- Location
  - Intrasellar
  - Rare: Ectopic origin outside pituitary fossa
    - Sphenoid sinus, cavernous sinus, clivus
    - Pituitary stalk, 3rd ventricle
    - Nasopharynx
- Size
  - By definition, microadenomas ≤ 10 mm in diameter
- Morphology
  - Circumscribed, well-demarcated mass surrounded by crescentic rim of compressed anterior pituitary
- Occasionally, microadenomas may be hemorrhagic or cystic

CT Findings

- NECT
  - If uncomplicated (no hemorrhage, cyst), microadenomas are isodense, invisible
- CECT
  - 2/3 are hypodense to normal pituitary on dynamic scans

MR Findings

- T1WI
  - Variable signal intensity
    - Usually isointense with normal pituitary gland
    - May be slightly hypointense to gland
    - Can be hyperintense if hemorrhage, necrosis
- T2WI
  - Typically isointense to normal pituitary gland
  - May be hypointense (blood products) or hyperintense (cystic)
- T2* GRE
  - May show "blooming" if hemorrhagic
- T1WI C+
  - 70-90% relatively hypointense compared to intensely enhancing pituitary gland, cavernous sinus
    - Generally enhance more slowly than normal pituitary
  - Beware: 10-30% can be seen only on dynamic contrast-enhanced scans

Other Modality Findings

- Cavernous/inferior petrosal sinus sampling (10% false-negative) in patients with ACTH-dependent Cushing syndrome

Imaging Recommendations

- Best imaging tool
  - Dynamic contrast-enhanced thin-section T1 MR
- Protocol advice
  - Coronal thin-section T1WI obtained during contrast infusion
    - Scans obtained at 5-10 second intervals following rapid bolus injection
    - At least 3 sections (3 mm or less, no interslice gap) through pituitary gland

DIFFERENTIAL DIAGNOSIS

Rathke Cleft Cyst

- Hypo-/hyperintense to normal gland on T1-/T2WI
- No enhancement
- Up to 75% have intracystic nodule

Craniopharyngioma

- Completely intrasellar craniopharyngioma is uncommon
- May have Ca++
- Displaces/compresses normal pituitary

Pituitary Hyperplasia

- Gland appears slightly, diffusely enlarged
- May appear slightly inhomogeneous, but usually no discrete foci of hypointensity seen on contrast-enhanced scans

Other Nonneoplastic Cyst (e.g., Pars Intermedia Cyst)

- Variable signal intensity
- Nonenhancing
- Indistinguishable from intrasellar Rathke cleft cyst

PATHOLOGY

General Features

- Etiology
  - 1 possible model of pituitary tumorigenesis
    - Hypophysiotrophic hormone excess, suppressive hormone insufficiency, or growth factor excess leads to hyperplasia
    - Increased proliferation predisposes to genomic instability; adenoma forms
  - 5 endocrine cell types in anterior pituitary (each secretes specific hormone, may develop into microadenoma or macroadenoma)
    - Lactotrophs: Prolactin (PRL)
      - 30% of adenomas
      - Prolactin secreting cells are located laterally
    - Somatotrophs: Growth hormone (GH)
      - 20% of adenomas
      - GH secreting cells are located laterally
    - Corticotrophs: Adrenocorticotrophic hormone (ACTH)
      - 10% of adenomas
      - ACTH secreting cells are located centrally
    - Thyrotrophs: Thyroid-stimulating hormone (TSH)
      - 1-2% of adenomas
      - TSH secreting cells are located centrally
    - Gonadotrophs: Gonadotropins, luteinizing hormone (LH), follicle-stimulating hormone (FSH)
      - FSH/LH (10%); located diffusely through gland
      - PRL/GH (5%)
  - Null cell (nonfunctional): 20-30% of adenomas

https://CafePezeshki.IR

- Genetics
  - No consistent allelic losses or point mutations identified
    - 2 normal copies of POU transcription factor Pit-1 (*POU1F1*) gene necessary for normal anterior pituitary lobe function
  - Can occur as part of MEN type 1, Carney complex, McCune-Albright syndrome
    - MEN1-associated adenomas often plurihormonal, larger, more invasive
    - Pituitary tumors occur in up to 40% of MEN1 patients
  - Familial isolated pituitary adenoma syndrome
    - Recently described
    - Family members develop only pituitary tumors
    - Prolactinomas in 40% of patients, somatotropinomas in 30%, nonsecreting in 13%
- Associated abnormalities
  - Growth hormone secreting adenoma
    - Acromegaly in adults
    - Gigantism in adolescents

Staging, Grading, & Classification

- Adenomas are almost always WHO grade I
- Pituitary carcinoma exceedingly rare
- Modified Kovacs and Horvath classification (cell type with tinctorial characteristics and hormones produced)
  - Growth hormone cell adenoma
  - Prolactin cell adenoma
  - Mixed GH, prolactin cell adenoma
  - Acidophil cell adenoma
  - Mammosomatotroph cell adenoma
  - Corticotroph cell adenoma
  - Thyrotroph cell adenoma
  - Gonadotroph cell adenoma
  - Nonfunctioning adenoma
  - Plurihormonal adenoma

Gross Pathologic & Surgical Features

- Small reddish-pink nodule

Microscopic Features

- Monotonous sheets of uniform cells
- Cell type varies, has variable trichrome staining, specific immunohistochemical stains

CLINICAL ISSUES

Presentation

- Most common signs/symptoms
  - Asymptomatic/nonfunctioning most common
  - Symptoms of secreting tumors vary according to type
    - Hyperprolactinemia: Amenorrhea, galactorrhea, infertility
    - Symptoms can also occur with non-prolactin-secreting tumors
      - Elevated prolactin related to mass effect on pituitary stalk ("stalk effect")
      - Macroprolactinemia may be idiopathic
- Clinical profile
  - Young female with primary or secondary amenorrhea and infertility, galactorrhea
- Noninvasive laboratory tests: Dexamethasone suppression, metyrapone stimulation, peripheral ovarian corticotropin-releasing hormone (CRH) stimulation

Demographics

- Age
  - Prolactinoma: 20-35 years
  - GH-secreting adenoma: 30-50 years
- Gender
  - Prolactinomas typically in females but can occur in males with delayed puberty, primary hypogonadism
  - Prolactinomas in men usually larger, more often cystic/hemorrhagic
- Epidemiology
  - 10-15% of all intracranial tumors (increasing due to improved imaging techniques)
    - ~ 20-25% incidental finding at autopsy
    - 1% of microadenomas are multiple
  - Prolactin-secreting = 30-40% of symptomatic adenomas
  - Pathologically, microadenoma > > macroadenoma
    - Most found incidentally (autopsy or imaging)
    - Pituitary "incidentaloma" seen in 6-27% of MR scans (common even in children)
    - 10-20% prevalence in general population (most are nonfunctioning)

Natural History & Prognosis

- Benign, slow growing
- Majority found incidentally

Treatment

- "Incidentaloma": Conservative (clinical, imaging follow-up unless change in size, ophthalmological/endocrinological evaluation)
- Functioning microadenomas
  - Medical (bromocriptine, other dopamine agonists, such as cabergoline) reduces PRL secretion to normal in 80%
  - Surgical (transsphenoidal) curative in 60-90%
- Radiation therapy for incompletely resected or recurrent tumors
  - Also helpful for patients not able to undergo surgery

DIAGNOSTIC CHECKLIST

Consider

- Intrapituitary filling defect may be benign nonneoplastic cyst, as well as incidental microadenoma

Image Interpretation Pearls

- Microadenomas **do** enhance but more slowly than normal pituitary, so dynamic studies are very helpful

SELECTED REFERENCES

1. Esteves C et al: Pituitary incidentalomas: analysis of a neuroradiological cohort. Pituitary. ePub, 2015
2. Karppinen A et al: Transition from microscopic to endoscopic transsphenoidal surgery for nonfunctional pituitary adenomas. World Neurosurg. ePub, 2015
3. Kinoshita M et al: Pituitary-targeted dynamic contrast-enhanced multisection CT for detecting MR imaging-occult functional pituitary microadenoma. AJNR Am J Neuroradiol. ePub, 2015

https://CafePezeshki.IR

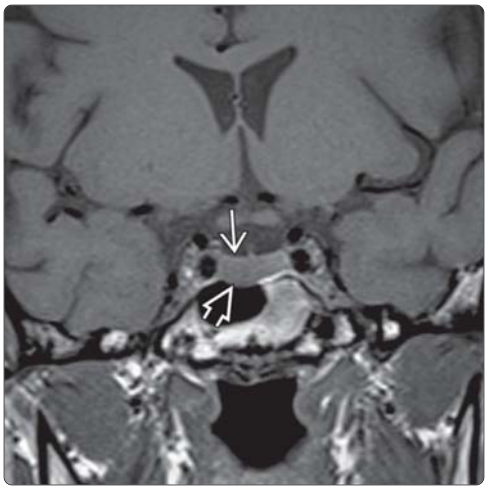

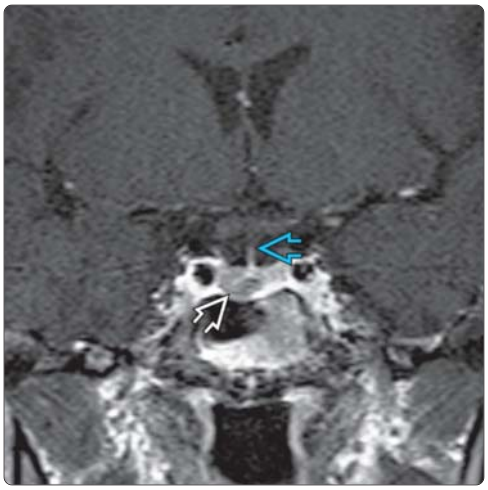

(Left) *Coronal T1 MR in a 32-year-old woman with elevated prolactin and galactorrhea shows subtle enlargement of the right pituitary gland* ⇨ *with mild thinning of the sella turcica floor* ⇨. **(Right)** *T1 C+ MR in the same patient shows a focal mass in the right anterior gland* ⇨ *that enhances less than the normal left gland. The infundibulum is in its normal midline location* ⇨. *The patient underwent trans-sphenoidal surgical resection after the tumor grew on medical therapy. Prolactin secreting adenoma found at resection.*

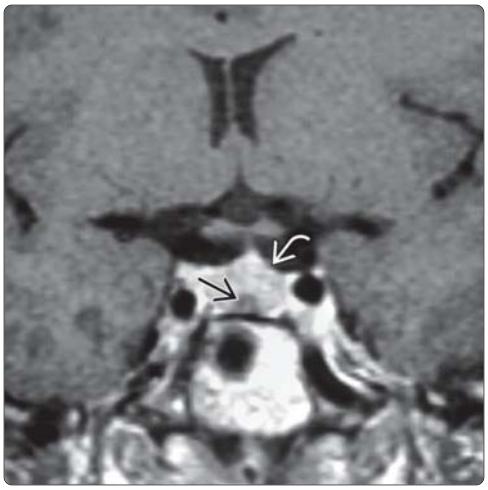

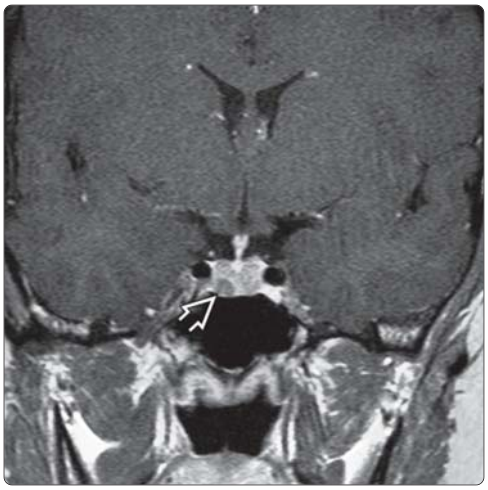

(Left) *Coronal T1WI C+ MR shows a focus of less enhancement* ⇨ *within a mildly enlarged pituitary gland* ⇨. *The patient was asymptomatic, and this was an incidental finding. Pituitary "incidentalomas" are common and may represent nonfunctioning adenomas or nonneoplastic cysts.* **(Right)** *Coronal T1 C+ MR in a 36-year-old patient with Cushing syndrome shows a mass* ⇨ *in the right gland related to her ACTH-secreting pituitary adenoma. ACTH secreting tumors are often centrally located within the gland.*

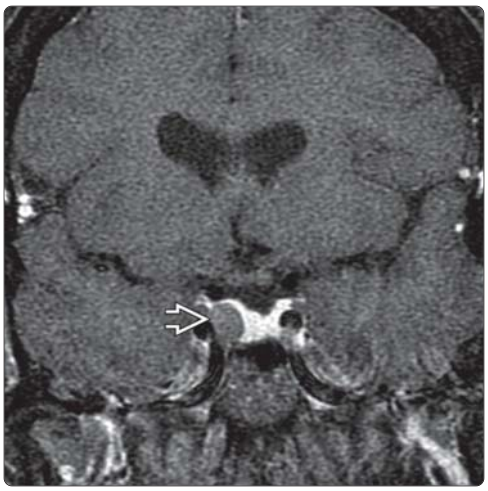

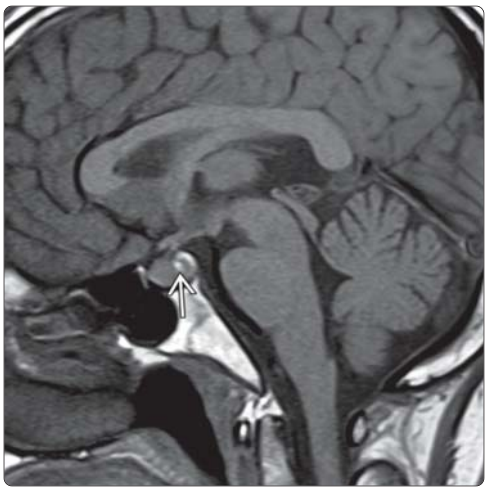

(Left) *Coronal T1 C+ MR in a patient with acromegaly shows a microadenoma* ⇨ *as a less enhancing mass in the right adenohypophysis. Growth-hormone secreting adenoma found at resection.* **(Right)** *Sagittal T1 MR in a young adult male shows a T1-hyperintense lesion* ⇨, *separate from the bright neurohypophysis, likely related to a hemorrhagic nonfunctional microadenoma in this patient with mild elevation of prolactin. A Rathke cleft cyst could have a similar appearance.*

https://CafePezeshki.IR

KEY FACTS

TERMINOLOGY

- Benign neoplasm of the adenohypophysis

IMAGING

- Upward extension of macroadenoma = most common suprasellar mass in adults
- Best imaging technique
  - MR with sagittal/coronal thin-section imaging through sella + T1 C+ with FS
- Sellar mass without separate identifiable pituitary gland = macroadenoma
- Mass **is** the pituitary gland
- Usually isointense with gray matter
- Enhance strongly, often heterogeneously
- Cavernous sinus invasion difficult to determine

TOP DIFFERENTIAL DIAGNOSES

- Pituitary hyperplasia
- Saccular aneurysm
- Meningioma (diaphragma sellae)
- Metastasis
- Lymphocytic hypophysitis
- Craniopharyngioma

PATHOLOGY

- WHO grade I
- MIB-1 > 1% suggests early recurrence, rapid regrowth
- Invasive adenoma > > pituitary carcinoma (rare)

CLINICAL ISSUES

- Beware: Adenoma-like mass in adolescent/prepubescent males may represent hyperplasia secondary to end-organ failure
- Prolactin-secreting adenoma is most common functional adenoma

DIAGNOSTIC CHECKLIST

- No matter how aggressive/invasive it looks, pituitary tumors are almost never malignant

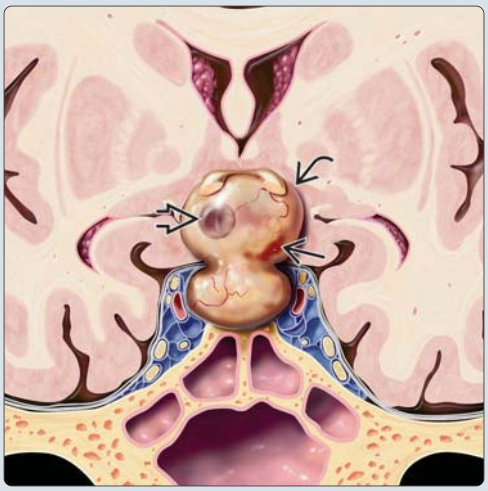

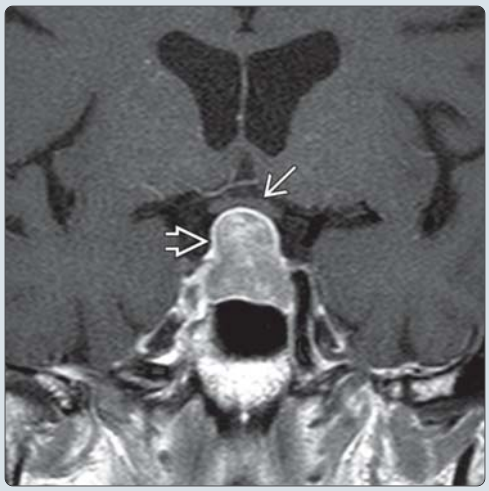

(Left) *Coronal graphic shows a snowman-shaped or "figure 8" sellar/suprasellar mass. Small foci of hemorrhage and cystic change are present within the lesion. The pituitary gland cannot be identified separate from the mass; indeed, the gland is the mass.* **(Right)** *T1 C+ MR in a 68-year-old male patient with elevated prolactin shows a classic "figure 8" or "snowman" appearance of the pituitary macroadenoma. There is mild displacement of the optic chiasm. The pituitary gland cannot be separated from the mass.*

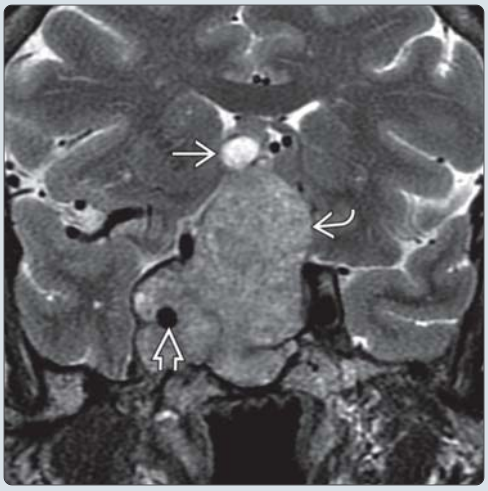

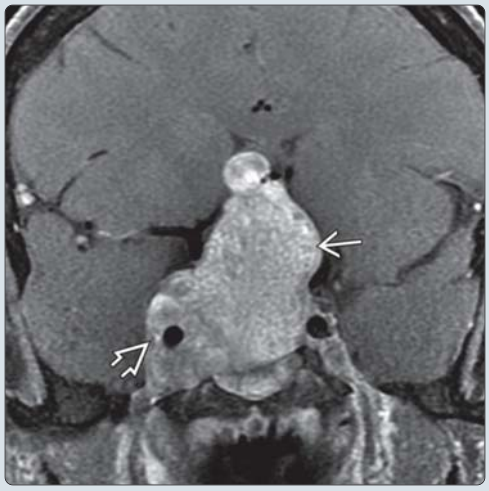

(Left) *Coronal T2 MR in a 64-year-old woman with visual changes shows a large adenoma with cystic change filling the sella and suprasellar region. Note the patent cavernous carotid artery.* **(Right)** *Coronal T1 C+ MR image in the same patient shows heterogeneous enhancement of the macroadenoma. There is tumor lateral to the cavernous carotid artery representing cavernous sinus invasion. Nonfunctional adenoma found at resection. The cavernous sinus disease was treated with radiation therapy.*

https://CafePezeshki.IR

TERMINOLOGY

Synonyms

- Macroadenoma, pituitary adenoma, prolactinoma

Definitions

- Benign neoplasm of adenohypophysis

IMAGING

General Features

- Best diagnostic clue
  - Sellar mass without separate identifiable pituitary gland; mass is gland
- Location
  - Most common: Intra- or combined intra-/suprasellar
    - Upward extension of macroadenoma = most common suprasellar mass in adults
  - Uncommon: Giant adenoma
    - May invade skull base, extend into anterior/middle/posterior fossae
    - Can mimic metastasis or other malignant neoplasm
  - Rare: "Ectopic" pituitary adenoma
    - Sphenoid sinus most common
    - Cavernous sinus, clivus, 3rd ventricle, infundibulum
- Size
  - > 10 mm
  - "Giant": > 4 cm in diameter (< 0.5%)
- Morphology
  - Most common: "Figure 8" or "snowman"
    - Indentation: Dural constriction caused by diaphragma sellae
  - Less common: Multilobulated margins

CT Findings

- NECT
  - Variable attenuation
    - Usually isodense with gray matter (typical)
    - Cysts, necrosis common (15-20%)
    - Hemorrhage (10%), Ca++ (1-2%)
- CECT
  - Moderate, heterogeneous enhancement
- Bone CT
  - Large adenomas expand sella, may erode floor
  - Aggressive adenomas extend inferiorly, invade sphenoid, may destroy upper clivus

MR Findings

- T1WI
  - Usually isointense with gray matter
    - Subacute hemorrhage (T1 shortening)
    - Fluid-fluid levels may occur, especially with pituitary apoplexy (acute hemorrhage or infarct of adenoma)
  - Posterior pituitary "bright spot" displaced into supradiaphragmatic level in 80% of cases
    - Posterior pituitary "bright spot" absent in 20% of large adenomas
  - Cavernous sinus invasion difficult to determine (medial wall is thin, weak)
    - If tumor exists between cavernous carotid artery and lateral dura = invasion
- T2WI
  - Most common: Isointense with gray matter
  - Less common
    - Cysts (hyperintense), hemorrhage (signal varies with age)
    - Densely granulated, growth-hormone-producing adenomas often hypointense
  - Uncommon: High signal along optic tracts
    - Seen with 15-20% of adenomas that touch/compress optic pathway
- T2* GRE
  - Susceptibility artifact (blooming) if hemorrhage present
- T1WI C+
  - Most enhance strongly but heterogeneously
    - Some macroadenomas (thyrotropin-secreting adenomas, necrotic adenomas) are hypoenhancing
    - Subtle/mild dural thickening ("tail") may be seen
- MRA
  - Internal carotid arteries (ICAs) often displaced and encased (20%) but rarely occluded

Angiographic Findings

- Suprasellar extension splays supraclinoid ICAs, anterior choroidal arteries laterally
- Pituitary normally "blushes"
  - With macroadenoma, meningohypophyseal trunk may enlarge, causing prominent vascular staining

Other Modality Findings

- Cavernous/inferior petrosal sinus sampling may be helpful in evaluating ACTH-dependent Cushing syndrome

Imaging Recommendations

- Best imaging tool
  - MR with sagittal/coronal thin-section imaging through sella
    - Pre- and post-contrast imaging with T1WI C+ FS

DIFFERENTIAL DIAGNOSIS

Pituitary Hyperplasia

- 25-50% of females 18-35 years have upwardly convex pituitary
  - Usually ≤ 10 mm unless pregnant, lactating
  - Homogeneous enhancement
  - Pituitary function normal
- Can occur with end-organ failure (e.g., ovarian, thyroid)
- If prepubescent female or young male has adenoma-looking pituitary, do endocrine work-up

Saccular Aneurysm

- Usually eccentric, not directly suprasellar
- Pituitary gland visible, identified separate from mass
- Flow void common on MR; MRA/CTA shows vessel of origin
- Ca++ more common (rare in adenoma)

Meningioma (Diaphragma Sellae)

- Pituitary gland visible, can be identified **separate** from mass
  - Diaphragma sellae identifiable as thin, dark line between mass (above) and pituitary gland (below)
- Dural thickening more extensive than with adenoma

https://CafePezeshki.IR

Metastasis

- Diffuse skull base invasion by adenoma may mimic more ominous disease
- May see systemic metastases to stalk or pituitary gland

Lymphocytic Hypophysitis

- Can mimic adenoma clinically on imaging studies
- Most common in peripartum female

Craniopharyngioma

- Ca++, cysts; children > adults
- Rim/nodular > solid enhancement

PATHOLOGY

General Features

- Etiology
  - Genetic, epigenetic factors, hormonal stimulation, growth factors and their receptors implicated in pituitary tumorigenesis
- Genetics
  - Allelic loss of chromosome 11q in *MEN1* region
  - *MEN1* gene (probably tumor suppressor) involved in adenoma formation
- Associated abnormalities
  - Acromegaly, gigantism (growth-hormone-secreting macroadenomas)
  - MEN type 1 (parathyroid, pancreatic tumors with multicentric pituitary adenomas in 50%)
  - May also be associated with McCune-Albright syndrome, Carney complex, familial isolated pituitary adenoma or isolated familial somatotropinoma syndrome

Staging, Grading, & Classification

- WHO grade I
- MIB-1 > 1% suggests early recurrence, rapid regrowth

Gross Pathologic & Surgical Features

- Reddish-brown, lobulated mass
- "Capsule" of macroadenoma is normal compressed pituitary gland
- Usual growth pattern: Bulges upward into suprasellar cistern
- Gross cavernous sinus invasion at autopsy in 5-10%, microscopic in 45%
- Invasive benign adenoma > > pituitary carcinoma (exceedingly rare)

CLINICAL ISSUES

Presentation

- Most common signs/symptoms
  - Endocrine abnormalities
    - 75% endocrinologically active (symptoms vary)
  - Visual field defect
    - 20-25% visual defect/cranial nerve palsy
    - Bitemporal hemianopsia
  - Rare: Nelson syndrome
    - Macroadenoma with elevated ACTH, MSH develops after bilateral adrenalectomy
- Clinical profile
  - Middle-aged female with bitemporal hemianopsia
  - Less common: Male with impotence, decreased libido, visual disturbance
  - Rare: Pituitary apoplexy (can be acute, life threatening)

Demographics

- Age
  - Peak: 20-40 years
  - Uncommon: Presentation in childhood/adolescence
    - Pituitary adenomas account for < 6% of intracranial tumors in adolescents, even rarer in children
    - ~ 60% are macroadenomas, 40% are microadenomas
    - Adenoma-like mass in adolescent/prepubescent males may represent hyperplasia secondary to end-organ failure
- Gender
  - Varies with secretory type; prolactin-secreting tumors much more common in females
- Epidemiology
  - 10-15% of intracranial neoplasms
  - Prolactin-secreting: Most common (prevalence ~ 500 cases per million)

Natural History & Prognosis

- Benign; usually slow but highly variable growth rate
  - Malignant transformation exceedingly rare
- "Giant" adenoma
  - Prolactin often > 1,000 ng/mL
- Metastasizing pituitary adenoma (pituitary carcinoma)
  - Occurs but very rare (both CSF, extra-CNS)
  - Carcinoma diagnosed only if metastases present
- Some adenomas (e.g., clinically silent corticotroph adenomas) behave in more aggressive manner with high recurrence rate
  - Apoptosis-related proteins (Bcl-2, BAX, p53) related to local control, recurrence

Treatment

- Resection is primary therapy (15% recurrence at 8 years, 35% at 20 years)
- Other: Medical, stereotaxic radiosurgery, conventional XRT

DIAGNOSTIC CHECKLIST

Consider

- Could sellar mass be nonneoplastic (e.g., hyperplasia, hypophysitis, etc.)
- Check prolactin levels in male with giant invasive skull base mass; it may be giant adenoma

Image Interpretation Pearls

- No matter how aggressive/invasive it looks, pituitary tumors are almost never malignant

SELECTED REFERENCES

1. Dallapiazza RF et al: Outcomes of endoscopic transsphenoidal pituitary surgery. Endocrinol Metab Clin North Am. 44(1):105-115, 2015
2. Lenzi J et al: Evaluation of trans-sphenoidal surgery in pituitary GH-secreting micro- and macroadenomas: a comparison between microsurgical and endoscopic approach. J Neurosurg Sci. 59(1):11-8, 2015
3. Tong T et al: Comparison of contrast-enhanced SPACE and CISS in evaluating cavernous sinus Invasion by pituitary macroadenomas on 3-T magnetic resonance. J Comput Assist Tomogr. 39(2):222-7, 2015

https://CafePezeshki.IR

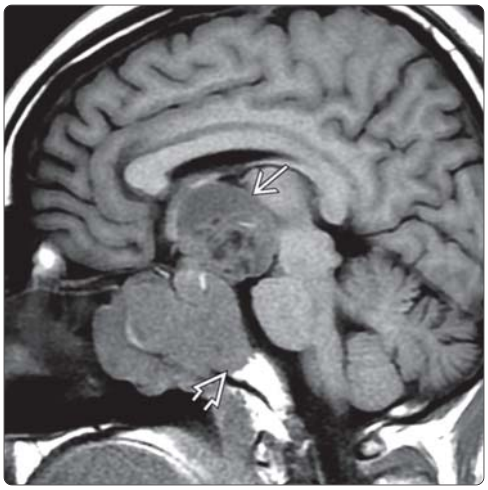

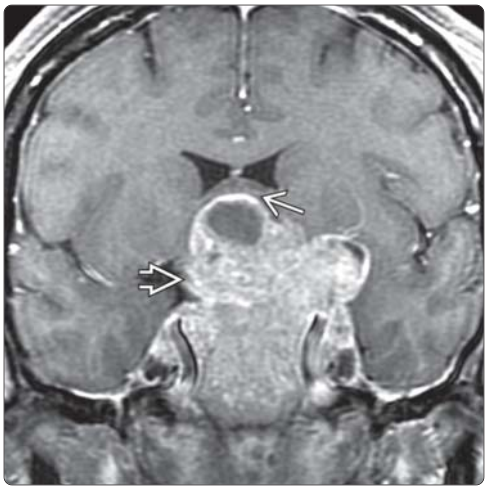

(Left) *Sagittal T1 MR in a 28-year-old woman with visual changes & elevated prolactin shows an invasive pituitary macroadenoma ➡ that has eroded the clivus ➡, extending into sphenoid sinus and nasopharynx. Imaging differential considerations on pre-contrast imaging include skull base lesions, such as chordoma, metastases, or myeloma.* **(Right)** *Coronal T1 C+ MR in the same patient shows strong, heterogeneous enhancement of the macroadenoma ➡. There is compression of the optic chiasm ➡.*

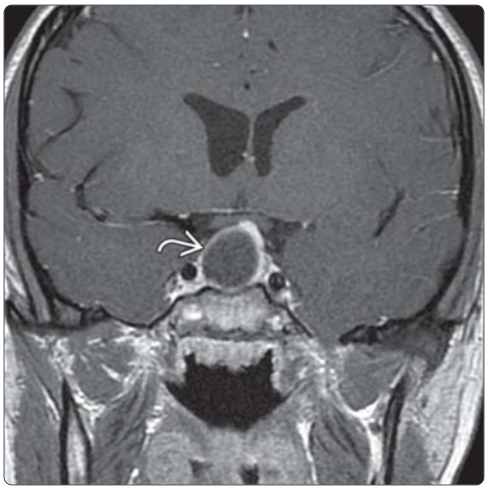

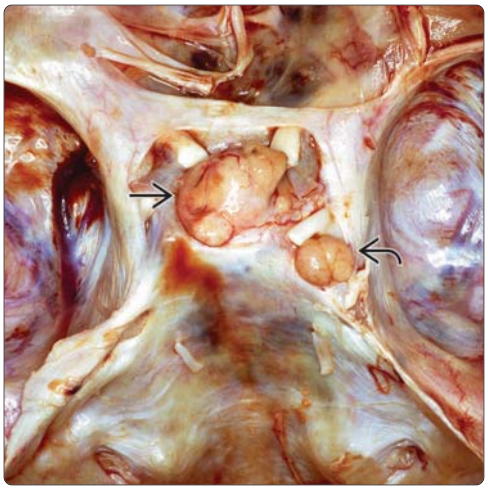

(Left) *Coronal T1 C+ MR in a 19-year-old woman with amenorrhea and markedly elevated prolactin shows a cystic macroadenoma ➡ with left lateral displacement of the infundibulum and remaining normal gland. Imaging mimics a Rathke cleft cyst.* **(Right)** *Gross pathology shows a pituitary macroadenoma that extends upward through the diaphragma sellae into the suprasellar cistern ➡ and laterally into the cavernous sinus ➡, which is partially unroofed. (Courtesy R. Hewlett, MD.)*

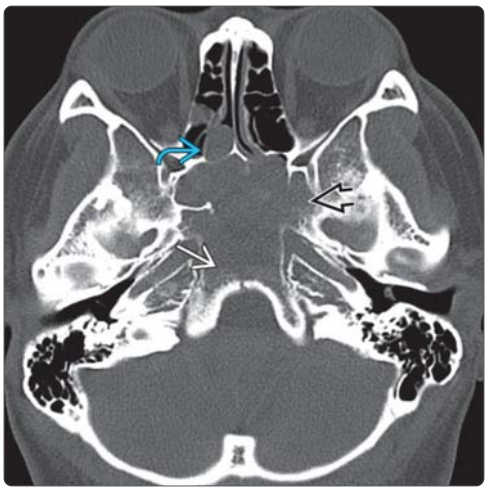

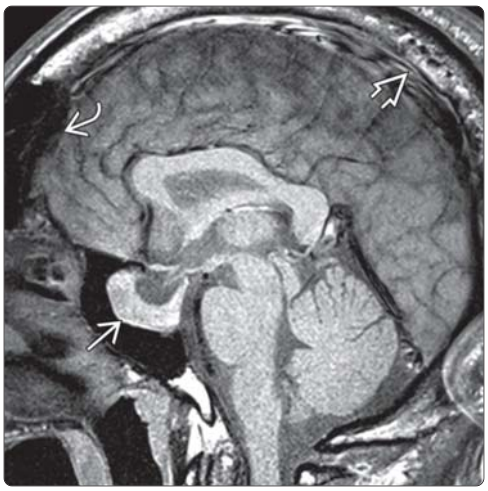

(Left) *Axial CT shows erosion of the anterior clivus ➡ from a large, invasive macroadenoma that extends anteriorly to fill the sphenoid sinus ➡ and posterior ethmoids ➡.* **(Right)** *Sagittal T1 MR in a 30-year-old man with longstanding acromegaly shows a pituitary macroadenoma enlarging the sella turcica and invading the sphenoid sinus ➡. Note the thick skull ➡ and enlarged frontal sinuses ➡ seen in acromegaly. Growth-hormone secreting adenoma was found at resection.*

https://CafePezeshki.IR

KEY FACTS

TERMINOLOGY

- Acute clinical syndrome with headache, visual defects/ophthalmoplegia, altered mental status, variable endocrine deficiencies
- Caused by either hemorrhage or infarction of pituitary gland
- Preexisting pituitary macroadenoma common

IMAGING

- CT
  - Sellar/suprasellar mass with patchy or confluent hyperdensity
  - Peripheral enhancement, ± hemorrhage
  - May be associated with subarachnoid hemorrhage
- MR
  - Enlarged, hypointense (hemorrhagic), or hyperintense (nonhemorrhagic) pituitary on T2WI
  - "Blooming" if blood products present
  - Restricted diffusion within adenoma may be early sign of apoplexy
- Associated findings
  - Adjacent dural thickening, enhancement in 50%
  - Thickening of sphenoid sinus mucosa in 80%

TOP DIFFERENTIAL DIAGNOSES

- Pituitary macroadenoma (nonhemorrhagic)
- Craniopharyngioma
- Rathke cleft cyst
- Lymphocytic hypophysitis
- Giant thrombosed intrasellar aneurysm
- Pituitary abscess
- Primary intrapituitary hemorrhage

DIAGNOSTIC CHECKLIST

- Rim enhancement or fluid level in snowman-shaped sellar/suprasellar mass may represent PA

(Left) *Coronal graphic shows a macroadenoma with acute hemorrhage ⇨ causing pituitary apoplexy. Superior displacement of the optic chiasm is common.* **(Right)** *Coronal T1 MR shows a hemorrhagic sellar and suprasellar macroadenoma in a 58-year-old woman with acute onset of headache and ophthalmoplegia. Note the T1 shortening ➡ in the superior aspect of the macroadenoma related to subacute blood products.*

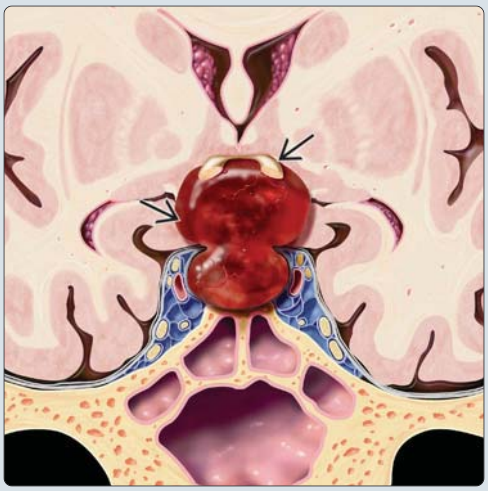

(Left) *Coronal T2 MR in the same patient shows heterogeneous signal throughout the sellar and suprasellar mass, typical of pituitary apoplexy.* **(Right)** *Sagittal T1 C+ FS MR in the same patient shows heterogeneous enhancement of the mass with a blood-fluid level ➡ and regions of nonenhancement ⇨ related to necrotic adenoma. A necrotic, hemorrhagic, nonfunctional adenoma was found at surgery. A preexisting macroadenoma is present in the vast majority of patients with pituitary apoplexy.*

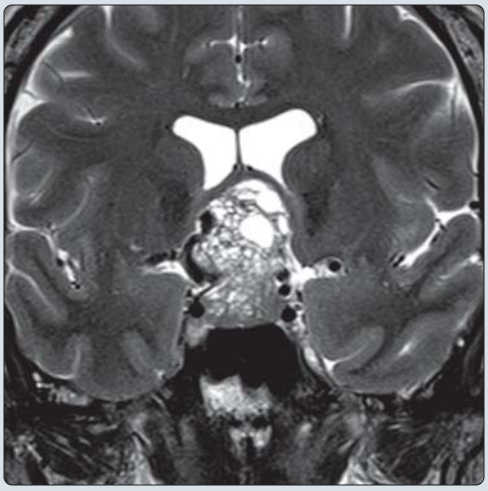

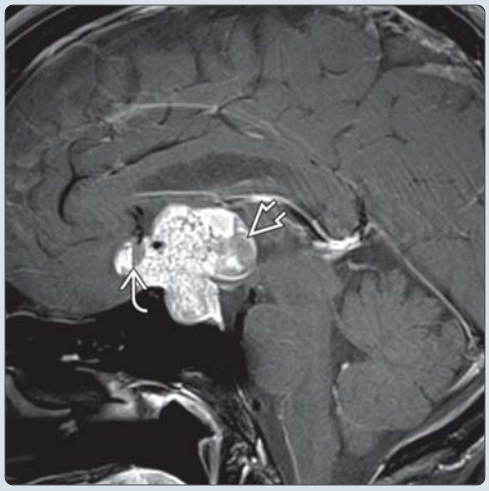

https://CafePezeshki.IR

TERMINOLOGY

Abbreviations

- Pituitary apoplexy (PA)

Synonyms

- Pituitary necrosis; hemorrhage into pituitary mass

Definitions

- Acute clinical syndrome with headache, visual defects/ophthalmoplegia, altered mental status, variable endocrine deficiencies
  - Caused by either hemorrhage or infarction of pituitary gland
  - Preexisting pituitary macroadenoma common

IMAGING

General Features

- Best diagnostic clue
  - Pituitary mass with peripheral or heterogeneous enhancement, ± hemorrhage
- Location
  - Intrasellar or combined sellar and suprasellar
- Size
  - Variable but typically > 1 cm
- Morphology
  - "Snowman" or "figure of eight" sellar and suprasellar mass

CT Findings

- NECT
  - Acute
    - Sellar/suprasellar mass with patchy or confluent hyperdensity (20-25%)
    - May rarely be associated with subarachnoid hemorrhage
  - May be normal acutely
  - Chronic: Empty sella
- CECT
  - Minimal or no enhancement
    - Rim enhancement suggestive (but not diagnostic) of pituitary apoplexy
- CTA
  - Avascular or hypovascular mass effect on adjacent vessels
  - Done to exclude aneurysm

MR Findings

- T1WI
  - Early acute: Enlarged gland, iso-/hypointense with brain
  - Late acute/subacute: Hyperintense
  - Chronic: Hypointense
    - Empty sella (filled with CSF)
    - Small isointense pituitary remnant
- T2WI
  - Acute
    - Enlarged, heterogeneous pituitary mass
    - May see fluid level
    - Acute compression of hypothalamus, optic chiasm may cause hyperintensity along optic tracts
  - Subacute: Hyperintense
  - Chronic: Hyperintense (empty sella filled with CSF)
- FLAIR
  - Acute: Hyperintense, heterogeneous mass
  - Chronic: Hypointense (CSF in empty sella suppresses)
- T2* GRE
  - "Blooming" if blood products present
- DWI
  - Restricted diffusion within adenoma may be early sign of apoplexy
  - ADC map: Markedly decreased signal intensity
- T1WI C+
  - Rim enhancement common
  - May have heterogeneously enhancing mass with areas of nonenhancement
  - Adjacent dural thickening and enhancement in 50% of cases
  - Thickening of sphenoid sinus mucosa in 80% of cases

Imaging Recommendations

- Best imaging tool
  - MR of central skull base
- Protocol advice
  - MR ± dynamic contrast-enhanced sequences; add GRE sequence
  - Consider adding GRE/SWI, DWI sequences

DIFFERENTIAL DIAGNOSIS

Pituitary Macroadenoma (Nonhemorrhagic)

- Clinical course usually subacute/chronic
- Predominately suprasellar, rather than intrasellar
- Cysts, small hemorrhagic foci may occur without necrosis

Craniopharyngioma

- Ca++, multiple cysts with variable contents, and mixed signal intensity common
- Can usually identify normal/compressed pituitary distinct from mass

Rathke Cleft Cyst

- Proteinaceous fluid may be hyperintense, mimic hemorrhage
- Cyst usually identifiable as separate from pituitary gland
- No enhancement
- Clinical symptoms subacute/chronic

Giant Thrombosed Sellar Aneurysm

- Acute thrombosis can present with panhypopituitarism, subarachnoid hemorrhage
- Patent aneurysm shows typical "flow void" on MR
- Partially/completely thrombosed aneurysm may show mixed-age laminated clot
- CTA helpful to determine vascular etiology
- Rare

Lymphocytic Hypophysitis

- Typically only modest gland enlargement
- Acute inflammation of gland
- Typically occurs in pregnancy or post-partum females

Pituitary Abscess

- Rare
- Clinical signs of infection may be absent

https://CafePezeshki.IR

- May be difficult to distinguish from bland (ischemic) infarction on imaging studies
- T1 shortening along rim > center of mass
- Both apoplexy, abscess may restrict on DWI

Primary Intrapituitary Hemorrhage

- Hemorrhage into nonadenomatous tissue is rare
- Has been reported with infection (hantavirus), other neoplasms (germinoma)

PATHOLOGY

General Features

- Etiology
  - Hemorrhagic or ischemic pituitary infarction
  - Preexisting macroadenoma common, but PA can occur with normal pituitary gland or microadenoma
- Genetics
  - Rare, MEN1 syndrome
- Associated abnormalities
  - Preexisting macroadenoma in 65-90% of PA cases
  - Multiple acute endocrine insufficiencies (pituitary, adrenal)
  - Both hemorrhagic and ischemic pituitary apoplexy typically occur in preexisting macroadenoma

Gross Pathologic & Surgical Features

- Hemorrhagic sellar/suprasellar mass
- Nonhemorrhagic (bland) pituitary infarction = swollen, edematous pituitary gland

Microscopic Features

- Pituicytes uniform but shrunken with dark pyknotic nuclei
- Most common adenoma affected by PA = nonfunctioning (null-cell type)

CLINICAL ISSUES

Presentation

- Most common signs/symptoms
  - Headache in nearly 100%
    - Nausea (~ 80%)
    - Panhypopituitarism (~ 80%)
    - Visual impairment, ophthalmoplegia common (~ 70%)
    - Occasionally can present with sudden-onset ptosis, diplopia
  - Other signs/symptoms
    - Life-threatening pituitary insufficiency, acute adrenal crisis
    - Hypovolemia, shock, disseminated intravascular coagulation
    - Rarely complicated by subarachnoid hemorrhage or acute intracranial ischemia (from carotid compression or vasospasm)
  - Rare: Sheehan syndrome
    - Common: Loss of anterior pituitary hormone function long after index pregnancy (up to 15-20 years later)
    - Less common: Acute (peripartum) presentation
  - Rarely associated with HELLP syndrome
    - PA with panhypopituitarism and diabetes insipidus may develop in patient with hemolysis, elevated liver enzymes, and low platelet count syndrome (HELLP)
- Clinical profile
  - Male with pituitary adenoma and acute headache, nausea, and ophthalmoplegia
  - Post-/peripartum female with hypovolemia, shock

Demographics

- Age
  - Mean: 57 years (50-60 years old, typically)
  - Rare < 15 years
- Gender
  - M:F = 2:1
- Epidemiology
  - PA occurs in approximately 1% of macroadenomas
  - Other reported clinical risk factors
    - Anticoagulation
    - Endocrinologic testing (dynamic pituitary function tests)
    - Radiation, bromocriptine or cabergoline (dopamine agonist) therapy for existing macroadenoma
    - Trauma, surgery (especially cardiac)
    - Peri- or postpartum state
    - Elevated estrogen levels (pregnancy, exogenous hormones)
    - Diabetes

Natural History & Prognosis

- Varies from clinically benign event to catastrophic presentation with permanent neurologic deficits or death
- Long-term pituitary insufficiency common in survivors

Treatment

- Early diagnosis, treatment of acute PA necessary to prevent morbidity/mortality
  - Best results with surgical decompression
  - Steroids, fluid/electrolyte replacement

DIAGNOSTIC CHECKLIST

Consider

- Could a high-density/hyperintense intrasellar mass represent something other than PA?
  - Giant intrasellar aneurysm
  - Craniopharyngioma or Rathke cleft cyst with high protein content

Image Interpretation Pearls

- Look for pituitary gland separate/distinct from mass (PA unlikely)
- Rim enhancement in snowman-shaped sellar/suprasellar mass may represent PA

SELECTED REFERENCES

1. Briet C et al: Pituitary apoplexy. Endocrinol Metab Clin North Am. 44(1):199-209, 2015
2. Jahangiri A et al: Incidence of headache as a presenting complaint in over 1000 patients with sellar lesions and factors predicting postoperative improvement. Clin Neurol Neurosurg. 132:16-20, 2015
3. Banerjee C et al: Bilateral cerebral infarction in the setting of pituitary apoplexy: a case presentation and literature review. Pituitary. ePub, 2014
4. Boellis A et al: Pituitary apoplexy: an update on clinical and imaging features. Insights Imaging. 5(6):753-62, 2014
5. Rebeiz T et al: Unusual case of bilateral caudate infarcts following pituitary apoplexy. JAMA Neurol. 71(2):226-7, 2014

https://CafePezeshki.IR

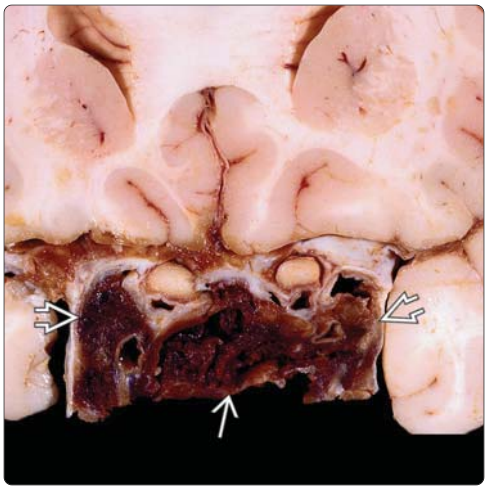

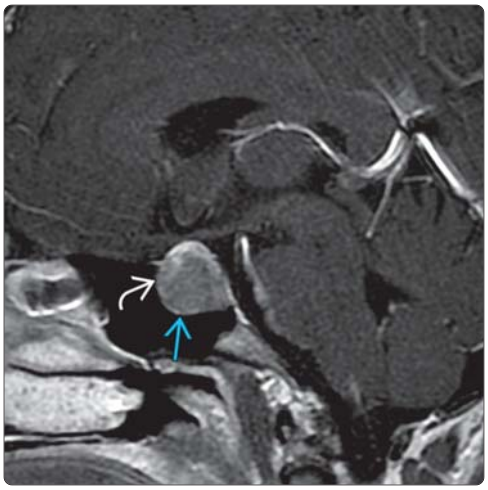

(Left) *Coronal gross pathology section through the sella turcica in a patient who died from complications of pituitary apoplexy shows hemorrhagic necrosis in the pituitary adenoma* ⇨ *that extended into both cavernous sinuses* ⇨. *(Courtesy R. Hewlett, MD.)* **(Right)** *Sagittal T1 C+ FS shows a peripherally enhancing, enlarged sellar and suprasellar mass* ⇨ *related to pituitary apoplexy in this 48-year-old man with acute headache, hypopituitarism, and visual changes. Note the enlarged sella turcica* ⇨.

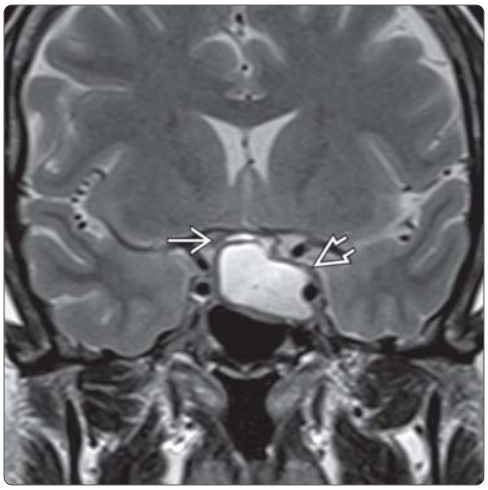

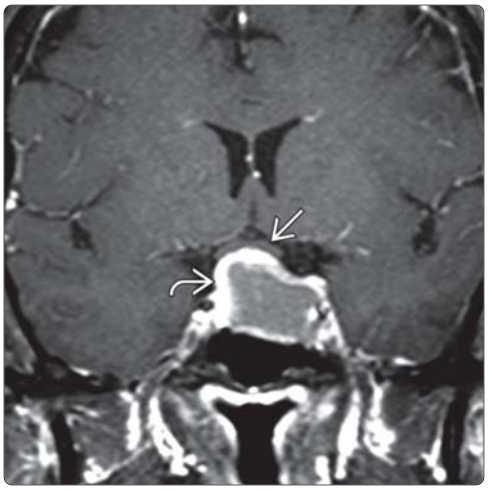

(Left) *Coronal T2 MR in a 60-year-old man with pituitary apoplexy shows a hyperintense sellar and suprasellar mass with a rim of hypointensity* ⇨. *Note the superior displacement of the optic chiasm* ⇨ *in this patient with headache, acute visual changes and nausea.* **(Right)** *Coronal T1 C+ FS in the same patient shows a centrally necrotic, peripherally enhancing* ⇨ *sellar and suprasellar mass related to pituitary apoplexy. Note the superior displacement of the optic chiasm* ⇨.

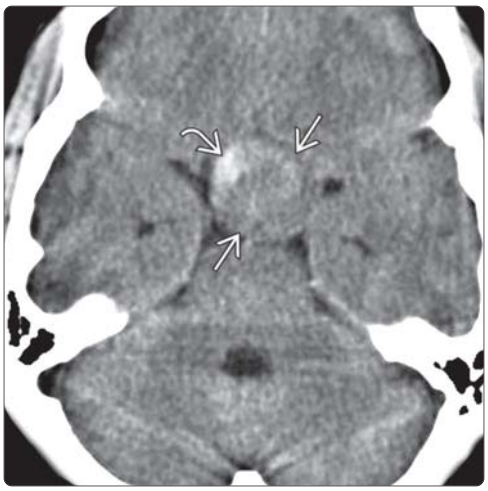

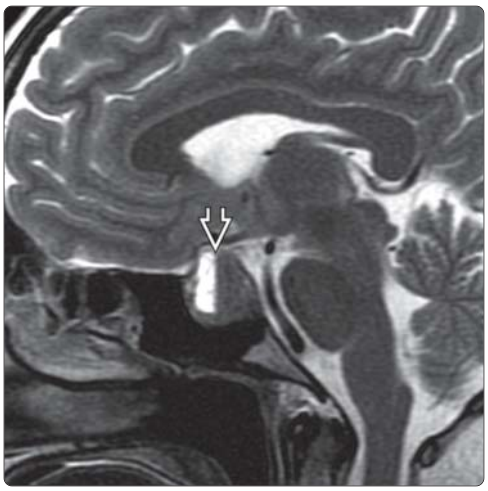

(Left) *Axial NECT in a patient with an acute severe headache and bitemporal hemianopsia shows a mostly isointense mass in the suprasellar cistern* ⇨. *Peripheral hemorrhage* ⇨ *into large necrotic macroadenoma was found at surgery. (Courtesy S. Candy, MD.)* **(Right)** *Sagittal T2 MR shows a blood-fluid level* ⇨ *in a patient with a previously diagnosed prolactin-secreting macroadenoma being treated with a dopamine receptor agonist (cabergoline). He presented acutely with headache, visual changes, and ophthalmoplegia.*

https://CafePezeshki.IR

KEY FACTS

TERMINOLOGY

- Benign, often partially cystic sellar region tumor derived from Rathke pouch epithelium
- 2 types
  - Adamantinomatous (cystic mass in childhood)
  - Papillary (solid mass in older adults)

IMAGING

- General features
  - Multilobulated, often large (> 5 cm)
  - Occasionally giant, multicompartmental
- CT
  - Cystic (90%), Ca++ (90%), enhancing (90%)
- MR: Signal varies with cyst contents
  - Cysts variably hyperintense on T1WI and T2WI
  - Solid portions enhance heterogeneously; cyst walls enhance strongly
  - Cyst contents show broad lipid peak (0.9-1.5 ppm) on MR spectroscopy

PATHOLOGY

- Most common pediatric intracranial tumor of nonglial origin
- WHO grade I
- Craniopharyngiomas arise from remnants of craniopharyngeal duct

CLINICAL ISSUES

- Bimodal age distribution
  - Peak 5-15 years; papillary craniopharyngioma > 50 years
- Pediatric patient with morning headache, visual defect, short stature
  - Endocrine disturbances include growth hormone (GH) deficiency
  - Others = hypothyroidism > adrenal failure > diabetes insipidus
- Surgical resection is primary therapy
- Surgery, radiation therapy, or cyst aspiration for recurrent tumors

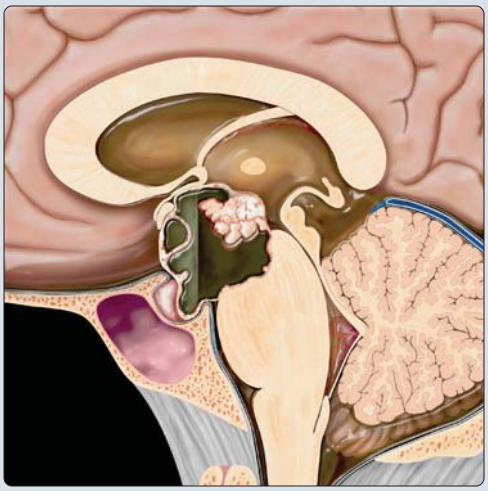

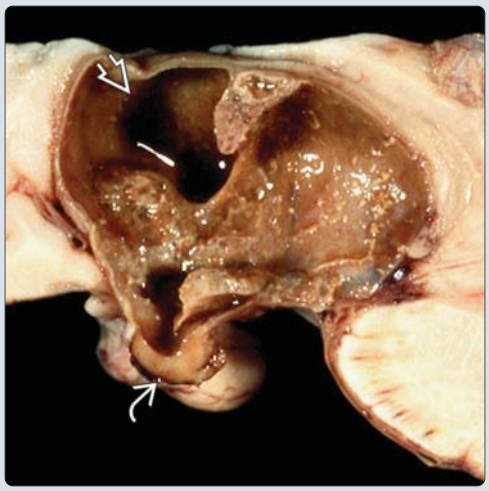

(Left) *Sagittal graphic shows a predominantly cystic, partially solid, suprasellar mass with focal rim calcifications. Note the small intrasellar component and fluid-fluid level. Craniopharyngiomas are the 90% tumors (90% cystic, 90% calcified, and 90% enhancing).* **(Right)** *Sagittal gross pathology shows classic adamantinomatous craniopharyngioma with mixed solid, cystic components. The classic machine or "crank case oil" ⇨ is present. Note the intrasellar extension ⇨. (Courtesy R. Hewlett, MD.)*

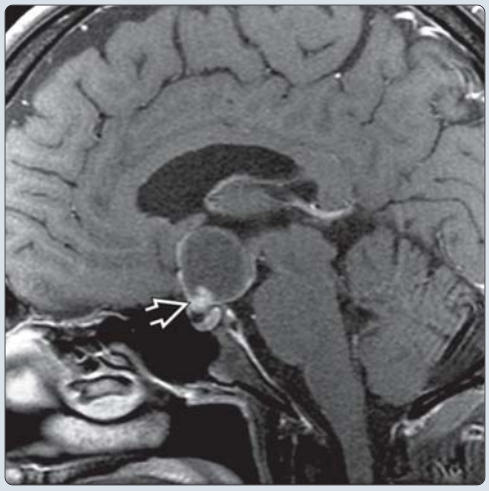

(Left) *T2 MR in a 48-year-old man who presented with visual changes shows a cystic suprasellar mass ⇨ with a focal T2-hypointense nodule ⇨. The T2 imaging mimics a Rathke cleft cyst.* **(Right)** *Sagittal T1 C+ MR in the same patient shows the enhancing nodule ⇨, which distinguishes this cystic lesion as a craniopharyngioma, not a Rathke cleft cyst. Surgical resection is the primary therapy for this WHO grade I neoplasm. However, the recurrence rate at 10 years approaches 20%.*

https://CafePezeshki.IR

TERMINOLOGY

Abbreviations

- Craniopharyngioma (CP)

Synonyms

- Craniopharyngeal duct tumor, Rathke pouch tumor, adamantinoma

Definitions

- Benign, often partially cystic sellar region tumor derived from Rathke pouch epithelium
  - 2 histologies: Adamantinomatous and papillary

IMAGING

General Features

- Best diagnostic clue
  - CT: Partially Ca++ mixed solid/cystic suprasellar mass in child
  - MR: Complex signal intensity suprasellar mass
- Location
  - Surgical division of CPs into 3 groups
    - Sellar
    - Prechiasmatic
    - Retrochiasmatic
  - Imaging locations of CPs (adamantinomatous type)
    - Suprasellar (75%)
    - Suprasellar + intrasellar component (21%)
    - Entirely intrasellar (4%)
    - Often extends into multiple cranial fossae: Anterior (30%), middle (23%), posterior, &/or retroclival (20%)
  - Rare ectopic locations
    - Optic chiasm, 3rd ventricle
    - Other: Nasopharynx, paranasal sinuses, pineal gland, sphenoid (clivus), cerebellopontine angle
- Size
  - Variable; often large at presentation (> 5 cm)
    - Occasionally giant, multicompartmental
- Morphology
  - Multilobulated, multicystic

CT Findings

- NECT
  - Adamantinomatous type (90% rule)
    - 90% mixed solid (isodense), cystic (hypodense)
    - 90% calcify
    - 90% enhance (solid = nodule; rim = capsule)
  - Papillary type: Often solid, isodense, rarely calcifies

MR Findings

- T1WI
  - Signal varies with cyst contents
    - Short T1 due to high protein content
    - Classic (adamantinomatous type)
      - Hyperintense cyst + heterogeneous nodule
    - Less common (papillary type)
      - Isointense solid component
- T2WI
  - Cysts are variably hyperintense
  - Solid component = heterogeneous (iso-/hyperintense, Ca++ portions hypointense)
  - Hyperintense signal in brain parenchyma adjacent to tumor may indicate
    - Gliosis, tumor invasion, irritation from leaking cyst fluid
    - Edema from compression of optic chiasm/tracts
    - Hypointense T2* = Ca++
- FLAIR
  - Cyst contents typically hyperintense
- DWI
  - Variable depending upon character of cyst fluid
- T1WI C+
  - Solid portions enhance heterogeneously; cyst walls enhance strongly
- MRA
  - Vascular displacement &/or encasement
- MRS
  - Cyst contents show broad lipid spectrum (0.9-1.5 ppm)

Imaging Recommendations

- Best imaging tool
  - MR with thin sagittal, coronal sequences
- Protocol advice
  - Pre-/post-contrast T1WI, T2, FLAIR, GRE, DWI, MRS

DIFFERENTIAL DIAGNOSIS

Rathke Cleft Cyst (RCC)

- Noncalcified, less heterogeneous
- Look for intracystic nodule on T2
- Does not enhance
  - Claw sign (enhancing pituitary draped around cyst)
- Small RCC may be indistinguishable from rare intrasellar CP
- RCCs express CK8 and CK20 (CPs generally do not)

Suprasellar Arachnoid Cyst

- No Ca++, enhancement

Hypothalamic/Chiasmatic Astrocytoma

- Solid or with small cystic/necrotic components
- Ca++ is rare; robust enhancement is common

Pituitary Adenoma

- Rare in prepubescent children
- Isointense with brain
- Enhances strongly
- Can mimic CP when cystic and hemorrhagic

Epidermoid/Dermoid Tumors

- Minimal or no enhancement

Thrombosed Aneurysm

- Contains blood products; use SWI
- Look for residual patent lumen, phase artifact

Germinoma or Mixed Germ Cell Tumor With Cystic Component(s)

- CSF spread is common, Ca++ is rare

PATHOLOGY

General Features

- Etiology
  - 2 proposed theories

https://CafePezeshki.IR

- CPs arise from remnants of craniopharyngeal duct
- CPs arise from squamous epithelial cells in pars tuberalis of adenohypophysis

- Genetics
  - No known genetic susceptibility (rare reports of siblings, parent-child)
  - Small subset of CPs are monoclonal tumors that arise from oncogenes at specific loci
  - β-catenin gene mutations found in adamantinomatous CP (genetically distinctive)

Staging, Grading, & Classification

- WHO grade I
- MIB-1 labeling index > 7% predicts recurrence

Gross Pathologic & Surgical Features

- Solid tumor with variable cysts
- Adamantinomatous cysts often contain thick "crankcase oil" fluid
- Epithelial fronds penetrate adjacent hypothalamus/chiasm

Microscopic Features

- Adamantinomatous (mostly pediatric)
  - Multi-stratified squamous epithelium with nuclear palisading
  - Nodules of "wet" keratin
  - Dystrophic Ca++
- Papillary (mostly adults)
  - Sheets of squamous epithelium form pseudopapilla
  - Villous fibrovascular stroma
- Malignant transformation, distant metastases rare
  - May occur with varied histologies, resulting in poor prognosis

CLINICAL ISSUES

Presentation

- Most common signs/symptoms
  - Symptoms vary with location, size of tumor, age of patient
  - Visual disturbances
    - Bitemporal hemianopsia
- Other signs/symptoms
  - Endocrine disturbances
    - Growth hormone (GH) deficiency > hypothyroidism > adrenal failure > diabetes insipidus
    - Headaches
- Clinical profile
  - Pediatric patient with morning headache, visual defect, short stature

Demographics

- Age
  - Bimodal distribution (peak 5-15 years, with smaller peak > 65 years)
    - Papillary CP > 50 years
- Gender
  - M = F
- Ethnicity
  - More common in Japanese children
- Epidemiology
  - Most common pediatric intracranial tumor of nonglial origin
  - Comprise 1.2-4% of all intracranial tumors across all ages
    - 6-9% of all pediatric intracranial tumors
    - Incidence = 0.5-2.5 new cases per 1 million per year
  - ~ 54% of all pediatric sellar/chiasmatic region tumors are CPs

Natural History & Prognosis

- Typically slow-growing benign neoplasm
- Prognosis based upon size, extent of tumor at presentation
  - < 5 cm, recurrence rate: 20%
  - > 5 cm, recurrence rate: 83%
  - Overall 10-year survival: 64-96%

Treatment

- Methods of primary treatment
  - Radical surgery = gross total resection
    - Complications = hypothalamic injury, endocrine symptoms, vasa vasorum injury, and pseudoaneurysm
  - Surgery may occur via craniotomy, transnasal, transorbital, or endoscopic routes
  - Limited surgery = subtotal resection plus radiation therapy
  - Biopsy, cyst drainage, and radiation therapy
- Treatment for residual or recurrent tumor
  - Surgery, radiation therapy, or cyst aspiration
  - Cyst instillation with intracavitary radioisotopes, bleomycin, or other sclerosing agents

DIAGNOSTIC CHECKLIST

Consider

- Preoperative ophthalmologic and endocrine evaluations

Image Interpretation Pearls

- Use NECT to detect Ca++ if MR diagnosis is in question
- Adamantinomatous craniopharyngioma = 90% rule (90% cystic, calcified, enhancing)
- Papillary craniopharyngioma is typically solid and primarily an adult neoplasm

SELECTED REFERENCES

1. Greenfield BJ et al: Long-term disease control and toxicity outcomes following surgery and intensity modulated radiation therapy (IMRT) in pediatric craniopharyngioma. Radiother Oncol. 114(2):224-9, 2015
2. Kim JH et al: BRAF V600E mutation is a useful marker for differentiating Rathke's cleft cyst with squamous metaplasia from papillary craniopharyngioma. J Neurooncol. ePub, 2015
3. Lee HJ et al: Pretreatment diagnosis of suprasellar papillary craniopharyngioma and germ cell tumors of adult patients. AJNR Am J Neuroradiol. 36(3):508-17, 2015
4. Sterkenburg AS et al: Survival, hypothalamic obesity, and neuropsychological/psychosocial status after childhood-onset craniopharyngioma: newly reported long-term outcomes. Neuro Oncol. ePub, 2015
5. Lee CC et al: Gamma Knife surgery for craniopharyngioma: report on a 20-year experience. J Neurosurg. 121 Suppl:167-78, 2014
6. Clark AJ et al: A systematic review of the results of surgery and radiotherapy on tumor control for pediatric craniopharyngioma. Childs Nerv Syst. 29(2):231-8, 2013
7. Müller HL: Childhood craniopharyngioma. Pituitary. 16(1):56-67, 2013
8. Clark AJ et al: Treatment-related morbidity and the management of pediatric craniopharyngioma: a systematic review. J Neurosurg Pediatr. 10(4):293-301, 2012

https://CafePezeshki.IR

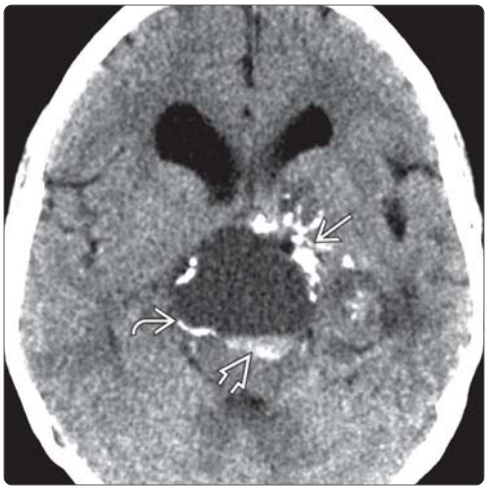

(Left) *Axial NECT shows classic findings of craniopharyngioma. Note the large suprasellar cyst with a fluid-fluid level ➡, rim ➡, and globular ➡ calcifications.* **(Right)** *Sagittal T1WI C+ MR shows a complex cystic suprasellar mass with an enhancing rim ➡ and solid components ➡. The cysts contain fluid of different signal intensities. Note the large suprasellar, smaller intrasellar ➡ components in this classic craniopharyngioma.*

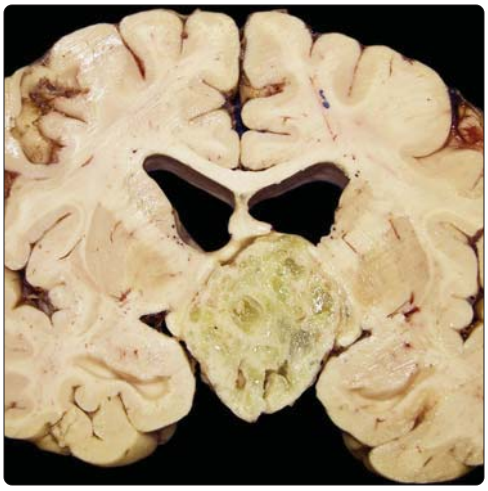

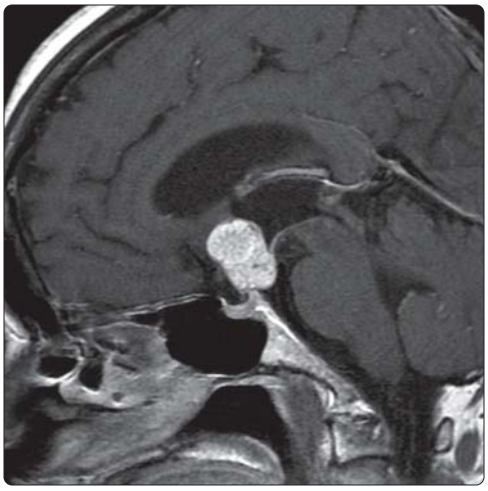

(Left) *Gross pathologic specimen displays a typical solid and cystic composition of an adamantinomatous craniopharyngioma. The cystic spaces contain a thick gelatinous material. (Courtesy AFIP.)* **(Right)** *Sagittal T1 C+ MR in this 45-year-old patient who presented with visual changes shows a solid enhancing suprasellar mass. Papillary craniopharyngioma was diagnosed at resection. Papillary craniopharyngiomas are WHO grade I tumors. However, they are more commonly solid, noncalcified lesions.*

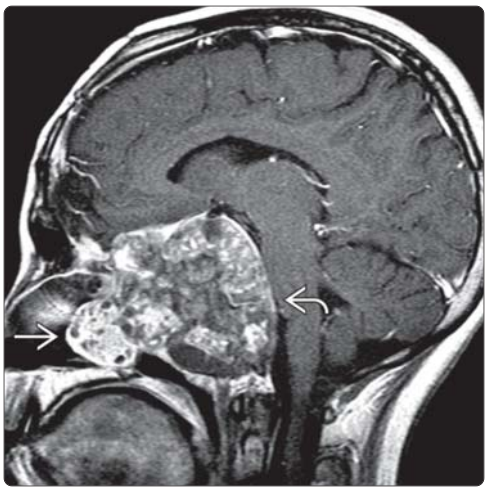

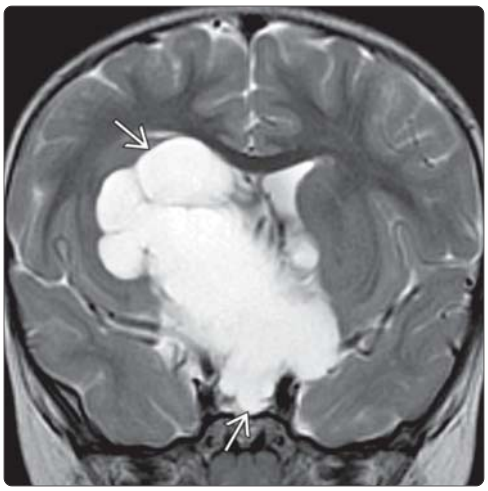

(Left) *Sagittal T1WI C+ MR shows a large recurrent adamantinomatous craniopharyngioma in the sella, suprasellar, nasopharyngeal ➡, & prepontine space ➡ with typical heterogeneous cystic & solid morphology. Note mass effect on the optic chiasm, hypothalamus, & pons. (Courtesy S. Blaser, MD.)* **(Right)** *Coronal T2WI MR in a 2 year old with a huge suprasellar mass shows multiple hyperintense cysts ➡. The intrasellar component is relatively small.*

https://CafePezeshki.IR

KEY FACTS

TERMINOLOGY

- Rare tumor arising from pituicytes, specialized glial cells in neurohypophysis and infundibulum

IMAGING

- Enhancing sellar or suprasellar mass arising from neurohypophysis or infundibulum
- Location is typically suprasellar (infundibular); pure intrasellar less common
- MR: Isointense to hypointense solid mass
  - Posterior pituitary "bright spot" often absent
  - Variable enhancement, typically strong & uniform
- Best imaging tool: High-resolution MR of sella (2.5-3 mm slice thickness)
  - Sagittal & coronal T1, coronal T2, post-contrast sagittal, & coronal T1 with fat saturation

TOP DIFFERENTIAL DIAGNOSES

- Pituitary adenoma
- Lymphocytic hypophysitis
- Pituitary hyperplasia
- Granular cell tumor

PATHOLOGY

- Distinct from granular cell tumor (WHO 2007)
- WHO grade I
- Well-demarcated, round or oval solid mass
- Hypervascular tumor at surgery

CLINICAL ISSUES

- Visual and endocrine dysfunction common symptoms
- May be asymptomatic
- Surgical resection: Primary therapy; transsphenoidal approach difficult given tumor vascularity

DIAGNOSTIC CHECKLIST

- If mass is present posteriorly within gland, is intrasellar but separate from gland, or involves stalk, consider pituicytoma

(Left) *Sagittal graphic shows a pituicytoma involving the infundibular stalk and neurohypophysis. A lobular suprasellar mass without significant compression of the adjacent structures is typical for this rare, low-grade, spindle cell glial neoplasm.* **(Right)** *H&E histopathology shows the typical benign features of a pituicytoma with bipolar spindle cells with abundant eosinophilic cytoplasm. Nuclear atypia and mitoses are absent. GFAP (not shown) showed strong staining, indicating the astrocytic origin of the tumor.*

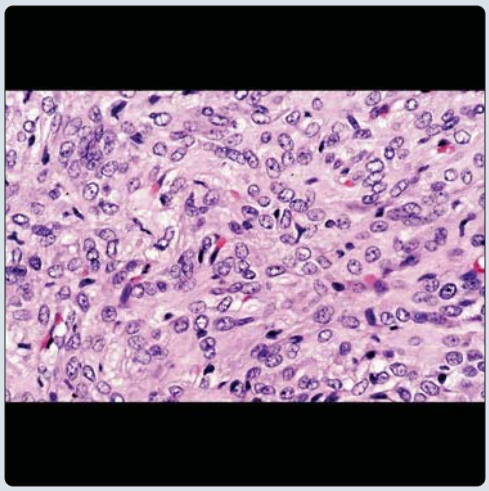

(Left) *Sagittal T1WI MR shows a well-delineated suprasellar mass ➡ extending into the posterior sella. Note the lack of a normal pituitary "bright spot," a common feature of pituicytoma.* **(Right)** *Coronal T1WI C+ MR in the same patient shows strong uniform enhancement of this large pituicytoma. Such enhancement is typical of these rare tumors of the neurohypophysis or infundibulum. These vascular tumors are WHO grade I. (Courtesy A.V. Hasso, MD.)*

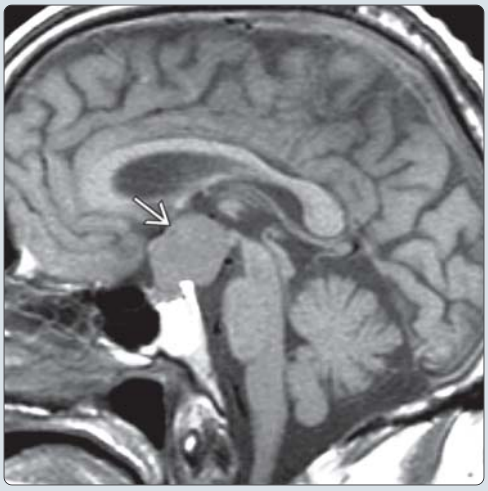

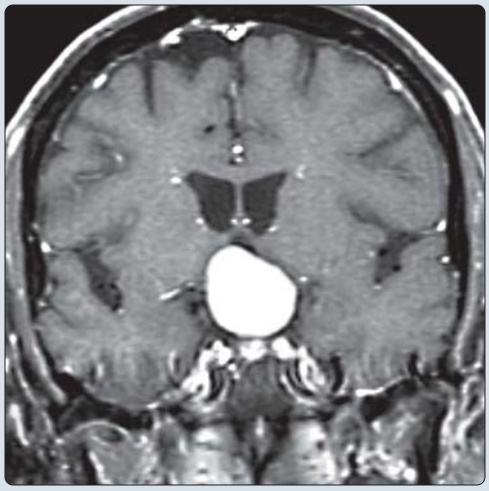

https://CafePezeshki.IR

TERMINOLOGY

Synonyms

- Less preferred terms include infundibuloma and posterior pituitary astrocytoma

Definitions

- Rare tumor arising from pituicytes, specialized glial cells in neurohypophysis and infundibulum

IMAGING

General Features

- Best diagnostic clue
  - Enhancing sellar or suprasellar mass arising from neurohypophysis or infundibulum
- Location
  - Typically suprasellar (infundibular); pure intrasellar less common
- Size
  - Variable (1-2 mm to 4 cm)
- Morphology
  - Well-demarcated, round or oval solid mass

CT Findings

- NECT
  - Hyperdense sellar &/or suprasellar mass; Ca++ rare

MR Findings

- T1WI
  - Isointense to hypointense solid mass
  - Posterior pituitary "bright spot" often absent
- T2WI
  - Heterogeneously hypo- to isointense
- T1WI C+
  - Variable enhancement, typically strong & uniform

Imaging Recommendations

- Best imaging tool
  - High-resolution MR of sella (2.5-3 mm slice thickness)
- Protocol advice
  - Sagittal & coronal T1, coronal T2, post-contrast sagittal & coronal T1 with fat saturation through sella

DIFFERENTIAL DIAGNOSIS

Pituitary Adenoma

- May be indistinguishable; typically anterior gland
- Sellar &/or suprasellar enhancing mass

Lymphocytic Hypophysitis

- May involve gland (anterior > posterior) or stalk
- Typically pregnant or peripartum females

Pituitary Hyperplasia

- Typically diffuse gland enlargement

Metastasis

- Primary tumor often known; multiple lesions common

Granular Cell Tumor

- Glial neoplasm originating in neurohypophysis or infundibulum

PATHOLOGY

General Features

- Etiology
  - Arise from pituicytes in neurohypophysis or infundibulum
  - Distinct from granular cell tumor (WHO 2007)

Staging, Grading, & Classification

- WHO grade I

Gross Pathologic & Surgical Features

- Well-circumscribed, soft to firm mass
  - Necrosis & cystic degeneration are uncommon
  - Rarely, tumor infiltrates surrounding structures including optic chiasm & cavernous sinus
- Hypervascular tumor at surgery

Microscopic Features

- Elongate, bipolar spindle cells with abundant cytoplasm
- Perivascular lymphocytic aggregates common
- Vimentin (+), S100 protein (+), GFAP(+)

CLINICAL ISSUES

Presentation

- Most common signs/symptoms
  - Visual and endocrine dysfunction common
    - Headache, amenorrhea, galactorrhea, decreased libido, infertility, diabetes insipidus, hypopituitarism
  - May be asymptomatic

Demographics

- Age
  - Peak incidence: 5th decade
  - No cases reported in patients younger than 20 years old
- Gender
  - M:F = 1.6:1
- Epidemiology
  - Rare (< 50 symptomatic cases have been reported)

Natural History & Prognosis

- Benign, slow-growing tumor
- Regrowth after subtotal resection not uncommon

Treatment

- Surgical resection: Primary therapy; transsphenoidal approach difficult given tumor vascularity
- Inconsistent data regarding radiation therapy
- Preoperative embolization may be helpful

DIAGNOSTIC CHECKLIST

Consider

- If mass is present posteriorly within gland, is intrasellar but separate from gland, or involves stalk, consider pituicytoma

SELECTED REFERENCES

1. Zygourakis CC et al: Pituicytomas and spindle cell oncocytomas: modern case series from the University of California, San Francisco. Pituitary. 18(1):150-8, 2015
2. Feng M et al: Surgical management of pituicytomas: case series and comprehensive literature review. Pituitary. 17(5):399-413, 2014
3. Teti C et al: Pituitary image: pituicytoma. Pituitary. ePub, 2014

https://CafePezeshki.IR

KEY FACTS

TERMINOLOGY

- Rare nonadenomatous, nonendocrine, nonfunctioning sellar tumor
- Thought to arise from folliculostellate cells of anterior pituitary

IMAGING

- Indistinguishable from macroadenoma on imaging
- Sellar and suprasellar mass
- CT: Iso- to hyperdense sellar/suprasellar mass
- MR: Mostly isointense with white matter
  - Strong, typically uniform enhancement

TOP DIFFERENTIAL DIAGNOSES

- Pituitary macroadenoma
- Lymphocytic hypophysitis
- Pituicytoma
- Granular cell tumor of neurohypophysis
- Metastasis

PATHOLOGY

- Gross appearance indistinguishable from macroadenoma
- Microscopic features
  - Interwoven fascicles of elongated spindled cells
  - Eosinophilic "oncocytic" cytoplasm
  - Mitotic rate typically low
- WHO grade I

CLINICAL ISSUES

- Tumor of adults (mostly 5th/6th decades)
- Symptoms indistinguishable from nonfunctioning pituitary macroadenoma
  - Visual defects
  - Panhypopituitarism
  - Headache
  - Less common symptoms reported include nausea and vomiting
- Treatment: Surgical resection
- Generally benign clinical course

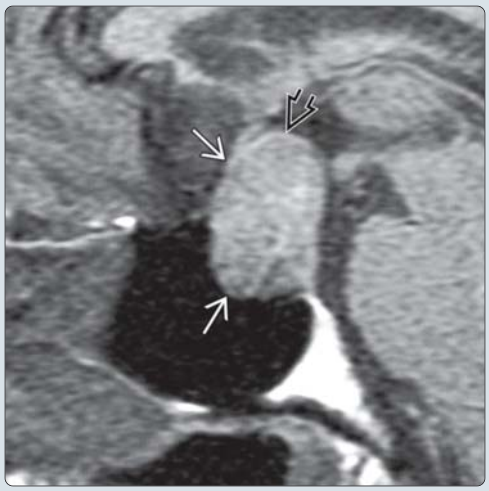

(Left) *Axial NECT in a 69-year-old woman with headaches and bitemporal hemianopsia shows a well-delineated, slightly hyperdense mass ⇨ in the suprasellar cistern.* **(Right)** *Sagittal T1WI MR in the same patient shows a sellar and suprasellar mass ➡ that appears isointense with white matter with superior displacement of the optic chiasm ⇨. Note that the pituitary gland cannot be identified separate from the mass, nor can the infundibular stalk be distinguished from the rest of the lesion.*

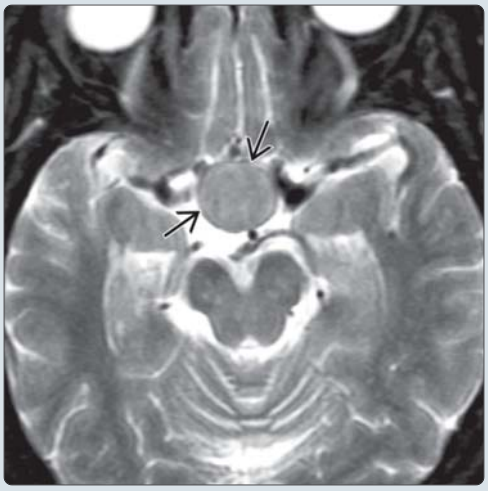

(Left) *Axial T2WI MR in the same patient shows that the mass ⇨ is sharply circumscribed and remains isointense with white matter.* **(Right)** *Coronal T1 C+ MR shows the tumor ➡ enhances strongly and uniformly. Preoperative diagnosis was pituitary macroadenoma. Oncocytoma was found at surgery. Although imaging and clinical findings are indistinguishable from macroadenomas, oncocytomas are readily distinguished on histologic, immunohistochemical, and fine structural features.*

https://CafePezeshki.IR

KEY FACTS

TERMINOLOGY

- Neoplasms that arise from pituicytes, specialized glial cells of the neurohypophysis or infundibulum
- Rare low-grade, nonendocrine neoplasms of sellar region
- Formerly called pituicytoma; granular cell tumor of the neurohypophysis

IMAGING

- Enhancing, well-circumscribed sellar/suprasellar or infundibular mass
- 1.5 -6.0 cm
- CT: Sellar/suprasellar mass with hyperattenuation
  - Rarely calcification may be present
- Best imaging tool: MR C+ with high-resolution imaging through sellar region
- Consider granular cell tumor if sellar/suprasellar mass appears separate from anterior pituitary gland

TOP DIFFERENTIAL DIAGNOSES

- Pituitary macroadenoma
- Lymphocytic hypophysitis
- Pituicytoma
- Spindle cell oncocytoma
- Rathke cleft cyst

PATHOLOGY

- WHO grade I

CLINICAL ISSUES

- Commonly asymptomatic (small lesions)
- Visual field deficit related to optic chiasm compression is most common presenting feature
- Less common symptoms: Panhypopituitarism, galactorrhea, amenorrhea, decreased libido, neuropsychological changes
- Typically present in adulthood, 5th-6th decades
- Generally benign clinical course

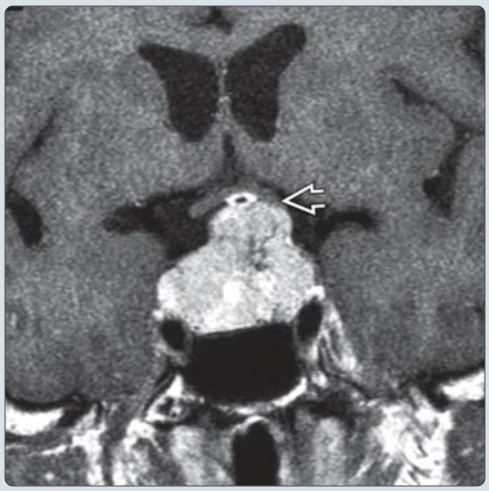

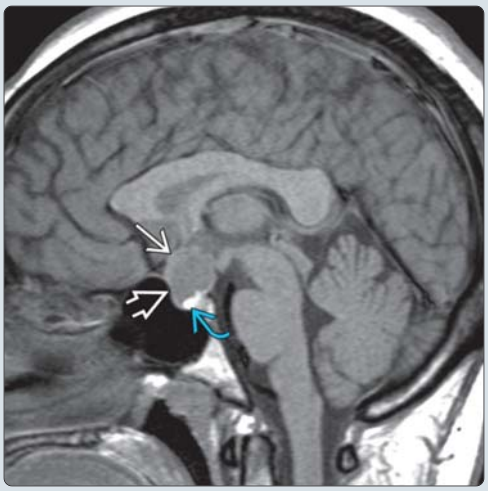

(Left) *Coronal T1 C+ MR shows a large sellar and suprasellar enhancing mass contacting the left optic chiasm ➡. Granular cell tumor was diagnosed at resection. Imaging mimics the much more common pituitary macroadenoma.* **(Right)** *Sagittal T1 MR in a 31-year-old woman with headache and visual complaints shows a sellar & suprasellar mass ➡ with superior displacement of the optic chiasm ➡. There is a hyperintense focus ⇨ along the inferior aspect of the mass.*

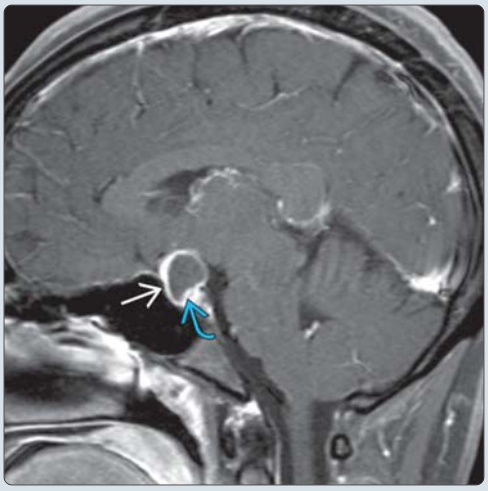

(Left) *Coronal T1 C+ MR in the same patient shows peripheral enhancement of the mass ➡.* **(Right)** *Sagittal T1 C+ MR in the same patient shows peripheral enhancement ➡ and central low signal within the mass. The region of T1 hyperintensity is also seen, resembling an intracystic nodule ⇨, typically seen in a Rathke cleft cyst. Pathology revealed a granular cell tumor of the neurohypophysis at resection. Granular cell tumor was recognized as a separate tumor entity by the 2007 WHO classification system.*

https://CafePezeshki.IR

KEY FACTS

TERMINOLOGY

- Sella partially filled with arachnoid-lined CSF collection
- Primary empty sella
  - Common normal, incidental finding (15% of brain MRs)
  - Can be normal variant
  - Normal or increased CSF pressure
  - Near normal volume of compressed pituitary tissue
- Secondary empty sella
  - Prior pituitary surgery, radiation, or injury

IMAGING

- Intrasellar CSF, pituitary flattened against sellar floor
  - Bony sella may be normal or moderately enlarged (secondary to pulsatile CSF)
  - Bony margins intact, not eroded/demineralized
  - Infundibular stalk, pituitary gland enhance normally
- Fluid exactly like CSF
  - Suppresses completely on FLAIR
  - Does not restrict on DWI

TOP DIFFERENTIAL DIAGNOSES

- Idiopathic intracranial hypertension
- Secondary intracranial hypertension
- Arachnoid cyst
- Pituitary apoplexy

PATHOLOGY

- "Deficient" diaphragma sellae
  - Dural covering of sella is incomplete (widened)
  - Leaves large opening for infundibular stalk
  - Allows intrasellar herniation of arachnoid with CSF from suprasellar subarachnoid cistern above

CLINICAL ISSUES

- Mostly incidental, asymptomatic (adults)
  - F:M = 5:1
- Headache, visual disturbances if related to intracranial hypertension
- Frequent endocrine abnormalities in children

(Left) *Sagittal graphic shows an empty sella (ES). The extension of arachnoid with CSF through the diaphragma sellae ➡ flattens and displaces the pituitary gland ⇨ posteroinferiorly against the sellar floor.* **(Right)** *Axial gross pathology shows a primary empty sella found incidentally at autopsy. Note the wide opening of the diaphragma sellae ⇨ and CSF ⇨ largely filling the bony sella. (Courtesy M. Sage, MD.)*

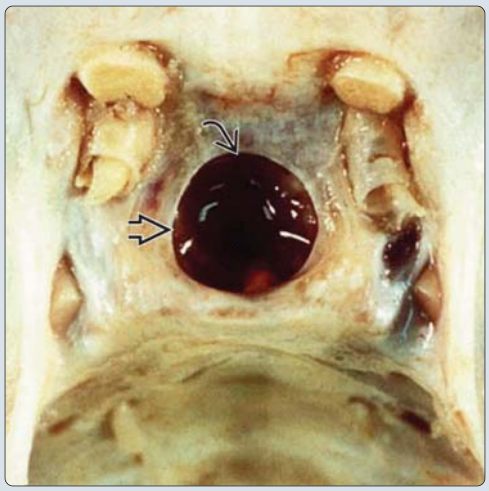

(Left) *Sagittal T1WI MR shows a 40-year-old man with incidentally found partially empty sella. No endocrine laboratory abnormalities. Notice enlarged bony sella with thin rim of pituitary tissue ⇨.* **(Right)** *This T2WI MR was taken from the same 40-year-old man with incidental partially empty sella. The bony sella is expanded and filled with CSF. A normal pituitary infundibulum is present in the midline.*

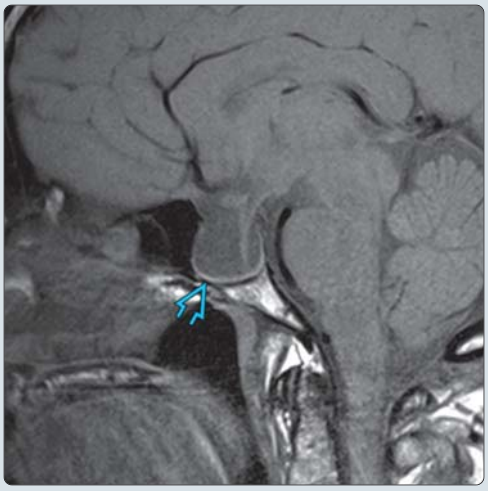

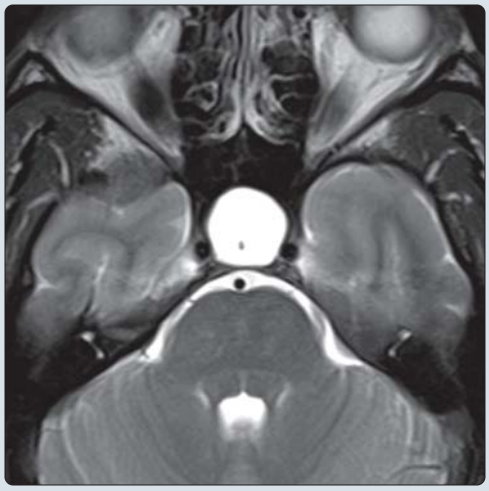

https://CafePezeshki.IR

TERMINOLOGY

Abbreviations

- Empty sella (ES)

Definitions

- Herniation of suprasellar arachnoid and CSF through wide diaphragma sellae into bony sella turcica
- Sella turcica is partially filled with CSF
  - Rarely completely empty
  - Pituitary gland
    - Almost never completely absent
    - Thin, flattened rim of residual pituitary tissue
    - Generally at posteroinferior sellar floor
- Primary or secondary
  - Primary empty sella
    - Common normal variant (15% of MRs), incidental finding
    - Normal or increased CSF pressure
    - Near normal volume of compressed pituitary tissue
    - No history of trauma, surgery, radiation
    - Patients typically endocrinologically normal
  - Secondary empty sella
    - Many etiologies
      - Surgery
      - Radiation
      - Bromocriptine therapy
      - Trauma
      - Sheehan syndrome (postpartum pituitary necrosis)
      - Pituitary apoplexy
      - Pituitary abscess

IMAGING

General Features

- Best diagnostic clue
  - Intrasellar CSF with pituitary gland flattened against sellar floor
  - Bony sella may be normal or large
- Location
  - Intrasellar CSF
- Size
  - Variable

Imaging Recommendations

- Best imaging tool
  - Sagittal T1WI
  - Coronal T2WI

CT Findings

- NECT
  - CSF-like herniation of CSF into bony sella
    - Bony sella typically appears normal
  - May also be moderately enlarged (secondary to pulsatile CSF)
    - Bony margins intact, not eroded/demineralized
- CECT
  - Infundibular stalk and pituitary gland enhance normally
  - Occasionally intrasellar CSF collection may be asymmetric
    - Stalk may appear tilted to 1 side

MR Findings

- T1WI
  - Primary empty sella
    - Fluid looks exactly like CSF
    - Stalk usually midline
      - Stalk may be tilted to 1 side if intrasellar CSF herniation is asymmetric
    - 3rd ventricle, hypothalamus usually normal
      - Rare: Herniation of optic chiasm, anterior 3rd ventricle into sella
  - Secondary empty sella
    - Look for changes of transsphenoidal hypophysectomy
      - Defect in sellar floor
      - Fat packing
    - May cause distortion of stalk, chiasm
      - Stalk and pituitary remnant(s) may be scarred/adhesed to side or bottom of sella turcica
- T2WI
  - Fluid exactly like CSF
- FLAIR
  - Intrasellar fluid suppresses completely on FLAIR
- DWI
  - No restriction
- T1WI C+
  - Primary empty sella
    - Stalk, gland enhance normally
    - No other abnormalities
  - Secondary empty sella
    - Gland and stalk may be adhesed/distorted

DIFFERENTIAL DIAGNOSIS

Idiopathic Intracranial Hypertension

- "Pseudotumor cerebri"
- Usually obese female, 20-40 years
- Headache, papilledema
- Enlarged optic nerve sheaths ± empty sella
- Ventricles may appear slit-like
- Subarachnoid spaces (cisterns, surface sulci) may be small

Secondary Intracranial Hypertension

- Increased intracranial pressure caused by
  - Obstructive hydrocephalus (intra-/extraventricular)
  - Mass (neoplasm, etc.)
- Dilated anterior recesses of 3rd ventricle herniate into sella
- Look for mass, evidence for transependymal CSF migration

Arachnoid Cyst

- Suprasellar arachnoid cyst may herniate into bony sella
  - Bony sella often enlarged, eroded/expanded
- Look for 3rd ventricle or optic chiasm displaced by CSF-containing mass
- Cyst walls may be visible on thin-section imaging

Pituitary Apoplexy

- Acute: Pituitary gland usually enlarged, not small
  - Usually hemorrhagic
  - Look for rim enhancement around periphery of enlarged, nonenhancing gland
- Chronic: May cause empty sella

https://CafePezeshki.IR

Pituitary Anomalies

- Ectopic posterior pituitary "bright spot"
  - May cause small pituitary gland
  - Infundibular stalk short, "stubby"
  - Bony sella often small, shallow appearing
  - Sella can appear partially empty
- Persisting embryonal infundibular recess of 3rd ventricle
  - Can mimic empty sella (rare)
- Pituitary stalk duplication
  - Rare
  - Look for 2 thin stalks
  - Sella may appear partially empty

Sheehan Syndrome

- Original clinical description
  - Postpartum hemorrhage
  - Pituitary necrosis
  - Lactation failure
  - Hypopituitarism
- Anterior pituitary necrosis
  - Leaves small residual pituitary gland
  - Result = empty sella
- May occur years after pregnancy
- Slow clinical progression over years suggests factors other than ischemia may be involved
- Necrosis may be caused by antihypothalamus, antipituitary antibodies
- Pituitary autoimmunity may perpetuate hypopituitarism

Epidermoid Cyst

- True intrasellar epidermoid cyst very rare
  - Off midline > midline
  - Usually extension from cerebellopontine angle epidermoid

PATHOLOGY

General Features

- Etiology
  - Primary empty sella
    - Deficient diaphragma sellae
      - Dural covering of sella is incomplete (widened)
      - Leaves widened dural opening for infundibular stalk
      - Allows intrasellar herniation of arachnoid with CSF from suprasellar subarachnoid cistern above
    - Pulsatile CSF may gradually enlarge sella
  - Secondary empty sella
    - Common: Surgery, bromocriptine therapy, radiation
    - Less common/rare: Pituitary apoplexy, pituitary abscess

Gross Pathologic & Surgical Features

- Diaphragma sellae appears widened, gaping
- Intrasellar herniation of arachnoid-containing CSF

CLINICAL ISSUES

Presentation

- Most common signs/symptoms
  - Incidental, asymptomatic
  - Headache, visual disturbances if caused by idiopathic intracranial hypertension (IIH)
  - Endocrine disturbances
    - 20% of adults have subtle laboratory abnormalities
    - Majority (70%) of children with ES have endocrine abnormalities

Demographics

- Age
  - Peak incidence between 50-60 years
  - Increased CSF pressure presents earlier, 30-40 years
- Gender
  - F:M = 5:1
- Epidemiology
  - 10-15% found incidentally on imaging

Natural History & Prognosis

- Both primary and secondary empty sella usually benign, do not require treatment
- If related to IIH, can result in vision loss or CSF leak
- Hormonal replacement therapy may be required in some cases
- Surgery (rare)
  - "Chiasmapexy" to elevate optic chiasm if severe visual disturbances caused by inferior displacement of optic chiasm into empty sella
  - CSF rhinorrhea may require surgical intervention

DIAGNOSTIC CHECKLIST

Consider

- Incidental, normal variant in older adults
- Additional findings of IIH in younger females (e.g., dilated optic nerve sheaths, papilledema, dural venous sinus narrowing)
- Look for endocrine abnormalities in children

Image Interpretation Pearls

- Intrasellar fluid follows CSF **exactly** on all sequences

SELECTED REFERENCES

1. Jamjoom DZ et al: The association between petrous apex cephalocele and empty sella. Surg Radiol Anat. ePub, 2015
2. Aruna P et al: Partial empty sella syndrome: a case report and review. Indian J Clin Biochem. 29(2):253-6, 2014
3. Kyung SE et al: Enlargement of the sella turcica in pseudotumor cerebri. J Neurosurg. 120(2):538-42, 2014
4. Mehta GU et al: Effect of primary empty sella syndrome on pituitary surgery for Cushing's disease. J Neurosurg. 121(3):518-26, 2014
5. Saindane AM et al: Factors determining the clinical significance of an "empty" sella turcica. AJR Am J Roentgenol. 200(5):1125-31, 2013
6. Lenz AM et al: Empty sella syndrome. Pediatr Endocrinol Rev. 9(4):710-5, 2012
7. Pepene CE et al: Primary pituitary abscess followed by empty sella syndrome in an adolescent girl. Pituitary. 13(4):385-9, 2010
8. De Marinis L et al: Primary empty sella. J Clin Endocrinol Metab. 90(9):5471-7, 2005

https://CafePezeshki.IR

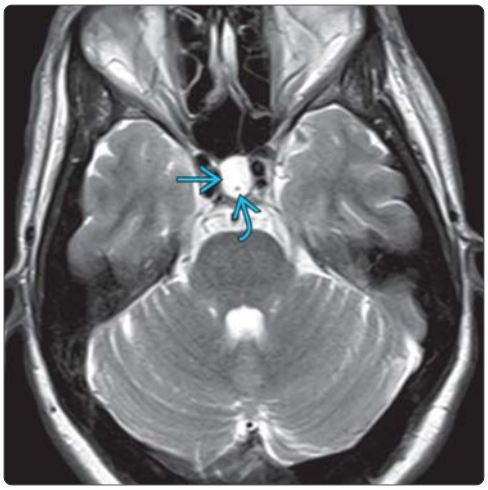

(Left) *Sagittal T1WI MR shows the incidental finding of a primary partially empty sella, mostly filled with CSF. Note the absence of a posterior pituitary "bright spot," which is found in 15-20% of endocrinologically normal patients.* **(Right)** *Axial T2WI MR in the same patient shows the sella mostly filled with CSF from intrasellar herniation of the suprasellar subarachnoid space. Note that the infundibular stalk within the mostly empty sella is normally positioned.*

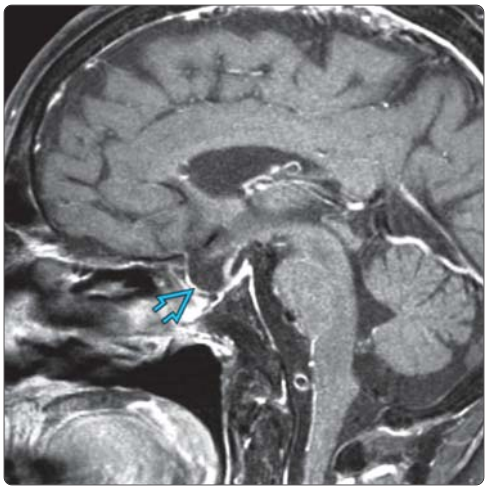

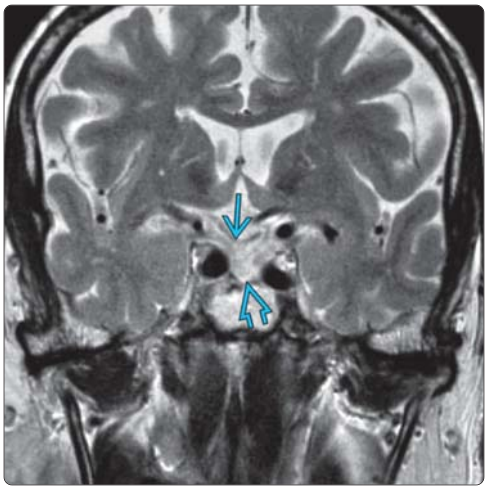

(Left) *Sagittal T1WI C+ FS MR shows an empty sella secondary to surgery for pituitary macroadenoma. Little pituitary tissue is apparent along the enlarged sellar floor.* **(Right)** *Coronal T2WI MR of a secondary empty sella in the same patient demonstrates that the sella is filled with CSF. Note the thinned optic chiasm retracted downward toward the sella.*

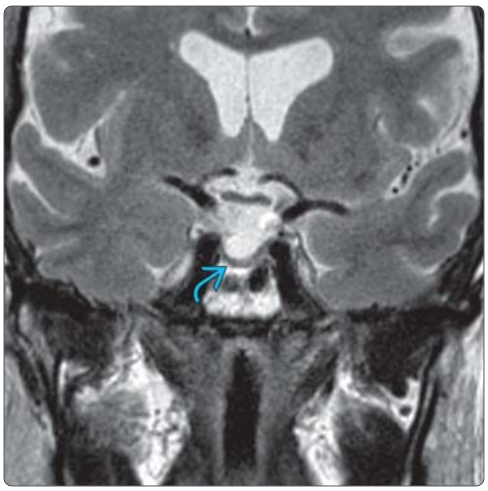

(Left) *T1WI C+ MR was taken from a 71-year-old woman with a sellar and suprasellar arachnoid cyst mimicking the appearance of an empty sella. Note the normally enhancing pituitary infundibulum and pituitary tissue displaced anteriorly by the CSF intensity arachnoid cyst.* **(Right)** *T2WI MR was taken from a 40-year-old man formerly treated with bromocriptine for elevated testosterone levels with a secondary empty sella. A small amount of residual pituitary tissue remains along the inferior margin of the normal-sized sella.*

https://CafePezeshki.IR

KEY FACTS

TERMINOLOGY

- Upper limit of normal pituitary height varies with age, gender
  - Pregnant/lactating females: 12 mm
  - Young menstruating females: 10 mm
  - Males, postmenopausal females: 8 mm
  - Infants, children: 6 mm
- Nonphysiologic hyperplasia seen with
  - Hypothyroidism, Addison disease, or other end-organ failure
  - Some neuroendocrine neoplasms

IMAGING

- Enlarged homogeneously enhancing pituitary gland with convex superior margin
- Best technique: High-resolution MR
  - Sagittal/coronal T1; coronal T2
  - Dynamic coronal T1WI
  - Post-contrast T1 FS sagittal/coronal T1
  - 3-4 mm slice thickness

TOP DIFFERENTIAL DIAGNOSES

- Pituitary macroadenoma
- Pituitary microadenoma
- Lymphocytic hypophysitis
- Venous congestion (intracranial hypotension, dural arteriovenous fistula)

PATHOLOGY

- Growth hormone cell hyperplasia usually diffuse, occurs with neuroendocrine tumors
- Prolactin cell hyperplasia: Diffuse > nodular
- Corticotroph hyperplasia: Nodular or diffuse
- Thyrotroph hyperplasia
  - Longstanding primary hypothyroidism, may have associated prolactin hyperplasia
- Gonadotroph hyperplasia (e.g., Turner, Klinefelter syndrome)

(Left) *Coronal graphic shows physiologic pituitary hyperplasia. The gland is uniformly enlarged and has a mildly convex superior margin.* **(Right)** *Sagittal T1W C+ MR in a 38-year-old woman undergoing infertility treatment imaged for headache shows a homogeneously enhancing pituitary measuring 12 mm.*

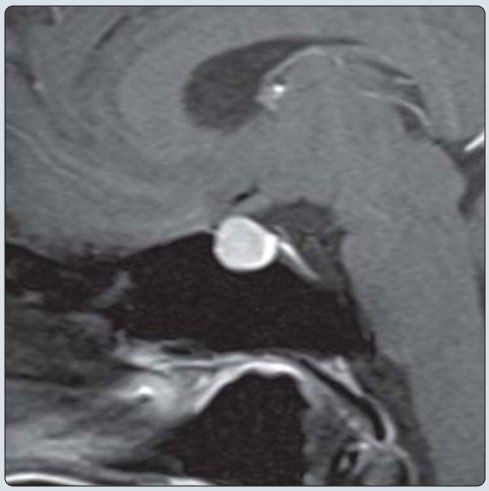

(Left) *Coronal T1WI C+ MR shows typical physiologic pituitary hyperplasia in a 28-year-old lactating woman. The gland has a mildly convex superior margin and measures nearly 14 mm in height.* **(Right)** *At follow-up 1 year later, coronal T1WI C+ MR reveals normal appearance to the pituitary gland with interval resolution of the postpartum physiologic enlargement.*

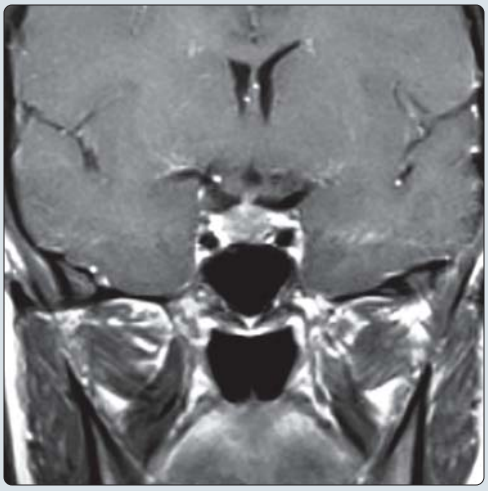

https://CafePezeshki.IR

TERMINOLOGY

Definitions

- Upper limit of normal pituitary height varies with age, gender
  - Pregnant/lactating females: 12 mm
  - Young menstruating females: 10 mm
  - Males, postmenopausal females: 8 mm
  - Infants, children: 6 mm
- Nonphysiologic hyperplasia seen with
  - Longstanding hypothyroidism, Addison disease, end-organ failure, or some neuroendocrine neoplasms

IMAGING

General Features

- Best diagnostic clue
  - Enlarged homogeneously enhancing pituitary gland with convex superior margin
  - May be nodular, mimic pituitary adenoma
- Location
  - Sella; may extend into suprasellar region, compress adjacent structures
- Size
  - > 10 mm up to 15 mm

CT Findings

- NECT
  - Noncalcified pituitary gland enlargement
- CECT
  - Homogeneous enhancement

MR Findings

- T1WI
  - Isointense with remainder of pituitary gland
- T2WI
  - Isointense with remainder of pituitary gland
- T1WI C+
  - Diffusely enhancing gland is typical
  - May cause focal nodular enlargement
  - Dynamic MR: Enhances similar to remainder of gland

Imaging Recommendations

- Best imaging tool
  - MR with 3 mm slices, small FOV
- Protocol advice
  - Sagittal/coronal T1; coronal T2
  - Dynamic enhanced coronal T1WI
  - Post-contrast T1 FS sagittal/coronal

DIFFERENTIAL DIAGNOSIS

Pituitary Macroadenoma

- May be indistinguishable

Pituitary Microadenoma

- May be indistinguishable
- Enhances slower than normal gland on dynamic study

Lymphocytic Hypophysitis

- Enlarged gland &/or stalk
- Pregnant or postpartum females

Venous Congestion

- Can occur with intracranial hypotension
- Dural arteriovenous fistulas

PATHOLOGY

General Features

- Etiology
  - Response to endocrinologic stimulation by orthotopic or ectopic production of hypothalamic releasing hormones
    - Orthotopic: Response to end-organ failure
    - Ectopic: Related to neuroendocrine tumors
  - Physiologic hyperplasia occurs in pregnancy and lactation

Microscopic Features

- Nodular hyperplasia characterized by marked expansion of acini, architectural distortion
- Diffuse hyperplasia requires formal cell count
- Growth hormone cell hyperplasia usually diffuse, occurs with neuroendocrine tumors
  - Pancreatic islet cell tumor, pheochromocytoma, bronchial and thyroid carcinoid tumor
  - Associated with McCune-Albright syndrome, multiple endocrine neoplasia syndrome, and Carney complex
- Prolactin cell hyperplasia: Diffuse > nodular
  - May be seen with pregnancy and lactation, estrogen treatment, primary hypothyroidism, Cushing disease
- Corticotroph hyperplasia: Nodular or diffuse
  - Associated with Cushing disease, neuroendocrine tumors, untreated Addison disease
- Thyrotroph hyperplasia
  - Longstanding primary hypothyroidism, may have associated prolactin hyperplasia
- Gonadotroph hyperplasia (e.g., Turner, Klinefelter syndrome)

CLINICAL ISSUES

Presentation

- Most common signs/symptoms
  - Varies with cell type of hyperplasia

Treatment

- If related to hypothyroidism, regression after thyroid hormone therapy common
- Treat end-organ failure or neuroendocrine tumor

DIAGNOSTIC CHECKLIST

Consider

- Hyperplasia may mimic adenoma
  - Clinical information can help differentiate
- If imaging looks like adenoma in prepubescent male, consider end-organ failure

SELECTED REFERENCES

1. Winters SJ et al: Addison's Disease and Pituitary Enlargement. Am J Med Sci. 349(6):526-9, 2015
2. Gläsker S et al: Hereditary pituitary hyperplasia with infantile gigantism. J Clin Endocrinol Metab. 96(12):E2078-87, 2011
3. Zhou J et al: Addison's disease with pituitary hyperplasia: a case report and review of the literature. Endocrine. 35(3):285-289, 2009
4. Alves C et al: Primary hypothyroidism in a child simulating a prolactin-secreting adenoma. Childs Nerv Syst. 24(12):1505-8, 2008

https://CafePezeshki.IR

KEY FACTS

TERMINOLOGY

- Lymphocytic hypophysitis (LH)
- Synonyms: Adenohypophysitis, primary hypophysitis, stalkitis
- Idiopathic inflammation of pituitary gland &/or stalk

IMAGING

- Thick stalk (> 2 mm + loss of normal "top to bottom" tapering)
- ± enlarged pituitary gland
- 75% show loss of posterior pituitary "bright spot"
- Enhances intensely, uniformly
- May have adjacent dural or sphenoid sinus mucosal thickening

TOP DIFFERENTIAL DIAGNOSES

- Macroadenoma
- Pituitary hyperplasia
- Adolescent pituitary gland
- Granulomatous disease
- Pituitary "dwarf"
- Ectopic posterior pituitary gland

CLINICAL ISSUES

- Peripartum woman with headache, multiple endocrine deficiencies
- Middle-aged man with diabetes insipidus (lymphocytic infundibuloneurohypophysitis)
- Mean in women = 35 years, men = 45 years
- M:F = 1:8-9
- Often self-limited
- Unrecognized, untreated LH can result in death from panhypopituitarism
- Conservative care (steroids, hormone replacement)

DIAGNOSTIC CHECKLIST

- LH can mimic pituitary adenoma

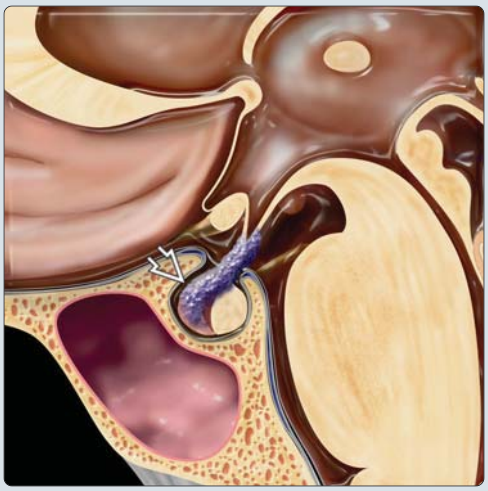

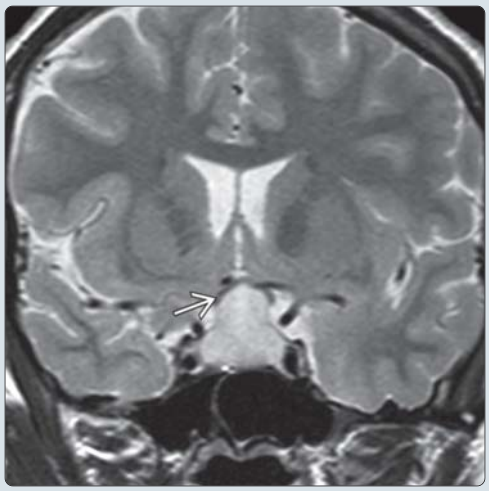

(Left) *Sagittal graphic shows lymphocytic hypophysitis. Note thickening of the infundibulum with loss of the normal "top to bottom" tapering as well as infiltration into the anterior lobe of the pituitary gland* ⇨. **(Right)** *Coronal T2 MR in a pregnant woman with visual changes and endocrine abnormalities shows a hyperintense sellar/suprasellar mass with superior displacement of the optic chiasm* ⇨. *Surgery for optic chiasm decompression disclosed lymphocytic hypophysitis. Imaging mimics pituitary macroadenoma.*

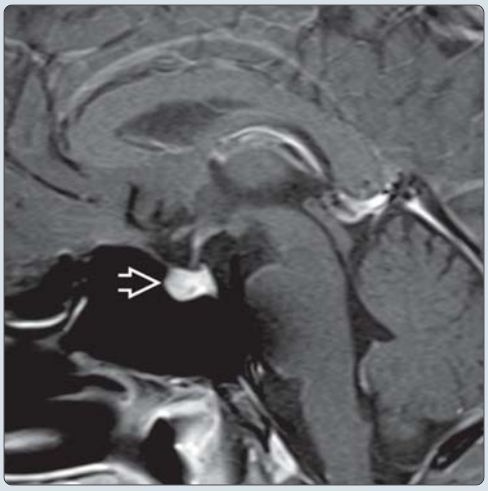

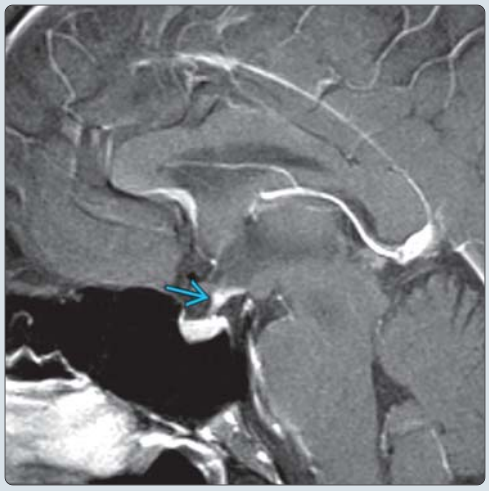

(Left) *Sagittal T1 C+ MR shows a prominent pituitary gland* ⇨ *in a 37-year-old man with panhypopituitarism during treatment with ipilimumab for metastatic melanoma. The gland had doubled in size since MR 6 weeks prior. Findings are consistent with drug-induced hypophysitis* **(Right)** *Sagittal T1 C+ MR in a 50 year old with diabetes insipidus shows focal enlargement of the pituitary infundibulum* ⇨ *related to lymphocytic infundibuloneurohypophysitis.*

https://CafePezeshki.IR

TERMINOLOGY

Abbreviations

- Lymphocytic hypophysitis (LH)

Synonyms

- Adenohypophysitis, primary hypophysitis, stalkitis

Definitions

- Idiopathic inflammation of pituitary gland or stalk

IMAGING

General Features

- Best diagnostic clue
  - Thick nontapered stalk, ± pituitary mass
- Location
  - Suprasellar, intrasellar
- Size
  - Usually < 10 mm but may reach 2-3 cm
- Morphology
  - Rounded pituitary gland with infundibulum that appears thickened, nontapering, or bulbous

MR Findings

- T1WI
  - Thick stalk (> 2 mm + loss of normal tapering)
  - ± enlarged pituitary gland
  - 75% show loss of posterior pituitary "bright spot"
- T2WI
  - Iso-/hypointense
- T1WI C+
  - Enhances intensely, uniformly
  - May see dural or sphenoid sinus mucosal thickening

Imaging Recommendations

- Protocol advice
  - MR: Pre-contrast thin-section (< 3 mm) sagittal, coronal T1WI and T2WI
  - Coronal dynamic T1WI C+ (may show delayed pituitary enhancement)

DIFFERENTIAL DIAGNOSIS

Macroadenoma

- Sellar and suprasellar mass
- Sella turcica enlarged/eroded
- Diabetes insipidus common in LH, rare with adenoma

Pituitary Hyperplasia

- Stalk usually normal
  - In young females, late pregnancy/peripartum
- May be seen with hypothyroidism, Addison disease, end-organ failure, neuroendocrine neoplasms

Adolescent Pituitary

- Enlarged gland with uniform enhancement

Granulomatous Disease

- Sarcoid, Langerhans cell histiocytosis (LCH), granulomatosis with polyangiitis; systemic disease often present

Pituitary "Dwarf"

- Stalk may appear short and stubby

Ectopic Posterior Pituitary

- Hyperintense focus at tuber cinereum or truncated stalk

PATHOLOGY

General Features

- Etiology
  - Autoimmune, inflammatory disorder
  - Other types of hypophysitis include
    - Granulomatous (sarcoid, LCH, infectious, etc.)
    - IgG4-related hypophysitis
    - Drug-related (cancer immunotherapy [e.g., ipilimumab])

Gross Pathologic & Surgical Features

- Diffusely enlarged stalk/pituitary gland

Microscopic Features

- Acute
  - Dense infiltrate of B-/T-lymphocytes, plasma cells, occasionally eosinophils; ± lymphoid follicles
  - No granulomas, giant cells, or organisms; no neoplasm
- Chronic may demonstrate extensive fibrosis

CLINICAL ISSUES

Presentation

- Most common signs/symptoms
  - Headache, visual impairment
- Clinical profile
  - Peripartum woman with headache, multiple endocrine deficiencies
  - Middle-aged man with diabetes insipidus (lymphocytic infundibuloneurohypophysitis)

Demographics

- Age
  - Mean in women = 35 years, men = 45 years
- Gender
  - M:F = 1:8-9
- Epidemiology
  - Rare (1-2% of sellar lesions)

Natural History & Prognosis

- Often self-limited
- Unrecognized, untreated LH can result in death from panhypopituitarism

Treatment

- Conservative (steroids, hormone replacement)

DIAGNOSTIC CHECKLIST

Image Interpretation Pearls

- LH can mimic pituitary adenoma

SELECTED REFERENCES

1. Tauziede-Espariat A et al: The prevalence of IgG4-positive plasma cells in hypophysitis: a possible relationship to IgG4-related disease. Clin Neuropathol. ePub, 2015
2. Chodakiewitz Y et al: Ipilimumab treatment associated pituitary hypophysitis: clinical presentation and imaging diagnosis. Clin Neurol Neurosurg. 125:125-30, 2014
3. Imber BS et al: Hypophysitis: a single-center case series. Pituitary. ePub, 2014

https://CafePezeshki.IR

This page intentionally left blank

https://CafePezeshki.IR

PART II
SECTION 3

CPA–IAC

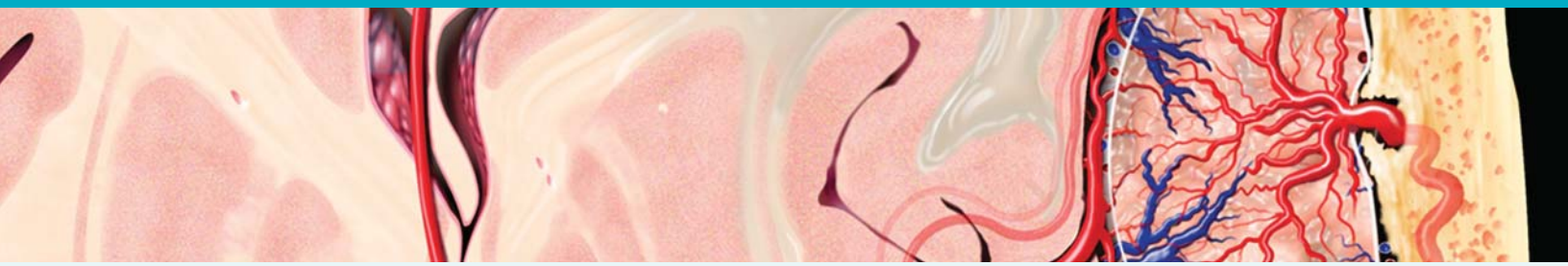

CPA-IAC Overview 1066

Congenital

Lipoma, CPA-IAC 1070
Epidermoid Cyst, CPA-IAC 1074
Arachnoid Cyst, CPA-IAC 1078

Inflammatory

Bell Palsy 1082

Vascular

Trigeminal Neuralgia 1086
Hemifacial Spasm 1088

Neoplasms

Vestibular Schwannoma 1090
Meningioma, CPA-IAC 1094
Metastases, CPA-IAC 1098

https://CafePezeshki.IR

Terminology

The contents of the cerebellopontine angle (CPA) and internal auditory canal (IAC) cisterns include the facial nerve (CN7), the vestibulocochlear nerve (CN8), and the anterior inferior cerebellar artery (AICA) loop. The bony IAC, its fundal crests (vertical and horizontal), and its opening in the porus acusticus are also included as part of this discussion.

Embryology

The temporal bone forms as 3 distinct embryological events: (1) The external and middle ear, (2) the inner ear, and (3) the IAC. The practical implications of these 3 related but separate embryological events is that the presence or absence of the IAC is independent of the development of the inner, middle, or external ear.

The IAC develops in response to formation and migration of the facial and vestibulocochlear nerves through this area. IAC size depends on the number of migrating nerve bundles. The fewer the nerve bundles, the smaller the IAC. If the IAC is very small and only 1 nerve is seen, it is usually the facial nerve.

Imaging Anatomy of Cochlea, IAC, and CPA

The cochlear nerve portion of the vestibulocochlear nerve begins in the modiolus of the cochlea where the bipolar **spiral ganglia** are found. Distally projecting axons reach the organ of Corti within the scala media. Proximally projecting axons coalesce to form the cochlear nerve itself within the fundus of the IAC.

CN8 in the IAC and CPA cisterns is made up of vestibular (balance) and cochlear (hearing) components. The cochlear nerve is located in the anteroinferior quadrant of the IAC. In the region of the porus acusticus, the cochlear nerve joins the superior and inferior vestibular nerve bundles to become the vestibulocochlear nerve in the CPA cistern.

The vestibulocochlear nerve crosses the CPA cistern as the posterior nerve bundle (CN7 is the anterior nerve bundle) to enter the brainstem at the junction of the medulla and pons. The entering cochlear nerve fibers pierce the brainstem and bifurcate to form synapses with both the **dorsal** and the **ventral cochlear nuclei**. These 2 nuclei are found on the lateral surface of the inferior cerebellar peduncle. Their location can be accurately determined by looking at high-resolution T2 axial images and identifying the contour of the inferior cerebellar peduncle. The entering vestibular nerve fibers divide into 4 branches to form synapses with the superior, inferior, medial, and lateral nuclei. The vestibular nuclei are clustered in the inferior cerebellar peduncle just anteromedial to the cochlear nuclei.

Remembering the normal orientation of nerves within the IAC cistern is assisted by the mnemonic "7-up, Coke down." CN7 is found in the anterosuperior quadrant whereas the cochlear nerve is confined to the anteroinferior quadrant. Given this information, it is simple to remember that the superior vestibular nerve (SVN) is posterosuperior while the inferior vestibular nerve (IVN) is posteroinferior.

Other normal structures to be aware of in the IAC include the **horizontal crest** (crista falciformis) and the **vertical crest** ("Bill's bar"). The horizontal crest is a medially projecting horizontal bony shelf in the IAC fundus that separates the CN7 and SVN above from the cochlear nerve and IVN below. The vertical crest is found between CN7 and the SVN along the superior fundal bony wall. The horizontal crest is easily seen on both bone CT and high-resolution MR. The vertical crest is more readily seen on bone CT.

Openings from the IAC fundus into the inner ear are numerous. The largest is the anteroinferior **cochlear nerve canal**, which conveys the cochlear nerve from the modiolus to the IAC fundus. Anterosuperiorly, the **meatal foramen** opens into the labyrinthine segment of CN7. The **macula cribrosa** is the multiply perforated bone that separates the vestibule of the inner ear from the IAC fundus.

Other non-neural normal anatomy of interest in the CPA cistern includes the AICA loop, flocculus, and choroid plexus. The **AICA** arises from the basilar artery, courses superolaterally into the CPA cistern, and then travels into the IAC cistern. Within the IAC, the AICA feeds the internal auditory artery of the cochlea. The AICA loop in the IAC or CPA cisterns may mimic a cranial nerve bundle on high-resolution T2WI MR. AICA vascular territory includes the cochlea, flocculus of the cerebellum, and anterolateral pons in the area of cranial nerve nuclei for CN5, CN7, and CN8. The **flocculus** is a lobule of the cerebellum that projects into the posterolateral CPA cistern. The 4th ventricle **choroid plexus** typically passes through the foramen of Luschka in the CPA cistern.

Imaging Techniques & Indications

The principal clinical indication requiring radiologists to examine the CPA-IAC is **sensorineural hearing loss (SNHL)**. Three principal parameters must be satisfied when completing the MR study in SNHL: (1) Use contrast-enhanced T1 fat-saturated thin-section sequences through the CPA-IAC to identify enhancing lesions in this location, (2) utilize high-resolution T2-weighted sequences to answer presurgical questions when a mass lesion is found, and (3) screen the brain for intraaxial causes, such as multiple sclerosis.

The gold standard for imaging patients with acquired SNHL is enhanced thin-section (≤ 3 mm) axial and coronal fat-saturated MR through the CPA-IAC. With these enhanced sequences, it is highly unlikely that a lesion causing SNHL will be missed. Be sure to obtain an axial or coronal pre-contrast T1 sequence and use fat saturation when contrast is applied to avoid the rare but troublesome mistake of calling a CPA-IAC lipoma a vestibular schwannoma. In the absence of fat saturation, the inherent high signal of lipoma will appear to enhance, leading to the misdiagnosis of vestibular schwannoma.

High-resolution T2-weighted thin-section (≤ 1 mm) MR sequences (CISS, FIESTA, T2 space) in the axial and coronal planes can be used as a screening exam without contrast to identify patients with mass lesions in the CPA-IAC area. However, these sequences are currently more commonly used as supplements when vestibular schwannoma is found on the enhanced T1 sequences to answer specific surgically relevant questions: What size is the fundal cap? What is the nerve of origin? Does the lesion enter the cochlear foramen?

Whenever MR is ordered for SNHL, remember to include whole-brain FLAIR, GRE, and DWI sequences. FLAIR will identify the rare multiple sclerosis patient presenting with SNHL as well as other intraaxial causes. GRE will demonstrate micro- or macrohemorrhage within a vestibular schwannoma and may help with aneurysm diagnosis when blooming of blood products or calcium in an aneurysm wall is seen. When

https://CafePezeshki.IR

CPA Mass Differential Diagnosis

Pseudolesions	**Vascular**
Asymmetric cerebellar flocculus	Aneurysm (vertebrobasilar, PICA, AICA)
Asymmetric choroid plexus	Arteriovenous malformation
High jugular bulb	**Benign tumor**
Jugular bulb diverticulum	Choroid plexus papilloma
Marrow foci around IAC	Facial nerve schwannoma
Congenital	Hemangioblastoma, cerebellum
Arachnoid cyst	IAC hemangioma (venous malformation)
Epidermoid cyst	Meningioma
Lipoma	Vestibular schwannoma
Neurofibromatosis type 2	**Malignant tumor**
Infectious	Brainstem glioma, pedunculated
Cysticercosis	Ependymoma, pedunculated
Meningitis	Melanotic schwannoma
Inflammatory	Metastases, systemic or subarachnoid spread ("drop")
Idiopathic intracranial pseudotumor	
Sarcoidosis	

DWI shows restricted diffusion in a CPA mass, the diagnosis of **epidermoid** is easily made.

Approaches to Imaging Issues of CPA-IAC

Approach to Sensorineural Hearing Loss in an Adult

Unilateral SNHL in an otherwise healthy adult is evaluated with enhanced thin-section fat-saturated T1WI MR of the CPA-IAC area, with high-resolution T2WI sequences providing help in surgical planning if a lesion is identified. Despite audiometric and brainstem-evoked response testing in the otolaryngology clinic, positive MR studies for lesions causing the SNHL are infrequent (< 5% even in highly screened patient groups). **Vestibular schwannoma** is by far the most common cause of unilateral SNHL (about 90% of lesions found with MR). It is important for the radiologist to become familiar with the wide range of appearances of vestibular schwannoma, including intramural cystic change, micro- and macroscopic hemorrhage, and associated arachnoid cyst.

Meningioma, epidermoid cyst, and CPA aneurysm are responsible for about 8% of lesions found in adult patients with SNHL. A long list of rare lesions, including otosclerosis, facial nerve, labyrinthine and jugular foramen schwannomas, IAC hemangioma, CPA metastases, labyrinthitis, sarcoidosis, lipoma, and superficial siderosis, make up < 2% of lesions causing unilateral SNHL in an adult that are found by MR.

Approach to Sensorineural Hearing Loss in a Child

When a child presents with unilateral or bilateral SNHL, the emphasis in the imaging work-up veers away from the typical adult tumor causes. Instead, congenital inner ear or CPA-IAC lesions are sought as the cause of the hearing loss. Complications of suppurative labyrinthitis (labyrinthine ossificans) are also included in the differential diagnosis.

When the child's presentation is bilateral profound SNHL, imaging is usually obtained as part of the work-up for possible **cochlear implantation**. High-resolution T2 MR imaging is obtained in the axial and **oblique sagittal** planes to look for inner ear anomalies and labyrinthine ossificans as well as the presence or absence of a cochlear nerve in the IAC. If complex congenital inner ear disease is found, bone CT is often obtained to further define the inner ear fluid spaces and look for an absent cochlear nerve canal.

In reviewing the MR and CT in a child with SNHL, it is important to accurately describe any inner ear congenital anomaly, if present. If there is a history of meningitis, labyrinthine ossificans may be present. Look for bony encroachment on the fluid spaces of the inner ear. In particular, make sure the basal turn of the cochlea is open because occlusion by bony plaque may thwart successful cochlear implantation. Check the T2 oblique sagittal MR images for the presence of a normal cochlear nerve. If absent, cochlear implantation results may be negatively affected. Finally, look carefully at the IAC and CPA for signs of epidermoid cyst (restricted diffusion on DWI), lipoma (high signal on T1 pre-contrast sequences), and neurofibromatosis type 2 (bilateral CPA-IAC vestibular or facial schwannoma).

Selected References

1. Giesemann AM et al: The vestibulocochlear nerve: aplasia and hypoplasia in combination with inner ear malformations. Eur Radiol. 22(3):519-24, 2012
2. Burmeister HP et al: Identification of the nervus intermedius using 3T MR imaging. AJNR Am J Neuroradiol. 32(3):460-4, 2011
3. Sheth S et al: Appearance of normal cranial nerves on steady-state free precession MR images. Radiographics. 29(4):1045-55, 2009
4. Trimble K et al: Computed tomography and/or magnetic resonance imaging before pediatric cochlear implantation? Developing an investigative strategy. Otol Neurotol. 28(3):317-24, 2007
5. Rabinov JD et al: Virtual cisternoscopy: 3D MRI models of the cerebellopontine angle for lesions related to the cranial nerves. Skull Base. 14(2):93-9; discussion 99, 2004
6. Daniels RL et al: Causes of unilateral sensorineural hearing loss screened by high-resolution fast spin echo magnetic resonance imaging: review of 1,070 consecutive cases. Am J Otol. 21(2):173-80, 2000
7. Schmalbrock P et al: Assessment of internal auditory canal tumors: a comparison of contrast-enhanced T1-weighted and steady-state T2-weighted gradient-echo MR imaging. AJNR Am J Neuroradiol. 20(7):1207-13, 1999
8. Held P et al: MRI of inner ear and facial nerve pathology using 3D MP-RAGE and 3D CISS sequences. Br J Radiol. 70(834):558-66, 1997

https://CafePezeshki.IR

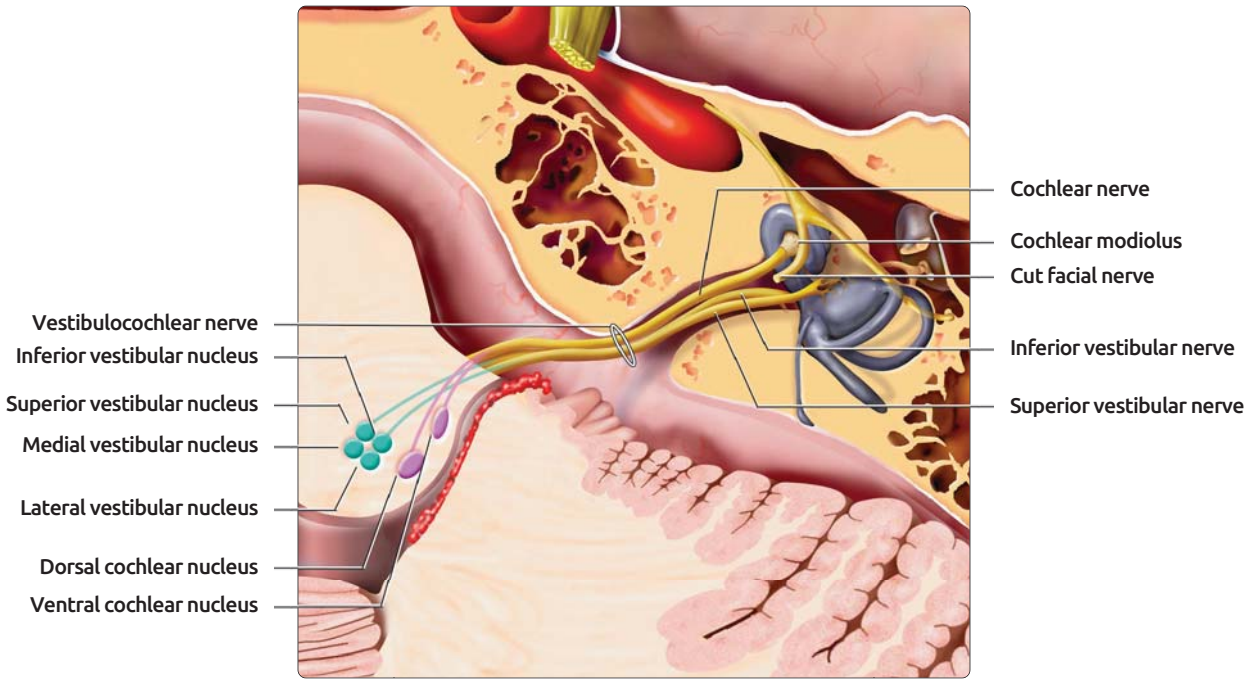

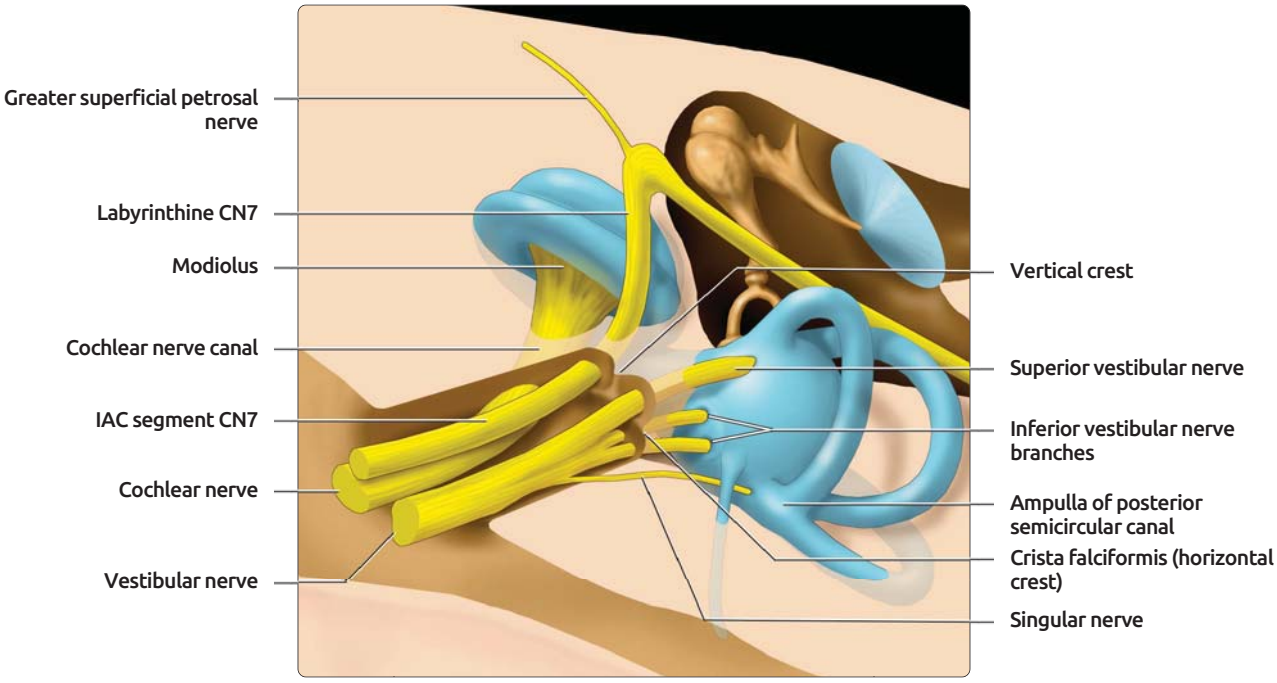

(Top) *Axial graphic depicts the vestibulocochlear nerve (CN8). The cochlear component of CN8 begins in bipolar cell bodies within the spiral ganglion in the modiolus. Central fibers run in the cochlear nerve to the dorsal and ventral cochlear nuclei on the lateral margin of the inferior cerebellar peduncle. Inferior and superior vestibular nerves begin in cell bodies in the vestibular ganglion; from there, they course centrally to 4 vestibular nuclei.* **(Bottom)** *Graphic shows the normal facial nerve and vestibulocochlear nerve in the internal auditory canal (IAC) and temporal bone. Notice that by the mid-IAC, there are 4 main nerves present, including the facial, cochlear, superior vestibular, and inferior vestibular nerves. The singular nerve branches off the inferior vestibular nerve midway through the IAC on its way to the ampulla of the posterior semicircular canal. Multiple inferior vestibular nerve branches pierce the macular cribrosa, as does the superior vestibular nerve, on their way to the vestibule.*

https://CafePezeshki.IR

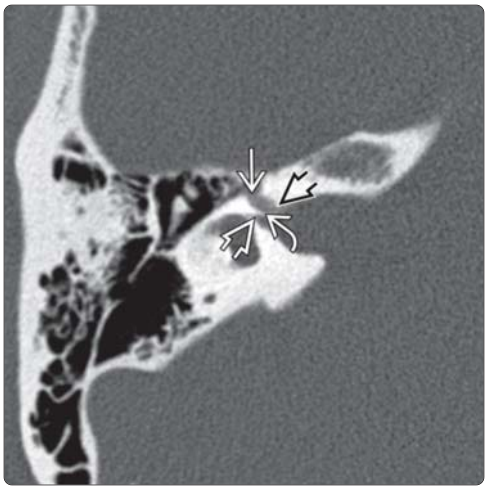

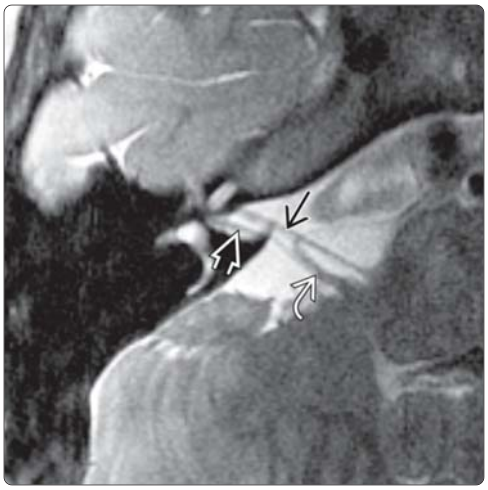

(Left) *Axial bone CT through the superior IAC reveals the labyrinthine segment of CN7 ➡, the meatal foramen ⇨, the vertical crest ➡, and the superior vestibular nerve ➡ connecting the IAC to the vestibule through the macula cribrosa.* **(Right)** *Axial T2WI MR through the superior IAC shows the anterosuperior CN7 ⇨, the superior vestibular nerve ➡, and the vestibulocochlear nerve ➡.*

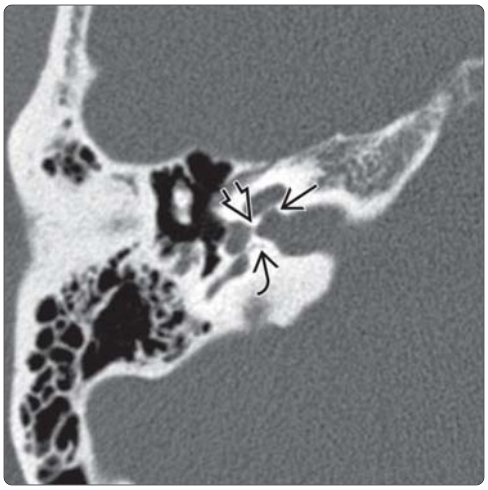

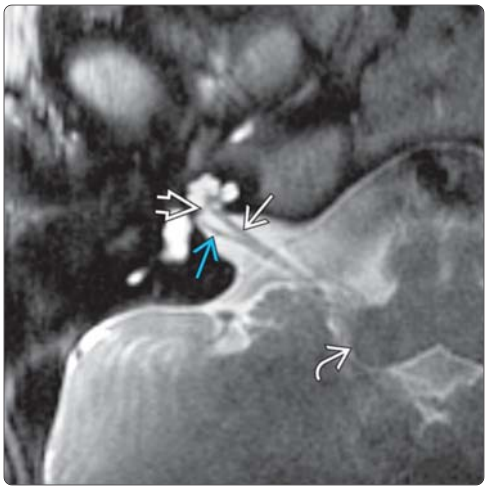

(Left) *Axial bone CT through the mid IAC shows the cochlear nerve canal ⇨, inferior vestibular nerve leaving the fundus ⇨, and singular nerve canal containing the posterior branch of the inferior vestibular nerve ➡.* **(Right)** *Axial T2WI MR through the inferior IAC reveals the cochlear nerve ➡ projecting into the cochlear nerve canal ➡. Dorsal and ventral cochlear nuclei are not seen but are known to reside in the lateral inferior cerebellar peduncle margin ➡. Note the inferior vestibular nerve ⇨.*

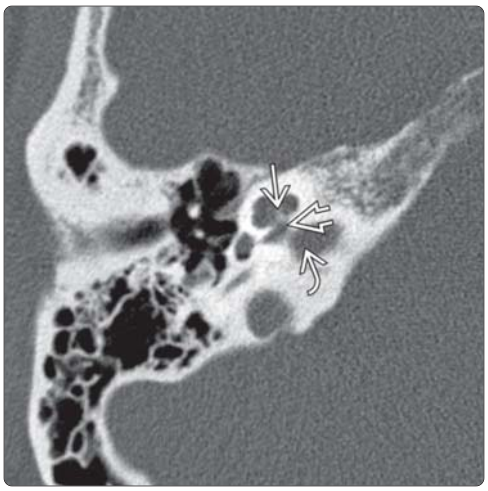

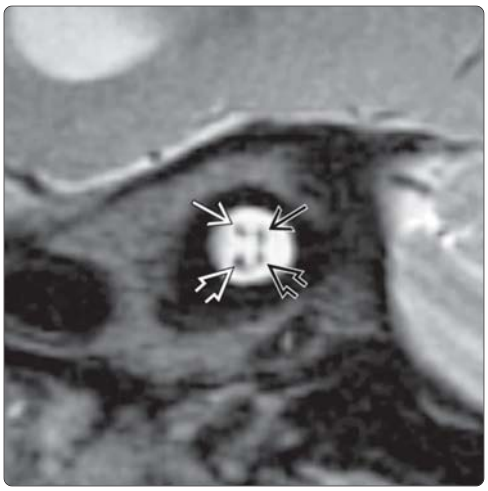

(Left) *Axial bone CT through the inferior IAC demonstrates the cochlear modiolus as a high-density structure at the cochlear base ➡. The cochlear nerve canal ➡ and the fundus of the IAC ➡ are also labeled.* **(Right)** *Oblique sagittal T2WI MR shows the 4 nerve bundles of the mid IAC cistern. CN7 is anterosuperior ➡, the cochlear nerve is anteroinferior ➡, and the superior ⇨ and inferior ⇨ vestibular nerves are posterosuperior and posteroinferior, respectively.*

https://CafePezeshki.IR

KEY FACTS

TERMINOLOGY

- Lipoma in CPA-IAC: Nonneoplastic mass of adipose tissue in CPA-IAC area

IMAGING

- Focal benign-appearing CPA-IAC mass, which follows fat density (CT) and intensity (MR)
- Concurrent intralabyrinthine deposit may be seen in association with CPA-IAC lipoma
- MR: Hyperintense CPA mass (parallels subcutaneous and marrow fat intensity)
  - Becomes **hypointense** with **fat saturation**
  - Caveat: Fat-saturated MR sequences avoid mistaking lipoma for enhancing CPA mass

TOP DIFFERENTIAL DIAGNOSES

- Hemorrhagic vestibular schwannoma
- Aneurysm in CPA-IAC
- Neurenteric cyst
- Ruptured dermoid cyst

PATHOLOGY

- Aberrant differentiation of embryonic meninx primitiva (meningeal precursor tissue)
- Lipoma composed of mature lipocytes (fat cells)

CLINICAL ISSUES

- Most common presentation: Adult presenting with unilateral sensorineural hearing loss
  - CN8 compression: Tinnitus (40%), vertigo (45%)
  - Compression of CN5 root entry zone: Trigeminal neuralgia (15%)
  - Compression of CN7 root exit zone: Hemifacial spasm, facial nerve weakness (10%)
  - Incidentally seen on brain CT or MR completed for unrelated reasons (33%)
- Treatment: **No treatment** is best treatment
  - If surgery required (cranial neuropathy), subtotal resection (debulking) only recommended

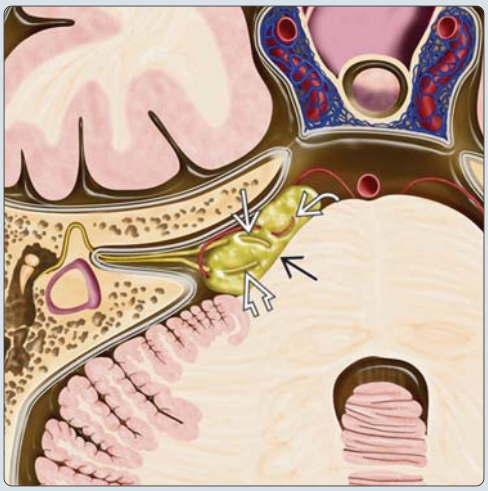

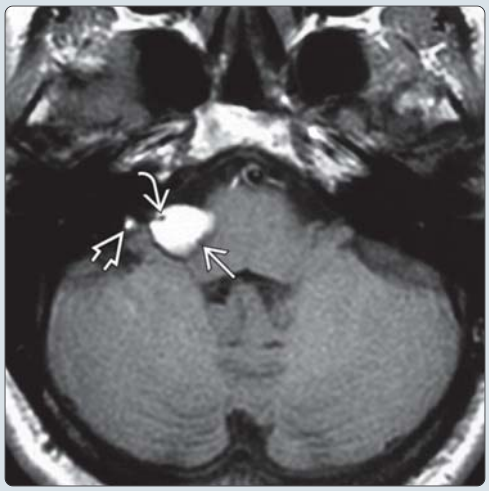

(Left) *Axial graphic demonstrates a CPA lipoma ⇨ abutting the lateral pons. Notice that the facial nerve ⇨, vestibulocochlear nerve ⇨, and AICA loop ⇨ all pass through the lipoma on their way to the internal auditory canal.* **(Right)** *Axial T1WI MR shows a right CPA lipoma ⇨ adherent to the lateral pontine pial surface. Note the 2nd smaller lipoma ⇨ along the lateral margin of the internal auditory canal. A portion of the AICA loop ⇨ passes through the anterolateral lipoma.*

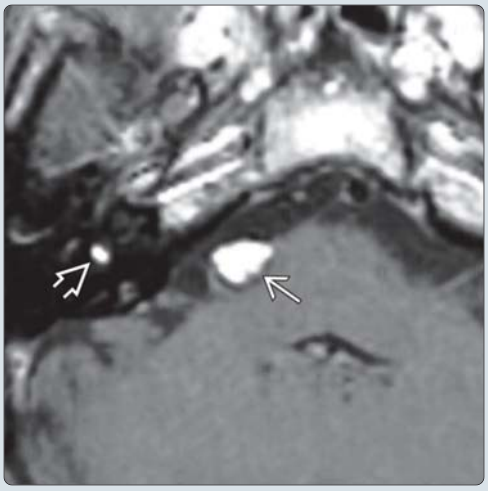

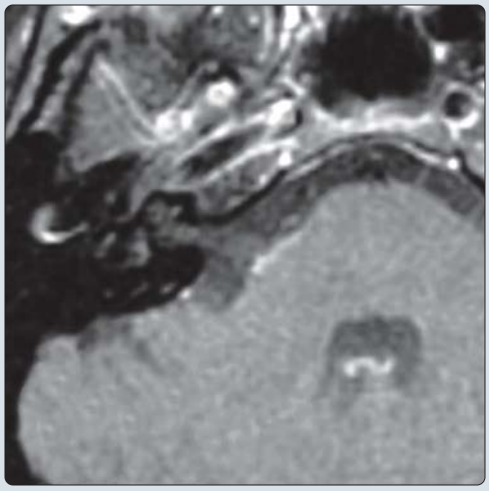

(Left) *Axial T1WI MR reveals a hyperintense CPA lipoma ⇨ abutting the lateral pons. Note the 2nd ⇨ focus of hyperintensity representing a small intravestibular lipoma. Such intralabyrinthine lipomas are very rare and may exist with or without CPA lipoma.* **(Right)** *Axial T1WI C+ FS MR in the same patient shows both lesions have disappeared. Fat-saturation MR sequences are key to confirming the diagnosis of lipoma and to avoid mistaking a lipoma for an enhancing CPA mass.*

https://CafePezeshki.IR

TERMINOLOGY

Synonyms

- Congenital lipoma, lipomatous hamartoma

Definitions

- Lipoma in CPA-IAC: **Nonneoplastic** mass of adipose tissue in CPA-IAC area
  - Congenital malformation; not true neoplasm

IMAGING

General Features

- Best diagnostic clue
  - Focal benign-appearing CPA-IAC mass, which follows fat density (CT) and intensity (MR)
- Location
  - 20% of intracranial lipomas are infratentorial
  - Primary location = CPA cistern
    - May be in IAC only
    - Concurrent **intralabyrinthine lipoma** may be present
      - Isolated intralabyrinthine lipoma also possible
- Size
  - Range: 0.5-5 cm in maximum diameter
    - May be as small as a few millimeters
- Morphology
  - Lobulated pial-based fatty mass
    - Characteristically encases facial nerve (CN7), vestibulocochlear nerve (CN8), anterior inferior cerebellar artery (AICA) loop
  - Small lesions
    - Linear along course of CN7 and CN8 in CPA
    - Ovoid within CPA cistern; tubular within IAC
  - Large lesions
    - Broad-based hemispherical shape adherent to lateral pontine pial surface

CT Findings

- NECT
  - **Low-density** CPA-IAC mass
  - Measure mass using Hounsfield units (HU) if uncertain
    - Hounsfield unit range: **-50 to -100 HU**
  - IAC lipoma may create bulbous bone CT appearance
- CECT
  - Lesion does **not** enhance

MR Findings

- T1WI
  - **Hyperintense** CPA-IAC mass (parallels subcutaneous and marrow fat intensity)
    - Noncontiguous 2nd fatty lesion in inner ear may be present
  - Becomes **hypointense** with fat-saturation MR sequences
- T2WI
  - Intermediate "fat intensity" lesion
  - Conspicuous **chemical shift artifact** (frequency-encoding direction)
  - Signal parallels subcutaneous and marrow fat
- STIR
  - Hypointense due to STIR inherent fat suppression
- FLAIR
  - Hyperintense compared to cisternal CSF
- T1WI C+
  - Lesion already hyperintense on pre-contrast images
  - Use fat-saturated T1WI C+ sequence
    - Lesion **"disappears"** secondary to **fat saturation** aspect of this MR sequence
    - No enhancement in region of lesion is present

Imaging Recommendations

- Best imaging tool
  - **MR** is 1st study ordered when symptoms suggest possibility of CPA-IAC mass
  - CT can easily confirm diagnoses by measuring HU if some confusion on MR images persists
- Protocol advice
  - When T1WI C+ MR focused to CPA area is anticipated, need at least 1 **pre-contrast T1 sequence**
    - Helps distinguish fatty and hemorrhagic lesions from enhancing lesions
    - Fatty lesions include lipoma and dermoid
    - Hemorrhagic lesions with methemoglobin high signal include aneurysm and venous varix
  - Once high signal is seen on pre-contrast T1 sequence, **fat-saturated sequences** distinguish fat from hemorrhage
    - **Caveat**: Fat saturation avoids mistaking lipoma for enhancing CPA mass (vestibular schwannoma)

DIFFERENTIAL DIAGNOSIS

Hemorrhagic Vestibular Schwannoma

- Rare manifestation of common lesion
- Patchy intraparenchymal hyperintensity on T1WI MR
- Hyperintensities persist with fat-saturated sequences
- T2* GRE shows "blooming" of intralesional hemorrhage

Aneurysm in CPA-IAC

- CPA aneurysm may have complex signal
  - PICA aneurysm most common > VA > AICA
- Rarely enters IAC (AICA)
- Ovoid CPA mass with calcified rim (CT) and complex layered signal (MR)
- MR signal complex with high signal areas from methemoglobin in aneurysm lumen or wall
  - Does not fat saturate

Neurenteric Cyst

- Most common in prepontine cistern
- Contains proteinaceous fluid (hyperintense on T1WI MR)
- Does not fat saturate

Ruptured Dermoid Cyst

- Ectodermal inclusion cyst
- Original location usually midline
- Rupture spreads fat droplets into subarachnoid space
- Rupture may lead to chemical meningitis

PATHOLOGY

General Features

- Etiology
  - Best hypotheses for congenital lipoma

https://CafePezeshki.IR

  - Aberrant differentiation of meninx primitiva (neural crest derived mesenchymal anlage)
    - Responsible for development of pia, arachnoid, dura, and subarachnoid cisterns
    - Maldifferentiates into fat instead
  - Hyperplasia of fat cells normally **within pia**
- Genetics
  - No known defects in sporadic CPA lipoma
  - Epidermal nevus syndrome has CPA lipomas as part of complex congenital anomalies
- Associated abnormalities
  - 2nd fatty lesion may occur in inner ear

Gross Pathologic & Surgical Features

- Soft, yellowish mass attached to leptomeninges
  - Sometimes adherent to lateral pontine pia
- May incorporate CN7 and CN8 with dense adhesions
  - AICA loop may also be engulfed

Microscopic Features

- Histologically normal lipocytes in atypical location
- Highly vascularized adipose tissue
- Mature lipocytes; mitoses rare

CLINICAL ISSUES

Presentation

- Most common signs/symptoms
  - Unilateral sensorineural hearing loss (60%)
- Clinical profile
  - Adult presenting with slowly progressive unilateral sensorineural hearing loss
- Other signs/symptoms
  - Incidentally on brain CT or MR (33%)
  - Cerebellopontine angle lipoma symptoms
    - CN8 compression: Sensorineural hearing loss (60%), tinnitus (40%), vertigo (40%)
    - Compression of CN5 root entry zone: **Trigeminal neuralgia** (15%)
    - Compression of CN7 root exit zone: **Hemifacial spasm**, facial nerve weakness (10%)
  - Internal auditory canal lipoma symptoms
    - SNHL, tinnitus, and vertigo only

Demographics

- Age
  - Range at presentation: 8-60 years
  - Mean at presentation: 45 years
- Epidemiology
  - Lipomas occur less frequently in CPA than epidermoid and arachnoid cysts
    - Epidermoid cyst > arachnoid cyst > > lipoma
  - CPA lipoma represents 10% of all intracranial lipomas
    - Interhemispheric (45%), quadrigeminal/superior cerebellar (25%), suprasellar/interpeduncular (15%), sylvian cisterns (5%)

Natural History & Prognosis

- Usually does not grow over time
  - Lesion consists of mature lipocytes
  - Growth has been seen in pediatric lesions
  - Growth reported in obese or steroid treated patients
- Stability confirmed with follow-up examinations

Treatment

- Primum non nocere ("first, do no harm") is guiding principle
  - **No treatment** is best treatment
- Conservative therapy recommendations
  - Medical therapy: Trigeminal neuralgia, hemifacial spasm
  - Discontinue steroid treatment if present; weight loss
- **Surgical removal** is **no longer recommended**
  - Injury to CN7, CN8, or AICA common
  - Historically, 70% of postoperative patients had new postoperative deficits
- Surgical intervention if CN5 or CN7 decompression needed
  - Subtotal removal (debulking) only recommended

DIAGNOSTIC CHECKLIST

Consider

- When high signal lesion is seen in CPA-IAC on T1WI unenhanced MR, 3 explanations to consider
  - Fatty lesion
    - Lipoma most common (will fat saturate)
  - Hemorrhagic lesion
    - Aneurysm wall clot or clotted venous varix (dural AVF)
    - Rare hemorrhagic acoustic schwannoma
    - Hemorrhage will not fat saturate
  - Highly proteinaceous fluid
    - Neurenteric cyst (usually in prepontine cistern)
    - High protein hyperintensity will not fat saturate

Image Interpretation Pearls

- Once high signal lesion is seen in CPA on pre-contrast T1WI MR, use **fat-saturation** sequences to confirm diagnosis

Reporting Tips

- Report size and extent of lipoma
  - Check inner ear for 2nd lesion
- Report CN7, CN8, and AICA loop engulfed by lipoma

SELECTED REFERENCES

1. Bacciu A et al: Lipomas of the internal auditory canal and cerebellopontine angle. Ann Otol Rhinol Laryngol. 123(1):58-64, 2014
2. White JR et al: Lipomas of the cerebellopontine angle and internal auditory canal: Primum Non Nocere. Laryngoscope. 123(6):1531-6, 2013
3. Mukherjee P et al: Intracranial lipomas affecting the cerebellopontine angle and internal auditory canal: a case series. Otol Neurotol. 32(4):670-5, 2011
4. Sade B et al: Cerebellopontine angle lipoma presenting with hemifacial spasm: case report and review of the literature. J Otolaryngol. 34(4):270-3, 2005
5. Dahlen RT et al: CT and MR imaging characteristics of intravestibular lipoma. AJNR Am J Neuroradiol. 23(8):1413-7, 2002
6. Kato T et al: Trigeminal neuralgia caused by a cerebellopontine-angle lipoma: case report. Surg Neurol. 44(1):33-5, 1995

https://CafePezeshki.IR

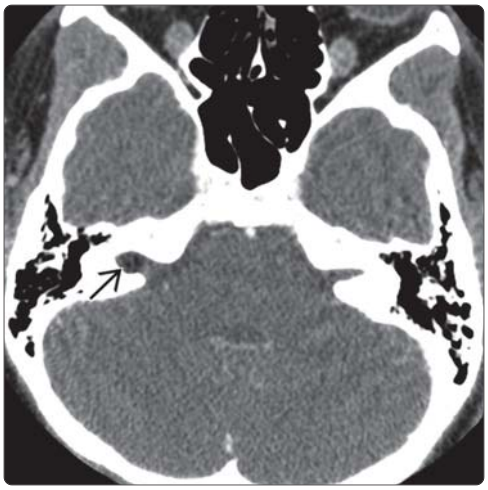

(Left) *Axial CECT reveals a fat-density lesion ⇨ in the fundus of the right internal auditory canal. The bone shape in this area is bulbous in comparison to the opposite normal IAC suggesting a congenital origin of the lesion.* **(Right)** *Axial T1WI MR in the same patient shows the expected hyperintense fundal intracanalicular congenital lipoma ⇨. Lipoma of the CPA-IAC area may be found in the CPA, IAC, and, rarely, in the inner ear.*

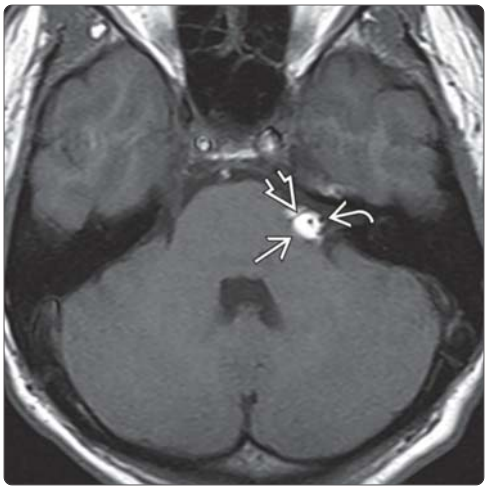

(Left) *Axial T2WI FS MR in the same patient shows the lipoma in the IAC fundus as a low signal filling defect ⇨ in the high signal surrounding CSF.* **(Right)** *Axial T1WI MR in a 30-year-old patient with sensorineural hearing loss and trigeminal neuralgia shows a hyperintense CPA lipoma abutting the lateral pons ⇨. The linear hypointense line ⇨ is the proximal facial nerve (CN7) while the hypointense dots within the lateral aspect of the lipoma ⇨ are anterior inferior cerebellar artery (AICA) loops.*

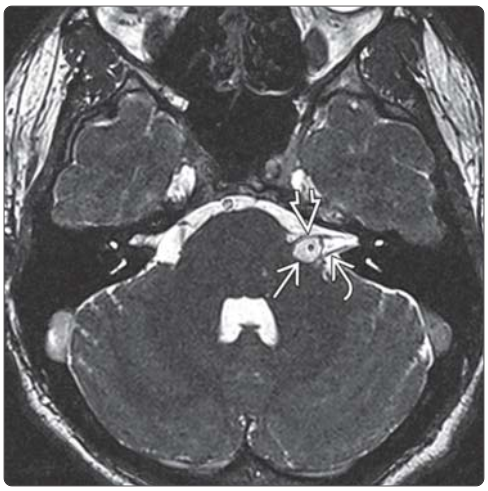

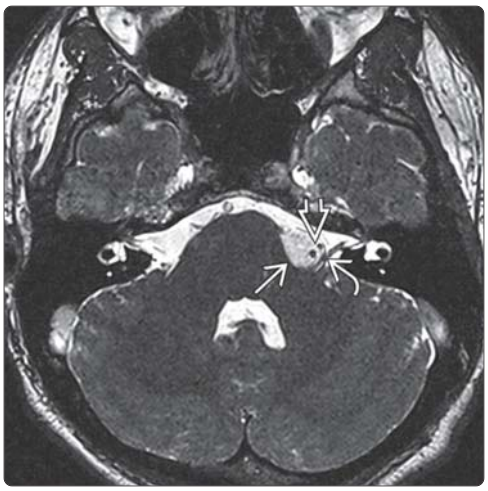

(Left) *Axial CISS MR in the same patient better demonstrates the lipoma adherent to the lateral pons ⇨. Note the lesion engulfs the proximal CN7 ⇨ and superior vestibular CN8 ⇨. The AICA loop is the hypointense dot in the center of the lipoma.* **(Right)** *Axial CISS MR in the same patient slightly inferior to the previous image shows the lipoma ⇨ surrounding the AICA loops ⇨ and superior vestibular branch of the CN8 ⇨. The possibility of CN7 and CN8 injury and AICA stroke preclude surgery in this patient.*

https://CafePezeshki.IR

KEY FACTS

TERMINOLOGY

- Definition: Congenital inclusion of ectodermal epithelial elements during neural tube closure

IMAGING

- CPA cisternal **insinuating** mass with high signal on DWI MR
  - 90% intradural, 10% extradural
  - Margins usually scalloped or irregular
  - Cauliflower-like margins with "fronds" possible
- TI and T2: Isointense or slightly hyperintense to CSF
- DWI: **Restricted diffusion** makes diagnosis

TOP DIFFERENTIAL DIAGNOSES

- Arachnoid cyst in CPA
- Cystic neoplasm in CPA
  - Cystic vestibular schwannoma
  - Cystic meningioma
  - Infratentorial ependymoma
  - Pilocytic astrocytoma
- Neurenteric cyst
- Neurocysticercosis, CPA

PATHOLOGY

- Surgical appearance: Pearly white CPA cistern mass
- Cyst wall: Internal layer of stratified squamous epithelium covered by fibrous capsule

CLINICAL ISSUES

- Clinical presentation
  - Principal presenting symptom: Dizziness and headache
    - Sensorineural hearing loss also common
  - If extends to lateral pons: Trigeminal neuralgia
  - Rarer symptoms: Facial palsy, seizure
- Treatment: Complete surgical removal is goal
  - If adherent to neural structures, complete removal may not be possible
  - If recurs, takes many years to grow
  - DWI MR key to diagnosing recurrence

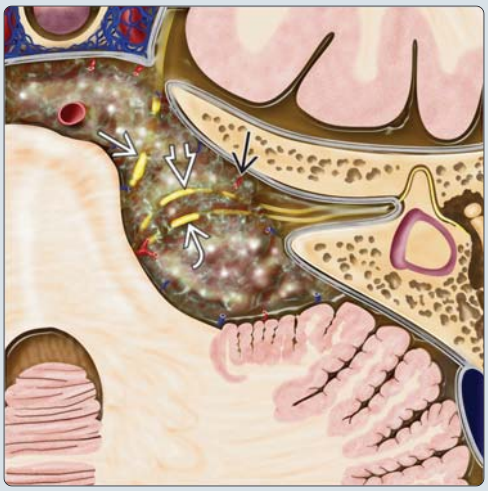

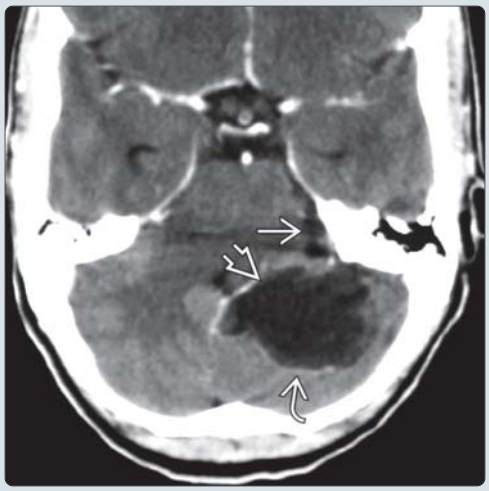

(Left) *Axial graphic shows a large CPA epidermoid cyst within a typical "bed of pearls" appearance. Note that the 5th ➡, 7th ➡, and 8th ➡ cranial nerves along with the AICA loop ⇨ are characteristically engulfed by this insinuating mass.* **(Right)** *Axial CECT shows a large CPA epidermoid cyst ➡. Note that this nonenhancing low-density lesion appears to invade the left cerebellar hemisphere ➡. Minimal rim enhancement is visible along the posterior margin of the cyst ➡.*

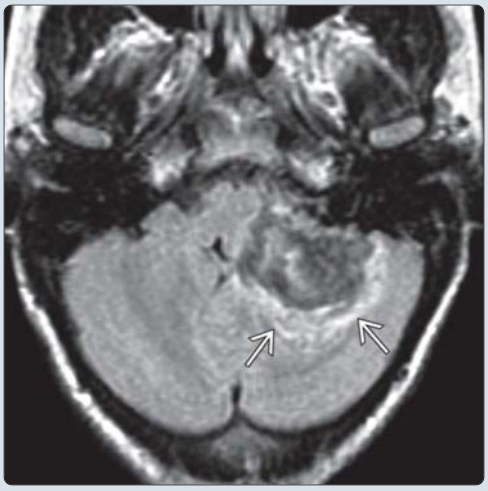

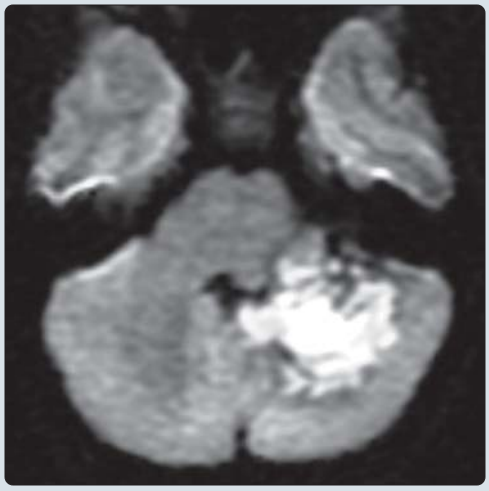

(Left) *Axial FLAIR MR of the same patient shows "incomplete" or partial nulling of the signal of this large epidermoid cyst. Associated high signal ➡ along the deep margins of the lesion is most likely due to gliosis of the cerebellar hemisphere.* **(Right)** *Axial DWI MR in the same patient reveals the expected high signal from epidermoid cyst diffusion restriction. DWI sequence allows straightforward differentiation of this epidermoid cyst from an arachnoid cyst.*

https://CafePezeshki.IR

TERMINOLOGY

Synonyms

- Epidermoid tumor, primary cholesteatoma, or epithelial inclusion cyst

Definitions

- Congenital **inclusion** of ectodermal epithelial elements during neural tube closure

IMAGING

General Features

- Best diagnostic clue
  - CPA cistern **insinuating** mass with high signal on DWI MR
    - Engulfs cranial nerves (7th and 8th) and anterior inferior cerebellar artery (AICA) loop
- Location
  - 90% intradural,10% extradural
    - Posterior fossa location most common
      - CPA ~ 40%; 4th ventricle ~ 20%
- Size
  - Wide range: 1-8 cm or more in diameter
- Morphology
  - Insinuating mass in cisterns
  - Margins usually scalloped or irregular
    - Cauliflower-like margins with "fronds" possible
  - When large, compresses or invades brainstem ± cerebellum

CT Findings

- NECT
  - Similar density to cerebrospinal fluid (CSF)
  - Calcification in 20%, usually margins
  - Pressure erosion of T-bone and skull base may occur
  - Rare variant: "Dense epidermoid"
    - 3% of intracranial epidermoids
    - From protein, cyst debris saponification to calcium soaps or iron-containing pigment
- CECT
  - No enhancement is rule
    - Sometimes margin of cyst minimally enhances

MR Findings

- T1WI
  - Isointense or slightly hyperintense to CSF
  - If hyperintense, term "dirty CSF" has been applied
  - Rare variant: "White epidermoid" with high T1 compared to brain
    - Secondary to high triglycerides and unsaturated fatty acids
    - Caveat: If lesion in prepontine cistern, consider neuroepithelial cyst diagnosis
  - Epidermoid with hemorrhage
    - Mixed low and high signal areas
    - High signal secondary to methemoglobin
- T2WI
  - Isointense to hyperintense to CSF
  - "White epidermoid": Low T2 signal
- FLAIR
  - Does not null (attenuate) like CSF or arachnoid cyst
- DWI
  - **Restricted diffusion** on DWI or DTI **makes diagnosis**
    - Secondary to high fractional anisotropy from diffusion along 2D geometric plane
      - Due to microstructure of parallel-layered keratin filaments and flakes
  - Apparent diffusion coefficient (ADC) = low signal
  - High signal foci on DWI trace images in surgical bed indicates recurrence
- T1WI C+
  - No enhancement is rule
  - Subtle marginal enhancement may occur (25%)
- MRA
  - Vessels of CPA may be displaced or engulfed
  - Artery wall dimension not affected
- MRS
  - Resonances from lactate
  - No NAA, choline, or lipid

Imaging Recommendations

- Best imaging tool
  - Brain MR with FLAIR, DWI, and T1WI C+ sequences
- Protocol advice
  - DWI sequences make diagnosis
  - If looking for recurrence, DWI (DTI) is best sequence

DIFFERENTIAL DIAGNOSIS

Arachnoid Cyst in CPA

- Displaces, does not engulf, adjacent structures
- Isointense to CSF on all standard MR sequences
  - T2 higher signal possible; if no CSF pulsations
- Completely nulls on FLAIR (low signal)
- Hypointense (no restricted diffusion) on DWI trace MR
  - Contains highly mobile CSF
  - ADC = stationary water

Cystic Neoplasm in CPA

- Cystic vestibular schwannoma
- Cystic meningioma in CPA
- Infratentorial ependymoma
  - Pedunculates from 4th ventricle
- Pilocytic astrocytoma
  - Pedunculates from cerebellum
- All show some areas of enhancement on T1WI C+ MR

Neurenteric Cyst

- Most common prepontine cistern in location
- T1 high signal (might mimic "white epidermoid")
- T2 signal often low

Neurocysticercosis in CPA

- Partially enhances
- Density/signal intensity does not precisely follow CSF
- Adjacent brain edema or gliosis common

PATHOLOGY

General Features

- Etiology
  - Congenital **inclusion of ectodermal elements** during neural tube closure

https://CafePezeshki.IR

  - 3rd to 5th week of embryogenesis
  - CPA lesion derived from 1st branchial groove cells

Gross Pathologic & Surgical Features

- **Pearly white mass** in CPA
- Surgeons refer to it as the "beautiful tumor"
- Lobulated, cauliflower-shaped surface features
- Insinuating growth pattern in cisterns
  - Engulfs cisternal vessels and nerves
    - May become adherent
- Lesion filled with soft, waxy, creamy, or flaky material

Microscopic Features

- Cyst wall: Internal layer of stratified squamous epithelium covered by fibrous capsule
- Cyst contents: Solid crystalline cholesterol, keratinaceous debris
  - **No** dermal appendages (hair follicles, sebaceous glands, or fat)
  - If any of these present, consider dermoid
- Grows in successive layers by desquamation of squamous epithelium from cyst wall
  - Conversion to keratin/cholesterol crystals forms concentric lamellae

CLINICAL ISSUES

Presentation

- Most common signs/symptoms
  - Principal presenting symptoms: Dizziness
  - Other symptoms depend on location, growth pattern
    - Sensorineural hearing loss: Common symptom
    - Trigeminal neuralgia (tic douloureux): If extends to lateral pontine CN5 root entry zone
    - Seizures: If extends superiorly through incisura to temporomesial location
  - Symptoms usually present for > 4 years before diagnosis
- Clinical profile
  - 40-year-old patient with minor symptoms and large lesion discovered in CPA on MR
  - Asymptomatic patient shows incidental hyperintense lesion in CPA on DWI MR sequence

Demographics

- Age
  - Although congenital, presents in adult life
  - Broad presentation: 20-60 years
    - Peak age: 40 years
- Epidemiology
  - 3rd most common CPA mass
  - 1% of all intracranial tumors

Natural History & Prognosis

- Slow-growing congenital lesions that remain clinically silent for many years
- Smaller cisternal lesions are readily cured with surgery
- Larger lesions with upward supratentorial herniation are more difficult to completely remove
  - Larger lesions have more significant surgical complications

Treatment

- Complete surgical removal is goal
  - If large, near-total removal is prudent surgical choice
    - Aggressive total removal may cause significant cranial neuropathy
    - Used when capsule is adherent to brainstem and cranial nerves
- If recurs, takes many years to grow
  - DWI MR key to diagnosing recurrence

DIAGNOSTIC CHECKLIST

Consider

- MR diagnosis based on
  - Insinuating CPA lesion
  - Low signal on T1, high on T2 (similar but not identical to CSF)
  - No or partial nulling on FLAIR
  - Hyperintense on DWI trace images

Image Interpretation Pearls

- **Diffusion MR** imaging sequence is **key to correct diagnosis**

Reporting Tips

- Be sure to report prepontine or medial middle cranial fossa extension if present

SELECTED REFERENCES

1. Gopalakrishnan CV et al: Long term outcome in surgically treated posterior fossa epidermoids. Clin Neurol Neurosurg. 117:93-9, 2014
2. Schiefer TK et al: Epidermoids of the cerebellopontine angle: a 20-year experience. Surg Neurol. 70(6):584-90; discussion 590, 2008
3. Bonneville F et al: Imaging of cerebellopontine angle lesions: an update. Part 2: intra-axial lesions, skull base lesions that may invade the CPA region, and non-enhancing extra-axial lesions. Eur Radiol. 17(11):2908-20, 2007
4. Dutt SN et al: Radiologic differentiation of intracranial epidermoids from arachnoid cysts. Otol Neurotol. 23(1):84-92, 2002
5. Kobata H et al: Cerebellopontine angle epidermoids presenting with cranial nerve hyperactive dysfunction: pathogenesis and long-term surgical results in 30 patients. Neurosurgery. 50(2):276-85; discussion 285-6, 2002
6. Dechambre S et al: Diffusion-weighted MRI postoperative assessment of an epidermoid tumour in the cerebellopontine angle. Neuroradiology. 41(11):829-31, 1999
7. Ochi M et al: Unusual CT and MR appearance of an epidermoid tumor of the cerebellopontine angle. AJNR Am J Neuroradiol. 19(6):1113-5, 1998
8. Talacchi A et al: Assessment and surgical management of posterior fossa epidermoid tumors: report of 28 cases. Neurosurgery. 42(2):242-51; discussion 251-2, 1998
9. Timmer FA et al: Chemical analysis of an epidermoid cyst with unusual CT and MR characteristics. AJNR Am J Neuroradiol. 19(6):1111-2, 1998
10. Ikushima I et al: MR of epidermoids with a variety of pulse sequences. AJNR Am J Neuroradiol. 18(7):1359-63, 1997
11. Kallmes DF et al: Typical and atypical MR imaging features of intracranial epidermoid tumors. AJR Am J Roentgenol. 169(3):883-7, 1997
12. Tien RD et al: Variable bandwidth steady-state free-precession MR imaging: a technique for improving characterization of epidermoid tumor and arachnoid cyst. AJR Am J Roentgenol. 164(3):689-92, 1995
13. Gao PY et al: Radiologic-pathologic correlation. Epidermoid tumor of the cerebellopontine angle. AJNR Am J Neuroradiol. 13(3):863-72, 1992
14. Tsuruda JS et al: Diffusion-weighted MR imaging of the brain: value of differentiating between extraaxial cysts and epidermoid tumors. AJNR Am J Neuroradiol. 11(5):925-31; discussion 932-4, 1990
15. Tampieri D et al: MR imaging of epidermoid cysts. AJNR Am J Neuroradiol. 10(2):351-6, 1989

https://CafePezeshki.IR

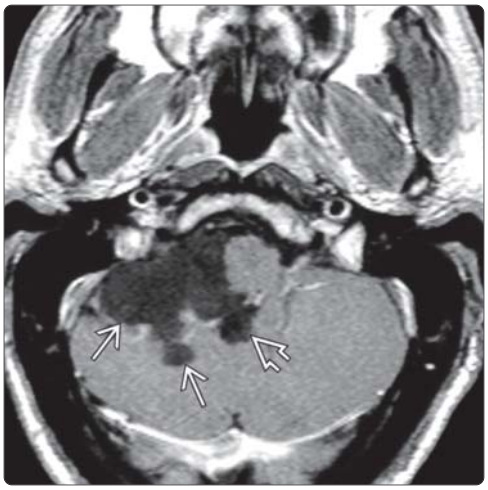

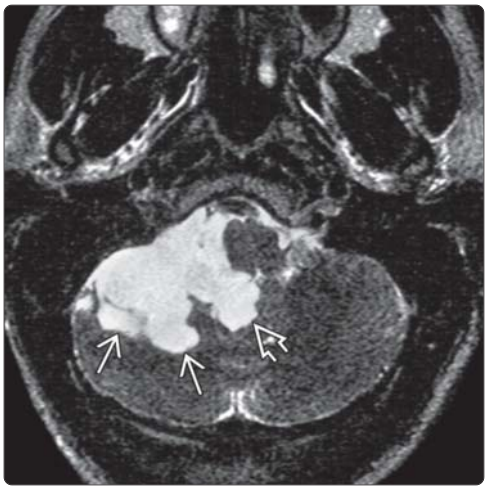

(Left) *Axial T1WI C+ MR demonstrates a large, insinuating, right CPA cistern epidermoid cyst ➡. Note the low signal with lack of enhancement of the lesion. The cyst insinuates into the cerebellar hemisphere and foramen of Luschka ➡.* **(Right)** *Axial T2WI MR in the same patient reveals a large, insinuating epidermoid cyst with typical high T2 signal and invagination into the cerebellar hemisphere ➡ and foramen of Luschka ➡.*

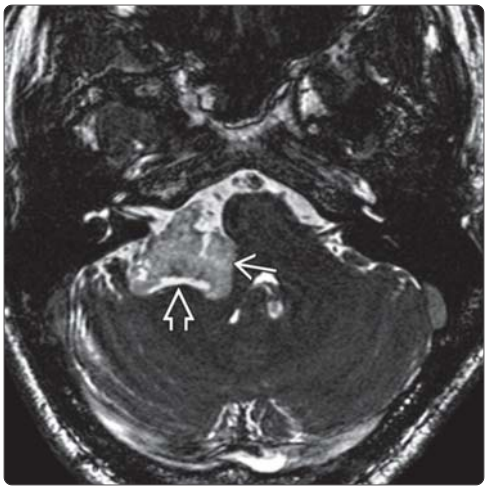

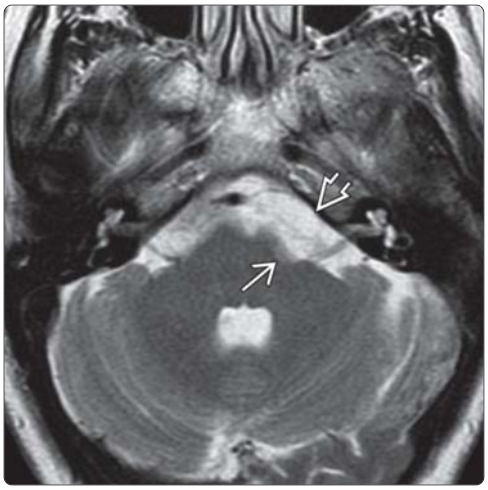

(Left) *Axial T2 FS thin-section high-resolution MR shows a right CPA epidermoid cyst. Note the cauliflower-like surface architecture. This lesion is compressing the brachium pontis ➡ and adjacent cerebellar hemisphere ➡.* **(Right)** *Axial T2WI MR shows slight widening of the left CPA cistern ➡ with minimal mass effect on the brachium pontis ➡, but no definite lesion is visible. In a patient with left sensorineural hearing loss, arachnoid cyst or epidermoid cyst should be considered.*

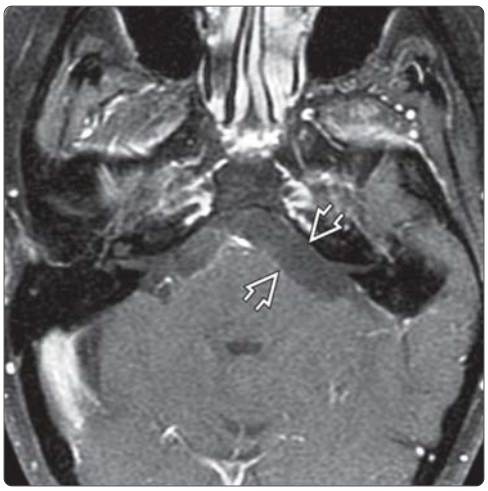

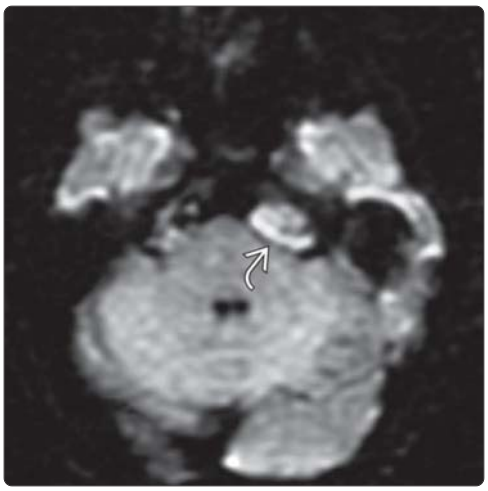

(Left) *Axial T1WI C+ FS MR in the same patient again reveals a widened CPA cistern ➡ but no evidence of enhancing tumor. If an epidermoid cyst is present in the enlarged cistern, DWI sequences will be positive with restricted diffusion making the diagnosis.* **(Right)** *Axial DWI MR in the same patient demonstrates the characteristic restricted diffusion of the epidermoid cyst ➡ in the left CPA cistern. Without DWI information, the lesion could have been missed altogether.*

https://CafePezeshki.IR

KEY FACTS

TERMINOLOGY

- Arachnoid cyst (AC): Developmental arachnoid duplication anomaly creating CSF-filled sac

IMAGING

- Sharply demarcated ovoid extraaxial cisternal cyst with imperceptible walls with CSF density (CT) or intensity (MR)
- AC signal parallels (is isointense to) CSF on **all** MR sequences
- Complete fluid attenuation on FLAIR MR
- **No** diffusion restriction on DWI MR

TOP DIFFERENTIAL DIAGNOSES

- Epidermoid cyst in CPA
- Cystic vestibular schwannoma
- Neurenteric cyst
- Cystic meningioma in CPA
- Cystic infratentorial ependymoma
- Cerebellar pilocytic astrocytoma

CLINICAL ISSUES

- Clinical presentation
  - Small AC: Asymptomatic, incidental finding (MR)
  - Large AC: Mostly asymptomatic
    - Symptoms may arise from direct compression ± ↑ intracranial pressure
- Natural history
  - Vast majority of ACs **do not** enlarge over time
- Treatment options
  - Most cases require **no** treatment
  - Treatment is highly selective process

DIAGNOSTIC CHECKLIST

- Differentiate AC from epidermoid cyst
- AC: No restriction on DWI = best clue
- Reporting tip: Since AC is usually not treated surgically, avoid offering any differential diagnosis when imaging findings diagnose AC

(Left) *Axial graphic of an arachnoid cyst in the CPA shows a thin, translucent wall. Notice the cyst bowing the 7th and 8th cranial nerves anteriorly ➡ and effacing the brainstem ⇨ and cerebellum ⇨.* **(Right)** *Axial T2WI MR reveals a right CPA arachnoid cyst causing bowing of the facial and vestibulocochlear nerves anteriorly ⇨, small bridging veins posteriorly ⇨, and flattening of the lateral margin of the brachium pontis ➡.*

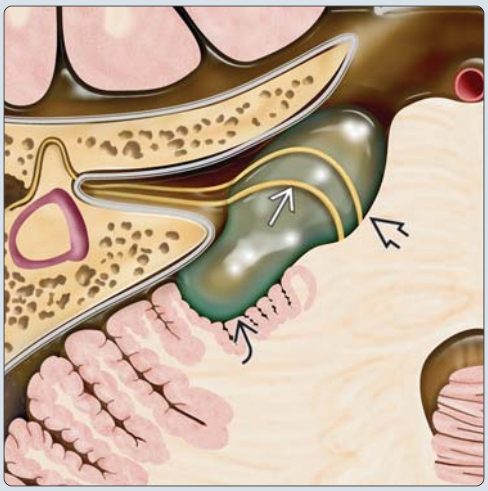

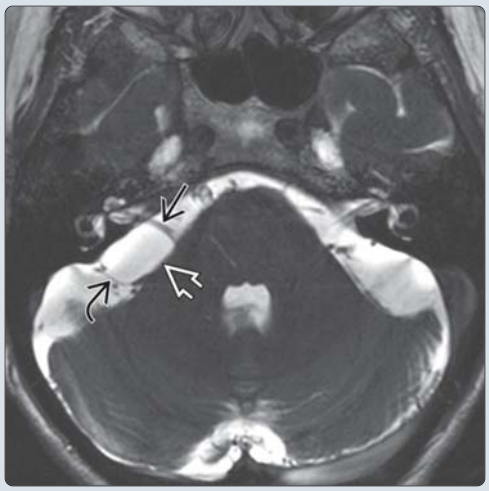

(Left) *Coronal graphic of a CPA arachnoid cyst depicts a typical translucent cyst wall. CN7 and CN8 are pushed by the cyst ➡ without being engulfed by it. In epidermoid cyst, cranial nerves are usually engulfed.* **(Right)** *Coronal T1WI MR demonstrates a small CSF intensity CPA arachnoid cyst ➡ with subtle mass effect on the adjacent brainstem ➡. Complete fluid attenuation on FLAIR MR helps differentiate this lesion from an epidermoid cyst, which is the primary imaging differential diagnosis.*

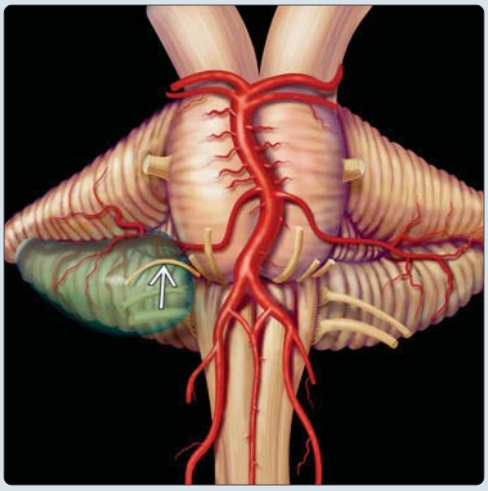

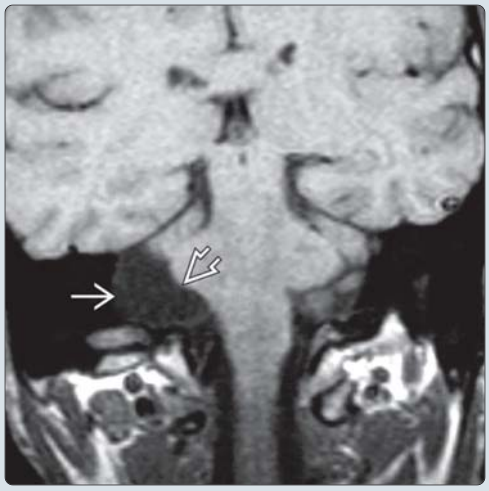

https://CafePezeshki.IR

TERMINOLOGY

Abbreviations

- Arachnoid cyst (AC)

Synonyms

- Primary or congenital AC, subarachnoid cyst

Definitions

- Developmental arachnoid duplication anomaly creating **intraarachnoid** CSF-filled sac

IMAGING

General Features

- Best diagnostic clue
  - Sharply demarcated ovoid or lentiform extraaxial cisternal cyst with imperceptible walls with CSF density (CT) or signal intensity (MR)
  - AC signal parallels CSF (is isointense to CSF) on all MR sequences
    - **Complete fluid attenuation** on FLAIR MR
    - **No diffusion restriction** on DWI MR imaging
- Location
  - 10-20% of all ACs occur in posterior fossa
    - Cerebellopontine angle (CPA) = most common infratentorial site
    - **10%** found in CPA
  - Spread patterns
    - Most remain confined to CPA (60%)
    - May spread dorsally along brainstem (25%)
    - Rarely spread into internal auditory canal (IAC)
- Size
  - Broad range: 1 cm to giant (> 8 cm)
  - In posterior fossa, when very large may be symptomatic
  - When large, will exert mass effect on vestibulocochlear and facial nerves, adjacent brainstem and cerebellum
- Morphology
  - Sharply demarcated with broad-arching margins
  - Displaces, does not engulf, surrounding structures
  - Pushes cisternal structures but does not insinuate
    - Epidermoid cyst insinuates adjacent structures

CT Findings

- NECT
  - Density same as CSF
  - Rare high density from hemorrhage or proteinaceous fluid
- CECT
  - No enhancement of cavity or wall
- Bone CT
  - Rarely causes expansile remodeling of bone
    - Seen mostly in children
- CT cisternography
  - May show connection to subarachnoid SPACE

MR Findings

- T1WI
  - Low signal AC is isointense to CSF
- T2WI
  - High signal lesion isointense to CSF
    - May have brighter signal than CSF
    - Cyst fluid lacks CSF pulsations
  - Well-circumscribed lesion
    - Compresses adjacent CN7-8 bundle, brainstem, and cerebellum when large
- FLAIR
  - Suppresses AC fluid completely
- DWI
  - No diffusion restriction
- T1WI C+
  - No enhancement seen
- High-resolution, thin-section MR (CISS, FIESTA, T2 space)
  - Help define cyst wall, relationship to adjacent structures (CN7, CN8, AICA, etc.)
- Phase-contrast cine MR
  - Flow quantification can sometimes distinguish AC from subarachnoid space
  - May rarely show connection between AC and cistern

Ultrasonographic Findings

- Grayscale ultrasound
  - Shows hypoechoic AC in infants < 1 year of age
  - Larger AC diagnosed in utero

Imaging Recommendations

- Best imaging tool
  - MR ± contrast
- Protocol advice
  - Add FLAIR (suppresses)
  - Add DWI (no restricted diffusion)

DIFFERENTIAL DIAGNOSIS

Epidermoid Cyst in CPA

- Major lesion of differential concern in setting of AC
- FLAIR: Incomplete fluid attenuation
- DWI: Restricted diffusion (high signal)
- Morphology: Insinuates into adjacent CSF spaces

Cystic Vestibular Schwannoma in CPA-IAC

- Intramural or marginal cysts seen in larger lesions
- Foci of enhancing tumor always present on T1WI C+ MR
- Rarely, larger lesions have associated AC

Cystic Meningioma in CPA-IAC

- Rare meningioma variant
- Dural "tails," asymmetry to IAC still present with mixed enhancement on T1WI C+ MR

Neurenteric Cyst

- Rare prepontine cistern near midline
- Often contains proteinaceous fluid (↑ on T1WI MR)

Cystic Infratentorial Ependymoma

- Ependymoma pedunculates from 4th ventricle via foramen of Luschka
- 50% calcified
- Cystic and solid enhancing components

Cerebellar Pilocytic Astrocytoma

- Cystic tumor in cerebellar hemisphere
- Enhancing mural nodule

https://CafePezeshki.IR

PATHOLOGY

General Features

- Etiology
  - Embryonic meninges fail to merge
    - Remain separate as **duplicated** arachnoid
    - Split arachnoid contains CSF
  - 2 types
    - Noncommunicating; most common type
    - Communicating with subarachnoid space/cistern
- Genetics
  - Usually sporadic; rarely familial
  - Inherited disorders of metabolism
    - "Sticky" leptomeninges: Mucopolysaccharidoses
- Associated abnormalities
  - Vestibular schwannoma has AC associated in 0.5%

Gross Pathologic & Surgical Features

- Fluid-containing cyst with translucent membrane
- Displaces adjacent vessels or cranial nerves

Microscopic Features

- Thin wall of flattened but normal arachnoid cells

CLINICAL ISSUES

Presentation

- Most common signs/symptoms
  - Small AC: **Asymptomatic, incidental** finding (MR)
  - Large AC: Symptoms from direct compression ± ↑ intracranial pressure
  - Pediatric AC associated with higher symptom rate
- Other signs/symptoms
  - Defined by location and size
    - Headache
    - Dizziness, tinnitus ± sensorineural hearing loss
      - Rarely facial nerve symptoms
    - Hemifacial spasm or trigeminal neuralgia
- Clinical profile
  - Adult undergoing brain MR for unrelated symptoms

Demographics

- Age
  - May be initially seen at any age
    - 75% of AC identified in childhood
- Gender
  - M:F = 3:1
- Epidemiology
  - Most common congenital intracranial cystic lesion
  - Accounts for 1% of intracranial masses

Natural History & Prognosis

- Most ACs **do not enlarge** over time
  - Infrequently enlarge via CSF pulsation through ball-valve opening into AC
  - Hemorrhage with subsequent ↓ in size reported
- If surgery is limited to AC where symptoms are clearly related, prognosis is excellent
- Radical cyst removal may result in cranial neuropathy ± vascular compromise

Treatment

- Most cases require **no treatment**
  - Pediatric AC more commonly treated than adult AC
- Surgical intervention is highly selective process
  - Reserved for cases where clear symptoms can be directly linked to AC anatomic location
  - Endoscopic cyst decompression via fenestration
    - Least invasive initial approach

DIAGNOSTIC CHECKLIST

Consider

- Differentiate AC from epidermoid cyst
  - AC: No restriction on DWI = best clue
- Determine if symptoms match location of AC before considering surgical treatment

Image Interpretation Pearls

- AC signal follows CSF on all MR sequences
  - Remember T2 signal may be higher than CSF from lack of CSF pulsation
- **DWI** sequence shows AC as **low signal**
- **FLAIR** sequence shows AC as **low signal**
- **No** enhancement of AC, including wall, is expected
  - Nodular enhancement suggests alternative diagnosis

Reporting Tips

- Since AC is usually not treated surgically, avoid offering any differential diagnosis when imaging findings diagnose AC

SELECTED REFERENCES

1. Gangemi M et al: Endoscopy versus microsurgical cyst excision and shunting for treating intracranial arachnoid cysts. J Neurosurg Pediatr. 8(2):158-64, 2011
2. Jayarao M et al: Recovery of sensorineural hearing loss following operative management of a posterior fossa arachnoid cyst. Case report. J Neurosurg Pediatr. 4(2):121-4, 2009
3. Boutarbouch M et al: Management of intracranial arachnoid cysts: institutional experience with initial 32 cases and review of the literature. Clin Neurol Neurosurg. 110(1):1-7, 2008
4. Helland CA et al: A population-based study of intracranial arachnoid cysts: clinical and neuroimaging outcomes following surgical cyst decompression in children. J Neurosurg. 105(5 Suppl):385-90, 2006
5. Osborn AG et al: Intracranial cysts: radiologic-pathologic correlation and imaging approach. Radiology. 239(3):650-64, 2006
6. Tang L et al: Diffusion-weighted imaging distinguishes recurrent epidermoid neoplasm from postoperative arachnoid cyst in the lumbosacral spine. J Comput Assist Tomogr. 30(3):507-9, 2006
7. Alaani A et al: Cerebellopontine angle arachnoid cysts in adult patients: what is the appropriate management? J Laryngol Otol. 119(5):337-41, 2005
8. Yildiz H et al: evaluation of communication between intracranial arachnoid cysts and cisterns with phase-contrast cine MR imaging. AJNR Am J Neuroradiol. 26(1):145-51, 2005
9. Boltshauser E et al: Outcome in children with space-occupying posterior fossa arachnoid cysts. Neuropediatrics. 33(3):118-21, 2002
10. Dutt SN et al: Radiologic differentiation of intracranial epidermoids from arachnoid cysts. Otol Neurotol. 23(1):84-92, 2002
11. Gangemi M et al: Endoscopic surgery for large posterior fossa arachnoid cysts. Minim Invasive Neurosurg. 44(1):21-4, 2001
12. Samii M et al: Arachnoid cysts of the posterior fossa. Surg Neurol. 51(4):376-82, 1999
13. Jallo GI et al: Arachnoid cysts of the cerebellopontine angle: diagnosis and surgery. Neurosurgery. 40(1):31-7; discussion 37-8, 1997
14. Higashi S et al: Hemifacial spasm associated with a cerebellopontine angle arachnoid cyst in a young adult. Surg Neurol. 37(4):289-92, 1992
15. Babu R et al: Arachnoid cyst of the cerebellopontine angle manifesting as contralateral trigeminal neuralgia: case report. Neurosurgery. 28(6):886-7, 1991

https://CafePezeshki.IR

(Left) *Axial T2WI MR shows a high signal large arachnoid cyst enlarging the left cerebellopontine angle cistern. The facial and vestibulocochlear nerves are visible bowing over the anteromedial surface of the arachnoid cyst* ➡. **(Right)** *Axial FLAIR MR in the same patient shows the low signal arachnoid cyst* ➡ *and complete fluid attenuation. FLAIR suppression is expected as the arachnoid cyst is essentially CSF collecting between arachnoid layers.*

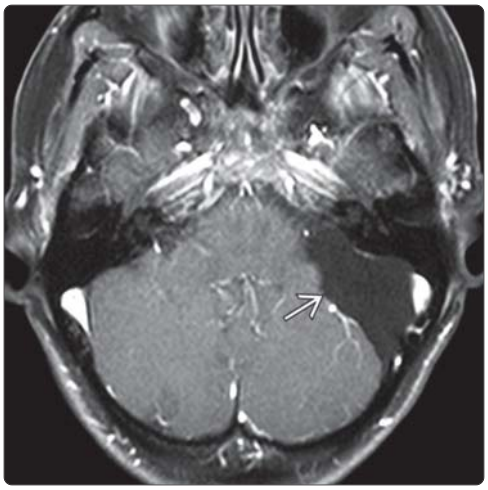

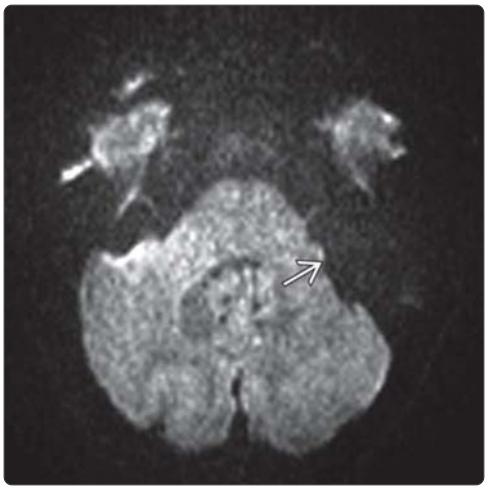

(Left) *Axial T1WI C+ FS MR in the same patient demonstrates that the CPA arachnoid cyst* ➡ *does not enhance.* **(Right)** *Axial DWI MR in the same patient shows that the arachnoid cyst* ➡ *has no associated signal (no restricted diffusion). If this were an epidermoid cyst, high signal on DWI (restricted diffusion) would be present. DWI is the best way to differentiate an arachnoid cyst from an epidermoid cyst.*

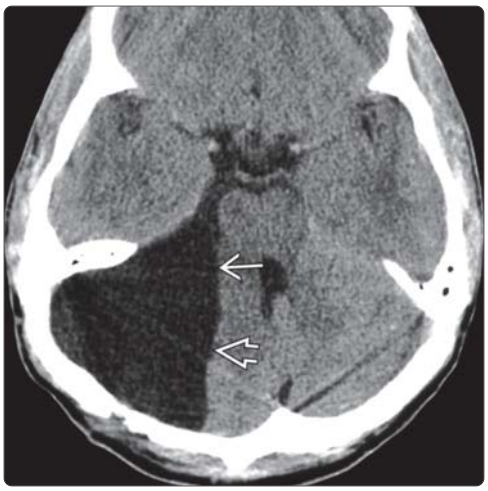

(Left) *Axial NECT through the upper CPA cistern shows a large low-density arachnoid cyst causing flattening of the lateral brachium pontis* ➡ *and cerebellar hemisphere* ➡. **(Right)** *Axial T2WI FS MR demonstrates an incidental hyperintense CPA arachnoid cyst* ➡ *found at the time of imaging for headache. This lenticular-shaped lesion displaces the glossopharyngeal nerve (CN9) anteriorly* ➡. *These small lesions require no additional imaging or treatment.*

https://CafePezeshki.IR

KEY FACTS

TERMINOLOGY

- Bell palsy (BP): Herpetic peripheral facial nerve paralysis secondary to herpes simplex virus

IMAGING

- T1WI C+ fat-saturated MR: Fundal "tuft" and labyrinthine segment CN7 show intense asymmetric enhancement
  - Entire intratemporal CN7 may enhance
- Imaging note: Classic rapid-onset BP requires **no imaging** in initial stages
- If **atypical Bell palsy**, search with imaging for underlying lesion

TOP DIFFERENTIAL DIAGNOSES

- Normal enhancement of intratemporal CN7
- Ramsay Hunt syndrome
- Facial nerve schwannoma
- Facial nerve venous malformation (hemangioma)
- Perineural tumor from parotid

PATHOLOGY

- Etiology-pathogenesis (current hypothesis)
  - Latent **herpes simplex** infection of geniculate ganglion with reactivation and spread of inflammatory process along proximal and distal intratemporal facial nerve fibers

CLINICAL ISSUES

- Classic clinical presentation
  - Acute-onset peripheral CN7 paralysis (36-hr onset)
- Medical therapy for BP
  - Tapering course of prednisone; begin within 3 days of symptoms for best result
  - Antiviral agents no longer used
- Surgical therapy for BP is controversial
  - Profound denervation (> 95%) treated with facial nerve decompression from internal auditory canal fundus to stylomastoid foramen

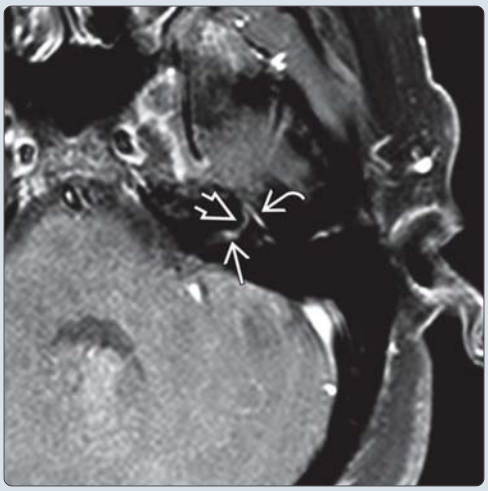

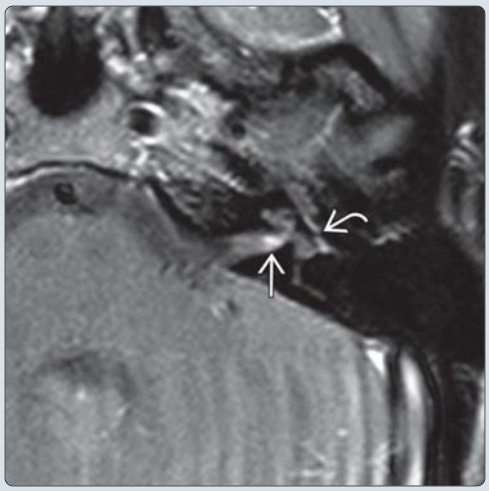

(Left) *Axial T1WI C+ FS MR shows classic findings of Bell palsy with the internal auditory canal fundal "tuft" sign ⇨, labyrinthine ⇨, and tympanic ⇨ facial nerve segment enhancement.* **(Right)** *Axial T1WI C+ FS MR in the same patient again shows the IAC fundal "tuft" sign ⇨ and tympanic segment of the facial nerve enhancement ⇨. Remember that the geniculate ganglion and posterior genu/upper mastoid segment of the facial nerve may normally enhance.*

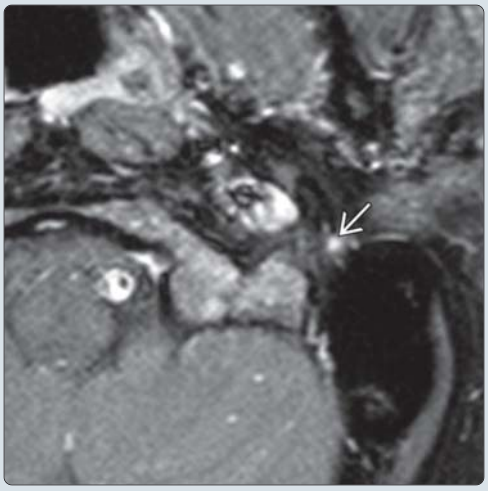

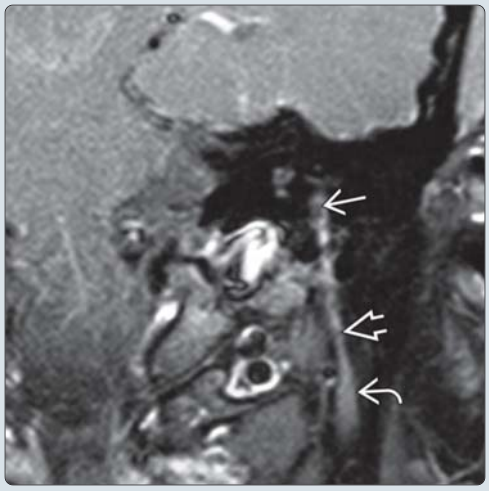

(Left) *Axial T1WI C+ FS MR in the same patient through the stylomastoid foramen demonstrates an enhancing, slightly enlarged facial nerve ⇨. Swelling of the facial nerve is possible outside the bony facial nerve canal within the temporal bone.* **(Right)** *Coronal T1WI C+ FS MR in the same patient reveals avid enhancement in the mastoid ⇨, stylomastoid ⇨, and extracranial facial nerve ⇨ in this patient with typical Bell palsy.*

https://CafePezeshki.IR

TERMINOLOGY

Abbreviations

- Bell palsy (BP)

Synonyms

- Herpetic facial paralysis

Definitions

- BP (original definition): Idiopathic acute onset of lower motor neuron facial paralysis
- BP (modern definition): Herpetic facial paralysis secondary to herpes simplex virus

Other Facts

- Named after Sir Charles Bell (1774-1842), who 1st described BP syndrome

IMAGING

General Features

- Best diagnostic clue
  - Fundal **"tuft"** and labyrinthine segment CN7 intense asymmetric enhancement on T1WI C+ MR
- Location
  - Fundal and labyrinthine segment CN7 most affected
  - Often involves entire intratemporal CN7
    - Intraparotid segment less commonly affected
- Size
  - CN7 swells within facial nerve canal

CT Findings

- Bone CT
  - Normal facial nerve canal
    - If enlargement present, **not** Bell palsy

MR Findings

- T2WI
  - Brain normal; no high signal lesions
  - High-resolution thin-section T2 or T2* GRE may show internal auditory canal (IAC) CN7 enlargement
- T1WI C+
  - Uniform, contiguous CN7 enhancement
    - CN7: Normal in size within bony canal
    - CN7: Conspicuous high signal appears slightly enlarged
    - Enhancement pattern is linear, not nodular
  - Enhancement usually present from distal IAC through labyrinthine segment, geniculate ganglion, and anterior tympanic segment
    - **Tuft** of enhancement in IAC fundus (premeatal segment) along with C+ of labyrinthine segment of CN7 are distinctive MR findings
    - Mastoid CN7 enhances less frequently
    - Enhancement of intraparotid CN7 infrequent

Imaging Recommendations

- Best imaging tool
  - Thin-section fat-saturated T1WI C+ MR focused to IAC and temporal bone
  - T-bone CT: Only used if MR creates suspicion of enlarged CN7 canal or focal lesion
- Classic rapid-onset BP requires **no imaging** in initial stages
  - 90% of BP recover spontaneously in < 2 months
  - If decompressive surgery is anticipated, MR imaging is warranted to ensure that no other lesion is causing CN7 paralysis
- If **atypical Bell palsy**, search for underlying lesion
  - Atypical Bell palsy
    - Slowly progressive CN7 palsy
    - Facial hyperfunction (spasm) preceding BP
    - Recurrent CN7 palsies
    - BP with any other associated cranial neuropathies
    - CN7 paralysis persisting or deepening > 2 months

DIFFERENTIAL DIAGNOSIS

Normal Enhancement of Intratemporal CN7

- Clinical: No facial nerve symptoms
- T1WI C+ MR: Mild, linear, discontinuous enhancement of anterior and posterior genus of intratemporal CN7
  - IAC and labyrinthine CN7 segments normal

Ramsay Hunt Syndrome

- Clinical: Peripheral CN7 paralysis with CN8 associated symptoms
  - External auditory canal (EAC) hemorrhagic vesicular rash
  - Varicella-zoster virus infection = cause
- T1WI C+ MR: Linear, continuous enhancement of fundal IAC and intratemporal CN7
  - Enhancement of inner ear structures and vestibulocochlear nerve variable

Facial Nerve Schwannoma

- Clinical: Hearing loss more common than CN7 palsy
- T1WI C+ MR: Well-circumscribed, tubular, C+ mass within enlarged CN7 canal most commonly centered on geniculate ganglion

Facial Nerve Venous Malformation ("Hemangioma")

- Clinical: CN7 paralysis occurs when lesion is small
- Bone CT: May show intratumoral bone spicules
- T1WI C+ MR: Poorly circumscribed, enhancing mass commonly found in geniculate fossa

Perineural Tumor from Parotid

- Clinical: Parotid malignancy usually palpable
- Imaging: Invasive parotid mass is present
  - Tissue-filled stylomastoid foramen
  - CN7 is enlarged from distal to proximal with associated mastoid air cell invasion

PATHOLOGY

General Features

- Etiology
  - Etiology-pathogenesis (current hypothesis)
    - Latent herpes simplex infection of geniculate ganglion with reactivation and spread of inflammatory process along proximal and distal CN7 fibers
    - Pathophysiology: Formation of intraneural edema in neuronal sheaths caused by breakdown of blood-nerve barrier and by venous congestion in epineural and perineural venous plexus
- Intratemporal CN7 normal anatomy
  - CN7 normal C+ at its anterior and posterior genus

https://CafePezeshki.IR

Brackman Facial Nerve Grading System

Grade	Description of Facial Paralysis	Measurement**	Function %	Estimated Function %
I	Normal	8/8	100	100
II	Slight	7/8	76-99	80
III	Moderate	5/8-6/8	51-75	60
IV	Moderately severe	3/8-4/8	26-50	40
V	Severe	1/8-2/8	1-25	20
VI	Total	0/8	0	0

*** Facial nerve injury is measured by the superior movement of the mid portion of the upper eyebrow and the lateral movement of the oral commissure. For each 0.25 cm of upward motion for both eyebrow and oral commissure, a scale of 1 is assigned up to 1 cm. The points are then added together. A total of 8 points can be obtained if both the eyebrow and the oral commissure both move 1 cm.*

Adapted from House JW et al: Facial nerve grading system. Otolaryngol Head Neck Surg. 93(2):146-7, 1985.

- C+ from robust circumneural arteriovenous plexus
- Familiarity with normal patterns of intratemporal CN7 C+ allows radiologist to identify abnormal enhancement seen with BP

Gross Pathologic & Surgical Features

- CN7 edema peaks at 3 weeks after symptom onset

Microscopic Features

- Herpes simplex DNA recovered from CN7

CLINICAL ISSUES

Presentation

- Most common signs/symptoms
  - Acute-onset peripheral CN7 paralysis (36-hour onset)
- Clinical profile
  - Healthy adult with acute unilateral CN7 paralysis
    - More common in diabetic patients
- Other signs/symptoms
  - Viral prodrome often reported before BP onset
  - 70%: Taste alterations days before CN7 paralysis
  - 50%: Pain around ipsilateral ear (not severe)

Demographics

- Age
  - All ages affected; incidence peaks in 5th decade
- Epidemiology
  - Herpetic facial paralysis thought to be responsible for ~ 75% of peripheral CN7 paralysis cases
  - Annual BP incidence: 10-50/100,000 persons

Natural History & Prognosis

- 80% of BP patients spontaneously recover all of CN7 function without therapy in 1st 2 months
  - 15% partially recover; 5% show no recovery

Treatment

- Test for diabetes and Lyme disease
- Medical therapy for BP
  - Tapering course of prednisone; begin within 3 days of symptoms for best result
  - Acyclovir or valacyclovir (antivirals) no longer used
- Surgical therapy for BP is controversial
  - Profound denervation (> 95%) treated with CN7 decompression, fundus to stylomastoid foramen
  - Decompression performed within 2 weeks of onset of total paralysis for maximal effect
- Intensity, pattern ± location of enhancement on T1WI C+ MR **not** helpful in predicting individual patient outcome
- Older patients: Lower rate of complete CN7 recovery

DIAGNOSTIC CHECKLIST

Consider

- **No** imaging necessary for typical BP
  - MR imaging reserved for **atypical** BP
- Abnormal CN7 C+ on MR may persist well beyond clinical improvement or full recovery
- Not all intratemporal facial nerves enhance in BP
  - < 10 days following onset of BP, CN7 often normal

Image Interpretation Pearls

- "Tuft" of IAC fundal C+ associated with labyrinthine segment CN7 C+ without associated focal lesion is highly suggestive of BP

Reporting Tips

- Remember to comment on parotid as normal
- Also note absence of focal CN7 lesions

SELECTED REFERENCES

1. Hohman MH et al: Etiology, diagnosis, and management of facial palsy: 2000 patients at a facial nerve center. Laryngoscope. 124(7):E283-93, 2014
2. Baugh RF et al: Clinical practice guideline: Bell's palsy. Otolaryngol Head Neck Surg. 149(3 Suppl):S1-27, 2013
3. Kim IS et al: Correlation between MRI and operative findings in Bell's palsy and Ramsay Hunt syndrome. Yonsei Med J. 48(6):963-8, 2007
4. Kress B et al: Bell palsy: quantitative analysis of MR imaging data as a method of predicting outcome. Radiology. 230(2):504-9, 2004
5. Unlu Z et al: Serologic examinations of hepatitis, cytomegalovirus, and rubella in patients with Bell's palsy. Am J Phys Med Rehabil. 82(1):28-32, 2003
6. Adour KK: Medical management of idiopathic (Bell's) palsy. Otolaryngol Clin North Am. 24(3):663-73, 1991
7. Schwaber MK et al: Gadolinium-enhanced magnetic resonance imaging in Bell's palsy. Laryngoscope. 100(12):1264-9, 1990
8. Tien R et al: Contrast-enhanced MR imaging of the facial nerve in 11 patients with Bell's palsy. AJNR Am J Neuroradiol. 11(4):735-41, 1990
9. Daniels DL et al: MR imaging of facial nerve enhancement in Bell palsy or after temporal bone surgery. Radiology. 171(3):807-9, 1989
10. Matsumoto Y et al: Facial nerve biopsy for etiologic clarification of Bell's palsy. Ann Otol Rhinol Laryngol Suppl. 137:22-7, 1988

https://CafePezeshki.IR

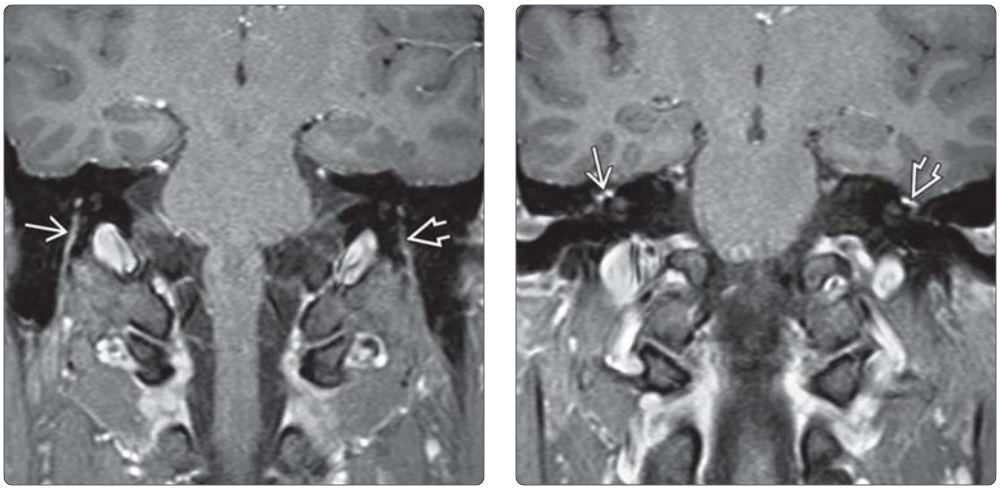

(Left) *Coronal T1WI C+ FS MR in a patient with right Bell palsy shows asymmetric right mastoid CN7 avid enhancement* ➡ *compared to minimal enhancement on the left* ➡. **(Right)** *Coronal T1WI C+ FS MR in the same patient shows similar enhancement of the right* ➡ *compared to the left* ➡ *geniculate ganglion. This can be explained by the fact that the geniculate ganglion, along with the posterior genu/upper mastoid facial nerve, may normally enhance.*

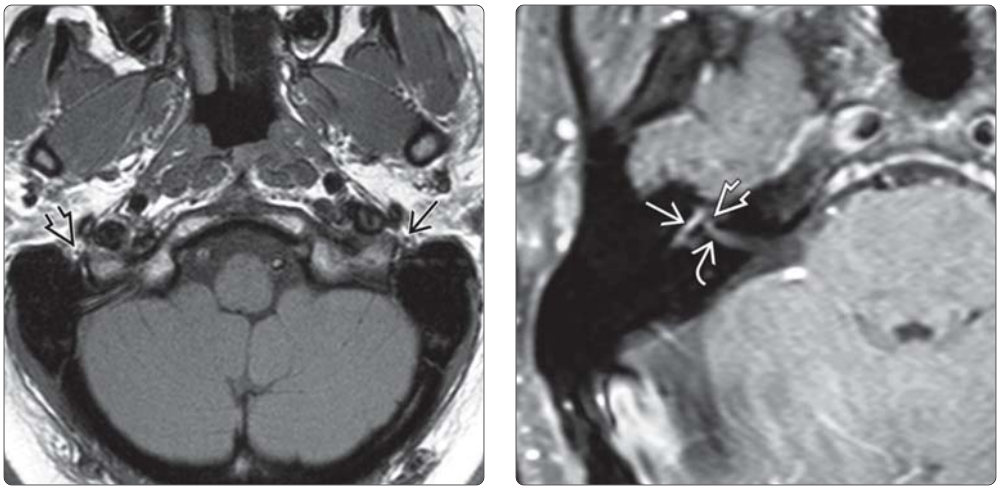

(Left) *Axial T1WI MR in a patient with left Bell palsy reveals that the left facial nerve in the stylomastoid foramen* ➡ *is larger than the right* ➡. *The injured left facial nerve swells when it is not confined by the intratemporal bony facial nerve canal.* **(Right)** *Axial T1WI C+ FS MR in a patient with right-sided Bell palsy demonstrates typical findings of enhancing tympanic* ➡ *and labyrinthine* ➡ *segments of the facial nerve. Notice the more subtle IAC fundus "tuft" sign* ➡.

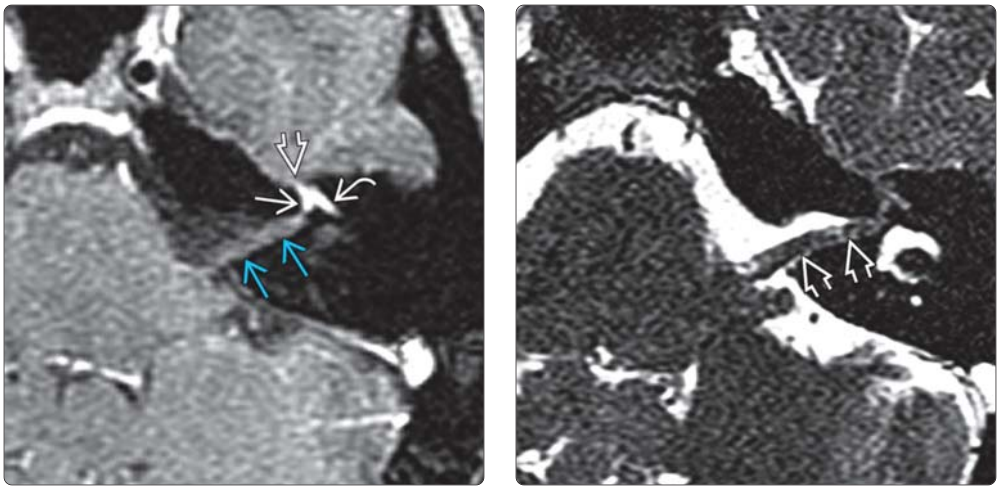

(Left) *Axial T1WI C+ FS MR in a patient with profound, unremitting Bell palsy shows intense enhancement of the labyrinthine* ➡, *geniculate ganglion* ➡, *and anterior tympanic portions* ➡ *of the facial nerve. The IAC "tuft" spreads along the IAC facial nerve as more subtle enhancement* ➡, *reaching the porus acusticus.* **(Right)** *Axial thin-section (1 mm) T2WI FS MR in the same patient reveals a swollen intracanalicular facial nerve* ➡ *through the internal auditory canal.*

https://CafePezeshki.IR

KEY FACTS

TERMINOLOGY

- Trigeminal neuralgia (TN) definition: Vascular loop compressing trigeminal nerve (CN5) at its root entry zone (REZ) or preganglionic segment (PGS)

IMAGING

- High-resolution MR: Serpiginous asymmetric signal void (vessel) in CPA CN5 REZ or PGS
  - CN5 PGS atrophy: Severe, prolonged compression
  - Compressing vessel will bow PGS
- Offending vessels: **Superior cerebellar artery** (55%) > AICA (10%) > basal artery (5%) > variant vein (5%) > other

TOP DIFFERENTIAL DIAGNOSES

- Aneurysm in CPA-IAC
- Arteriovenous malformation in CPA
- Developmental venous anomaly in posterior fossa

PATHOLOGY

- CN5 REZ or PGS experiences "irritation" from vessel

CLINICAL ISSUES

- Trigeminal neuralgia symptoms
  - Lancinating pain following V2 ± V3 distributions
  - May occur spontaneously or in response to "trigger" from tactile stimulation
- Treatment
  - Begin with conservative drug therapy
  - Microvascular decompression or focused radiotherapy (~ 70% long-term success rate)

DIAGNOSTIC CHECKLIST

- 1st look for multiple sclerosis or DVA with draining vein along PGS
  - Also check for cisternal mass: Schwannoma, meningioma, epidermoid
- Next follow CN5 distally into cavernous sinus and face
  - Exclude perineural tumor, malignancies of face
- Last view high-resolution thin-section MR for causal vessel
  - Causal vessel will bow PGS or deform REZ

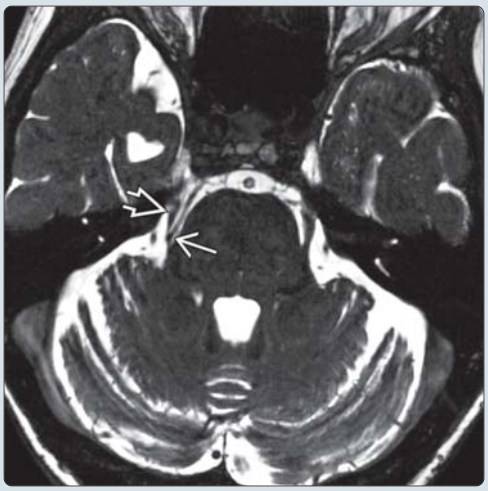

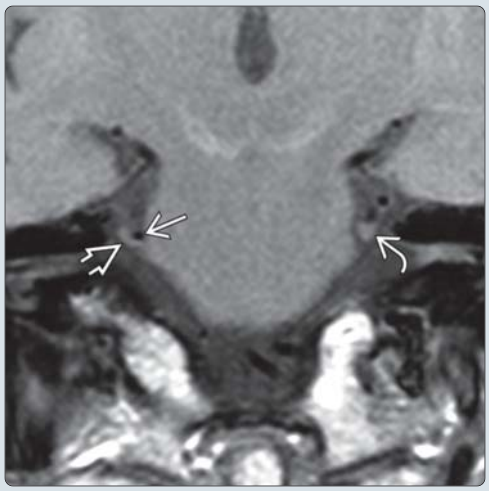

(Left) *Axial T2WI MR in this patient with right trigeminal neuralgia shows the low signal superior cerebellar artery ➡ impinging on the root entry zone of the preganglionic segment ➡ of the trigeminal nerve.* **(Right)** *Coronal T1WI MR in the same patient reveals the superior cerebellar artery ➡ compressing and deforming the right proximal preganglionic segment of CN5 ➡. Notice the larger, normal left preganglionic CN5 ➡ indicating that atrophy is a feature of the affected right side.*

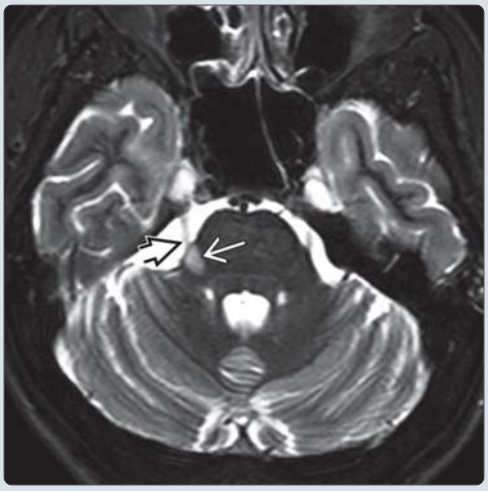

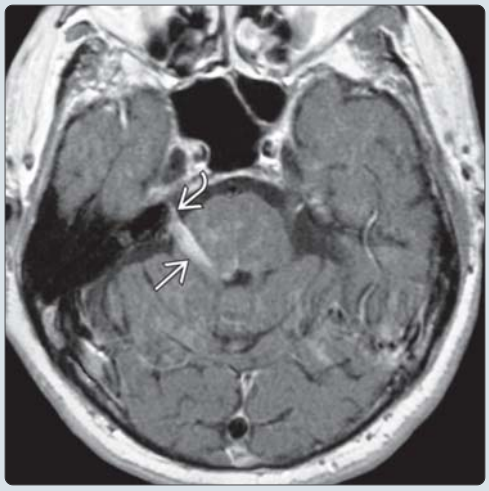

(Left) *Axial T2WI FS MR in a patient with right trigeminal neuralgia reveals a multiple sclerosis lesion ➡ involving the lateral pons at the root entry zone of the trigeminal nerve ➡. Rarely, cisternal masses or MS may present with trigeminal neuralgia.* **(Right)** *Axial T1WI C+ MR in a patient with right TN shows a developmental venous anomaly of the cerebellum draining through the lateral pons ➡ and root entry zone ➡ of CN5. Less than 5% of patients with TN have a venous explanation for their symptoms.*

https://CafePezeshki.IR

TERMINOLOGY

Abbreviations

- Trigeminal neuralgia (TN)

Synonyms

- Tic douloureux, trigeminal nerve vascular loop syndrome, trigeminal nerve hyperactive dysfunction syndrome

Definitions

- Vascular loop compressing trigeminal nerve at its root entry zone (REZ) or preganglionic segment (PGS)

IMAGING

General Features

- Best diagnostic clue
  - High-resolution MR shows serpentine asymmetric signal void (vessel) in CPA CN5 REZ or PGS
- TN offending vessels: Superior cerebellar artery (SCA) > AICA > basal artery > petrosal vein

MR Findings

- FLAIR
  - Multiple sclerosis (MS) may present with TN
- DWI
  - Hyperintense cisternal mass diagnoses epidermoid
- T1WI C+
  - In vascular loop-caused TN, CN5 PGS does **not** enhance
  - May show rare venous cause of TN or perineural tumor
  - Rare cisternal mass possible
- High-resolution MR (CISS, FIESTA, T2 space, other)
  - Causal vessel compressing CN5 REZ or PGS
    - Vessel bows PGS or deforms REZ if cause of neurovascular conflict
  - CN5 PGS atrophy: When compression severe, prolonged
- MRA: Source images most helpful

Imaging Recommendations

- Best imaging tool
  - High-resolution MR for imaging of causal vascular loop

DIFFERENTIAL DIAGNOSIS

Aneurysm in CPA-IAC

- AICA or vertebral artery aneurysm
- Oval complex signal mass
- Rarely causes TN

Arteriovenous Malformation in CPA

- Much larger vessels (arteries and veins) with nidus
- Rare in posterior fossa

Developmental Venous Anomaly in Posterior Fossa

- Larger vessels (veins)
- CPA rare as venous drainage route
- Rarely causes venous compression-induced TN

PATHOLOGY

General Features

- Etiology
  - CN5 REZ or PGS vascular compression → **atrophy**
  - Atrophy secondary to axonal loss and demyelination
  - Atrophy → abnormal contacts among nerve fibers
    - Abnormal contacts cause paroxysmal pain of TN

Microscopic Features

- Myelin cover of proximal CN5 is breached

CLINICAL ISSUES

Presentation

- Most common signs/symptoms
  - Lancinating pain following V2 ± V3 distributions
  - Spontaneous or in response to tactile stimulation

Demographics

- Age
  - Older patients (usually > 65 years)
- Epidemiology
  - 5:100,000

Natural History & Prognosis

- Prognosis
  - ~ 70% pain-free 10 years after surgery or radiotherapy

Treatment

- Begin with conservative drug therapy
- Other treatments if conservative therapy fails
  - Focused radiotherapy (Gamma knife)
  - Microvascular decompression

DIAGNOSTIC CHECKLIST

Consider

- Many normal vessels in CPA cistern
- Look for asymmetric vessel with visible compression

Image Interpretation Pearls

- 1st look for MS, pontine DVA, cisternal masses
- Follow CN5 distally into cavernous sinus and face
  - Exclude perineural tumor, malignancies of face
- View high-resolution MR for neurovascular conflict

SELECTED REFERENCES

1. Lee JK et al: Long-term outcome of gamma knife surgery using a retrogasserian petrous bone target for classic trigeminal neuralgia. Acta Neurochir Suppl. 116:127-35, 2013
2. Lutz J et al: Trigeminal neuralgia due to neurovascular compression: high-spatial-resolution diffusion-tensor imaging reveals microstructural neural changes. Radiology. 258(2):524-30, 2011
3. Kabatas S et al: Microvascular decompression as a surgical management for trigeminal neuralgia: long-term follow-up and review of the literature. Neurosurg Rev. 32(1):87-93; discussion 93-4, 2009
4. Satoh T et al: Severity analysis of neurovascular contact in patients with trigeminal neuralgia: assessment with the inner view of the 3D MR cisternogram and angiogram fusion imaging. AJNR Am J Neuroradiol. 30(3):603-7, 2009
5. Sindou M et al: Microvascular decompression for primary trigeminal neuralgia: long-term effectiveness and prognostic factors in a series of 362 consecutive patients with clear-cut neurovascular conflicts who underwent pure decompression. J Neurosurg. 107(6):1144-53, 2007
6. Yoshino N et al: Trigeminal neuralgia: evaluation of neuralgic manifestation and site of neurovascular compression with 3D CISS MR imaging and MR angiography. Radiology. 228(2):539-45, 2003
7. Hutchins LG et al: Trigeminal neuralgia (tic douloureux): MR imaging assessment. Radiology. 175(3):837-41, 1990

https://CafePezeshki.IR

KEY FACTS

TERMINOLOGY

- Definition: Vascular loop compressing facial nerve at its root exit zone within cerebellopontine angle cistern causing hemifacial spasm

IMAGING

- High-resolution T2WI MR or source MRA images show serpentine asymmetric signal void (vessel) in medial CPA
  - AICA (50%) > PICA (30%) > VA (15%) > vein (5%)

TOP DIFFERENTIAL DIAGNOSES

- Aneurysm, CPA-IAC
- Arteriovenous malformation, CPA
- Developmental venous anomaly, posterior fossa

PATHOLOGY

- CN7 bundle experiences "irritation" from vessel
- Rare, nonvascular causes of HFS
  - Multiple sclerosis
  - Cisternal masses
    - Epidermoid, meningioma, schwannoma
  - T-bone and parotid lesions
    - Perineural CN7 malignancy

CLINICAL ISSUES

- Clinical presentation
  - Unilateral involuntary facial spasms (HFS)
  - HFS begins with orbicularis oculi spasms
  - Tonic-clonic bursts become constant over time

DIAGNOSTIC CHECKLIST

- Positive MR findings present in ~ 50% HFS patients
- 1st look for cisternal mass lesions, multiple sclerosis
- Then follow CN7 distally into T-bone and parotid
  - Exclude CN7 venous malformation, parotid malignancy
- Determine if MRA source images or high-resolution T2WI images identify causal vessel
  - Negative MR does not preclude surgical therapy

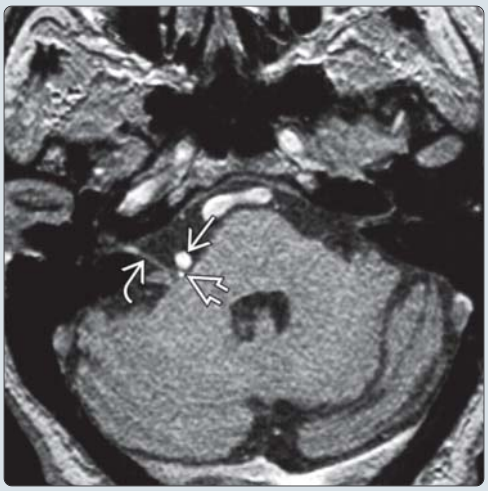

(Left) *Axial MRA source image in a patient with right hemifacial spasm shows a tortuous right vertebral artery ➡ and associated PICA ➡ pushing on the root exit zone of the facial nerve. The facial nerve is visible in the CPA cistern ➡.* **(Right)** *Axial CISS MR through the CPA cisterns in a patient with right hemifacial spasm demonstrates a PICA loop ➡ pushing the cisternal CN7 and CN8 posteriorly, causing them to drape over the posterior margin of the porus acusticus ➡.*

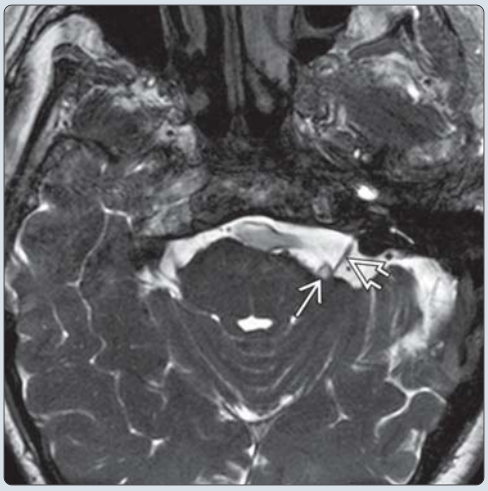

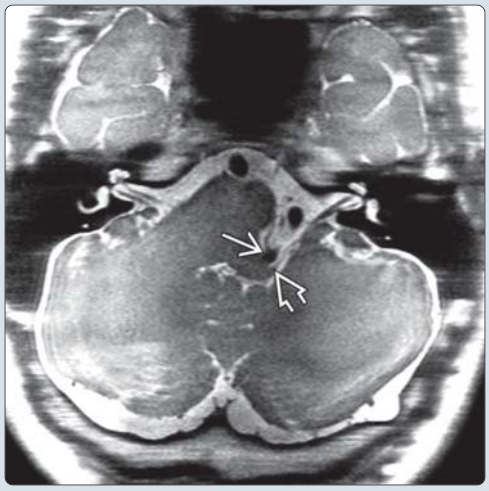

(Left) *Axial CISS MR in a patient with left hemifacial spasm reveals the left vertebral artery ➡ looping into the CPA cistern where it impinges on the proximal facial nerve ➡ at the root exit zone.* **(Right)** *Axial T2WI MR reveals a dolichoectatic vertebral artery ➡ impinging on the root exit zone ➡ of the facial nerve in the medial CPA cistern in this patient with hemifacial spasm. Approximately 50% of patients with hemifacial spasm have positive MR findings, typically on thin-section T2 or MRA sequences.*

https://CafePezeshki.IR

TERMINOLOGY

Abbreviations

- Hemifacial spasm (HFS)

Synonyms

- Facial nerve vascular loop syndrome, facial nerve hyperactive dysfunction syndrome

Definitions

- Vascular loop compressing facial nerve at its root exit zone within CPA cistern causing hemifacial spasm

IMAGING

General Features

- Best diagnostic clue
  - High-resolution T2WI MR shows serpentine asymmetric signal void (vessel) in medial CPA
- Location
  - Loop in medial CPA cistern at CN7 root exit zone
- HFS offending vessels: AICA (50%), PICA (30%), VA (15%), vein (5%)

MR Findings

- T2WI
  - High-resolution T2WI: Vessel best seen as low signal tube coursing through high signal CSF
- FLAIR
  - Adjacent brain most commonly normal
  - Multiple sclerosis may present with HFS
- MRA
  - Source images most helpful

Imaging Recommendations

- Best imaging tool
  - Thin-section high-resolution T2WI MR of CPA allows best vascular loop visualization
- Protocol advice
  - Begin with whole brain T2 or FLAIR sequence to exclude multiple sclerosis
  - Follow with axial and coronal T1WI C+ FS of brainstem and CPA cistern, including deep face
    - Look for asymmetric venous cause
    - Look for cisternal or perineural tumor, cranial neuritis
  - High-resolution T2WI of brainstem and CPA cistern next
    - Best sequence to look for causal artery

DIFFERENTIAL DIAGNOSIS

CPA-IAC Aneurysm

- PICA or vertebral artery aneurysm
- Oval complex signal mass

CPA Arteriovenous Malformation

- Larger vessels (arteries and veins) with nidus
- Rare in posterior fossa

Posterior Fossa Developmental Venous Anomaly

- Larger vessels (veins)
- CPA rare as venous drainage route
- Rarely causes venous compression with HFS

PATHOLOGY

General Features

- Etiology
  - CN7 bundle experiences "irritation" from vessel
    - Brainstem nuclei secondarily affected
    - Abnormal brainstem response (ABR)

Microscopic Features

- Myelin cover on proximal CN7 breached

CLINICAL ISSUES

Presentation

- Most common signs/symptoms
  - HFS: Unilateral involuntary facial spasms
    - Begins with orbicularis oculi spasms
    - **Tonic-clonic bursts** become constant

Demographics

- Age
  - Older patients (usually > 65 years)
- Epidemiology
  - < 1:100,000

Natural History & Prognosis

- 90% symptom-free ≥ 5 years after surgery

Treatment

- Local injections of botulinum toxin
  - 85% of patients obtain significant relief from local injections
  - Repeat treatment every 4 months
- **Microvascular decompression** as needed
  - Provides permanent relief in 90% of patients

DIAGNOSTIC CHECKLIST

Consider

- Positive MR findings present in ~ 50% of HFS patients

Image Interpretation Pearls

- 1st look for cisternal mass lesions, multiple sclerosis
- Follow CN7 distally into T-bone and parotid
  - Exclude CN7 hemangioma, parotid malignancy
- Review MRA and high-resolution T2WI for causal vessel
  - Negative MR does **not** preclude surgical therapy

SELECTED REFERENCES

1. Garcia M et al: High-resolution 3D-constructive interference in steady-state MR imaging and 3D time-of-flight MR angiography in neurovascular compression: a comparison between 3T and 1.5T. AJNR Am J Neuroradiol. 33(7):1251-6, 2012
2. Huh R et al: Microvascular decompression for hemifacial spasm: analyses of operative complications in 1582 consecutive patients. Surg Neurol. 69(2):153-7; discussion 157, 2008
3. Lee MS et al: Clinical usefulness of magnetic resonance cisternography in patients having hemifacial spasm. Yonsei Med J. 42(4):390-4, 2001
4. Yamakami I et al: Preoperative assessment of trigeminal neuralgia and hemifacial spasm using constructive interference in steady state-three-dimensional Fourier transformation magnetic resonance imaging. Neurol Med Chir (Tokyo). 40(11):545-55; discussion 555-6, 2000
5. Mitsuoka H et al: Delineation of small nerves and blood vessels with three-dimensional fast spin-echo MR imaging: comparison of presurgical and surgical findings in patients with hemifacial spasm. AJNR Am J Neuroradiol. 19(10):1823-9, 1998

https://CafePezeshki.IR

KEY FACTS

TERMINOLOGY

- Vestibular schwannoma (VS): Benign tumor from Schwann cells that wrap vestibular CN8 branches in CPA-IAC

IMAGING

- T1WI fat-saturated enhanced MR = gold standard
  - Focal, enhancing mass of CPA-IAC cistern centered on porus acusticus
  - Small VS: Ovoid enhancing intracanalicular mass
  - Large VS: "Ice cream on cone" shape in CPA and IAC
  - 15% with intramural cysts (low signal foci)
  - 0.5% with associated arachnoid cyst/"trapped" CSF
- High-resolution T2 space, CISS, or FIESTA: "Filling defect" in hyperintense cerebrospinal fluid of CPA-IAC cistern
- FLAIR: ↑ cochlear signal from ↑ protein
- T2* GRE: Microhemorrhages ↓ signal foci (common)
  - Characteristic VS finding when present
  - Not seen in meningioma

TOP DIFFERENTIAL DIAGNOSES

- Meningioma in CPA-IAC
- Epidermoid cyst in CPA
- Aneurysm in CPA
- Facial nerve schwannoma in CPA-IAC
- Metastases in CPA-IAC

PATHOLOGY

- Benign tumor arising from vestibular portion of CN8 at glial-Schwann cell junction

CLINICAL ISSUES

- Demographics and symptoms
  - Adults with unilateral SNHL
- Surgical approaches
  - Translabyrinthine resection if no hearing
  - Middle cranial fossa approach for IAC VS
  - Retrosigmoid approach when CPA involved
- Fractionated or stereotactic radiosurgery

(Left) *Axial graphic shows small intracanalicular vestibular schwannoma ➡ arising from the superior vestibular nerve. Notice that the cochlear nerve canal is uninvolved ➡.* **(Right)** *Axial T2WI MR reveals a small intracanalicular vestibular schwannoma ➡ visualized as a soft tissue intensity mass surrounded by high intensity cerebrospinal fluid. The cochlear nerve canal ➡ is not involved, and an 8 mm fundal cap ➡ is present.*

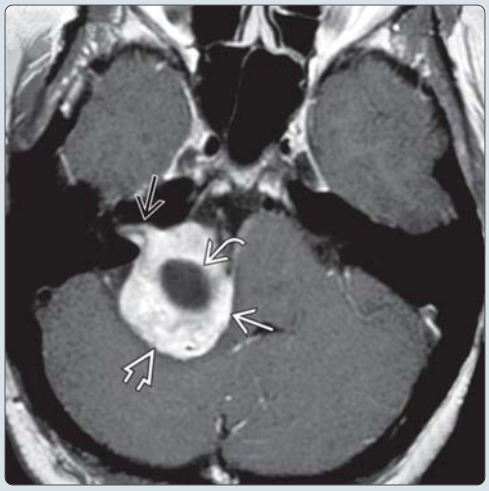

(Left) *Axial graphic of a large vestibular schwannoma reveals the typical "ice cream on cone" CPA-IAC morphology. Mass effect on the middle cerebellar peduncle ➡ and cerebellar hemisphere ➡ is evident.* **(Right)** *Axial T1WI C+ MR demonstrates a large CPA-IAC vestibular schwannoma compressing the middle cerebellar peduncle ➡ and cerebellar hemisphere ➡. Enhancement within the IAC ➡ and the large intramural cyst ➡ makes the imaging diagnosis certain.*

https://CafePezeshki.IR

TERMINOLOGY

Abbreviations

- Vestibular schwannoma (VS)

Synonyms

- Acoustic schwannoma, acoustic neuroma, acoustic tumor
  - Uncommon names: Neurinoma, neurilemmoma

Definitions

- Benign tumor arising from Schwann cells that wrap vestibular branches of CN8 in CPA-IAC

IMAGING

General Features

- Best diagnostic clue
  - Avidly enhancing cylindrical (IAC) or "**ice cream on cone**" (CPA-IAC) mass
- Location
  - Small lesions: Intracanalicular
  - Large lesions: Intracanalicular with CPA cistern extension
- Size
  - Small lesions: 2-10 mm
  - Larger lesions: Up to 5 cm in maximum diameter
- Morphology
  - Small and intracanalicular VS: Ovoid mass
  - Large VS: "Ice cream" (CPA) "on cone" (IAC)

CT Findings

- CECT
  - Well-delineated, enhancing mass of CPA-IAC cistern
  - Calcification not present (compared to CPA meningioma)
  - May flare IAC when large
  - Smaller intracanalicular lesions (< 5 mm) may be missed with CECT

MR Findings

- T1WI
  - Usually isointense with brain
  - ↑ signal foci if rare hemorrhage present
    - Microhemorrhages more common but not seen on T1
- T2WI FS
  - High-resolution T2 space, CISS, or FIESTA: "Filling defect" in ↑ signal cerebrospinal fluid (CSF) of CPA-IAC cistern
    - Small lesion: Ovoid filling defect in ↑ signal CSF of IAC
    - Large lesion: "Ice cream on cone" filling defect in CPA-IAC
- FLAIR
  - ↑ cochlear signal from ↑ perilymph protein
- T2* GRE
  - **Microhemorrhage** low-signal foci common
    - Not seen in meningioma unless sufficient intramural calcifications present to cause "blooming"
- T1WI C+ FS
  - Focal, enhancing mass of CPA-IAC cistern centered on porus acusticus
  - 100% enhance strongly
  - **15%** with **intramural cysts** (low signal foci)
  - Dural "tails" rare (compared to meningioma)
- Other MR findings
  - < 1%: Macroscopic intratumoral hemorrhage
  - 0.5% with associated arachnoid cyst/"trapped" CSF

Imaging Recommendations

- Best imaging tool
  - Gold standard is full brain FLAIR MR with axial and coronal thin-section T1WI C+ FS MR of CPA-IAC
- Protocol advice
  - High-resolution T2 space, CISS, or FIESTA MR of CPA-IAC is only screening exam for VS
    - Used for uncomplicated unilateral sensorineural hearing loss (SNHL) in adult
    - Not useful for postoperative follow-up imaging

DIFFERENTIAL DIAGNOSIS

Meningioma in CPA-IAC

- Intracanalicular meningioma may mimic VS (rare)
- CECT: Calcified dural-based mass eccentric to porus acusticus
- T1WI C+ MR: Broad dural base with associated dural "tails"
- T2* GRE: Typically **no** microhemorrhages seen

Epidermoid Cyst in CPA

- May mimic rare cystic VS
- Insinuating morphology
- T1WI C+ MR: Nonenhancing CPA mass
- DWI: **Diffusion restriction** (high signal) diagnostic

Arachnoid Cyst in CPA

- Well-marginated CPA lesion: Does not enter IAC
- Follows CSF signal on all MR sequences
- DWI: No restricted diffusion

Aneurysm in CPA

- Ovoid to fusiform **complex signal** CPA mass

Facial Nerve Schwannoma in CPA-IAC

- When confined to CPA-IAC, may exactly mimic VS
- Look for labyrinthine segment "**tail**" to differentiate

Metastases in CPA-IAC

- May have bilateral meningeal involvement
  - Beware of misdiagnosing as neurofibromatosis type 2 (NF2)

PATHOLOGY

General Features

- Etiology
  - Benign tumor arising from vestibular portion of CN8 at glial-Schwann cell junction
    - Rare in cochlear portion CN8
- Genetics
  - Inactivating mutations of *NF2* tumor suppressor gene in 60% of sporadic VS
  - Loss of chromosome 22q also seen
  - Multiple or bilateral schwannomas = NF2
- Associated abnormalities
  - Arachnoid cyst (0.5%)
  - At surgery may be arachnoid cyst or "trapped" CSF

Staging, Grading, & Classification

- WHO grade I lesion

https://CafePezeshki.IR

Gross Pathologic & Surgical Features

- Tan, round-ovoid, encapsulated mass
- Arises eccentrically from CN8 at glial-Schwann cell junction
  - Glial-Schwann cell junction usually at porus acusticus

Microscopic Features

- Differentiated Schwann cells in collagenous matrix
- Areas of compact, elongated cells = Antoni A
  - Most VS composed mostly of Antoni A cells
- Areas less densely cellular with tumor loosely arranged, ± clusters of lipid-laden cells = Antoni B
- Strong, diffuse expression of S100 protein
- No necrosis; instead intramural cysts
- < 1% hemorrhagic

CLINICAL ISSUES

Presentation

- Most common signs/symptoms
  - Adults with unilateral SNHL
- Clinical profile
  - Slowly progressive SNHL
  - Laboratory
    - Brainstem electric response audiometry (BERA) most sensitive preimaging test for VS
    - Screening MR could replace BERA
- Other symptoms
  - Small VS: Tinnitus (ringing in ear); disequilibrium
  - Large VS: Trigeminal ± facial neuropathy possible

Demographics

- Age
  - Adults (rare in children unless NF2)
  - Peak age: 40-60 years
  - Age range: 30-70 years
- Epidemiology
  - Most common lesion in unilateral SNHL (**> 90%**)
  - Most common CPA-IAC mass (85-90%)
  - 2nd most common extraaxial neoplasm in adults

Natural History & Prognosis

- 60% of VS are slow growing (< 1 mm/year)
- 10% of VS grow rapidly (> 3 mm/year)
- 60% of VS grow slowly; can be followed with imaging
  - Used in > 60 years old, poor health, small tumor size, patient preference
- Successful surgical removal of VS will not restore any hearing already lost
- Negative prognostic imaging findings for hearing preservation
  - Size > 2 cm
  - VS involves IAC fundus ± cochlear aperture

Treatment

- **Translabyrinthine** resection if no hearing preservation possible
- **Middle cranial fossa** approach for intracanalicular VS
  - Especially lateral IAC location
- **Retrosigmoid approach** when CPA or medial IAC component present
- Fractionated or stereotactic radiosurgery
  - Gamma knife: Low dose, sharply collimated, focused cobalt-60 treatment
  - Used when medical contraindications to surgery and residual postoperative VS
  - Can be used as 1st treatment

DIAGNOSTIC CHECKLIST

Consider

- Consider using high-resolution T2 space, CISS, or FIESTA MR as "screening" for VS
- Thin-section, T1WI C+ enhanced, fat-saturated axial and coronal MR = gold standard imaging approach

Image Interpretation Pearls

- Unilateral well-circumscribed IAC or CPA-IAC mass should be considered VS until proven otherwise
- Always make sure there is no labyrinthine "tail" on all VS to avoid misdiagnosing facial nerve schwannoma

Reporting Tips

- Comment on tumor size ± CPA involvement
- Does VS involve cochlear nerve canal or IAC fundus?
- How large in millimeters is "fundal cap"?
- Is hemorrhage, intramural cyst, or arachnoid cyst/"trapped" CSF present within or associated with VS?
- When small, comment on nerve of origin if possible

SELECTED REFERENCES

1. Oh JH et al: Clinical application of 3D-FIESTA image in patients with unilateral inner ear symptom. Korean J Audiol. 17(3):111-7, 2013
2. Tomogane Y et al: Usefulness of PRESTO magnetic resonance imaging for the differentiation of schwannoma and meningioma in the cerebellopontine angle. Neurol Med Chir (Tokyo). 53(7):482-9, 2013
3. Bakkouri WE et al: Conservative management of 386 cases of unilateral vestibular schwannoma: tumor growth and consequences for treatment. J Neurosurg. 110(4):662-9, 2009
4. Fukuoka S et al: Gamma knife radiosurgery for vestibular schwannomas. Prog Neurol Surg. 22:45-62, 2009
5. Bhadelia RA et al: Increased cochlear fluid-attenuated inversion recovery signal in patients with vestibular schwannoma. AJNR Am J Neuroradiol. 29(4):720-3, 2008
6. Ferri GG et al: Conservative management of vestibular schwannomas: an effective strategy. Laryngoscope. 118(6):951-7, 2008
7. House JW et al: False-positive magnetic resonance imaging in the diagnosis of vestibular schwannoma. Otol Neurotol. 29(8):1176-8, 2008
8. Meijer OW et al: Tumor-volume changes after radiosurgery for vestibular schwannoma: implications for follow-up MR imaging protocol. AJNR Am J Neuroradiol. 29(5):906-10, 2008
9. Thamburaj K et al: Intratumoral microhemorrhages on T2*-weighted gradient-echo imaging helps differentiate vestibular schwannoma from meningioma. AJNR Am J Neuroradiol. 29(3):552-7, 2008
10. Maire JP et al: Twenty years' experience in the treatment of acoustic neuromas with fractionated radiotherapy: a review of 45 cases. Int J Radiat Oncol Biol Phys. 66(1):170-8, 2006
11. Furuta S et al: Prediction of the origin of intracanalicular neoplasms with high-resolution MR imaging. Neuroradiology. 47(9):657-63, 2005
12. Dubrulle F et al: Cochlear fossa enhancement at MR evaluation of vestibular Schwannoma: correlation with success at hearing-preservation surgery. Radiology. 215(2):458-62, 2000
13. Nakamura H et al: Serial follow-up MR imaging after gamma knife radiosurgery for vestibular schwannoma. AJNR Am J Neuroradiol. 21(8):1540-6, 2000
14. Allen RW et al: Low-cost high-resolution fast spin-echo MR of acoustic schwannoma: an alternative to enhanced conventional spin-echo MR? AJNR Am J Neuroradiol. 17(7):1205-10, 1996

https://CafePezeshki.IR

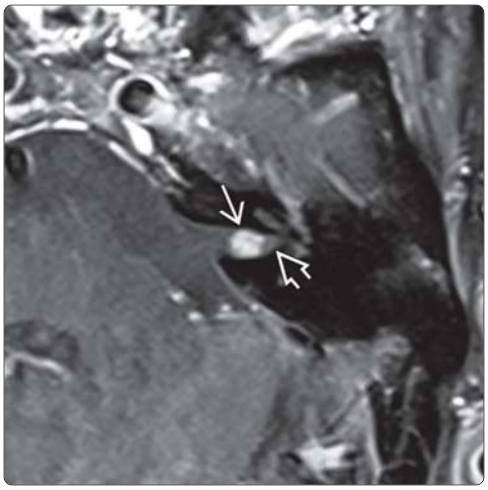

(Left) *Axial T1WI C+ FS MR in a patient with left sensorineural hearing loss shows a small enhancing vestibular schwannoma within the internal auditory canal with a 3 mm fundal CSF cap lateral to the tumor.* **(Right)** *Axial CISS MR in the same patient reveals a "filling defect" within the high signal CSF in the IAC. The vestibular schwannoma is easily diagnosed with CISS imaging. The fundal CSF cap is more readily seen with T2 or CISS MR.*

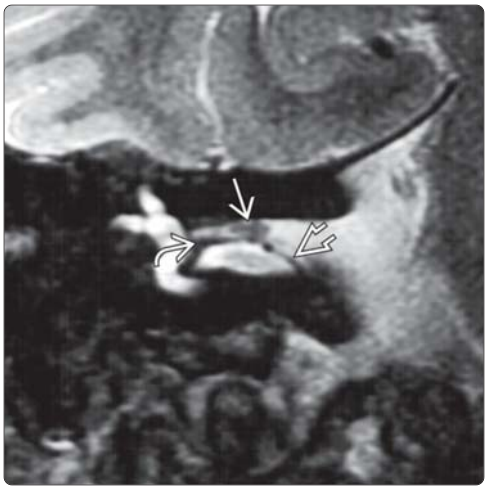

(Left) *Coronal high-resolution thin-section T2WI MR demonstrates a 2 mm superior vestibular schwannoma. The lesion is seen superior to the crista falciformis with the anterior inferior cerebellar artery loop visible in the lateral IAC.* **(Right)** *Axial T2* GRE MR reveals punctate microhemorrhages in the CPA component of a larger vestibular schwannoma. When present this finding is highly suggestive of vestibular schwannoma.*

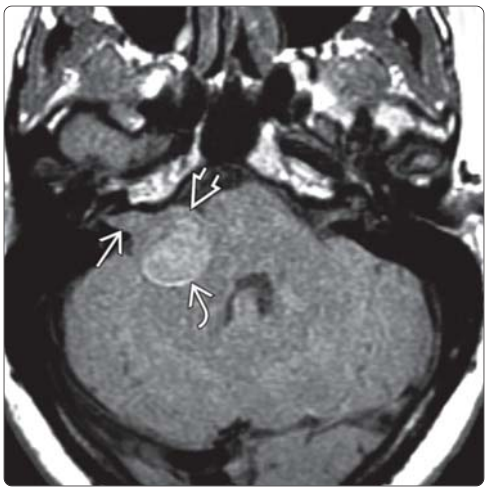

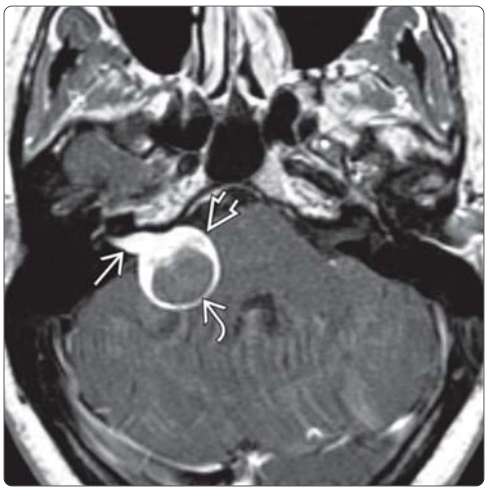

(Left) *Axial T1WI MR reveals the IAC and CPA components of a larger vestibular schwannoma. Increased signal in the medial CPA portion of this tumor is due to methemoglobin from a subacute intratumoral hemorrhage.* **(Right)** *Axial T1WI C+ MR in the same patient shows an enhancing vestibular schwannoma with IAC and CPA components. The medial CPA intramural cystic change is due to hemorrhage.*

https://CafePezeshki.IR

KEY FACTS

TERMINOLOGY

- Definition: Benign, unencapsulated neoplasm arising from meningothelial arachnoid cells of CPA-IAC dura

IMAGING

- 10% occur in posterior fossa
- When in CPA, asymmetric to IAC porus acusticus
- NECT: 25% calcified; 2 types seen
  - Homogeneous, sand-like (psammomatous)
  - Focal "sunburst," globular, or rim pattern
- Bone CT: Hyperostotic or permeative-sclerotic bone changes possible (en plaque type)
- T2WI MR: Pial blood vessels seen as surface flow voids between tumor and brain
  - High signal crescent from CSF ("CSF cleft")
- T1WI C+ MR: Enhancing dural-based mass with dural "tails" centered along posterior petrous wall
  - When IAC tail present, usually dural reaction, not tumor

TOP DIFFERENTIAL DIAGNOSES

- Vestibular schwannoma
- Epidermoid cyst, CPA-IAC
- Dural metastases, CPA-IAC
- Sarcoidosis, CPA-IAC
- Idiopathic inflammatory pseudotumor

CLINICAL ISSUES

- 2nd most common CPA tumor
- Slow-growing tumor, displacing adjacent structures
- Often found as incidental brain MR finding
- < 10% symptomatic
  - Usually do not cause sensorineural hearing loss
- Treatment
  - Follow with imaging if smaller size and older patient
  - Surgical removal if medically safe
  - Adjunctive radiation therapy with incomplete surgery

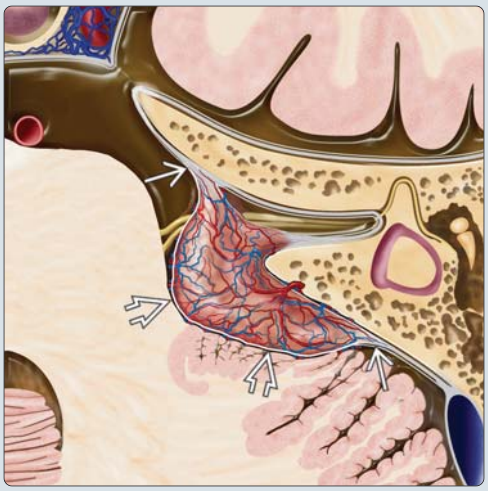

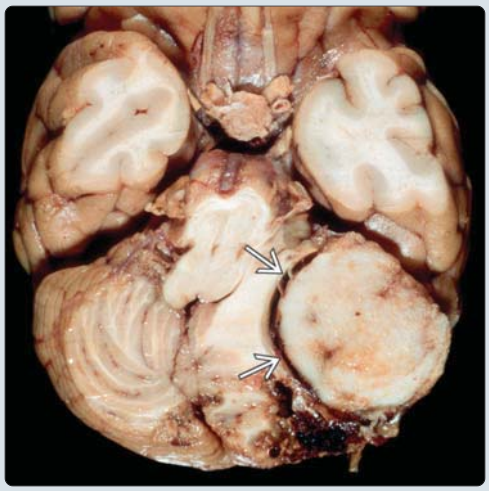

(Left) *Axial graphic at level of the IAC shows a large CPA meningioma causing mass effect on the brainstem and cerebellum. Notice the broad dural base creating the shape of a mushroom cap. Dural "tails" ⇨ are present in ~ 60% of cases, typically representing reactive rather than neoplastic change. CSF-vascular cleft is also visible ⇨.* **(Right)** *Gross pathologic section viewed from below shows a large CPA meningioma with a broad dural base compressing the cerebellum. The specimen demonstrates a CSF-vascular cleft ⇨.*

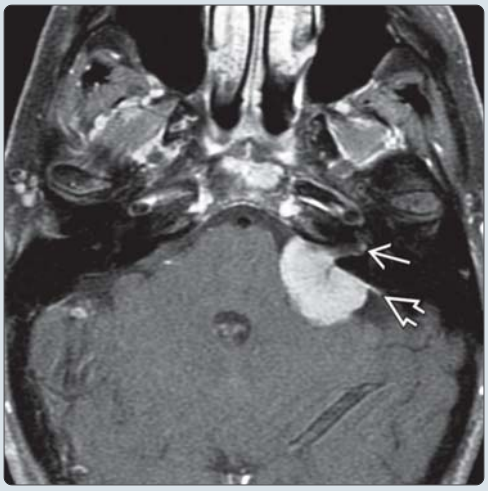

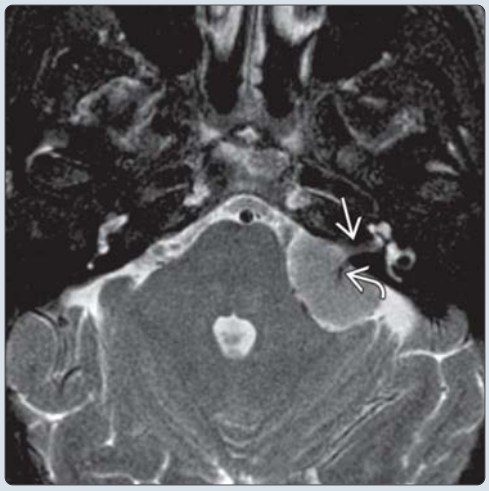

(Left) *Axial T1WI C+ FS MR through the IAC shows a meningioma overlying the porus acusticus. Note the dural "tail" ⇨ extending along the temporal bone posterior wall. A dot of enhancement in the IAC fundus ⇨ suggests that the low signal area in the IAC is a nonenhancing meningioma.* **(Right)** *Axial T2WI FS MR in the same patient reveals a high-velocity flow void ⇨ representing a dural artery feeder penetrating the meningioma core. Low signal in the IAC ⇨ is a intracanalicular meningioma.*

https://CafePezeshki.IR

TERMINOLOGY

Definitions

- Benign, unencapsulated neoplasm arising from meningothelial arachnoid cells of CPA-IAC dura

IMAGING

General Features

- Best diagnostic clue
  - CPA dural-based enhancing mass with **dural "tails"**
- Location
  - 10% occur in posterior fossa
  - When in CPA, **asymmetric** to IAC porus acusticus
- Size
  - Broad range; usually 1-8 cm but may be larger
  - Generally significantly larger than vestibular schwannoma at presentation
- Morphology
  - 3 distinct morphologies
    - "Mushroom cap" (hemispherical) with broad base toward posterior petrous wall (75%)
    - Plaque-like (en plaque), ± bone invasion with hyperostosis (20%)
    - Ovoid mass mimics vestibular schwannoma (5%)
  - Larger lesions often herniate superiorly through incisura into medial middle cranial fossa

CT Findings

- NECT
  - 25% isodense, 75% hyperdense
  - 25% calcified; 2 types seen
    - Homogeneous, sand-like (psammomatous)
    - Focal "sunburst," globular, or rim pattern
- CECT
  - > 90% have strong, uniform enhancement
- Bone CT
  - Hyperostotic or permeative-sclerotic bone changes possible (en plaque type)
  - IAC widening is rare (seen with vestibular schwannoma)

MR Findings

- T1WI
  - Isointense or minimally hyperintense to gray matter
  - When tumor has calcifications or is highly fibrous, hypointense areas are visible
- T2WI
  - Wide range of possible signals on T2 sequence
    - Isointense or hypointense CPA mass (compared to gray matter) is most likely meningioma
    - Focal or diffuse parenchymal low signal seen if calcified or highly fibrous
  - **CSF-vascular cleft**
    - Pial blood vessels seen as surface flow voids between tumor and brain
    - High-signal crescent from CSF
  - Tumor arterial feeders seen as arborizing flow voids
  - High signal in adjacent brainstem or cerebellum
    - Represents peritumoral brain edema
    - Correlates with pial blood supply
    - Signals problems with safe removal
- T2* GRE
  - Calcifications may "bloom"
- T1WI C+
  - Enhancing **dural-based mass** with **dural "tails"** centered along posterior petrous wall
    - > 95% enhance strongly
    - Heterogeneous enhancement when large
  - Dural "tail" in ~ 60%
    - Represents **reactive** rather than neoplastic change in most cases
    - When extending into IAC, may mimic IAC component of vestibular schwannoma
  - En plaque: Sessile, thickened enhancing dura

Angiographic Findings

- Digital subtraction angiography
  - Dural vessels supply tumor center, **pial vessels** supply **tumor rim**
  - "Sunburst" pattern: Enlarged dural feeders
  - Prolonged vascular "stain" into venous phase
- Interventional: Preoperative embolization
  - ↓ operative time and blood loss
  - Particulate agents favored (e.g., polyvinyl alcohol)
  - Optimal interval between embolization and surgery is 7-9 days
    - Allows for greatest tumor softening

Imaging Recommendations

- Best imaging tool
  - Enhanced MR focused to posterior fossa
  - Bone CT if bone invasion suspected on MR
- Protocol advice
  - Full brain T2 ± FLAIR shows brain edema best

DIFFERENTIAL DIAGNOSIS

Vestibular Schwannoma

- Intracanalicular 1st, then CPA extension
- Intracanalicular meningioma may mimic

Epidermoid Cyst, CPA-IAC

- Near CSF signal insinuating mass on MR
- DWI high signal characteristic

Dural Metastases, CPA-IAC

- May be bilateral in CPA area
- Multifocal meningeal involvement

Sarcoidosis, CPA-IAC

- Often multifocal, dural-based foci
- Look for infundibular stalk involvement

Idiopathic Inflammatory Pseudotumor

- Diffuse or focal meningeal thickening
- CPA involvement is rare

PATHOLOGY

General Features

- Etiology
  - Arises from arachnoid ("cap") meningothelial cells
  - Radiation therapy (XRT) predisposes

https://CafePezeshki.IR

  - Most common radiation-induced tumor; latency 20-35 years
- Genetics
  - Long arm deletions of chromosome 22 are common
  - *NF2* gene inactivated in 90% of sporadic cases
  - May have progesterone, prolactin receptors; may express growth hormone
- Associated abnormalities
  - Neurofibromatosis type 2 (NF2)
    - 10% of multiple meningiomas have NF2
    - Meningioma + schwannoma = NF2
    - Multiple inherited schwannomas, meningiomas, and ependymomas (MISME)

Staging, Grading, & Classification

- WHO grading classification (grades I-III)
  - Typical meningioma (grade I, benign) = 90%
  - Atypical meningioma (grade II) = 9%
  - Malignant (anaplastic) meningioma (grade III) = 1%

Gross Pathologic & Surgical Features

- "Mushroom cap" (globose, hemispherical) morphology most common (75%)
- En plaque morphology (20%) also seen in CPA
- Sharply circumscribed, unencapsulated
- Adjacent dural thickening (collar or "tail") is usually reactive, not neoplastic

Microscopic Features

- Subtypes (wide range of histology with little bearing on imaging appearance or clinical outcome)
  - Meningothelial (lobules of meningothelial cells)
  - Fibrous (parallel, interlacing fascicles of spindle-shaped cells)
  - Transitional (mixed; "onion-bulb" whorls and lobules)
  - Angiomatous (↑ vascular channels), not equated with obsolete term "angioblastic meningioma"
  - Lipoblastic: Metaplasia into adipocytes; large triglyceride fat droplets
  - Miscellaneous forms (microcystic, chordoid, clear cell, secretory, lymphoplasmacyte-rich, etc.)

CLINICAL ISSUES

Presentation

- Most common signs/symptoms
  - Incidental brain MR finding
  - < 10% symptomatic
- Clinical profile
  - Adult undergoing brain MR for unrelated indication

Demographics

- Age
  - Middle-aged, elderly; peak = 60 years old
  - If found in children, consider possibility of NF2
- Gender
  - M:F = 1:1.5-3
- Ethnicity
  - More common in African Americans
- Epidemiology
  - Accounts for ~ 20% of primary intracranial tumors
    - Most common primary nonglial tumor
  - 1-1.5% prevalence at autopsy or imaging
  - 10% multiple (NF2; multiple meningiomatosis)
  - 2nd most common CPA-IAC mass

Natural History & Prognosis

- Slow-growing tumor
- Compresses rather than invades structures
- Negative prognostic findings on MR
  - Peritumoral edema in adjacent brainstem
  - Significant subjacent bone invasion

Treatment

- Asymptomatic: Follow with serial imaging if smaller tumor or older patient
- Surgical removal if medically safe
  - Complete surgical removal possible in 95% when tumor does not invade skull base
- Radiation therapy
  - Adjunctive therapy with incomplete surgery
  - Primary therapy if extensive skull base invasion

DIAGNOSTIC CHECKLIST

Consider

- Meningioma when MR shows hemispherical, dural-based enhancing CPA mass with dural "tails"
- Meningioma when CPA mass is large but asymptomatic

Image Interpretation Pearls

- Focal or diffuse hypointensity on T2 in CPA mass suggests meningioma
- Dural "tail" in IAC suggests meningioma

Reporting Tips

- Report extent of meningioma, including intraosseous component
  - Mention cranial nerves in area of involvement
  - Note any brainstem or brain edema indicating pia-arachnoid involvement

SELECTED REFERENCES

1. Park SH et al: Stereotactic radiosurgery for cerebellopontine angle meningiomas. J Neurosurg. 120(3):708-15, 2014
2. Agarwal V et al: Cerebellopontine angle meningiomas: postoperative outcomes in a modern cohort. Neurosurg Focus. 35(6):E10, 2013
3. Zeidman LA et al: Growth rate of non-operated meningiomas. J Neurol. 255(6):891-5, 2008
4. Nakamura M et al: Facial and cochlear nerve function after surgery of cerebellopontine angle meningiomas. Neurosurgery. 57(1):77-90; discussion 77-90, 2005
5. Roser F et al: Meningiomas of the cerebellopontine angle with extension into the internal auditory canal. J Neurosurg. 102(1):17-23, 2005
6. Asaoka K et al: Intracanalicular meningioma mimicking vestibular schwannoma. AJNR Am J Neuroradiol. 23(9):1493-6, 2002
7. Filippi CG et al: Appearance of meningiomas on diffusion-weighted images: correlating diffusion constants with histopathologic findings. AJNR Am J Neuroradiol. 22(1):65-72, 2001
8. Kuratsu J et al: Incidence and clinical features of asymptomatic meningiomas. J Neurosurg. 92(5):766-70, 2000
9. Yoshioka H et al: Peritumoral brain edema associated with meningioma: influence of vascular endothelial growth factor expression and vascular blood supply. Cancer. 85(4):936-44, 1999
10. Haught K et al: Entirely intracanalicular meningioma: contrast-enhanced MR findings in a rare entity. AJNR Am J Neuroradiol. 19(10):1831-3, 1998

https://CafePezeshki.IR

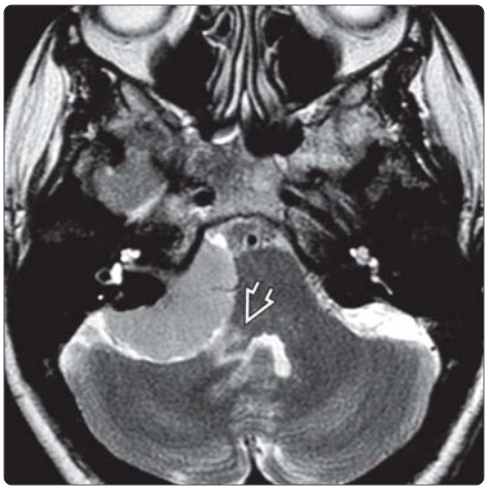

(Left) *Axial T1WI C+ MR demonstrates a large CPA meningioma with an IAC component. This degree and depth of IAC enhancement usually signifies tumor rather than dural reaction.* **(Right)** *Axial T2WI MR in the same patient reveals high signal in the adjacent brachium pontis. Pial invasion by the meningioma is likely. This MR finding is predictive of an increased risk of complications when surgical removal occurs.*

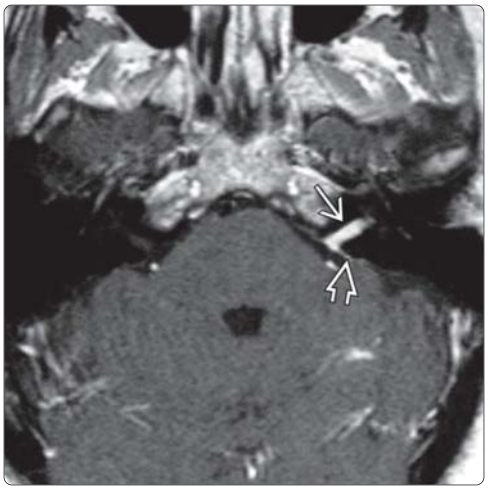

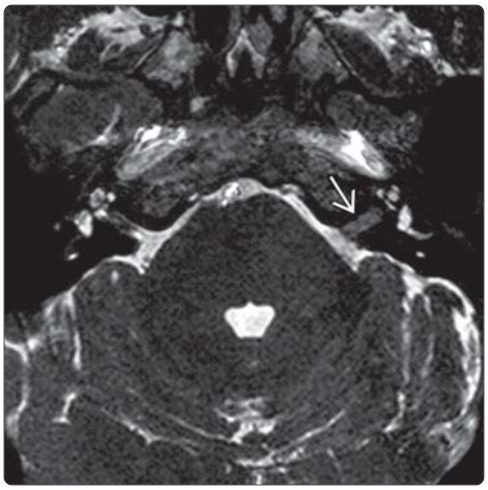

(Left) *Axial T1WI C+ MR shows an enhancing intracanalicular mass. Subtle dural "tails" along the posterior margin of the porus acusticus suggest but do not definitively diagnose meningioma.* **(Right)** *Axial T2WI MR in the same patient reveals the intracanalicular meningioma as low signal tissue filling the IAC. Often IAC meningioma cannot be reliably distinguished from IAC vestibular schwannoma, the most common lesion in this location.*

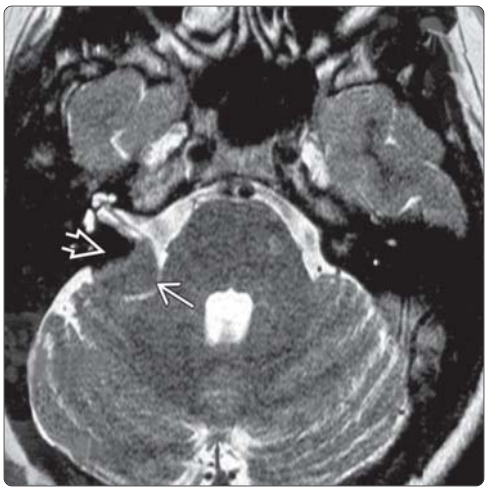

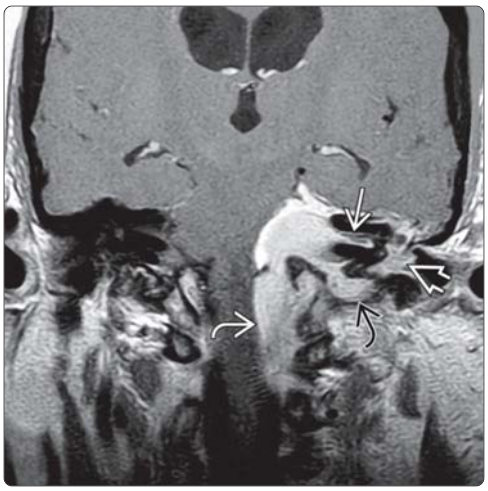

(Left) *Axial T2WI MR shows a gray matter signal intensity meningioma abutting the posterior wall of the temporal bone. Note the underlying dark signal of bony hyperostosis. Despite the tumor abutting CN7-8 along the posterior margin of the porus acusticus, the patient did not have hearing loss.* **(Right)** *Coronal T1WI C+ MR shows a large enhancing CPA meningioma. Note that the IAC, middle ear, and jugular foramen are filled with tumor. Tumor extends through the foramen magnum.*

https://CafePezeshki.IR

KEY FACTS

TERMINOLOGY

- Definition: CPA-IAC metastases refers to systemic or CNS neoplasia affecting area of CPA-IAC

IMAGING

- 4 major sites: Leptomeningeal (pia-arachnoid), dura, flocculus, and choroid plexus
- T1WI C+ MR
  - **Leptomeningeal metastases**: Diffuse thickening and enhancement of cranial nerves in IAC
  - **Dural metastases**: Thickened enhancing dura; may be diffuse or focal
  - **Floccular metastases**: Enhancing floccular mass extends into CPA cistern
  - **Choroid plexus metastases**: Enhancing nodular lesion along normal course of choroid plexus
  - Focal, enhancing brain metastases may be present
- FLAIR MR
  - Parenchymal brain metastases usually high signal

TOP DIFFERENTIAL DIAGNOSES

- Bilateral vestibular schwannoma (NF2)
- Sarcoidosis
- Meningitis
- Ramsay Hunt syndrome

CLINICAL ISSUES

- Rapidly progressive unilateral or bilateral facial nerve paralysis and sensorineural hearing loss
- Patient with past history of treated malignancy

DIAGNOSTIC CHECKLIST

- If trying to diagnose bilateral "vestibular schwannoma" in adult as NF2, probably CPA metastases instead
- Rapidly progressive 7th & 8th cranial nerve palsies + CPA mass suggests metastatic focus
  - Vestibular schwannoma rarely causes CN7 palsy

(Left) *Axial graphic depicts the 4 major types of CPA-IAC area metastases. Along the posterolateral margin of the IAC, thickened dural metastases ⇨ are visible. Within the IAC metastatic leptomeningeal (pia-arachnoid) ⇨ involvement is present. Choroid plexus ⇨ and floccular ⇨ metastases are also depicted.* **(Right)** *Axial T1WI C+ MR shows bilateral leptomeningeal breast carcinoma metastases ⇨ within the internal auditory canals. The left-sided disease is more subtle than the right.*

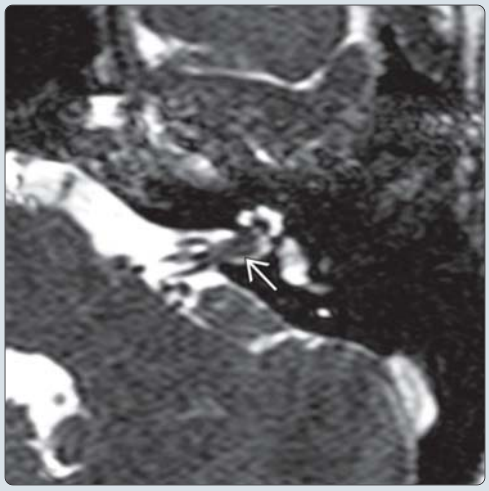

(Left) *Axial T2WI MR demonstrates right IAC leptomeningeal metastatic foci as thickening of the branches of CN7 and CN8 ⇨ within the internal auditory canal.* **(Right)** *Axial T2WI MR reveals left IAC metastatic disease as subtle thickening of the branches of CN7 and CN8 ⇨ within the internal auditory canal. In an adult patient with suspected "bilateral vestibular schwannoma," consider metastatic disease rather than NF2.*

https://CafePezeshki.IR

TERMINOLOGY

Abbreviations

- Metastases (mets)

Synonyms

- Leptomeningeal carcinomatosis, meningeal carcinomatosis, carcinomatous meningitis
  - All of the above terms are misnomers for the following reasons
    - Neoplasms are not always carcinomas
    - Pachymeninges (dura) and leptomeninges (pia + arachnoid) are often both involved
    - Usually does not contain inflammatory component
      - -itis suffix makes no sense

Definitions

- CPA-IAC metastases: Systemic or central nervous system (CNS) neoplasia affecting area of CPA-IAC

IMAGING

General Features

- Best diagnostic clue
  - Multiple enhancing masses on T1WI C+ MR
- Location
  - 4 major sites: **Leptomeningeal (pia-arachnoid), dura, flocculus, and choroid plexus**
  - Primary site locations
    - Primary tumors: Breast, lung, and melanoma
    - Meningeal lymphoproliferative malignancy
      - Lymphoma and leukemia
    - Primary CNS tumor seeds basal cisterns via cerebrospinal fluid (CSF) pathways: "Drop" metastases
- Size
  - Often small (< 1 cm)
    - Metastases cause symptoms early
- Morphology
  - Leptomeningeal: Thickened CN7 and CN8 in IAC
  - Dura: Diffuse dural thickening (pachymeninges)
  - Flocculus: Enlarged flocculus with associated brain edema; mass extends into CPA cistern
  - Choroid plexus: Nodular thickening

CT Findings

- CECT
  - Unilateral or bilateral dural enhancement along CPA
  - CT shows metastases only when larger ± multiple

MR Findings

- T1WI
  - Focal dural thickening isointense to gray matter
- T2WI
  - High-resolution T2 MR
    - Leptomeningeal metastases: CN7 and CN8 thickening
    - Floccular metastases: ↑ signal edema associated
- FLAIR
  - Larger CPA-IAC metastases may cause ↑ signal in adjacent brainstem ± cerebellum
  - Floccular metastases seen as ↑ signal
- T1WI C+
  - **Leptomeningeal metastases**: Diffuse thickening and enhancement of cranial nerves in IAC
    - Late finding shows plug of enhancing tissue in IAC
    - Unilateral or bilateral
  - **Dural metastases**: Thickened enhancing dura; may be focal or diffuse
    - Associated with other dural or skull lesions
  - **Floccular metastases**: Enhancing floccular mass
  - **Choroid plexus metastases**: Enhancing nodular lesion along normal course of choroid plexus
    - Lateral recess 4th ventricle → foramen of Luschka → inferior CPA cistern
  - Focal, enhancing brain metastases may be present

Imaging Recommendations

- Best imaging tool
  - T1WI C+ MR of posterior fossa is best imaging tool and sequence
  - Whole-brain FLAIR and T1WI C+ for associated brain metastases
- Protocol advice
  - Axial and coronal planes recommended

DIFFERENTIAL DIAGNOSIS

Bilateral Vestibular Schwannoma (NF2)

- Younger patients; no history of malignancy
- T1WI C+ MR shows bilateral CPA-IAC enhancing masses
  - Mimics bilateral leptomeningeal metastases
- Other cranial nerve schwannoma ± meningiomas possible

Sarcoidosis, CPA-IAC

- ↑ erythrocyte sedimentation rate (ESR) and serum angiotensin converting enzyme (ACE)
- T1WI C+ MR may be identical to metastases when multifocal meningeal type
  - May be bilateral CPA lesions mimicking neurofibromatosis 2 (NF2) or metastases
  - May be single, en plaque focus mimicking meningioma
- Look for infundibular stalk involvement

Meningitis, CPA-IAC

- Bacterial meningitis
- Fungal meningitis
- Tuberculous meningitis
- T1WI C+ MR may be identical to CPA-IAC metastases
- Clinical information and CSF evaluation are key

Ramsay Hunt Syndrome

- External ear vesicular rash
- T1WI C+ MR shows enhancement in IAC fundus and inner ear ± 7th cranial nerve
  - Mimics unilateral leptomeningeal metastasis

PATHOLOGY

General Features

- Etiology
  - Metastatic tumor involves leptomeningeal or dural surfaces of CPA-IAC
    - Leptomeningeal metastases follow CN7 and CN8 into IAC
  - Metastatic tumor deposits in flocculus or choroid plexus

https://CafePezeshki.IR

- Routes of spread
  - Extracranial neoplasm spreads hematogenously to meninges
  - CSF spread from intracranial or intraspinal neoplasm is less common
- Associated abnormalities
  - Multiple other pial or dural metastatic foci
  - Parenchymal brain metastases also possible
    - Pia + arachnoid = **leptomeninges**
- Key anatomy: Meninges has 3 discrete layers
  - **Dura** (pachymeninges): Dense connective tissue attached to calvaria
  - **Arachnoid**: Interposed between pia and dura
  - **Pia**: Clear membrane firmly attached to surface of brain; extends deeply into sulci

Gross Pathologic & Surgical Features

- Diffuse, nodular ± discrete

Microscopic Features

- Common tissue types found
  - Solid tumors = breast, lung, and melanoma
    - All involve both leptomeninges and pachymeninges
  - Lymphoproliferative malignancy = lymphoma and leukemia
    - Involve both leptomeninges and pachymeninges
  - "Drop" metastases from CNS tumors
    - Medulloblastoma, ependymoma, glioblastoma multiforme

CLINICAL ISSUES

Presentation

- Most common signs/symptoms
  - **Rapidly progressive** unilateral or bilateral facial nerve (CN7) paralysis and sensorineural hearing loss (CN8)
- Other signs/symptoms
  - Vertigo and polycranial neuropathy
- Clinical profile
  - Patient with past history of treated malignancy

Demographics

- Age
  - Older adults
- Epidemiology
  - Increasingly more common neurologic complication of systemic cancer
    - Due to increase in survival rate of cancer patients

Natural History & Prognosis

- Meningeal metastases usually late-stage finding
- Poor prognosis as patients have advanced, incurable disease by definition

Treatment

- No curative treatments available
- Therapies aimed at preserving neurologic function and improving quality of life
- Treatments are same as for underlying neoplasm
  - Radiotherapy ± chemotherapy depending on tissue type
- Surgery will rarely play role at this stage
  - Solitary melanoma metastases may be exception
- If any question of diagnosis, excisional biopsy necessary

DIAGNOSTIC CHECKLIST

Consider

- If trying to diagnose bilateral "vestibular schwannoma" in adult as NF2, probably CPA metastases instead
- Rapidly progressive 7th cranial nerve palsy + sensorineural hearing loss with CPA mass suggests metastatic focus
  - Vestibular schwannoma rarely causes CN7 palsy

Image Interpretation Pearls

- If suspect CPA-IAC metastasis from T1WI C+ MR appearance or history of known malignancy, make sure to review
  - Extracranial and calvarial structures for other lesions to confirm diagnosis
  - Look for involvement of other meningeal sites, such as parasellar, other basal meninges
  - Parenchymal brain for abnormal FLAIR high signal ± enhancing lesions on T1WI C+ sequences

SELECTED REFERENCES

1. Lee EK et al: Intracranial metastases: spectrum of MR imaging findings. Acta Radiol. 53(10):1173-85, 2012
2. Warren FM et al: Imaging characteristics of metastatic lesions to the cerebellopontine angle. Otol Neurotol. 29(6):835-8, 2008
3. Siomin VE et al: Posterior fossa metastases: risk of leptomeningeal disease when treated with stereotactic radiosurgery compared to surgery. J Neurooncol. 67(1-2):115-21, 2004
4. Soyuer S et al: Intracranial meningeal hemangiopericytoma: the role of radiotherapy: report of 29 cases and review of the literature. Cancer. 100(7):1491-7, 2004
5. Kesari S et al: Leptomeningeal metastases. Neurol Clin. 21(1):25-66, 2003
6. Krainik A et al: MRI of unusual lesions in the internal auditory canal. Neuroradiology. 43(1):52-7, 2001
7. Schick B et al: Magnetic resonance imaging in patients with sudden hearing loss, tinnitus and vertigo. Otol Neurotol. 22(6):808-12, 2001
8. Whinney D et al: Primary malignant melanoma of the cerebellopontine angle. Otol Neurotol. 22(2):218-22, 2001
9. Cha ST et al: Cerebellopontine angle metastasis from papillary carcinoma of the thyroid: case report and literature review. Surg Neurol. 54(4):320-6, 2000
10. Shen TY et al: Meningeal carcinomatosis manifested as bilateral progressive sensorineural hearing loss. Am J Otol. 21(4):510-2, 2000
11. Zamani AA: Cerebellopontine angle tumors: role of magnetic resonance imaging. Top Magn Reson Imaging. 11(2):98-107, 2000
12. Lewanski CR et al: Bilateral cerebellopontine metastases in a patient with an unknown primary. Clin Oncol (R Coll Radiol). 11(4):272-3, 1999
13. Swartz JD: Meningeal metastases. Am J Otol. 20(5):683-5, 1999
14. Arriaga MA et al: Metastatic melanoma to the cerebellopontine angle. Clinical and imaging characteristics. Arch Otolaryngol Head Neck Surg. 121(9):1052-6, 1995
15. Kingdom TT et al: Isolated metastatic melanoma of the cerebellopontine angle: case report. Neurosurgery. 33(1):142-4, 1993
16. Mark AS et al: Sensorineural hearing loss: more than meets the eye? AJNR Am J Neuroradiol. 14(1):37-45, 1993
17. Yuh WT et al: Metastatic lesions involving the cerebellopontine angle. AJNR Am J Neuroradiol. 14(1):99-106, 1993
18. Lee YY et al: Loculated intracranial leptomeningeal metastases: CT and MR characteristics. AJR Am J Roentgenol. 154(2):351-9, 1990
19. Maiuri F et al: Cerebellar metastasis from prostatic carcinoma simulating, on CT-scan, a cerebellopontine angle tumor. Case report. Acta Neurol (Napoli). 11(1):21-4, 1989
20. Gentry LR et al: Cerebellopontine angle-petromastoid mass lesions: comparative study of diagnosis with MR imaging and CT. Radiology. 162(2):513-20, 1987

https://CafePezeshki.IR

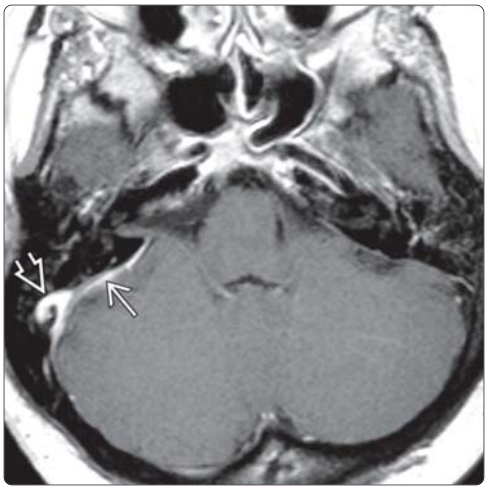

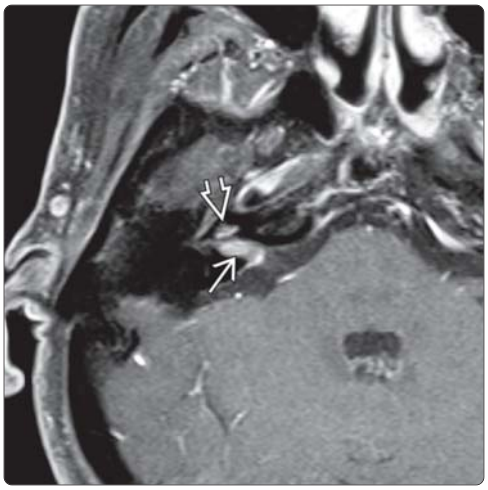

(Left) *Axial T1WI C+ MR reveals dural lung carcinoma metastases ⇨ in the CPA region. The enhancing, thickened dura should be distinguished from the enhancement in the normal sigmoid sinus ⇨. CSF examination was positive for malignant cells.* **(Right)** *Axial T1WI C+ FS MR shows an enhancing metastasis in the right IAC ⇨ with extension of enhancing tissue through the cochlear nerve canal, across the modiolus into the membranous labyrinth of the cochlea ⇨.*

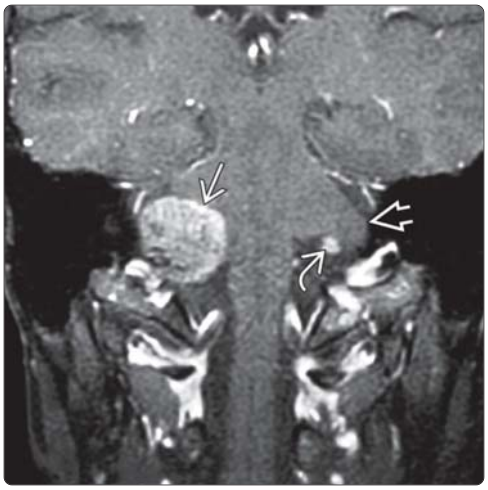

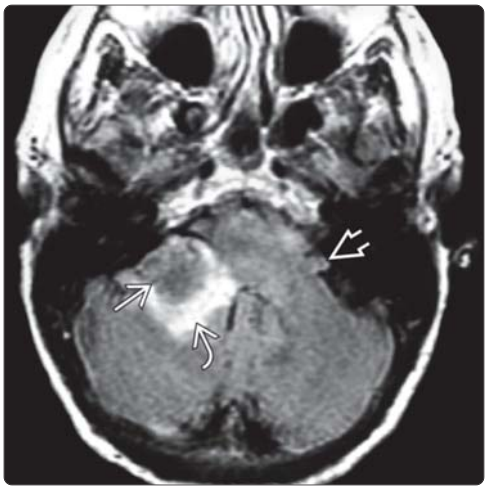

(Left) *Coronal T1WI C+ MR depicts an enhancing breast carcinoma metastasis ⇨ centered within the right flocculus. Note the normal flocculus ⇨ and cisternal choroid plexus ⇨.* **(Right)** *Axial FLAIR MR in the same patient shows the mass ⇨ to be slightly lower in signal than the adjacent gray matter. Vasogenic edema within the brachium pontis and cerebellum ⇨ is seen as high signal. The left flocculus ⇨ is normal.*

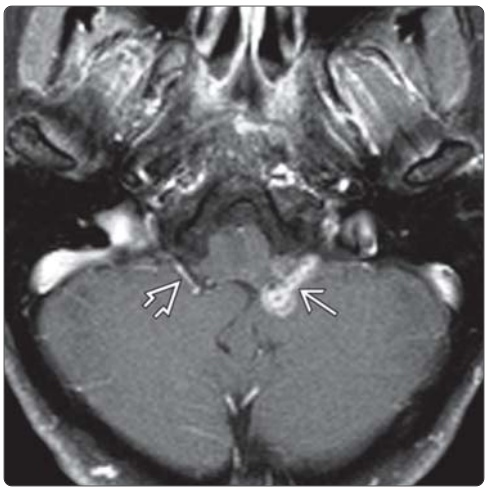

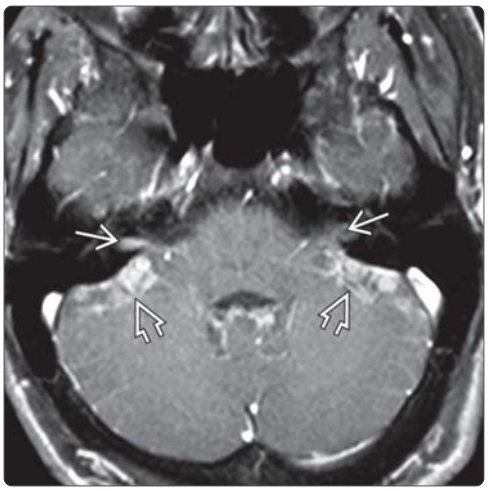

(Left) *Axial T1WI C+ FS MR in a patient with known metastatic rectal carcinoma shows an enhancing metastasis ⇨ of the choroid plexus projecting into the low CPA cistern through the foramen of Luschka. The normal right choroid plexus ⇨ is seen.* **(Right)** *Axial T1WI C+ FS reveals bilateral CPA-IAC "drop" metastases from a supratentorial glioblastoma multiforme. Bilateral IAC enhancing metastases ⇨ are seen along with multiple leptomeningeal metastases on the cerebellar surface ⇨.*

https://CafePezeshki.IR

This page intentionally left blank

https://CafePezeshki.IR

PART II
SECTION 4

Skull, Scalp, and Meninges

Skull, Scalp, & Meninges Overview 1104

Congenital

Congenital Calvarial Defects 1108
Craniostenoses 1112
Cephalocele 1116
Atretic Cephalocele 1122

Trauma

Leptomeningeal Cyst ("Growing Fracture") 1126
Intracranial Hypotension 1128

Nonneoplastic and Tumor-Like Disorders

Intracranial Idiopathic Inflammation Pseudotumor 1132
IgG4-Related Disease 1136
Fibrous Dysplasia 1138
Paget Disease 1142
Extramedullary Hematopoiesis 1146
Thick Skull 1150
Langerhans Cell Histiocytosis, Skull and Brain 1152
Neurosarcoid 1156
Miscellaneous Histiocytoses 1160
Sebaceous Cyst 1164

Neoplasms

Meningioma 1166
Atypical and Malignant Meningioma 1172
Miscellaneous Benign Mesenchymal Tumors 1176
Miscellaneous Malignant Mesenchymal Tumors 1180
Calvarial Hemangioma 1184
Dura/Venous Sinuses Hemangioma 1188
Myeloma 1190
Skull and Meningeal Metastases 1194

https://CafePezeshki.IR

Overview

Understanding the anatomy of the skull, scalp, and meninges is key to formulating a correct imaging diagnosis. Several important differential diagnoses are based on location. Yet each of these locations requires a different imaging approach.

For example, CT is often the best imaging modality for lesions of the skull and scalp. When faced with a complex skull base lesion, a combination of bone CT and contrast-enhanced MR images is often required for optimal imaging. MR with contrast is the best imaging modality for meningeal processes.

Scalp

The scalp is made up of 5 layers including the dermis (skin), subcutaneous fibro-adipose tissue, epicranium and muscles, subaponeurotic areolar tissue, and pericranium. The first three layers are firmly connected and surgically act as a single layer.

The majority of scalp lesions are not imaged, as the area is easily accessible to both visual and manual inspection. Imaging becomes important when a scalp lesion is malignant or has a vascular component that could alter the surgical approach.

Skull Vault (Calvaria)

The calvaria is composed of 5 bones: Frontal, parietal, occipital, temporal, and sphenoid (greater wings) bones that are primarily connected by the major sutures, including the coronal, sagittal, and lambdoid sutures. The metopic suture is variably seen in adults.

There are many normal variants of the skull. These must be recognized to prevent misdiagnosis and unnecessary biopsy. Some of the most common skull normal variants include arachnoid granulations, vascular grooves from the meningeal arteries and veins, venous lakes, emissary veins, parietal thinning, asymmetric marrow (particularly in the petrous apex), aerated clinoid processes, and accessory sutures.

Meninges

Dura

The dura (or pachymeninges) is a thick, dense, fibrous connective tissue that is made up of 2 layers: An outer (peri- or endosteal) layer and an inner (meningeal) layer. These outer and inner layers are closely adherent and apposed except where they separate to enclose the venous sinuses.

The outer layer forms the periosteum of the calvaria, tightly attached to the inner table, particularly at the sutures. The inner layer folds to form the falx cerebri, tentorium, and diaphragma sellae. It also divides the cranial cavity into compartments. On imaging, the dura usually shows smooth, thin enhancement (< 2 mm).

The dura forms 2 important potential spaces. First, the epidural space is located between the dura and the inner table of the calvaria. Important lesions of the epidural space include hemorrhage related to trauma and infection causing an empyema, a rare but potentially lethal complication of sinusitis. Second, the subdural space is the potential space between the inner (meningeal) layer of the dura and the arachnoid. A traumatic subdural hematoma is the most common process to affect the subdural space (more accurately, it probably collects within the border cell layer along the inner margin of the dura). The subdural space may also be affected by infection, either a subdural effusion related to meningitis or a subdural empyema related to meningitis in a child or sinusitis in an adult.

Leptomeninges

The leptomeninges are formed by the arachnoid and pia. The arachnoid is loosely attached to the dural border cell layer. Pathologies often affect both the arachnoid and dura together, and the 2 areas cannot be easily differentiated on imaging.

The arachnoid is a thin, nearly transparent layer of meninges closely applied to the inner (meningeal) dura. It forms the outer margin of the subarachnoid space (SAS). It does not enter the sulci or fissures except along the falx where it dips into the interhemispheric fissure. Trabeculae extend from the arachnoid across the SAS to the pia and are invested with a thin pia-like layer. The SAS is a CSF-filled space between the arachnoid and pia.

The pia is a thin, delicate membrane closely applied to the brain. It covers vessels and trabeculae in the SAS and lines the perivascular spaces.

Perivascular (Virchow-Robin) spaces are normal variants. They appear as interstitial fluid-filled, pial-lined spaces that accompany penetrating arteries and veins.

Arachnoid Granulations

Arachnoid granulations are normal extensions of the SAS and arachnoid through the dural wall and into the venous sinuses. They are covered with arachnoid cap cells and venous sinus endothelium. CSF drains through the endothelium into the venous sinus. The most common locations for arachnoid granulations are the superior sagittal sinus and transverse sinuses. These normal variants are important "pseudolesions" to recognize, as they may be misdiagnosed as pathology. They are CSF density or intensity on imaging and do not enhance. They are often associated with bone changes on CT, particularly in the occipital bone.

Differential Diagnosis

The following differential diagnosis lists are provided to help organize the most common scalp, skull, and meningeal lesions.

Scalp Masses

- Subgaleal hematoma, foreign body (most common)
- Trichilemmal ("sebaceous") cyst
- Lipoma
- Dermoid
- Metastases (extension from calvaria)
- Vascular malformation (sinus pericranii in a child)
- Skin cancer (basal cell or squamous cell)

Calvarial Thickening

- Normal variant (most common)
- Chronic phenytoin (Dilantin) therapy
- Shunted hydrocephalus
- Paget disease
- Fibrous dysplasia
- Hyperparathyroidism
- Acromegaly
- Anemias

Calvarial Thinning

- Normal variants (parietal thinning) (most common)
- Arachnoid cyst
- Mega cisterna magna
- Peripherally located tumors (oligodendroglioma, DNET)

https://CafePezeshki.IR

"Hair on End"
- Classic appearance of anemias: Thalassemia, sickle cell disease, hereditary spherocytosis
- Skull hemangioma
- Metastases (commonly neuroblastoma and prostate cancer)

Lytic Skull Lesion
- Normal variant or surgical defects (most common)
- Metastases
- Epidermoid cyst
- Eosinophilic granuloma
- Hemangioma
- Paget disease
- Plasmacytoma
- Osteomyelitis

Sclerotic Skull Lesion
- Metastasis (most common)
- Osteoma
- Fibrous dysplasia
- Meningioma-associated
- Paget disease

Diffuse Dura-Arachnoid Enhancement
- Postoperative or post procedure (i.e., lumbar puncture)
- Chronic subdural hematoma
- Meningitis (leptomeningeal enhancement common)
- Neoplasm
- Neurosarcoid
- Intracranial hypotension (venous congestion)
- Hypertrophic pachymeningitis (may be IgG4-related)
- Dural sinus thrombosis

Pial Enhancement
- Meningitis (infectious or neoplastic); neurosarcoid

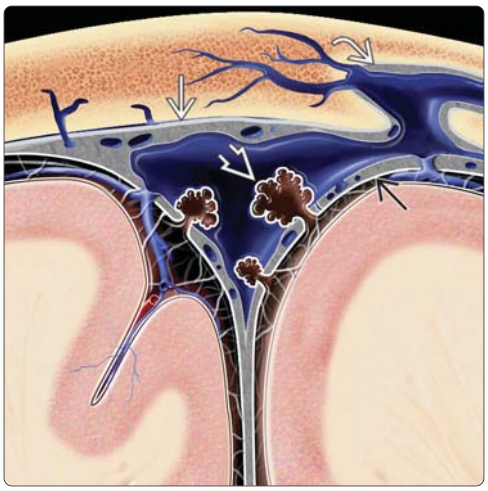

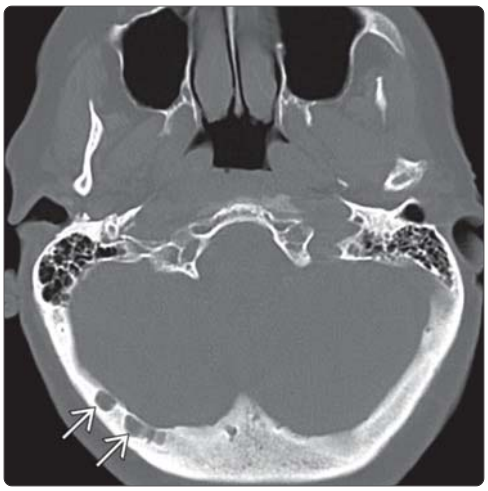

(Left) *Coronal graphic shows the calvarial apex with the superior sagittal sinus (SSS) and a venous lake. The SSS is formed by 2 dural layers, an outer (periosteal) layer and inner (meningeal) layer. Arachnoid granulations extend from the arachnoid into the SSS. The arachnoid is closely applied to the inner layer of dura.* **(Right)** *Axial bone CT shows multiple sharply marginated, lucent, occipital bone lesions adjacent to the transverse sinus, characteristic of arachnoid granulations.*

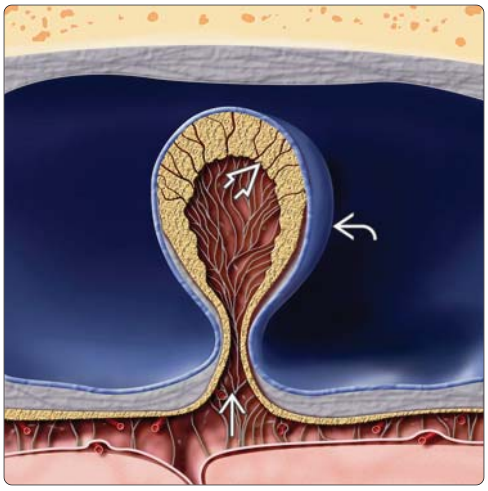

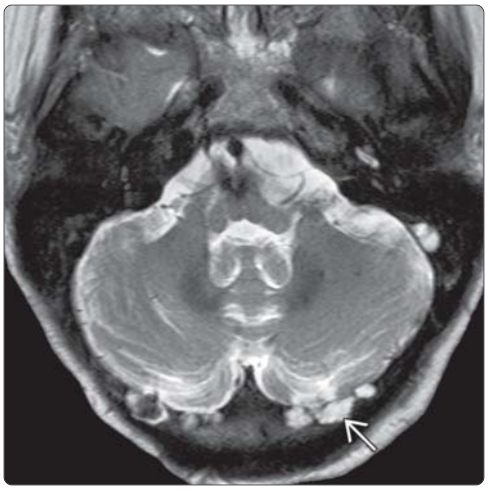

(Left) *Coronal graphic shows an arachnoid granulation projecting from the subarachnoid space (SAS) into the SSS. A CSF core extends into the arachnoid granulation and is separated by arachnoid cap cells from the venous sinus endothelium. Arachnoid granulations allow drainage of CSF into the venous circulation.* **(Right)** *Axial T2WI FS MR shows multiple CSF signal intensity lesions representing arachnoid granulations in the occipital bone, a typical location.*

https://CafePezeshki.IR

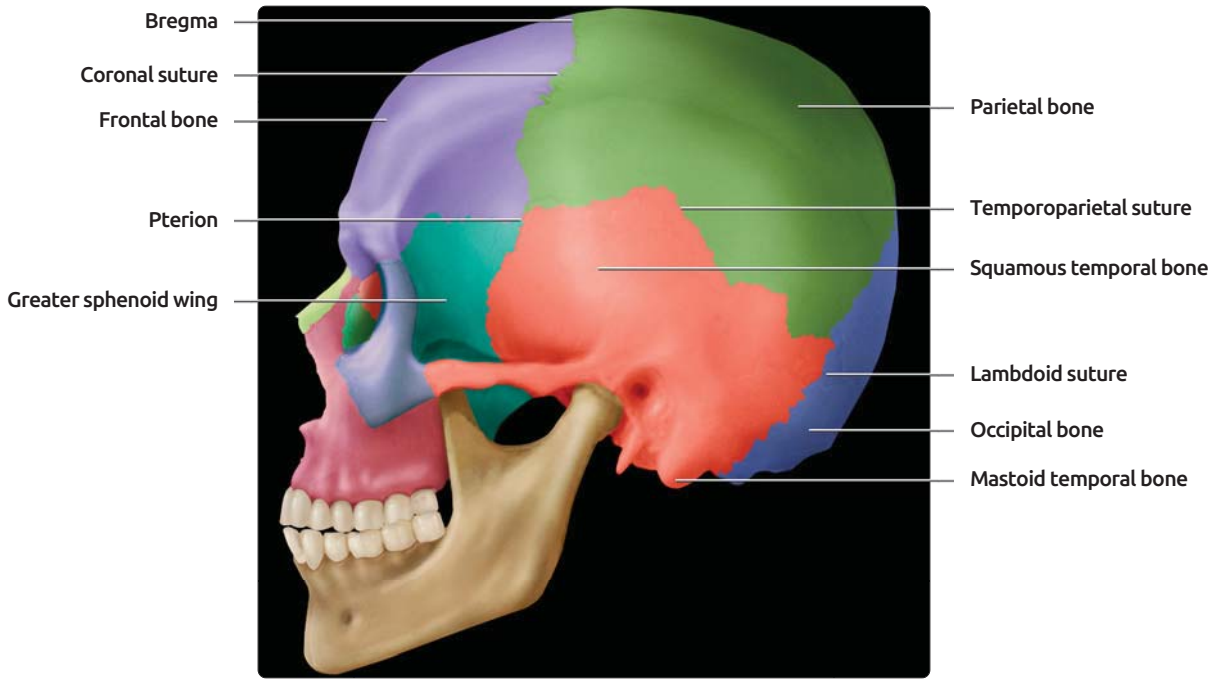

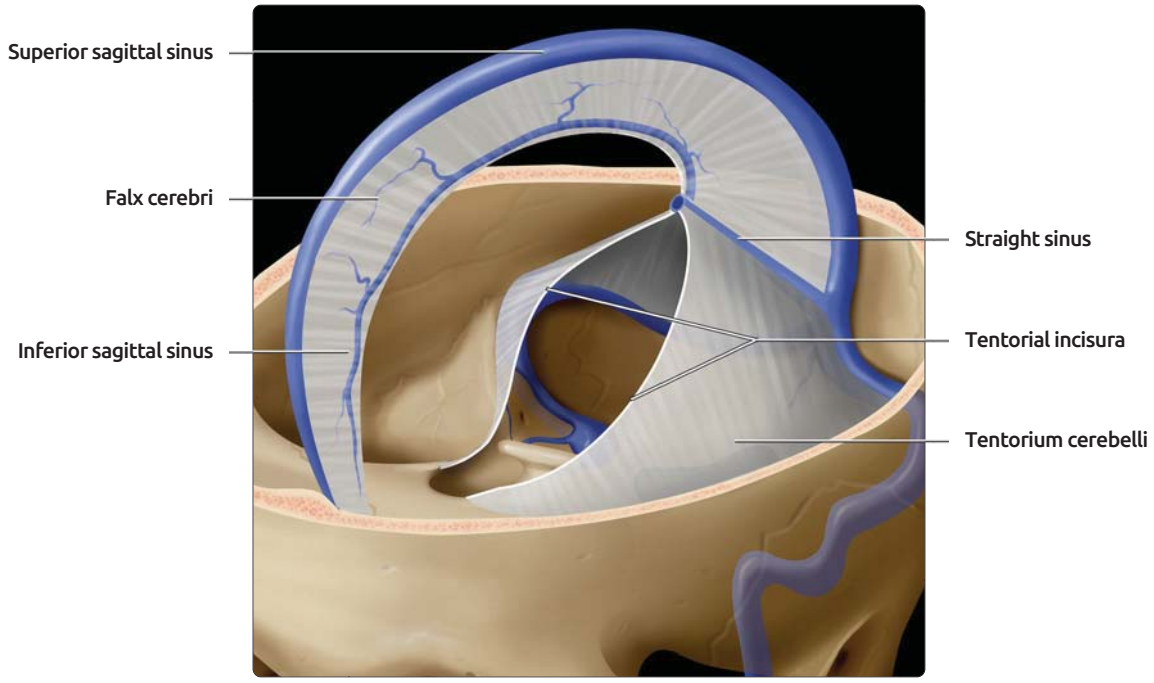

(Top) *Lateral view shows calvarial vault components. The pterion, an important surgical landmark, is a small area on the lateral skull at the intersection of the frontal, parietal, sphenoid, and squamosal temporal bones.* **(Bottom)** *Graphic shows the major dural sinuses as they relate to the falx cerebri and tentorium cerebelli. The falx inserts on the crista galli anteriorly and sweeps backwards in the midline to the straight sinus, becoming taller as it passes posteriorly. The tentorium meets the falx at the tentorial apex and curves downwards to contain the transverse sinuses. The leaves of the tentorium insert anteriorly on the petrous apex and fibers extend forward to the anterior clinoid processes.*

https://CafePezeshki.IR

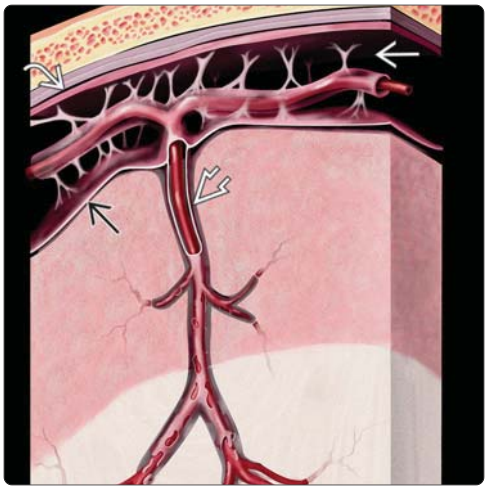

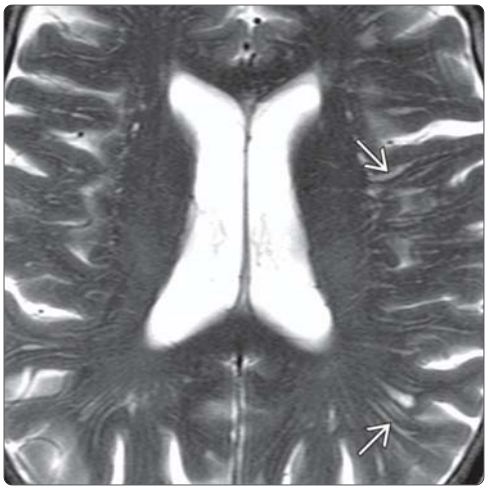

(Left) *Coronal graphic shows the cranial meninges and SAS ➡. The pia is a thin delicate membrane that covers the brain ⇨ as well as the vessels and trabeculae in the SAS. The pia also invaginates along a penetrating cortical artery to form a perivascular space ➡. The arachnoid ➡ forms the outer margin of the SAS and is loosely attached to the dura.* **(Right)** *Axial T2WI MR at 3T shows multiple normal perivascular spaces ➡ in the subcortical and deep white matter.*

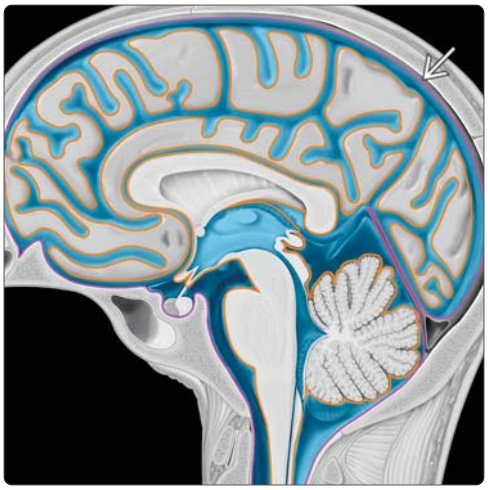

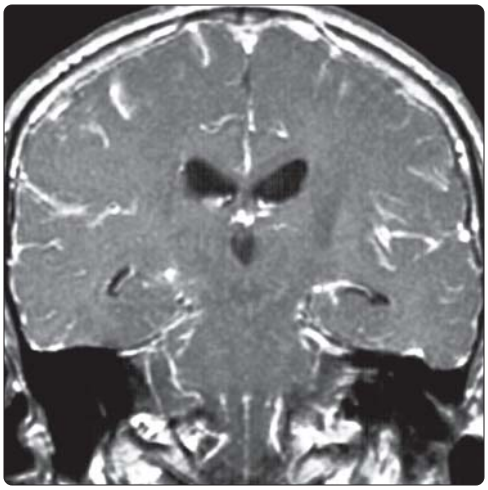

(Left) *Sagittal graphic depicts the cranial leptomeninges as they enclose the CSF cisterns, shown in blue. The arachnoid ➡ (purple) follows the dura around the inner calvaria but does not invaginate into the sulci. The pia (orange) is the innermost layer of leptomeninges and follows the brain surface and dips into the sulci. The SAS lies between the pia and arachnoid.* **(Right)** *Coronal T1 C+ MR shows extensive abnormal leptomeningeal enhancement related to infectious meningitis.*

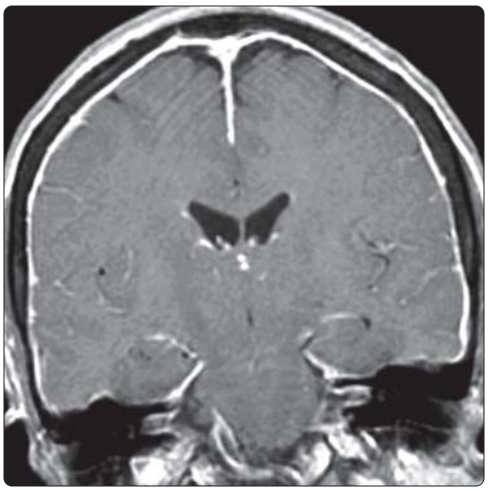

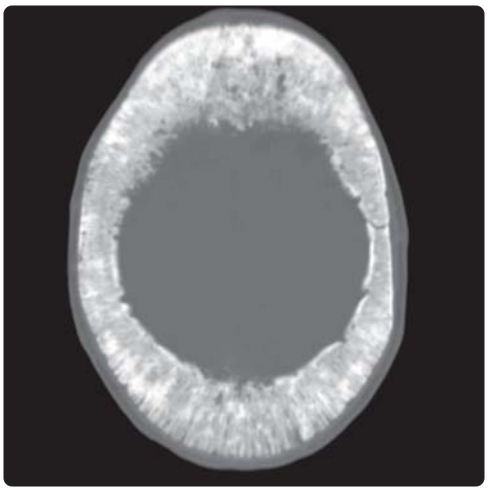

(Left) *Coronal T1 C+ MR shows diffuse dural enhancement related to intracranial hypotension in this patient with a CSF leak. Diffuse dural enhancement is commonly related to a prior procedure, infection, or inflammatory etiology. Venous congestion is the cause in intracranial hypotension.* **(Right)** *Axial bone CT shows diffuse calvarial thickening with widening of the diploic marrow resulting in a "hair on end" appearance. Thalassemia major is the most common cause of this classic imaging finding.*

https://CafePezeshki.IR

KEY FACTS

TERMINOLOGY

- Parietal foramina
  - Nonossification of medial parietal bone embryonal rest
- Sinus pericranii
  - Abnormal communication between intracranial and extracranial venous systems through calvarial defect
- Aplasia cutis congenita
  - Congenital skin malformation; may have underlying skull defect
- Cleidocranial dysplasia
  - Defective membranous and endochondral bone formation → delayed skull ossification
- Amniotic band syndrome
  - Strands of amniotic sac (bands) from ruptured amnion entangle digits, limbs, or other fetal parts
- Cranium bifidum occultum

IMAGING

- Symmetry, location best clues for diagnosis
- CT for calvaria, MR for underlying brain

TOP DIFFERENTIAL DIAGNOSES

- Epidermoid/dermoid
- Hemangioma
- Langerhans cell histiocytosis
- Metastasis
- Lacunar skull (Lückenschädel)

CLINICAL ISSUES

- Incidental finding on imaging or palpable scalp/calvarial mass that may protrude with crying, ↑ ICP

DIAGNOSTIC CHECKLIST

- Patients with EPF (> 5 mm) warrant imaging of brain parenchyma and vasculature

(Left) *Axial bone CT of the calvaria in a patient with a bilateral enlarged parietal foramina shows soft tissue extension through symmetrical, smooth, sharply demarcated osseous calvarial defects* ⇨. **(Right)** *Axial NECT in the same patient shows soft tissue windows with bilateral enlarged parietal foramina and otherwise normal brain parenchyma* ⇨ *protruding through the large, well-demarcated bilateral calvarial defects.*

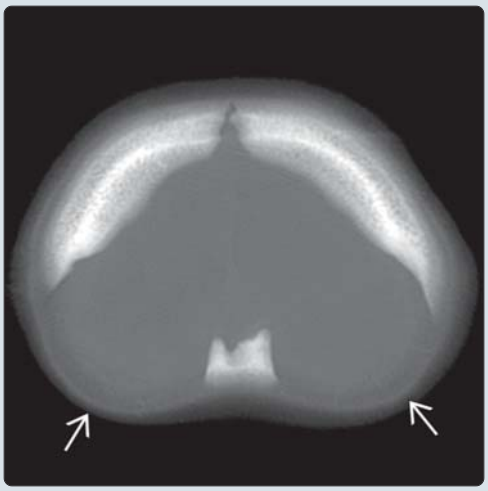

(Left) *Sagittal T1WI MR in a patient with sinus pericranii shows dilated parietal scalp veins* ⇨ *in contiguity with the superior sagittal sinus through a small calvarial defect* ⇨. **(Right)** *Sagittal MRV MIP reconstruction in the same patient confirms the presence of large parietal scalp veins* ⇨ *in contiguity with the superior sagittal sinus* ⇨ *via a small transcalvarial vein* ⇨. *These are the classic imaging findings of sinus pericranii.*

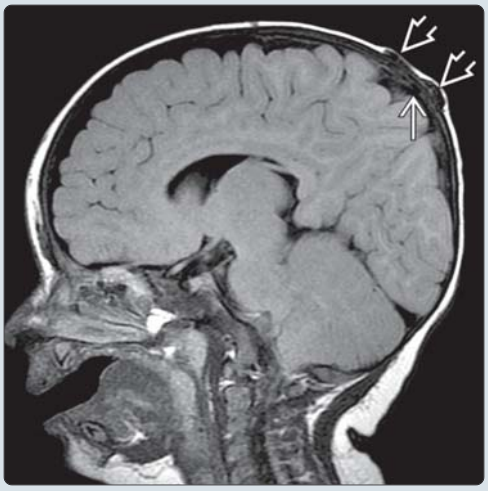

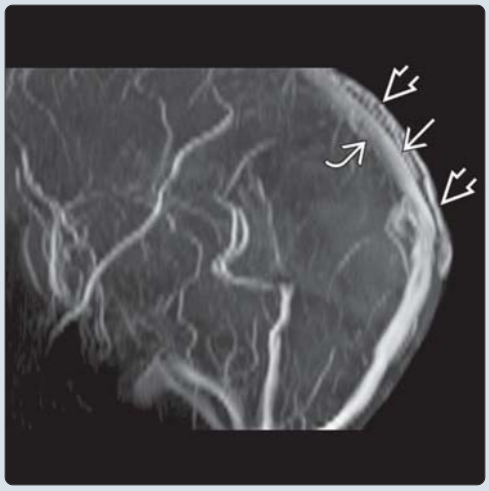

https://CafePezeshki.IR

TERMINOLOGY

Abbreviations

- Enlarged parietal foramen (EPF), aplasia cutis congenita (ACC)

Definitions

- Parietal fissure (common)
  - Small, residual, "incomplete" medial parietal bone suture
- Parietal foramina (common; 60-70% of normal skulls)
  - Nonossification of medial parietal bone embryonal rest
  - Emissary vein portal between superior sagittal sinus and extracranial scalp veins
- Enlarged parietal foramina (rare; prevalence 1:15,000-25,000)
  - Delayed/incomplete ossification of membranous parietal bone → round or oval parietal bone defects
  - Calvarial defect may be large, palpable
- Sinus pericranii
  - Abnormal communication between intracranial, extracranial venous systems through calvarial defect
  - Soft (often red or blue) scalp mass near superior sagittal or transverse dural sinuses
  - ↑ size with ↑ ICP (Valsalva, dependent positioning)
- Craniolacunia (venous lakes)
  - Patulous calvarial diploic veins
  - Irregular, geographic, well-demarcated contour
  - Variable size and number
- Arachnoid (pacchionian) granulations
  - Located within 3 cm of superior sagittal sinus
  - Often multiple, irregular contour
- Abnormally large fontanelle
  - Secondary to ↑ intracranial pressure (suture spreading) or skeletal dysplasia
  - Search for ventriculomegaly, skeletal anomalies
- Cleidocranial dysplasia (uncommon)
  - Defective membranous and endochondral bone formation → delayed skull ossification
  - Enlarged sagittal and metopic sutures, wide anterior and posterior fontanelles, broad cranial diameter, multiple wormian bones along lambdoid sutures
- Cranium bifidum occultum ("cleft skull")
  - Delayed ossification of parietal bones → large midline skull defects
  - Progressive parietal bone ossification fills defects; may persist as parietal foramina
    - Persistence in adulthood rare (< 1%)
  - Brain covered by dura, intact scalp
- Amniotic band syndrome
  - Occurs when inner amnion membrane ruptures or tears without disruption of outer chorion
  - Strands of amniotic sac (bands) from ruptured amnion entangle digits, limbs, or other fetal parts
- Aplasia cutis congenita (uncommon)
  - Congenital skin malformation; may have underlying skull defect
  - Skin defects most frequent on midline scalp > trunk, face, limbs
- Acalvaria (rare)
  - Absent superior osseous cranial vault, dura mater
  - Normal skull base, facial bones, brain (usually)
- Acrania (rare)
  - Partial or complete absence of cranial vault bones, abnormal cerebral hemisphere development

IMAGING

General Features

- Best diagnostic clue
  - Symmetry, location best clues for diagnosis
- Size
  - Variable; small → large

CT Findings

- NECT
  - Variable soft tissue component
  - Intracranial extent may not be well demonstrated
- Bone CT
  - Characterize osseous margins as sharp or destructive, sclerotic or nonsclerotic, inner or outer table

MR Findings

- Variable; depends on composition of soft tissue component, size and etiology of calvarial defect

Imaging Recommendations

- Best imaging tool
  - Bone CT with 3D shaded surface reformats best demonstrates calvarial defect, bone margins
  - MR best demonstrates soft tissue component composition, intracranial extension, brain anomalies

DIFFERENTIAL DIAGNOSIS

Epidermoid/Dermoid

- Most common childhood benign calvarial tumor
- Sharp, slightly sclerotic osseous margins
- Most common along frontal, parietal bone sutures or adjacent to fontanelles

Hemangioma

- "Honeycomb" or "sunburst" pattern of bony spicules, avid enhancement
- Outer > inner table, nonsclerotic, nonbeveled margins
- ± prominent vascular grooves

Langerhans Cell Histiocytosis

- Lytic lesion(s) with nonsclerotic rim
- Beveled (outer > inner table)
- Predilection for calvaria, temporal bone

Metastasis

- Multiple poorly defined destructive osteolytic lesions
- Advanced leukemia, neuroblastoma most common
  - Neuroblastoma ± "hair on end" appearance
- Look for additional appendicular skeletal lesions, hepatosplenomegaly (leukemia)

Lacunar Skull (Lückenschädel) of Newborn

- Membranous bone dysplasia present at birth
- Well-defined calvarial lucencies = nonossified fibrous bone surrounded by normally ossified bone
- Resolve spontaneously by ~ 6 months, unrelated to hydrocephalus severity

https://CafePezeshki.IR

- Associated with myelomeningocele or encephalocele, Chiari 2 malformation

Leptomeningeal Cyst

- "Growing fracture" with adjacent encephalomalacia
- 0.6% of skull fractures (usually in child < 3 years)

Convolutional Markings

- True convolutional markings occur after sutural closure → differentiate from Lückenschädel

Osteomyelitis

- Lytic, poorly defined infiltrating margins, overlying soft tissue edema, fever or ↑ serum inflammatory markers

Cephalocele

- Osseous defect in characteristic location
- Brain anomalies, soft tissue component often clinically obvious

PATHOLOGY

General Features

- Etiology
  - Variable; many developmental and present early in life
  - Fortunately, majority of pediatric skull masses are histologically and clinically benign
- Genetics
  - Enlarged parietal foramina
    - Isolated autosomal dominant or syndromal
      - Chromosome 11p deletion with *ALX4* gene mutation
    - No causative mutation identified in nonsyndromic cases
  - Cleidocranial dysplasia
    - Autosomal dominant, locus on chromosome 6p21
      - Mutation in *RUN2* (also called *CBFA1*) gene coding for transcription factor activating osteoblastic differentiation
    - Variable expression, high penetrance
  - Cranium bifidum
    - Autosomal dominant, strong genetic heterogenicity
- Associated abnormalities
  - Enlarged parietal foramina
    - Scalp defects, cleft lip/palate, structural brain malformations
    - Vascular anomalies, including persistent falcine venous sinus ± adjacent focal encephalomalacia, occipital cortical infolding variations, atretic occipital encephalocele
  - Abnormally large fontanelles
    - Variable; depends on etiology or syndrome
  - Cleidocranial dysplasia
    - Absent/hypoplastic clavicles, small bell-shaped thorax, widened pubic symphysis, spinal anomalies, hypoplastic middle and distal phalanges, delayed deciduous dentition, hearing loss (38%)
  - Cranium bifidum
    - Midline neural tube malformations (myelomeningocele, meningoencephalocele, dermal sinus)
  - Amniotic band syndrome
    - ± constriction bands around limbs, congenital amputations, abdominal wall defects, and facial clefting
  - Acrania
    - Amniotic bands, anencephaly

CLINICAL ISSUES

Presentation

- Most common signs/symptoms
  - Palpable scalp or calvarial mass may bulge with crying, ↑ ICP
  - Incidental finding detected during imaging for other reasons
- Other signs/symptoms
  - Abnormally large anterior fontanelle (seen in osteogenesis imperfecta, cleidocranial dysplasia)

Natural History & Prognosis

- Dependent on severity of associated anomalies (especially orthopedic, neurological)

Treatment

- Surgical closure of calvarial defect with autologous bone or alloplastic material
- Multidisciplinary supportive care

DIAGNOSTIC CHECKLIST

Consider

- Patients with EPF (> 5 mm) warrant imaging of brain parenchyma and vasculature

Image Interpretation Pearls

- Confirm presence or absence of skull base, vascular, skeletal anomalies

SELECTED REFERENCES

1. Hawasli AH et al: Acalvaria. J Neurosurg Pediatr. 14(2):200-2, 2014
2. Singh S et al: Cleidocranial dysplasia: a case report illustrating diagnostic clinical and radiological findings. J Clin Diagn Res. 8(6):ZD19-20, 2014
3. Griessenauer CJ et al: Enlarged parietal foramina: a review of genetics, prognosis, radiology, and treatment. Childs Nerv Syst. 29(4):543-7, 2013
4. Glass RB et al: The infant skull: a vault of information. Radiographics. 24(2):507-22, 2004

https://CafePezeshki.IR



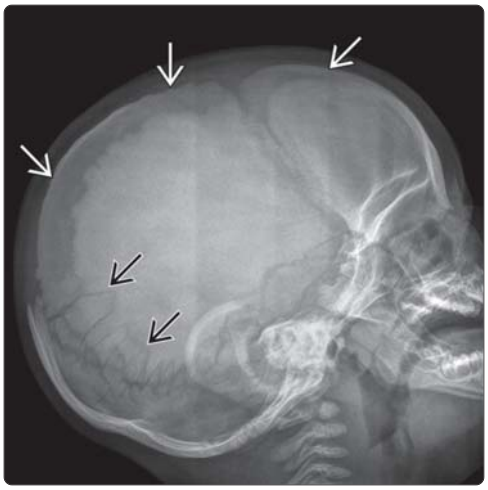

(Left) *Axial bone CT of the calvaria in a young patient with cleidocranial dysplasia demonstrates diminished midline bone structures, with abnormally large anterior and posterior fontanelles and wide sagittal suture.* **(Right)** *Lateral skull radiograph in a patient with cleidocranial dysplasia depicts large anterior/posterior fontanelles and a wide sagittal suture ➡. Note the numerous wormian bones ⇨ characteristically distributed along the lambdoid sutures.*

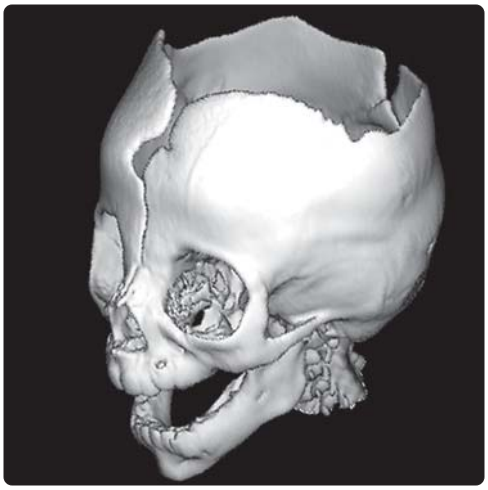

(Left) *Sagittal oblique 3D bone CT reconstruction shows the head of a patient with a large calvarial defect resulting from amniotic band syndrome. Note the absence of the superior portions of the bilateral frontal and parietal bones. The superior cranial vault is "open."* **(Right)** *Axial T2WI MR in the same patient with amniotic band syndrome shows left parietal lobe white matter volume loss and ependymal irregularity with associated periventricular nodular gray matter heterotopia ➡.*

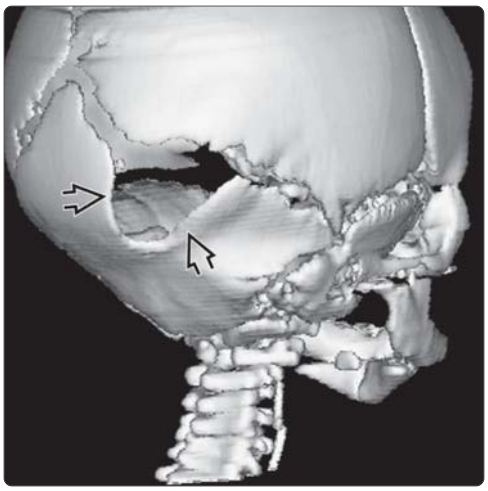

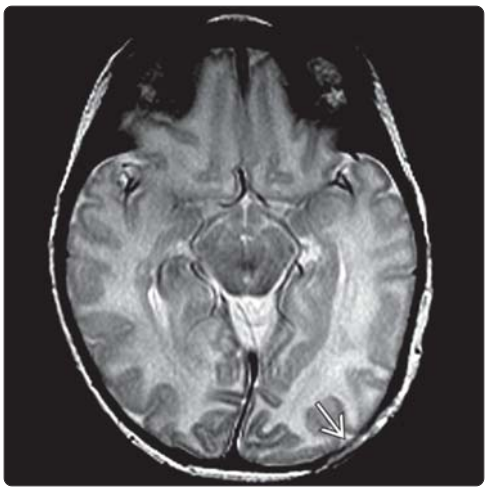

(Left) *Coronal oblique 3D bone CT reconstruction of the calvaria in a patient with focal cutis aplasia congenita of the scalp depicts a large calvarial defect ⇨ subjacent to the region of cutis aplasia abutting the lambdoid suture.* **(Right)** *Axial T2WI MR in the same patient with focal cutis aplasia congenita and a left occipital calvarial defect demonstrates thinning of subcutaneous fat, but intact dura ➡, in the region immediately beneath the area of cutis aplasia.*

https://CafePezeshki.IR

KEY FACTS

TERMINOLOGY

- Synonyms: Craniosynostosis, sutural synostosis, cranial dysostosis, craniofacial dysostosis
- Heterogeneous group with abnormal head shape, premature sutural closure and fusion

IMAGING

- Calvarial (and facial) distortion predictable based on suture(s) involved
- Fibrous or bony "bridging" ± "beaking" along suture

TOP DIFFERENTIAL DIAGNOSES

- Postural flattening or positional molding
- Secondary craniosynostosis

PATHOLOGY

- Premature upregulation of growth factors signaling sutural fusion → craniostenosis
- Head shape may be abnormal before osseous sutural changes detectable on imaging
- Some single sutural and nonsyndromic synostoses are genetic
- Syndromic synostoses usually autosomal dominant

CLINICAL ISSUES

- Asymmetric face/cranium, ↓ head growth, extremity anomalies, developmental delay
- Patients with more severe anomalies often present at time of birth

DIAGNOSTIC CHECKLIST

- Nonsyndromic does not necessarily mean nongenetic; single sutural synostoses also governed by genes
- Look for venous drainage anomalies or occlusion (particularly with multisutural synostosis)

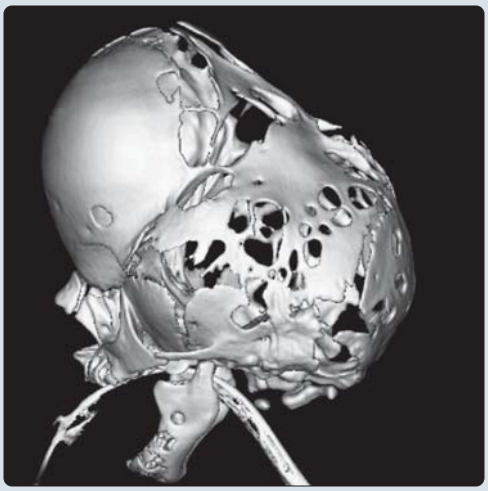

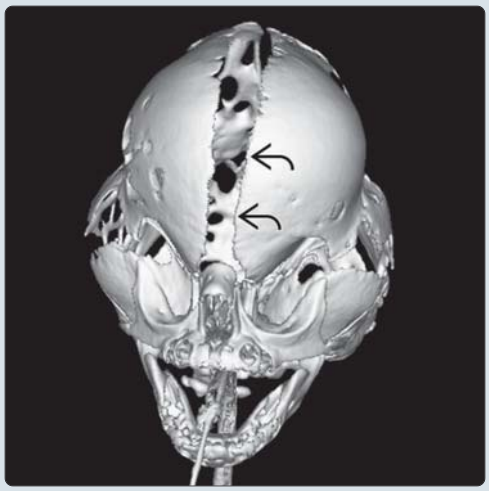

(Left) *Sagittal bone CT 3D shaded surface reformat of the calvaria in a 1 day old with Carpenter syndrome shows an abnormal head shape and frontal bossing with facial hypoplasia and premature closure of the squamosal, coronal, lambdoid, and sagittal sutures.* **(Right)** *Anterior coronal bone CT 3D shaded surface reformat in the same patient shows a very wide metopic suture ⇨ and anterior fontanelle with harlequin eyes and a small face due to premature closure of the facial sutures.*

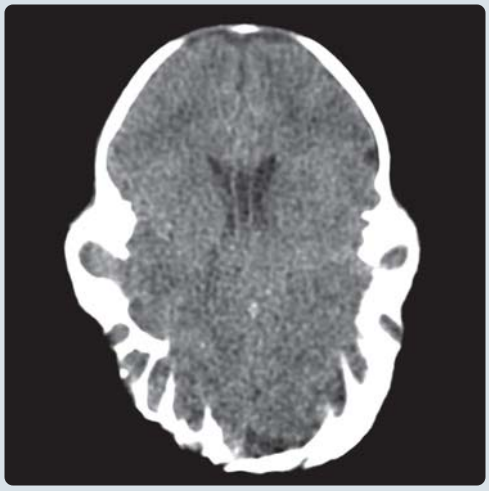

(Left) *Posterior coronal bone CT 3D shaded surface reformat in the same patient shows an abnormal head shape with occiput flattening, partial or complete closure of the lambdoid, sagittal sutures, and apparent holes ⇨ due to focal calvarial thinning.* **(Right)** *Axial NECT in the same patient reveals marked irregularity of the calvaria. The intracranial compartment is small, producing brain compression with posterior effacement of the convexity sulci.*

https://CafePezeshki.IR

TERMINOLOGY

Synonyms

- Craniosynostosis, sutural synostosis, cranial dysostosis, craniofacial dysostosis

Definitions

- Heterogeneous group with abnormal head shape, premature sutural closure and fusion
  - Nonsyndromic (85%); isolated, classified according to involved suture(s)
    - Simple (single) suture (75-80%)
      - Abnormal head shape, (usually) normal intelligence
      - Usually sporadic, operated for cosmetic reasons
    - Multiple sutures (20-25%)
      - Oxycephaly (40-50%), brachycephaly (30-40%), unclassified (20%)
  - Syndromic (> 180 syndromes [15%]); multiple anomalies with (frequent) developmental delay
    - Association with craniofacial, skeletal, nervous system, other anomalies
    - Syndrome description based on clinical features
      - Acrocephalosyndactyly type 1 (Apert)
      - Acrocephalosyndactyly type 2 (Apert-Crouzon)
      - Acrocephalosyndactyly type 3 (Saethre-Chotzen)
      - Acrocephalosyndactyly type 4 (Waardenburg)
      - Acrocephalosyndactyly type 5 (Pfeiffer)
      - Acrocephalopolysyndactyly type 2 (Carpenter)

IMAGING

General Features

- Best diagnostic clue
  - Head shape predicts abnormal suture(s)
- Size
  - Part or all of abnormal suture may be fused
- Morphology
  - Classic imaging appearance: Calvarial (and facial) distortion predictable based on suture(s) involved
    - Scaphocephaly (dolichocephaly): ↓ transverse, ↑ AP, forehead bossing → sagittal synostosis
    - Trigonocephaly: Wedge-shaped forehead, hypotelorism → metopic synostosis
    - Plagiocephaly: Asymmetry → unilateral single or asymmetric multiple sutures
      - Unilateral coronal synostosis: Unilateral harlequin orbit, hemicalvarium shortened and pointed
      - Lambdoid synostosis: Trapezoid skull, ipsilateral posterior ear displacement, occipital flattening
    - Brachycephaly: ↑ transverse, ↓ AP → bicoronal or bilambdoid synostosis
      - Bilateral coronal synostosis: Bilateral harlequin orbit, brachycephaly, skull base and craniofacial aberrations
    - Turricephaly: "Towering skull" → bicoronal or bilambdoid synostosis
    - Oxycephaly: Coronal, sagittal, lambdoid sutures
    - Kleeblattschädel: "Cloverleaf skull," bulging temporal bone, shallow orbits → bicoronal and bilambdoid synostosis
    - Unclassified: Multiple assorted sutural synostoses

CT Findings

- Bone CT
  - Fibrous or bony "bridging" ± "beaking" along suture
  - Head shape determined by involved suture(s)

MR Findings

- T1WI
  - Syndromic: Abnormal head shape ± cerebellar tonsillar ectopia, hydrocephalus, agenesis corpus callosum
  - Nonsyndromic: Abnormal head shape, brain (usually) normal
- T2WI
  - Same as T1WI
- MRV
  - ± congenital venous drainage anomalies
  - Postoperative dural venous occlusion

Imaging Recommendations

- Best imaging tool
  - Low-dose 3D bone CT reconstruction for sutural status
  - MR for brain abnormalities

DIFFERENTIAL DIAGNOSIS

Postural Flattening or Positional Molding

- Sutures normal

Secondary Craniosynostosis

- Brain growth arrest (myriad causes) → premature sutural fusion (especially metopic or universal craniosynostosis)

PATHOLOGY

General Features

- Etiology
  - Normal sutures permit skull growth perpendicular to long axis, close when brain growth slows
    - Order of closure: Metopic > coronal > lambdoid > sagittal
  - Premature upregulation of growth factors signaling sutural fusion → anomalous skull base development, craniostenosis
    - Transforming growth factor (TGF), fibroblast growth factor/receptor (FGF/FGFR) mutations expressed in face, skull base, limb buds
  - Abnormal head shape before osseous sutural changes apparent
    - Identifiable as early as 13 weeks gestation
    - Only part of suture needs to close → craniosynostosis
  - ↓ growth of 1 suture compensated by ↑ growth of other sutures
    - Skull growth ↓ perpendicular, ↑ parallel to fused suture → abnormal head shape
- Genetics
  - Some single sutural and nonsyndromic synostoses are genetic
    - Gene expression often suture specific
  - Syndromic synostoses usually autosomal dominant
    - *FGFR1* (Pfeiffer syndrome)
    - *FGFR2* (Apert, Pfeiffer, Crouzon, Jackson-Weiss)
    - *FGFR3* (Thanatophoric dysplasia types 1 and 2, Crouzon)

https://CafePezeshki.IR

  - *TWIST* (Saethre-Chotzen syndrome)
  - *MSX2* (Boston-type craniosynostosis)
- Associated abnormalities
  - Limb anomalies (syndactyly and polysyndactyly [30%], deficiencies [22%])
  - Neurological abnormalities/complications
    - ↑ intracranial pressure: Mechanical brain distortion, hydrocephalus, dural and collateral venous outflow obstruction at skull base
    - Tonsillar herniation ± syringohydromyelia
    - Exophthalmos, visual loss, mental retardation (secondary to ↑ ICP)

Gross Pathologic & Surgical Features

- Fibrous or osseous "bridging," "beaking" along suture

Microscopic Features

- ↑ osteoblastic cell differentiation/maturation

CLINICAL ISSUES

Presentation

- Most common signs/symptoms
  - Asymmetric face/cranium, ↓ head growth
  - Affected patients with more severe abnormalities often present at birth
- Other signs/symptoms
  - Extremity anomalies, developmental delay
- Clinical profile
  - Craniofacial asymmetry ± extremity anomalies
  - More common in twins (mechanical forces?)

Demographics

- Age
  - Usually present at birth or in infancy
- Gender
  - Overall (M:F = 4:1)
  - Scaphocephaly (M:F = 3.5:1)
  - Trigonocephaly (M:F = 2-3.3:1)
  - Coronal synostosis (M:F = 1:2)
  - Apert (M:F = 1:1)
- Epidemiology
  - Overall (1:2,500)
  - Sagittal (55-60%), coronal (20-30%), plagiocephaly (5-10%), metopic (1-2%)

Natural History & Prognosis

- Single suture → cosmetic only or secondary mandibular/maxillary deformities (suture dependent)
- Multiple suture → cosmetic with secondary mandibular/maxillary deformities, ↑ ICP, ↓ CBF; airway/aural/visual compromise
  - Craniofacial deformity socially stigmatizing
- Nonsyndromic → normal cognitive and motor development (debated)
- Syndromic ± midline brain anomalies → developmental delay

Treatment

- Mild deformity or positional molding
  - Aggressive physiotherapy, head repositioning, orthotic headband/helmet therapy
- Moderate to severe deformity
  - Surgical cranial vault reconstruction or cranial vault distraction osteogenesis

DIAGNOSTIC CHECKLIST

Consider

- Nonsyndromic does not mean nongenetic; single sutural synostoses also governed by genes
- Venous drainage anomalies (multisutural synostosis)

Image Interpretation Pearls

- Positional lambdoid flattening: Long axis of skull is oblique (forehead to contralateral occiput)
- Unilateral lambdoid synostosis: Long axis of skull remains unilateral A-P (forehead to ipsilateral occiput)

SELECTED REFERENCES

1. Assadsangabi R et al: Morphology of the foramen magnum in syndromic and non-syndromic brachycephaly. Childs Nerv Syst. ePub, 2015
2. di Rocco F et al: Y-craniosynostosis by premature fusion of the metopic and coronal sutures: A new nosological entity or a variety of Saethre-Chotzen syndrome? Birth Defects Res A Clin Mol Teratol. ePub, 2015
3. Anderson IA et al: Does patient ethnicity affect site of craniosynostosis? J Neurosurg Pediatr. 14(6):682-7, 2014
4. Calandrelli R et al: Identification of skull base sutures and craniofacial anomalies in children with craniosynostosis: utility of multidetector CT. Radiol Med. 119(9):694-704, 2014
5. Greenwood J et al: Familial incidence and associated symptoms in a population of individuals with nonsyndromic craniosynostosis. Genet Med. 16(4):302-10, 2014
6. Snider TN et al: Cranial neural crest cell contribution to craniofacial formation, pathology, and future directions in tissue engineering. Birth Defects Res C Embryo Today. 102(3):324-32, 2014
7. Badve CA et al: Craniosynostosis: imaging review and primer on computed tomography. Pediatr Radiol. 43(6):728-42; quiz 725-7, 2013
8. Birgfeld CB et al: Making the diagnosis: metopic ridge versus metopic craniosynostosis. J Craniofac Surg. 24(1):178-85, 2013
9. Jezela-Stanek A et al: Genetic causes of syndromic craniosynostoses. Eur J Paediatr Neurol. 17(3):221-4, 2013
10. Tubbs RS et al: Kleeblattschädel skull: a review of its history, diagnosis, associations, and treatment. Childs Nerv Syst. 29(5):745-8, 2013
11. Massimi L et al: Isolated sagittal craniosynostosis: definition, classification, and surgical indications. Childs Nerv Syst. 28(9):1311-7, 2012
12. Blaser SI: Abnormal skull shape. Pediatr Radiol. 38 Suppl 3:S488-96, 2008
13. Cunningham ML et al: Evaluation of the infant with an abnormal skull shape. Curr Opin Pediatr. 19(6):645-51, 2007

https://CafePezeshki.IR

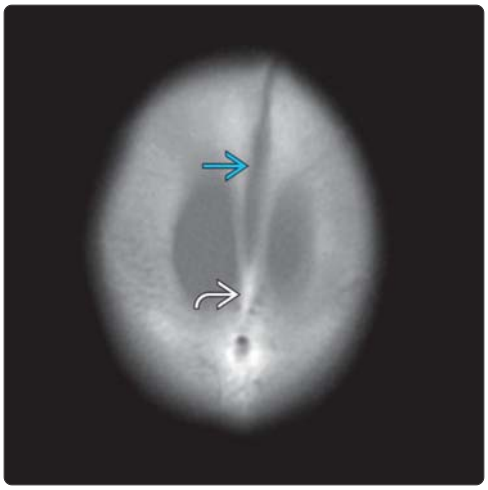

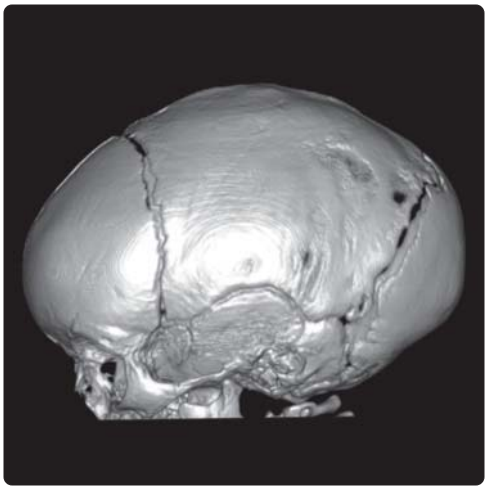

(Left) *Axial bone CT of the calvaria in a patient presenting with severe scaphocephaly shows sagittal synostosis. Note the straightening and narrowing of the sagittal suture ⇨ with prominent ridges, osseous bridging, and bony fusion ➡ across the sagittal suture.* **(Right)** *Sagittal 3D bone CT of the calvaria in the same patient shows prominent dolichocephaly and confirms characteristic findings of isolated sagittal synostosis. The coronal, lambdoid, and squamosal sutures are normal.*

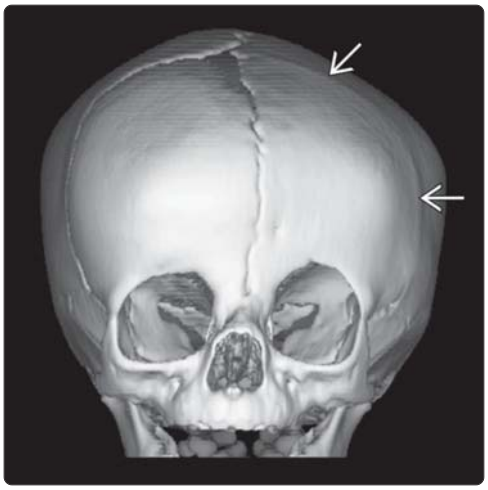

(Left) *Axial bone CT of the calvaria in a patient with plagiocephaly reveals abnormal flattening of the left forehead and pointed configuration ➡ at the left coronal suture from premature closure and fusion of the suture. The right coronal and lambdoid sutures are open.* **(Right)** *Coronal 3D bone CT reformat of the skull in the same patient confirms closure of left coronal suture ➡ with characteristic flattening of the ipsilateral forehead and retrusion of lateral superior orbit ("harlequin eye").*

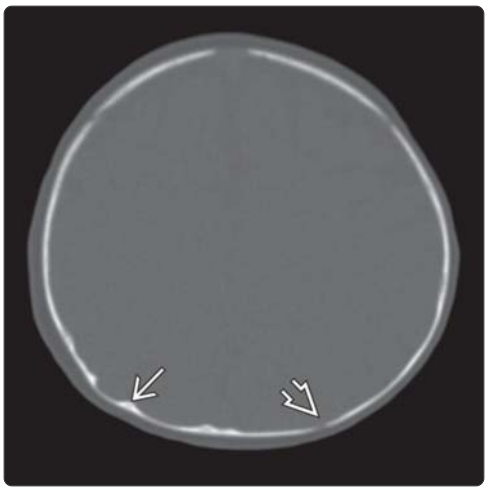

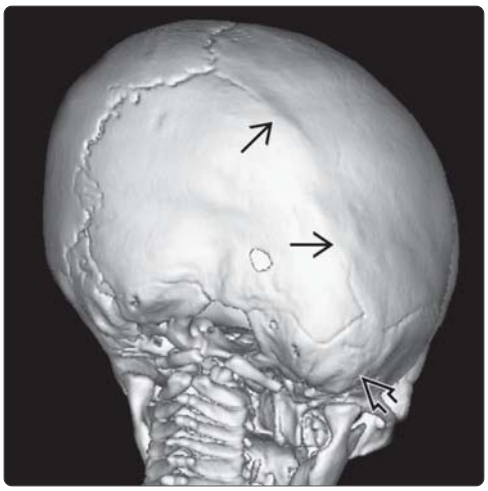

(Left) *Axial bone CT of the head in a patient with unilateral lambdoid synostosis demonstrates a fused right lambdoid suture ➡ producing asymmetric occipital flattening. The left lambdoid ➡ suture is normal.* **(Right)** *Coronal oblique 3D bone CT shaded surface reformat of the same patient confirms obliteration of the right lambdoid suture ⇨ producing occipital flattening and protrusion of the right mastoid bone ("mastoid bump") ⇨. The left lambdoid and sagittal sutures are open.*

https://CafePezeshki.IR

KEY FACTS

TERMINOLOGY

- Cephalocele is generic term for intracranial content protrusion through calvarial or skull base defect
  - Meningoencephalocele (encephalocele): Brain tissue, meninges, CSF
  - Meningocele: Meninges, CSF only
- Cephalocele types
  - Basal
  - Cranial vault
  - Frontoethmoidal (sincipital)
  - Nasopharyngeal
  - Occipital
  - Parietal
  - Temporal bone

IMAGING

- Meninges ± brain tissue protruding through osseus skull defect
- Heterogeneous signal intensity reflecting brain tissue composition, CSF

TOP DIFFERENTIAL DIAGNOSES

- Atretic parietal cephalocele
- Nasal dermoid/epidermoid
- Nasal glioma (nasal cerebral heterotopia)
- Calvarial dermoid

CLINICAL ISSUES

- Most cephaloceles (except nasopharyngeal) present at birth

DIAGNOSTIC CHECKLIST

- Location determines risk of associated anomalies, predicates prognosis
- Evaluation of cartilaginous nasofrontal region in infants using CT problematic; consider MR

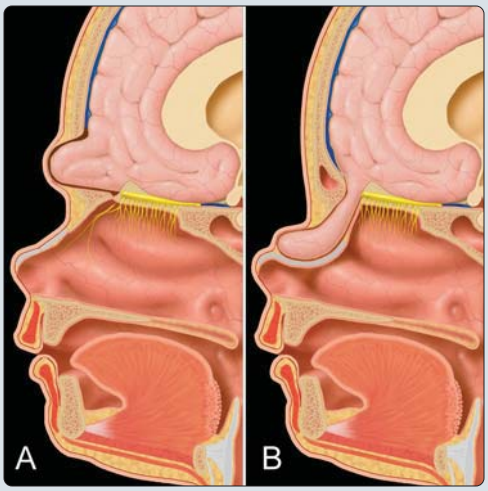

(Left) *Sagittal graphics show 2 variants of sincipital encephalocele. In the frontonasal type (A), the brain extends through the frontonasal suture into the glabellar region. In the nasoethmoidal type (B), the encephalocele extends through the foramen cecum into the nasal cavity.* **(Right)** *Sagittal T2WI MR demonstrates the nasoethmoidal type of sincipital encephalocele ⇨ extending through the foramen cecum and anterior skull base defect ⇨ into the nasal cavity.*

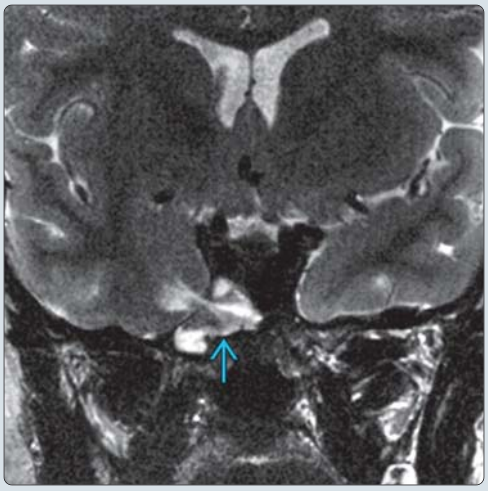

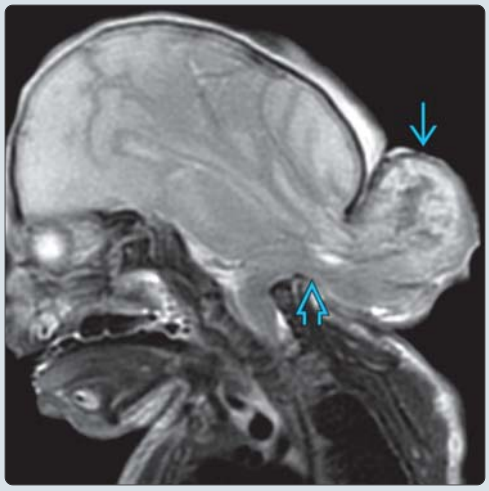

(Left) *Coronal T2WI MR shows a sphenoid encephalocele ⇨ extending through a small right lateral sphenoid bone defect identified during evaluation for temporal lobe epilepsy. EEG localized to the right mesial temporal lobe.* **(Right)** *Sagittal T2WI MR shows a low occipital cephalocele containing both occipital lobes ⇨ and the cerebellum ⇨ with severe traction distortion of the brainstem. Note the involvement of the foramen magnum. The herniated occipital lobe is dysmorphic and disorganized.*

https://CafePezeshki.IR

TERMINOLOGY

Definitions

- Generic term for intracranial content protrusion through calvarial or skull base defect
  - Named for roof and floor of bone defect
  - Open or skin covered, dura attenuated or dehiscent
  - Congenital or post-traumatic
- Cephalocele contents
  - Meningoencephalocele (encephalocele): Brain tissue, meninges, CSF
  - Meningocele: Meninges, CSF only
- Cephalocele types
  - Basal (10%)
    - Midline basal cephalocele
      - Sphenopharyngeal: Sphenoid body
      - Sphenoethmoidal: Sphenoid, ethmoid bones
      - Transethmoidal: Cribriform plate
    - Lateral basal cephalocele
      - Sphenomaxillary: Maxillary sinus, orbital fissure into pterygopalatine fossa
      - Sphenoorbital: Sphenoid bone into orbit
    - May include pituitary gland, hypothalamus, optic nerves/chiasm, anterior 3rd ventricle
  - Frontoethmoidal (sincipital) (10-15%)
    - Midface, dorsum of nose, orbits, forehead
    - Subtypes (may be mixed 10%)
      - Frontonasal (40-60%): Foramen cecum, fonticulus frontalis into glabella
      - Nasoethmoidal (30%): Foramen cecum into nasal cavity
      - Nasoorbital: Maxilla, lacrimal bone into orbit
  - Nasopharyngeal (very uncommon)
    - Occult cephalocele through ethmoid, sphenoid, or basiocciput → nasal cavity or pharynx
  - Occipital (75%)
    - Occipitocervical: Occipital bone, foramen magnum, upper cervical posterior arches
    - Low occipital: With foramen magnum
    - High occipital: Without foramen magnum
  - Parietal (10%)
    - Usually associated with significant brain anomalies → poor prognosis
  - Temporal bone
    - Inferior extension through middle ear/mastoid, petrous apex
  - Cranial vault
    - Anterior fontanelle, interfrontal, lateral (coronal or lambdoid sutures), temporal, interparietal, posterior fontanelle

IMAGING

General Features

- Best diagnostic clue
  - Meninges ± brain tissue protruding through osseous skull defect

CT Findings

- NECT
  - Contrast resolution limits ability to distinguish encephalocele from paranasal sinus opacification
- Bone CT
  - Excellent delineation of bone margins
  - Nasofrontal lesions problematic in infants because of cartilaginous anterior skull base
    - By 24 months, 84% of anterior skull base ossified; CT more reliable
- CTA
  - CTV characterizes venous vascular anatomy and relationship to encephalocele

MR Findings

- T1WI
  - Heterogeneous signal intensity reflecting brain tissue composition, CSF
- T2WI
  - Heterogeneous signal intensity reflecting brain tissue composition, CSF
  - Best contrast resolution, signal properties for CSF, characterizing gliosis in dysplastic brain tissue
- MRV
  - Characterize venous vascular anatomy, relationship to encephalocele

Ultrasonographic Findings

- Grayscale ultrasound
  - Will identify many cephaloceles in fetuses
    - Allows for early treatment post delivery
  - May have limited use in neonates

Imaging Recommendations

- Best imaging tool
  - Multiplanar MR to delineate soft tissues and intracranial relationships
  - Bone CT to define osseous anatomy (except nasofrontal region in infants)
- Protocol advice
  - Multiplanar MR; contrast usually not necessary
  - Thin-section bone CT with multiplanar reformats

DIFFERENTIAL DIAGNOSIS

Atretic Parietal Cephalocele

- Small midline parietal mass, sharply marginated calvarial defect ± associated brain anomalies
- Cephalocele form fruste containing dura, fibrous tissue, dysplastic brain tissue

Nasal Dermoid/Epidermoid

- Failure of normal regression of dural projection through embryologic foramen cecum
- Small skin dimple or pit on external nose ± intracranial dermal sinus, (epi)dermoid cyst

Nasal Glioma (Nasal Cerebral Heterotopia)

- Congenital nonneoplastic heterotopia composed of dysplastic glial tissue
- Lack of normal regression of dural projection through embryologic foramen cecum
- Extranasal (60%), intranasal (30%), or mixed (10%)

https://CafePezeshki.IR

Calvarial Dermoid

- Usually near sutures
- Signal intensity reflects ectodermal, skin elements

Chiari 3

- Cephalocele through foramen magnum + cervical dysraphism
- Many cases of Chiari 3 are occipital cephaloceles (no cervical dysraphism)

Exencephaly

- Absence of cranial vault bones, protrusion of brain tissue into amniotic cavity

PATHOLOGY

General Features

- Etiology
  - General theories for cephalocele formation
    - Membranous calvaria: Defective bone induction, focal dural dysgenesis, bone erosion by cephalocele, local failure of neural tube closure
    - Endochondral skull base: Faulty neural tube closure, failure of basilar ossification center unification
  - Specific cephaloceles
    - Occipital encephalocele
      - Abnormal primary neural tube closure failure
      - Association with other neural tube defects
    - Frontal encephaloceles
      - Cutaneous ectoderm, neuroectoderm at anterior neuropore fail to detach ~ 3rd week
      - Genetic, toxic, environmental causes
      - No relationship to neural tube defects
    - Basal encephaloceles
      - Developmental failure of skull base ossification → migration of neural crest cells, tissue herniation through defect
      - Persistent craniopharyngeal canal theory out of favor
- Associated abnormalities
  - Basal: Hypertelorism, optic nerve hypoplasia, coloboma, midline facial anomalies, cleft lip/palate
  - Frontoethmoidal: Microcephaly, hypertelorism, eye anomalies, hydrocephalus, seizures
  - Nasopharyngeal: Callosal dysgenesis, optic hypoplasia, hypothalamic-pituitary axis dysfunction
  - Occipital: Cerebellar and cerebral gray matter migrational anomalies, dural venous anomalies, callosal dysgenesis, Chiari 2 malformation, Dandy-Walker malformation
  - Parietal: Callosal dysgenesis, Chiari 2 malformation, Dandy-Walker malformation, Walker-Warburg syndrome, holoprosencephaly spectrum

Gross Pathologic & Surgical Features

- Bone dehiscence occurs at suture or synchondrosis
- Smoothly marginated rim of cortical bone

CLINICAL ISSUES

Presentation

- Most common signs/symptoms
  - Usually clinically obvious
  - Soft, bluish (skin covered) or moist red (nonskin covered) discoloration over soft tissue mass
- Other signs/symptoms
  - CSF rhinorrhea → meningitis
  - Airway obstruction, nasal stuffiness/mouth breathing (basal, nasopharyngeal)
  - Occult mass in oro-/nasopharynx → change in size with Valsalva (basal, nasopharyngeal)
  - Hypertelorism, broad nasal bridge (frontoethmoidal)

Demographics

- Age
  - Most cephaloceles present at birth
  - Nasopharyngeal present by end of 1st decade
- Gender
  - Frontoethmoidal (M = F)
  - Occipital (M:F = 1:2.4)
- Ethnicity
  - Occipital most common location in European, North American Caucasians
  - Frontoethmoidal most common location in South/Southeast Asia, Latin America
- Epidemiology
  - 1:4,000 live births
  - 7% of neural tube defects
  - Usually sporadic but can be syndromic (e.g., Meckel syndrome)

Natural History & Prognosis

- Varies depending on type and location
- Cephalocele relationship to dural venous sinuses important for operative planning

Treatment

- Complete surgical resection of dysplastic herniated brain tissue to prevent CSF leakage, meningitis

DIAGNOSTIC CHECKLIST

Consider

- Location determines risk of associated anomalies, predicates prognosis

Image Interpretation Pearls

- Evaluation of cartilaginous nasofrontal region in infants using CT problematic; consider MR
  - Absence of ossified bone in crista galli/cribriform plate region does not = cephalocele
- MR + MR venography best for operative planning

SELECTED REFERENCES

1. Da Silva SL et al: Risk factors for hydrocephalus and neurological deficit in children born with an encephalocele. J Neurosurg Pediatr. 15(4):392-8, 2015
2. Kasprian GJ et al: Prenatal imaging of occipital encephaloceles. Fetal Diagn Ther. 37(3):241-8, 2015
3. Rawal RB et al: Endoscopic sinonasal meningoencephalocele repair: a 13-year experience with stratification by defect and reconstruction type. Otolaryngol Head Neck Surg. 152(2):361-8, 2015
4. Abele TA et al: Craniopharyngeal canal and its spectrum of pathology. AJNR Am J Neuroradiol. 35(4):772-7, 2014
5. Dhirawani RB et al: Frontoethmoidal encephalocele: Case report and review on management. Ann Maxillofac Surg. 4(2):195-7, 2014

https://CafePezeshki.IR

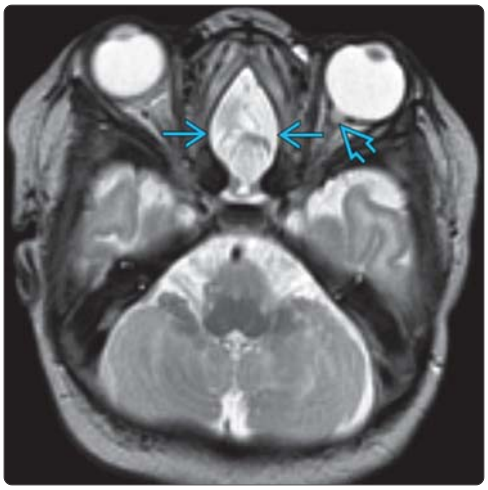

(Left) *Sagittal T1WI MR in an infant with nasal obstruction shows midline basal cephalocele containing CSF, meninges, and probably olfactory tracts. Note the associated callosal agenesis, abnormal palate, and dysmorphic nose.* **(Right)** *Axial T2WI MR in a newborn presenting with nasal obstruction reveals a large midline basal (sphenoethmoidal) encephalocele. Note the associated marked hypertelorism and left ocular coloboma, suggesting "morning glory" syndrome.*

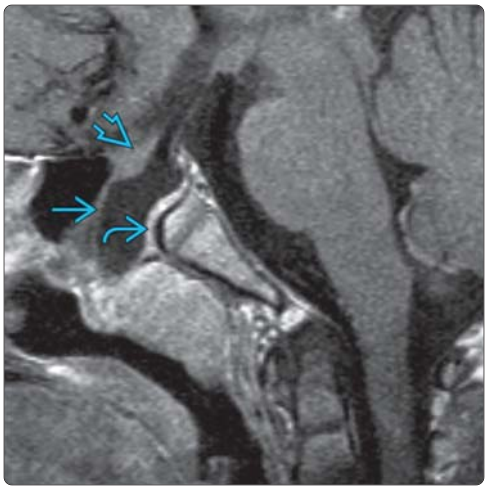

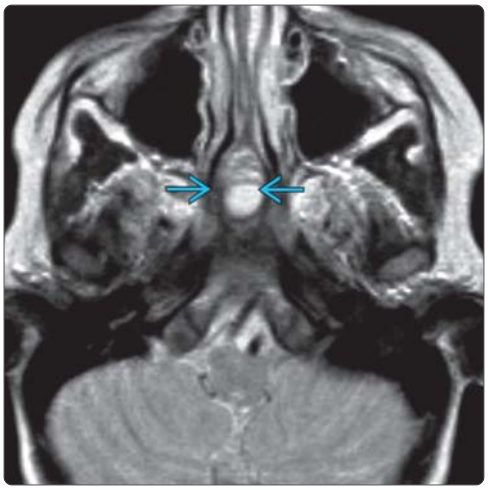

(Left) *Sagittal T1WI C+ FS MR shows a large transsphenoidal cephalocele, with CSF and meninges extending through a large midline defect in the sphenoid bone. Optic chiasm is under traction, optic nerves are stretched, and pituitary is compressed.* **(Right)** *Axial T2WI MR depicts an area of hyperintensity in the midline, anterior to the sphenooccipital synchondrosis. This proved to be a midline sphenoidal cephalocele.*

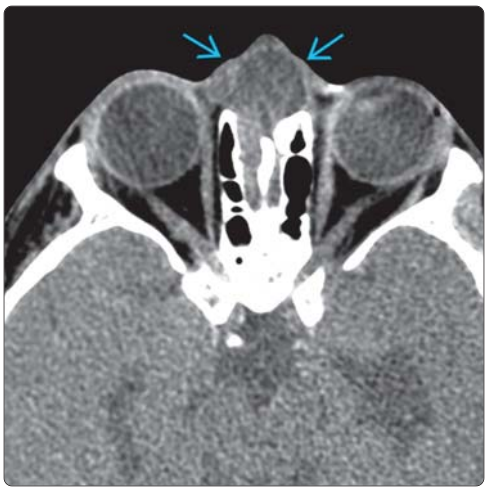

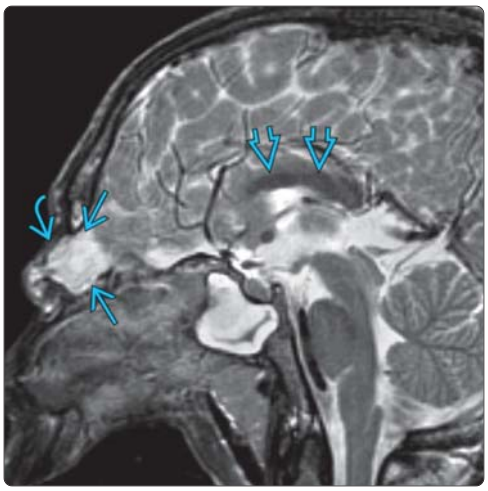

(Left) *Axial NECT in a boy with a glabellar mass (frontonasal cephalocele) shows absence of nasal bones and nasal processes of frontal bones and a fluid-intensity mass in the glabellar region. Mild hypertelorism is present. The left temporal horn is dilated.* **(Right)** *Sagittal T2WI MR in the same patient shows a bone defect near the frontonasal suture with a CSF-intensity mass, findings compatible with a cephalocele protruding through the defect. The corpus callosum is dysmorphic.*

https://CafePezeshki.IR

(Left) *Axial T2WI MR (frontonasal sincipital cephalocele) shows herniated brain ⇨ extending through a large bone defect at the junction of the frontal and nasal bones. Signal intensity of the dysplastic herniated brain tissue is heterogeneous and slightly hyperintense to normal parenchyma.* **(Right)** *Coronal 3D bone CT (frontonasal sincipital cephalocele) demonstrates a large midline osseous defect ⇨ correlating with the abnormally wide fonticulus frontalis.*

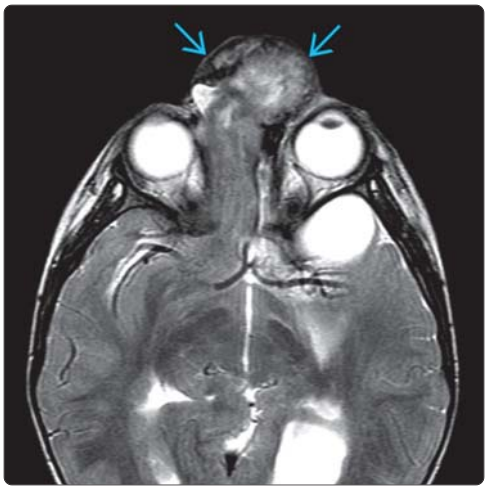

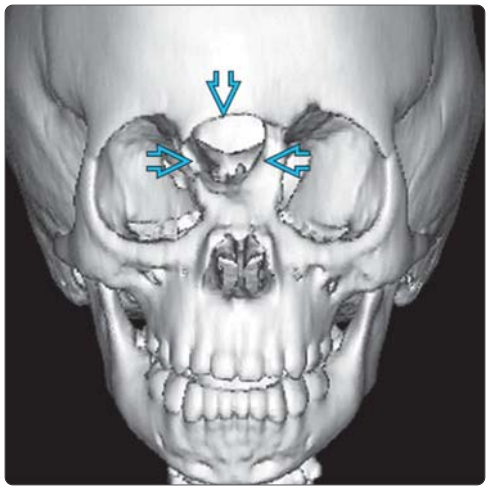

(Left) *Sagittal T2WI MR (acquired frontoethmoidal encephalocele) depicts extension of inferior frontal lobes ⇨ through anterior skull base defect into the ethmoid sinuses. The initial injury was a bungee cord hook through the nose into the frontal fossa, treated nonsurgically.* **(Right)** *Coronal bone CT (acquired frontoethmoidal encephalocele) in a patient with post-traumatic CSF rhinorrhea reveals a midline osseous defect ⇨ in the cribriform plate/frontal fossa.*

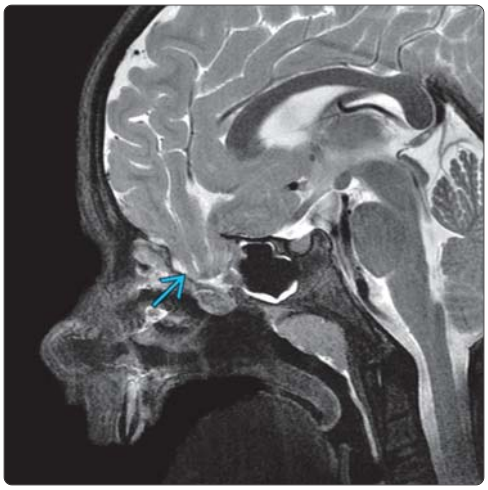

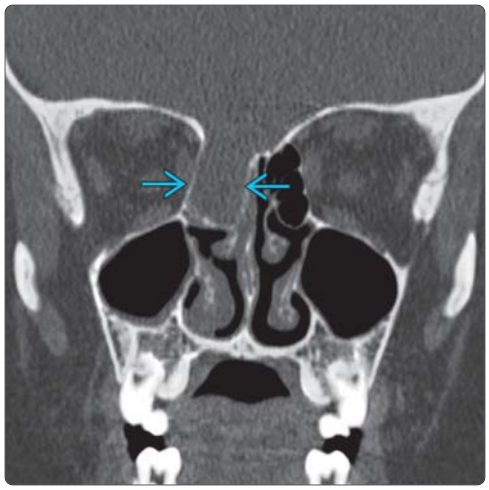

(Left) *Sagittal T1WI MR (occipital encephalocele) demonstrates extension of the dysmorphic occipital lobes into the posterior cephalocele sac ⇨. The cerebellum is distorted but not included within the sac. Bone defect sparing the foramen magnum indicates the high occipital variant.* **(Right)** *Axial T2WI MR in the same patient depicts displacement of both occipital lobes through the occipital bone defect into the cephalocele sac. The cortex in the cephalocele ⇨ appears dysplastic.*

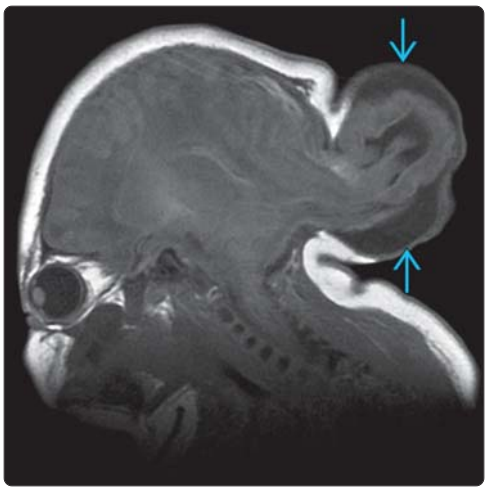

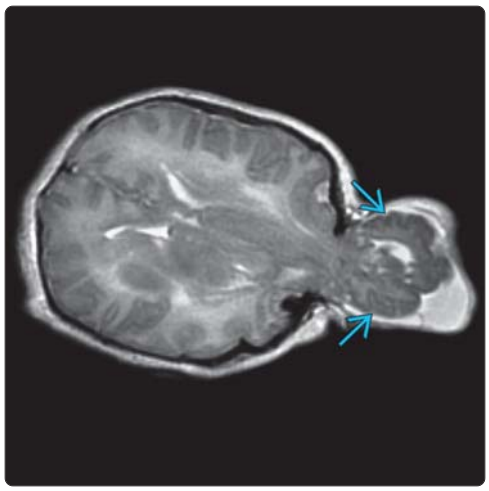

https://CafePezeshki.IR

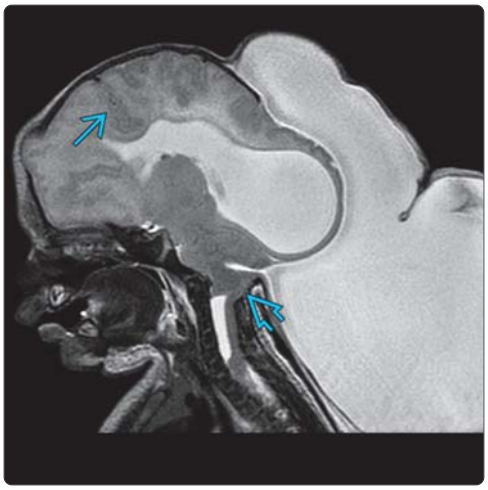

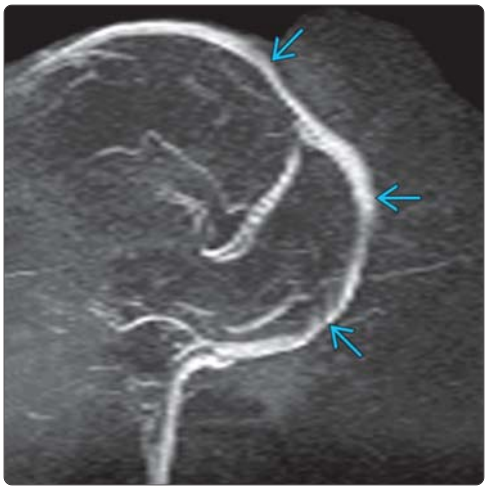

(Left) *Sagittal T2WI MR (occipital encephalocele) shows extension of both the posterior parietal and occipital lobes, as well as the cerebellum into the large fluid-filled cephalocele sac. Note traction deformity of the brainstem and upper cervical cord ⇨ and associated frontal lobe cortical dysplasia ⇨.* **(Right)** *Sagittal MRV in the same patient shows posterior displacement of the patent posterior superior sagittal sinus and venous confluence ⇨ into the cephalocele sac.*

(Left) *Sagittal T2WI MR in a newborn with parietal encephalocele and multiple severe congenital anomalies shows more brain parenchyma residing in the cephalocele than within the cranium. Brain tissue appears dysplastic within the cranium and the cephalocele.* **(Right)** *Coronal T2WI MR (parietal encephalocele) shows a combination of severe congenital brain malformation (bilateral cortical dysplasia) and acquired intraparenchymal hemorrhage ⇨ within the cephalocele.*

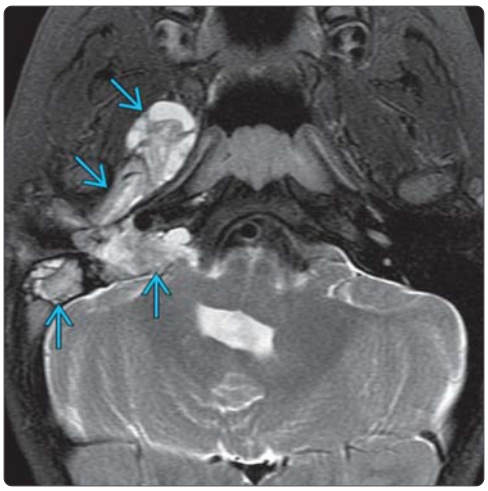

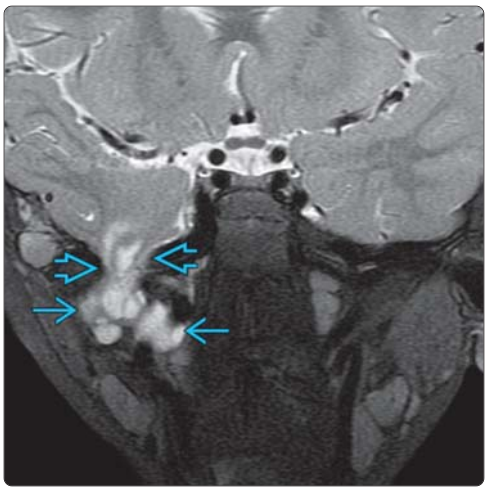

(Left) *Axial T2WI FS MR shows a large right post-traumatic encephalocele with multiple areas of temporal bone osseous dehiscence ⇨. The patient presented with right hearing loss and a remote history of head injury. Note the traction distortion of the medulla and cerebellum.* **(Right)** *Coronal T2WI FS MR of a post-traumatic temporal encephalocele reveals extension of the inferior right temporal lobe ⇨ through a post-traumatic bone defect ⇨ into the right middle ear and mastoid bone.*

https://CafePezeshki.IR

KEY FACTS

TERMINOLOGY

- Atretic parietal cephalocele (APC)
- Cephalocele "form fruste" consisting of dura, fibrous tissue, and dysplastic brain tissue

IMAGING

- Heterogeneous subcutaneous scalp mass with intracranial extension
- Focal fenestration of superior sagittal sinus at APC
- CSF tract and vertical falcine vein "point" to subcutaneous scalp mass
- Cephalocele itself may be very small

TOP DIFFERENTIAL DIAGNOSES

- Dermoid or epidermoid cyst
- Proliferating (infantile) hemangioma
- Sinus pericranii
  - Often associated with APC
- Cephalohematoma or subgaleal hematoma
- Sebaceous cyst
- Metastasis

PATHOLOGY

- Considered involuted true cephalocele (meningocele or encephalocele) connected to dura mater via fibrous stalk
- Syndromic patients have increased incidence of associated intracranial anomalies

CLINICAL ISSUES

- Soft palpable interparietal subgaleal mass
- Usually identified in infants and young children
  - M ≤ F

DIAGNOSTIC CHECKLIST

- Consider APC in differential diagnosis for child with midline parietal skin-covered subgaleal mass
- Prognosis depends more on associated "occult" brain anomalies than existence of cephalocele itself

(Left) *Sagittal graphic shows a skin-covered midline atretic parietal cephalocele ➡ protruding through a sharply demarcated skull defect ⇨. The atretic cephalocele is associated with a dura-lined sinus tract ➡ and a persistent falcine sinus ⇨.* **(Right)** *3D rendered bone CT in a child with an atretic parietal cephalocele demonstrates a small, sharply delineated midline skull defect ⇨.*

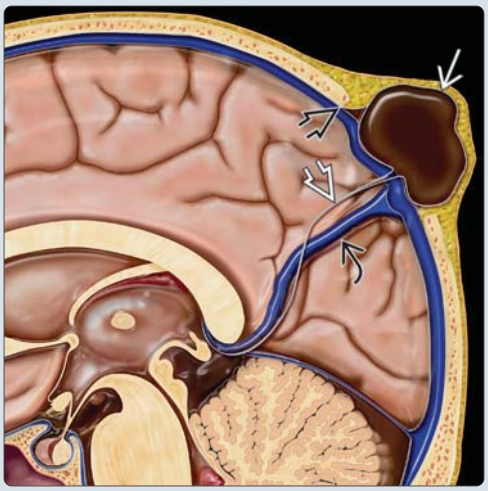

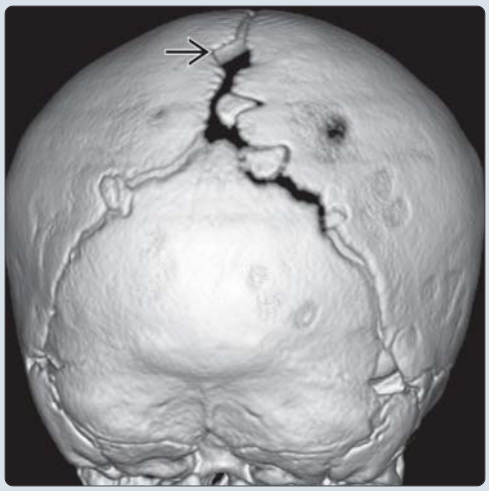

(Left) *Sagittal CTA in the same case shows a persistent falcine sinus ⇨, atretic cephalocele ➡ passing between a split superior sagittal sinus ⇨.* **(Right)** *Sagittal T2WI MR in the same case demonstrates the persistent falcine sinus ⇨ and a tiny atretic cephalocele ➡.*

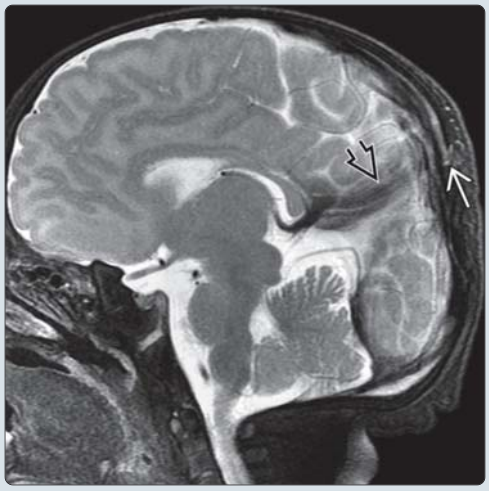

https://CafePezeshki.IR

TERMINOLOGY

Abbreviations

- Atretic parietal cephalocele (APC)

Definitions

- Cephalocele "form fruste" consisting of dura, fibrous tissue, and dysplastic brain tissue

IMAGING

General Features

- Best diagnostic clue
  - Fibrous tract and vertical falcine vein "point" to subcutaneous scalp mass (APC)
- Location
  - Midline interparietal most common, occasionally occipital
- Size
  - Usually small (5-15 mm)
- Morphology
  - Skin-covered subgaleal mass with sharply marginated calvarial defect

Radiographic Findings

- Radiography
  - Cranium bifidum at obelion
    - May be difficult to appreciate

CT Findings

- NECT
  - Subgaleal soft tissue mass
  - Small cranium bifidum superior to lambda
  - "Spinning top" configuration of tentorial incisura (axial)
- CECT
  - Extension of subcutaneous scalp mass through dura delineated by enhancing veins
  - Fenestration of superior sagittal sinus, vertically oriented primitive falcine vein
- CTA
  - Vertical embryonic positioning of straight sinus equivalent (falcine sinus)
  - Fenestration of superior sagittal sinus

MR Findings

- T1WI
  - Heterogeneous subcutaneous scalp mass with intracranial extension
  - ± cigar-shaped CSF tract within interhemispheric fissure
  - Prominent superior cerebellar cistern and suprapineal recess
  - Characteristic appearance of tentorial incisura
    - "Spinning top" (axial) and "peaked" (coronal) configuration
  - Tissue are stretched in direction of defect and may "point" to lesion
- T2WI
  - Subcutaneous scalp mass representing APC is usually hyperintense
  - Other findings similar to T1WI
- STIR
  - Fat suppression better delineates subgaleal hyperintense cephalocele
- T1WI C+
  - Subcutaneous scalp mass usually shows heterogeneous enhancement
  - APC fibrous tract delineated by adjacent enhancing veins
- MRV
  - Vertically positioned straight sinus equivalent (persistent falcine vein)
  - Focal fenestration or lateral displacement of superior sagittal sinus at APC

Ultrasonographic Findings

- Grayscale ultrasound
  - Scalp mass with heterogeneous echotexture
  - Cranium bifidum osseous defect usually too small to identify

Imaging Recommendations

- Best imaging tool
  - Multiplanar MR with intravenous contrast + MRV
- Protocol advice
  - MR: Thin section, small field of view, sagittal T1 and T2 with fat saturation
  - Intravenous contrast with fat saturation to define sagittal sinus and falcine vein; exclude sinus pericranii

DIFFERENTIAL DIAGNOSIS

Dermoid or Epidermoid Cyst

- Often located near sutures
- Scallops outer table of calvaria
- + marginal enhancement, no internal enhancement

Proliferating (Infantile) Hemangioma

- Lobulated soft tissue mass with internal flow voids
- + avid contrast enhancement

Sinus Pericranii

- Often associated with APC
- Abnormal communication between intracranial and extracranial venous systems through osseous calvarial defect
- Soft red or blue scalp mass adjacent to superior sagittal or transverse dural sinuses
- ↑ size with ↑ intracranial pressure (Valsalva, dependent positioning)
- Internal venous flow, robust enhancement

Cephalohematoma or Subgaleal Hematoma

- Fluid in subgaleal space adjacent to intact calvaria
- Consider in newborn post trauma or following vaginal delivery

Sebaceous Cyst

- Dermal inclusion in scalp
- No calvarial defect or venous anomalies

Metastasis

- Destructive calvarial lesion + soft tissue mass
- Consider neuroblastoma in infant or toddler

https://CafePezeshki.IR

Heterotopic Scalp Nodule

- Neuroectodermal malformation containing heterotopic leptomeningeal or glial tissue
- Focal alopecia surrounded by ring of long coarse hair ("hair collar" sign) ± surrounding capillary stain
  - May have rudimentary stalk with intracranial communication
- Clinically resembles dermoid cyst

PATHOLOGY

General Features

- Etiology
  - Considered involuted true cephalocele (meningocele or encephalocele)
  - Originates from overdistended rhombencephalic vesicle at 7-10 weeks of fetal life
    - Presence of persistent midline neural crest cells may prevent mutual induction of ectoderm and mesoderm
  - Postulated link to folate deficiency, valproic acid exposure
- Genetics
  - Typically sporadic, some cases syndromic
  - Syndromic more likely to have associated intracranial anomalies
- Associated abnormalities
  - Variable incidence
    - Most APC are incidentally identified without additional intracranial anomalies
    - Holoprosencephaly, callosal agenesis, eye anomalies, and interhemispheric cyst most common

Gross Pathologic & Surgical Features

- Hamartomatous subgaleal mass with adjacent focal cranium bifidum
- Connects to dura mater via fibrous stalk terminating in falx or tentorium
- CSF tract to supracerebellar, suprapineal, and quadrigeminal cisterns

Microscopic Features

- Meningeal and vestigial neural tissue rests
- CSF tract ependymal lined

CLINICAL ISSUES

Presentation

- Most common signs/symptoms
  - Soft palpable interparietal subgaleal mass
  - Overlying skin may be abnormally thin (cutis aplasia) and hairless (alopecia)
- Other signs/symptoms
  - APC may enlarge with crying
- Clinical profile
  - Subgaleal mass identified incidentally or during imaging evaluation for other anomalies

Demographics

- Age
  - Infants and young children
- Gender
  - M ≤ F
- Epidemiology
  - APC 10x more common than large parietal cephalocele
  - More common in Western hemisphere

Natural History & Prognosis

- Outcome determined more by associated anomalies than presence of APC
  - Children with no associated intracranial anomalies usually have normal clinical outcome
  - Additional intracranial anomalies (more common in syndromic patients) → worse outcome

Treatment

- Surgical resection of cephalocele with dural repair

DIAGNOSTIC CHECKLIST

Consider

- APC in differential diagnosis for child with midline parietal skin-covered subgaleal mass
- Prognosis depends more on associated occult brain anomalies than existence of cephalocele itself

Image Interpretation Pearls

- Persistent falcine sinus points to cephalocele
- Lack of abnormally dilated scalp veins, absence of falcine vein, and characteristic fibrous tract distinguish from sinus pericranii

SELECTED REFERENCES

1. Leykamm S et al: Atretic cephalocele and associated anomalies in a newborn child. Clin Neuroradiol. 23(1):37-40, 2013
2. Hsu SW et al: Atretic parietal cephalocele associated with sinus pericranii: embryological consideration. Brain Dev. 34(4):325-8, 2012
3. Şengöz A et al: Atretic cephalocele in adults. Acta Neurochir (Wien). 153(11):2275-7, 2011
4. Morioka T et al: Detailed anatomy of intracranial venous anomalies associated with atretic parietal cephaloceles revealed by high-resolution 3D-CISS and high-field T2-weighted reversed MR images. Childs Nerv Syst. 25(3):309-15, 2009
5. Güzel A et al: Atretic parietal cephalocele. Pediatr Neurosurg. 43(1):72-3, 2007
6. Yamazaki T et al: Atretic cephalocele--report of two cases with special reference to embryology. Childs Nerv Syst. 17(11):674-8, 2001

https://CafePezeshki.IR

(Left) *Sagittal T1WI MR shows a typical small, subscalp, fluid-filled atretic parietal cephalocele* ➡. **(Right)** *Axial 3D bone CT of the calvaria in the same case demonstrates a small, focal, midline, interparietal calvarial defect* ⇨ *representing the focal cranium bifidum through which the cephalocele communicates intracranially via the fibrous stalk.*

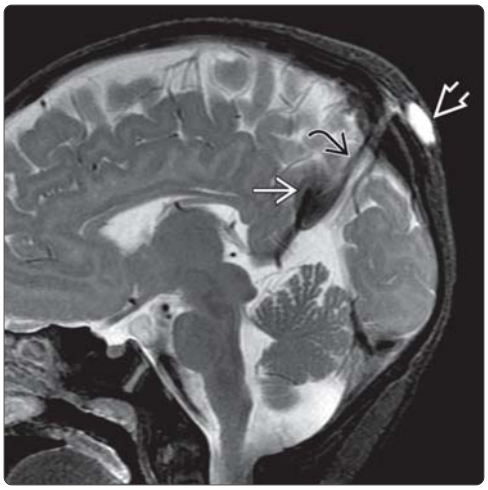

(Left) *Sagittal T1WI FS MR shows a classic atretic parietal cephalocele with falcine vein* ➡ *and fluid collection* ➡. *The fibrous stalk* ⇨ *connecting the cephalocele through the calvarial defect is difficult to distinguish from the venous flow void.* **(Right)** *Sagittal T1WI C+ MR in the same patient shows a persistent falcine vein* ➡ *and a fluid-filled, skin-covered cephalocele* ➡. *The fibrous stalk* ⇨ *connecting the cephalocele through the calvarial defect is clearly visible next to the enhancing falcine vein.*

(Left) *Axial 2D time-of-flight MRV source image clearly demonstrates a focal split of the superior sagittal sinus* ➡ *surrounding the atretic cephalocele fibrous stalk* ⇨. **(Right)** *Sagittal T1WI C+ FS MR demonstrates the uncommon occipital variant of atretic cephalocele. As in the parietal variant, there is an aberrant vein* ➡ *and fibrous tract* ⇨ *"pointing" to the atretic cephalocele* ➡.

https://CafePezeshki.IR

Leptomeningeal Cyst ("Growing Fracture")

KEY FACTS

TERMINOLOGY
- Enlarging calvarial fracture adjacent to post-traumatic encephalomalacia

IMAGING
- Linear lytic skull lesion with scalloped margins
- Brain tissue and cerebrospinal fluid (CSF) extending between bone edges acutely
- Subsequent development of encephalomalacia underlying fracture

TOP DIFFERENTIAL DIAGNOSES
- Epidermoid
- Parietal foramina/fissures
- Langerhans cell histiocytosis
- Calvarial metastasis
- Osteomyelitis

PATHOLOGY
- Scalloped fracture margins with differential erosion of inner, outer tables
- Absence of leptomeninges along inner surface of torn dura, over adjacent brain
- Brain necrosis, gliosis

CLINICAL ISSUES
- Infant or child: Enlarging palpable soft scalp mass
- Adults: Usually discovered as nontender, nonpulsatile, subcutaneous mass
- 90% occur in patients < 3 years

DIAGNOSTIC CHECKLIST
- Consider diagnosis in all infants with radiographic skull defect or palpable scalp mass
- Increasing fracture diastasis over time rather than healing

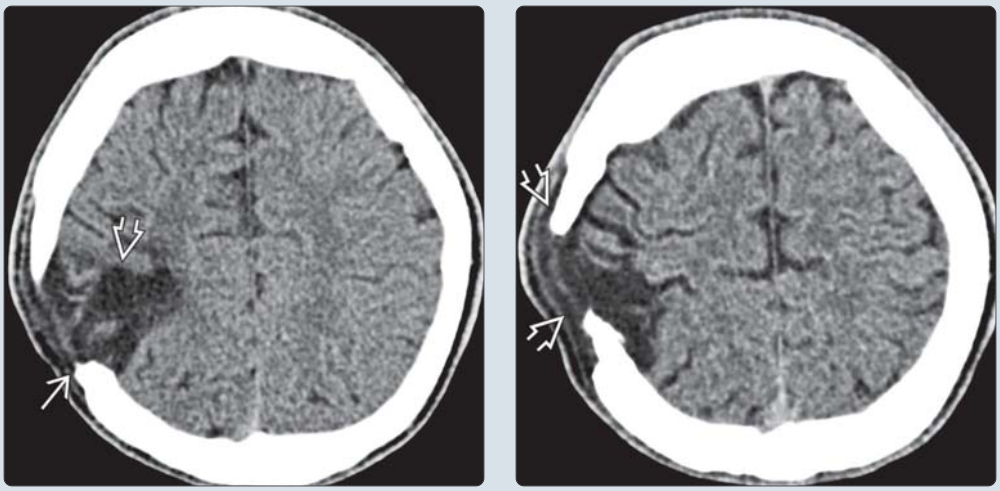

(Left) *A routine follow-up axial NECT scan in a 14-year-old male was obtained 2 months after a football injury with concussion led to evacuation of a subdural hematoma. The study shows a skull defect ➡ and post-traumatic encephalomalacia ➡.* **(Right)** *Two years later, the same patient noticed a gradually increasing "lump" on the side of his head. Repeat NECT scan shows the edges of the skull defect protrude outwards with a CSF-like mass ➡ extending through the defect under the galea.*

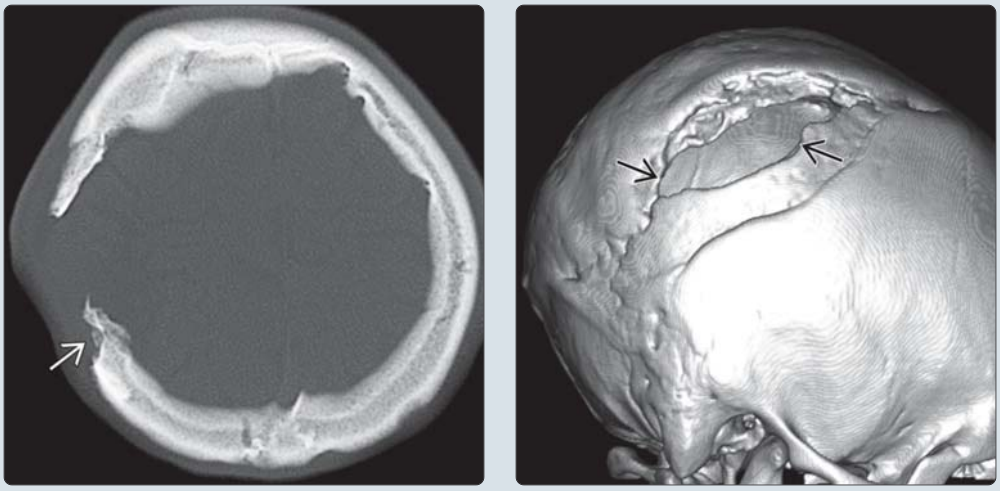

(Left) *Axial bone CT shows the margins of the skull defect are well corticated. Note the scalloping of the outer table of the calvaria ➡.* **(Right)** *3D reformatted image of the bone CT scan with shaded surface display shows widened, scalloped bone defect ⇨. A "growing" skull fracture with leptomeningeal cyst was surgically repaired.*

https://CafePezeshki.IR

TERMINOLOGY

Definitions

- Enlarging calvarial fracture adjacent to post-traumatic encephalomalacia

IMAGING

General Features

- Best diagnostic clue
  - Persistent or widening calvarial fracture line following head trauma
- Location
  - Parietal bone most common

Imaging Recommendations

- Protocol advice
  - Routine NECT viewed in brain and bone algorithm

Radiographic Findings

- Radiography
  - Linear lytic skull lesion with scalloped margins

CT Findings

- NECT
  - Brain tissue, cerebrospinal fluid (CSF) extending between bone edges acutely
  - Subsequent encephalomalacia under fracture

MR Findings

- T1WI
  - Cyst isointense with CSF, communicates with subarachnoid space
  - Subsequent development of encephalomalacia underlying fracture
- T2WI
  - Same as T1WI

DIFFERENTIAL DIAGNOSIS

Epidermoid Cyst

- Well-defined sclerotic margins, + diffusion restriction

Congenital Calvarial Defects

- Look for bilateral symmetry, characteristic location to suggest diagnosis

Langerhans Cell Histiocytosis

- Classic beveled edge appearance unusual in infants prior to development of diploic layer

Calvarial Metastasis

- Consider leukemia, neuroblastoma

Osteomyelitis

- Overlying soft tissue edema, poorly defined infiltrating destructive margins

PATHOLOGY

General Features

- Etiology
  - Skull fracture + dural tear → herniation of pia, arachnoid (leptomeninges) through dural tear
  - Leptomeninges disappear from inner surface of torn dura and over adjacent brain
  - CSF pulsations → progressive skull erosion around fracture
  - Interposition of brain tissue prevents osteoblast migration, inhibits fracture healing
  - Damaged brain becomes necrotic or gliotic → encephalomalacia

Gross Pathologic & Surgical Features

- Absence of leptomeninges along inner surface of torn dura, over adjacent brain

Microscopic Features

- Brain necrosis, gliosis

CLINICAL ISSUES

Presentation

- Most common signs/symptoms
  - Infant or child: Enlarging palpable soft scalp mass
    - Predisposing fracture may not have been clinically recognized
  - Adults: Usually discovered as nontender subcutaneous mass
    - History of childhood trauma rarely remembered or difficult to elicit

Demographics

- Age
  - 90% occur in patients < 3 years
- Epidemiology
  - Rare: 0.6% of pediatric skull fractures
  - Falling is most frequent injury mechanism

Natural History & Prognosis

- Increasing fracture diastasis over time
- ± progressive neurologic deficits (seizures, paresis), particularly in adult presentation

Treatment

- Surgical repair of dura, cyst resection

DIAGNOSTIC CHECKLIST

Consider

- Consider diagnosis in all infants with radiographic skull defect or palpable scalp mass

Image Interpretation Pearls

- Increasing fracture diastasis over time rather than healing

SELECTED REFERENCES

1. Collins J et al: Growing skull fracture of midline posterior cranial vault. J Pediatr. 166(2):494, 2015
2. Hollon T et al: Skull fracture mimicking eosinophilic granuloma. Childs Nerv Syst. ePub, 2015
3. Prasad GL et al: Surgical results of growing skull fractures in children: a single centre study of 43 cases. Childs Nerv Syst. 31(2):269-77, 2015
4. Drapkin AJ: Growing skull fracture: a posttraumatic neosuture. Childs Nerv Syst. 22(4):394-7, 2006
5. Glass RB et al: The infant skull: a vault of information. Radiographics. 24(2):507-22, 2004

https://CafePezeshki.IR

KEY FACTS

TERMINOLOGY

- Headache caused by ↓ intracranial CSF pressure

IMAGING

- Classic imaging
  - Diffuse dural thickening/enhancement
    - Smooth, not nodular or "lumpy-bumpy"
  - Downward displacement of brain through incisura ("slumping" midbrain)
  - Veins, dural sinuses distended
  - ± subdural hygromas/hematomas
- Lack of 1 or more of 4 classic findings does not preclude diagnosis

TOP DIFFERENTIAL DIAGNOSES

- Meningitis
- Meningeal metastases
- Chronic subdural hematoma
- Dural sinus thrombosis
- Postsurgical dural thickening
- Idiopathic hypertrophic cranial pachymeningitis

CLINICAL ISSUES

- Severe headache (orthostatic, persistent, pulsatile, or even associated with nuchal rigidity)
- Uncommon: CN palsy (e.g., abducens), visual disturbances
- Rare: Severe encephalopathy with disturbances of consciousness
- Profile: Young/middle-aged adult with orthostatic headache

DIAGNOSTIC CHECKLIST

- Frequently misdiagnosed clinically; imaging is key to diagnosis
  - Do not misdiagnose intracranial hypotension as Chiari 1
  - Surgery can exacerbate symptoms; in rare cases can be fatal
- Only rarely are **all** classic findings of IH present in same patient

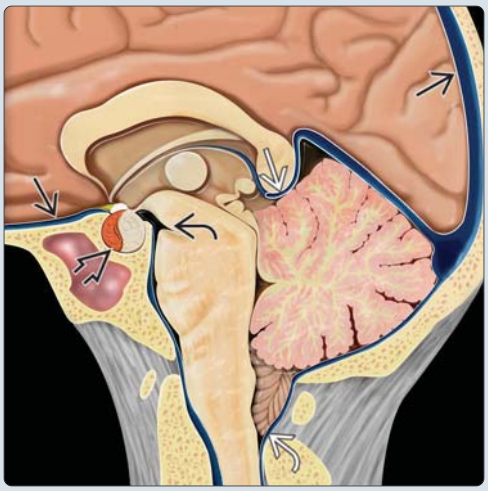

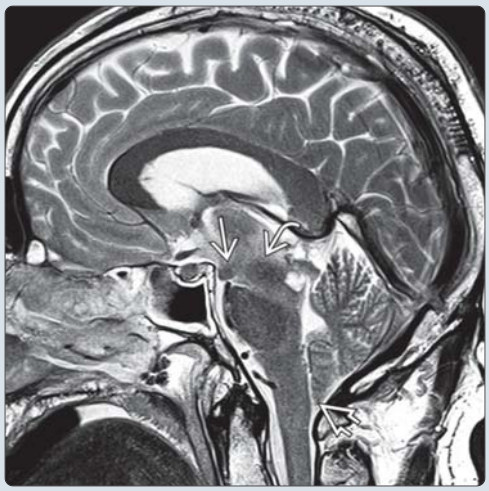

(Left) *Graphic shows IH with distended dural sinuses, enlarged pituitary, & herniated tonsils. Central brain descent causes midbrain slumping, inferiorly displaced pons, closed pons-midbrain angle, & splenium depressing ICV/vein of Galen junction.* **(Right)** *Sagittal T2 WI in a 57-year-old man treated for "migraine" headaches shows severe midbrain slumping, downwardly displaced cerebellar tonsils, draping of hypothalamus over dorsum sellae with mammillary bodies below dorsum.*

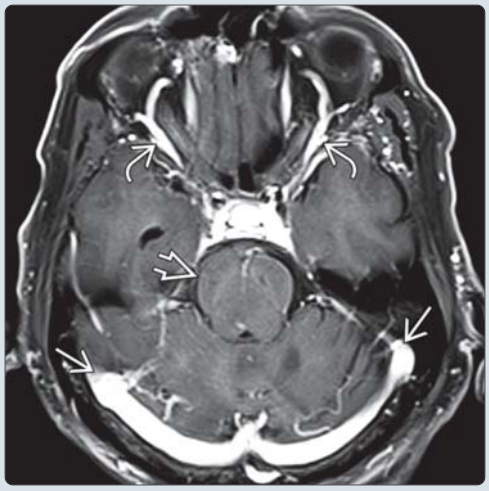

(Left) *Sagittal T1 C+ FS MR scan in the same case shows the severe midbrain "slumping" and inferiorly displaced tonsils. In addition, the pituitary gland appears "fat" and the dural venous sinuses are engorged.* **(Right)** *Axial T1 C+ FS scan in the same case shows a "fat" midbrain/pons, prominent superior ophthalmic veins, and engorged, outwardly convex transverse/sigmoid sinuses. No subdural hematomas were identified. Severe intracranial hypotension was treated successfully with blood patch.*

https://CafePezeshki.IR

TERMINOLOGY

Abbreviations

- Intracranial hypotension (IH)

Definitions

- Headache caused by ↓ intracranial CSF pressure

IMAGING

General Features

- Best diagnostic clue
  - Classic imaging quartet
    - Downward displacement of brain through incisura ("slumping" midbrain)
    - Diffuse dural thickening/enhancement
    - Veins, dural sinuses distended
    - Subdural hygromas/hematomas
  - Lack of 1 or more of 4 classic findings does not preclude diagnosis
- Location
  - Pachymeninges (dura)
    - Both supra- and infratentorial
    - May extend into internal auditory canals
    - Spinal dura, epidural venous plexuses may be involved
- Morphology
  - Dural enhancement is smooth, not nodular or "lumpy-bumpy"

CT Findings

- NECT
  - Relatively insensitive; may appear normal
  - Look for effaced suprasellar/basilar cisterns, "fat" midbrain/pons
  - ± thick dura
  - ± subdural fluid collections
    - Usually bilateral
    - CSF (hygroma) or blood (hematoma)
  - Atria of lateral ventricles may appear deviated medially, abnormally close ("tethered") to midline
- CECT
  - Diffuse dural thickening, enhancement

MR Findings

- T1WI
  - Sagittal view shows brain descent in 40-50% of cases
    - "Sagging" midbrain
      - Midbrain displaced inferiorly below level of dorsum sellae
      - Pons may be compressed against clivus
    - Decreased angle between peduncles, pons
    - Caudal displacement of tonsils in 25-75%
    - Optic chiasm, hypothalamus draped over sella
    - Pituitary enlarged above sella in 50%
    - Veins/dural sinuses distended (convex margins)
    - Decreased angle between ICVs, vein of Galen
  - Axial
    - Suprasellar cistern crowded/effaced
    - Midbrain, pons appear elongated ("fat" midbrain)
    - Temporal lobes herniated over tentorium, into incisura
    - Lateral ventricles small, often distorted
      - Atria pulled medially by downward displacement of midbrain
  - Coronal
    - Severe cases show decreased venous angle (< 120°) between roofs of lateral ventricles
  - Bilateral subdural fluid collections in 15%
    - 70% hygromas (clear fluid collects within dural border cell layer)
    - 10% hematomas (blood of variable signal intensity)
- T2WI
  - Thickened dura usually hyperintense
  - Subdural fluid (variable signal)
- FLAIR
  - Hyperintense dura, subdural fluid
- T2* GRE
  - May bloom if hemorrhage present
- T1WI C+
  - Diffuse, intense dural enhancement in 85%
  - Often extends into CPAs

Ultrasonographic Findings

- Color Doppler
  - Enlarged superior ophthalmic veins with higher mean maximum flow velocity

Angiographic Findings

- Cortical, medullary veins may be diffusely enlarged

Nonvascular Interventions

- Myelography
  - May demonstrate epidural contrast accumulation at site of CSF leak
    - Dynamic CT myelogram may show "fast" high-flow leaks
  - Caution: Myelography may facilitate CSF leak, worsen symptoms

Nuclear Medicine Findings

- Radionuclide cisternography (RNC)
  - Direct findings: Focal accumulation of radioactivity outside of subarachnoid space at leakage site
  - Indirect findings
    - Rapid washout from CSF space
    - Early appearance of activity in kidneys, urinary bladder
    - Poor migration of isotope over convexities

Imaging Recommendations

- Best imaging tool
  - Contrast-enhanced cranial MR for diagnosis
  - Radionuclide cisternography if localization required
- Protocol advice
  - Search for actual leakage site only if
    - 2 technically adequate blood patches fail
    - Post-traumatic leak is suspected

DIFFERENTIAL DIAGNOSIS

Meningitis

- Pia-subarachnoid enhancement > dura-arachnoid

Meningeal Metastases

- Enhancement usually thicker, irregular ("bumpy")

https://CafePezeshki.IR

Chronic Subdural Hematoma

- Look for enhancing membranes with blood products

Dural Sinus Thrombosis

- Look for thrombosed sinus (empty delta sign, etc.)

Postsurgical Dural Thickening

- Look for other postoperative findings (e.g., burr holes)
- May occur almost immediately after surgery, persist for months/years

Idiopathic Hypertrophic Cranial Pachymeningitis

- Headache usually not orthostatic
- May cause bone invasion

PATHOLOGY

General Features

- Etiology
  - Dural thickening, enhancement due to venous engorgement
  - Common cause of IH = spontaneous spinal CSF leak
    - Weak dura ± arachnoid diverticulae common
    - Aberrant extracellular matrix with abnormalities of fibrillin-containing microfibrils
  - Most (but not all) cases caused by reduced CSF pressure precipitated by
    - Surgery (CSF overshunting) or trauma (including trivial fall)
    - Vigorous exercise or violent coughing
    - Diagnostic lumbar puncture
    - Spontaneous dural tear, ruptured arachnoid diverticulum
    - Severe dehydration
    - Disc herniation or osteophyte (rare)
  - Pathophysiology = Monro-Kellie doctrine
    - CSF, intracranial blood volume vary inversely
    - In face of low CSF pressure, dural venous plexuses dilate
- Associated abnormalities
  - Dilated cervical epidural venous plexus, spinal hygromas, retrospinal fluid collections
  - Typical
    - Low opening pressure (OP), < 6 cm H_2O
    - CSF frequently shows pleocytosis, ↑ protein
  - Variant
    - OP occasionally normal (CSF hypovolemia rather than hypotension)
  - Stigmata of systemic connective tissue disorder found in up to 2/3 of patients
    - Marfan, Ehlers-Danlos type 2
    - Clinical findings = minor skeletal features, small joint hypermobility, etc.; may be subtle

Gross Pathologic & Surgical Features

- Surgical specimen generally unremarkable with grossly normal-appearing dura
- Spinal meningeal diverticula (often multiple), dural holes/rents common
- No specific leakage site identified at surgery in at least 50%

Microscopic Features

- Meningeal surface normal
  - No evidence for inflammation or neoplasia
- Inner surface
  - Layer of numerous delicate, thin-walled dilated, vessels often attached to inner surface
  - Nests of meningothelial cells may be prominent, should not be misinterpreted as meningioma
  - May show marked arachnoidal, dural fibrosis if longstanding

CLINICAL ISSUES

Presentation

- Most common signs/symptoms
  - Severe headache (orthostatic, persistent, pulsatile, or even associated with nuchal rigidity)
  - Uncommon: CN palsy (e.g., abducens), visual disturbances
  - Rare: Severe encephalopathy with disturbances of consciousness
- Clinical profile
  - Young/middle-aged adult with orthostatic headache

Demographics

- Age
  - Peak in 3rd, 4th decades

Natural History & Prognosis

- Most IH cases resolve spontaneously
  - Dural thickening, enhancement disappears; midline structures return (ascend) to normal position
- Rare: Coma, death from severe intracranial herniation

Treatment

- Epidural blood patching
- Surgery if blood patch fails (usually large dural tear) or SDHs with acute clinical deterioration

DIAGNOSTIC CHECKLIST

Consider

- Frequently misdiagnosed clinically; imaging is key to diagnosis
  - Do not misdiagnose intracranial hypotension as Chiari 1
    - Surgery can exacerbate symptoms; in rare cases can be fatal

Image Interpretation Pearls

- Only rarely are **all** classic findings of IH present in the same patient
- Look for enlarged spinal epidural venous plexuses

SELECTED REFERENCES

1. Nesbitt C et al: Lumbar blood patching for proximal CSF leaks: where does the blood go? BMJ Case Rep. 2015, 2015
2. Xia P et al: Risk factors for subdural haematoma in patients with spontaneous intracranial hypotension. PLoS One. 10(4):e0123616, 2015
3. Graff-Radford SB et al: High-pressure headaches, low-pressure syndromes, and CSF leaks: diagnosis and management. Headache. 54(2):394-401, 2014
4. Scott S et al: Low pressure headaches caused by spontaneous intracranial hypotension. BMJ. 349:g6219, 2014

https://CafePezeshki.IR

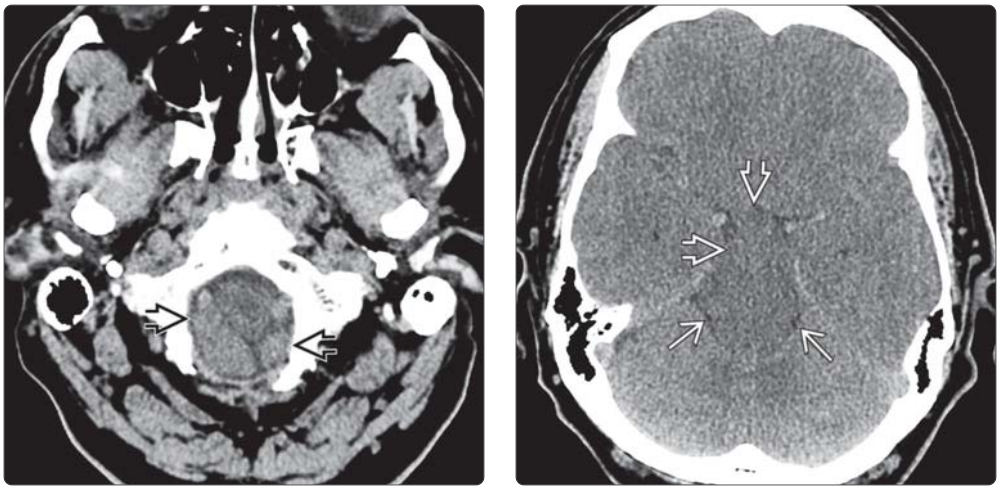

(Left) *Axial NECT in a 55-year-old man with severe headache in the ER shows downward herniation of both cerebellar tonsils through the foramen magnum.* **(Right)** *More cephalad NECT in the same patient shows effacement of all basal cisterns, especially the suprasellar cistern. The midbrain appears "fat". The imaging findings are suggestive of intracranial hypotension.*

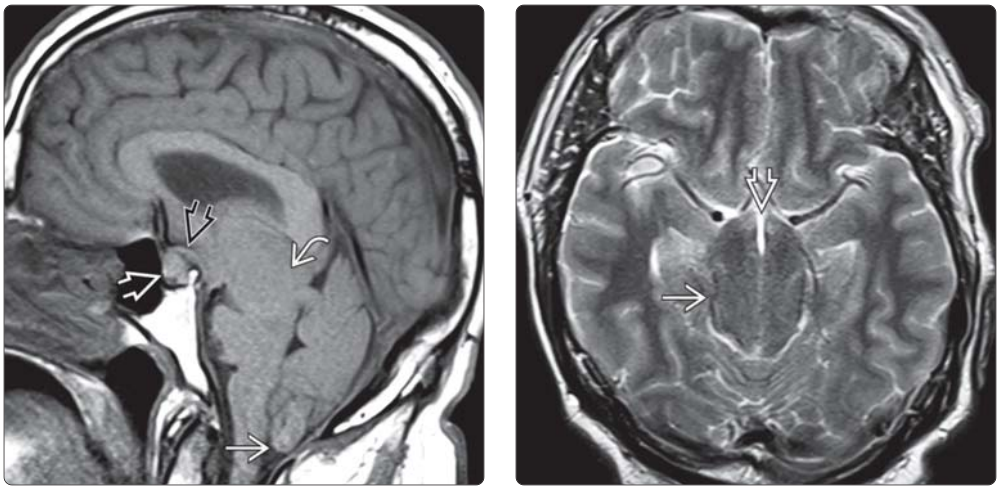

(Left) *Sagittal T1WI MR in the same patient shows changes of severe intracranial hypotension, with midbrain "slumping", downward tonsillar displacement, "fat" pituitary gland, and draping of the optic chiasm/hypothalamus over the dorsum sellae.* **(Right)** *Axial T2WI MR in the same patient shows the inferiorly displaced hypothalamus and third ventricle obliterating the suprasellar cistern. The midbrain appears "fat" and elongated.*

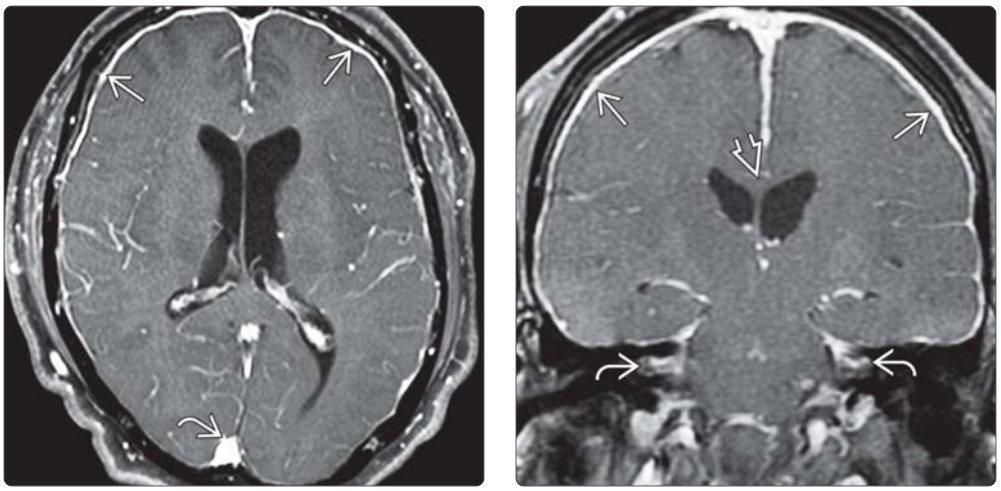

(Left) *Axial T1 C+ FS MR in the same patient shows smooth, diffuse dura-arachnoid enhancement and an engorged, outwardly convex superior sagittal sinus.* **(Right)** *Coronal T1 C+ FS MR in the same patient shows the diffuse dura-arachnoid enhancement extends into both internal auditory canals. The lateral ventricles have a more acute angle and appear "pulled down" toward the incisura. Epidural blood patch relieved the symptoms.*

https://CafePezeshki.IR

KEY FACTS

TERMINOLOGY

- Definition: Nonspecific, nonneoplastic benign inflammatory lesion without identifiable local or systemic causes characterized by polymorphous lymphoplasmacytic infiltrate
- Idiopathic orbital inflammation (IOI)
  - May involve any part(s) of orbit
- Idiopathic extraorbital inflammation (IEI)
  - **Intracranial involvement**: Spread through superior orbital fissure (SOF) or optic canal (OC)
    - Cavernous sinus, dura, Meckel cave
  - **Skull base-extracranial involvement**: Spreads from inferior orbital fissure (IOF) or through orbital wall
    - Anterior skull base, sinuses, nasopharyngeal spaces
- IgG4-related disease: Subgroup of idiopathic inflammation with systemic involvement
  - Intracranial noncontiguous sites: Pituitary, infundibulum
  - Extracranial noncontiguous H&N sites: Parotid, submandibular glands, thyroid

IMAGING

- T1WI C+ FS MR: Diffusely enhancing, infiltrating mass
  - Extends from orbit through SOF ± OC to cavernous sinus, dura, Meckel cave
  - Extends through IOF to pterygopalatine fossa, nose, deep nasopharyngeal spaces
- T2: Iso- to **hypointense** lesion; ↑ fibrosis, ↓ intensity

TOP DIFFERENTIAL DIAGNOSES

- En plaque meningioma
- Meningeal non-Hodgkin lymphoma
- Nasopharyngeal carcinoma
- Neurosarcoid

CLINICAL ISSUES

- Symptoms: Painful proptosis ± headaches ± cranial neuropathies
- Diagnosis of exclusion; must be biopsied
- Treatment: High-dose systemic **steroids**

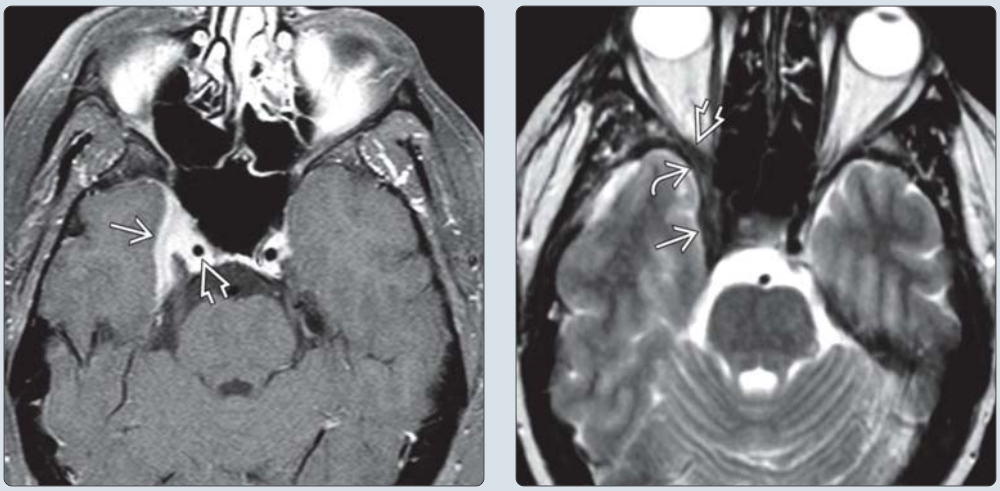

(Left) *Axial T1WI C+ FS MR shows a focus of enhancing idiopathic extraorbital inflammation (IEI) involving the right cavernous sinus ⇨ with subtle narrowing ⇨ of the intracavernous internal carotid artery.* **(Right)** *Axial T2WI MR in the same patient reveals a idiopathic orbital inflammation (IOI) lesion ⇨ connects to the cavernous sinus IEI ⇨ through the superior orbital fissure ⇨. Both areas of idiopathic inflammation are hypointense due to the fibrosis often found within this lesion.*

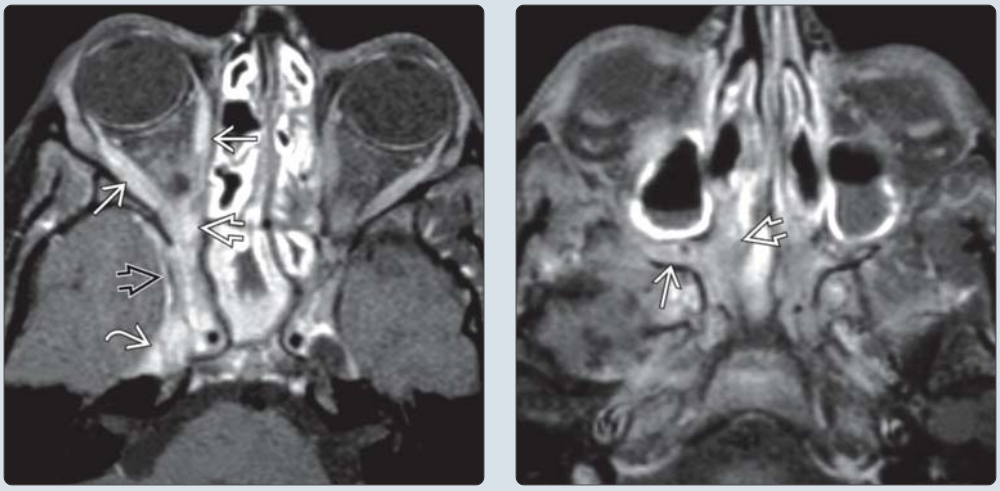

(Left) *Axial T1WI C+ FS MR through the orbits shows enlarged, enhancing orbital rectus muscles ⇨ connecting through the SOF ⇨ with the cavernous sinus ⇨ and Meckel cave ⇨. The initial impression of adenoid cystic carcinoma gave way to biopsy-proven idiopathic inflammation with both intraorbital and intracranial components.* **(Right)** *Axial T1WI C+ FS MR in the same patient shows the lesion invading inferiorly through the inferior orbital fissure into the pterygopalatine fossa ⇨ and nose ⇨.*

https://CafePezeshki.IR

TERMINOLOGY

Abbreviations

- Idiopathic extraorbital inflammation (IEI)

Synonyms

- Idiopathic inflammatory disease, Tolosa-Hunt syndrome, hypertrophic cranial pachymeningitis, plasma cell granuloma

Definitions

- Nonspecific, nonneoplastic benign inflammatory lesion without identifiable local or systemic causes characterized by polymorphous lymphoplasmacytic infiltrate
  - IgG4-related disease (IgG4-RD): Subgroup of idiopathic orbital inflammation (IOI) IEI lesions where multisystem manifestation are present with positive cell immunostain showing IgG4-rich plasma cells

IMAGING

General Features

- Best diagnostic clue
  - IOI combined with contiguous extraorbital (intracranial, skull base, or extracranial) idiopathic inflammation
- Location
  - IOI
    - May involve any part(s) of orbit
  - IEI
    - **Intracranial involvement**: Spread through superior orbital fissure (SOF) or optic canal (OC)
      - Cavernous sinus
      - Dural thickening (previously called "pachymeningitis")
      - Meckel cave area
      - Noncontiguous IgG4-RD: Pituitary, infundibulum
    - **Skull base-extracranial involvement**: Spreads from inferior orbital fissure (IOF) or through orbital wall
      - Pterygopalatine fossa, nose, sinuses
      - Anterior skull base, sinuses
      - Deep spaces of nasopharynx
      - Noncontiguous IgG4-RD: Parotid, submandibular glands, thyroid
- Size
  - Small, subtle to very extensive extraorbital involvement
  - Skull base and extracranial soft tissue masses may be large (many centimeters)
- Morphology
  - Soft tissue infiltrating lesions mimic invasive malignancy

CT Findings

- CECT
  - Orbital enhancing, infiltrating mass with extension through SOF or OC to cavernous sinus, dura, skull base
    - If extension through IOF, lesion reaches pterygopalatine fossa, nose, sinuses, deep spaces
    - If extension through orbital wall, sinuses or anterior skull base affected
- Bone CT
  - Associated bone erosion unusual
- CTA
  - If cavernous internal carotid artery (ICA) involved, often narrowed

MR Findings

- T1WI
  - Lesion isointense to gray matter
- T2WI
  - Iso- to **hypointense** infiltrating mass
    - Increased **fibrosis** yields increased hypointensity
- FLAIR
  - No adjacent brain edema
- T1WI C+
  - Orbital enhancing, infiltrating lesion spread to intra- ± extracranial contiguous sites
    - Extends though SOF-OC to cavernous sinus, local dura, Meckel cave
    - Extends through IOF to pterygopalatine fossa, nose, sinuses, deep spaces
    - If extension through orbital wall, sinuses or anterior skull base affected
- MRA
  - If cavernous sinus involved, **ICA narrowing** common

Imaging Recommendations

- Protocol advice
  - Begin with MR, including full brain FLAIR and T1WI C+ with fat saturation
    - Fat-saturated T1 C+ best sequence
  - Bone CT may help differentiate this lesion from en plaque meningioma

DIFFERENTIAL DIAGNOSIS

En Plaque Meningioma

- Enhancing meningeal mass with dural "tails"
- Permeative-sclerotic invasive bone changes typical
- May exactly mimic intracranial IEI

Meningeal Non-Hodgkin Lymphoma (NHL)

- More diffuse, multifocal with underlying bone involvement
- "Great pretender" (can mimic many intracranial diseases)

Nasopharyngeal Carcinoma

- Arises in nasopharyngeal mucosal space
- Invades cephalad into skull base, sinuses
- Orbit usually spared

Neurosarcoid

- Systemic manifestations abound
- Increased erythrocyte sedimentation rate (ESR) and serum angiotensin converting enzyme (ACE)

Skull and Meningeal Metastases

- Simultaneous orbital metastases unusual
- Nodular meningeal carcinomatosis less common than diffuse carcinomatosis
- Cranial neuropathy occurs early

PATHOLOGY

General Features

- Etiology
  - Benign inflammatory process of unknown origin

https://CafePezeshki.IR

- Immune-autoimmune pathophysiology suspected
- IgG4-RD is now recognized as subgroup of IOI-IEI

Microscopic Features

- Characteristic histopathologic features of IOI and IEI
  - Diffuse lymphoplasmacytic infiltration
  - Varying degrees of **fibrosis** present

IgG4-Related Disease Subtype Additional Features

- Microscopic features
  - IgG4-RD subgroup: IgG4-rich plasma cells
  - IgG4-RD subgroup: Mild to moderate eosinophil infiltrate
- Immunohistochemical features
  - Semiquantitative analysis of **IgG4 immunostaining** may provide compelling features
    - > 30 IgG4-positive cells per high-power field
    - IgG4:IgG ratio > 50%
    - Lower values of IgG4-positive cells acceptable for diagnosis when characteristic microscopic appearance is present
- Serum IgG4 levels
  - Serum IgG4 is not by itself sufficient to diagnose IgG4-related disease
  - Serum IgG4 is elevated in majority (can reach ≥ 25x normal) but can be seen in 20-40% of normals

CLINICAL ISSUES

Presentation

- Most common signs/symptoms
  - IOI and IEI
    - Orbital lesion: **Painful proptosis**
    - Intracranial lesion only: Chronic headaches
    - Cavernous sinus: Cranial neuropathy (CN3, 4, 5, 6)
    - Extracranial soft tissues: Focal or diffuse mass
      - Sinonasal, nasopharyngeal space mass
  - IgG-RD subtype: Other sites involved
    - Tumor-like lesion with indolent disease course (develops over months to years)
    - Head and neck: Salivary glands > thyroid gland, lymph nodes, laryngeal disease
      - Orbit: Bilateral > unilateral proptosis ± CN2 symptoms from optic nerve compression
      - Suprahyoid neck: Chronic sialoadenitis (submandibular = Küttner tumor; parotid = Mikulicz disease)
      - Infrahyoid neck: Hypothyroidism ± goiter (Hashimoto and Riedel thyroiditis); lymph nodes
    - Involvement outside of head and neck
      - Brain: Pituitary hypophysitis
      - Chest: Lung lesions; fibrosing mediastinitis and pleuritis
      - Abdomen: Type 1 autoimmune pancreatitis, sclerosing cholangitis, cholecystitis, renal lesions, retroperitoneal fibrosis
      - Vascular: Aortitis, arteritis
- Clinical profile
  - Adult presenting with painful proptosis, headaches, and cranial nerve palsies

Demographics

- Age
  - Extraorbital: Adults (40-65 years of age)

Natural History & Prognosis

- Idiopathic intraorbital and extraorbital inflammation
  - Rapid response to steroid therapy common
  - When extensive extraorbital involvement present, may be resistant to all therapies
    - May cause severe disability or death

Treatment

- Options, risks, complications
  - **Diagnosis of exclusion**
    - Extraorbital disease must be biopsied
    - Biopsy excludes infectious and neoplastic (meningioma, NHL) causes of focal dural thickening
  - **High-dose systemic steroids** with slow taper is principal treatment option
    - 70% success rate
  - Steroid-resistant cases ± cases with extensive skull base involvement
    - Radiotherapy ± chemotherapy
    - Surgical resection as possible

DIAGNOSTIC CHECKLIST

Consider

- IEI is diagnosis of exclusion
  - 1st exclude infection and malignancy with biopsy

Image Interpretation Pearls

- If infiltrating mass in orbit with contiguous dural and cavernous sinus lesion, consider IEI
- IOI alone > > IOI + IEI > > IEI alone (rare)
- If IOI + IEI with noncontiguous head and neck lesions of salivary glands, thyroid, lymph nodes ± systemic disease, consider subgroup IgG-RD
  - Recommend IgG4 immunostaining of tissue biopsy and serum IgG4 analysis

SELECTED REFERENCES

1. Bhatti RM et al: IgG4-related disease of the head and neck. Adv Anat Pathol. 20(1):10-6, 2013
2. Fujita A et al: IgG4-related disease of the head and neck: CT and MR imaging manifestations. Radiographics. 32(7):1945-58, 2012
3. Toyoda K et al: MR imaging of IgG4-related disease in the head and neck and brain. AJNR Am J Neuroradiol. 33(11):2136-9, 2012
4. Battineni ML et al: Idiopathic hypereosinophilic syndrome with skull base involvement. AJNR Am J Neuroradiol. 28(5):971-3, 2007
5. Mangiardi JR et al: Extraorbital skull base idiopathic pseudotumor. Laryngoscope. 117(4):589-94, 2007
6. Narla LD et al: Inflammatory pseudotumor. Radiographics. 23(3):719-29, 2003
7. Cho YS et al: Inflammatory pseudotumour involving the skull base and cervical spine. J Laryngol Otol. 115(7):580-4, 2001
8. Bencherif B et al: Intracranial extension of an idiopathic orbital inflammatory pseudotumor. AJNR Am J Neuroradiol. 14(1):181-4, 1993

https://CafePezeshki.IR

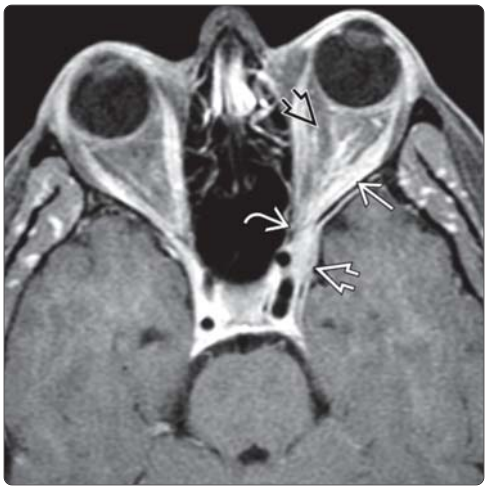

(Left) *In this patient with painful proptosis, axial T1WI C+ FS MR shows an intraorbital lateral rectus ⇨ and intraconal ⇨ lesion. Note the idiopathic inflammation spreads through the superior orbital fissure (SOF) ⇨ to the anterior cavernous sinus ⇨.* **(Right)** *Coronal T1WI C+ FS MR in the same patient shows the intracranial extension of the lesion into the left cavernous sinus ⇨. Idiopathic orbital inflammation extending into the cavernous sinus is the most common form of extraorbital extension.*

(Left) *Axial T1WI C+ FS MR shows extensive orbital apex ⇨, ethmoid sinus ⇨, and foramen rotundum ⇨ infiltrating, enhancing idiopathic inflammation.* **(Right)** *On a more inferior slice in the same patient, axial T1WI C+ FS MR reveals bilateral pterygopalatine fossa ⇨ involvement with continuous intranasal IEI ⇨. Both inferior orbital fissures are also affected ⇨. Large IOI-IEI deposits often respond poorly to steroid treatment.*

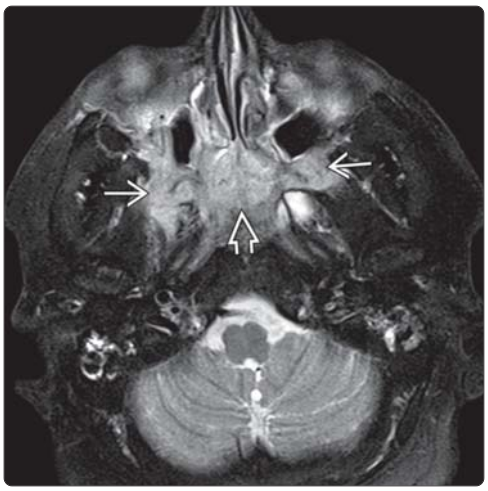

(Left) *Axial T2WI FS MR in the same patient shows an infiltrating idiopathic inflammation in the orbital apex ⇨, ethmoid sinus ⇨, and foramen rotundum ⇨. Hyperintense obstructed sinuses are easily differentiated from the IOI-IEI. Hypointensity results from diffuse fibrosis often seen within larger lesions.* **(Right)** *Axial T2WI FS MR in the same patient shows extensive idiopathic extraorbital inflammation involving of the pterygopalatine fossae ⇨ and posterior nose ⇨.*

https://CafePezeshki.IR

IgG4-Related Disease

KEY FACTS

TERMINOLOGY

- IgG4-related disease (IgG4-RD)
- Chronic fibroinflammatory disease characterized by IgG4(+) plasma cell infiltrates

IMAGING

- Diffusely infiltrating enhancing mass
  - Orbital adnexae (lacrimal gland most common)
  - Dura-arachnoid (IgG4-related hypertrophic pachymeningitis)
  - Pituitary gland, stalk (hypophysitis)
  - Other: Cranial nerves (especially infraorbital nerve), brain (autoimmune-like encephalopathy)
- MR
  - Isointense to brain on T1WI, hypointense on T2WI
  - Enhances strongly, uniformly

TOP DIFFERENTIAL DIAGNOSES

- Idiopathic inflammatory pseudotumor
- Meningioma
- Neurosarcoid
- Lymphoma

CLINICAL ISSUES

- All ages, but 6th-7th decades most common
  - Exophthalmos, headache
  - Cranial neuropathy
- Clinical course
  - Glucocorticosteroids → improvement/remission (relapses common if tapered/discontinued)
- Between 3-30% of IgG4-RD patients have normal serum IgG4 concentrations
- Elevated serum IgG4 is **not** diagnostic of IgG4-RD (neither sensitive nor specific)

DIAGNOSTIC CHECKLIST

- Best diagnostic clue is combination of clinical history, physical examination, laboratory, imaging

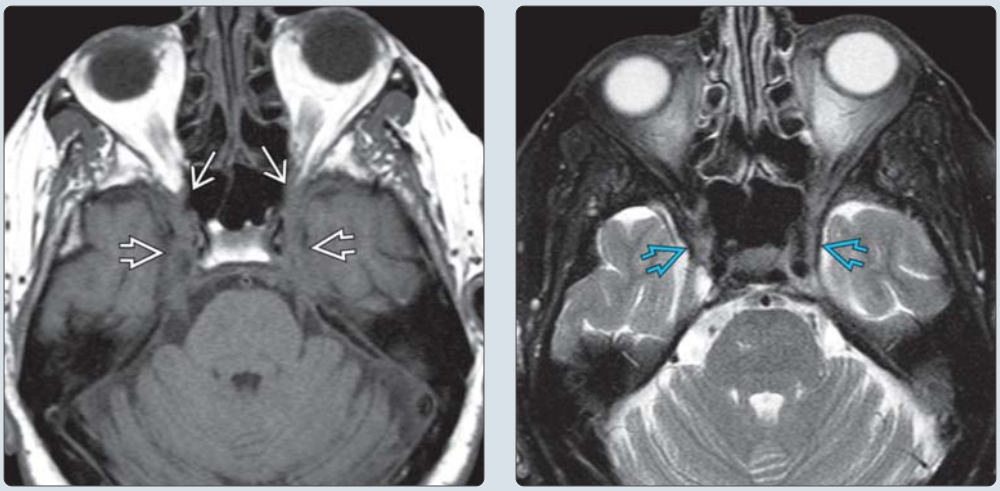

(Left) *Axial T1WI MR in an 81-year-old man with decreasing vision in his left eye shows diffuse infiltration of the cavernous sinus ⇨ and orbital apices ⇨ by soft tissue that is isointense relative to the brain. The lacrimal glands are not affected.* **(Right)** *Axial T2 FS MR in the same patient shows the infiltrates ⇨ are hypointense relative to the brain.*

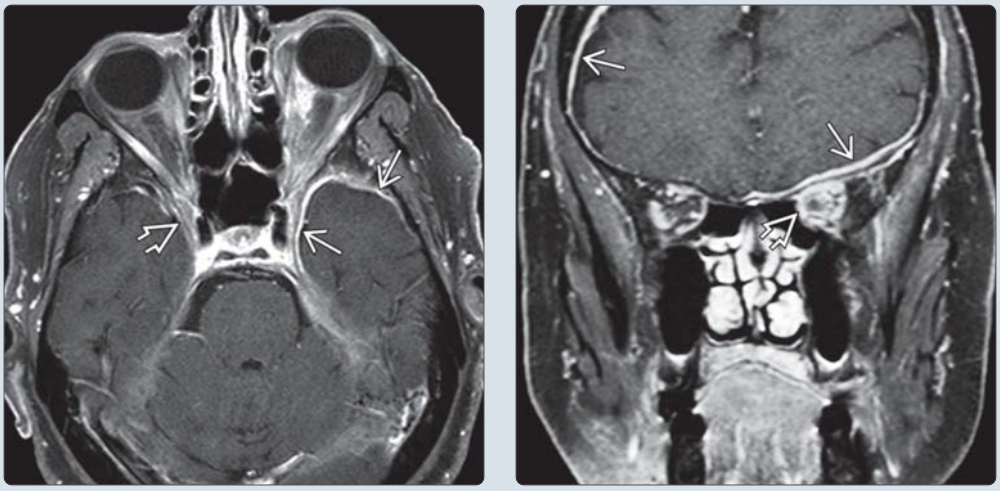

(Left) *T1 C+ FS MR in the same patient shows the cavernous sinus ⇨ and orbital apex infiltrates enhance strongly. In addition, note thickened, enhancing dura-arachnoid ⇨ in the left middle cranial fossa.* **(Right)** *Coronal T1 C+ FS scan in the same case shows that the dura-arachnoid enhancement is bilateral ⇨, and the posterior orbit is filled with enhancing soft tissue ⇨ that surrounds and encases the left optic nerve. Biopsy disclosed IgG4-related disease.*

https://CafePezeshki.IR

TERMINOLOGY

Abbreviations

- IgG4-related disease (IgG4-RD)

Synonyms

- Organ-specific conditions now related to IgG4
  - Mikulicz disease (lacrimal, parotid, submandibular glands)
  - Autoimmune pancreatitis (AIP)
  - Ormond disease (retroperitoneal fibrosis)
  - IgG4-related ophthalmic disease
- "Idiopathic" pseudotumor (generic)

Definitions

- Chronic fibroinflammatory disease characterized by IgG4(+) plasma cell infiltrates

IMAGING

General Features

- Best diagnostic clue
  - Diffusely infiltrating, enhancing mass involving orbit, cavernous sinus, dura
- Location
  - Can affect nearly any organ
    - Pancreas, kidney, retroperitoneum most common
    - Can cause granulomatosis with polyangiitis (formerly Wegener)
  - Head and neck
    - Salivary glands
    - Orbital adnexal structures (lacrimal gland most common)
      - Bilateral disease common
    - Otologic involvement occurs but less common
  - CNS
    - Dura-arachnoid (IgG4-related hypertrophic pachymeningitis)
    - Pituitary gland, stalk (hypophysitis)
    - Other: Cranial nerves (especially infraorbital nerve enlargement), brain (autoimmune-like encephalopathy)

CT Findings

- May be normal if no orbital involvement
- Bone erosion if involves skull base

MR Findings

- T1WI
  - Infiltrative mass isointense with brain
- T2WI
  - Hypointense
- T1WI C+
  - Enhances strongly, uniformly
    - Dura-arachnoid thickening ± focal mass-like lesion
    - Pituitary stalk, cranial nerves may be infiltrated

Nuclear Medicine Findings

- Hypermetabolic on FDG PET/CT
  - May delineate multiorgan involvement (e.g., aorta)

Imaging Recommendations

- Best imaging tool
  - Thin-section T1-, T2WI; contrast-enhanced axial, coronal

DIFFERENTIAL DIAGNOSIS

Idiopathic Inflammatory Pseudotumor

- Many "idiopathic" pseudotumors may be IgG4-RD
- "Idiopathic" hypertrophic pachymeningitis may be IgG4-RD

Meningioma

- En plaque meningioma of greater sphenoid wing can mimic IgG4-RD
- Bone thickening, erosion more common

Neurosarcoid

- May require biopsy for diagnosis

Lymphoma

- Metastatic > primary CNS lymphoma
- Skull ± "lumpy-bumpy" dura-arachnoid

PATHOLOGY

Gross Pathologic & Surgical Features

- "Tumefactive" mass-like lesion
- Variable fibrosis

Microscopic Features

- IgG4(+) plasma infiltrate

CLINICAL ISSUES

Presentation

- Most common signs/symptoms
  - Exophthalmos, headache
- Other signs/symptoms
  - Cranial neuropathy

Demographics

- Age
  - 6th-7th decades most common

Natural History & Prognosis

- Relapsing, remitting

Treatment

- Steroids (improve; relapses common)

DIAGNOSTIC CHECKLIST

Consider

- Best diagnostic clue is combination of clinical history, physical examination, laboratory, and imaging
  - 3-30% of IgG4-RD patients have normal serum IgG4 concentrations
  - Elevated serum IgG4 is **not** diagnostic of IgG4-RD (neither sensitive nor specific)
- Biopsy recommended for diagnosis, excluding malignancy
  - Immunohistochemistry shows IgG4(+) plasma cells
    - Caution: Occur in conditions other than IgG4-RD

SELECTED REFERENCES

1. Deshpande V: IgG4 related disease of the head and neck. Head Neck Pathol. 9(1):24-31, 2015
2. Joshi D et al: Cerebral involvement in IgG4-related disease. Clin Med. 15(2):130-4, 2015

https://CafePezeshki.IR

KEY FACTS

TERMINOLOGY

- Fibrous dysplasia (FD)
  - Synonyms: Craniofacial fibrous dysplasia (CFD), osteitis fibrosa, osteodystrophy fibrosa
- McCune-Albright syndrome (MAS)
  - One of the most common FD syndromes
- Congenital disorder characterized by expanding lesion(s)
  - Defect in osteoblastic differentiation, maturation
  - Contains mixture of fibrous tissue, woven bone

IMAGING

- Best diagnostic clue: Ground-glass matrix in bone lesion on CT
- CFD: Majority have > 1 bone involved
- MR: ↓ T2WI signal throughout (if solid) or in rim (if cystic)
  - Variable enhancement
  - Rim, diffuse, or none

TOP DIFFERENTIAL DIAGNOSES

- Paget disease
- Garré sclerosing osteomyelitis
- Meningioma

CLINICAL ISSUES

- Most common signs/symptoms: Painless swelling or deformity
- Demographics
  - < 6 years (39%), 6-10 years (27%), > 10 years (39%)
  - MAS usually (but not exclusively) female
  - Monostotic FD 6x more common than polyostotic FD
  - Monostotic FD (75%): 25% found in skull, face
  - Polyostotic FD (25%): 50% found in skull, face
  - Calvarial involvement differs: Polyostotic FD (50%) > monostotic FD (25%)
- RARE progression to fibro-, osteo-, chondro-, and mesenchymal sarcoma

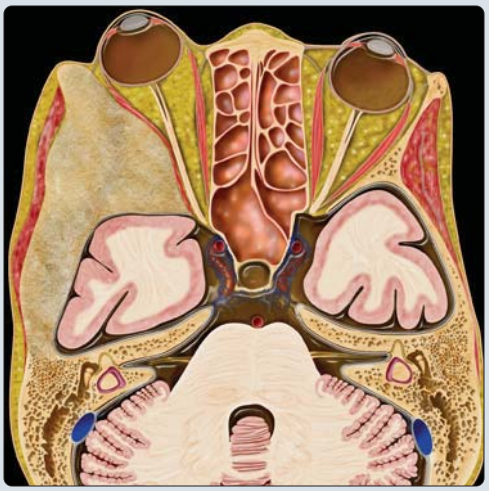

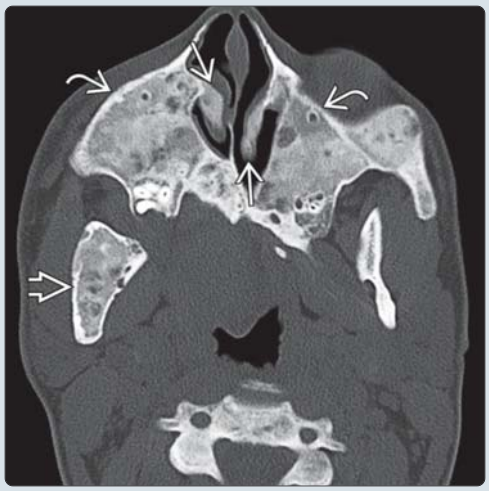

(Left) *Axial graphic shows expansion of the lateral orbital rim, sphenoid wing, and temporal squamosa by fibrous dysplasia. Note the exophthalmos and stretching of the optic nerve on the ipsilateral side.* **(Right)** *Axial bone CT in a 16-year-old male with McCune-Albright syndrome shows classic findings of polyostotic fibrous dysplasia (FD). The typical expansile lesions with ground-glass appearance are seen in the right mandible, both maxillary sinuses, and even the bony nasal turbinates.*

(Left) *Another cephalad scan in the same patient shows the basisphenoid, sphenoid alae, and frontal bones are expanded with mottled ground-glass pattern intermixed with more heterogeneous areas of radiopacity and radiolucency. Note the narrowing of the right optic canal.* **(Right)** *More cephalad scan in the same patient shows the classic multifocal areas of bony expansion with characteristic ground-glass appearance of FD.*

https://CafePezeshki.IR

TERMINOLOGY

Abbreviations

- Fibrous dysplasia (FD)

Synonyms

- Craniofacial fibrous dysplasia (CFD), osteitis fibrosa, osteodystrophy fibrosa
- McCune-Albright syndrome (MAS): One of the most common FD syndromes
- Jaffe-Lichtenstein dysplasia (monostotic FD)

Definitions

- Congenital disorder characterized by expanding lesions with mixture of fibrous tissue and woven bone
- Defect in osteoblastic differentiation and maturation
- One of the most common fibroosseous lesions

IMAGING

General Features

- Best diagnostic clue
  - Ground-glass matrix in bone lesion on CT
- Location
  - May involve any aspect of skull
  - CFD: Majority have > 1 bone involved
    - Maxilla, orbit, and frontal bones most common in one series; ethmoids and sphenoids in another

Radiographic Findings

- Radiography
  - Expanded bone with ground-glass appearance
  - CFD: Dental malocclusions in 20%

CT Findings

- NECT
  - Imaging patterns relate to relative content of fibrous and osseous tissue
  - Expansile bone lesion, widened diploic space
  - Ground-glass, sclerotic, cystic, or mixed bone changes
    - If cystic, may have thick sclerotic rind

MR Findings

- T1WI
  - Usual: ↓ signal
- T2WI
  - Usual: ↓ signal (if solid) or in rind (if cystic)
  - ↑ clinical-pathologic activity leads to ↑ signal
- T1WI C+
  - Variable enhancement depends on lesion pattern (rim, diffuse, or none)

Nuclear Medicine Findings

- Bone scan
  - Variable radionuclide uptake: Perfusion/delayed phases
  - Nonspecific; sensitive to extent of skeletal lesions in polyostotic FD
- PET
  - Accumulation of 11C-MET
  - Can be variably hot on FDG PET
    - Should not be mistaken for metastasis
    - Correlation with radiograph, CT helps

Imaging Recommendations

- Best imaging tool
  - Bone CT
- Protocol advice
  - CT or MR to define local extent
  - Bone scan to search for additional lesions

DIFFERENTIAL DIAGNOSIS

Paget Disease

- Pagetoid ground-glass FD mimics Paget disease
- Paget: Calvaria, not craniofacial; "cotton wool" CT

Garré Sclerosing Osteomyelitis

- Bony expansion, but inhomogeneous sclerotic pattern; ± dehiscent bone cortex; ± periosteal reaction

Jaffe-Campanacci (J-C) Syndrome

- Nonossifying fibromas, axillary freckling, and café au lait (lacks neurofibromas)
- Mimics polyostotic forms of FD
  - J-C café au lait: Coast of California (like neurofibromatosis type 1)
  - McCune-Albright café au lait: Coast of Maine

Craniometaphyseal Dysplasia

- Hyperostosis and sclerosis of craniofacial bones → facial distortion, cranial nerve compression
- Abnormal modeling of long bone metaphyses; paranasal "bossing"

Meningioma

- Resulting hyperostosis mimics FD
- MR spectroscopy: Characteristic alanine peak

Other Disorders With Expanded Bone and Abnormal Bony Density

- Thalassemia: Maxillary sinus involvement typical; "hair on end" skull
- Osteopetrosis: Involvement of all bones
- Neurocutaneous disorders: Osteitis fibrosa cystica in
  - Tuberous sclerosis
  - Neurofibromatosis type 1
- Chronic renal failure: Renal osteodystrophy may simulate leontiasis ossea
- Morgagni syndrome of hyperostosis frontalis interna
  - Postmenopausal women, limited to frontal bone

PATHOLOGY

General Features

- Etiology
  - Mutation of Gsα protein in osteoblastic progenitor cells leads to ↑ proliferation; abnormal differentiation
- Genetics
  - Numerous up-/down-regulated genes described
    - Mutations in regulatory Gsα protein (encoded by *GNAS1* gene) common to monostotic, polyostotic, and MAS
    - *ADAMTS2* significantly overexpressed in FD tissues

Staging, Grading, & Classification

- Monostotic vs. polyostotic

https://CafePezeshki.IR

- Specific lesion type (pagetoid, sclerotic, cystic) relates to disease activity
  - Cystic, pagetoid, and sclerotic FD believed to represent (in order) most to least active
    - Cystic FD (11-21%): Hypodense (CT) except rind
    - Pagetoid mixed FD (56%): Ground-glass plus cystic change
    - Homogeneous sclerotic FD (23-34%)

Gross Pathologic & Surgical Features

- Fibrous, tan to gray gritty tissue
- Variable consistency depends upon fibrous vs. osseous components
- Woven bone immature, structurally weak, prone to fractures
- Hemorrhage, cystic change may be present

Microscopic Features

- Fibrous stroma, usually avascular, low cellularity
- Osseous metaplasia: Bone trabeculae made up of immature, woven bone seen as peculiar shapes floating in fibrous stroma
  - Looks like "Chinese letters" or "alphabet soup"

CLINICAL ISSUES

Presentation

- Most common signs/symptoms
  - Swelling &/or deformity, pain
- Clinical profile
  - Proptosis, cranial neuropathy (diplopia, hearing loss, blindness), atypical facial pain or numbness, headache
  - Multiple endocrine disorders typically with severe polyostotic FD
- Presentations: Monostotic, polyostotic, craniofacial (CFD), syndromic (many known syndromes)
  - Monostotic FD
    - 70% of all FD cases; single osseous site affected
      - Skull, face involved in 27%
      - Most common: Maxilla (especially zygomatic process), mandible (molar area)
      - Less common: Frontal > ethmoid, sphenoid > temporal > occipital bones
    - Older children/young adults (75% present < 30 years)
  - Polyostotic FD
    - 30% of all FD cases; involves ≥ 2 separate sites
    - Skull, face involved in 50%
    - Younger group, 2/3 have symptoms by age 10
  - CFD
    - Autosomal dominant, stabilizes with skeletal maturity
  - McCune-Albright syndrome
    - Subtype of unilateral polyostotic FD: Clinical triad of polyostotic FD, hyperfunctioning endocrinopathies, café au lait spots
    - 5% of FD cases; appears earlier; affects more bones more severely
    - Renal phosphate wasting (50%) associated with elevation of circulating factor FGF-23; may result in rickets and osteomalacia
  - Mazabraud syndrome
    - Polyostotic FD, intramuscular myxoma
  - Cherubism: Familial bilateral FD of jaw
  - "Mulibrey" nanism: Severe, progressive growth failure; pericardial constriction; primarily Finland
    - **Mu**scle, **li**ver, **br**ain, **ey**e = triangular face, yellow ocular fundi pigment, hypoplastic tongue, peculiar high voice, nevi flammei (65%)
    - FD of long bones in 25%

Demographics

- Age
  - < 6 years (39%), 6-10 years (27%), > 10 years (39%)
- Gender
  - MAS usually (but not exclusively) female
- Epidemiology
  - Actual incidence unknown
    - Monostotic FD is 6x more common than polyostotic FD
    - Calvarial involvement differs: Polyostotic FD (50%) > monostotic FD (25%)
    - Monostotic FD (75%): 25% found in skull, face
    - Polyostotic FD (25%): 50% found in skull, face

Natural History & Prognosis

- **Rare** progression to osteo-, fibrous-, chondro-, and mesenchymal sarcoma
  - Usually polyostotic/syndromic forms
  - Nearly 1/2 arise following irradiation (marked increase in malignant potential)
- Monostotic craniofacial FD has excellent prognosis
- Most spontaneously "burn out" in teens, 20s

Treatment

- Aggressive resection reserved for visual loss, severe deformity ("vault" more accessible than skull base)
- No radiation therapy → malignant progression
- Alendronate treatment doesn't change pain scores, skeletal disease burden scores, or functional parameters

DIAGNOSTIC CHECKLIST

Consider

- Monostotic and polyostotic FD likely on same spectrum of phenotypic expression; consider checking for gene to predict complications

Image Interpretation Pearls

- Ground-glass appearance on plain films or CT, homogeneously decreased signal on T2WI characteristic

SELECTED REFERENCES

1. Bowers CA et al: Surgical treatment of craniofacial fibrous dysplasia in adults. Neurosurg Rev. 37(1):47-53, 2014
2. Boyce AM et al: A randomized, double blind, placebo-controlled trial of alendronate treatment for fibrous dysplasia of bone. J Clin Endocrinol Metab. 99(11):4133-40, 2014
3. Frisch CD et al: Fibrous dysplasia of the temporal bone: A review of 66 cases. Laryngoscope. ePub, 2014
4. Neelakantan A et al: Benign and malignant diseases of the clivus. Clin Radiol. 69(12):1295-303, 2014
5. Rossi DC et al: Extensive fibrous dysplasia of skull base: case report. Neurol Sci. ePub, 2014
6. Thomsen MD et al: Clinical and radiological observations in a case series of 26 patients with fibrous dysplasia. Calcif Tissue Int. 94(4):384-95, 2014
7. Zhou SH et al: Gene expression profiling of craniofacial fibrous dysplasia reveals ADAMTS2 overexpression as a potential marker. Int J Clin Exp Pathol. 7(12):8532-41, 2014

https://CafePezeshki.IR

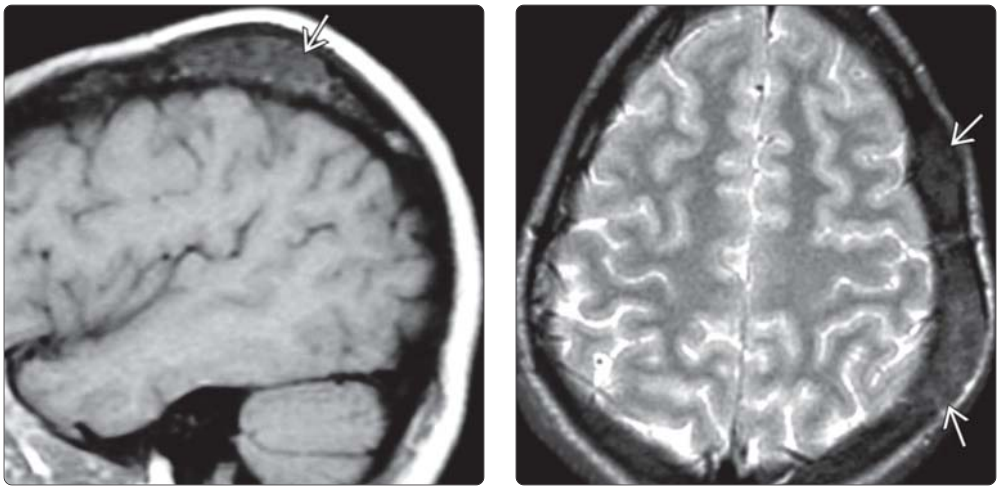

(Left) *Sagittal T1WI MR in a 17-year-old male with a slowly enlarging "scalp bump" shows an expansile calvarial mass* ➡ *that is moderately hypointense.* **(Right)** *Axial T2WI FS MR in the same patient shows the lesion* ➡ *is slightly heterogeneously hypointense.*

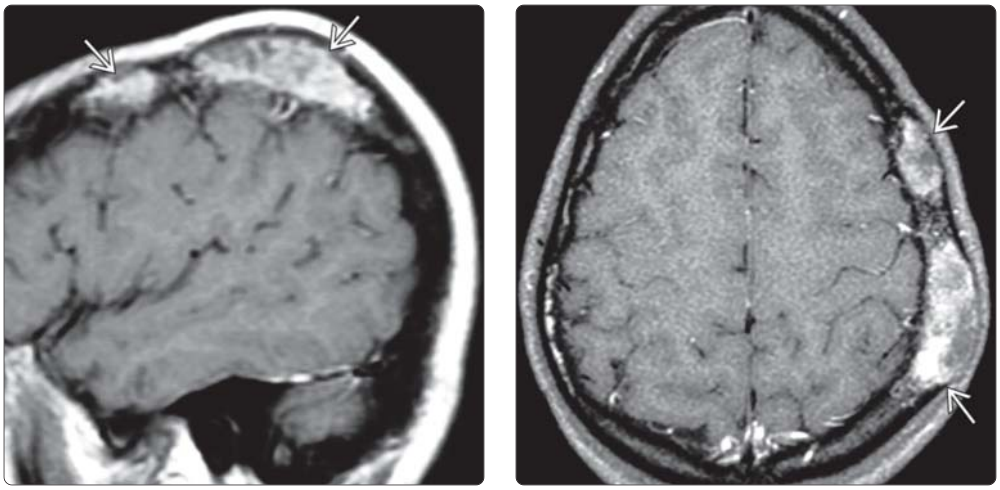

(Left) *Sagittal T1WI C+ MR in the same patient shows 2 calvarial lesions* ➡ *that enhance moderately strongly but heterogeneously.* **(Right)** *Axial T1WI C+ FS shows the lesions* ➡ *exhibit avid but heterogeneous enhancement. The imaging findings are characteristic of active fibrous dysplasia.*

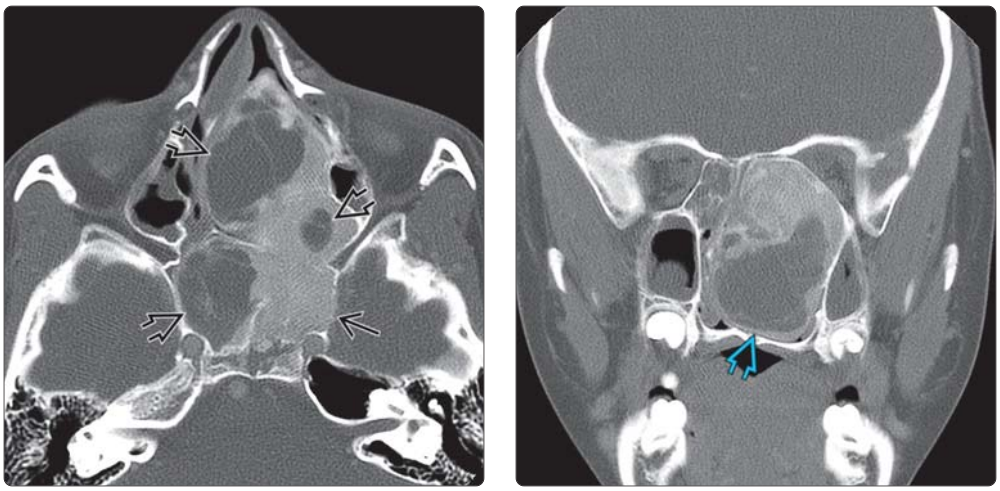

(Left) *Axial bone CT in a 9-year-old female shows the cystic variant of fibrous dysplasia. Note the areas of frank cystic formation* ⇨ *within and adjacent to more characteristic ground-glass appearance* ⇨. **(Right)** *Coronal bone CT in the same patient shows the expansile nasoethmoidal FD with the internal cystic changes characterized by thin but sclerotic borders* ⇨.

https://CafePezeshki.IR

KEY FACTS

TERMINOLOGY

- Chronic metabolic skeletal disorder
- Characterized by bony expansion with variable destruction ± sclerosis

IMAGING

- Well-circumscribed, sharply marginated defects &/or marked thickening + sclerosis
- Skull in 25-65% (may be isolated to skull base)
  - Diploic widening, coarse trabecula, thick cortices
  - "Tam-o'-shanter" skull: Marked ↑ diploic space, particularly inner table
  - "Cotton wool" skull: Focal sclerosis within previous areas of "osteoporosis circumscripta"
- Platybasia
- Typically "hot" throughout all bone scan acquisitions (blood flow, blood pool, static)
- Bone scans + radiographs abnormal in 56-86%

TOP DIFFERENTIAL DIAGNOSES

- Osteosclerotic metastases
- Osteolytic metastases
- Fibrous dysplasia
- Other causes of calvarial thickening

PATHOLOGY

- Excessive and abnormal remodeling of bone, with both active and quiescent phases
  - Localized areas of ↑ bone resorption + exuberant but aberrant new bone formation
- Individual sites progress at variable rates
  - PD of differing phases may be seen within same patient

CLINICAL ISSUES

- 20% asymptomatic; pain, tenderness, ↑ hat size
- New pain/swelling → malignant transformation

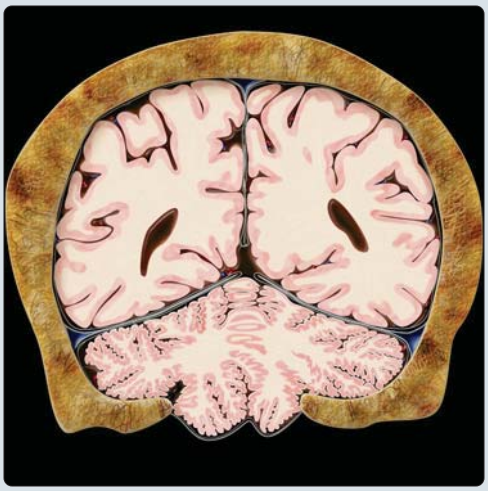

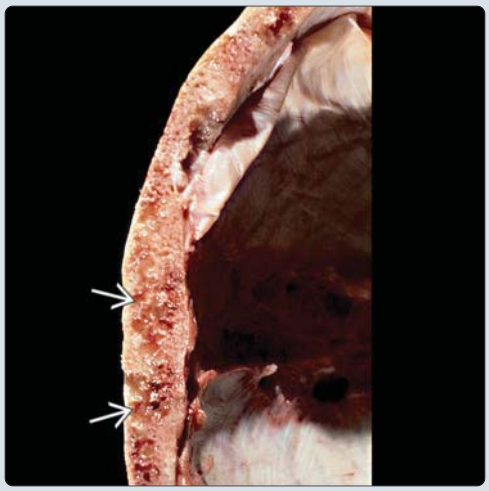

(Left) *Coronal graphic illustrates diffuse Paget disease of the skull with severe diploic widening.* **(Right)** *Autopsy specimen shows pagetoid changes in the calvaria with diffuse thickening, replacement of fatty marrow with fibrovascular tissue ➡. (Courtesy E.T. Hedley-Whyte, MD.)*

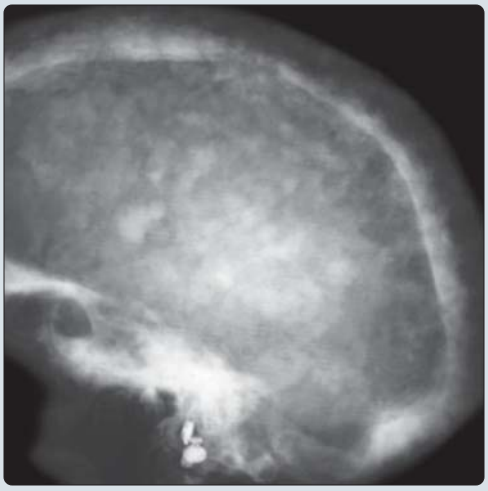

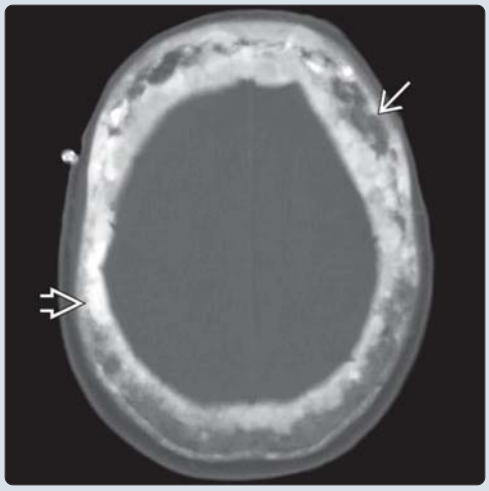

(Left) *Lateral radiograph shows classic "cotton wool" appearance of mixed active stage Paget disease, with enlarged bone (thickened calvaria), mixed lytic and sclerotic foci, and confluent nodular calcifications.* **(Right)** *Axial bone CT shows the mixed areas of bony lysis ➡ and sclerosis ➡ that produces the "cotton wool" appearance seen on digital radiographs of mixed active stage Paget disease.*

https://CafePezeshki.IR

TERMINOLOGY

Abbreviations

- Paget disease (PD)

Synonyms

- Osteitis deformans

Definitions

- Chronic metabolic skeletal disorder
- Characterized by bony expansion with variable destruction ± sclerosis

IMAGING

General Features

- Best diagnostic clue
  - Well-circumscribed, sharply marginated defects &/or marked thickening + sclerosis
- Location
  - Monostotic (10-35%): Often axial skeleton
  - Polyostotic (65-90%)
  - Skull (25-65%): May be isolated to skull base

Radiographic Findings

- Radiography
  - Diploic widening, coarse trabecula, thick cortices
  - 3 phases identified
    - Early destructive phase
      - Well-defined lysis; commonly frontal > occipital
      - Osteoporosis/osteolysis circumscripta
      - Inner and outer tables involved; inner > outer
    - Intermediate phase
      - Both lytic and blastic lesions
      - Trabeculae and cortices coarsening and thickening
    - Late sclerotic phase
      - Blastic lesions, often crossing sutures
      - "Tam o' shanter" skull: Marked ↑ diploic space, particularly inner table
      - "Cotton wool" skull: Focal sclerosis within previous areas of osteoporosis circumscripta
  - Platybasia with variable basilar invagination

CT Findings

- NECT
  - Bones: 3 phases (same as radiography)
  - Platybasia with basilar invagination (BI)
  - Sarcomatous transformation
    - Aggressive osteolysis, cortical destruction, soft tissue mass without periosteal reaction
  - Giant cell tumor (GCT) transformation
    - Lytic lesion without periosteal reaction or mass
    - Marrow replacement distinguishes from PD lysis
    - Cystic and hemorrhagic regions possible
  - PD pseudomass
    - "Soft tissue mass" 2° periosteal lifting by active PD
    - Significant absence of lysis
- CECT
  - ↑ enhancement reflecting pathologic ↑ vascularity
  - Sarcomatous transformation: Mass enhancement, often with central necrosis, aggressive lysis, cortical destruction
  - GCT transformation: Enhancing solid tumor areas

MR Findings

- T1WI
  - Yellow marrow hyperintensity usually maintained
    - Occasionally have more fat than uninvolved bone
  - Early destructive to early intermediate phase
    - ↓ marrow intensity 2° to marrow replacement
    - Residual normal yellow marrow foci → excludes malignant transformation
  - Late sclerotic phase: Marrow hypointensity from sclerosis of coarse trabeculae and cortical thickening
  - PD pseudomass: Maintained areas of yellow marrow
- T2WI
  - Marrow changes with marrow replacement
- T1WI C+
  - ↑ enhancement reflecting pathologic ↑ vascularity
- MR findings of PD complications
  - Distortion and flattening of brain
  - Brainstem impingement from basilar invagination
  - Acquired Chiari 1 malformation
  - Sarcomatous transformation
    - Marrow replacement, focal bone destruction, soft tissue mass
  - GCT transformation
    - Lytic lesion without periosteal reaction/mass
    - Marrow replacement allows it to be distinguished from normal lytic phase of PD
    - Cystic and hemorrhagic regions possible

Nuclear Medicine Findings

- Bone scan
  - Marked uptake throughout all phases of PD
    - Typically "hot" throughout all bone scan acquisitions (blood flow, blood pool, static)
    - Findings may precede radiographic changes
  - Can be "cold" or normal in late sclerotic stage
  - Findings that suggest recurrence
    - New uptake, extension beyond initial boundaries
    - Cold foci in areas of ↑ activity of bone destruction
- Sulfur colloid scan: ↓ uptake = marrow replacement

Imaging Recommendations

- Best imaging tool
  - Radiography + bone scan
    - Bone scans + radiographs abnormal in 56-86%
    - Bone scan alone abnormal in 2-23%
    - Radiographs alone abnormal in 11-20%
  - NECT defines detail/extent, especially PD of skull base
  - MR for imaging PD complications
- Protocol advice
  - NECT: High-resolution, thin cuts through skull base
  - MR
    - Coronal + sagittal sequences for BI
    - T1WI C+ to evaluate for malignant transformation

DIFFERENTIAL DIAGNOSIS

Osteosclerotic Metastases

- Classically prostate, breast, lymphoma

Osteolytic Metastases

- Most metastases, including lung, renal, thyroid

https://CafePezeshki.IR

Fibrous Dysplasia

- Ground-glass appearance, outer > inner table involved

Causes of Calvarial Thickening

- Hyperostosis frontalis interna, meningioma, chronic calcified subdural hematoma

PATHOLOGY

General Features

- Etiology
  - Unknown
  - Viral theory
    - Probable chronic paramyxoviral infection, possibly measles
    - Intranuclear inclusion bodies found in osteoclasts
  - Genetic theory supported by findings listed above
  - Familial, as well as geographic "foci," clustering support both environmental and genetic factors
    - 15-30% have family history, autosomal dominant pattern of inheritance
- Genetics
  - Only gene mutation linked to PD is sequestosome-1 (*SQSTM1*), which encodes p62 protein
    - Elevated cytokine activation in osteoclasts; does not induce pagetic osteoclast phenotype
    - Probably insufficient to cause PD

Gross Pathologic & Surgical Features

- Localized areas of ↑ bone resorption + exuberant but aberrant new bone formation
  - Abnormally soft new bone causes deformity

Microscopic Features

- Early destructive phase: Giant osteoclasts with numerous nuclei show intense activity and aggressive bone resorption
  - Fibrovascular tissue with large vascular channels replaces normal yellow marrow
- Intermediate phase: ↓ osteoclastic and ↑ osteoblastic activity; gradual return of yellow marrow
- Late sclerotic phase: ↓ osteoblastic activity, bone turnover, and vascularity
- General histopathologic findings
  - Cement lines along coarsened/enlarged trabeculae characteristic; denotes bone resorption and formation
  - Trabecular thickening lacks normal interconnections and are weak; a.k.a. "pumice" bone
  - Cortices thickened, have most active bone turnover and repair
  - Areas of resorption and formation are hypervascular
  - Often ↑ in marrow fat ("atrophic marrow")

CLINICAL ISSUES

Presentation

- Most common signs/symptoms
  - 20% asymptomatic
  - Fatigue, pain, tenderness, ↑ hat size
  - Hyperthermia from hypervascularity
  - Cranial nerve deficit(s), pulsatile tinnitus
  - New pain/swelling → malignant transformation
- Clinical profile
  - Older patients
  - ↑ serum alkaline phosphatase (mixed and blastic phase)
  - ↑ serum/urine hydroxyproline (lytic phase)

Demographics

- Age
  - > 55 years (usually late 60s); unusual < 40 years
- Gender
  - M:F = 2:1, onset slightly younger in men
- Ethnicity
  - Caucasians > African Americans > Africans
  - Ashkenazi Jewish have ↑ prevalence
- Epidemiology
  - 3-4% > 40 years; 10-11% > 80 years
- Geographic distribution
  - Overall ↑ prevalence in northern latitudes
  - ↑ in Great Britain: Lands settled by British (Australia, New Zealand, USA) share ↑ prevalence
  - Rare in Asia and Africa (excluding South Africa)

Natural History & Prognosis

- 10% develop secondary hyperparathyroidism from hypercalcemia related to aggressive bone remodeling
- Skull base thickening → CN deficit(s), sensorineural hearing loss (cochlear involvement), mixed hearing loss (stapes fixation to oval window)
- BI in up to 30%; more common in women → brainstem compression, syrinx, obstructive hydrocephalus
- Malignant transformation
  - Sarcomatous transformation (1% or less)
    - M:F = 2:1; 55-80 years
    - Osteosarcoma (50-60%), fibrosarcoma/malignant fibrous histiocytoma (20–25%), chondrosarcoma (10%)
    - Metastasizes frequently, most commonly to lung
  - GCT
    - Skull/facial GCT almost always associated with PD
    - M:F = 1.6:1; 32-85 years
    - Solitary or multiple; 91% in polyostotic PD
    - Rarely cause mortality; generally do not metastasize

Treatment

- Medical
  - Goal: Control, reduction, and alleviation of pain, rather than return to normal bone
    - Calcitonin, bisphosphonates, mithramycin
    - NSAIDs and acetaminophen for pain management
    - Radiography may or may not improve/normalize
- Biopsy with CT guidance needed to diagnose sarcomatous transformation

SELECTED REFERENCES

1. Wodajo FM: Top Five Lesions That Do Not Need Referral to Orthopedic Oncology. Orthop Clin North Am. 46(2):303-314, 2015
2. Galson DL et al: Pathobiology of Paget's Disease of Bone. J Bone Metab. 21(2):85-98, 2014
3. Griz L et al: Diagnosis and management of Paget?s disease of bone. Arq Bras Endocrinol Metabol. 58(6):587-99, 2014
4. Gruener G et al: Paget's disease of bone. Handb Clin Neurol. 119:529-40, 2014
5. Guañabens N et al: Implications of a new radiological approach for the assessment of Paget disease. Calcif Tissue Int. 91(6):409-15, 2012

https://CafePezeshki.IR

(Left) *Axial T1WI MR in a patient with mixed lytic, sclerotic Paget shows intermixed hyper-* ➡ *and hypointense* ⇨ *diploic lesions in a massively expanded calvaria in this elderly patient.* **(Right)** *Axial T2WI MR in the same patient shows the extremely "mottled" heterogeneous appearance of calvarial Paget disease.*

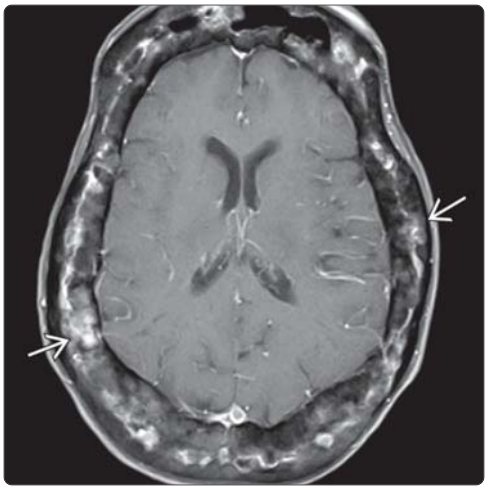

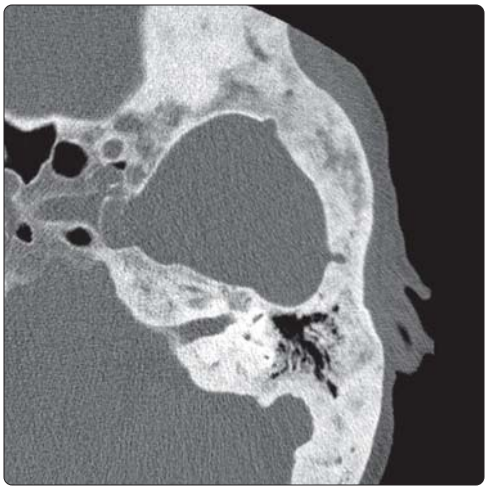

(Left) *Axial T1 C+ FS MR in the same patient shows patchy enhancement* ➡*, indicating that some active disease is present in this longstanding case.* **(Right)** *Axial close-up bone CT shows classic sclerotic Paget disease of the temporal bone. The bone is thickened and densely sclerotic.*

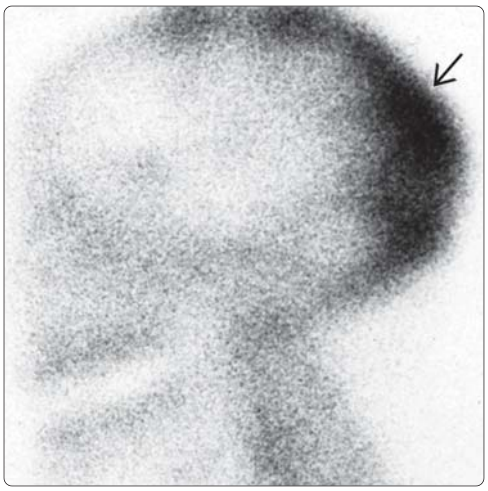

(Left) *Lateral skull radiograph shows the lytic phase of Paget disease, osteoporosis circumscripta,* ⇨ *together with an area of sclerotic skull thickening* ➡*.* **(Right)** *Bone scan in the same patient shows an area of abnormal uptake in the occiput* ⇨*, a typical location of Paget disease in the calvaria.*

https://CafePezeshki.IR

KEY FACTS

TERMINOLOGY

- Extramedullary compensatory formation of blood elements due to decreased medullary hematopoiesis

IMAGING

- Skull (epidural, dura matter, sinuses), spine (paraspinal, epidural)
  - Too thick or dense skull
  - May show findings of underlying disease
- Contrast-enhanced MR
  - Smooth juxtaspinal or cranial homogeneous masses in patients with chronic anemias or marrow depletion
- Look for local complication
  - Cranial foramina, nerves
  - Spinal nerve involvement
  - Cord compression

TOP DIFFERENTIAL DIAGNOSES

- Meningioma
- Metastases
- Subdural collections
- Intracranial hypotension

PATHOLOGY

- "Trilineage" hyperplasia: Erythroid, myeloid, and megakaryocytic elements
- Primarily patients with congenital hemoglobinopathies
  - Thalassemia, sickle cell disease
- May be secondary to any depleted, infiltrated, or hyperactive bone marrow
  - Myelofibrosis/myelodysplastic syndromes
  - Leukemia

DIAGNOSTIC CHECKLIST

- EMH is dural &/or subdural hematoma mimic
- Think of EMH in unexplained extraaxial "collections" or perivertebral masses in child with congenital anemia or other hematological disorder

(Left) *Graphic depicts cranial manifestations of extramedullary hematopoiesis (EMH). The diploic space converts from fatty to hematopoietic ("red") marrow ⇨. Multiple lobulated extraaxial masses ⇨, usually subdural, can occur in severe cases.* **(Right)** *Axial NECT in a patient with myelofibrosis shows a well-delineated, lobulated hyperdense mass ⇨ adjacent to the falx cerebri.*

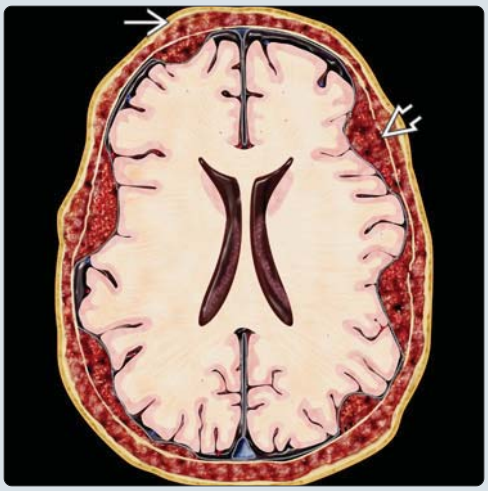

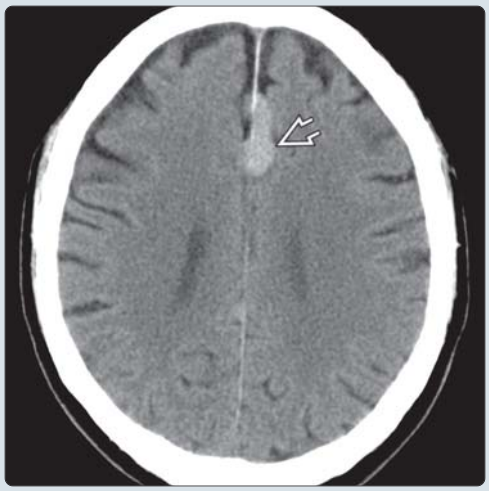

(Left) *Axial T2WI MR in the same patient shows multiple extra-axial, dural-based hypointense masses ⇨ along the falx.* **(Right)** *Axial T1 C+ FS MR in the same patient shows the masses enhance intensely and uniformly ⇨. Myelofibrosis/myelodysplastic syndromes are second only to anemia as the most common underlying cause of extramedullary hematopoiesis.*

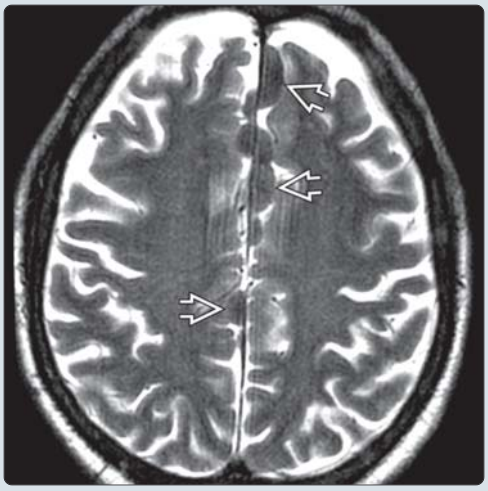

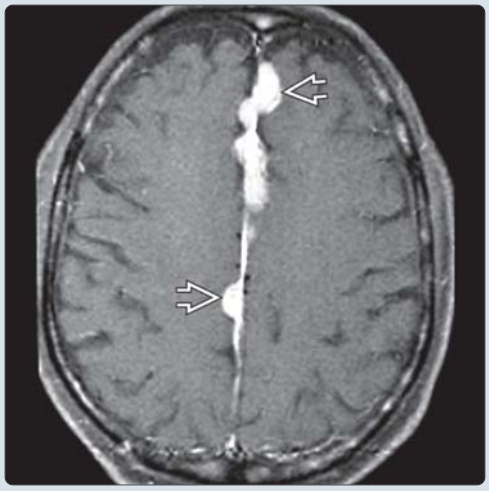

https://CafePezeshki.IR

TERMINOLOGY

Abbreviations

- Extramedullary hematopoiesis (EMH)

Synonyms

- Extramedullary erythropoiesis

Definitions

- Extramedullary compensatory formation of blood elements due to decreased medullary hematopoiesis

IMAGING

General Features

- Best diagnostic clue
  - Smooth juxtaspinal or cranial homogeneous masses in patients with chronic anemia or marrow depletion
- Location
  - Skull (epidural, dura matter, sinuses), spine (paraspinal, epidural)
  - May be seen in multiple other organs: Kidneys, adrenals, thyroid, liver, spleen, lymph nodes, peritoneum
- Size
  - Variable, sometimes huge
- Morphology
  - Smooth, juxtaosseous circumscribed masses
  - Hypercellular tissue

Radiographic Findings

- Radiography
  - May show findings of underlying disease
    - Thalassemia → "hair-on-end" skull
    - Osteopetrosis → dense bone obliterating medullary space

CT Findings

- NECT
  - Smooth, homogeneous, isodense masses
    - May mimic subdural hematoma, lymphoma
    - Also simulates en plaque meningioma
  - May show osseous findings of underlying disease
    - Too thick or dense skull
    - Enlarged diploe
    - Changes of vertebral structure
  - Soft tissue filling paranasal sinus(es), orbits, juxtasellar regions
- CECT
  - Homogeneous enhancement

MR Findings

- T1WI
  - Isointense to slightly hyperintense to cortex
- T2WI
  - Slightly hypointense to cortex
- FLAIR
  - Hyperintense
  - No underlying parenchymal edema
- T1WI C+
  - Homogeneous enhancement
  - Simulates en plaque meningioma

Nuclear Medicine Findings

- Uptake by Tc-99m sulfur colloid

Imaging Recommendations

- Best imaging tool
  - Contrast-enhanced MR
- Protocol advice
  - Investigate bone as well as soft tissue masses
    - Etiological context usually known
    - CT: Thickening of diploe, erosions, paranasal sinus disease
    - MR: Bone marrow changes in vertebral bodies
  - Look for local complication
    - Cranial foramina, nerves
    - Spinal nerve involvement
    - Cord compression

DIFFERENTIAL DIAGNOSIS

Meningioma

- Different context, different bony findings
- MRS (often impossible in masses adjacent to bone): Characteristic alanine peak

Metastases

- Often multifocal, infiltrative, skull invasion

Subdural Collections

- Trauma history
- Enhancement of limiting membranes, not diffuse

Intracranial Hypotension

- Thick skull, thick enhancing dura
- May have associated subdural hematomas
- Enlarged venous dural sinuses
- Tonsillar descent, bulging pituitary
- ± history of CSF diversion or leak

Neurosarcoid

- Abnormal chest radiograph, labs

Other Paraspinal Masses

- Spondylitis, abscesses: Bone, disk involved, peripheral abscesses
- Lymphoma

PATHOLOGY

General Features

- Etiology
  - Hematogenous stem cell spread to different organs
    - Liver and spleen
    - Kidneys
    - Lungs
    - Peritoneum
    - Juxtaosseous also common
      - Face
      - Skull
      - Spine
  - Primarily patients with congenital hemoglobinopathies
    - Thalassemia
    - Sickle cell disease

https://CafePezeshki.IR

  - Hereditary spherocytosis
  - Hemorrhagic thrombocytopenia
  - Leukemia
  - Lymphoma
  - Myeloid metaplasia
- Others
  - May be secondary to any depleted, infiltrated, or hyperactive bone marrow
    - Can be seen after granulocyte colony-stimulating factor therapy
  - May be seen in any myelofibrosis/myelodysplastic syndrome
    - Hematological disorders (e.g., polycythemia vera)
    - Bone diseases
    - Exposure to ionizing radiation, benzene
- Occasionally no etiology found
- Genetics
  - Causal disease
    - Congenital hemoglobinopathies
    - Genetic hemopathies
    - Myelosclerosis of genetic causes
- Associated abnormalities
  - Secondary subdural hemorrhage from EMH involvement of dura reported

Gross Pathologic & Surgical Features

- Periosseous soft tissue masses
- Epidural EMH may compress underlying neural tissue
- Associated bony changes

Microscopic Features

- "Trilineage" hyperplasia
  - Erythroid elements
  - Myeloid elements
  - Megakaryocytic elements

CLINICAL ISSUES

Presentation

- Most common signs/symptoms
  - Asymptomatic
  - Seizures
  - Cranial nerve deficit(s) at skull base
  - Increased intracranial pressure if compressing dural sinuses
  - Myelopathy if compressing spinal cord
- Clinical profile
  - Generally older adults with myelofibrosis
  - Younger patients with congenital hemolytic anemias

Demographics

- Age
  - Generally in older patients, but EMH has its own specific pediatric causes
- Gender
  - Equal
- Epidemiology
  - Rare

Natural History & Prognosis

- Evolution dependent on primary underlying disease
- Compensatory for bone marrow failure
- Uncommonly, local complications related to compression

Treatment

- Treat primary disease
- Low-dose radiotherapy is treatment of choice
  - Remember that hematopoietic tissue is extremely sensitive to irradiation
- Surgical resection

DIAGNOSTIC CHECKLIST

Consider

- Think of EMH in unexplained extraaxial "collections" or perivertebral masses in child with congenital anemia or other hematological disorder

Image Interpretation Pearls

- EMH is dural &/or subdural hematoma mimic

SELECTED REFERENCES

1. Mehta S et al: Intracranial extramedullary haematopoiesis: A case report. Br J Neurosurg. 1-3, 2015
2. Mughal TI et al: Myelofibrosis-associated complications: pathogenesis, clinical manifestations, and effects on outcomes. Int J Gen Med. 7:89-101, 2014
3. Singer A et al: Intracranial extramedullary hematopoiesis: a rare cause of headaches. J Neuroimaging. 24(5):524-7, 2014
4. Ghieda U et al: Progressive spinal cord compression due to epidural extramedullary hematopoiesis in thalassemia intermedia. A case report and literature review. Neuroradiol J. 26(1):111-7, 2013
5. Palma JA et al: Intracranial extramedullary hematopoiesis associated with multiple myeloma. Neurology. 80(17):1620, 2013
6. Tefferi A: Primary myelofibrosis: 2013 update on diagnosis, risk-stratification, and management. Am J Hematol. 88(2):141-50, 2013
7. Eskazan AE et al: Intracranial extramedullary hematopoiesis in patients with thalassemia: a case report and review of the literature. Transfusion. 52(8):1715-20, 2012
8. Sohawon D et al: Extra-medullary haematopoiesis: a pictorial review of its typical and atypical locations. J Med Imaging Radiat Oncol. 56(5):538-44, 2012
9. Jiang WX et al: 37-year-old woman with multiple intracranial masses. Brain Pathol. 21(5):607-10, 2011
10. Zherebitskiy V et al: Extramedullary hematopoiesis involving the central nervous system and surrounding structures. Hum Pathol. Epub ahead of print, 2011
11. Debard A et al: Dural localization of extramedullary hematopoiesis. Report of a case. J Neurol. 256(5):837-8, 2009
12. Tun K et al: Meningeal extramedullary haematopoiesis mimicking subdural hematoma. J Clin Neurosci. 15(2):208-10, 2008
13. Collins WO et al: Extramedullary hematopoiesis of the paranasal sinuses in sickle cell disease. Otolaryngol Head Neck Surg. 132(6):954-6, 2005
14. Koch CA et al: Nonhepatosplenic extramedullary hematopoiesis: associated diseases, pathology, clinical course, and treatment. Mayo Clin Proc. 78(10):1223-33, 2003

https://CafePezeshki.IR

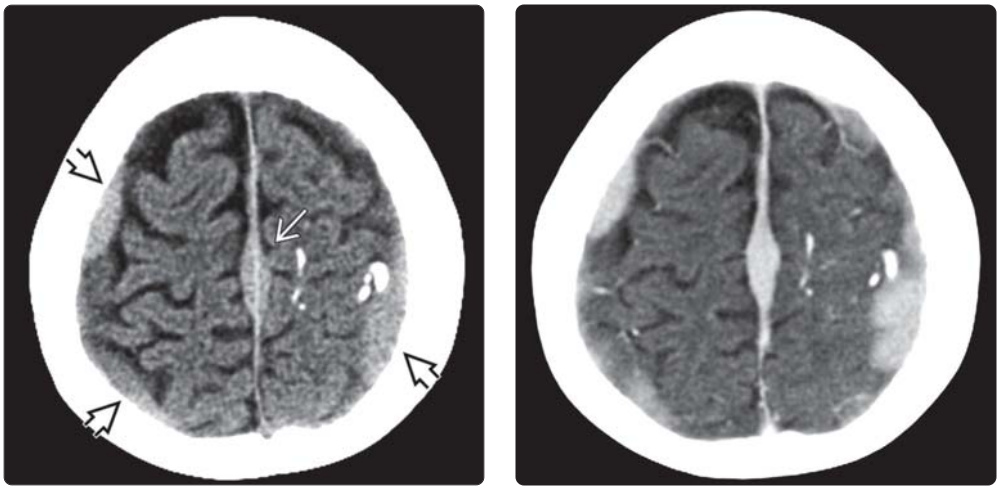

(Left) *Axial NECT in an 8-year-old girl with myelofibrosis shows multiple extraaxial masses ⇨, most likely due to dural, epidural, &/or subdural intramedullary hematopoiesis. Note the falx ➡ where the mass is shown on both sides of the dural layer. The masses are slightly denser than brain, with (probably) dural calcifications, consistent with EMH.* **(Right)** *Axial CECT in the same patient demonstrates diffuse, rather homogeneous enhancement of the lesions, again in keeping with EMH. This was confirmed by biopsy.*

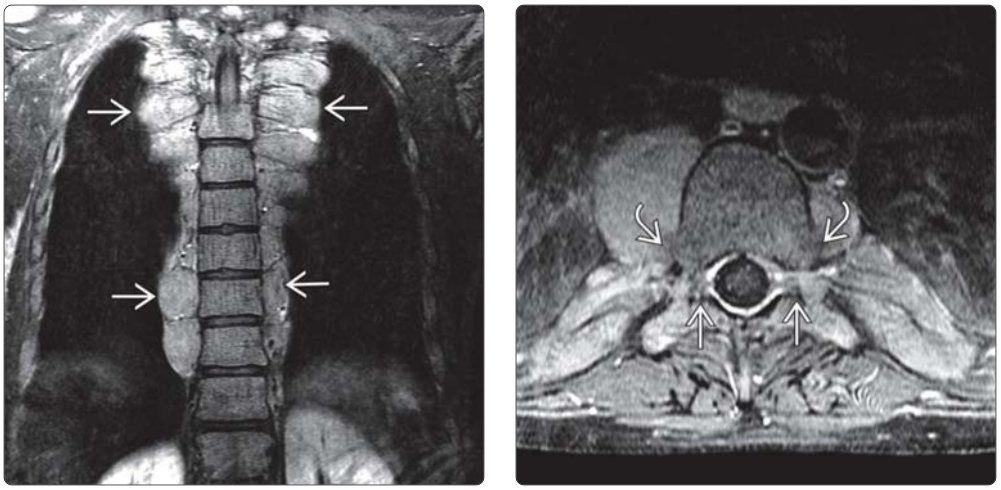

(Left) *Coronal T1WI C+ FS MR in a 17 year old with thalassemia shows multiple paravertebral masses ➡ along the thoracic vertebral, extending into intercostal spaces. Given the context, appearances, and homogeneous enhancement, they likely represent EMH.* **(Right)** *Axial T1WI C+ FS MR demonstrates in-plane extension of the masses, especially into the intervertebral foramina bilaterally ➡, where they involve the spinal nerves. Note the absence of cortical bone ⇨.*

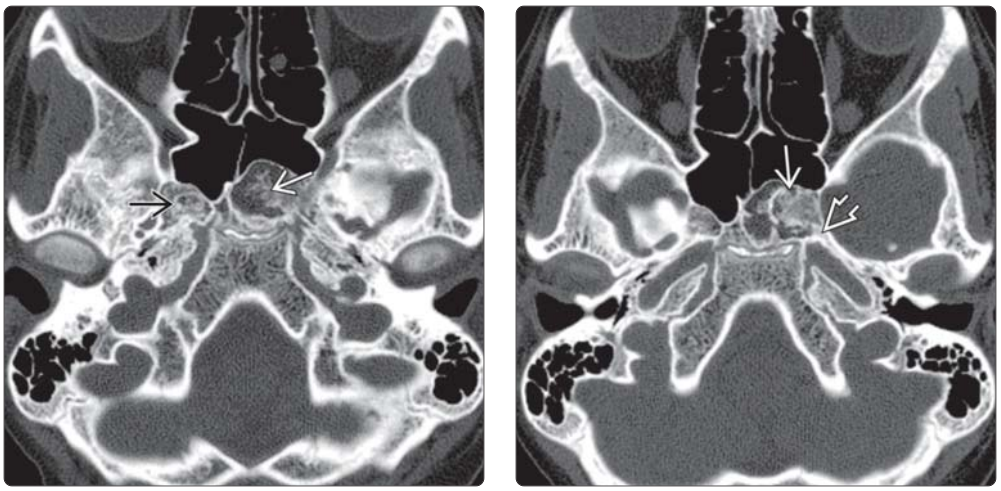

(Left) *Axial bone CT in a 13 year old with thalassemia shows asymptomatic masses within the body of the sphenoid ➡ and the base of the right pterygoid plate ⇨ with bone expansion but preservation of the cortex, suggestive of, but not specific for, EMH.* **(Right)** *Axial bone CT at a higher level shows the proximity of the sphenoid body lesion ➡ to the carotid canal ⇨. This patient had multiple sites of proven EMH in other locations; therefore, this is the most likely diagnosis.*

https://CafePezeshki.IR

KEY FACTS

TERMINOLOGY

- Skull thickening (ST)
  - Diploic space expanded ± thickened cortex

IMAGING

- Widened calvaria (skull width)
  - Can be diffuse or focal
- NECT best for most causes of ST
  - Thin-section MDCT for detailed skull base evaluation
- MR C+ contrast: Look for adjacent dural involvement

TOP DIFFERENTIAL DIAGNOSES

- Normal variation (most common cause)
- Shunted hydrocephalus or infantile brain injury
  - Neonatal meningitis or cerebritis
  - Hypoxia/ischemia/hypoglycemia in neonatal period
  - Metabolic/genetic disease with infantile brain atrophy
  - ± phenytoin
- Metastases (diffuse sclerotic)
- Microcephaly
- Chronic anemias

CLINICAL ISSUES

- Often asymptomatic
- Patients with skull base ST
  - Look for foraminal/canal overgrowth/encroachment
  - May cause cranial neuropathy
- In many cases, evaluation of underlying brain can help to establish diagnosis
- Many tests can help discriminate among etiologies
- Skull findings often harbinger of underlying disease
- Therapy aimed at treating underlying etiology

DIAGNOSTIC CHECKLIST

- What is underlying cause of skull thickening
  - Keep in mind: Most often it's normal variant

(Left) *Bone CT in a 64-year-old woman with nonspecific headaches, normal neurologic examination, and shows a diffuse, circumferentially thickened calvaria. The most common cause of diffusely thickened skull is a normal variant.* **(Right)** *The skull may thicken if the underlying brain is abnormally small. Due to the severe perinatal brain injury in this child, the brain is atrophic with ventriculomegaly, the calvaria is massively thickened, and the frontal sinuses are massively enlarged.*

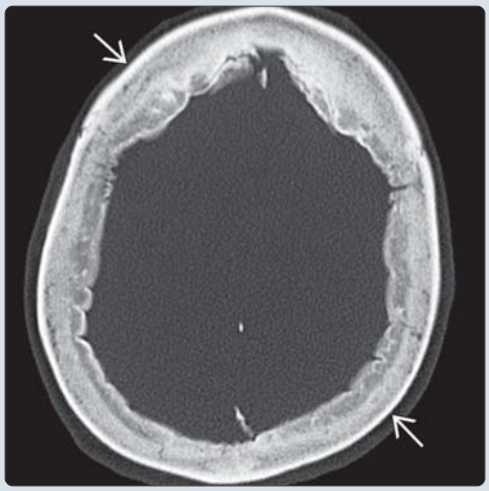

(Left) *The calvaria can be thickened in a spectrum of inherited disorders. In this 19-year-old man with known craniometaphyseal dysplasia, the occipital bone (including the clivus) is markedly thickened, as are the maxillary sinuses.* **(Right)** *More cephalad image in the same patient shows the calvarial vault is also diffusely and symmetrically thickened, most strikingly in the parietal bones.*

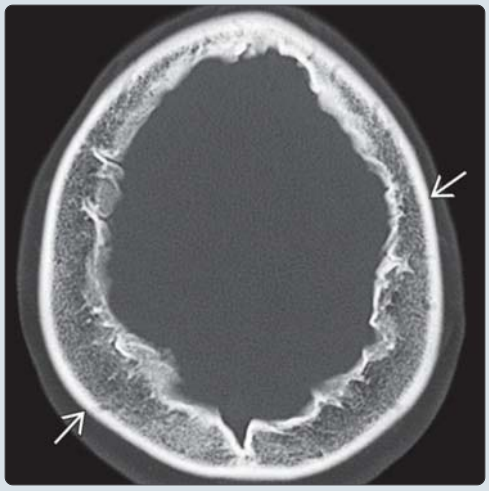

https://CafePezeshki.IR

TERMINOLOGY

Synonyms

- Skull thickening (ST), calvarial thickening

Definitions

- Diploic space expansion ± adjacent cortical thickening

IMAGING

General Features

- Best diagnostic clue
  - Diffuse/focal increased skull width; variable size
- Location
  - Any bone can be involved; calvaria > skull base > occipital squamae
- Morphology
  - Generalized, regional or focal, depending on etiology

Radiographic Findings

- Radiography
  - Not useful for diffuse unless thickening is striking
  - Focal thickening more easily appreciated

CT Findings

- NECT
  - Thick skull: Findings may be classic/pathognomic
    - Local brain atrophy: Ipsilateral compensatory osseous hypertrophy/hyperpneumatization of paranasal sinuses
    - β-thalassemia: "Hair-on-end" skull
    - Shunted hydrocephalus: Thick skull + shunt + chronic collapsed ventricles
    - Fibrous dysplasia: Medullary expansion with ground-glass appearance

MR Findings

- T1-, T2WI may show diploic widening; depends on etiology
- Any sequence: Dural sinus displacement in focal thickening

Nuclear Medicine Findings

- Bone scan
  - Variable, dependent on cause of skull thickening
- PET
  - Rarely useful in children

Imaging Recommendations

- Best imaging tool
  - NECT for most causes of skull thickening
  - MR for brain assessment
- Protocol advice
  - Thin-section, high-resolution MDCT
    - Coronal and sagittal reformats
    - Goal: Thoroughly evaluate foramina and canals

DIFFERENTIAL DIAGNOSIS

Normal Anatomic Variation

- Normal skulls may have symmetric areas of thickening

Microcephaly

- Skull overgrowth occurs secondary to decreasing brain size in child

Many Others

- Shunted hydrocephalus
- Localized atrophy (e.g., Sturge-Weber disease)
- Chronic anemias

PATHOLOGY

General Features

- Etiology
  - Generalized ST: Drugs (phenytoin), microcephaly, hyperparathyroidism, osteopetrosis
  - Regional ST: Calcified cephalohematoma, localized cerebral atrophy, epidermal nevus syndrome, fibrous dysplasia
- Associated anomalies vary with genetic involvement/predisposition and systemic causes

Microscopic Features

- Specific histopathology varies greatly, dependent on underlying cause

CLINICAL ISSUES

Presentation

- Most common signs/symptoms
  - Most often asymptomatic; varies with etiology
  - Without skull base disease: Most symptoms referable to disease affecting systems outside skull
  - Patients with skull base ST may be symptomatic from foraminal or canal encroachment
    - Manifests as cranial nerve (CN) deficit(s)
    - Sinoorbital and auditory complications

Natural History & Prognosis

- Aggressive lesions, especially those involving skull base, have associated morbidity; usually CN deficit(s)

Treatment

- Usually no treatment required

DIAGNOSTIC CHECKLIST

Consider

- What is underlying cause of skull thickening

Reporting Tips

- Focal vs. diffuse, other bones, intracranial findings

SELECTED REFERENCES

1. Borra VM et al: Localization of the gene for X-linked calvarial hyperostosis to chromosome Xq27.3-Xqter. Bone. 58:67-71, 2014
2. Sharma B et al: Dyke-Davidoff-Masson syndrome: a clinicoradiological amalgam. BMJ Case Rep. 2014, 2014
3. May H et al: Intracranial volume, cranial thickness, and hyperostosis frontalis interna in the elderly. Am J Hum Biol. 24(6):812-9, 2012
4. Suoranta S et al: Thickened skull, scoliosis and other skeletal findings in Unverricht-Lundborg disease link cystatin B function to bone metabolism. Bone. 51(6):1016-24, 2012
5. Akhaddar A et al: Nonsuppurative calvarial thickening: a new form of Garré disease? J Neurosurg. 110(4):808, 2009
6. Lisle DA et al: Imaging of craniofacial fibrous dysplasia. J Med Imaging Radiat Oncol. 52(4):325-32, 2008
7. Waclawik AJ: Hyperostosis frontalis interna. Arch Neurol. 63(2):291, 2006
8. Sharma RR et al: Symptomatic cranial fibrous dysplasias: clinico-radiological analysis in a series of eight operative cases with follow-up results. J Clin Neurosci. 9(4): 381-90, 2002

https://CafePezeshki.IR

KEY FACTS

TERMINOLOGY

- Langerhans cell histiocytosis (LCH)
- LCH now best understood as a neoplastic disease
  - Activating somatic *BRAF* mutations, LCH cell clonality

IMAGING

- NECT
  - Sharply marginated lytic skull defect
    - Beveled edges
  - Mastoid: Geographic destruction, soft tissue mass
- MR
  - Absent posterior pituitary "bright spot" on T1WI
  - Thick enhancing infundibulum
  - Enhancing masses in choroid plexus, leptomeninges, basal ganglia
  - Sometimes cerebellar WM disease

TOP DIFFERENTIAL DIAGNOSES

- Lytic calvarial lesions
  - Surgical (burr hole, shunt, surgical defect)
  - Epidermoid
  - Dermoid
- Pituitary infundibular/hypothalamic thickening, enhancement
  - Germinoma
  - Metastasis
  - Pituicytoma
  - Neurosarcoid

DIAGNOSTIC CHECKLIST

- Calvaria is most frequent bony site involved by LCH
- Thick enhancing pituitary stalk is most common CNS manifestation of LCH
  - If initially "normal" MR in patient with DI, repeat in 2-3 months
- Consider LCH for ataxic patient with choroid plexus masses, cerebellar WM demyelination

(Left) *Lateral graphic demonstrates 3 sharply defined lytic lesions ⇨ of the membranous calvaria with geographic destruction. Note the beveled margins of the bony lysis ⇨.* **(Right)** *Lateral radiograph in a 3-year-old boy with several subcutaneous masses and central diabetes insipidus demonstrates multiple lytic lesions of the skull ⇨. Note the "cookie cutter" sharp pattern of bony lysis and the beveled edge pattern ⇨ of differential inner and outer table calvarial involvement.*

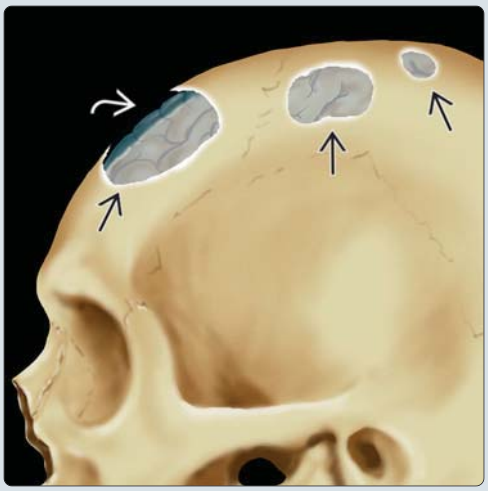

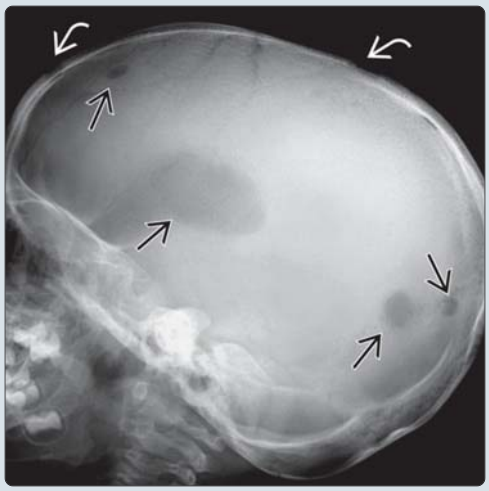

(Left) *Axial NECT in a 5-year-old girl with multiple scalp masses demonstrates 2 lytic lesions ⇨ of the left frontal bone. Both lesions show the characteristic pattern of sharply defined geographic bony lysis. Note the unequal inner and outer table involvement creating a beveled edge appearance.* **(Right)** *Axial NECT in a proptotic 10-year-old boy shows a sharply defined lytic lesion of the lateral orbital wall ⇨. Note the soft tissue mass displacing the lateral rectus muscle ⇨.*

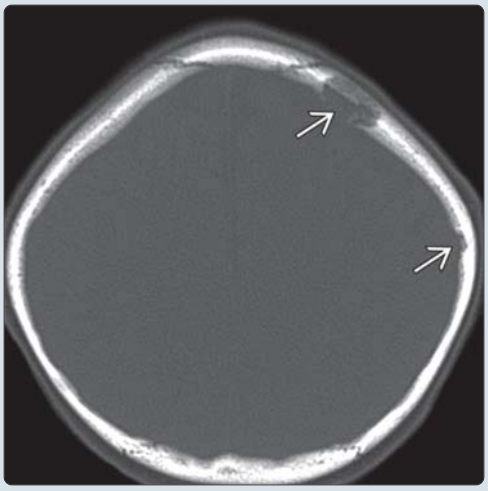

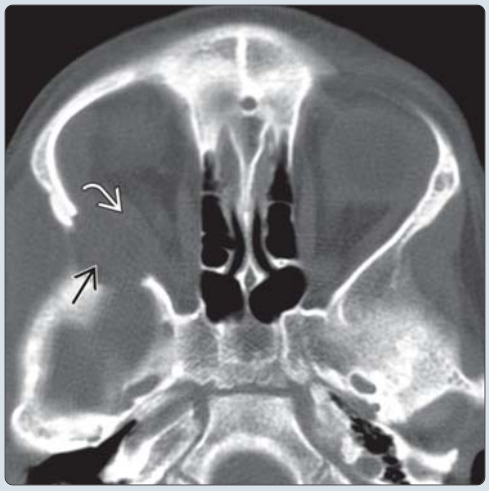

https://CafePezeshki.IR

TERMINOLOGY

Synonyms

- Langerhans cell histiocytosis (LCH)
  - Several entities (eosinophilic granuloma, Hand-Schuller-Christian disease, Letterer-Siwe disease, and "histiocytosis X" now under single designation of LCH

Definitions

- LCH now best understood as neoplastic disease
  - Activating somatic *BRAF* mutations, LCH cell clonality
  - Inflammatory myeloid neoplasia
- Divided into 3 groups (based on number of lesions, systems involved)
  - Unifocal (localized) form
    - 70% of cases
    - Limited to single or a few bones, may involve lung
  - Multifocal unisystem
    - 20% of cases
    - Chronic, recurring
    - Multiple bones, reticuloendothelial system, pituitary/hypothalamus
  - Multifocal, multisystem
    - 10% of cases
    - Fulminant (often fatal)

IMAGING

General Features

- Best diagnostic clue
  - Calvaria: Sharply marginated lytic skull defect with beveled margins
  - Skull base (mastoid most common): Geographic destruction ± soft tissue mass
  - Brain: Thick enhancing infundibulum, absent posterior pituitary bright spot on T1WI
- Location
  - Calvaria
    - Most common bony site
      - Frontal, parietal bones > temporal, occipital
    - Also mastoid portion of temporal bone, mandible, orbit, facial bones
  - Brain: Pituitary gland/infundibulum, hypothalamus
    - Rare: Choroid plexus, leptomeninges, basal ganglia, cerebellar white matter (WM), and brain parenchyma
- Size
  - Skull and facial bones: May grow, coalesce
  - Pituitary infundibulum: Small lesions due to early endocrine dysfunction (central DI)
- Morphology
  - Variable patterns of bony lysis ("geographic" skull)
  - Soft tissue masses vary from discrete ↔ infiltrative

CT Findings

- NECT
  - Calvaria
    - Lytic defect, "beveled" edge (inner table > outer table)
    - Small soft tissue mass, no periosteal reaction
  - Mastoid
    - Bone destruction, often bilateral, soft tissue mass
- CECT
  - Calvaria/mastoid: Enhancing soft tissue in lytic defect
  - Brain: Enhancing, thick pituitary stalk, ± hypothalamic mass or enhancement

MR Findings

- T1WI
  - Soft tissue mass at site of bony lysis (± T1 shortening due to lipid-laden histiocytes)
  - Brain
    - Pituitary/infundibulum: Absent posterior pituitary bright spot, thick stalk, ± soft tissue mass
- T2WI
  - Skull, mastoid, orbital/facial lesions: Soft tissue masses show slight T2 hyperintensity
  - Brain
    - Infundibulum/hypothalamus: Slightly hyperintense
    - ± cerebellar WM hyperintensity (autoimmune-mediated demyelination)
- FLAIR
  - Rare: Hyperintense cerebellar white matter demyelination
- T1WI C+
  - Skull, mastoid, orbital/facial: Enhancing soft tissue masses (defined or infiltrating)
  - Brain
    - Infundibulum: Thick, strongly enhancing stalk
    - Parenchyma: Enhancing masses in choroid plexus, leptomeninges, and basal ganglia

Nuclear Medicine Findings

- Bone scan
  - Tc-99m bone scan: Variable (cold ↔ warm)
- PET
  - F-18 FDG: ↑ uptake in proliferating lesions, ↓ uptake for "burned-out" lesions

Imaging Recommendations

- Best imaging tool
  - Skull: NECT (with CECT for mastoid disease)
  - Brain: MR with contrast
- Protocol advice
  - Skull: CT using bone algorithm; include coronal and sagittal reconstructions
  - Brain MR
    - Pituitary MR: Small field of view, thin section, no gap, sagittal and coronal T1WI with contrast
      - If initially "normal" in patient with DI, repeat in 2-3 months

DIFFERENTIAL DIAGNOSIS

Lytic Calvarial Lesions

- Surgical (burr hole, shunt, surgical defect)
- Epidermoid
- Dermoid
- Leptomeningeal cyst
- Metastases

Temporal Bone Destructive Processes

- Severe mastoiditis: Infection usually spares bony labyrinth
- Rhabdomyosarcoma: Often with large ipsilateral cervical nodes

https://CafePezeshki.IR

Pituitary Infundibular/Hypothalamic Thickening or Masses

- Germinoma
- Pituicytoma
- Metastasis
- Lymphocytic hypophysitis
- Neurosarcoid

PATHOLOGY

General Features

- Genetics
  - Pathologic LCH cells are clonal
  - Activating *BRAF* mutations
  - Activation of ERK signaling pathway in myeloid differentiation as essential/universal driver of LCH pathology
- Associated abnormalities
  - ↑ risk of LCH: Family history of thyroid disease, underimmunization, penicillin use, solvent exposure

Staging, Grading, & Classification

- Formerly classified into 1 of 3 overlapping forms
  - Eosinophilic granuloma
    - Localized, calvaria most common (70%)
  - Hand-Schüller-Christian
    - Chronic disseminated form, multifocal (20%)
  - Letterer-Siwe
    - Acute disseminated form, onset at < 2 years of age, ± skeletal involvement (10%)
- Now classified according to risk factors: Young age, multifocal involvement, multiorgan dysfunction, relapse

Gross Pathologic & Surgical Features

- Yellow, gray, or brown tumor mass

Microscopic Features

- Monoclonality of Langerhans cells
  - Presence of CD1a and Birbeck granules needed to establish diagnosis
- Accumulation of CD1A(+)/CD207(+) mononuclear phagocytes in granulomatous lesions

CLINICAL ISSUES

Presentation

- Most common signs/symptoms
  - Calvarial: Pain, subscalp mass, bony defect
  - Mastoid destruction: Pain, chronic otitis externa, retroauricular subscalp mass
  - Retroorbital mass: Exophthalmos, ± painful ophthalmoplegia
  - Pituitary infundibular involvement: Central DI, ± visual disturbance, ± hypothalamic dysfunction
- Clinical profile
  - Child < 2 years with diabetes insipidus, ± lytic calvarial lesion

Demographics

- Age
  - LCH typically presents at < 2 years
- Gender
  - M:F = 2:1
- Ethnicity
  - More common among Caucasians
- Epidemiology
  - Affects 4 in 1,000,000
  - Peak age at onset 1 year (isolated), 2-5 years (multifocal disease)
  - Inverse relation between severity of involvement and age
  - 50% of LCH cases are monostotic
  - Familial LCH < 2%
  - Lytic bone lesions are most common manifestations of LCH (seen in 80-95% of children with LCH)

Natural History & Prognosis

- Variable depending on age of onset and extent of involvement
  - Multifocal and systemic LCH: Mortality may approach 18%
- Rarely, may spontaneously hemorrhage → epidural hematoma

Treatment

- Therapeutic options depend on symptoms, location, and extent of disease
  - Observation, excision/curettage, sclerotherapy/injection, radiation/chemotherapy
- Solitary eosinophilic granuloma has best prognosis with spontaneous remission common
  - Painful: Curettage
  - Asymptomatic: Observe
- LCH patients with DI: Oral or nasal vasopressin, ± chemotherapy and radiation

DIAGNOSTIC CHECKLIST

Consider

- CNS LCH for ataxic patient with choroid plexus masses and cerebellar WM demyelination

Image Interpretation Pearls

- Skull is most frequent bony site involved by LCH
- Thick enhancing pituitary stalk is most common CNS manifestation of LCH

SELECTED REFERENCES

1. Berres ML et al: Progress in understanding the pathogenesis of Langerhans cell histiocytosis: back to Histiocytosis X? Br J Haematol. 169(1):3-13, 2015
2. De La Hoz Polo M et al: Neuroimaging of Langerhans cell histiocytosis in the central nervous system of children. Radiologia. 57(2):123-130, 2015
3. Esmaili N et al: Langerhans cll histiocytosis of the orbit: spectrum of disease and risk of central nervous system sequelae in unifocal cases. Ophthal Plast Reconstr Surg. ePub, 2015
4. Zaveri J et al: More than just Langerhans cell histiocytosis: a radiologic review of histiocytic disorders. Radiographics. 34(7):2008-24, 2014
5. Badalian-Very G et al: Pathogenesis of Langerhans cell histiocytosis. Annu Rev Pathol. 8:1-20, 2013
6. D'Ambrosio N et al: Craniofacial and intracranial manifestations of langerhans cell histiocytosis: report of findings in 100 patients. AJR Am J Roentgenol. 191(2):589-97, 2008

https://CafePezeshki.IR

(Left) *Coronal CECT in a 5-year-old boy with chronic draining of left ear and conductive hearing loss shows a soft tissue mass ➡ and bone destruction involving the mastoid segment of the temporal bone. Note the sharply defined margins of bony destruction ⇨ and displaced middle ear ossicle ⇨.* **(Right)** *Axial CECT in child with a slowly growing right cheek mass demonstrates the mass as soft tissue ➡ in the lower masticator space. Note the associated lysis of the lateral mandibular ramus ⇨.*

(Left) *Sagittal T1WI MR in a 7-year-old girl with central diabetes insipidus demonstrates a soft tissue mass ➡ involving the hypothalamus. Note the absence of the normal posterior pituitary focus of T1 shortening ⇨, a common finding in children with diabetes insipidus.* **(Right)** *Coronal T1WI C+ FS MR in the same patient shows enhancement of the hypothalamic nodule ⇨. Pituitary stalk thickening is the most common finding with CNS involvement.*

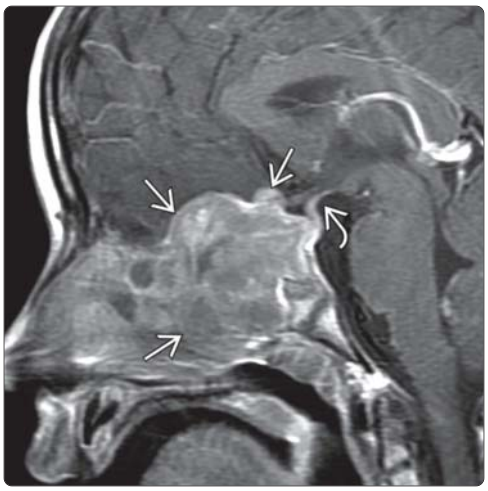

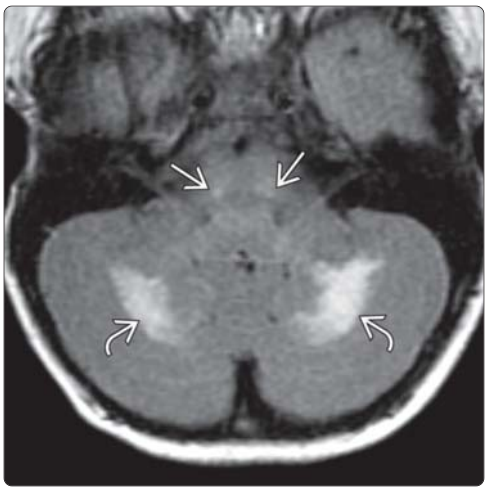

(Left) *Sagittal T1WI C+ FS MR in a 5-year-old boy with chronic headaches and diabetes insipidus demonstrates a heterogeneously enhancing lesion ➡ of the central skull base. Note the thickening and displacement of the pituitary infundibulum ⇨.* **(Right)** *Axial FLAIR MR in a 6-year-old boy with behavior problems shows confluent regions of demyelination with FLAIR signal hyperintensity involving the cerebellar white matter ⇨. Note the involvement of the abducens nuclei ➡.*

https://CafePezeshki.IR

KEY FACTS

TERMINOLOGY

- Multisystem inflammatory disease characterized by noncaseating epithelioid-cell granulomas

IMAGING

- Solitary or multifocal CNS mass(es) ± abnormal CXR
  - Chest x-ray abnormal in > 90% with NS
- Wide spectrum of MR manifestations
  - Dura-arachnoid thickening (diffuse or focal))
  - May coat pia, CNs, fill internal auditory canals
  - Pituitary stalk/hypothalamus thickening
  - Can thicken, infiltrate choroid plexi
  - Can infiltrate orbital adnexae, optic nerve
  - Rare
    - Small vessel vasculitis/angiitis in white matter
    - Focal parenchymal mass

TOP DIFFERENTIAL DIAGNOSES

- Meningitis
- Meningioma
- Metastases
- Lymphocytic hypophysitis

PATHOLOGY

- Etiology remains unknown
- May infiltrate along perivascular spaces into brain

CLINICAL ISSUES

- Often indolent disease (up to 50% asymptomatic)
- CNS involved in 5% (clinical) to 27% (autopsy)
  - Most common CNS symptom: CN deficit(s), most often facial nerve palsy
- Natural history
  - 2/3 of NS self-limited monophasic illness; remainder have chronic remitting-relapsing course

DIAGNOSTIC CHECKLIST

- Protean manifestations make NS "great mimicker"

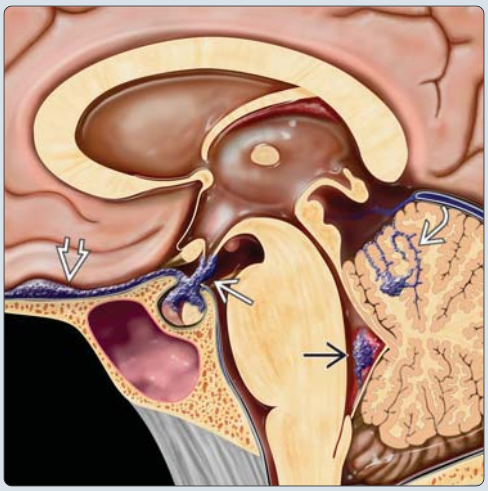

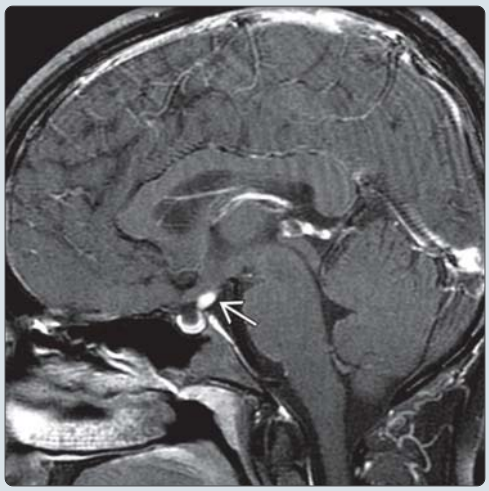

(Left) *Sagittal graphic illustrates common neurosarcoid locations: (1) enveloping the infundibulum and extending into the parasellar region ➡; (2) contiguous disease wrapping the inferior frontal lobes ➡; and (3) synchronous lesions of the superior vermis ➡ and 4th ventricle choroid plexus ➡.* **(Right)** *Sagittal T1 C+ FS MR in a patient with neurosarcoidosis and diabetes insipidus demonstrates thickening of the infundibulum and hypothalamus ➡.*

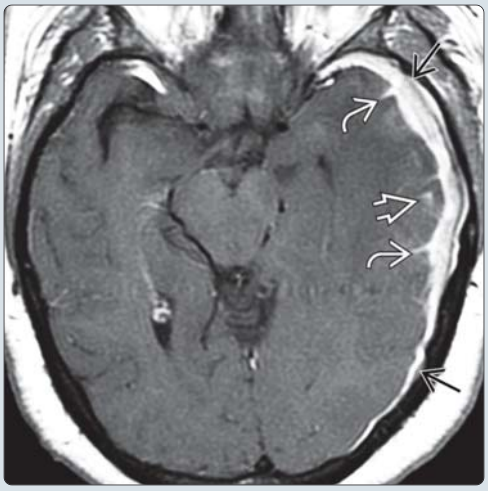

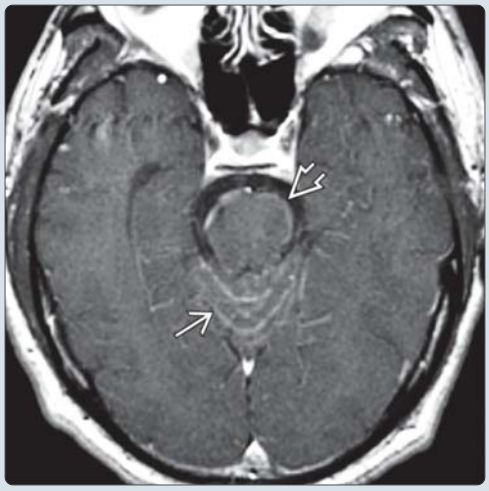

(Left) *Axial T1 C+ MR in a 44-year-old woman with worsening headaches and diplopia shows diffuse dura-arachnoid thickening over the left hemisphere ➡. Extension into the sulci ➡ and underlying brain ➡ is present. Biopsy disclosed neurosarcoid with brain invasion.* **(Right)** *Axial T1 C+ MR in a case of proven neurosarcoid demonstrates diffuse pial enhancement over the surface of the upper pons ➡ and cerebellum ➡.*

https://CafePezeshki.IR

TERMINOLOGY

Abbreviations

- Neurosarcoid (NS)

Definitions

- Chronic multisystem inflammatory disease characterized by noncaseating epithelioid-cell granulomas

IMAGING

General Features

- Best diagnostic clue
  - Solitary or multifocal CNS mass(es) + abnormal CXR
- Location
  - Dura (29-50%), leptomeninges (31%), subarachnoid/perivascular spaces
    - Preferential involvement of basal cisterns
    - Optic chiasm, hypothalamus, infundibulum
  - Cranial nerves (CNs) (34-50%); optic nerve (28%)
  - Brain parenchyma (22%): Hypothalamus > brainstem > cerebral hemispheres > cerebellum
  - Choroid plexus
  - Spine (25%)
- Morphology
  - Focal or diffusely infiltrating granulomas
  - Absence of pathological enhancement does not rule out diagnosis of neurosarcoid

Radiographic Findings

- Radiography
  - Chest x-ray abnormal in > 90% with NS
    - Hilar adenopathy ± parenchymal involvement

CT Findings

- CECT
  - May show basilar leptomeningeal enhancement

MR Findings

- T1WI
  - Hydrocephalus
  - Lacunar infarcts (brainstem, basal ganglia)
  - Isointense material within subarachnoid spaces
  - Isointense dural lesion(s)
- T2WI
  - Lacunar infarcts (brainstem, basal ganglia)
  - Hypointense material within subarachnoid spaces
  - Hypointense dural lesion(s)
  - Sellar disease may appear cystic
- FLAIR
  - ~ 50% have periventricular T2-hyperintense lesions
    - Can infiltrate perivascular (Virchow-Robin) spaces
    - May cause vasculitis/angiitis of white matter
- DWI
  - Distinguish restricted (acute ischemic cytotoxic edema) from nonrestricted NS (vasogenic) edema
- T1WI C+
  - Wide spectrum of MR enhancement
    - 10% seen as solitary intraaxial mass
    - Slightly > 1/3 have multiple parenchymal lesions
    - Slightly > 1/3 have leptomeningeal involvement; nodular &/or diffuse
    - 5-10% hypothalamus, infundibular thickening
    - 5% solitary dural-based extraaxial mass
    - Other: Vasculitic or ependymal enhancement
    - May coat CN, fill internal auditory canals

Nuclear Medicine Findings

- PET: High pulmonary sarcoidosis FDG uptake
- Gallium scan: ↑ uptake at systemic sites of inflammation, including NS (as high as 85%)

Imaging Recommendations

- Best imaging tool
  - MR C+
- Protocol advice
  - Multiplanar, fat saturation, T1WI C+

DIFFERENTIAL DIAGNOSIS

Dural, Leptomeningeal, Subarachnoid NS

- Meningitis: CSF shows infection/organism
- Meningioma: Not parenchymal or subarachnoid space
- Infundibular histiocytosis: Age of onset: 6-14 years

Brain Parenchymal NS

- Metastases: Labs different, negative CXR
- Periventricular white matter disease: Different symptomatology and lab results, negative CXR

PATHOLOGY

General Features

- Etiology
  - Etiology remains unknown
    - Possibly stimulation of immune system by 1 or more antigens &/or abnormal immune response
  - DNA and RNA of *Mycobacterium*, *Propionibacterium* detected in some lesions, suggesting a possible cause
- Genetics
  - Sarcoidosis may occur in families
  - Genetic polymorphisms of MHC are associated with ↑ risk of disease or affect disease presentation
    - HLA-DRB1 (*11 & *14), HLA-DQB1*0201 alleles
    - Number of HLA genes involved unknown, but clear HLA region strongly implicated
  - Genetic polymorphisms of cytokines are associated with ↑ risk of disease or affect disease presentation
- Associated abnormalities
  - Löfgren syndrome (a.k.a. acute pulmonary sarcoid)
    - All: Fever, malaise, bilateral hilar adenopathy
    - Erythema nodosum and large joint arthralgia
    - May have uveitis, parotitis
  - Heerfordt syndrome (a.k.a. salivary gland sarcoidosis)
    - Fever, parotitis, uveitis, and facial nerve paralysis

Gross Pathologic & Surgical Features

- Granulomatous leptomeningitis (most common) or dural-based solitary mass (diffuse > nodular)
- May infiltrate along perivascular spaces

Microscopic Features

- Noncaseating granuloma: Compact, radially arranged epithelioid cells with pale-staining nuclei

https://CafePezeshki.IR

- Large, multinucleated giant cells in arc/circle around central granular zone
- Arterial wall invasion by epithelioid cell granuloma causing disruption of media and internal elastica
  - Tissue may then cause luminal stenosis or occlusion
- Fibrocollagenous tissue accumulates in dural lesions
  - Correlates with T2-hypointense lesions
- Inflammatory infiltration
  - Correlates with T2-hyperintense lesions

CLINICAL ISSUES

Presentation

- Most common signs/symptoms
  - Neurologic manifestations frequently presenting symptoms of systemic sarcoid
  - Imaging findings often do not have correlating symptoms at time of presentation
    - Nonetheless, post-therapy imaging shows excellent correlation with clinical improvement/worsening
  - Most common symptom: CN deficit(s), most often facial nerve palsy
    - Bell palsy 14x ↑ compared to general population
  - By imaging, optic nerve ± chiasm most affected
    - Clinical and imaging CN findings often disparate
  - Symptoms vary with location, size of granulomas
    - Other CN: Hearing loss, diplopia
    - Headache, fatigue, seizures, encephalopathy, dementia
    - Weakness, paresthesias
    - Pituitary/hypothalamic dysfunction
  - 5-10% occur without pulmonary/systemic sarcoid
  - Progressive encephalopathy, confusion, and dementia
    - Ascribed to longstanding microvascular changes of presumed granulomatous angiitis
  - Systemic involvement
    - Lung hilar nodes most often involved
    - Skin lesions 2nd (up to 1/3)
    - Eye (iritis, uveitis); polyarthritis
  - Children present differently
    - More likely: Seizures, space-occupying lesion
    - Less likely: Cranial nerve palsies
- Clinical profile
  - Kveim-Siltzbach skin test positive in 85%
  - Serum ACE levels elevated in < 50% of cases with NS
    - Normal CSF ACE levels do not rule out NS
  - Hypercalcemia + hypercalciuria in up to 15%
  - Serum CD4:CD8 ratio often ↓
  - ↑ CSF protein &/or cells insensitive, nonspecific
  - Use modified Zajicek criteria for diagnosis
    - Divides into "confirmed," "probable" and "possible" NS

Demographics

- Age
  - Bimodal: Initial peak at 20-29 years, later peak in women > 50 years
- Gender
  - M:F = 2:1
- Ethnicity
  - In USA, lifetime risk in African Americans is nearly 3x higher than Caucasians
  - In Europe, Caucasians mostly affected
- Epidemiology
  - In USA
    - Women: 6.3 per 100,000 person-years
    - Men: 5.9 per 100,000 person-years
  - CNS involved between 5% (clinical) and 27% (autopsy)
    - Primary, isolated CNS sarcoidosis rare (< 1%)
    - Imaging detects neurologic disease in 10% of all patients with sarcoidosis
- Geographic predilection
  - Temperate > tropical climates (< 10/100,000)
  - Swedes and Danes commonly affected
  - Rare in Chinese, Southeast Asians, Inuits, Canadian Indians, New Zealand Maoris, and Spanish

Natural History & Prognosis

- Often indolent disease; up to 50% asymptomatic
- 67% with NS have self-limited monophasic illness; remainder have chronic remitting-relapsing course
  - Most respond rapidly to steroids; others refractory
- Simultaneous expression of new and old granulomas suggest process may wax and wane
- Hydrocephalus
  - Direct obstruction (most common complication)
  - Also by loss/reduction of brain tissue compliance resulting from parenchymal infiltration
- Vasculitis may cause small vessel ischemia, lacunes, cortical infarcts
- Indicators of poor prognosis: Seizures; enhancing leptomeningeal, parenchymal, and spinal lesions
- Indicators of good prognosis: Nonenhancing dural, CN, and parenchymal lesions
- Death in 5%, mostly from pulmonary complications

Treatment

- No known cure; goal to alleviate symptoms
- Corticosteroids useful in most cases; immunosuppressive drugs occasionally
- In NS ~ 50% progress despite corticosteroid and immunosuppressive therapy
- MR imaging resolution lags clinical symptom resolution

DIAGNOSTIC CHECKLIST

Consider

- Look for abnormal CXR

Image Interpretation Pearls

- Protean manifestations make NS "great mimicker"
- CN deficit(s) and pituitary dysfunction often have normal MR C+ imaging; conversely MR findings may be clinically silent

SELECTED REFERENCES

1. Carlson ML et al: Cranial base manifestations of neurosarcoidosis: a review of 305 patients. Otol Neurotol. 36(1):156-66, 2015
2. Hebel R et al: Overview of neurosarcoidosis: recent advances. J Neurol. 262(2):258-67, 2015
3. Mercan M et al: A case of sarcoidosis of the central nervous system and orbita. Case Rep Med. 2015:403459, 2015
4. Wegener S et al: Clinically isolated neurosarcoidosis: a recommended diagnostic path. Eur Neurol. 73(1-2):71-7, 2015
5. Wiśniewski K et al: Isolated neurosarcoidosis mimicking intracranial tumours - Analysis of 3 cases. Neurocirugia (Astur). ePub, 2015

https://CafePezeshki.IR

(Left) *Axial T2 MR in a 43-year-old woman with Tolosa-Hunt syndrome shows a thickened right lateral rectus muscle* ⇨ *and hypointense mass extending through the orbital apex into the cavernous sinus* ⇨. **(Right)** *Axial T1 C+ FS MR shows the infiltrating mass* ➡ *enhances intensely and uniformly. Subtle dura-arachnoid enhancement is also present* ➡. *Biopsy disclosed neurosarcoid.*

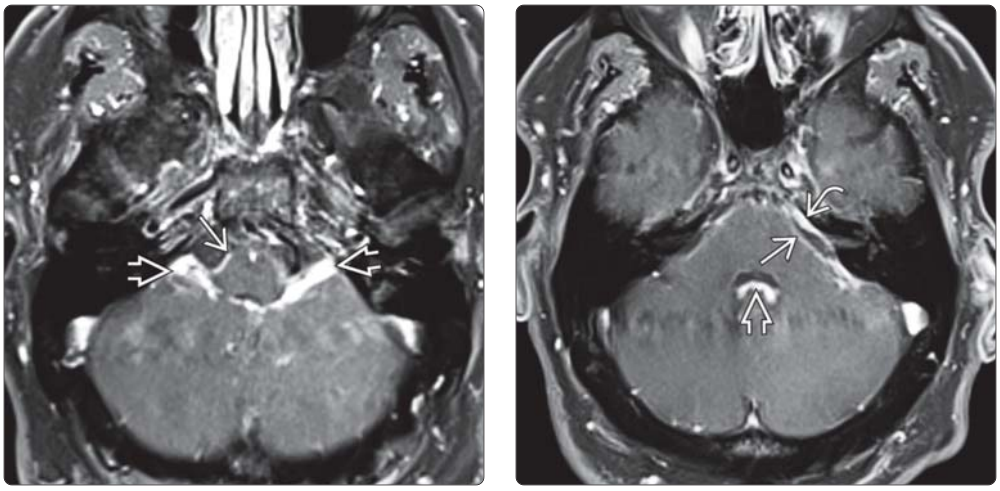

(Left) *Axial T1 C+ FS MR in a 56-year-old woman with neurosarcoid shows diffuse enhancement over the pial surface of the medulla* ➡, *as well as thickening of the choroid plexi* ➡ *in the 4th ventricle and lateral recesses.* **(Right)** *More cephalad T1 C+ FS MR in the same patient shows diffuse enhancement over the surface of the pons* ➡. *Note the enhancing choroid plexus mass in the floor of the 4th ventricle* ➡. *A dural-based cerebellopontine angle mass* ➡ *is also present.*

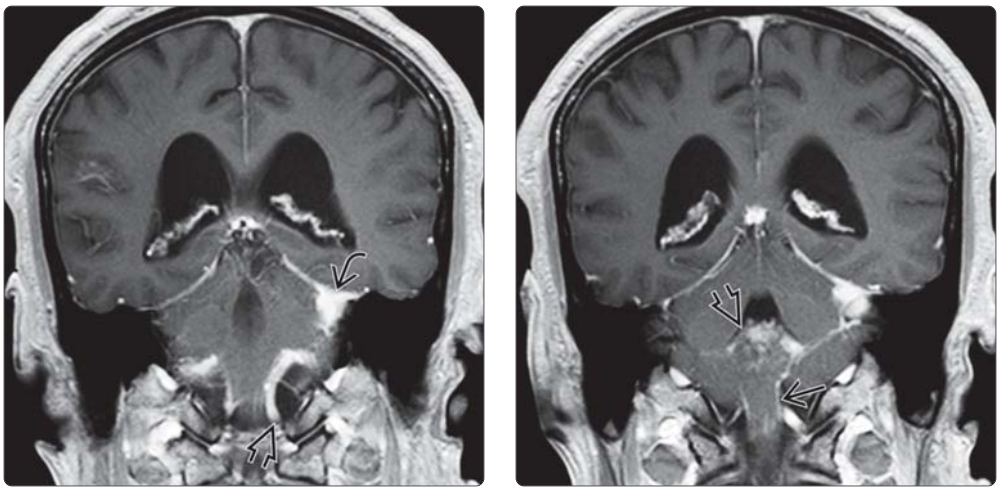

(Left) *Coronal T1 C+ MR in the same patient shows the left cerebellopontine angle mass* ⇨ *and enhancement extending over the brainstem into the upper cervical spine* ⇨. **(Right)** *Coronal MR in the same patient shows the extensive involvement of the 4th ventricle choroid plexus* ⇨. *The pia of the medulla and upper cervical spinal cord is thickened and enhancing* ⇨. *Mild enlargement of both lateral ventricles is also present. Obstructive hydrocephalus is a relatively uncommon complication of neurosarcoidosis.*

https://CafePezeshki.IR

KEY FACTS

TERMINOLOGY

- Non-Langerhans cell histiocytoses
  - Four major disorders
    - Rosai-Dorfman disease (RDD)
    - Erdheim-Chester disease (ECD)
    - Hemophagocytic lymphohistiocytosis (HLH)
    - Juvenile xanthogranuloma (JXG)

IMAGING

- RDD: Massive, painless cervical lymphadenopathy
- CNS: T2-hypointense orbital or dural masses that mimic meningioma
- HLH: Hyperintense, enhancing WM lesions (cerebellum, hemispheres), often with leptomeningeal disease
- JXG: Uncommon in brain (WM lesions resemble HLH; sellar, choroid plexus, orbit)

TOP DIFFERENTIAL DIAGNOSES

- Orbit: Lymphoma, pseudotumor, sarcoid
- Dural-based mass(es): Meningioma, sarcoid, lymphoma, extramedullary hematopoiesis, metastases

CLINICAL ISSUES

- RDD
  - Children and young adults (peak 20 years)
  - Good prognosis (usually benign, slowly progressive disease
- ECD
  - Any age but older adults/elderly (5th, 6th decades) most common
  - Poor prognosis (5-year survival 40%)
- HLH
  - Infants (most < 1 year), young children
  - Generally poor outcome
- JXG
  - Usually limited to skin
  - Disseminated WM lesions; sellar, pituitary/hypothalamus, choroid plexus lesions

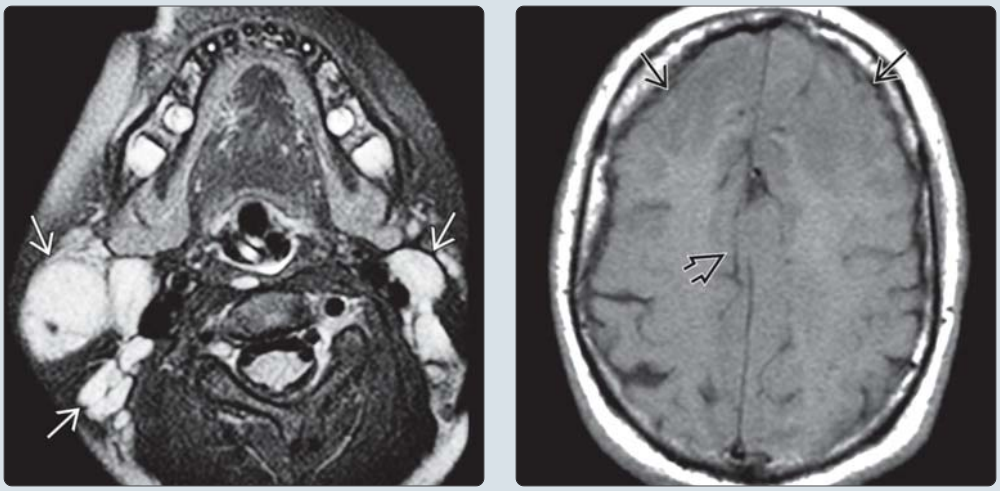

(Left) *Axial T2 FS MR scan in a 42-year-old woman with cervical adenopathy shows multiple enlarged, hyperintense lymph nodes ➡. Biopsy disclosed Rosai-Dorfman disease (RDD).* **(Right)** *Axial T1 MR in the same patient was obtained after the patient complained of headaches. Note effacement of the sulci, gray-white interfaces in both frontal lobes ⇨ and along the interhemispheric fissure ⇨.*

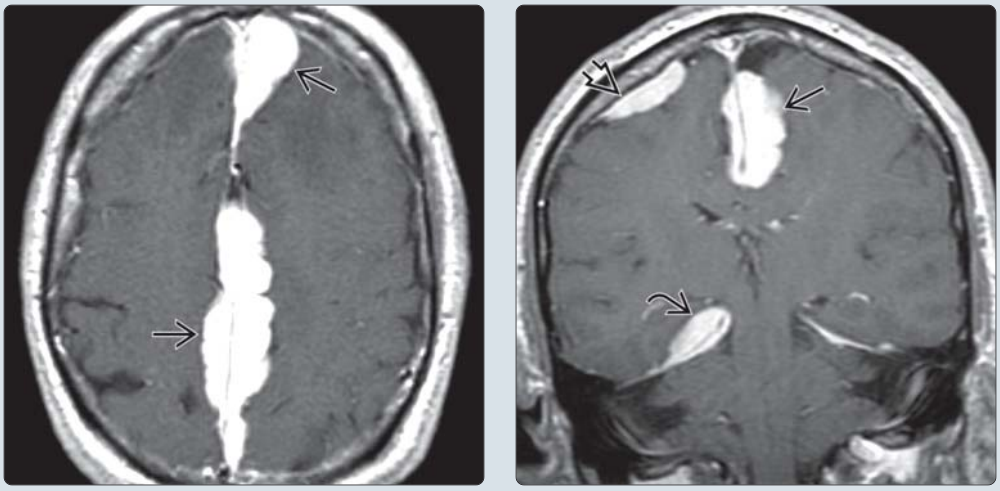

(Left) *Axial T1 C+ MR in the same patient shows multifocal, intensely enhancing, lobulated extraaxial dural-based masses ⇨ along the falx.* **(Right)** *Coronal T1 C+ MR in the same patient shows the dural-based enhancing masses also involve the convexity ⇨ and tentorium ⇨, as well as both sides of the falx ⇨.*

https://CafePezeshki.IR

TERMINOLOGY

Abbreviations

- Non-Langerhans cell histiocytoses (non-LCH)

Definitions

- Non-Langerhans cell histiocytoses
  - 4 major disorders
    - Rosai-Dorfman disease (RDD)
    - Erdheim-Chester disease (ECD)
    - Hemophagocytic lymphohistiocytosis (HLH)
    - Juvenile xanthogranuloma (JXG)
- RDD: Rare, benign, idiopathic histioproliferative disorder generally (but not always) restricted to lymph nodes
- ECD: Rare, non-Langerhans form of histiocytosis of unknown etiology that affects multiple organs
- HLH: Syndrome of pathologic activation of macrophages, T cells with "hemophagocytosis" (engulfment of RBCs and leukocytes)
  - May affect multiple organ systems, including central nervous system (CNS)
- "Malignant histiocytosis" now considered histiocytic sarcoma, not true histiocytic lesion

IMAGING

General Features

- Best diagnostic clue
  - RDD: Massive, painless cervical lymphadenopathy
    - CNS: T2-hypointense orbital or dural masses that mimic meningioma
  - ECD: Enhancing brainstem and cerebellar lesions
  - HLH: T2 Hyperintense, enhancing WM lesions (cerebellum, hemispheres), often with leptomeningeal disease
  - JXG: Usually just skin, sometimes brain and choroid plexus lesions
- Location
  - RDD: Cervical lymph nodes, orbits, meninges, skin, paranasal sinuses, nasal cavity, bone, salivary glands
  - ECD: Bones, visceral organs, systemic fatty spaces
    - CNS: Cerebral hemispheres, hypothalamus, cerebellum, brainstem, orbits
  - HLH: Brain parenchyma, leptomeninges
  - JXG: Cerebellum, hemispheric WM, choroid plexus
- Morphology
  - RDD: Homogeneous orbital mass; nodular dural-based masses
  - ECD: Parenchymal nodules or masses ± meningeal thickening or masses
  - HLH: Nodular or linear parenchymal lesions

CT Findings

- NECT
  - RDD: Iso/hyperdense orbit, dural-based masses
  - ECD: Hypodense parenchymal lesions typical
    - Rarely see hyperdense lesions
  - HLH: Hypodense lesions
    - May see diffuse brain edema
  - JXG: Hypodense WM lesions
- CECT
  - RDD: Cervical lymphadenopathy
    - Orbital mass with diffuse enhancement
    - Nodular dural mass with diffuse enhancement

MR Findings

- T1WI
  - RDD: Isointense dural-based lesions
  - HLH: Ventriculomegaly; hypointense lesions
- T2WI
  - RDD: Variable; usually hypointense
  - ECD: Hyperintense lesions
  - HLH: Laminated, nodular hyperintense lesions; may become confluent
  - JXG: Patchy, confluent WM lesions in cerebellum, cerebral WM
- T1WI C+
  - RDD: Dural-based masses with diffuse, homogeneous enhancement
  - ECD
    - Hypothalamic-pituitary axis (loss of posterior pituitary "bright spot", thickened mass-like lesion in stalk/hypothalamus
    - Other
      - 3 patterns: Infiltrative (44%), meningeal (37%), or composite (infiltrative and meningeal lesions [19%])
  - HLH: Nodular, linear, or ring-enhancing lesions ± meningeal enhancement
  - JXG: Often minimal or no enhancement; enhancing choroid plexus mass

Imaging Recommendations

- Best imaging tool
  - Enhanced MR best for CNS manifestations
  - WG: Sinus CT; consider MR to evaluate for intracranial involvement if disease is extensive

DIFFERENTIAL DIAGNOSIS

Rosai-Dorfman Disease

- Orbital mass: Lymphoma, inflammatory pseudotumor, sarcoid, granulomatosis with polyangiitis (formerly known as Wegener granulomatosis)
- Meningeal masses: Meningiomas (most common), sarcoid, lymphoma, extramedullary hematopoiesis, metastases
- Cervical lymphadenopathy: Lymphoma, reactive lymph nodes, tuberculosis

Erdheim-Chester Disease and Hemophagocytic Lymphohistiocytosis

- LCH: Sharply marginated, lytic skull lesion; thick enhancing infundibulum; parenchymal lesions rare
- TB: Meningeal and parenchymal enhancing lesions
- Metastases: Multiple enhancing nodules; primary tumor often known

PATHOLOGY

General Features

- RDD
  - S100(+) histiocytes in fibrous stroma
  - Chronic inflammatory cells (T, B lymphocytes)
  - Lymphophagocytosis common (70% of cases)

https://CafePezeshki.IR

- ECD
  - Xanthogranulomatous infiltrate with lipid-laden, foamy histiocytes
  - CD68(+), factor VIII(+), CD1a(-), S100(-)
- HLH
  - Severe hyper-inflammation
  - Starts as leptomeningeal process → perivascular infiltration with astrocytic proliferation affecting mainly white matter → areas of necrosis and focal demyelination
  - Benign-appearing histiocytes with hemophagocytosis (mostly RBCs, neutrophils)
- JXG
  - Histiocytes
    - CD68(+)
    - Touton giant cells (vacuolated foamy histiocytes) classic but not universal

Staging, Grading, & Classification

- World Health Organization classifies histiocytic disorders according to type of histiocyte involved
  - Dendritic cell disorders (LCH, ECD, JXG)
  - Macrophage-related disorders (RDD, HLH)
  - Malignant histiocytic disorders (some leukemias, malignant neoplasms)
- HLH: Consequence of uncontrolled, dysregulated cellular immune reactivity caused by number of different underlying diseases
  - 2 forms of HLH identified
    - Genetic (primary) form
      - Familial (autosomal recessive or X-linked) with clinical HLH syndrome as only manifestation; usually in early infancy
      - Immune deficiencies (e.g., Chediak-Higashi)
    - Acquired (secondary) HLH
      - All ages
      - Usually in immunocompromised individuals
      - Infection-associated hemophagocytic syndrome (EBV, CMV, *Leishmania*)
      - Can occur in reaction to malignancies
      - Can be life-threatening

CLINICAL ISSUES

Presentation

- Most common signs/symptoms
  - RDD: Painless lymphadenopathy most common
    - Sinonasal disease: Progressive nasal obstruction
    - Orbit: Proptosis
    - CNS: Headache
  - ECD
    - Most common: Bone pain, fever, weight loss
      - Bilateral, symmetrical osteosclerosis (long bones most common)
    - CNS manifestations
      - Most common = central DI (can be longstanding, only symptom), orbits
      - Cerebellar (41%) and pyramidal (45%) syndromes
      - Other: Seizures, headaches, neuropsychiatric or cognitive troubles, sensory disturbances, cranial neuropathy
  - HLH
    - Fever, hepatosplenomegaly most common in familial HLH
    - Neurologic (seizures, irritability, cranial neuropathy, coma)
  - JXG
    - Most common: Limited skin disease
    - Can be systemic (eye, brain, other organs)

Demographics

- Age
  - RDD: Children and young adults (peak 20 years)
  - ECD: Any age but older adults/elderly (5th, 6th decades) most common
  - HLH: Infants (most < 1 year), young children

Natural History & Prognosis

- RDD: Benign, progressive disease
- ECD: Poor prognosis (5 year survival 40%)
- HLH: Generally poor outcome

DIAGNOSTIC CHECKLIST

Consider

- When orbital or dural mass has T2 hypointensity, consider inflammatory pseudotumor (including IgG4-related disease) and RDD
- Brainstem or cerebellar lesions in patient with bone lesions or diabetes insipidus, consider ECD
- Infant or child with enhancing parenchymal and meningeal lesions, consider HLH

SELECTED REFERENCES

1. Cives M et al: Erdheim-Chester disease: A systematic review. Crit Rev Oncol Hematol. ePub, 2015
2. Gabbay LB et al: Histiocytosis: a review focusing on neuroimaging findings. Arq Neuropsiquiatr. 72(7):548-58, 2014
3. Munoz J et al: Erdheim-Chester disease: characteristics and management. Mayo Clin Proc. 89(7):985-96, 2014
4. Zaveri J et al: More than just Langerhans cell histiocytosis: a radiologic review of histiocytic disorders. Radiographics. 34(7):2008-24, 2014
5. Hinduja A et al: Rosai-Dorfman disease manifesting as intracranial and intraorbital lesion. J Neurooncol. 92(1):117-20, 2009
6. D'Ambrosio N et al: Craniofacial and intracranial manifestations of langerhans cell histiocytosis: report of findings in 100 patients. AJR Am J Roentgenol. 191(2):589-97, 2008
7. La Barge DV 3rd et al: Sinus histiocytosis with massive lymphadenopathy (Rosai-Dorfman disease): imaging manifestations in the head and neck. AJR Am J Roentgenol. 191(6):W299-306, 2008
8. Goo HW et al: A spectrum of neuroradiological findings in children with haemophagocytic lymphohistiocytosis. Pediatr Radiol. 37(11):1110-7, 2007

https://CafePezeshki.IR

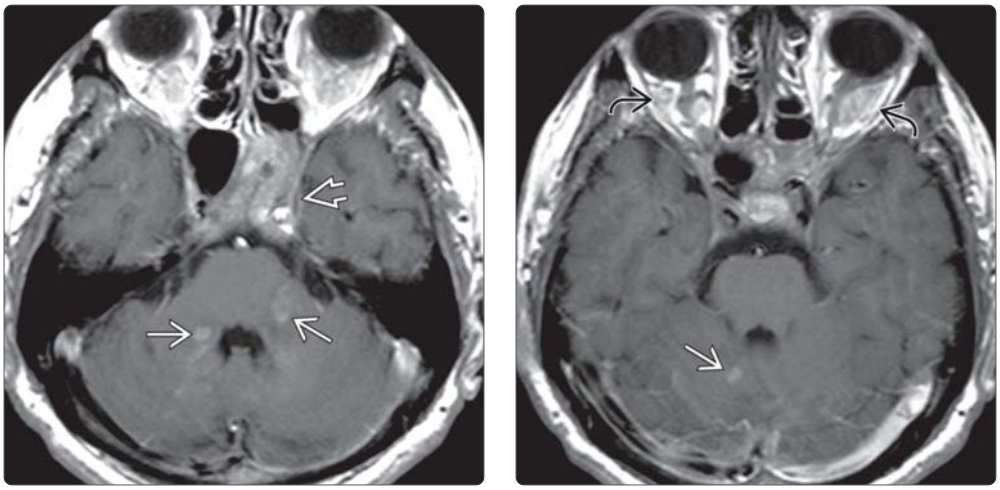

(Left) *Axial T1 C+ MR in a patient with biopsy-proven Erdheim-Chester disease shows enhancing lesions in both cerebellar hemispheres ➡, as well as the cavernous sinus ➡.* **(Right)** *More cephalad T1 C+ MR in the same patient shows additional lesions in the superior cerebellum ➡ and orbits ⇨. (Courtesy M. Warmuth-Metz, MD.)*

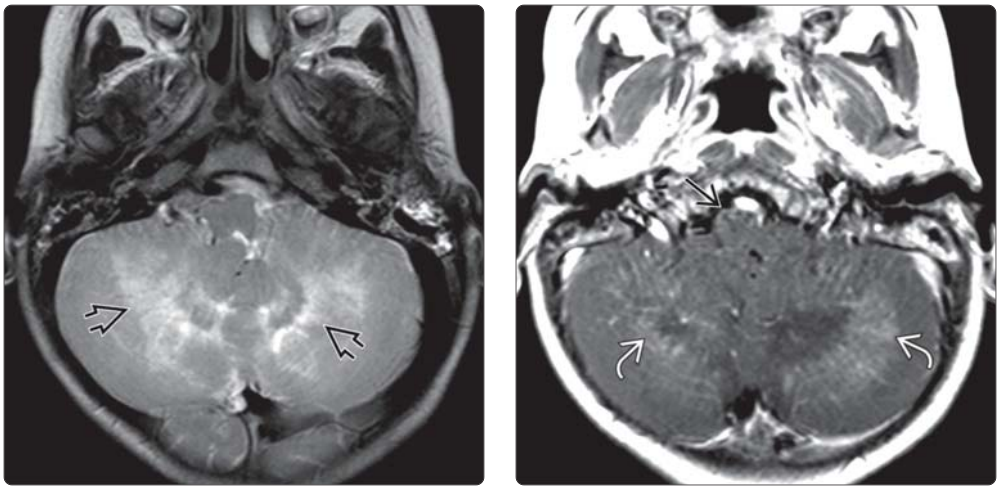

(Left) *Axial T2WI MR in a child with hemophagic lymphohistiocytosis shows bilateral patchy and confluent hyperintensities ⇨ in both cerebellar hemispheres.* **(Right)** *Axial T1 C+ MR in the same patient shows patchy and linear enhancement of the extensive cerebellar infiltrates ➡. Subtle pial enhancement over the medulla is also present ⇨. (Courtesy D. Phillips, MD.)*

(Left) *Axial FLAIR MR in a patient with juvenile xanthogranuloma (JXG) shows bilateral confluent and patchy white matter lesions in the subcortical and deep periventricular white matter.* **(Right)** *T1 C+ MR in the same patient shows an enhancing mass in the choroid plexus ➡. Diagnosis of JXG was proven by skin biopsy.*

https://CafePezeshki.IR

KEY FACTS

TERMINOLOGY

- Trichilemmal cyst (TC) is preferred term
  - "Sebaceous cyst" (SC) commonly used but incorrect
  - Variant = proliferating trichilemmal tumor (PTT)
- Keratin-containing cyst
  - Lined by stratified squamous epithelium
  - Pathology looks like root sheath of hair follicle

IMAGING

- General features
  - Most within dermis or subcutaneous tissue
  - Size varies (few mm to several cm)
  - Can be single or multiple
- CT
  - Round/ovoid, well-delineated scalp mass
  - Multifocal punctate/curvilinear/coarse Ca++
- MR
  - Isointense with brain, muscle on T1WI
  - Inhomogeneously hypointense on T2WI
  - Does not suppress on FLAIR
  - Multifocal "blooming" foci common on T2*
  - Simple sebaceous cysts usually do not enhance

TOP DIFFERENTIAL DIAGNOSES

- Basal cell, SCCa
- Dermoid cyst
- Epidermoid cyst
- Metastasis
- Cephalocele

CLINICAL ISSUES

- Classic presentation
  - Subepidermal scalp mass in woman > 60 years of age
  - Hairless, rubbery, nontender, mobile subcutaneous scalp mass(es)
  - Usually nonpainful

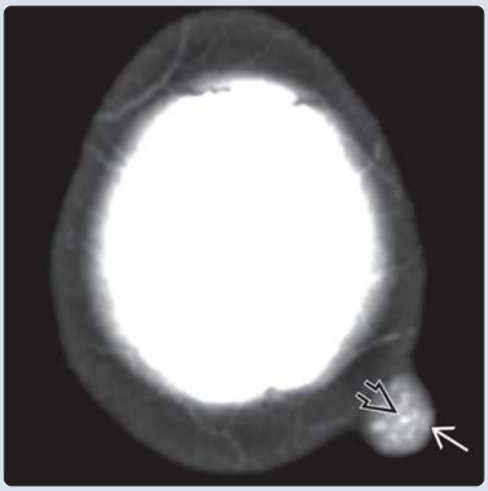

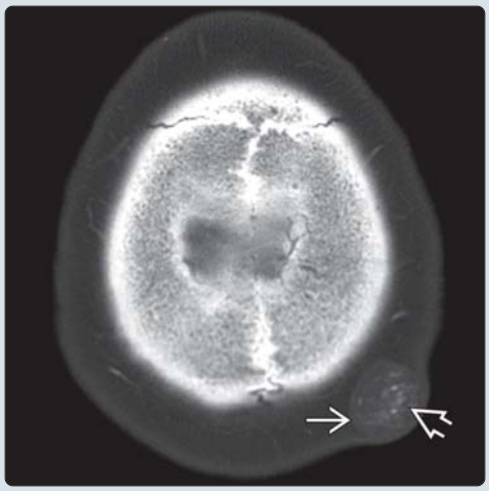

(Left) *Axial NECT in a 63-year-old man was obtained for trauma evaluation. A superficial scalp mass ⇨ that contained several hyperintense foci suggesting calcifications ⇨ was incidentally noted.* **(Right)** *Axial bone CT in the same patient shows that the scalp mass ⇨ is sharply delineated. Multiple punctate and curvilinear calcifications ⇨ within the mass can be seen. Note the lack of bone erosion or invasion. The remainder of the scalp appears normal. This was presumed to be a sebaceous cyst.*

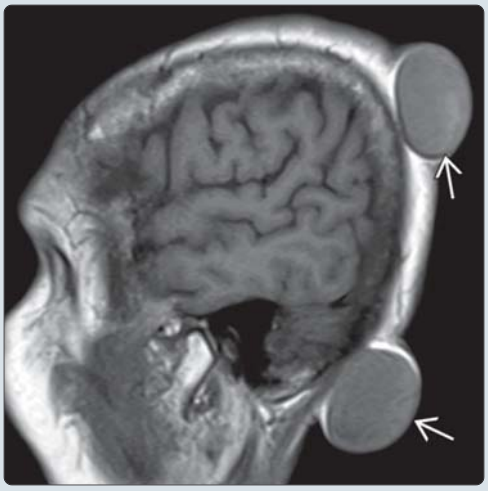

(Left) *Sagittal T1WI MR in a 68-year-old woman with headaches shows 2 large but very well-circumscribed scalp masses ⇨. The masses are incompletely surrounded by fat and isointense with brain and muscle.* **(Right)** *Axial T2WI MR in the same patient shows the mass ⇨ to be inhomogeneously hypointense. Both lesions demonstrated some internal "blooming" on T2* that suggested calcifications. These lesions had been slowly enlarging over many years and are benign proliferating trichilemmal cysts.*

https://CafePezeshki.IR

TERMINOLOGY

Abbreviations

- Trichilemmal cyst (TC) is preferred terminology
  - "Sebaceous cyst" (SC) commonly used but incorrect
- Variant = proliferating trichilemmal tumor (PTT)

Synonyms

- PTT also called "pilar" or "turban" tumor

Definitions

- Keratin-containing cyst
  - Lined by stratified squamous epithelium

IMAGING

General Features

- Best diagnostic clue
  - Nontender scalp mass in older woman
- Location
  - Soft tissues of scalp
    - Most within dermis or subcutaneous tissue
- Size
  - Varies from few mm to several cm
    - Can become huge
  - Can be single or multiple
- Morphology
  - Round/ovoid, well delineated

Imaging Recommendations

- Best imaging tool
  - CT with soft tissue, bone windows

CT Findings

- NECT
  - Solid or cystic scalp mass(es)
  - Sharply delineated
  - Hyperdense to fat
  - Multifocal punctate, curvilinear, and coarse Ca++
    - May layer in dependent portion of larger cysts
- CECT
  - No enhancement

MR Findings

- T1WI
  - Isointense with brain, muscle
- T2WI
  - Inhomogeneously hypointense
- FLAIR
  - Does not suppress
- T2* GRE
  - Multifocal "blooming" foci common
  - Ca++, not hemorrhage
- T1WI C+
  - Simple sebaceous cysts usually do not enhance
  - PTTs may show significant enhancement with solid lobules, cystic cavities

DIFFERENTIAL DIAGNOSIS

Basal Cell, SCCa

- Basal cell carcinomas are ill defined, invade locally
- Primary scalp SCCas rare

Dermoid Cyst

- Skull > > scalp

Epidermoid Cyst

- Skull > > scalp

Hemangioma

- Skull > > scalp

Metastasis

- Ill defined, invasive

Cephalocele

- Young patient
- Usually complex, containing brain/meninges/vessels

PATHOLOGY

Gross Pathologic & Surgical Features

- Elevated, slightly reddish scalp mass

Microscopic Features

- Resembles external root sheath of hair follicle
  - Lined by stratified squamous epithelial cells
- Cyst contents: Keratin, Ca++ frequent
- Malignant transformation rare

CLINICAL ISSUES

Presentation

- Most common signs/symptoms
  - Hairless, rubbery, nontender, mobile subcutaneous scalp mass
  - Usually nonpainful

Demographics

- Age
  - Any age
  - Proliferating trichilemmal cysts most common in elderly women
    - Classic is subepidermal scalp tumor in female > 60 years of age
- Gender
  - Female predominance

Natural History & Prognosis

- Usually slow growth
- May become locally aggressive
- Malignant transformation of trichilemmal cysts is rare
  - Proliferating trichilemmal cystic carcinoma (PTCC)

Treatment

- Surgical excision

SELECTED REFERENCES

1. Leyendecker P et al: 18F-FDG PET/CT findings in a patient with a proliferating trichilemmal cyst. Clin Nucl Med. ePub, 2015
2. Türk CÇ et al: Incidence and clinical significance of lesions presenting as a scalp mass in adult patients. Acta Neurochir (Wien). 157(2):217-23, 2015
3. Dewanda NK et al: Baker's dozen on the scalp: an interesting case of multiple trichilemmal cyst. J Cutan Aesthet Surg. 7(1):67-8, 2014

https://CafePezeshki.IR

KEY FACTS

TERMINOLOGY

- Typical ("benign") meningioma (TM) = WHO grade 1

IMAGING

- Location
  - Supratentorial (90%)
    - Parasagittal/convexity (45%), sphenoid (15-20%)
    - Olfactory groove (5-10%), parasellar (5-10%)
  - Infratentorial (8-10%) (CPA most common site)
  - Multiple meningiomas in 1-9% of cases
- General features
  - Extraaxial mass with broad-based dural attachment
  - > 90% enhance homogeneously, intensely
- CT
  - Hyper- (70-75%), iso- (25%), hypodense (1-5%)
  - Hyperostosis, irregular cortex, ↑ vascular markings
  - Ca++ (20-25%) (diffuse, focal, sand-like, "sunburst," globular, rim)
  - Necrosis, cysts common; hemorrhage rare
- MR
  - Look for CSF/vascular "cleft" between tumor, brain
  - Dural "tail" (35-80% but nonspecific)
- Correlation between imaging, ↑ tumor grade
  - Indistinct tumor-brain interface
  - Capsular enhancement
  - Heterogeneous tumor enhancement

TOP DIFFERENTIAL DIAGNOSES

- Dural metastasis
- Granuloma (TB, sarcoid)
- Idiopathic hypertrophic pachymeningitis
- Extramedullary hematopoiesis
- Hemangioma, dura/venous sinuses

CLINICAL ISSUES

- Most common adult 1° intracranial neoplasm (20-35%)
- Peak age = 40-60 years (rare in children unless NF2)
- Often asymptomatic, incidentally found, grow slowly

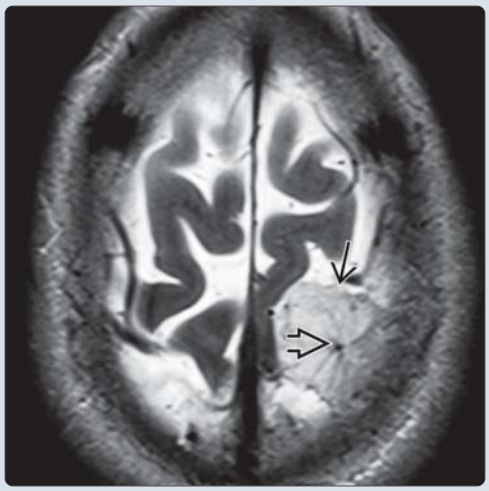

(Left) *Coronal graphic depicts classic meningioma with broad base toward dura with reactive dural tail ⇨. Note the CSF-vascular cleft ⇨ between invaginating tumor and brain. Typical "sunburst" of dural vessels ⇨ (in this case, the middle meningeal artery) supplies center of lesion, while pial vessels supply periphery.* **(Right)** *Axial T2 FS MR in a 59-year-old man with headaches shows a moderately hyperintense extraaxial mass ⇨ with "sunburst" of vessels (flow voids) supplying center of tumor ⇨.*

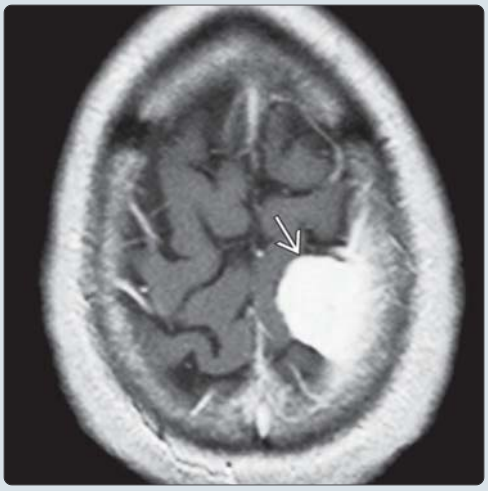

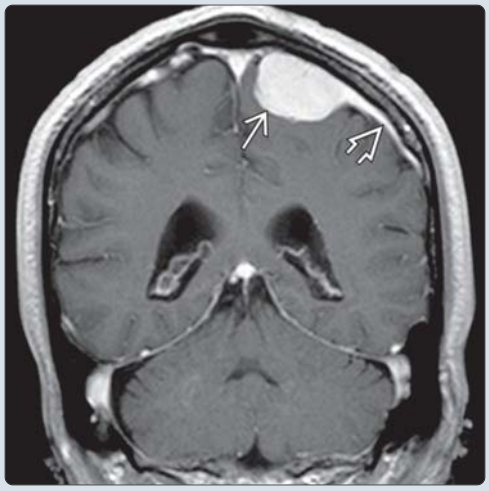

(Left) *Axial T1 C+ MR in the same patient shows the mass ⇨ enhances strongly and uniformly.* **(Right)** *Coronal T1 C+ MR shows the enhancing mass ⇨ with slightly more intensely enhancing dural tail ⇨. A WHO grade I meningioma was removed at surgery. The dural tail was not involved by tumor.*

https://CafePezeshki.IR

TERMINOLOGY

Abbreviations

- Typical meningioma (TM)
- Atypical meningioma (AM), malignant meningioma (MM)

Definitions

- TM = WHO grade 1 meningioma

IMAGING

General Features

- Best diagnostic clue
  - Dural-based enhancing mass → cortical buckling, trapped CSF/vessels in "cleft" between tumor and brain
- Location
  - Supratentorial (90%)
    - Parasagittal/convexity (45%), sphenoid ridge (15-20%)
    - Olfactory groove (5-10%), parasellar (5-10%)
    - Other (5%): Intraventricular, optic nerve sheath (ONSM), pineal region
    - Rare: Intraparenchymal without dural attachment
  - Infratentorial (8-10%): CPA most common
  - Extradural (mostly intraosseous, calvaria) > 2%
  - Extracranial (head/neck)
    - Most common: Paranasal sinuses
    - Less common: Nasal cavity, parotid, skin
  - Multiple meningiomas: Seen in 1-9% of cases
    - 16% at autopsy (M < F)
- Morphology
  - Extraaxial mass with broad-based dural attachment

CT Findings

- NECT
  - Sharply circumscribed smooth mass abutting dura
    - Hyperdense (70-75%), isodense (25%)
      - Hypodense (1-5%), fat density (rare lipoblastic subtype)
    - Calcified (20-25%)
      - Can be diffuse, focal, sand-like ("psammomatous")
      - "Sunburst," globular, rim patterns
      - Calcification correlates with slow growth in asymptomatic meningiomas
    - Necrosis, cysts, hemorrhage (8-23%)
  - Trapped CSF pools, cysts in adjacent brain common
  - Peritumoral hypodense vasogenic edema (60%)
  - Bone CT
    - Hyperostosis, irregular cortex, ↑ vascular markings
- CECT
  - > 90% enhance homogeneously, intensely
- CTA
  - May be helpful prior to DSA, embolization
  - Delineates arterial supply, venous drainage

MR Findings

- T1WI
  - Typically iso- to slightly hypointense with cortex
  - Necrosis, cysts, hemorrhage (8-23%)
  - Look for gray matter "buckling"
- T2WI
  - Variable ("sunburst" pattern may be evident)
  - 8-23% of intratumoral cysts (common; can be almost microcystic), hemorrhage (rare)
  - Best sequence for
    - Visualizing CSF/vascular cleft between tumor, brain (80%)
    - Identifying vascular flow voids (80%)
    - Predicting "hard" meningioma at surgery (hypointense)
- FLAIR
  - Hyperintense peritumoral edema, dural tail
- T2* GRE
  - Ca++ common, hemorrhage rare
- DWI
  - DWI, ADC maps for TM variable in appearance
  - Lower ADC in MM and AM compared to TM
- T1WI C+
  - > 95% enhance homogeneously, intensely
  - Dural tail (35-80% of cases) nonspecific
    - Other neoplasms (schwannoma, adenoma, metastases), nonneoplastic dural-based masses
  - En plaque: Sessile thickened enhancing dura
- MRV
  - Evaluate sinus involvement
- MRS
  - Elevated levels of alanine at short TE
    - Triplet-like spectral pattern at 1.3-1.5 ppm (overlapping of Ala, Lac)
    - Elevated Glx alfa/glutathione
- Perfusion MR
  - rCBV and rMTE values of peritumoral edema differentiate TM and MM
    - High rCBV in peritumoral edema of anaplastic meningiomas
- Correlation between imaging, ↑ tumor grade
  - Indistinct tumor-brain interface
  - Capsular enhancement
  - Heterogeneous tumor enhancement

Angiographic Findings

- DSA
  - "Sunburst" or radial appearance
    - Dural vessels supply lesion core
    - Pial vessels may be parasitized, supply periphery
  - Prolonged vascular "stain"
  - Venous phase vital to evaluate sinus involvement

Nuclear Medicine Findings

- Thallium-201 SPECT better than FDG PET at predicting tumor grade

Other Modality Findings

- Imaging predictors of difficult, extrapial surgical cleavage plane
  - Peritumoral edema on MR/CT → may obscure pial invasion by tumor
  - Tumor pial vascularization on DSA = pial invasion
  - Tumor/cortex interface is not reliable predictor

Imaging Recommendations

- Best imaging tool
  - MR C+

https://CafePezeshki.IR

- Protocol advice
  - Consider MRS → look for alanine, glu:cr ratio

DIFFERENTIAL DIAGNOSIS

Dural Metastasis

- Skull often infiltrated; multifocal
- Breast most common primary

Granuloma

- Sarcoid
- TB

Idiopathic Hypertrophic Pachymeningitis

- Dural biopsy essential to confirm diagnosis
- Often IgG4-related disease

Extramedullary Hematopoiesis

- Known hematologic disorder
- Often multifocal

Hemangioma, Dura/Venous Sinuses

- Can be indistinguishable from TM
- Venous sinus (e.g., cavernous) > dural-based mass

PATHOLOGY

General Features

- Etiology
  - Arise from arachnoid meningothelial ("cap") cells
  - Loss of chromosome 22 (40-60% of sporadic meningiomas)
  - NF2 meningiomas
    - Genomic instability
    - More likely to be atypical
    - Cerebral, cerebellar hemispheres, lateral skull base, spine
  - Non-NF2 meningiomas
    - Nearly always benign
    - Chromosomal stability, SMO mutations common
    - Medial skull base
  - *SMARCB1* mutations common in multiple meningiomas
- Associated abnormalities
  - Neurofibromatosis type 2 (NF2)
    - Multiple inherited schwannomas, meningiomas, and ependymomas (MISME)
    - 50-75% of patients with NF2 develop meningioma
    - 10% of patients with multiple meningiomas have NF2
  - Metastases to meningioma ("tumor to tumor" sometimes called "collision tumor")
    - CM are most common primary intracranial tumor to harbor metastases; majority are lung or breast
- Slow growing, benign

Gross Pathologic & Surgical Features

- 2 basic morphologies
  - Globose = globular, well-demarcated neoplasm with wide dural attachment (dural tail)
    - 60% of tumors demonstrate local invasion into dural tail
  - En plaque = sheet-like extension covering dura without parenchymal invagination
- Homogeneous reddish-brown translucent pale surface
- Soft to tough, occasionally gritty
  - Depends on fibrous tissue, Ca++ calcium content
- TMs usually invaginate into brain, do not invade it

Microscopic Features

- TM (WHO grade I) has wide range of subtypes
  - Meningothelial: Uniform tumor cells, collagenous septa, psammomatous calcifications (most common)
  - Fibrous: Interlacing fascicles of spindle-shaped cells, collagen/reticulin matrix
  - Transitional (mixed): "Onion bulb" whorls, psammoma bodies
  - Psammomatous
  - Angiomatous
  - Microcystic
  - Secretory
  - Lymphoplasmacyte rich
  - Metaplastic

CLINICAL ISSUES

Presentation

- Most common signs/symptoms
  - < 10% of all meningiomas are symptomatic
  - Symptoms depend on tumor site

Demographics

- Age
  - Middle decades
- Gender
  - M:F = 1:1.5-3
- Epidemiology
  - Most common 1° adult intracranial tumor (20-35%)
    - 1-1.5% autopsy prevalence

Natural History & Prognosis

- Generally grow slowly, compress adjacent structures
- Parasagittal often grow into and occlude superior sagittal sinus
- Metastases rare (0.1-0.2%): Histology, location do NOT correlate with metastases

Treatment

- Asymptomatic followed with serial imaging
- Surgical goals
- Radiotherapy infrequently utilized for CM

DIAGNOSTIC CHECKLIST

Image Interpretation Pearls

- Preoperatively define **entire** extent of tumor
- Could patient be syndromic (e.g., NF2)

SELECTED REFERENCES

1. Shibuya M: Pathology and molecular genetics of meningioma: recent advances. Neurol Med Chir (Tokyo). 55(1):14-27, 2015
2. Watanabe K et al: Prediction of hard meningiomas: quantitative evaluation based on the magnetic resonance signal intensity. Acta Radiol. ePub, 2015
3. Lin BJ et al: Correlation between magnetic resonance imaging grading and pathological grading in meningioma. J Neurosurg. 121(5):1201-8, 2014
4. Wen M et al: Immunohistochemical profile of the dural tail in intracranial meningiomas. Acta Neurochir (Wien). 156(12):2263-73, 2014

https://CafePezeshki.IR

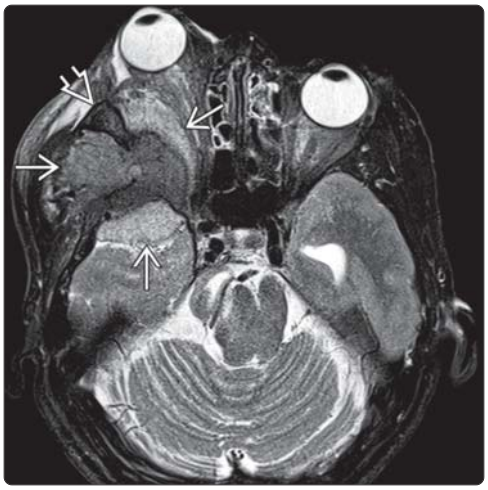

(Left) *Axial T2 FS MR in a 66-year-old woman with severe proptosis shows massive thickening of the greater sphenoid wing ➡ surrounded by a mildly hyperintense soft tissue mass ➡ involving the orbit, high deep masticator space, and middle cranial fossa.* **(Right)** *The marked hyperostosis of the sphenoid wing ➡ is well shown on this coronal STIR MR. There is a distinct dural tail ➡ that is noticeably more hyperintense than the soft tissue component of the mass ➡.*

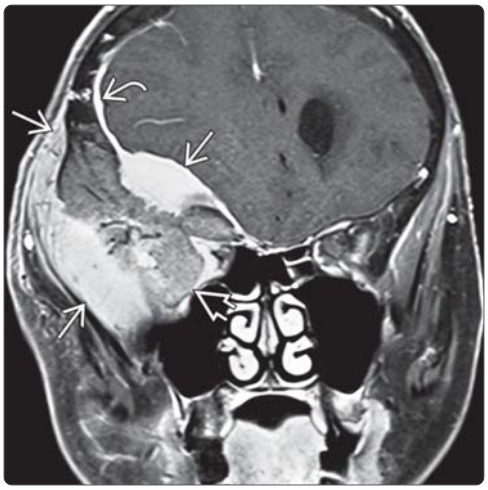

(Left) *Axial T1 C+ FS MR in the same patient shows the soft tissue component of the mass ➡ enhances strongly and uniformly. The hyperostotic bone ➡ enhances mildly.* **(Right)** *Coronal T1 C+ FS MR shows the intensely enhancing soft tissue mass ➡, the markedly thickened, hyperostotic and vascularized sphenoid wing ➡, and the adjacent dural tail ➡. WHO grade I meningioma with tumor cells in the resected sphenoid bone was found at surgery.*

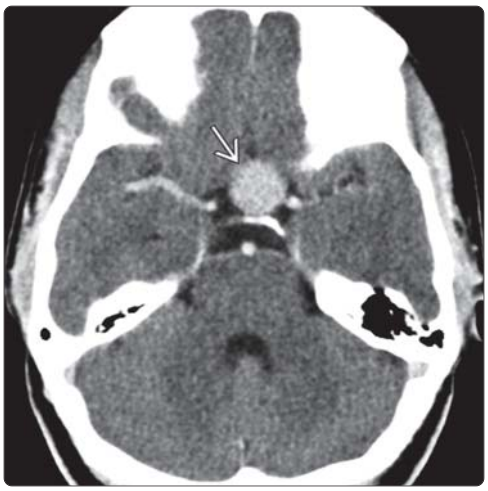

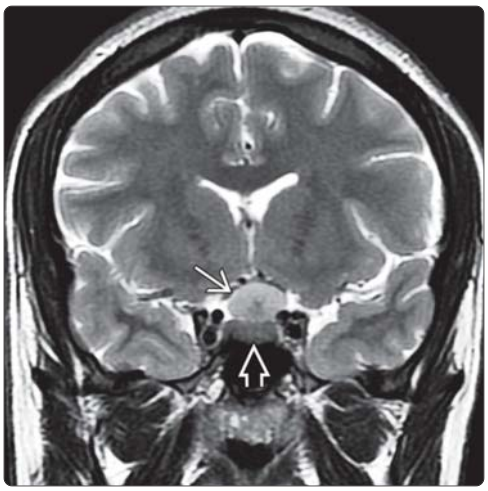

(Left) *Axial CECT in a 26-year-old pregnant woman with sudden visual loss shows an enhancing suprasellar mass ➡.* **(Right)** *Because of the concern for hemorrhagic pituitary neoplasm, an MR was obtained for further evaluation. Coronal T2WI shows a normal pituitary gland ➡ with a well-delineated hyperintense mass ➡ above it that arises from the diaphragma sellae and is clearly separate from the gland. Classic diaphragma sellae meningioma was found at surgery, proven to be a WHO grade I tumor.*

https://CafePezeshki.IR

(Left) *Axial T2WI MR shows a well-defined mass in the right cerebellopontine angle ⇨ with extension into the right auditory canal ⇨.* **(Right)** *Axial T1WI C+ MR demonstrates marked and homogeneous enhancement of the CPA meningioma.*

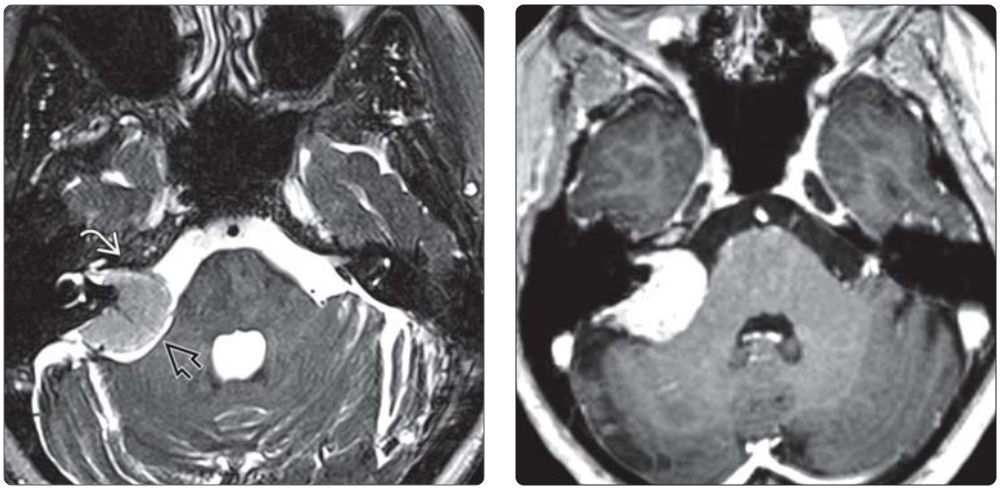

(Left) *Coronal T2WI MR shows a cortex isointense mass ⇨ in the region of the left olfactory bulb with perifocal edema ⇨.* **(Right)** *Axial T1WI C+ MR shows marked and homogeneous enhancement of the mass ⇨ representing olfactory meningioma.*

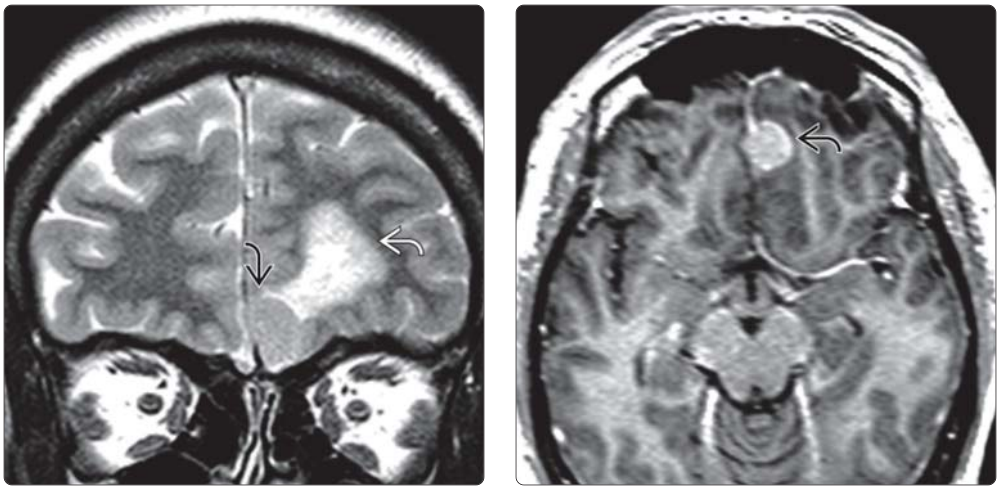

(Left) *Axial CECT in a patient with primary optic nerve sheath meningioma shows marked enhancement along the left optic nerve, described as a "tram-track" sign ⇨.* **(Right)** *Axial T1WI C+ MR in this patient with secondary optic nerve sheath meningioma shows meningioma arising from the sphenoid ridge around the anterior clinoid, narrowing the cavernous internal carotid, extending through the optic canal, and infiltrating the optic nerve sheath ⇨.*

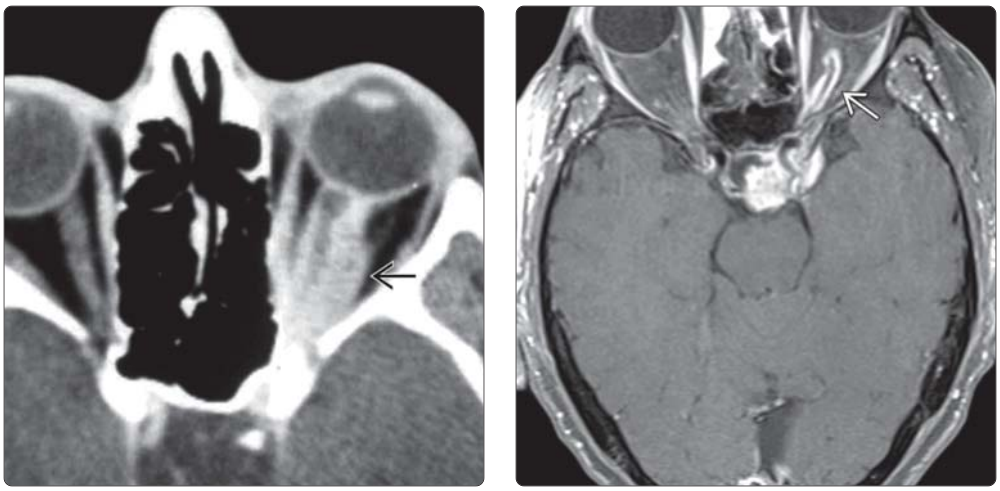

https://CafePezeshki.IR

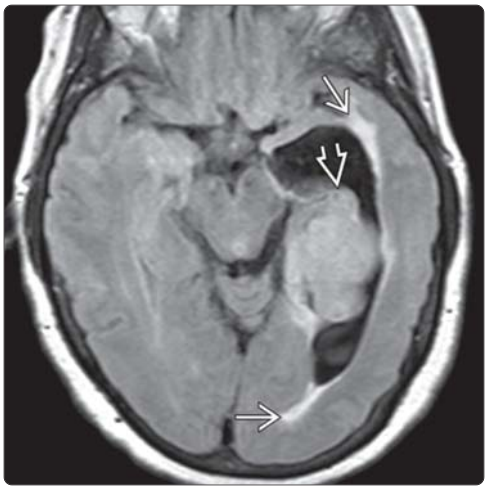

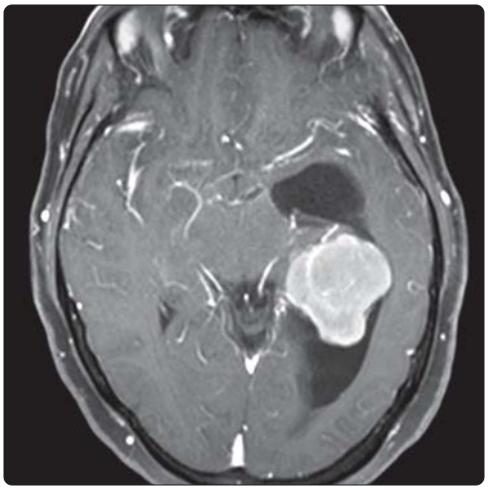

(Left) *Axial FLAIR MR shows a lobulated, mildly hyperintense intraventricular mass* ➡ *arising from the choroid plexus glomus. Note the enlarged temporal horn of left lateral ventricle with periventricular accumulation of interstitial fluid migration* ➡. **(Right)** *Axial T1 C+ FS MR shows a strongly, uniformly enhancing mass. Intraventricular meningioma was found at surgery. About 1% of intracranial meningiomas are intraventricular; this is the most common location as arachnoid rests may persist within choroid plexus.*

(Left) *Axial NECT shows marked hyperostosis* ➡ *and calcification* ➡ *in this plaque-like meningioma extending along the left inner table of the skull.* **(Right)** *Axial T1WI MR in the same patient demonstrates the characteristic hypointense appearance of calcification/ossification* ➡.

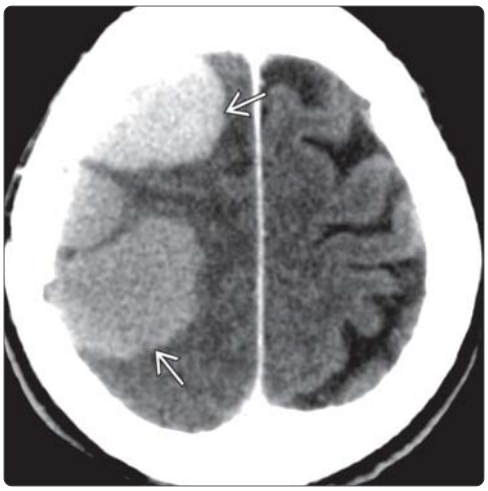

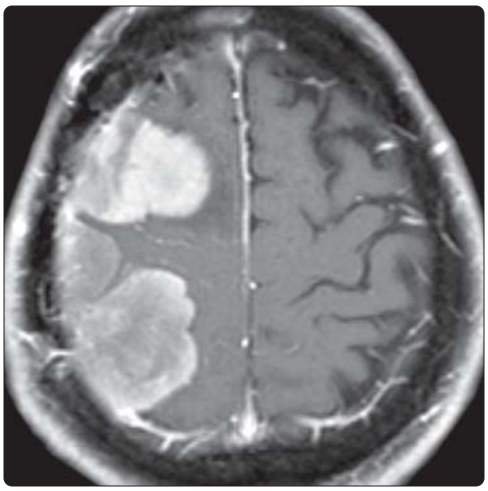

(Left) *Axial CECT shows multiple well-delineated, right-sided extraaxial masses* ➡ *that were moderately hyperdense on NECT (not shown) and enhance strongly.* **(Right)** *Axial T1WI C+ MR shows strongly enhancing masses. Multiple meningiomas are more common in female patients and patients with NF2.*

https://CafePezeshki.IR

KEY FACTS

TERMINOLOGY

- Typical (benign) meningioma = WHO grade 1
- Atypical meningioma (AM) = WHO grade 2
- Malignant meningioma (MM) = WHO grade 3

IMAGING

- CT triad of MM: Extracranial mass, osteolysis, intracranial tumor
- MR
  - Dural-based locally invasive lesion with areas of necrosis, marked brain edema
  - Indistinct tumor margins (tumor invades, interdigitates with brain)
  - Prominent tumor pannus extending away from mass = "mushrooming"
  - Marked peritumoral edema
  - DWI, ADC correlate with hypercellular histopathology (high signal on DWI, low ADC)

TOP DIFFERENTIAL DIAGNOSES

- Meningioma (typical)
- Dural metastasis
- Lymphoma
- Sarcoma (osteosarcoma, Ewing, gliosarcoma, etc.)

PATHOLOGY

- AM: High mitotic activity
- MM: AM features + findings of frank malignancy

CLINICAL ISSUES

- AM 29% recurrence (26% become MM)
- MM 50% recurrence

DIAGNOSTIC CHECKLIST

- Difficult to predict meningioma tumor grade on imaging
- Imaging findings of typical meningioma do not exclude atypical, malignant variants

(Left) *Coronal graphic illustrates a malignant meningioma infiltrating the scalp, skull, and underlying brain. Extensive vasogenic edema (in gray) is present. Note osteolysis, invasion through dura/arachnoid, tumor "mushrooming" ⇨, and interdigitation with the brain.* **(Right)** *Sagittal T1WI C+ MR of malignant meningioma shows enhancing tumor involving the scalp, skull, and underlying brain. Note "mushrooming" of tumor through the dura ⇨, prominent hypointense brain edema ⇨.*

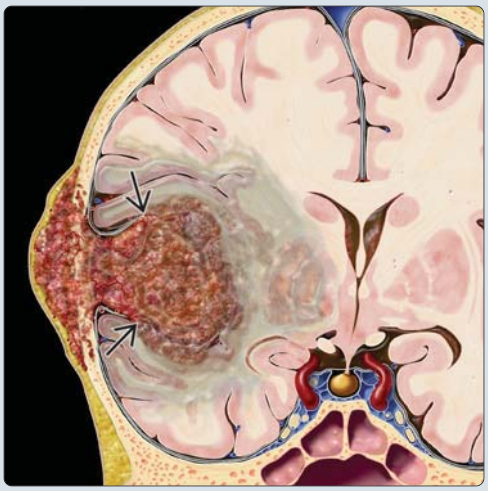

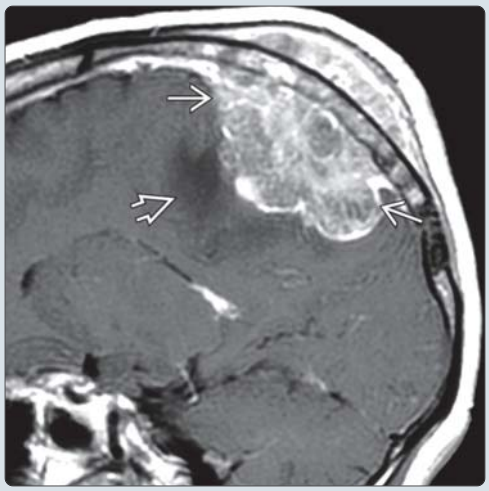

(Left) *Axial T2WI MR in a 71-year-old man shows well-demarcated dural-based mass along right greater sphenoid wing ⇨. Mass is isointense with cortex & distinct CSF-vascular cleft ⇨ with no evidence for focal brain invasion.* **(Right)** *Axial T1 C+ FS MR scan shows intense, uniform enhancement ⇨. At surgery there was no evidence for invasion of adjacent parenchymal. Pathology disclosed WHO grade II meningioma. This case illustrates the difficulty of predicting meningioma tumor grade on imaging.*

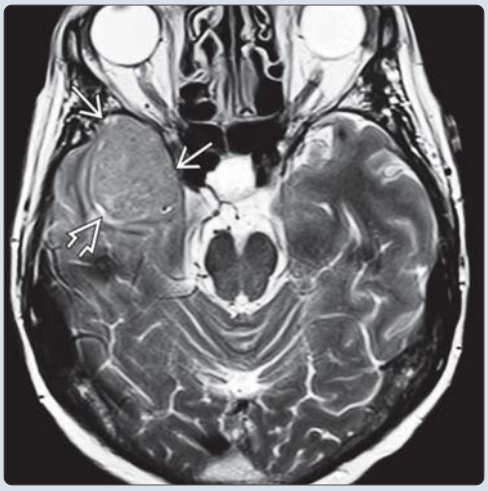

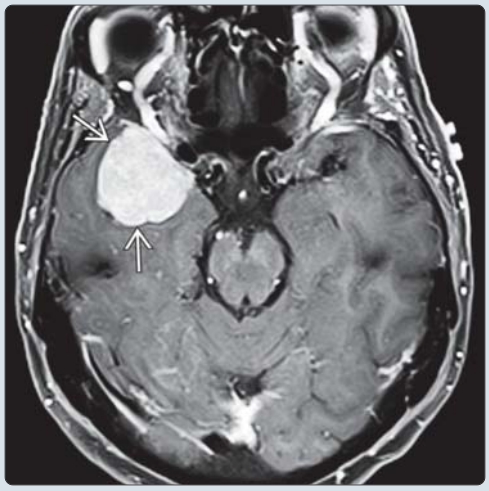

https://CafePezeshki.IR

TERMINOLOGY

Abbreviations

- Atypical meningioma (AM), malignant meningioma (MM)

Definitions

- Typical (benign) meningioma = WHO grade 1
  - Common meningioma (CM)
- Atypical meningioma = WHO grade 2
  - Papillary, clear cell meningiomas (CCM)
- Malignant meningioma = WHO grade 3
  - Anaplastic meningioma

IMAGING

General Features

- Best diagnostic clue
  - Dural-based, locally invasive lesion with areas of necrosis, marked brain edema
- Location
  - May occur anywhere in neuraxis (brain > > spine)
  - AM (clear cell variant)
    - Frequent in CPA, along tentorium
  - MM
    - Parasagittal (44%), cerebral convexities (16%) most common sites
    - Both AM, MM far less frequent in spine, skull base

CT Findings

- NECT
  - CT triad of MM: Extracranial mass, osteolysis, intracranial tumor
  - Hyperdense; minimal or no Ca++
    - Calcified = generally lower growth rate
  - Marked perifocal edema, bone destruction
- CECT
  - Enhancing tumor mass
  - Prominent tumor pannus extending away from mass = "mushrooming"

MR Findings

- T1WI
  - Indistinct tumor margins
  - Infiltrating tumor interdigitates with brain
- FLAIR
  - Marked peritumoral edema
- DWI
  - Markedly hyperintense on DWI, hypointense on ADC
- T1WI C+
  - Enhancing tumor mass
    - May extend into brain, skull, scalp
    - Often plaque-like ± "mushrooming"
- MRV
  - Look for dural sinus invasion
- MRS
  - Elevated levels of alanine at short TE (peak ranges from 1.3-1.5 ppm)
- Perfusion MR
  - Good correlation between volume transfer constant (K-trans), histologic grade

Angiographic Findings

- Conventional
  - Dural supply → central "sunburst" appearance
  - Intense vascular stain appears early, persists late
  - Venous phase vital to evaluate sinus involvement

Nuclear Medicine Findings

- PET
  - F-18 FDG: AM, MM ↑ ↑ glucose utilization
  - High glucose metabolism present in radiation-induced meningiomas

Imaging Recommendations

- Best imaging tool
  - MR C+, ± MRS

DIFFERENTIAL DIAGNOSIS

Meningioma (Typical)

- Usually noninvasive but may need histology for definitive diagnosis

Dural Metastasis

- Often known extracranial primary neoplasm
- Osteolytic & destructive or osteoblastic & sclerotic

Lymphoma (Metastatic Intracranial)

- Lytic bone lesion with epidural and extracranial component

Osteosarcoma

- Osteolytic with soft tissue mass and poorly defined margins
- Tumoral calcification may be "sunburst"

Ewing Sarcoma

- Affects children
- CT: Laminated periosteal "onion skin" appearance

Primary Meningeal Sarcoma

- Extremely rare nonmeningothelial tumor of meninges

Gliosarcoma

- GBM with meningeal sarcoma

PATHOLOGY

General Features

- Etiology
  - CM: 90% inactivation of *NF2* gene product "Merlin"
  - AM & MM: After *NF2* inactivation, additional events occur and are related to greater aggressiveness
  - Occasionally no genetic defect found as etiology
- Genetics
  - Loss of 1 copy of chromosome 22 is most common chromosomal change in meningioma
  - 2nd most frequent genetic abnormalities are 1p and 14q deletions, more aggressive behavior
  - Chromosome 10 abnormalities shared with nonmeningioma tumors
  - Chromosome 9p losses important in AM and MM
  - Multiple meningiomas
    - Many display expected *NF2* gene mutations
    - Some have normal *NF2* genes: Suggests 2nd tumor-suppressor gene is also on chromosome 22
  - Radiation-associated meningiomas (RAM)

https://CafePezeshki.IR

- No significant differences between RAM and non-RAM in chromosome 1 and 22 losses
- Genetic effects on location and histology
  - Strong correlations found among anterior skull base location, intact 22q, and meningothelial; convexity location, disrupted 22q, transitional, fibrous
- **Summary**: Significant correlation between number of chromosomal imbalances and tumor grade
  - CM: 22q loss (47%), 1p deletion (33%)
  - AM: 1p (86%), 22q (71%), 10q (57%), 14q and 18q (43%) losses; 15q and 17q (43%) gains
  - MM: 1p loss (100%); also losses on 9p, 10q, 14q, 15q, 18q, and 22q and gains on 12q, 15q & 18p
  - Combined 1p/14q deletions in CM (13%), AM (43%), and MM (67%)

Staging, Grading, & Classification

- Immunohistochemical staining with MIB-1 antibody (Ki-67) correlates with recurrence
  - MIB-1 = nuclear, nonhistone protein expressed during cell-cycle proliferation but not resting
  - Staining with MIB-1 yields labeling index (LI) for quantification of number of dividing cells
    - LI < 4.4% → 82% recurrence free at 6 years
    - LI > 4.4% → 32% recurrence free at 6 years

Microscopic Features

- AM features (WHO criteria)
  - ↑ mitotic activity (4 or more mitoses/10 HPFs)
  - 3 or more
    - Small cells with high nuclear:cytoplasmic ratio
    - Prominent nucleoli
    - Uninterrupted patternless or sheet-like growth
    - Foci of spontaneous or geographic necrosis
- MM features (WHO criteria)
  - AM features with findings of frank malignancy
    - Malignant cytology, high mitotic index

CLINICAL ISSUES

Demographics

- Age
  - Middle decades
  - AM occurs about 10 years earlier than typical meningioma
- Gender
  - M:F = 1:1.3-1.5
- Ethnicity
  - More common in African Americans
- Epidemiology
  - Meningioma 1 of most common primary adult intracranial neoplasms (13-20%)
    - AM: 10-30% of all meningiomas (frequency rising)
    - MM: 1-3% of meningiomas (rare)
  - ~ 6 in 100,000 population
  - Familial predilection for meningioma = *NF2*
- Geographic predilection
  - In Africa, meningioma nears 30% of adult primary intracranial tumors

Natural History & Prognosis

- Recurrence-free survival, median time to recurrence longer for typical meningioma vs. AM vs. MM
  - Typical benign meningioma = only 9% recurrence
  - AM recurrence: 28%
    - 5-year survival: 86%; 10-year survival: 61%
    - 5-year recurrence-free survival: 48%
    - Median time to recurrence: 3 years
  - MM recurrence: 75%
    - 5-year survival: 35%
    - 5-year recurrence-free survival: 29%
    - Median time to recurrence: 2 years
  - MicroRNA-224 contributes to malignant progression of meningioma

Treatment

- Preoperative embolization
  - Particulate agents (e.g., polyvinyl alcohol) favored
  - ↓ operative time, blood loss
- Surgical goals
  - Resection of tumor and involved dura/dural tail (with tumor-free margins) with duraplasty
  - Resection of involved or hyperostotic bone
  - Preoperative knowledge whether tumor is AM or MM may alter neurosurgery preoperative plan
    - More aggressive to achieve complete resection
    - Complication: CSF seeding
- Radiotherapy: Frequently used for AM, MM
  - Fractionated external beam irradiation
  - Stereotactic radiosurgery
- Recurrence treatments
  - Repeat surgery
  - External beam irradiation, stereotactic radiosurgery

DIAGNOSTIC CHECKLIST

Image Interpretation Pearls

- Preoperatively define **entire** tumor extent
- Typical imaging findings do not exclude atypical variants

SELECTED REFERENCES

1. Aboukais R et al: Grade 2 meningioma and radiosurgery. J Neurosurg. 1-6, 2015
2. Cao X et al: Survival rates, prognostic factors and treatment of anaplastic meningiomas. J Clin Neurosci. ePub, 2015
3. Shibuya M: Pathology and molecular genetics of meningioma: recent advances. Neurol Med Chir (Tokyo). 55(1):14-27, 2015
4. Smith MJ: Germline and somatic mutations in meningiomas. Cancer Genet. ePub, 2015
5. Wang M et al: MicroRNA-224 targets ERG2 and contributes to malignant progressions of meningioma. Biochem Biophys Res Commun. ePub, 2015

https://CafePezeshki.IR

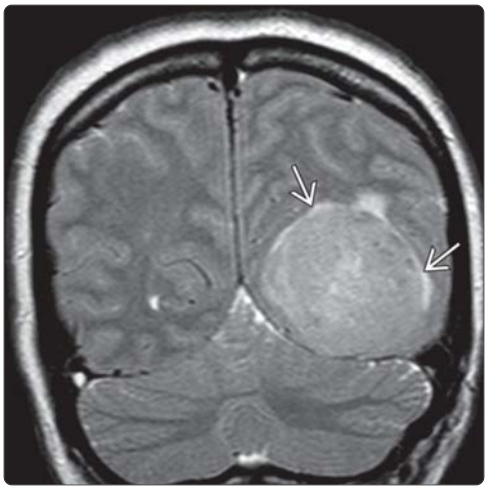

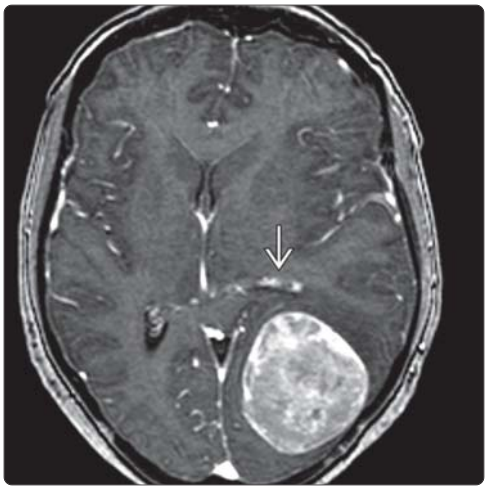

(Left) *Coronal T2WI MR in a 47-year-old man demonstrates a well-defined, homogeneous, extraaxial mass with minimal edema* ➡. **(Right)** *Axial T1 C+ MR in the same patient shows marked, relatively homogeneous enhancement. Note the compression of the left trigonum* ➡. *Surgical resection and histological evaluation revealed malignant meningioma (WHO grade III) despite the lack of aggressive features on imaging. Biopsy is necessary for definitive histologic type and grade of meningioma.*

(Left) *Axial NECT demonstrates a lobulated hyperdense mass along the right tentorium.* **(Right)** *Axial FLAIR MR in the same patient shows a hypointense, multilobulated mass* ➡ *with perifocal edema* ➡ *and mass effect on the 4th ventricle.*

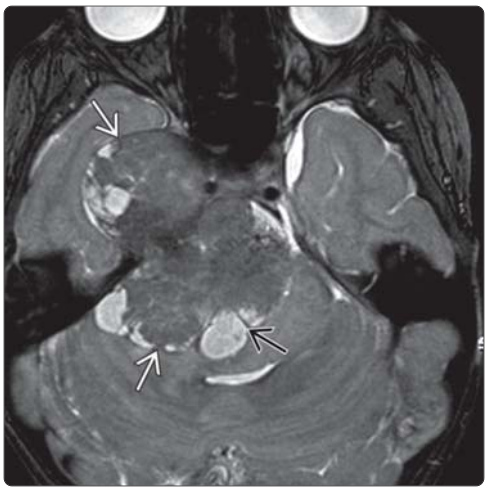

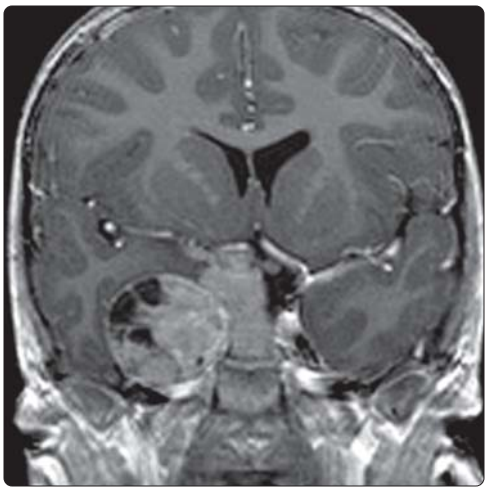

(Left) *High-resolution axial T2WI MR in the same patient nicely demonstrates a well-defined, low signal mass* ➡ *with cystic components* ➡. *Hypodensity indicates a high cellular matrix of the tumor.* **(Right)** *Coronal T1WI C+ SPGR MR shows enhancement of the solid tumor parts. Surgical removal was performed, and histological diagnosis was a mixture of clear cell meningioma (WHO grade II) and a whorling sclerosing variant of meningioma.*

https://CafePezeshki.IR

KEY FACTS

TERMINOLOGY

- Nonmenigotheliomatous benign mesenchymal tumor (BMT)
  - Typically dura, skull, &/or scalp lesion
  - Examples = chondroma, osteochondroma, osteoma, etc.

IMAGING

- Lesion of dura, skull, skull base, scalp without malignant features
- Use NECT, bone CT for most
- T1WI C+ MR to image noncalcified cartilage, brain involvement, malignant transformation

TOP DIFFERENTIAL DIAGNOSES

- Benign meningothelial tumors
- Malignant meningothelial tumors
- Malignant nonmeningothelial tumors

PATHOLOGY

- Meninges contain primitive multipotential mesenchymal cells
  - May give rise to broad spectrum of nonmeningothelial neoplasms

CLINICAL ISSUES

- BMT are most often asymptomatic
- BMT are rare to very rare
- Asymptomatic lesions require no treatment
- Surgical indications: Relief of symptoms, cosmesis

DIAGNOSTIC CHECKLIST

- Look for evidence of syndromic BMTs
  - Gardner: Multiple osteomas
  - Maffucci: Multiple enchondromas with hemangiomas
  - Ollier: Enchondromatosis

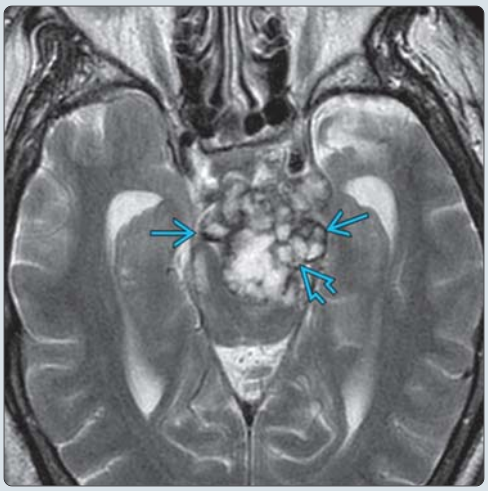

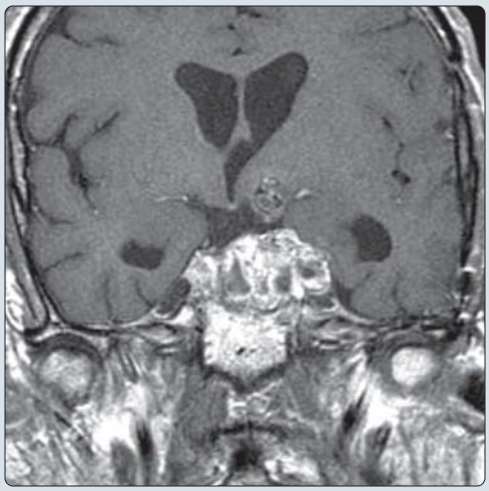

(Left) *Axial T2WI MR shows a well-delineated suprasellar mass with hypointense arcs surrounding hyperintense lobulated areas.* **(Right)** *Coronal T1 WI C+ MR in the same case shows that the mass involves the left cavernous sinus and enhances strongly but heterogeneously. Enchondroma was the histologic diagnosis. (Courtesy P. Sundgren, MD.)*

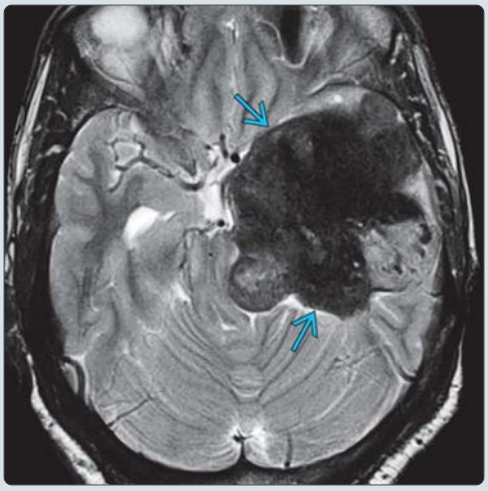

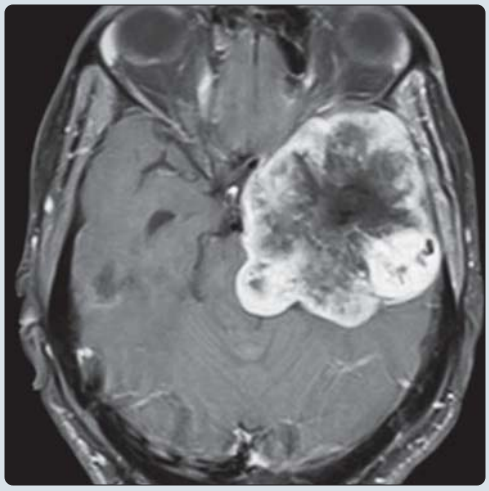

(Left) *Axial T2 WI MR shows a well-demarcated, lobulated, very hypointense mass in the left middle cranial fossa.* **(Right)** *Axial T1 WI C+ FS MR in the same case shows the strong but heterogeneous enhancement is mostly in the periphery of the mass. Solitary fibrous tumor was found at surgery. (Courtesy R. Hewlett, MD.)*

https://CafePezeshki.IR

TERMINOLOGY

Abbreviations

- Benign mesenchymal tumors (BMT)
  - Includes chondroma (CD), osteochondroma (OCD), osteoma (OST), and many others

Synonyms

- Benign nonmeningothelial tumors

Definitions

- Nonmenigotheliomatous mesenchymal benign neoplasm
  - Typically dura, skull, &/or scalp lesion

IMAGING

General Features

- Best diagnostic clue
  - Dura, skull, skull base, or scalp lesion without malignant features
- Location
  - BMT: Dura, skull, skull base, scalp
    - CD: Sellar/parasellar most common; dura/falx rare
    - OCD: Usually arises from skull base; dura/falx, rare
    - OST: Involves outer table; inner table rare

Radiographic Findings

- Radiography
  - CD: Expansile lesion containing matrix calcification with scalloped endosteum
  - OCD: Sessile or pedunculated bone-like projection
  - OST: Dense lesions without diploic involvement

CT Findings

- NECT
  - Chondroma
    - Expansile, lobulated, soft tissue mass
    - Contains curvilinear matrix calcification
    - Scalloped endosteal bone resorption → "saucerization"
    - No stalk or peduncle as in OCD
  - Osteochondroma
    - May see calcified matrix in cap atop cortical bone
    - Parent bone contiguous with cortex of OCD
  - Osteoma
    - Dense lesions without diploic involvement
- CECT
  - CD: May have slight enhancement
  - OCD: ± cartilaginous cap enhancement
  - OST: No enhancement

MR Findings

- T1WI
  - CD: Intermediate intensity
  - OCD: Mixed intensity; may see hypointense calcified matrix within cap atop cortical bone
  - OST: Hypointense
- T2WI
  - CD: Hyper- to hypointense
  - OCD: Mixed intensity; may see hypointense calcified matrix within cap atop cortical bone
  - OST: Variable intensity
- T1WI C+
  - CD: Enhancement of curvilinear septae (ring-and-arc pattern), scalloped margins
  - OCD: May have peripheral cartilaginous cap enhancement
  - OST: No enhancement

Nuclear Medicine Findings

- Bone scan
  - CD: Uptake if actively making bone
  - OCD: Varies
  - OST: Uptake during active growth phase, diminishing to background levels

Imaging Recommendations

- Best imaging tool
  - NECT + bone CT for most
  - MR C+ for imaging noncalcified cartilage, affects on soft tissues, evaluating for malignant transformation
- Protocol advice
  - CT: Axial and coronal thin sections at skull base
  - MR: Fat saturation to confirm fat content or to optimize imaging of scalp lesions

DIFFERENTIAL DIAGNOSIS

Benign Meningothelial Tumors

- Common meningioma
  - Characteristic MR appearance with dural tail

Malignant Meningothelial Tumors

- Atypical/malignant meningioma
  - Infiltrative, destructive lesion

Malignant Nonmeningothelial Tumors

- Osteosarcoma
  - Osteolytic + soft tissue mass & ill-defined margins
  - Tumoral calcification may be "sunburst"
- Primary meningeal sarcoma
  - Extremely rare nonmeningothelial tumor of meninges
- Many other sarcomas

PATHOLOGY

General Features

- Etiology
  - Meninges contain primitive multipotential mesenchymal cells
    - May give rise to spectrum of nonmeningothelial neoplasms
  - CD
    - From clivus/skull base cartilage synchondroses
    - Ectopic embryologic cartilage cell rests; perhaps perivascular mesenchymal tissue metaplasia
  - OCD
    - Most common radiation-associated benign tumor
    - Arise from fragment of growth plate; in skull most likely from congenital defect
  - OST: Uncertain; found in auditory canals of cold water swimmers → may be inflammatory reaction
- Associated abnormalities
  - Gardner syndrome: Multiple osteomas, skin tumors, colon polyps

https://CafePezeshki.IR

- Maffucci syndrome: Multiple enchondromas associated with soft tissue hemangiomas
- Multiple hereditary exostoses: Multiple OCD
- Ollier disease: Enchondromatosis

Staging, Grading, & Classification

- 2007 WHO classification
  - Tumors of meninges
    - Tumors of meningothelial cells
      - Meningioma (15 subtypes listed)
    - Mesenchymal tumors
      - 23 subtypes listed
      - Includes both benign **and** malignant nonmeningothelial mesenchymal tumors
    - Primary melanocytic lesions (4 subtypes listed)
    - Other neoplasms related to meninges: Only hemangioblastoma listed

Gross Pathologic & Surgical Features

- General comment: Skull vs. skull base ossification
  - Skull develops by intramembranous ossification → origin of membranous tumors (e.g., OST)
  - Clivus and skull base develop by endochondral ossification → origin for cartilaginous tumors (e.g., CD and OCD)
- CD
  - Benign osteocartilaginous tumor
  - "Enchondroma" if within bone or cartilage
  - Multiple tumors = chondromatosis or enchondromatosis
  - No stalk or peduncle as in OCD
  - Gross path: Cartilage and ossified cartilage
- OCD
  - Benign osteocartilaginous tumor
  - Cartilage-capped bony exostosis; sessile or pedunculated
  - Gross path: Irregular bony mass with cartilage cap ± calcification
- OST: Benign membranous tumor
  - Gross path: Appears as mature lamellar bone

Microscopic Features

- CD
  - Benign chondrocytes in scattered lacunae
  - Abundant hyaline cartilage matrix
  - May exhibit cellular atypia
  - Immunohistochemical staining positive for vimentin and S100 protein
- OCD: Cartilaginous cap over bony excrescence with cortex, trabeculae, marrow identical to normal bone
- OST: 2 types
  - Compact or "ivory": Made of mature lamellar bone; no Haversian canals or fibrous components
  - Trabecular: Composed of cancellous trabecular bone with marrow surrounded by cortical bone margin

CLINICAL ISSUES

Presentation

- Most common signs/symptoms
  - BMT are most often asymptomatic
  - OCD and OST: May present as "bony lump"
  - CD and OCD: May have cranial nerve deficit(s) if at clivus/skull base; very rarely seizure

Demographics

- Age
  - CD: Occur at any age, peak in 2nd to 4th decades
  - OCD: Mean age for multiple = 21 years, solitary = 30 years
  - OST: Highest incidence in 6th decade
- Gender
  - CD: M:F = 1-2:1
  - OCD: M:F = 1.5-2.5:1
  - OST: M:F = 1:3
- Epidemiology
  - BMT are rare to very rare
  - CD: Most common benign osteocartilaginous tumor of clivus/skull base; 0.1-1% of intracranial tumors
  - OCD
    - Most common benign skeletal tumor (8-9% of primary bone tumors, 36% of those benign)
    - Most common cartilaginous tumor (12% multiple)
  - OST: Most common primary calvarial tumors → 0.4% of population

Natural History & Prognosis

- CD: Malignant transformation is rare
- OCD: Malignant transformation rare
  - Sessile, large cartilage cap more likely to degenerate
  - Risk increases as number and size of OCD increases
  - Malignant transformation in osteochondromatosis 25-30% compared to ~ 1% for solitary
- OST
  - Slow-growing lesions normally asymptomatic
  - Secondary mucocele invading intracranial vault

Treatment

- Asymptomatic lesions require no treatment
- Surgical indications: Relief of symptoms, cosmesis
- Surgical goals: Complete excision, curettage if tumors cannot be resected completely

DIAGNOSTIC CHECKLIST

Consider

- Patient may be syndromic

SELECTED REFERENCES

1. Lee DH et al: Characteristics of paranasal sinus osteoma and treatment outcomes. Acta Otolaryngol. 1-6, 2015
2. Atalay FO et al: Intracranial extra-axial chondroma: a case report. J Nippon Med Sch. 81(1):35-9, 2014
3. Sanal HT et al: Bumps over cheeks. Skeletal Radiol. 43(2):233, 267-8, 2014
4. Wen G et al: Solitary fibrous tumor of the central nervous system: report of 2 cases and review of literature. Int J Clin Exp Pathol. 7(6):3444-8, 2014
5. Fountas KN et al: Intracranial falx chondroma: literature review and a case report. Clin Neurol Neurosurg. 110(1):8-13, 2008
6. Louis DN et al: The 2007 WHO classification of tumours of the central nervous system. Acta Neuropathol. 2007 Aug;114(2):97-109. Epub 2007 Jul 6. Review. Erratum in: Acta Neuropathol. 114(5):547, 2007

https://CafePezeshki.IR

(Left) *Coronal NECT demonstrates matrix calcification within a chondroma. There was no stalk connecting it to the parent bone.* **(Right)** *Axial T2WI MR shows primarily hypointensity from calcifications within the cartilaginous cap of an osteochondroma.*

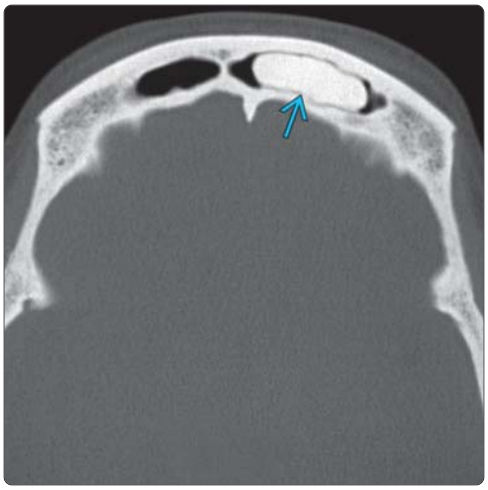

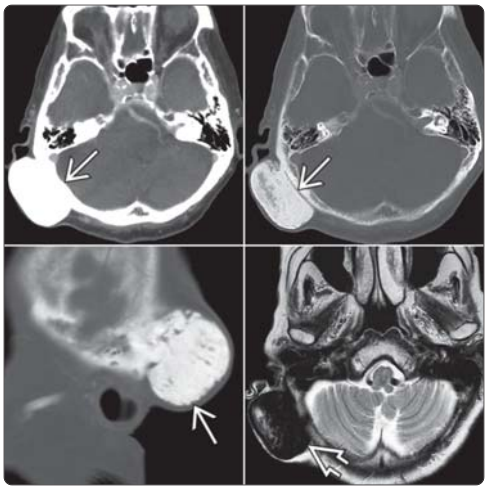

(Left) *Axial bone CT shows a typical osteoma of the left frontal sinus.* **(Right)** *Collage of imaging studies shows a classic osteoma arising from the occipital bone. Note very hypointense signal on T2WI. In the head, the paranasal sinuses and calvaria are the most common sites for these benign tumors.*

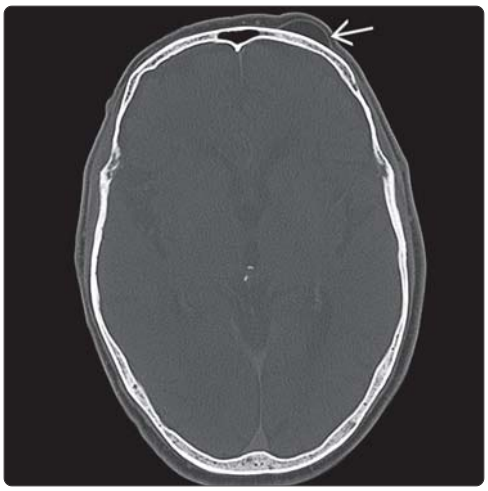

(Left) *Axial NECT in an 81-year-old man in the ER with altered mental status shows a very hypointense scalp lesion over the left frontal bone.* **(Right)** *Bone CT in the same case shows the lesion is the same density as the subcutaneous fat. Incidental scalp lipomas are not uncommon. Intracranial lipomas are generally considered malformative, not neoplastic, lesions.*

https://CafePezeshki.IR

KEY FACTS

TERMINOLOGY

- Nonmenigotheliomatous malignant mesenchymal neoplasms
  - Correspond histologically to extracranial tumors of soft tissue or bone
  - Most are sarcomas

IMAGING

- Highly aggressive dural, skull, skull base, scalp, lesions invading locally
- Amorphous, ill-defined, rapidly enlarging mass, often with both intra- and extraaxial components
- Best imaging tool: T1WI C+ FS MR; CT for matrix

TOP DIFFERENTIAL DIAGNOSES

- Benign meningothelial tumors
- Malignant meningothelial tumors
- Metastases

PATHOLOGY

- Accepted theory: Meninges contain primitive multipotential mesenchymal cells capable of giving rise to different histological types of nonmeningothelial neoplasms

CLINICAL ISSUES

- Prognosis of MMT patients is generally very poor
- Biopsy is crucial to establish histiologic diagnosis and guide treatment plan
- Primary treatment: Wide radical surgical extirpation
- XRT: Prevent local recurrence, ↓ risk of metastasis
- Chemotherapy, brachytherapy often considered

DIAGNOSTIC CHECKLIST

- No characteristic radiologic findings that distinguish from other neoplasms

(Left) *Axial T1WI C+ MR in a patient with chondrosarcoma shows a lobulated dural-based mass with intense enhancement* ➡ *and minimal reaction within the underlying brain parenchyma.* **(Right)** *Axial CECT demonstrates a very rare primary meningeal sarcoma as a strikingly infiltrative lesion with heterogeneous enhancement, skull destruction* ➡*, and scalp infiltration* ➡*.*

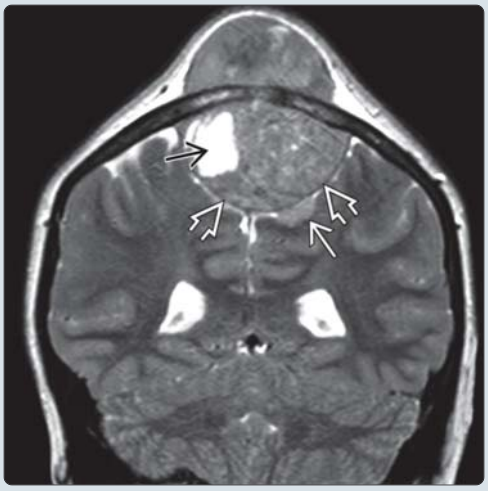

(Left) *Coronal T2WI MR in a patient with primary calvarial Ewing sarcoma shows a predominantly hypointense, extradural cellular mass with hyperintense cystic/necrotic components* ⇨*, appearing to arise from the calvaria. Note the displaced dura* ➡*, transdural extension* ➡*, and large subgaleal component.* **(Right)** *Coronal T1WI C+ MR in the same patient reveals strong but inhomogeneous enhancement, better demonstrating the transdural component* ➡*.*

https://CafePezeshki.IR

TERMINOLOGY

Abbreviations

- Malignant mesenchymal tumors (MMT)

Synonyms

- Malignant nonmeningothelial tumors

Definitions

- Nonmenigotheliomatous malignant mesenchymal neoplasms
  - Histologically correspond to extracranial tumors of soft tissue or bone
  - Most are sarcomas
    - Angiosarcoma (ANGIO), chondrosarcoma (CHON), fibrosarcoma (FIBRO)
    - Osteosarcoma (OSTEO), rhabdomyosarcoma (RHAB)
    - Meningeal sarcoma (MENSARC), Ewing sarcoma (EWING), etc.

IMAGING

General Features

- Best diagnostic clue
  - Highly aggressive dural, skull, skull base, scalp, lesions invading locally
- Morphology
  - Amorphous, ill-defined, rapidly enlarging mass, often with both intra- & extraaxial components

Radiographic Findings

- Radiography
  - Usually radiolucent lesions → ill-defined lytic borders, no periosteal reaction (except EWING)

CT Findings

- NECT
  - Usually radiolucent lesions → ill-defined lytic borders, no periosteal reaction (except EWING)
  - ANGIO: Reactive ossification, necrosis possible
  - CHON: May have stippled or rings & arcs Ca++
  - MENSARC: May be dense, biconvex, mimicking acute subdural hematoma
  - OSTEO: Calcified "sunburst" matrix possible
  - EWING: Often hyperdense (cellular)
- CECT
  - Most enhance
  - ANGIO: Very marked enhancement
  - EWING: Heterogeneous with periosteal reaction (but not "onion peel" for skull lesions)

MR Findings

- T1WI
  - Variably hypointense
  - Very hypointense (fibrous, chondroid, osteoid tissue)
  - Usually infiltrate brain
- T2WI
  - Most are predominantly hyperintense with heterogeneous signal and brain infiltration
  - May see extremely low signal from fibrous, chondroid, and osteoid tissue
  - EWING: Often hypointense (cellular)
- FLAIR
  - Best to evaluate edema, brain infiltration
- T1WI C+
  - Most enhance, often intensely
  - May have dural tail, necrotic foci
  - ANGIO: Very marked enhancement
  - CHON: May show "honeycomb" pattern
  - EWING: Heterogeneous with necrosis

Angiographic Findings

- DSA
  - Most have high degree of neovascularity
  - Others show avascular mass effect
- Interventional: Preoperative embolization to ↓ operative time and bleeding

Imaging Recommendations

- Best imaging tool
  - T1WI C+ FS MR; CT for matrix

DIFFERENTIAL DIAGNOSIS

Benign Meningothelial Tumors

- Common meningioma
  - Characteristic MR appearance
  - Not infiltrative

Malignant Meningothelial Tumors

- Atypical/malignant meningioma
  - Infiltrative, destructive lesion
  - Much more common than MMT

Metastases

- Often known extracranial malignancy
- Frequently multifocal
- Much more common than MMT

PATHOLOGY

General Features

- Etiology
  - Accepted theory: Meninges contain primitive multipotential mesenchymal cells capable of giving rise to different histological types of nonmeningothelial neoplasms
  - Exact cause is uncertain; 2 theories
    - Sarcomatous component may arise from mesenchymal elements of perivascular sheaths (fibroblasts, endothelium, smooth muscle, pericytes) or from arachnoid
    - Most likely from pluripotential meningeal mesenchymal cells
  - Radiation is known cause, most commonly FIBRO, with latency of 5-12 years
  - EWING: Uncertain histogenesis, belonging to family of neuroectodermal tumors
- Genetics
  - EWING: Cytogenetic translocation between chromosome 22 and 11 (80%)

Staging, Grading, & Classification

- 2007 WHO 4th edition classification
  - Tumors of meninges

https://CafePezeshki.IR

  - Tumors of meningothelial cells
    - Meningioma (15 subtypes listed)
  - Mesenchymal tumors (23 subtypes listed)
    - Includes both benign **and** malignant nonmeningothelial mesenchymal tumors
  - Primary melanocytic lesions (4 subtypes listed)
  - Other neoplasms related to meninges: Only hemangioblastoma listed

Gross Pathologic & Surgical Features

- CHON: Bluish-white glistening external surface of homogeneous tan cartilaginous tissue
- FIBRO: Pinkish, meaty
- MENSARC: Diffuse leptomeningeal involvement (10%) or large discrete lesions
- OSTEO: Soft tissue with hemorrhage, Ca++, necrosis

Microscopic Features

- Given lack of clinical/radiologic findings specific for MMT, diagnosis nearly always made by histopathology
- ANGIO
  - Irregular anastomosing vascular channels lined by anaplastic endothelial cells and pericytes
  - Cytokeratin, vimentin, ulex europaeus agglutinin, antihuman endothelial cell marker CD31(+)
- CHON
  - Undifferentiated mesenchymal cells, islands of hyaline cartilage, vimentin, & S100 protein positive
  - Scant material mainly of monomorphic small round cells with granular cytoplasm and central round nuclei in a background of myxoid matrix
  - Occasional giant cells; periodic acid-Schiff (-)
- FIBRO
  - Highly cellular with spindle-shaped cells in sheets or interlacing fascicles with herring-bone pattern
  - Cells contain elongated nuclei with mild hyperchromasia and high mitotic activity
  - Bone, osteoid, cartilage are absent
- MENSARC
  - Polymorphocellular sarcoma
- OSTEO
  - Single or multinucleated atypical polygonal cells in lacunae surrounded by immature osteoid
  - Osteoblastic, chondroblastic, & small-cell subtypes
- RHAB
  - Malignant undifferentiated tumor
    - Foci of muscular differentiation
  - Electron microscopy: Intracytoplasmic filamentous striations of poorly formed myofibrils
  - Positive for actin, desmin, myoglobin, vimentin
- EWING
  - Small round-cell tumor
  - High nuclear:cytoplasmic ratio

CLINICAL ISSUES

Presentation

- Most common signs/symptoms
  - Highly variable dependent on tumor location
  - Convexity: Most commonly hemiparesis, seizure
  - Skull base: Cranial nerve deficit(s)
  - Often rapidly growing mass with swelling
  - Headache, pain, fever, malaise, emesis

Demographics

- Age
  - More highly differentiated tumors appear in childhood whereas poorly differentiated in adults
  - ANGIO: Any age
  - CHON: 2nd and 3rd decade, mean: 37 years
  - FIBRO: Usually middle-aged adults
  - MENSARC: Children > adults
  - OSTEO: > 30 years; peak in 6th decade
  - RHAB: Children > > adults
  - EWING: 75% < 20 years; peak at 5-13 years
- Gender
  - Most have no sex predilection
  - FIBRO, MENSARC, and EWING: M > F
- Epidemiology
  - MMT: 0.5-2.7% of intracranial neoplasms
  - CHON: 0.15% of all intracranial tumors
  - MENSARC: 0.7–4.3% of pedi intracranial tumors
  - RHAB: < 1% of all intracranial tumors

Natural History & Prognosis

- Prognosis of MMT patients is generally very poor
  - CHON of dura & meninges have good prognosis; recurrence-free survival rate 65% after 5 years
  - EWING: Majority have good prognosis as can be fully or partially resected; 5-year survival (57.1%)
- Most have relentless tendency for local recurrence and metastases outside CNS
  - May recur years after diagnosis & initial treatment

Treatment

- Goal of treatment is to control disease locally
- Biopsy is crucial to establish histiologic diagnosis and guide treatment plan
- Primary treatment: Wide radical surgical extirpation
- Postoperative radiation therapy: Prevent local recurrence, ↓ risk of metastasis
- Chemotherapy, brachytherapy often considered

DIAGNOSTIC CHECKLIST

Image Interpretation Pearls

- No characteristic radiologic findings that distinguish MMT from other neoplasms

SELECTED REFERENCES

1. Koyama M et al: Radiation-induced osteosarcoma might mimic metastatic bone lesions: a case with bone scan and FDG PET/CT imaging. Clin Nucl Med. 40(5):427-9, 2015
2. Müller U et al: Is there a role for conventional MRI and MR diffusion-weighted imaging for distinction of skull base chordoma and chondrosarcoma? Acta Radiol. ePub, 2015
3. Hadley C et al: Osteosarcoma of the cranial vault and skull base in pediatric patients. J Neurosurg Pediatr. 13(4):380-7, 2014
4. Jing Z et al: The imaging features of meningeal Ewing sarcoma/peripheral primitive neuroectodermal tumours (pPNETs). Br J Radiol. 87(1041):20130631, 2014
5. Krishnamani K et al: Primary Ewing's sarcoma of the cranium: case series and review of literature. J Cancer Res Ther. 10(2):377-80, 2014

https://CafePezeshki.IR

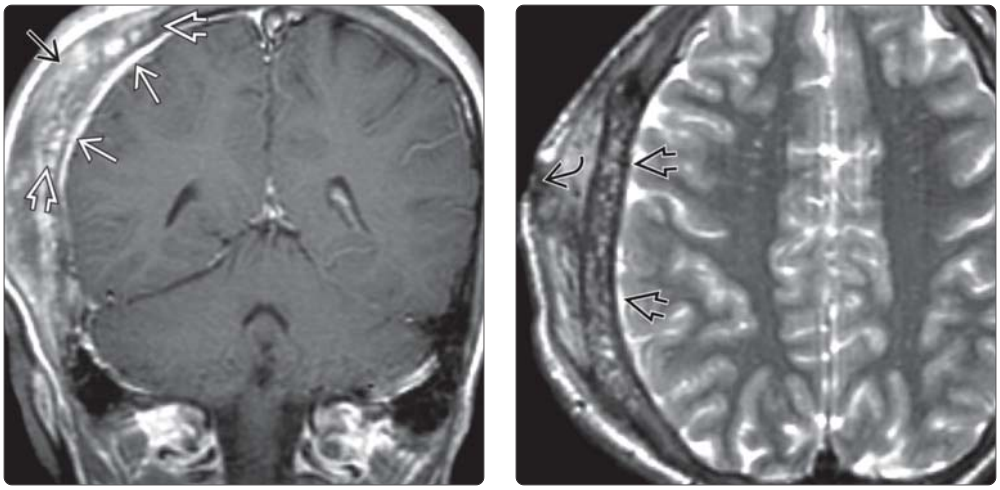

(Left) *Coronal T1WI C+ MR in a patient with primary calvarial Ewing sarcoma demonstrates striking scalp involvement ⇨, a mottled appearance of the expanded underlying calvaria ⇨, and thickening of the underlying dura ⇨.* **(Right)** *Axial T2WI MR in the same patient shows superficial ulceration, seen as disruption of the cutis ⇨. Note the expansion and mottled appearance of the underlying calvaria ⇨.*

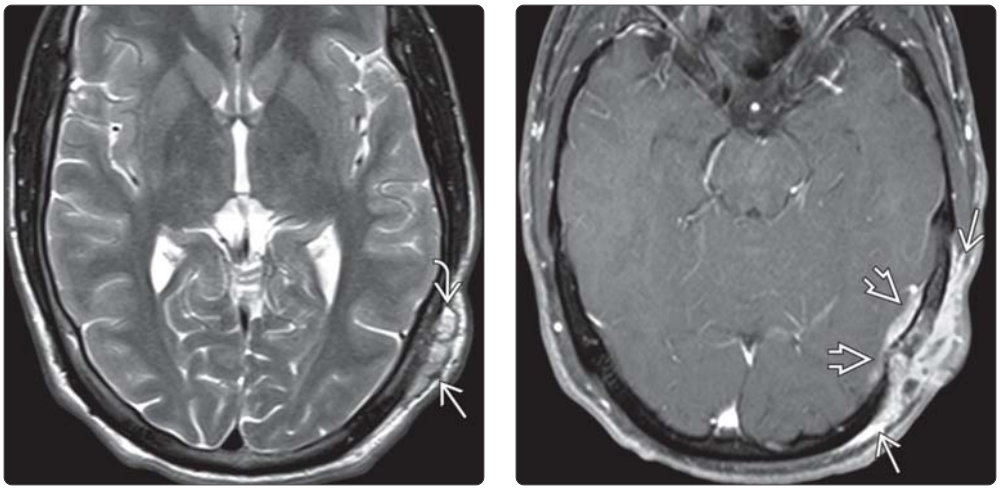

(Left) *Axial T2WI MR demonstrates a left parietal scalp mass ⇨ infiltrating the underlying skull and containing a blood-fluid level ⇨. Histology revealed a high-grade chondroblastic osteosarcoma (WHO III).* **(Right)** *Axial T1WI C+ FS MR in the same patient shows the true extent of the mass ⇨ and more clearly delineates intracranial extension with calvarial penetration and dural infiltration ⇨.*

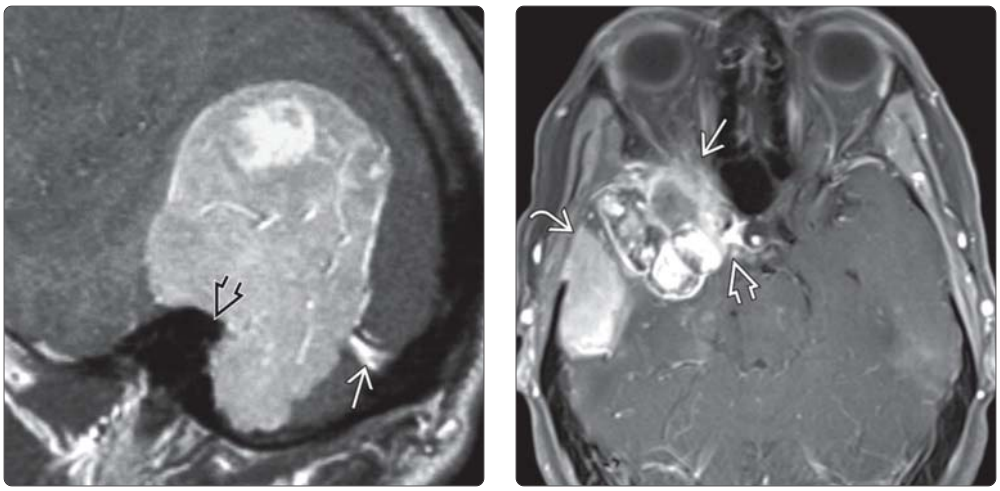

(Left) *Sagittal T1WI C+ MR shows a fibrosarcoma arising from the petrous apex ⇨ and occluding the transverse sinus ⇨.* **(Right)** *Axial T1WI C+ FS MR shows an aggressive inhomogeneously enhancing mass invading the orbit ⇨ and cavernous sinus ⇨, extending through a craniotomy defect into the scalp ⇨. Histology confirmed chondrosarcoma & osteosarcoma intermixed with atypical meningotheliomatous meningioma, arising as a complication from radiation therapy of a previously resected meningioma.*

https://CafePezeshki.IR

KEY FACTS

TERMINOLOGY

- Benign intraosseous skull lesion with predominantly vascular and some avascular components

IMAGING

- Best clue: Sharply marginated expansile skull lesion
- Frontal, temporal, parietal bone in decreasing order
- Most often solitary, but multiple in 15%
- Best imaging tool: Bone CT
  - Sharply marginated expansile lesion
  - Thin peripheral sclerotic rim in 1/3
  - Intact inner and outer table
  - Outer table often more expanded than inner table
  - Trabecular thickening with radiating spicules
- MR signal characteristics dependent on
  - Quantity of slow-moving venous blood
  - Ratio of red marrow to converted fatty marrow
  - Hypointense trabeculae
- T1WI
  - Hypo- to isointense
- T2WI
  - Usually heterogeneously hyperintense ("light bulb bright")
- T1 C+
  - Enhances diffusely and heterogeneously
  - "Fills in" with delayed imaging
  - May have dural tail

PATHOLOGY

- Classified on basis of dominant vessels: Capillary, cavernous, or mixed

CLINICAL ISSUES

- Most often asymptomatic
- Calvarial hemangiomas rare: 0.2% of bone tumors
- Rarely requires treatment

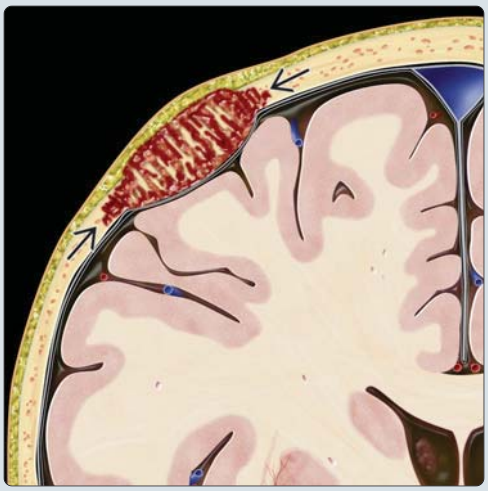

(Left) *Coronal graphic illustrates a sharply marginated expansile skull lesion with a slight honeycomb-appearing pattern from intradiploic trabecular thickening.* **(Right)** *Coronal T1WI C+ MR shows diffuse yet heterogeneous enhancement of an expansile calvarial hemangioma. Heterogeneity is a result of vascular enhancement combined with hypointense bony trabeculae.*

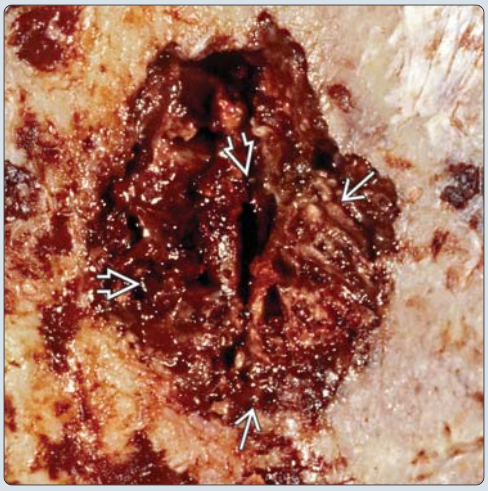

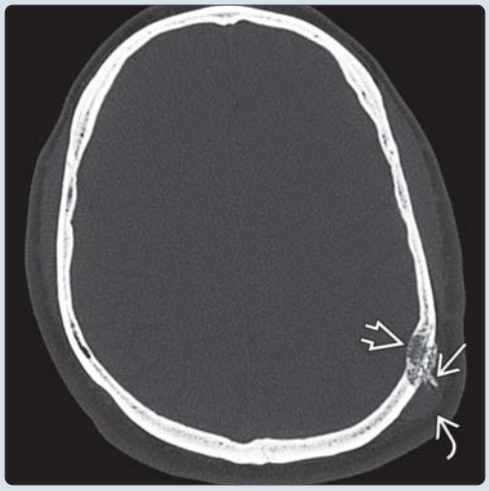

(Left) *Image shows a close-up view of resected calvarial hemangioma. Note the radiating spicules of lamellar bone interspersed with vascular channels of varying sizes.* **(Right)** *Axial bone CT shows a scalp mass with the spiculated bone of an underlying calvarial hemangioma.*

https://CafePezeshki.IR

TERMINOLOGY

Synonyms

- Osseous hemangioma, intraosseous hemangioma

Definitions

- Benign intraosseous skull lesion with predominantly vascular and some avascular components

IMAGING

General Features

- Best diagnostic clue
  - Sharply marginated expansile skull lesion
- Location
  - Skull: 20% of intraosseous hemangiomas
    - Diploic space
    - Frontal, temporal, parietal in decreasing order
    - Less commonly occipital or sphenoid
  - Vertebra: 28% of intraosseous hemangiomas
- Size
  - 1-4 cm
- Morphology
  - Solitary but multiple in 15%; round or oval

Radiographic Findings

- Radiography
  - Sharply marginated expansile lesion
  - May have thin peripheral sclerotic rim
  - "Honeycomb" or "sunburst" pattern

CT Findings

- CECT
  - Enhances
- Bone CT
  - Sharply marginated expansile lesion
    - Thin peripheral sclerotic rim in 1/3
  - Intact inner and outer table
    - Outer table often more expanded than inner table
      - Erosion of both tables unusual (3%)
    - Scalloped nonsclerotic margins
  - "Spoke-wheel," "reticulated," or web-like pattern
    - Intradiploic trabecular thickening with radiating spicules
  - Also "soap bubble" or "honeycomb" appearance

MR Findings

- T1WI
  - Hypo- to isointense
    - Small lesions may appear hyperintense: Fatty tissue is main cause of T1WI hyperintensity
    - Larger lesions typically hypointense secondary to presence of thickened trabeculae
  - May be hemorrhagic
    - Signal dependent on hemoglobin stage
- T2WI
  - Usually heterogeneously hyperintense ("light bulb bright")
    - Slow flow or venous stasis is main cause of T2WI hyperintensity
    - May see hypointense spicules
  - May be hemorrhagic
    - Signal dependent on hemoglobin stage
- T1WI C+
  - Enhances diffusely and heterogeneously
    - "Fills in" with delayed imaging
- MR signal characteristics dependent on
  - Quantity of slow-moving venous blood
  - Ratio of red marrow to converted fatty marrow
  - Hypointense trabeculae

Nuclear Medicine Findings

- Bone scan
  - From photopenia to moderate increased activity

Imaging Recommendations

- Best imaging tool
  - Bone CT defines trabecular and cortical detail
- Protocol advice
  - MR C+ to characterize interstices

DIFFERENTIAL DIAGNOSIS

"Holes in Skull," Solitary (Common)

- Normal anatomic variant: Fissure, foramen, canal, emissary venous channel, pacchionian (arachnoid) granulation, parietal thinning
  - CT reveals normal anatomy
- Surgical: Burr holes, shunt, surgical defect
  - Surgical history
- Trauma, fracture
  - Fracture confirmed on CT
- Dermoid
  - Well-circumscribed unilocular cyst containing fat
- Eosinophilic granuloma
  - < 5 years; "beveled edge," "hole-within-a-hole," "button sequestrum"
  - Involves inner/outer tables
- Metastases
  - Older patients, often history of cancer
- Low-grade hemangioendothelioma
  - Can be indistinguishable

"Holes in Skull," Solitary (Uncommon)

- Osteoporosis circumscripta
  - Hypointense on T1WI and T2WI from cortical thickening, coarse trabeculation
- Epidermoid
  - Nonenhancing lesion with dense sclerotic borders
- Cephalocele
  - Very young; bony defect with tissue herniation
- Intradiploic arachnoid cyst
  - CSF isointensity on both T1WI and T2WI
- Intradiploic meningioma
  - Homogeneously enhances
  - May have inner/outer table destruction
- Leptomeningeal cyst
  - Appears as "growing fracture" on radiography/NECT
- Malignant mesenchymal tumors, miscellaneous
  - Very rare, large, highly aggressive tumors

https://CafePezeshki.IR

"Holes in Skull," Multiple (Common)

- Normal anatomic variants: Fissure, foramen, canal, emissary venous channel, pacchionian (arachnoid) granulation, parietal thinning
  - CT reveals normal anatomy
- Surgical
  - Burr holes, surgical defects
- Metastases
  - Older patients, often history of cancer
- Lymphoma
  - History of systemic lymphoma
- Osteoporosis
  - Older; osteopenia, trabecular loss, cortical thinning

"Holes in Skull," Multiple (Uncommon)

- Hyperparathyroidism
  - "Salt and pepper" skull
- Myeloma
  - Multiple, well-circumscribed, lytic, "punched-out"
  - Involves both inner and outer tables
- Osteomyelitis
  - 2-12 years; M:F = 3:1; mixed lytic/proliferative lesion
  - Characteristically "moth-eaten"/permeative medullary and cortical destruction with new bone formation

PATHOLOGY

General Features

- Etiology
  - Congenital or related to previous trauma
- Genetics
  - Nearly all sporadic
  - In rare congenital hemangiomatosis, skull, vertebra, muscle, skin, and subcutaneous tissues may all be involved

Staging, Grading, & Classification

- Classified on basis of dominant vessels: Capillary, cavernous, or mixed

Gross Pathologic & Surgical Features

- Brownish-red, nonencapsulated, under periosteum

Microscopic Features

- 3 histopathologic types
  - Capillary (classically in spine)
    - Abundant vessels ~ 10-100 μm in diameter with walls 1-3 cells thick
    - Vessels tend to run in parallel
  - Cavernous (classically in skull)
    - Large, dilated sinusoidal vessels separated by fibrous septi
    - Single layer of endothelial cells
    - Intravascular thrombosis with dystrophic calcification may be seen
  - Mixed capillary/cavernous
- There may be reactive new bone formation, which can appear similar to osteoblastoma
- Radiating, web-like, or "spoke-wheel" trabecular thickening caused by intramembranous bone formation adjacent to angiomatous channels

CLINICAL ISSUES

Presentation

- Most common signs/symptoms
  - Asymptomatic
  - Other signs/symptoms
    - Longstanding palpable lump, tender to pressure, spontaneous pain, deformity
    - Rarely epidural, subdural, or subarachnoid hemorrhage
- Clinical profile
  - Freely mobile skin above lump

Demographics

- Age
  - Usually adults: 4th-5th decades
  - Any age can be affected
- Gender
  - M:F = 1:2-4
- Epidemiology
  - Osseous hemangiomas: 0.7-1% of bone tumors
    - Calvarial hemangiomas (rare): 0.2% of bone tumors
  - 10% benign primary neoplasms of skull

Natural History & Prognosis

- Benign slow-growing neoplasms
- Increase in size may be due to repeated hemorrhage

Treatment

- Rarely requires treatment
- Indications for surgery include correction of mass effect, control of hemorrhage, cosmesis
  - En bloc surgical excision with rim of normal bone
  - Usually definitive treatment; recurrence is rare
- Radiotherapy may be considered when surgical access is difficult or as complement to subtotal resections
  - Complications may include scar formation, impairment of regional bone growth in children, rarely malignant transformation

DIAGNOSTIC CHECKLIST

Consider

- Hemangiomas are just 1 of large "holes in skull" diagnosis that require exclusion of others
- **Beware**: Routine bone biopsy and curettage may result in severe hemorrhage
  - Prior imaging diagnosis can prevent complications

Image Interpretation Pearls

- Intact inner/outer tables, thickened trabeculae, best aid in diagnosis

SELECTED REFERENCES

1. Demir MK et al: Rare and challenging extra-axial brain lesions: CT and MRI findings with clinico-radiological differential diagnosis and pathological correlation. Diagn Interv Radiol. 20(5):448-52, 2014
2. AlMakadma Y et al: Diffuse calvarial cavernoma: case report and review of the literature. Childs Nerv Syst. 29(6):1047-9, 2013
3. Hong B et al: Surgical resection of osteolytic calvarial lesions: clinicopathological features. Clin Neurol Neurosurg. 112(10):865-9, 2010

https://CafePezeshki.IR

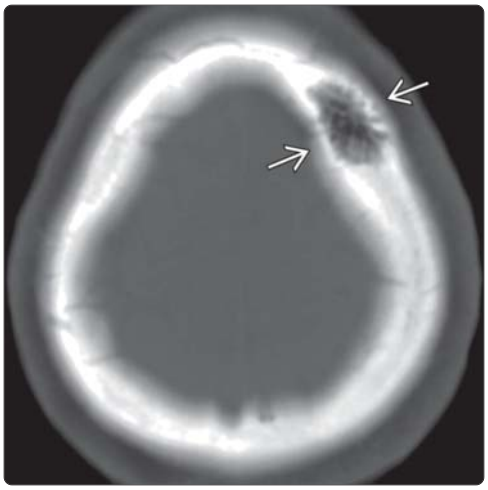

(Left) *Axial bone CT demonstrates the benign appearance of a hemangioma as a sharply marginated expansile lesion with scalloped margins, a "honeycomb" or web-like pattern from thickened trabeculae, as well as intact inner and outer tables* ➡. **(Right)** *Axial T2WI MR in the same patient demonstrates hyperintense components, mainly the result of slow flow or venous stasis with a contribution from fat* ➡. *Note the "honeycomb" or web-like hypointensities from thickened trabeculae.*

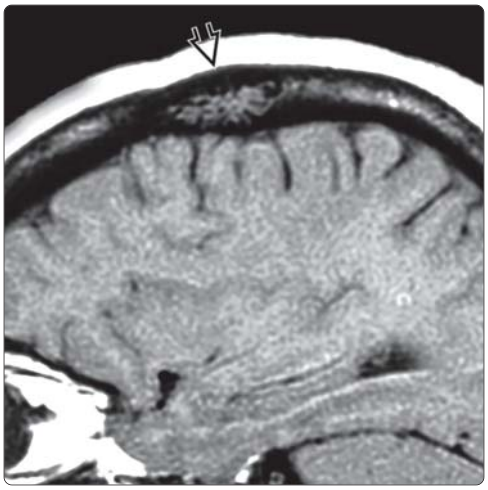

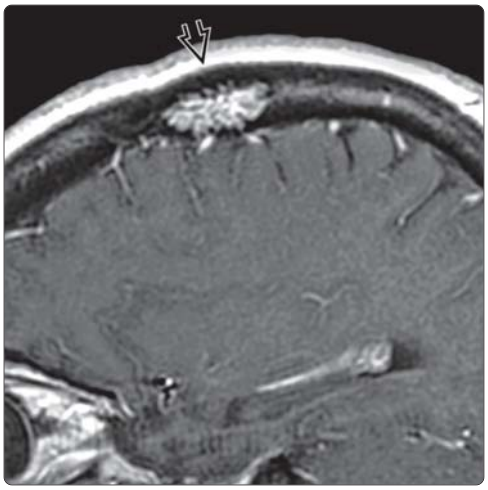

(Left) *Sagittal T1WI MR in the same patient shows the hemangioma as a mostly isointense lesion* ⇨, *which is less bright than the overlying fatty scalp.* **(Right)** *Sagittal T1WI C+ MR in the same patient demonstrates diffuse yet heterogeneous enhancement* ⇨, *the latter a result of intense vascular enhancement combined with hypointense bony trabeculae.*

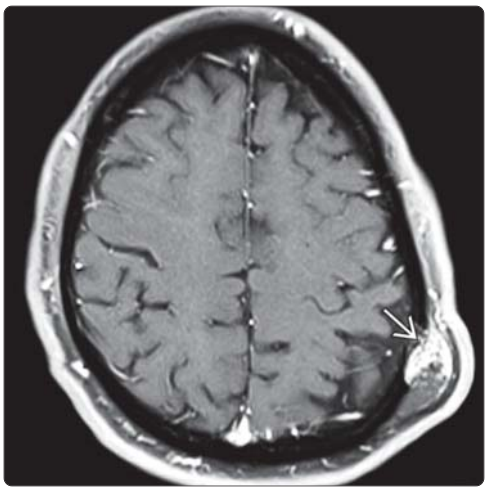

(Left) *Axial T1WI MR in a 47-year-old man with a scalp "lump" for 10 years shows a calvarial mass that scallops the adjacent calvaria* ➡ *and has broken through the outer table to extend under the galea* ➡. *The mass was very hyperintense on T2WI (not shown).* **(Right)** *Early post-contrast scan in the same patient shows partial "filling in"* ➡ *of the intensely enhancing mass characteristic of hemangioma. Slightly delayed scan (not shown) demonstrated complete enhancement of the lesion.*

https://CafePezeshki.IR

KEY FACTS

TERMINOLOGY

- Benign nonmeningothelial mesenchymal neoplasm
  - Typically presents as extraaxial vascular mass of dura &/or venous sinus

IMAGING

- Best diagnostic clue: Marked T2 hyperintensity; delayed "filling in" with dynamic T1WI C+
- Location: Cavernous sinus, CPA, other dura
- Bone CT: Erosion or remodeling, not hyperostosis
- T1 C+: May be heterogeneous with slow centripetal "filling in" (analogous to liver hemangiomas)
- Best imaging tool: Dynamic T1WI C+ MR

TOP DIFFERENTIAL DIAGNOSES

- Cavernous sinus: Meningioma, nerve sheath tumor, granuloma
- CPA: Schwannoma, meningioma, epidermoid
- Dural based: Meningioma, metastases, granuloma, mesenchymal tumor

CLINICAL ISSUES

- Grows very slowly; no malignant degeneration
- Dural-based treatment: Surgical resection, avoided unless tumor growth demonstrated
- Cavernous sinus treatment much more difficult
  - Complete resection difficult due to location, bleeding, and relationship to vital neurovascular structures
  - Complete resection rates as low as 16%; overall surgical mortality up to 25%
  - Preoperative radiation therapy has been used to reduce hemorrhage with doses up to 30 Gy
  - γ knife radiosurgery may be effective, safe alternative treatment

DIAGNOSTIC CHECKLIST

- Frequently misdiagnosed as meningioma on imaging
- Dynamic T1 C+ may show "edge to center" enhancement

(Left) *Axial NECT shows the left middle cranial fossa is expanded, and the overlying calvaria is thinned by a well-demarcated, slightly hyperdense mass ➡. The mass almost completely fills the middle fossa, extending into the posterior fossa ➡ and the sella/cavernous sinus ➡.* **(Right)** *Bone CT in the same case shows the expanded left middle fossa and extensively thinned overlying calvaria ➡. The bony sella turcica also appears remodeled ➡.*

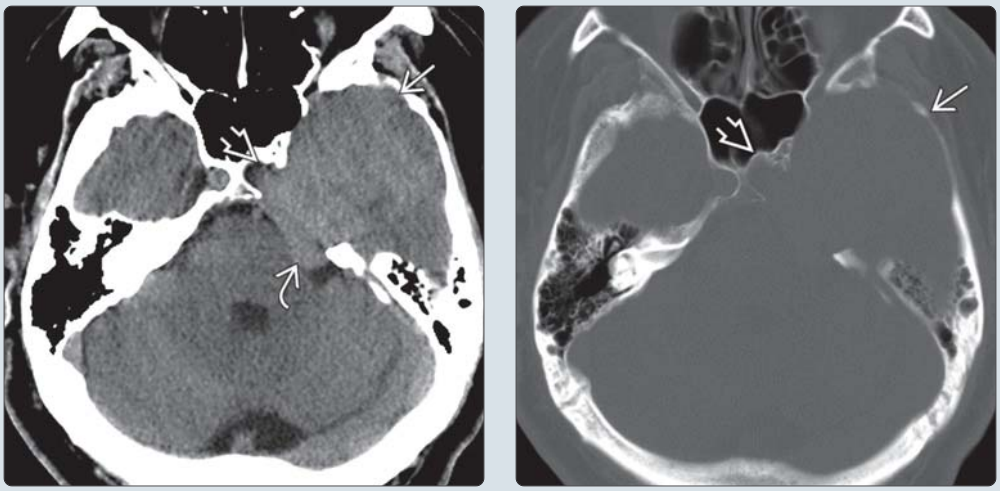

(Left) *Axial T2WI MR in same case shows the mass ➡ is markedly hyperintense, almost completely filling the left middle fossa and extending into the sella/cavernous sinus ➡.* **(Right)** *Axial T1 C+ FS MR in the same case shows the mass enhances strongly and uniformly after contrast administration ➡. Hemangioma of the cavernous sinus was found at surgery. Hemangioma should be included in the differential diagnosis of strongly enhancing cavernous sinus masses that appear to be completely extradural.*

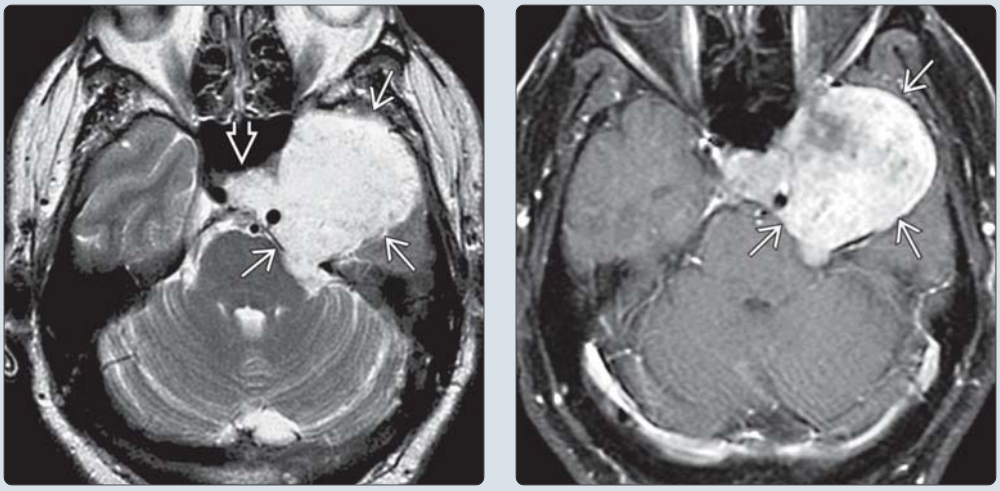

https://CafePezeshki.IR

TERMINOLOGY

Definitions

- Benign, nonmeningothelial mesenchymal neoplasm
  - Typically presents as extraaxial vascular mass of dura &/or venous sinus

IMAGING

General Features

- Best diagnostic clue
  - Marked T2 hyperintensity
  - Delayed "filling in" on dynamic contrast-enhanced MR
- Location
  - Cavernous sinus, CPA, other dura

CT Findings

- NECT: Iso- to hyperdense mass
- CECT: Marked homogeneous enhancement
- Bone CT: Erosion or remodeling, not hyperostosis

MR Findings

- T1WI
  - Hypo- to isointense
- T2WI
  - Marked hyperintensity
- T1WI C+
  - Dynamic may show "edge to center" enhancement
  - Homogeneous enhancement if delayed
- MRV
  - Assess sinus &/or flow involvement

Angiographic Findings

- Variable: Avascular to staining with feeder arteries
- Consider preoperative embolization to decrease intraoperative blood loss

Nuclear Medicine Findings

- Tc-99m labeled red cell scintigraphy
  - Slow progressive accumulation
  - Persistent increased activity on delayed images

Imaging Recommendations

- Best imaging tool
  - Dynamic T1WI C+ MR for centripetal "filling in"

DIFFERENTIAL DIAGNOSIS

Cavernous Sinus

- Meningioma, nerve sheath tumor, granuloma

CPA

- Schwannoma, meningioma, epidermoid

Dural Based

- Meningioma, mets, granuloma, mesenchymal tumor

PATHOLOGY

Staging, Grading, & Classification

- WHO grade I

Gross Pathologic & Surgical Features

- Soft mass often with pseudocapsule formed by dura

Microscopic Features

- Honeycomb of multiple, thin-walled vascular channels
- Single endothelial cell layer with no elastic membrane or smooth muscle cells
- Contiguous walls of collagen & flattened endothelium
- Vascular channels separated by fibroconnective stroma

CLINICAL ISSUES

Presentation

- Most common signs/symptoms
  - Headaches, retroorbital pain
- Other signs/symptoms
  - Cranial neuropathies, anisocoria, proptosis
  - Intracranial hypertension if sinus flow involved
  - Kasabach-Merritt syndrome (consumptive coagulopathy)
  - May occur as part of POEMS syndrome
  - Symptoms may appear or worsen during pregnancy or after hormone administration

Demographics

- Age
  - Cavernous sinus: Mean is 44 (range: 22–64)
- Gender
  - Cavernous sinus: M:F = 1:7
- Epidemiology
  - Lesions very rare

Natural History & Prognosis

- Grows very slowly; no malignant degeneration

Treatment

- Dural based: Surgical resection, avoided unless tumor growth demonstrated
- Cavernous sinus much more difficult
  - Complete resection difficult due to location, bleeding, & relationship to neurovascular structures
  - Major intraoperative bleeding in 42%; massive or severe in 75% of these
  - Complete resection rates as low as 16%; overall surgical mortality up to 25%
  - γ knife radiosurgery may be effective, safe alternative treatment

DIAGNOSTIC CHECKLIST

Image Interpretation Pearls

- Frequently misdiagnosed as meningioma on imaging
  - Dynamic may show "edge to center" enhancement

SELECTED REFERENCES

1. Anqi X et al: Cavernous sinus cavernous hemangioma: imaging features and therapeutic effect of Gamma Knife radiosurgery. Clin Neurol Neurosurg. 127:59-64, 2014
2. He K et al: Magnetic resonance standard for cavernous sinus hemangiomas: proposal for a diagnostic test. Eur Neurol. 72(1-2):116-24, 2014
3. Song SW et al: Stereotactic radiosurgery for cavernous sinus hemangiomas. J Neurooncol. 118(1):163-8, 2014
4. Hasiloglu ZI et al: Cavernous hemangioma of the cavernous sinus misdiagnosed as a meningioma: a case report and MR imaging findings. Clin Imaging. 37(4):744-6, 2013
5. Yin YH et al: Surgical management of large and giant cavernous sinus hemangiomas. J Clin Neurosci. 20(1):128-33, 2013

https://CafePezeshki.IR

KEY FACTS

TERMINOLOGY

- Clonal B-lymphocyte neoplasm of terminally differentiated plasma cells
  - Solitary = plasmacytoma (PC)
    - Brain/CNS is extramedullary plasmacytoma
  - Multifocal = multiple myeloma (MM)

IMAGING

- Intracranial MM rare (1% of MM)
- Can occur as solitary (primary) plasmacytoma or manifestation of systemic MM (secondary)
  - **Secondary**
    - Extension from osteolytic skull lesion > hematogenous spread
  - **Primary** CNS myeloma rare
    - Extraaxial dural-based nonosseous lesions
    - CNS "myelomatosis" involving leptomeninges &/or cranial nerves
    - Parenchymal masses (discrete nodules)
- Best overall imaging tool: Radiography (skeletal survey)
  - Detects 80% of sites in 90% of patients
  - Up to 20% of radiographs & MR may be "normal"
- CNS disease
  - Bone CT for calvaria, skull base
  - MR ± T1 C+ FS for nonosseous intracranial lesions

TOP DIFFERENTIAL DIAGNOSES

- Surgical defect
- Lytic metastasis
- Hemangioma
- Hyperparathyroidism

CLINICAL ISSUES

- Peak onset = 65-70 years
  - Most common symptom: Bone pain (68%)
- Prognosis
  - 70% of plasmacytomas progress to MM

(Left) *Sagittal graphic depicts the multiple "punched-out" lesions ⇨ of multiple myeloma in the calvaria.* **(Right)** *Lateral digital radiograph in a patient with multiple myeloma shows the classic "salt and pepper" appearance of the skull caused by innumerable "punched-out" lesions ⇨.*

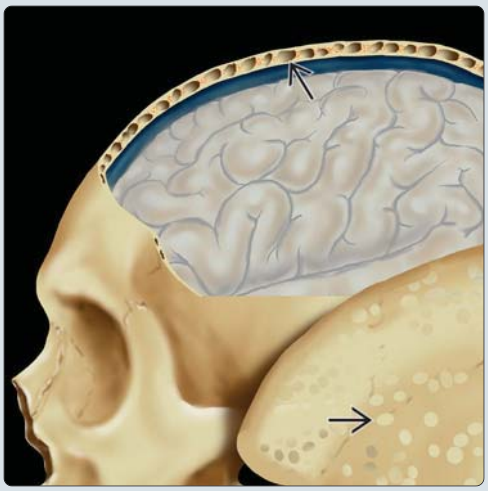

(Left) *Axial NECT in a 50-year-old man with altered mental status, "possible TIA," shows no abnormalities.* **(Right)** *Axial bone CT with bone algorithm reconstruction in the same patient shows innumerable well-defined lytic lesions ⇨ in the calvaria. Further evaluation disclosed metastatic multiple myeloma.*

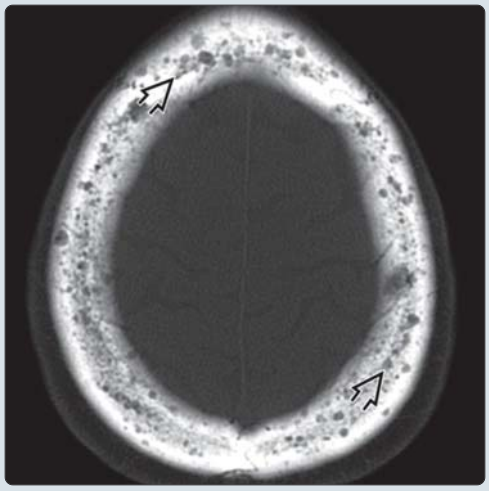

https://CafePezeshki.IR

TERMINOLOGY

Abbreviations

- Solitary = plasmacytoma (PC)
  - Solitary plasmacytoma of bone
  - Extramedullary plasmacytoma (includes brain/CNS)
- Multifocal = multiple myeloma (MM)

Definitions

- Clonal B-lymphocyte neoplasm of terminally differentiated plasma cells

IMAGING

General Features

- Best diagnostic clue
  - Osteolytic skull lesion
- Location
  - Intracranial MM rare (1% 0f MM)
    - Can occur as solitary (primary) plasmacytoma or manifestation of systemic MM (secondary)
      - In Waldenström macroglobulinemia (a.k.a. Bing-Neel syndrome)
      - Often widely disseminated at time of diagnosis
    - **Secondary** (extension from osseous lesions in calvaria, skull base, nose/paranasal sinuses > hematogenous spread) most common
    - **Primary** CNS myeloma rare
      - Extraaxial dural-based nonosseous lesions
      - CNS "myelomatosis" involving leptomeninges &/or cranial nerves
      - Parenchymal masses (discrete nodules)
- Morphology
  - Focal, round or oval lesion(s)

Radiographic Findings

- Radiography
  - "Punched-out" lytic lesion(s) (90%)
  - Osteopenia/osteoporosis (10%)
  - Rarely sclerotic, except following therapy

CT Findings

- NECT
  - "Punched-out" lytic lesion(s)
  - Meningeal myelomatosis: Marked hyperdensity
- CECT
  - MM renal failure (RF) after contrast (0.6-1.25%)
    - 0.15% in general population
    - Thus, not 100% risk-free but may be performed if necessary and patient well hydrated
  - Meningeal myelomatosis: Uniform enhancement

MR Findings

- T1WI
  - Osseous lesions: Focal hypointensity (25%)
    - Diffuse marrow infiltration less common
  - Meningeal myelomatosis: Iso- to hyperintense
- T2WI
  - Osseous: Focal hyperintensity (53%)
  - Meningeal myelomatosis: Markedly hypointense
- T1WI C+
  - Marked lesional enhancement
  - Meningeal myelomatosis: Uniform enhancement, diffuse or focal

Nuclear Medicine Findings

- Bone scan
  - Scintigraphy insensitive
- PET
  - 18-fluorodeoxyglucose (FDG) > bone scan
  - Conflicting reports of FDG PET vs. radiography
  - Residual or recurrent FDG activity after therapy is poor prognostic factor

Other Modality Findings

- Sensitivity of imaging detection for diagnosis
  - Radiography detects 90% of patients, 80% of sites
  - Bone scan detects 74% of patients, 24-54% of sites
  - Gallium scan detects 55% of patients, 40% of sites
- Up to 20% radiographs and MR may be "normal"
- MR → about 10% understaging of stage III disease
- Whole-body MDCT = lower detection rate and staging compared to whole-body MR

Imaging Recommendations

- Best imaging tool
  - Radiography (skeletal survey)
  - Bone CT > MR for evaluation of skull lesions
  - MR best for delineating dural, leptomeningeal, parenchymal disease

DIFFERENTIAL DIAGNOSIS

Surgical Defects

- Burr hole, shunt, postoperative defect

Lytic Metastasis

- Commonly lung, breast, renal, thyroid

Hemangioma

- Sharply marginated expansile lesion often with "honeycomb" or "sunburst" appearance

Hyperparathyroidism

- Local destructive lesions ("brown tumor"), ↑ PTH

Other Causes of "Holes in Skull"

- Normal foramina, fissures, venous lakes

PATHOLOGY

General Features

- Etiology
  - Etiology remains unknown
  - Possible associations and supporting evidence
    - Immune system decline: More common in elderly
    - Genetic factors: Slight ↑ risk among children and siblings of MM patients; also definite ↑ racial risk
    - Certain occupations/chemicals: Agriculture, petroleum, leather industry, cosmetology, herbicides, insecticides, petroleum products, heavy metals, plastics, dusts (including asbestos)
    - Radiation: ↑ in Japanese atomic bomb survivors
    - Viral: Kaposi sarcoma-associated herpes virus found in marrow cells of some MM patients
- Genetics

https://CafePezeshki.IR

- 80-90% of patients have cytogenetic abnormalities
  - Chromosome 13 deletion is most common
- Associated abnormalities
  - "POEMS" syndrome: **P**olyneuropathy, **o**rganomegaly, **e**ndocrine abnormalities, **m**yeloma (usually sclerotic lesions), **s**kin changes
  - PC = early/initial MM stage; precedes by 1-20 years
  - Underlying pathology is single plasma cell lineage expansion that replaces normal marrow and produces monoclonal immunoglobulins

Staging, Grading, & Classification

- Durie-Salmon staging system
  - Stage I: All of following
    - Hemoglobin value < 10 g/dL
    - Serum calcium value normal or ≤ 12 mg/dL
    - No anemia, hypercalcemia, bone lesions
    - Low M-component: IgG value < 5 g/dL, IgA value < 3 g/dL, Bence Jones protein < 4 g/24 hours
    - Low myeloma cell mass: < 0.6 cells x 10^{12}/m2
  - Stage II: Fitting neither stage I nor stage III
    - Intermediate cell mass: 0.6-1.2 cells x 10^{12}/m2
  - Stage III: 1 or more of following
    - Hemoglobin value < 8.5 g/dL
    - Serum calcium value > 12 mg/dL
    - Advanced lytic bone lesions
    - IgG value > 7 g/dL, IgA value > 5 g/dL, Bence Jones protein > 12 g/24 hours
    - High myeloma cell mass: > 1.2 cells x 10^{12}/m2
  - Subclassification (either A or B)
    - A = relatively normal renal function
    - B = abnormal renal function

Gross Pathologic & Surgical Features

- Marrow replacement with gelatinous red-brown tissue

Microscopic Features

- Pleomorphic, enlarged plasma cells, often in sheets
  - Admixed with normal hematopoietic cells
  - Contain round/oval eccentric nuclei with clumped chromatin and perinuclear "halo" or pale zone
  - May have cytoplasmic inclusions: Mott, morula, or grape cells; Russell bodies
  - Cell clone produces excess monoclonal (M proteins) and free light-chain proteins
    - M proteins may be IgA, IgD, IgG, IgE or, IgM; depends on heavy chain class
    - Light-chain proteins may be κ or λ

CLINICAL ISSUES

Presentation

- Most common signs/symptoms
  - Most common symptom: Bone pain (68%)
  - Rare signs
    - Hyperviscosity syndrome: Shortness of breath, confusion, and chest pain
    - Cryoglobulinemia: Precipitating particles cause pain/numbness in fingers/toes during cold weather
    - Amyloidosis: Amyloid protein deposition, ↓ blood pressure, and kidney, heart, or liver failure
    - Bing-Neel syndrome: CNS involvement by lymphoplasmacytic lymphoma
- Clinical profile
  - Diagnosis often made with routine labs
  - Diagnosis confirmed by marrow aspirate/biopsy

Demographics

- Age
  - Peak onset: 65-70 years
  - Recent statistics: ↑ incidence and earlier age of onset
- Gender
  - Slight male predilection
- Ethnicity
  - African Americans and Native Pacific islanders have highest reported incidence; Asians lowest
- Epidemiology
  - 2nd most prevalent blood cancer (1st = NHL)
  - Incidence: ↑ with age
  - 1st primary bone malignancy in 4th-8th decades
    - Solitary PC without MM rare; solitary skull PC very rare (0.7% of all PC)

Natural History & Prognosis

- Solitary skull PC: No difference in prognosis between PC originating from bone vs. dura mater
- Multiple myeloma
  - 70% of plasmacytomas progress to MM
  - Renal insufficiency frequent
  - Leukopenia leads to frequent pneumonias
  - Secondary amyloidosis (6-15%)
- 5-year survival (20%); death not from MM, but renal disease, infection, thromboembolism
  - Median survival is ~ 3 years with conventional chemotherapy
- Good prognosis indicators
  - Stage I or II disease
  - Normal chromosome 13
    - Abnormal cytogenetics is most important factor
    - Chromosome 13 or 11q deletions, or any translocation, predict poor prognosis
- Biphosphonate treatment related osteonecrosis of mandible

Treatment

- Treatment dependent on disease status

DIAGNOSTIC CHECKLIST

Image Interpretation Pearls

- "Old-fashioned" skeletal survey still highest sensitivity imaging modality

SELECTED REFERENCES

1. Ghodke K et al: A retrospective study of correlation of morphologic patterns, MIB1 proliferation index, and survival analysis in 134 cases of plasmacytoma. Ann Diagn Pathol. ePub, 2015
2. Shpilberg KA et al: Imaging of extraosseous intracranial and intraspinal multiple myeloma, including central nervous system involvement. Clin Imaging. 39(2):213-9, 2015
3. Abdallah AO et al: Patterns of central nervous system involvement in relapsed and refractory multiple myeloma. Clin Lymphoma Myeloma Leuk. 14(3):211-4, 2014

https://CafePezeshki.IR

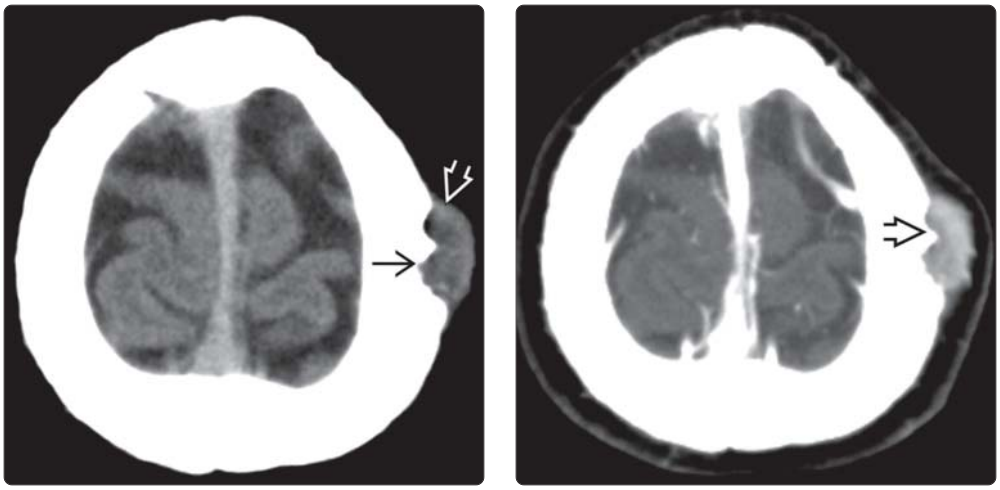

(Left) *Axial NECT in an elderly man who noted a progressively enlarging scalp "bump" shows a destructive lesion ⇨ arising from the calvaria and extending into the scalp ⇨.* **(Right)** *Axial CECT in the same patient shows the lesion ⇨ enhances strongly uniformly. Further evaluation disclosed multiple myeloma. This was the only lesion in the head and neck.*

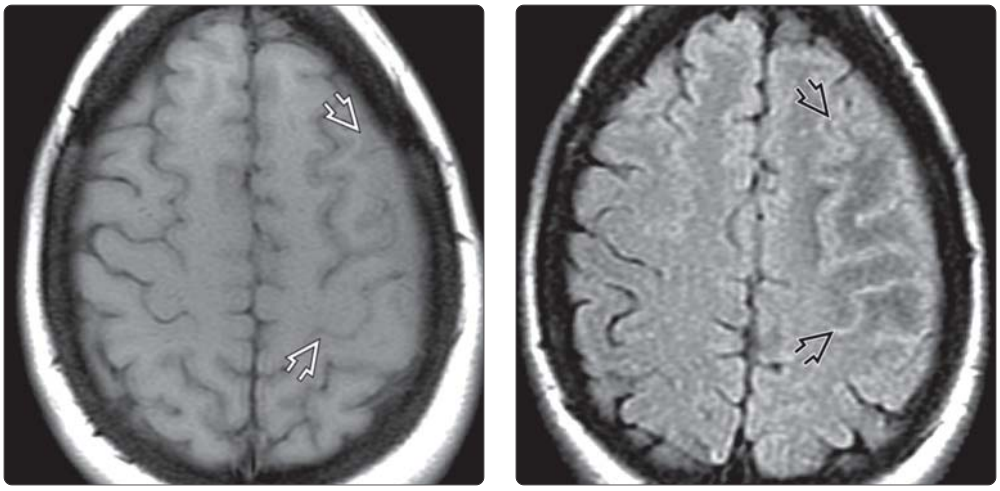

(Left) *Axial T1WI MR in a patient with Waldenstrom macroglobulinemia and right-sided weakness shows subtle effacement of the left convexity sulci ⇨.* **(Right)** *Axial FLAIR MR in the same patient shows hyperintensity ⇨ in the effaced sulci.*

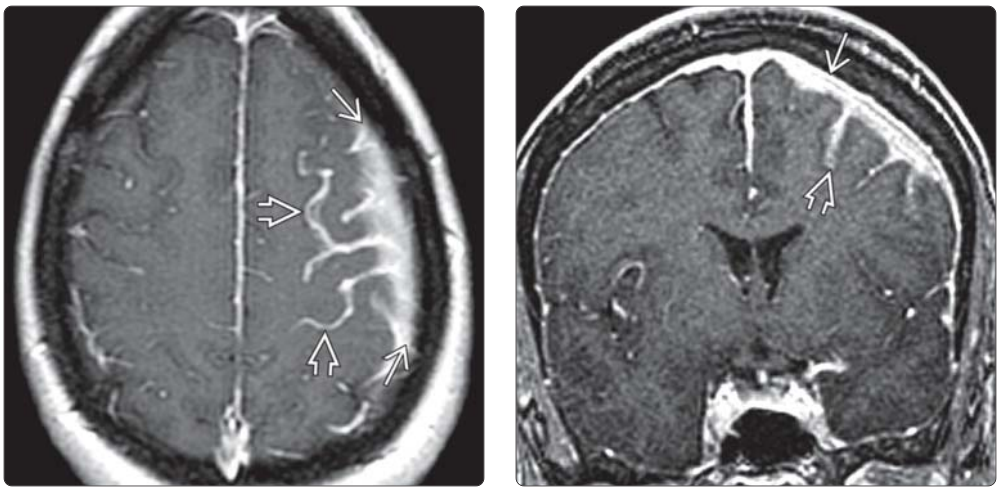

(Left) *Axial T1 C+ MR in the same patient shows an enhancing dural mass ⇨ with extension into the underlying subarachnoid spaces and pia ⇨.* **(Right)** *Coronal T1 C+ FS MR demonstrates the dural-based mass ⇨ and extension into the adjacent sulci ⇨. Plasma cells in his CSF were consistent with Waldenstrom macroglobulinemia. (Courtesy P. Hildenbrand, MD.)*

https://CafePezeshki.IR

KEY FACTS

IMAGING

- Enhancing lesion(s) with skull/meningeal destruction/infiltration
- Skull, dura, leptomeninges, arachnoid/subarachnoid, pia, and subgaleal
- Many manifestations: Smooth thickening, nodularity, loculation, lobulation, fungating masses

TOP DIFFERENTIAL DIAGNOSES

- SM: Surgical defect (burr hole, craniectomy), myeloma
- DM: Epidural/subdural hematoma, meningioma
- LM: Subarachnoid hemorrhage, sarcoidosis, infectious meningitis

CLINICAL ISSUES

- 18% patients with extracranial and intracranial malignancies
- Primary tumor never identified in 2-4%
- All metastases: May be asymptomatic and unsuspected clinically
- Headache is most common symptom (50%)
- CSF cytology often falsely negative
- Accuracy of single lumbar puncture (LP) is 50-60% but 90% after 3 attempts
- Bimodal → children (medulloblastoma & leukemia); adults (breast, lung, melanoma, prostate)
- Average age ~ 50 years (relatively young secondary pediatric cancer and young women with breast cancer)
- Entire neuraxis must be treated as tumor cells are often widely disseminated throughout CSF

DIAGNOSTIC CHECKLIST

- Both enhanced MR and LP should be performed, especially if initial test is negative

(Left) *Axial graphic illustrates a destructive skull metastasis ➡ expanding the diploic space and invading/thickening the underlying dura (light blue linear structure) ⇨.* **(Right)** *Axial T1WI C+ MR shows skull metastasis with enhancement of the diploic space ➡. There is associated small subgaleal soft tissue ⇨ and extensive nodular dural thickening ⇨.*

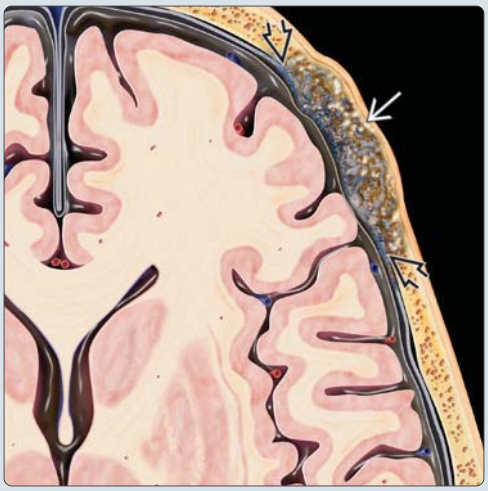

(Left) *Axial graphic illustrates diffuse leptomeningeal metastases, shown here as abnormal blue material ⇨ coating the pial surface of the brain and filling the subarachnoid spaces between interdigitating sulci.* **(Right)** *Carcinomatous "meningitis" can be indistinguishable on imaging from pyogenic meningitis. In this case of diffuse CSF spread from glioblastoma, there is both sulcal-cisternal ➡ and ependymal ⇨ spread of tumor.*

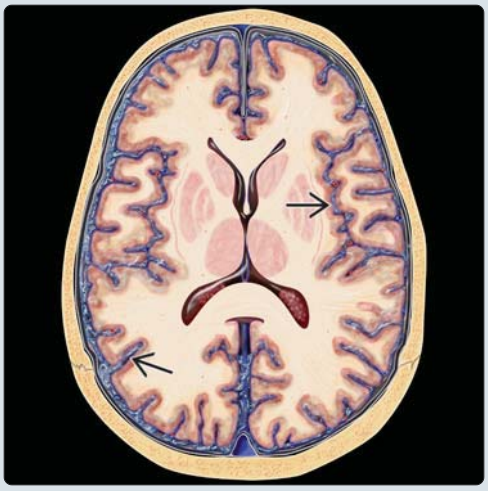

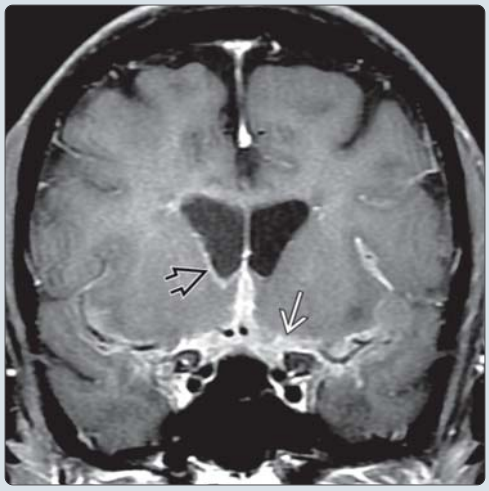

https://CafePezeshki.IR

TERMINOLOGY

Abbreviations

- Skull metastases (SM), dural metastases (DM), arachnoid/subarachnoid metastases (ASAM), pial metastases (PM), leptomeningeal (pia + arachnoid) metastases (LM)

Definitions

- Metastatic disease from extracranial primary tumor to tissues overlying brain

IMAGING

General Features

- Best diagnostic clue
  - Enhancing lesion(s) with skull/meningeal destruction/infiltration
- Location
  - Skull, dura, leptomeninges, arachnoid/subarachnoid, pia, and subgaleal
- Morphology
  - Many manifestations: Smooth thickening, nodularity, loculation, lobulation, fungating masses

Radiographic Findings

- Radiography
  - SM: Focal lytic or blastic lesions lacking "benign" sclerotic border

CT Findings

- NECT
  - Any metastases: May find hemorrhagic hyperdensity
  - Subgaleal space: Relatively dense lesion
- CECT
  - SM: Enhancing mass centered in bone with osseous destruction, lacking "benign" sclerotic border
    - Most are lytic, though a few are sclerotic (e.g., prostate)
  - DM and LM: Both may appear as enhancing biconvex masses displacing brain
    - DM characterized by calvarial involvement
  - Carcinomatosis: CT is insensitive; however, hydrocephalus may be early sign

MR Findings

- T1WI
  - SM: Hypointense marrow lesion
  - DM and LM: Most masses hypointense to gray matter (GM)
  - Subgaleal space: Relative hypointense lesion
  - Any metastases: May find hemorrhagic signal
- T2WI
  - SM: Hyperintense marrow lesion; dura usually intact
  - DM between skull & elevated hypointense dura
  - DM and LM: Most hyperintense relative to GM
  - Any metastases: May find hemorrhagic signal
- FLAIR
  - LM and ASAM: Diffuse hyperintense CSF
  - ASAM infiltrating perivascular spaces (PVS): Loss of normal PVS-CSF suppression → hyperintensity
  - Carcinomatosis: Hyperintense thickening; affects adjacent sulcal nulling → hyperintensity
  - Brain infiltration: Hyperintense vasogenic edema
- DWI
  - Dural metastasis may show restricted diffusion due to high cellularity
  - DWI sensitive in picking subtle calvarial lesions
- T1WI C+
  - SM: Lesion may enhance to "normal" T1 marrow signal → requires fat saturation
    - Usually some dural thickening & enhancement
  - DM and LM: Both appear as enhancing biconvex masses displacing brain
    - DM often has calvarial involvement
    - LM often invades underlying brain
  - LM, ASAM, PM: Diffuse enhancing tissue ± nodularity
  - ASAM infiltrating perivascular spaces: Tiny enhancing nodules with miliary appearance
  - Carcinomatosis: Enhancing and thickened tissue ± nodules
    - May coat ependymal surfaces, cranial nerves
- MRV
  - May be helpful in evaluation of sinus displacement, compression, thrombosis

Nuclear Medicine Findings

- Bone scan
  - SM: Usually intensely positive
- PET
  - 18-fluorodeoxyglucose (FDG) PET may detect small calvarial metastases not seen by MR
  - Caveat: Adjacent activity from normal gray matter may limit detection of SM

Imaging Recommendations

- Best imaging tool
  - SM: NECT/bone algorithm for osseous evaluation
    - MR with contrast if dura, scalp involved
  - DM, ASAM, PM, LM: MR + Gd, although sensitivity still only ~ 70%
    - 90% for extracranial solid tumor metastases
    - 55% when hematologic (lymphoma, leukemia)
- Protocol advice
  - Fat saturation necessary to distinguish enhancement from normal hyperintense marrow and scalp fat

DIFFERENTIAL DIAGNOSIS

Skull Metastases

- Surgical defect: Burr hole, craniectomy
- Myeloma: Characteristic labs

Dural Metastases

- Epidural hematoma: Distinctive MR
- Subdural hematoma: Distinctive MR
- Meningioma

Arachnoid/Subarachnoid Metastases

- Subarachnoid hemorrhage: Typical NECT appearance

https://CafePezeshki.IR

Leptomeningeal Metastases (LM)

- Sarcoidosis: CXR → hilar adenopathy + Kveim-Siltzbach skin test
- Infectious meningitis: CSF → infection/organism

PATHOLOGY

General Features

- Etiology
  - SM: Hematogenous (most commonly breast, lung, prostate, kidney) or by direct extension (SCCa)
  - DM: Hematogenous (most commonly breast > lymphoma > prostate > neuroblastoma)
  - LM, ASAM, PM: Hematogenous (most commonly lung, gastric, breast, ovary, melanoma, leukemia, lymphoma) or direct extension (primary CNS tumors)
- Associated abnormalities
  - Limbic encephalitis
- Dura and leptomeninges provide considerable barriers to contiguous spread of metastasis
  - General mechanisms of spread
    - Arterial hematogenous: Arterial transfer (e.g., breast, lung, melanoma, prostate)
    - Venous hematogenous: Via choroid plexus or through arachnoid vessels (classic for leukemia)
    - Direct extension: From primary brain tumors (e.g., GBM, PNET, ependymoma)
    - Perineural spread: H&N cancers (SCCa)
    - Iatrogenic: Following initial resection/debulking of primary brain tumors

Gross Pathologic & Surgical Features

- DM: Well-defined dural masses often invading skull
  - Necropsy → nodules on inner dura (subdural)
- LM, ASAM, PM: Gray-white or yellow thickening

Microscopic Features

- SM and DM: Metastatic cell infiltrates
- LM and ASAM: Metastatic cell infiltrates, often along perivascular spaces extending into brain

CLINICAL ISSUES

Presentation

- Most common signs/symptoms
  - All metastases: May be asymptomatic and unsuspected clinically
  - Headache is most common symptom (50%)
  - Less common signs/symptoms
    - N/V, pain, sensory deficit, weakness (33%)
    - Mental status change (25%)
    - Seizures (20%)
    - ↑ ICP from CSF obstruction
    - Cranial nerve deficit(s)
  - Symptoms from brain compression → highly dependent on locale
- Clinical profile
  - CSF cytology often falsely negative
    - Accuracy of single lumbar puncture (LP) is 50-60% but 90% after 3 attempts

Demographics

- Age
  - Bimodal → children (medulloblastoma and leukemia); adults (breast, lung, melanoma, prostate)
  - Average age ~ 50 years (relatively young 2° pediatric cancer and young women with breast cancer)
- Epidemiology
  - 18% patients with extra- and intracranial malignancies
  - 6-18% of CNS metastases also involve arachnoid/subarachnoid space, pia, or both
  - Carcinomatosis in up to 25% of cancer patients
    - Primary tumor never identified in 2-4%
    - Occurs in breast (35%), lung small cell (25%), melanoma cancer (25%) patients

Natural History & Prognosis

- Dural sinus thrombosis from invasion or compression
- Obstructive hydrocephalus
  - Noncommunicating: Normal CSF flow obstructed, usually by cisternal metastases
  - Communicating: Normal CSF flow, ↓ arachnoid villi absorption, obstruction 2° tumor cells, blood, debris
  - Important to evaluate presence prior to LP to prevent downward herniation and death
  - Up to 70% of carcinomatosis patients have some degree of CSF obstruction
- Pachymeningitis interna hemorrhagica
  - Rare, usually bilateral, spontaneous, subdural hematomas from meningeal metastasis
  - Commonly from breast but also prostate, melanoma
- Untreated malignant meningeal metastases decreases survival time to 1-2 months

Treatment

- Early detection of meningeal metastases is crucial
  - MR often provides 1st clue
- Usually radiation with chemotherapy (intrathecal &/or systemic) initiated to slow progression
  - Entire neuraxis must be treated as tumor cells are often widely disseminated throughout CSF
- Biopsy may be necessary if no evidence of primary tumor
- Ventriculoperitoneal shunt may be necessary in patients with symptomatic CSF obstruction

DIAGNOSTIC CHECKLIST

Image Interpretation Pearls

- Both enhanced MR and LP should be performed, especially if initial test is negative

SELECTED REFERENCES

1. Kak M et al: Treatment of leptomeningeal carcinomatosis: Current challenges and future opportunities. J Clin Neurosci. 22(4):632-637, 2015
2. Lee EQ: Nervous system metastases from systemic cancer. Continuum (Minneap Minn). 21(2 Neuro-oncology):415-28, 2015
3. Subirá D et al: Diagnostic and prognostic significance of flow cytometry immunophenotyping in patients with leptomeningeal carcinomatosis. Clin Exp Metastasis. 32(4):383-91, 2015
4. Yokote A et al: Diagnosis of leptomeningeal metastasis without a history of malignancy in the absence of cerebrospinal fluid abnormalities. Clin Neurol Neurosurg. 119:88-90, 2014
5. Nayak L et al: Intracranial dural metastases. Cancer. 115(9):1947-53, 2009

https://CafePezeshki.IR

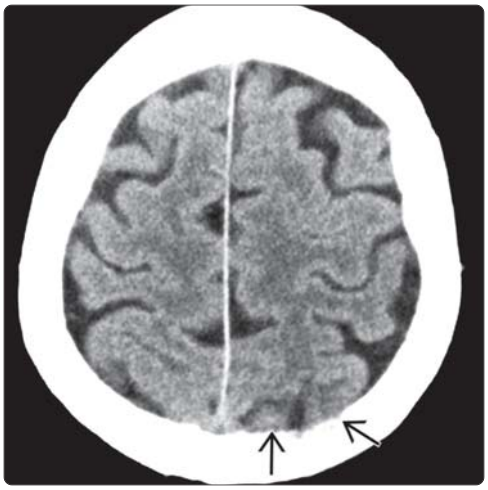

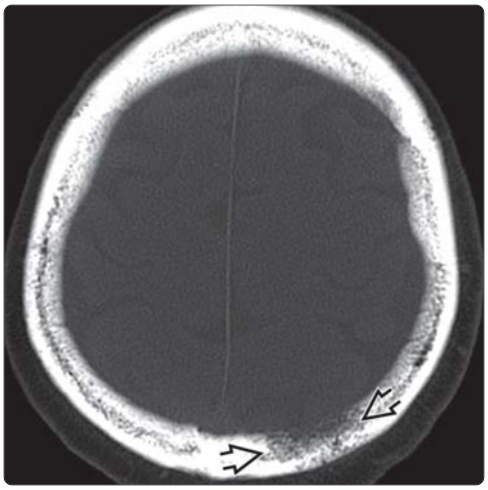

(Left) *Skull metastases can be difficult to see on routine NECT scans performed with soft tissue algorithm reconstructions. Axial NECT in this case shows very subtle erosions along the inner table of the calvaria* ⇨. **(Right)** *Axial NECT in the same case with bone algorithm reconstruction clearly shows the erosive, destructive lesion* ⇨. *In this case, this was the first manifestation of this patient's metastatic breast cancer.*

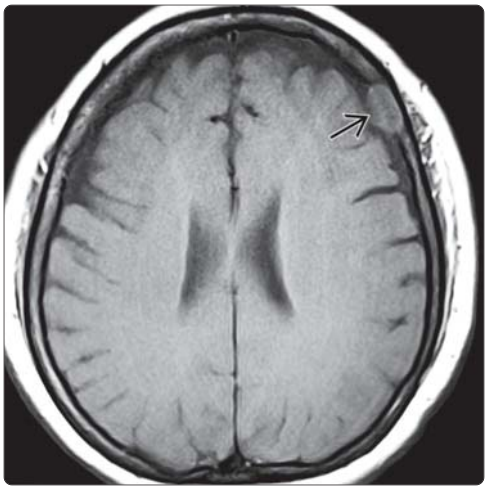

(Left) *Solitary calvarial metastases* ⇨ *are often well-seen on non-fat-saturated T1WI because the tumor replaces fatty marrow in the diploic space.* **(Right)** *Axial T2WI MR in the same case shows the lesion* ⇨ *is mixed iso- to hyperintense compared to the adjacent normal diploic space.*

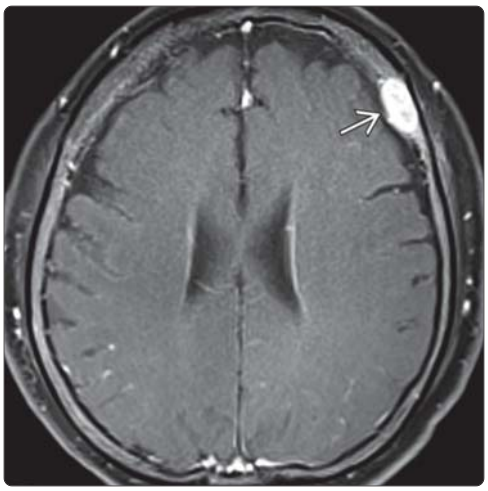

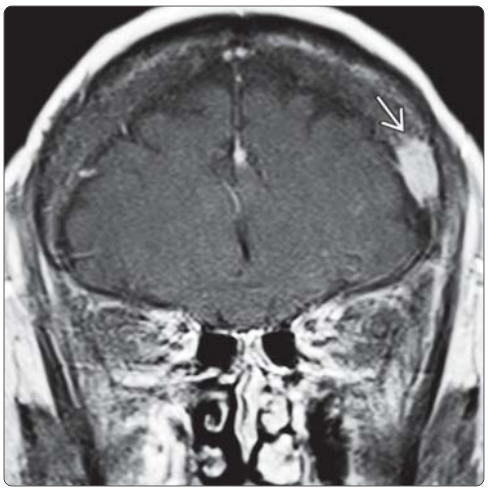

(Left) *Axial T1 C+ FS MR in the same case shows the lesion* ➡ *clearly.* **(Right)** *Coronal T1 C+ MR shows the lesion margins are slightly irregular* ➡. *While the lesion has penetrated the inner table of the skull, there is no evidence for involvement of the underlying dura. This lesion was the only metastasis from the patient's known breast cancer.*

https://CafePezeshki.IR

This page intentionally left blank

https://CafePezeshki.IR

INDEX

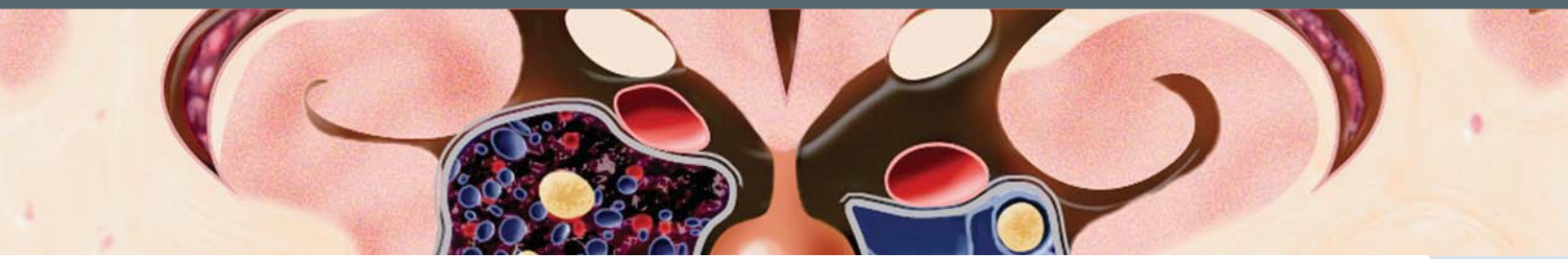

A

Abscess, **682–685**
- differential diagnosis, **683–684**
- pituitary gland, pituitary apoplexy vs., **1045–1046**
- radiation and chemotherapy complications vs., **917–918**

Abusive head trauma, **188–191**
Adrenoleukodystrophy
- X-linked, **812–815**
  - diagnostic checklist, **814**
  - differential diagnosis, **813**
  - megalencephaly with leukoencephalopathy and cysts vs., **839**
  - staging, grading, and classification, **814**
  - Wallerian degeneration vs., **978**

Aging brain
- normal, **934–937**

Aicardi-Goutières syndrome, Fahr disease vs., **877**
Aicardi syndrome, **126–127**
AIDS
- miscellaneous manifestations, **752–755**

Alcoholic encephalopathy, **880–883**
- differential diagnosis, **881–882**

Alexander disease, **832–835**
- X-linked adrenoleukodystrophy vs., **814**

Alzheimer disease, **938–941**
- Creutzfeldt-Jakob disease vs., **953**
- differential diagnosis, **939–940**
- frontotemporal lobar degeneration vs., **947–948**

Amebic disease, **722–723**
Aminoacidopathies, miscellaneous, **836–837**
Amyloid angiopathy
- chronic hypertensive encephalopathy vs., **893–894**

Amyotrophic lateral sclerosis (ALS), **972–975**
- differential diagnosis, **973–974**

Anderson-Fabry disease. *See* Fabry disease.
Aneurysm, **218–219**
- blood blister-like, **218, 244–245**
  - diagnostic checklist, **245**
  - differential diagnosis, **245**
- cerebellopontine angle-internal auditory canal
  - hemifacial spasm vs., **1089**
  - lipoma vs., **1071**
  - trigeminal neuralgia vs., **1087**
  - vestibular schwannoma vs., **1091**
- fusiform
  - arteriosclerotic vascular disease, **240–241**
  - non-ASVD, **242–243**
- saccular, **232–235**
  - atypical, non-ASVD fusiform aneurysm vs., **243**
  - blood blister-like aneurysm vs., **245**
  - differential diagnosis, **233–234**

Angiocentric glioma (AG), **480–481**
Angiocentric (intravascular) lymphoma, **570–573**
Anoxic encephalopathy
- post-traumatic brain swelling vs., **198**

Antiphospholipid antibody syndrome
- non-SLE, systemic lupus erythematosus vs., **313**

Aqueductal stenosis, **1006–1009**
Arachnoid cyst, **608–611**
- cerebellopontine angle-internal auditory canal, **1078–1081**
  - diagnostic checklist, **1080**
  - differential diagnosis, **1079**
  - vestibular schwannoma vs., **1091**
- differential diagnosis, **609–610**
- nonneoplastic tumor-associated cyst vs., **653**
- posterior fossa, Dandy-Walker continuum vs., **27–28**

Arachnoid granulation
- aberrant, **388–391**

Arteriolosclerosis, **280–283**
- Creutzfeldt-Jakob disease vs., **953**
- differential diagnosis, **281–282**

Arteriovenous fistula
- dural, **400–403**
- pial, **404–405**

Arteriovenous malformations (AVMs), **396–399**
- cerebellopontine angle-internal auditory canal
  - hemifacial spasm vs., **1089**
  - trigeminal neuralgia vs., **1087**
- multiple, in vascular neurocutaneous syndrome, von Hippel-Lindau syndrome vs., **93**

Arteritis
- central nervous system, primary, **298–301**

Astroblastoma, **476–477**
Astrocytoma
- anaplastic, **438–441**
  - low-grade diffuse astrocytoma vs., **435**
- cerebellar pilocytic
  - arachnoid cyst of cerebellopontine angle-internal auditory canal vs., **1079**
- desmoplastic infantile, **506–509**
- low-grade (grade II)
  - ganglioglioma vs., **503**
  - mesial temporal sclerosis vs., **925**
  - pleomorphic xanthoastrocytoma vs., **461**
- low-grade diffuse, **434–437**
  - anaplastic astrocytoma vs., **439**
  - diagnostic checklist, **436**
  - differential diagnosis, **435–436**
  - oligodendroglioma vs., **469**
  - paraneoplastic syndromes vs., **599**
  - pilomyxoid astrocytoma vs., **457**
  - staging, grading, and classification, **436**

https://CafePezeshki.IR

- pilocytic, **452–455**
  differential diagnosis, **453–454**
  nonneoplastic tumor-associated cyst vs., **653**
  rosette-forming glioneuronal tumor vs., **523**
  von Hippel-Lindau syndrome vs., **93**
- pilomyxoid, **456–459**
  staging, grading, and classification, **457–458**
- subependymal giant cell, **464–467**

Atherosclerosis
- extracranial, **276–279**
- intracranial, **272–275**
  differential diagnosis, **273–274**

Atherosclerotic fusiform aneurysm (ASVD FA), **240–241**
Atherosclerotic vascular disease (ASVD)
- blood blister-like aneurysm vs., **245**

Atrophy
- multiple system, **960–963**
  differential diagnosis, **960–963**
- nonalcoholic, alcoholic encephalopathy vs., **881–882**
- optic nerve, idiopathic or post-inflammatory, intracranial hypertension vs., **897**

Atypical teratoid/rhabdoid tumor (AT/RT). *See* Teratoid-rhabdoid tumor, atypical.
Autoimmune-mediated vasculitis, acute disseminated encephalomyelitis vs., **765**
Autoimmune pancreatitis (AIP). *See* IgG4-related disease.
Axonal injury, diffuse, **176–179**
- traumatic, cerebral amyloid disease vs., **317–318**

B

Basal cell nevus syndrome, **106–109**
- Li-Fraumeni syndrome vs., **129**

Basal ganglia, **4–5, 858–861**
- T2 hyperintense, **858–859**

Basal ganglia calcification
- pathologic, Fahr disease vs., **877–878**

Behçet disease, **324–325**
- acute disseminated encephalomyelitis vs., **765–766**

Bell palsy, **1082–1085**
"Black dots"
- multifocal, cerebral amyloid disease vs., **317–318**

Blood blister-like aneurysm, **244–245**
- diagnostic checklist, **245**
- differential diagnosis, **245**

Blue rubber bleb nevus syndrome, Sturge-Weber syndrome vs., **101–102**
Bourneville-Pringle syndrome. *See* Tuberous sclerosis complex.
Brain
- aging
  normal, **934–937**
- cysts
  anatomy-based approach, **604–605**
- lesions
  multiple ring-enhancing, fungal disease vs., **731**
- malformations, general imaging approach, **4–5**

Brain death, **204–205**
Brain swelling, post-traumatic, **196–199**
- diagnostic checklist, **198**
- differential diagnosis, **198**

Brainstem glioma
- Wallerian degeneration vs., **977–978**

C

CADASIL (cerebral autosomal dominant arteriopathy with subcortical infarcts and leukoencephalopathy), **320–323**
- arteriolosclerosis vs., **281–282**

Callosal dysgenesis, **18–21**
- differential diagnosis, **19–20**

Calvarial defects, congenital, **1108–1111**
- differential diagnosis, **1109–1110**

Calvarium (calvaria)
- hemangioma, **1184–1187**
  differential diagnosis, **1185–1186**

Canavan disease, **830–831**
Canavan-van Bogaert-Bertrand disease. *See* Canavan disease.
Capillary hemangioma, capillary telangiectasia vs., **425–426**
Capillary telangiectasias, **424–427**
- differential diagnosis, **425–426**

Carbon monoxide poisoning, **900–903**
- differential diagnosis, **901–902**

Carney complex, Li-Fraumeni syndrome vs., **129**
Carotid artery, internal
- aberrant, **284–287**
  differential diagnosis, **285–286**

Carotid basilar anastomoses, persistent, **288–289**
Carotid cavernous fistula
- traumatic, **212–213**

Cavernous malformations, **420–423**
Central nervous system (CNS)
- primary arteritis, **298–301**

Cephalocele, **1116–1121**
- atretic, **1122–1125**
  differential diagnosis, **1123–1124**
- differential diagnosis, **1117–1118**

Cerebellar disorders
- crossed cerebellar diaschisis, **980–981**
- remote hemorrhage, **266–267**

Cerebellar dysplasias
- unclassified, **34–35**
  Lhermitte-Duclos disease vs., **119**

Cerebellar infarction
- subacute, Lhermitte-Duclos disease vs., **119**

Cerebellar neoplasms
- pilocytic astrocytoma
  arachnoid cyst of cerebellopontine angle-internal auditory canal vs., **1079**

Cerebellitis, **704–705**
- Lhermitte-Duclos disease vs., **119**

Cerebellopontine angle (CPA) masses
- neurofibromatosis type 2 vs., **89–90**

Cerebellopontine angle-internal auditory canal (CPA-IAC)
- aneurysm
  hemifacial spasm vs., **1089**
  lipoma vs., **1071**
  trigeminal neuralgia vs., **1087**

https://CafePezeshki.IR

vestibular schwannoma vs., **1091**
- arachnoid cyst, **1078–1081**
  differential diagnosis, **1079**
  vestibular schwannoma vs., **1091**
- Bell palsy, **1082–1085**
- dura/venous sinus hemangioma vs., **1189**
- epidermoid cyst, **1074–1077**
  diagnostic checklist, **1076**
  differential diagnosis, **1075**
- hemifacial spasm, **1088–1089**
- lipoma, **1070–1073**
  diagnostic checklist, **1072**
  differential diagnosis, **1071**
- meningioma, **1094–1097**
- metastases, **1098–1101**
- overview, **1066–1069**
- trigeminal neuralgia, **1086–1087**

Cerebral amyloid disease, **316–319**
- differential diagnosis, **317–318**

Cerebral contusion, **172–175**
Cerebral hemiatrophy, **352–353**
Cerebral hyperperfusion syndrome, **372–375**
- differential diagnosis, **373–374**

Cerebral infarction
- chronic, **362–365**
- hypotensive, **344–347**
  differential diagnosis, **345–346**
- subacute, **358–361**

Cerebral ischemia
- oligodendroglioma vs., **469–470**

Cerebral ischemia-infarction
- acute, **354–357**
  acute hypertensive encephalopathy/PRES vs., **889**
  adult hypoglycemia vs., **867**
  adult hypoxic ischemic injury vs., **341**
  cerebral hyperperfusion syndrome vs., **373**
  diagnostic checklist, **356**
  differential diagnosis, **356**
  fat emboli cerebral infarction vs., **367**
  herpes encephalitis vs., **693**
- status epilepticus vs., **929**
- transient global amnesia vs., **933**
- traumatic, **200–203**
  diagnostic checklist, **202**
  differential diagnosis, **201**

Cerebral malaria, **724–725**
Cerebral vasoconstriction syndrome, reversible, **306–307**
Cerebritis
- low-grade diffuse astrocytoma vs., **435**

Cerebrospinal fluid (CSF) shunts and complications, **1014–1017**
Chiari 1, **8–11**
Chiari 2, **12–15**
Chiari 3, **16–17**
Childhood stroke, **348–351**
Chordoid glioma of third ventricle (CGOTV), **478–479**
Choroid plexus carcinoma, **498–501**
- differential diagnosis, **499–500**

Choroid plexus cyst, **640–643**
- differential diagnosis, **641–642**

Choroid plexus papilloma
- atypical teratoid-rhabdoid tumor vs., **545**
- typical, **494–497**
  differential diagnosis, **495–496**

Chronic progressive external ophthalmoplegia (CPEO), Kearns-Sayre syndrome vs., **791**
Chronic traumatic encephalopathy, **214–215**
Cisterns, overview, **988–993**
Citrobacter meningitis, **674–677**
- differential diagnosis, **675–676**

CLIPPERS (chronic lymphocytic inflammation with pontine perivascular enhancement responsive to steroids), **770–771**
"Closed-lip" schizencephaly, heterotopic gray matter vs., **65**
Colloid cyst, **612–615**
Congenital lipoma. *See* Lipoma, cerebellopontine angle-internal auditory canal.
Congenital malformations
- Aicardi-Goutières syndrome, Fahr disease vs., **877**
- Aicardi syndrome, **126–127**
- basal cell nevus syndrome, **106–109**
- callosal dysgenesis, **18–21**
  differential diagnosis, **19–20**
- cerebellar dysplasias, unclassified, **34–35**
- Chiari 1, **8–11**
- Chiari 2, **12–15**
- Chiari 3, **16–17**
- Dandy-Walker continuum, **26–29**
  differential diagnosis, **27–28**
- encephalocraniocutaneous lipomatosis, **114–117**
- hemimegalencephaly, **80–83**
  differential diagnosis, **81–82**
- hereditary hemorrhagic telangiectasia, **110–113**
- Lhermitte-Duclos disease, **118–121**
  differential diagnosis, **119**
- Li-Fraumeni syndrome, **128–129**
- lissencephaly, **72–75**
- meningioangiomatosis, **104–105**
- muscular dystrophy, **60–63**
- neurocutaneous melanosis, **122–125**
- neurofibromatosis type 1, **84–87**
- neurofibromatosis type 2, **88–91**
  differential diagnosis, **89–90**
- overview, **4–7**
- polymicrogyria, **68–71**
  differential diagnosis, **69–70**
- rhombencephalosynapsis, **30–33**
- schwannomatosis, **130–131**
- septooptic dysplasia, **52–55**
- Sturge-Weber syndrome. *See* Sturge-Weber syndrome.
- von Hippel-Lindau syndrome, **92–95**
  differential diagnosis, **93**

Conradi-Hünermann-Happle syndrome, peroxisomal disorders vs., **817**
Cortical venous thrombosis, **380–383**
Corticobasal degeneration, **964–967**
- Creutzfeldt-Jakob disease vs., **953**

Cranial fossa, bilateral middle cyst-like spaces, glutaric aciduria type 1, **827**

https://CafePezeshki.IR

Craniopharyngioma, **1048–1051**
Craniostenoses, **1112–1115**
Craniovertebral junction, fracture, **135–136**
Creutzfeldt-Jakob disease (CJD), **952–955**
- adult hypoxic ischemic injury vs., **342**
- Alzheimer disease vs., **940**
- carbon monoxide poisoning vs., **902**
- cyanide poisoning vs., **911**
- diagnostic checklist, **954**
- differential diagnosis, **953**
- methanol poisoning vs., **909**
- Wilson disease vs., **853**

Crossed cerebellar diaschisis, **980–981**
Cryptococcosis, **746–747**
Cyanide poisoning, **910–911**
Cystic neoplasms
- nonneoplastic tumor-associated cyst vs., **653**

Cysts
- choroid plexus, **640–643**
  differential diagnosis, **641–642**
- colloid, **612–615**
- hydatid, **720–721**
- leptomeningeal
  "growing fracture," **1126–1127**
- neuroglial, **624–625**
- nonneoplastic
  primary, overview, **604–607**
- periventricular, **626–629**
- pineal, **636–639**
- tumor-associated nonneoplastic, **652–653**

Cytomegalovirus infection
- acquired, **744–745**
- congenital, **662–665**

Cytotoxic edema. *See* Brain swelling, post-traumatic.

D

Dandy-Walker continuum, **26–29**
- diagnostic checklist, **28**
- differential diagnosis, **27–28**
- molar tooth malformations vs., **37**
- staging, grading and classification, **28**

Dandy-Walker malformation, **4**
- porencephalic cyst vs., **647**

Dandy-Walker spectrum, Dandy-Walker continuum vs., **27**
Degenerative disorders
- amyotrophic lateral sclerosis, **972–975**
  differential diagnosis, **973–974**
- corticobasal degeneration, **964–967**
  Creutzfeldt-Jakob disease vs., **953**
- crossed cerebellar diaschisis, **980–981**
- Fahr disease, **876–879**
  differential diagnosis, **877–878**
- hypertrophic olivary degeneration, **982–985**
- Parkinson disease, **956–959**
  progressive supranuclear palsy vs., **969–970**
- progressive supranuclear palsy, **968–971**
  differential diagnosis, **969–970**
- Wallerian degeneration, **976–979**
  differential diagnosis, **977–978**

Dementia
- Creutzfeldt-Jakob disease. *See* Creutzfeldt-Jakob disease (CJD).
- multi-infarct. *See* Multi-infarct dementia.

Dementia with Lewy bodies, **950–951**
Demyelinating disease
- neuromyelitis optica, **760–763**
- Susac syndrome, **326–327**

Demyelination
- primary CNS lymphoma vs., **567–568**

Demyelination syndrome, osmotic, **912–915**
- Creutzfeldt-Jakob disease vs., **953**
- differential diagnosis, **913–914**

Dermoid cyst, **616–619**
Dermoid tumors
- T1-hyperintense, neurocutaneous melanosis vs., **123**

Desmoplastic infantile astrocytoma (DIA), **506–509**
Desmoplastic infantile ganglioglioma (DIG/DIGG), **506–509**
Developmental venous anomalies, **410–415**
- differential diagnosis, **411–412**

Diffuse astrocytoma. *See* Astrocytoma, low-grade diffuse.
Diffuse axonal injury, **176–179**
- traumatic, cerebral amyloid disease vs., **317–318**

Diffuse brain swelling. *See* Brain swelling, post-traumatic.
Diffuse dura-arachnoid enhancement, **1104**
Dissection
- intracranial atherosclerosis vs., **273–274**
- traumatic, intracranial arterial, **208–211**

Dolichoectasia
- vertebrobasilar, **238–239**

Drug abuse, **904–907**
Dura/venous sinus hemangioma, **1188–1189**
Dural neoplasms
- metastases
  cerebellopontine angle-internal auditory canal, meningioma vs., **1095**

Dural sinus
- granulations, **388–391**
- hypoplasia-aplasia
  dural sinus and aberrant arachnoid granulations vs., **389**
  dural sinus thrombosis vs., **378**

Dural sinus thrombosis, **376–379**
Dyke-Davidoff-Masson syndrome. *See* Cerebral hemiatrophy.
Dysembryoplastic neuroepithelial tumor (DNET), **510–513**
- of cerebellum. *See* Rosette-forming glioneuronal tumor (RGNT).

E

Eclampsia (pregnancy-induced hypertension), traumatic subarachnoid hemorrhage vs., **169**
Empty sella, **1056–1059**
- differential diagnosis, **1057–1058**

Empyema
- epidural, **688–691**
  differential diagnosis, **689–690**

https://CafePezeshki.IR

INDEX

Encephalitis
- herpes simplex virus, human herpes virus 6 (HHV-6) encephalitis vs., **703**
- HIV
  acquired, **738–741**
- human herpes virus 6 (HHV-6), **702–703**
- limbic
  paraneoplastic, human herpes virus 6 (HHV-6) encephalitis vs., **703**
- miscellaneous, **696–699**
- post-traumatic brain swelling vs., **198**
- Rasmussen, **706–709**
- subacute sclerosing panencephalitis, **710–711**
- West Nile virus, **700–701**

Encephalocraniocutaneous lipomatosis, **114–117**
Encephalomalacia
- postoperative/post-traumatic, chronic cerebral infarction vs., **363**

Encephalomyelitis, acute disseminated, **764–767**
- differential diagnosis, **765–766**

Encephalopathy
- alcoholic, **880–883**
  differential diagnosis, **881–882**
- anoxic, post-traumatic brain swelling vs., **198**
- chronic traumatic, **214–215**
- hepatic, **884–887**
  differential diagnosis, **885–886**
- metabolic, post-traumatic brain swelling vs., **198**
- subcortical arteriosclerotic, normal pressure hydrocephalus vs., **1011–1012**

Encephalotrigeminal angiomatosis. *See* Sturge-Weber syndrome.
Enlarged subarachnoid spaces, **996–999**
- differential diagnosis, **997–998**

Ependymal cyst, **644–645**
Ependymoma
- atypical teratoid-rhabdoid tumor vs., **545**
- infratentorial, **482–485**
- neurofibromatosis type 2 vs., **89–90**
- rosette-forming glioneuronal tumor vs., **523**
- supratentorial, **486–489**

Epidermoid cyst, **620–623**
- cerebellopontine angle-internal auditory canal, **1074–1077**
  arachnoid cyst vs., **1079**
  diagnostic checklist, **1076**
  differential diagnosis, **1075**
  meningioma vs., **1095**
  vestibular schwannoma vs., **1091**
- differential diagnosis, **621–622**

Epidermoid tumors. *See also* Cerebellopontine angle-internal auditory canal, epidermoid cyst.
Epidural empyema, **688–691**
- differential diagnosis, **689–690**

Epidural hematoma
- classic, **148–151**
  differential diagnosis, **149–150**
- variant, **152–155**

Epilepsy, myoclonic, with ragged-red fibers, MELAS vs., **787**
Epithelial inclusion cyst. *See* Cerebellopontine angle-internal auditory canal, epidermoid cyst.
Erdheim-Chester disease, **1161**
Extraaxial cysts, **604–605**
Extracranial atherosclerosis, **276–279**
Extramedullary hematopoiesis, **1146–1149**
Extraventricular neurocytoma (EVN), **518–519**

F

Fabry disease, **808–809**
Fahr disease, **876–879**
- differential diagnosis, **877–878**

Fat-containing lesions, evolution of intracranial hemorrhage vs., **255**
Fibrillary astrocytoma. *See* Astrocytoma, low-grade diffuse.
Fibromuscular dysplasia, **328–329**
Fibrous dysplasia, skull, **1138–1141**
- staging, grading, and classification, **1139–1140**

Frontotemporal lobar degeneration, **946–949**
- Creutzfeldt-Jakob disease vs., **953**
- differential diagnosis, **947–948**

Fungal diseases, **730–733**
Fusiform aneurysm
- ASVD, **240–241**
- non-ASVD, **242–243**
  diagnostic checklist, **243**
  differential diagnosis, **243**

G

Ganglioglioma, **502–505**
- desmoplastic infantile, **506–509**
- differential diagnosis, **503–504**
- Lhermitte-Duclos disease vs., **119**

Gangliosidosis, **796–799**
Germ cell neoplasms, miscellaneous malignant, **586–589**
Germinal matrix hemorrhage, **268–271**
Germinoma, **578–581**
- differential diagnosis, **579–580**

Giant aneurysm
- serpentine
  non-ASVD fusiform aneurysm vs., **243**

Glioblastoma, **442–445**
- atypical teratoid-rhabdoid tumor vs., **545**
- differential diagnosis, **443–444**

Glioma
- angiocentric, **480–481**
- brainstem
  Wallerian degeneration vs., **977–978**
- chordoid, of third ventricle, **478–479**
- low-grade, **430**
  herpes encephalitis vs., **693**

Gliomatosis cerebri, **448–451**
- differential diagnosis, **449–450**

Glioneuronal tumor
- rosette-forming, **522–523**
  diagnostic checklist, **523**

https://CafePezeshki.IR

differential diagnosis, **523**
staging, grading, and classification, **523**
Gliosarcoma, **446–447**
Glutaric aciduria type 1, **826–829**
Gorlin-Goltz syndrome. *See* Basal cell nevus syndrome.
Grade II astrocytoma. *See* Astrocytoma, low-grade diffuse.
Granulomatous disease
- meningeal, Lhermitte-Duclos disease vs., **119**
Gray matter, heterotopic, **64–67**
Gray matter disorders, **774–775**
Group B b-hemolytic streptococcal meningitis. *See* Meningitis, group B streptococcal.

H

Hallervorden-Spatz syndrome. *See* Pantothenate kinase-associated neurodegeneration (PKAN).
Hamartoma
- syndrome, multiple. *See* Lhermitte-Duclos disease.
- tuber cinereum, **1028–1031**
Hemangioblastoma, **558–561**
- nonneoplastic tumor-associated cyst vs., **653**
- solitary, von Hippel-Lindau syndrome vs., **93**
Hemangioendothelioma, low-grade, calvarial hemangioma vs., **1185**
Hemangioma
- calvarial, **1184–1187**
- capillary, capillary telangiectasia vs., **425–426**
- dura/venous sinuses, **1188–1189**
Hemangiopericytoma, **562–565**
Hematoma
- epidural
  classic, **148–151**
    differential diagnosis, **149–150**
  variant, **152–155**
Hematopoiesis, extramedullary, **1146–1149**
Hemifacial spasm, **1088–1089**
Hemimegalencephaly, **80–83**
- differential diagnosis, **81–82**
Hemorrhage
- cerebellar, remote, **266–267**
- germinal matrix, **268–271**
- spontaneous, coagulopathy-related, remote cerebellar hemorrhage vs., **267**
- T1-hyperintense, neurocutaneous melanosis vs., **123**
Hemorrhagic leukoencephalitis, acute, **768–769**
Hemorrhagic telangiectasia, hereditary, **110–113**
Hepatic encephalopathy, **884–887**
- differential diagnosis, **885–886**
"Herald" cyst. *See* Nonneoplastic tumor-associated cysts.
Herniation
- intracranial herniation syndromes, **192–195**
Herpes encephalitis, **692–695**
- low-grade diffuse astrocytoma vs., **435**
- neonatal, **668–669**
Herpes simplex virus type 2 (HSV-2) infection, group B streptococcal meningitis vs., **671**
Heterotopia
- subependymal, X-linked, tuberous sclerosis complex vs., **97**
Heterotopic gray matter, **64–67**
High-grade astrocytoma. *See* Astrocytoma, anaplastic.
High-grade oligodendroglioma (oligo). *See* Oligodendroglioma, anaplastic.
Histiocytosis
- miscellaneous, **1160–1163**
  non-Langerhans cell, **1161**
HIV-associated mineralizing calcific microangiopathy, Fabry disease vs., **809**
HIV encephalitis
- acquired, **738–741**
HIV infections
- congenital, **666–667**
- miscellaneous manifestations, **752–755**
Holoprosencephaly, **40–43**
- differential diagnosis, **41–42**
- middle interhemispheric variant (syntelencephaly), **48–51**
  differential diagnosis, **49–50**
- variants, **44–47**
Human herpes virus 6 (HHV-6) encephalitis, **702–703**
- diagnostic checklist, **703**
- differential diagnosis, **703**
Huntington disease, **848–851**
Hydatid disease, **720–721**
Hydranencephaly, **330–331**
Hydrocephalus
- extraventricular obstructive, **1004–1005**
- intraventricular obstructive, **1000–1003**
  differential diagnosis, **1001–1002**
- normal pressure, **1010–1013**
  differential diagnosis, **1011–1012**
Hyperdense vessel mimics, acute cerebral ischemia-infarction vs., **356**
Hyperglycemia, chorea-ballism associated with, hepatic encephalopathy vs., **885**
Hypertension
- intracranial
  idiopathic, **896–899**
Hypertension-related microvascular disease. *See* Hypertensive encephalopathy, chronic.
Hypertensive encephalopathy
- acute/PRES, **888–891**
  differential diagnosis, **889–890**
- chronic, **892–895**
  differential diagnosis, **893–894**
  normal pressure hydrocephalus vs., **1011–1012**
Hypertensive intracranial hemorrhage, **262–265**
- differential diagnosis, **263–264**
Hypertrophic olivary degeneration, **982–985**
Hypoglycemia
- adult, **866–867**
- neonatal, X-linked adrenoleukodystrophy vs., **814**
- pediatric, **862–865**
Hypomyelination, **778–781**
- differential diagnosis, **779–780**
Hypotension, intracranial, **1128–1131**
- differential diagnosis, **1129–1130**
Hypotensive cerebral infarction, **344–347**
- differential diagnosis, **345–346**

https://CafePezeshki.IR

Hypoxic-ischemic encephalopathy
- cyanide poisoning vs., **911**
- group B streptococcal meningitis vs., **671–672**
- hepatic encephalopathy vs., **885**
- maple syrup urine disease vs., **821**
- parathyroid disorders vs., **875**
- perinatal, mucopolysaccharidoses vs., **793**
- urea cycle disorders vs., **825**
- Wilson disease vs., **853**

Hypoxic-ischemic injury
- adult, **340–343**
  - Creutzfeldt-Jakob disease vs., **953**
  - diagnostic checklist, **342**
  - differential diagnosis, **341–342**
- neonatal, **775**
- preterm, pediatric hypoglycemia vs., **863**
- term, **336–339**
  - diagnostic checklist, **338**
  - differential diagnosis, **337–338**
  - kernicterus vs., **869**
  - pediatric hypoglycemia vs., **863**

I

"Idiopathic" pseudotumor. *See* IgG4-related disease.

IgG4-related disease, **1136–1137**
- diagnostic checklist, **1137**
- differential diagnosis, **1137**

IgG4-related ophthalmic disease. *See* IgG4-related disease.

Immune reconstitution inflammatory syndrome (IRIS), **750–751**

Infantile-onset leukoencephalopathy with swelling and discrepantly mild course. *See* Megalencephaly with leukoencephalopathy and cysts.

Infarction
- lacunar, **368–371**
- traumatic. *See* Cerebral ischemia-infarction, traumatic.

Infections
- central nervous system, overview, **656–657**
- cerebral malaria, **724–725**
- cryptococcosis, **746–747**
- fungal, **730–733**
- immune reconstitution inflammatory syndrome (IRIS), **750–751**
- Lyme disease, **736–737**
- miscellaneous parasites, **726–729**
- rickettsial diseases, **734–735**
- ventriculitis, **686–687**

Inflammatory pseudotumor, intracranial idiopathic, **1132–1135**

Infratentorial extraaxial cysts, **604–605**

Intracranial arterial dissection, traumatic, **208–211**

Intracranial atherosclerosis, **272–275**
- differential diagnosis, **273–274**

Intracranial cystic-appearing lesions, **606**

Intracranial hemorrhage
- evolution of, **254–257**
- hypertensive, **262–265**
  - differential diagnosis, **263–264**
- spontaneous nontraumatic, **258–261**
  - differential diagnosis, **259–260**

Intracranial herniation syndromes, **192–195**

Intracranial hypertension
- idiopathic, **896–899**

Intracranial hypotension, **1128–1131**

Intravascular B-cell lymphoma. *See* Angiocentric (intravascular) lymphoma.

Ischemia
- low-grade diffuse astrocytoma vs., **435**
- traumatic. *See* Cerebral ischemia-infarction, traumatic.

J

Jaffe-Campanacci (J-C) syndrome, fibrous dysplasia vs., **1139**

Jaffe-Lichtenstein dysplasia. *See* Fibrous dysplasia, skull.

K

Kaplan-Grumbach-Hoyt syndrome. *See* Septooptic dysplasia.

Kearns-Sayre syndrome, **790–791**
- diagnostic checklist, **791**
- differential diagnosis, **791**
- MELAS vs., **787**
- PKAN vs., **845**

Kernicterus, **868–869**

Klippel-Trenaunay-Weber syndrome, Sturge-Weber syndrome vs., **102**

Krabbe disease, **804–807**

L

L-2 hydroxyglutaric aciduria, PKAN vs., **845**

Lacunar infarction, **368–371**

Lacunar skull of newborn, congenital calvarial defects vs., **1109–1110**

Langerhans cell histiocytosis (LCH), **1152–1155**
- differential diagnosis, **1153–1154**

Lateral sclerosis, primary
- amyotrophic lateral sclerosis vs., **973–974**

Leigh syndrome, **782–785**
- Creutzfeldt-Jakob disease vs., **953**

Leptomeningeal carcinomatosis. *See* Metastasis (metastatic disease), cerebellopontine angle-internal auditory canal.

Leptomeningeal cyst
- "growing fracture," **1126–1127**

Leptomeningeal enhancement
- Sturge-Weber syndrome vs., **102**

Leukemia, **574–577**
- differential diagnosis, **575–576**

Leukodystrophy
- metachromatic, **800–803**

Leukoencephalitis, acute hemorrhagic, **768–769**

https://CafePezeshki.IR

Leukoencephalopathy
- megalencephalic, with cysts, **838–841**
- progressive multifocal, **748–749**
Lhermitte-Duclos disease, **118–121**
- diagnostic checklist, **120**
- differential diagnosis, **119**
- rhombencephalosynapsis vs., **31**
- staging, grading and classification, **120**
Li-Fraumeni syndrome, **128–129**
- diagnostic checklist, **129**
- differential diagnosis, **129**
- staging, grading and classification, **129**
Limbic encephalitis
- paraneoplastic, human herpes virus 6 (HHV-6) encephalitis vs., **703**
Lipoma, **22–25**
- cerebellopontine angle-internal auditory canal, **1070–1073**
  diagnostic checklist, **1072**
  differential diagnosis, **1071**
- differential diagnosis, **23–24**
- T1-hyperintense, neurocutaneous melanosis vs., **123**
Lipomatosis, encephalocraniocutaneous, **114–117**
Lipomatous hamartoma. *See* Lipoma, cerebellopontine angle-internal auditory canal.
Lissencephaly, **72–75**
Low-grade astrocytoma (LGA). *See* Astrocytoma, low-grade diffuse.
Lyme disease, **736–737**
Lymphocytic hypophysitis, **1062–1063**
Lymphoma
- IgG4-related disease vs., **1137**
- intravascular (angiocentric), **570–573**
- metastatic intracranial, **596–597**
- primary CNS, **566–569**
  deep cerebral venous thrombosis vs., **385–386**
  differential diagnosis, **567–568**

M

Malaria, cerebral, **724–725**
Malignant rhabdoid tumor of brain. *See* Teratoid-rhabdoid tumor, atypical.
Maple syrup urine disease, **820–823**
Marchiafava-Bignami disease. *See also* Alcoholic encephalopathy.
- maple syrup urine disease vs., **821**
McCune-Albright syndrome (MAS). *See* Fibrous dysplasia, skull.
Medulloblastoma, **536–539**
- atypical teratoid-rhabdoid tumor vs., **545**
- hemispheric, von Hippel-Lindau syndrome vs., **93**
- Lhermitte-Duclos disease vs., **119**
- rosette-forming glioneuronal tumor vs., **523**
"Mega-corpus callosum," callosal dysgenesis vs., **20**
Megalencephaly with leukoencephalopathy and cysts, **838–841**
Melanoma-astrocytoma syndrome, Li-Fraumeni syndrome vs., **129**
Melanosis, neurocutaneous, **122–125**
MELAS (mitochondrial encephalopathy with lactic acidosis and stroke-like episodes), **786–789**
- adult hypoxic ischemic injury vs., **342**
- CADASIL vs., **321**
- cerebral hyperperfusion syndrome vs., **373**
- diagnostic checklist, **788**
- differential diagnosis, **787**
- Kearns-Sayre syndrome vs., **791**
- Leigh syndrome vs., **783**
- pediatric hypoglycemia vs., **863**
- Rasmussen encephalitis vs., **707**
- status epilepticus vs., **929**
Meningeal carcinomatosis. *See* Metastasis (metastatic disease), cerebellopontine angle-internal auditory canal.
Meningeal granulomatous disease, Lhermitte-Duclos disease vs., **119**
Meningeal neoplasms
- metastases, **1194–1197**
  differential diagnosis, **1195–1196**
  Lhermitte-Duclos disease vs., **119**
- non-Hodgkin lymphoma, intracranial idiopathic inflammatory pseudotumor vs., **1133**
Meningeal tumors, **431–432**
Meninges
- overview, **1104–1107**
Meningioangiomatosis, **104–105**
- Sturge-Weber syndrome vs., **102**
Meningioma, **1166–1171**
- anaplastic oligodendroglioma vs., **473–474**
- atypical and malignant, **1172–1175**
- cerebellopontine angle-internal auditory canal, **1094–1097**
  diagnostic checklist, **1096**
  differential diagnosis, **1095**
  staging, grading, and classification, **1096**
  vestibular schwannoma vs., **1091**
- IgG4-related disease vs., **1137**
- malignant
  and atypical, **1172–1175**
Meningitides
- neonatal, gram-negative meningitis, group B streptococcal meningitis vs., **671**
Meningitis, **678–681**
- cerebellopontine angle-internal auditory canal, metastases vs., **1099**
- *Citrobacter*, **674–677**
- group B streptococcal, **670–673**
- post-traumatic brain swelling vs., **198**
Merosin-deficiency congenital muscular dystrophy, Canavan disease vs., **831**
Mesenchymal tumors
- benign, **1176–1179**
- malignant, **1180–1183**
Mesial temporal sclerosis, **924–927**
- differential diagnosis, **925–926**
Metabolic disorders
- acquired
  overview, **858–861**
- Fabry disease, **808–809**

https://CafePezeshki.IR

- gangliosidosis, **796–799**
- glutaric aciduria type 1, **826–829**
  genetics, **827–828**
- hepatic encephalopathy, **884–887**
  differential diagnosis, **885–886**
- Huntington disease, **848–851**
- inherited
  overview, **774–777**
- Kearns-Sayre syndrome, **790–791**
  differential diagnosis, **791**
  MELAS vs., **787**
  PKAN vs., **845**
- kernicterus, **868–869**
- Krabbe disease, **804–807**
- maple syrup urine disease, **820–823**
- megalencephaly with leukoencephalopathy and cysts, **838–841**
- metachromatic leukodystrophy, **800–803**
- mucopolysaccharidoses, **792–795**
- neurodegeneration with brain iron accumulation (NBIA), **842–843**
- organic/aminoacidopathies, miscellaneous, **836–837**
- osmotic demyelination syndrome vs., **913–914**
- pantothenate kinase-associated neurodegeneration, Huntington disease vs., **849**
- parathyroid disorders, **874–875**
- PKAN, **844–847**
  genetics, **845–846**
- thyroid disorders, **870–873**
- urea cycle disorders, **824–825**
- X-linked adrenoleukodystrophy, **812–815**
  differential diagnosis, **813**
  megalencephaly with leukoencephalopathy and cysts vs., **839**
  Wallerian degeneration vs., **978**
- Zellweger syndrome spectrum, **810–811**

Metabolic encephalopathy, post-traumatic brain swelling vs., **198**
Metastasis (metastatic disease)
- cerebellopontine angle-internal auditory canal, **1098–1101**
  diagnostic checklist, **1100**
  differential diagnosis, **1099**
  vestibular schwannoma vs., **1091**
- intracranial, miscellaneous, **594–595**
- meningeal
  differential diagnosis, **1195–1196**
  Lhermitte-Duclos disease vs., **119**
- neuroblastoma, **548–551**
  differential diagnosis, **549–550**
- parenchymal, **590–593**
  differential diagnosis, **591–592**
- rosette-forming glioneuronal tumor vs., **523**
- skull, **1194–1197**
  differential diagnosis, **1195–1196**
- vascular, von Hippel-Lindau syndrome vs., **93**

Metastatic intracranial lymphoma, **596–597**
Methanol poisoning, **908–909**
Microangiopathy
- HIV-associated mineralizing calcific, Fabry disease vs., **809**

Microcephaly, **56–59**
Mikulicz disease. *See* IgG4-related disease.
Missile and penetrating injury, **144–147**
Mitochondrial myopathy, encephalopathy, lactic acidosis, and stroke-like episodes. *See* MELAS.
Mixed glial-neuronal neoplasm. *See* Dysembryoplastic neuroepithelial tumor (DNET).
Mixed neuronal-glial tumors, **430–431**
Molar tooth malformations (Joubert), **36–39**
- Dandy-Walker continuum vs., **28**

Moyamoya, **294–297**
Mucopolysaccharidoses, **792–795**
Multi-infarct dementia
- alcoholic encephalopathy vs., **881**
- chronic hypertensive encephalopathy vs., **893**
- Creutzfeldt-Jakob disease vs., **953**
- intravascular (angiocentric) lymphoma vs., **571**
- normal pressure hydrocephalus vs., **1011**

Multiple hamartoma syndrome. *See* Lhermitte-Duclos disease.
Multiple sclerosis, **756–759**
Multiple system atrophy, **960–963**
Muscular dystrophy, congenital, **60–63**
- merosin-deficiency, Canavan disease vs., **831**

Myeloma, **1190–1193**
Myoclonic epilepsy with ragged-red fibers (MERRF), MELAS vs., **787**

N

Neoplasms, **430–433**
- classification, **430–431**
- grading, **430–431**
- low-grade, cerebral contusion vs., **173**
- underlying, spontaneous nontraumatic intracranial hemorrhage vs., **259–260**

Neurenteric cyst, **650–651**
- arachnoid cyst of cerebellopontine angle-internal auditory canal vs., **1079**

Neuro-Behçet disease. *See* Behçet disease.
Neuroblastoma
- metastatic, **548–551**
  differential diagnosis, **549–550**

Neurocutaneous melanosis, **122–125**
Neurocutaneous syndromes, Sturge-Weber syndrome vs., **101–102**
Neurocysticercosis, **716–719**
- differential diagnosis, **717–718**
- ganglioglioma vs., **503–504**

Neurocytoma
- central, **514–517**
- extraventricular, **518–519**

Neurodegeneration with brain iron accumulation (NBIA), **842–843**
- type 1. *See* Pantothenate kinase-associated neurodegeneration (PKAN).

https://CafePezeshki.IR

Neurofibroma (NF), **556–557**
Neurofibromatosis type 1, **84–87**
- Li-Fraumeni syndrome vs., **129**
Neurofibromatosis type 2, **88–91**
- differential diagnosis, **89–90**
Neuroglial cyst, **624–625**
Neuromyelitis optica, **760–763**
Neuronal tumors, **430–431**
Neurosarcoid, **1156–1159**
- IgG4-related disease vs., **1137**
Neurosarcoidosis
- tuberculosis vs., **713–714**
Non-Hodgkin lymphoma, meningeal, intracranial idiopathic inflammatory pseudotumor vs., **1133**
Nonneoplastic tumor-associated cysts, **652–653**
- differential diagnosis, **653**

O

Odontoid fractures, **135–136**
Oligodendroglioma, **468–471**
- anaplastic, **472–475**
  differential diagnosis, **473–474**
- differential diagnosis, **469–470**
- low-grade diffuse astrocytoma vs., **435**
Olivary degeneration, hypertrophic, **982–985**
Ophthalmoplegia, chronic progressive external , Kearns-Sayre syndrome vs., **791**
Optic-infundibular dysplasia, septooptic dysplasia vs., **53**
Optic nerve atrophy, idiopathic or post-inflammatory, intracranial hypertension vs., **897**
Ormond disease. *See* IgG4-related disease.
Osler-Weber-Rendu syndrome. *See* Hemorrhagic telangiectasia, hereditary.
Osmotic demyelination syndrome, **912–915**
- differential diagnosis, **913–914**
Oxygen, high-inspired, traumatic subarachnoid hemorrhage vs., **169**

P

Pachygyria-agyria complex. *See* Lissencephaly.
Pachymeningopathies (thickened dura)
- chronic subdural hematoma vs., **165–166**
- subacute subdural hematoma vs., **161–162**
Paget disease, **1142–1145**
- differential diagnosis, **1143–1144**
Palsy
- Bell palsy, **1082–1085**
- progressive supranuclear, **968–971**
  differential diagnosis, **969–970**
Panencephalitis, subacute sclerosing, **710–711**
Pantothenate kinase-associated neurodegeneration (PKAN), **844–847**. *See also* Neurodegeneration with brain iron accumulation (NBIA).
- diagnostic checklist, **846**
- differential diagnosis, **845**
- genetics, **845–846**
- Huntington disease vs., **849**
Papillary tumor of pineal region (PTPR), **534–535**
Paraneoplastic syndromes (PS), **598–601**
Parasitic infections
- miscellaneous, **726–729**
  differential diagnosis, **727–728**
Parathyroid disorders, **874–875**
Parenchymal hypodensity, acute cerebral ischemia-infarction vs., **356**
Parkinson disease, **956–959**
- progressive supranuclear palsy vs., **969–970**
Parkinson-plus syndromes, multiple system atrophy vs., **962**
Parkinsonism-dementia-amyotrophic lateral sclerosis complex, Parkinson disease vs., **958**
Pearson marrow-pancreas syndrome, Kearns-Sayre syndrome vs., **791**
Pediatric human immunodeficiency virus-1 infection. *See* HIV infections, congenital.
Pelizaeus-Merzbacher disease
- Canavan disease vs., **831**
- hypomyelination vs., **779**
- metachromatic leukodystrophy vs., **801**
Penetrating injury, **144–147**
Perimesencephalic nonaneurysmal subarachnoid hemorrhage, **224–225**
Peritumoral cyst. *See* Nonneoplastic tumor-associated cysts.
Perivascular spaces
- enlarged, **632–635**
  nonneoplastic tumor-associated cyst vs., **653**
Periventricular cyst, **626–629**
Periventricular halo, normal, white matter injury of prematurity vs., **333–334**
Peroxisomal disorders, **816–819**
PHACES, Sturge-Weber syndrome vs., **102**
Pilomyxoid astrocytoma (PMA), **456–459**
- staging, grading, and classification, **457–458**
Pineal cyst, **636–639**
Pineal parenchymal tumor of intermediate differentiation (PPTID), **528–529**
Pineal region papillary tumor, **534–535**
Pineoblastoma, **530–533**
- differential diagnosis, **531–532**
Pineocytoma, **524–527**
Pituicytoma, **1052–1053**
Pituitary apoplexy, **1044–1047**
- differential diagnosis, **1045–1046**
Pituitary gland
- abscess, pituitary apoplexy vs., **1045–1046**
- anomalies, **1024–1027**
- overview, **1020–1023**
Pituitary hyperplasia, **1060–1061**
Pituitary macroadenoma, **1040–1043**
- differential diagnosis, **1041–1042**
Pituitary microadenoma, **1036–1039**
PKAN. *See* Pantothenate kinase-associated neurodegeneration (PKAN).
Pneumocephalus, **184–187**

https://CafePezeshki.IR

Polymicrogyria, **68–71**
- bilateral perisylvian syntelencephaly vs., **49–50**
- differential diagnosis, **69–70**
- Taylor-type, tuberous sclerosis complex vs., **97**

Porencephalic cyst, **646–649**
Posterior fossa arachnoid cyst, Dandy-Walker continuum vs., **27–28**
Pressure-related edema, post-traumatic brain swelling vs., **198**
Primary cholesteatoma. *See* Cerebellopontine angle-internal auditory canal, epidermoid cyst.
Primitive neuroectodermal tumor-medulloblastoma (PNET-MB). *See* Medulloblastoma.
Primitive neuroectodermal tumor (PNET)
- supratentorial, **540–543**

Progressive multifocal leukoencephalopathy (PML), **748–749**
Pseudo-TORCH infections
- metachromatic leukodystrophy vs., **801**
- Zellweger syndrome spectrum vs., **811**

Pseudo-TORCH syndromes
- congenital cytomegalovirus infection vs., **663**
- TORCH infections vs., **659**

Pseudoaneurysm, **236–237**
- non-ASVD fusiform aneurysm vs., **243**

Pseudoprogression, **920–921**
Pseudoresponse, **922–923**
Pseudotumor, inflammatory, idiopathic
- IgG4-related disease vs., **1137**
- intracranial, **1132–1135**
- meningioma, cerebellopontine angle-internal auditory canal vs., **1095**

R

Radiation-induced injury, **916–919**
- diagnostic checklist, **918**
- differential diagnosis, **917–918**
- staging, grading, and classification, **918**

Ramsay Hunt syndrome
- cerebellopontine angle-internal auditory canal, metastases vs., **1099**

Rasmussen encephalitis, **706–709**
Rathke cleft cyst, **1032–1035**
Rendu-Osler syndrome. *See* Hemorrhagic telangiectasia, hereditary.
Rendu-Osler-Weber syndrome. *See* Hemorrhagic telangiectasia, hereditary.
Reversible cerebral vasoconstriction syndrome, **306–307**
Rhabdoid brain tumor. *See* Teratoid-rhabdoid tumor, atypical.
Rhombencephalosynapsis, **30–33**
Rickettsial diseases, **734–735**
Rosai-Dorfman disease, **1161**
Rosette-forming glioneuronal tumor (RGNT), **522–523**
- diagnostic checklist, **523**
- differential diagnosis, **523**
- staging, grading, and classification, **523**

S

Saccular aneurysm, **232–235**
- atypical, non-ASVD fusiform aneurysm vs., **243**
- blood blister-like aneurysm vs., **245**
- differential diagnosis, **233–234**

Sarcoidosis
- cerebellopontine angle-internal auditory canal meningioma vs., **1095**
  - metastases vs., **1099**

Sarcoma
- atypical teratoid-rhabdoid tumor vs., **545**
- gliosarcoma, **446–447**

Scalp
- overview, **1104–1107**
- sebaceous cyst, **1164–1165**

Scalp injuries, **140–143**
Schizencephaly, **76–79**
- "closed-lip," heterotopic gray matter vs., **65**
- severe bilateral open-lip, hydranencephaly vs., **331**

Schwannoma
- nonneoplastic tumor-associated cyst vs., **653**
- nonvestibular, **552–555**
- vestibular, **1090–1093**
  - cystic, arachnoid cyst of cerebellopontine angle-internal auditory canal vs., **1079**
  - meningioma, CPA-IAC vs., **1095**

Schwannomatosis, **130–131**
Sebaceous cyst, **1164–1165**
Second impact syndrome, **206–207**
Sella, empty, **1056–1059**
- differential diagnosis, **1057–1058**

Sella turcica, overview, **1020–1023**
Septooptic dysplasia, **52–55**
Septooptic-pituitary dysgenesis. *See* Septooptic dysplasia.
Shunts
- cerebrospinal fluid shunts and complications, **1014–1017**

Sickle cell disease of brain, **290–293**
Siderosis, superficial, **228–231**
Sigmoid sinus pseudolesion
- sinus-jugular foramen, dural arteriovenous fistula vs., **401**

Sinus pericranii, **416–419**
Skull
- craniostenoses, **1112–1115**
- extramedullary hematopoiesis, **1146–1149**
- fibrous dysplasia, **1138–1141**
  - staging, grading, and classification, **1139–1140**
- intracranial hypotension, **1128–1131**
  - differential diagnosis, **1129–1130**
- lacunar skull of newborn, congenital calvarial defects vs., **1109–1110**
- Langerhans cell histiocytosis, **1152–1155**
  - differential diagnosis, **1153–1154**
- leptomeningeal cyst ("growing fracture"), **1126–1127**
- metastases, **1194–1197**
- overview, **1104–1107**

https://CafePezeshki.IR

- Paget disease, **1142–1145**
  differential diagnosis, **1143–1144**
- thick, **1150–1151**
Skull base
- pseudotumor, inflammatory, intracranial idiopathic, **1132–1135**
Skull injuries, **140–143**
Spine and cord trauma, **135–136**
Status epilepticus, **928–931**
- differential diagnosis, **929–930**
- human herpes virus 6 (HHV-6) encephalitis vs., **703**
- low-grade diffuse astrocytoma vs., **436**
Steele-Richardson-Olszewski syndrome. *See* Supranuclear palsy, progressive.
Steroid-responsive encephalopathy associated with autoimmune thyroiditis (SREAT). *See* Thyroid disorders.
Streptococcal meningitis, group B, **670–673**
Stroke, **248–253**
- aberrant internal carotid artery, **284–287**
  differential diagnosis, **285–286**
- antiphospholipid antibody syndrome
  non-SLE, systemic lupus erythematosus vs., **313**
- Behçet disease, **324–325**
- cerebellar hemorrhage, remote, **266–267**
- cerebral hemiatrophy, **352–353**
- cerebral hyperperfusion syndrome, **372–375**
  differential diagnosis, **373–374**
- cerebral ischemia-infarction. *See* Cerebral ischemia-infarction, acute.
- childhood, **348–351**
- cortical venous thrombosis, **380–383**
- deep cerebral venous thrombosis, **384–387**
  differential diagnosis, **385–386**
- dural sinus and aberrant arachnoid granulations, **388–391**
- fibromuscular dysplasia, **328–329**
- germinal matrix hemorrhage, **268–271**
- hydranencephaly, **330–331**
- imaging, approach to, **248–249**
- lacunar infarction, **368–371**
- moyamoya, **294–297**
- persistent carotid basilar anastomoses, **288–289**
- reversible cerebral vasoconstriction, **306–307**
- sickle cell disease of brain, **290–293**
- systemic lupus erythematosus, **312–315**
  differential diagnosis, **313–314**
- traumatic. *See* Cerebral ischemia-infarction, traumatic.
- white matter injury of prematurity, **332–335**
  differential diagnosis, **333–334**
Sturge-Weber-Dimitri syndrome. *See* Sturge-Weber syndrome.
Sturge-Weber syndrome, **100–103**
- cerebral hemiatrophy vs., **353**
- choroid plexus cyst vs., **641**
- developmental venous anomaly vs., **411–412**
- diagnostic checklist, **102**
- differential diagnosis, **101–102**
- encephalocraniocutaneous lipomatosis vs., **115**
- meningioangiomatosis vs., **105**
- Rasmussen encephalitis vs., **707**
- staging, grading, and classification, **102**
Subarachnoid hemorrhage, **218–219**
- aneurysmal, **220–223**
  differential diagnosis, **221–222**
- convexal, **226–227**
- perimesencephalic nonaneurysmal, **224–225**
- "pseudo-SAH," aneurysmal subarachnoid hemorrhage vs., **222**
- traumatic, **168–171**
Subarachnoid spaces
- enlarged, **996–999**
Subcortical arteriosclerotic encephalopathy, normal pressure hydrocephalus vs., **1011–1012**
Subcortical injury, **180–183**
Subdural hematoma
- acute, **156–159**
  differential diagnosis, **157–158**
- chronic, **164–167**
  differential diagnosis, **165–166**
- subacute, **160–163**
  differential diagnosis, **161–162**
Subependymal giant cell astrocytoma, **464–467**
Subependymal heterotopia, X-linked, tuberous sclerosis complex vs., **97**
Subependymoma, **490–493**
Supranuclear palsy, progressive, **968–971**
- differential diagnosis, **969–970**
Susac syndrome, **326–327**
Syntelencephaly (middle interhemispheric variant), **48–51**
- differential diagnosis, **49–50**
Systemic lupus erythematosus, **312–315**
- differential diagnosis, **313–314**

T

Tay-Sachs (TS) disease. *See* Gangliosidosis.
Telangiectasia
- capillary, **424–427**
  differential diagnosis, **425–426**
- hereditary hemorrhagic, **110–113**
Temporal bone (T-bone) fractures, **135**
Teratoid-rhabdoid tumor, atypical, **544–547**
- astroblastoma vs., **477**
- choroid plexus carcinoma vs., **499–500**
- diagnostic checklist, **546**
- differential diagnosis, **545**
- infratentorial ependymoma vs., **483**
- medulloblastoma vs., **537**
- staging, grading, and classification, **546**
- supratentorial ependymoma vs., **487**
- supratentorial PNET vs., **541**
- teratoma vs., **583**
Teratoma, **582–585**
- atypical teratoid-rhabdoid tumor vs., **545**
- lipoma vs., **23–24**
Thick skull, **1150–1151**
Thyroid disorders, **870–873**
Tolosa-Hunt syndrome. *See* Inflammatory pseudotumor, intracranial idiopathic.
TORCH infections, **658–661**

https://CafePezeshki.IR

Toxic disorders
- acquired
  overview, **858–861**
- alcoholic encephalopathy, **880–883**
  differential diagnosis, **881–882**
- cyanide poisoning, **910–911**
- methanol poisoning, **908–909**

Toxoplasmosis
- acquired, **742–743**

Transient global amnesia (TGA), **932–933**
Transient seizure-related MR changes. *See* Status epilepticus.
Transverse-sigmoid sinus pseudolesion, dural sinus and aberrant arachnoid granulations vs., **389**
Trauma, **134–139**
- brain death, **204–205**
- cerebral contusion, **172–175**
- cerebral ischemia/infarction, traumatic, **200–203**
- chronic encephalopathy, **214–215**
- diffuse axonal injury, **176–179**
- epidural hematoma, classic, **148–151**
  differential diagnosis, **149–150**
- epidural hematoma, variant, **152–155**
- intracranial arterial dissection, **208–211**
- intracranial herniation syndromes, **192–195**
- missile and penetrating injury, **144–147**
- second impact syndrome, **206–207**

Trigeminal neuralgia, **1086–1087**
Tuber cinereum hamartoma, **1028–1031**
Tuberculosis, **712–715**
- differential diagnosis, **713–714**

Tuberous sclerosis complex, **96–99**
- Lhermitte-Duclos disease vs., **119**
- Li-Fraumeni syndrome vs., **129**

Tumor-associated arachnoid cyst. *See* Nonneoplastic tumor-associated cysts.
Tumor-associated enlarged perivascular spaces. *See* Nonneoplastic tumor-associated cysts.
Tumors, low-attenuation, chronic cerebral infarction vs., **363**
Turcot syndrome, Li-Fraumeni syndrome vs., **129**

U

Urea cycle disorders, **824–825**

V

Vascular dementia, **942–945**
- differential diagnosis, **943–944**
- multi-infarct, traumatic cerebral ischemia/infarction vs., **201**

Vascular malformations
- capillary telangiectasia, **424–427**
  differential diagnosis, **425–426**
- overview, **394–395**
- sinus pericranii, **416–419**
- vein of Galen aneurysmal malformation, **406–409**

Vascular metastasis, von Hippel-Lindau syndrome vs., **93**
Vascular neurocutaneous syndromes
- multiple AVMs in, von Hippel-Lindau syndrome vs., **93**

Vasculitis
- autoimmune-mediated
  acute disseminated encephalomyelitis vs., **765**
  multiple sclerosis vs., **757**
- Lhermitte-Duclos disease vs., **119**
- miscellaneous, **302–305**

Vasogenic edema. *See* Brain swelling, post-traumatic.
Vasospasm, **308–311**
- blood blister-like aneurysm vs., **245**
- subarachnoid hemorrhage-induced, traumatic cerebral ischemia/infarction vs., **201**

Vein of Galen aneurysmal malformation, **406–409**
Venous thrombosis
- deep cerebral, **384–387**
  differential diagnosis, **385–386**

Ventricles
- aqueductal stenosis, **1006–1009**
- chordoid glioma of third ventricle, **478–479**
- isolated 4th, Dandy-Walker continuum vs., **28**
- overview, **988–993**
- subarachnoid spaces
  enlarged, **996–999**

Ventriculitis, **686–687**
Vertebrobasilar dolichoectasia, **238–239**
- non-ASVD fusiform aneurysm vs., **243**

Vessel infundibulum
- blood blister-like aneurysm vs., **245**

Vestibular schwannoma, **1090–1093**
- cystic, arachnoid cyst of cerebellopontine angle-internal auditory canal vs., **1079**
- meningioma, CPA-IAC vs., **1095**

Vestigial carotid-basilar anastomoses. *See* Carotid basilar anastomoses, persistent.
Virchow-Robin spaces. *See* Perivascular spaces, enlarged.
von Hippel-Lindau syndrome, **92–95**
- diagnostic checklist, **94**
- differential diagnosis, **93**
- Li-Fraumeni syndrome vs., **129**
- staging, grading, and classification, **94**

W

Wallerian degeneration, **976–979**
- differential diagnosis, **977–978**

West Nile virus encephalitis, **700–701**
White matter
- age-related changes, arteriolosclerosis vs., **281**

White matter disease
- with lactate, X-linked adrenoleukodystrophy vs., **814**

White matter injury of prematurity, **332–335**
- differential diagnosis, **333–334**

Wilson disease, **852–855**
- Creutzfeldt-Jakob disease vs., **953**
- differential diagnosis, **853–854**

Wyburn-Mason syndrome
- hemangioblastoma vs., **559**
- Sturge-Weber syndrome vs., **102**

https://CafePezeshki.IR

X

Xanthoastrocytoma, pleomorphic, **460–463**
X-linked adrenoleukodystrophy, **812–815**
- diagnostic checklist, **814**
- differential diagnosis, **813**
- megalencephaly with leukoencephalopathy and cysts vs., **839**
- staging, grading, and classification, **814**
- Wallerian degeneration vs., **978**

X-linked dominant chondrodysplasia punctata, peroxisomal disorders vs., **817**
X-linked lissencephaly. *See* Lissencephaly.
X-linked subependymal heterotopia, tuberous sclerosis complex vs., **97**

Z

Zellweger syndrome spectrum, **810–811**

https://CafePezeshki.IR

This page intentionally left blank

https://CafePezeshki.IR

Expert CONSULT Built with inkling | E books

Any screen. Any time. Anywhere.

Activate the eBook version of this title at no additional charge.

Expert Consult eBooks give you the power to browse and find content, view enhanced images, share notes and highlights—both online and offline.

Unlock your eBook today.

1. Visit **expertconsult.inkling.com/redeem**
2. Scratch off your code
3. Type code into "Enter Code" box
4. Click "Redeem"
5. Log in or Sign up
6. Go to "My Library"

It's that easy!

Scan this QR code to redeem your eBook through your mobile device:

FPO:
Peel Off Sticker

For technical assistance:
email expertconsult.help@elsevier.com
call 1-800-401-9962 (inside the US)
call +1-314-447-8200 (outside the US)

ELSEVIER

Use of the current edition of the electronic version of this book (eBook) is subject to the terms of the nontransferable, limited license granted on expertconsult.inkling.com. Access to the eBook is limited to the first individual who redeems the PIN, located on the inside cover of this book, at expertconsult.inkling.com and may not be transferred to another party by resale, lending, or other means.

https://CafePezeshki.IR